ESTRO Course: TVD from Imaging to Margins – Lisbon 2017

Introduction: Rationale for Target Volume Delineation (TVD)

VINCENT KHOO

Royal Marsden Hospital & Institute of Cancer Research
St George's Hospital & University of London
ONJCC & Austin Health, University of Melbourne & Monash University

THE ROYAL MARSDEN

St George's Healthcare NHS Trust

Austin Health

ICR The Institute of Cancer Research

Aims

- To comprehend terminology: current & future
  - Common platforms, standardisation
- To understand the evidence base & rationale of disease to guide TVD in different cancer sites
  - The natural history & disease extent
  - The prognostic factors
- To appreciate imaging methodology & what imaging information is provided.
  - Multimodality and functional/ biological volumes
  - The limitations and caveats
- To understand how to use imaging for RTP & Delivery.
  - To understand temporal spatial variations
  - How to develop appropriate planning margins
  - Image guided strategies

THE ROYAL MARSDEN

Radiotherapy Technology Chain

Review

Diagnosis

Target Volume Determination

XRT QA

?The weakest link?

Staging

Verification

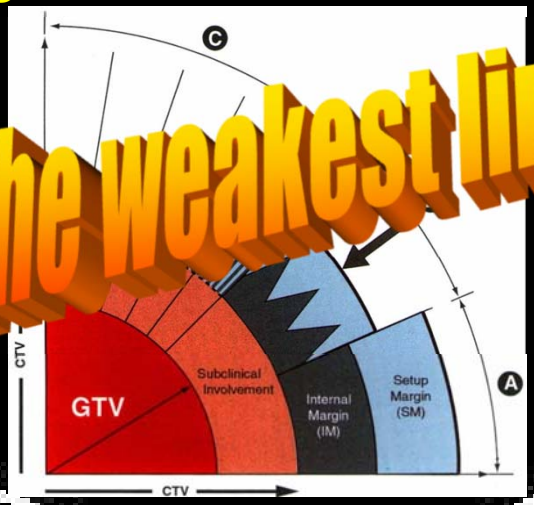

XRT Set-up & Simulation

XRT Delivery

MMI

RT Planning

TVD

THE ROYAL MARSDEN

Value of TVD

- TVD is the 'Basis' and 'Foundation' of RT

THE ROYAL MARSDEN

XRT: Therapeutic Ratio

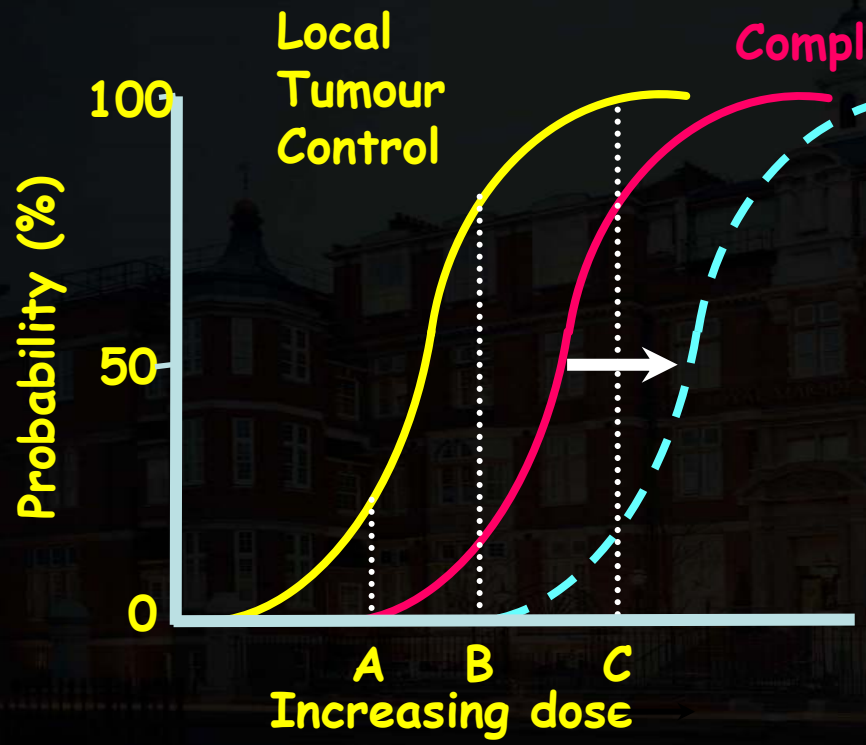

- VOI Definition
  - 3D Imaging
  - Functional
- XRT Techniques
  - CFRT / IMRT
  - Fractionation
  - Brachytherapy
  - Protons / Ions
- Localise & Verify
  - IGRT
  - ART
  - MRI-RT
- CMT
  - Radiosensitisers
  - Targeted Therapy
  - Immunotherapy

THE ROYAL MARSDEN

If you would understand anything,
observe its beginning
and its development…

Aristotle
(384 BC - 322 BC)

THE ROYAL MARSDEN

Historically

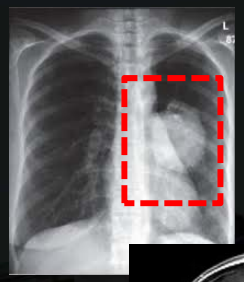

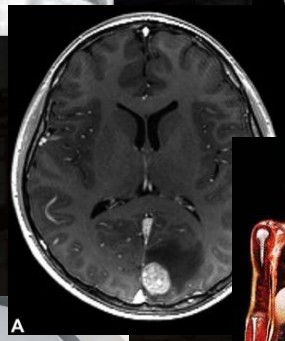



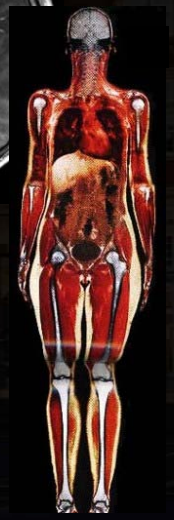

THE ROYAL MARSDEN

CT: The Early Years

1 Oct 1971:
EMI prototype



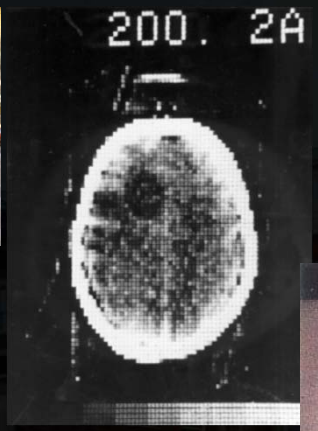

"I've had this before. First time lucky then everything else goes wrong after that……

Then they did the next 10 cases and every one of them came out as being obvious diseases of the brain……"

THE ROYAL MARSDEN

CT Impact: XRT

Table 2. Changes in treatment as a result of CT

	No. patients with CT induced changes /No. in group	% Patients with any change	Number of patients with change in: Treatment modality	Quality, number or angulation of fields	Field shape or size	Total dose
Thorax	7/16	44	1	3	4	0
Abdomen	12/14	86	1	4	7	2
Pelvis	18/41	44	2	2	16	1
Extremities	3/6	50	0	1	2	0
Total	40/77	52	4 (5%)	10 (13%)	29 (38%)	3 (4%)

Table 3. Analysis of inadequate tumor coverage

	Main field		Boost field	
	Miss	Marginal miss	Miss	Marginal miss
Thorax	3	1	1	1
Abdomen	2	0	6	0
Pelvis	3	2	10	4
Extremities	2	1	0	1
Total (% of 77 Patients)	10(13%)	4(5%)	17(22%)	6(8%)

THE ROYAL MARSDEN

Goitein et al IJROBP 1979

Understanding the Disease

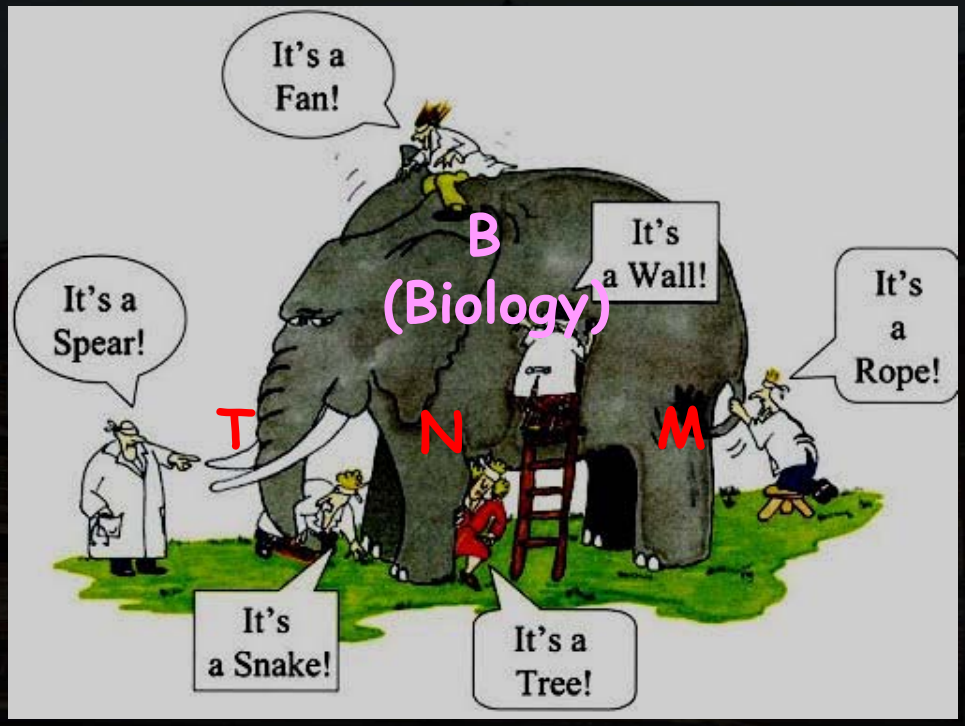

THE ROYAL MARSDEN

Imaging the Cancer Biology?

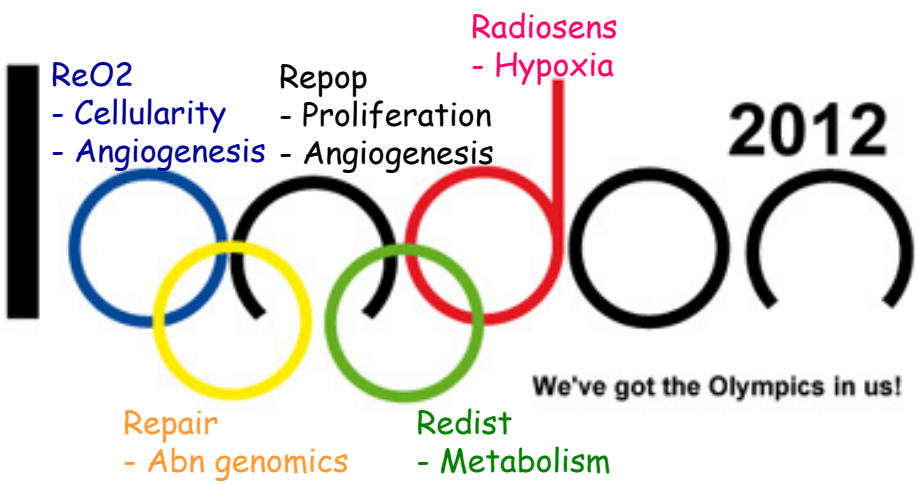

The 5 Rs in Radiotherapy Olympics

THE ROYAL MARSDEN

Functional Imaging: Rationale

- Defining the Cancer Biology
  - Tailored treatment strategy
    - RT: SIB, Dose painting or CMT
- Appreciating Patient Characteristics
  - Improved patient cohort selection
  - Reduced Intra- & Inter-Observer Variability
- Tumour / Tissue Characterisation
  - Functional parameters
    - Hypoxia, angiogenesis, metabolism, proliferation, cellularity, genomics
  - Qualitative & Quantitative
- Dynamic Assessments
- Response Evaluations

} ART

THE ROYAL MARSDEN

PET Impact: Staging & Management

Changes in XRT management (TVD, dose or therapy intent)

Diagnosis (Ca)	Case (N)	Mx Change (N)	Mx Change (%)
H & N	55	18	33
Gyn	28	9	32
Breast	28	7	25
Lung	26	8	31
Lymphoma	24	5	21
GI	18	4	22
Unknown Prim	4	3	75
Melanoma	2	1	50
Other Ca	17	0	0
Total	202	55	**27**

THE ROYAL MARSDEN

Dizendorf et al. J Nuc Med 2003

Understanding 'Change'



THE ROYAL MARSDEN

Intrinsic Anatomic Changes

Planning CT

During RT Course

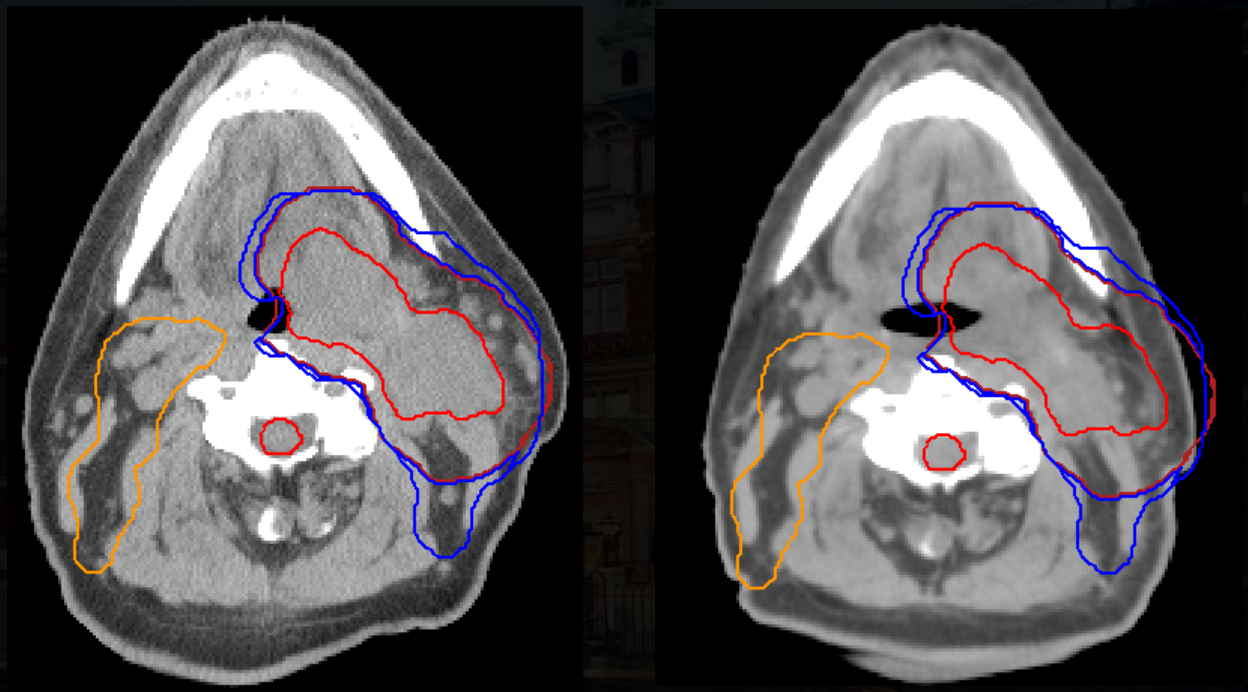

THE ROYAL MARSDEN

Courtesy D Schwartz, NY

H&N ChemoRT: GTV, LN & OARs

N=10 (sequential cases) + early interventional nutritional program (PEG)
Repeat 2nd IV contrast CT, PET & MRI scans @40-50Gy

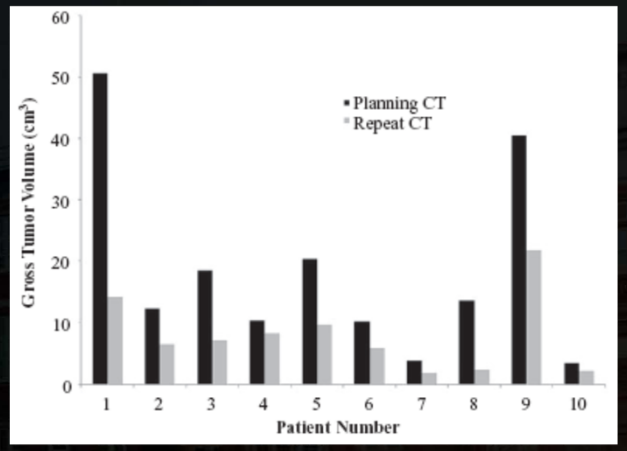

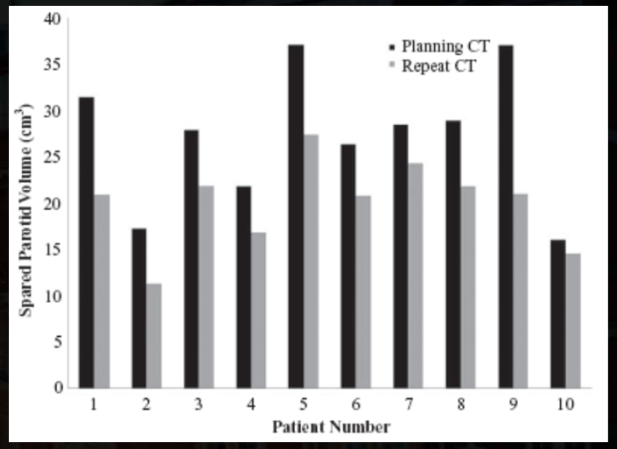

- GTV & LN reduced by 49.9% (21.3-82%)
- Spared and unspared Parotid volumes reduced by median of 23.5% and 20.5%

THE ROYAL MARSDEN

JARROC

Height et al, JMIRO 2010

Lung Cancer: External beam XRT

N = 10, NSCLC, MDACC (Orlando), Thompson CC (Knoxville)

Tomotherapy. MV-CT. Average 27 scans/pat (9-35 scans)

Median tumour size 20.1cc (5.9 - 737.2cc)

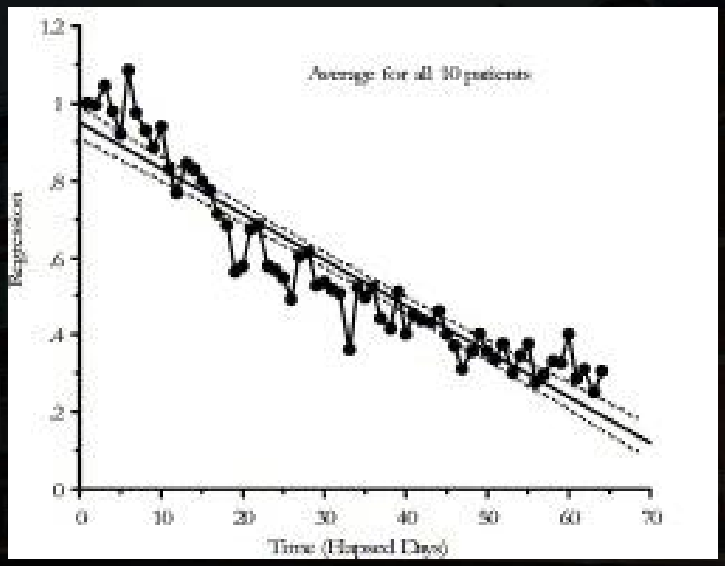

Average shrinkage
1.2% / day
(range 0.6-2.3%)

Kupelian et al IJROBP 2005

THE ROYAL MARSDEN

'Feedback Control Strategy'

Considerations for Clinical Implementation

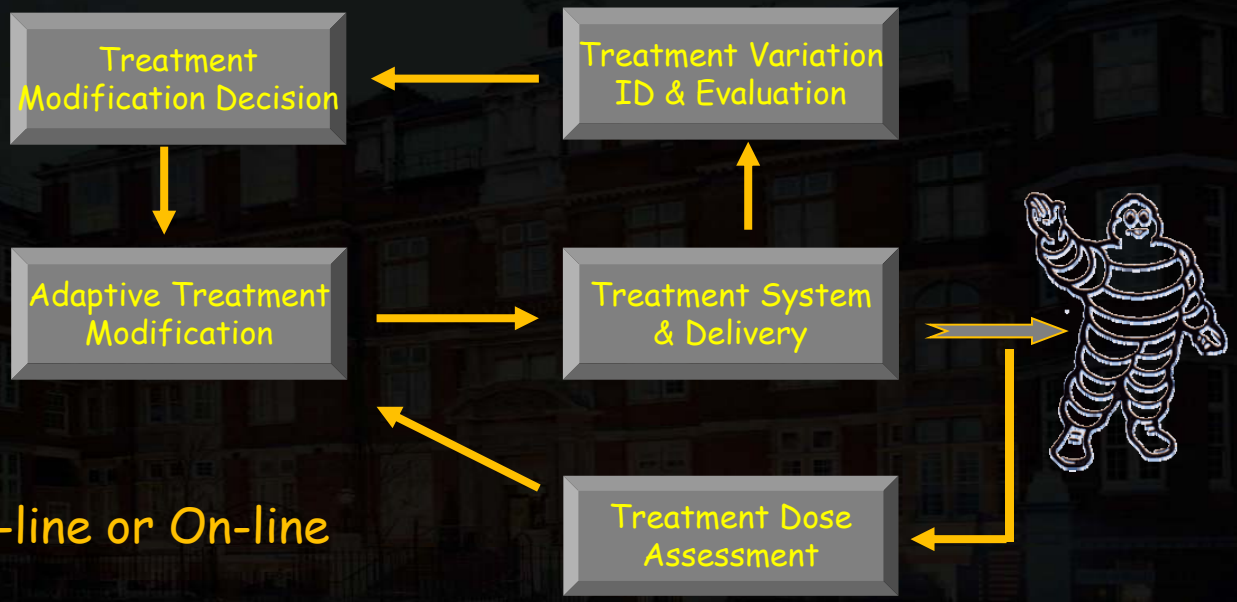

- Off-line or On-line
- Output: Correction of patient position or beam aperture, modification of margin or plan, reopt dose distribution (adaptive inverse optimisation)

THE ROYAL MARSDEN

Bladder XRT - Target Variation

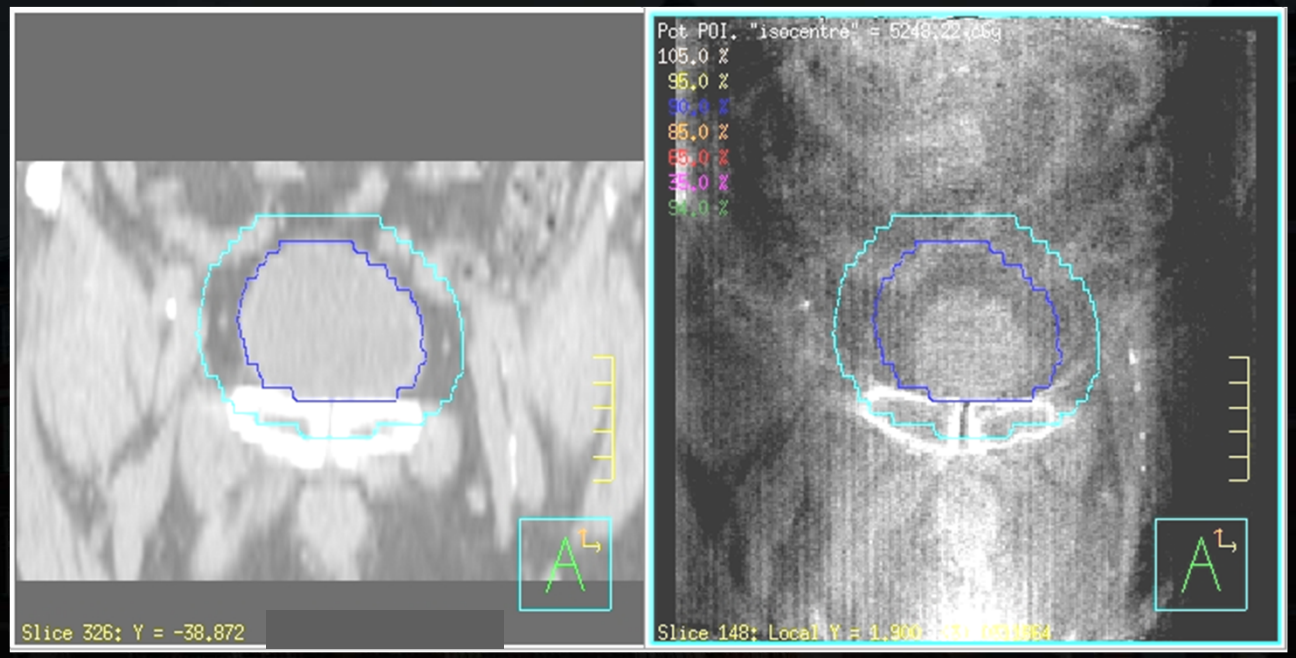

THE ROYAL MARSDEN

Bladder XRT: Inter-fraction Effects

- Sur 1993 [N=90, CTx1]
  - 17% > pCTV
- Turner 1997 [N=30, CTx4]
  - 33% > 1.5 cm
- Pos 2003 [N=17, CTx4]
  - 42% > pPTV
- Muren 2003 [N=20, CTx weekly]
  - 89% > pCTV
  - 40% > 15 mm

THE ROYAL MARSDEN

Bladder ART: Multiple scans for better m

RTP #1 #2 #3 Average

- 5 scans taken in the 1st week of RT
  - reduces Σ from 0.4 - 1.3cm (SD) to 0.2 - 0.6cm (SD)
- Choosing patients with small day to day variation (<1cm SD)
  - ART can further reduce SE to 0.1 - 0.3cm

THE ROYAL MARSDEN

Remeijer et al ESTRO 2003

Predictive Organ Localisation (POLO)

Reproducible relationship
between bladder position and volume/shape

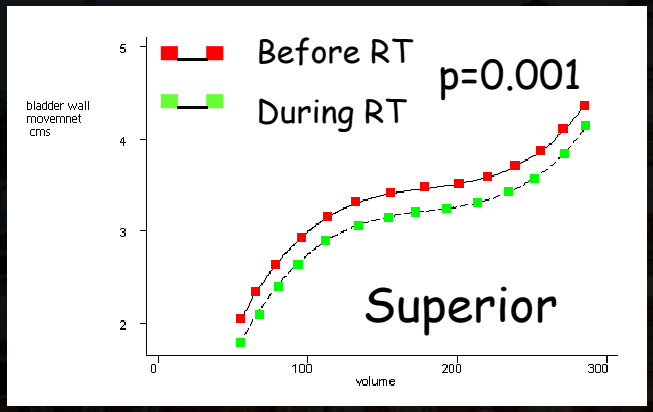

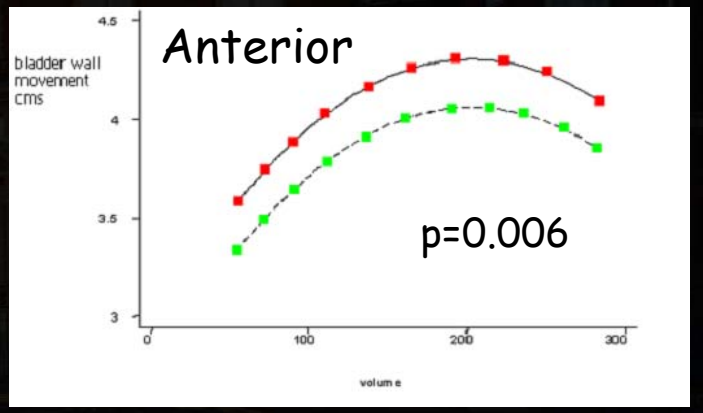

Mangar et al Radiother Oncol 2007

THE ROYAL MARSDEN

BC: IGRT Scheme: A-POLO

The individual filling patterns over time.

The change in bladder volume over 30 minutes is depicted.

Direction	Cranial	Caudal	Anterior	Posterior	Left	Right
Mean (mm)	9	0	8	2	2.6	2.4
Range (mm)	0 to 26	-5 to 5	0 to 16	-7 to 16	0 to 11	0 to 13

Bladder wall motion at planning scan (i.e.CT0 – CT30) associated with volume change.

THE ROYAL MARSDEN

Lalondrelle et al. IJROBP 2010

RMH Bladder IGRT: A-POLO Strategy

Modelling: Individual Intra-fractional 3D changes

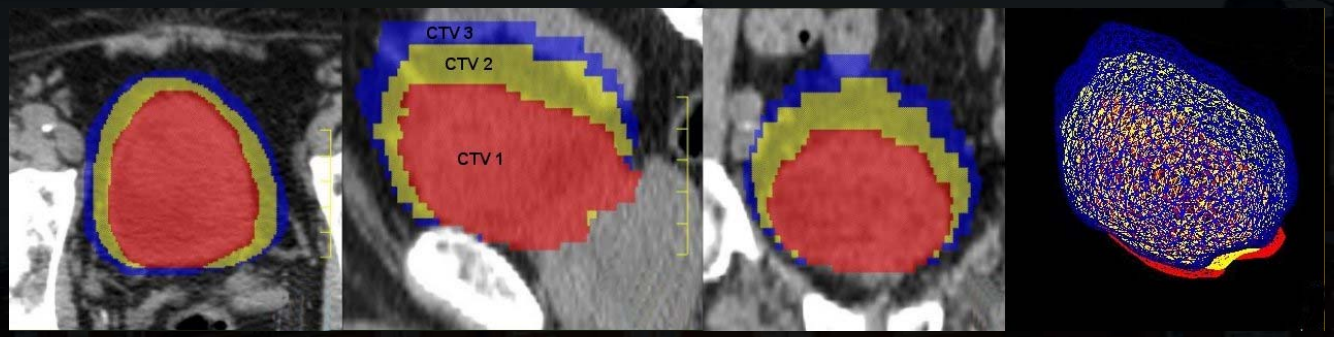

Library: Patient specific 3D PTV

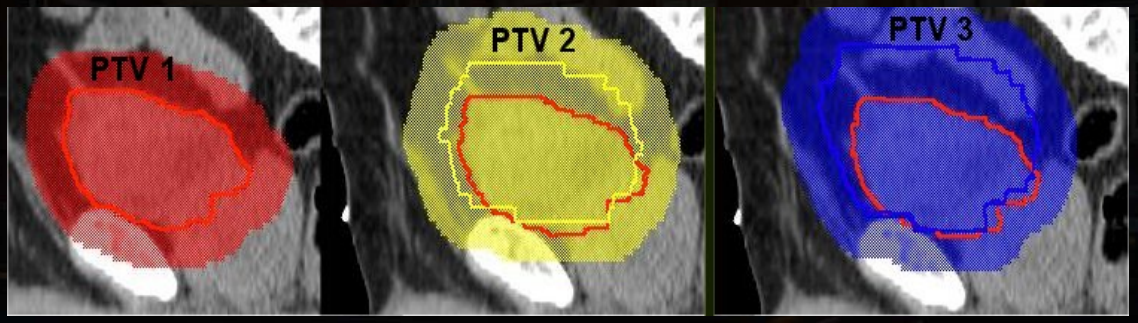

THE ROYAL MARSDEN

Lalondrelle et al. IJROBP 2010

BC: IGRT Scheme: A-POLO

Frequency and Size of Anistropic 'Plans of Day' used

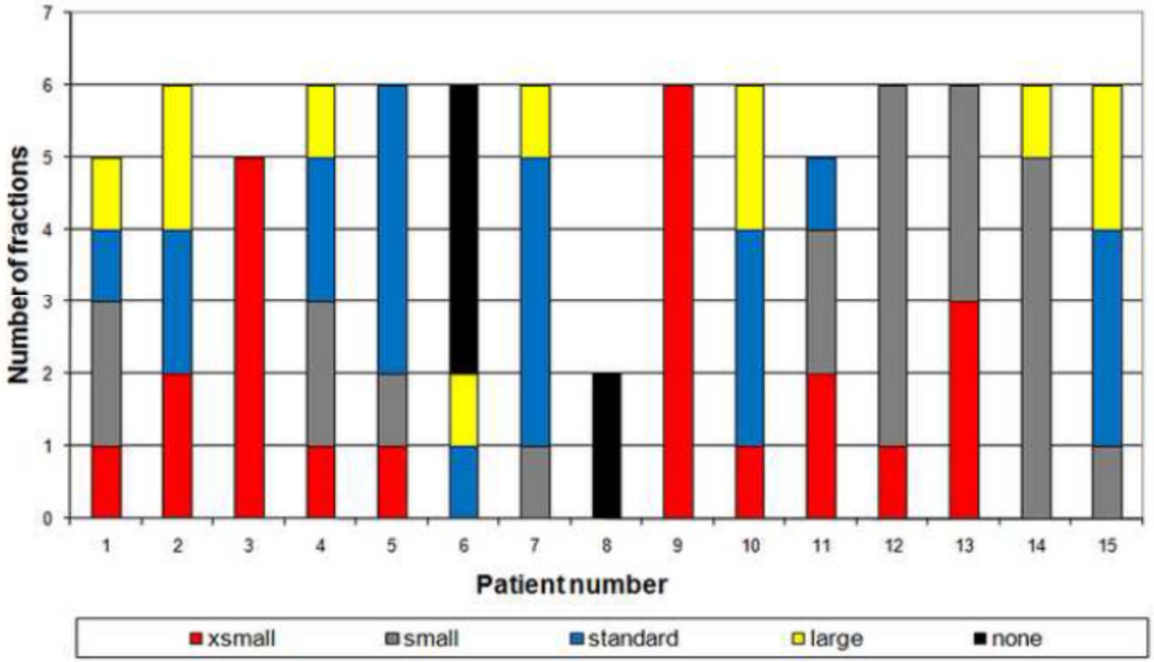

THE ROYAL MARSDEN

Lalondrelle et al. IJROBP 2010

PTV comparison using A-POLO

Mean A-POLO PTV as percentage of 1.5cm isotropic PTV

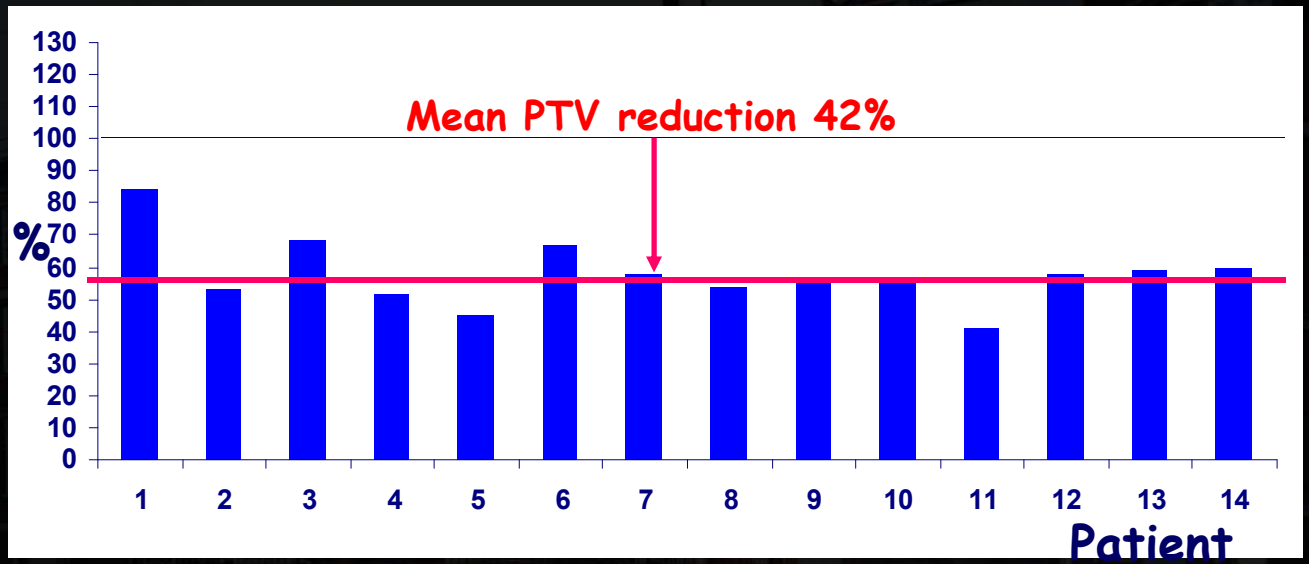

Assessed and delivered within 15 treatment slot

THE ROYAL MARSDEN

McDonald et al. Clin Onc 2013

THE ROYAL MARSDEN

Is Recurrence Important?

EBCTCG: Meta-analysis 10801 women (17 PRT)

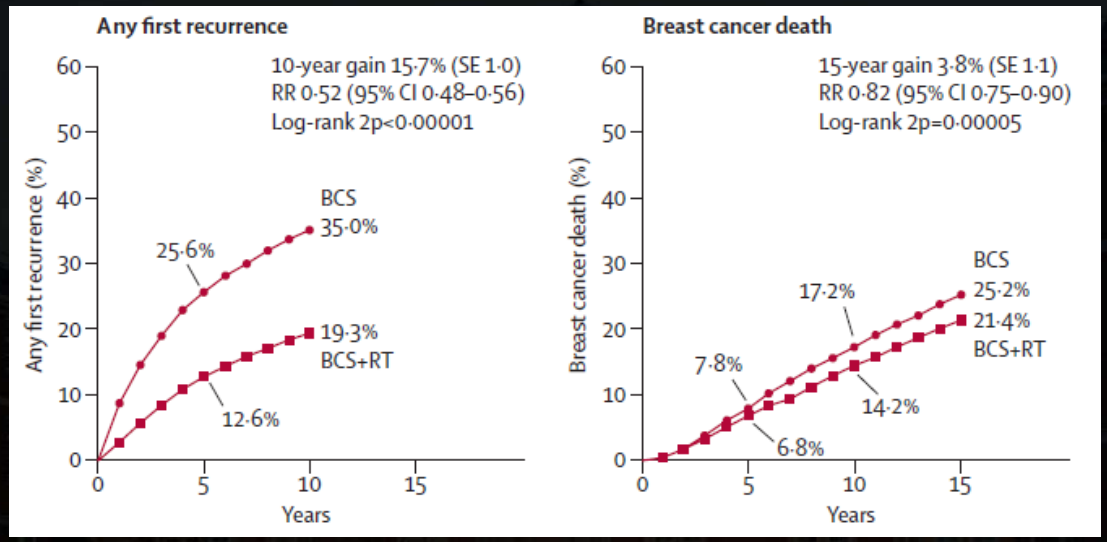

Interpretation After breast-conserving surgery, radiotherapy to the conserved breast halves the rate at which the disease recurs and reduces the breast cancer death rate by about a sixth. These proportional benefits vary little between different groups of women. By contrast, the absolute benefits from radiotherapy vary substantially according to the characteristics of the patient and they can be predicted at the time when treatment decisions need to be made.

THE ROYAL MARSDEN

EBCTCG Lancet 2011

Critical Impact of Radiotherapy Protocol Compliance and Quality in the Treatment of Advanced Head and Neck Cancer: Results From TROG 02.02

VOLUME 28 · NUMBER 18 · JUNE 20 2010
JOURNAL OF CLINICAL ONCOLOGY

Lester J. Peters, Brian O'Sullivan, Jordi Giralt, Thomas J. Fitzgerald, Andy Trotti, Jacques Bernier, Jean Bourhis, Kally Yuen, Richard Fisher, and Danny Rischin

Table 2. Results of Interventional and TMC Compliance Reviews

QARC Review Category	TMC Compliance Status			
	Compliant	Noncompliant	Not Evaluable	Total
No plan submitted	109	32	25	166
Modification(s) not required	402	81*	7	490
Modification(s) required and made	89	0	0	89
Modification(s) required and not made	12	95	1	108
Total	612	208	33	853

Abbreviations: TMC, Trial Management Committee; QARC, Quality Assurance Review Center.

*For 69 patients, incomplete plans were submitted initially and the deviations were introduced subsequent to QARC review.

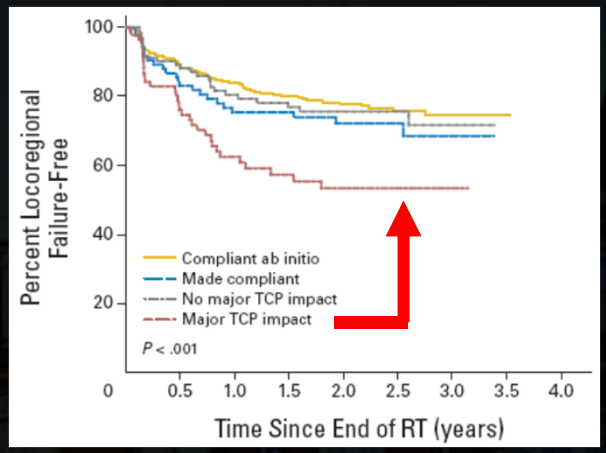

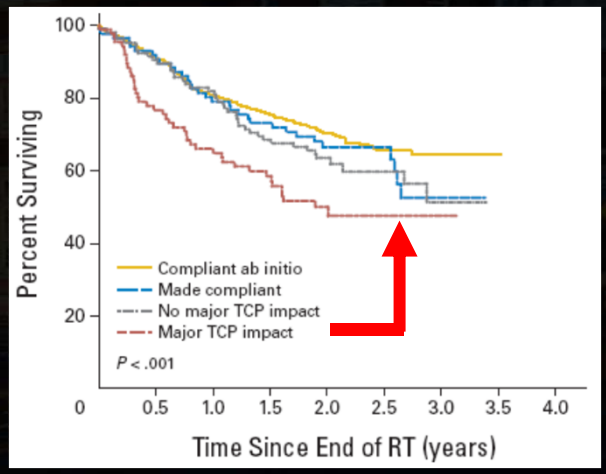

THE ROYAL MARSDEN



Thank you

THE ROYAL MARSDEN

ESTRO

School

WWW.ESTRO.ORG/SCHOOL

MRI including functional methods

Julien Dinkel

University Hospital of Munich

Department of Radiology

Germany

ESTRO School

Teaching points

To understand the basics in MRI (contrasts)

To know the methods for revealing physiological functions using MRI

- Perfusion
- Diffusion
- Tissue characterization - spectroscopy
- Motion

ESTRO School

Complexity of MRI

$$\omega = \gamma B_0$$

ω angular precessional frequency of proton

γ gyromagnetic ratio

B_0 strength of external magnetic field

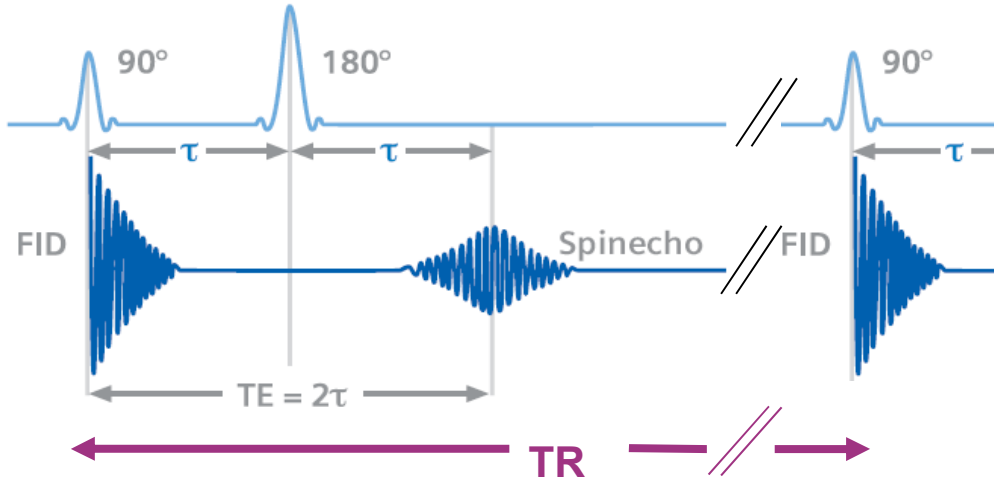

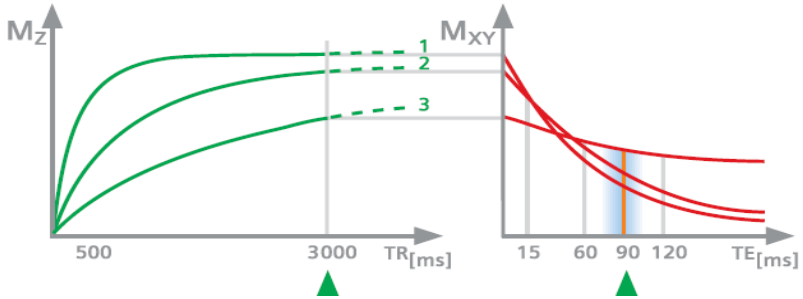

ESTRO School

MRI - basics

$$\omega = \gamma B_0$$

ω angular precessional frequency of proton

γ gyromagnetic ratio

B_0 strength of external magnetic field

- Certain atomic nuclei are able to absorb and emit radio frequency energy when placed in a magnetic field
- In MRI, hydrogen atoms are most-often used nuclei; they exist naturally in abundance, particularly in water and fat

ESTRO School

MRI – pulse sequence

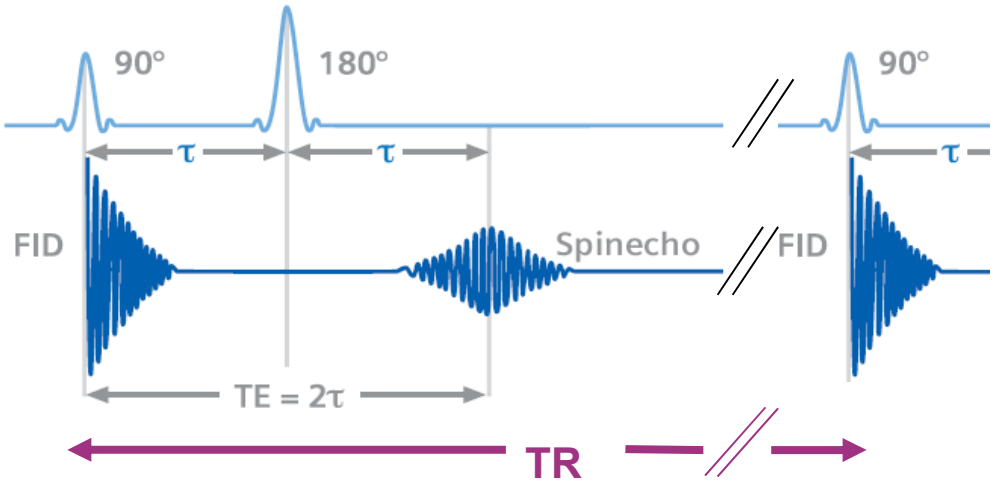

- Pulses of radio waves excite the nuclear spin of hydrogen protons
- Magnetic field gradients localize the signal in space

ESTRO School

MRI – relaxation of H atoms

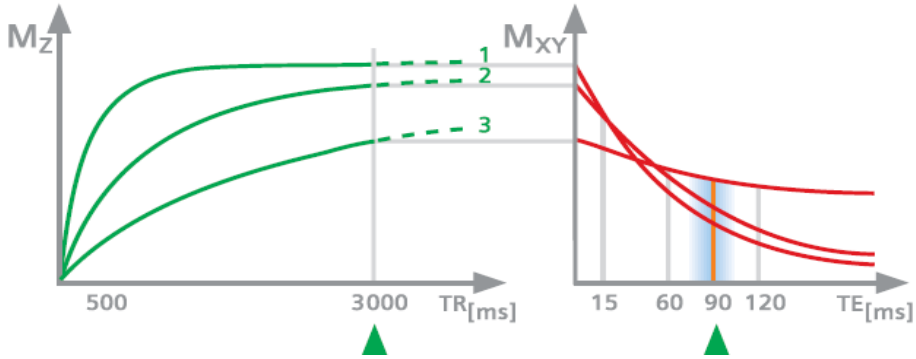

By varying the parameters of the pulse sequence, different contrasts may be generated between tissues based on the relaxation properties of the hydrogen atoms.

ESTRO School

Complexity of MRI

Do we need to understand the MR physic in order to use it?

ESTRO School

Complexity of the iPhone

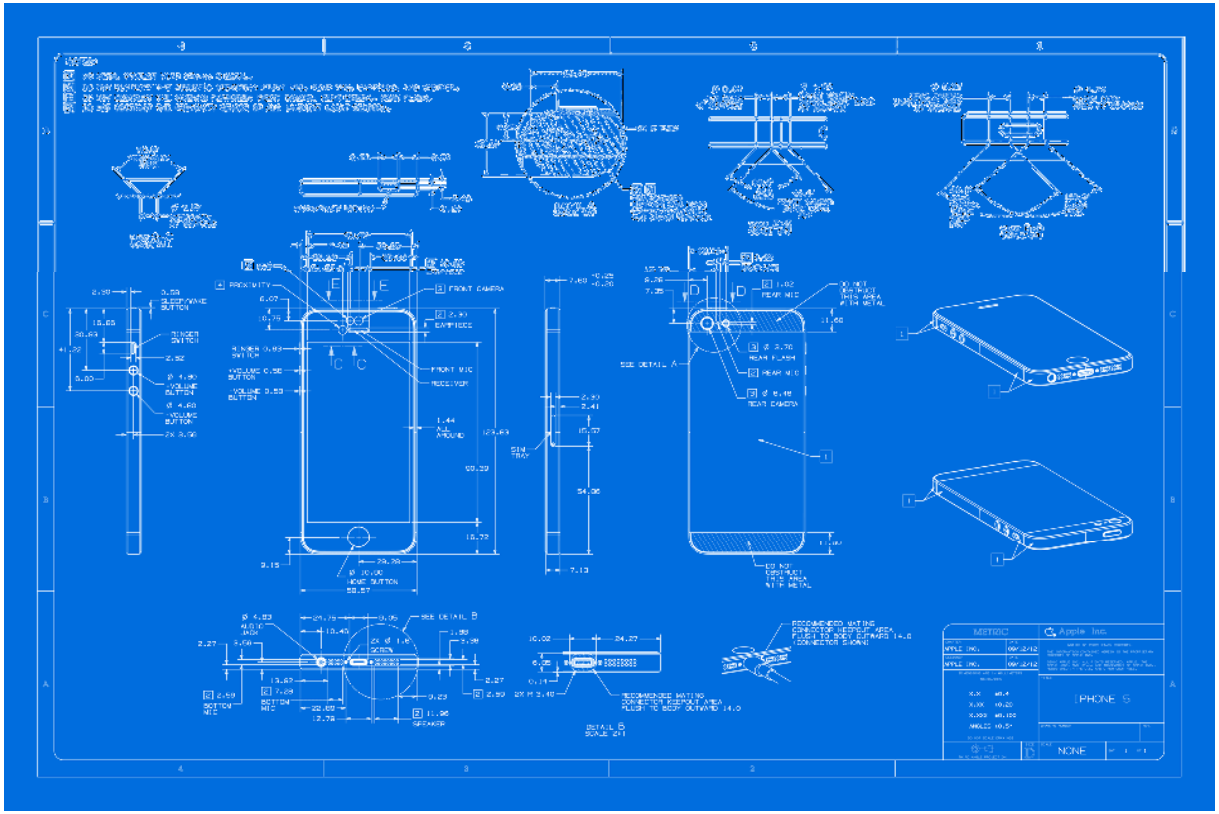

http://www.equipmentworld.com/the-iphone-5-blueprint/

ESTRO School

Do you read MRI?

ESTRO School

MRI contrasts

Warhol, Marilyn, 1960

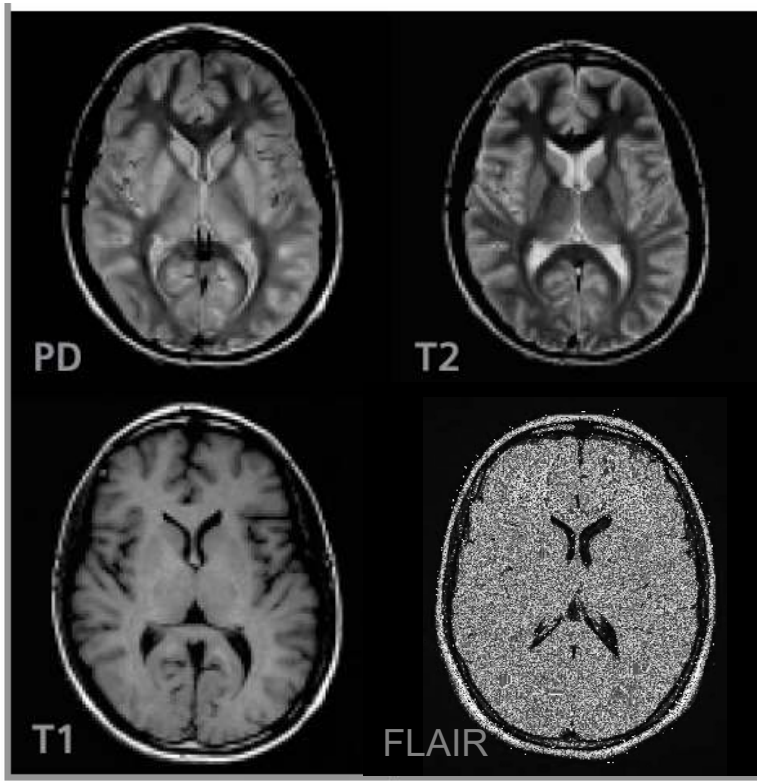

ESTRO School

MRI contrast agents

- MRI contrast agents shorten the relaxation times
- The most commonly used intravenous contrast agents are based on chelates of gadolinium
- Anaphylactoid reactions are rare, < 0.03%
- Risk of a rare but serious illness, nephrogenic systemic fibrosis, in patients with severe renal failure requiring dialysis
- Hepatobiliary contrast agent (gadoxetate) with dual excretion path

ESTRO School

MRI contrasts

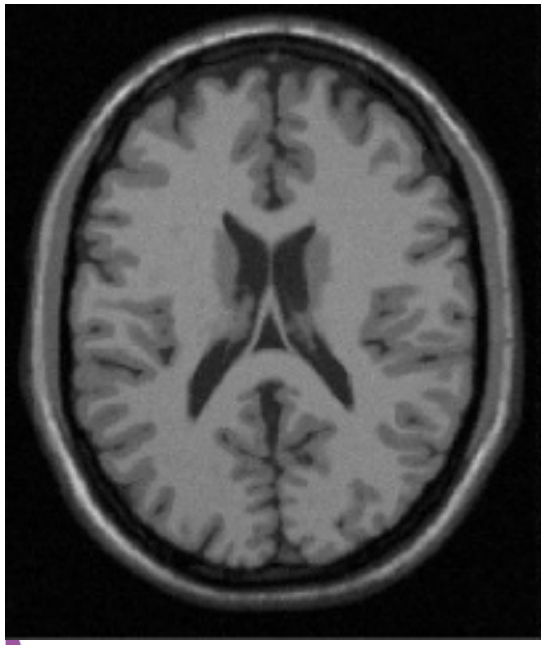

	T1	T2
CSF		
Gray matter		
White matter		
Edema /Tu		
Fat		
Contrast agent		

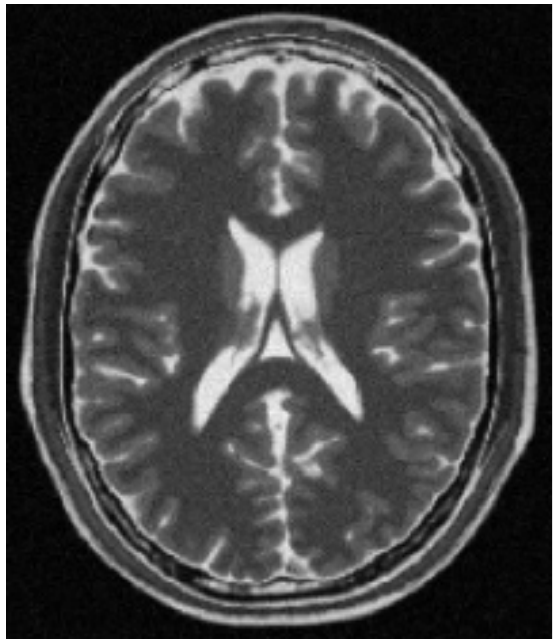

ESTRO School

MRI contrasts – ageing blood

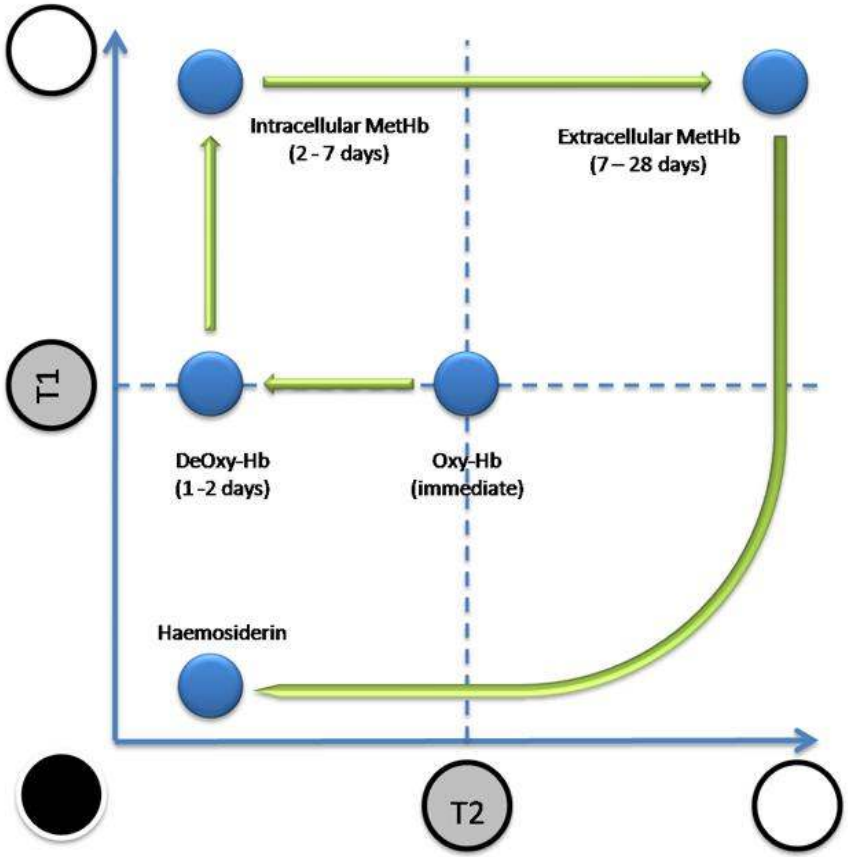

radiopedia

ESTRO School

MRI contrasts

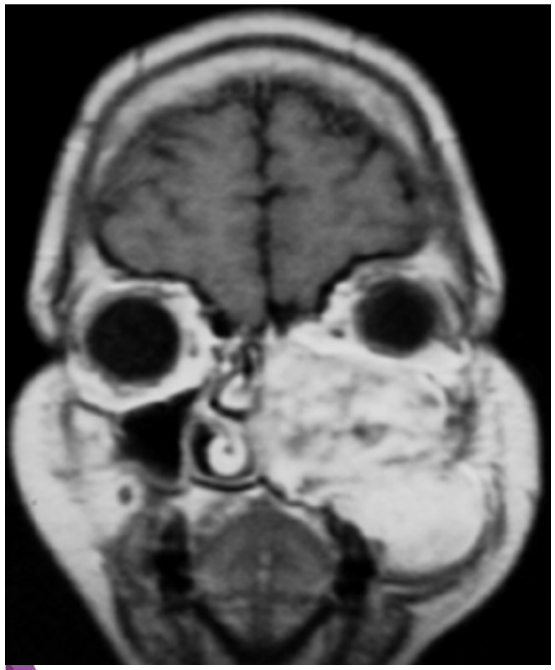

	T1
CSF	
Gray matter	
White matter	
Edema /Tu	
Fat	
Contrast agent	

ESTRO School

MRI contrasts

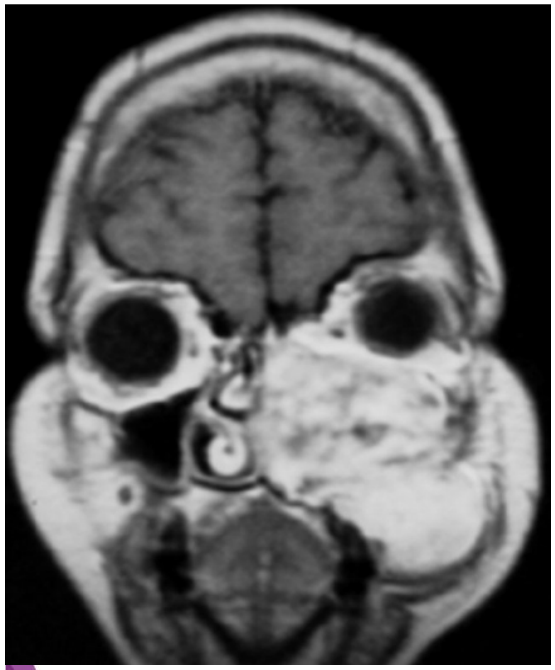

	T1
CSF	
Gray matter	
White matter	
Edema /Tu	
Fat	
Contrast agent	

ESTRO School

MRI contrasts

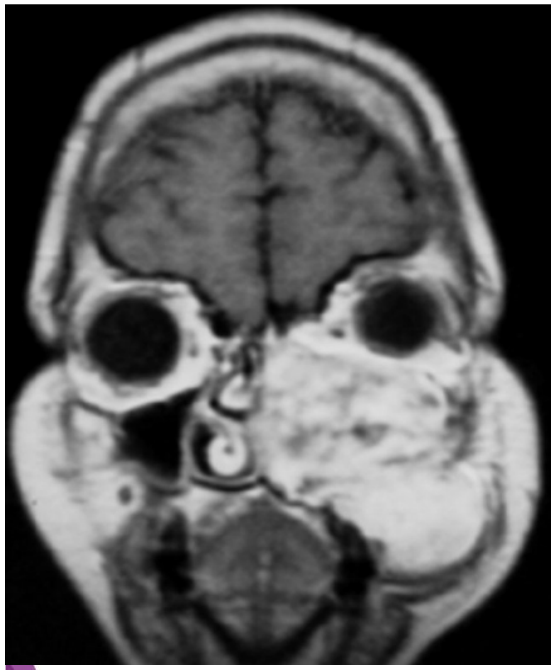

	T1	T1fs
CSF		
Gray matter		
White matter		
Edema /Tu		
Fat		
Contrast agent		

ESTRO School

FLAIR and STIR

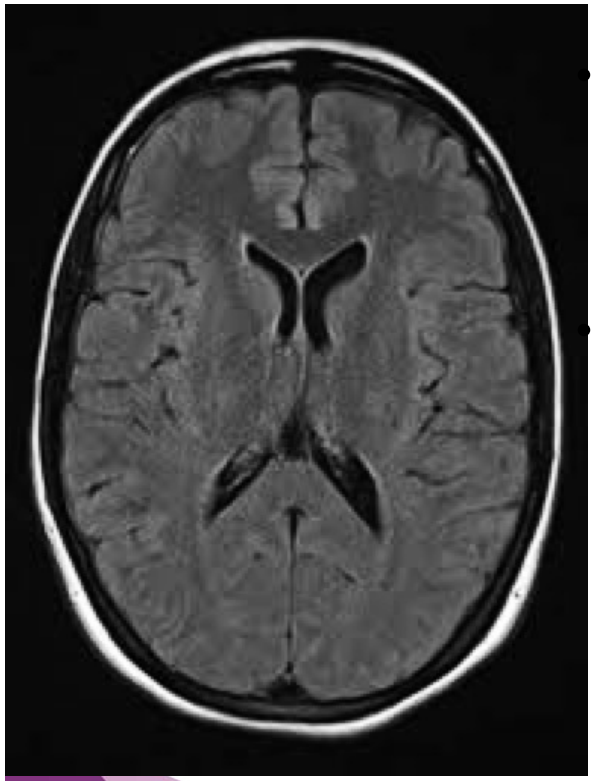

Inversion-recovery pulse sequence used to nullify the signal from a specific tissue

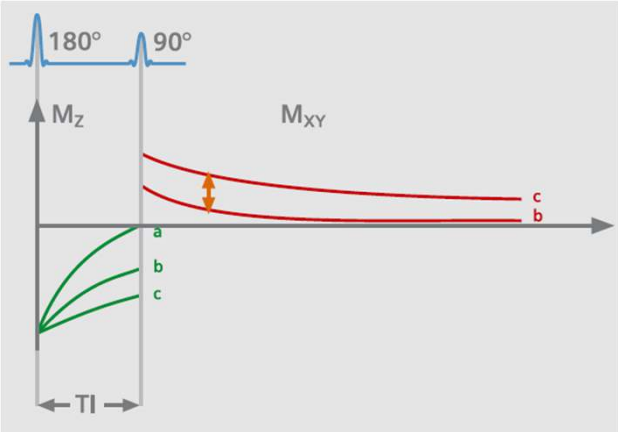

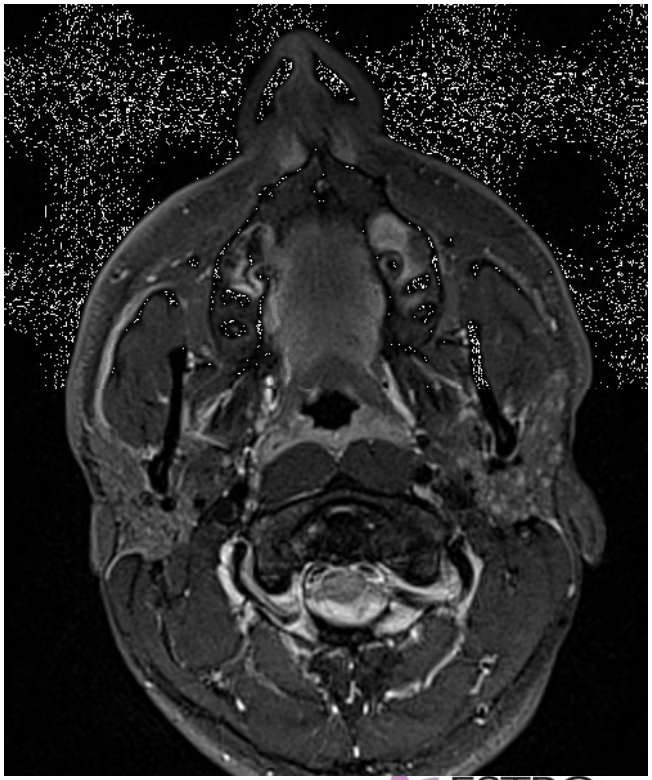

ESTRO School

FLAIR and STIR

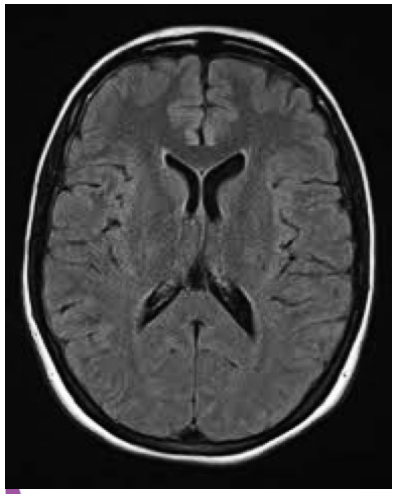

	T1	T2	FLAIR	STIR	T2fs
CSF					
Gray matter					
White matter					
Edema /Tu					
Fat					
Contrast agent					

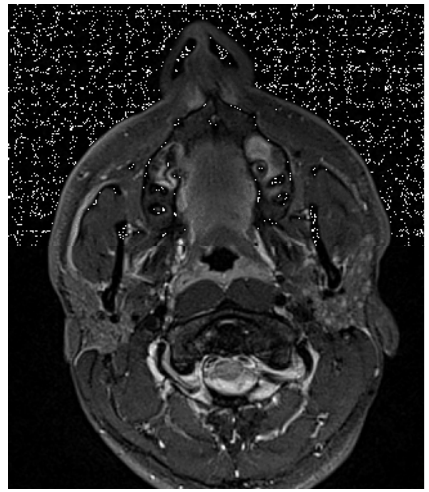

ESTRO School

FLAIR and STIR

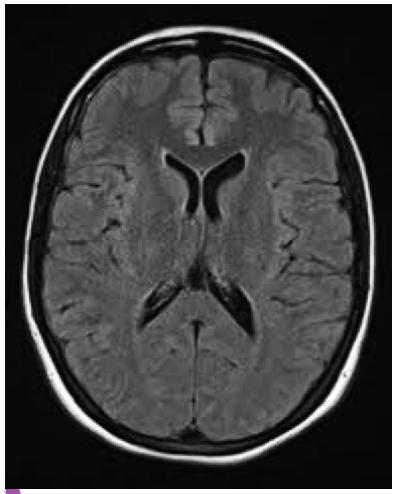

	T1	T2	FLAIR	STIR	T2fs
CSF					
Gray matter					
White matter					
Edema /Tu					
Fat					
Contrast agent					

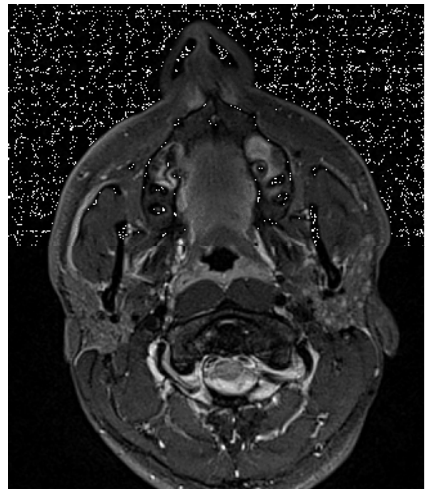

ESTRO School

FLAIR and STIR

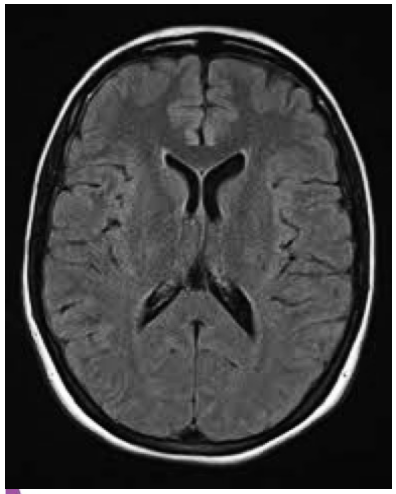

	T1	T2	FLAIR	STIR	T2fs
CSF					
Gray matter					
White matter					
Edema /Tu					
Fat					
Contrast agent					

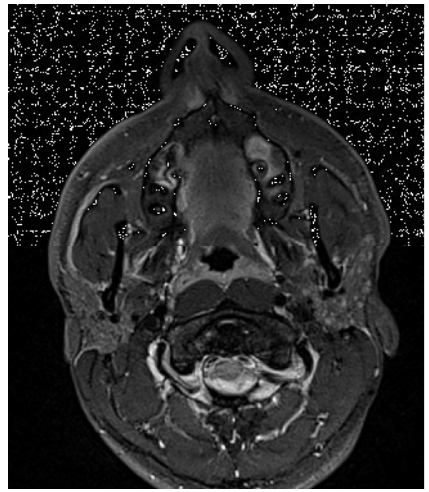

ESTRO School

STIR vs T2fs

- STIR: superior and homogeneous fat suppression
- STIR: very strong T2w contrast
- STIR: no contrast agent allowed

ESTRO School

T2*

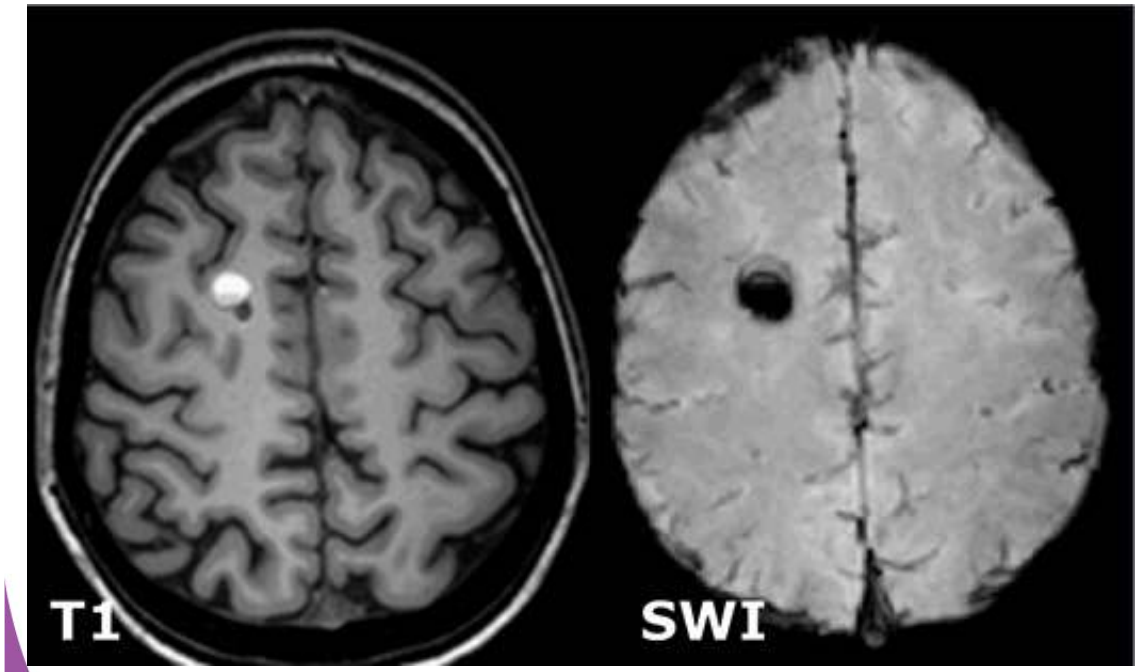

- Signal loss due to MR susceptibility:
  - Blood (hemosiderin)
  - Contrast agent
  - Air
  - iron

ESTRO School

???

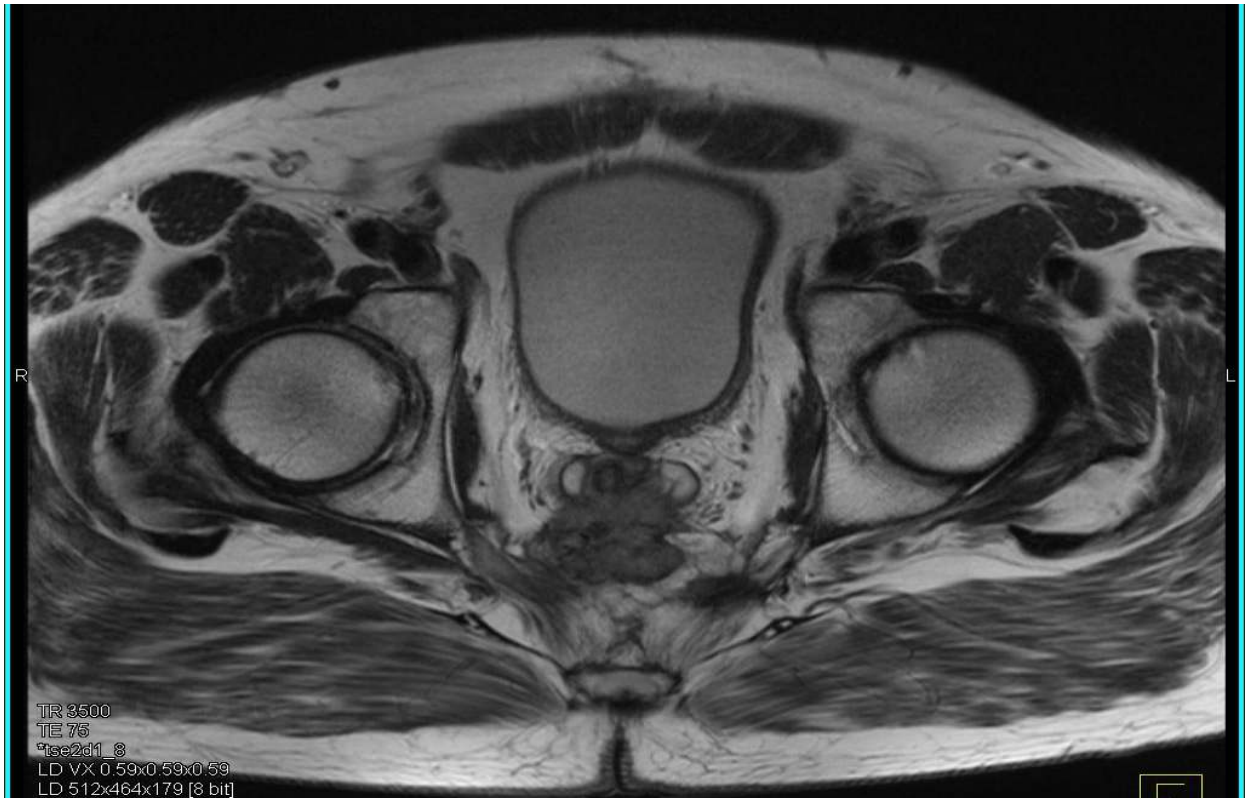

1) T1w
2) T2w
3) T3w
4) other

ESTRO School

1) T1w
2) T2w
3) T-bone
4) FLAIR
5) STIR

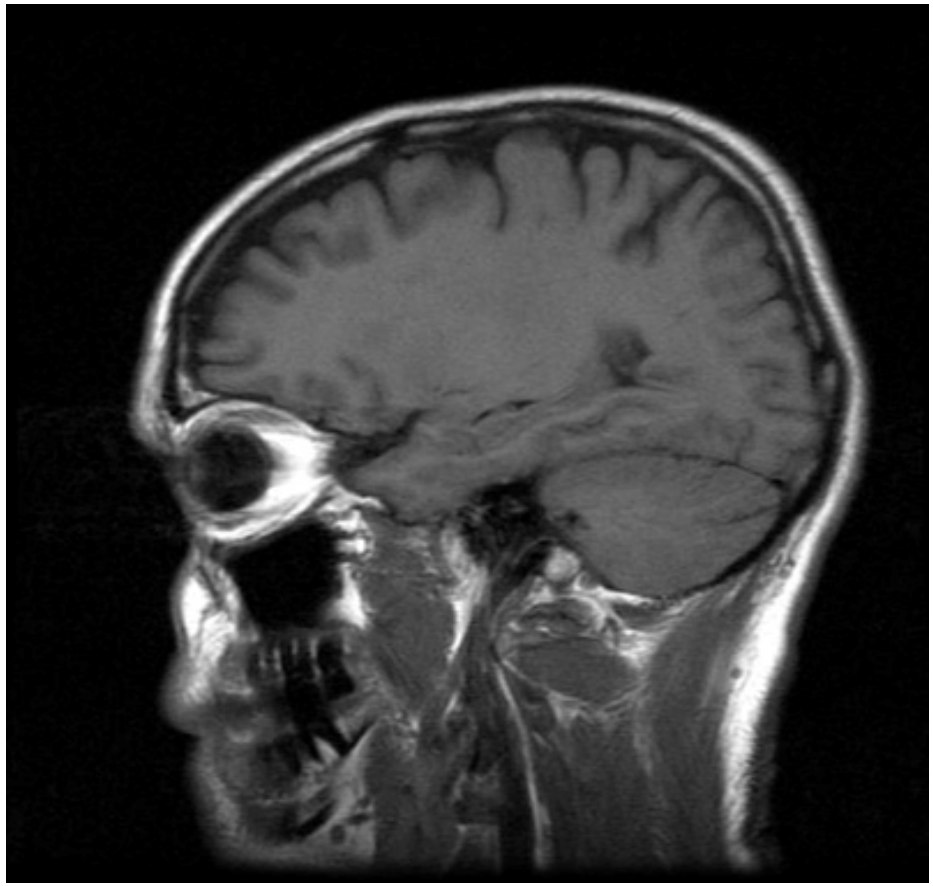

ESTRO School

???

1) T1w
2) T2w
3) T-rex
4) FLAIR
5) STIR

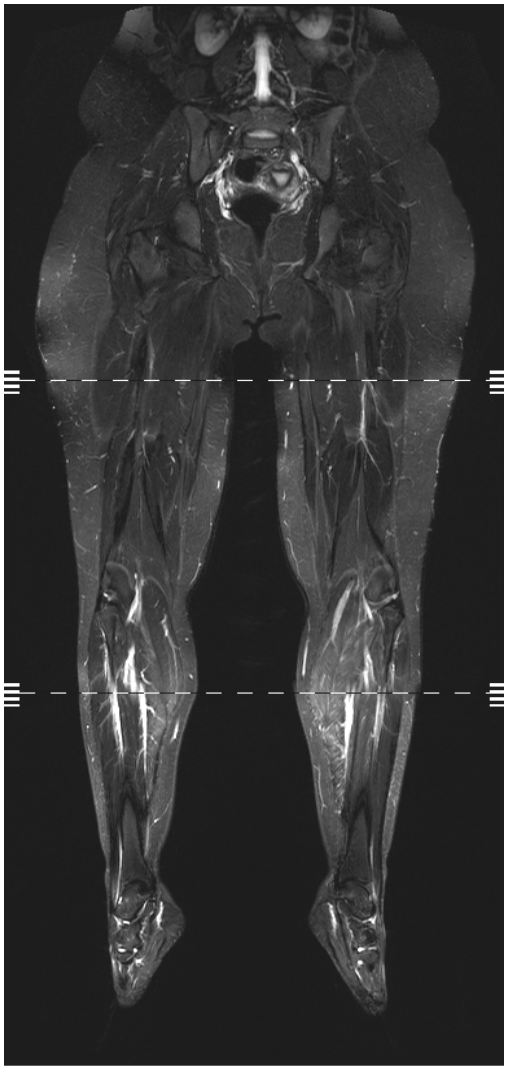

ESTRO School

1) T1w
2) T2w
3) FLAIR
4) STIR
5) other

ESTRO School

1) T1w
2) T2w
3) FLAIR
4) STIR
5) other

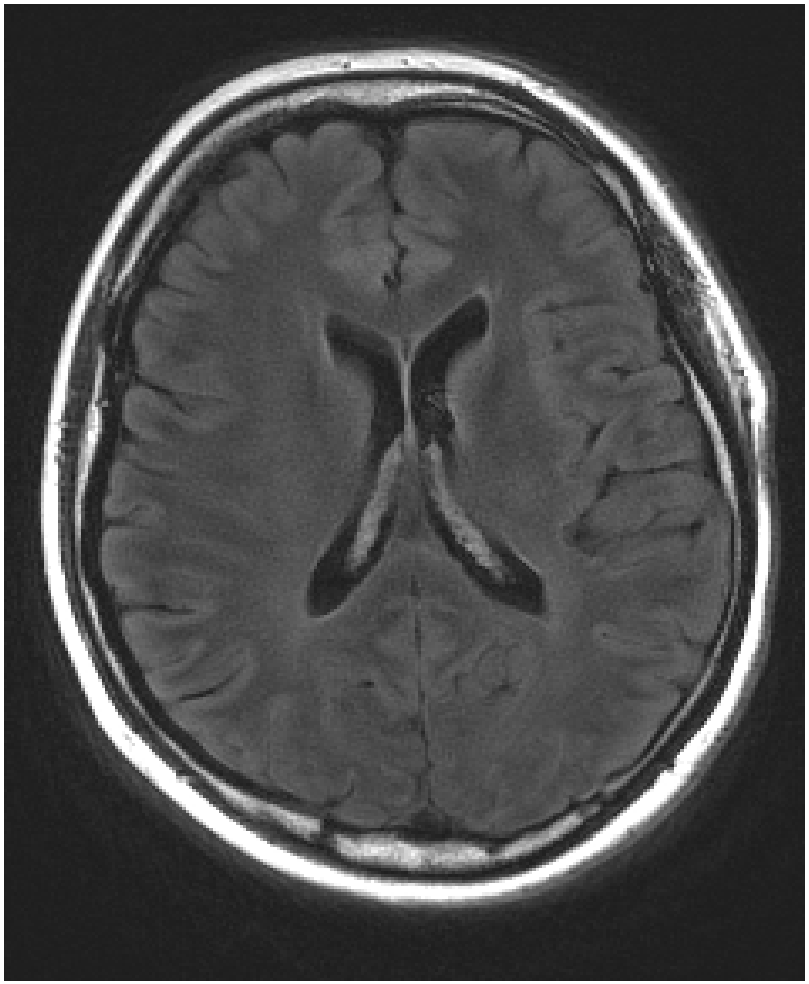

ESTRO School

1) T1w
2) T2w
3) FLAIR
4) STIR
5) other

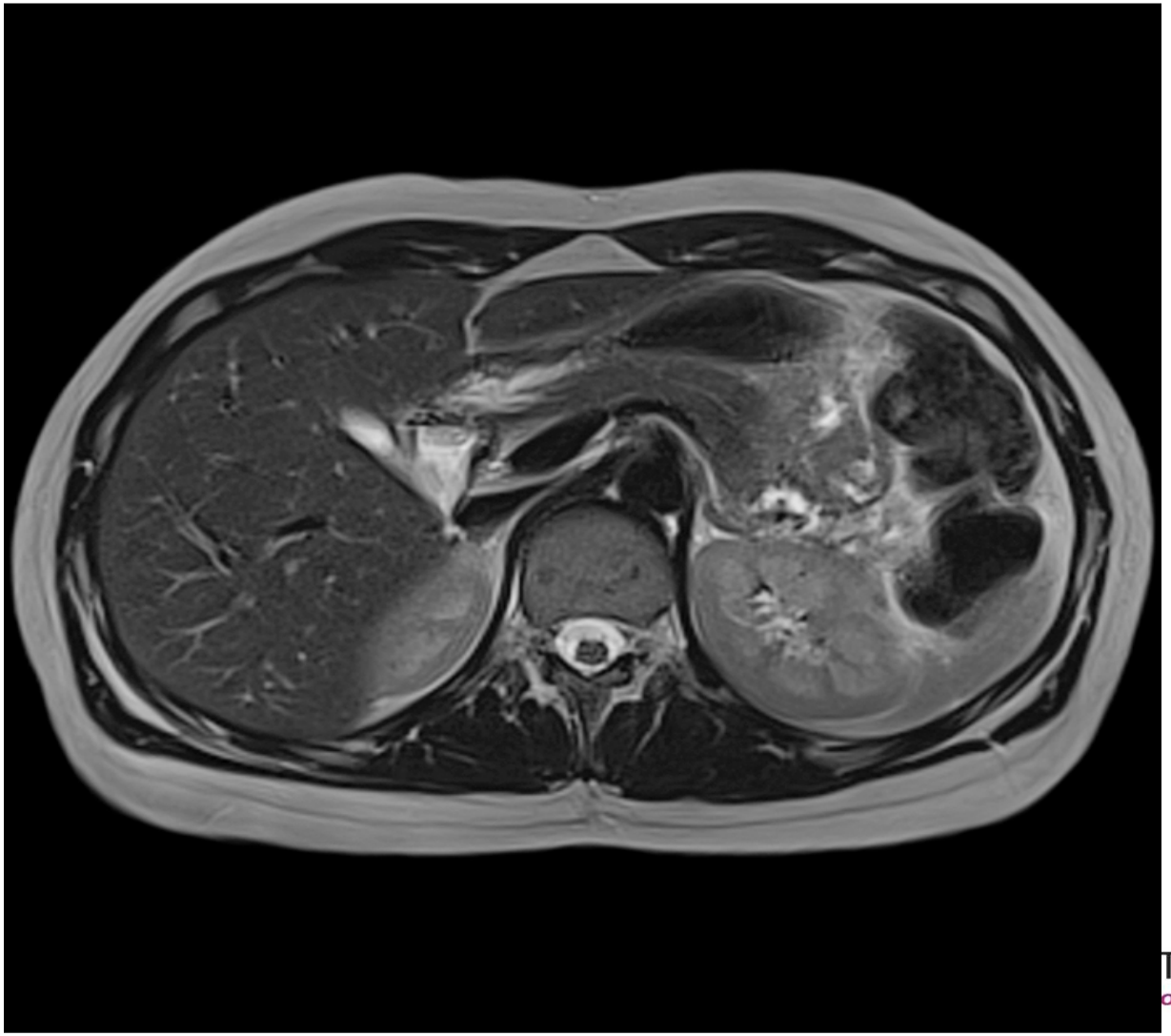

1) T1w
2) T2w
3) FLAIR
4) STIR
5) other

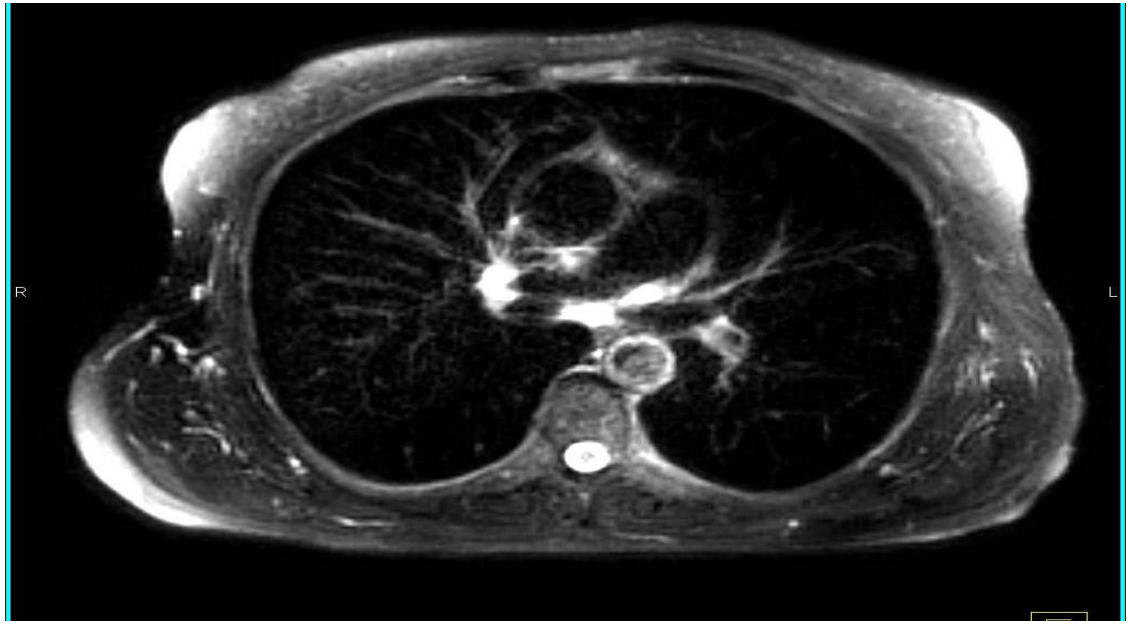

ESTRO School

1) T1w
2) T2w
3) FLAIR
4) STIR
5) other

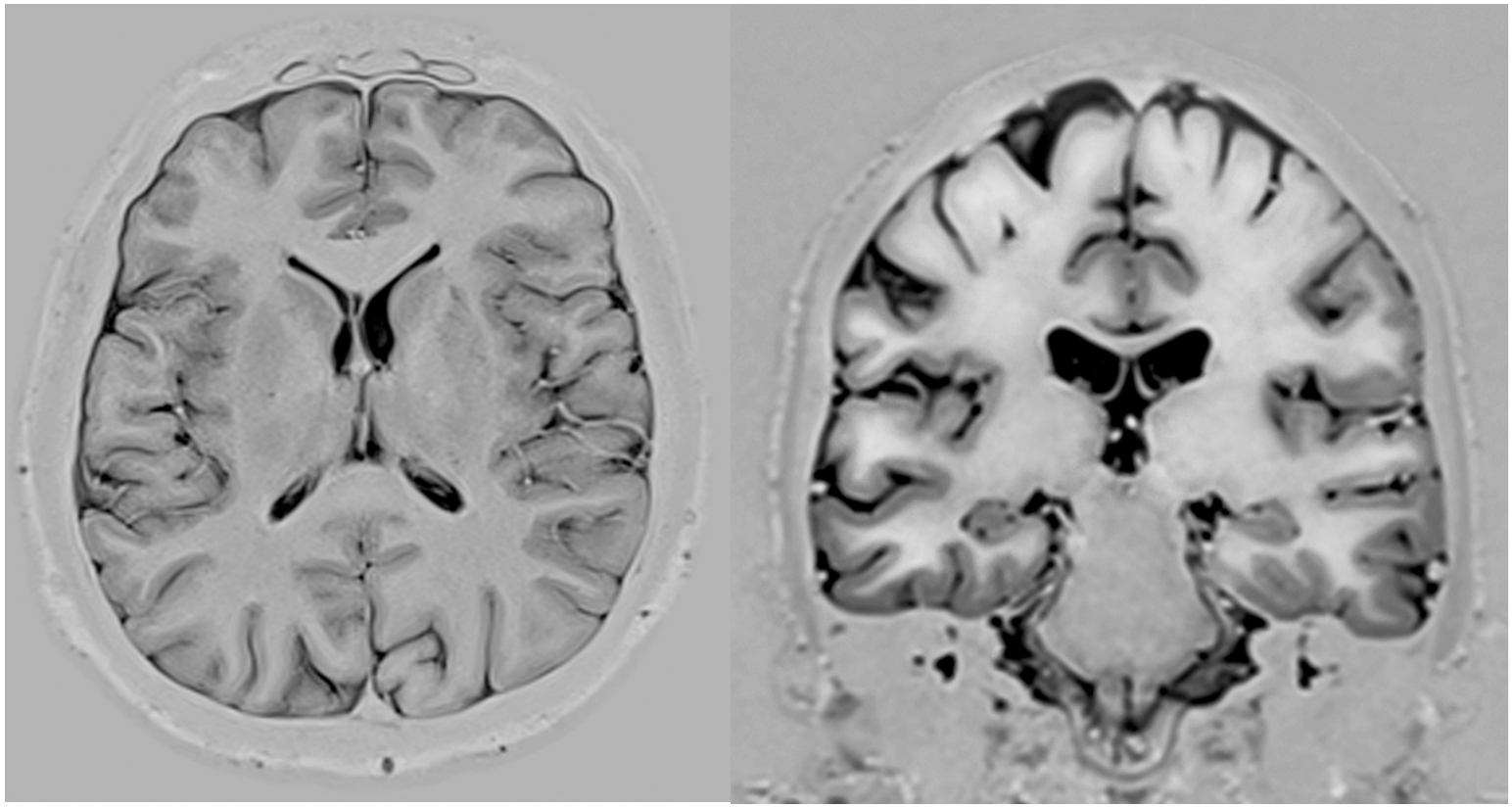

ESTRO School

3d vs 2d

- Most of the MR sequences are 2D
- Signal proportional to slice thickness (√2)
- The vast majority of 3D sequences are T1w
- MPRage / FGATIR: combination of 3D and IR to increase the T1w

MR Distortion

uncorrected

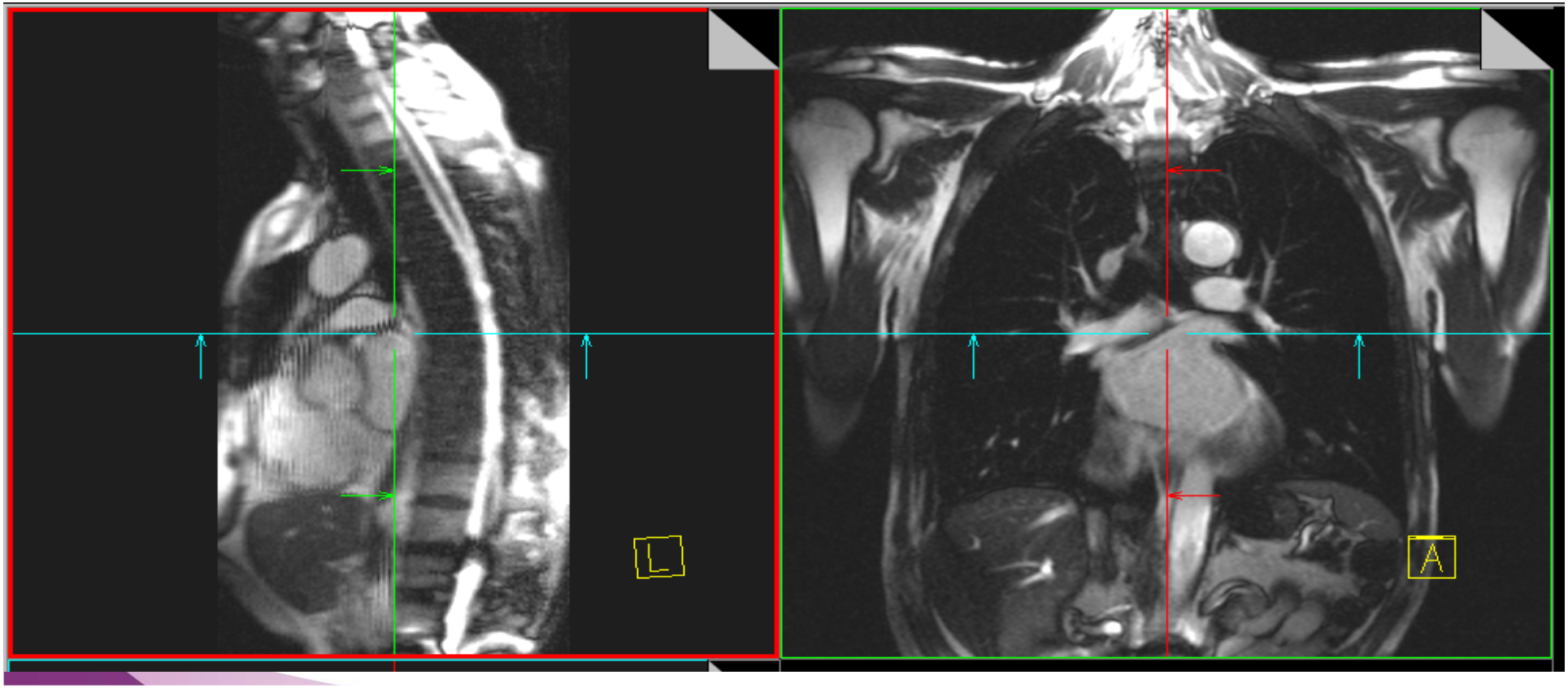

MR Distortion

2D-distortion correction

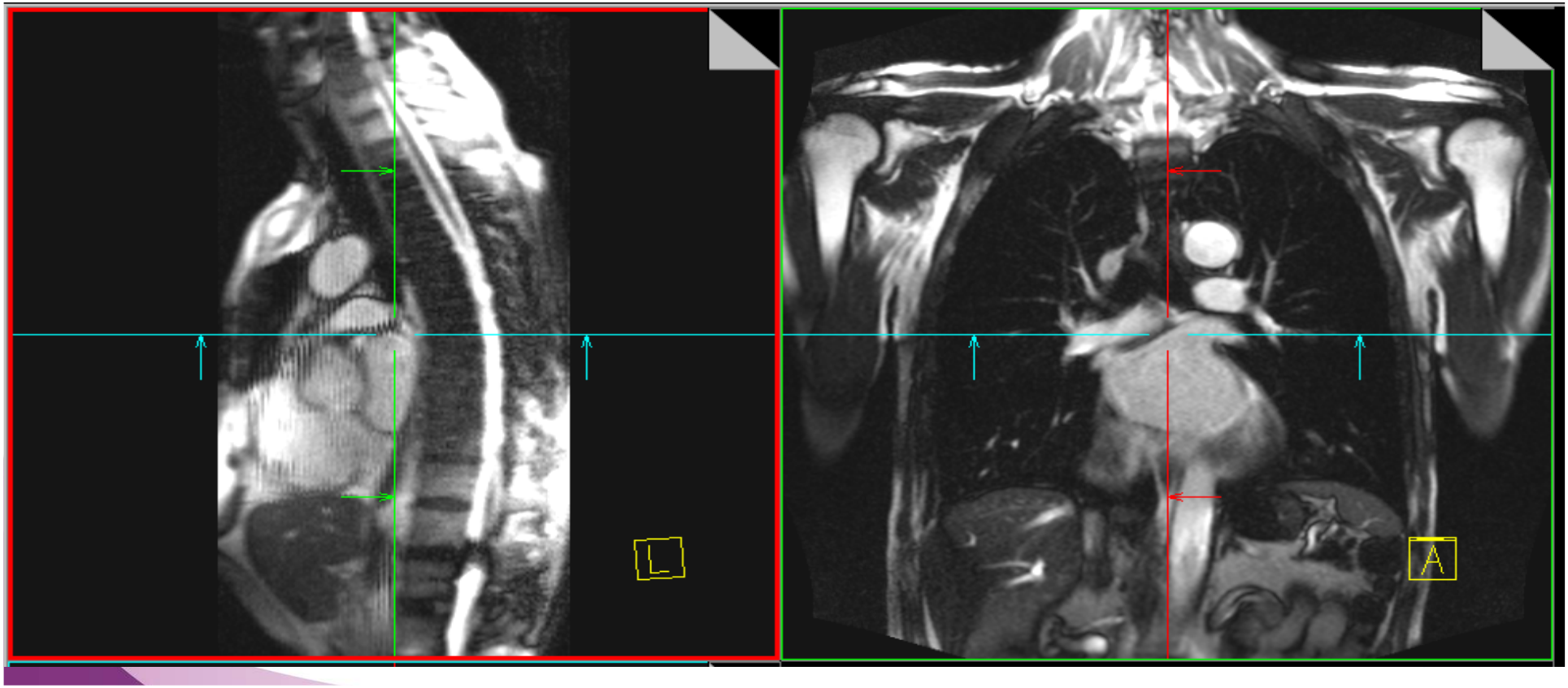

MR Distortion

3D-distortion correction

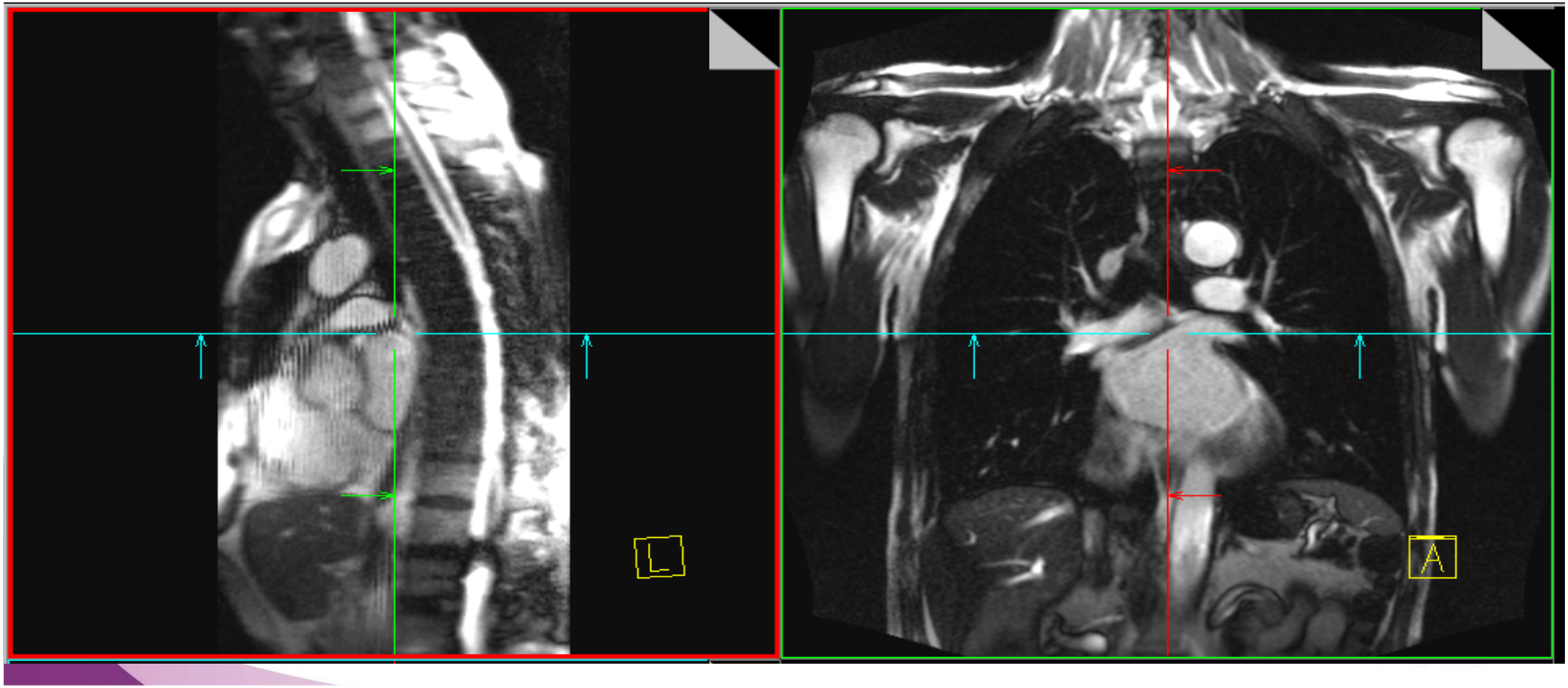

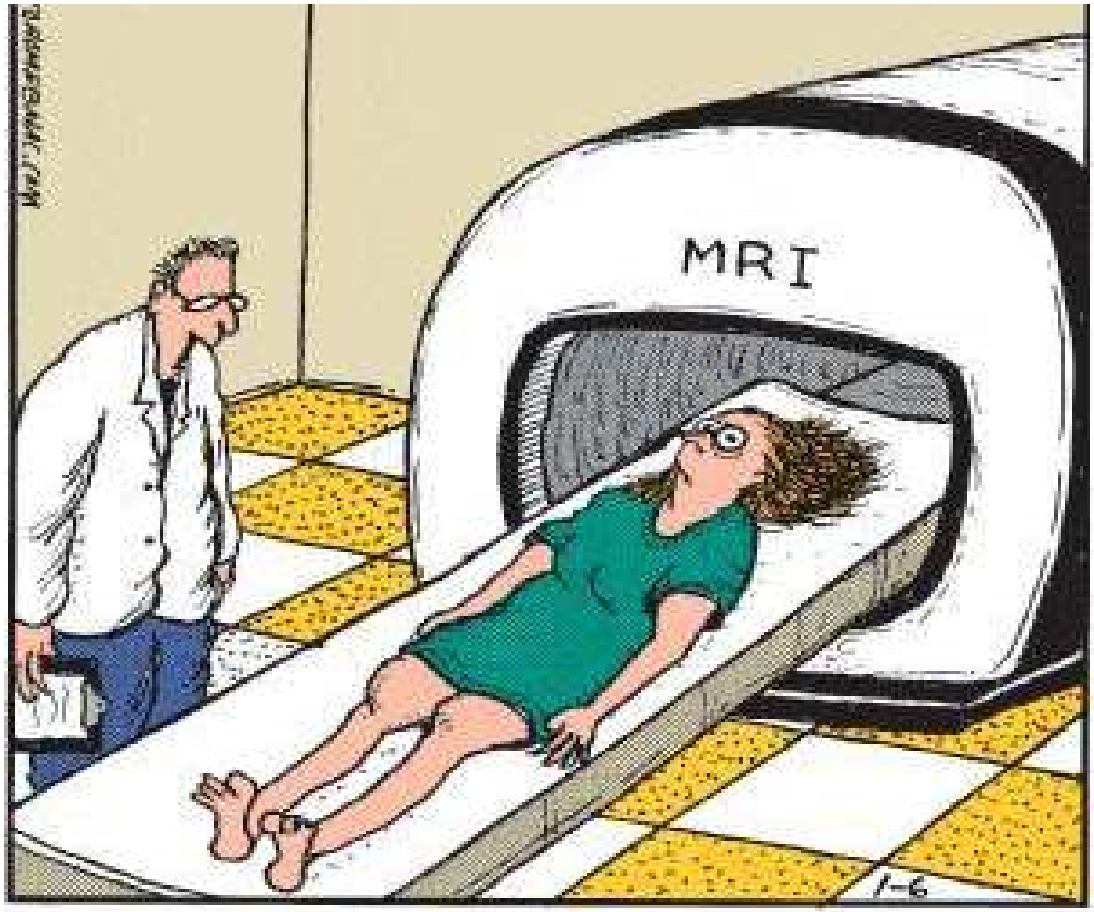

"OK, Mrs. Dunn. We'll slide you in there, scan your brain, and see if we can find out why you've been having these spells of claustrophobia."

Functional imaging

ESTRO School

Dynamic contrast-enhanced MRI

How it works: DCE MRI

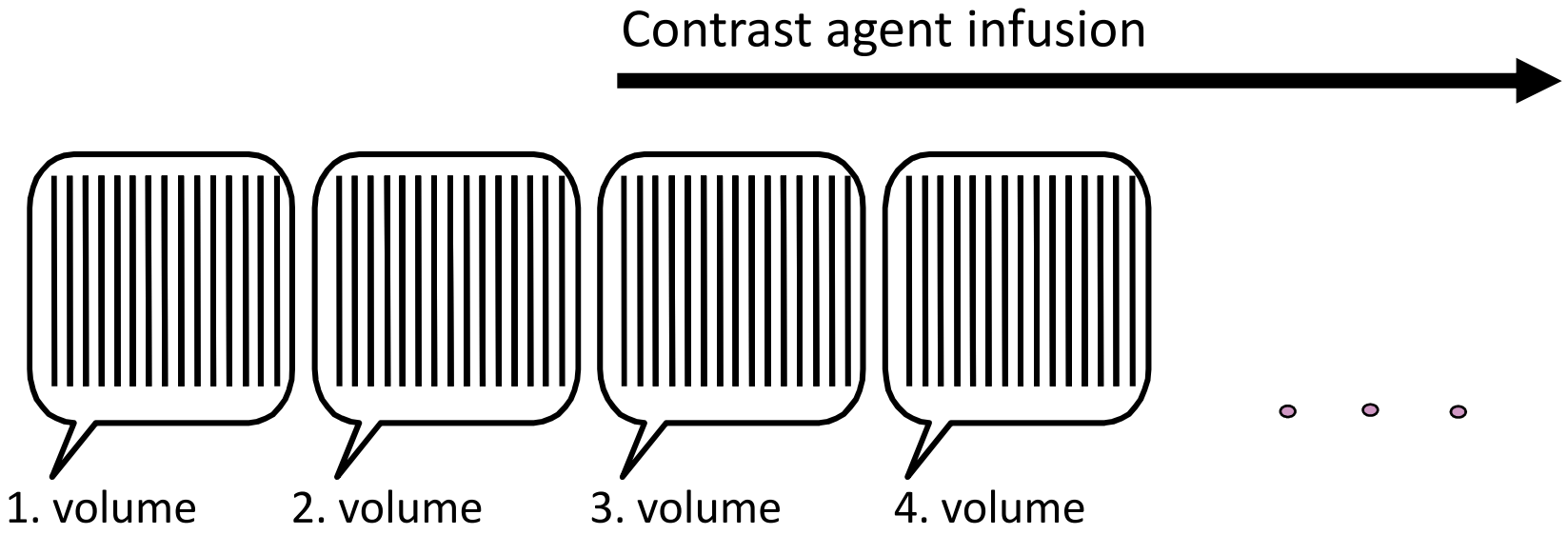

DCE MRI

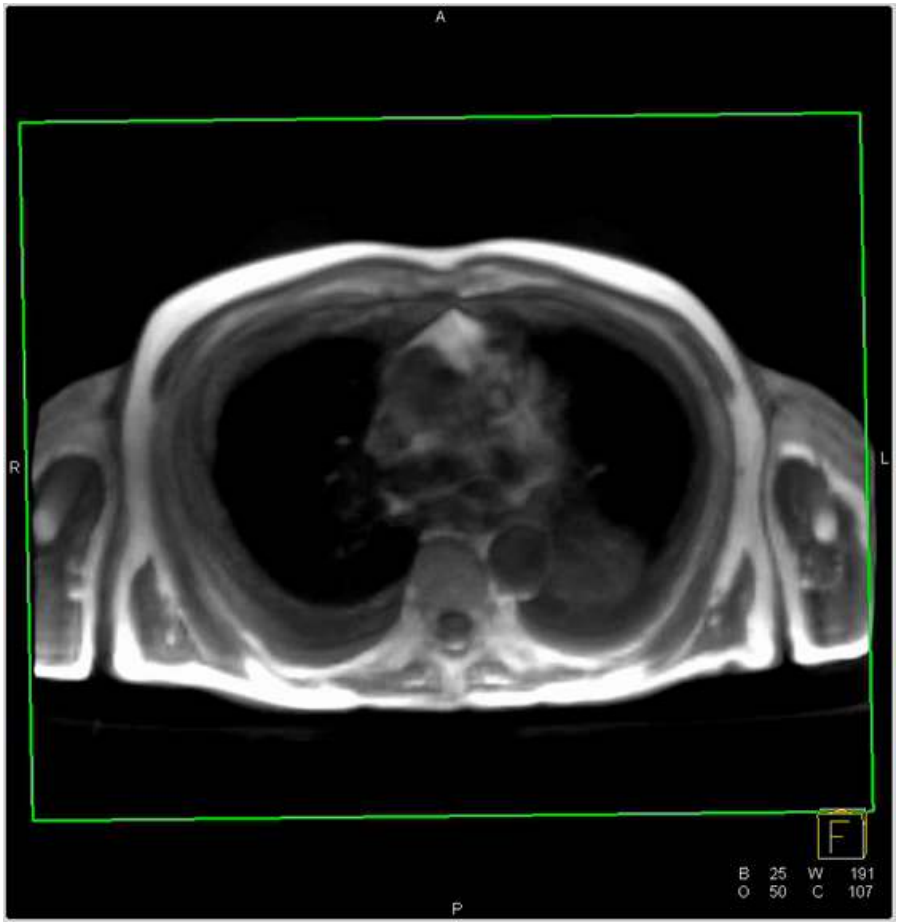

MRI Perfusion

- Perfusion MRI provides a relative measurement of the parameters of microvascularisation:
  - regional blood volume
  - mean transit time
  - regional blood flow
- It relies on the use of a tracer (usually Gadolinium)
- The signal change during the first pass of the contrast agent allows perfusion parameters to be extracted.

ESTRO School

Pattern of Enhancement

Fibroadenoma

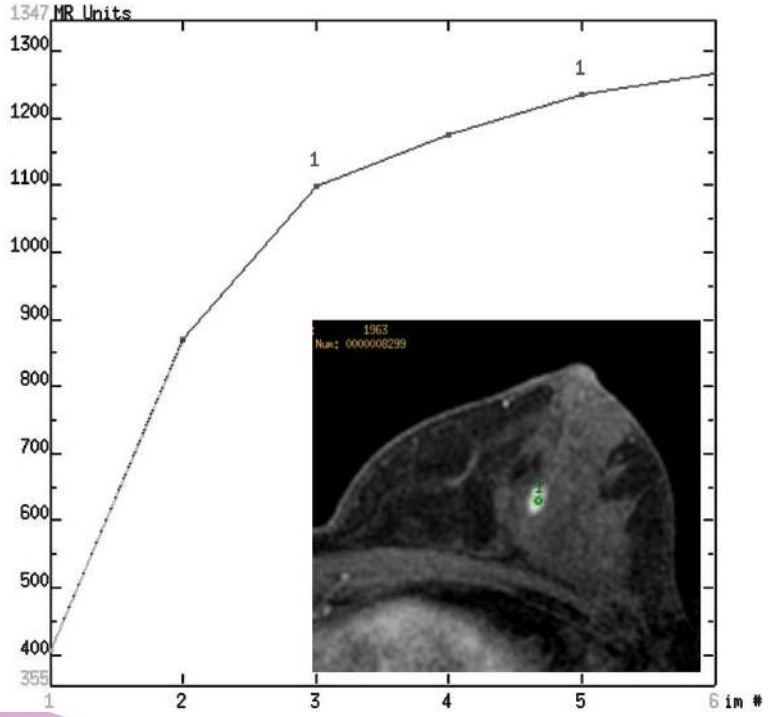

Case courtesy of Dr Roberto Schubert, Radiopaedia.org, rID: 13817

Primary breast angiosarcoma

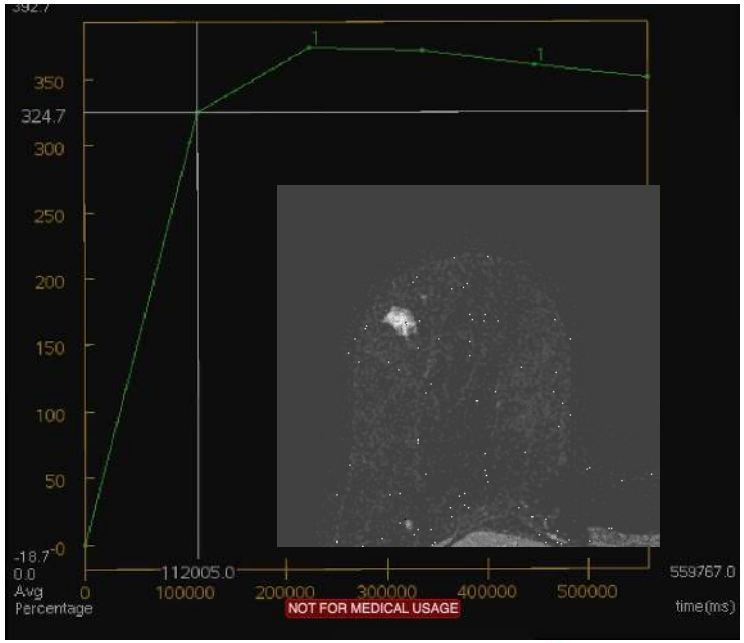

Case courtesy of Dr Enrico Citarella, Radiopaedia.org, rID: 35224

ESTRO School

Brain perfusion

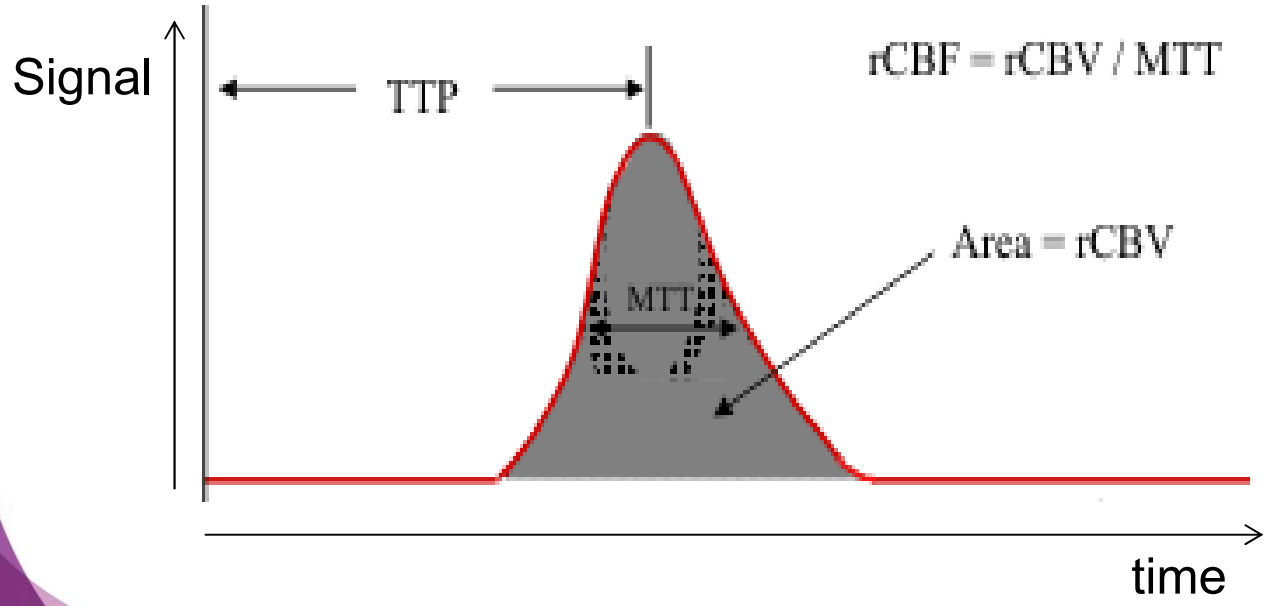

TTP: time to peak
CBV: cerebral blood volume
MTT: mean transit time
CBF: cerebral blood flow

ESTRO School

T2*w MRT Perfusion

Transient signal loss by intravascular CM

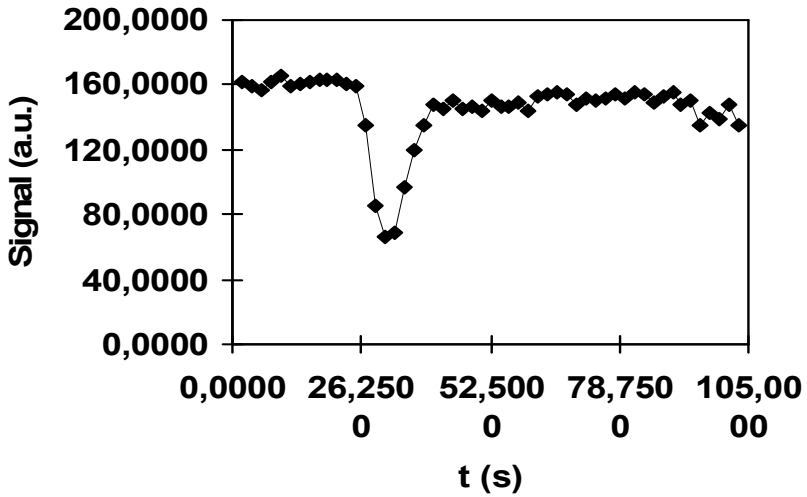

T2*-weighted MRI

ESTRO School

CBV in glioma

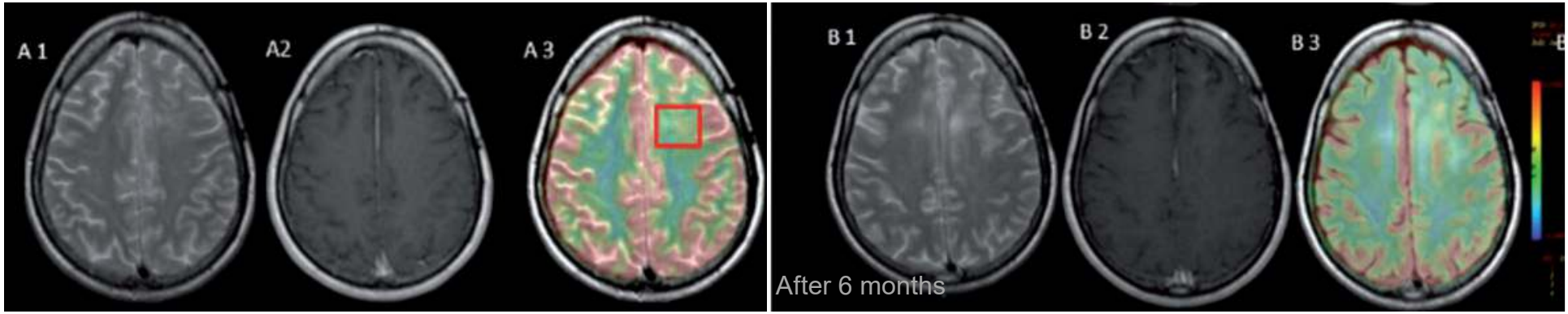

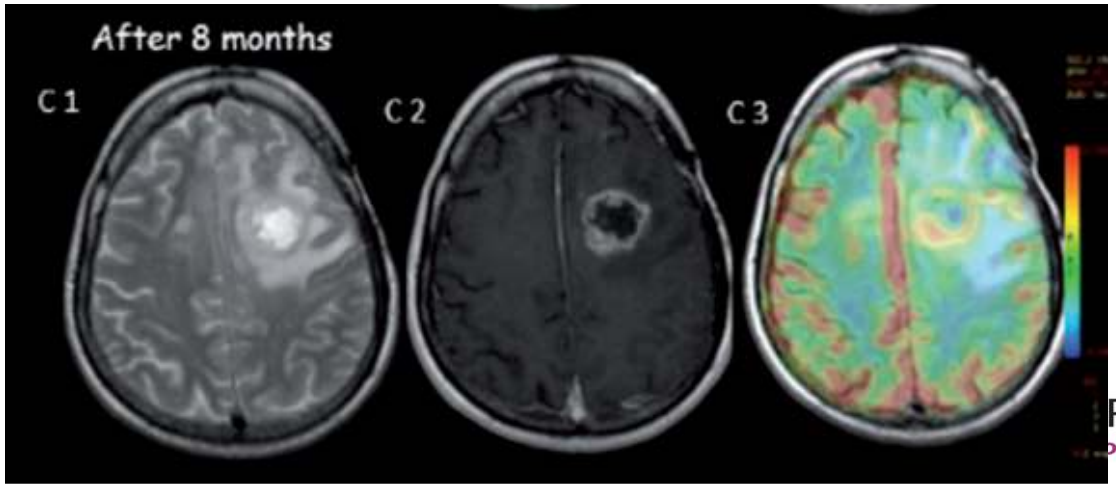

Anselmi et al, *Diagnostic accuracy of proton magnetic resonance spectroscopy and perfusion-weighted imaging in brain gliomas follow-up: a single institutional experience* The Neuroradiology Journal 2017

Distribution of MRI contrast agent

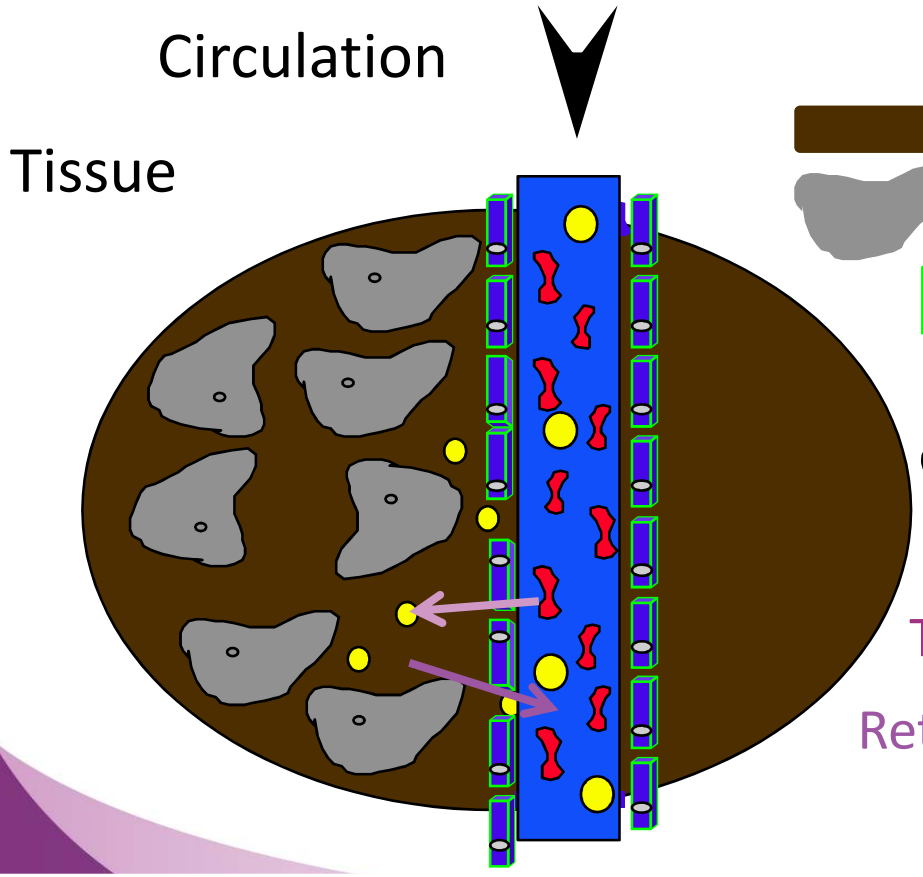

Extracellular space

Intracellular space

Capillary wall

Red blood cell

Gd-Chelate

Transition into extracellular space

Return into intravascular space

ESTRO School

Pharmacokinetic model

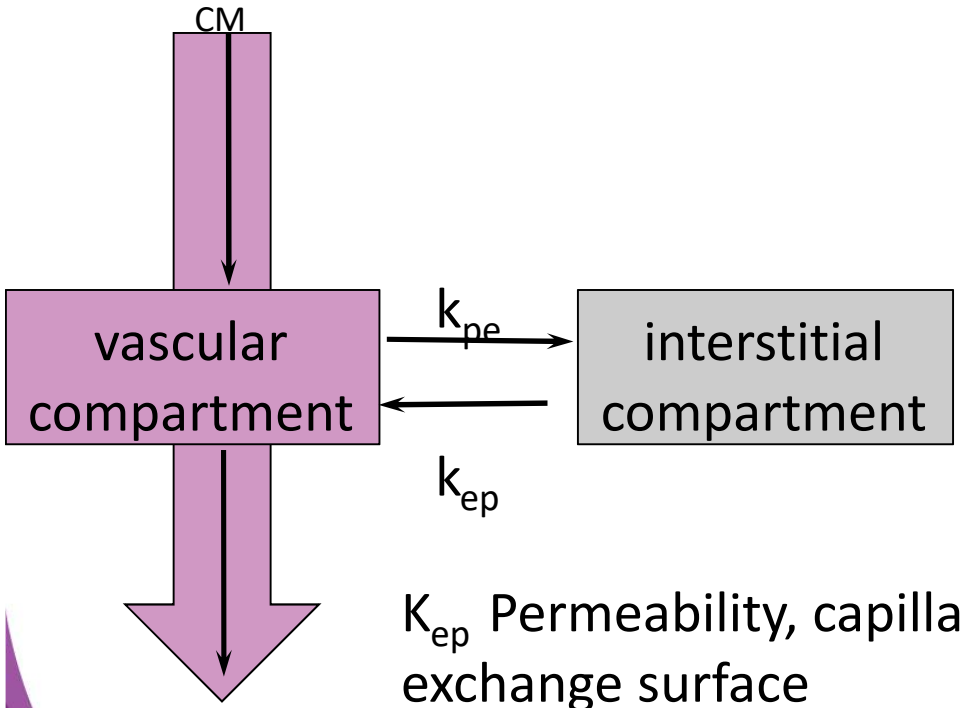

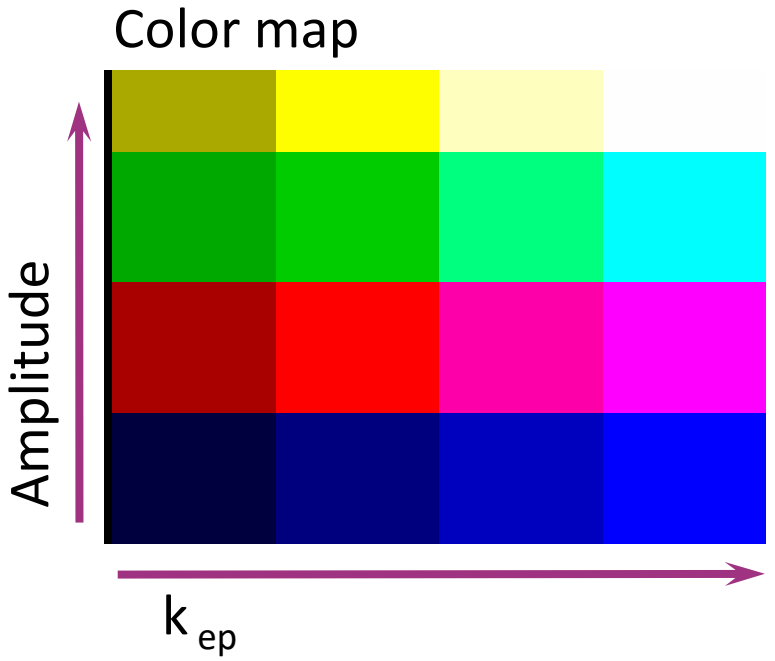

K_{ep} Permeability, capillary exchange surface

Amplitude: Relative CA volume in interstitial space

ESTRO School

Diffuse infiltration by multiple myeloma

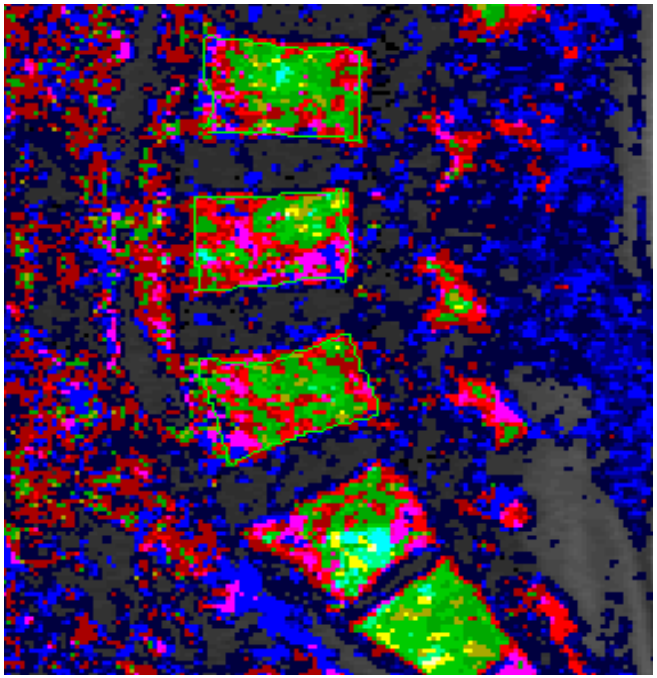

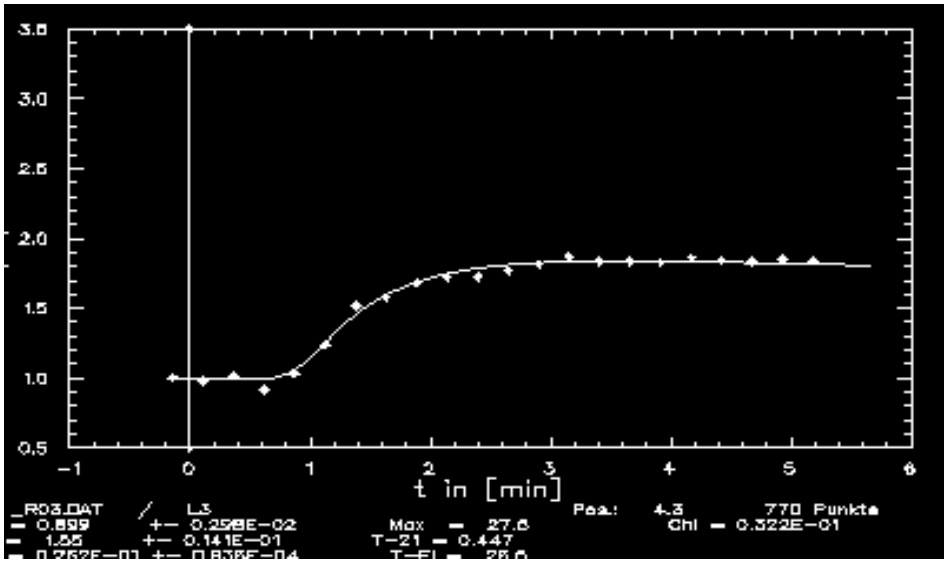

Normal spine

T1w post contrast FS

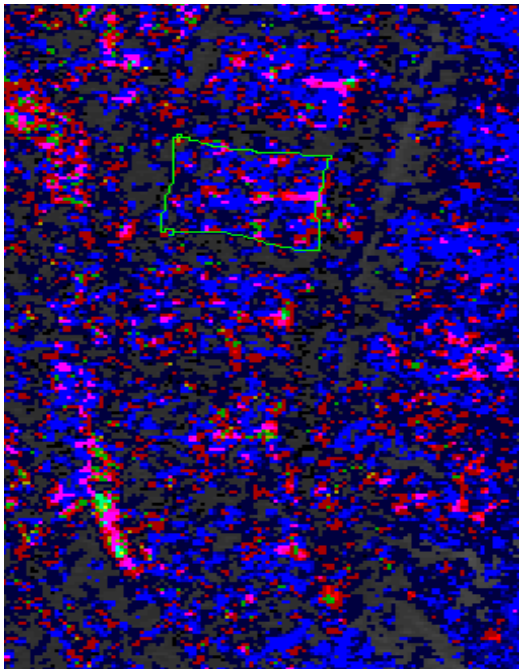

Parameter image

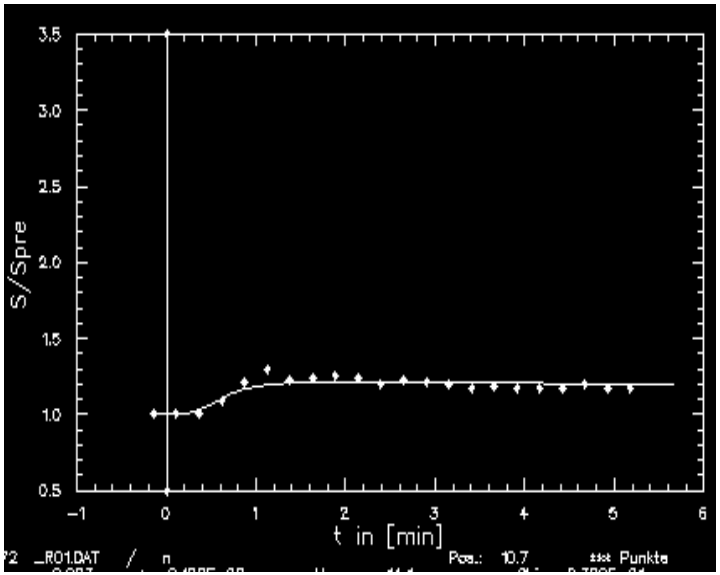

Time-intensity curve

ESTRO School

Diffusion

ESTRO School

DWI

- MRI can be made sensitive to the microscopic displacements of water molecules

DWI

micromovements of water molecules

- free (as in cerebrospinal fluid)
- restricted (by cell membranes, macromolecules, fibers…)

- in all spatial directions (isotropic diffusion)
- in a given direction (anisotropic diffusion) as in nerve fibers

ESTRO School

Diffusion

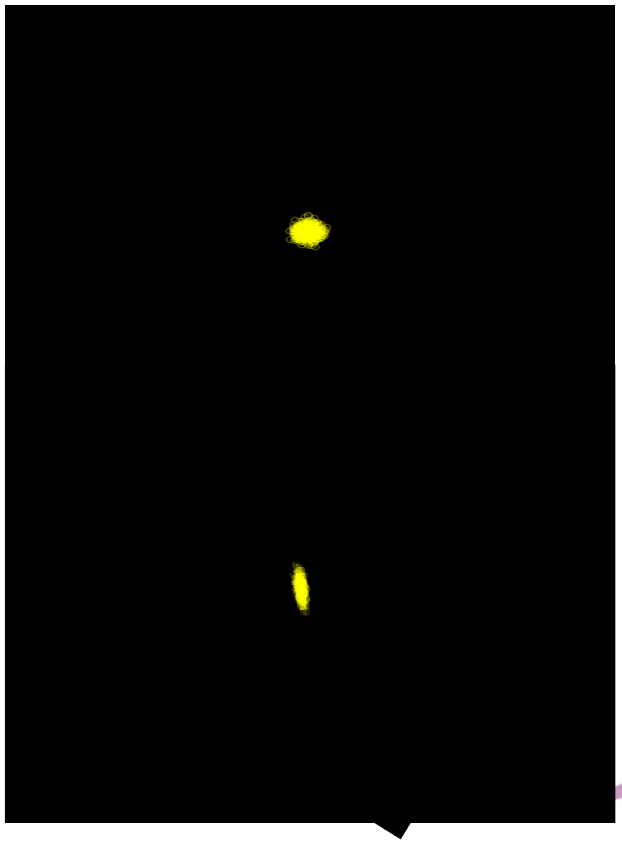

ESTRO School

DWI – how it works

- Diffusion gradients: dephasing + rephasing
- b value represents sensitivity to diffusion and determines the strength and duration of the diffusion gradients

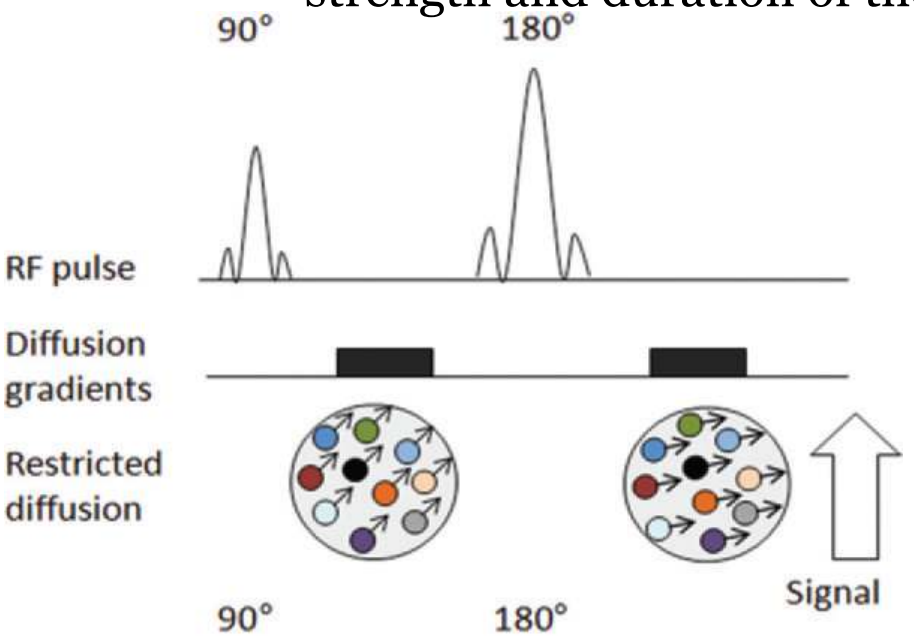

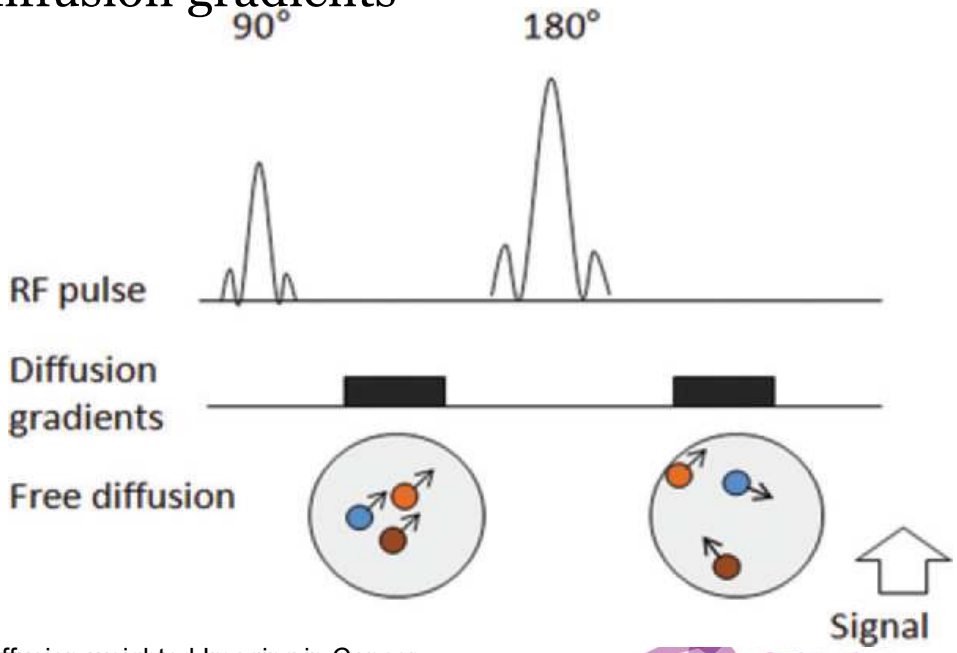

Ashkan A et al Principles and Applications of Diffusion-weighted Imaging in Cancer Detection, Staging, and Treatment Follow-up. Radiographics 2011

Calculation of the ADC

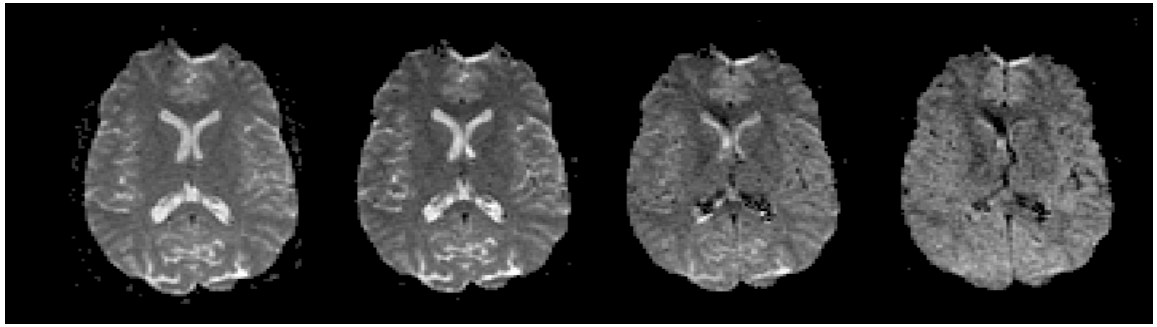

Low b-value → High b-value

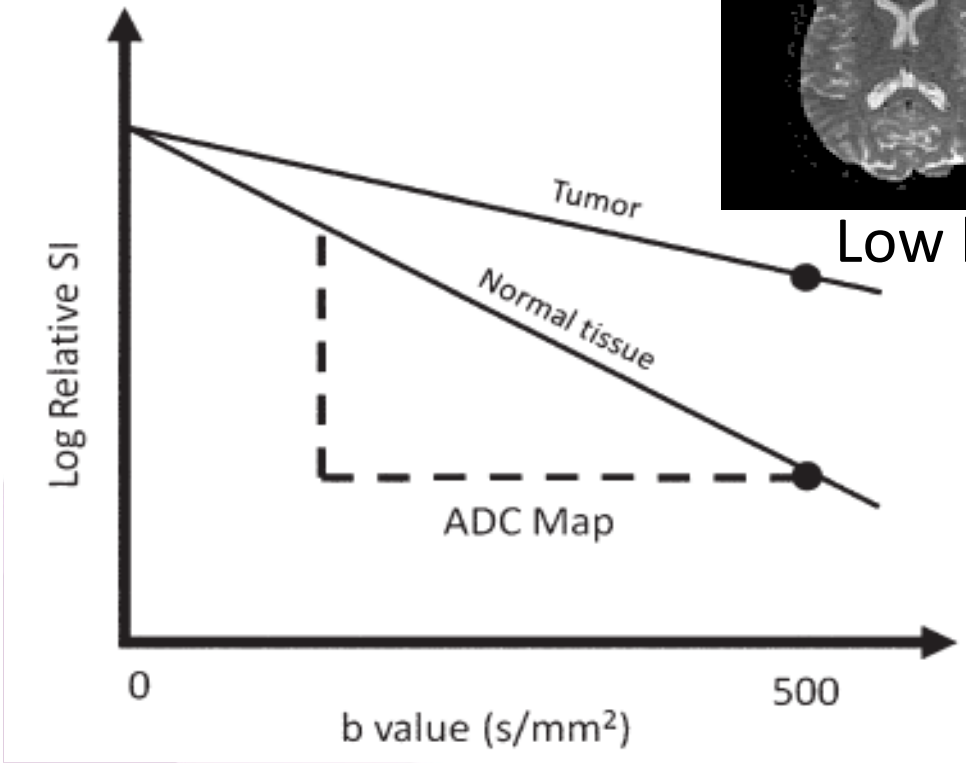

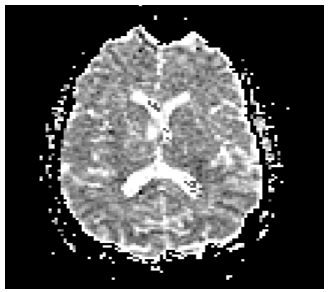

ADC image

Calculation of signal loss/pixel

ESTRO School

DWI

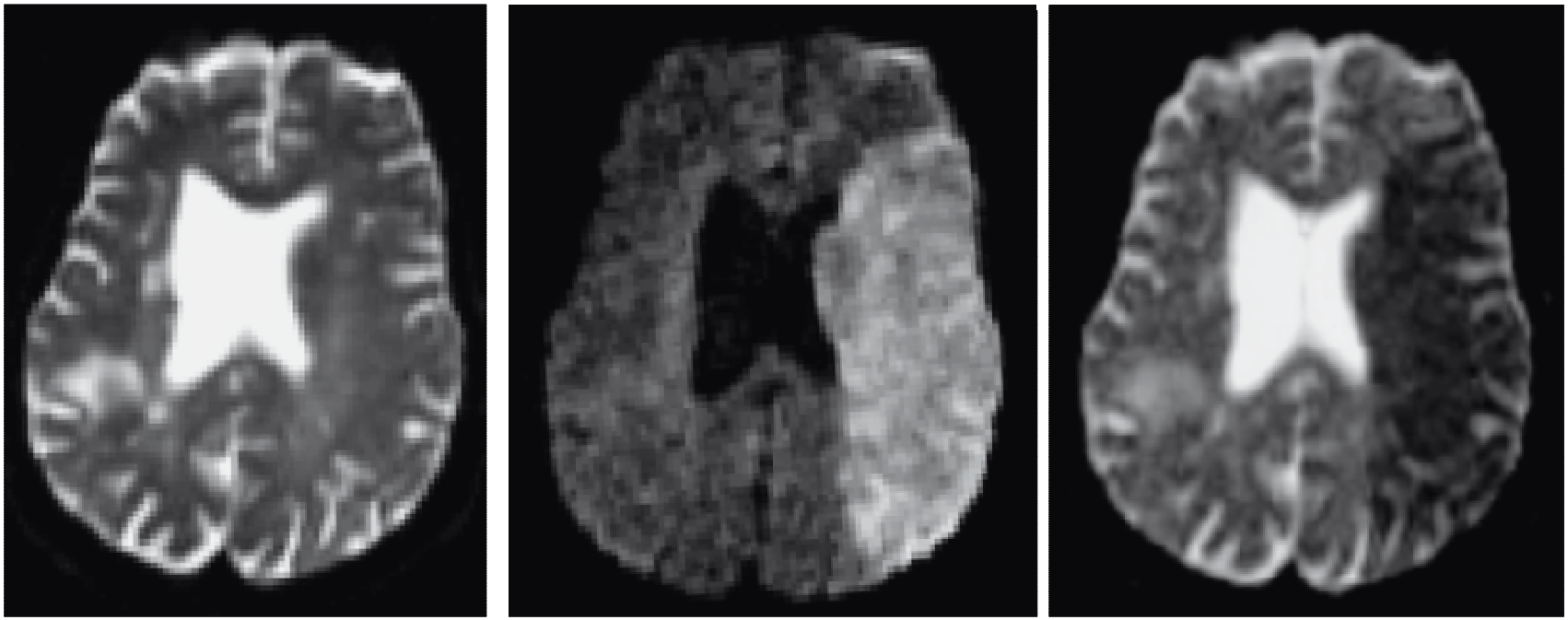

b0
(low res. T2fs)

b1000

ADC

Graessner et al Magnetom 2011

ESTRO School

T2 shine through

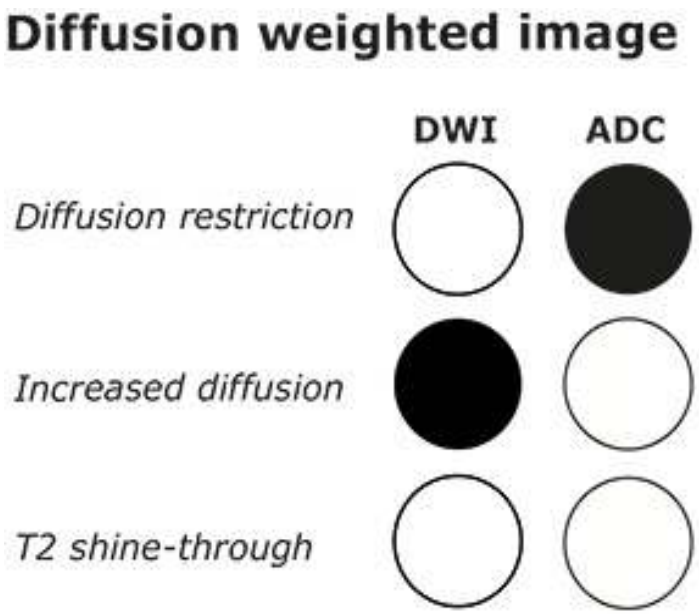

Ashkan A et al Principles and Applications of Diffusion-weighted Imaging in Cancer Detection, Staging, and Treatment Follow-up. Radiographics 2011

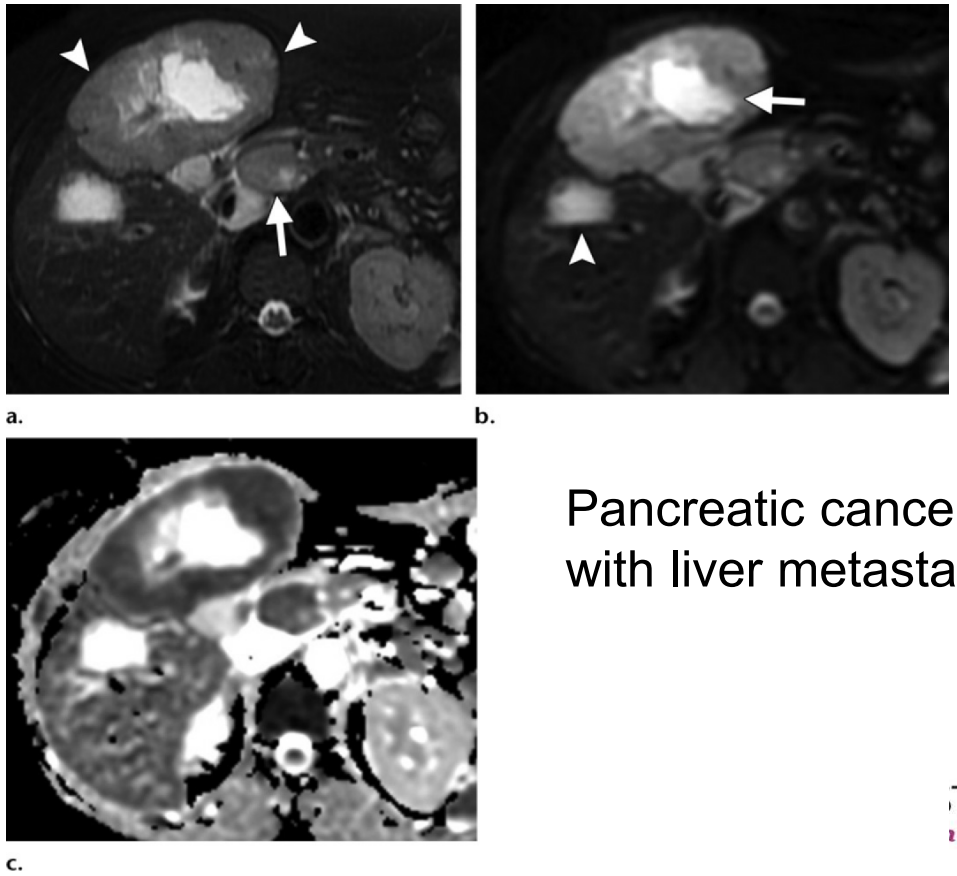

Pancreatic cancer with liver metastasis

ADC

- Quantitative measure of diffusion rate
  - Lower values mean more restricted diffusion
- Independent of T2

ESTRO School

ADC and cellularity

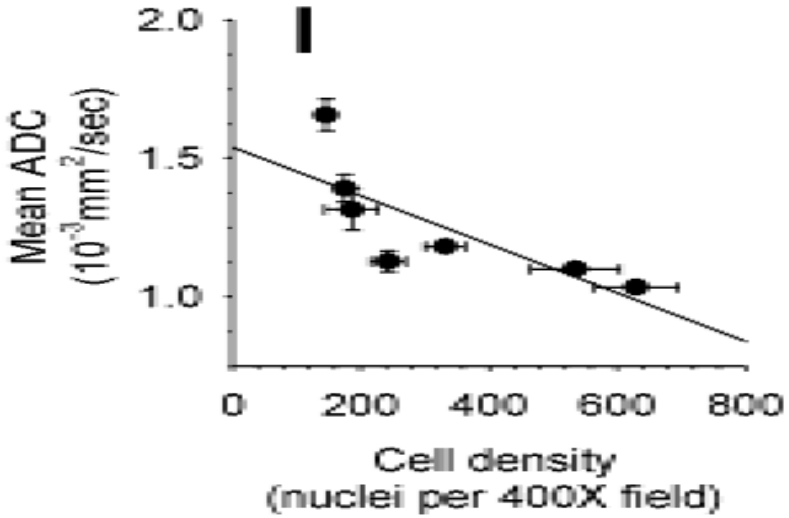

Previous studies report a negative correlation between **ADC** and tumour **cellularity**

Increased **cellularity in tumor** compared to **normal tissue**

Chenevert et al., J Natl Cancer Inst 2000; 92:2029–36

ESTRO School

DWI – TU/atelectasis

PET-CT

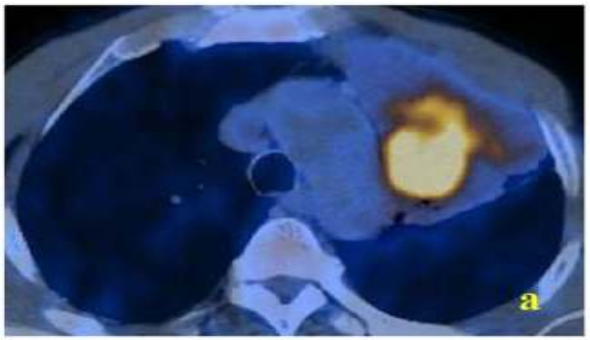

DWI

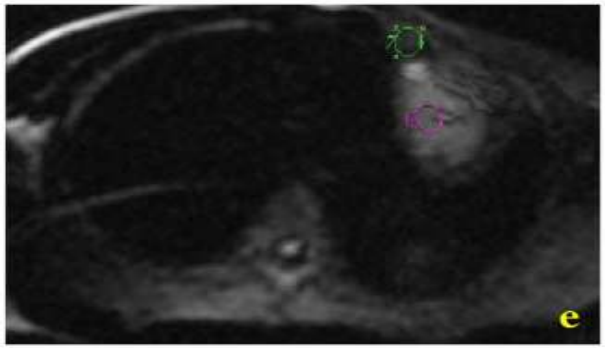

ADC

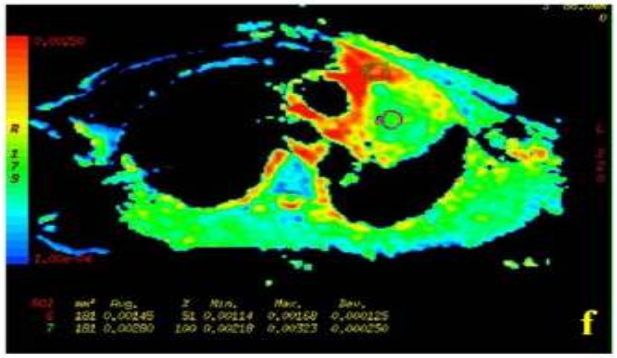

t2

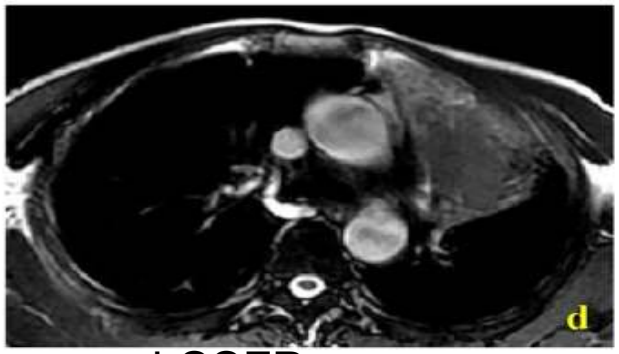

bSSFP

Yang et al. *Differentiation of Central Lung Cancer from Atelectasis: Comparison of Diffusion-Weighted MRI with PET/CT* PlosOne 2013.

ESTRO School

DWI – renal disease

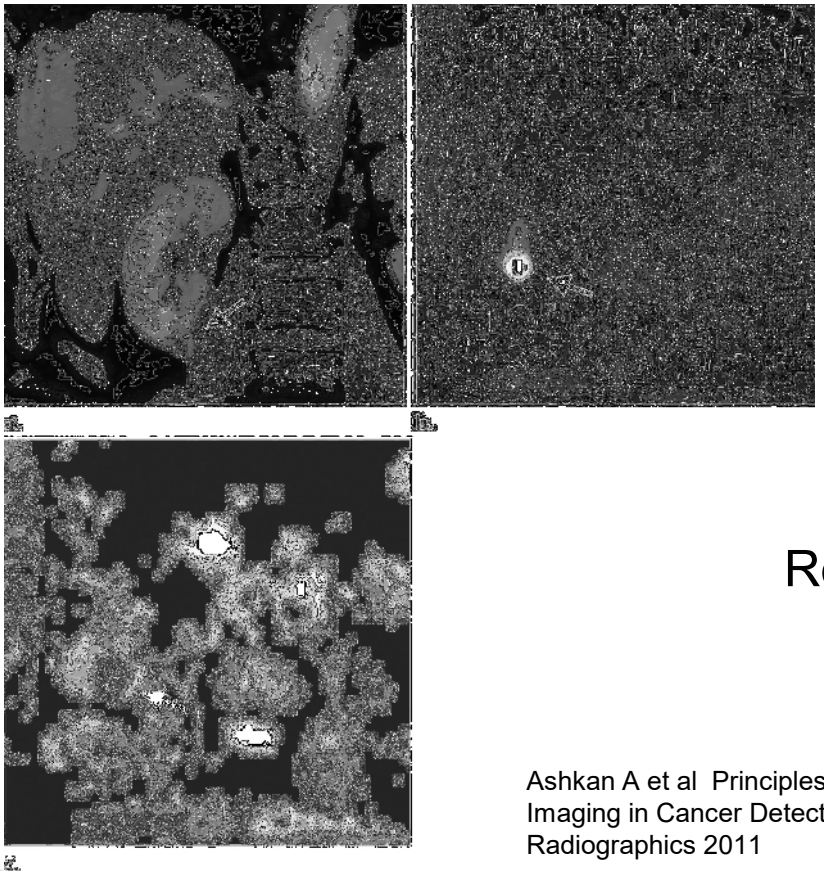

Renal cancer

Ashkan A et al Principles and Applications of Diffusion-weighted Imaging in Cancer Detection, Staging, and Treatment Follow-up. Radiographics 2011

ESTRO School

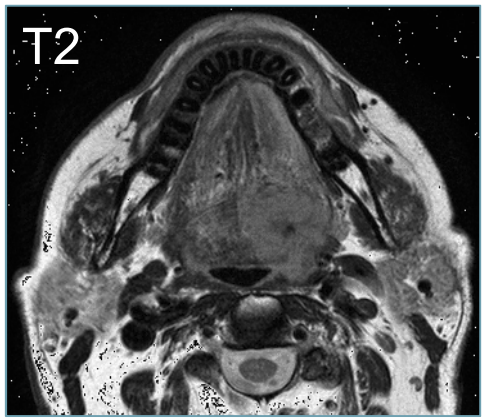

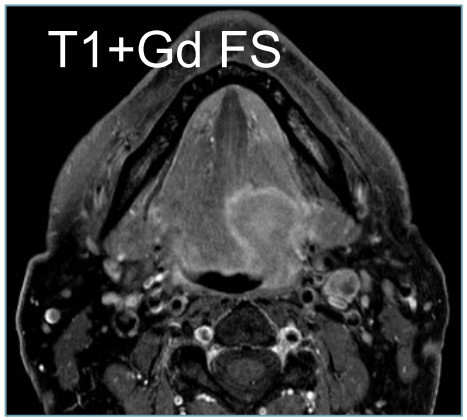

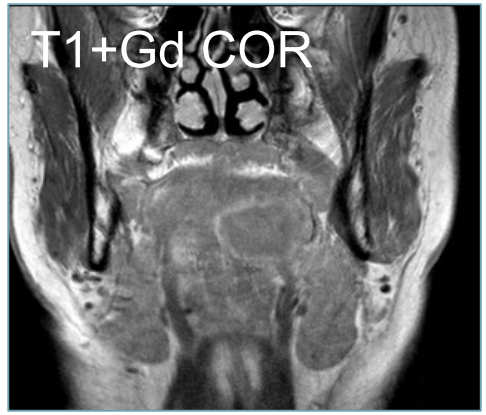

Squamous Cell Carcinoma of the base of the tongue

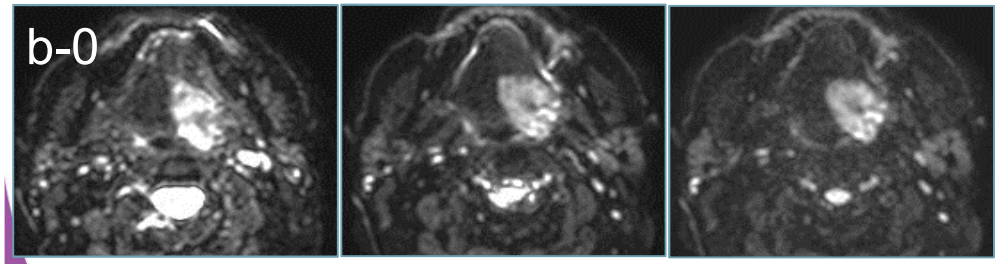

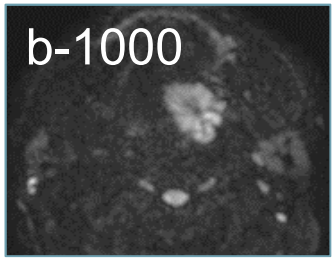

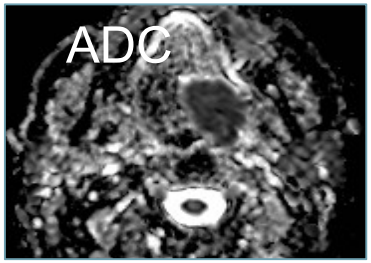

Courtesy J.W. Casselman

ESTRO School

DWI – Therapy monitoring

Percentage of voxels with significantly increased ADC as a biomarker for early prediction of treatment response in patients with NSCLC

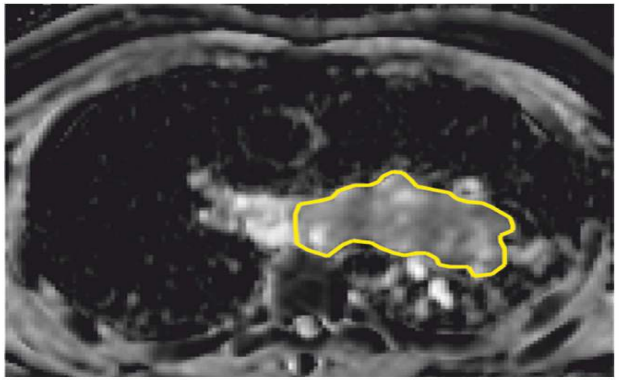

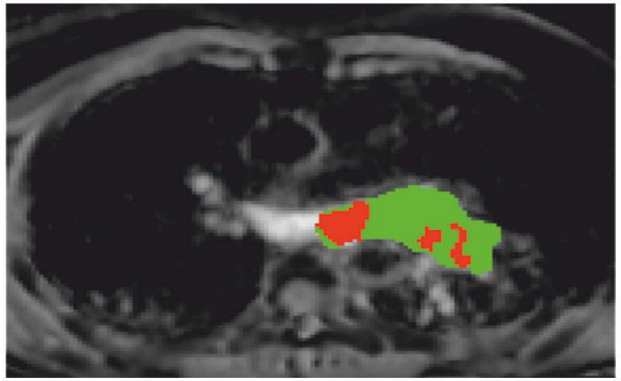

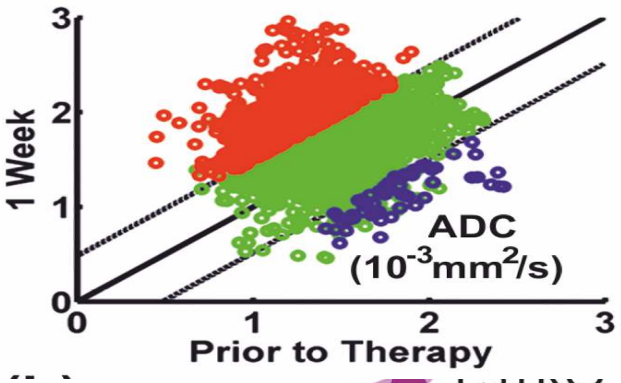

Reischauer et al. *Early Treatment Response in Non-Small Cell Lung CancerPatients Using Diffusion-Weighted Imaging and Functional Diffusion Maps – A Feasibility Study PlosOne*2014

DWI – Therapy monitoring

Percentage of voxels with significantly increased ADC as a biomarker for early prediction of treatment response in patients with NSCLC

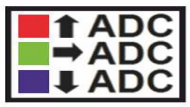

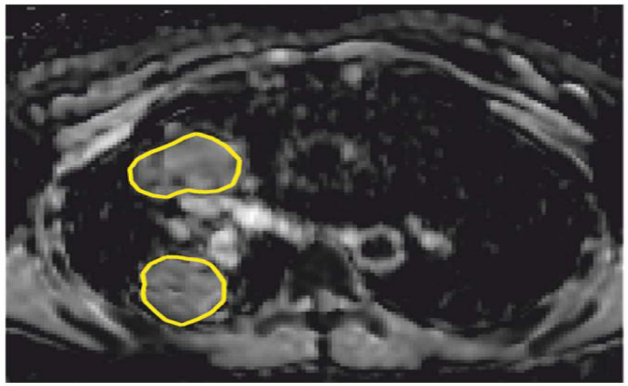

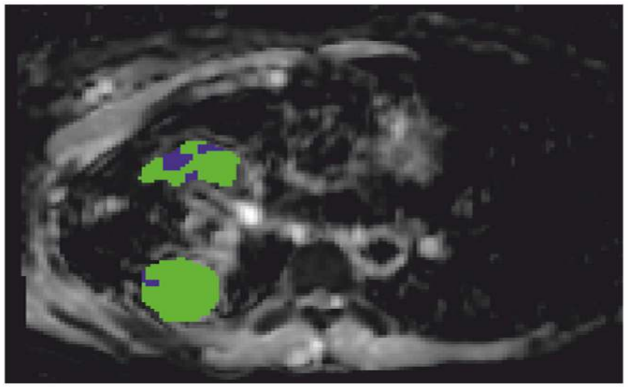

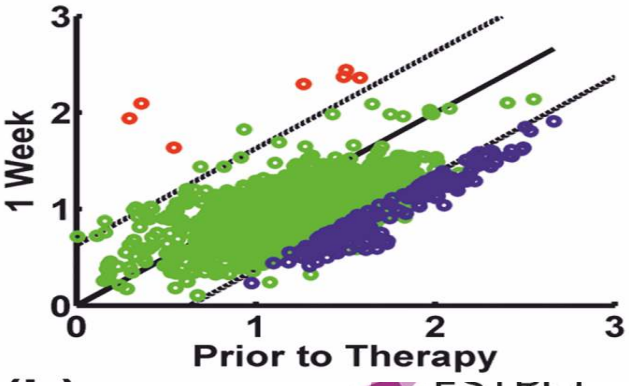

Reischauer et al. *Early Treatment Response in Non-Small Cell Lung CancerPatients Using Diffusion-Weighted Imaging and Functional Diffusion Maps – A Feasibility Study PlosOne*2014

ESTRO School

Six principal axes: A second look

DWI assesses also preferential direction of movement of water molecules

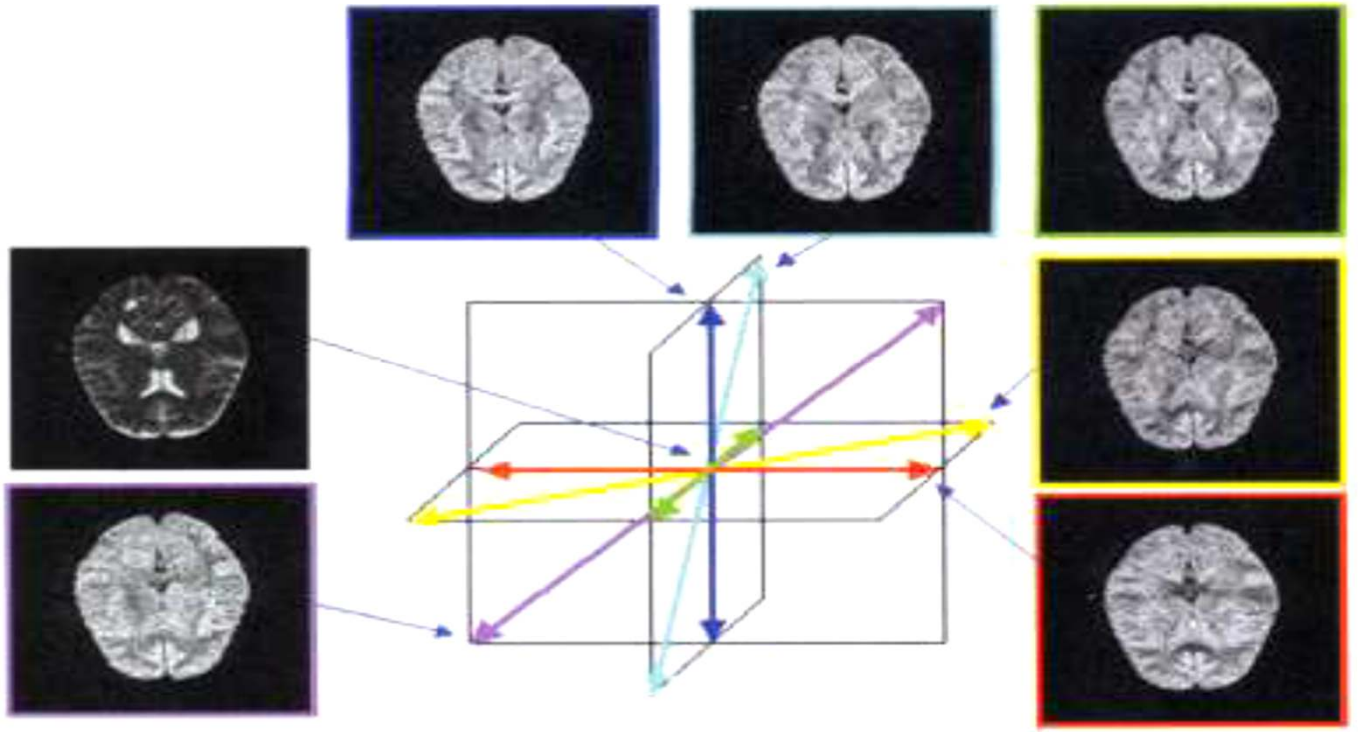

ESTRO School

Fiber tracking with Diffusion Tensor Imaging

- White matter pathways estimation based on voxel-wise estimates of fiber orientations
- Tractography and fractional anisotropy

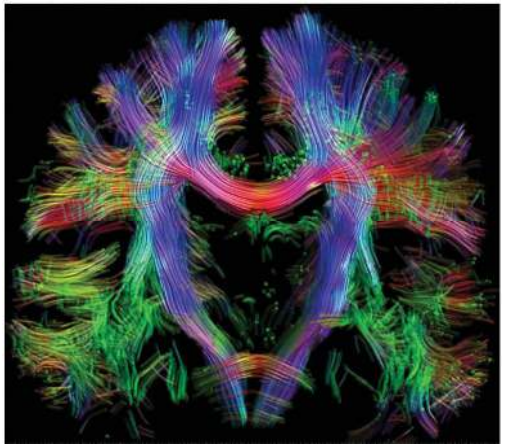

Tensor imaging/ tractography

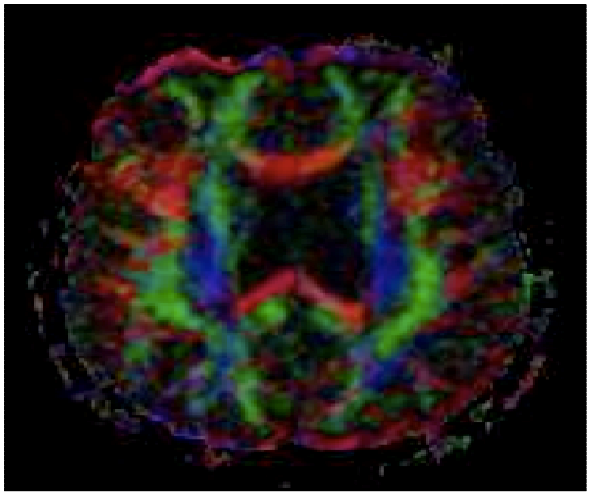

Fractional anisotropy

ESTRO School

Quantifying disorder in fiber arrangement

- Diffusion: fractional anisotropy

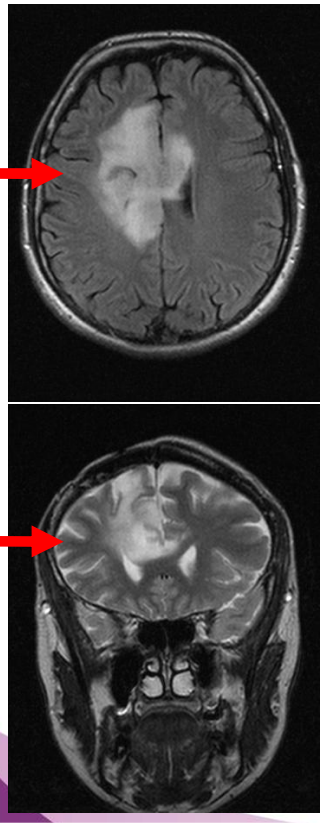

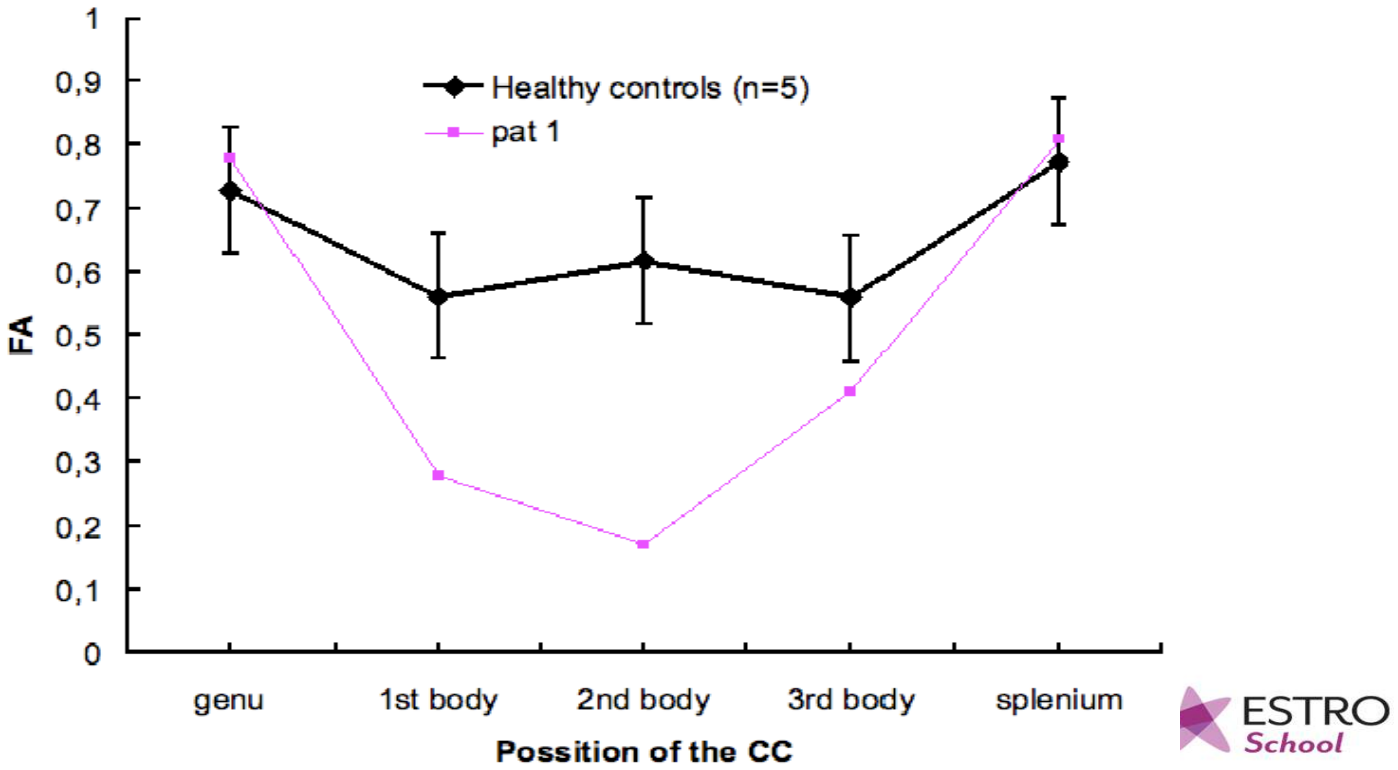

ESTRO School

Disturbance in fiber architecture by tumors

Control

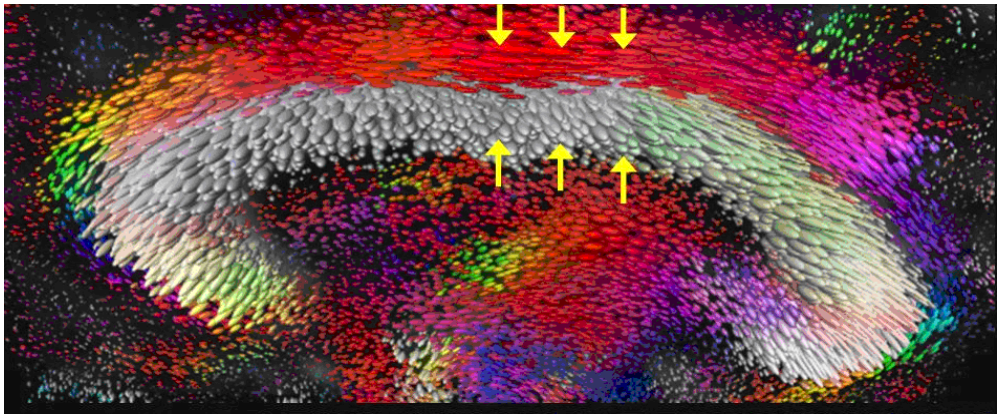

Patient

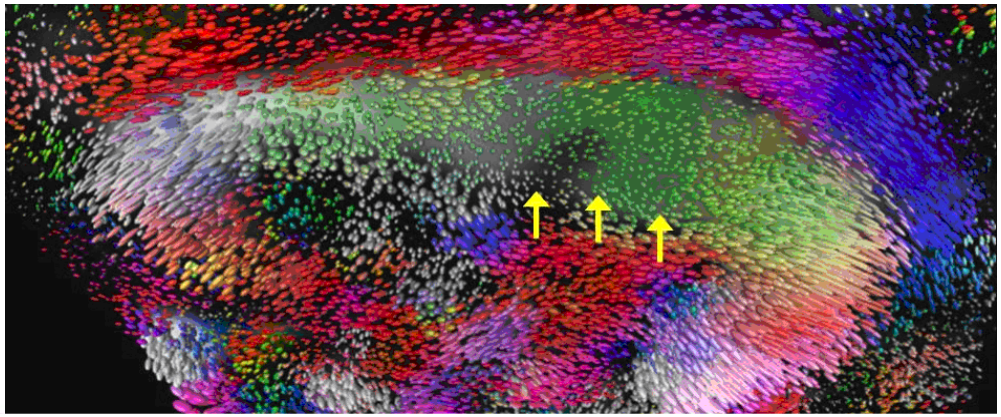

Stieltjes et al.
Neuroimage 2006

ESTRO School

Glioma: Inapparent CC infiltration

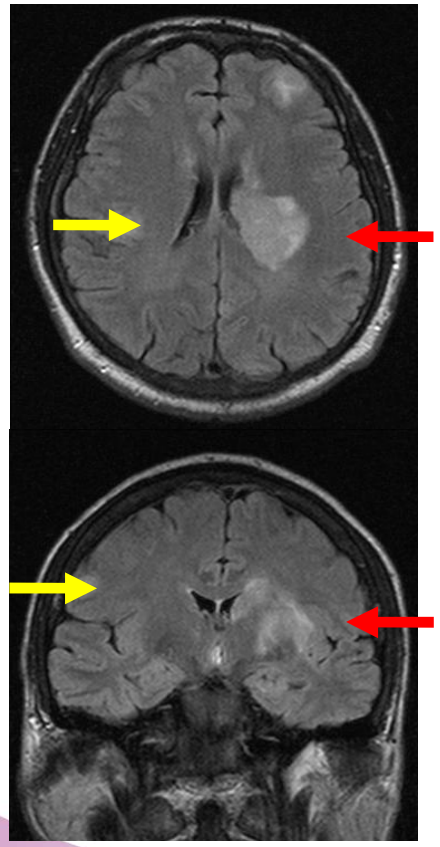

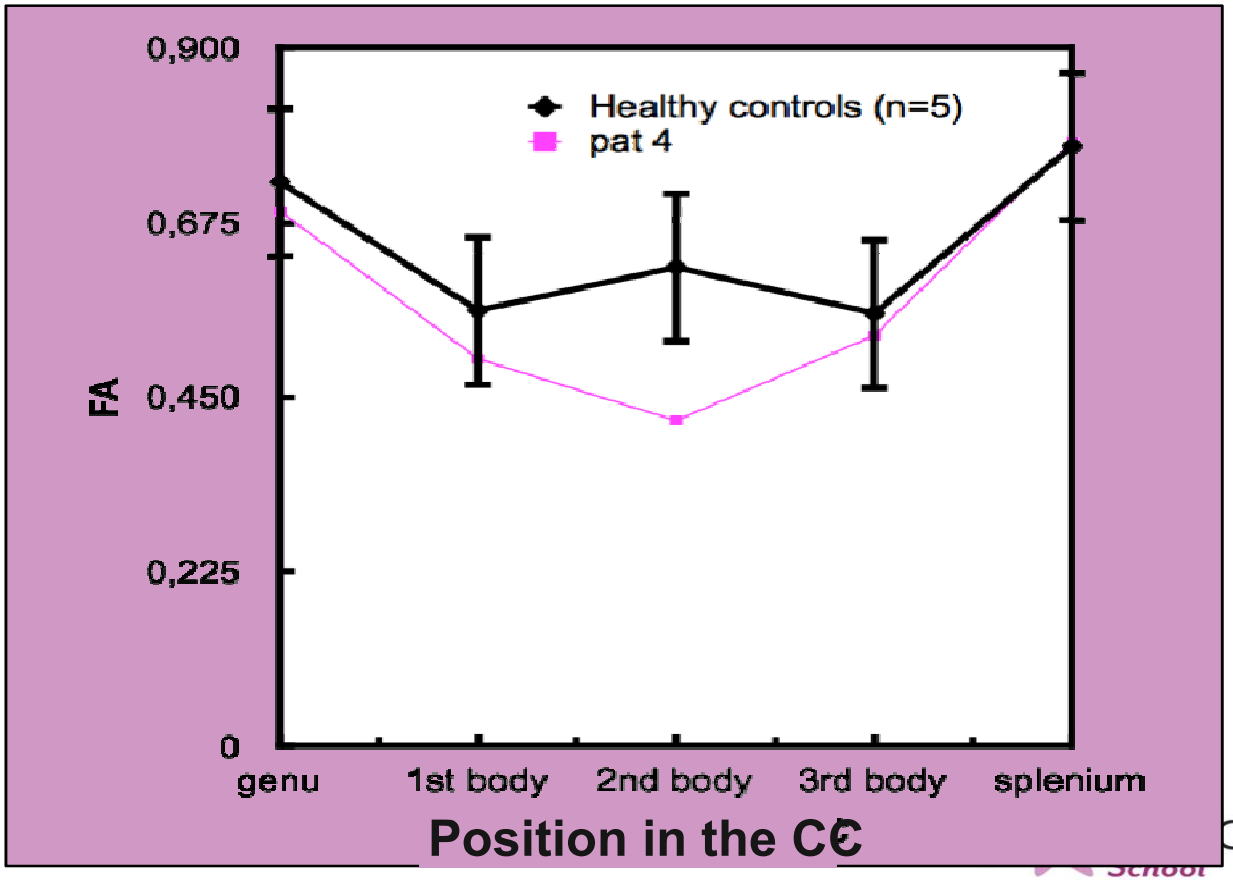

DWI

- Why is the diffusion faster on the left?

ESTRO School

Tissue differentiation

Gadoxetate MRI

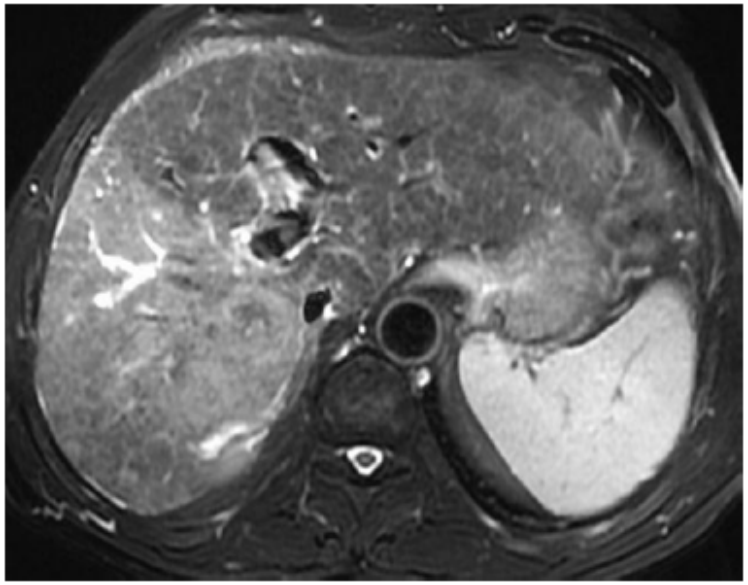

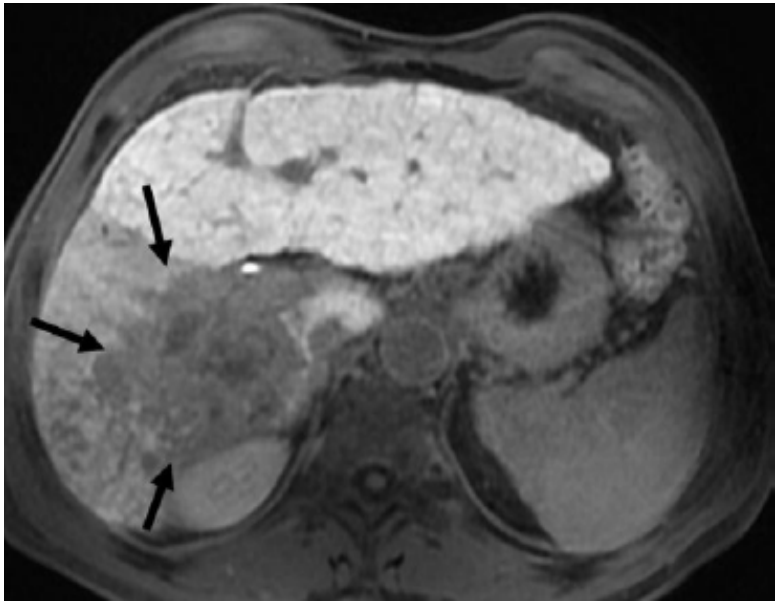

Hepatocellular carcinoma. Decreased function around the tumor. Preserved function in left lobe

Ünal et al, *Liver function Assessment by Magnetic Resonance Imaging*
Seminars in Ultrasound, CT, and MRI

ESTRO School

MR-Spectroscopy
Physiologic metabolites in the brain

- NAA: Neuronal marker
  - N-acetyl-L-aspartate
  - δ = 2.01 ppm
- Cr: Energy store
  - (Phospho-) Creatine
  - δ = 3.03 ppm and 4 ppm
- Cho: Membrane turnover
  - Phosphocholin, Glycerophosphorylcholin
  - δ = 3.22 ppm

ESTRO School

Brain: pathologic metabolites

- Lactate: Anaerobic glycolysis
  - Hypoxic areas
  - Macrophages
  - δ = 1.33 ppm doublet (inverted at 135 ms)
- Lipids (fatty acids): Necrosis
  - δ = 1.2 - 1.4 ppm

ESTRO School

?

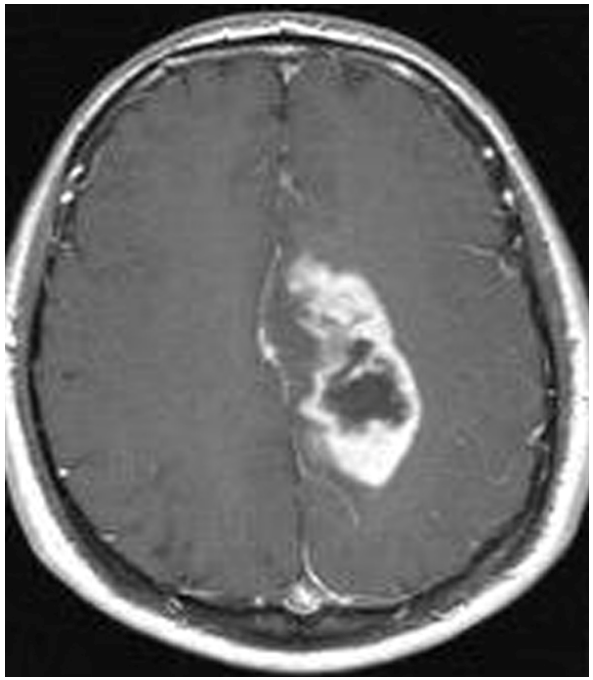

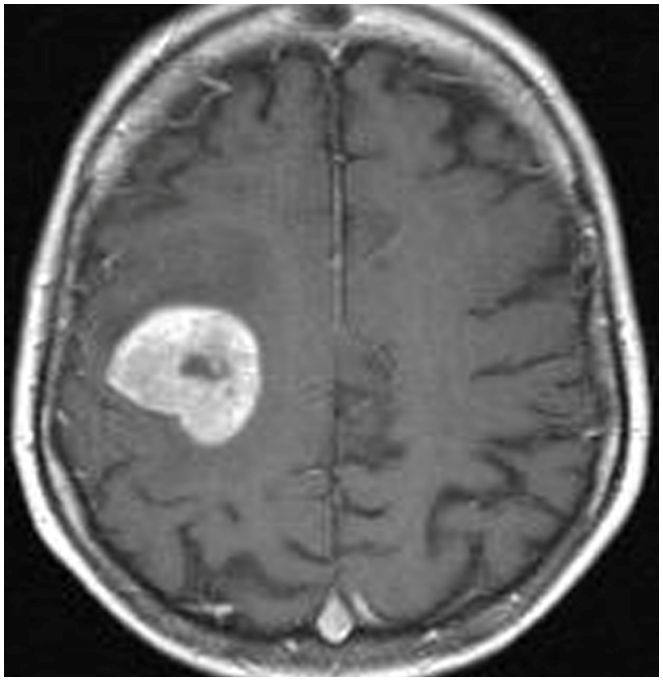

Typical spectra

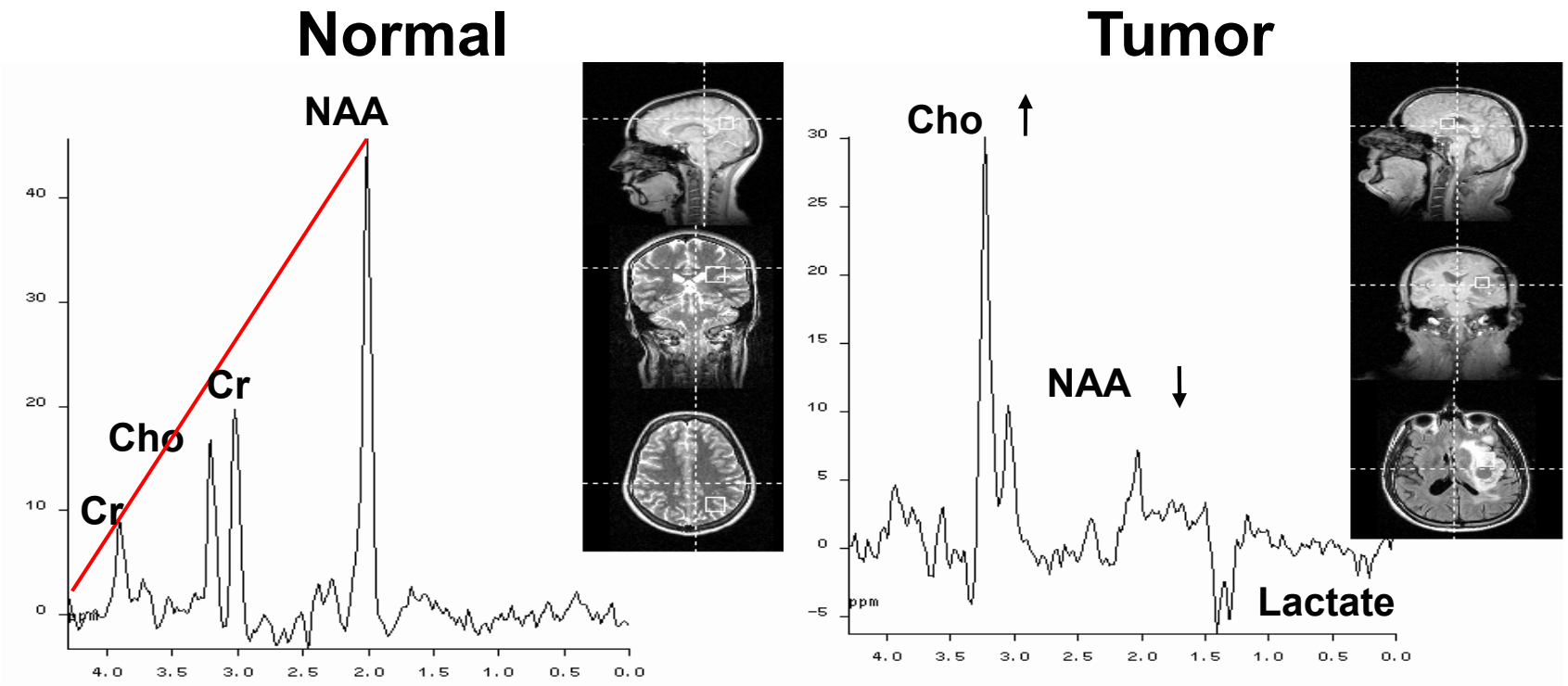

Bachert et al., Radiologe 2004

ESTRO School

Metastasis

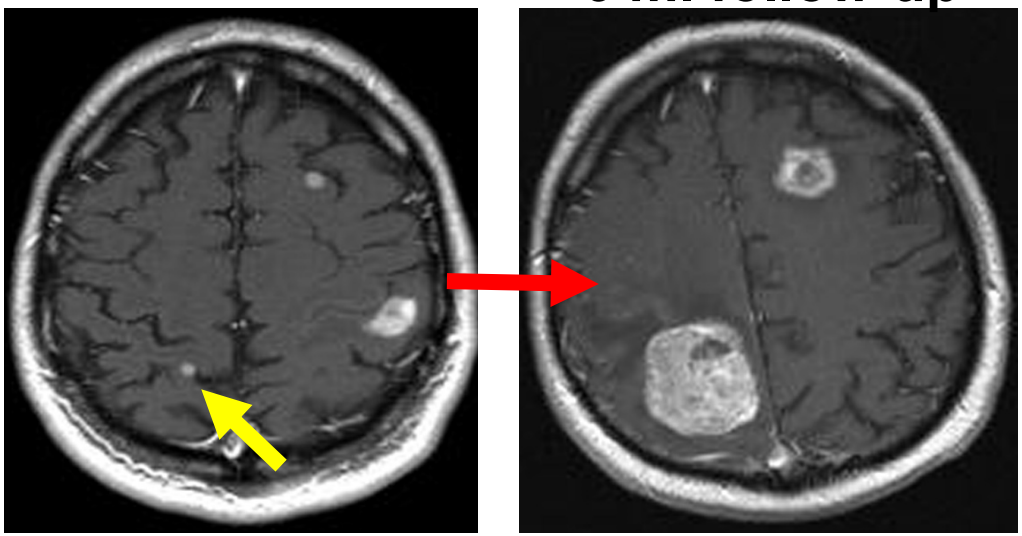

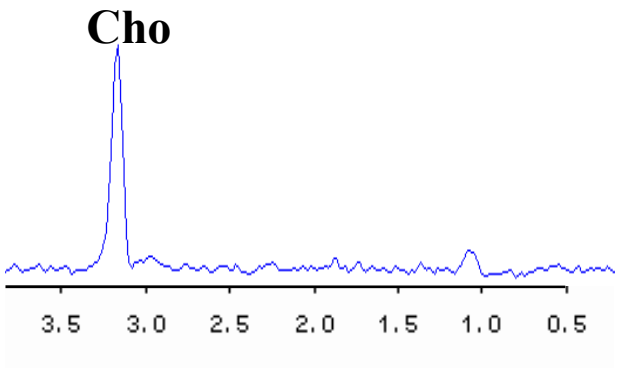

Schlemmer et al., AJNR 2001; Weber et al., Radiologe 2003

ESTRO School

Grade II glioma

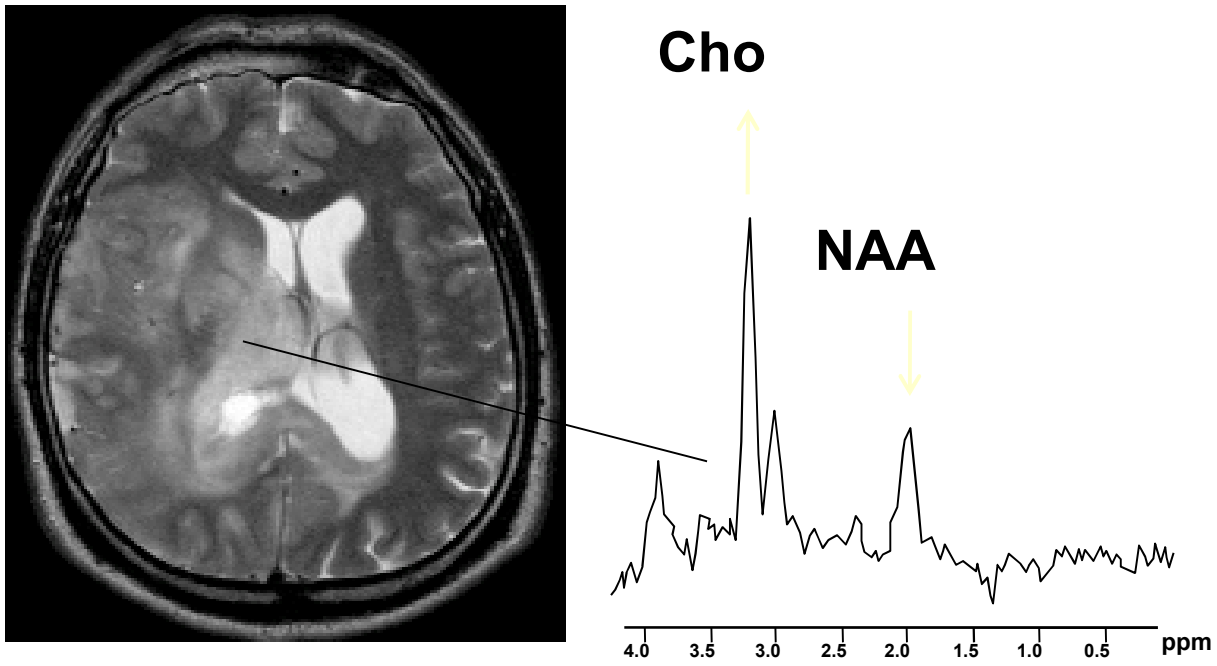

Glioblastoma ?

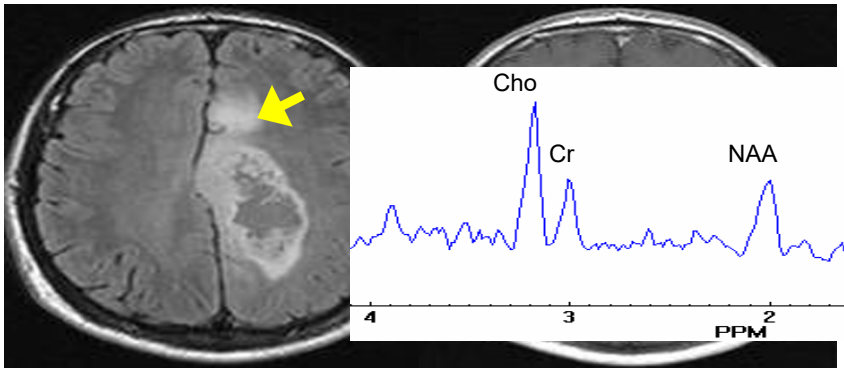

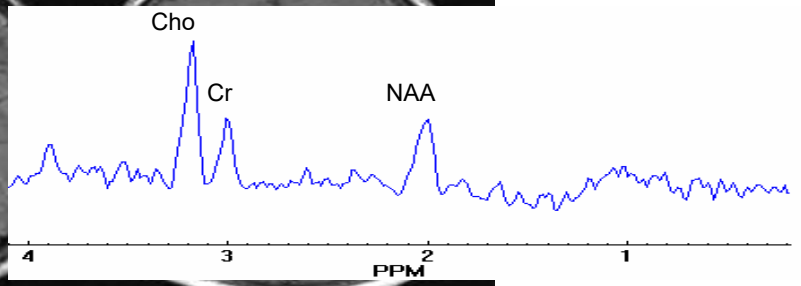

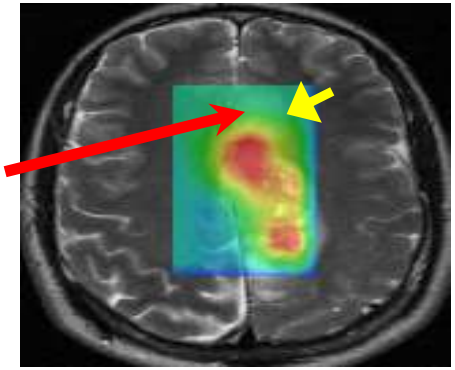

FLAIR CE T1 Cho / Cr

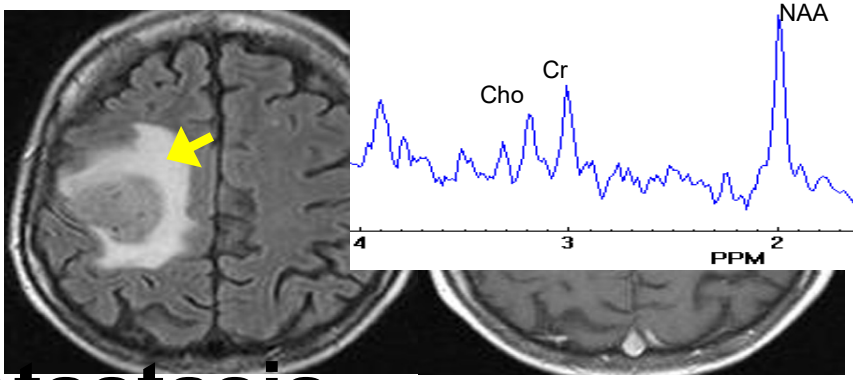

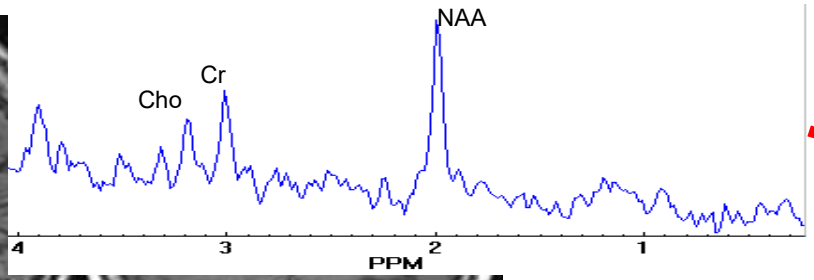

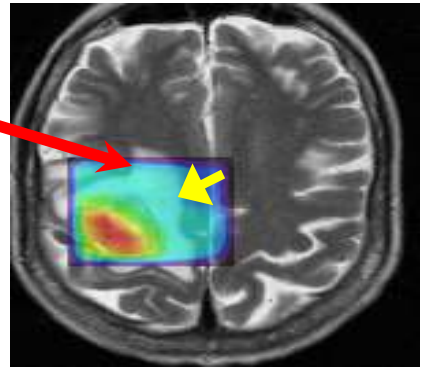

Metastasis

FLAIR CE T1 Cho / Cr

ESTRO School

Grading in gliomas

Grade II glioma

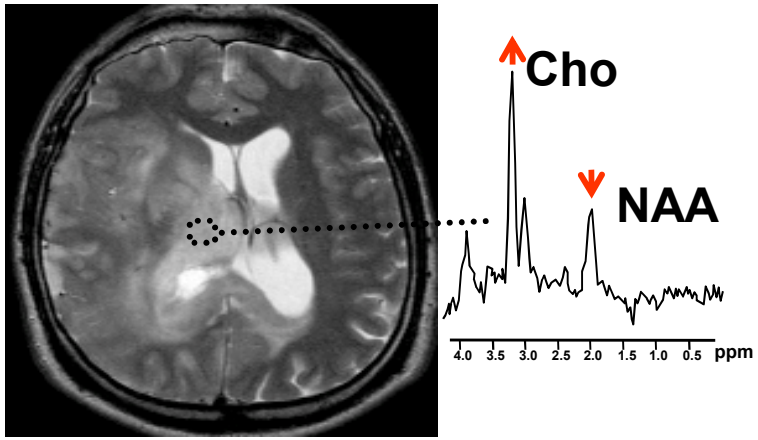

Grade III / IV glioma

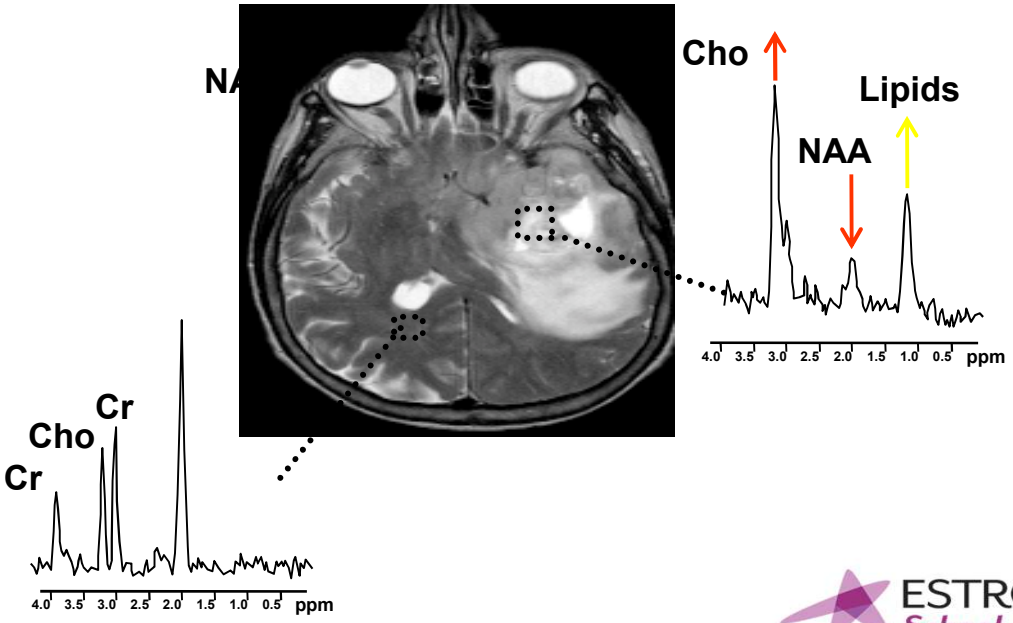

H.-P. Schlemmer,Heidelberg

ESTRO School

Tumor hetereogeneity

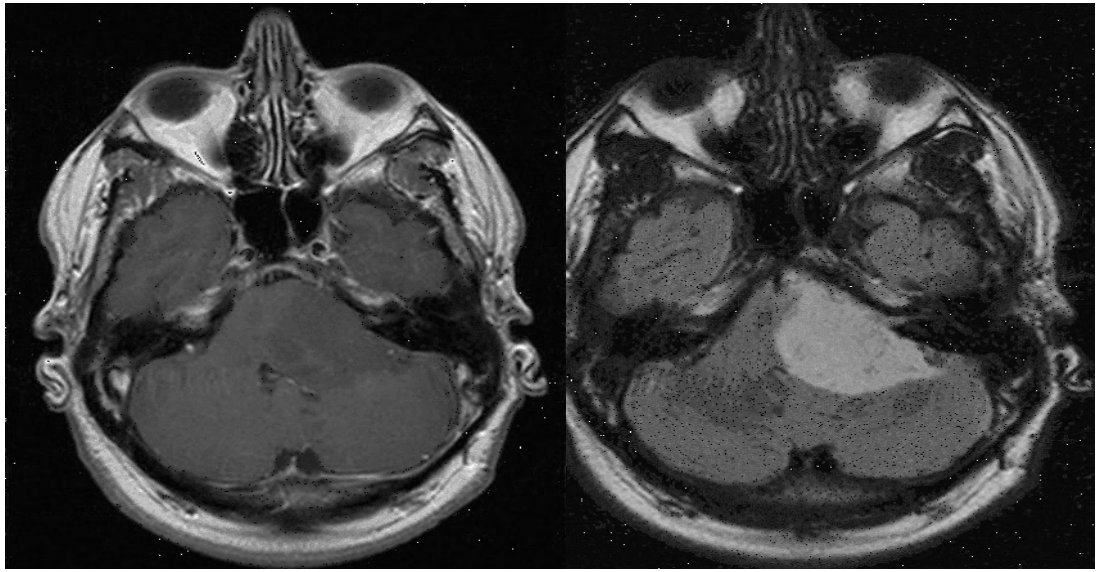

FLAIR

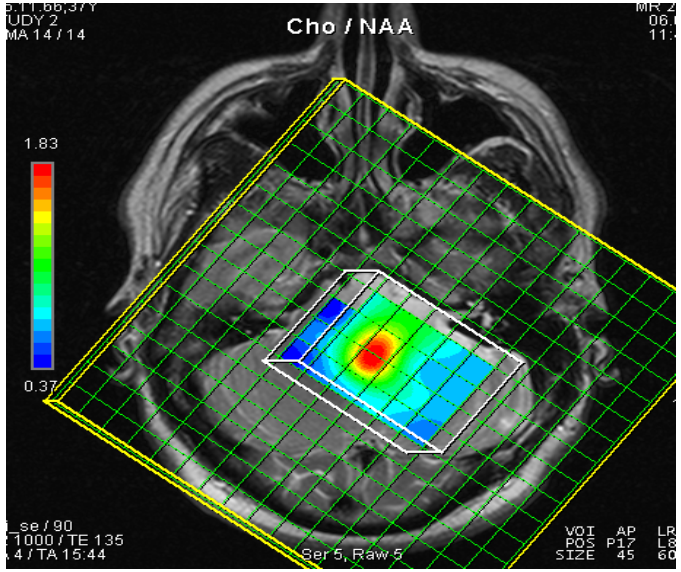

1H-MRS (Choline/NAA)

ESTRO School

Radiation injury

Radiation Injury

- Few days after RTh: acute
- Weeks to few months after Rth: early delayed
- Months to years after RTh: late delayed

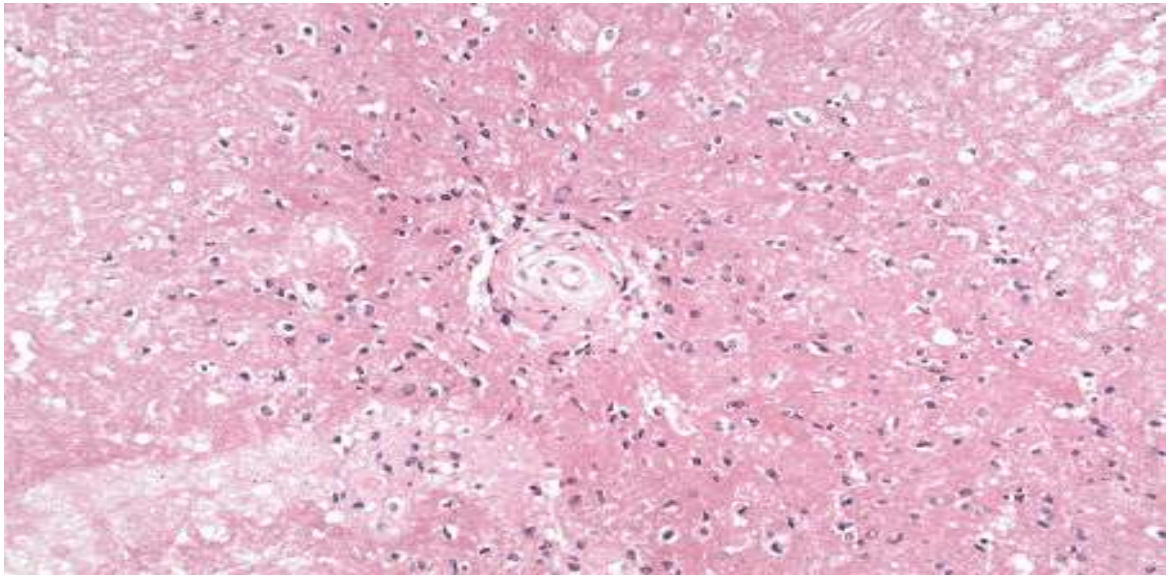

radiation necrosis: HE. 25x

ESTRO School

Radiation Injury: Pathology

- Damage of oligodendrocytes:
  - Demyelination
- Damage of endothelial cells:
  - Vascular thrombosis
  - Necrosis
  - Altered permeability
- Unspecific MRI findings:
  - Prolongation of T_1 and T_2
  - +/- contrast enhancement

ESTRO School

Enhancing lesion post radiotherapy

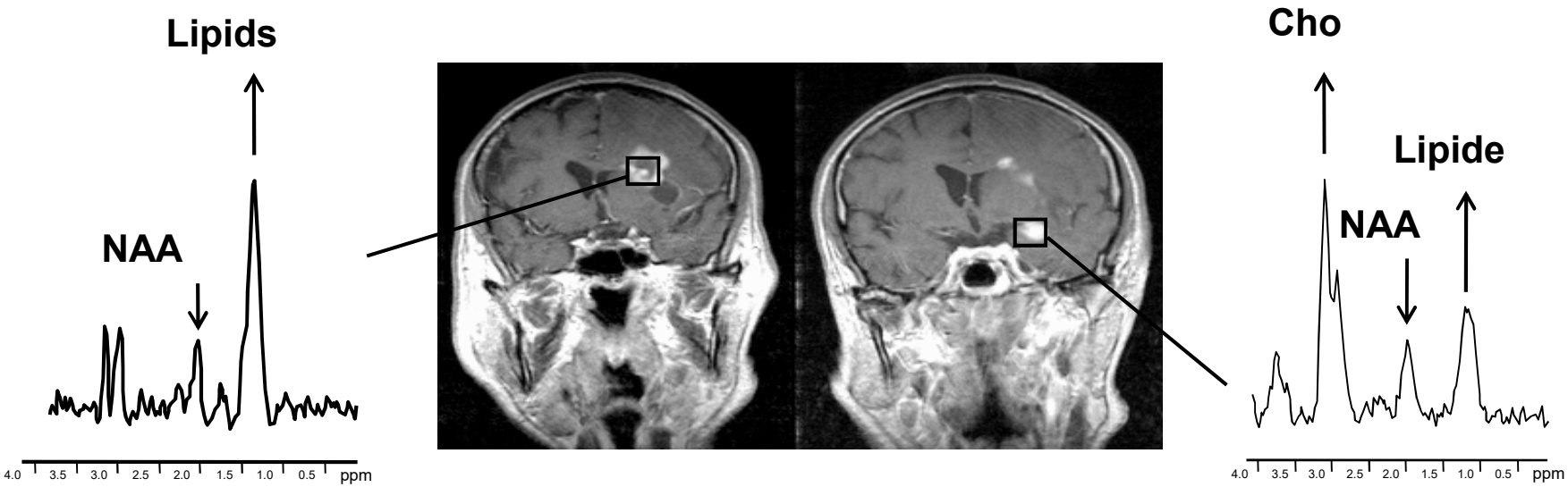

Radiation damage **Tumor progression**

ESTRO School

MRSI in brain lesions: Summary

Pathology	Cho/Cr	Cho/Cho(n)	NAA/Cr	Cho peritumoral
High grade glioma	++	++	– –	+
Low grade glioma	+	+	–	**~**
Radiation necrosis	–	–	–	–
Metastasis	+	+	––	–
Lymphoma	+	+	––	–

Law 2004

ESTRO School

Motion

ESTRO School

Motion

- MRI
  - Fast MRI techniques
  - Real time 2D MRI
  - …real time 3D MRI

ESTRO School

Real time 2D MRI – Respiration

- Tumor and atelectasis

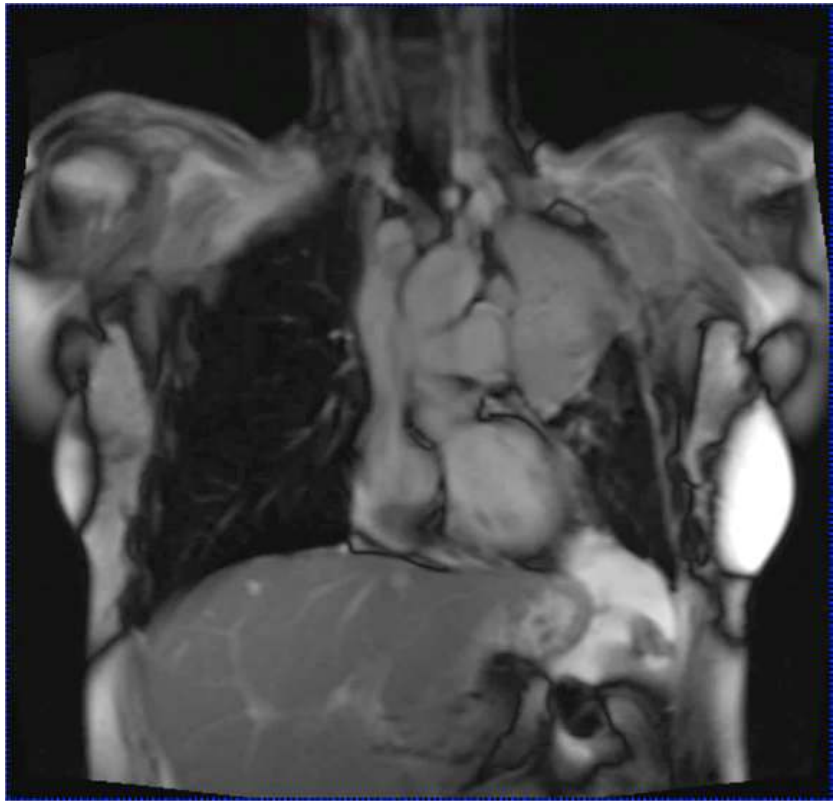

4D MRI – Respiration

excellent soft tissue contrast
multiple respiratory exercises
no rebinning necessary

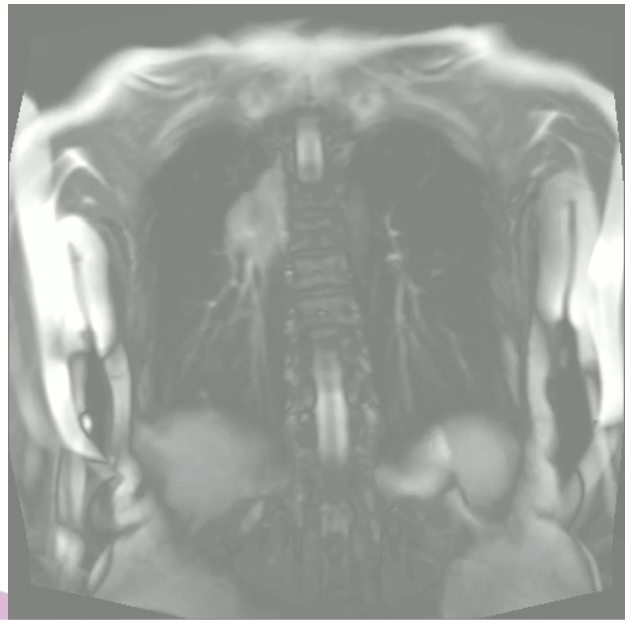

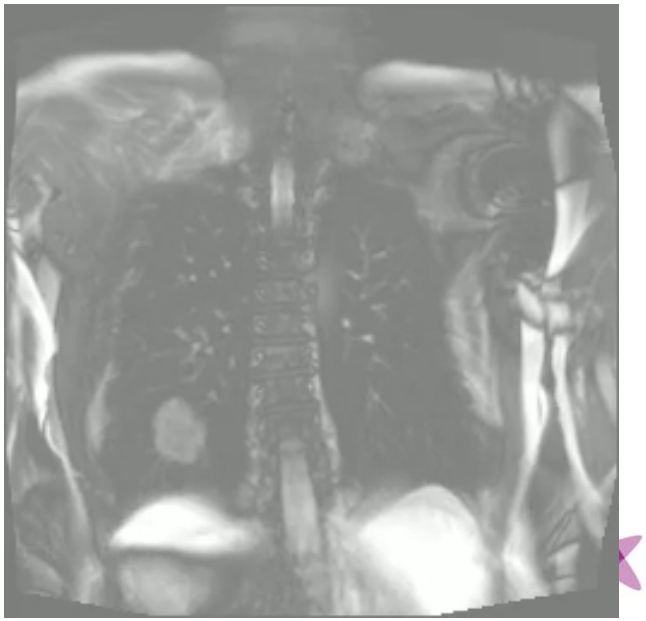

ESTRO School

4D MRI – Respiration

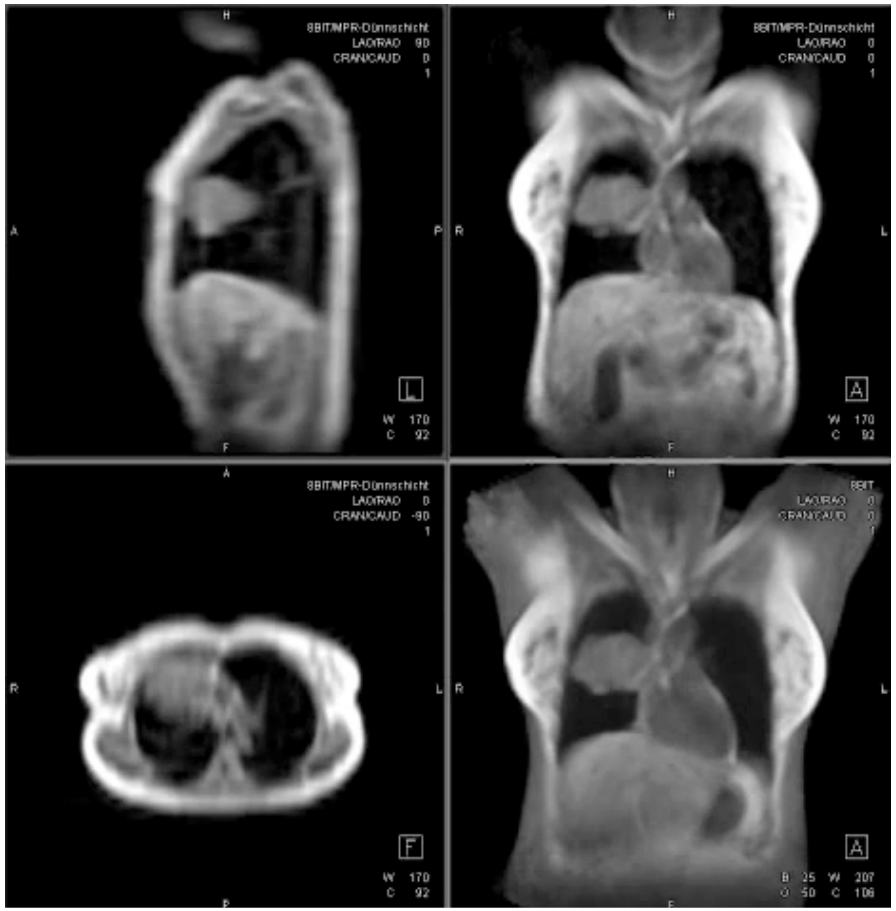

ESTRO School

Take home: Functional imaging

- Information beyond anatomy
  - Movement
  - Microstructure
  - Physiology
  - Biology
- Ready to use:
  - Movement analysis
  - Diffusion-weighted imaging
- Need for evidence base in RT planning:
  - Spectroscopy
  - Dynamic perfusion MRI
  - Diffusion tensor imaging

ESTRO School

ESTRO
School

ESTRO
School

Morphologic imaging techniques

Stefan Delorme

ESTRO School

Acknowledgements

Marc Kachelrieß, Heidelberg
Michael Bock, Freiburg
Bettina Beuthien-Baumann, Heidelberg

ESTRO School

Outline

- Computed tomography
  - ➢How it works
  - ➢Strengths
  - ➢Weaknesses
- Ultrasound
  - ➢How it works
  - ➢Strengths
  - ➢Weaknesses
- Positron emission tomography
  - ➢How it works
  - ➢Strengths
  - ➢Weaknesses

ESTRO School

Outline

- Computed tomography
  - ➢How it works
  - ➢Strengths
  - ➢Weaknesses
- Ultrasound
  - ➢How it works
  - ➢Strengths
  - ➢Weaknesses
- Positron emission tomography
  - ➢How it works
  - ➢Strengths
  - ➢Weaknesses

ESTRO School



Sir Godfrey Hounsfield

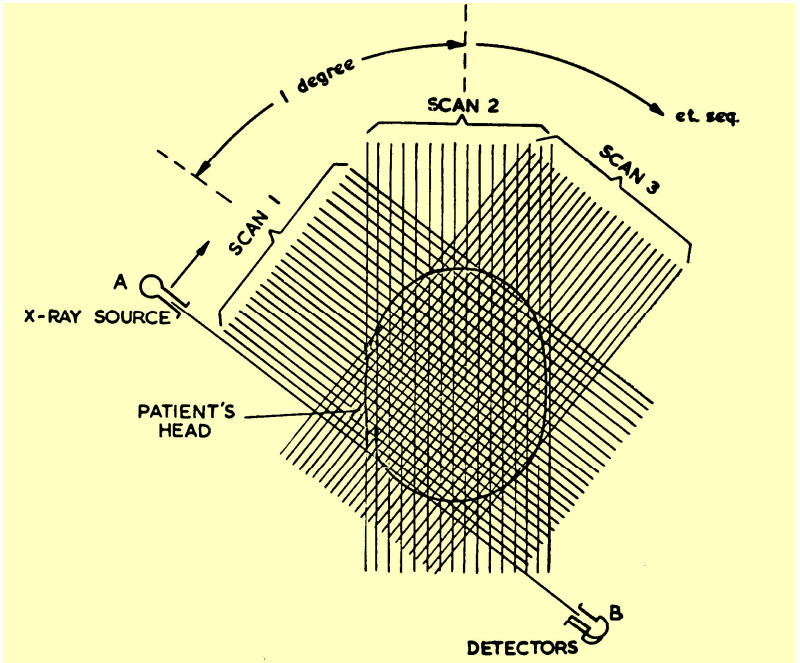

FIG. 3.
Simplified illustration of the scanning sequence.

17

Hounsfield’s experimental setup



ESTRO School

Generation 1

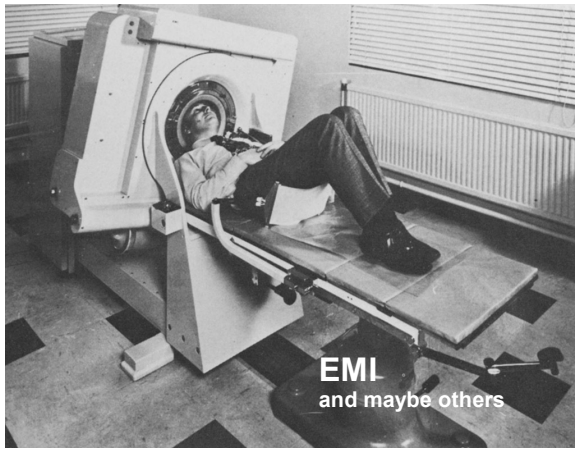



Generation 1

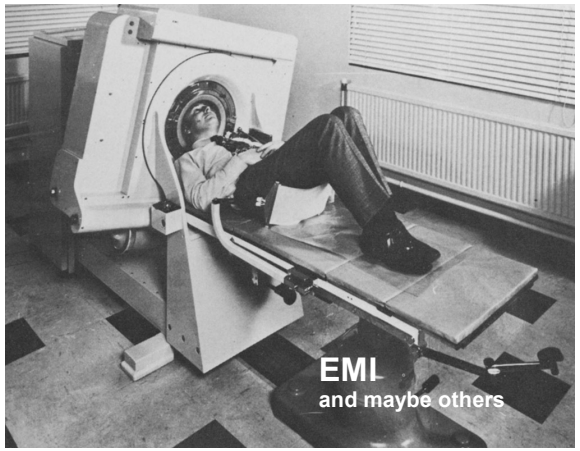



Generation 1

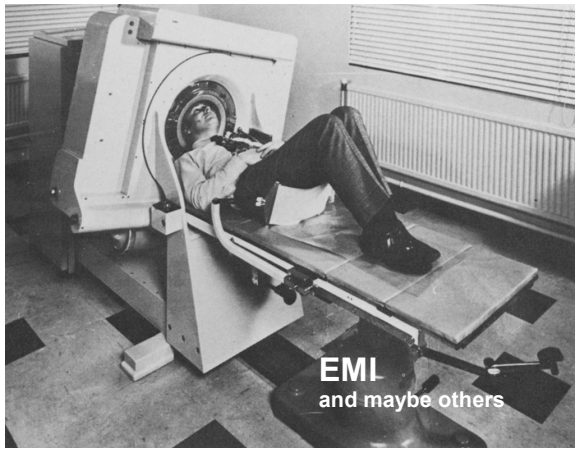



Generation 1

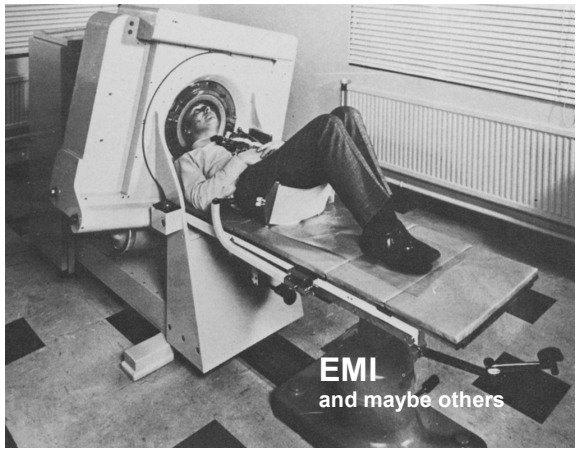

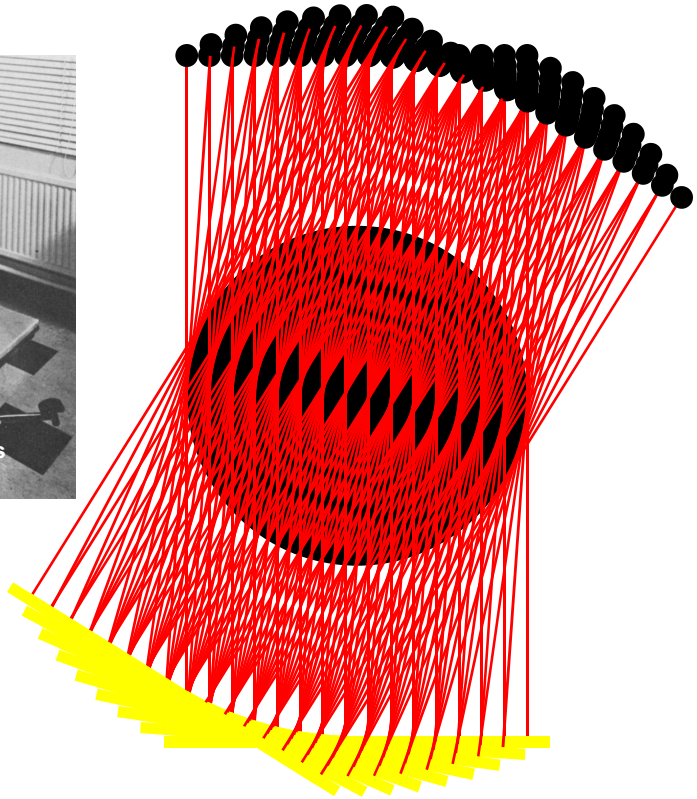

ESTRO School

Generation 3

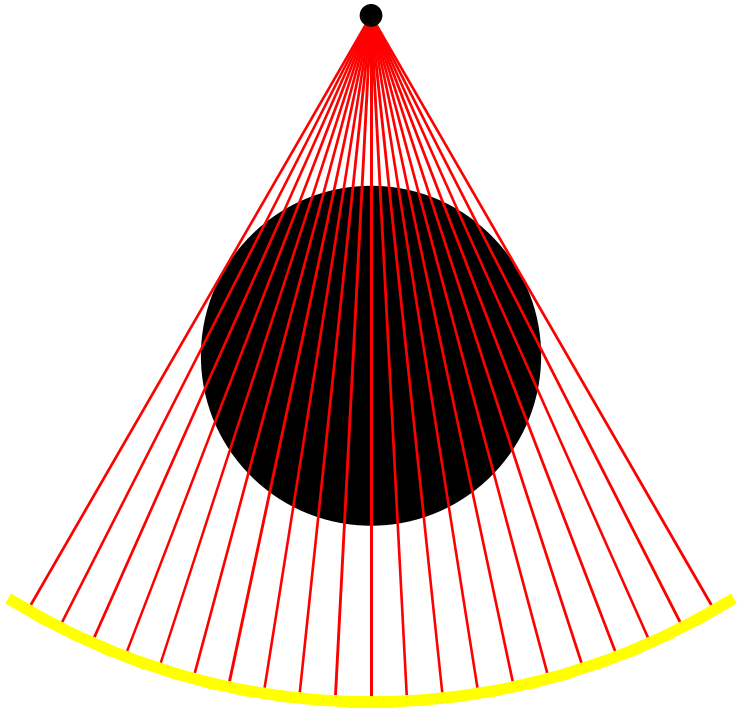

Generation 3

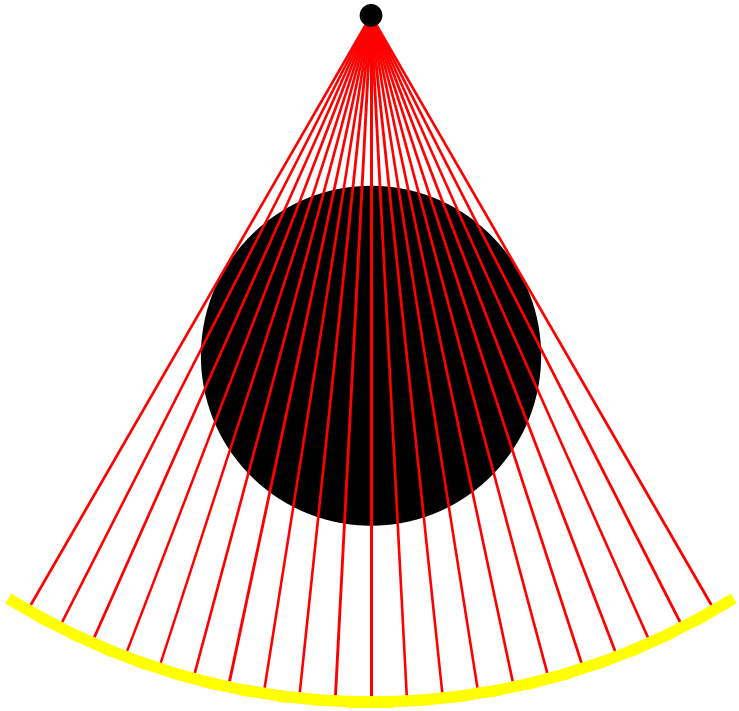

Generation 4

Elscint
Picker
Marconi
Philips

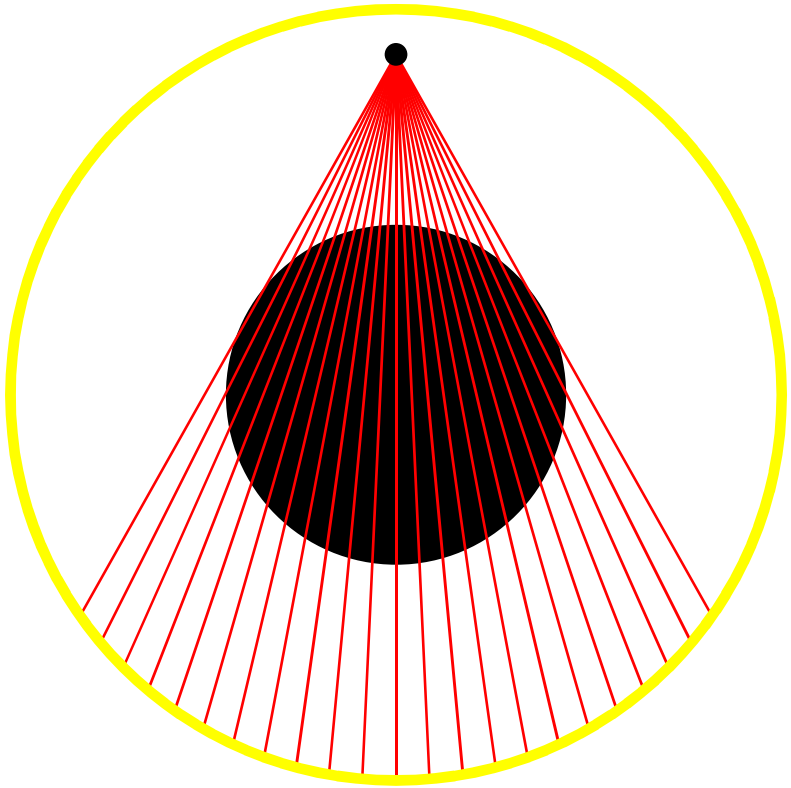

ESTRO School

Generation 4

Elscint
Picker
Marconi
Philips

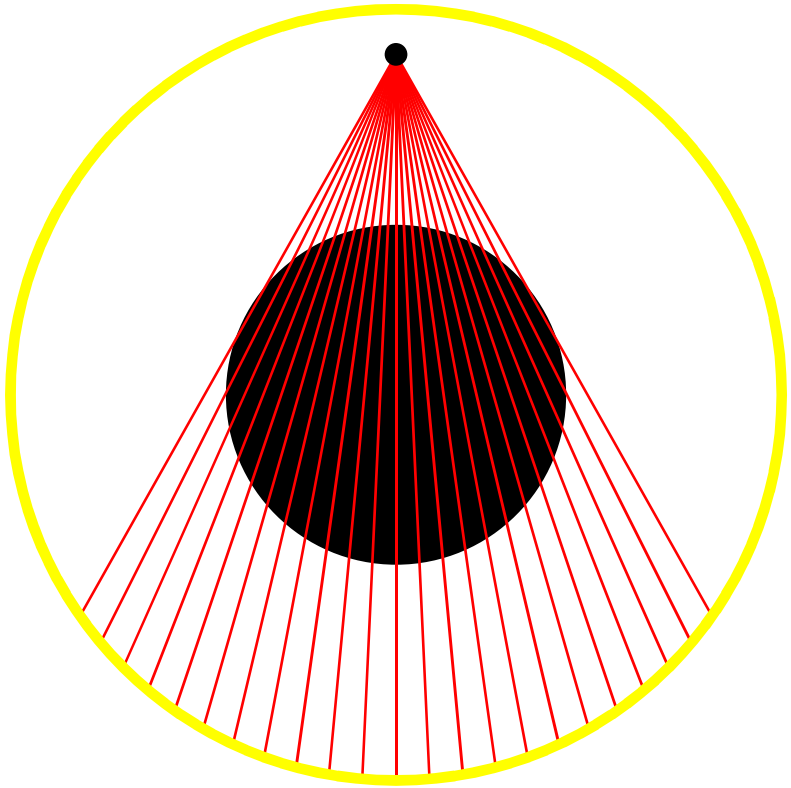

ESTRO School



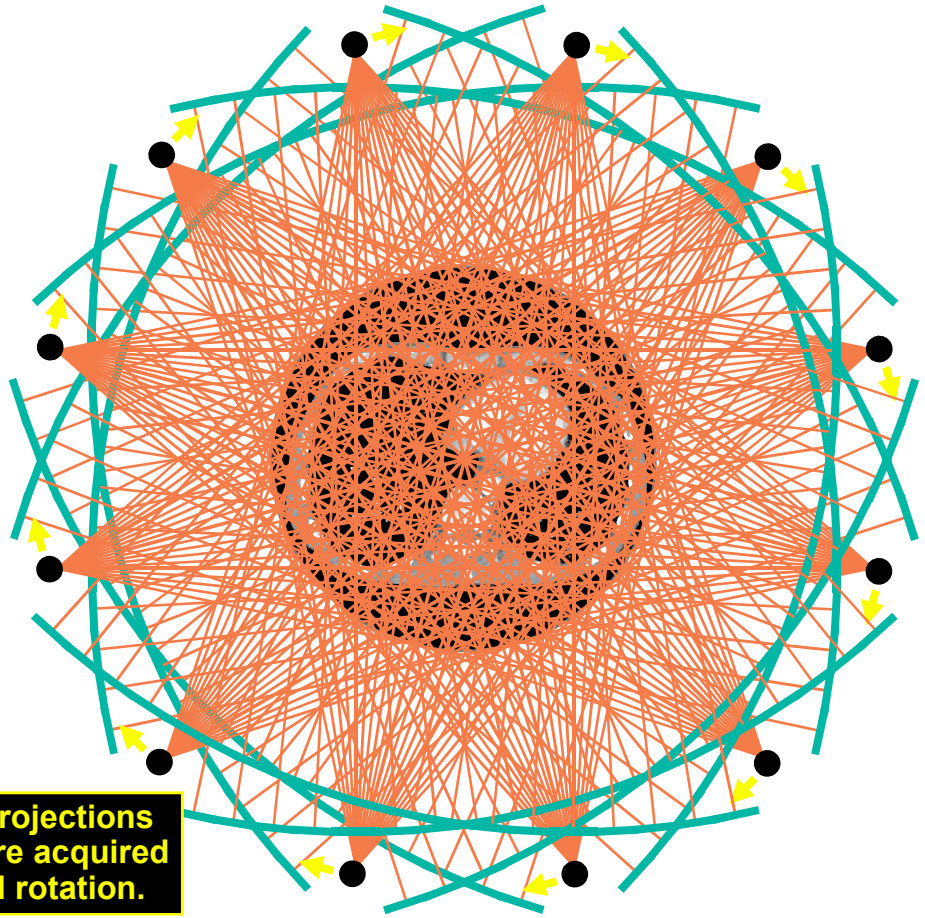

In the order of 1000 projections with 1000 channels are acquired per detector slice and rotation.

ESTRO School

Axial Geometry (z-Direction)

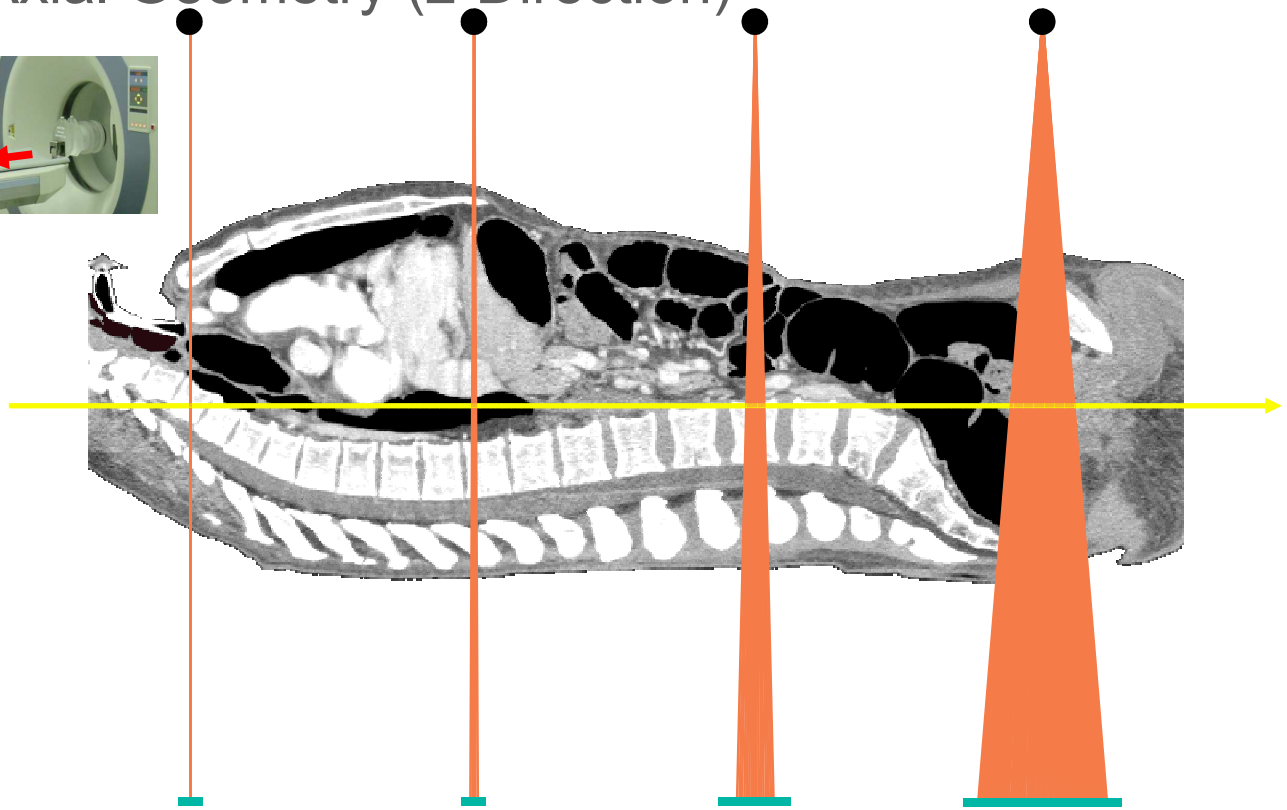

<1998: *M*=1 **1998: *M*=4** **2002: *M*=16** **2006: *M*=64**

ESTRO School

Multi-Threaded CT Scanners and Dual-Source-CT

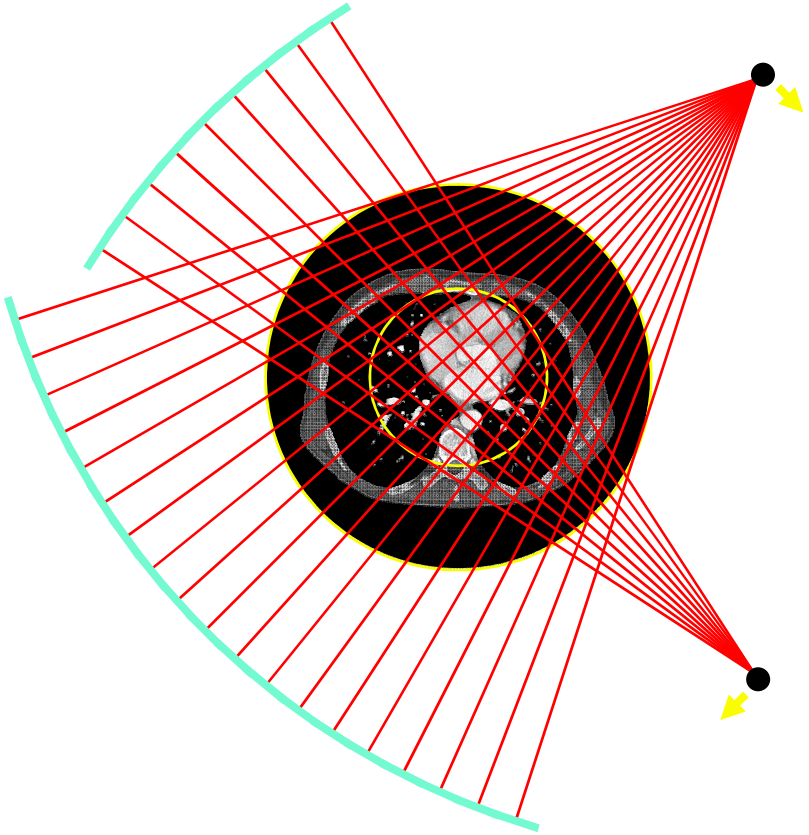

ESTRO School

Dual-source CT

Siemens 2·2·96=384-slice dual source cone-beam spiral CT(2013)

525 views (1050 readings) per rotation in 0.25 s

2·96×(920+640) two-byte channels per view

1,200 MB/s data transfer rate

up to 4 GB rawdata, 2 GB volume size typical

EMI parallel beam scanner (1972)

180 views per rotation in 300 s

2×160 positions per view

384 B/s data transfer rate

113 kB data size

ESTRO School

Siemens 2·2·96=384-slice
dual source cone-beam spiral CT(2013)

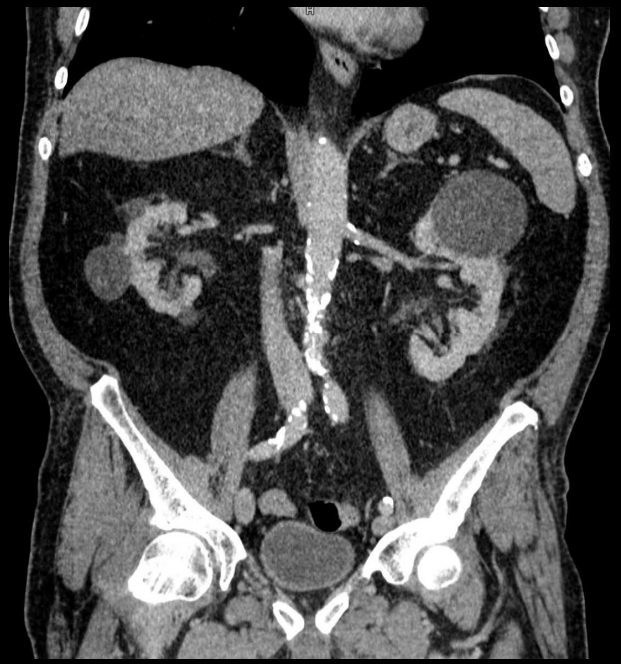

525 views (1050 readings) per rotation in 0.25 s

2·96×(920+640) two-byte channels per view

1,200 MB/s data transfer rate

up to 4 GB rawdata, 2 GB volume size typical

EMI parallel beam scanner (1972)

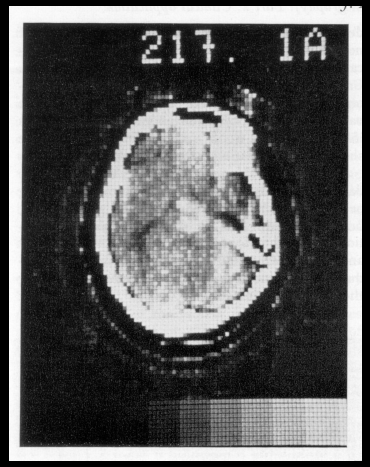

180 views per rotation in 300 s

2×160 positions per view

384 B/s data transfer rate

113 kB data size

ESTRO School

EMI parallel beam scanner (1972)

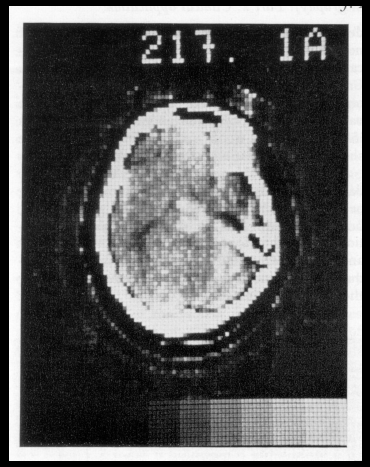

180 views per rotation in 300 s

2×160 positions per view

384 B/s data transfer rate

113 kB data size

Siemens 2·2·96=384-slice dual source cone-beam spiral CT(2013)

525 views (1050 readings) per rotation in 0.25 s

2·96×(920+640) two-byte channels per view

1,200 MB/s data transfer rate

up to 4 GB rawdata, 2 GB volume size typical

ESTRO School

EMI parallel beam scanner (1972)

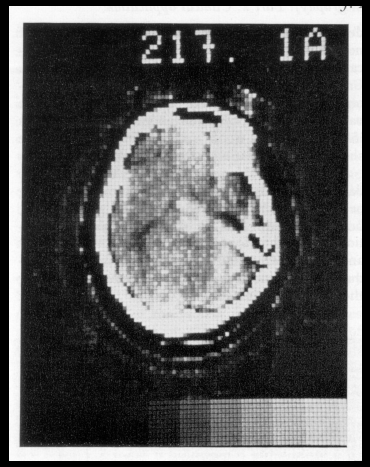

180 views per rotation in 300 s

2×160 positions per view

384 B/s data transfer rate

113 kB data size

Siemens 2·2·96=384-slice dual source cone-beam spiral CT(2013)

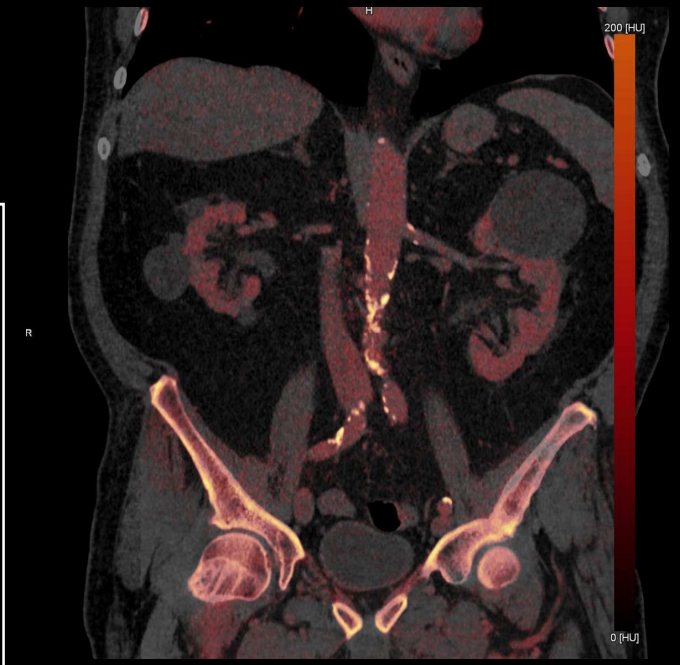

525 views (1050 readings) per rotation in 0.25 s

2·96×(920+640) two-byte channels per view

1,200 MB/s data transfer rate

up to 4 GB rawdata, 2 GB volume size typical

ESTRO School

What is displayed?

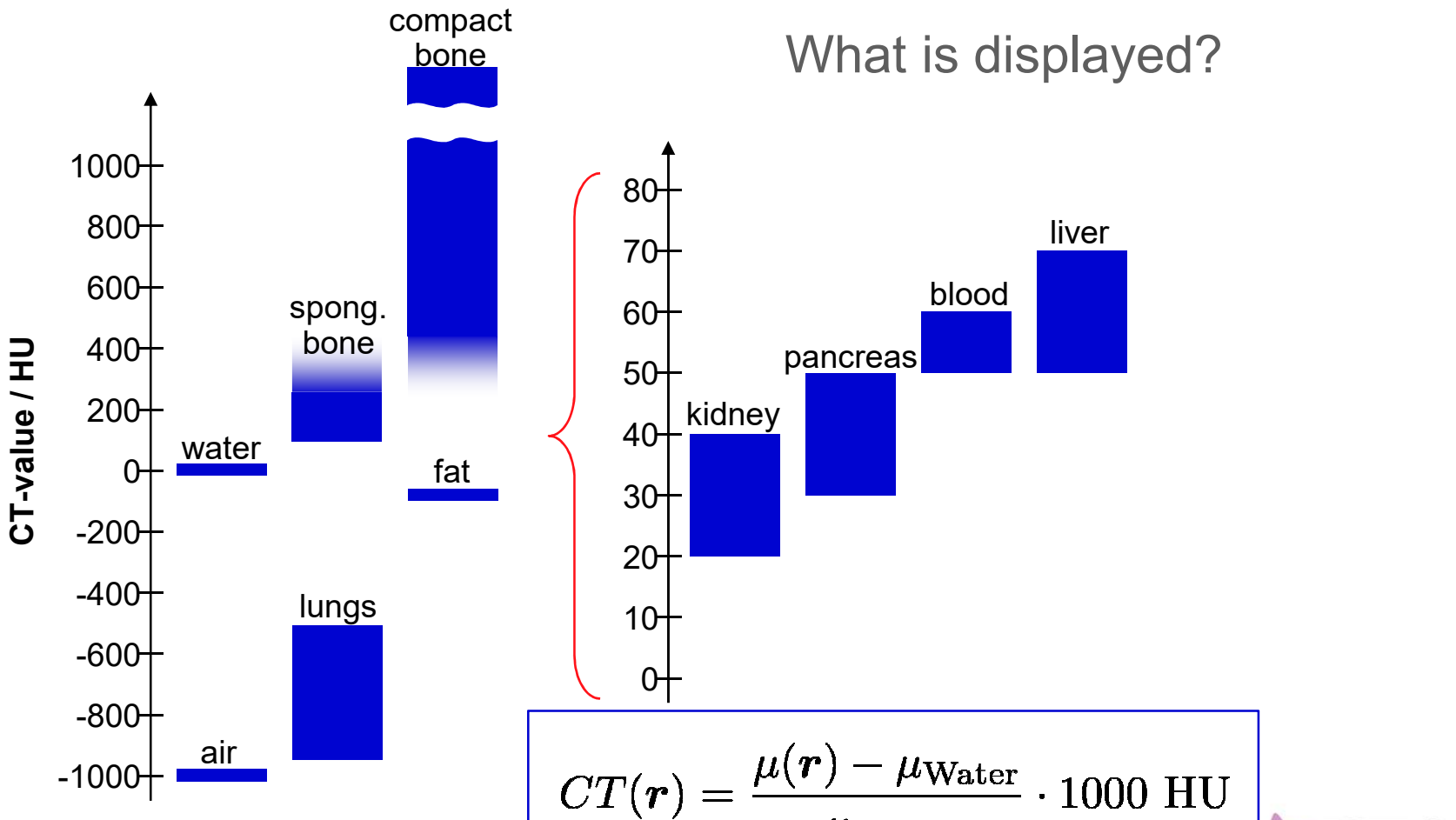

$$CT(\boldsymbol{r}) = \frac{\mu(\boldsymbol{r}) - \mu_{\text{Water}}}{\mu_{\text{Water}}} \cdot 1000 \text{ HU}$$

ESTRO School

Windowing

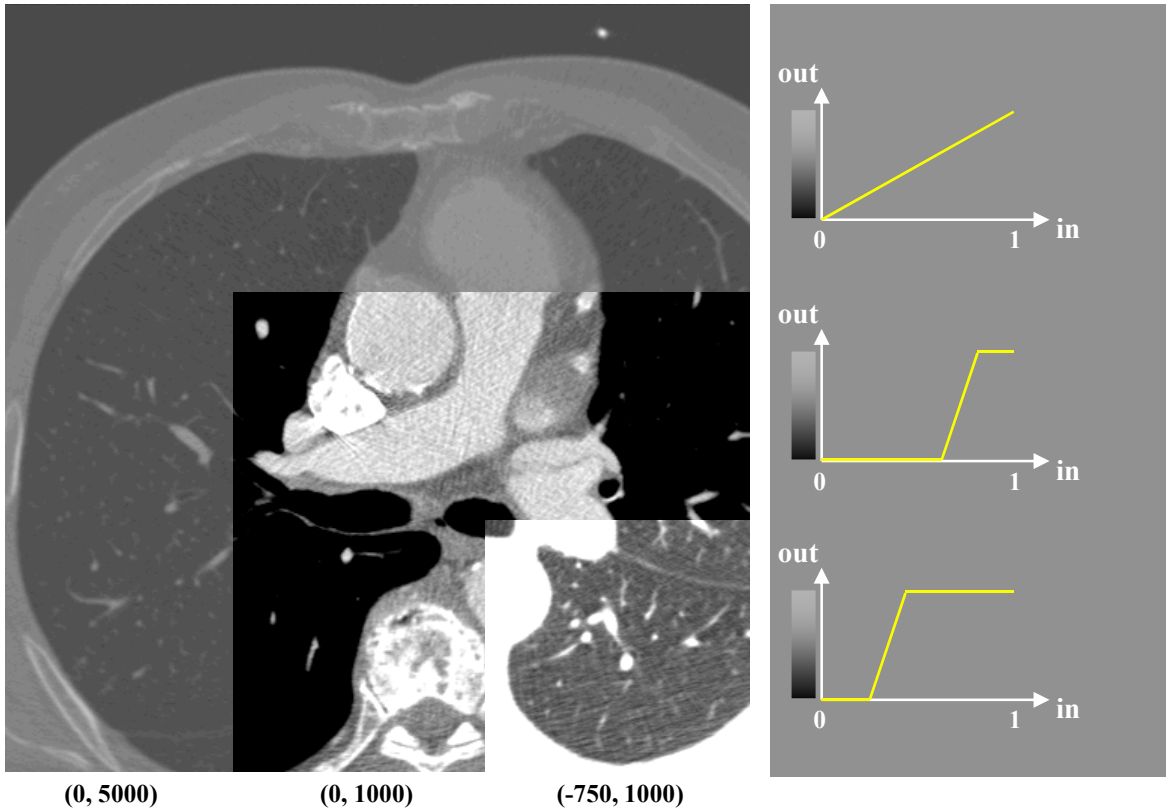

(0, 5000) (0, 1000) (-750, 1000)

ESTRO School

Outline

- Computed tomography
  - ➢How it works
  - ➢Strengths
  - ➢Weaknesses
- Ultrasound
  - ➢How it works
  - ➢Strengths
  - ➢Weaknesses
- Positron emission tomography
  - ➢How it works
  - ➢Strengths
  - ➢Weaknesses

ESTRO School

CT: Strengths

- Reliable
- Geometrically correct
- Fast
  - ➢Patient ease and comfort
  - ➢Minimal motion artefacts
  - ➢4D imaging possible
- Density values
  - ➢Electron density with dual-energy CT
- High spatial resolution

ESTRO School

CT: Weaknesses

- Relatively low tissue contrast
- Artefacts in neighbourhood to metal
- Limited potential for functional imaging
- Iionising radiation

ESTRO School

Outline

- Computed tomography
  - ➢How it works
  - ➢Strengths
  - ➢Weaknesses
- Ultrasound
  - ➢How it works
  - ➢Strengths
  - ➢Weaknesses
- Positron emission tomography
  - ➢How it works
  - ➢Strengths
  - ➢Weaknesses

ESTRO School

Pre-ultrasound era…

Pulse-echo techniques

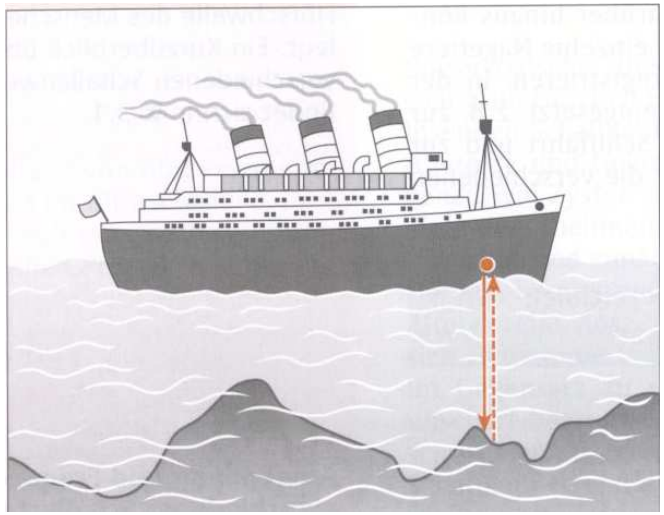

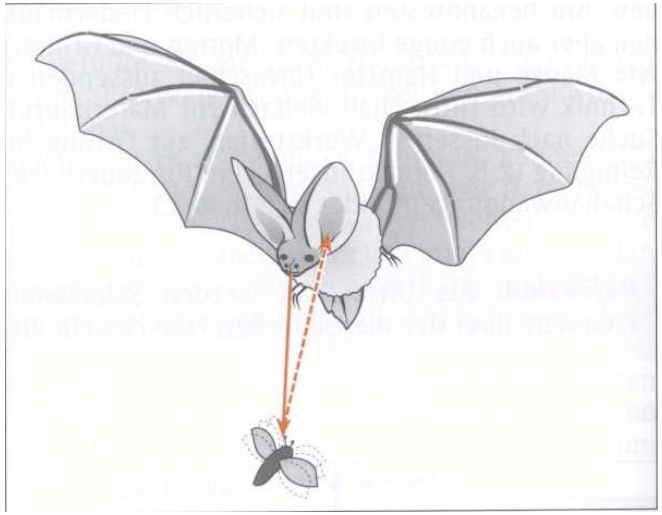

Interaction between sound and tissue

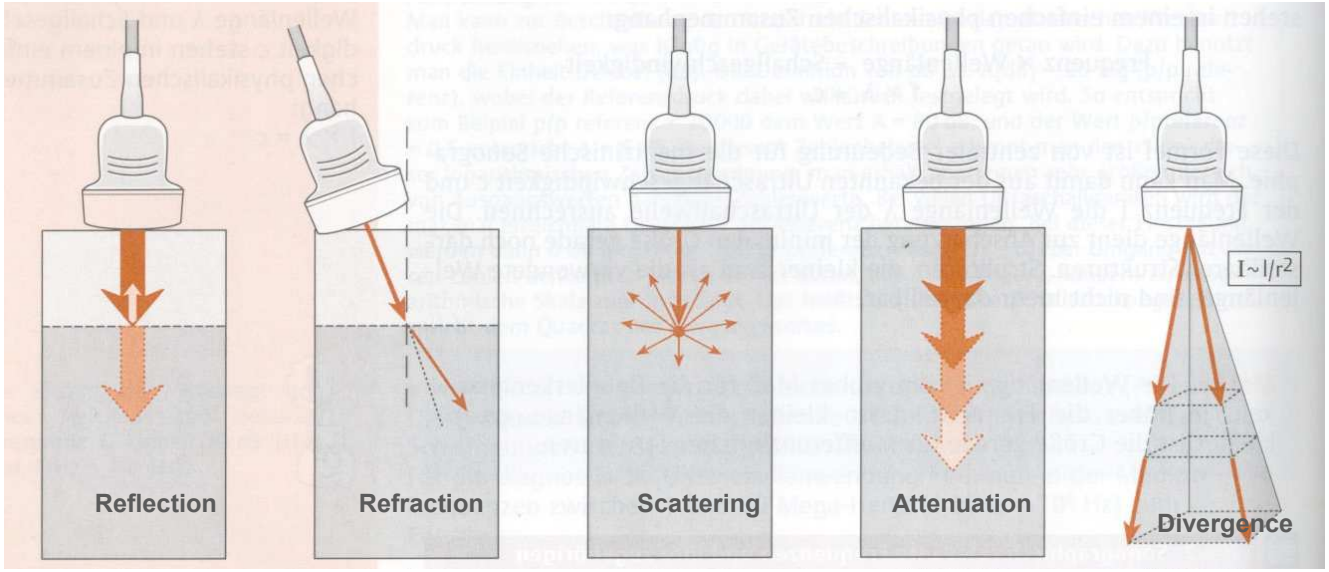

Pulse-echo experiment



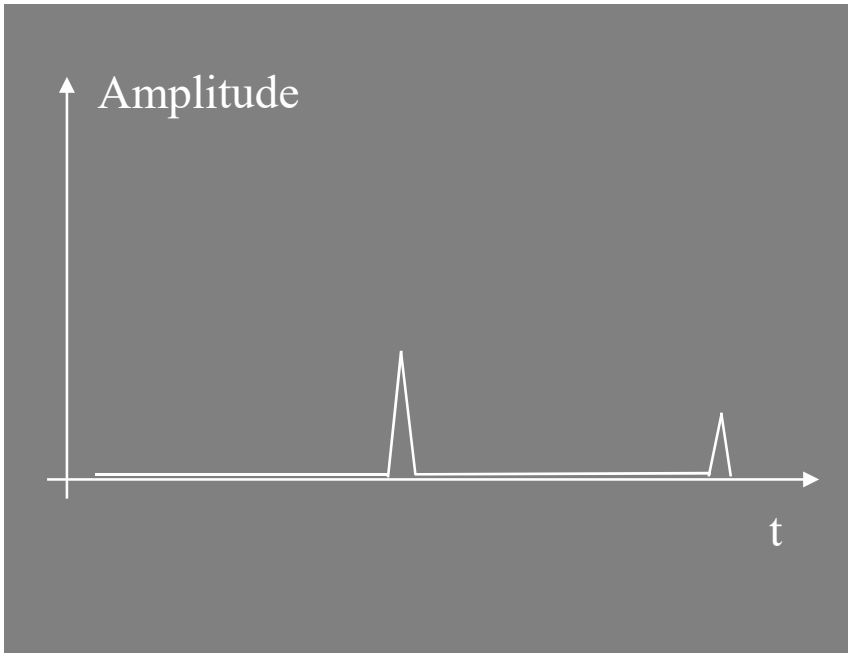

ESTRO School

Compound ultrasound imaging

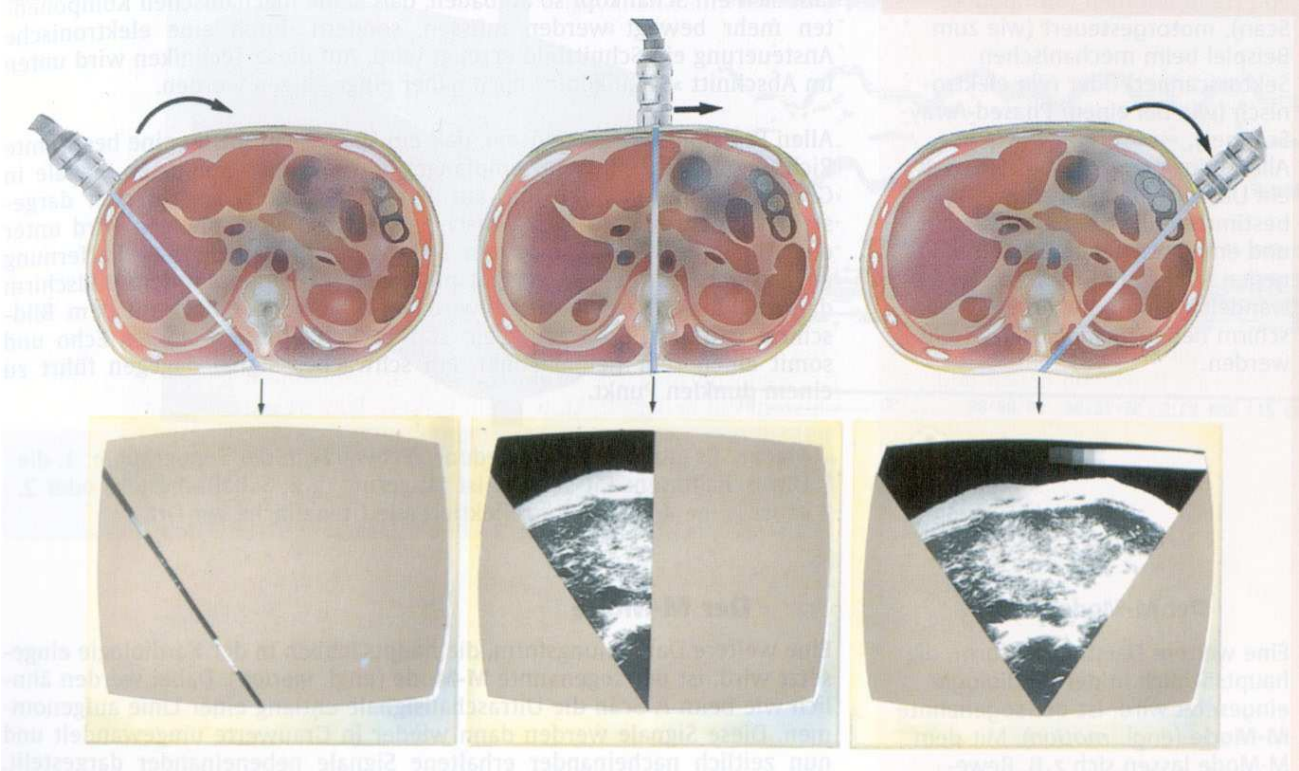

Ultrasound probes

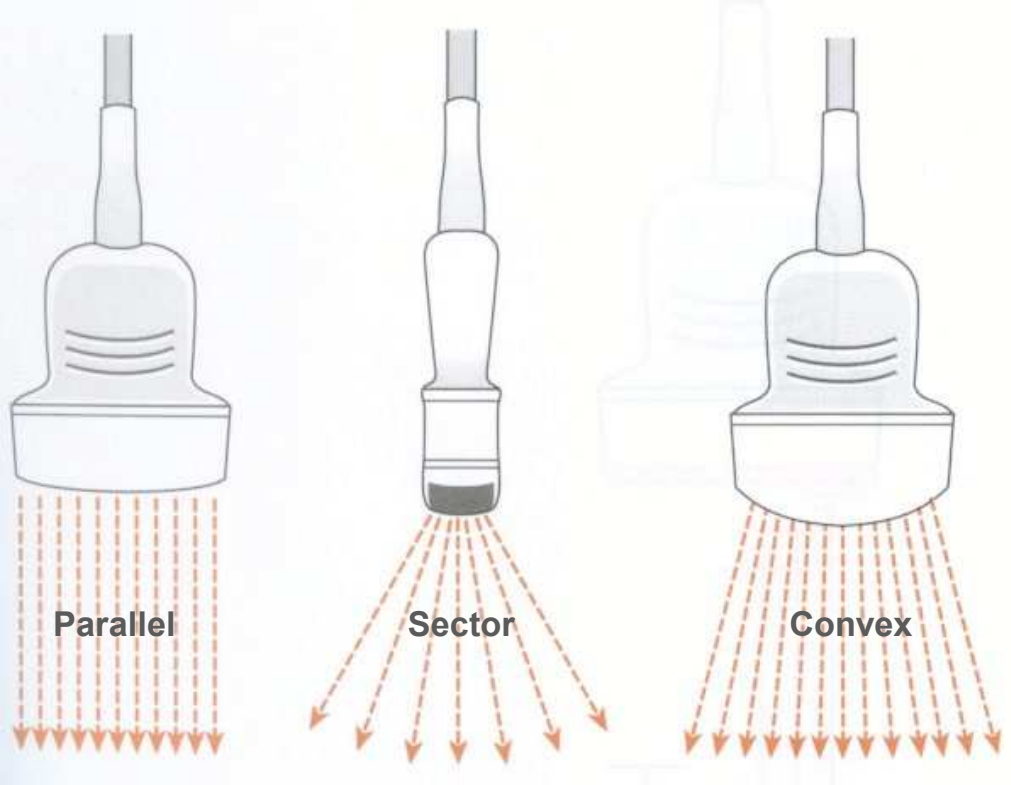

ESTRO School

Acoustic shadowing

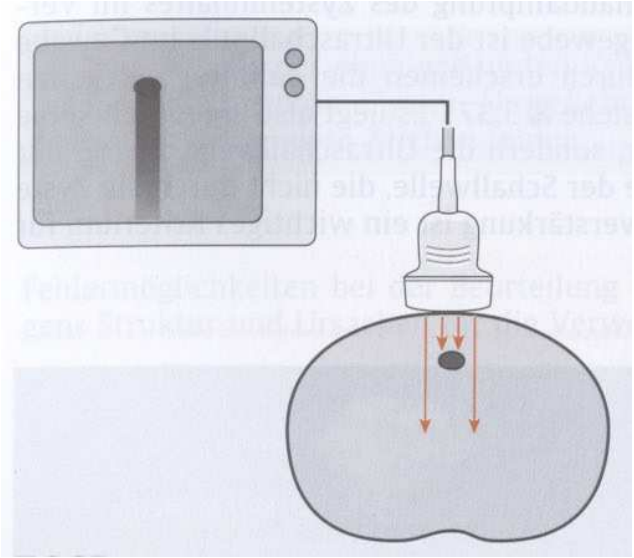

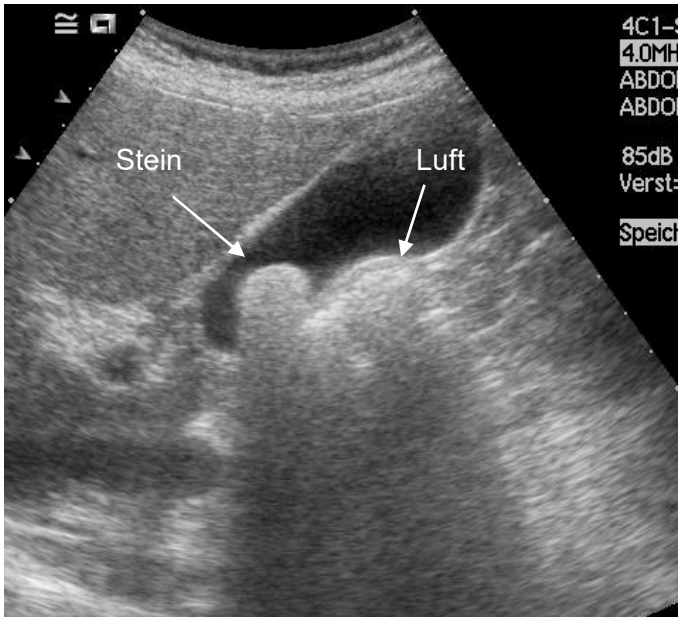

Tangential deflection

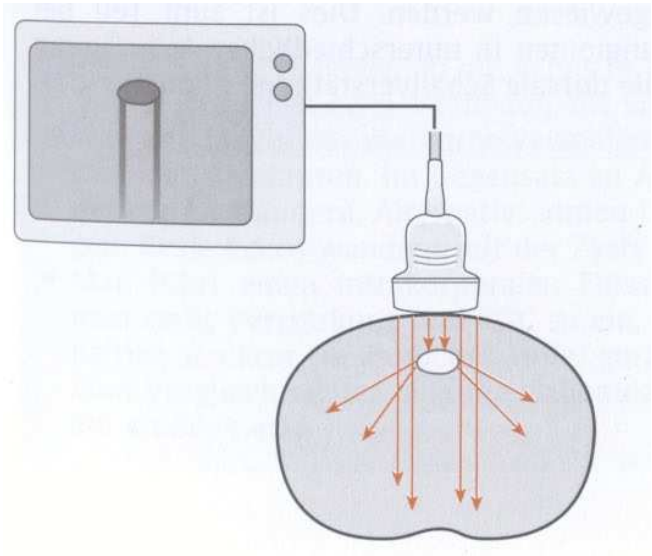

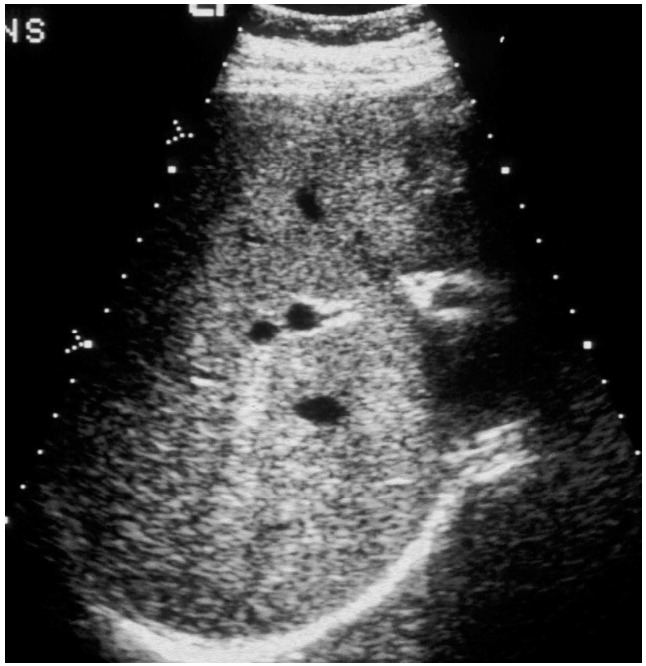

ESTRO School

Normal thyroid

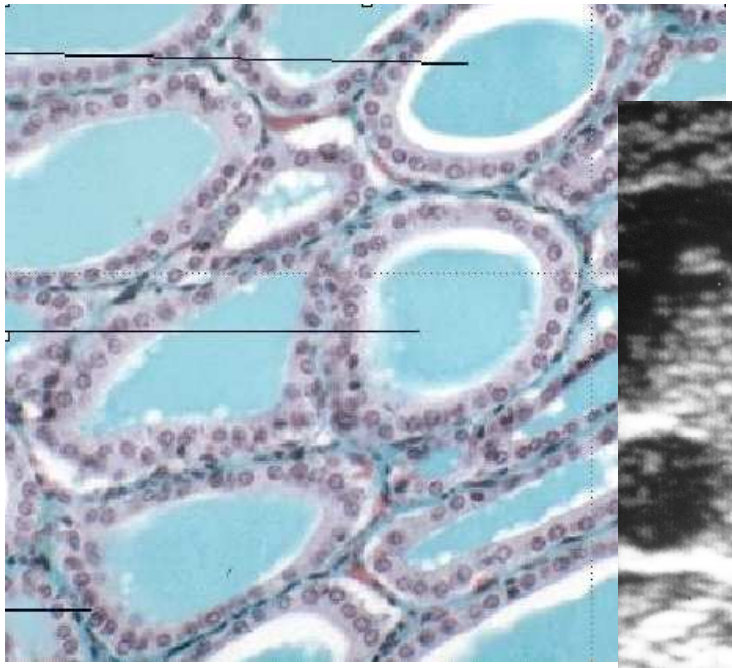

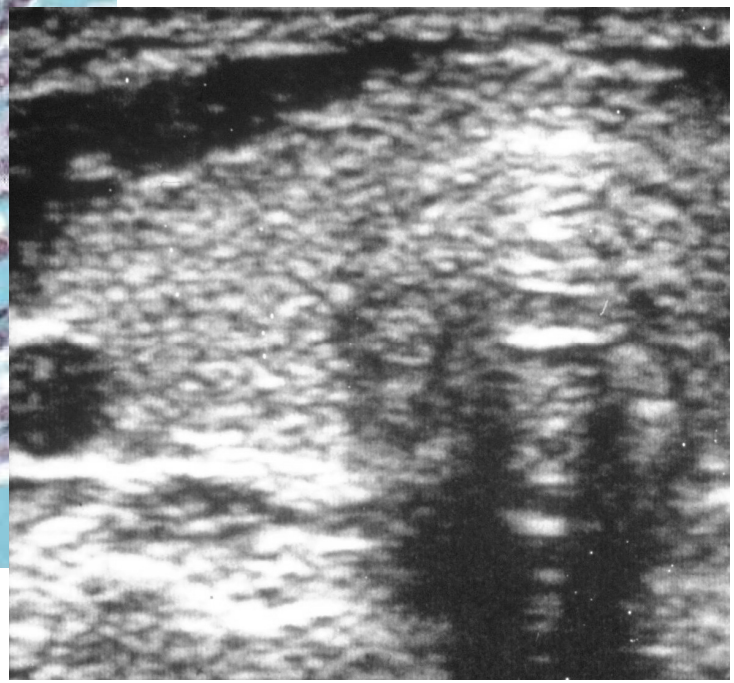

Graves disease

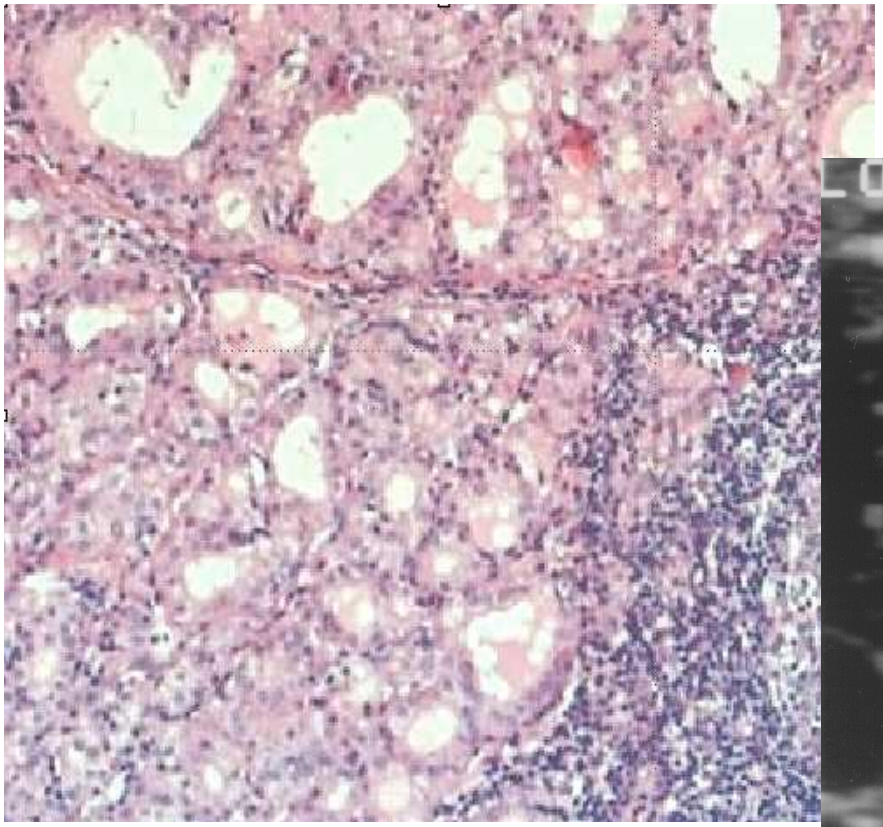

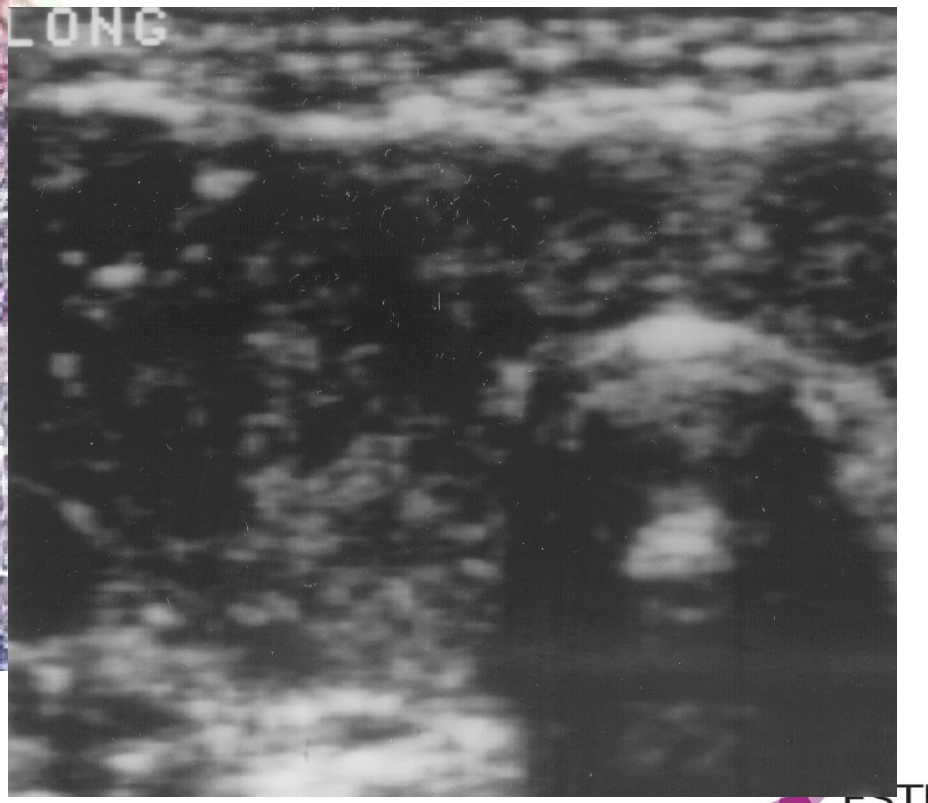

www.pathologie-online.de

ESTRO School

Metastasis

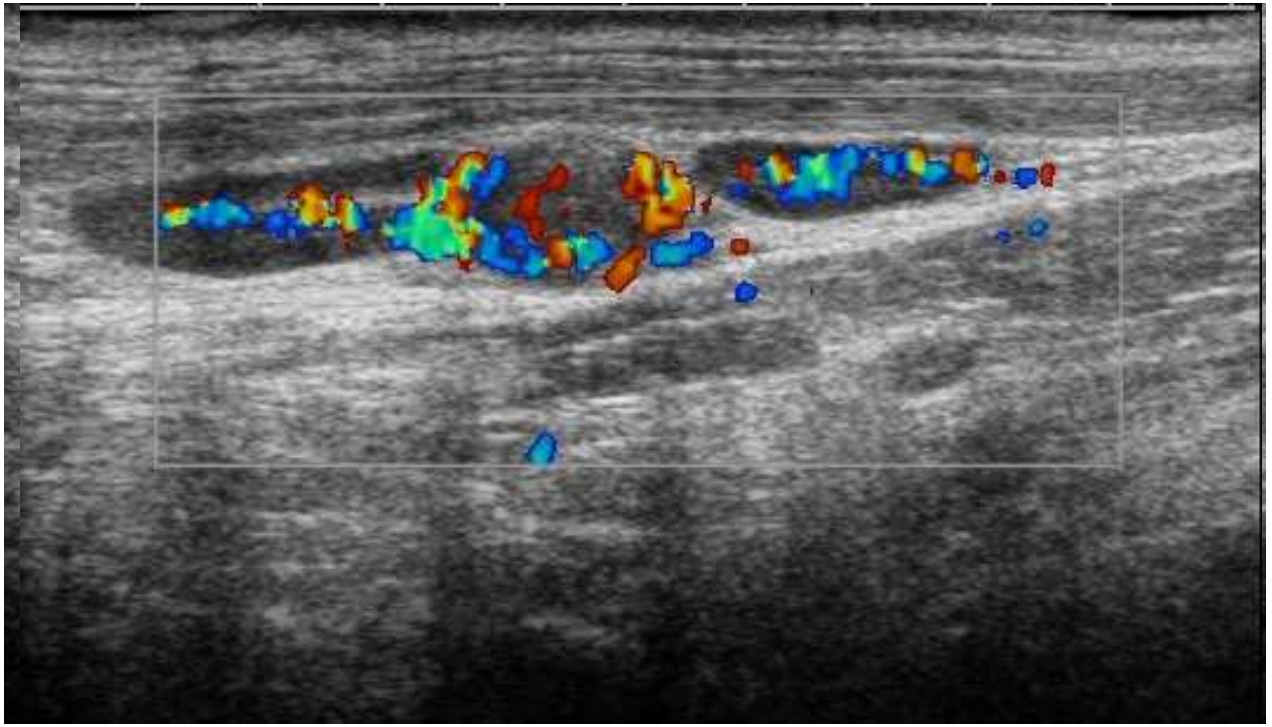

Metastasis

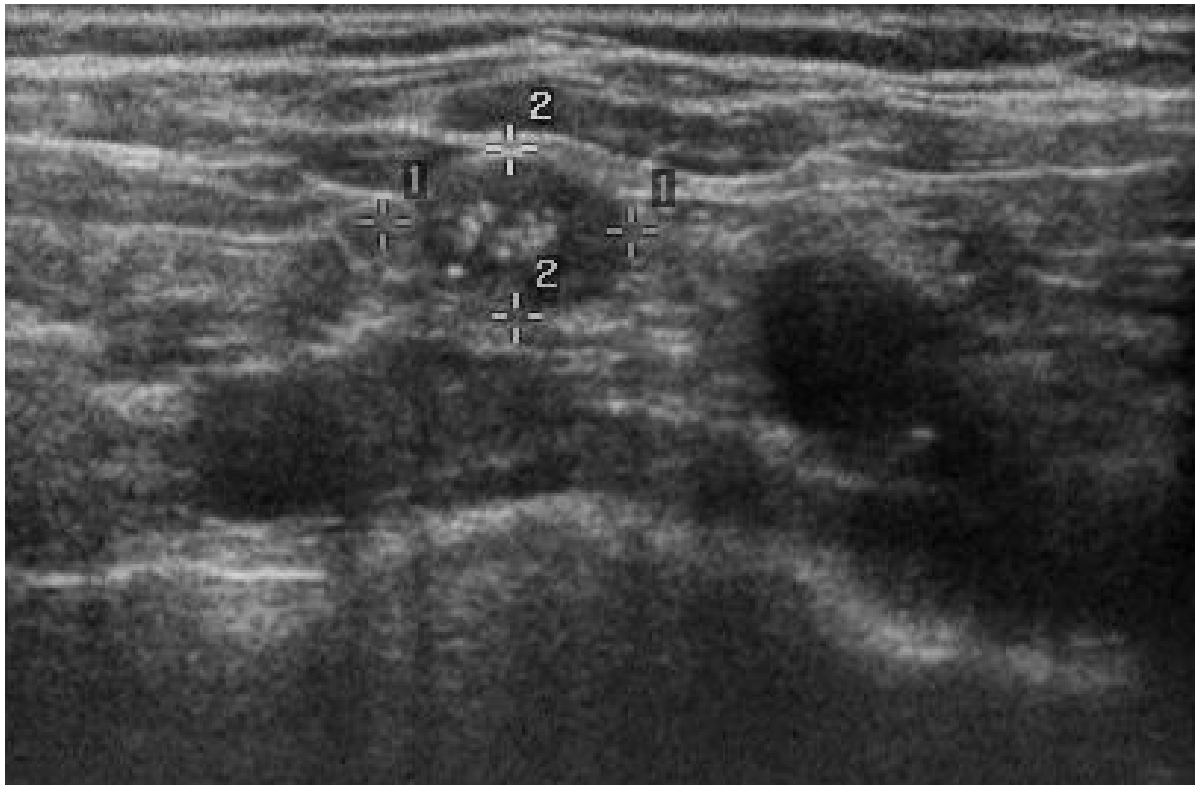

ESTRO School

Contrast-enhanced ultrasound: Arterial phase

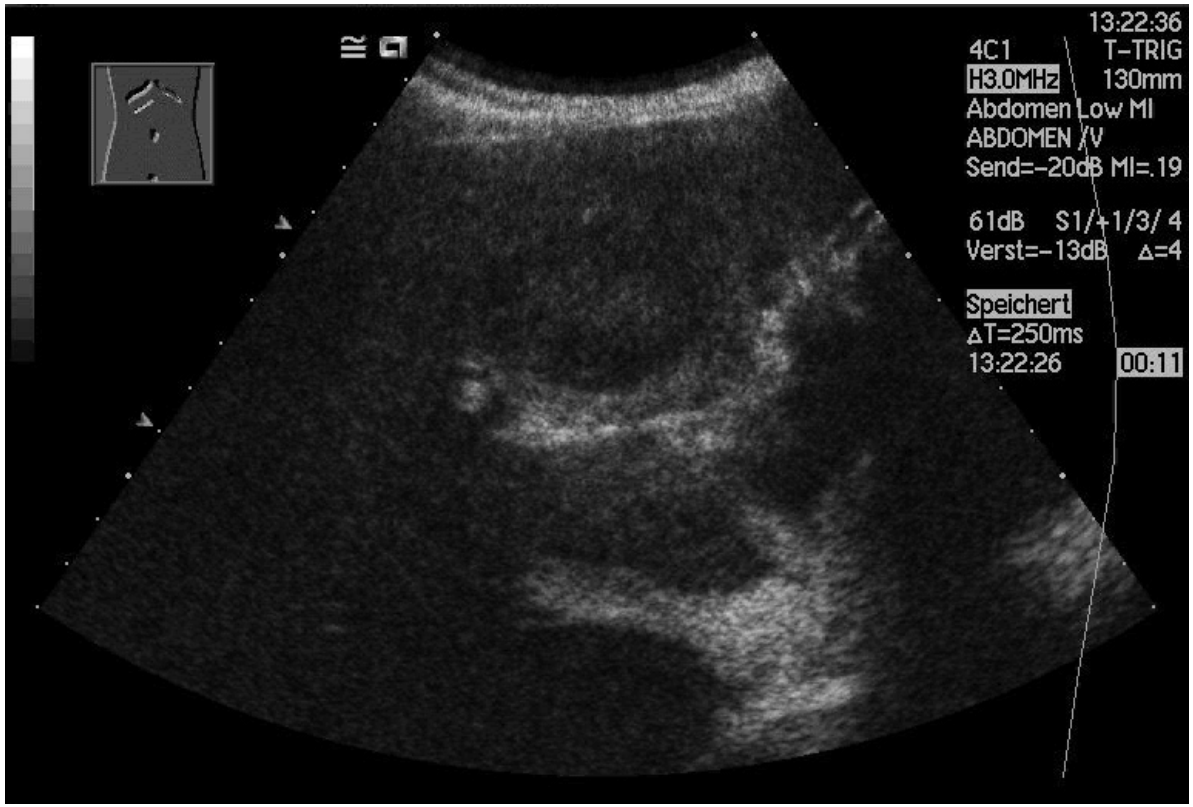

ESTRO School

Contrast-enhanced ultrasound: Portal phase

ESTRO School

Outline

- Computed tomography
  - ➢How it works
  - ➢Strengths
  - ➢Weaknesses
- Ultrasound
  - ➢How it works
  - ➢Strengths
  - ➢Weaknesses

➢Positron emission tomography

- ➢How it works
- ➢Strengths
- ➢Weaknesses

ESTRO School

Ultrasound: Strengths

- Fast
- Flexible
- High soft tissue contrast
- Highest resolution of all
- Real-time
- No ionising radiation
- Functional information
  - ➢Motion
  - ➢Blood flow
    - Color Doppler
    - Contrast agents

ESTRO School

Ultrasound: Weaknesses

- Difficult
  - ➢Requires skill and dexterity
- No geometrically reliable method
- No volume-covering documentation
- Access limited
  - ➢Bone
  - ➢Air

ESTRO School

Outline

- Computed tomography
  - ➢How it works
  - ➢Strengths
  - ➢Weaknesses
- Ultrasound
  - ➢How it works
  - ➢Strengths
  - ➢Weaknesses
- Positron emission tomography
  - ➢How it works
  - ➢Strengths
  - ➢Weaknesses

ESTRO School

Positron emission tomography

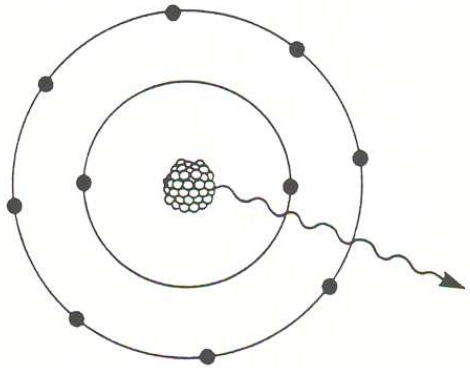

Gamma decay

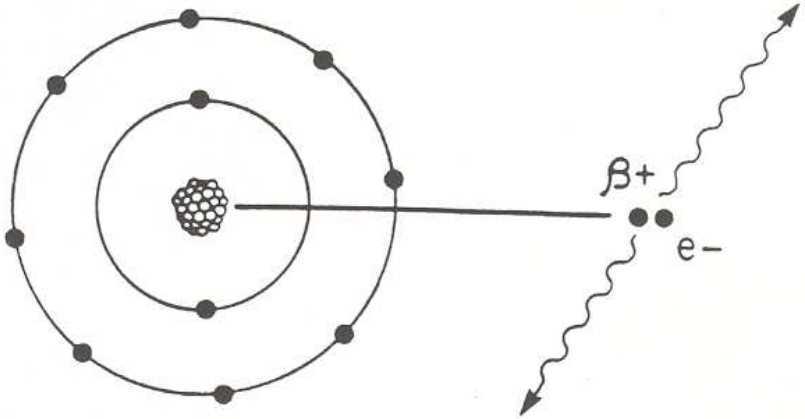

Positron decay

ESTRO School

Positron flight in tissues

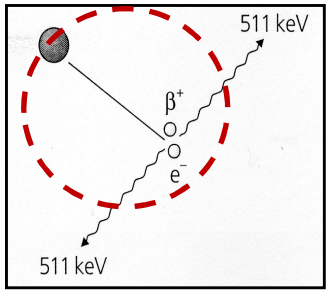



Monte Carlo-calculated distribution of annihilation events around a positron point source embedded in different human tissues as seen in the image plane of a PET camera

Positron flight in human tissues and its influence on PET image spatial resolution
Alejandro Sanchez-Crespo, Pedro Andreo, Stig A. Larsson. Eur J Nucl Med Mol Imaging (2004) 31:44–51

ESTRO School

PET isotopes

Isotope	$T_{1/2}$(min)	E_{max}(MeV)
^{11}C	20,4	0,97
^{13}N	9,9	1,19
^{15}O	2,05	1,72
^{18}F	109	0,64
^{68}Ga	68	1,9

ESTRO School

PET tracers - oncology

- Metabolism
  - ^{18}FDG
- Amino acids
  - ^{11}C-methionine
  - ^{18}F-tyrosine
  - ^{11}C-AIB
  - ^{18}FET
- Peptides
  - ^{68}Ga-DOTATOC
  - ^{68}Ga-PSMA

Perfusion

$H_2{}^{15}O$

Proliferation

^{11}C-thymidine

^{18}FLT

^{18}F-ethyl choline

^{11}C-choline

Drugs

^{18}FU

Hypoxia

^{18}F-misonidazole

ESTRO School

68Ga-DKFZ-PSMA-11

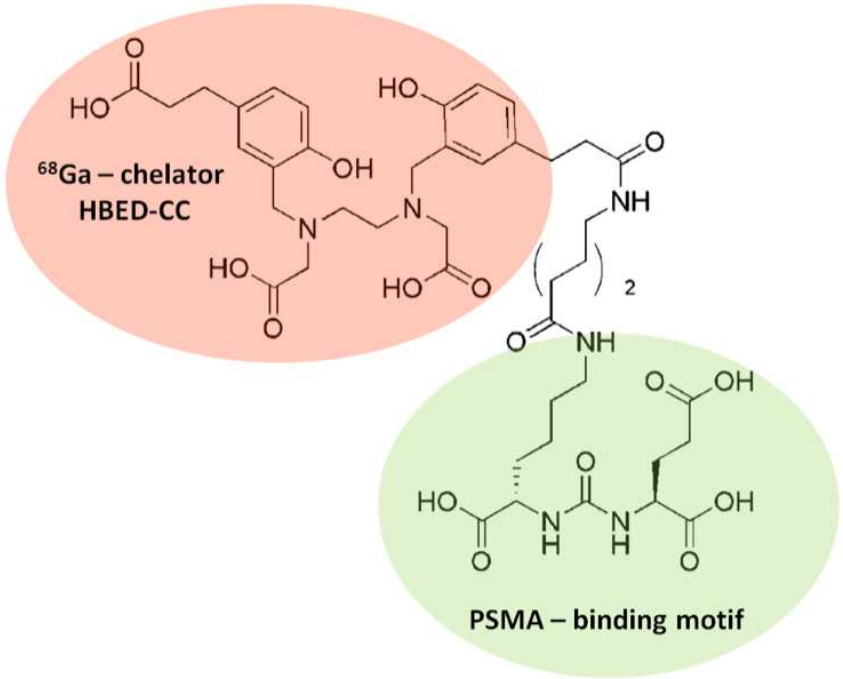

Eder M et al. Bioconjugate Chem 2012; 23: 688-697.
Afshar-Oromieh A et al. Eur J Nucl Med Mol Imaging 2013; 40: 486-495.

ESTRO School

FDG metabolism

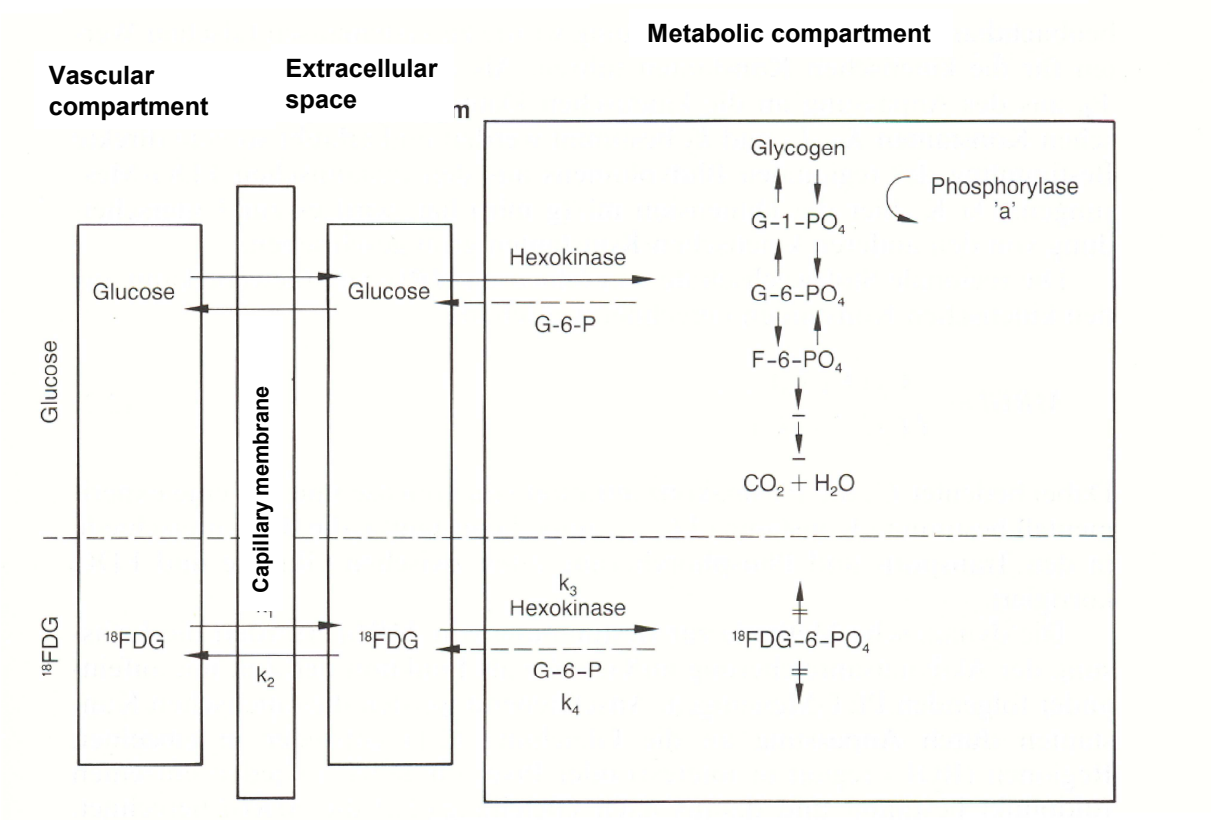

PET scanner

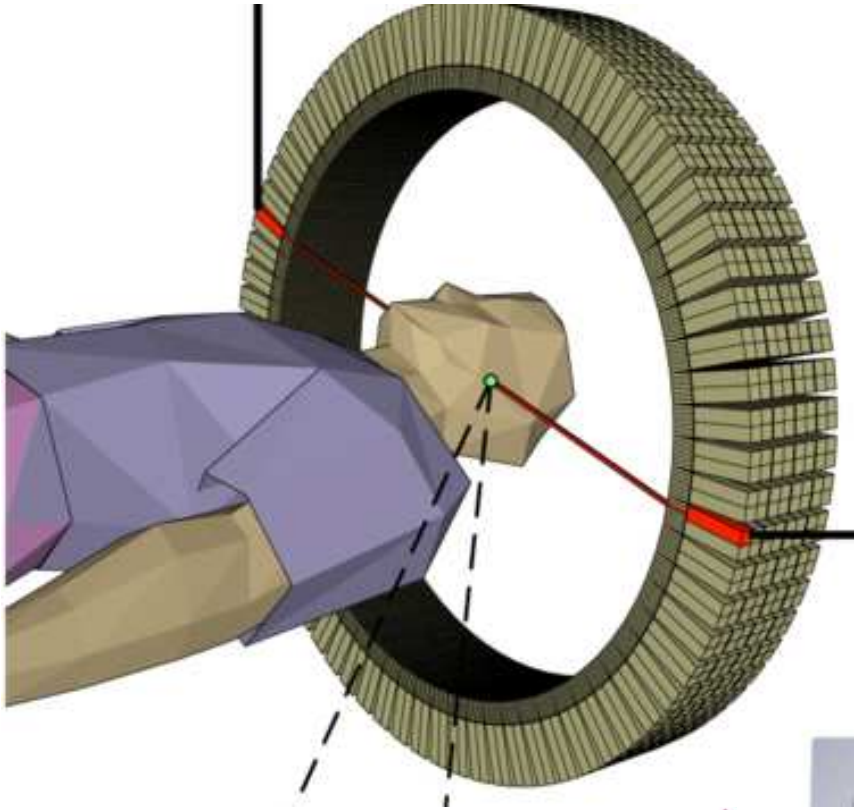

ESTRO School

Detection of coincidences

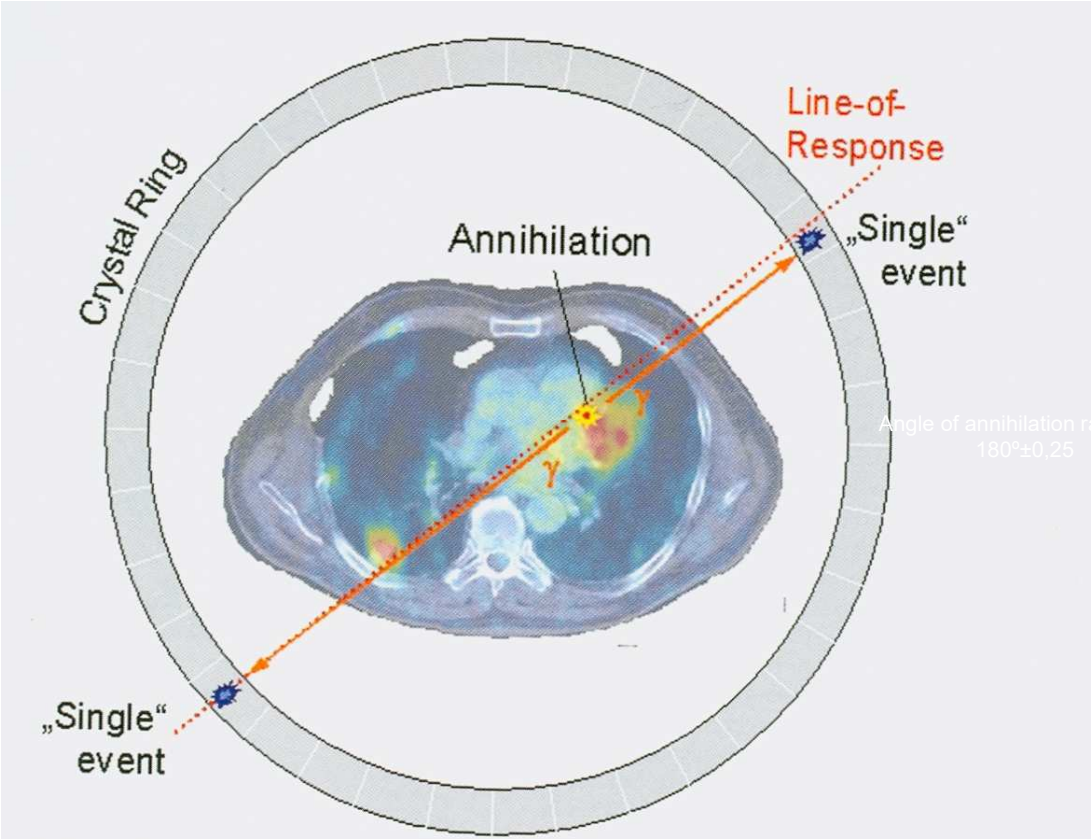

GK von Schulthess: Clinical Molecular Anatomic Imaging.
Lippincott Williams& Wilkins 2003

Time-of-flight (TOF) PET technology

Time window ~1- 6 ns

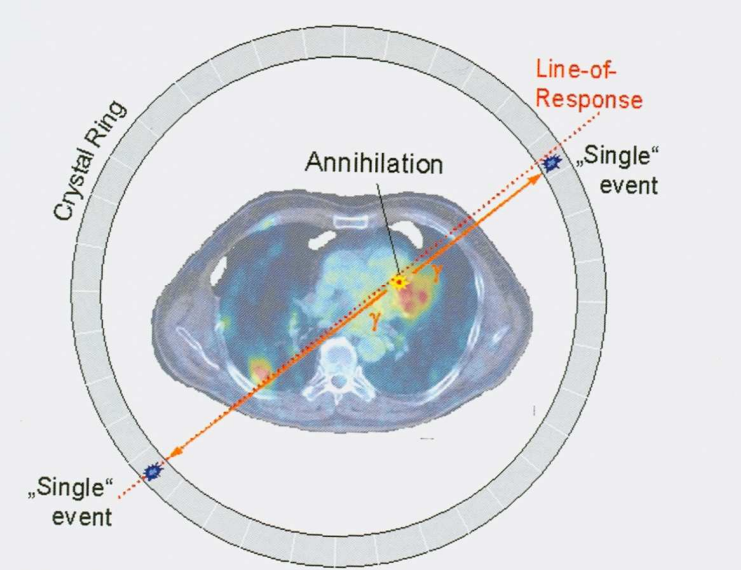

TOF: time-of-flight

Improved localization of annihilation Events along the line of response (LOR)

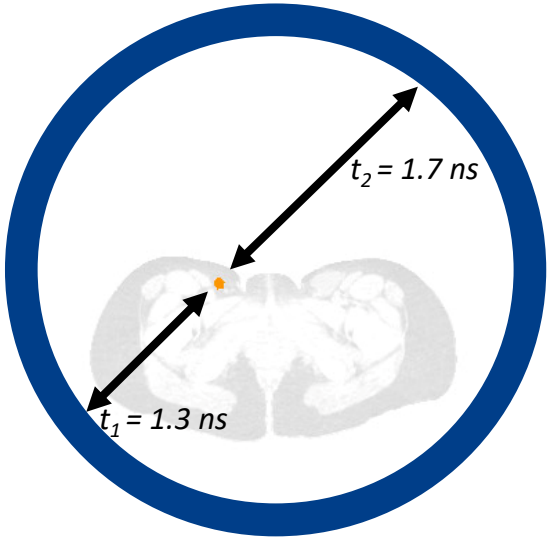

Images courtesy of Philips Healthcare

ESTRO School

Randoms

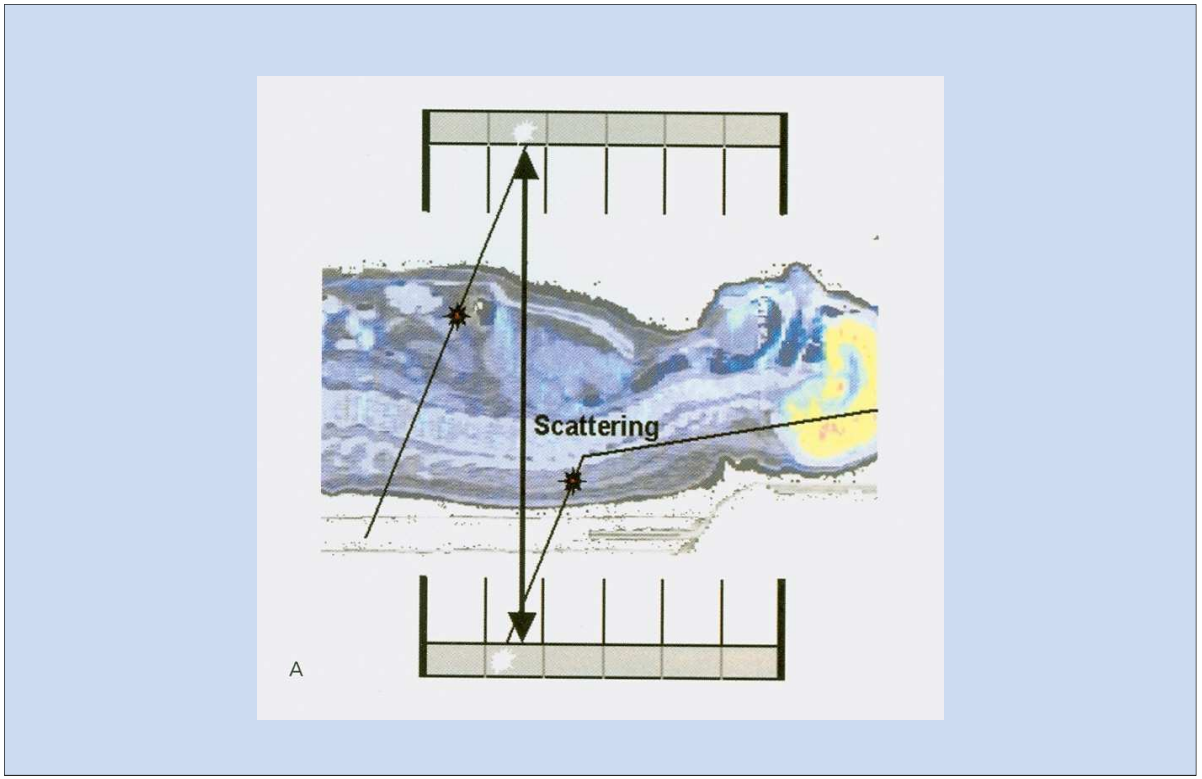

GK von Schulthess: Clinical Molecular Anatomic Imaging.
Lippincott Williams& Wilkins 2003

ESTRO School

Singles

99 % of photons are rejected because they are single

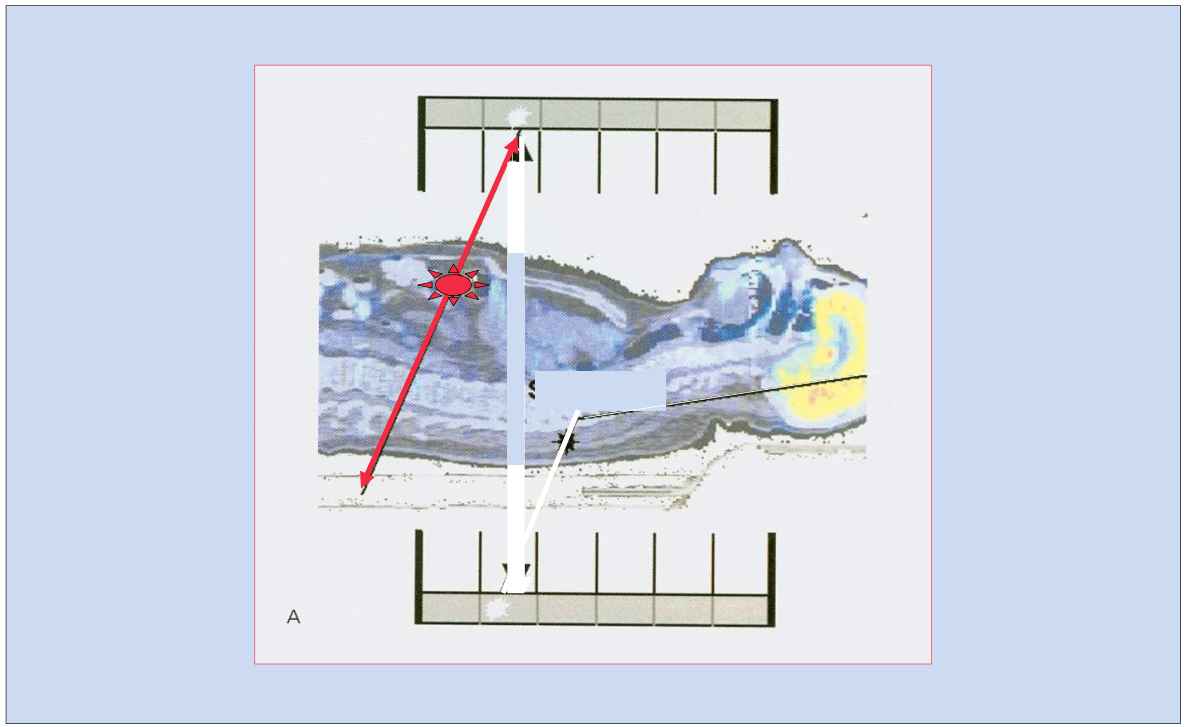

ESTRO School

Field of view of a PET camera

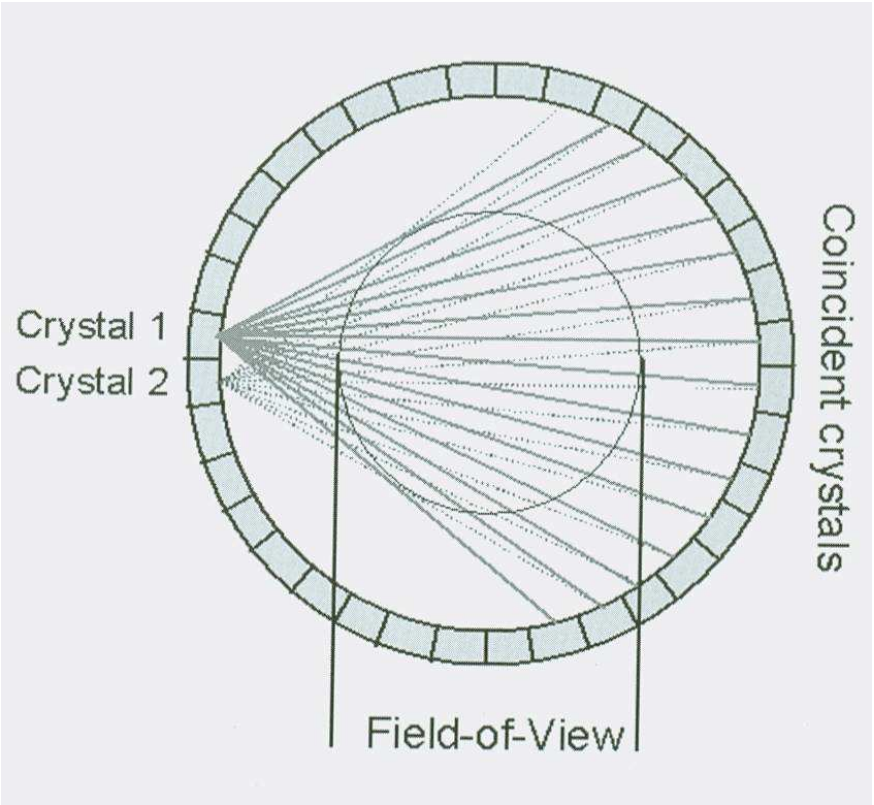

GK von Schulthess: Clinical Molecular Anatomic Imaging.
Lippincott Williams& Wilkins 2003

ESTRO School

Attenuation correction

- Improved image quality
- No quantification possible without attenuation correction

Without correction

With correction

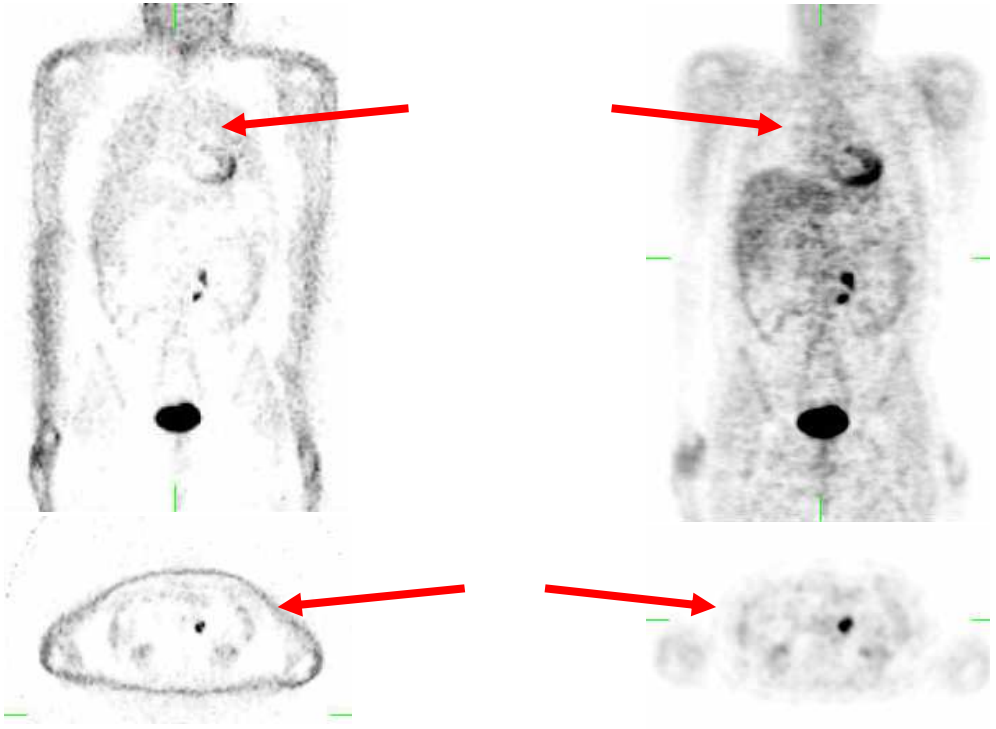

ESTRO School

PET: Glucose Metabolism

pre therapy
SUV 10,2

After 2nd cycle
SUV 5,7

ESTRO School

Where is the tumour?

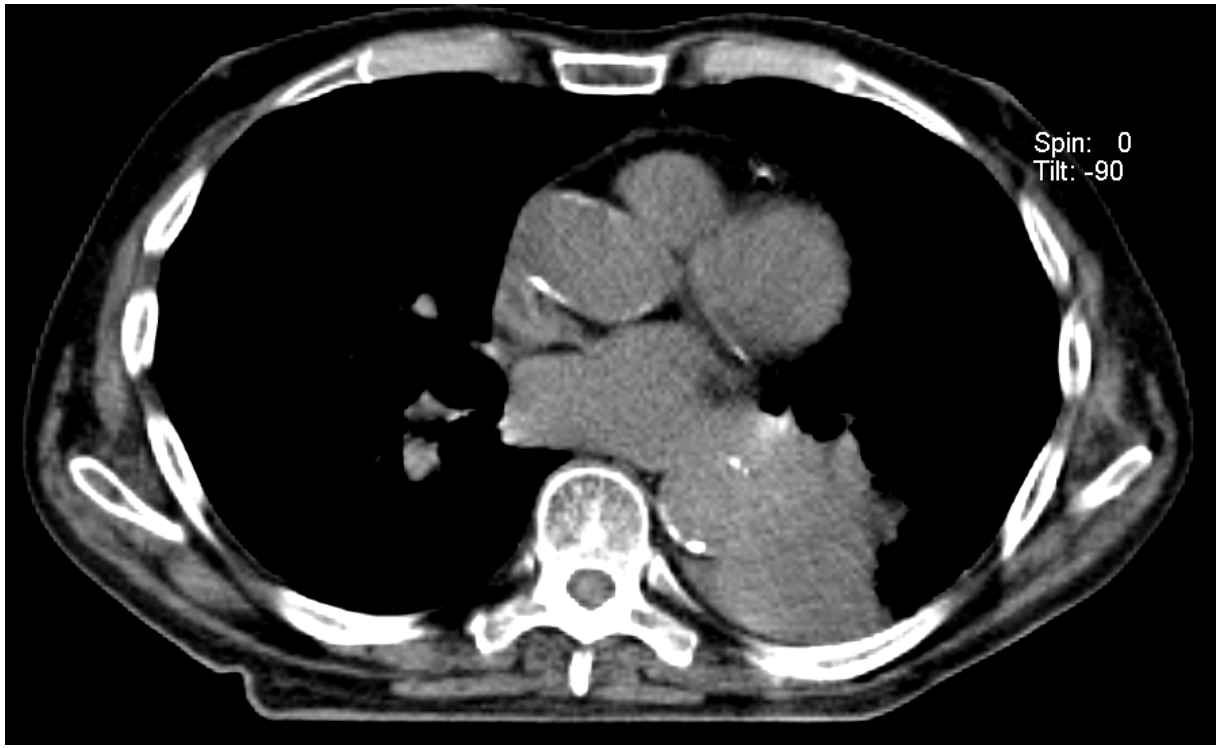

Central tumour, distal atelectasis

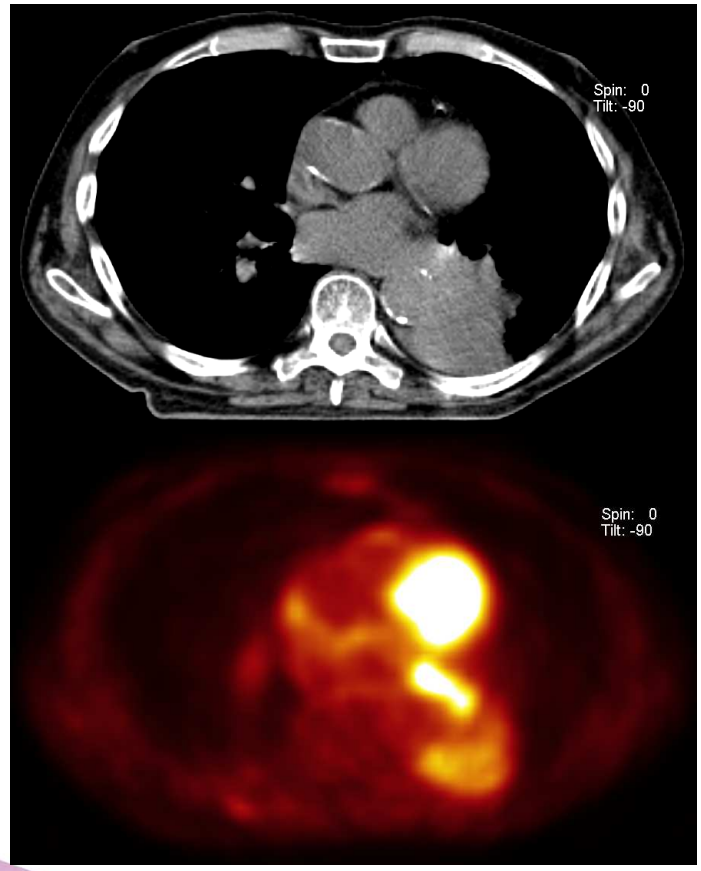

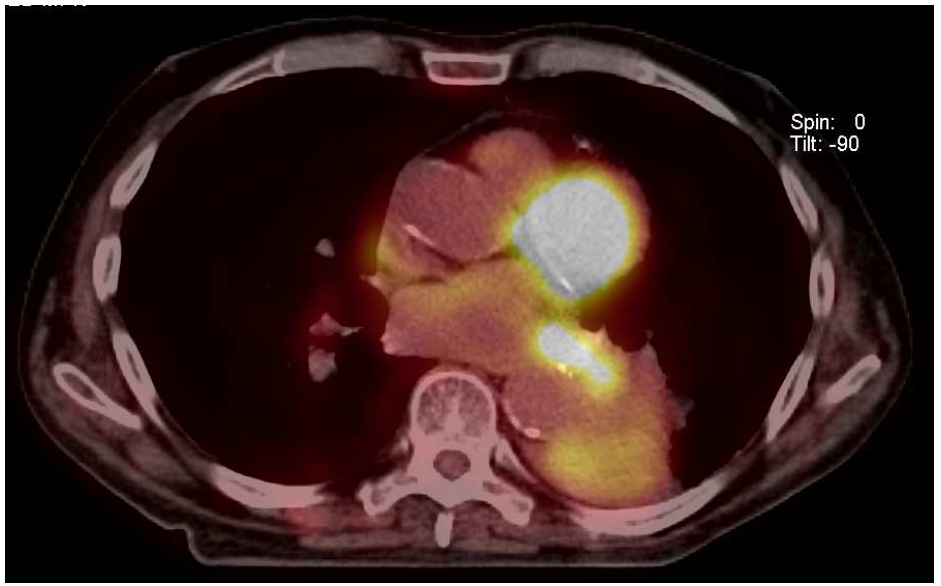

Outline

- Computed tomography
  - ➢How it works
  - ➢Strengths
  - ➢Weaknesses
- Ultrasound
  - ➢How it works
  - ➢Strengths
  - ➢Weaknesses
- Positron emission tomography
  - ➢How it works
  - ➢Strengths
  - ➢Weaknesses

ESTRO School

PET: Strengths

- True functional information
- Flexible choice of tracers for various parameters
  - Metabolism
  - Receptors and surface markers
  - Proliferation
- Helpful identifying active tumor areas
- Helpful discriminating tumour from non-tumour tissue
- Shows treatment response earlier than CT or MRI
- May show unexpected tumour deposits outside intended target volume

ESTRO School

PET: Weaknesses

- Needs matching with morphological techniques
  - PET/CT or PET/MRI hybrid scanners
  - **Possible matching errors in moving structures**
- Size of hot areas dependent on windowing
  - **Does not show real tumour extension**
- FDG-PET not necessarily tumour-specific
  - **Uptake in inflammatory conditions**
- Some tumours need specific tracers
  - ^{68}Ga-DOTATOC for neuroendocrine tumours
  - PSMA ligand for prostate cancer



ESTRO School

Image Handling

& Image registration

Martina Kunze-Busch
Radboudumc
Nijmegen, The Netherlands

Peter Remeijer
NKI-AVL
The Netherlands Cancer Institute
Antoni van Leeuwenhoek Hospital

ESTRO School

Overview

Image Handling

- Image data in the RT chain
  potential errors, challenges

Martina Kunze-Busch
Radboudumc
Nijmegen, The Netherlands

Image Registration

PART I

- Definition
- A closer look at the different components/steps
  geometrical transformation - similarity measure - optimization algorithm
- Registration accuracy

PART II

- Deformable Image registration – practice at the AvL

Peter Remeijer
NKI-AVL
The Netherlands Cancer Institute
Antoni van Leeuwenhoek Hospital

Image data…

…to determine (diagnostic) &
hit the target (positioning, adaptive RT)

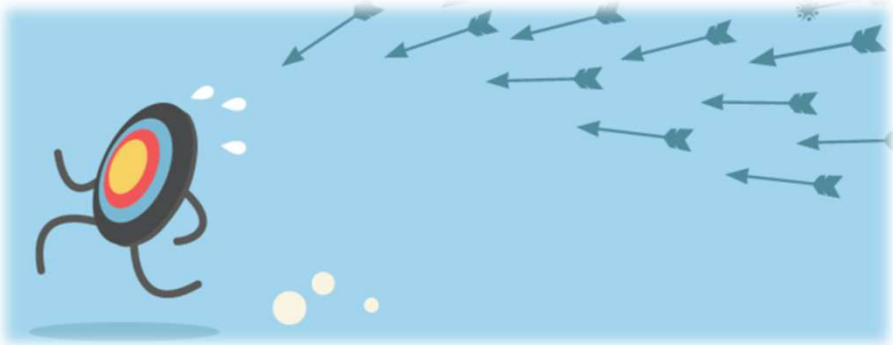

Radboudumc

ESTRO School

Image data in RT chain

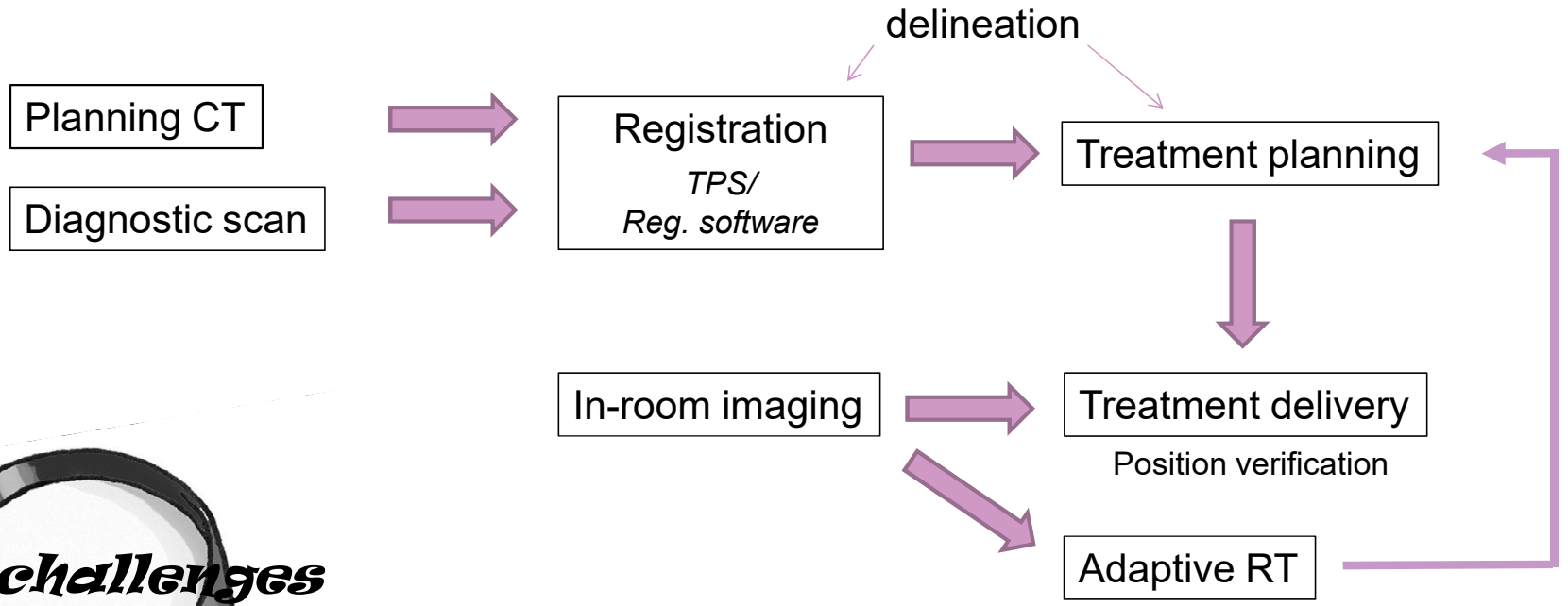

Radboudumc

ESTRO School

Treatment preparation – (planning) CT scan

Example: scatter

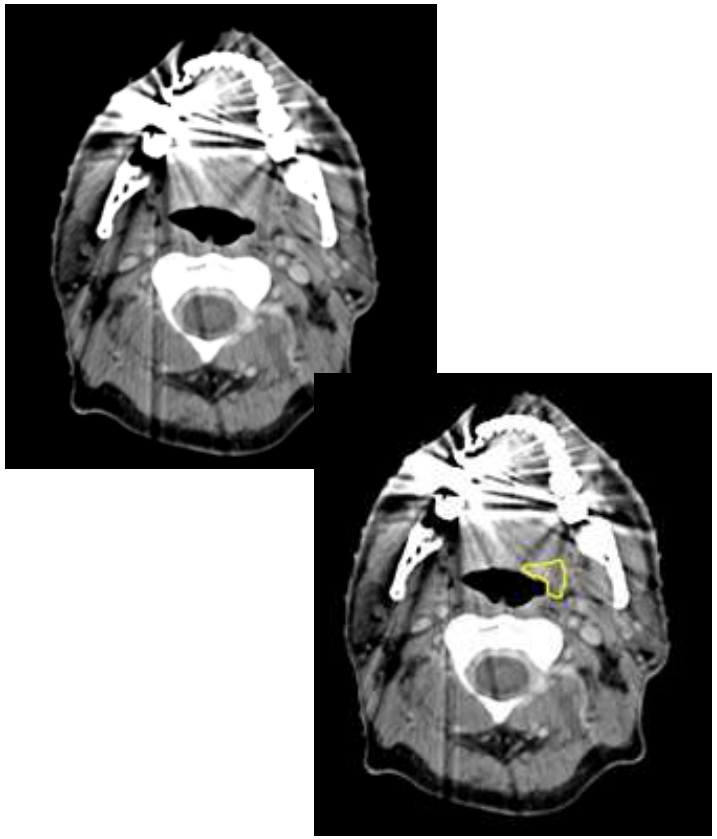

Metal Artefact Reduction software

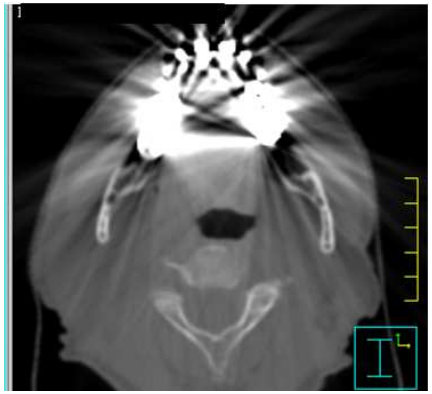

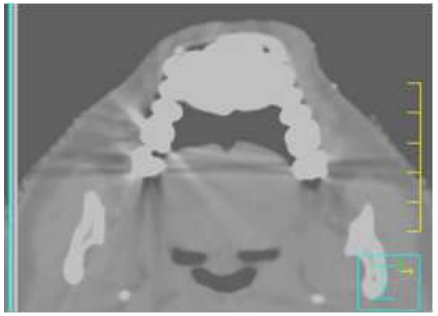

Radboudumc

ESTRO School

Treatment preparation – delineation

Example: motion

fast

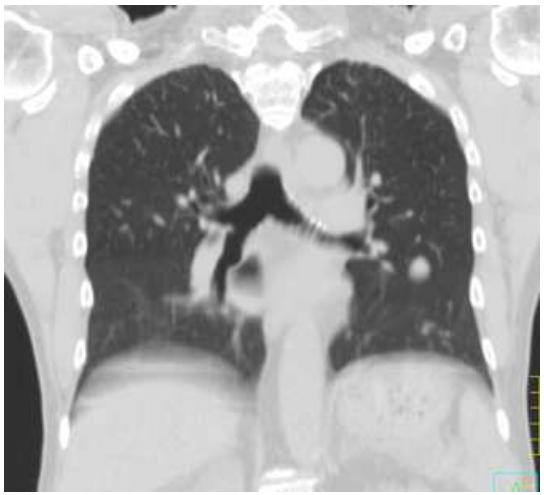

slow

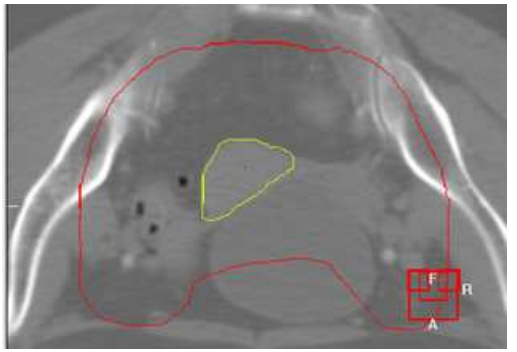

CT

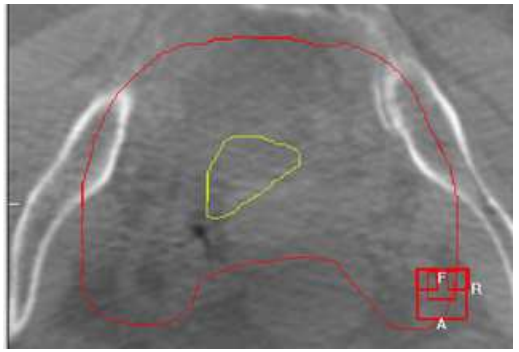

CBCT

Radboudumc

ESTRO School

Dealing with tumor motion

Fast motion

- breath-hold CT scan
- gated CT scan
- 4D CT scan
  = 3D scans at multiple phases

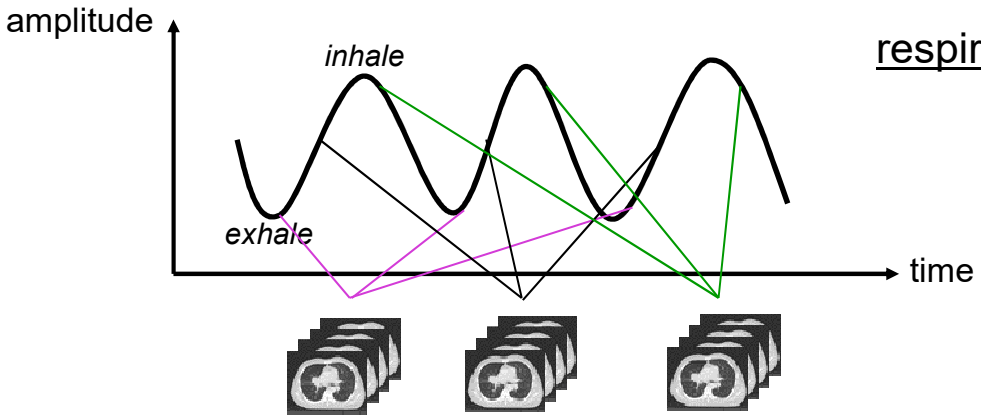

respiration correlated CT

Dealing with tumor motion

Intra-fraction changes

4D CT – mid-ventilation

time-weighted average position

→ Peter

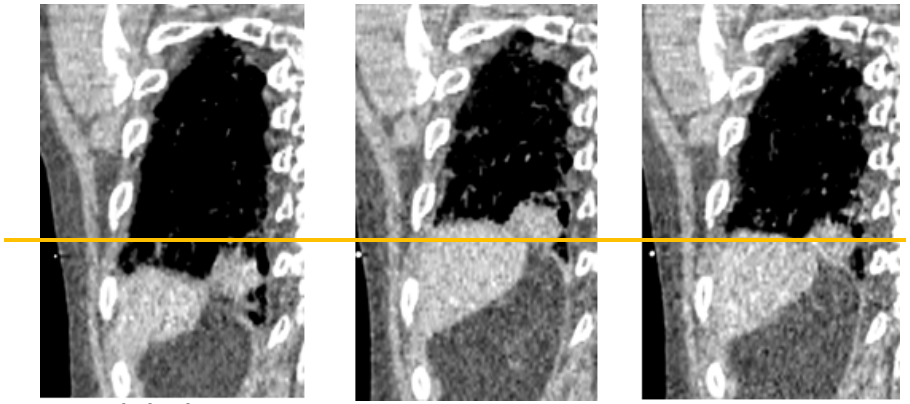

Inter-fraction changes

→ Peter

“plan of the day”

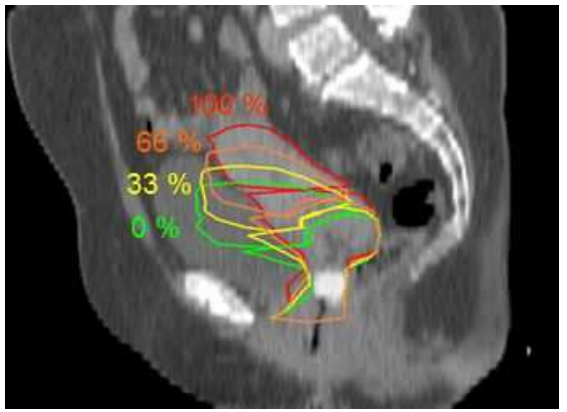

NKI-AVL

Radboudumc

ESTRO School

Treatment preparation – diagnostic MR scan

Example: MR imaging artefacts

Wrap around

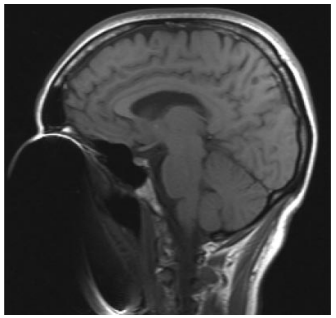

Susceptibility

RadioGraphics 2006



"Here's where it gets a little challenging."

false positive in breast MRI
(pseudo-enhancement)

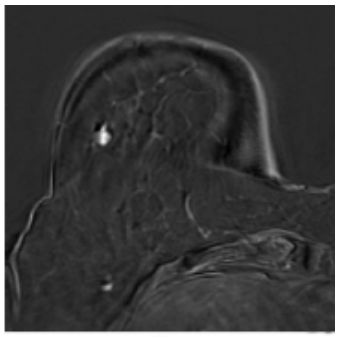

Millet et al., Br J Radiol 85 (2012)

Radboudumc

ESTRO School

Treatment preparation – ~~diagnostic~~ MR scan

dedicated MR scan

diagnostic scans → detection/staging

scans for treatment planning → tumor location/extent

↓

geometric accuracy of MR images

(can be compromised e.g. by - inhomogeneity of main magnetic field
- magnetic field disturbance by imaged objects)

Treatment preparation - registration

planning CT – diagnostic MRI

MIRADA medical

registration

visual check

delineation

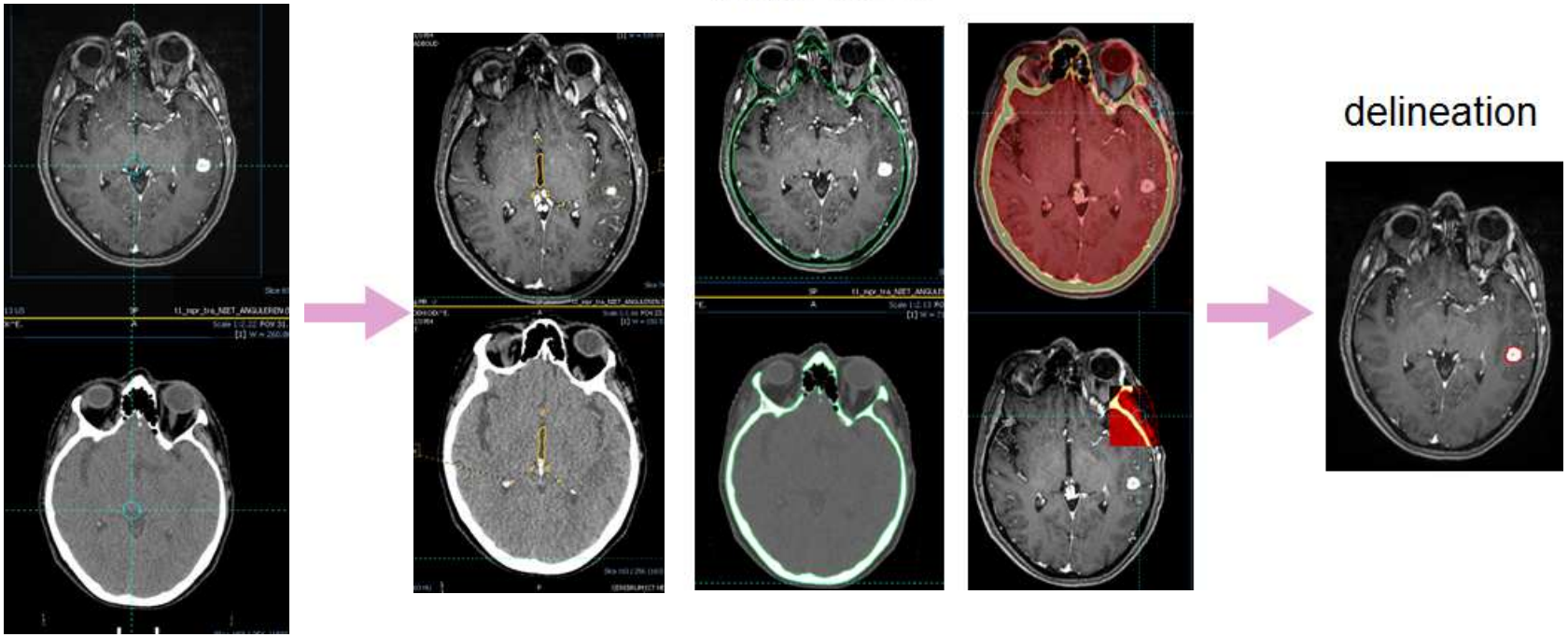

Radboudumc

ESTRO School

Treatment preparation - registration

problems/challenges

- different table tops
- scan artefacts (MRI: geometrical distortions....)
- patient movement / organ motion during scan
- different scanning positions in different imaging modalities
- no use of fixation mask in MRI / PET
- limited available volume for registration (e.g. in cran-caud direction)
- anatomical changes
- .....

Treatment preparation - registration

Example: different scanning position

planning CT | diagnostic MRI

no fixation mask on MRI

→ different flexion of neck

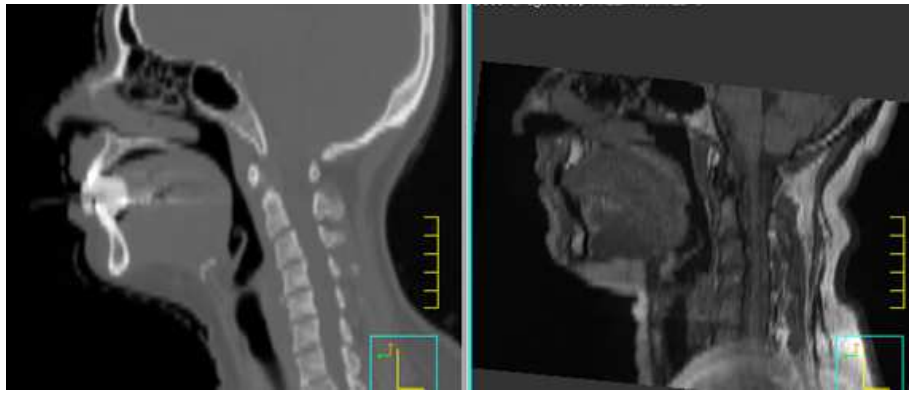

mouth open - closed

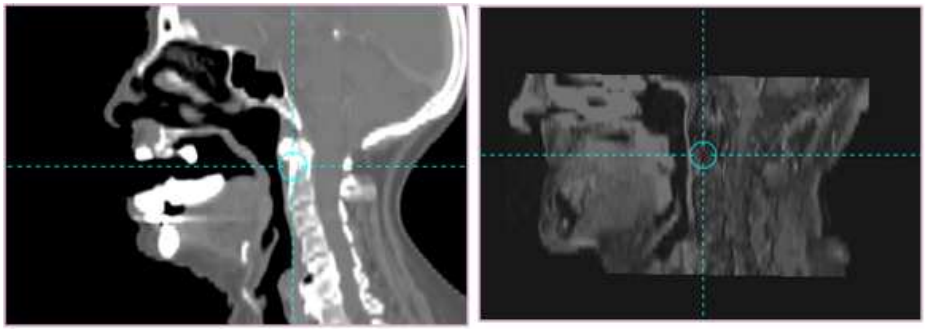

Radboudumc

ESTRO School

Treatment preparation - registration

Example: limited available volume / motion

MR scan too short

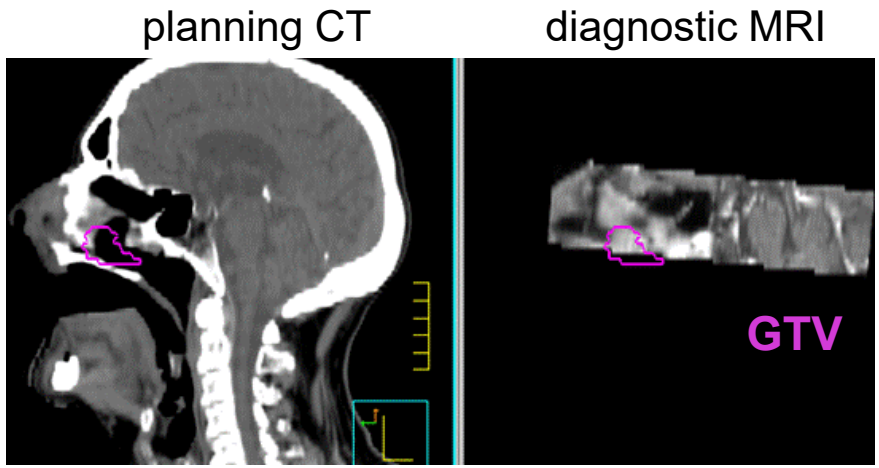

Collection of data continues …..

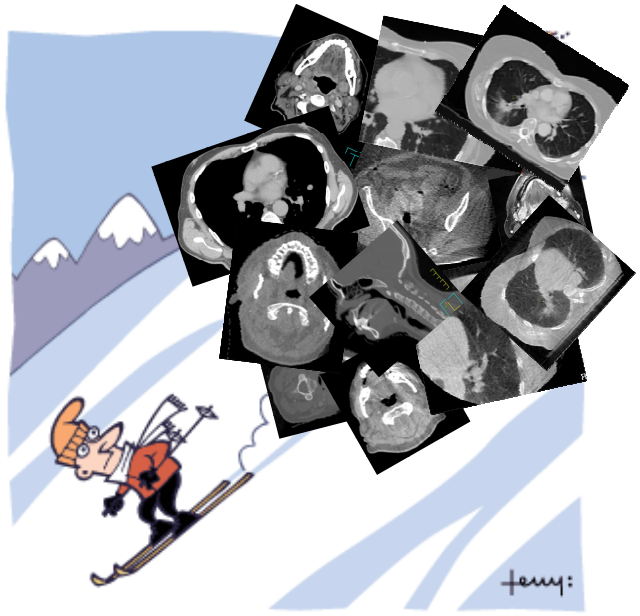

Radboudumc

ESTRO School

Treatment delivery

Image guided RT with Cone Beam CT

alignment of in-room CBCT images
with planning CT images

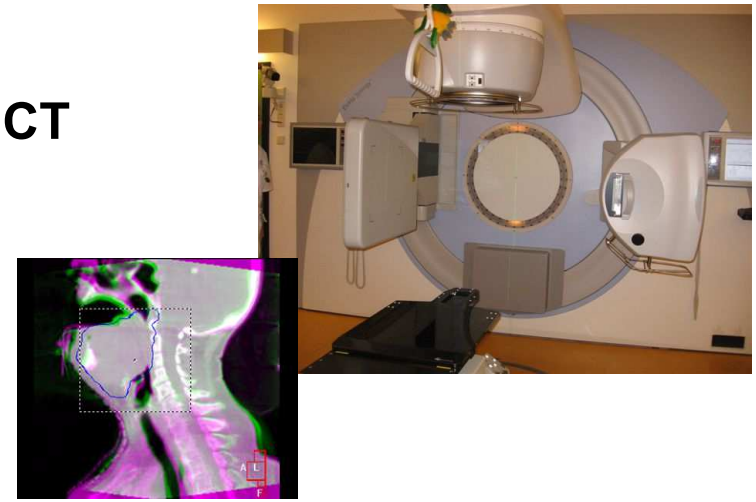

→ position verification of patient (online/offline protocols)
→ localization of tumor at time of treatment
→ assessment of change in anatomy (tumor size/weight loss or gain)

Image guided Adaptive Radiotherapy (ART)

Radboudumc

ESTRO School

Treatment delivery – ImageGuidedRT

In-room imaging

e.g. with Cone Beam CT (e.g. Elekta, Varian)

tumor regression

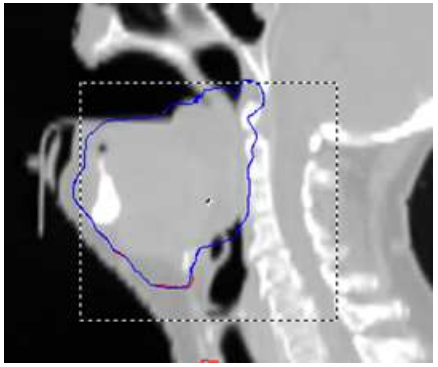

planning CT

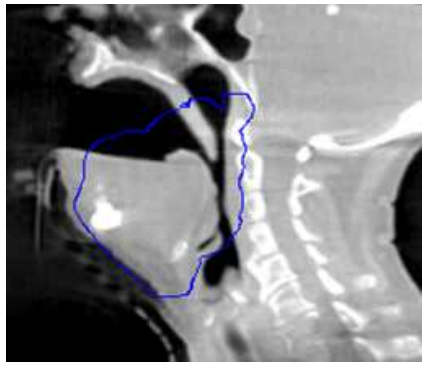

CBCT

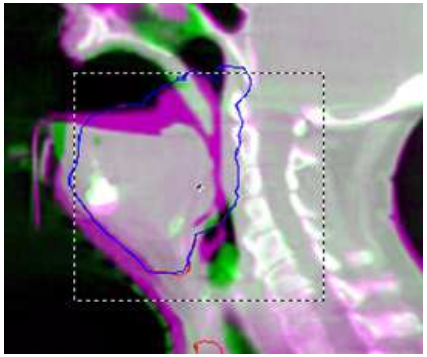

planning CT

CBCT

→ back to the CT scanner

Next IGRT generation: MR-guided RT

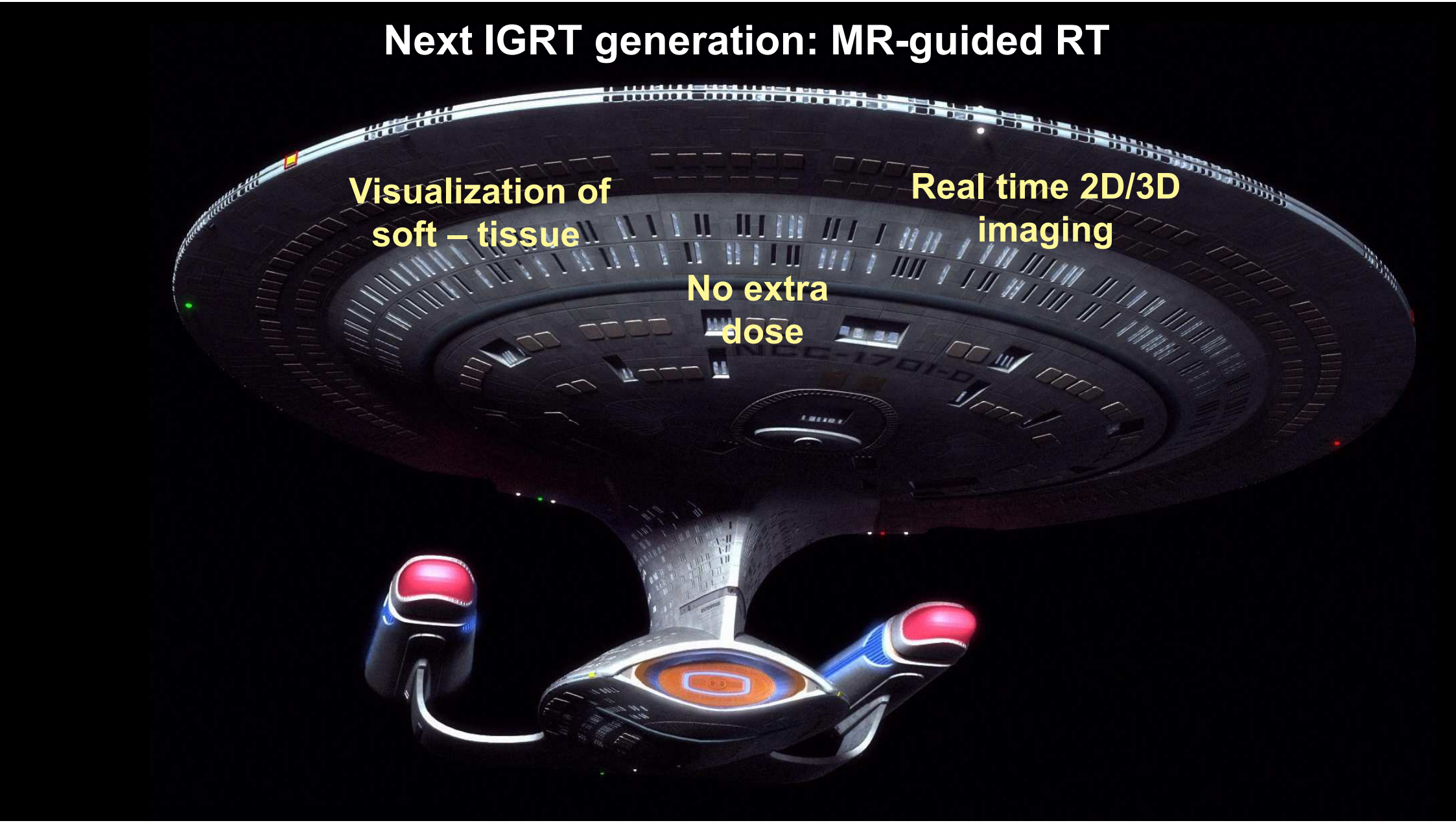

Treatment delivery

MR-guided RT

MRIdian **Viewray**

http://medicalphysicsweb.org/cws/article/research/5617916

0.35 T split magnet MRI
3 Cobalt-60 teletherapy heads → Linac

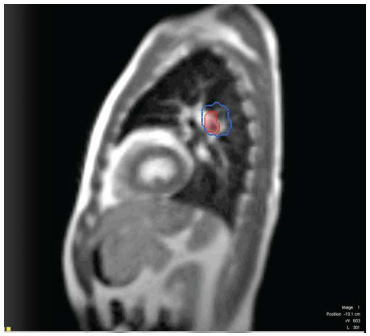

Unity **Philips/Elekta**

cylindrical 1.5 T closed-bore MRI
1st patiënt treated 23rd of May 2017

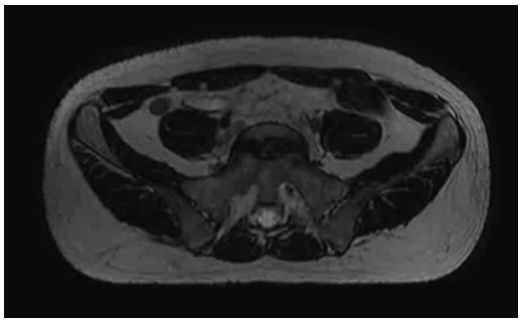

ESTRO School

Image guided Adaptive RT

= modify treatment plan due to anatomical (or physiological) changes

(**IGRT**: acquire image → (rigid) registration → move isocenter/table)

Offline ART ↔ **Online ART**

adapt treatment plan between fractions
→ re-contour & re-plan

- choose plan from “library”
  → plan of the day
- adapt plan “online”
  (while patient on treatment table)

Radboudumc

ESTRO School

“With Great *Imaging* Comes Great Responsibility”

Martina

Radboudumc

ESTRO School

Overview

Image Handling

- Image data in the RT chain
  potential errors, challenges

Martina Kunze-Busch
Radboudumc
Nijmegen, The Netherlands

Image Registration

PART I

- Definition
- A closer look at the different components/steps
  geometrical transformation - similarity measure - optimization algorithm
- Registration accuracy

PART II

- Deformable Image registration – practice at the AvL

Peter Remeijer
NKI-AVL
The Netherlands Cancer Institute
Antoni van Leeuwenhoek Hospital

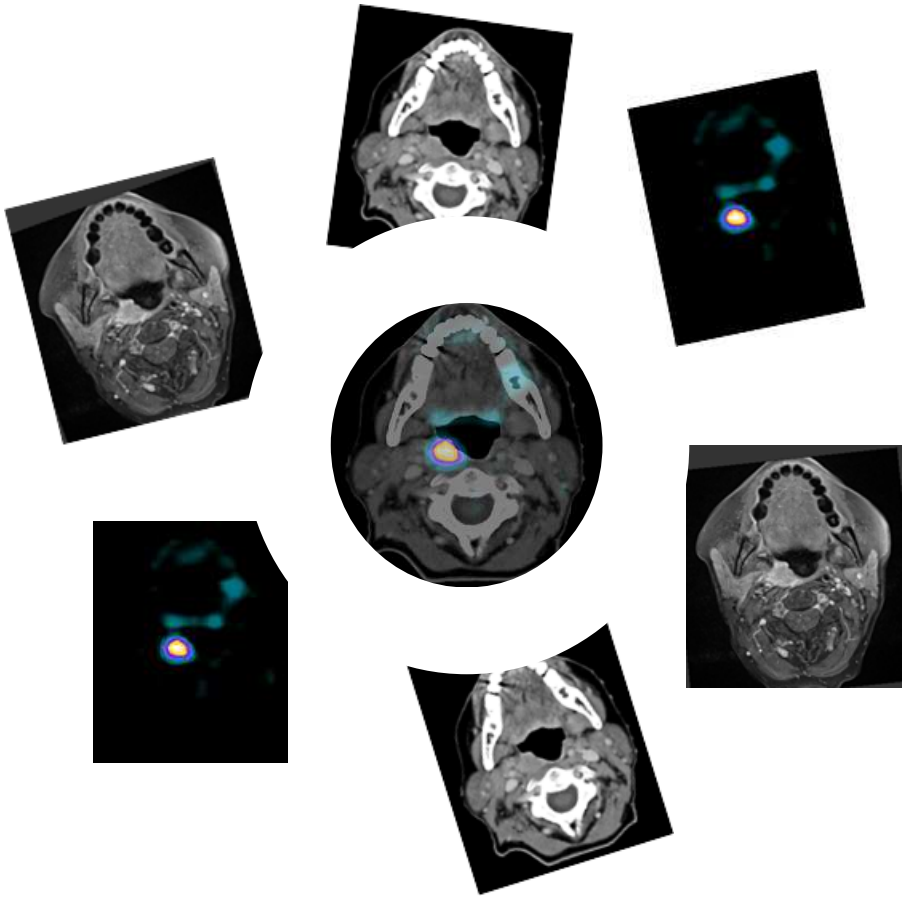

Image fusion
Ju click here

Radboudumc

ESTRO School

Image registration ↔ image fusion

Image registration

spatial alignment/
geometrical transformation T of image

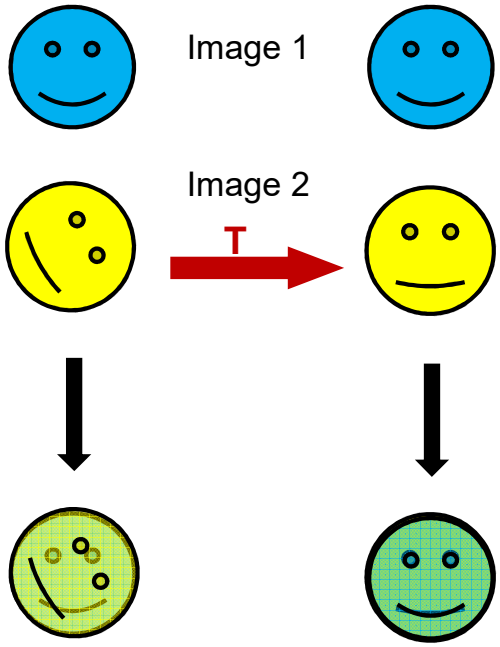

Image fusion

integrated display of data

goal of image registration = find geometric **transformation** that **best** aligns two images

Image registration

The three core components of image registration:

1. Spatial/geometrical transformation T
2. Similarity measure/cost function
3. Optimization algorithm

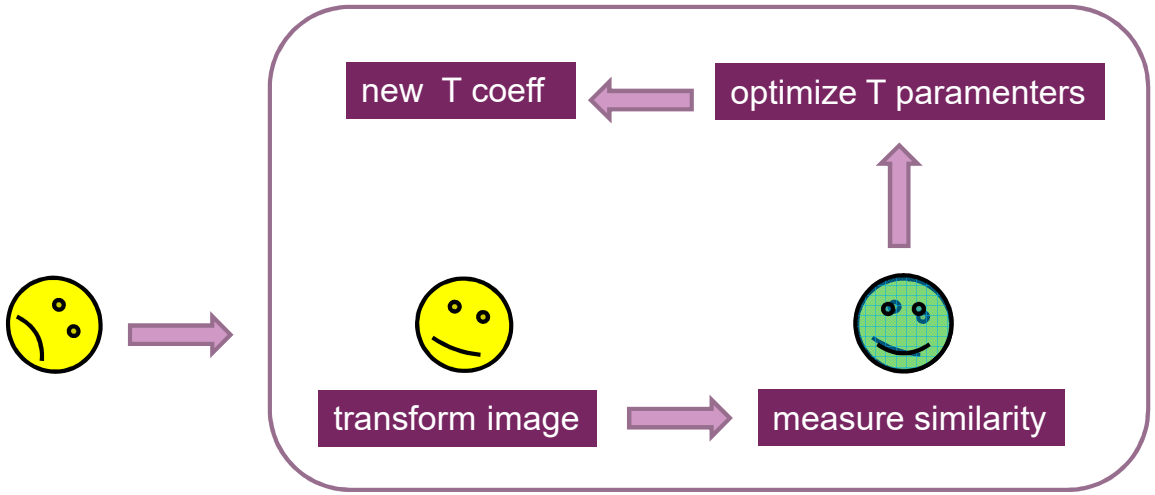

Image registration

The three core components of image registration:

1. Spatial/geometrical transformation T
2. Similarity measure/cost function
3. Optimization algorithm

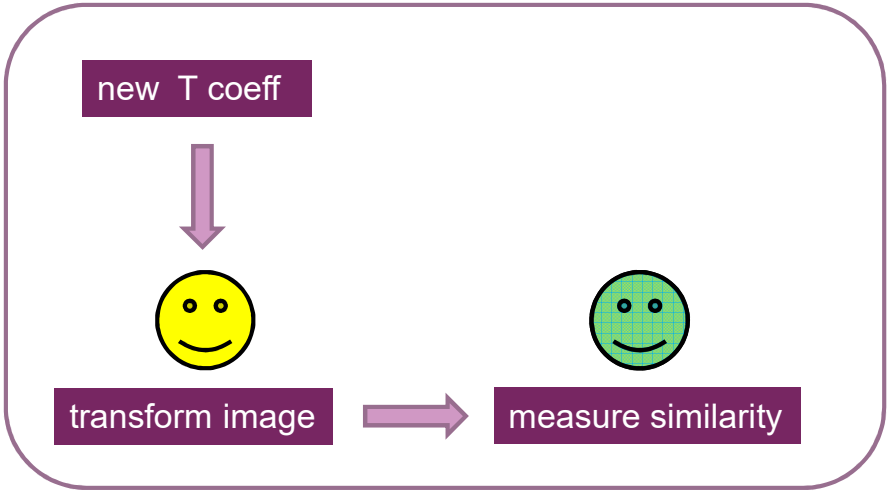

1. Geometrical transformation T

Image 1

- **Rigid**
  - no deformation
  - only translations and rotations are allowed

  (3 rotations, 3 translations → (max) 6 independent parameters)

- **Affine**
  - shearing, stretching

  (3 rotations, 3 translations, 3 stretches, 3 shears → (max) 12 parameters)

1. Geometrical transformation T

- **Deformable /non-rigid**
  - e.g. elastic
    (milions of parameters!)

Image 1

average errors can be in the range of 1 – 5 mm

Validation !

Main applications of DIR in ART

Delineation propagation

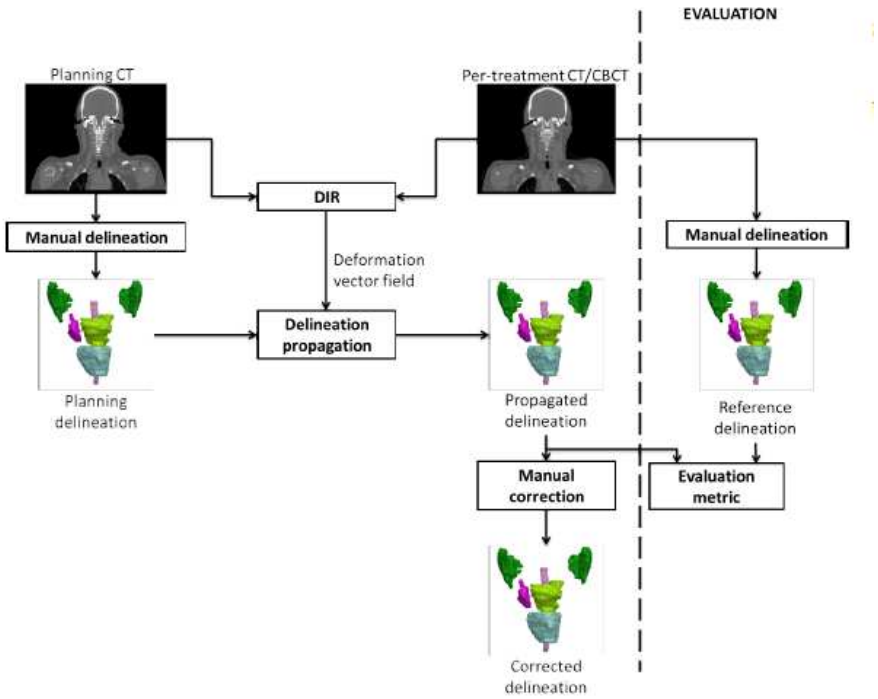

Dose accumulation

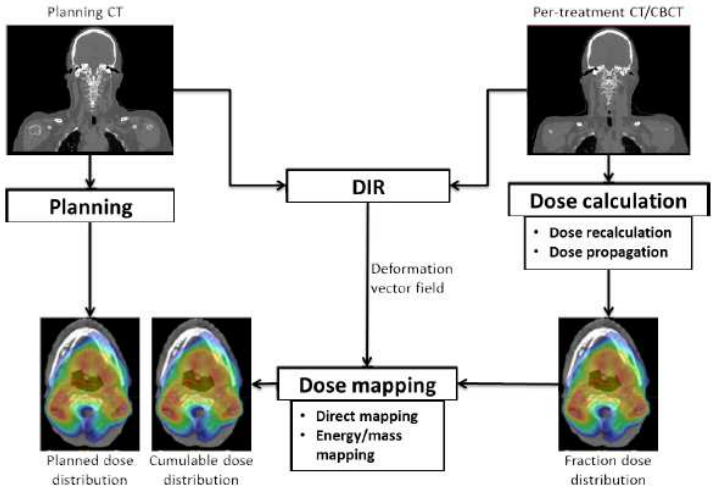

Ref: Simon et al., Conf Proc IEEE Eng Med Biol Soc. 2015

Radboudumc

ESTRO School

Delineation propagation

Would you tell me, please, which way I ought to go from here?
That depends a good deal on where you want to get to.

Alice and the Cat
”Alice in Wonderland”(1951)

Atlas based segmentation

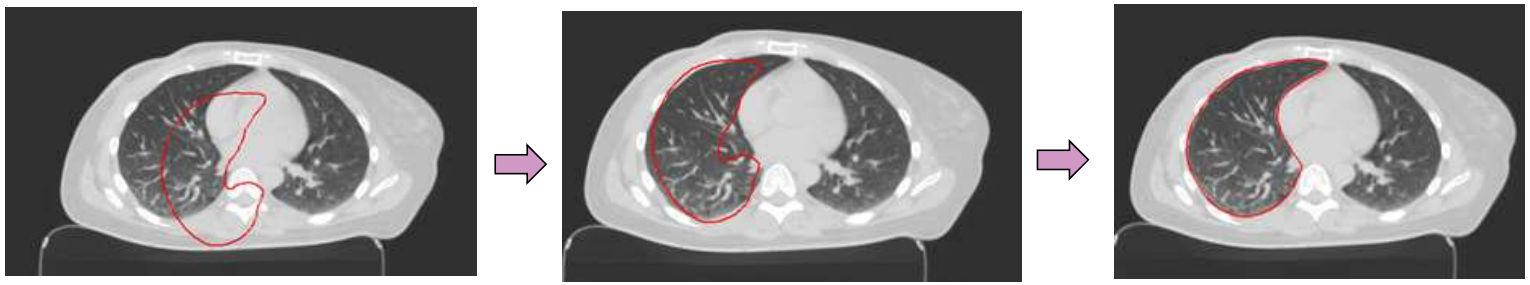

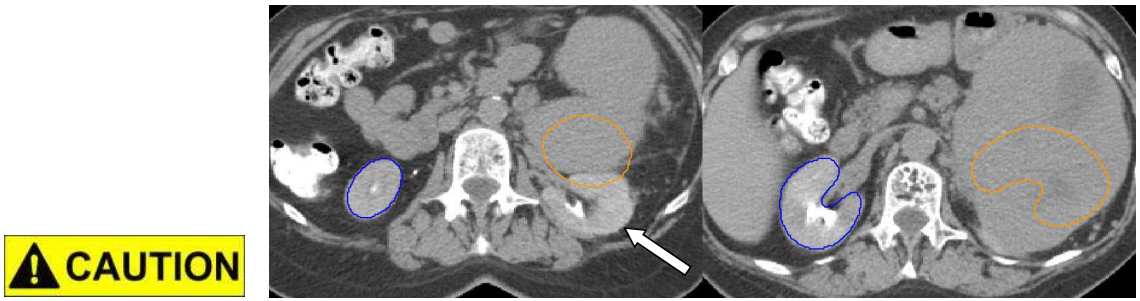

Xin Li et al. PLOS ONE 2017 *Comprehensive evaluation of ten DIR algorithms for contour propagation between CT and CBCT images in adaptive H&N RT*
“Careful examinations and modifications are required before accepting the auto-propagated contours..”

Woerner et al. Technology in Cancer Research & Treatment 2017 *Evaluation of DIR-Based Contour Propagation From Planning CT to CBCT*
“The automatic workflows using DIR to deform contours to CBCT to evaluate the changes during treatment should be used with caution..”

Main applications of DIR in ART

Delineation propagation ✓

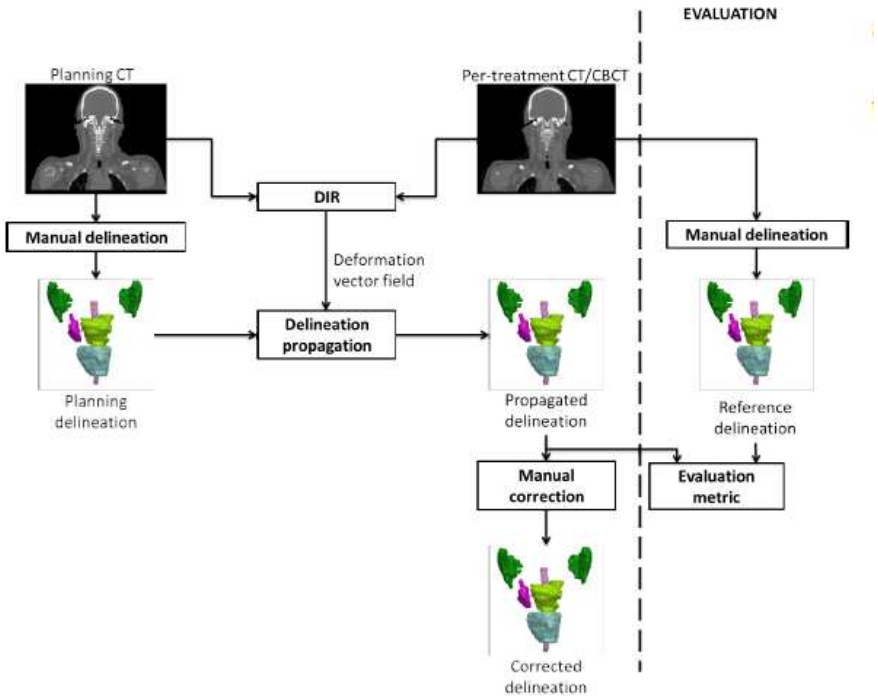

Dose accumulation

Ref: Simon et al., Conf Proc IEEE Eng Med Biol Soc. 2015

Radboudumc

ESTRO School

CAUTION

Dose warping/mapping

Dose accumulation

warped dose uncertainty
=
spatial error (due to registration) x dose gradient

Prof. Jean Pouliot
AAPM 2014

active area of research
and discussion

J. Appl Clin Med Phys (2016) Nie et al.
"As dose-transferring errors could cause misinterpretations when attempting to accumulate dose for ART …standard & clinically meaningful QA criterion should be established….

IJROBP 90 (2014) Mencarelli et al.
"Caution…when applying DIR for tumor changes in adaptive procedures"

AAPM 2014 Moriya et al.
Study on lung SBRT patients
"commissioning test is essential .... should understand pitfalls of dose warping"

Med Phys 39 (2012)
It is not appropriate to "deform" dose along with deformable image registration in adaptive RT Point/Counterpoint

Med Phys 39 (2012) Yeo et al.
"Substantial differences can be seen between … different algorithms indicating that DIR performance should be scrutinized before application to dose-warping."

Radboudumc

ESTRO School

Image registration

The three core components of image registration:

1. Spatial/geometrical transformation T
2. Similarity measure/cost function
3. Optimization algorithm

2. Similarity measure

Similarity measure quantifies degree of similarity between 2 images

Different methods exist:

- FEATURE – based
- INTENSITY – based (grey values)
- MODEL – based

Radboudumc

ESTRO School

2. Similarity measure

Feature-based method

- extract feature from images & evaluate distance between features
- employed when local accuracy is important
- dependent on accuracy of feature extraction

2 types:

Landmark-based method



Segmentation-based method



2. Similarity measure

Intensity-based method (grey values)





- all pixels in overlapping regions are utilized
- does not require detection of geometric features
- time consuming

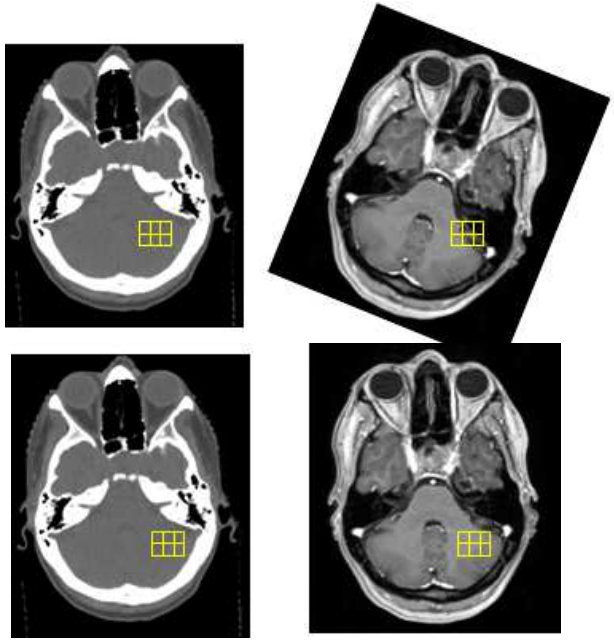

e.g. *mutual information*

2. Similarity measure

Model-based method

e.g. deformable transformation model for contours

similarity measure + regularization/penalty term (tissue characteristics)



CAUTION

deformable image registration

deformable image registration

reality

without deformable image registration

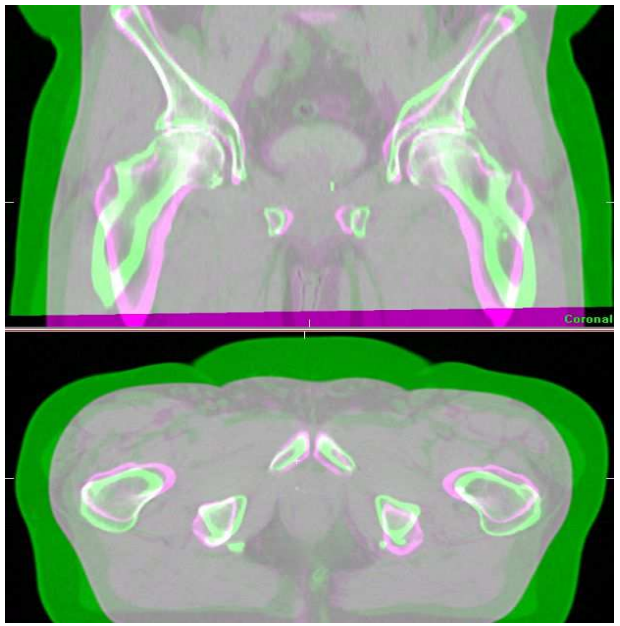

Radboudumc NKI-AVL The Netherlands Cancer Institute Antoni van Leeuwenhoek Hospital ESTRO School

2. Similarity measure/COST FUNTION

description of problem in **mathematical terms**

value of cost function reflects quality of registration: smallest value = best solution

Example:

find shortest way to Rome → cost function = Σ path lengths

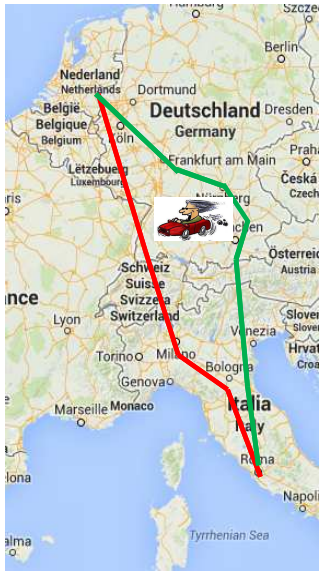

answer: red

find fastest way to Rome → extra parameter: speed limit

answer: green

Radboudumc

ESTRO School

3. Optimizer/optimization algorithm

optimizer finds smallest value of cost function (= “optimal” transformation)

example: gradient descent

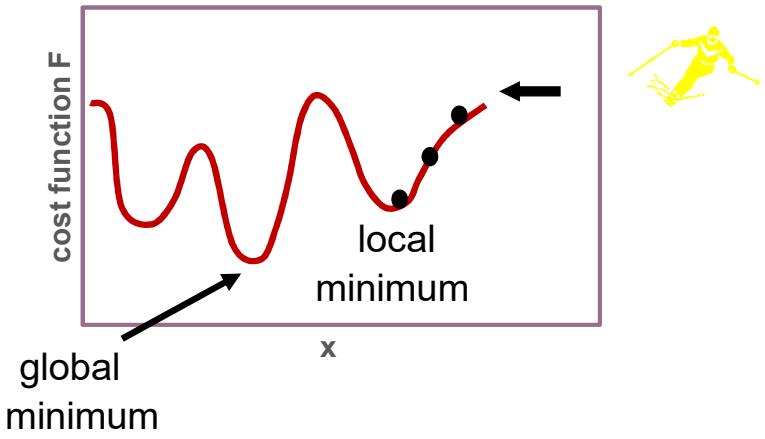

simplified

Registration accuracy

Examples for registration uncertainties:

~ 0.5 mm for cranial **CT-CBCT** registration
(Sykes et al.,PMB 2009)

≤ 2 mm for cranial **CT-MR** registration
(Ulin et al., IJROBP 2010)

≥ 2 mm for **CT-MR** registration for rectal cancer
(Dean et al., BJR 2012)

~ 2 mm for **CT-MR** registration for prostate
(Nyholm et al., Radiat. Onc. 2009)

~ 5-7 mm for DIR
(Yeo et al., Med. Phys 2013)

Registration accuracy

Registration uncertainties depend e.g. on:

- anatomical site
- amount of deformation between the 2 images
- limitations of registration algorithm
- spatial distortions (e.g. MR distortion)

Impact

RT chain

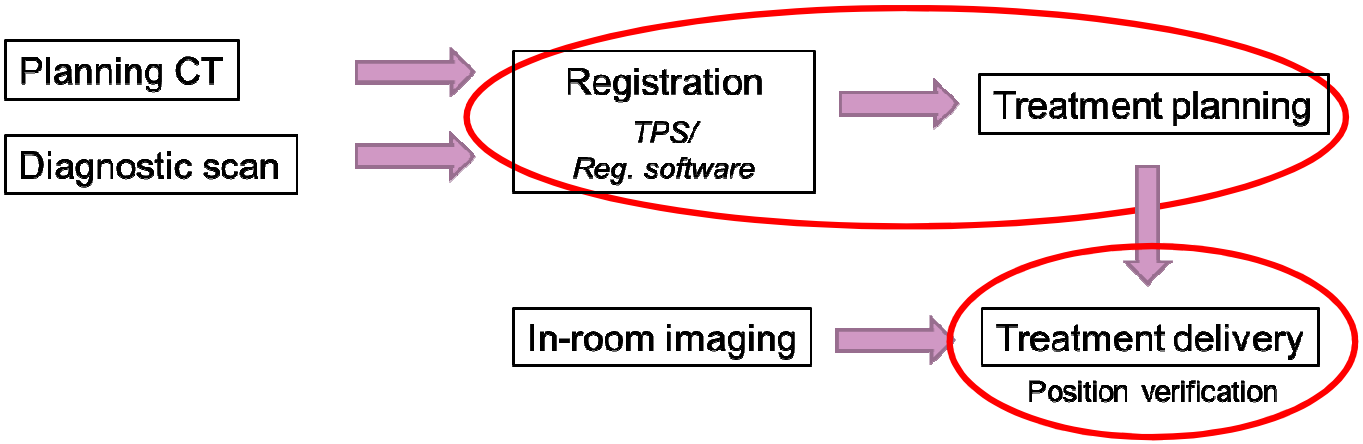

Radboudumc

ESTRO School

Evaluation of registration

Visual inspection of deformation field

warped grid | vector field | heat maps

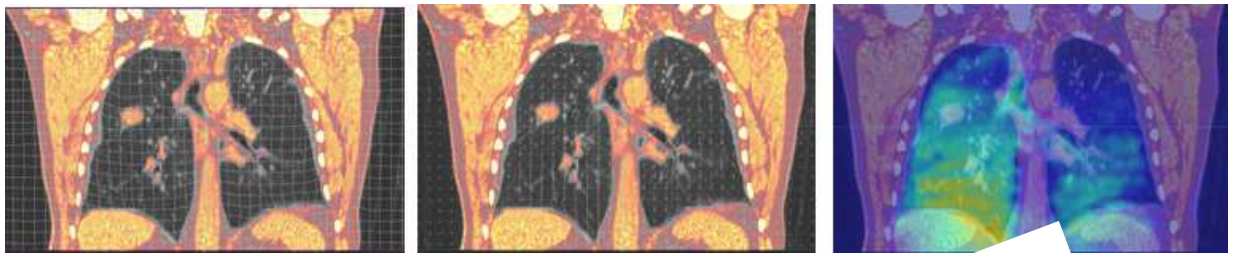

MIRADA medical

Common metr

- Volume based metric: DIC

Metrics not a reliable criteria for registration accuracy

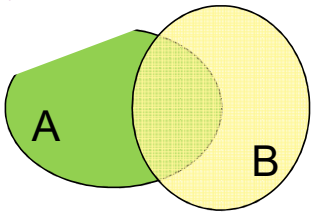

- Surface based m . Hausdorff Distance, DTA distance to agreement

ESTRO School

Physical or digital QA of software required!

Mechanical phantom

- physical deformable
- in vivo-dosimetry

e.g. lung phantom Univ. of Michigan

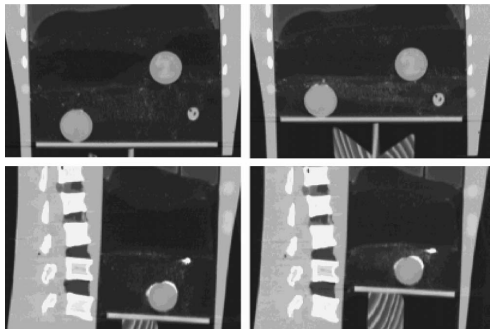

Kashani et al., Med Phys 35 (2008)

e.g. deformable H&N phantom Univ. of Calif.

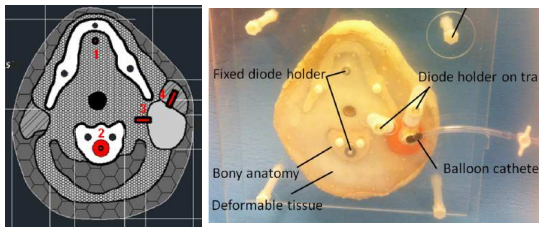

Graves et al., Med Phys 42 (2015)

Simulation

- artificially deformed real patient images or virtual phantoms

e.g. ImSimQA (commercial software)

Clinical images

- real patient image data

e.g. - data set from dir-lab/popi…

- replanning CTs or CBCTs

Radboudumc

ESTRO School

Some reading material



- Brock (editor) *Image Processing in Radiation Therapy,* CRC Press 2013
- Kessler et al., BJR 2006 *Image registration and data fusion in radiation therapy*
- Brock et al., IJROBP 2010 *Results of a multi-institution deformable registration accuracy study (MIDRAS)*

OUT NOW !

Use of Image Registration and Fusion Algorithms and Techniques in Radiotherapy: Report of the AAPM Radiation Therapy Committee Task Group No. 132

Kristy K Brock, Chair *Medical Physics 2017*

Start: 3/9/2006
End: May 2017

Radboudumc

ESTRO School

Overview

Image Handling

- Image data in the RT chain
  potential errors, challenges

Martina Kunze-Busch
Radboudumc
Nijmegen, The Netherlands

Image Registration

PART I

- Definition
- A closer look at the di
  geometrical transforma
- Registration accuracy

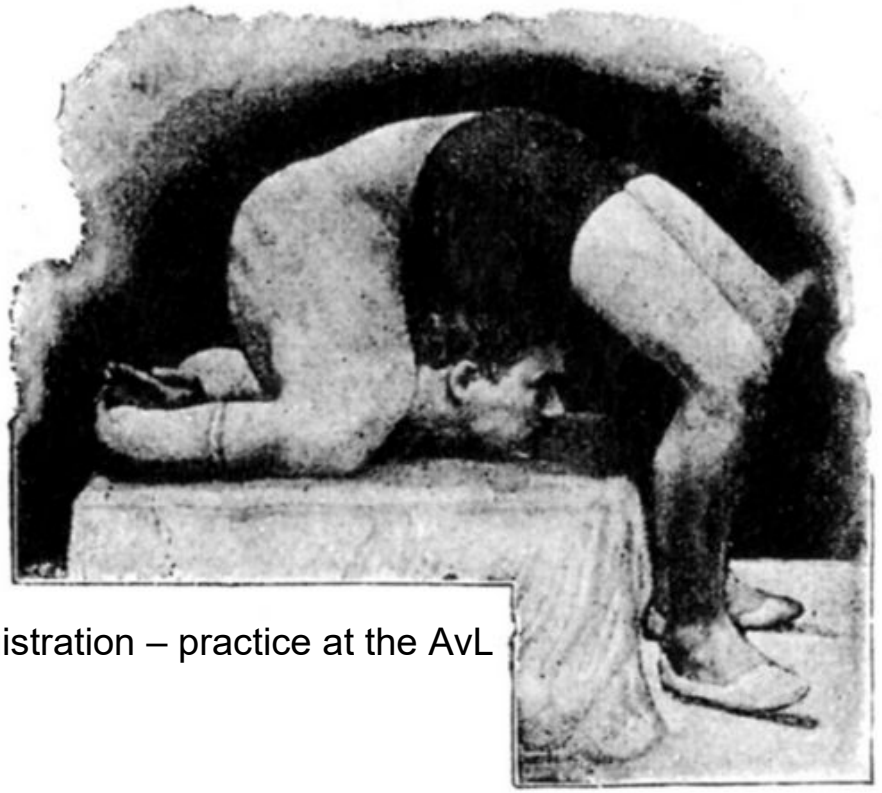

PART II

- Deformable Image registration – practice at the AvL

Peter Remeijer
NKI-AVL
The Netherlands Cancer Institute
Antoni van Leeuwenhoek Hospital

ESTRO School

WWW.ESTRO.ORG/SCHOOL

Inter-observer variation in target volume delineation

Peter Remeijer
Department of Radiation Oncology
The Netherlands Cancer Institute

ESTRO School

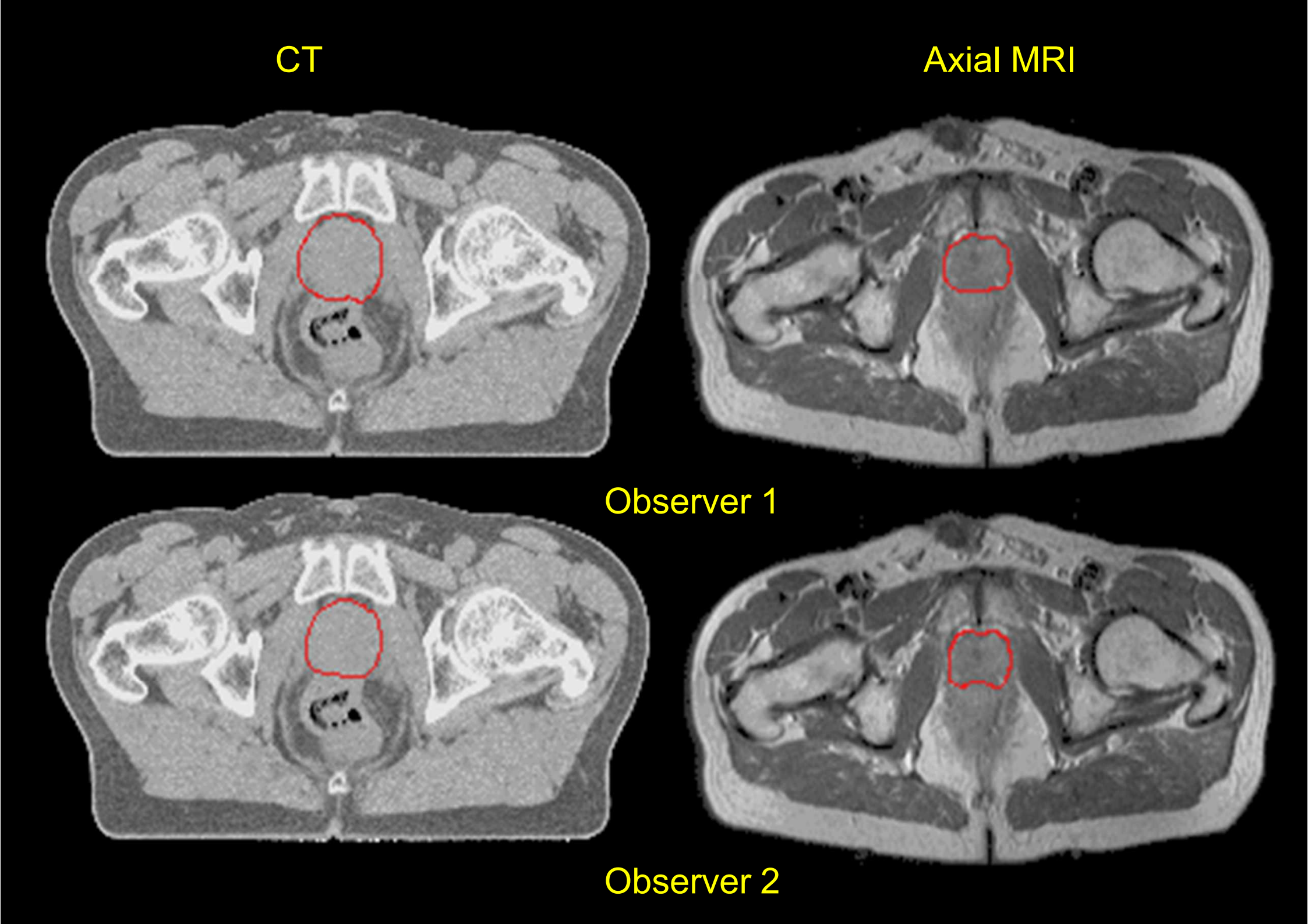
CT
Axial MRI
Observer 1
Observer 2

What influences delineation uncertainty?

ESTRO School

Lack of coffee…..

ESTRO School

… or too much coffee

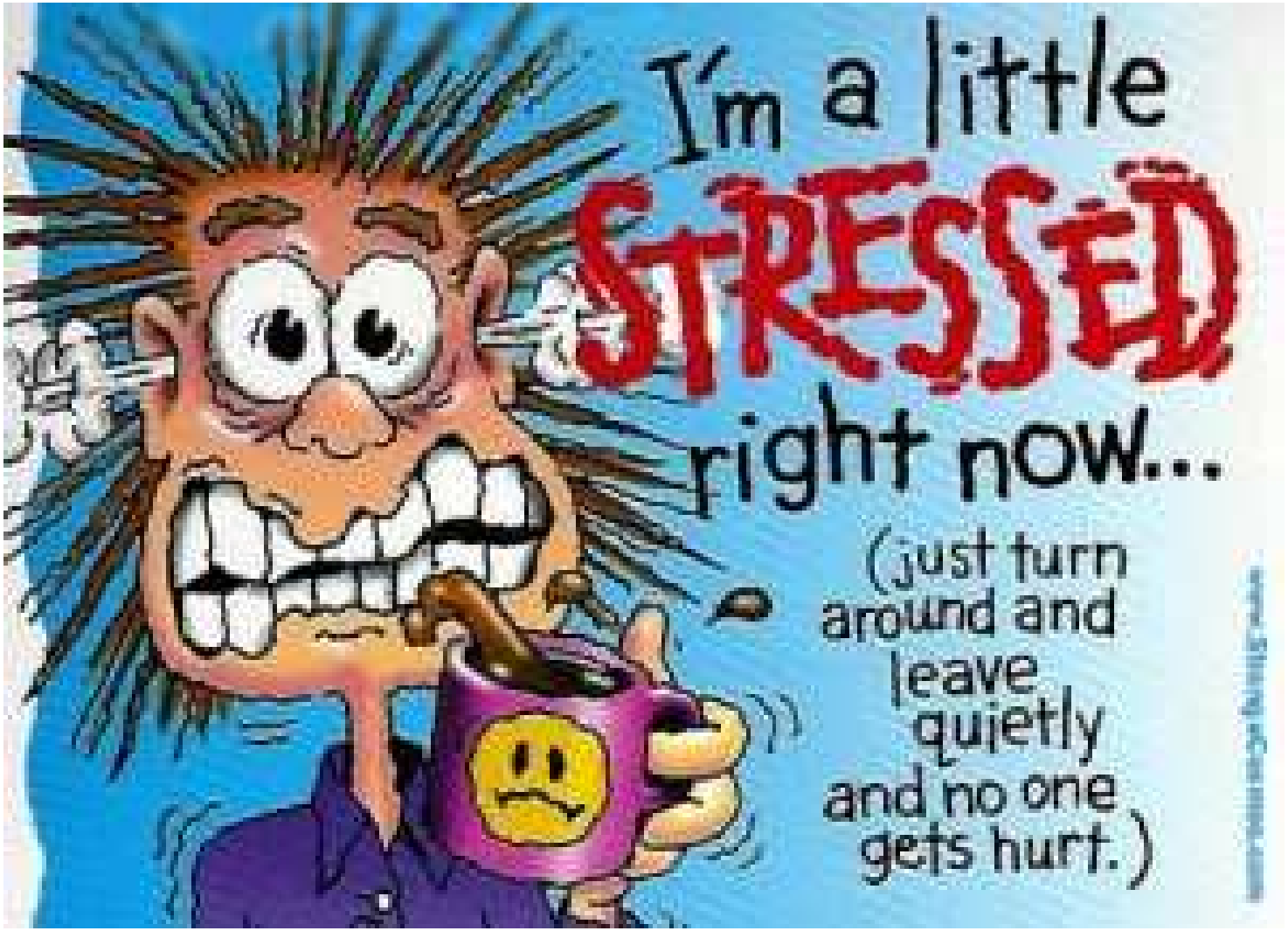

Level/window

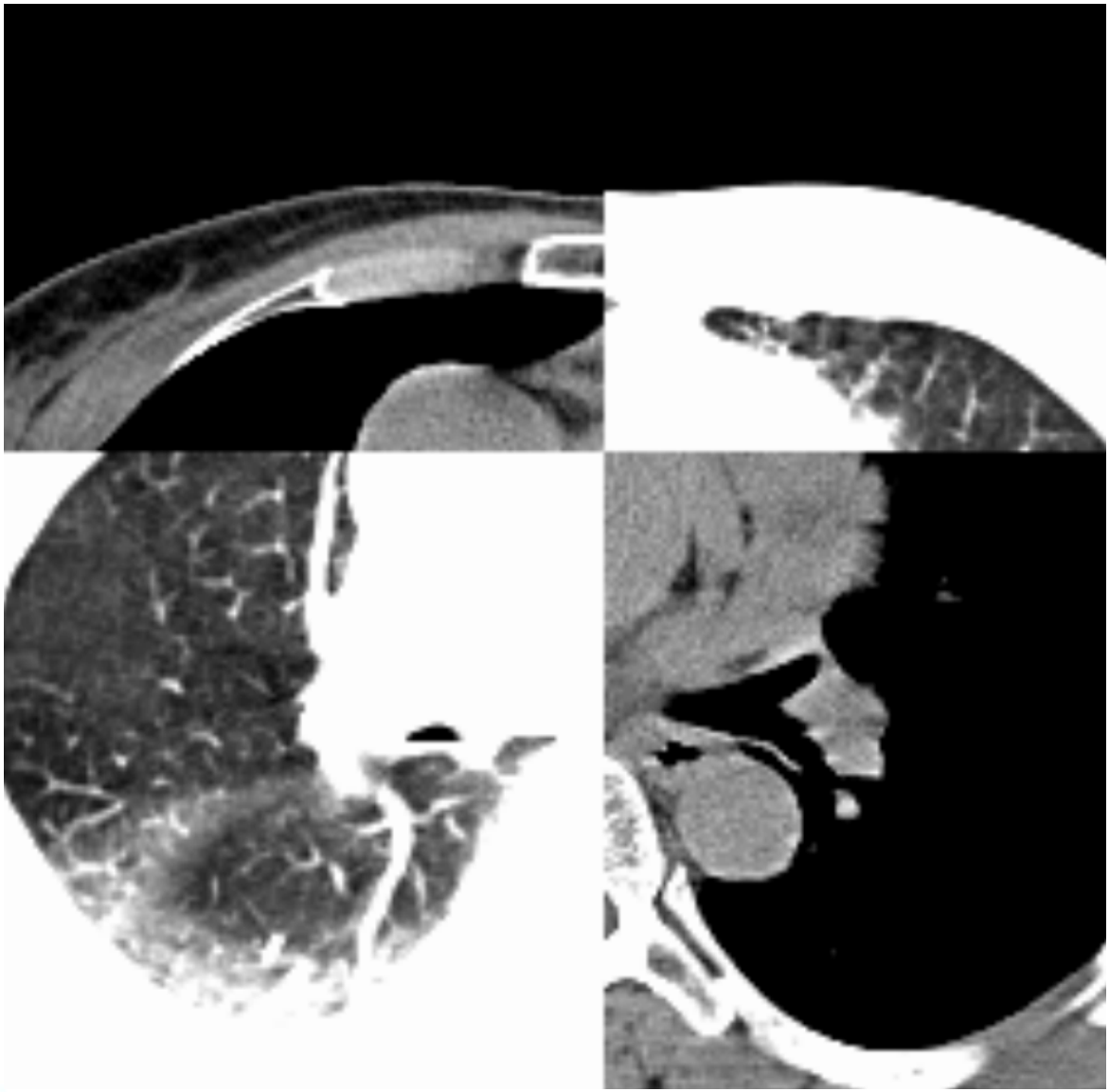

Modalities

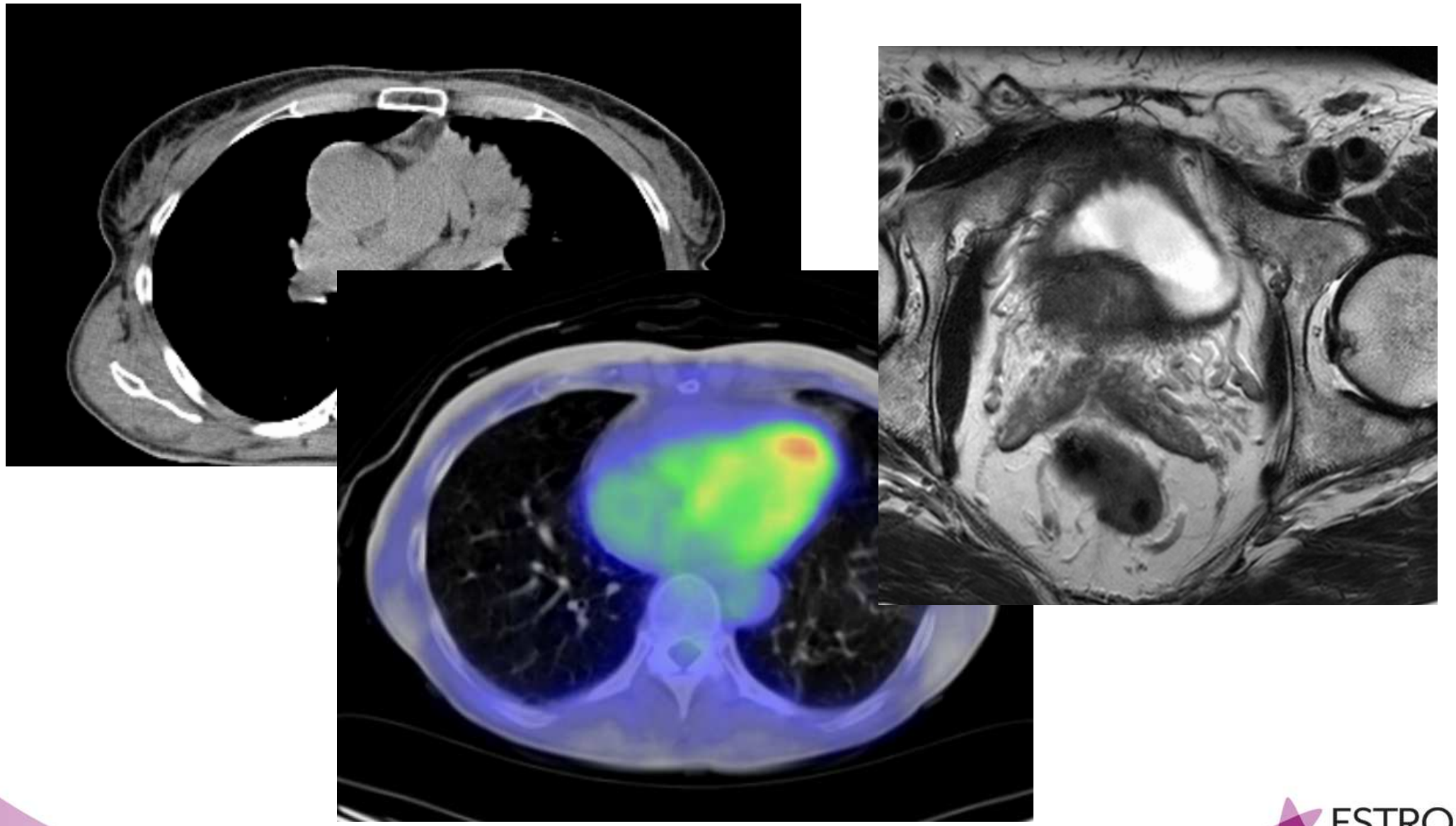

Resolution

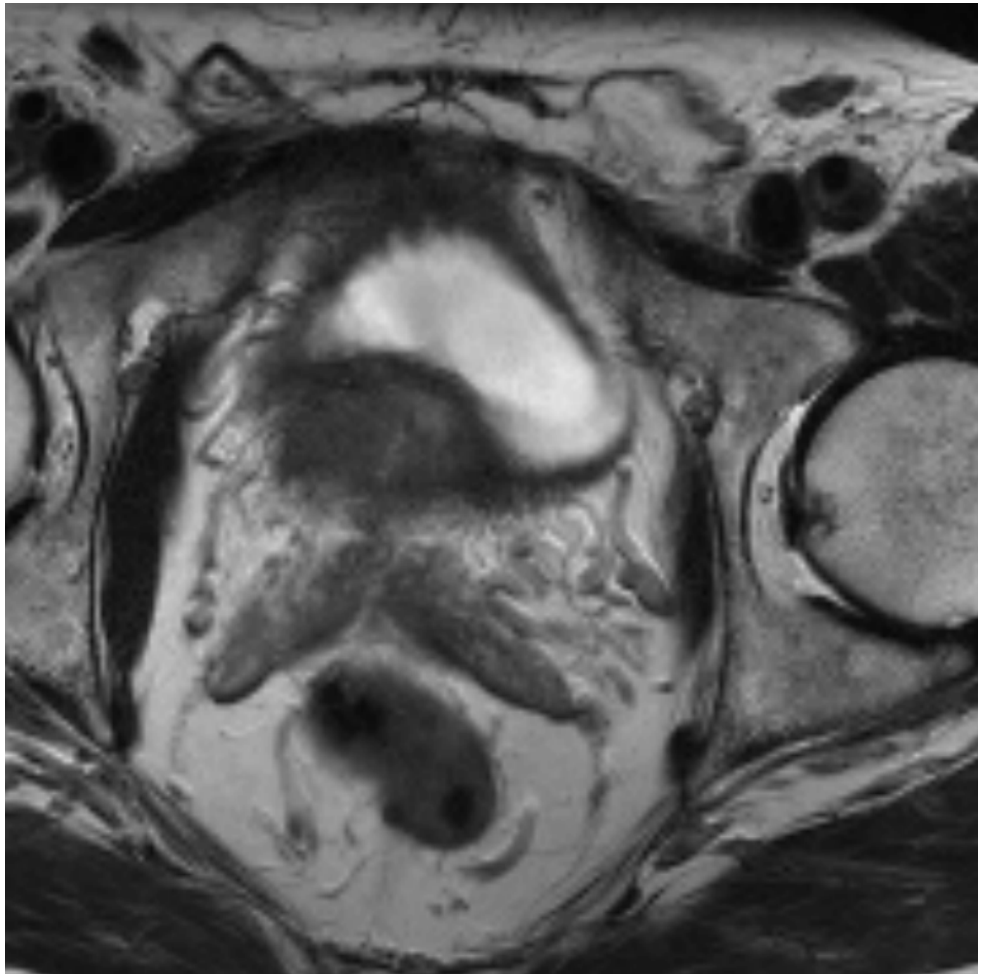

1 mm pixel size

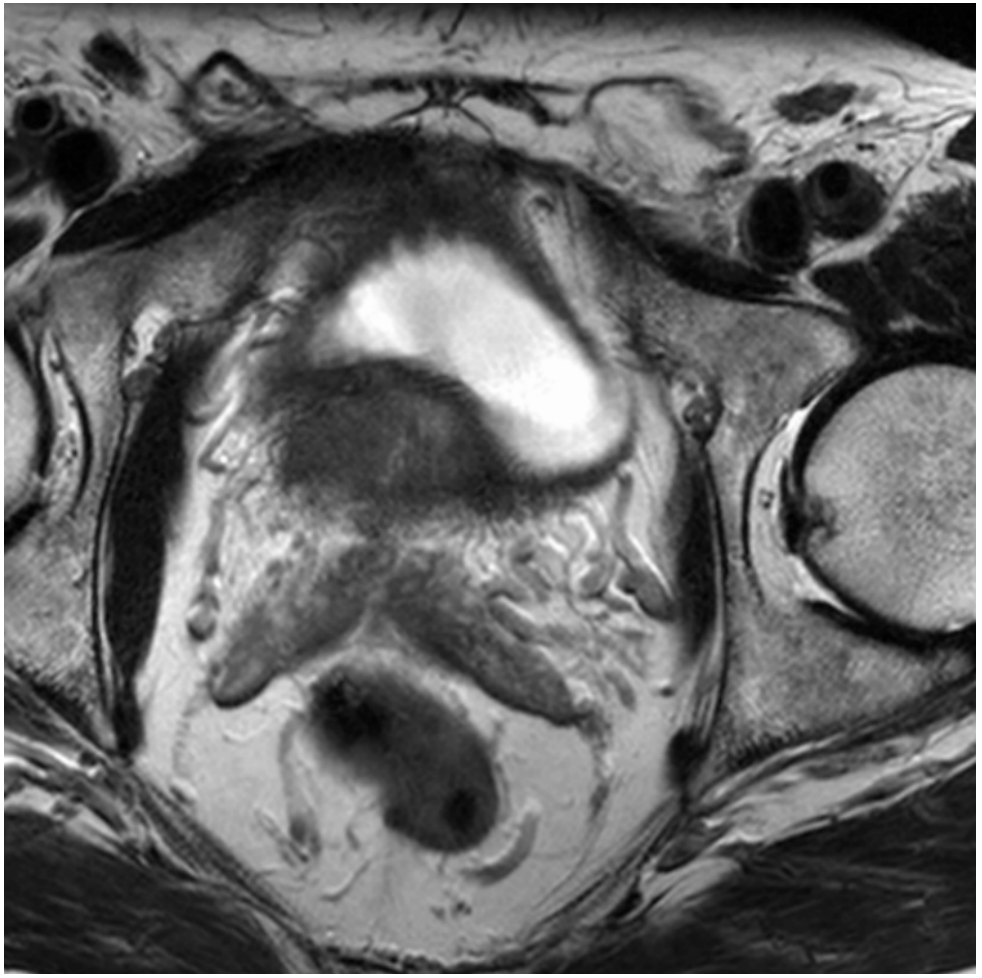

0.4 mm pixel size

ESTRO School

MRI artifacts can cause invisible geometrical errors!

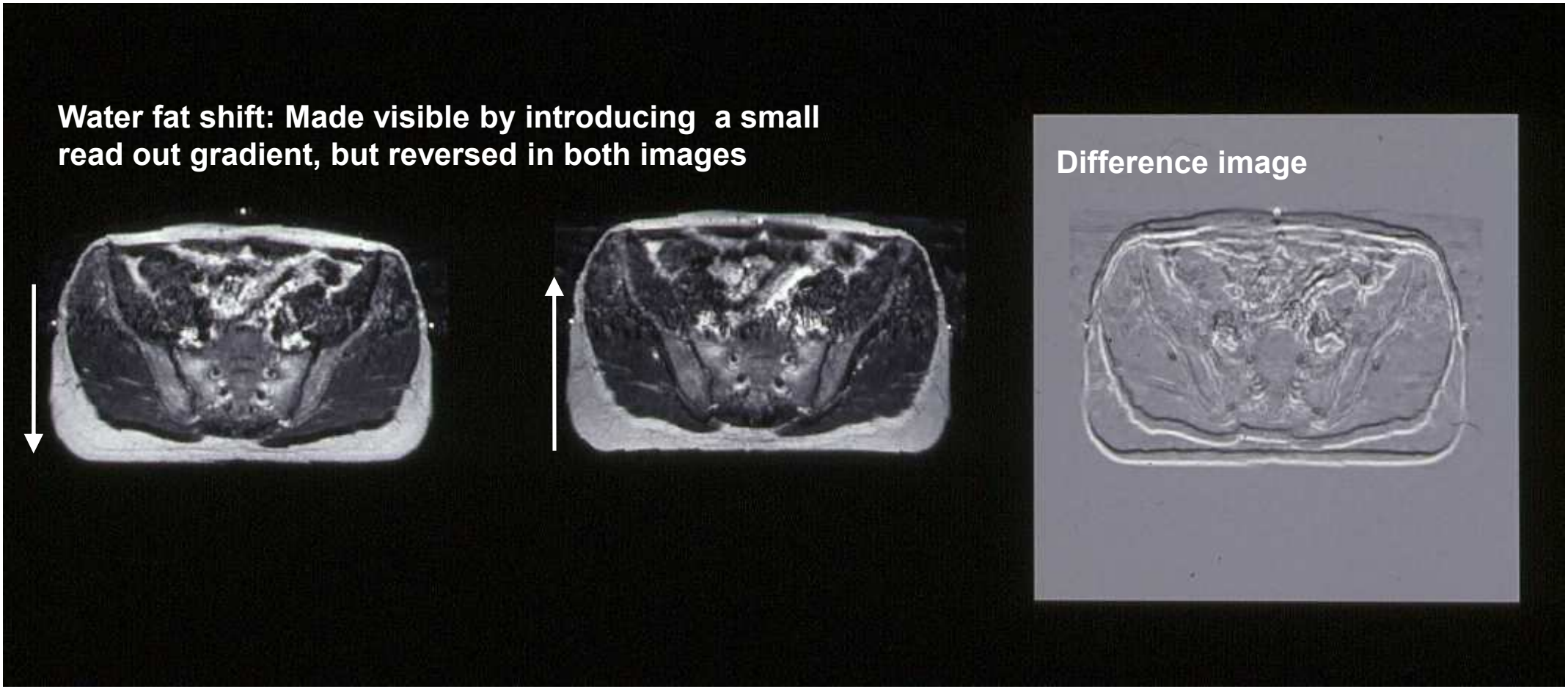

→ Relative position of bone and tumor geometrically incorrect

Courtesy U. van der Heide

Registration

- Planning and image guidance is CT and CBCT based
- Delineation often based on MRI or PET

→ Registration error = Delineation error!

- Be careful with registrations – especially deformable

Anything can be deformed in anything else…
But is it true?



Why is this so important?

- Purely systematic error source
- Effectively shifts the dose distribution for ALL fractions
- Margin = 2.5 x SD of the errors
- E.g. 4 mm SD → 1 cm margin!

ESTRO School

How to analyze?

- Volumes?

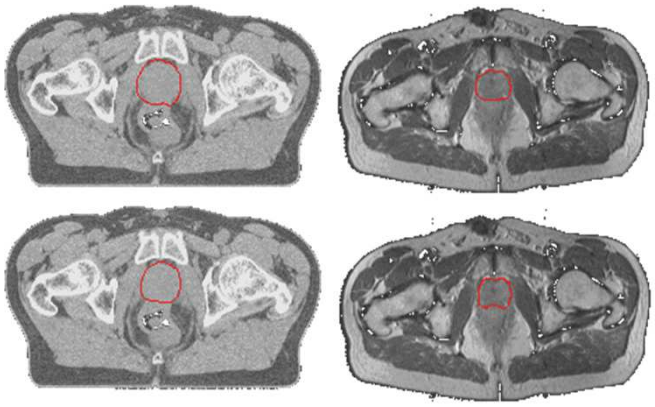



How to analyze: Volumes?

- Volumes?
- Often used: DICE index

- DICE Index = $\frac{2 * \text{common volume}}{\text{Volume 1} + \text{Volume 2}}$

- No common volume: Index = 0
- Volumes identical: Index = 1

ESTRO School

How to analyze: Volumes?

- Problem: Left and right have the same volume difference!
- DICE index the same for both situations
- Clinically this may have a completely different impact

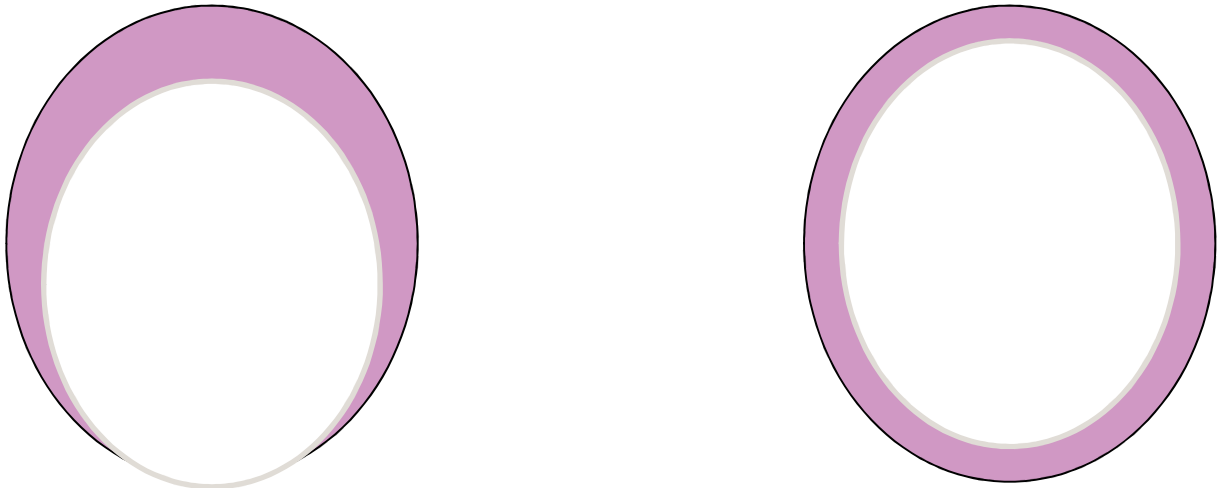

→ DICE is mainly a qualitative comparison tool

ESTRO School

How to analyze?

- Dose?
- E.g. evaluate DVHs of different structures
- Better, because spatial information is taken into account

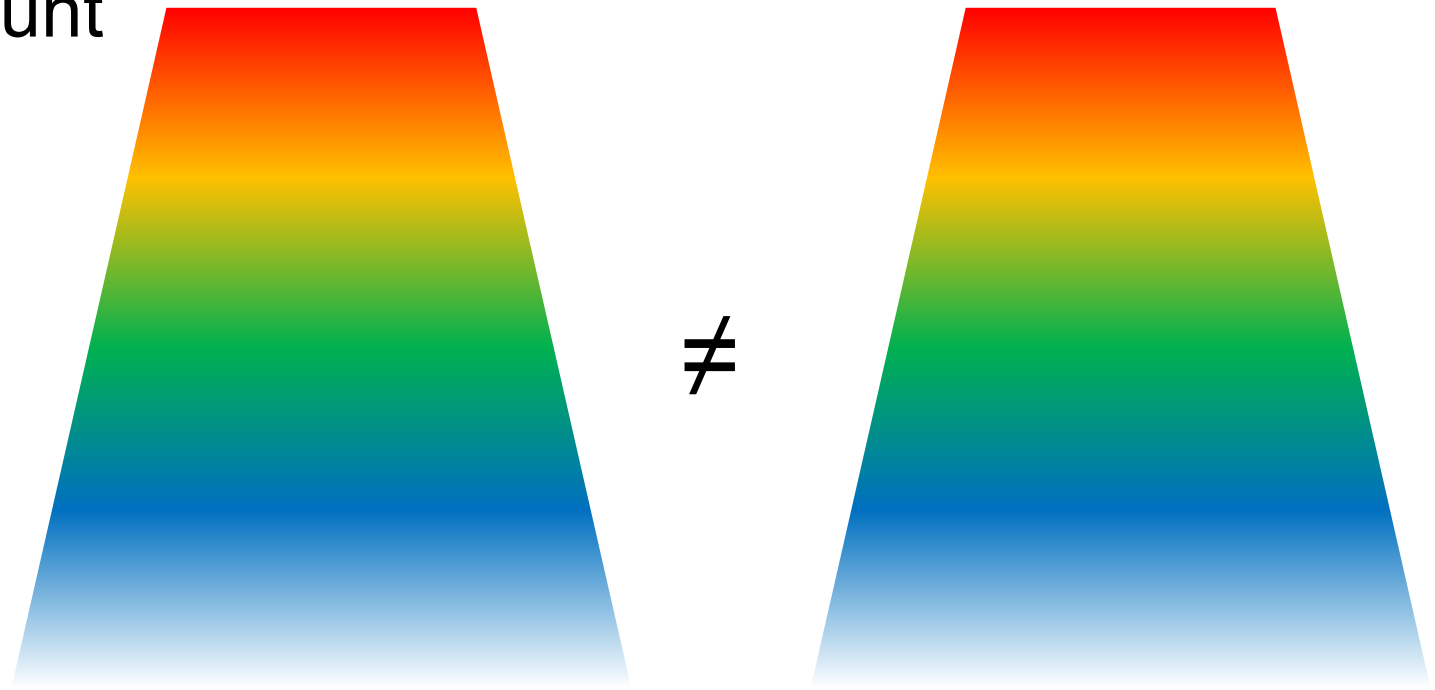

- Still no information on where the difference is

ESTRO School

How to analyze?

- Volumes?
- Dose?
- Distances in many directions!

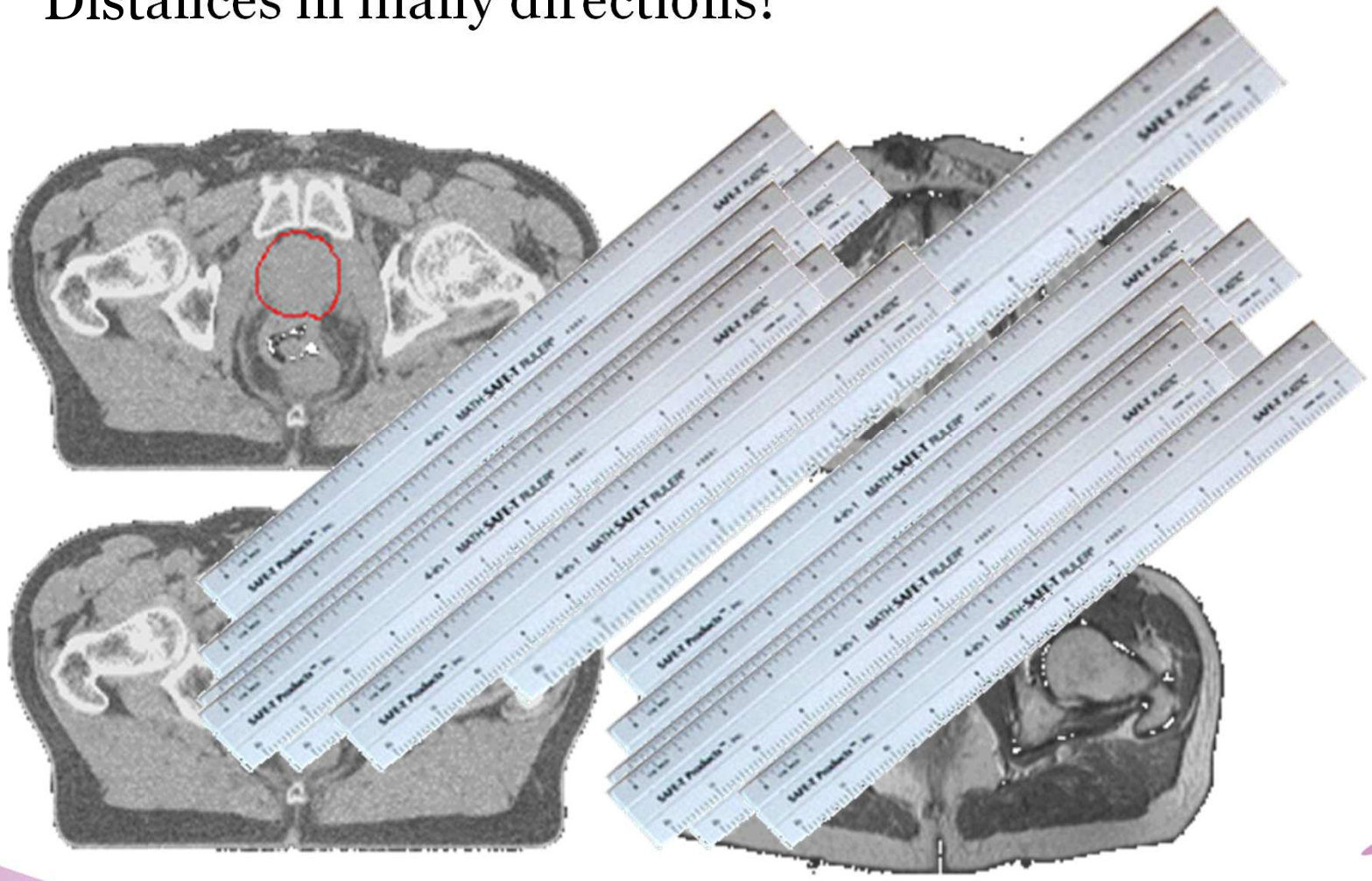

ESTRO School

Distance maps

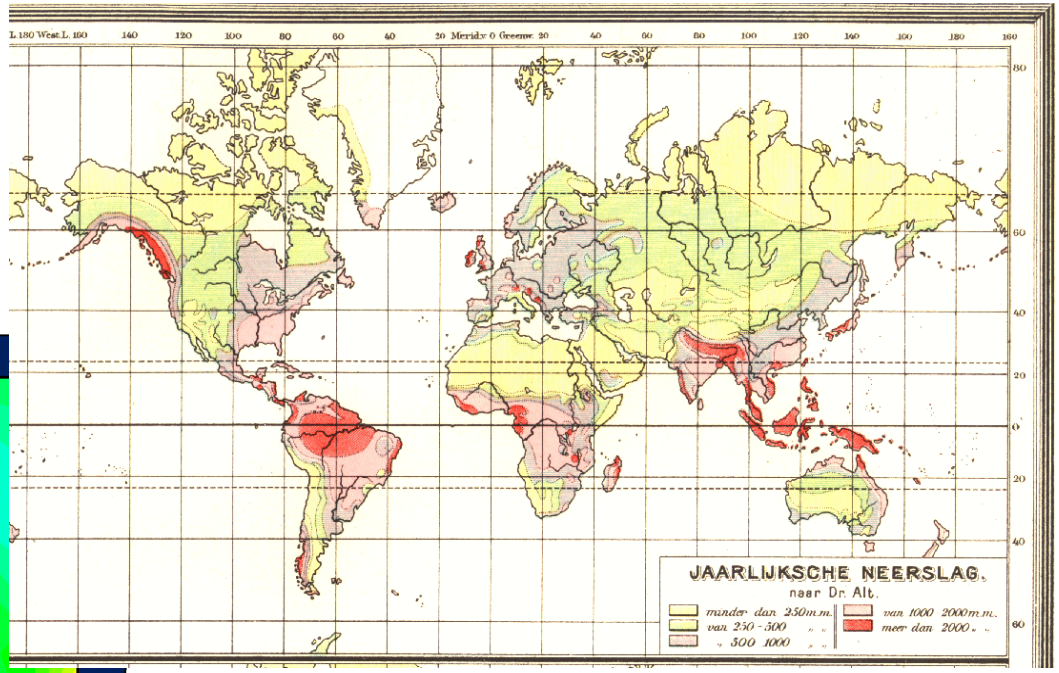

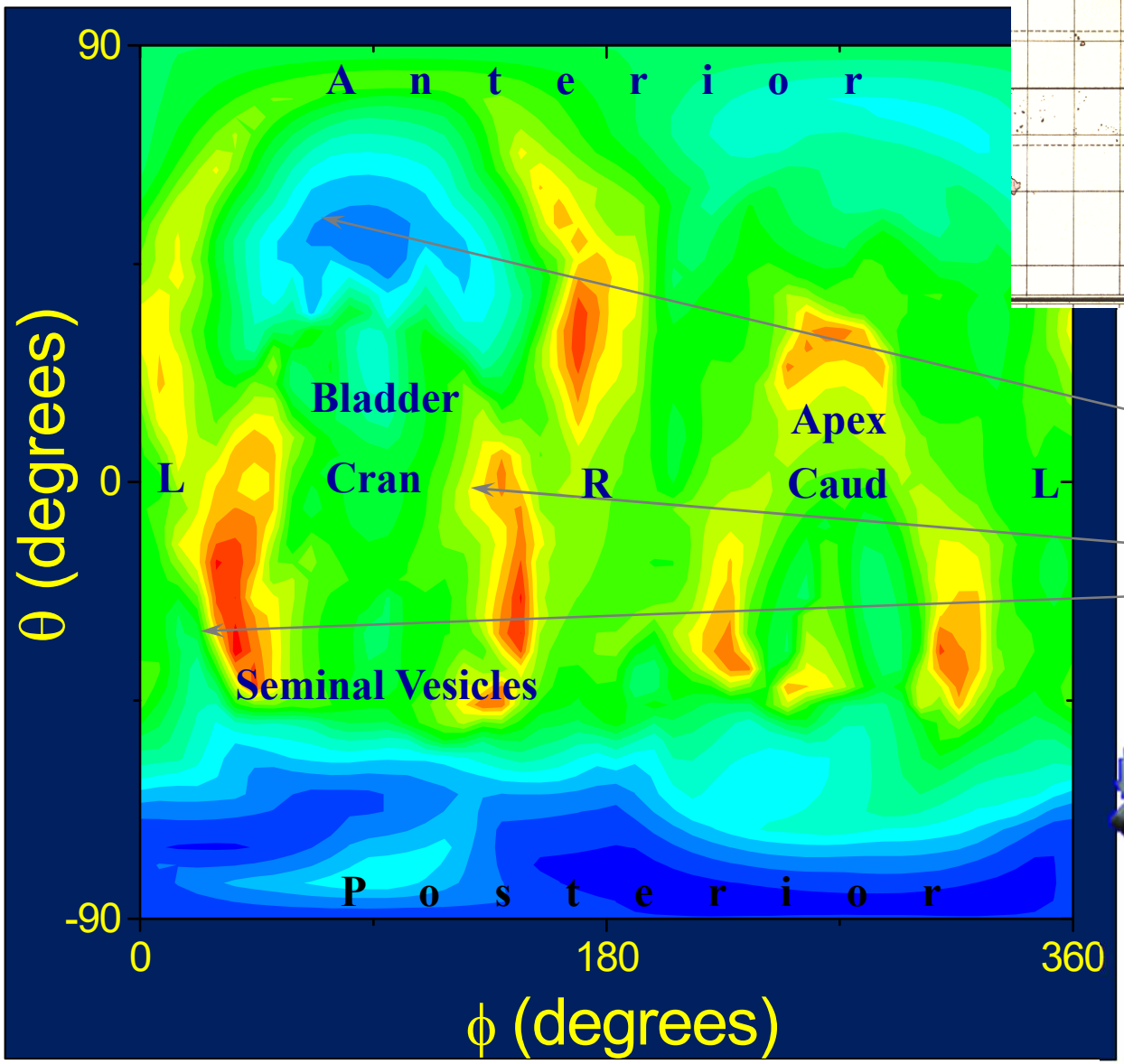

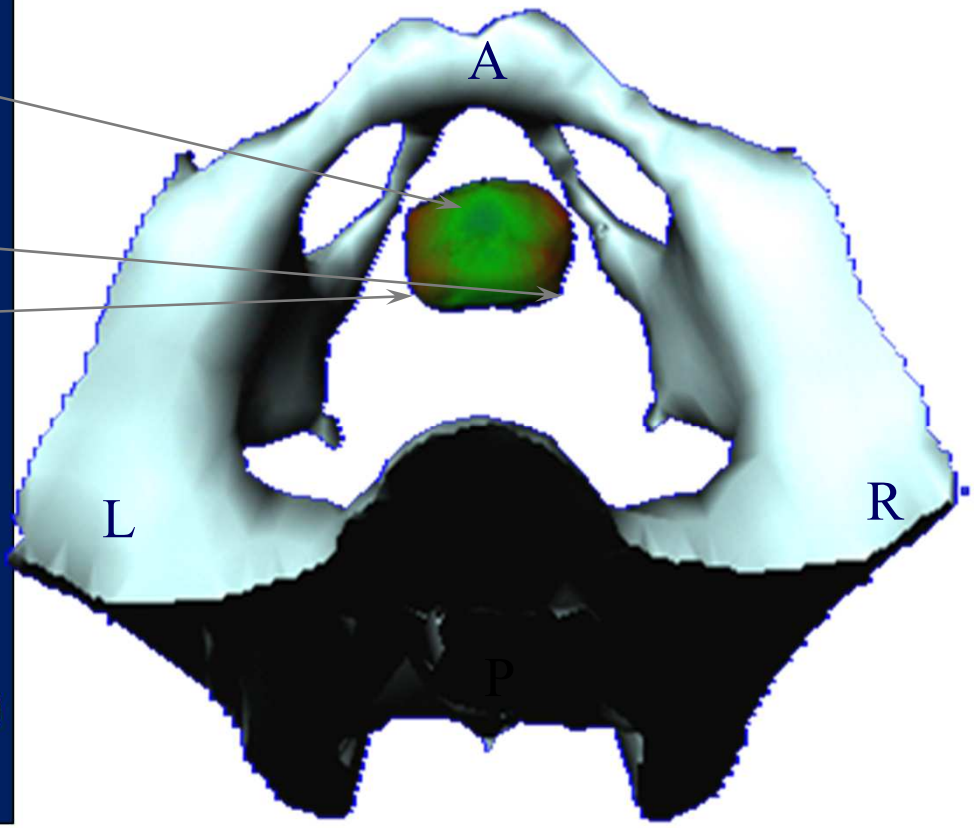

Systematic modality difference (axial MRI - CT)

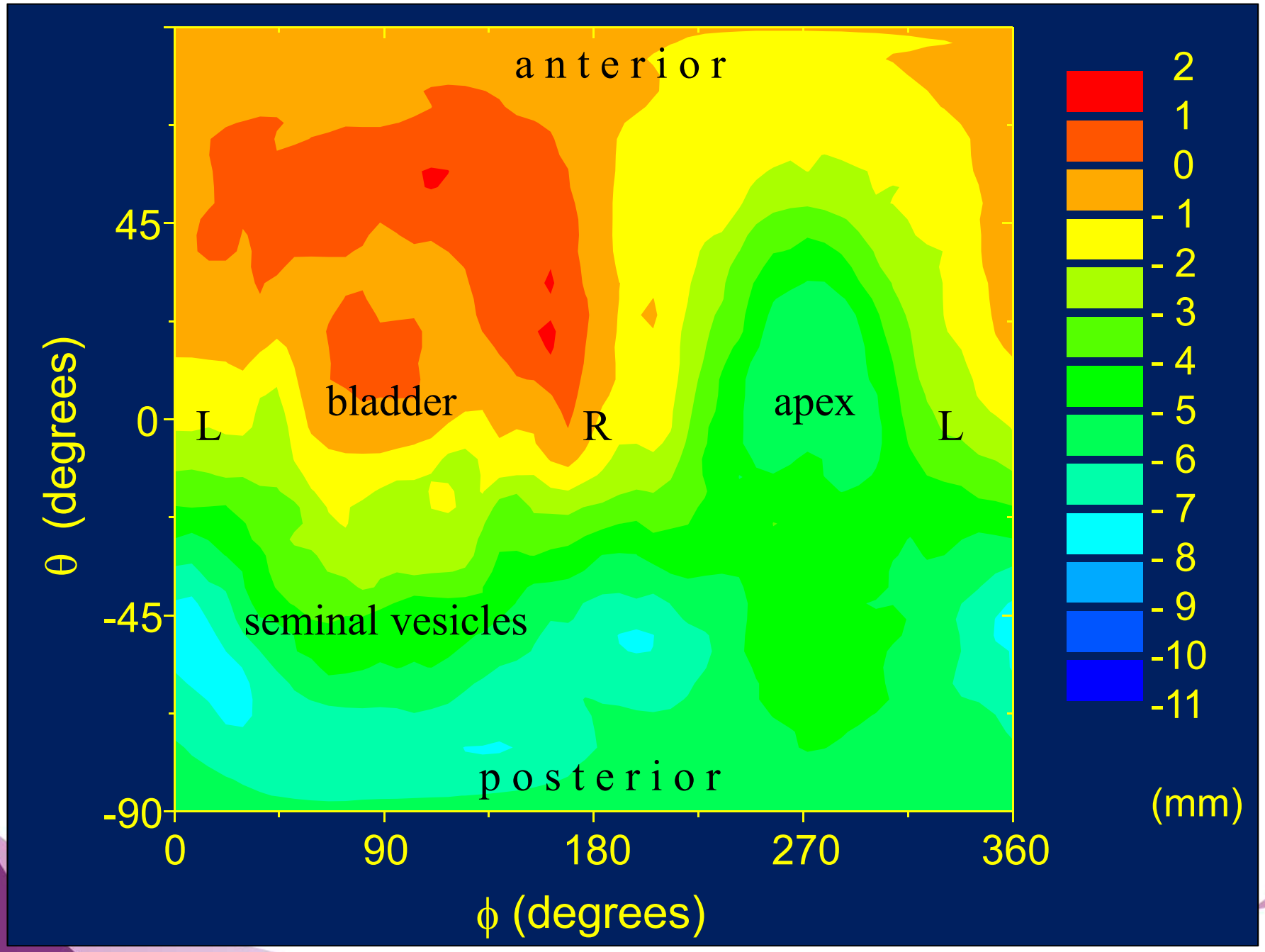

ESTRO School

Overall observer variation in CT (SD)

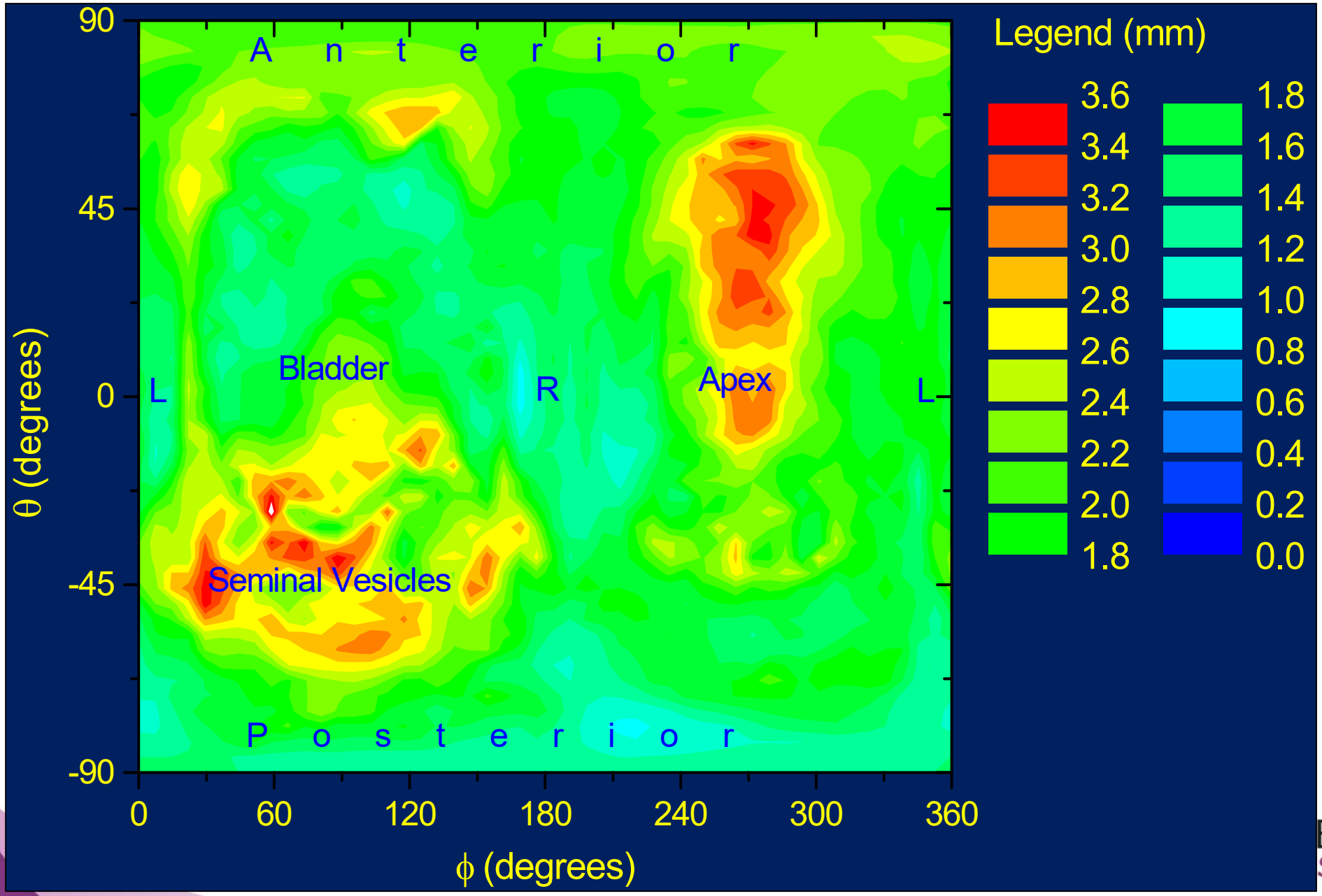

ESTRO School

What next?

- Improve delineation uncertainty by
  - Inclusion of more modalities – Quantify improvements
  - Clear protocols

- To quantify improvements → Extend model to measure more complex structures

- To determine protocols → See how the doctors are delineating

ESTRO School

What next?

- Measure complex structures

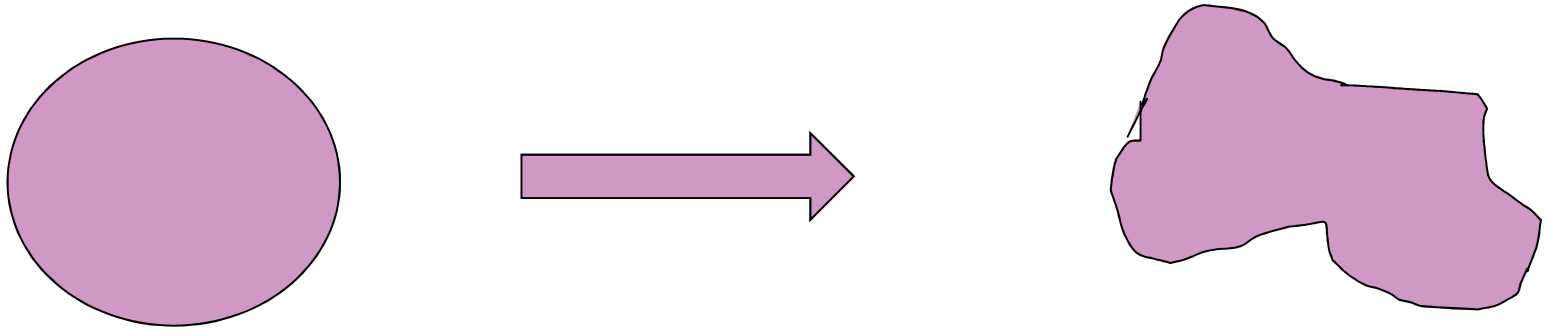

- Measure normal to the surface instead of using polar coordinates (=measurement from one central point)

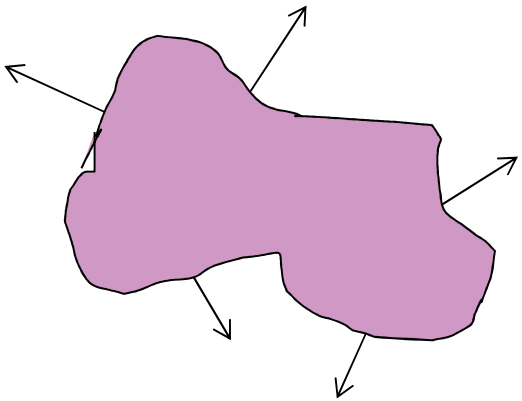

ESTRO School

Geometrical analysis in 3-D

Median Surface

Distance measured

Local SD

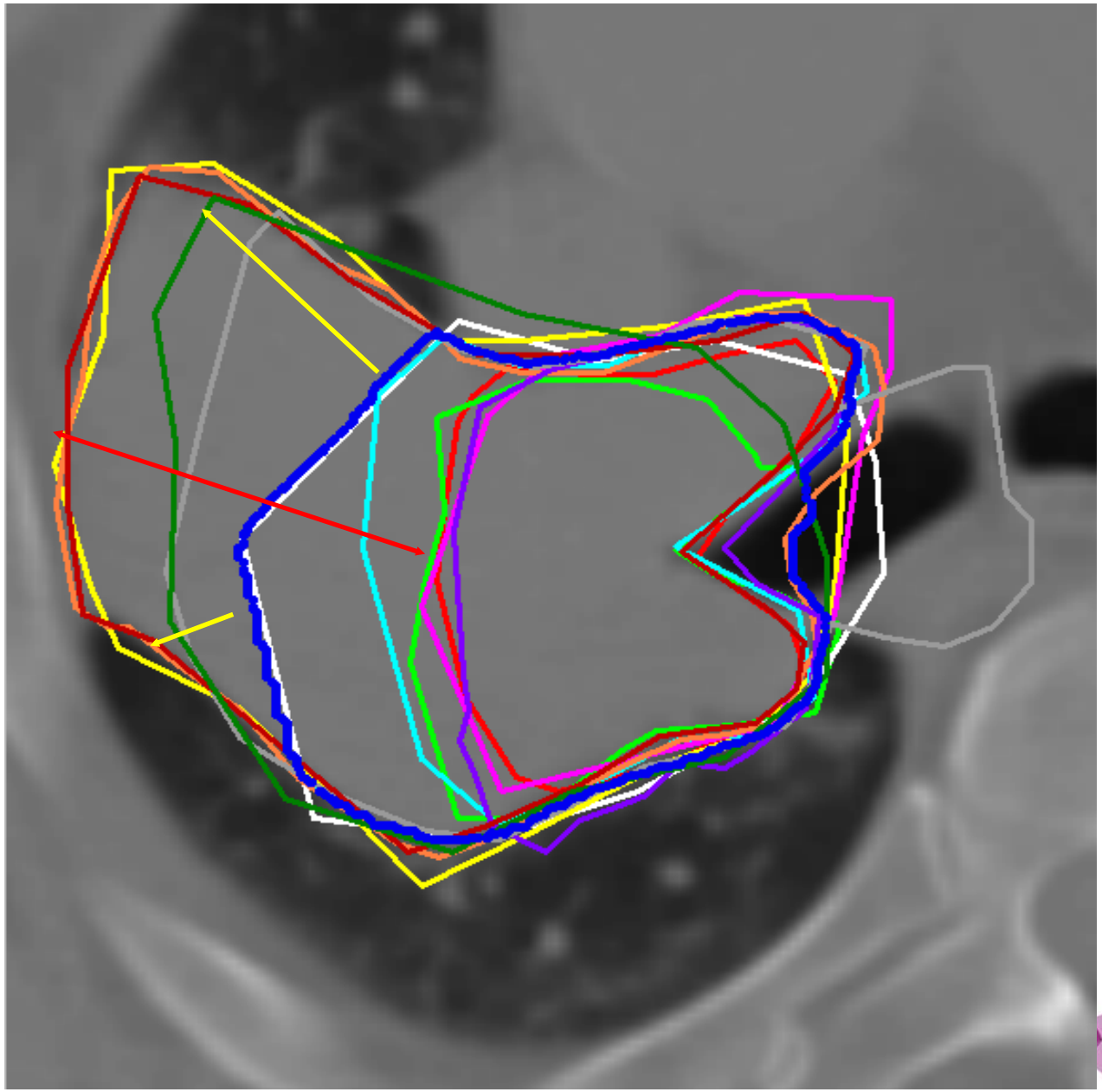

ESTRO School

Geometrical analysis in 3-D

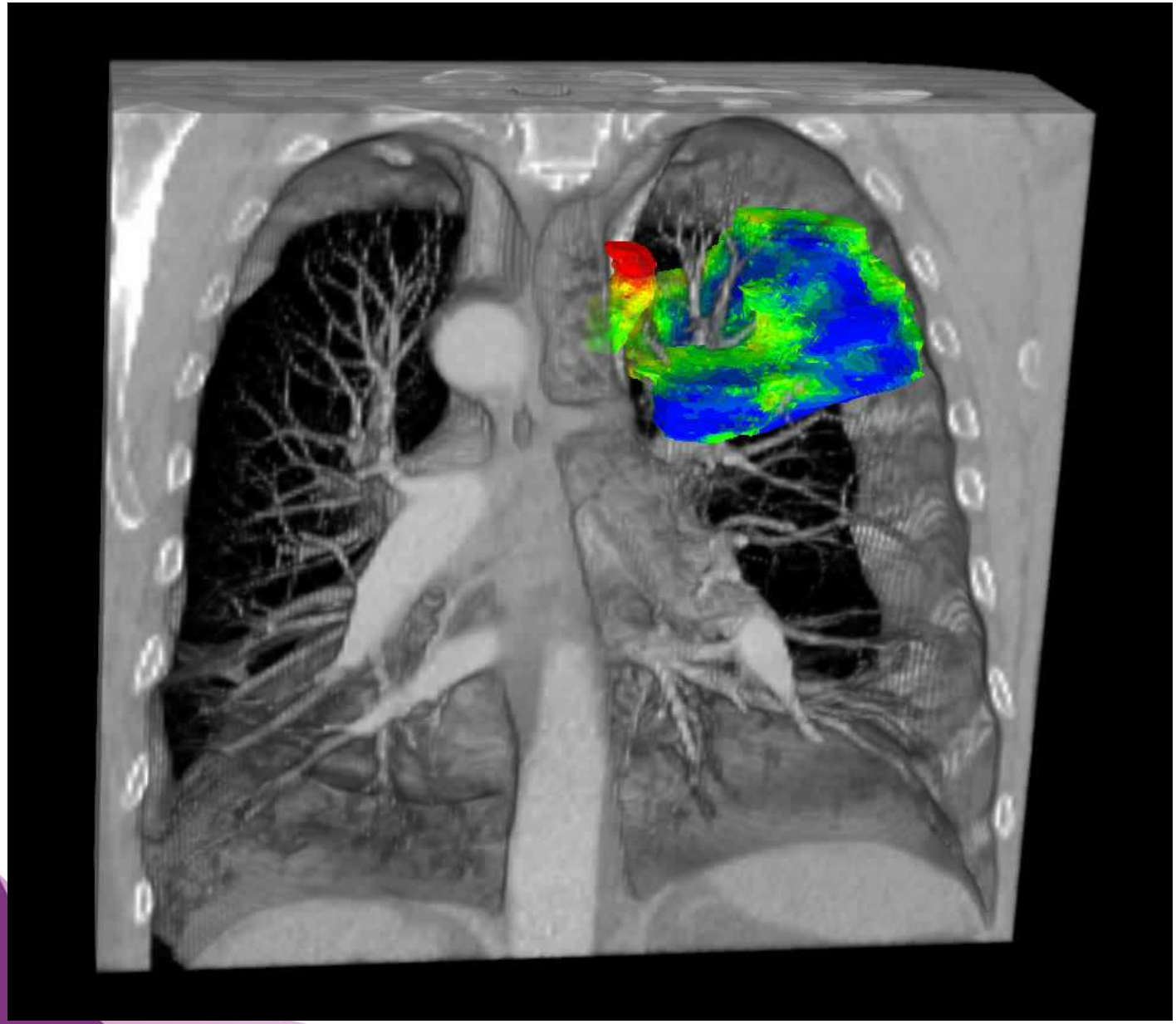

LOCAL SD (mm)

- 0 – 1
- 1 – 2
- 2 – 3
- 3 – 4
- 4 – 5
- 5 – 6
- 6 – 7
- 7 – 8
- 8 – 9
- 9 – 10
- 10 – 11
- 11 – 12
- 12 – 13
- 13 – 14
- 14 – 15
- > 15

ESTRO School

What are the doctors doing?

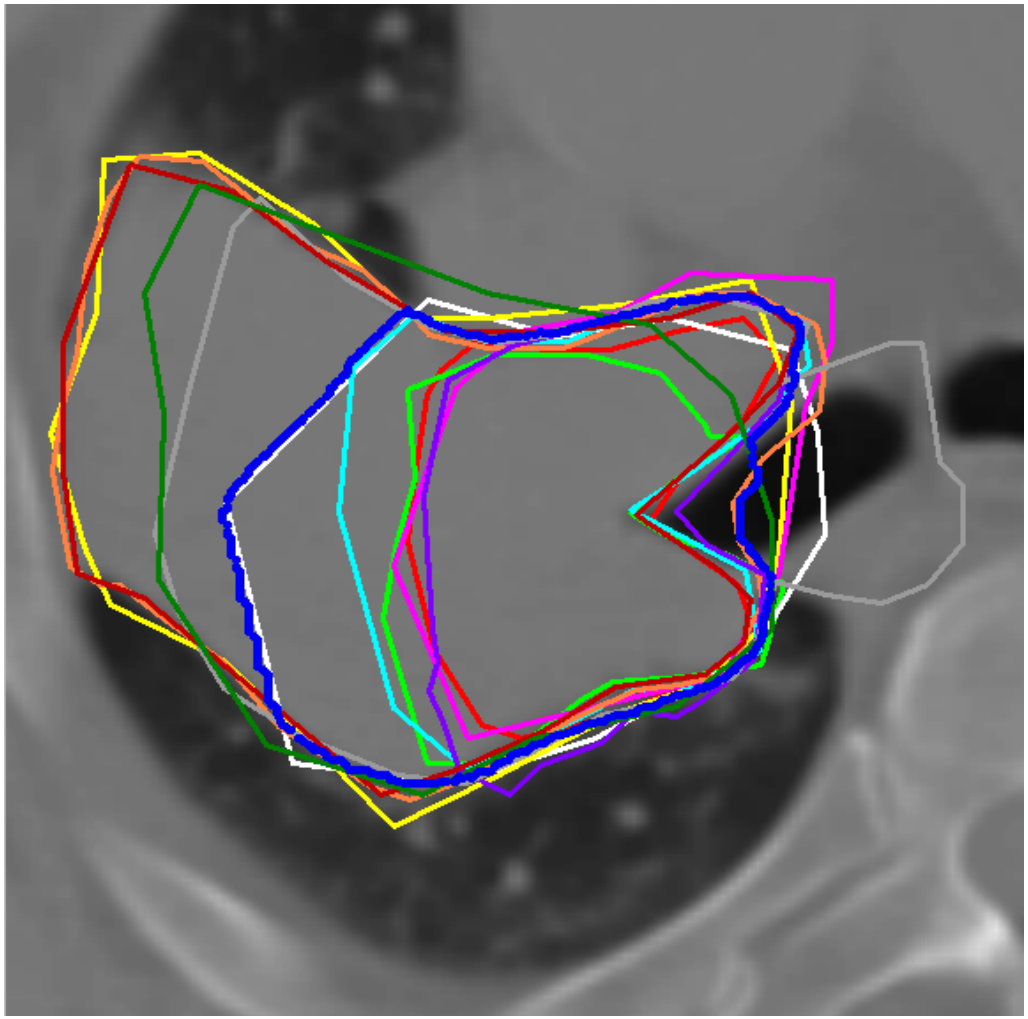

Big brother… ☺

ESTRO School

Target volume delineation

More sites were investigated

- Lung

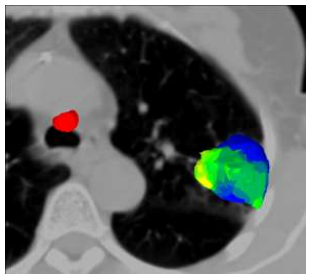

11 radiation oncologists

- H&N

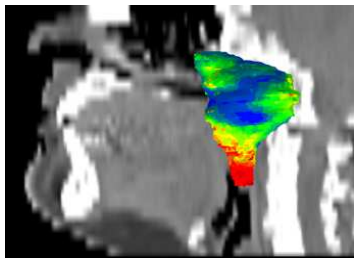

10 radiation oncologists

- Prostate

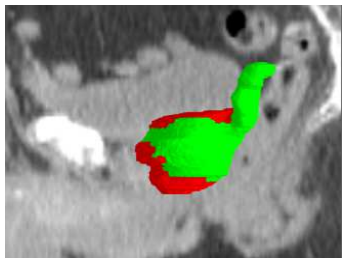

13 radiation oncologists

ESTRO School

Some examples……

Lung

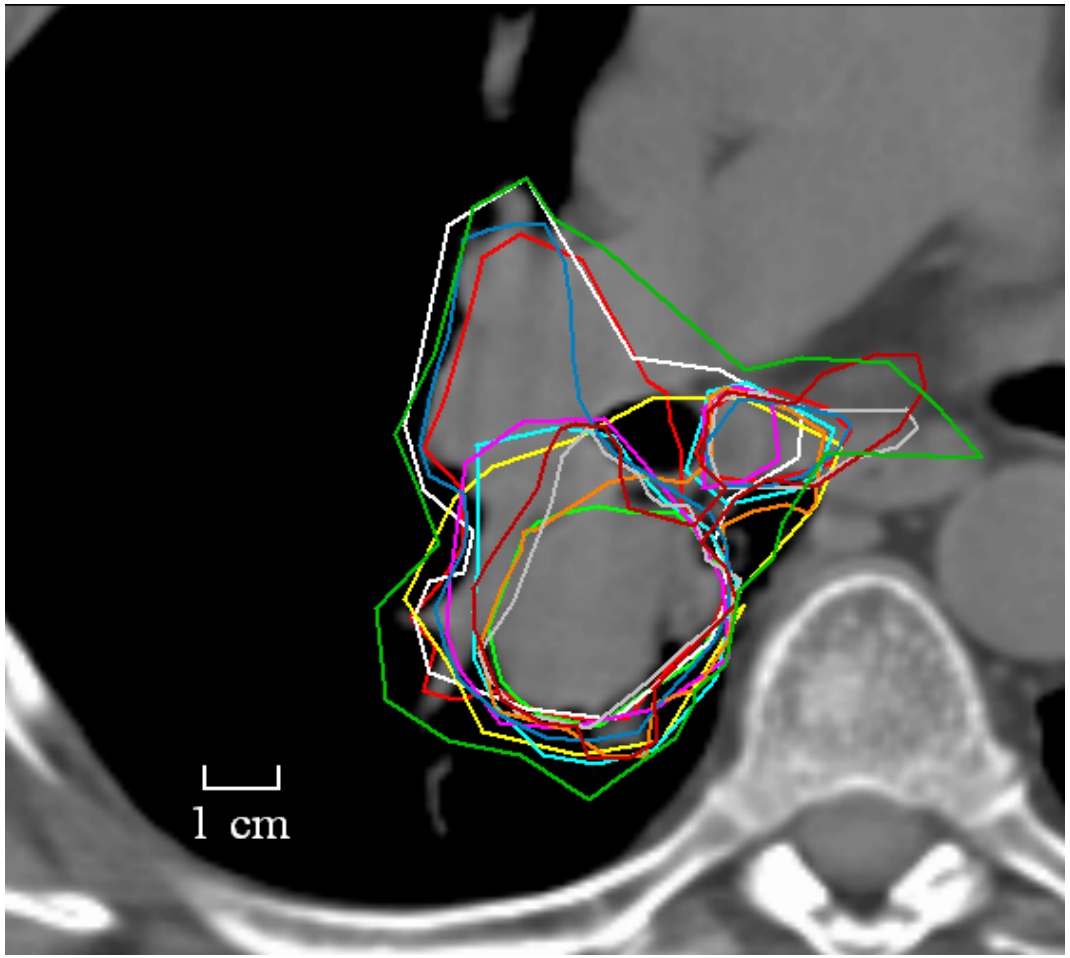

CT

SD 10.2 mm

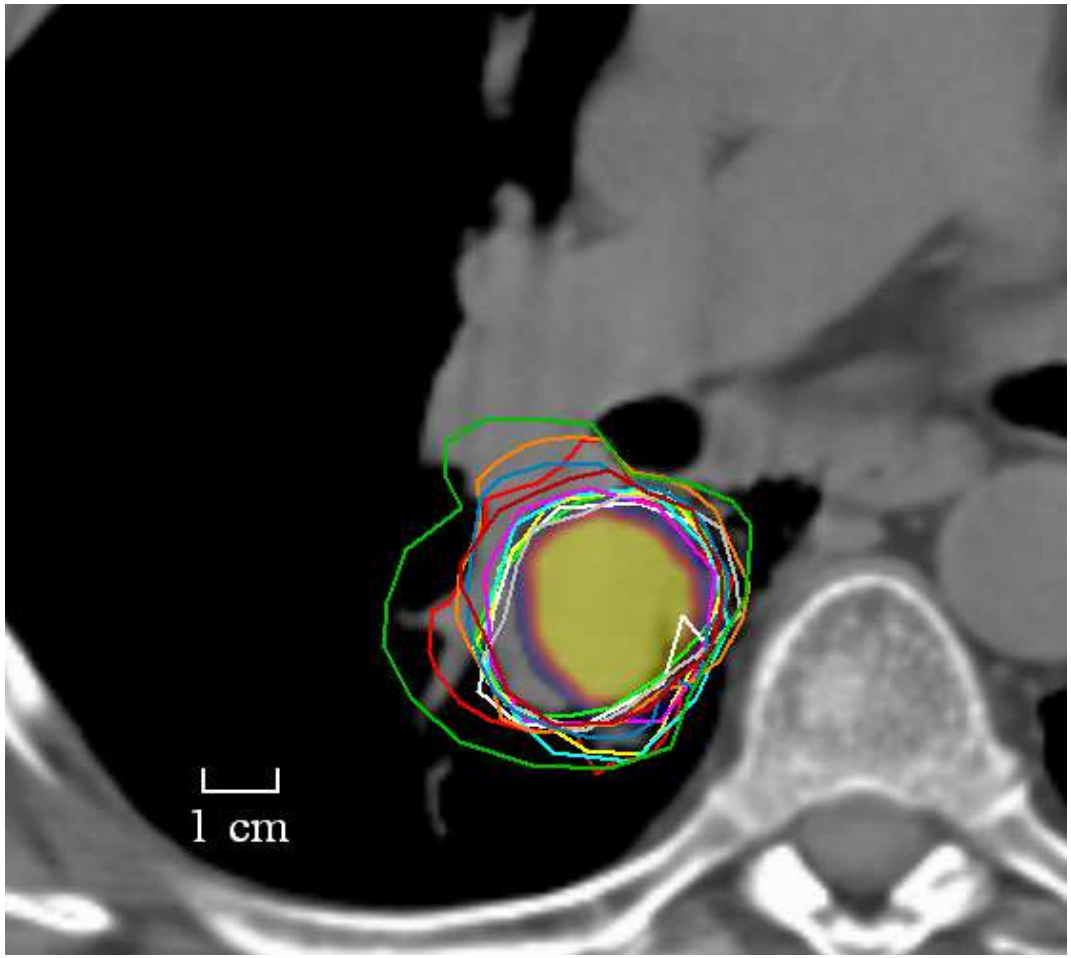

CT + PET

SD 4.2 mm

ESTRO School

Lung

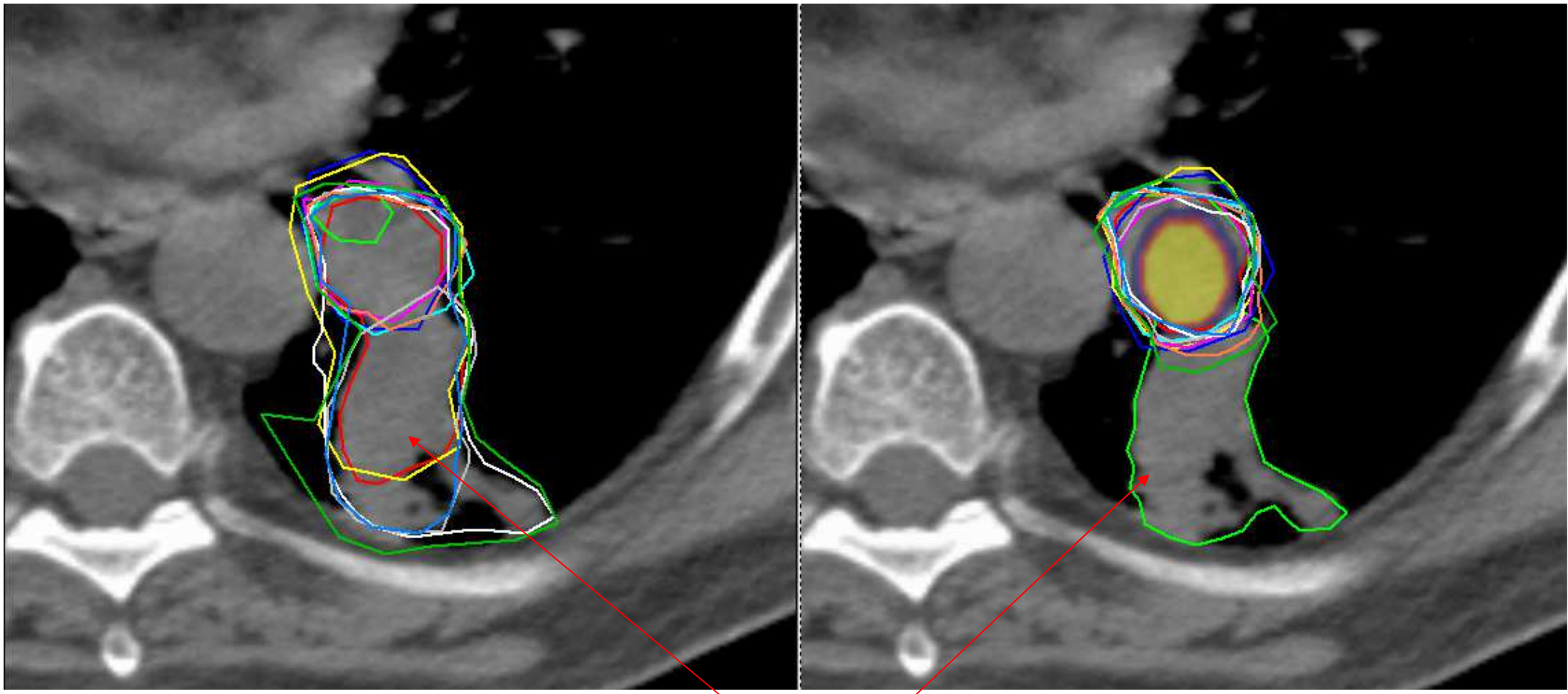

CT

SD 10.9 mm

Atelectasis?

CT+PET

SD 3.5 mm

ESTRO School

Lung

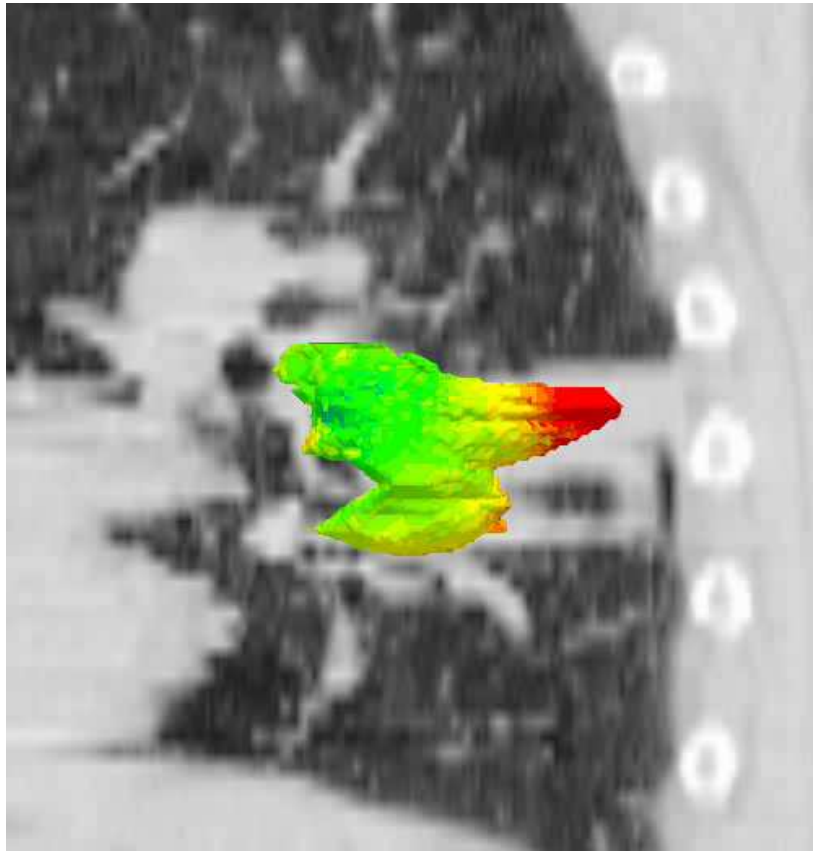

CT



CT + PET

LOCAL SD (mm)

0 – 1	4 – 5	8 – 9	12 – 13
1 – 2	5 – 6	9 – 10	13 – 14
2 – 3	6 – 7	10 – 11	14 – 15
3 – 4	7 – 8	11 – 12	> 15

“Big Brother”

- Mean del. time: CT 16 min
  CT-PET 12 min
  } $p < 0.001$ paired students T-test

- Corrections

Region	CT (corr / cm^2)	CT-PET (corr / cm^2)
Tumor – lung	4.2	3.1
Tumor – chest wall	5.0	3.8
Tumor – mediastinum	4.1	3.4
Lymph nodes	4.9	**5.4**
Tumor – atelectasis	2.4	1.9
Total	**4.0**	**3.2**
Total # corrections	**9416**	**6144**

Prostate case

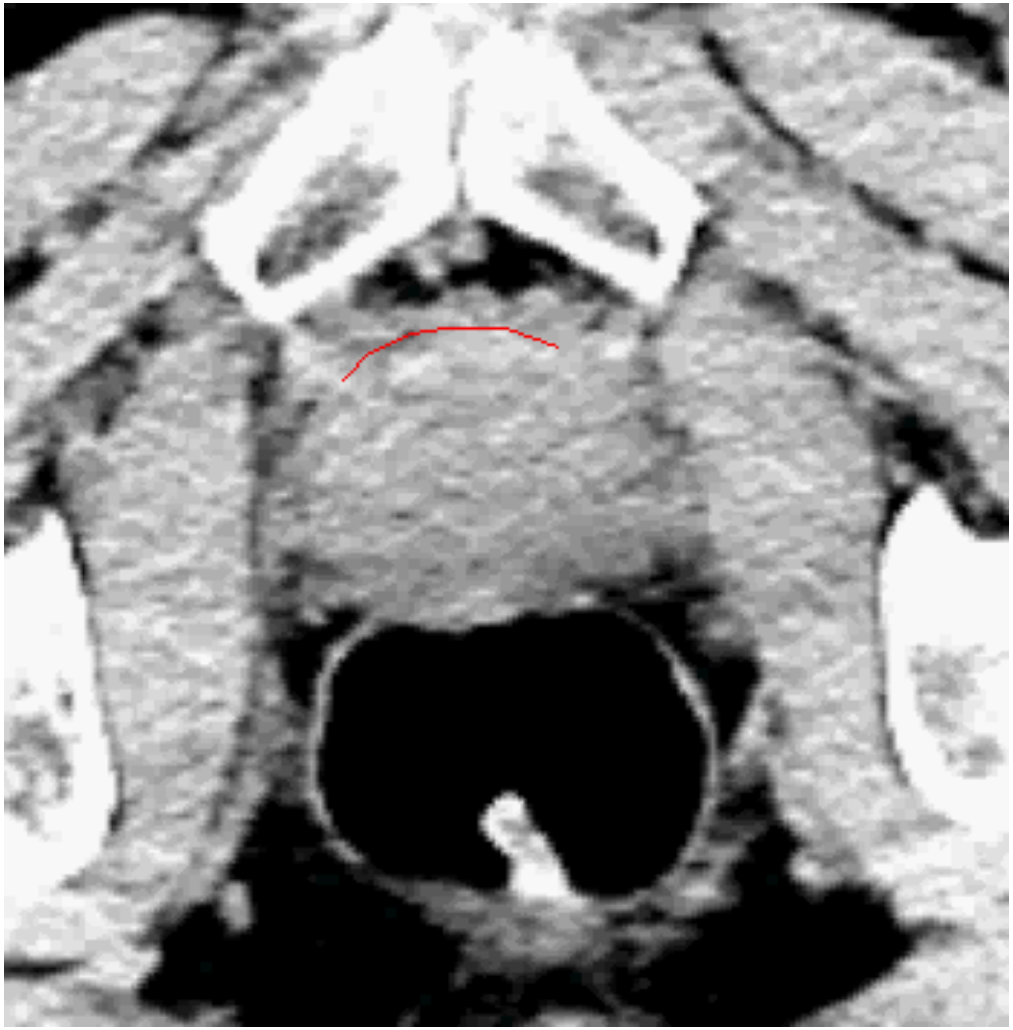

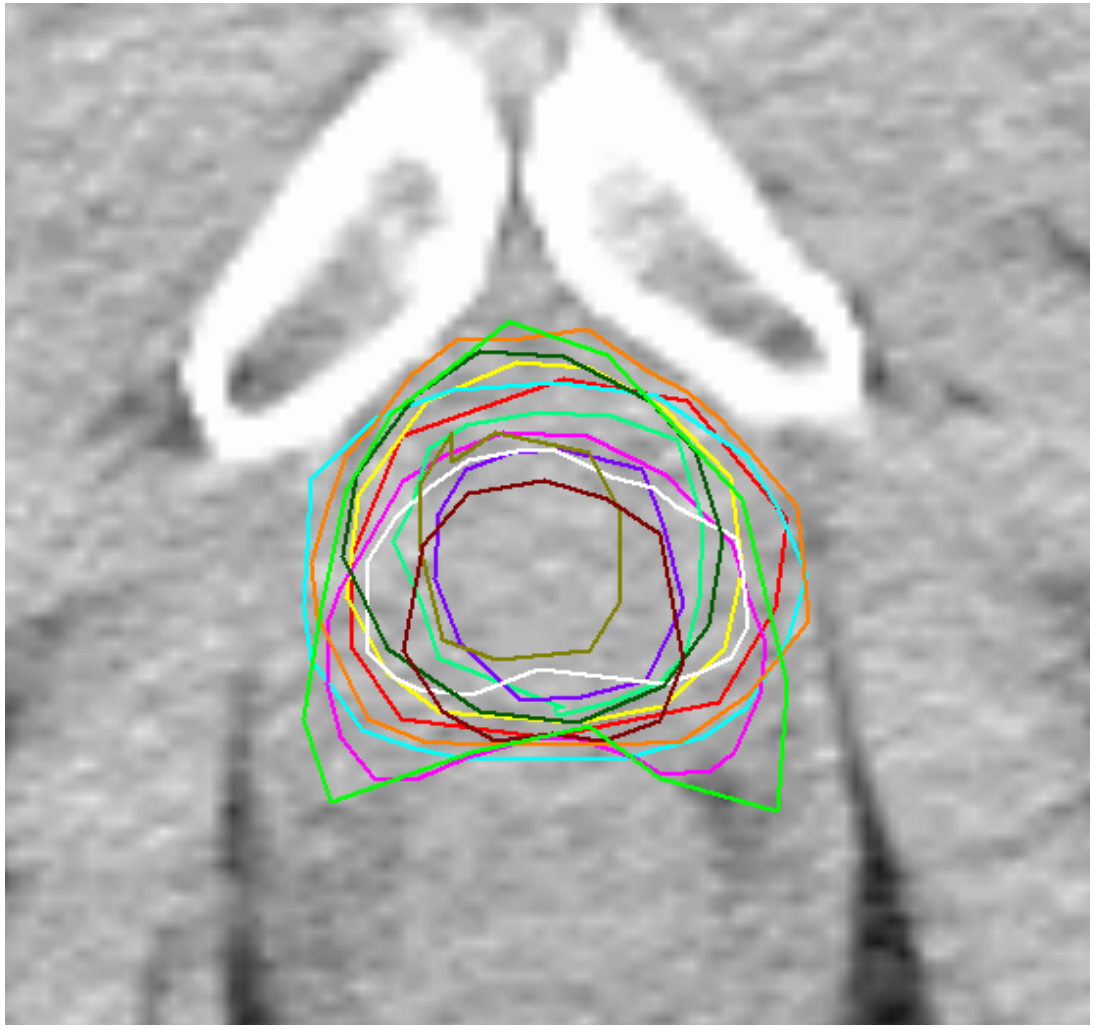

ESTRO School

3-D median surface with local SD

Median Surface

Distance measured

Local SD

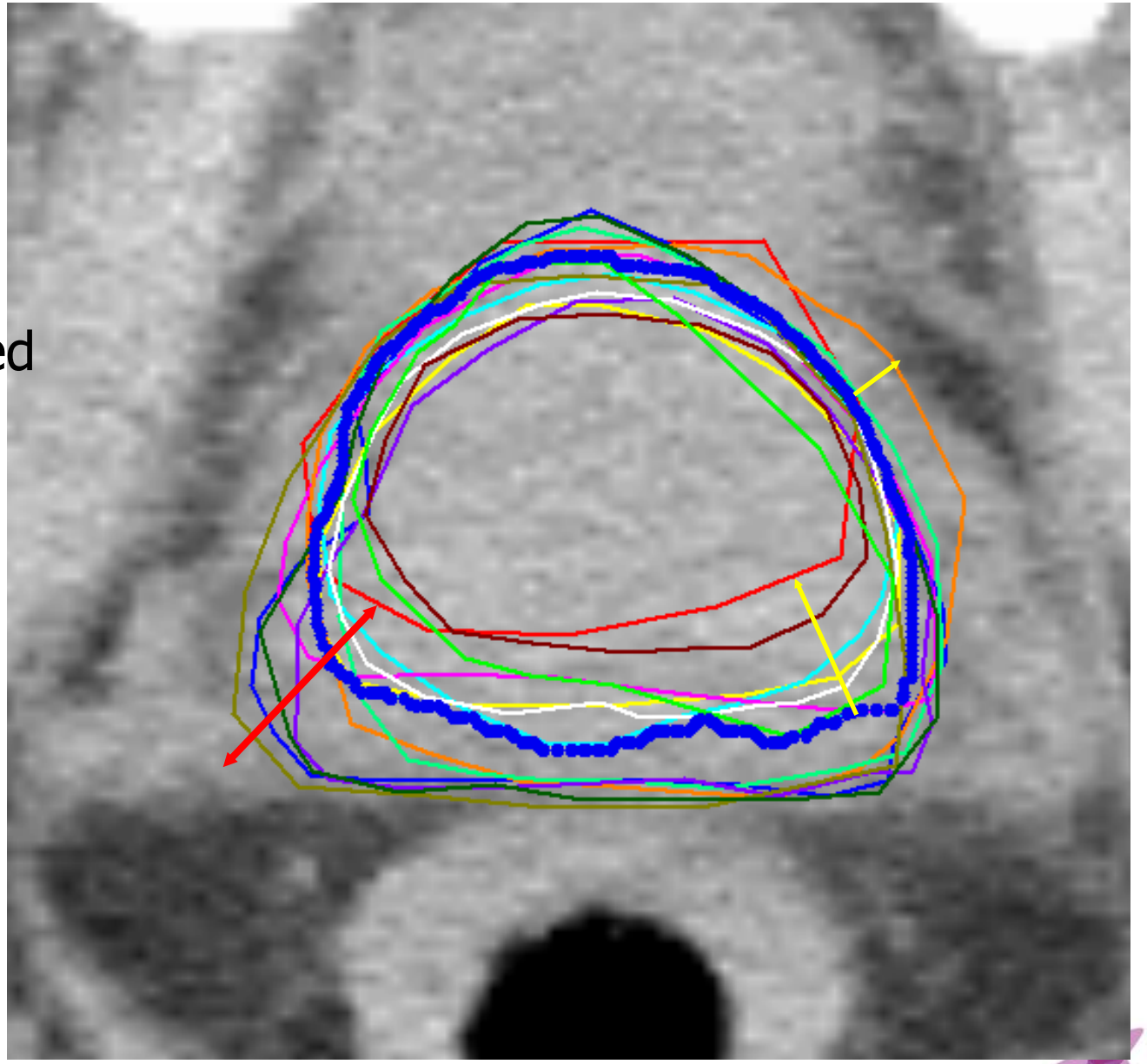

ESTRO School

3-D median surface with local SD

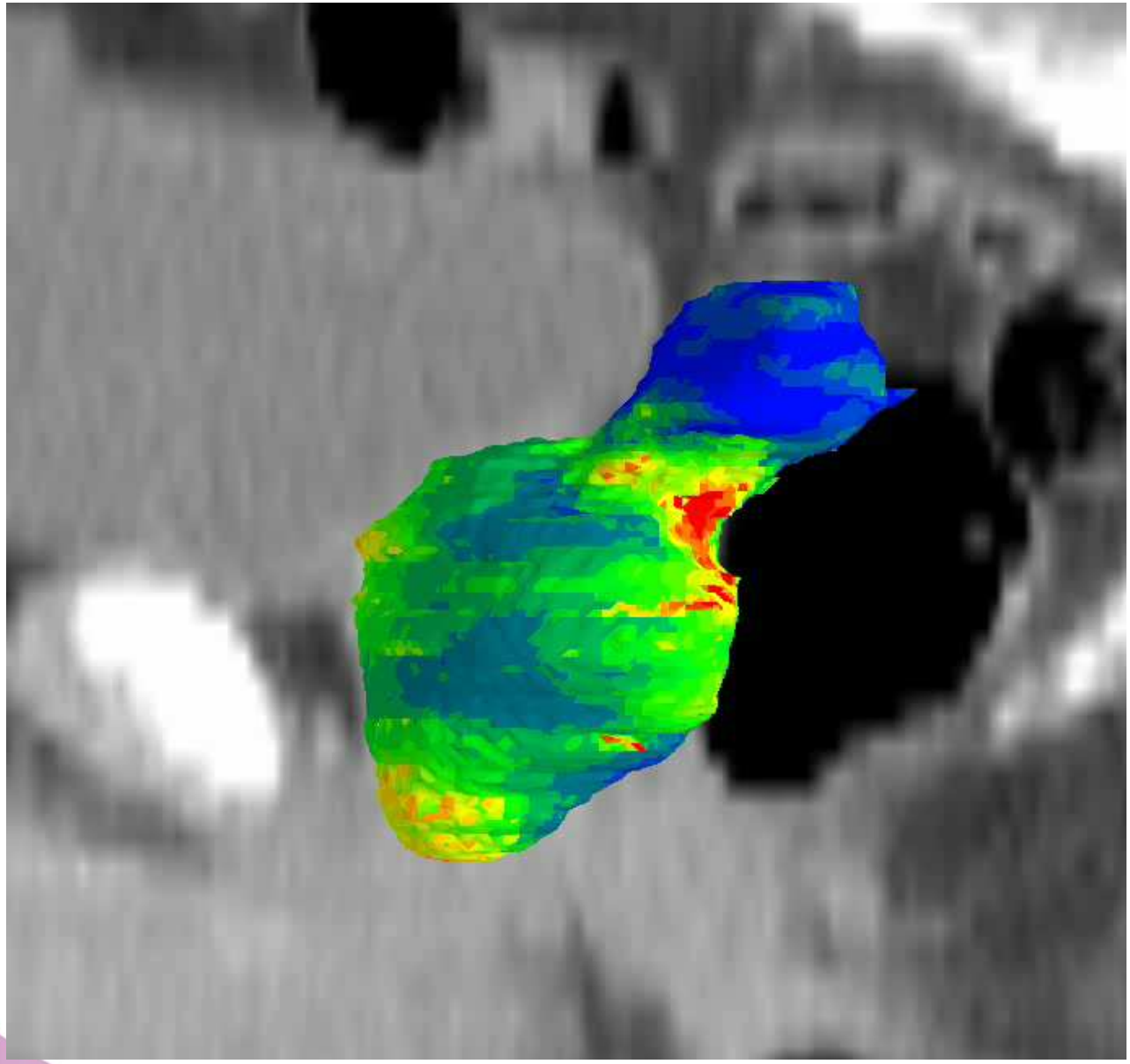



Use diffferent imaging modalities

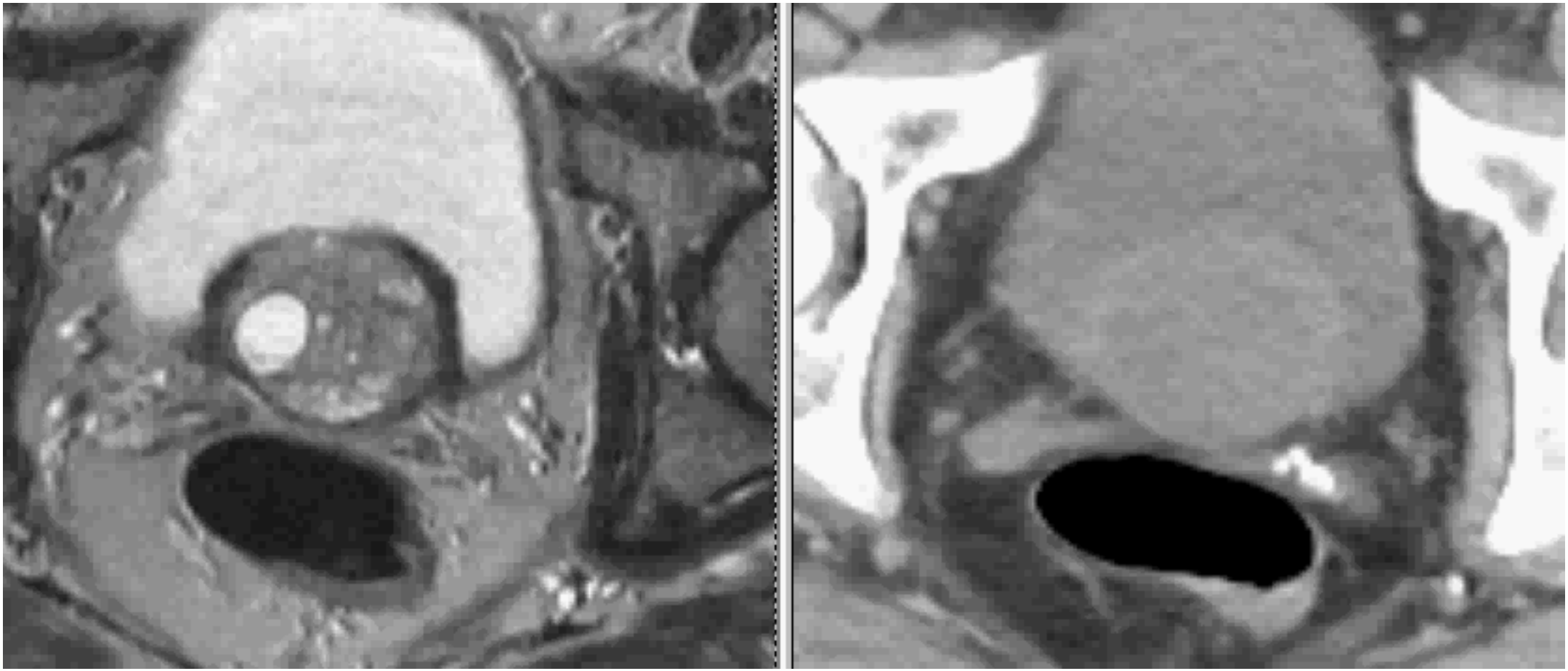

Matched MRI – CT

ESTRO School

Prostate

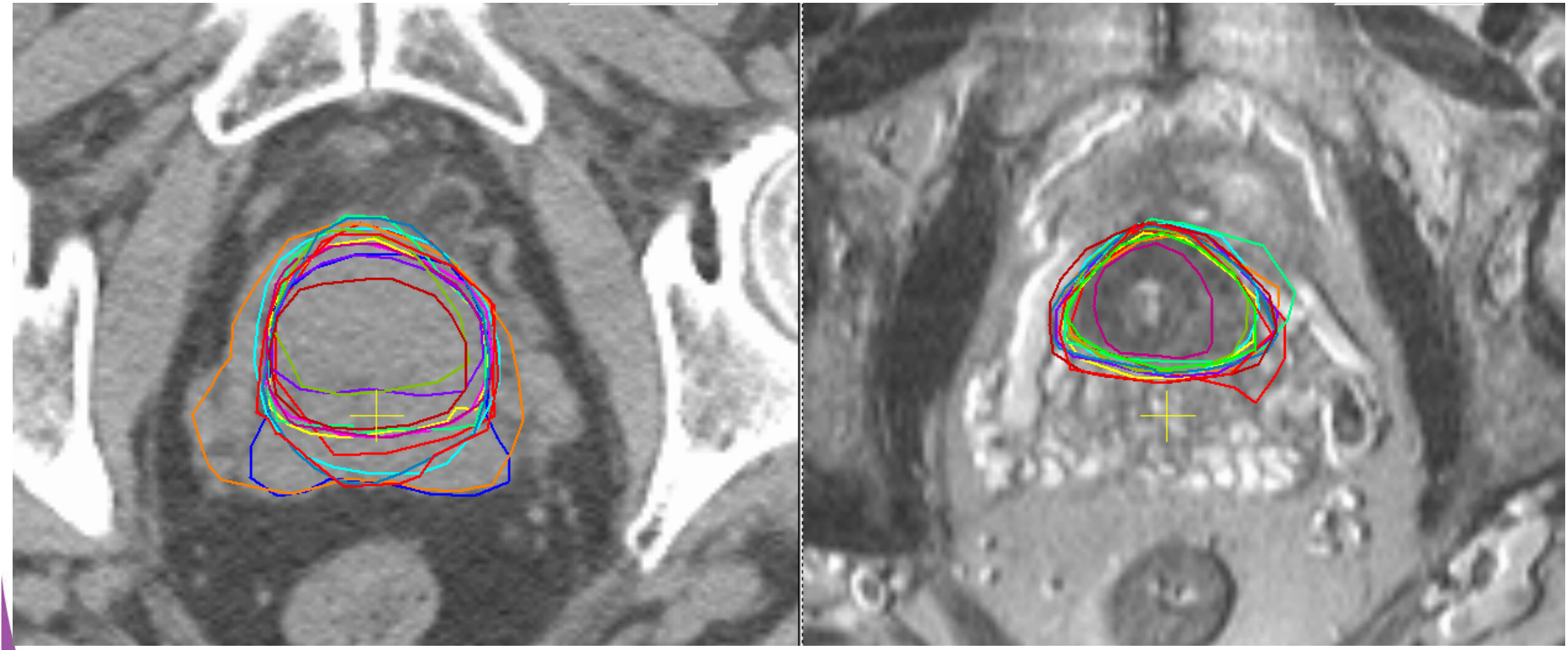

CT

SD 3.0 mm

CT + MRI

SD 2.8 mm

ESTRO School

So do we need margins for delineation uncertainties?

- Yes and no
- If it is genuine uncertainty → Yes
- If it is a protocol related difference → No

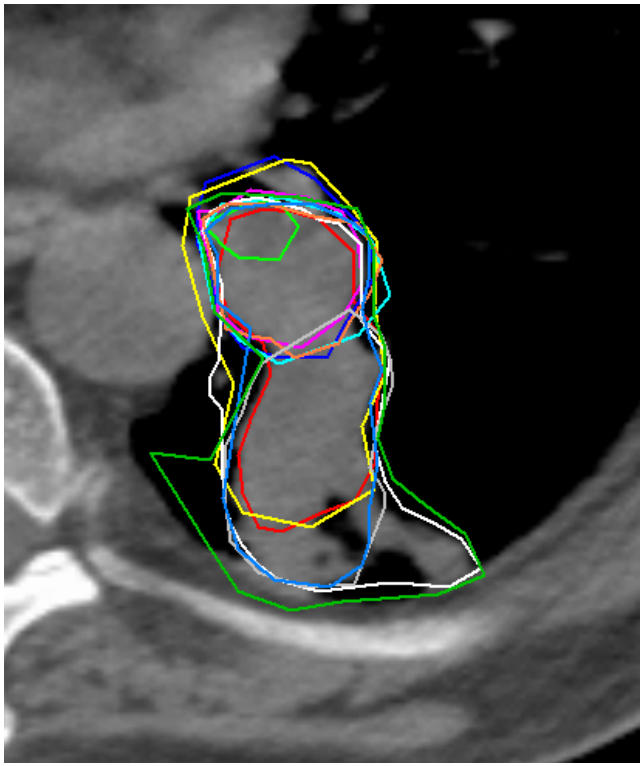

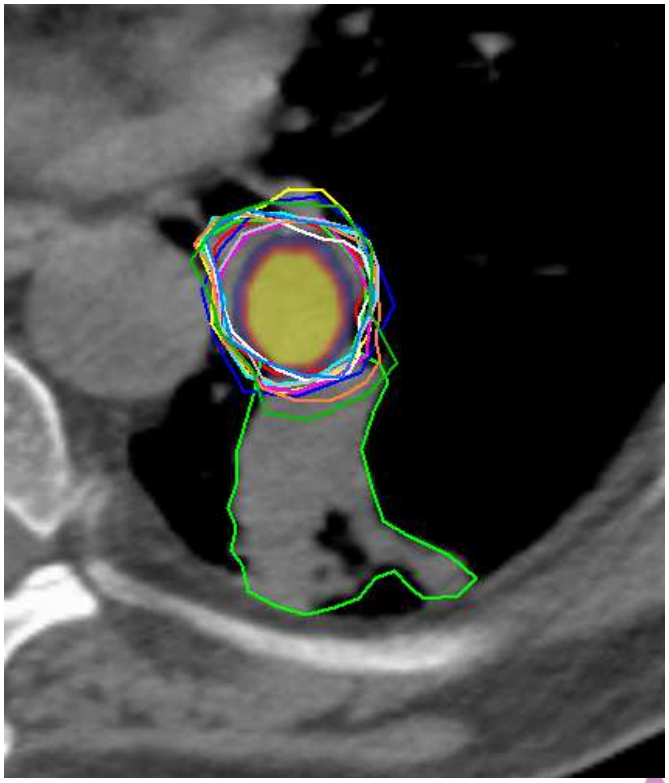

Margins for delineation uncertainties

- But: The standard recipe may not apply….
- Assumes translations only and rigid structures
- Delineations are often biased towards larger volumes
  - Areas with poor tumor definition are included to ensure coverage of the target
  - The better the imaging, the smaller this bias will be
- What is the golden standard?

Conclusions

- Many factors influence the delineation accuracy
- To quantify, a full 3-D analysis (in cms) is needed
- Benefits of different modalities, protocols can then be validated
- Because it's a systematic deviation, the effect on the treatment is large
- However, incorporation into a margin is not always trivial

ESTRO School

ESTRO School

WWW.ESTRO.ORG/SCHOOL

GTV, CTV and PTV
(ICRU 62 + 83 and beyond)

,

Sarah Jefferies PhD

Department of Oncology,

Oncology Centre, Addenbrooke's Hospital, Cambridge, UK

Learning Objectives

- To understand the concept of different planning volumes
- To understand definitions of
  - GTV, CTV, PTV
- To understand the relevance of Organs At Risk (OAR) and planning organs at risk volume (PRV)
- To understand how to manage overlapping volumes
- To understand prescribing

TomoTherapy
HI·ART

The history of radiotherapy

- 1895 - Röntgen discovered X-rays
- 1896 - first treatment of cancer with X-rays
- ***120 years later the technology has changed!***

- ICRU reports are here to ***help*** us
- Series began with Report 50 and Supplement 62 (1993 + 1999)
- ICRU 71 (2004) added a few details
- ICRU 83 (2010) is designed for IMRT

Target volumes

We need to consider, and define, how we describe target volumes

This is a prerequisite for integrating any diagnostic imaging

Think of an onion …

Target volumes



Target volumes are like the concentric rings of an onion

Target volumes

ICRU 50 target volumes

The PTV can be eccentric

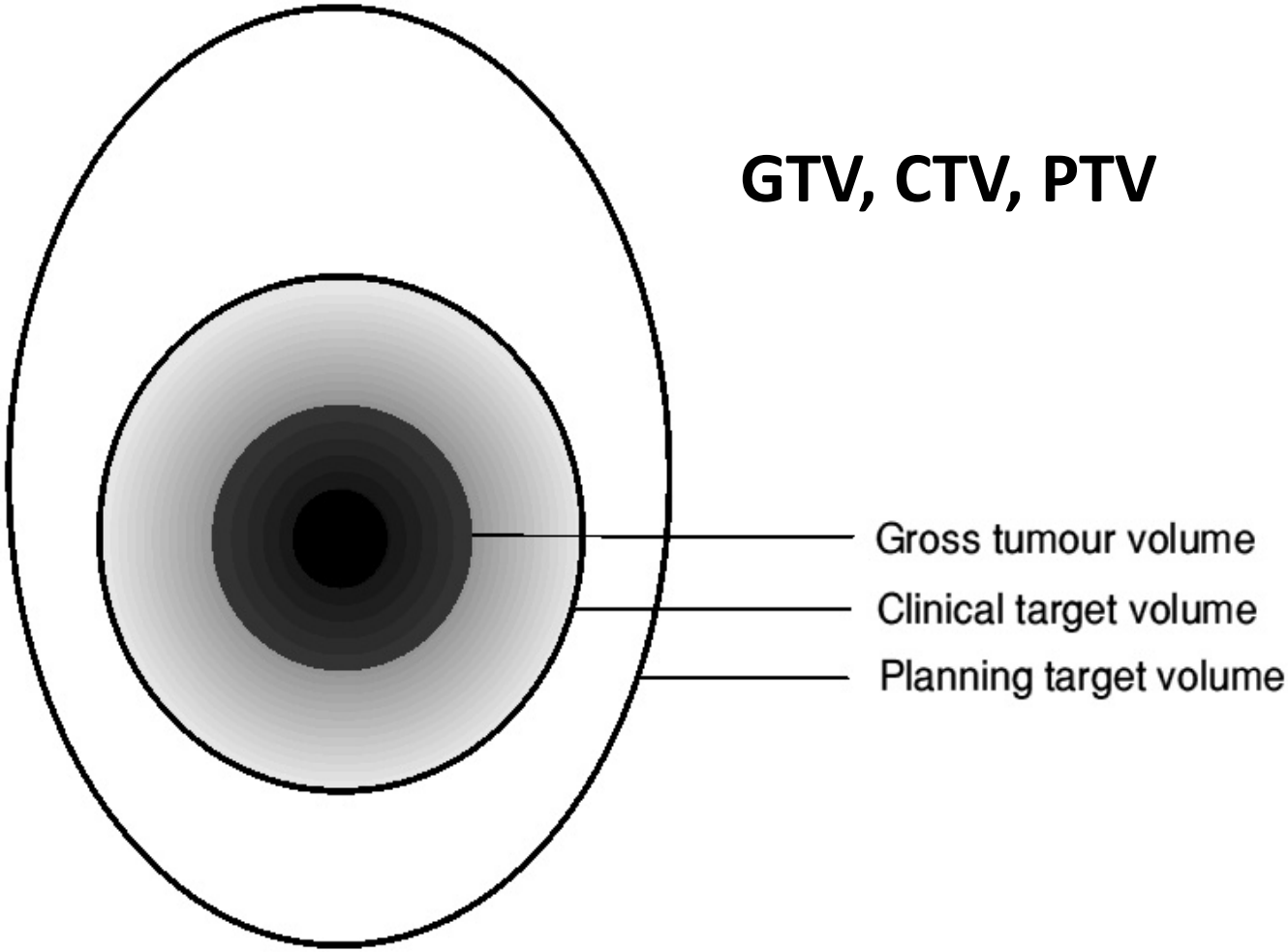

GTV, CTV, PTV

Target volumes

- ICRU report 50 and supplement 62 (1993 + 1999) specified definitions of different target volumes

- ICRU 62 was an update triggered by:
  i) increasing availability of conformal therapy where margins are more critical
  ii) need to describe normal tissues better

- ICRU 62 introduced the Planning organ at Risk Volume (PRV)

- ICRU 83 (2010) developed concepts for IMRT

Target volumes - GTV

- GTV - Gross Tumour Volume is the gross demonstrable extent and location of the tumour

- So, GTV is tumour you can:
  - **See, Feel, Image**

- Use different imaging modalities for different situations

- GTV can include lymph nodes or soft tissue spread as well as the primary tumour itself

- GTV - completely obvious in this case
- (though not an easy clinical problem)

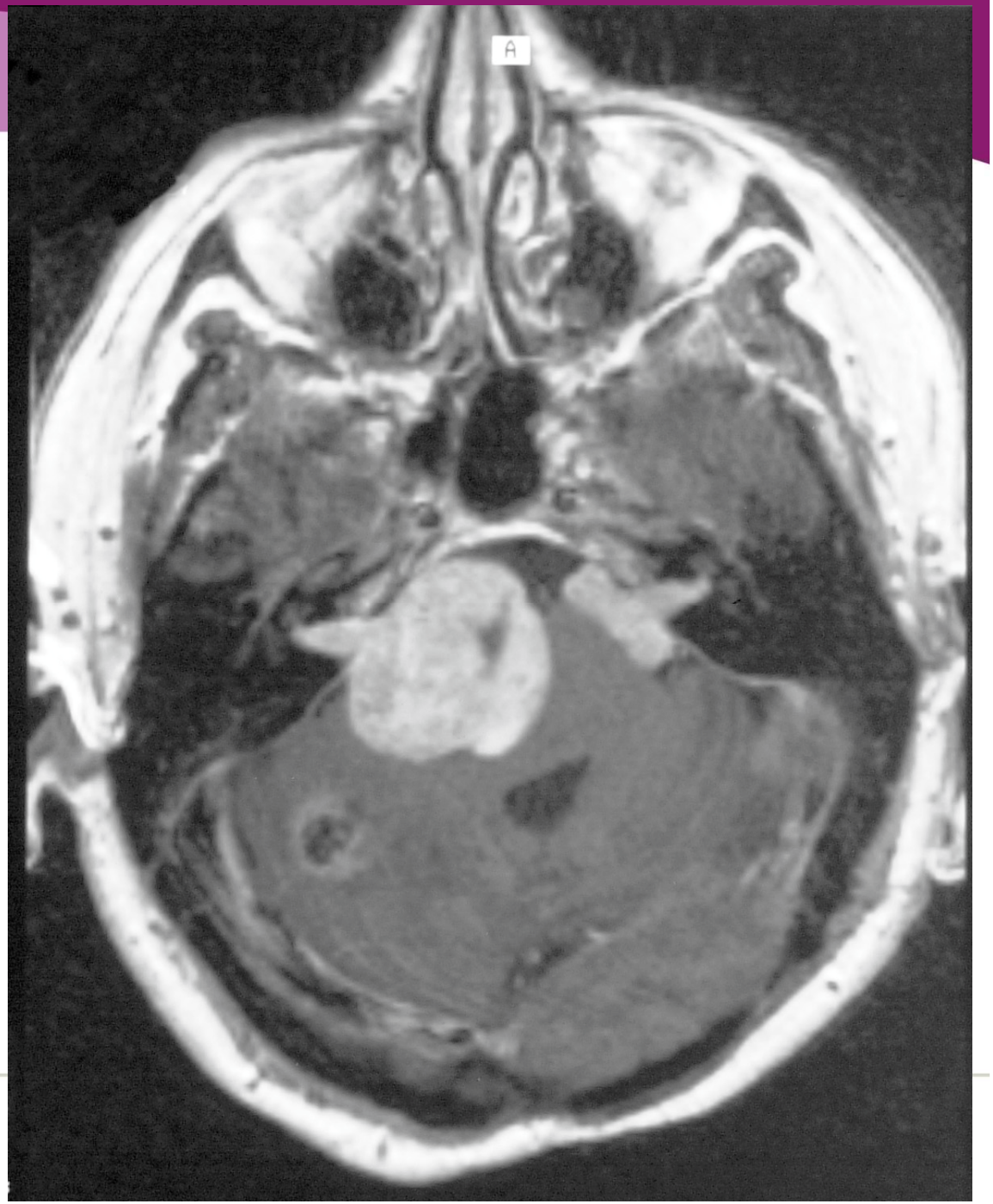

- GTV - reasonably obvious in this case
- (MRI would be better)

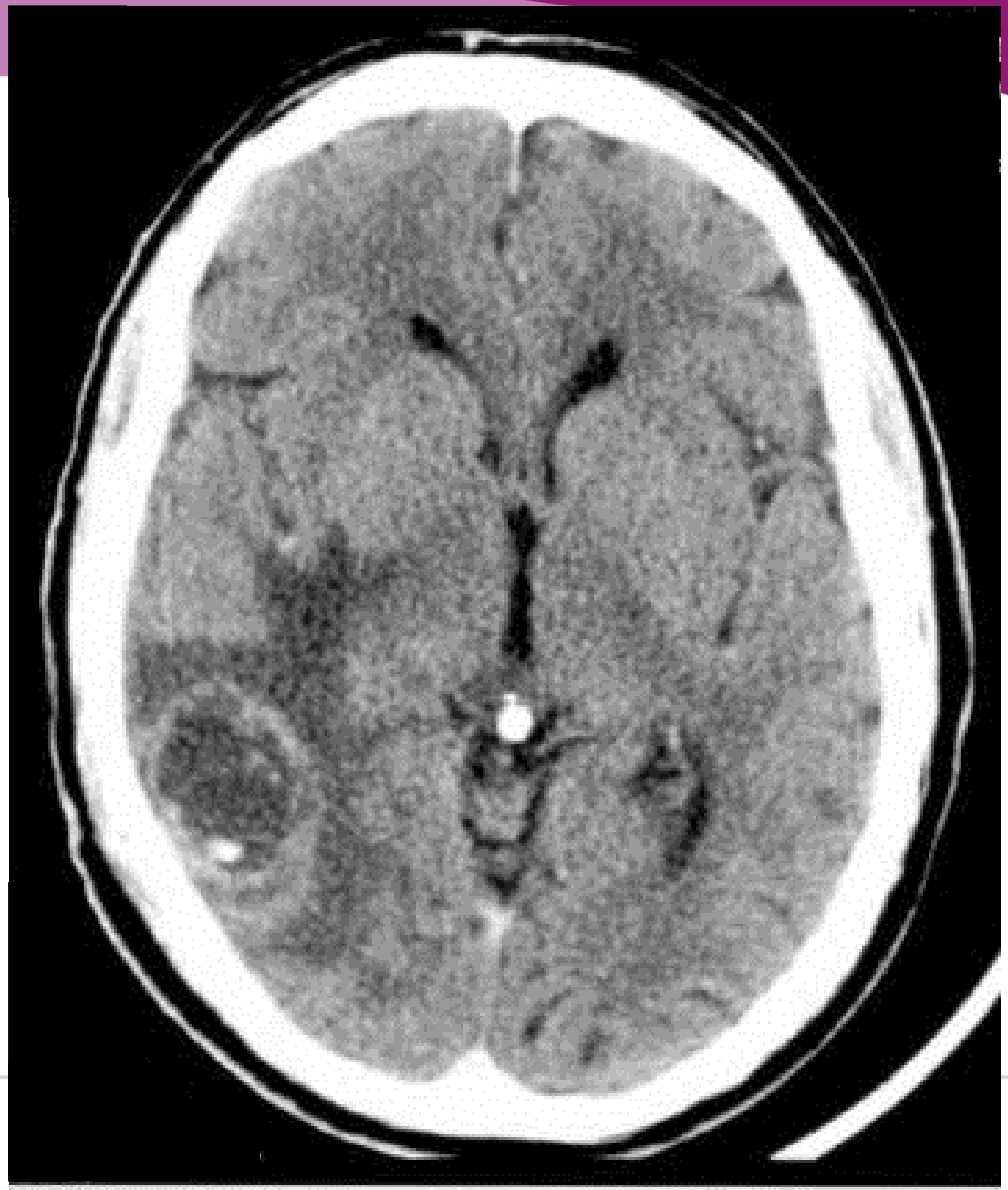

- GTV is hard to see on both CT and MRI
- The two modalities show different parts of the tumour

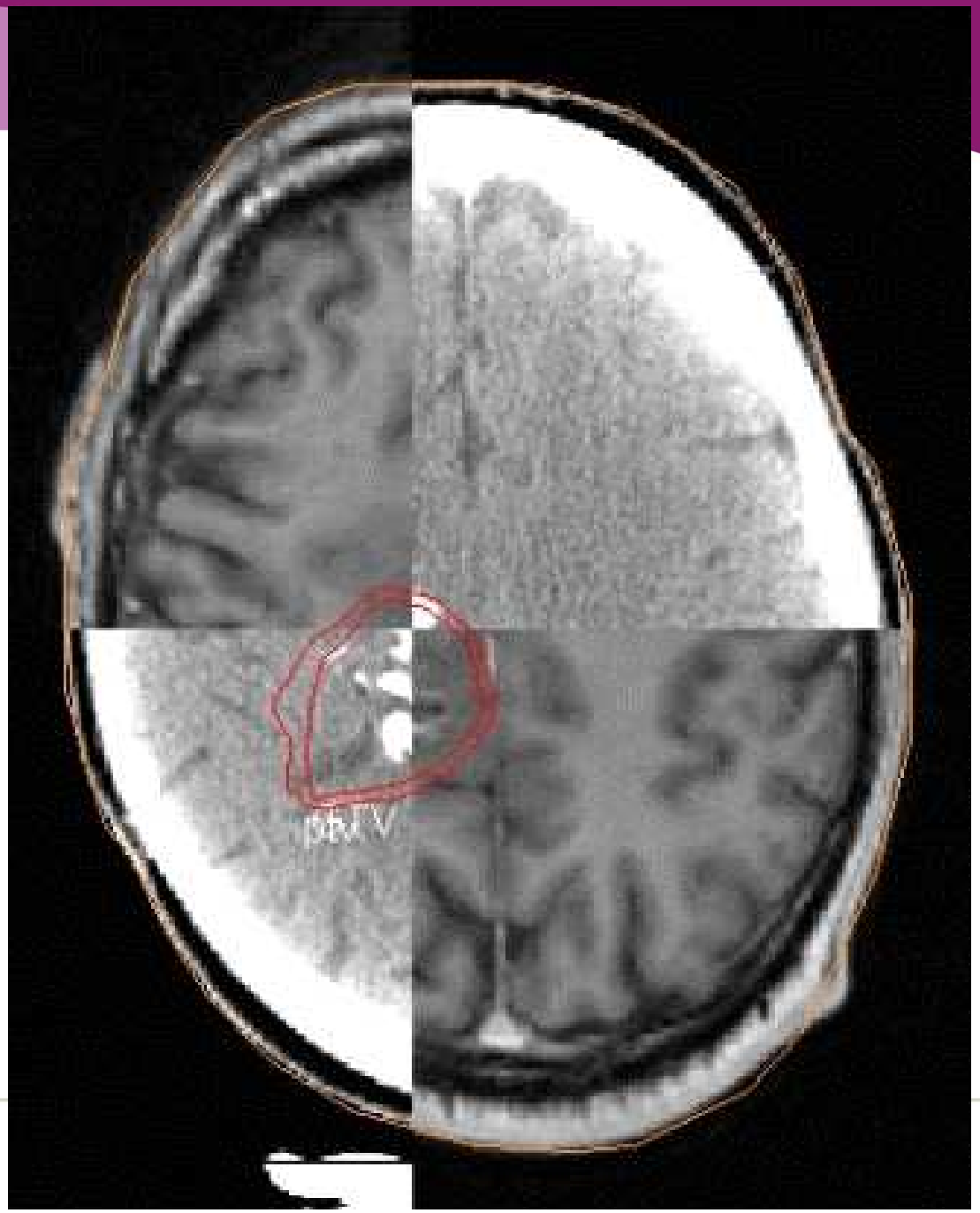

Target volumes - GTV

- Imaging does ***not*** always correlate perfectly with
  - Other imaging
  - Pathology

- Specimen to imaging: 10% mismatch

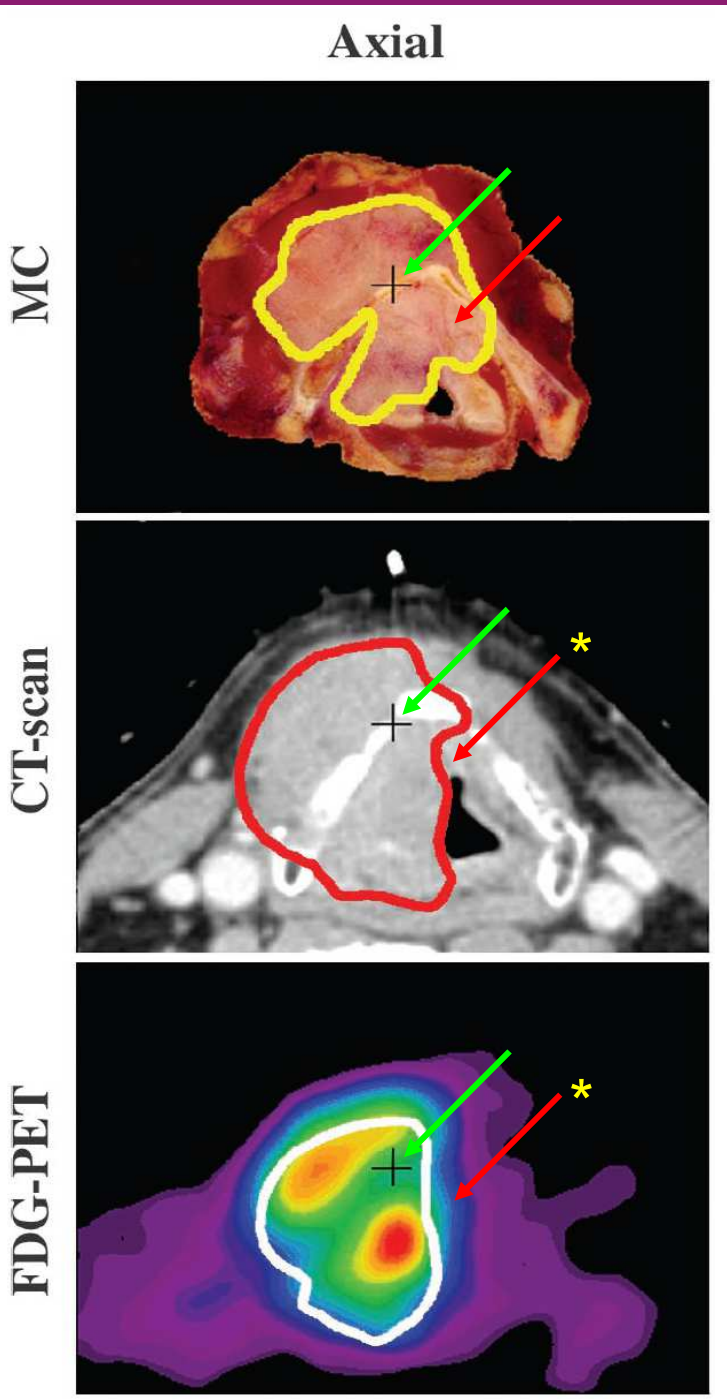

Daisne JF et al Radiology 2004; 233(1):93-100

Target volumes - GTV

- ICRU 83 suggests specifying the modality used for GTV
- Primary rectal tumour (prone)
  - 1. GTV-T (CT)
  - 2. GTV-T (MRI T1 fat sat)
  - 3. GTV-T (FDG-PET)
  - 4. GTV-T (F-miso-PET)

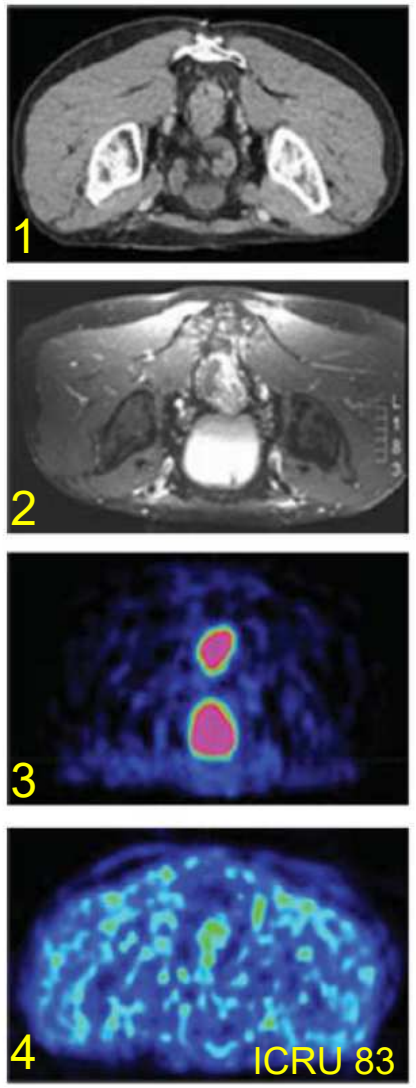

Target volumes - GTV

- Talk to your radiologists!
- They know ***lots*** about
  - Choosing the best imaging
  - The correct imaging sequences
  - Interpreting the imaging

Improving concordance

Rasch *et al. Radiation Oncology* 2010, **5**:21
http://www.ro-journal.com/content/5/1/21

RESEARCH Open Access

Decreased 3D observer variation with matched CT-MRI, for target delineation in Nasopharynx cancer

Coen RN Rasch[1*], Roel JHM Steenbakkers[2], Isabelle Fitton[3], Joop C Duppen[1], Peter JCM Nowak[4], Frank A Pameijer[5], Avraham Eisbruch[6], Johannes HAM Kaanders[7], Frank Paulsen[8], Marcel van Herk[1]

ESTRO School

Improving concordance

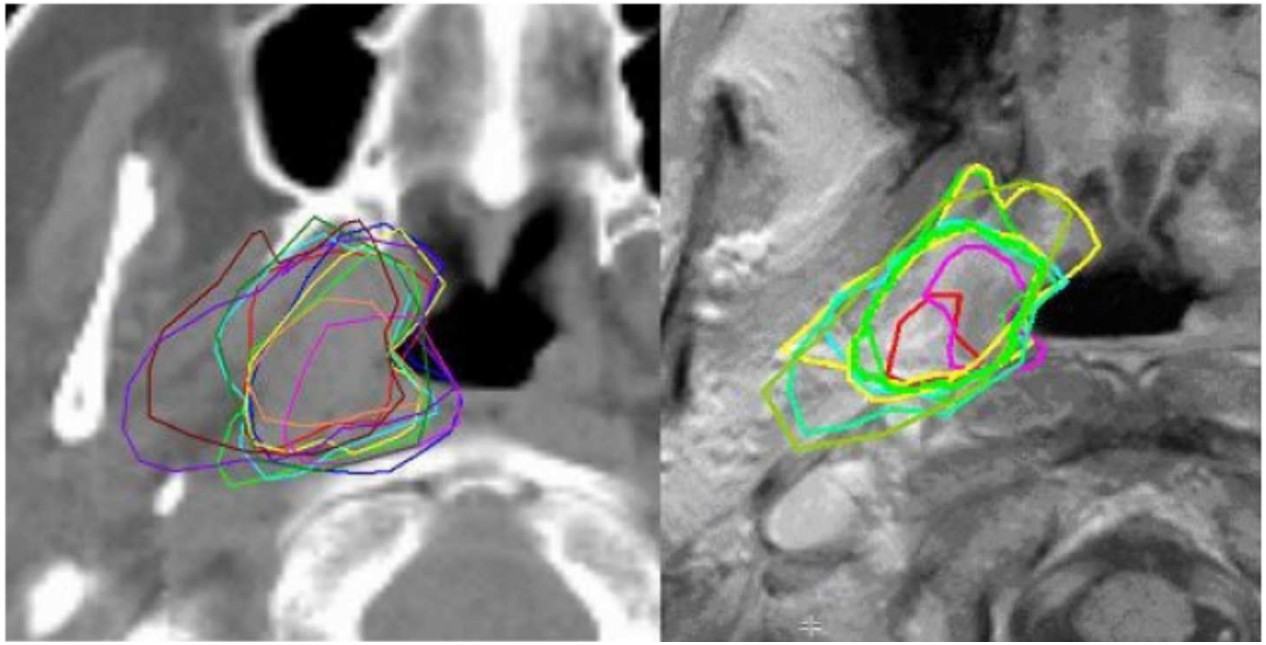

Better imaging improves consistency

Improving concordance

- The largest impact was by improved target volume definitions = **protocol**

- Biggest differences seen at the top and bottom

  A problem of imaging

- Better concordance using sagittal image display

Quality of RT affects outcome

VOLUME 28 · NUMBER 18 · JUNE 20 2010

JOURNAL OF CLINICAL ONCOLOGY

ORIGINAL REPORT

(2010; 28(18): 2996-3001)

Critical Impact of Radiotherapy Protocol Compliance and Quality in the Treatment of Advanced Head and Neck Cancer: Results From TROG 02.02

Lester J. Peters, Brian O'Sullivan, Jordi Giralt, Thomas J. Fitzgerald, Andy Trotti, Jacques Bernier, Jean Bourhis, Kally Yuen, Richard Fisher, and Danny Rischin

Very scary results

Poor radiotherapy

↓ 20% in OS

↓ 24% in DFS



In 3% contouring responsible for poor outcome

ESTRO School

Parotid and Neck Outlining

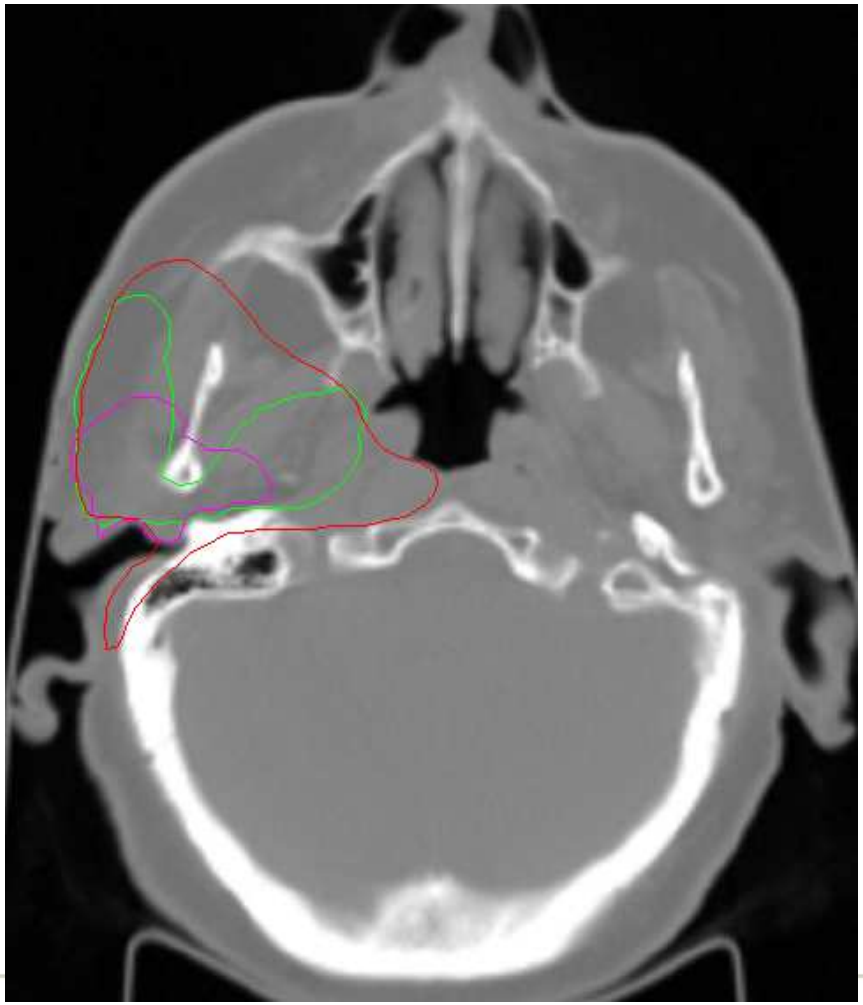

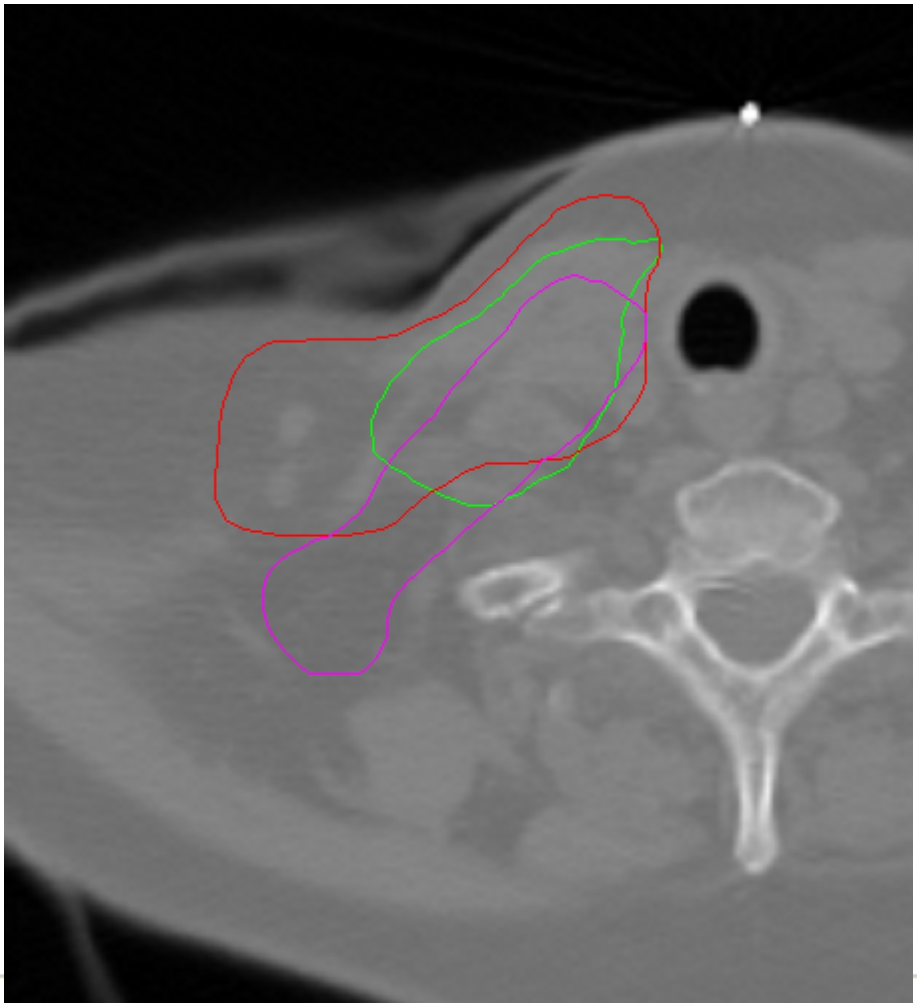

Mukesh, M et al, Br J Radiol 2012

ESTRO School

OAR Outlining

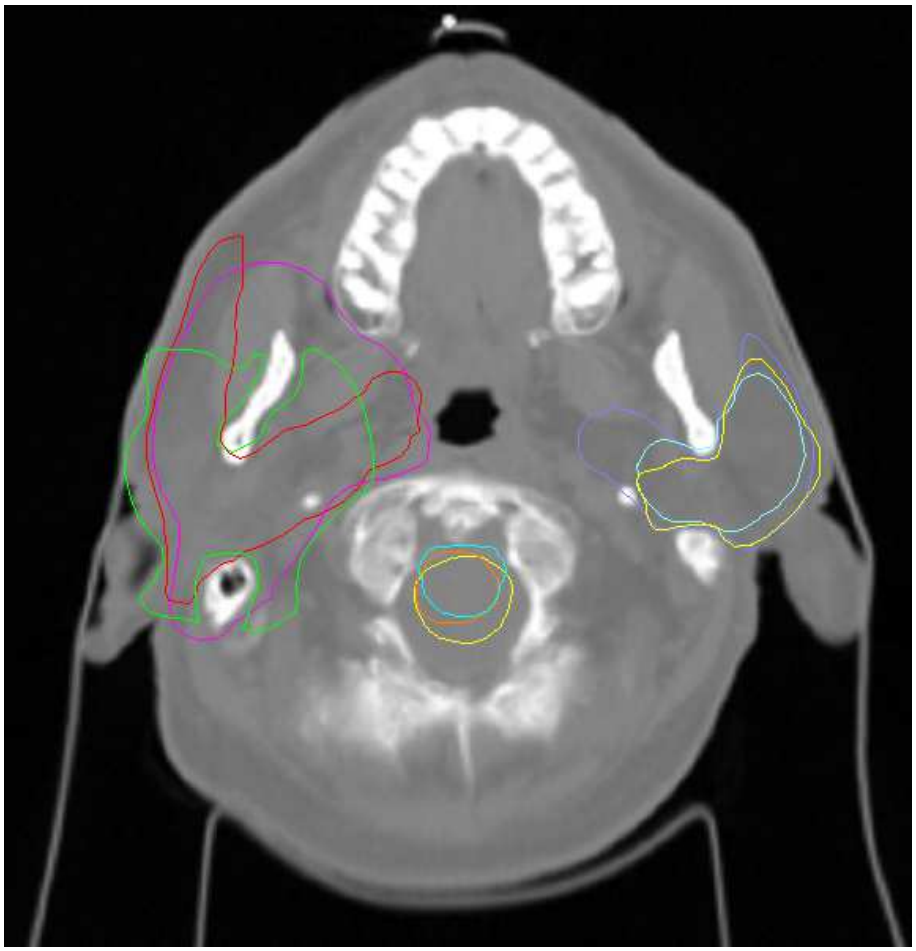

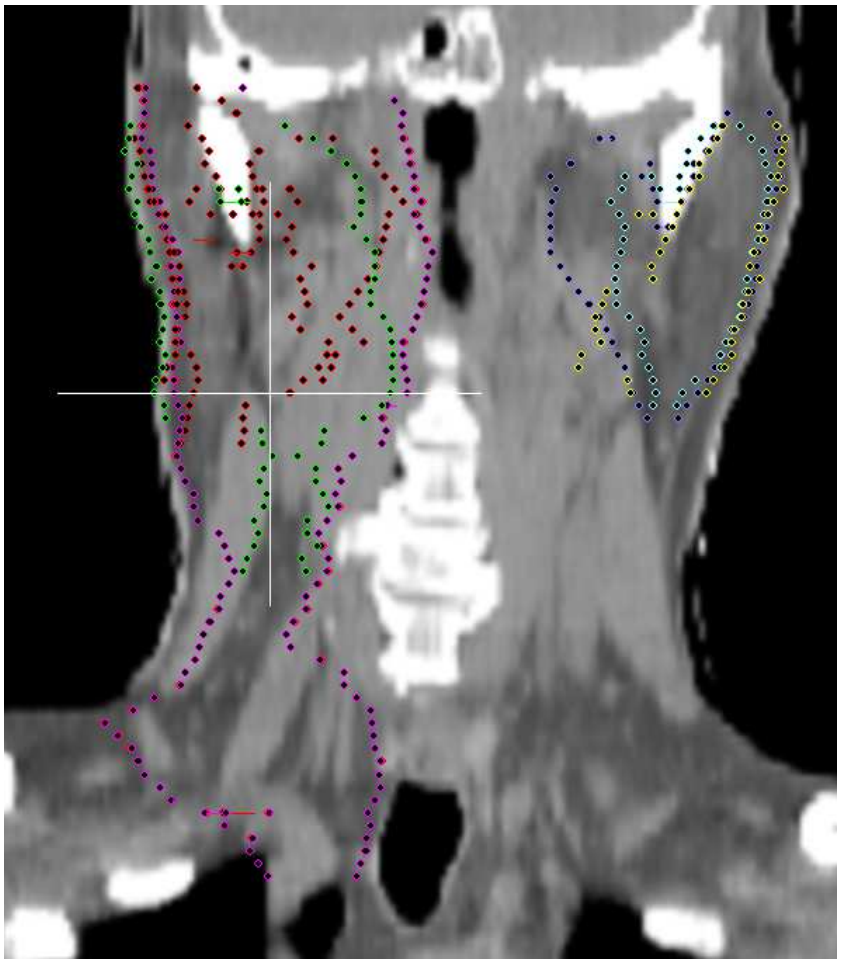

Mukesh, M et al, Br J Radiol 2012

ESTRO School

Target volumes - CTV

- Now includes the concept that the CTV contains sub-clinical disease ***with a certain probability***
- No consensus as to what probability actually requires treatment
- Probability of ~ 90-95% may be reasonable

  Should it be lower or higher?
- Concept of probability introduced in ICRU 83 (2010)

Target volumes - CTV

- CTV - contains demonstrable GTV and/or sub-clinical disease,
- Typically tumour ***cannot*** be seen or imaged in the CTV
- This volume must be treated adequately for cure

Target volumes - CTV

- CTV is based on historical data
  - Derived from population data
  - Margin not individualised

- Some individualisation according to anatomical boundaries is possible
  - This implies that isotropic growing is often ***not*** appropriate to derive the CTV

Target volumes - CTV

- It is allowable to have more than one CTV if necessary
- It is assumed that tumour cell density is lower in the CTV than in the GTV
- Therefore lower dose may be appropriate

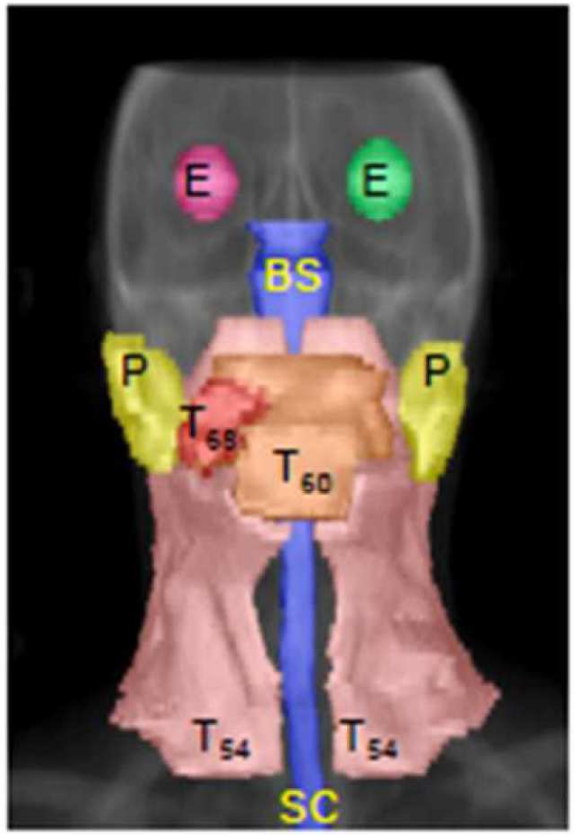

- CTV - ***not*** obvious from the imaging
- CTV ***cannot*** be imaged
- Based on knowledge of population pathology

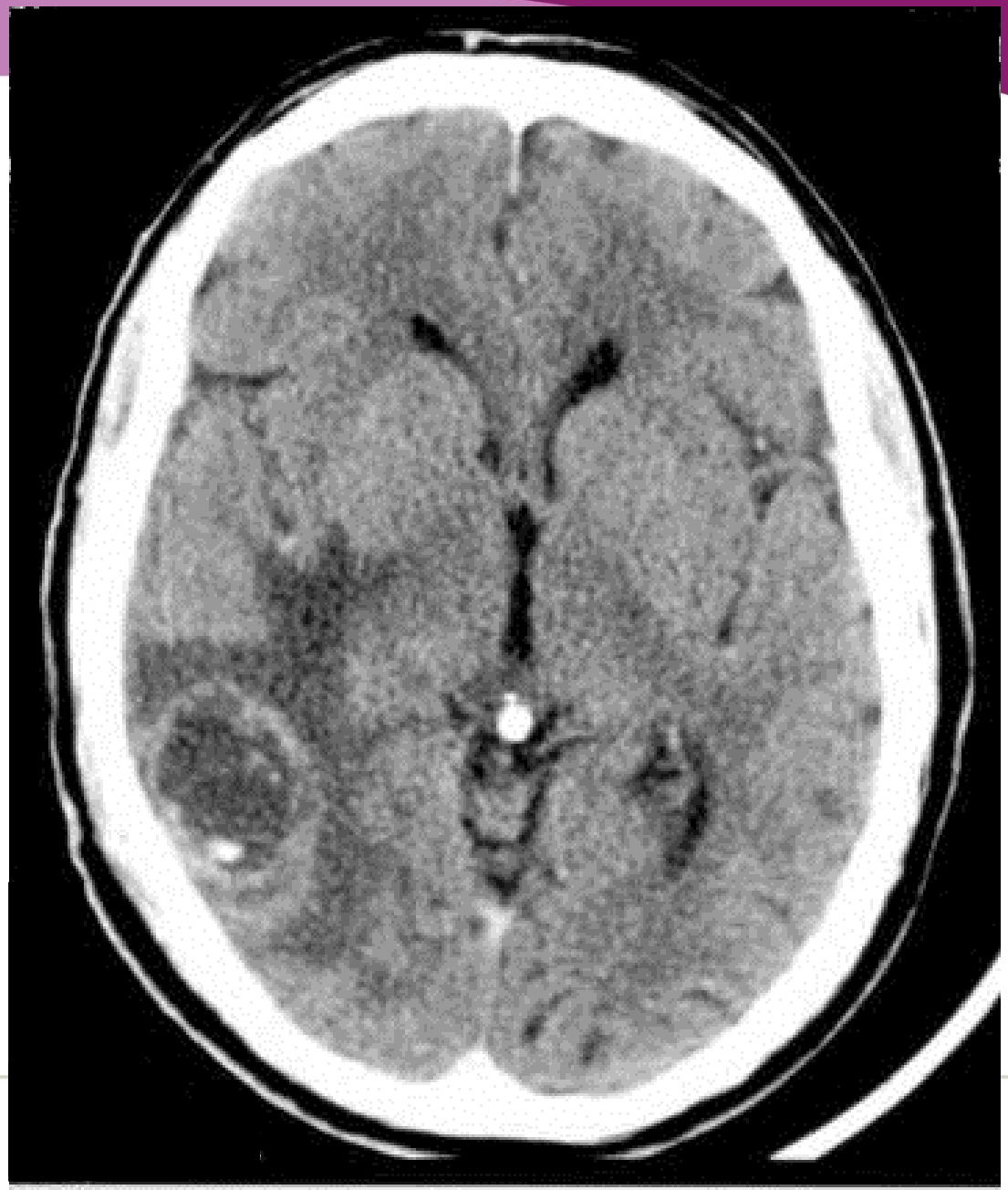

- CTV is an‘average’ volume
- CTV is enclosed by the skull
- Anatomical considerations useful

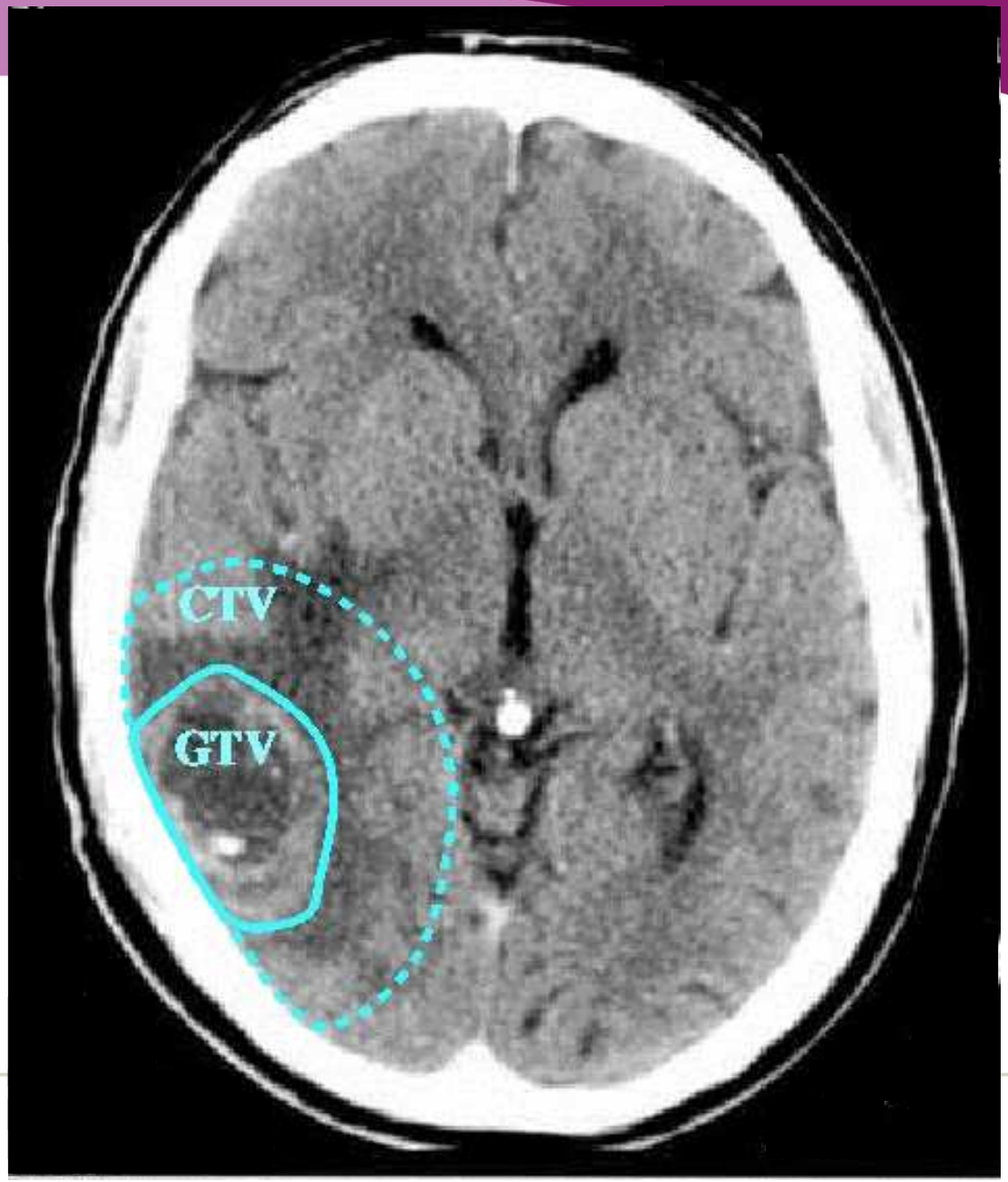

Target volumes - CTV

Newer imaging may push the edge of the GTV outwards into the CTV

If CTV stays the same, the margin will change

May need new definitions

? “Imaging High-risk Volume” – IHV

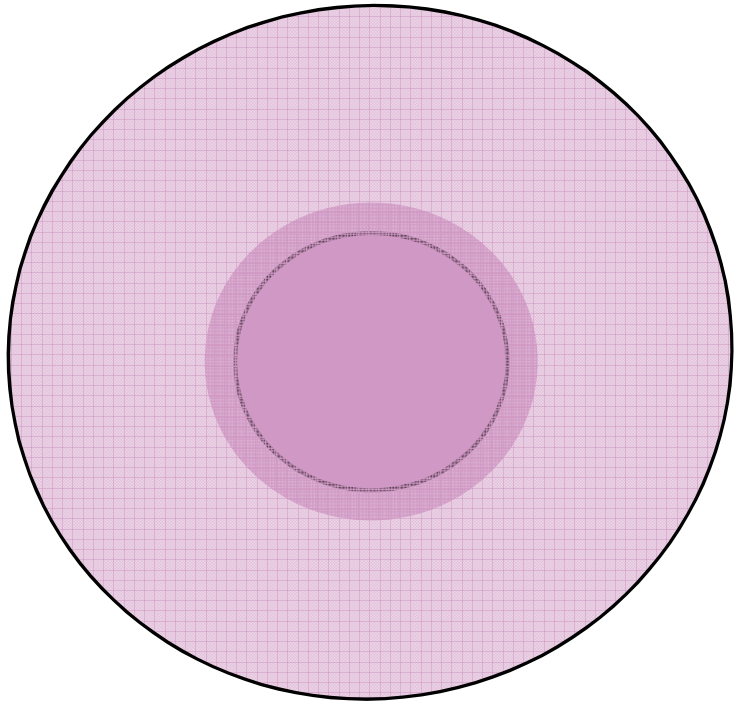

Target volumes - PTV

Target volumes - PTV

PTV is a geometric concept designed to ensure that the prescription dose is actually delivered to the CTV

In a sense, it is a volume in space, rather than one directly related to the anatomy of the patient

PTV may extend beyond bony margins, and even outside

Target volumes - PTV

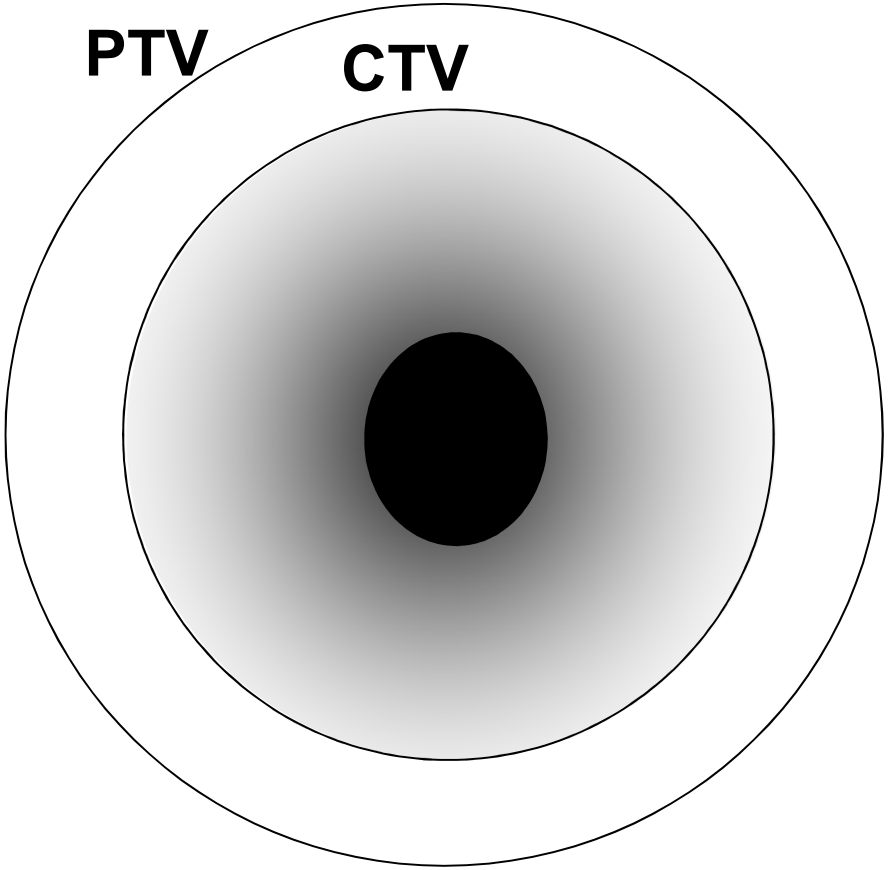

CTV safely enclosed within PTV

ESTRO School

Target volumes - PTV

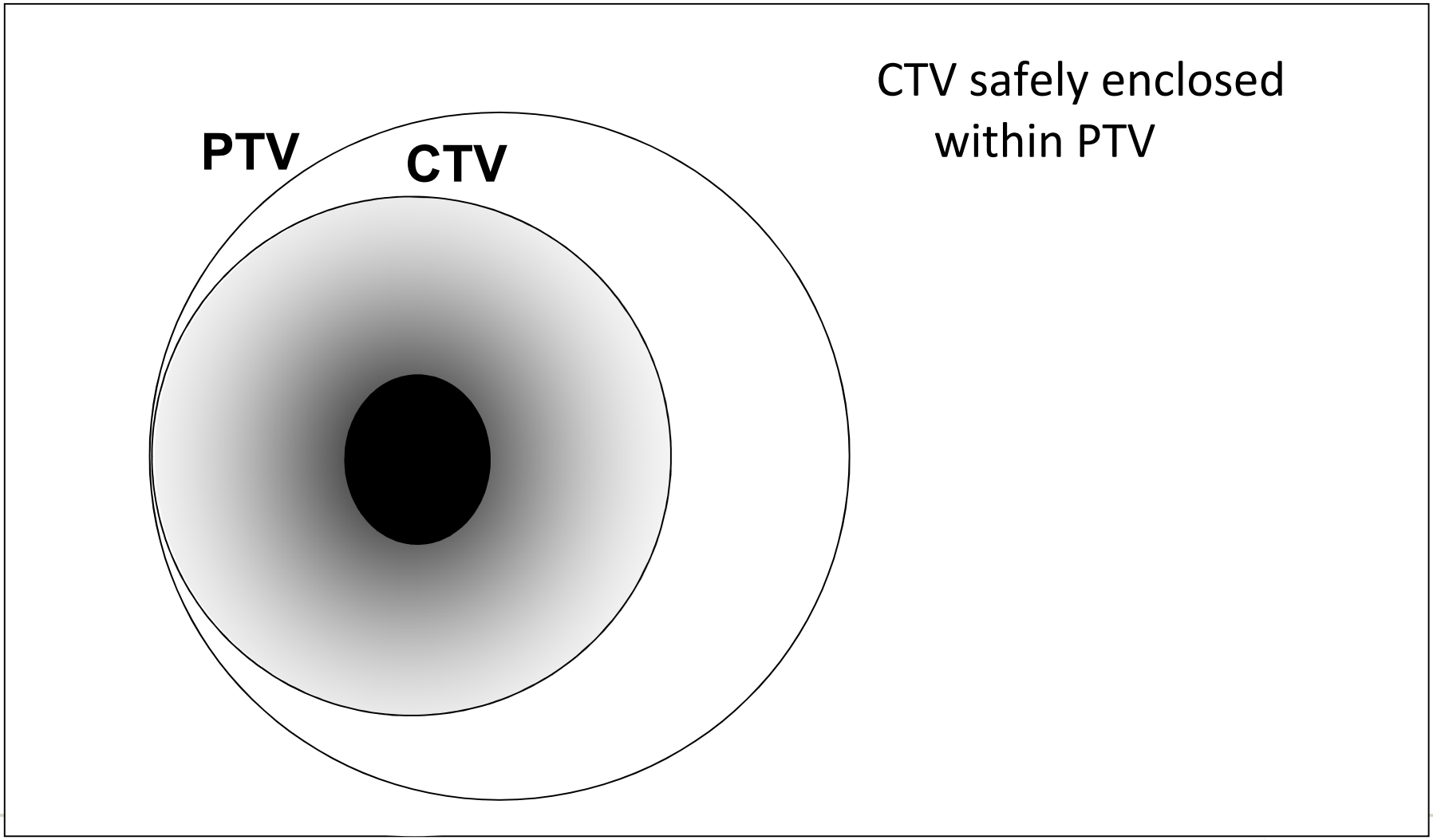

Target volumes - PTV

PTV outside the patient

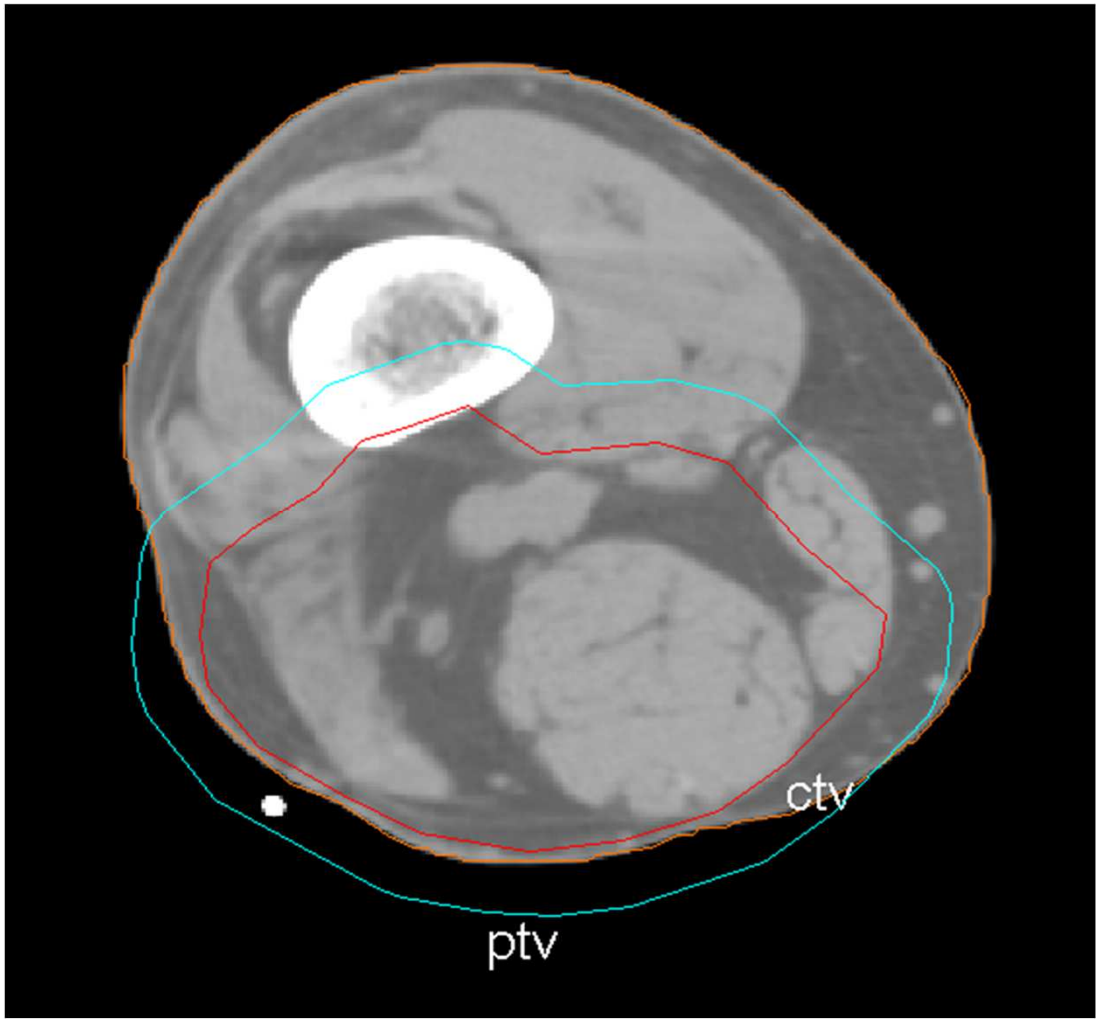

Target volumes - PTV

- The CTV must be treated adequately for cure
- The PTV is used to ensure that the CTV ***is*** properly treated
- PTV designed to allow for uncertainties in the process of planning and delivery
  - These uncertainties are many …

Target volumes – PTV

- **ICRU 62 suggested 2 components to the PTV:**
  - Internal Margin IM – for eg organ movement
  - Setup Margin SM – for set-up inaccuracies

- **CTV + "Internal Margin" (IM) = Internal Target Volume (ITV)**
- **ITV + "Set-up Margin" (SM) = PTV**
- Inadequate PTV margins:
  - risk increased treatment failure
- Excessive PTV margins risk:
  - increased treatment toxicity

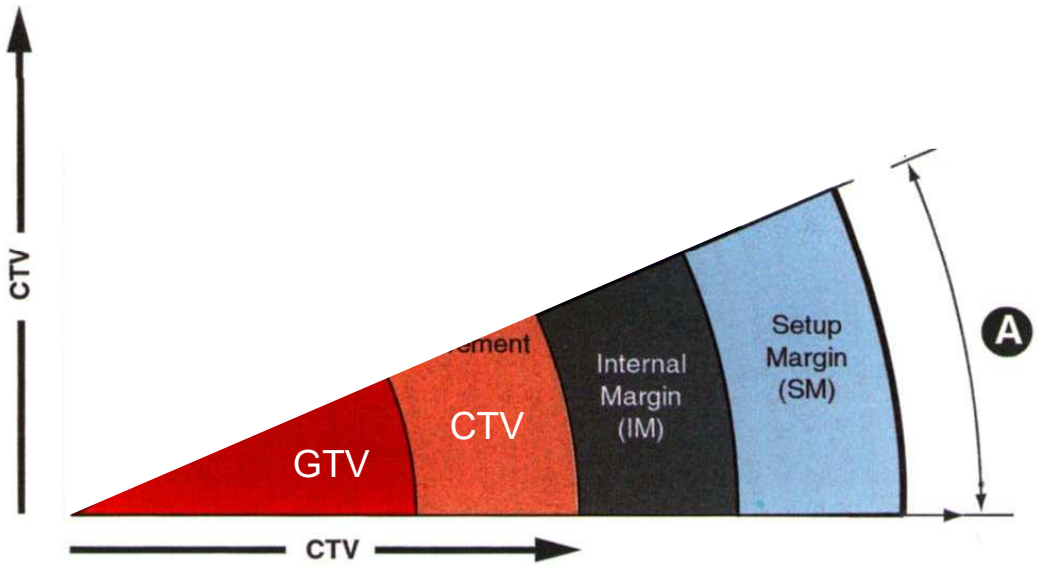

- Fig from ICRU 62 (also in ICRU 71)
- Adding IM + SM to reach the PTV

Gross Tumor Volume (GTV)
Subclinical Involvement
Internal Margin (IM)
Set Up Margin (SM)

ESTRO School

Target volumes – PTV

- ICRU 62 also acknowledged that simple addition may not be :
  - realistic – because the margin becomes very large
  - correct – because not every error occurs in the same direction on the same occasion

- Components to be added in quadrature rather than arithmetically

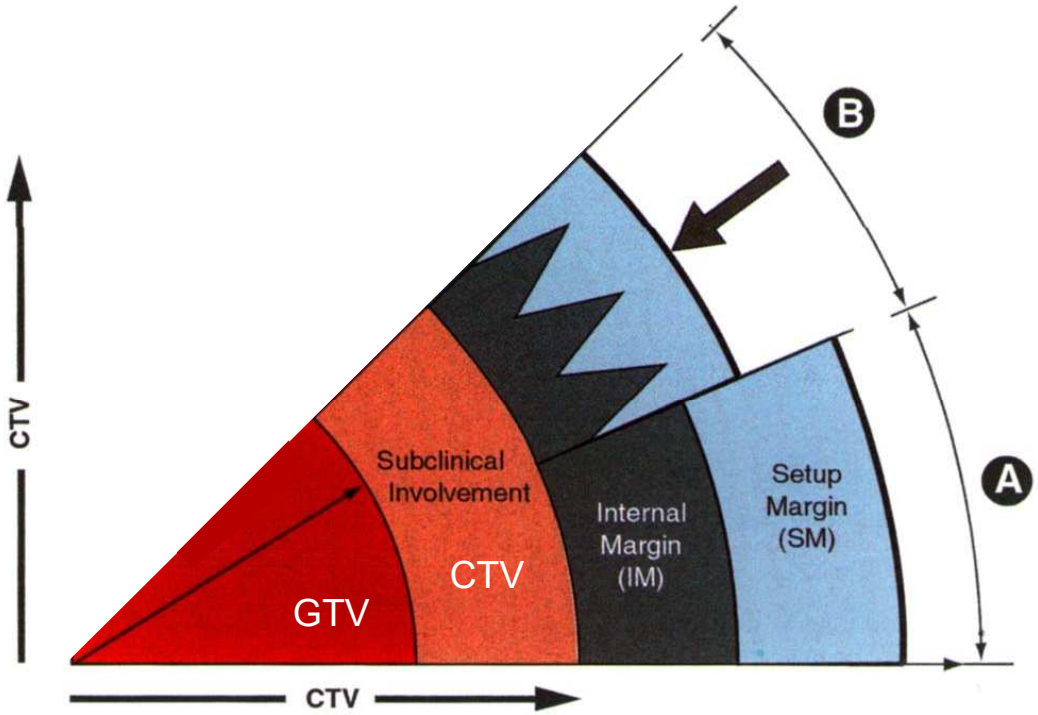

- Scenario B
- Adding IM + SM in quadrature
- Specific margins must still be addressed

Gross Tumor Volume (GTV)
Subclinical Involvement
Internal Margin (IM)
Set Up Margin (SM)

ESTRO School

Target volumes - PTV

- Various formulae have been proposed for calculating population-based expansion margins
- the van Herk margin formula is widely adopted to calculate PTV margins
- It is expressed as a weighted function of the total systematic (Σ) and random errors (σ) where the calculated margin will deliver 95% of the prescribed dose to the CTV for 90% of patients

$$\mathbf{PTV = 2.5\Sigma + 0.7\sigma}$$

Target volumes – PTV - Adaptation

To date PTV margins have been based on population data

Imaging during treatment – allows the concept of individualised PTV margins

Eg. Plan of the day for bladder cancer treatments

This could be a whole separate talk ……

Target volumes – OARs + PRVs

OAR - Organ at Risk

PRV - Planning organ at Risk Volume

Target volumes – OARs

- Organs at Risk are normal tissues whose radiation tolerance influences treatment planning, and /or prescribed dose
- Now know as OARs
- Uncertainties apply to an OAR as well as to the CTV…

OARs

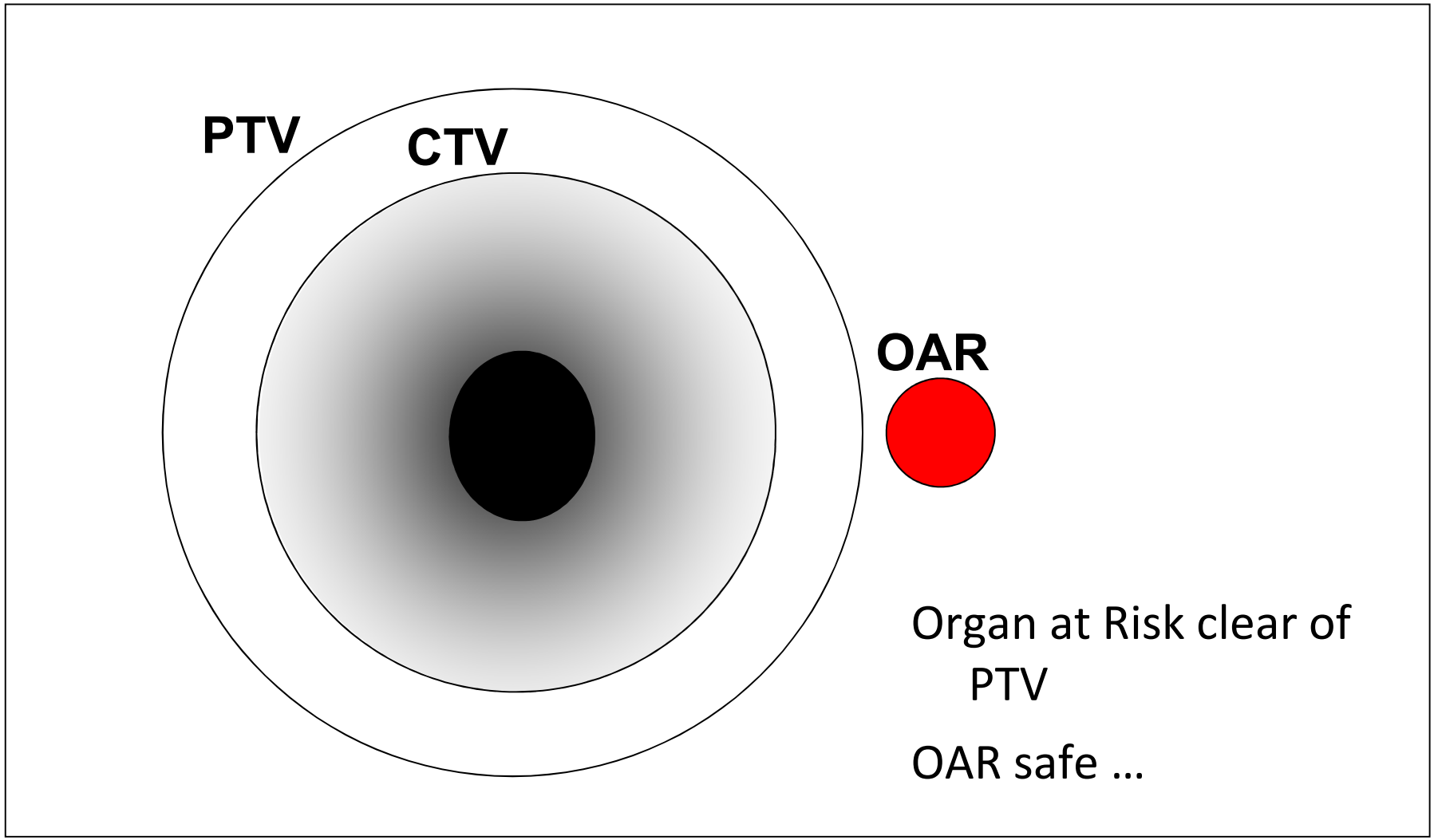

Organ at Risk clear of PTV

OAR safe …

OARs

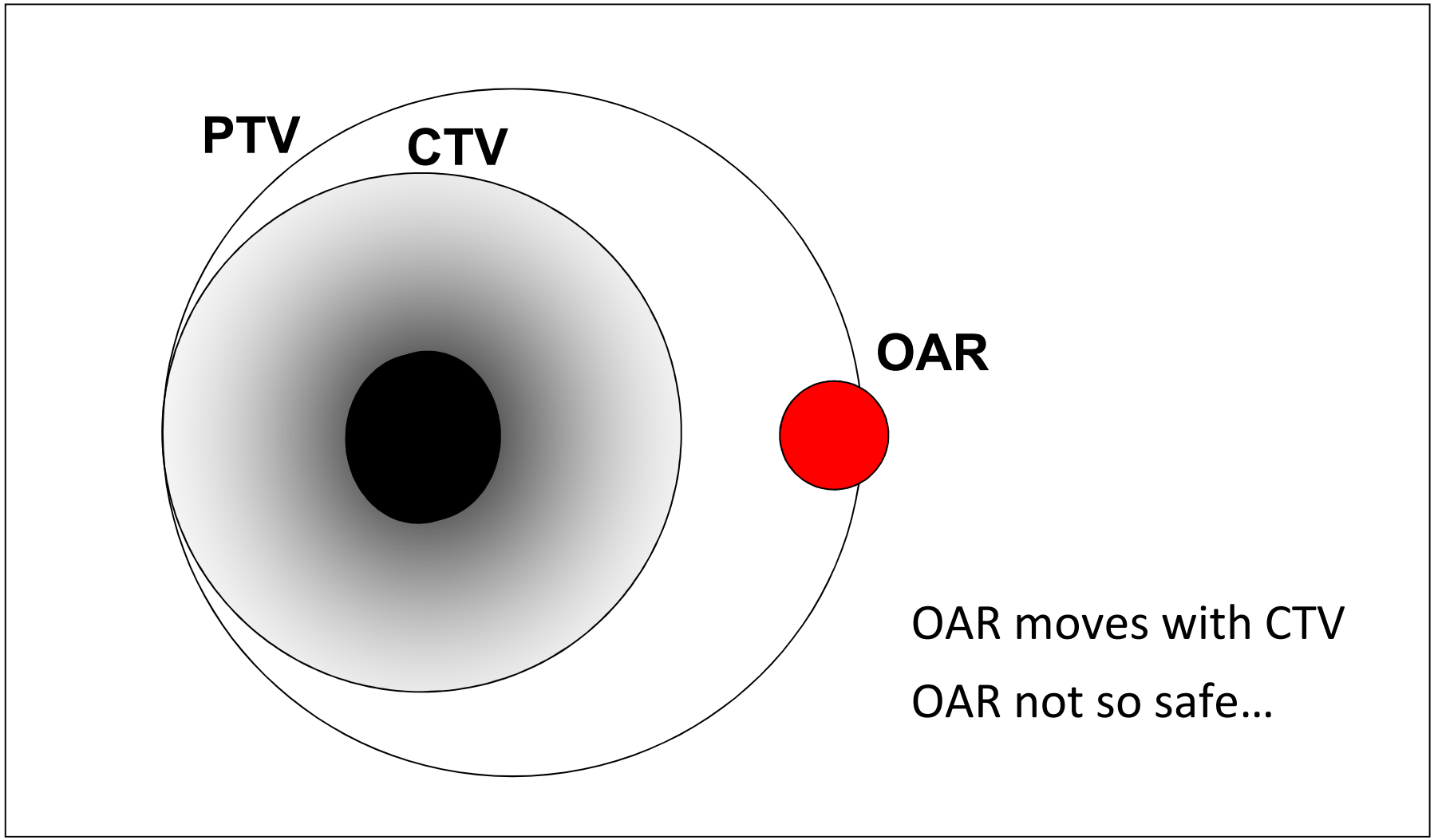

Target volumes - OARs

- Imaging must also show Organs Risk

- Essential to achieve a therapeutic gain

Target volumes – OARs

For parallel organs, comparison between plans, patients or centres requires the ***whole*** organ to be delineated, according to an agreed ***protocol***

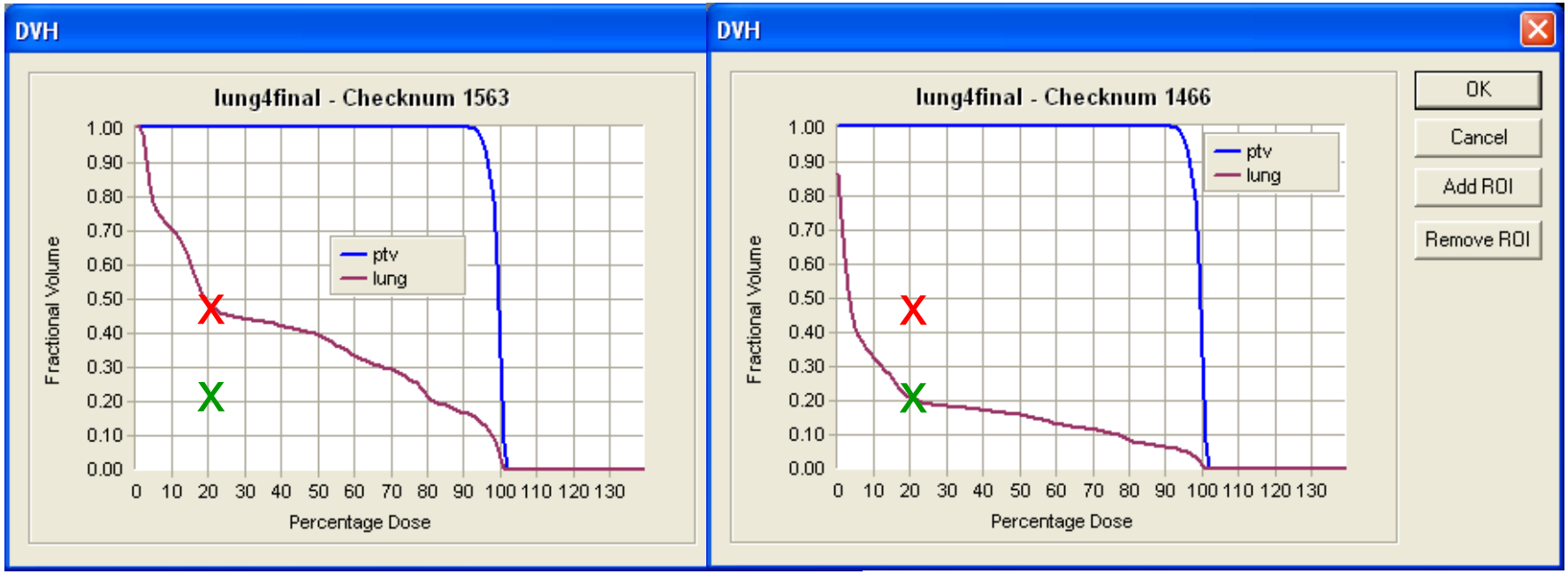

- Whole lung not outlined
- Better DVH!

ESTRO School

Target volumes – OARs

Rectum–clear delineation, according to an agreed ***protocol***

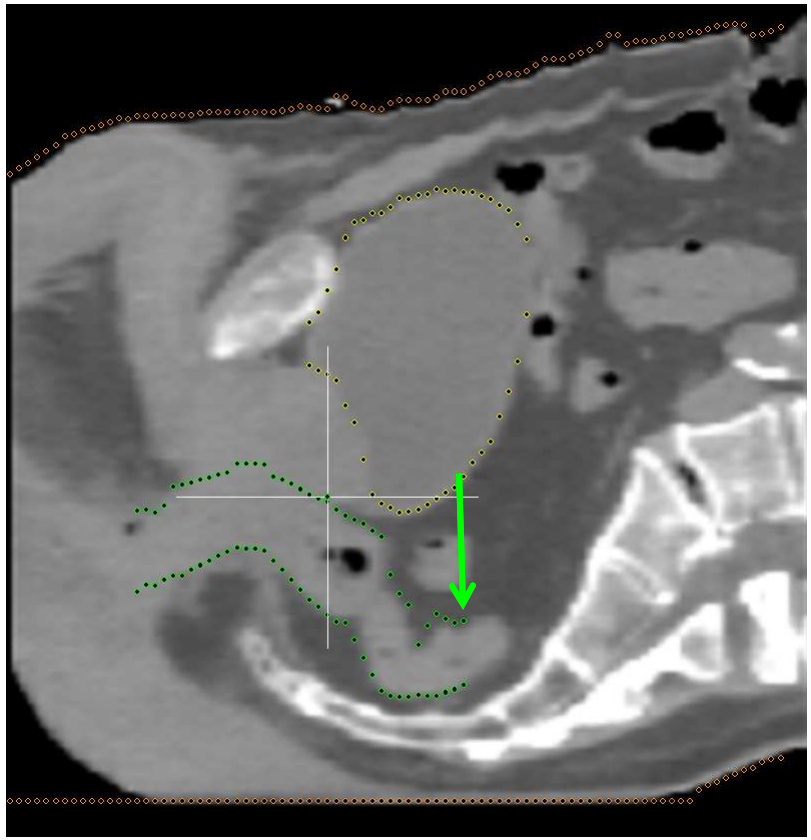

- Rectum correct

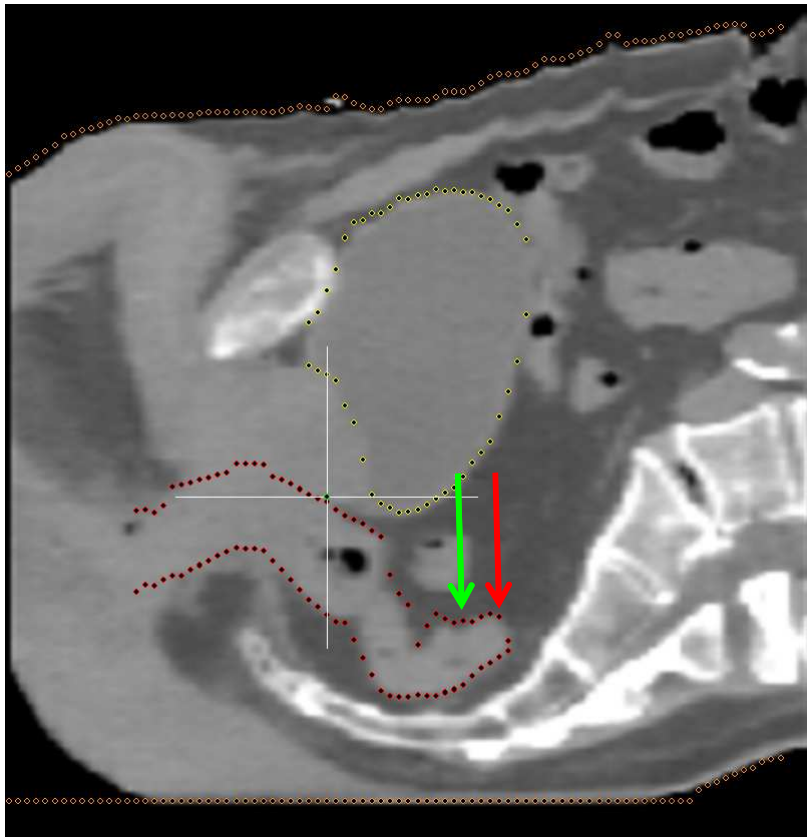

- Rectum on 4 slices more

ESTRO School

Target volumes – OARs

For other parallel organs, over-contouring may lead to DVHs which appear better but are incorrect

Rectum– needs clear delineated, according to an agreed ***protocol***

- Rectum 'over-contoured'

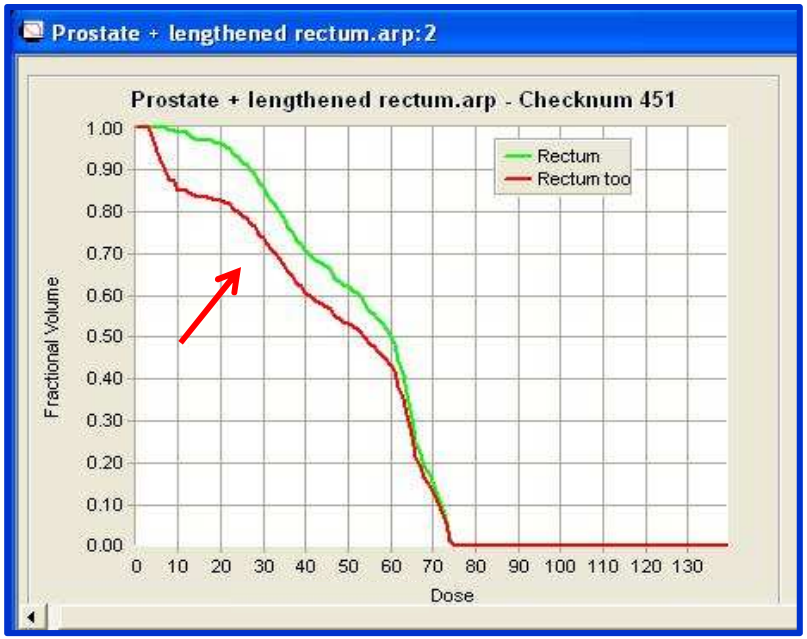

- 'Better' DVH is incorrect

ESTRO School

Target volumes – OARs + PRVs

- Uncertainties apply to the OAR … so a ‘PTV margin’ can be added around it - to give the Planning organ at Risk Volume (PRV)

- But … the use of this technique will substantially increase the volume of normal structures

- May be smaller than PTV margin

  Component for systematic error can often be smaller

Target volumes – PRV

- The use of a PRV around an Organ at Risk is relevant for OARs whose damage is especially dangerous

- This applies to organs where loss of a ***small*** amount of tissue would produce a ***severe*** clinical manifestation

- A PRV is more critical around an OAR with serial organisation

Tissue architecture

Serial organ

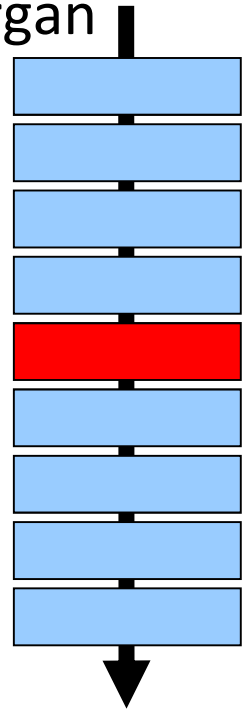

Damage to 1 part causes failure – eg spinal cord

Severe clinical consequence

- Parallel organ

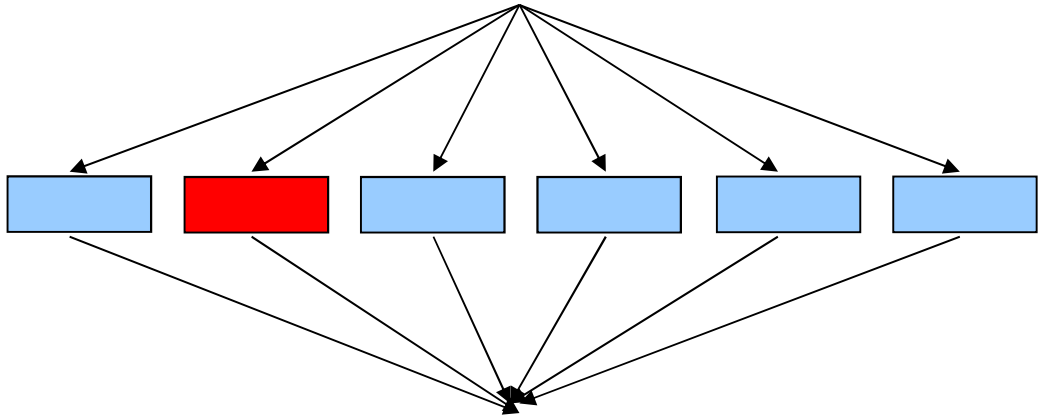

- Damage to 1 part (only) does not compromise function
- Examples …

ESTRO School

Target volumes – PRV

- Spinal cord, brainstem & optic nerves/chiasm perfect examples where a PRV may be helpful
  - serial tissue organisation
  - damage is clinically catastrophic

- Add a PRV, especially if high doses are planned
- Almost no other OARs where a PRV is needed
- PRV may be misleading for parallel organs

(This advice is more definitive than ICRU 83)

Target volumes – PRV

PRV around optic nerves and chiasm

Allows dose escalation

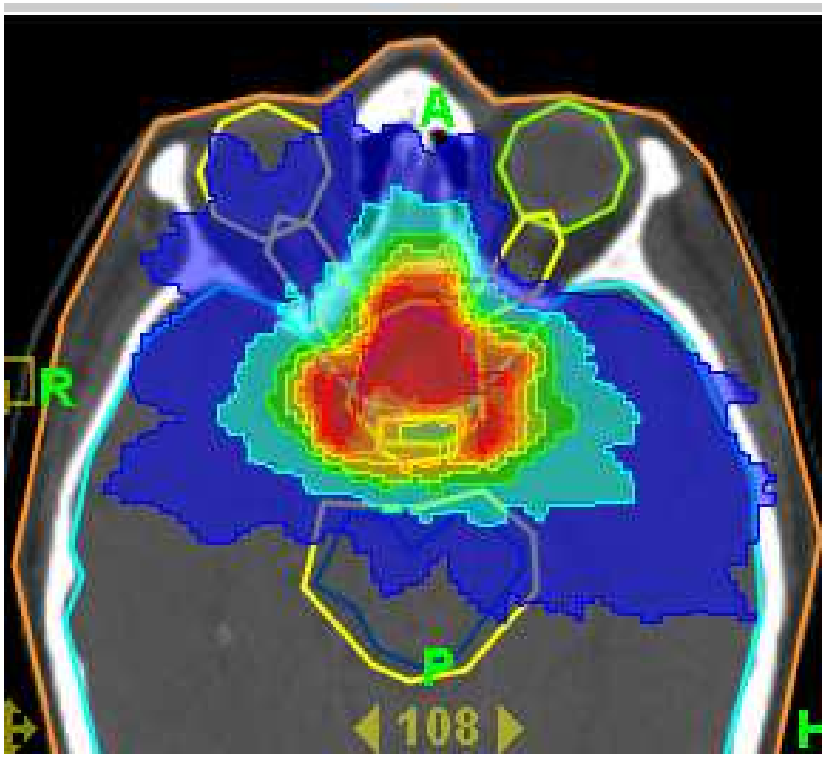

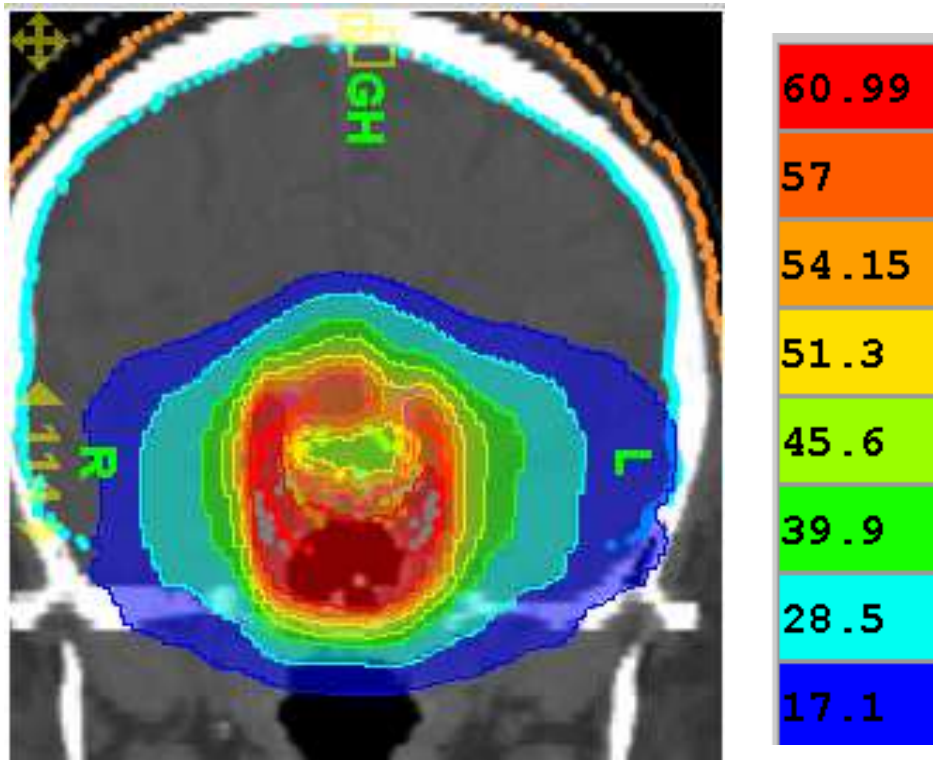

Target volumes – PRV

- Kidney PRV 10mm
- DVH for PTVs ≈ PRVs
- PRV often not of particular value

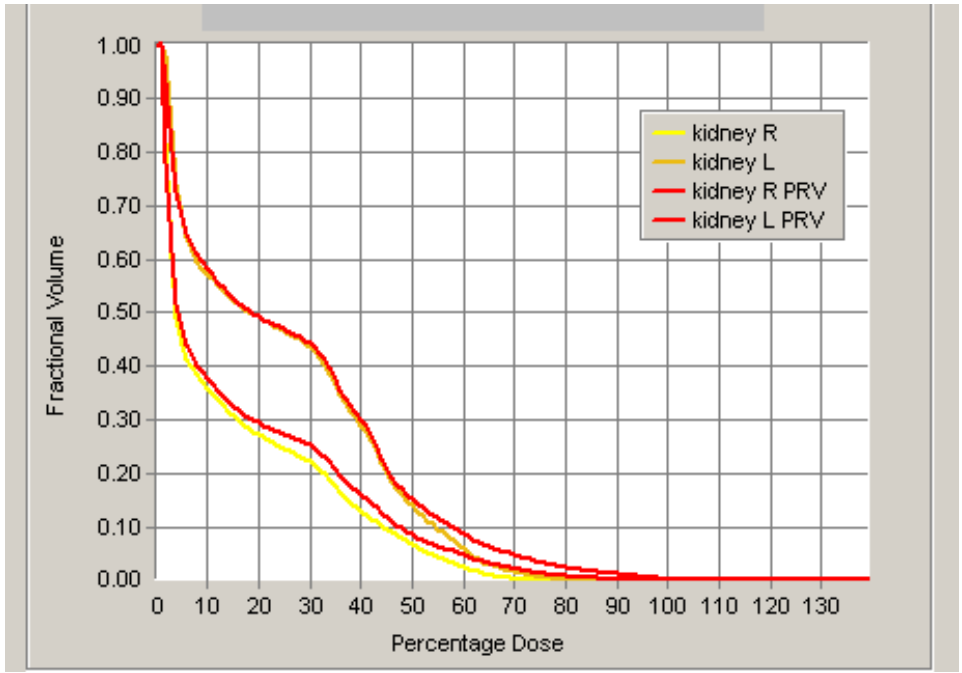

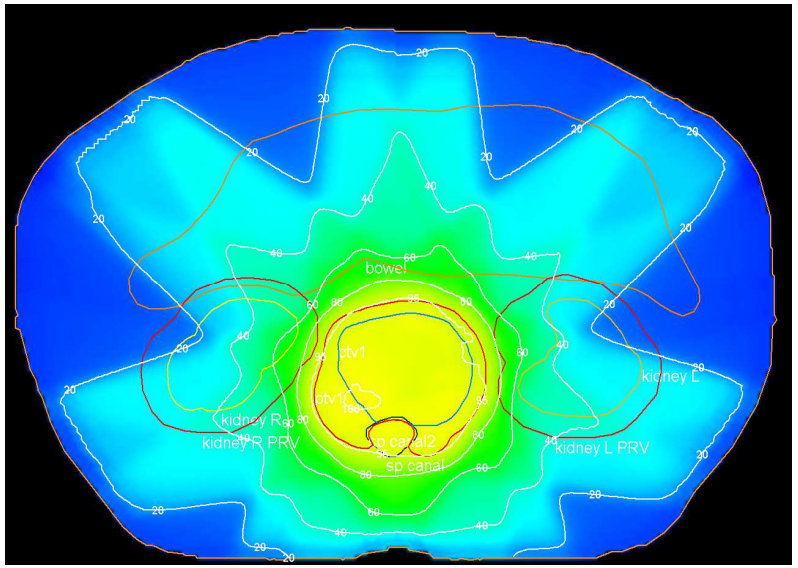

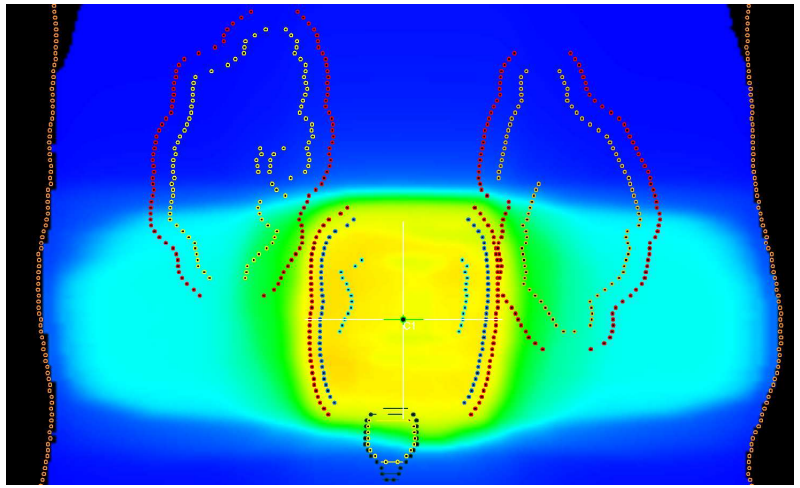

Target volumes – PRV or optimising structure?

ESTRO School

Hypothalamus DVHs

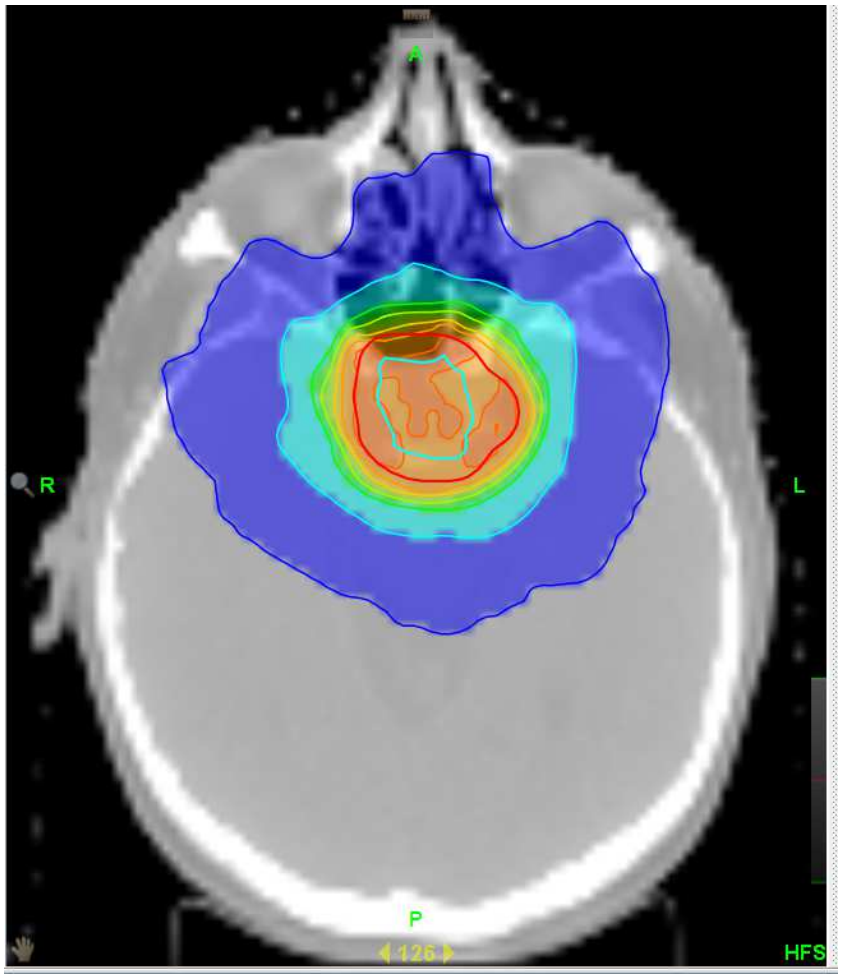

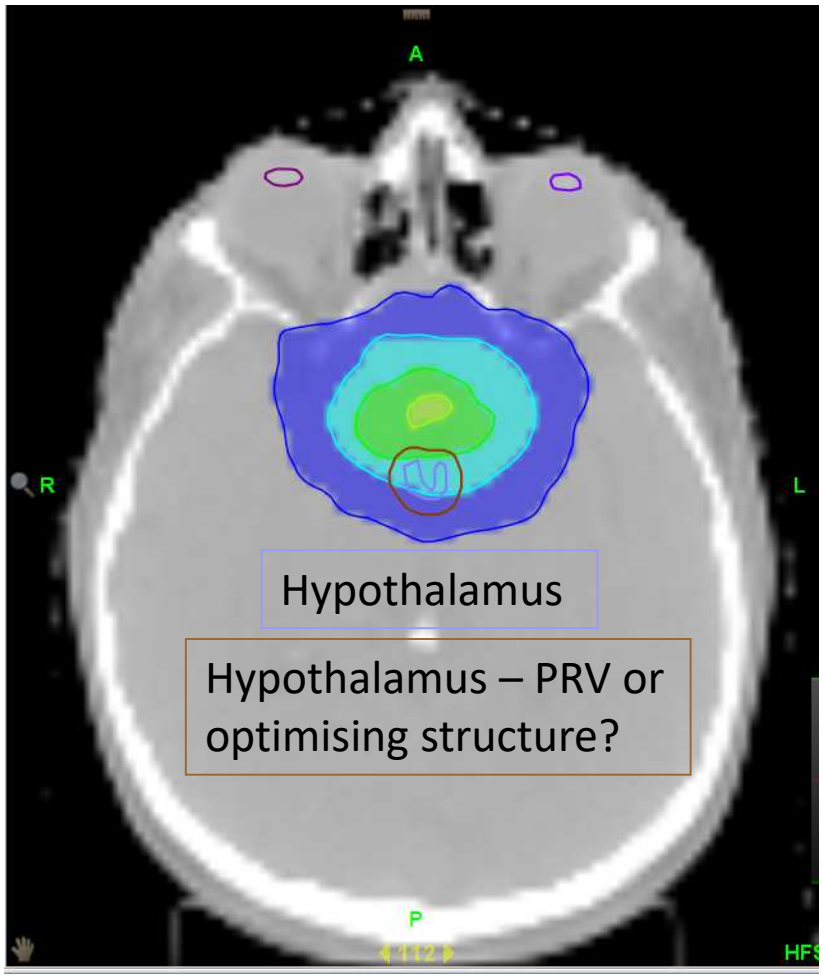

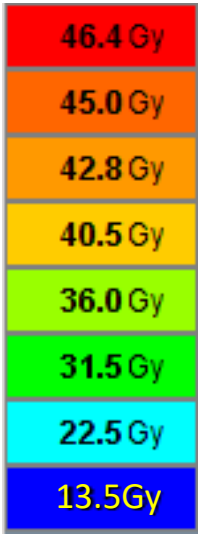

ESTRO School

Hypothalamus DVHs

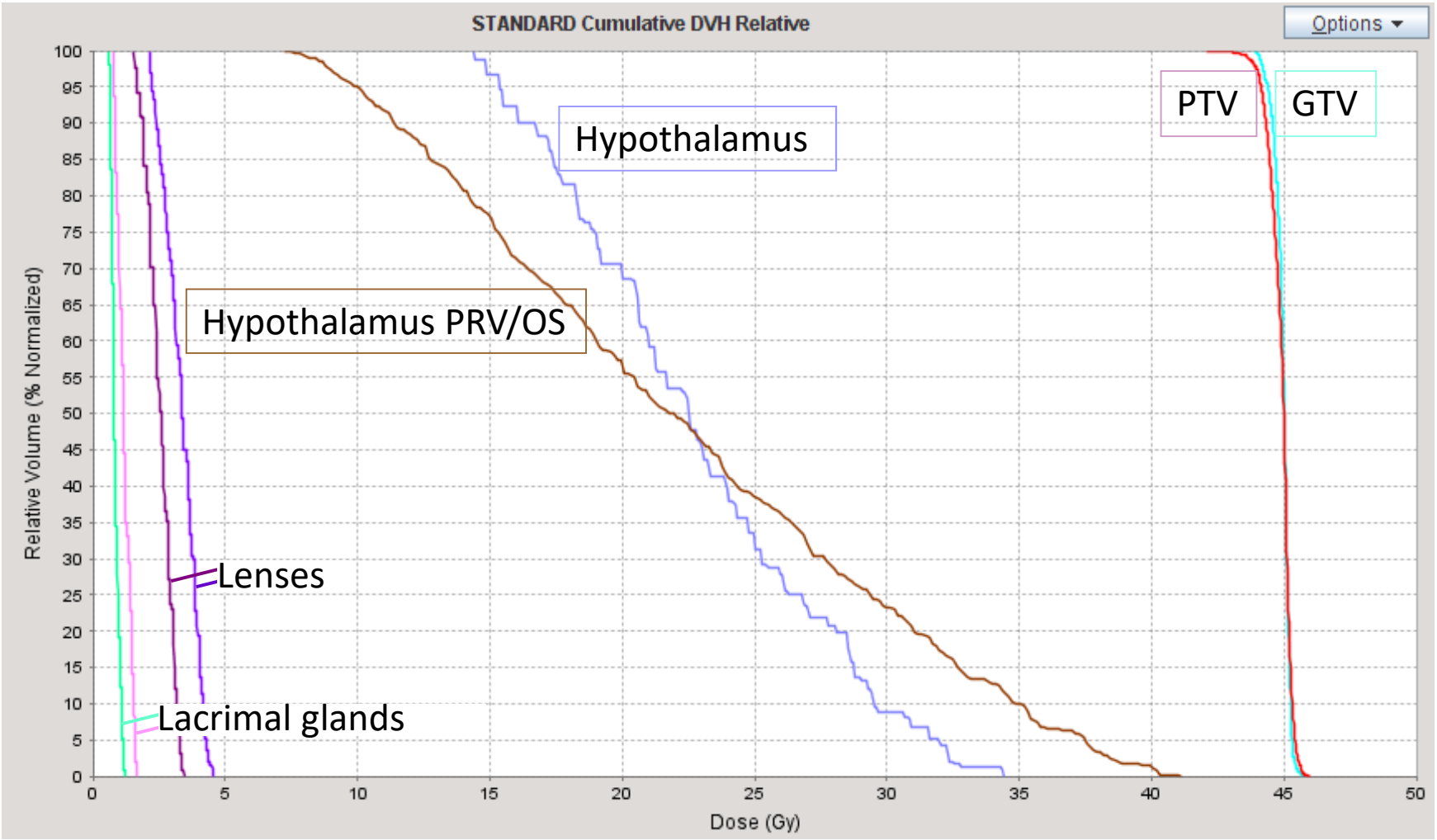

Hypothalamus DVHs

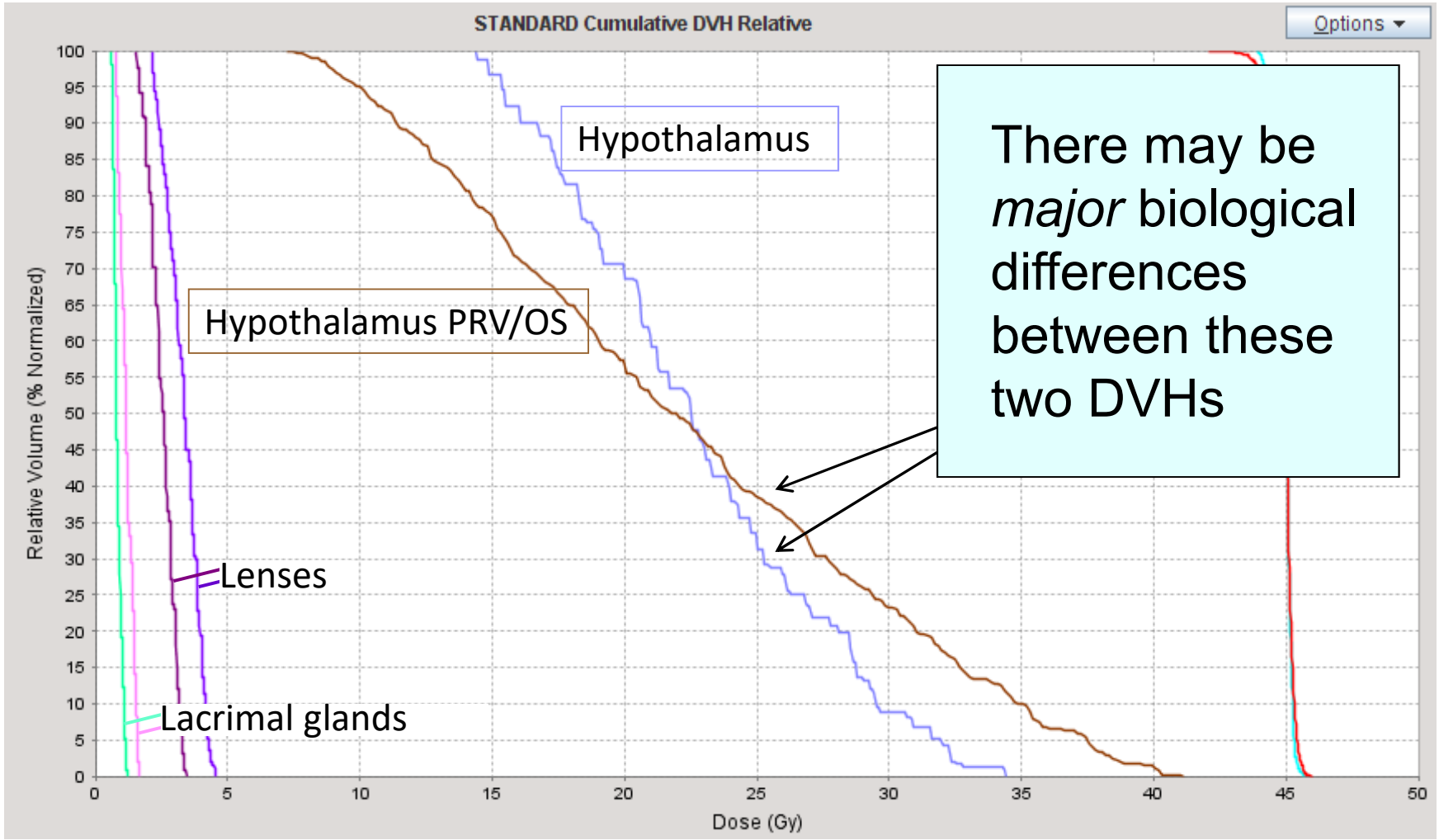

PRV

Example

Ca tonsil

Spinal cord
close

Aim for 70 Gy

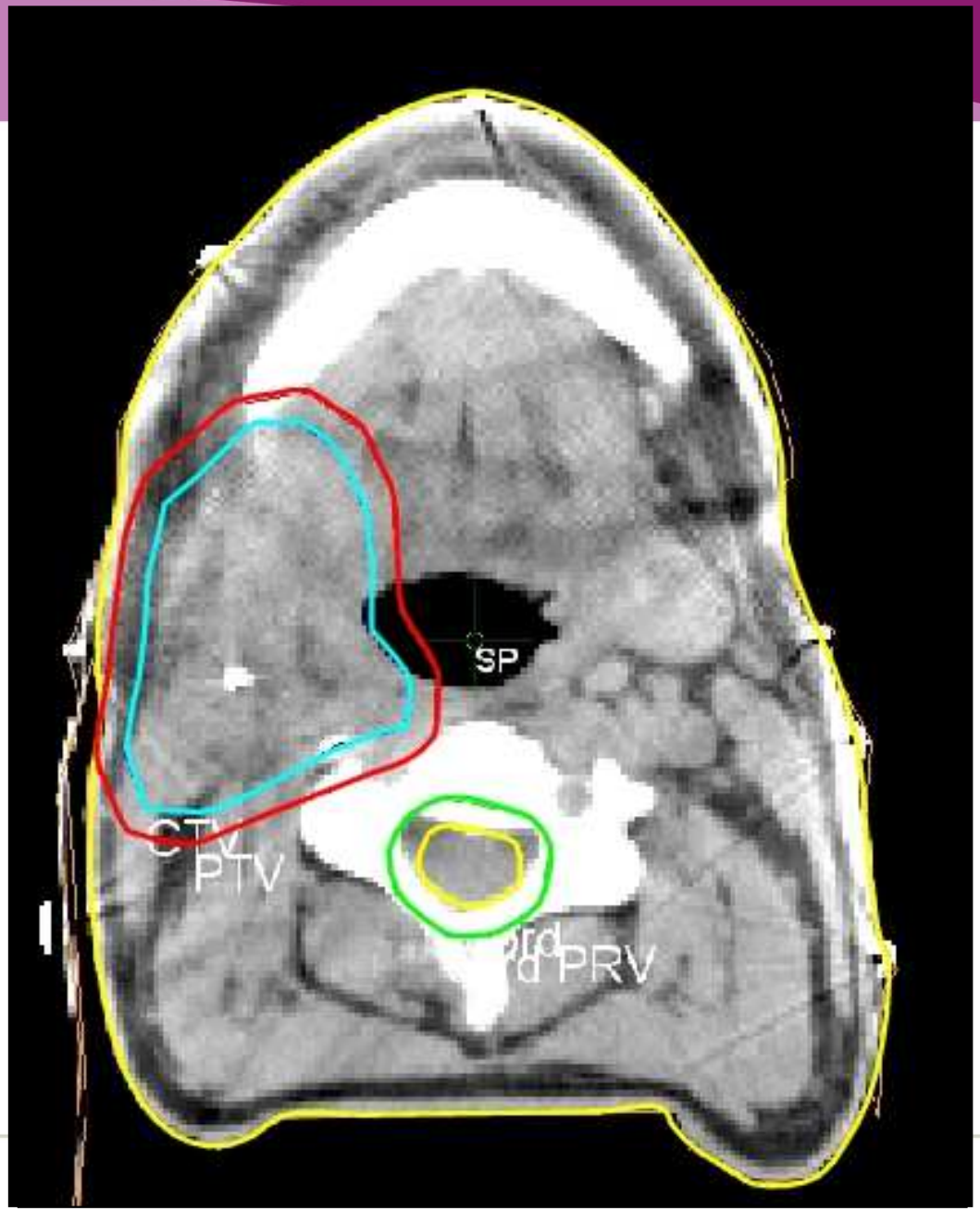

Simple outlines

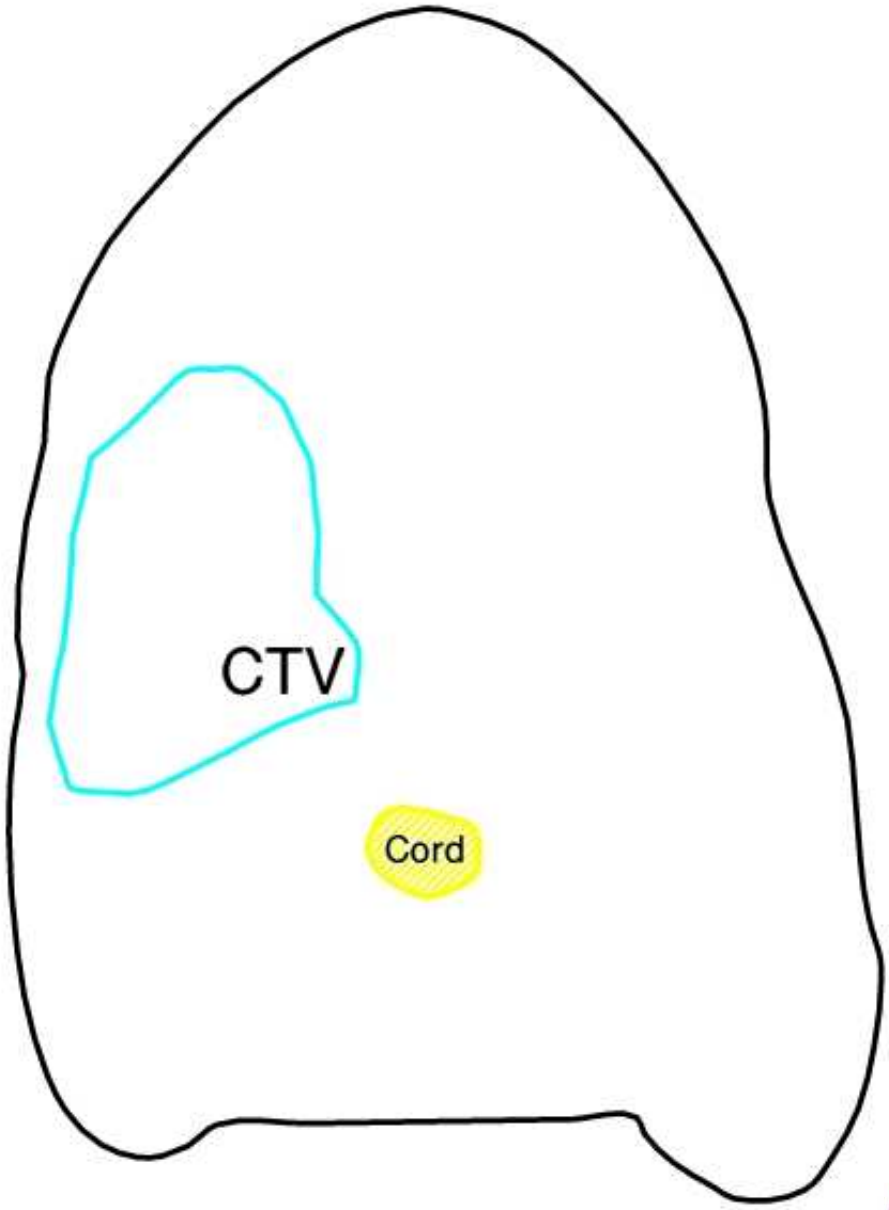

ESTRO School

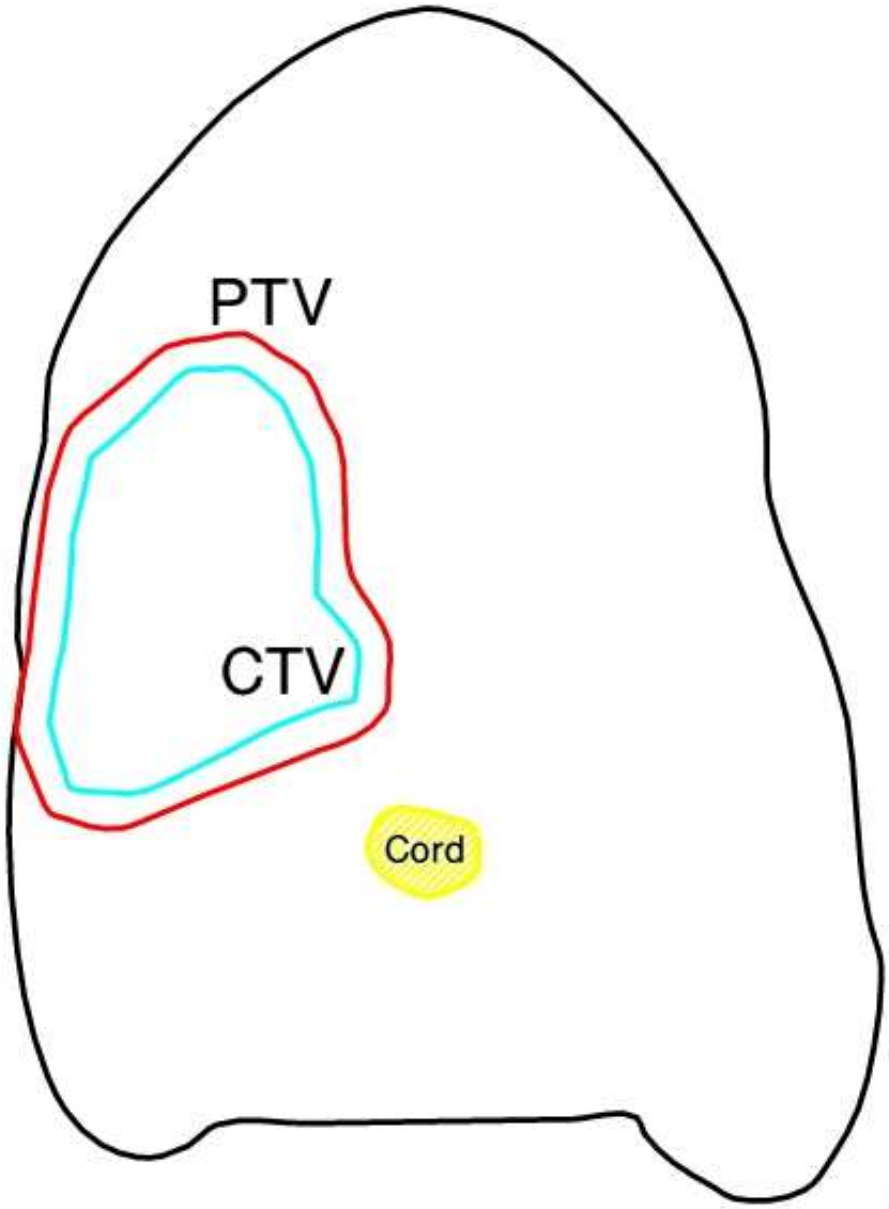
PTV
CTV
Cord

Cord should be safe

PRV is away from PTV

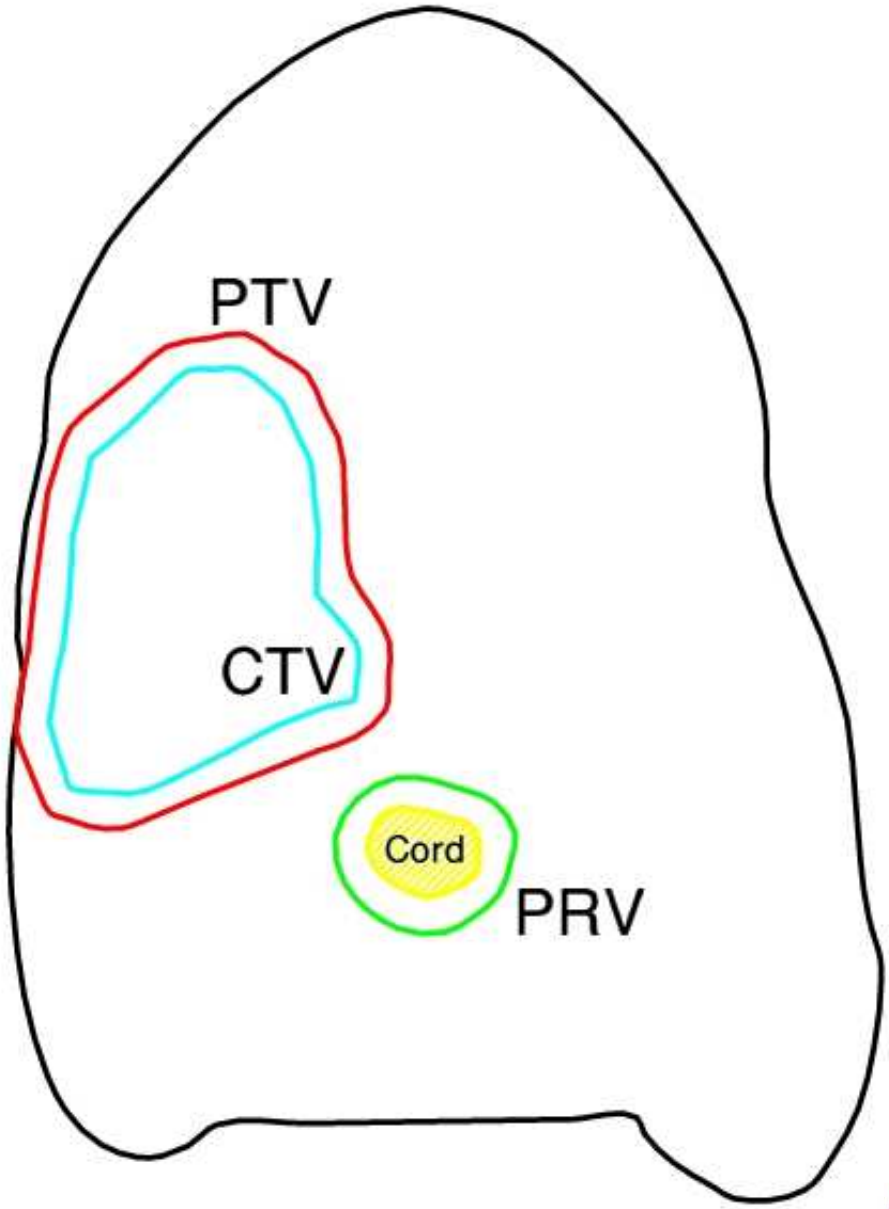

- Cord still safe even if set up is imperfect
- Note: patient, CTV and cord have moved
- PTV and PRV have not moved

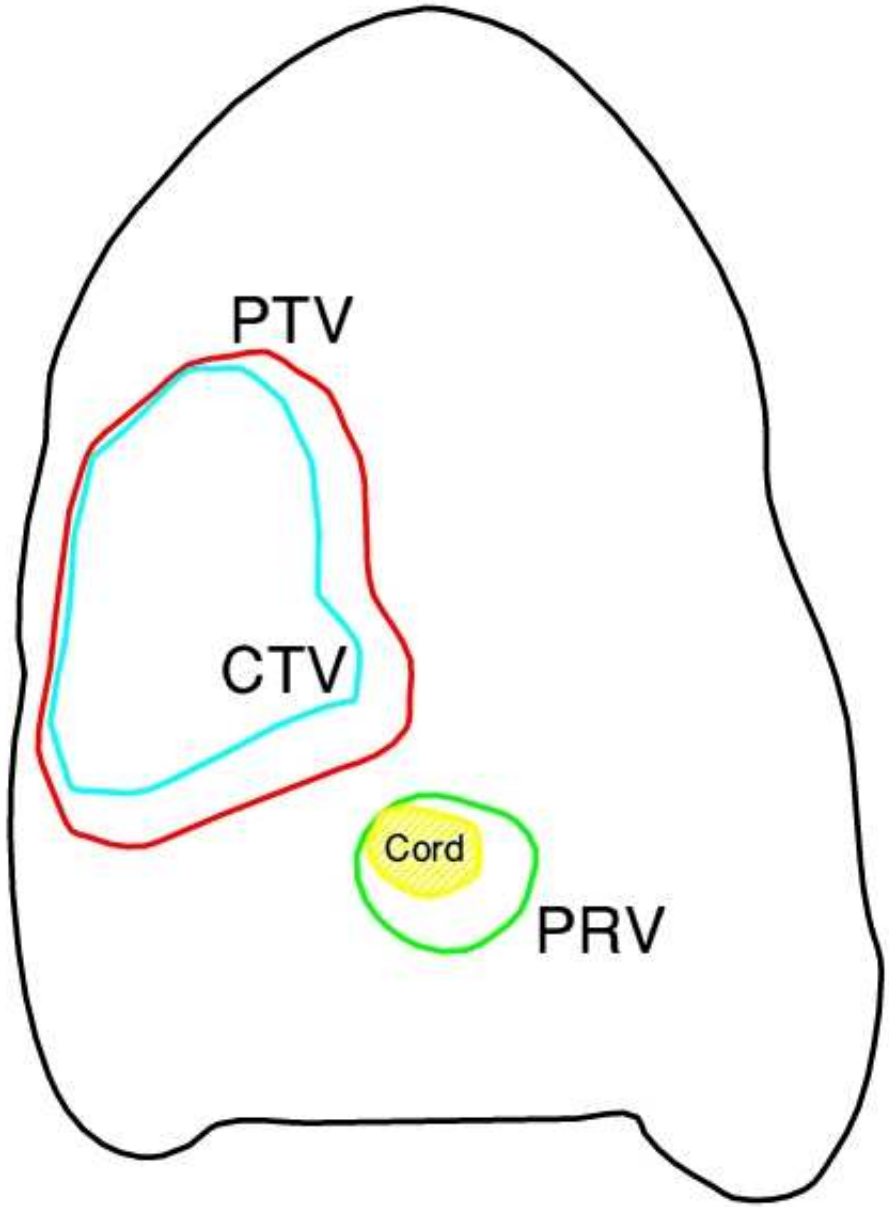

ESTRO School

- PTV & PRV closer
- PRV shows area to avoid with high dose to ensure the cord is safe
- No conflict

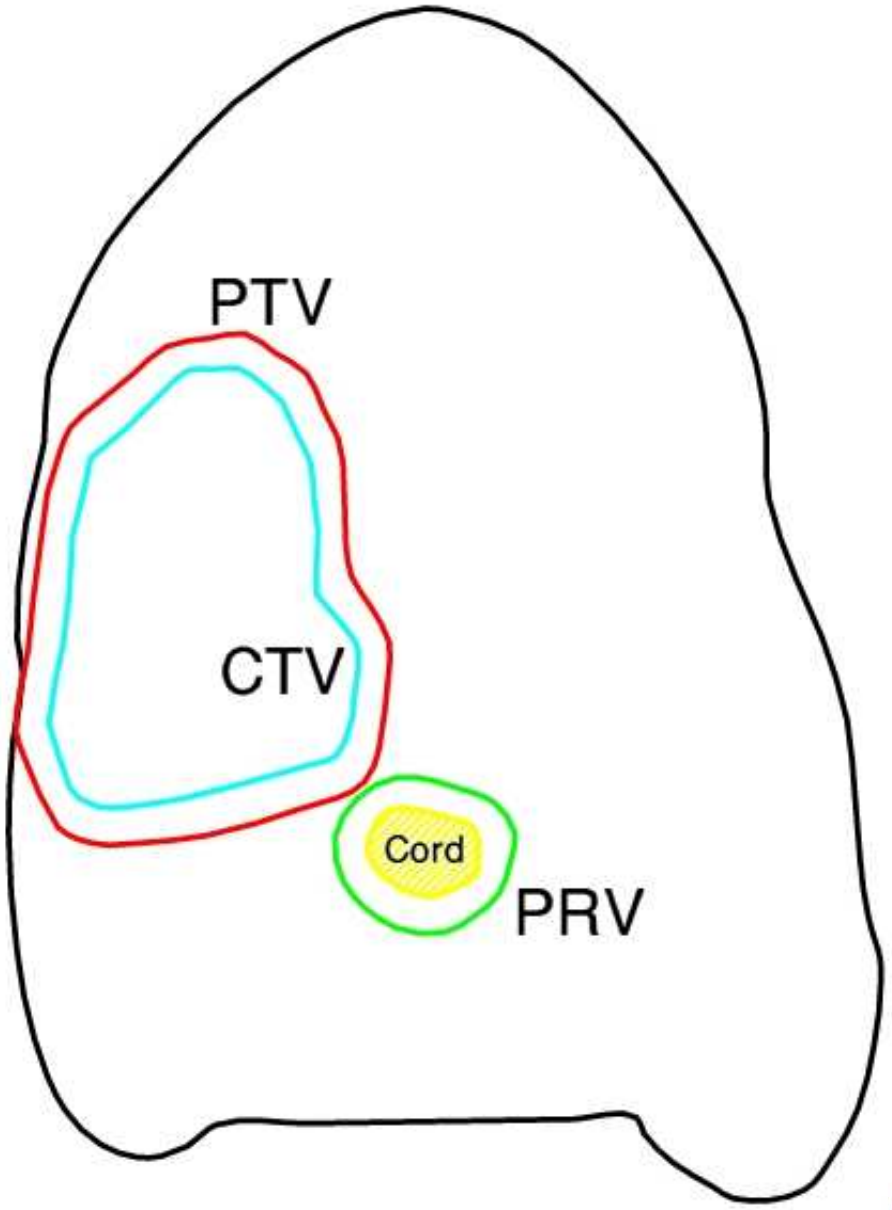

ESTRO School

Target volumes – PTV + PRV

PRV margin can be ***smaller*** than the PTV margin

This is a helpful step for high dose treatments close to an OAR

This is because OAR movement is usually a 1D problem
(occasionally 2D, rarely 3D)

Target volumes – overlaps

Target volumes – overlaps

There are always occasions when the PTV and OARs/PRVs overlap

What is the best strategy?

The planning concept ***changed*** between ICRU 62 and 83 …..

ICRU 62 – edit PTV (even CTV) – fine for CRT

ICRU 83 – ***do not*** edit – better for IMRT

- PTV and PRV now overlap
- A problem for planning
- We need a solution to the dilemma

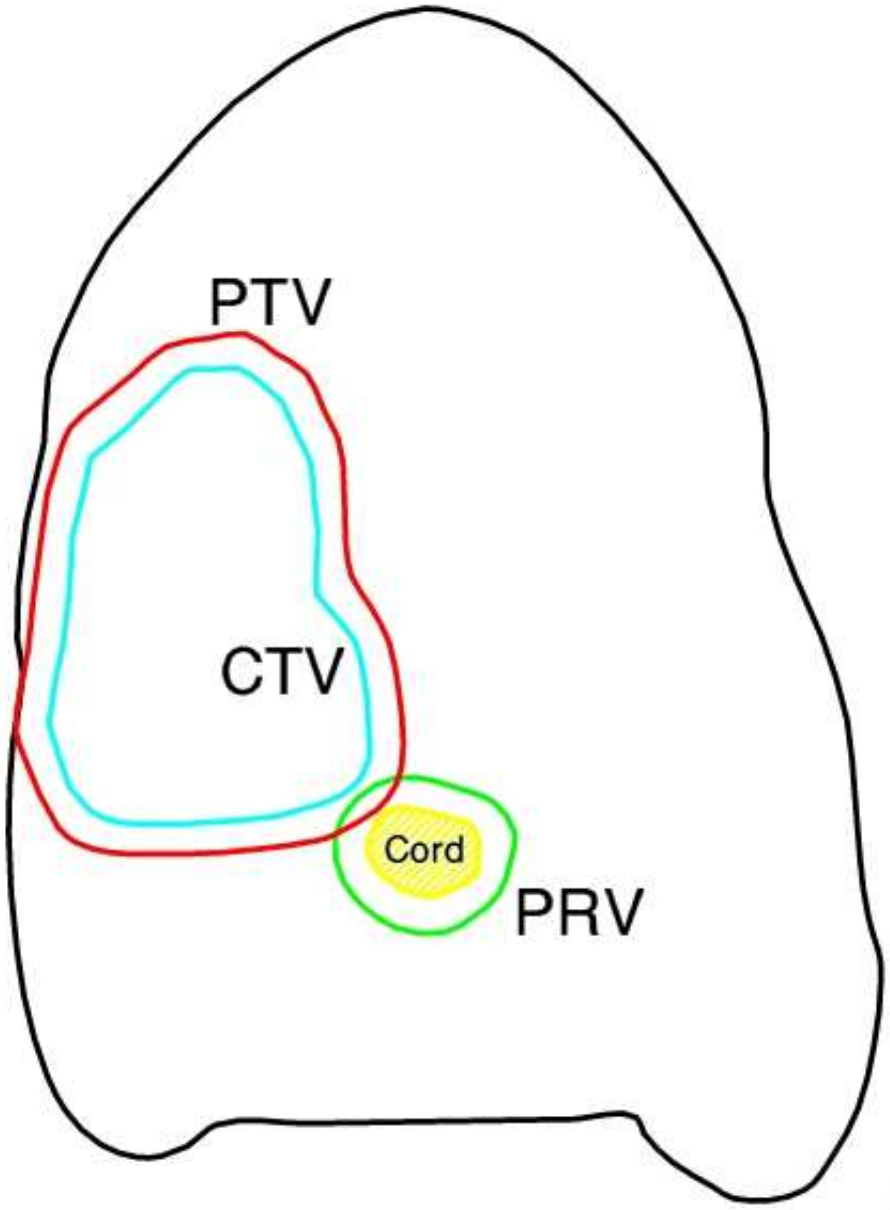

- ICRU 62 recommendation
- OAR would be safe
- Obscures target dose objective

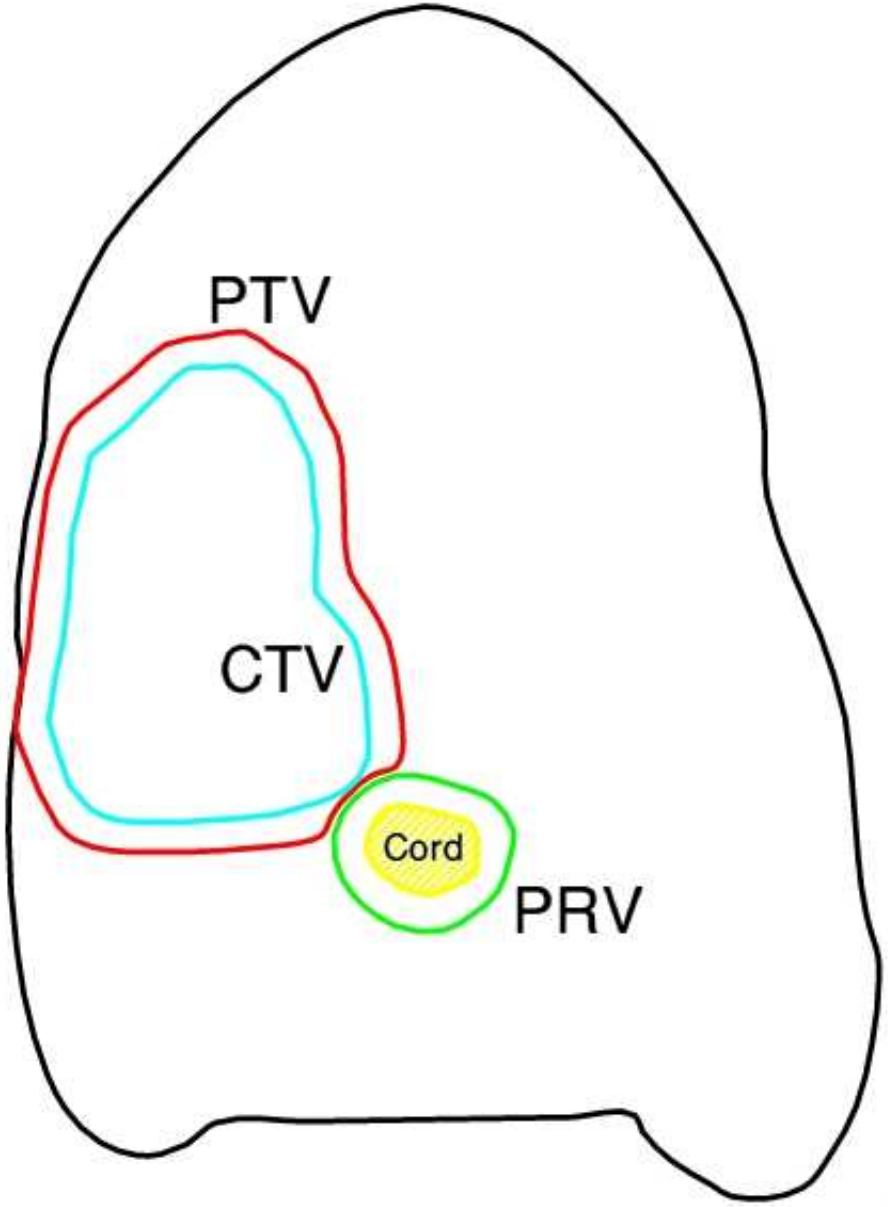

ESTRO School

- ICRU 62 recommendation
- OAR would be safe
- Obscures target dose objective
- Please don't ...

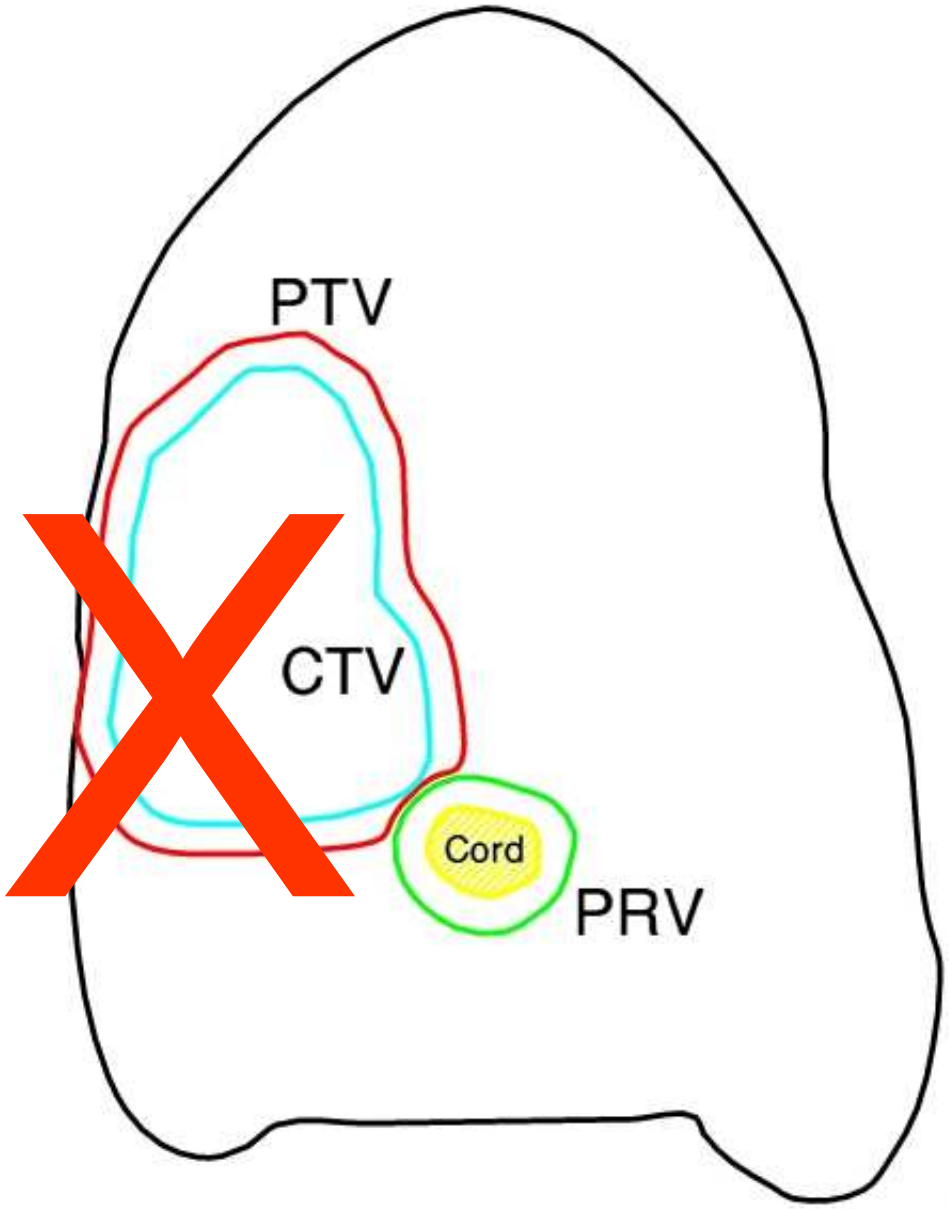

ESTRO School

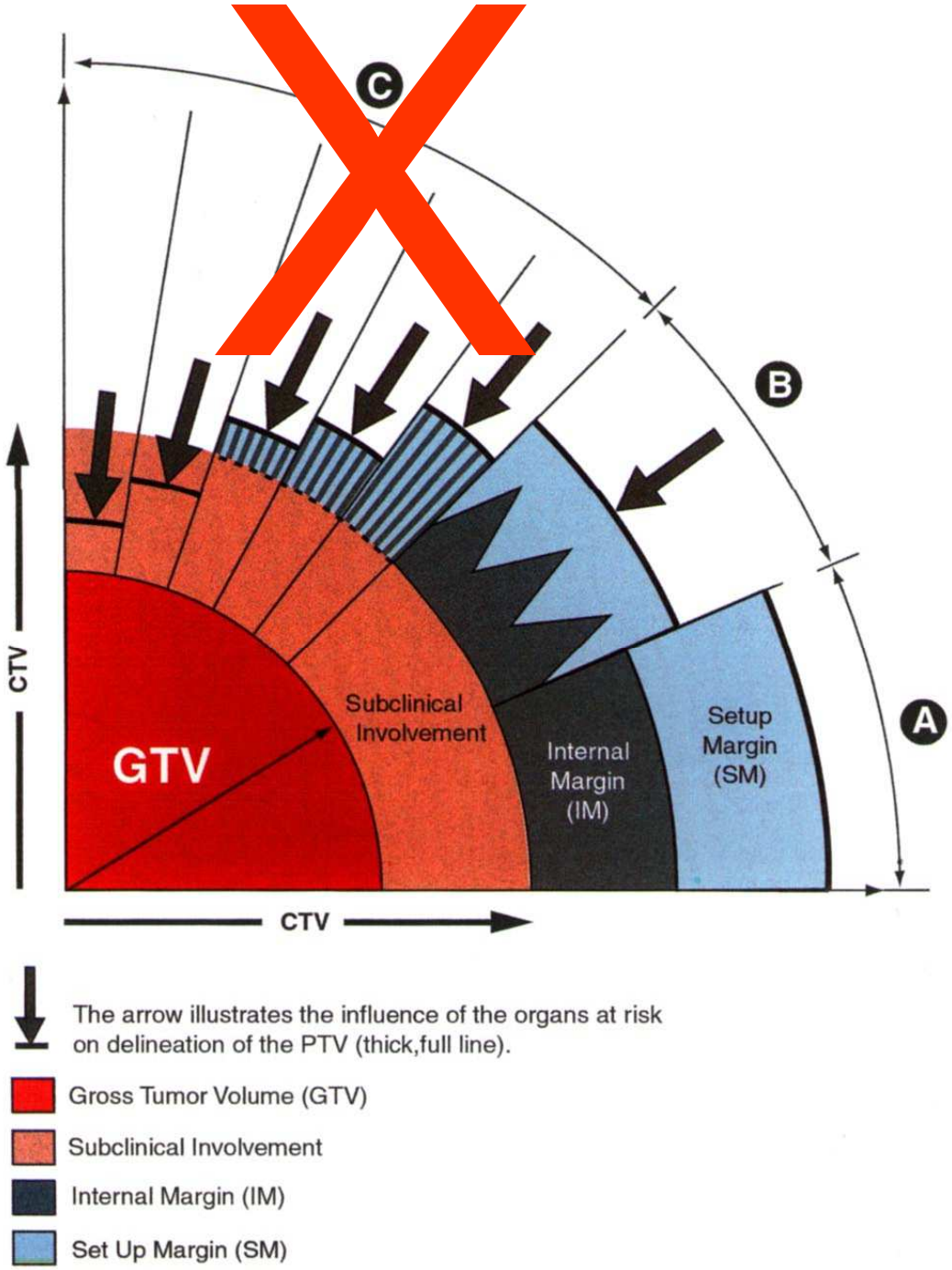

- Fig from ICRU 62 (also in ICRU 71)
- Scenario C not recommended now, in the era of IMRT

ESTRO School

- PTV and PRV now overlap
- IMRT allows variable dose
- Therefore draw what you want
- ***Do not*** modify PTV

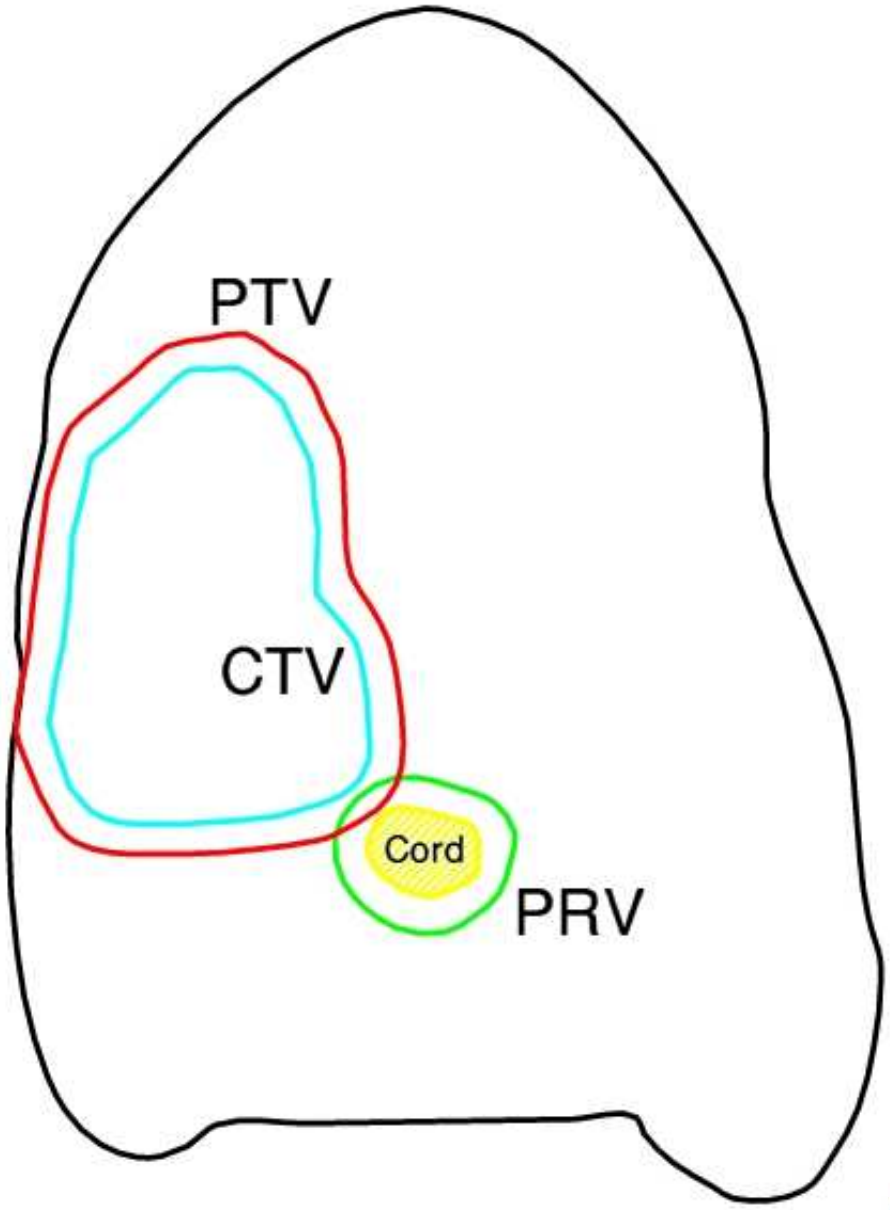

ESTRO School

- ICRU 83 approach for IMRT
- Add 2nd volume avoiding overlap
- Specify priorities and doses

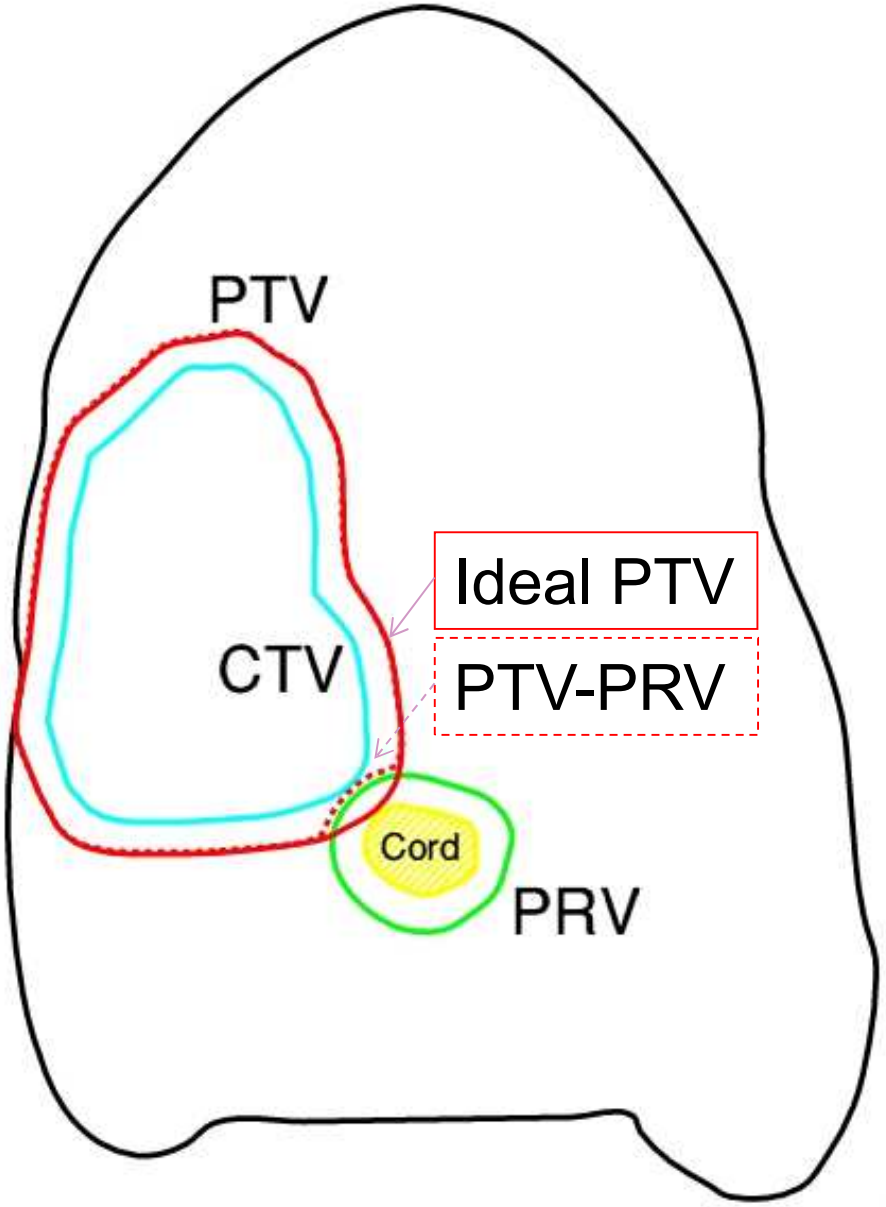

ESTRO School

Target volumes – PTV / PRV

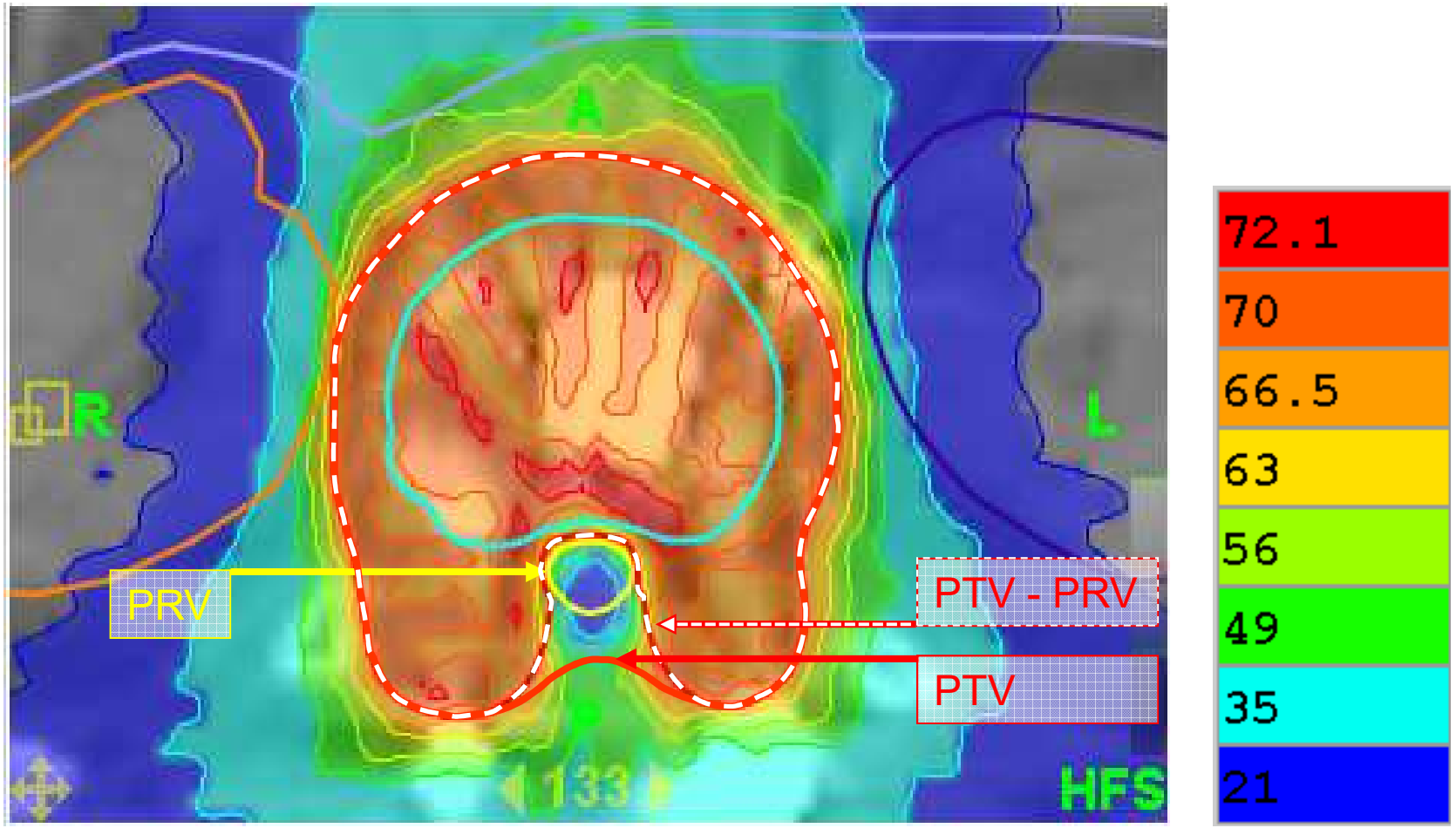

PRV essential here to protect cord (so is IGRT)

Priority PRV > PTV

ESTRO School

Target volumes – overlaps

Overlapping volumes requires:

- Very clear objective setting
- Good communication between clinician & planner
  - Dialogue (i.e. 2 way communication) is recommended !
- Use optimiser to deliver different doses to different parts of the target
- Makes plan evaluation using DVH more difficult

Target volumes – overlaps

From ICRU 83

Review DVHs carefully

Overall, more robust method

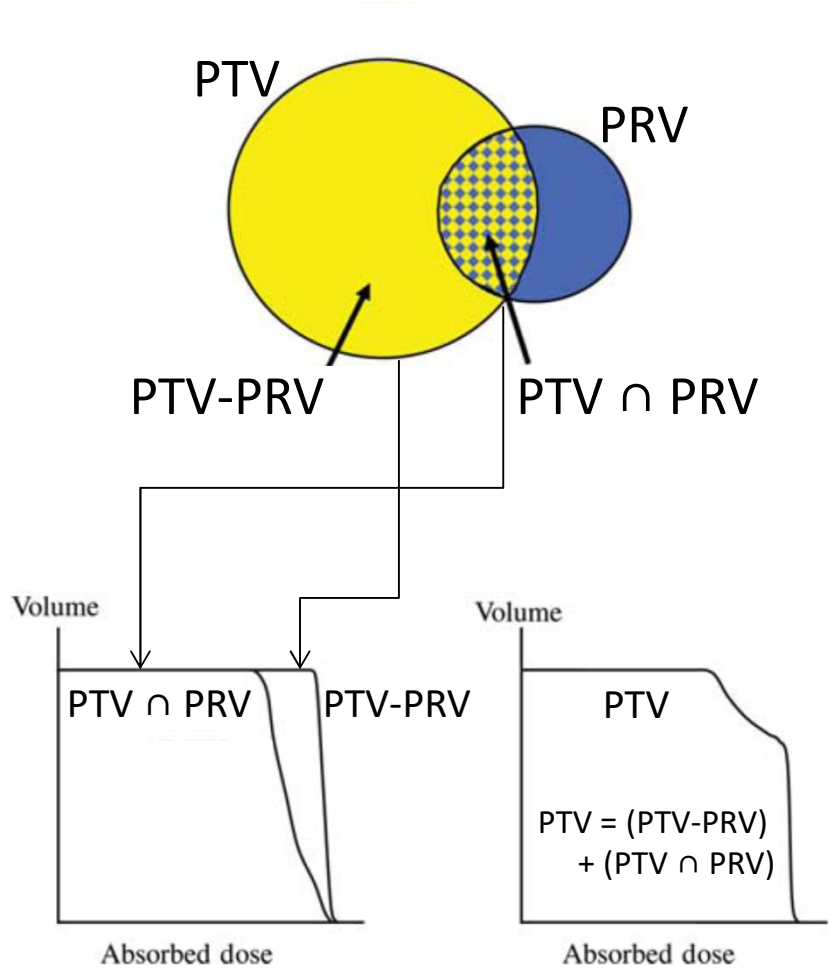



ICRU guidance on planning and prescribing

ICRU guidance

- ICRU 83 specifically dedicated to IMRT
- Recommendations for prescribing changed
- Introduces some specific aspects of reporting of dose to normal tissues

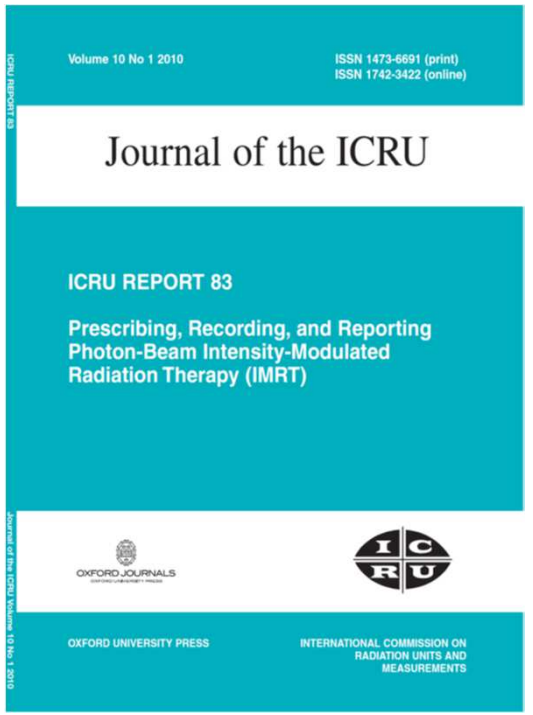

ESTRO School

ICRU guidance

- Advice on dose planning in the build up region or if PTV extends outside the body contour is given

- Concept of adaptive review introduced

  Possible to review dose and dose change during treatment

- Comments on QA given

  Not discussed here

Prescribing

- Key changes in prescribing

Prescribe to ***median dose*** rather than ICRU reference point (≈ isocentre dose)

median dose = $D_{50\,\%}$

= dose to 50% of the volume

Report ***near-maximum*** and ***near-minimum***, rather than actual max & min

Still need to be aware of target coverage

Prescribing

- Specify median dose - $D_{median} = D_{50\,\%}$

  Corresponds best to previous ICRU reference point dose (≈ isocentre dose)

  - Often close to mean dose
  - Not influenced by 'tails' on the DVH
  - Accurately calculated in TPSs

NB useful to add units e.g $D_{50\,\%}$ or $V_{20\,Gy}$

Prescribing

Median dose = $D_{median} = D_{50\ \%}$

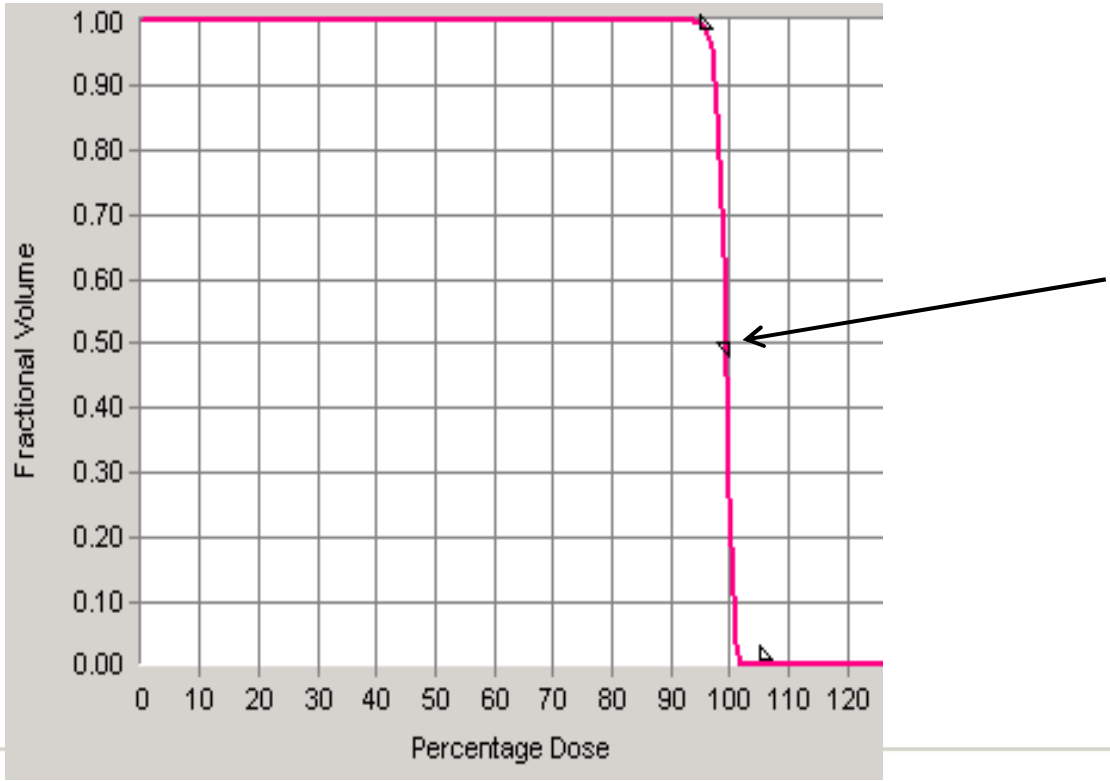

ESTRO School

Prescribing

Prescribing to median dose without some restriction on the slope of the target DVH could allow a shallow slope and low target minimum dose

Need some agreement on minimum acceptable

- At least 99% of the volume ($D_{99\,\%}$) to receive>95% of dose
- At least 98% of the volume ($D_{98\,\%}$) to receive>95% of dose

Limit on maximum also needed, for example

- Less than 1% of the volume >105% of dose

Prescribing

Dose constraints (objectives) for min & max included (and median)

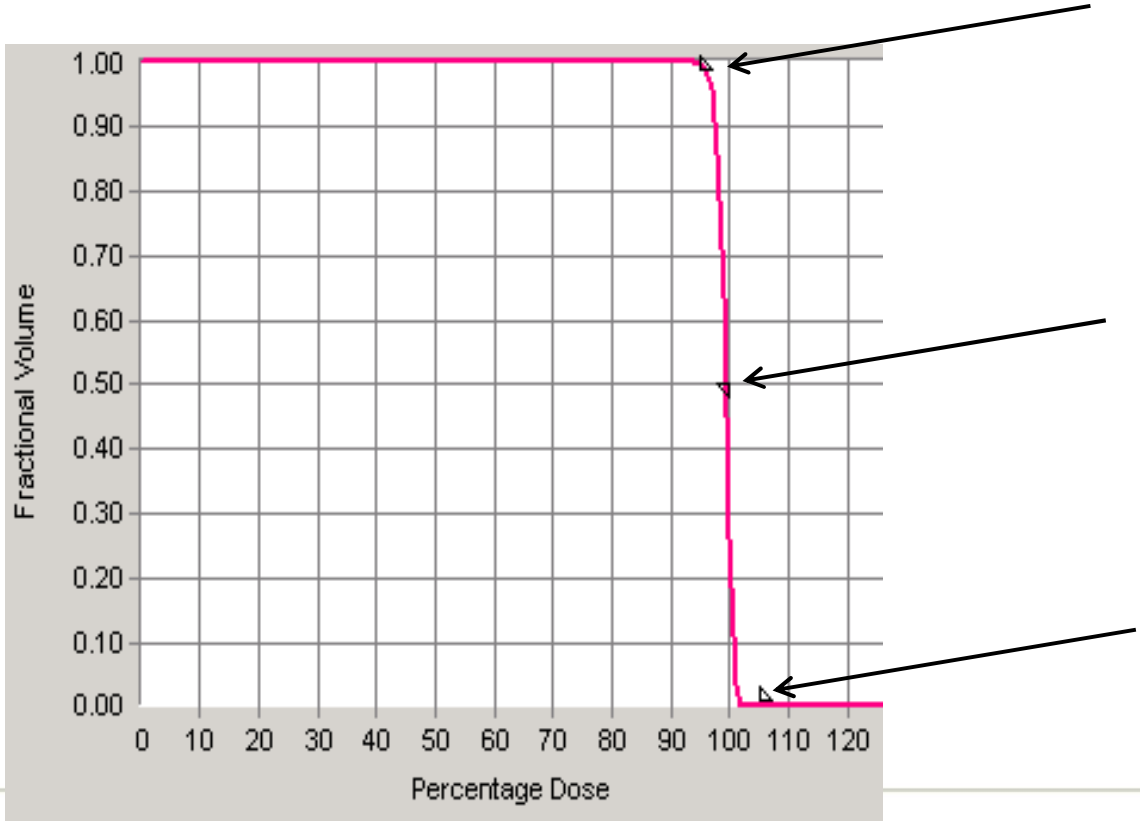

ESTRO School

Prescribing

$D_{99\ \%}$ >95% (of prescription dose)

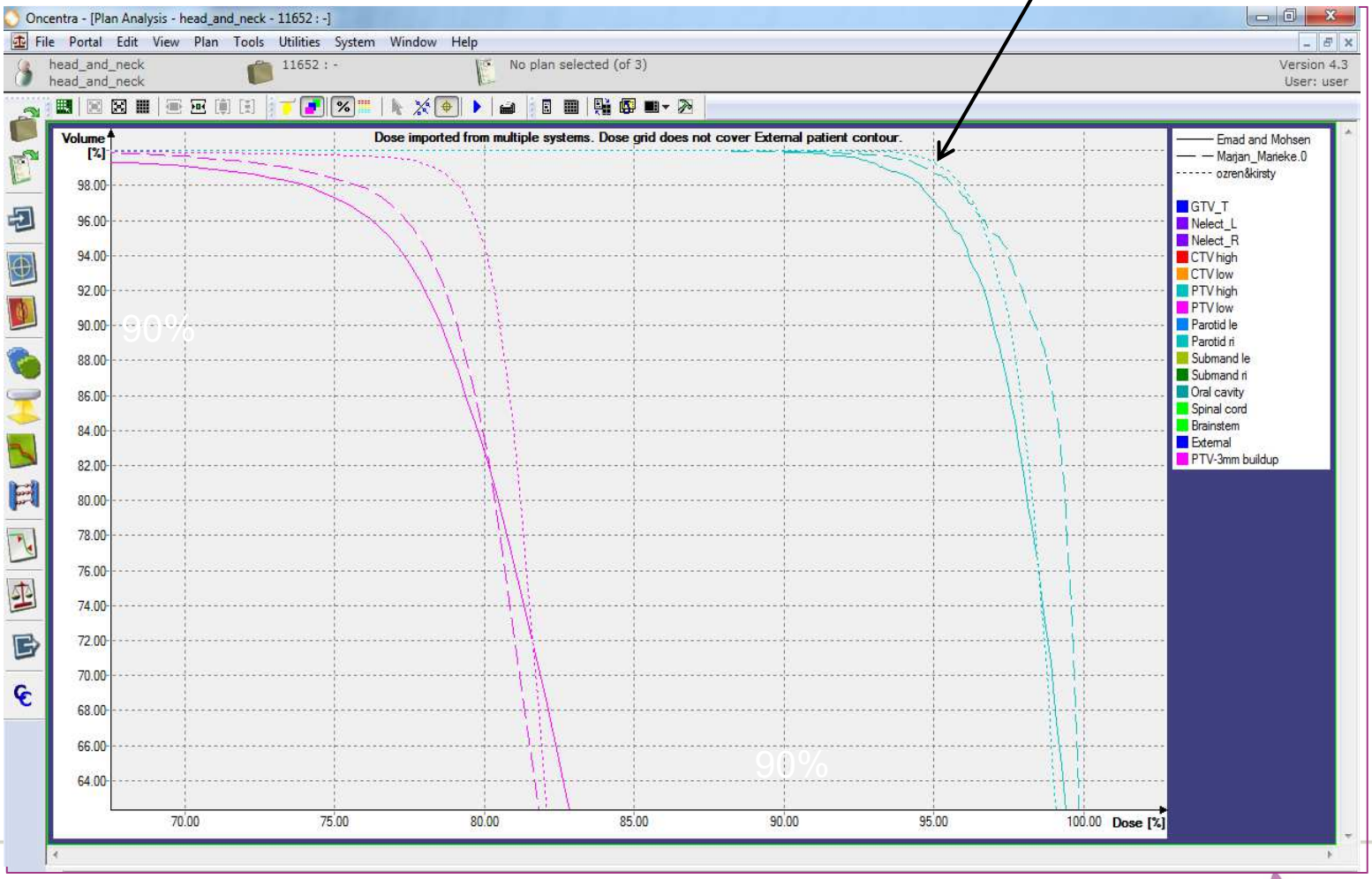

ESTRO School

Prescribing

$D_{99\ \%}$ >95% (of prescription dose)

$V_{95\ \%}$ >99%

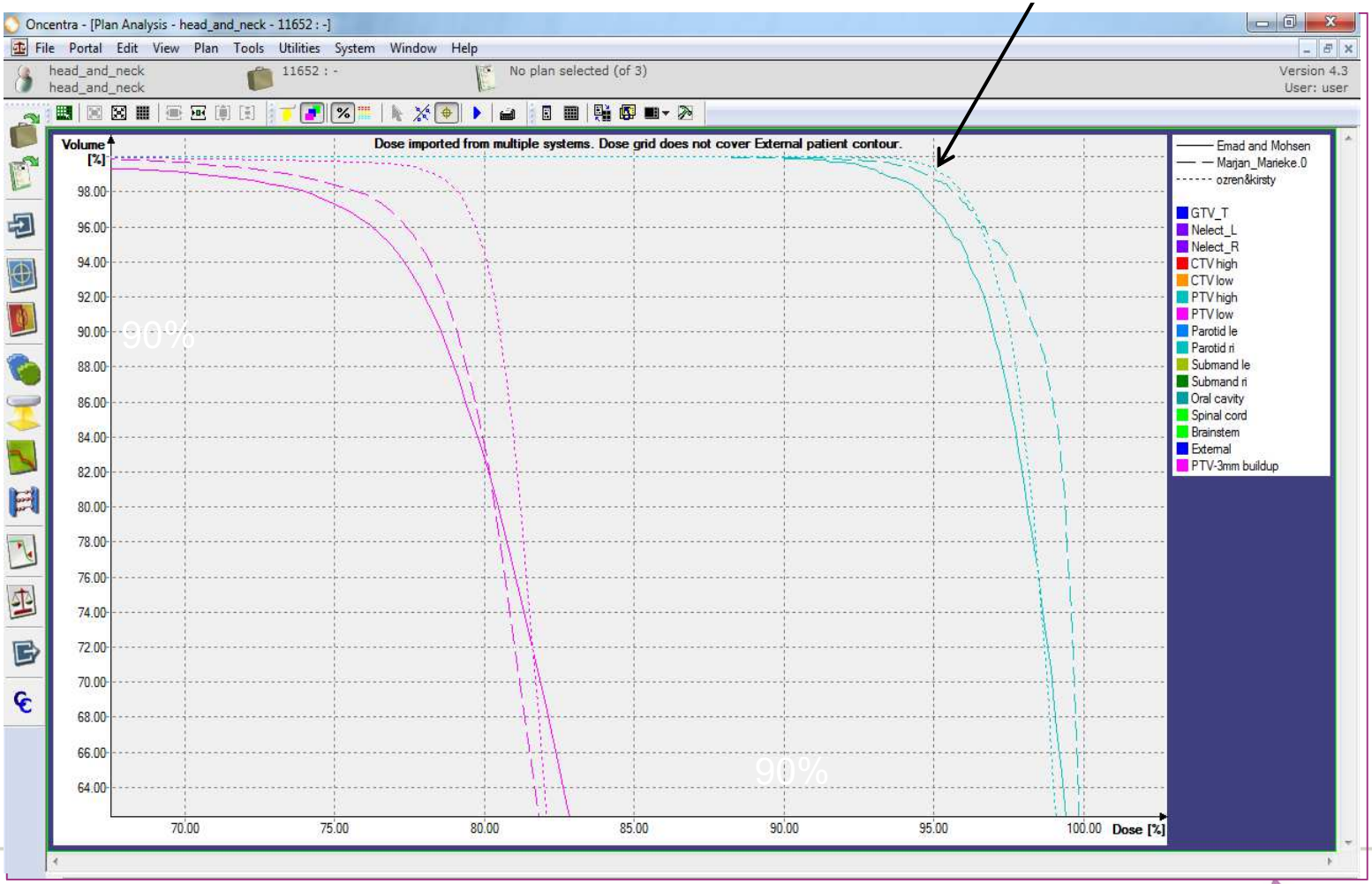

ESTRO School

Prescribing

Dose constraints (objectives) for min & max included (and median)

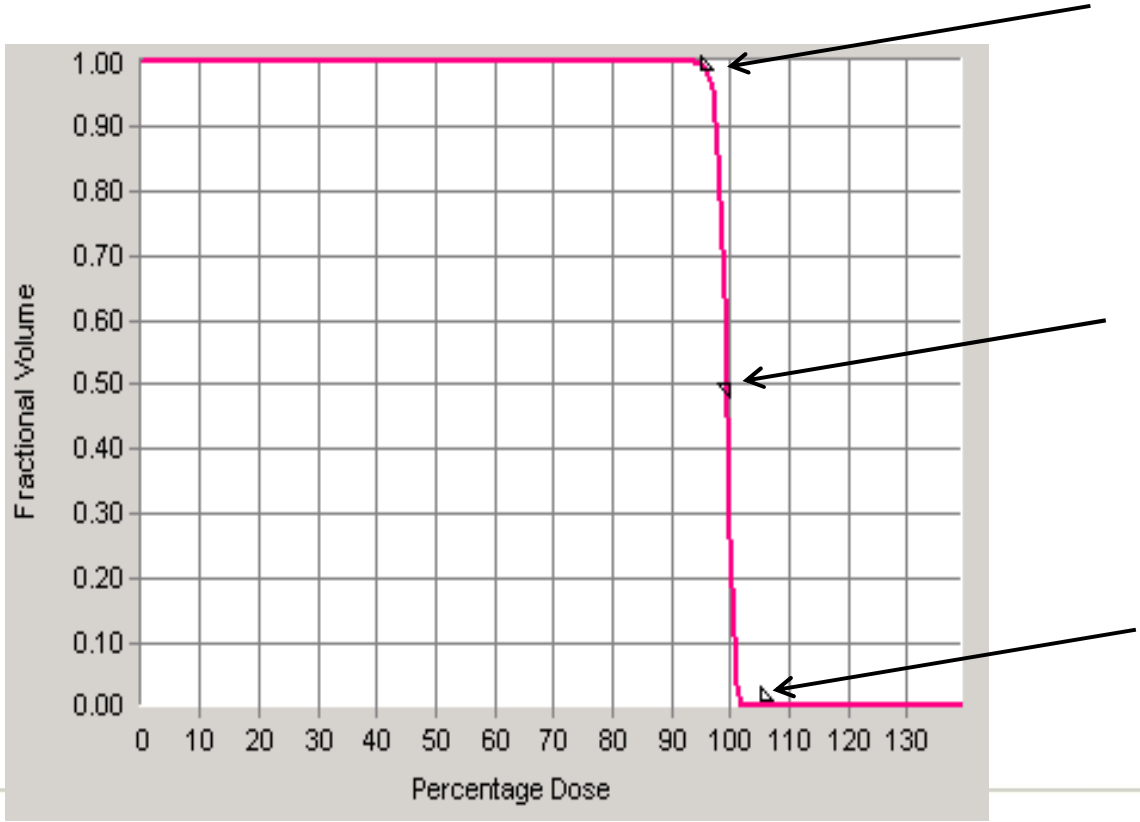

ESTRO School

Prescribing

Dose constraints (objectives) for min & max included (and median)

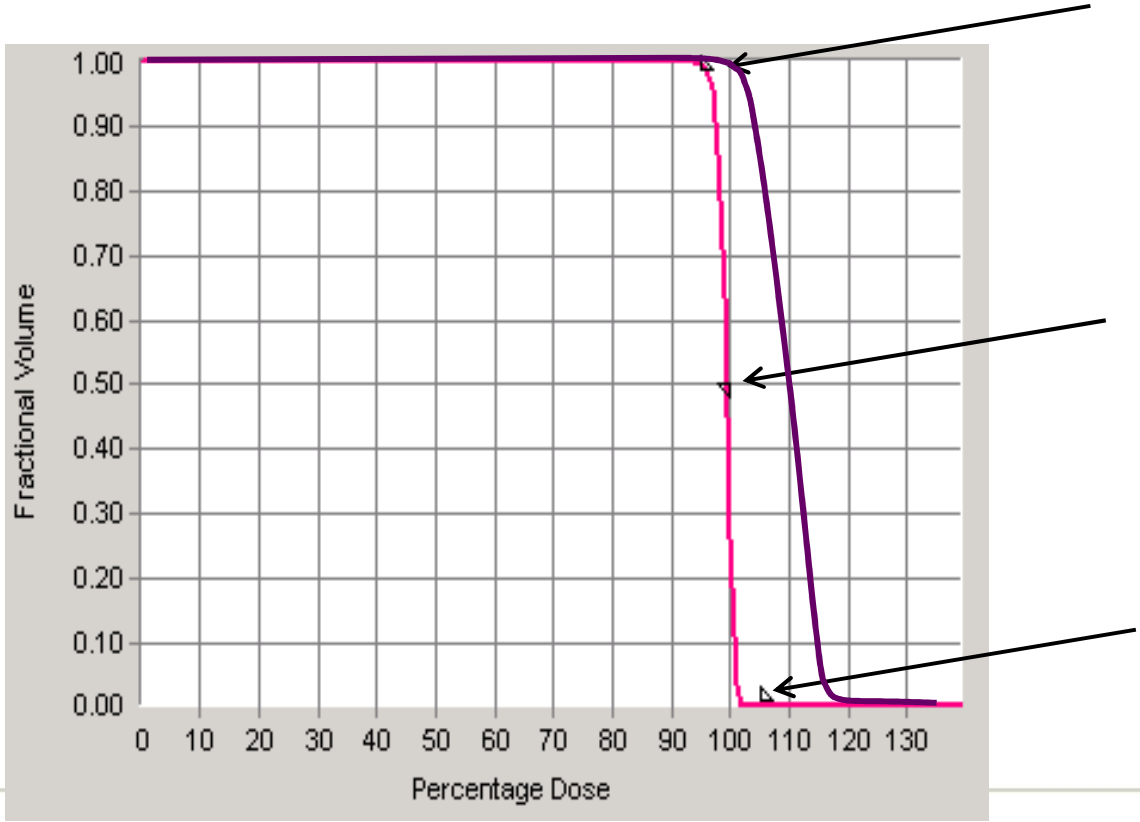

ESTRO School

Prescribing

Dose constraints (objectives) for min & max included (and median)

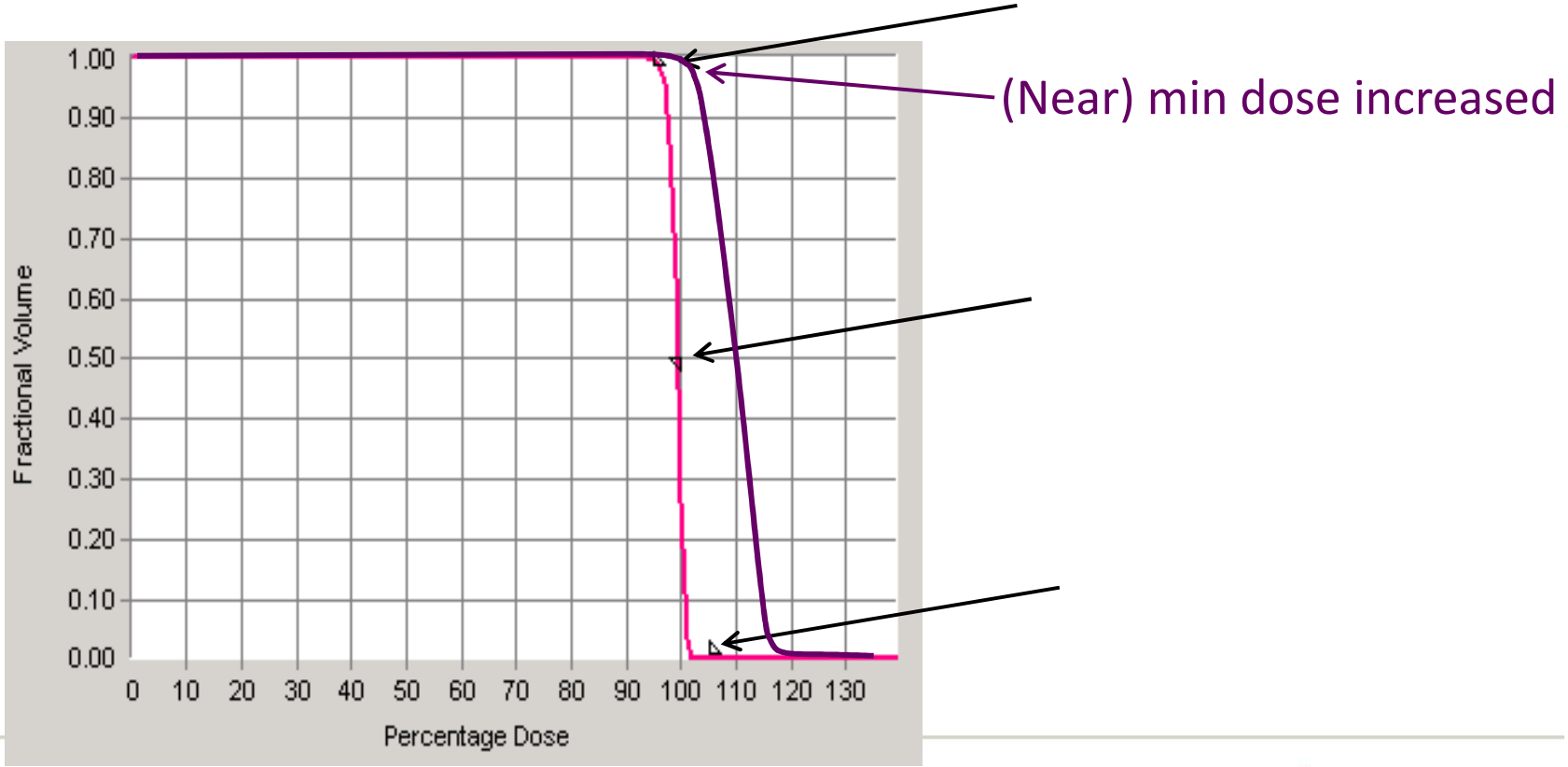

ESTRO School

Prescribing

Dose constraints (objectives) for min & max included (and median)

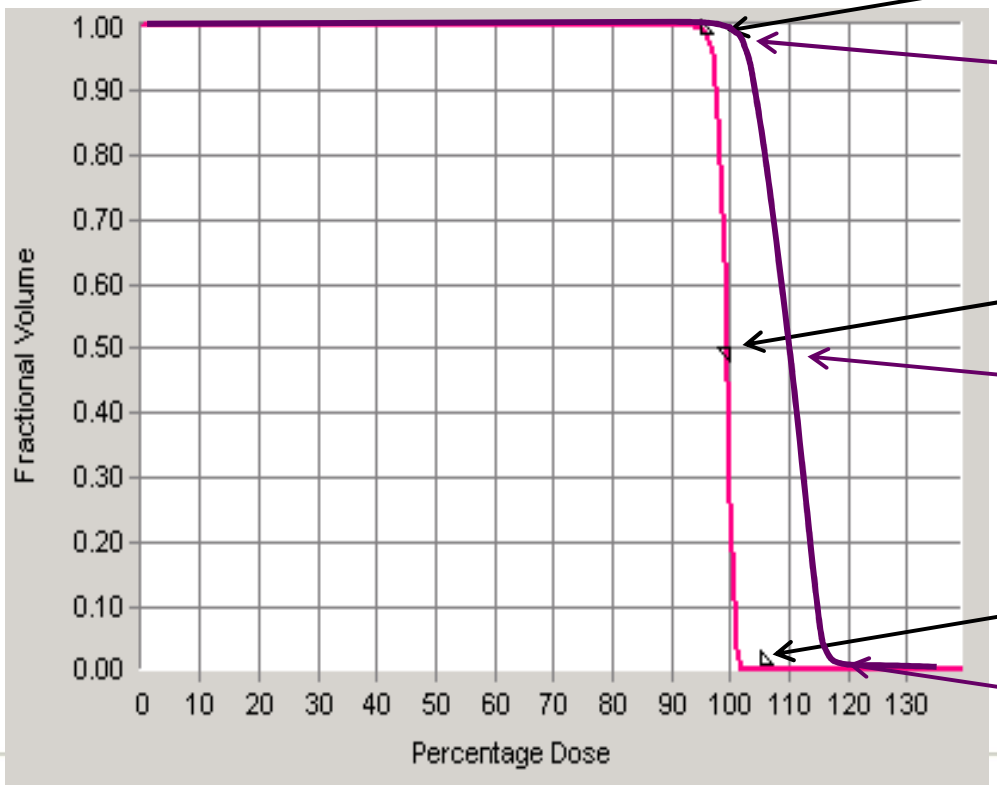

(Near) min dose increased

Median now too high

(Near) max very high

ESTRO School

Prescribing

- Report near-maximum and near-minimum in target volume, rather than actual max & min

  $D_{2\ \%}$ for near-max, $D_{98\ \%}$ for near-min

Prescribing

- Report near-maximum and near-minimum in target volume, rather than actual max & min

  $D_{2\ \%}$ for near-max, $D_{98\ \%}$ for near-min

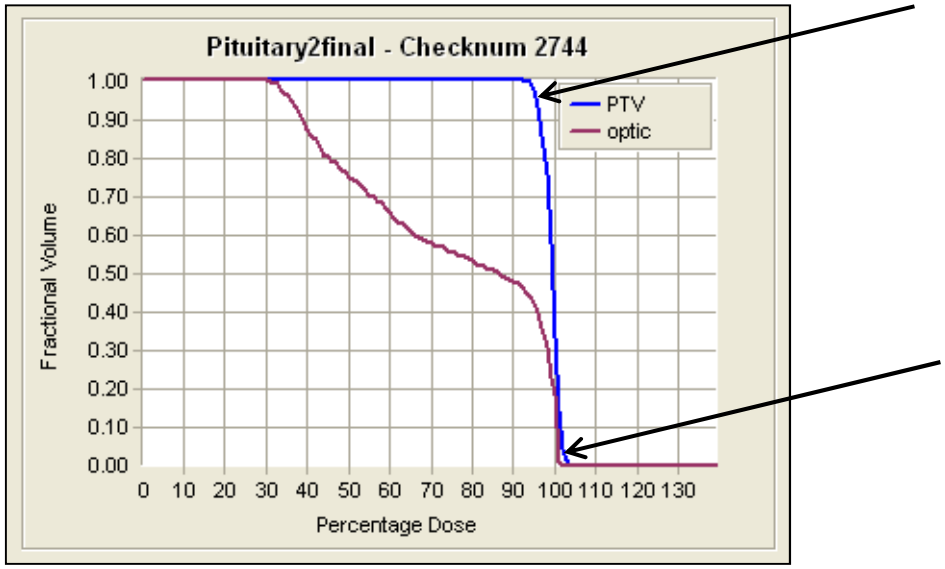

Prescribing

- Clinical relevance of minimum (near-min) dose point may depend on its position within the PTV

  Minimum dose in edge of PTV may be of marginal significance

  Minimum dose in centre (in GTV) may be rather important

Prescribing

- Concept of using dose volume histograms for dose specification is introduced in ICRU 83

  Dose-volume prescribing in place of dose

  Dose-at-a-point specification is retained for purposes of comparison

- Contains worked examples, which may be helpful

Prescribing

- Add volume parameters where relevant
  e.g. $V_{20\ Gy}$ for lung

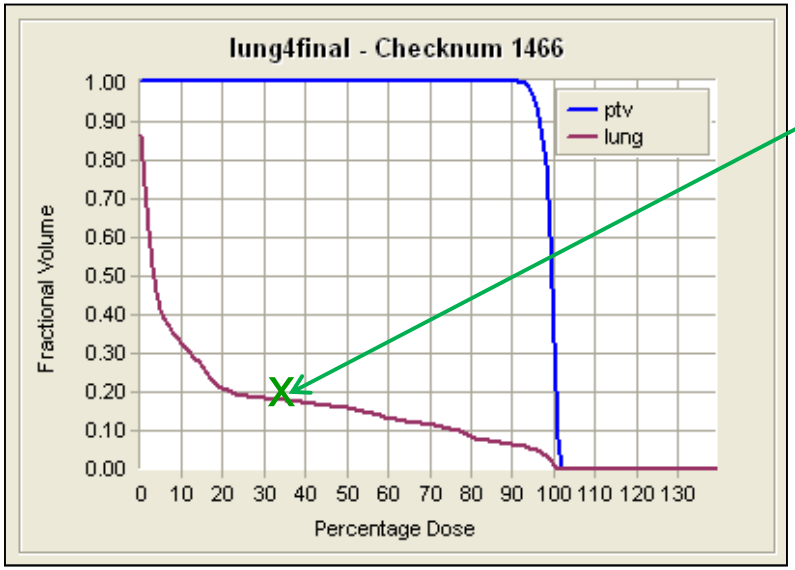

$V_{20\ Gy}$

Relates to clinical outcome

NB $V_{20\ Gy} = V_{33\ \%}$ (for 60 Gy)

Lung doses

- 2 plans compared
  - IMRT : ‘CRT’
- Mean lung dose same = 9 Gy
- DVH different
- In reporting, the DVH (or some points on it) may be useful

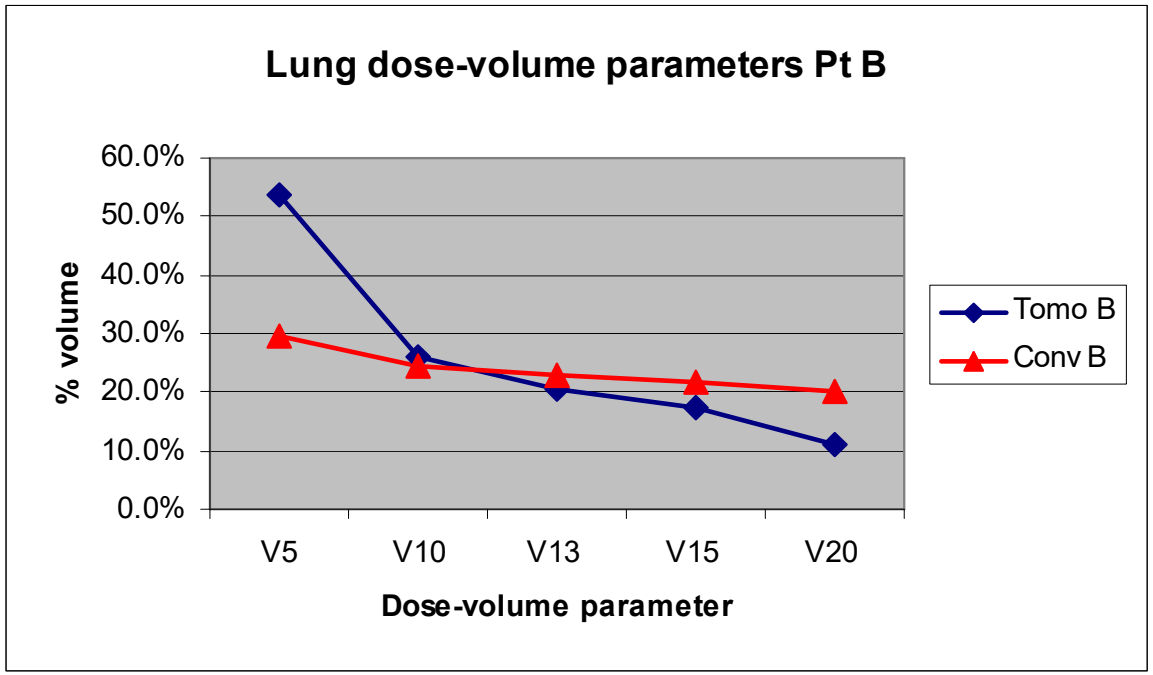

ESTRO School

Prescribing

- For serial organs, maximum (near-max) dose is relevant parameter

  ICRU recommends $D_{2\,\%}$ rather than D_{Max} ($D_{0\,\%}$)

  Overcomes problem of defining (knowing!) what volume of the structure is important

  Note that $D_{2\,\%}$ not validated (yet); caution given !

  But … it is logical

  However, effect will depend on total volume of structure

  In gynae brachtherapy often use $D_{2\,cm^3}$

ICRU guidance

- ICRU 83 mentions the possibility of adding some additional parameters relating to dose
- Optional, but may become interesting

Homogeneity Index & Conformity Index

EUD – Equivalent Uniform Dose

TCP, NTCP

Probability of uncomplicated tumour control (PUC)

Remaining Volume at Risk (RVR)

Remaining Volume at Risk (RVR)

- Remaining Volume at Risk risk assessment of the dose delivered to a patient
- To assess the risk of second cancers the whole patient volume must be considered
  - PTV
  - PRV
  - RVR
- Can potentially influence the choice of radiotherapy delivery – eg. IMRT vs dynamic arc therapy

Take home messages

- GTV is tumour you can ***See - Feel – Image***
  - Outline what you see!

- CTV - contains GTV and/or sub-clinical disease
  - Tumour ***cannot*** be seen or imaged
  - Can be individualised to anatomy

- PTV is a geometric volume
  - Ensures prescription dose is delivered to the CTV
  - Includes systematic + random error components

Take home messages

- Add PRV around CNS structures if giving high doses
- Overlaps can occur between PTV and OAR (or PRV)
  - Do ***not*** edit
- Use clear protocols & follow them
- Assess the treatment to see if adaptation required

Radiation oncology

ESTRO School

From uncertainties to margins

Peter Remeijer

NETHERLANDS CANCER INSTITUTE
ANTONI VAN LEEUWENHOEK

Introduction

- Geometrical uncertainties are unavoidable
- Many are patient related
- What types of errors do we get?
- How large a margin do we need?

ANTONI VAN LEEUWENHOEK

Some examples

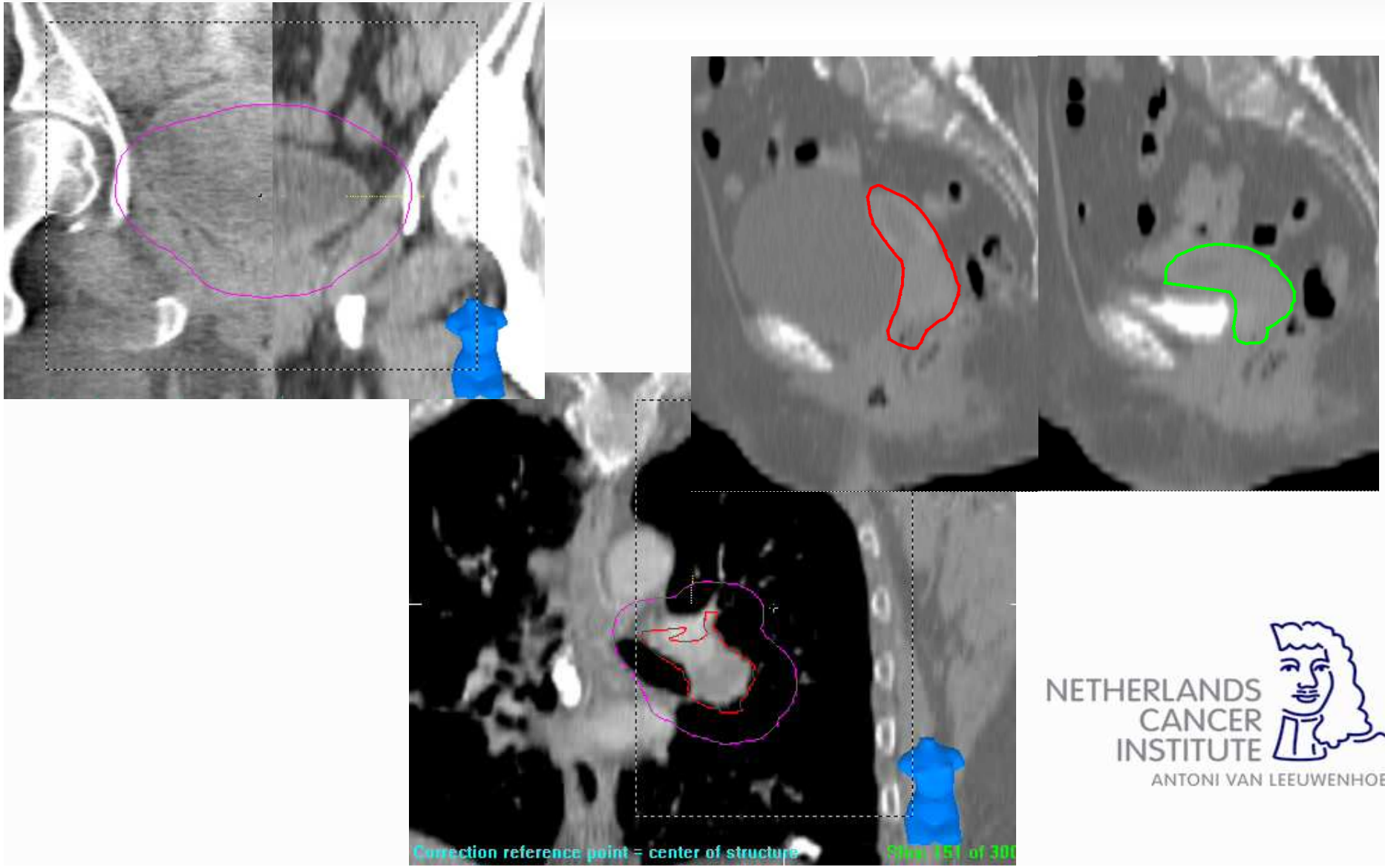

NETHERLANDS CANCER INSTITUTE
ANTONI VAN LEEUWENHOEK

The basics

The radiotherapy chain

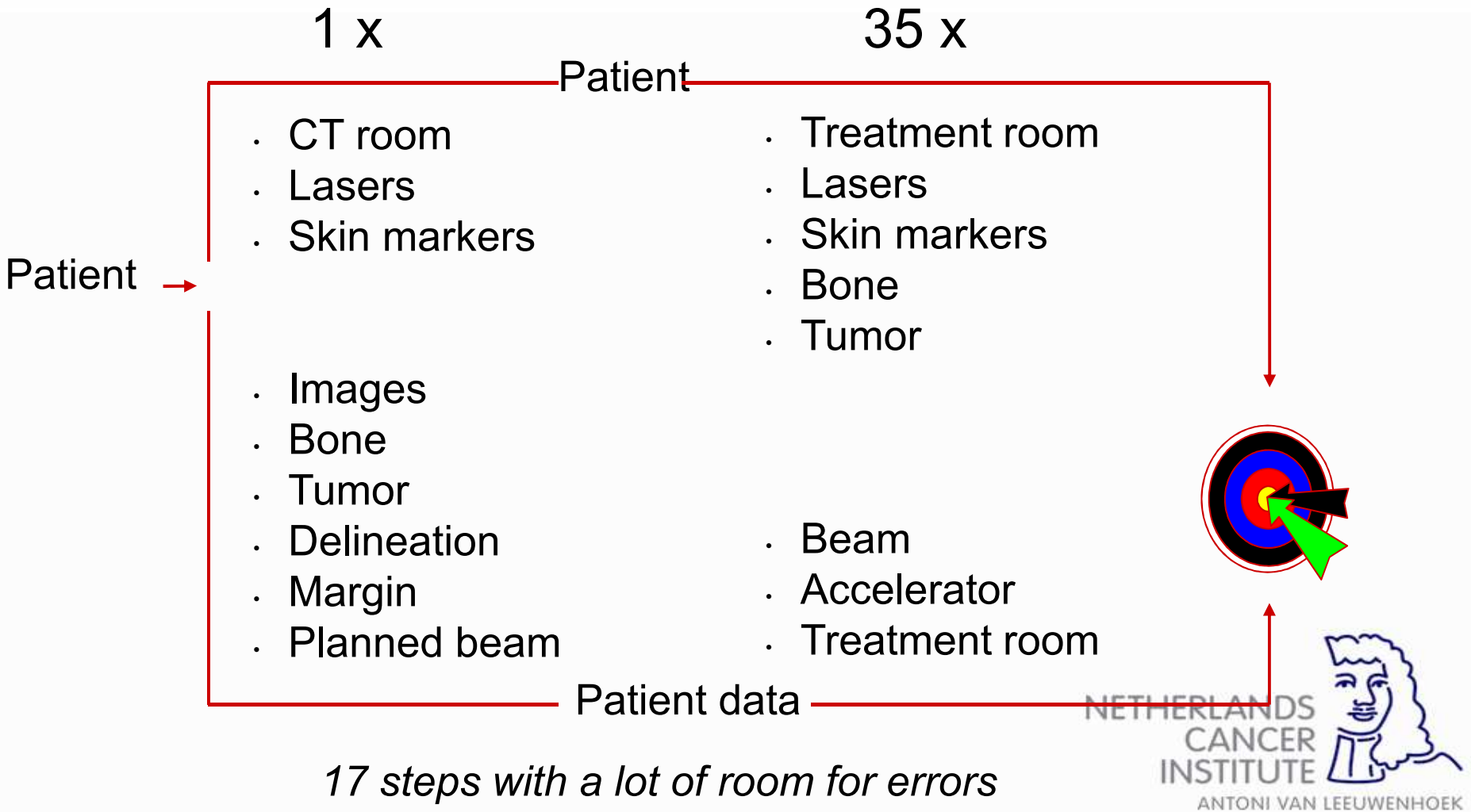

17 steps with a lot of room for errors

NETHERLANDS CANCER INSTITUTE
ANTONI VAN LEEUWENHOEK

Geometrical uncertainties

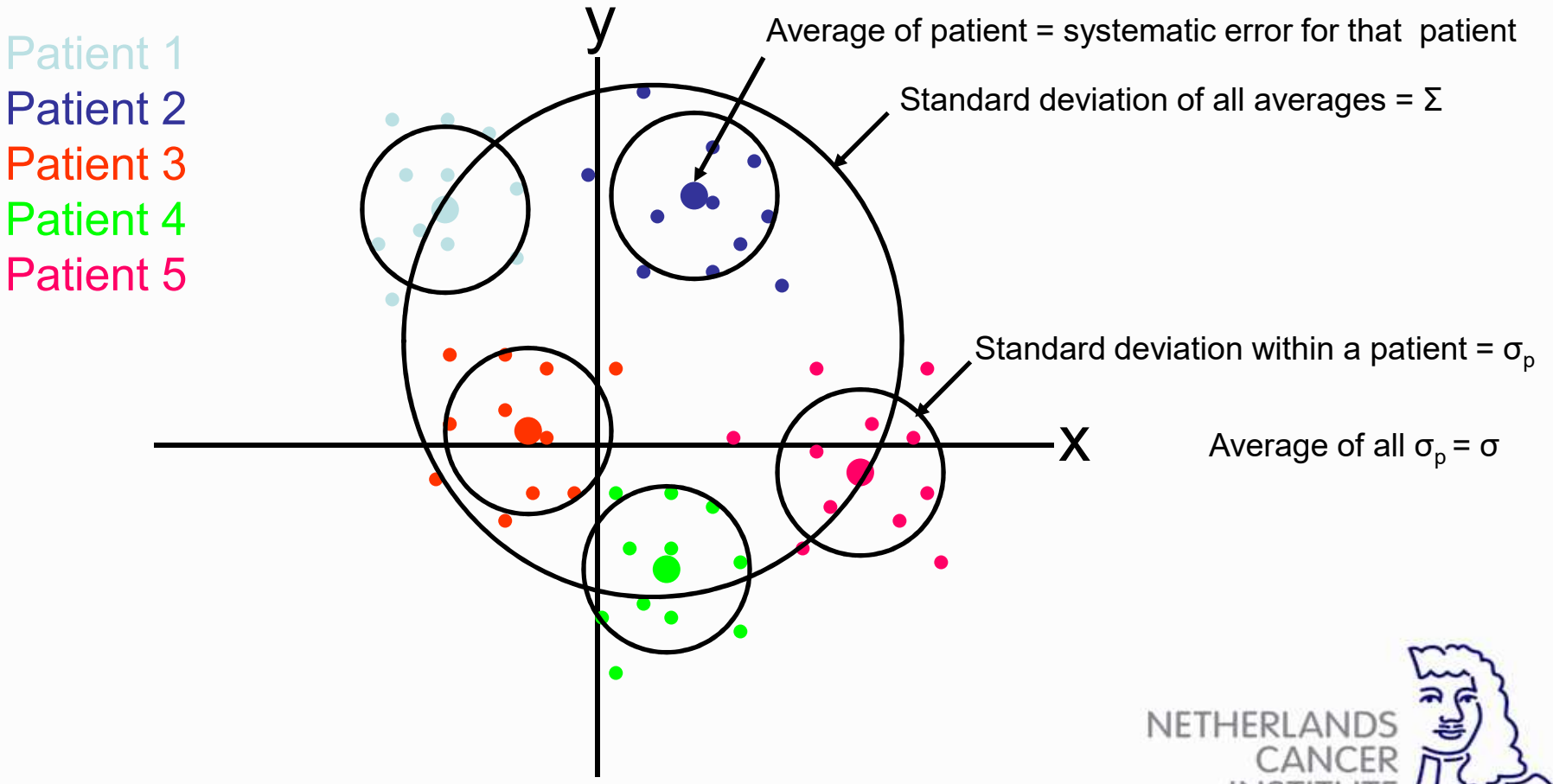

NETHERLANDS CANCER INSTITUTE
ANTONI VAN LEEUWENHOEK

Geometrical uncertainties

Patient 1
Patient 2
Patient 3
Patient 4
Patient 5

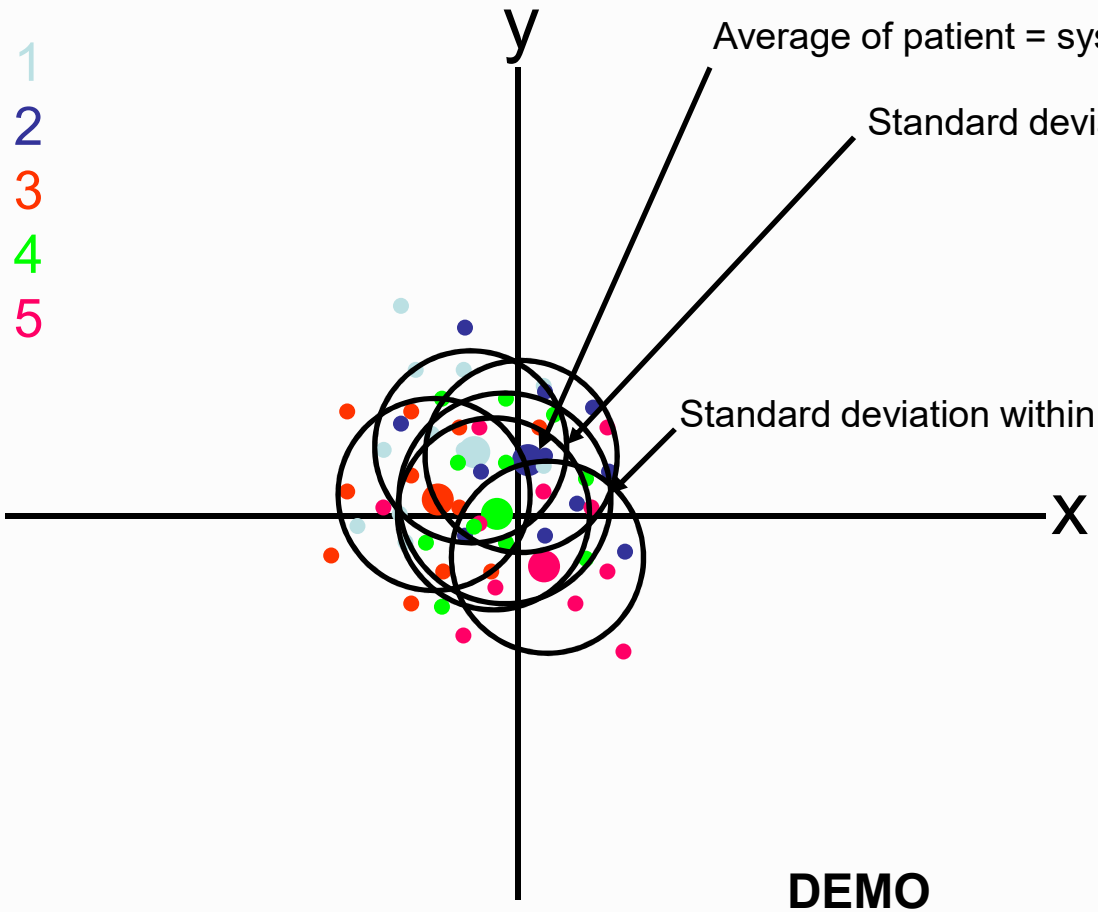

Average of patient = systematic error for that patient

Standard deviation of all averages = Σ

Standard deviation within a patient = σ_p

Average of all σ_p = σ

DEMO

NETHERLANDS CANCER INSTITUTE
ANTONI VAN LEEUWENHOEK

Effect of geometrical errors

Random errors (σ) **blur** the cumulative dose distribution

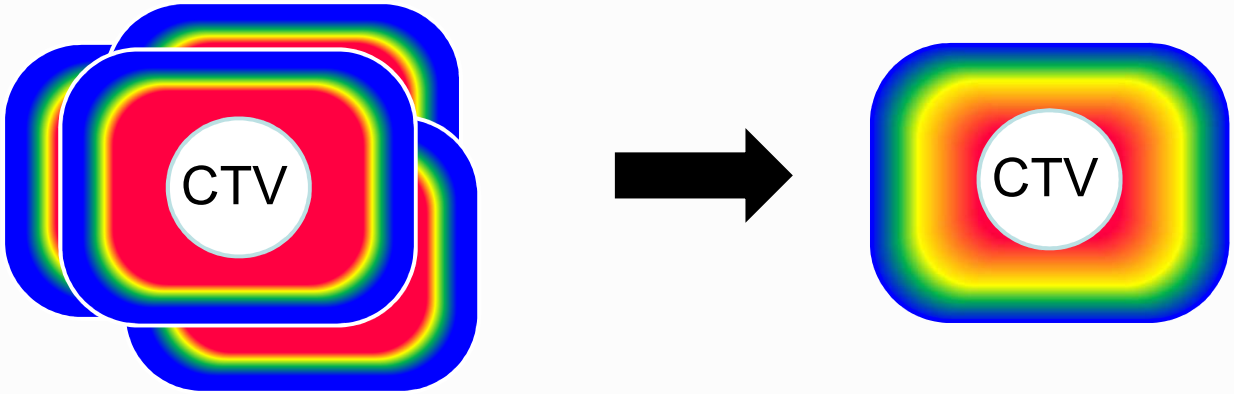

Single fraction doses with random shifts *All fraction doses added*

Systematic errors (Σ) **shift** the cumulative dose distribution

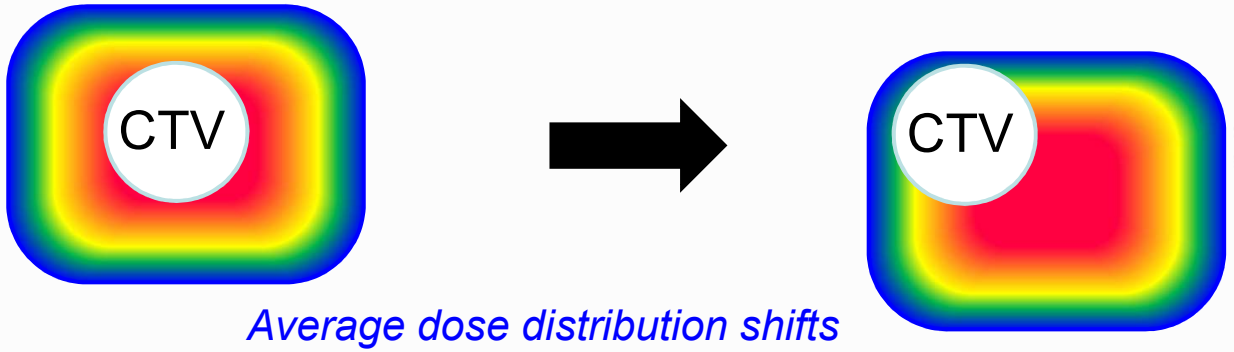

Average dose distribution shifts

NETHERLANDS CANCER INSTITUTE
ANTONI VAN LEEUWENHOEK

Geometrical uncertainties

- Systematic
  - Same for whole treatment
  - Shifts the dose distribution
  - May be different for each patient but the same for one patient
  - Quantified with standard deviation Σ
- Random
  - Different every day
  - Some patients may have larger variations from day to day than others
  - Blurs the dose distribution
  - Quantified with standard deviation σ

NETHERLANDS CANCER INSTITUTE
ANTONI VAN LEEUWENHOEK

Many varieties

- Translational errors
- Rotational errors
- Shape changes



But also different sources!

Source	Systematic	Random	Solution
Delineation	1-?? Mm	-	Multiple modalities
Setup	1-5 mm	1-5 mm	Portal imaging
Organ motion	<1-50 mm	<1-50mm	Markers Repeat CT

And all come as translations / rotations / deformations!

NETHERLANDS CANCER INSTITUTE
ANTONI VAN LEEUWENHOEK

Examples of geometrical uncertainties

Delineation variation

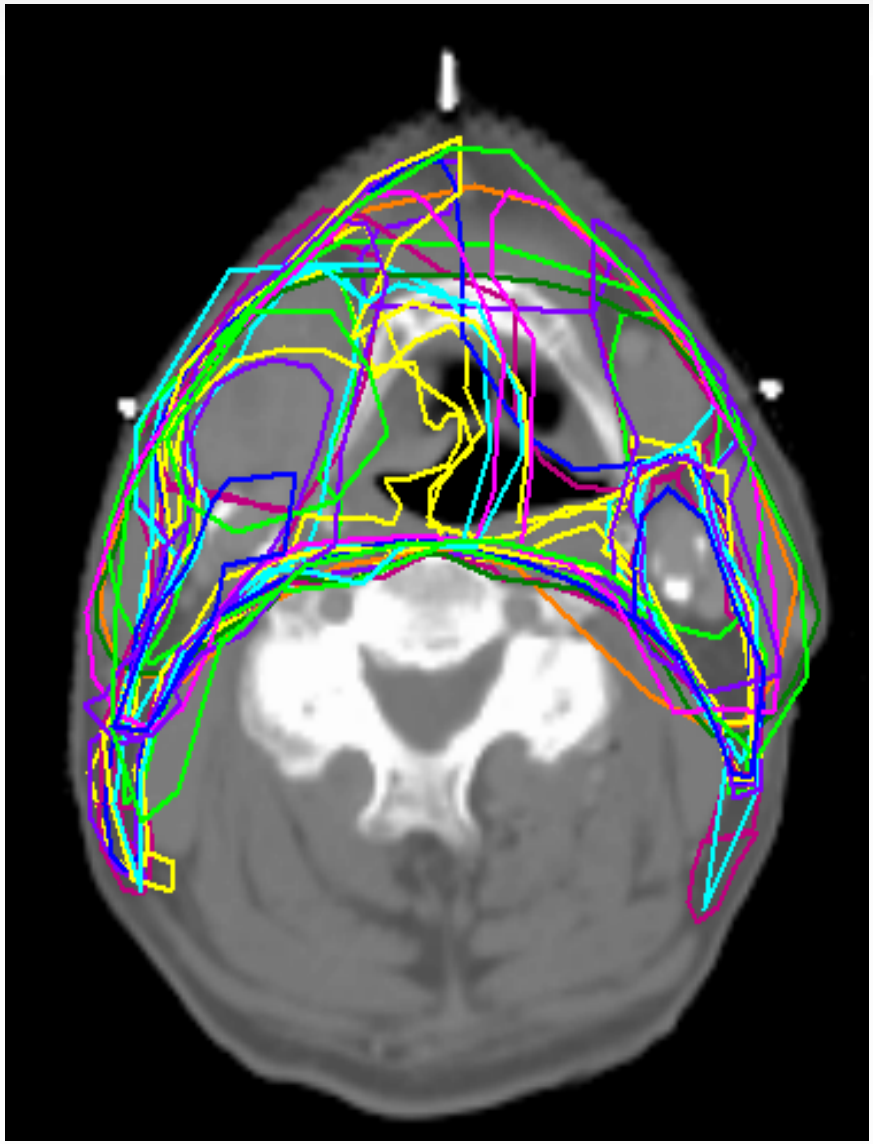

- Previous TVD course
- Individual participants

NETHERLANDS CANCER INSTITUTE
ANTONI VAN LEEUWENHOEK

back

Prostate motion

- Large amount of air in rectum during planning scan
- Not present during treatment

Bladder filling changes

- Bladder volume in one of the CBCT scans is considerably larger than in most other CBCT scans and the planning CT

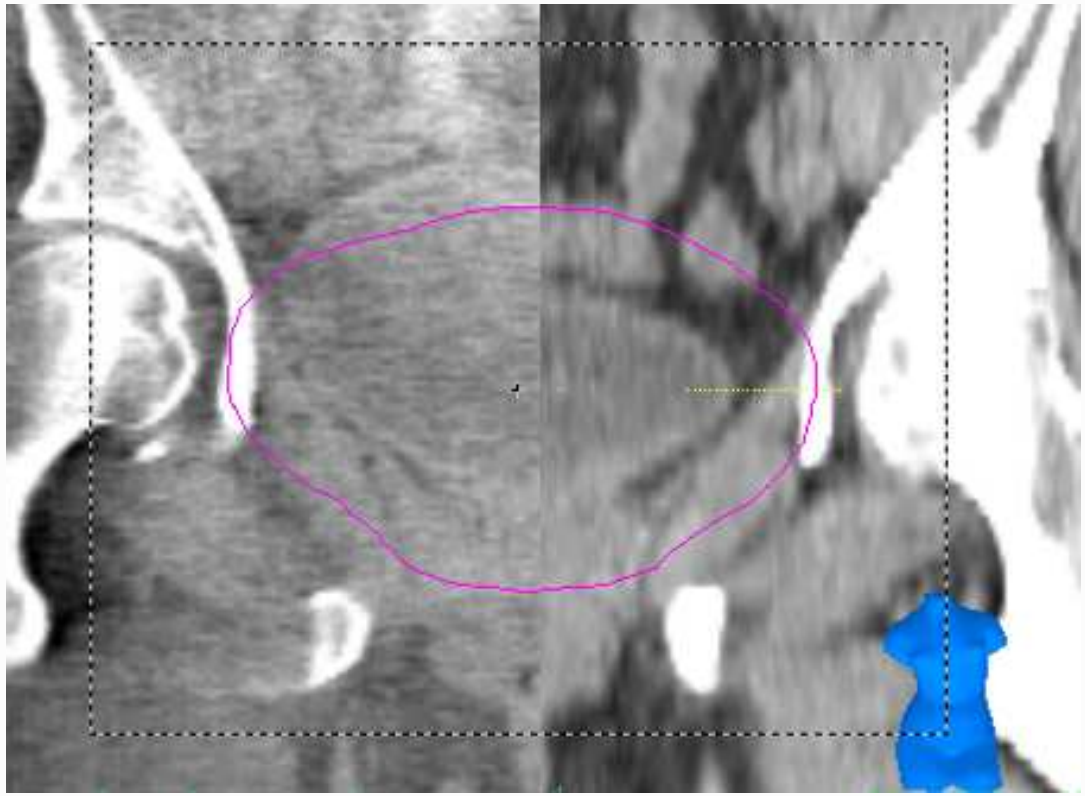

NETHERLANDS CANCER INSTITUTE
ANTONI VAN LEEUWENHOEK

So how do we determine these errors?

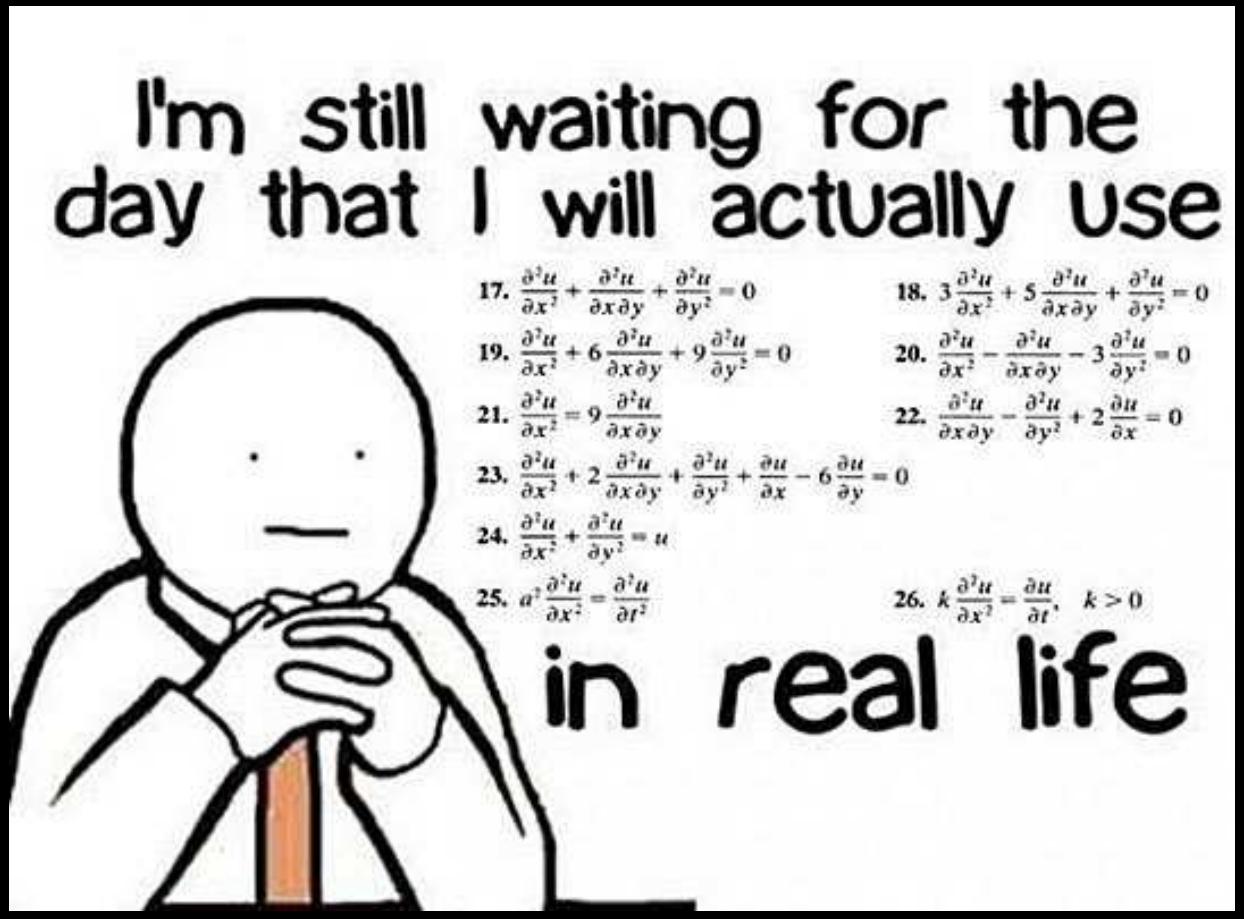

Determining the uncertainties

- Imaging!

HERLANDS CANCER INSTITUTE
ANTONI VAN LEEUWENHOEK

Determining the uncertainties

- We can image the patient from fraction to fraction and analyze the geometrical changes

- Image tumor

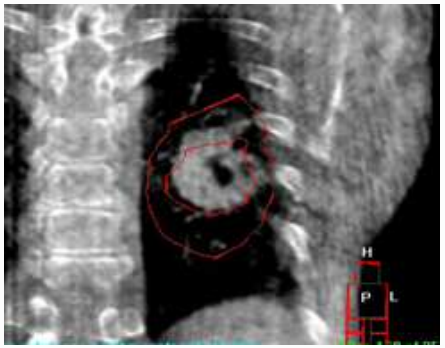

- Use surrogates
  - Fiducials
  - Bony anatomy (margin for organ motion!)

NETHERLANDS CANCER INSTITUTE
ANTONI VAN LEEUWENHOEK

Determining the uncertainties

- Register bony anatomy → Setup error
- Register tumor position → Organ motion
- Analyse re-delineation → Delineation variability

NETHERLANDS CANCER INSTITUTE
ANTONI VAN LEEUWENHOEK

Margins

How do we determine the PTV margin?

- Effect of random and systematic errors on the dose distribution is different

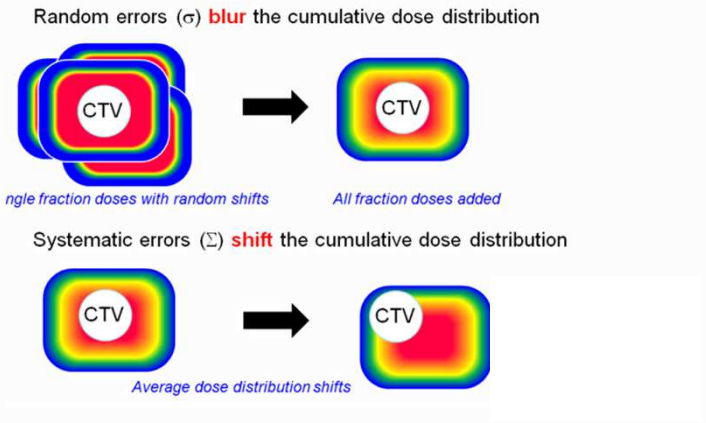

→ We need a separate approach!

NETHERLANDS CANCER INSTITUTE
ANTONI VAN LEEUWENHOEK

Margins for random errors

Random errors (σ) blur the cumulative dose distribution

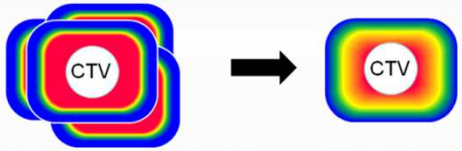

- Random errors <u>blur</u> the dose distribution
  - Translations : Convolution dose with error distribution
  - Rotations : Convolution dose with error distribution (Bel)

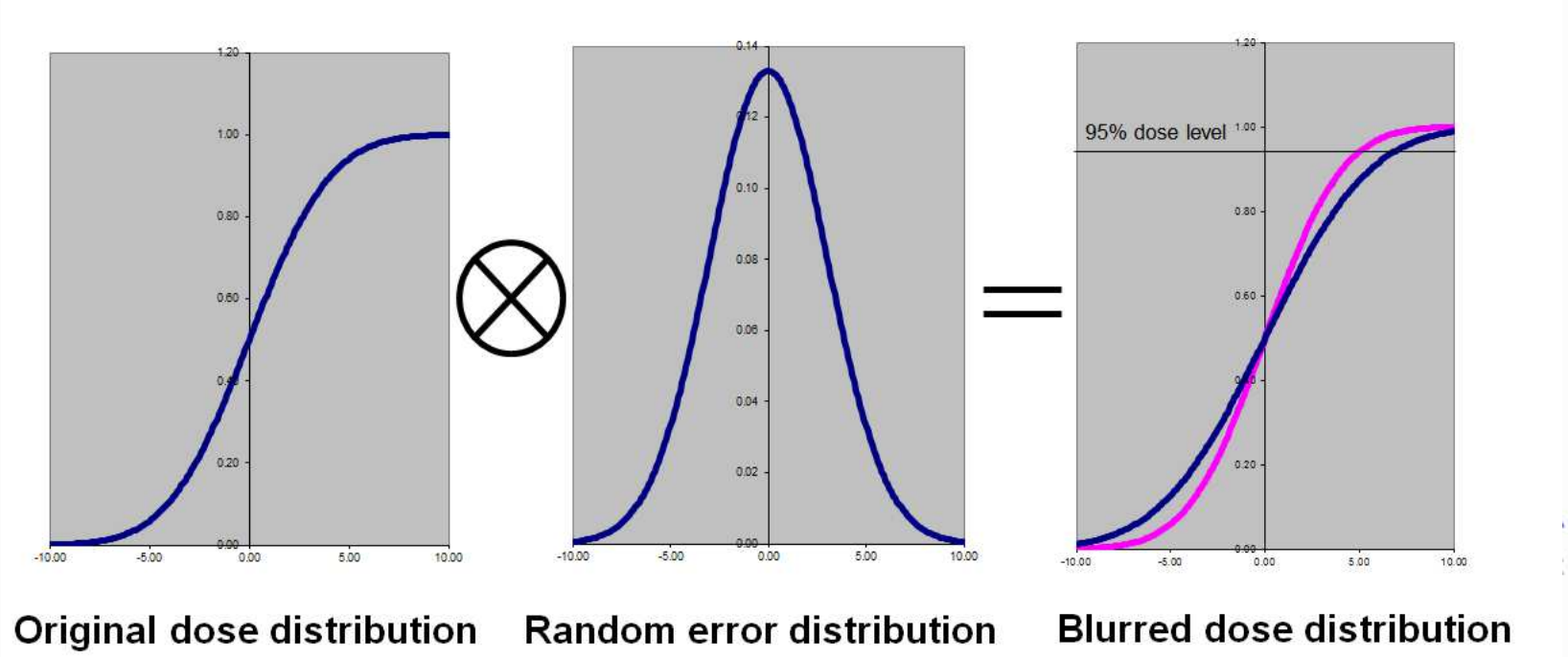

Margins for random errors

- Margin for random errors:

→Difference at 95 % dose level (i.e. the dose level of interest) before/after convolution

- Example

NETHERLANDS CANCER INSTITUTE
ANTONI VAN LEEUWENHOEK

Margins for random errors

Dose level	PTV margin	PTV margin* (ψ = 3.2 mm)
80%	$0.84\sqrt{(\sigma^2+\psi^2)} - 0.84\,\psi$	$0.4\,\sigma$
85%	$1.03\sqrt{(\sigma^2+\psi^2)} - 1.03\,\psi$	$0.5\,\sigma$
90%	$1.28\sqrt{(\sigma^2+\psi^2)} - 1.28\,\psi$	$0.6\,\sigma$
95%	$1.64\sqrt{(\sigma^2+\psi^2)} - 1.64\,\psi$	$0.7\,\sigma$

σ = SD of random errors,

ψ = σ of Gaussian penumbra

NETHERLANDS CANCER INSTITUTE
ANTONI VAN LEEUWENHOEK

*linear approximation

Margins for systematic errors

- Systematic errors <u>shift</u> the dose distribution
  - But we don't know in advance in which direction!

NETHERLANDS CANCER INSTITUTE
ANTONI VAN LEEUWENHOEK

Margins for systematic errors

- Systematic errors shift the dose distribution
  - But we can say something about the “target area’ if we know the distribution of the errors, i.e. the standard deviation

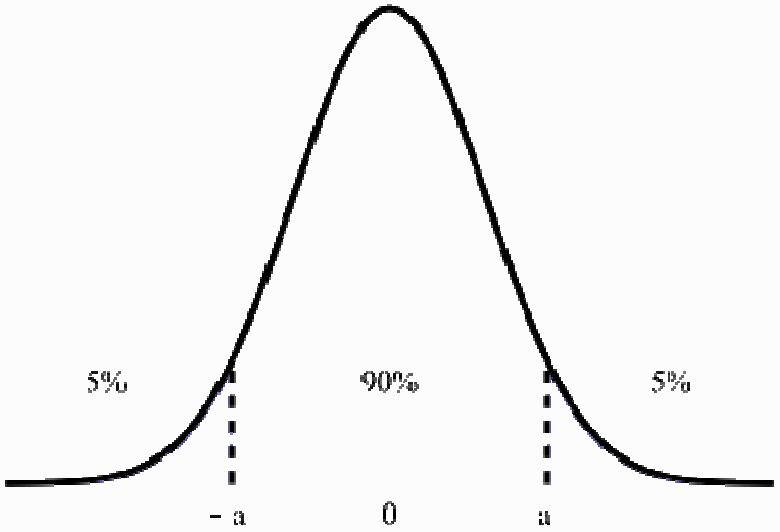

NETHERLANDS CANCER INSTITUTE
ANTONI VAN LEEUWENHOEK

PTV for systematic translations

- 90 % Confidence interval
  - 1-D : ±1.64 Σ
  - 2-D : Ellipse with radii 2.15 $\Sigma_{x,y}$
  - 3-D : Ellipsoid with radii 2.50 $\Sigma_{x,y,z}$

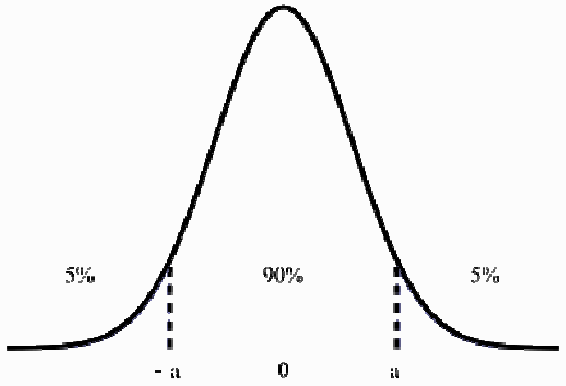

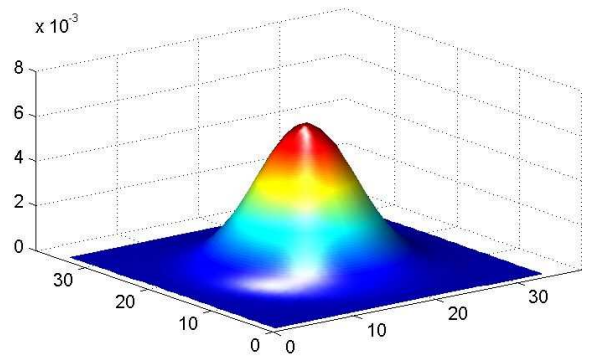

Margins for systematic translations

- Select point in (square shaped) CTV
- Determine CI = Ellipse with radii $\alpha\Sigma_{x,y}$ mm *
- Determine envelope of all CTVs in CI

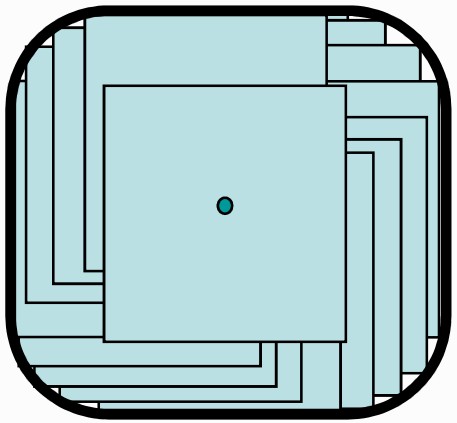

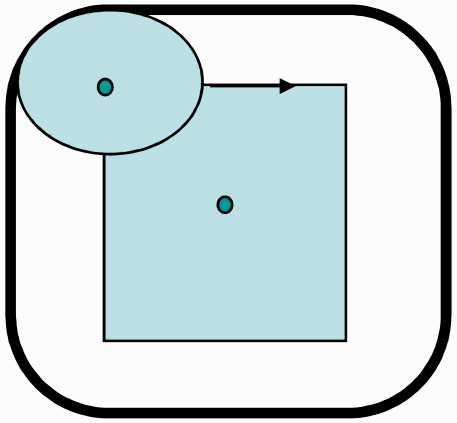

NETHERLANDS CANCER INSTITUTE
ANTONI VAN LEEUWENHOEK

*90% 2D CI: α=2.15

Margin for systematic errors

Confidence level	1-D errors	2-D errors	3-D errors
80%	1.28 Σ	1.79 Σ	2.16 Σ
85%	1.44 Σ	1.95 Σ	2.31 Σ
90%	1.64 Σ	2.15 Σ	2.50 Σ
95%	1.96 Σ	2.45 Σ	2.79 Σ

Σ = SD of preparation/systematic errors

NETHERLANDS CANCER INSTITUTE
ANTONI VAN LEEUWENHOEK

Margin recipe

- To cover 90% of the patients with the 95% isodose level:

Margin = 2.5 * Σ + 0.7 * σ

Where

$$\Sigma = \sqrt{\Sigma_{organmotion}^2 + \Sigma_{setup}^2 + \Sigma_{delineation}^2}$$

$$\sigma = \sqrt{\sigma_{organmotion}^2 + \sigma_{setup}^2}$$

NETHERLANDS CANCER INSTITUTE
ANTONI VAN LEEUWENHOEK

Keeping things in perspective

- Margin recipe assumptions
  - Perfectly conformal dose distribution
  - Large and smooth (compared to penumbra size) CTV
  - Translational errors only
  - Homogeneous dose distribution
  - Large number of fractions (for the 0.7 part)



- Real life
  - Not conformal, i.e. margin will depend on shape of dose distribution
  - Not smooth
  - Lots of changes → translations, rotations, shape changes…
  - Inhomogeneous dose distributions
  - Any number of fractions (or very few!)

NETHERLANDS CANCER INSTITUTE
ANTONI VAN LEEUWENHOEK

GTV versus CTV underdosage

GTV: Whole volume tumor

CTV: Probability of tumor

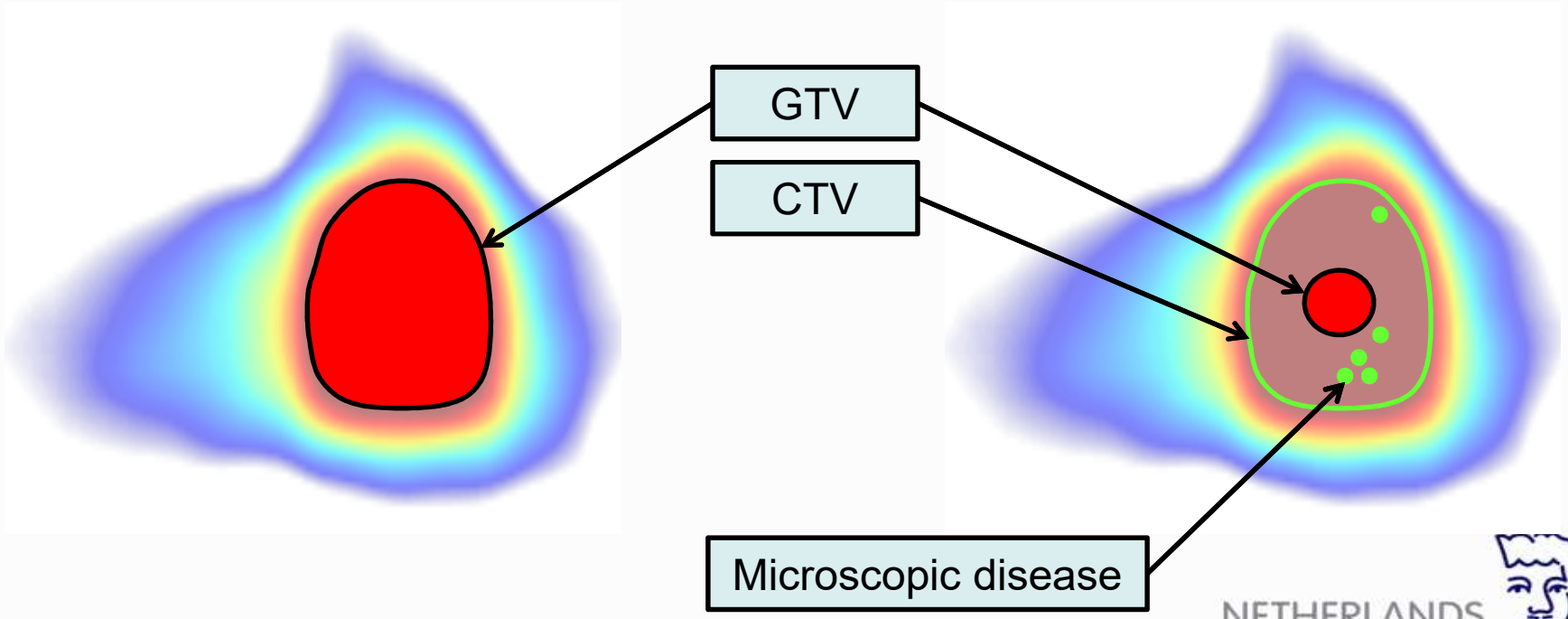

NETHERLANDS CANCER INSTITUTE
ANTONI VAN LEEUWENHOEK

GTV versus CTV underdosage

Underdosage of GTV will always lead to underdosage of tumor cells

Underdosage of CTV will **not** always lead to underdosage of tumor cells

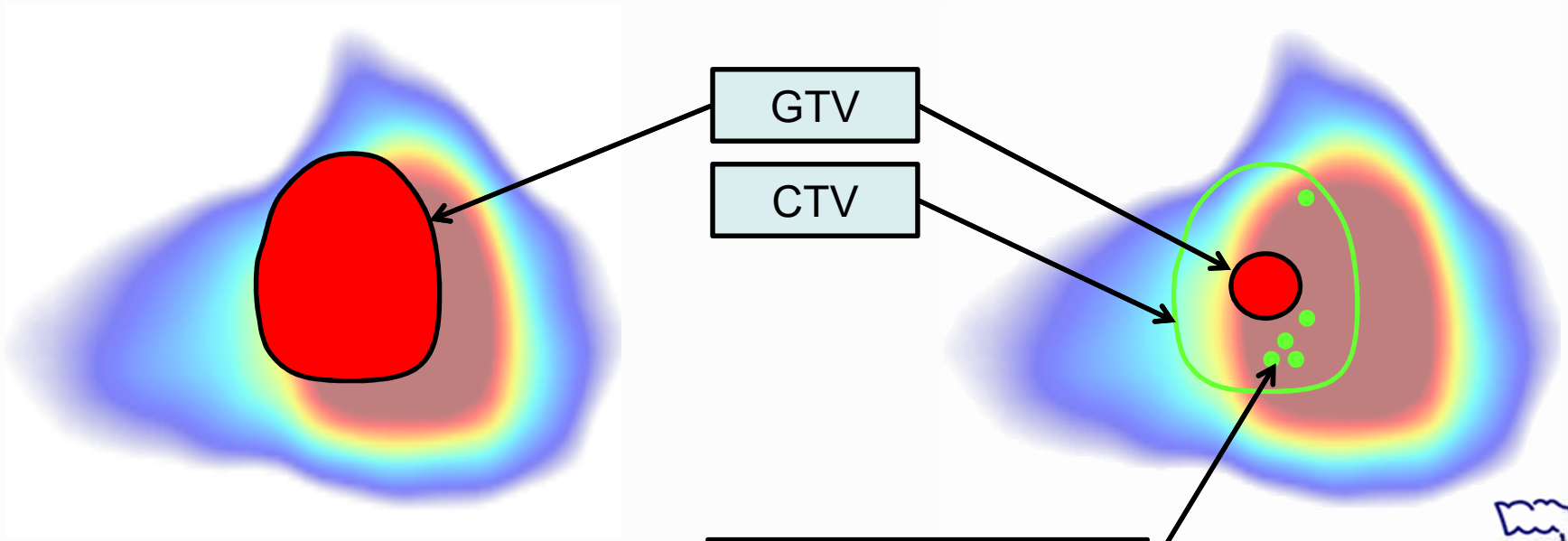

NETHERLANDS CANCER INSTITUTE
ANTONI VAN LEEUWENHOEK

Keeping things in perspective

- GTV → PTV margin
  - All cells in the GTV are considered to be tumor
  - $P_{underdosage} = P_{geometrical\ miss}$
  - Use margin prescription

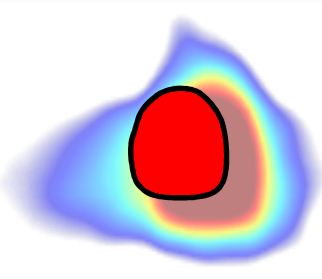

- CTV → PTV margin
  - In the CTV there is a probability of tumor cells
  - $P_{underdosage} = P_{geometrical\ miss} \times P_{presence\ of\ tumor\ cells}$
  - Margin can probably be smaller

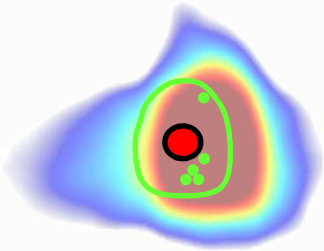

- Caveat: Tumor cell probability is needed

NETHERLANDS CANCER INSTITUTE
ANTONI VAN LEEUWENHOEK

Conclusions

- Systematic errors have different and **larger** dose effects than random errors
- A margin is always necessary. Without the proper margin underdosage will occur
- To determine margins it is important to now the statistics of the geometrical errors
- Since delineation uncertainties are systematic, they will have a large effect on the required margin

NETHERLANDS CANCER INSTITUTE
ANTONI VAN LEEUWENHOEK



ESTRO

School

WWW.ESTRO.ORG/SCHOOL

H&N - Anatomy and Nodal Drainage

Julien Dinkel

University Hospital of Munich
Department of Radiology
Germany

ESTRO School

Teaching points

- To grasp the subtlety of H&N anatomy
- To know the best imaging methods for H&N
- To understand the basics of nodal drainage in H&N

ESTRO School

Compartments – why bother?

- location of the spaces in the head and neck
- Important for differential diagnosis
- Routes of spread

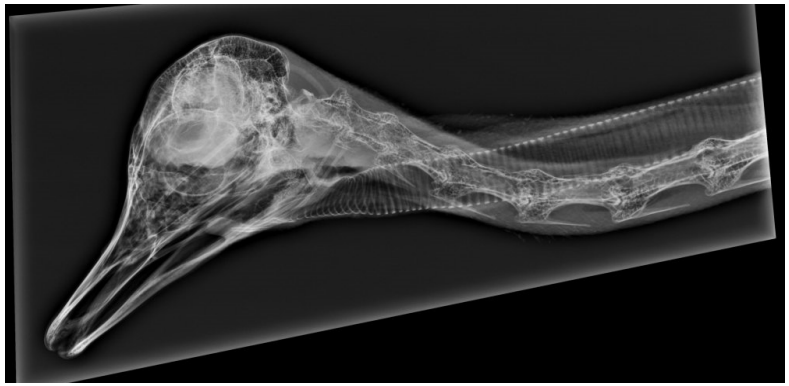

HR Harnsberger, AG Osborne, AJR 157:147-154
WRK Smoker, HR Harnsberger, AJR 157:155-159

VOLUME 28 · NUMBER 18 · JUNE 20 2010

JOURNAL OF CLINICAL ONCOLOGY

ORIGINAL REPORT

Critical Impact of Radiotherapy Protocol Compliance and Quality in the Treatment of Advanced Head and Neck Cancer: Results From TROG 02.02

Lester J. Peters, Brian O'Sullivan, Jordi Giralt, Thomas J. Fitzgerald, Andy Trotti, Jacques Bernier, Jean Bourhis, Kally Yuen, Richard Fisher, and Danny Rischin

2 year overall survival:

- 50 % if major deficiency in treatment plan (n=87)
- 70% if protocol compliant (n=502)

Includes errors in target delineation

ESTRO School

- Imaging is not „stand-alone“
- Imaging complements clinical examination
- Imaging emphasizes abnormal anatomy
  - Crucial to know normal anatomy

ESTRO School

CT or MRI?

- Metal artefacts (e.g. dental implants) vs. Motion artefacts (MRI). Challenging fat sat
- MRI: T2w. T1w (STIR) and T1fs CE (DIXON)

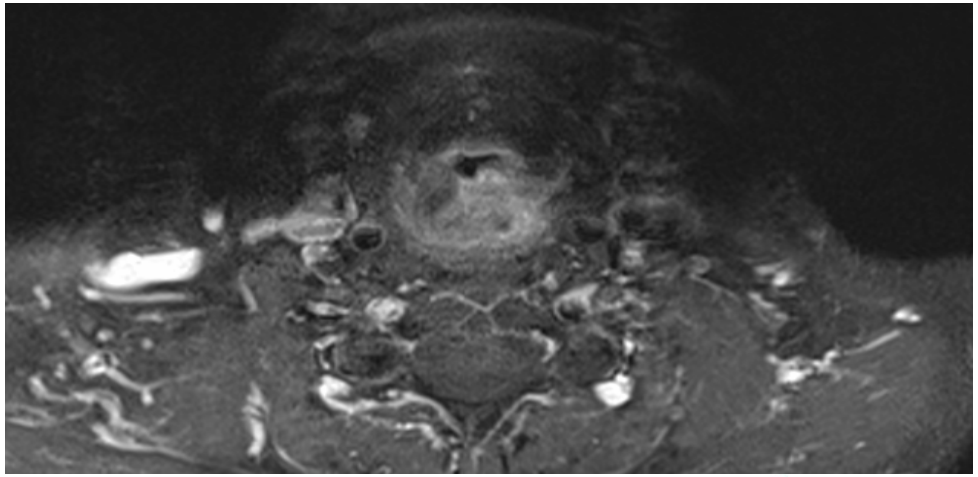

ESTRO School

CT or MRI?

MRI:

- **Better contrast/soft tissue resolution**
- **More sensitive to detect perineural tumor spread**
- **More sensitive to detect bone invasion**

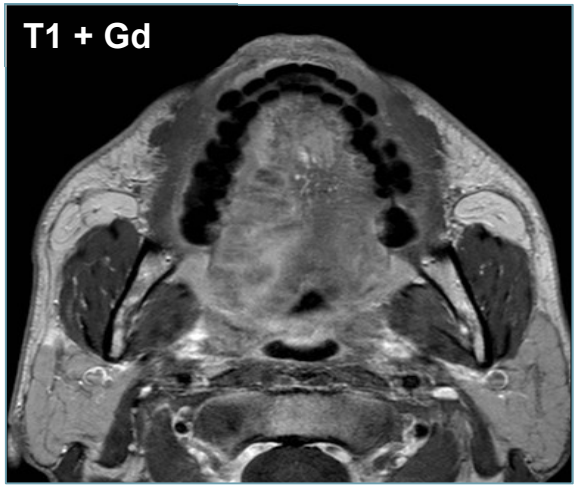

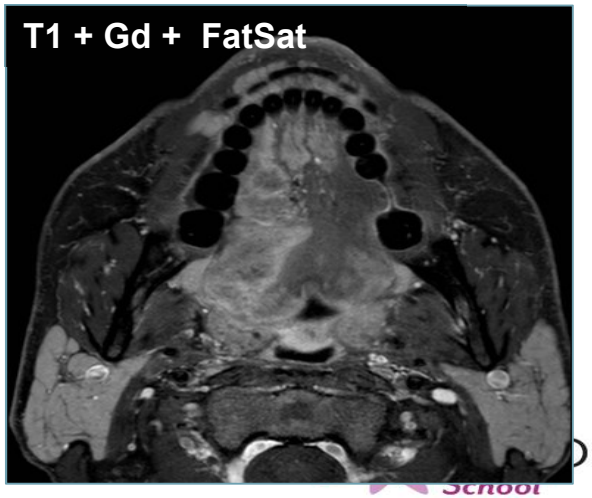

CT or MRI?

CT:

- Volumetric
- Virtual endoscopy
- Good imaging for bone and cartilage
- Basis of RT planning
- Basis of PET-CT
- Fast
- Well tolerated
- Inexpensive

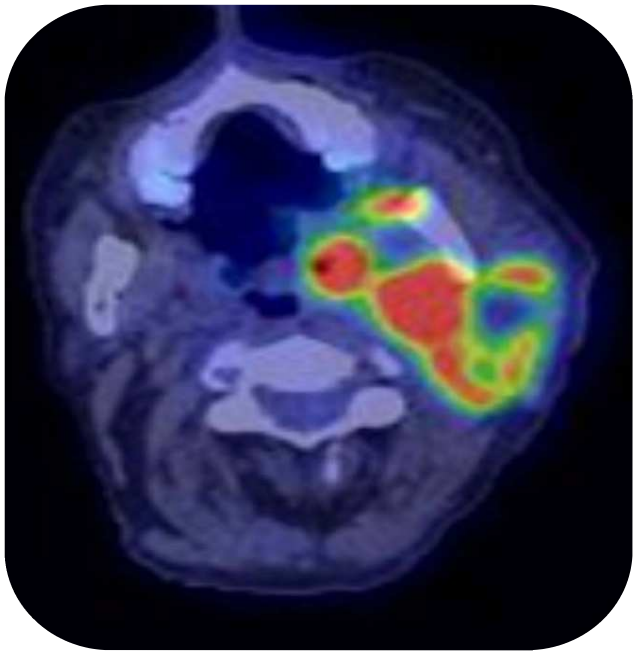

ESTRO School

Pharyngeal Mucosal Space (PMS)

Mucosal surface of naso-, oro- and hypopharynx

- Above the soft palate: nasopharynx
- Below the soft palate and above the hyoid bone: oropharynx
- Below the hyoid bone: hypopharynx

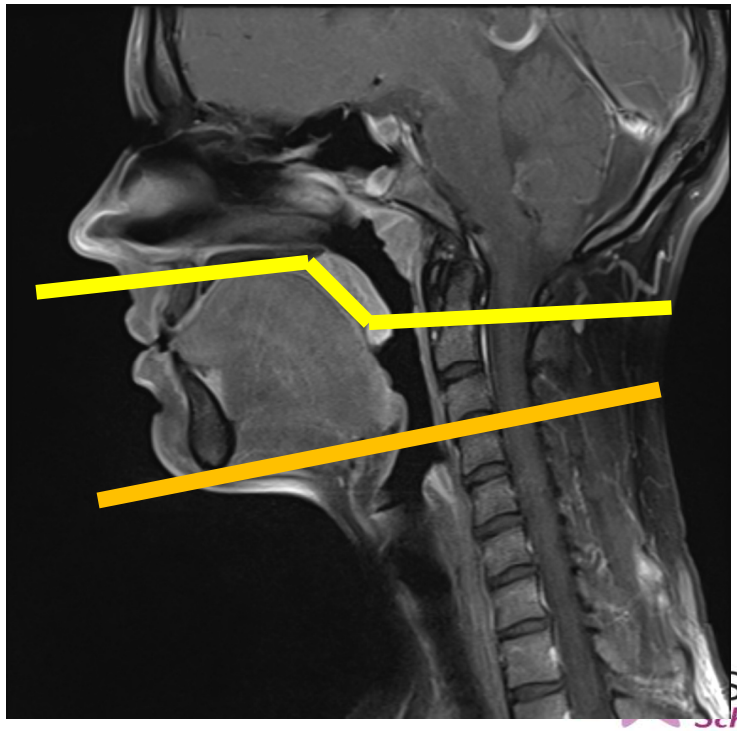

STRO School

Pharyngeal Mucosal Space (PMS)

Mucosal surface of naso-, oro- and hypopharynx

- Above the soft palate: nasopharynx
- Below the soft palate and above the hyoid bone: oropharynx
- Below the hyoid bone: hypopharynx

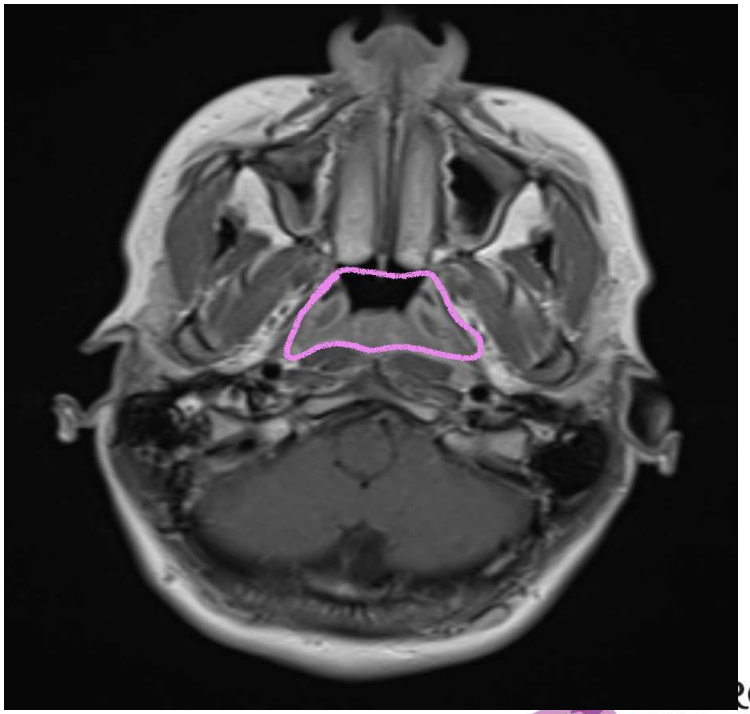

School

Pharyngeal Mucosal Space (PMS)

Mucosal surface of naso-, oro- and hypopharynx

- Above the soft palate: nasopharynx
- Below the soft palate and above the hyoid bone: oropharynx
- Below the hyoid bone: hypopharynx

Nasopharyngeal tumors

- MRI assists accurate GTV delineation
- Confluent involvement with retropharyngeal nodes

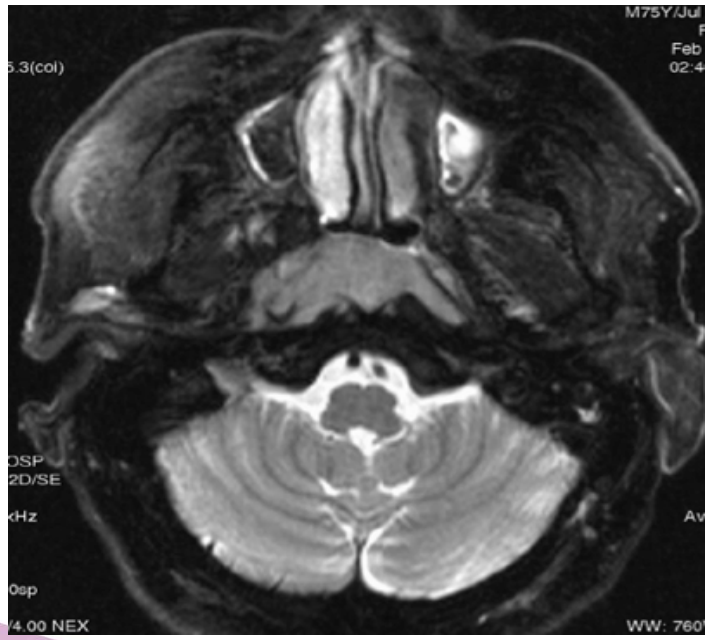

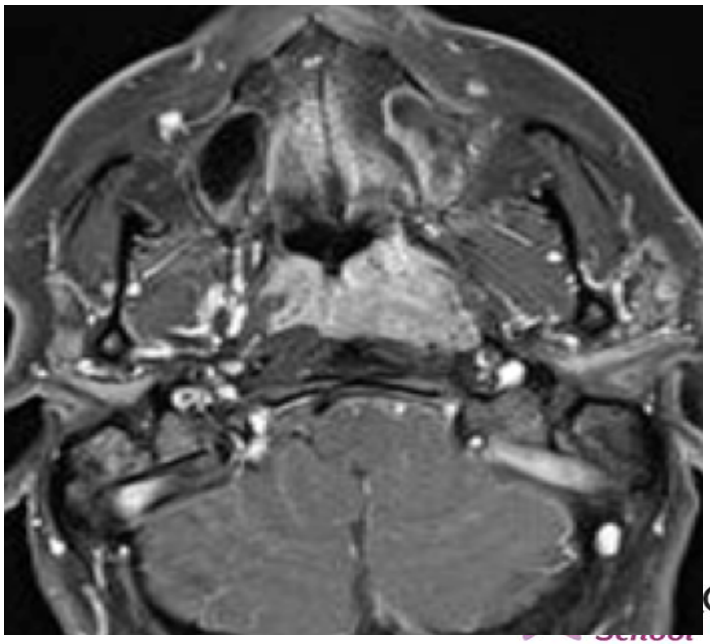

Early nasopharyngeal tumors

- Subtle asymmetry of the fossa of Rosenmüller

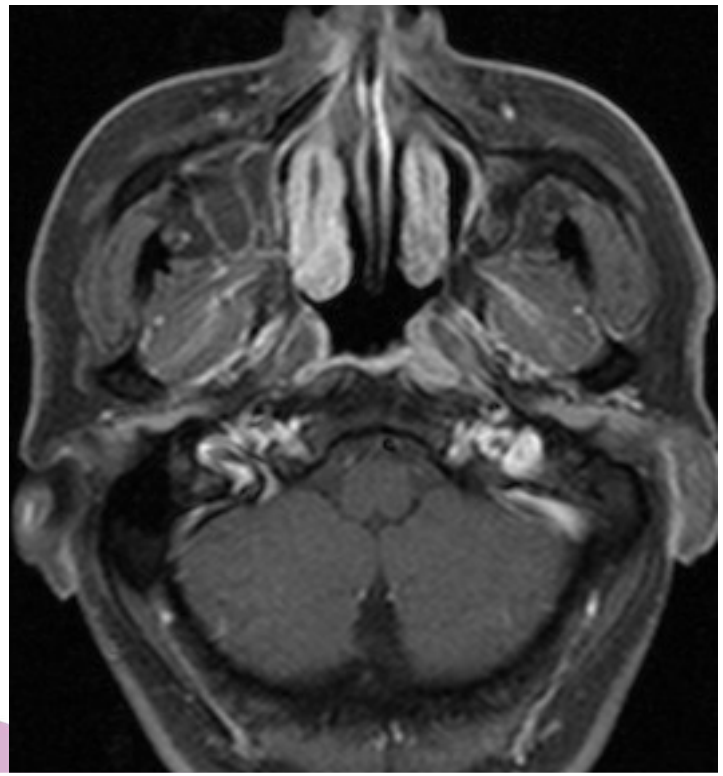

ESTRO School

Adv. nasopharyngeal tumors

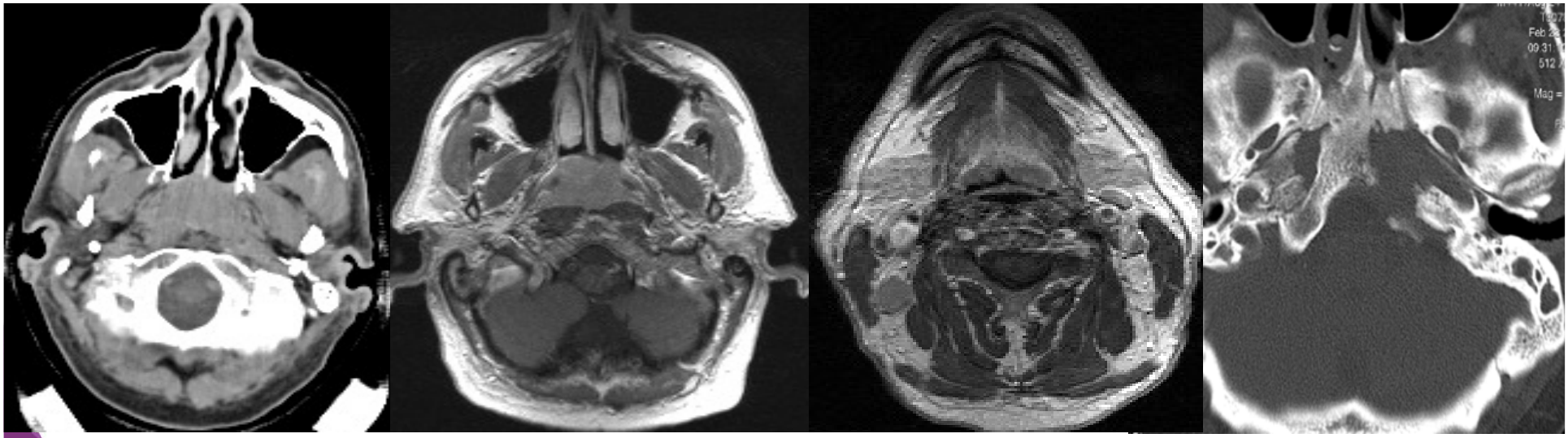

ESTRO School

Oropharyngeal tumors

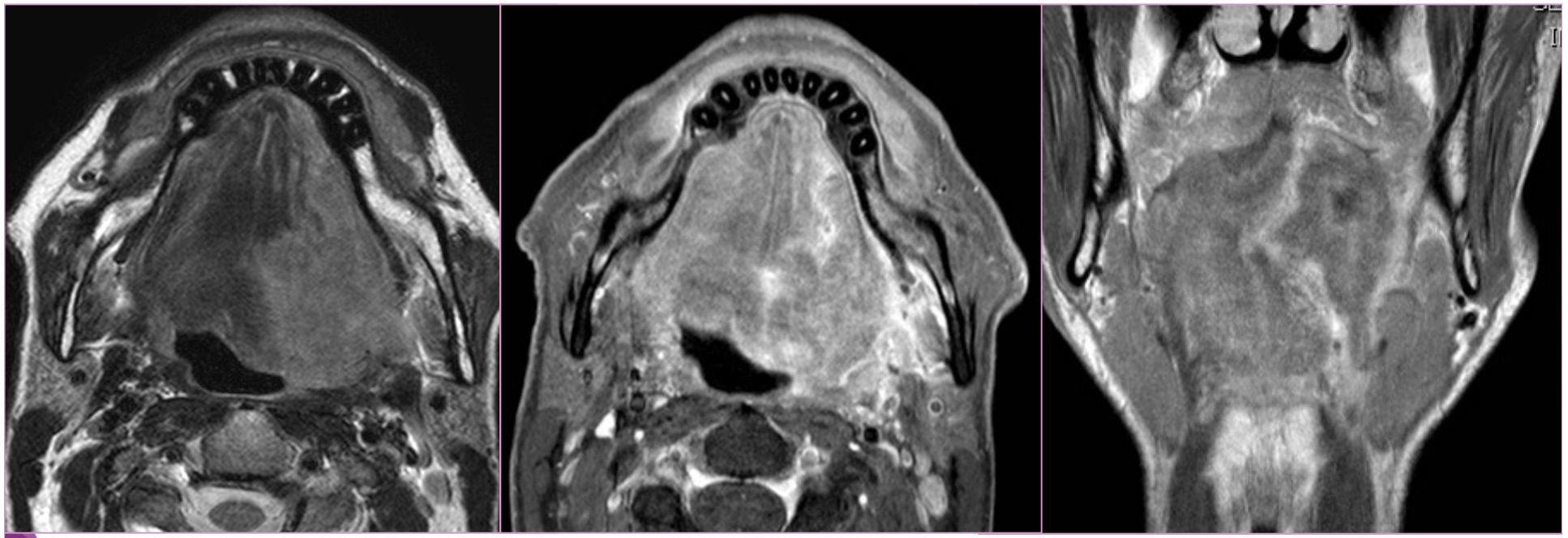

ESTRO School

Oropharyngeal tumors

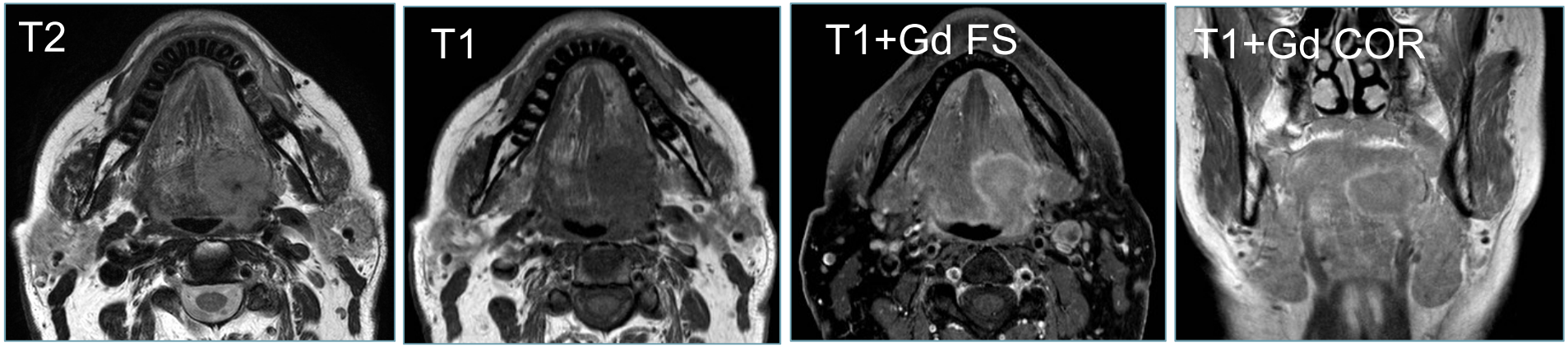

Squamous Cell Carcinoma of the base of the tongue

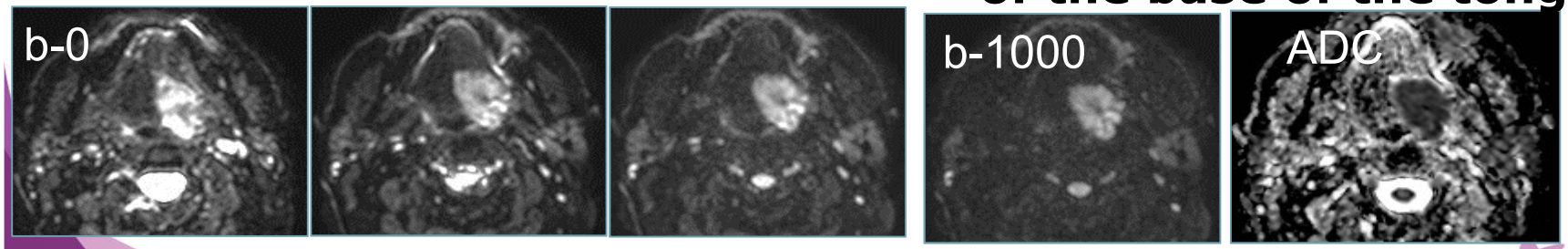

Courtesy J.W. Casselman

ESTRO School

Visceral Space (VS)

- Cylindrical space
- Midline
- Only in infrahyoid neck
- Enclosed by middle layer of deep cervical fascia

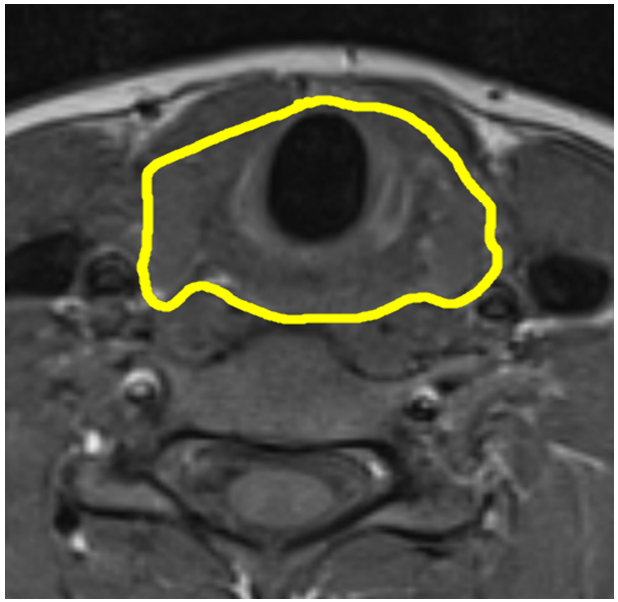

Visceral Space (VS)

- Larynx
- Hypopharynx
- Esophagus
- Trachea
- Thyroid
- Parathyroid glands

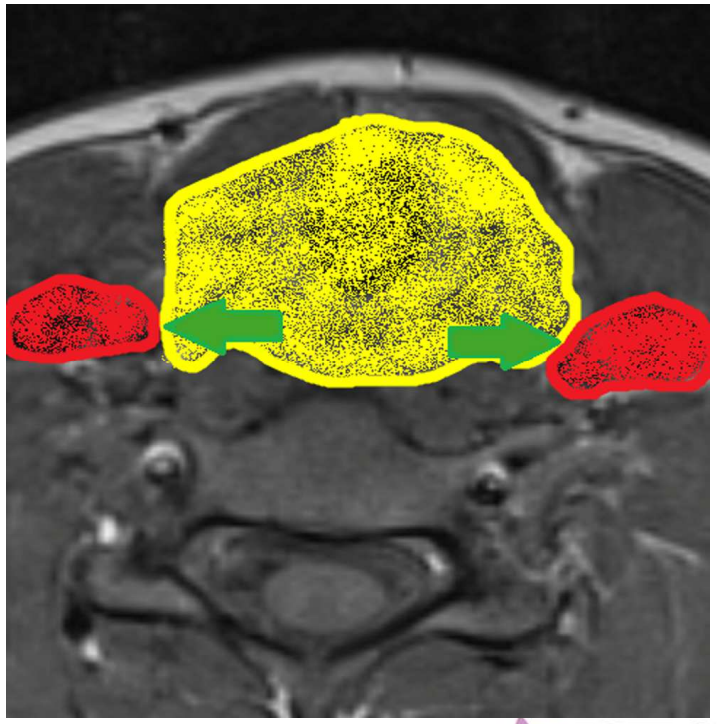

ESTRO School

Carotid Space (CS)

carotid arteries
internal jugular veins

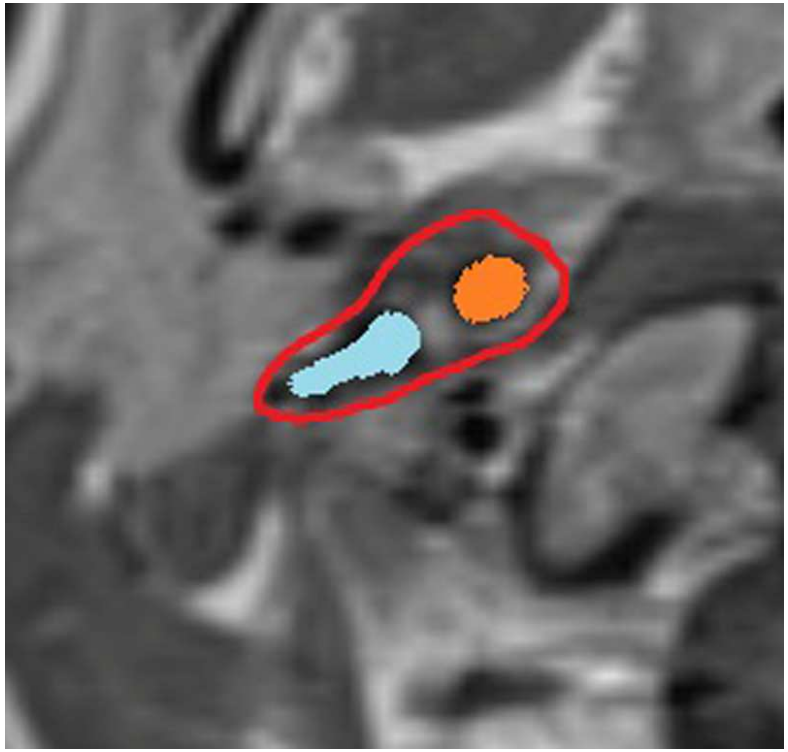

ESTRO School

Hypopharyngeal tumors

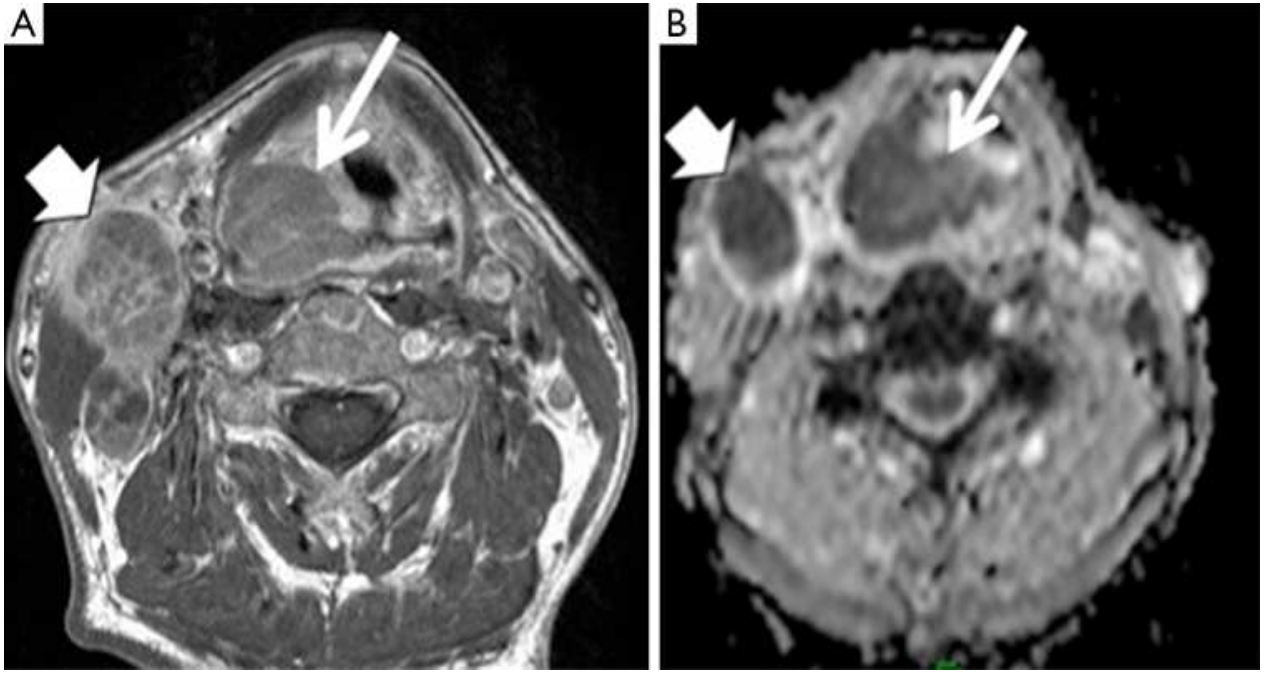

Yuan et al Functional magnetic resonance imaging techniques and their development for radiation therapy planning and monitoring in the head and neck cancers QIMS 2016

ESTRO School

Hypopharyngeal tumors

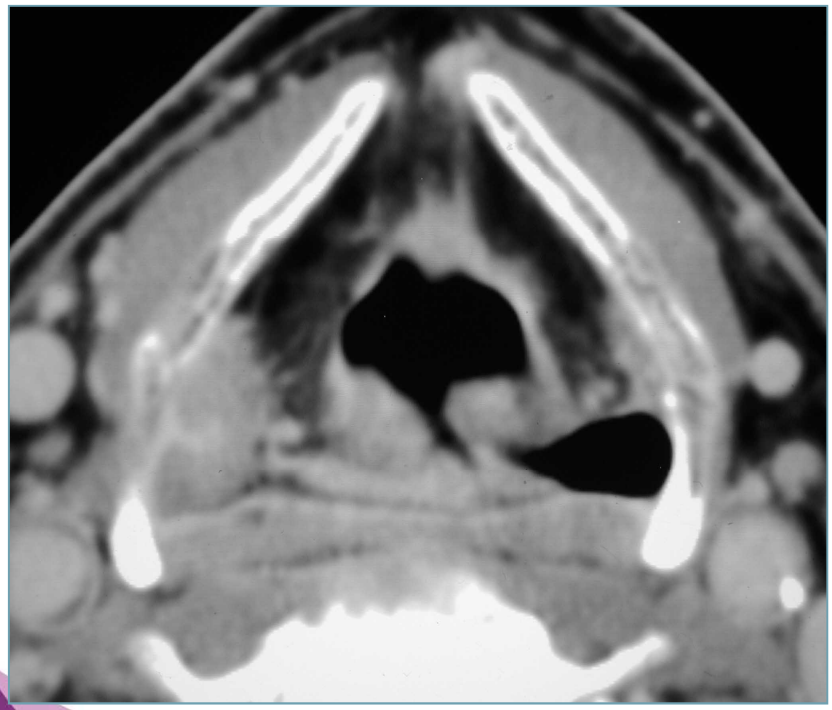

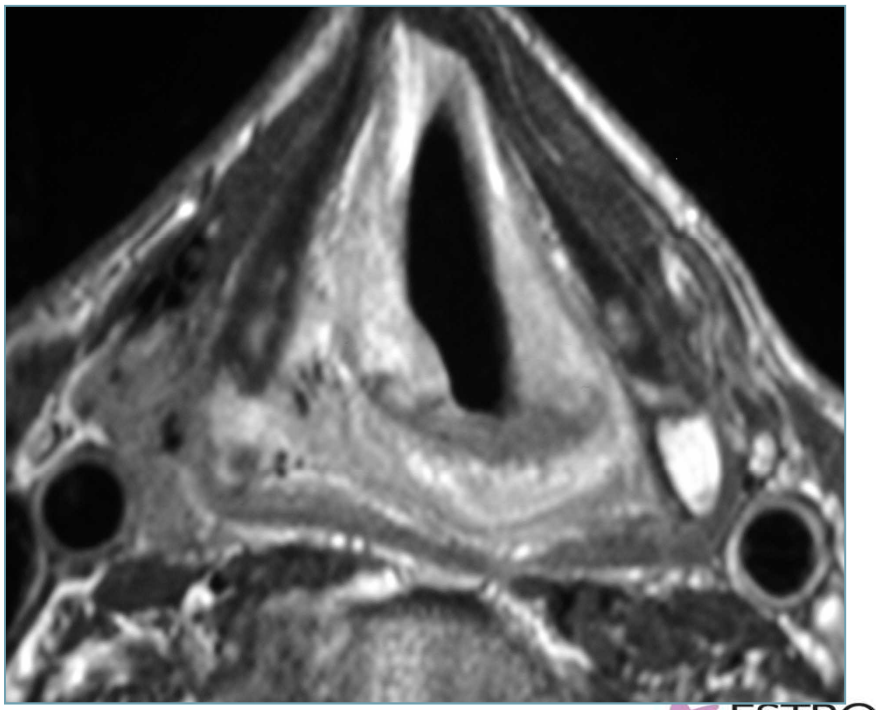

ESTRO School

Imaging of the larynx

- CT modality of choice
- Inexpensive, available
- Fast and convenient
- Cessation of respiration and swallowing

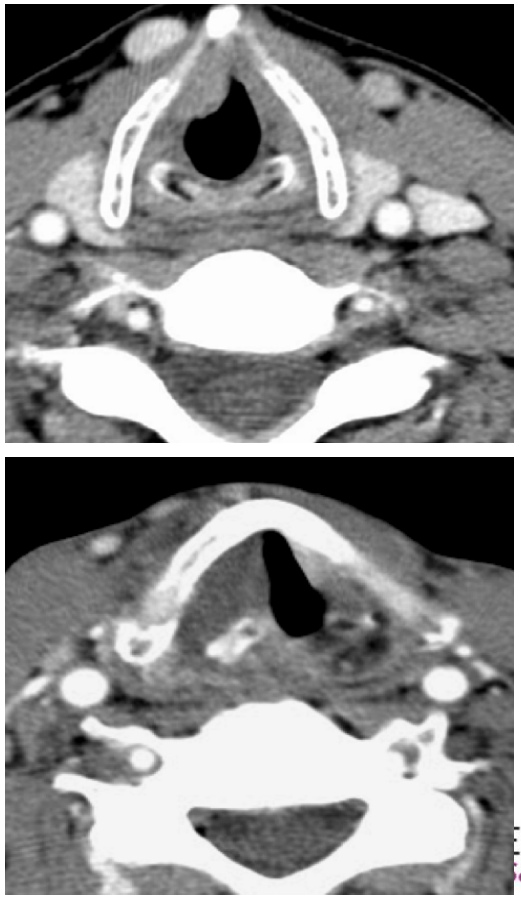

Imaging of the larynx

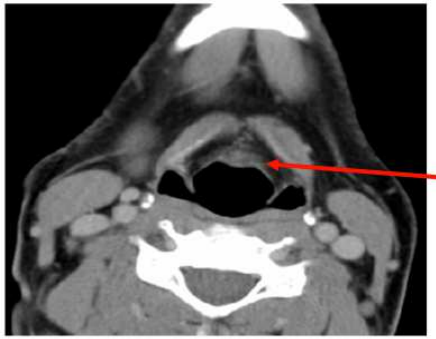

supraglottic

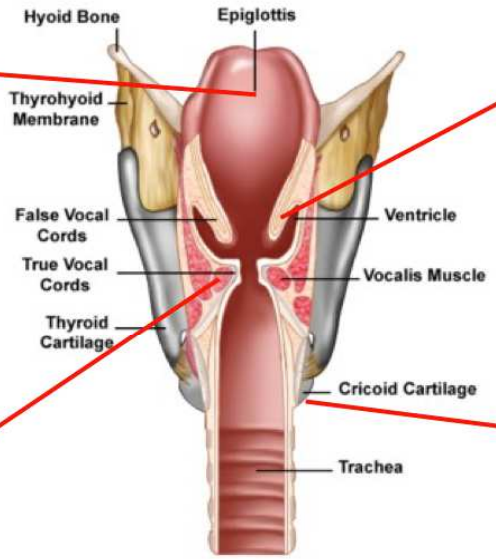

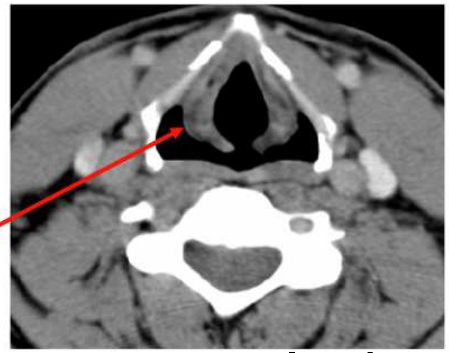

supraglottic

glottic

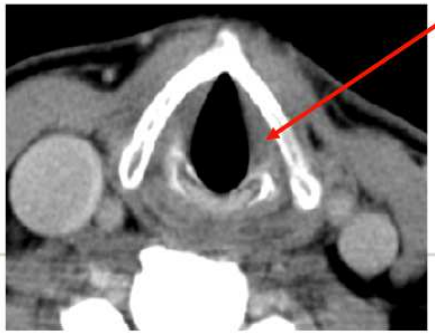

ESTRO School

Imaging of the larynx

- Involvement of the anterior commissure -> treat both cords

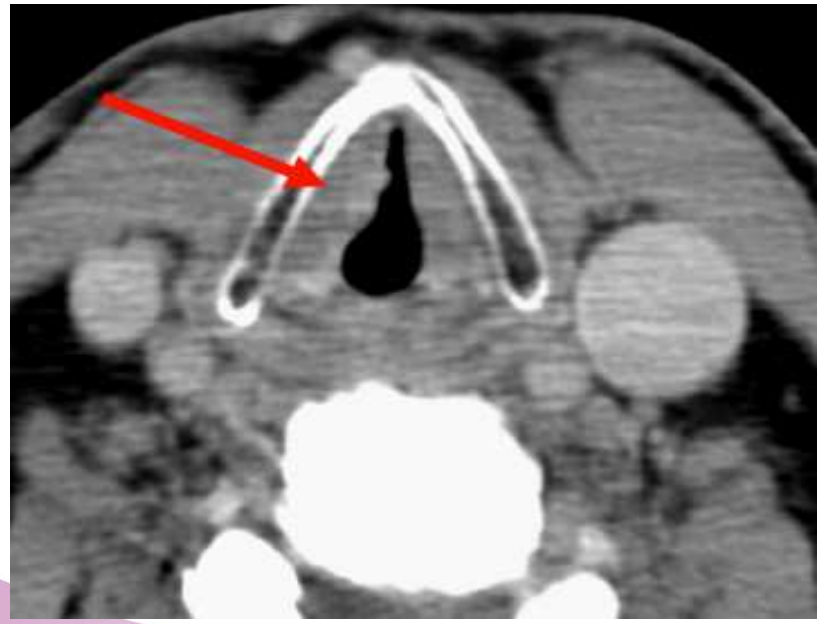

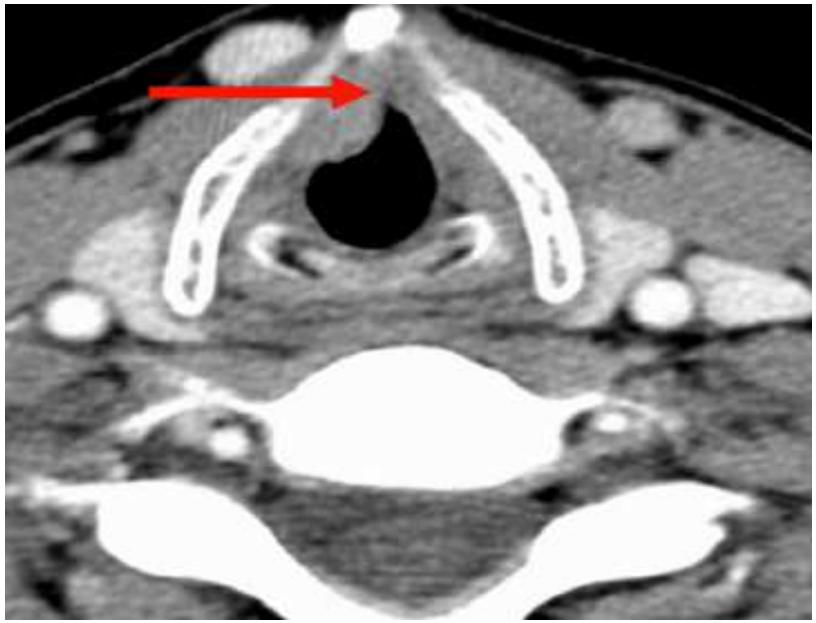

Imaging of the larynx

- Cartilage involvement
  - Sclerosis
  - Lysis
  - Erosion

ESTRO School

Imaging of the larynx

- Supraglottic extension

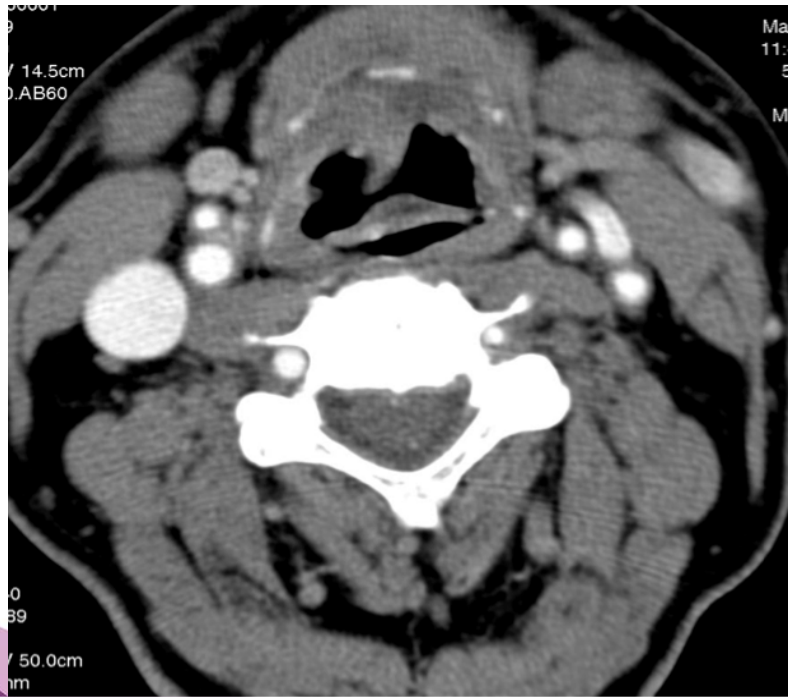

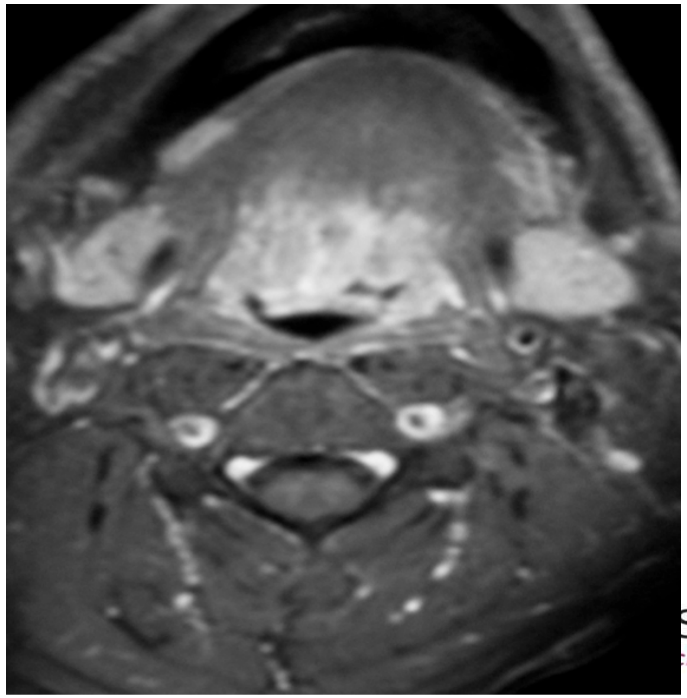

Imaging of the larynx

- Infraglottic extension

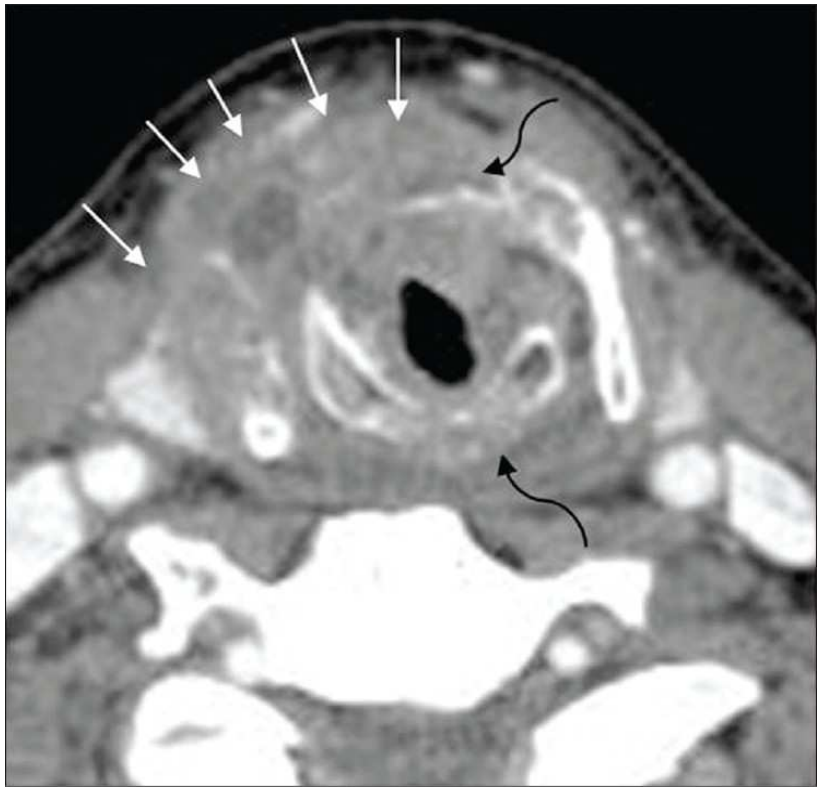

Joshi et al. Imaging in laryngeal cancers IJRI 2012

ESTRO School

Parapharyngeal Space (PPS)

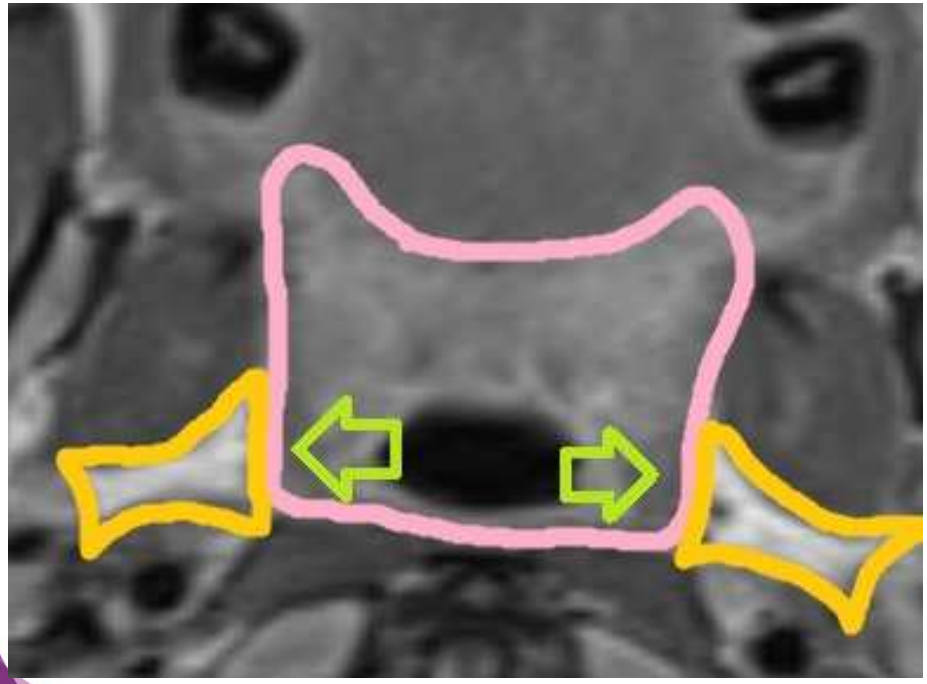

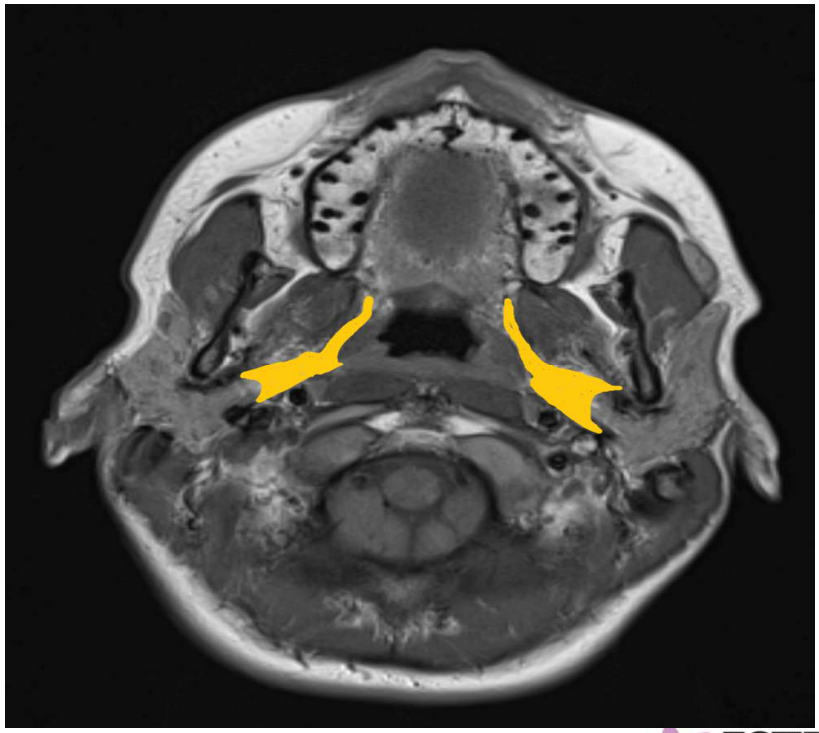

PMS lesions push the fat of the PPS laterally

ESTRO School

Adv. nasopharyngeal tumors with PPS infiltration

Masticator Space

- muscles of mastication (temporalis, masseter, medial and lateral pterygoid muscles)

- cranial nerve V3

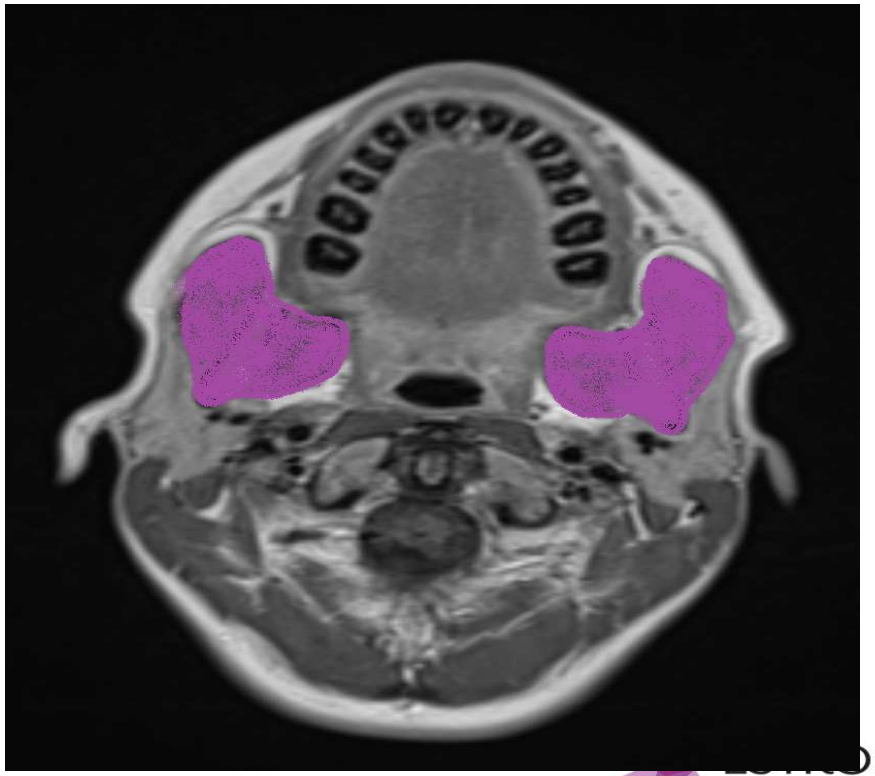

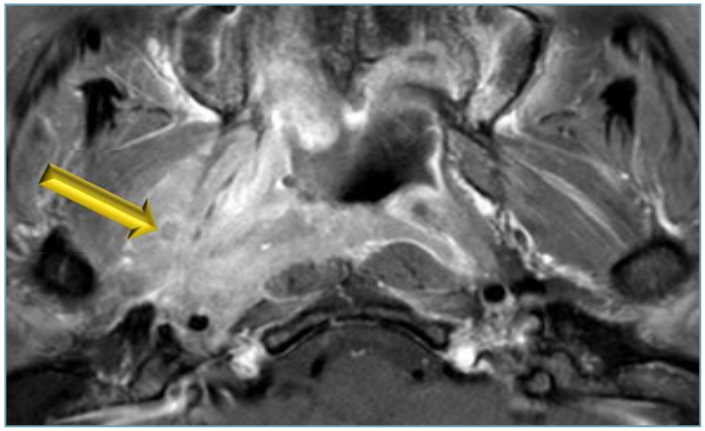

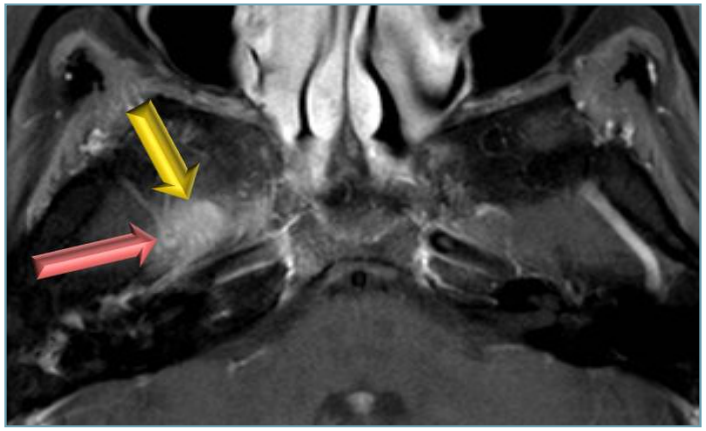

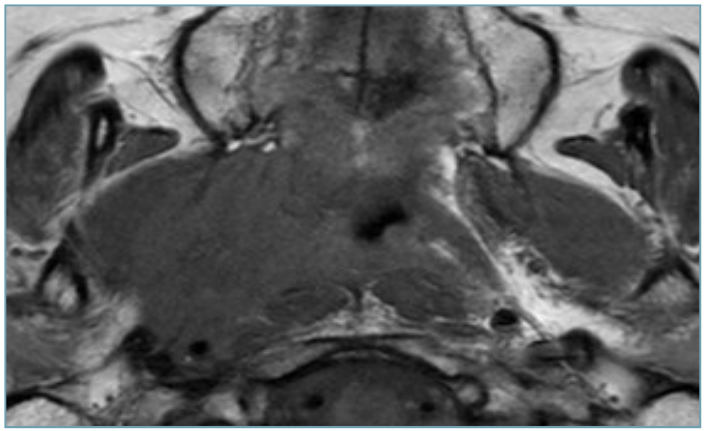

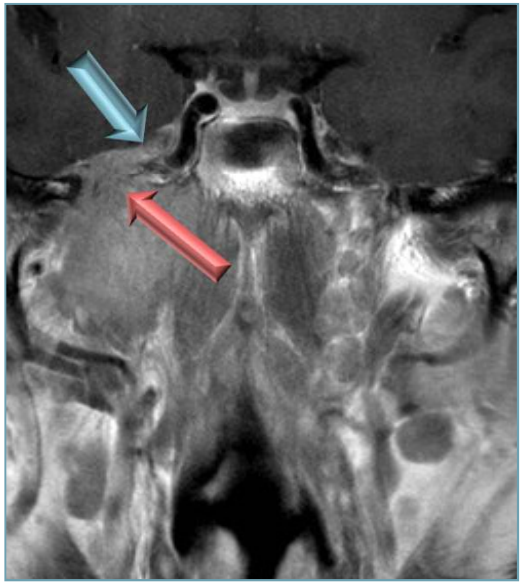

Adv. Nasopharynx Ca

V_3 & masticator space invasion = T4

Courtesy J W Casselman

ESTRO School

Retropharyngeal Space

- Midline space
- Posterior to pharynx and cervical esophagus
- Filled with fat
- Relatively narrow in suprahyoid

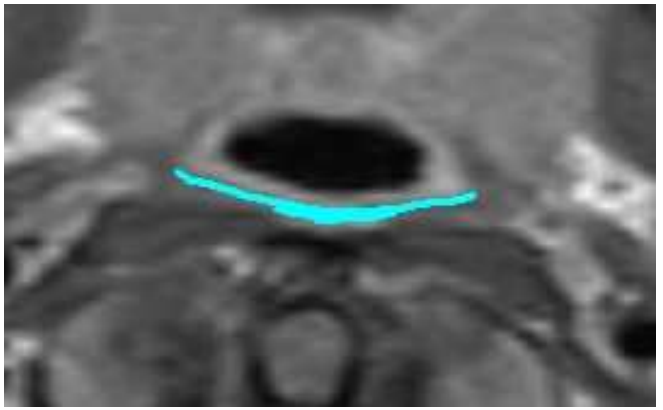

- Retropharyngeal abscess
- Retropharyngeal tumor spread
- Lymph nodes

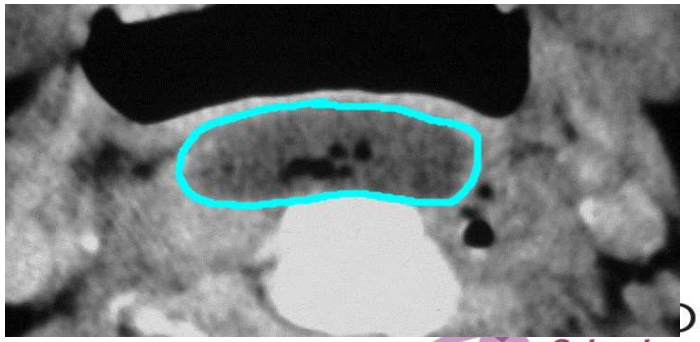

Parotid Space (PS)

- Parotid gland
- facial nerve
- lymph nodes

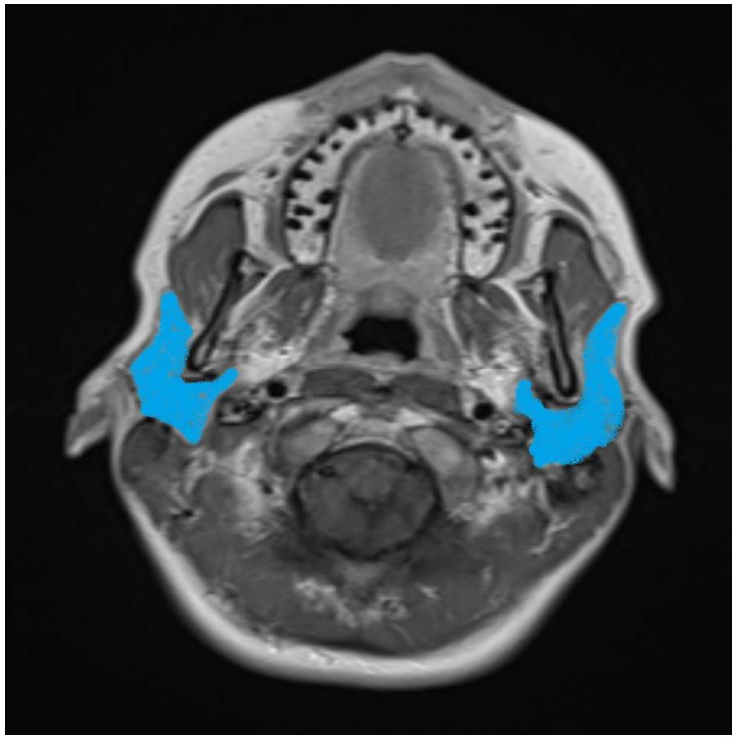

ESTRO School

Perivertebral Space (PVS) & Posterior Cervical Space (PCS)

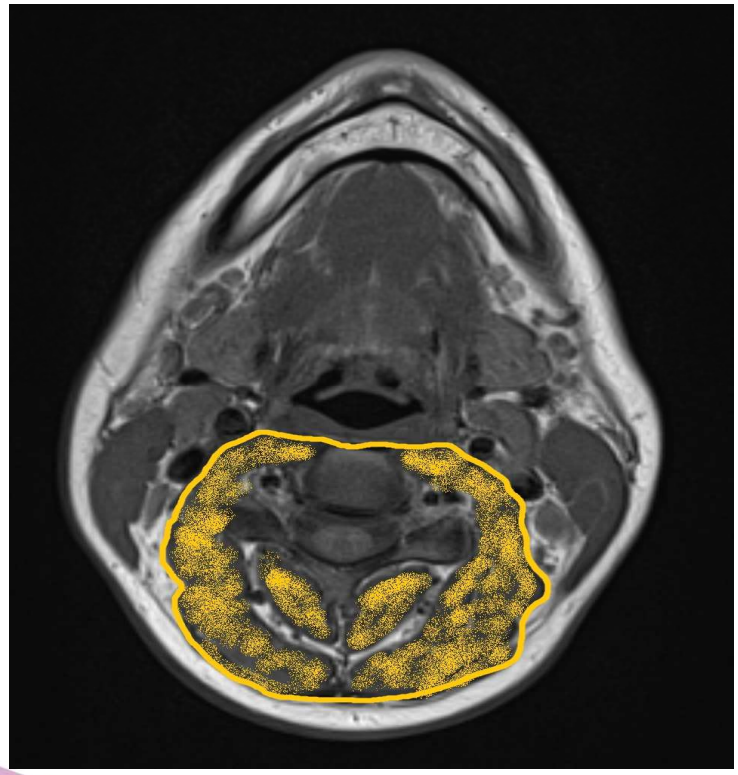

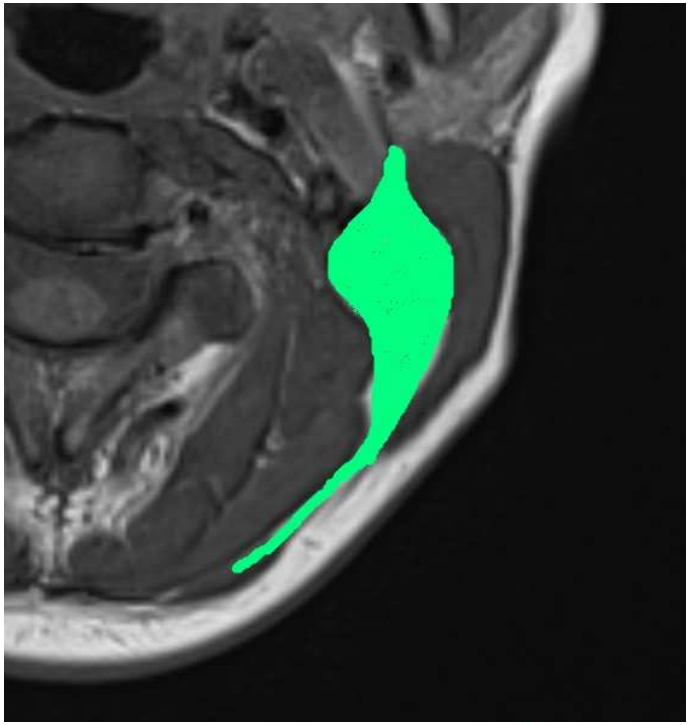

Lymph nodes– level 5A and 5B

Paranasal sinus tumors

MRI better than CT

- Soft tissue extent
- Discrimiation from mucosal swelling and mucus retention

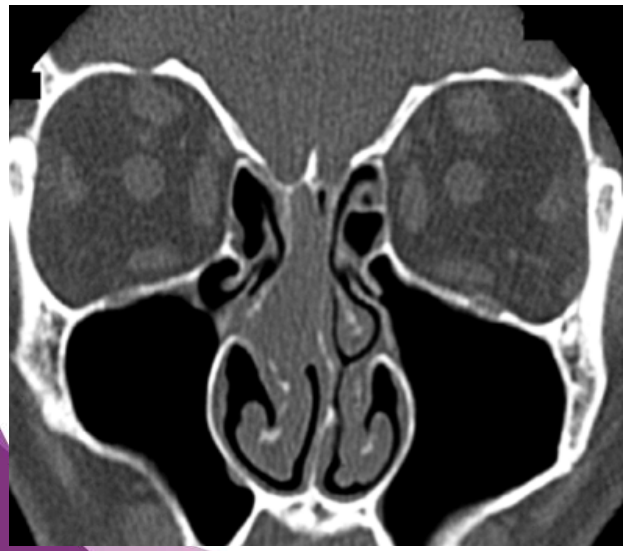

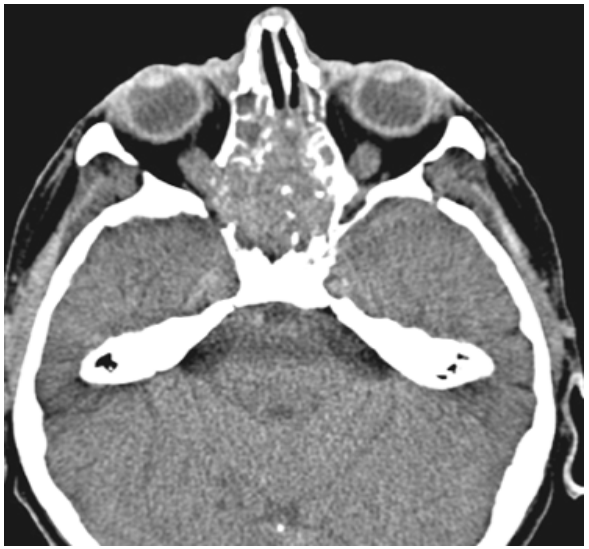

Paranasal sinus tumors

Tissue	*Morphology*
Solid tumor	- Moderate enhancement - Solid or inhomogeneous
Inflamed mucosa	- Brilliant and smooth enhancement - Thin enhancing layer - Non-enhancing submucosa - „Bubbly“ appearance
Fluid and mucus retention	- Non-enhancing - T2 bright hyperintense

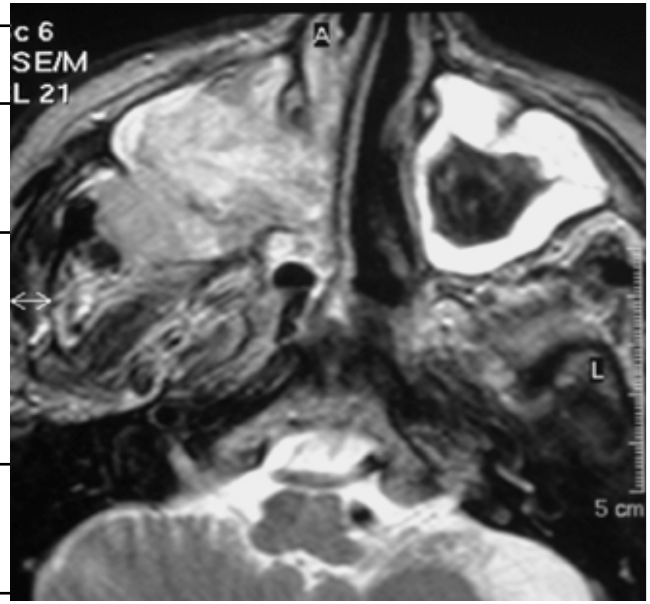

ESTRO School

Paranasal sinus tumors

- Primary treatment often surgical
- Often no visible GTV
- Flap reconstruction

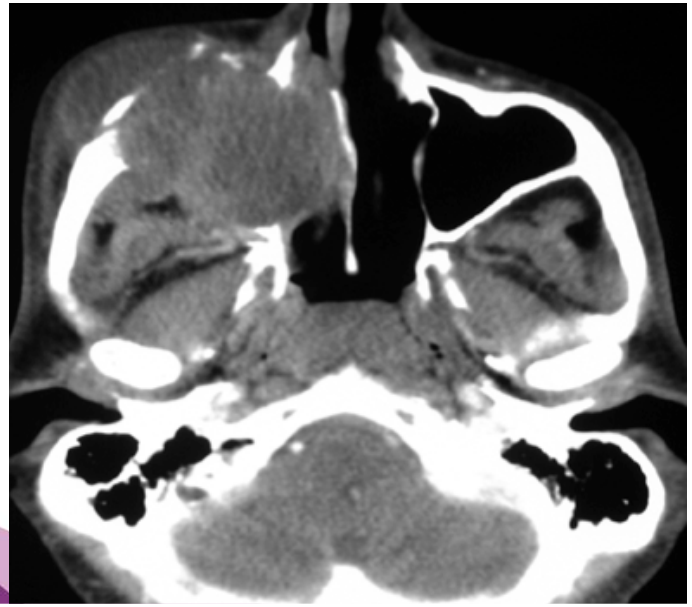

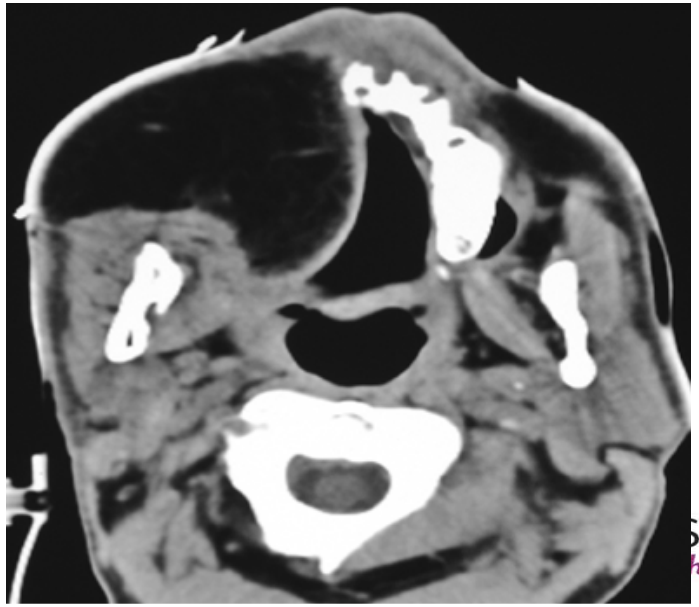

Role of PET-CT

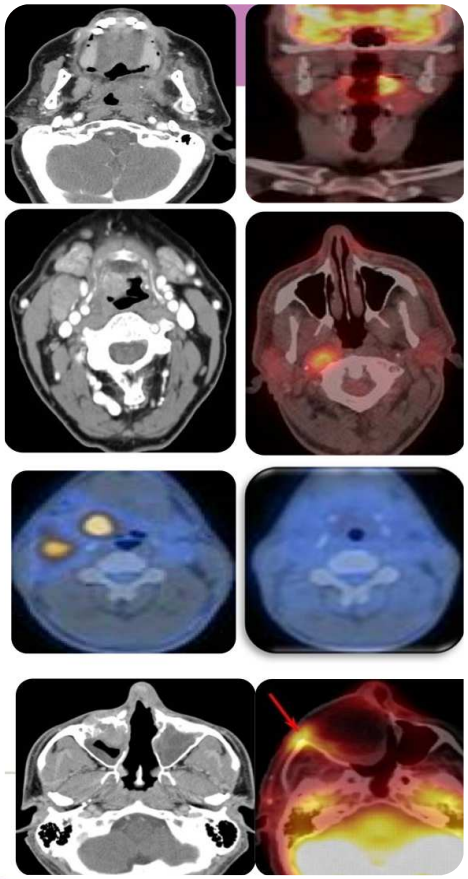

Find primary Tu

Stage the lymph nodes

- Sensitivity: ca 80%
- Specificity: ca 90%

- Monitor response

- Detect recurrence

ESTRO School

Conturing with PET

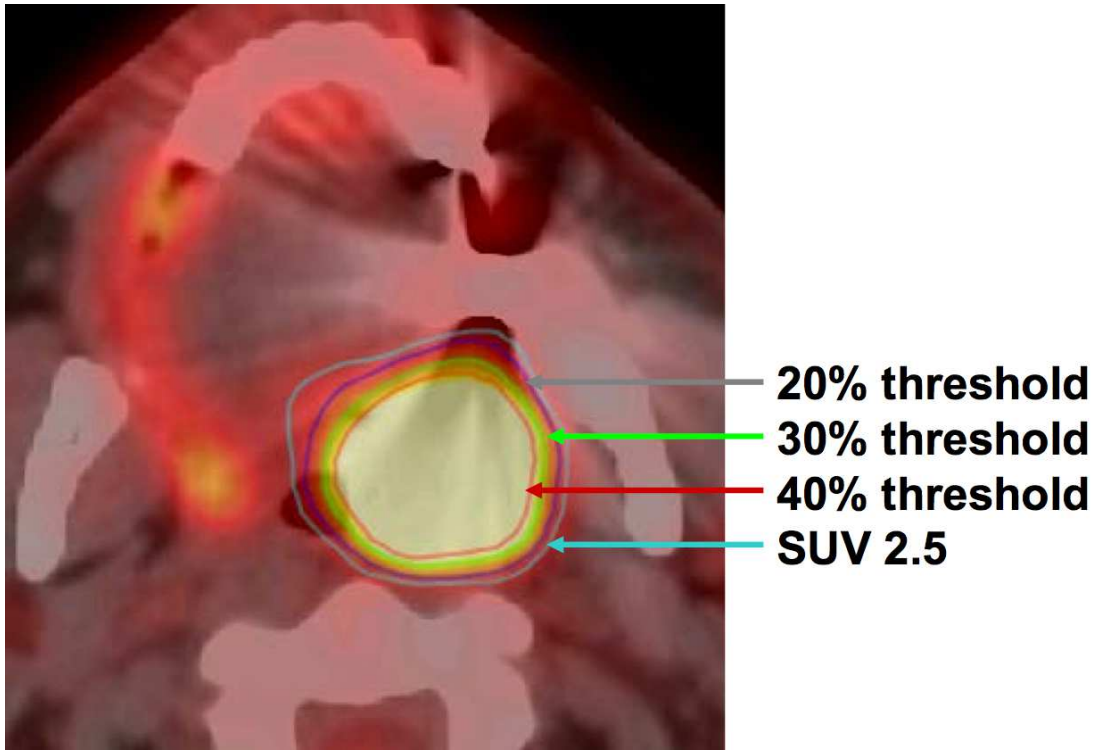

ESTRO School

Cervical lymph nodes

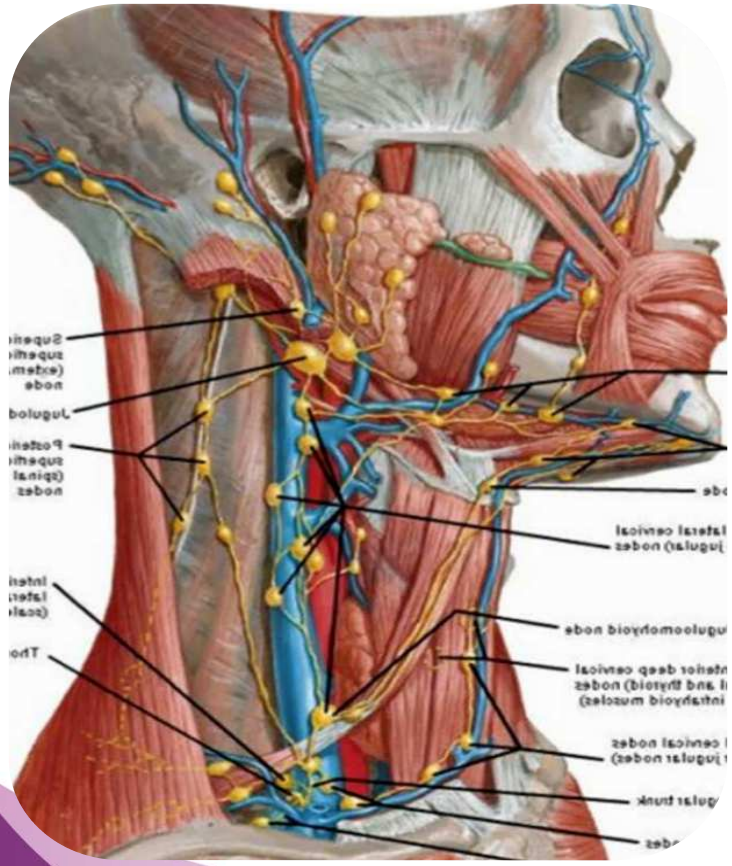

ESTRO School

Cervical lymph nodes

signs of nodal malignancy

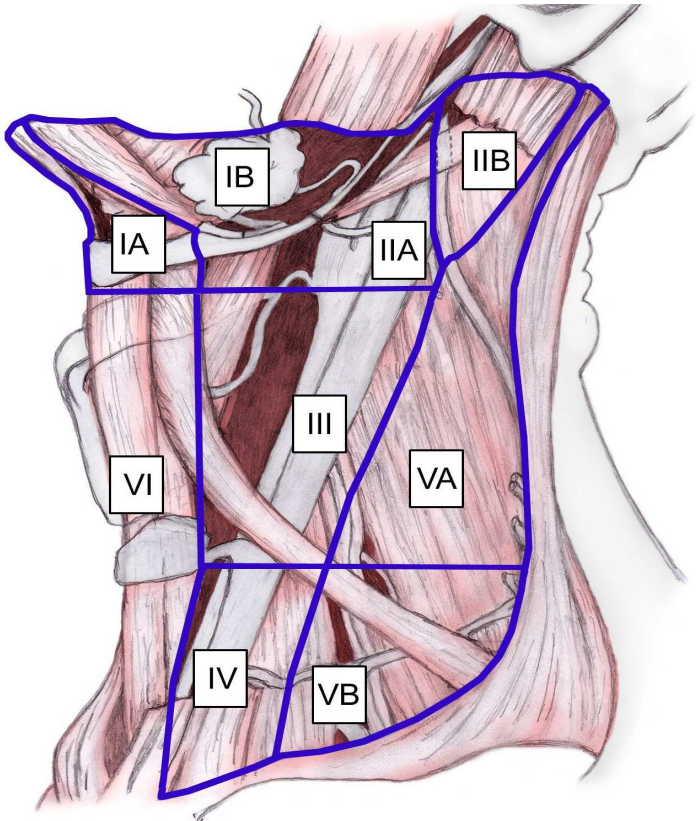

medscape

- Ia Submental group
- Ib Submandibular group
- II Upper jugular group
- III Middle jugular group
- IVa Lower jugular group
- IVb Medial supraclavicular group
- Va - Upper posterior triangle nodes
- Vb - Lower posterior triangle nodes
- Vc Lateral supraclavicular group
- VIa Anterior jugular nodes
- VIb - Prelaryngeal, pretracheal, &

ESTRO School

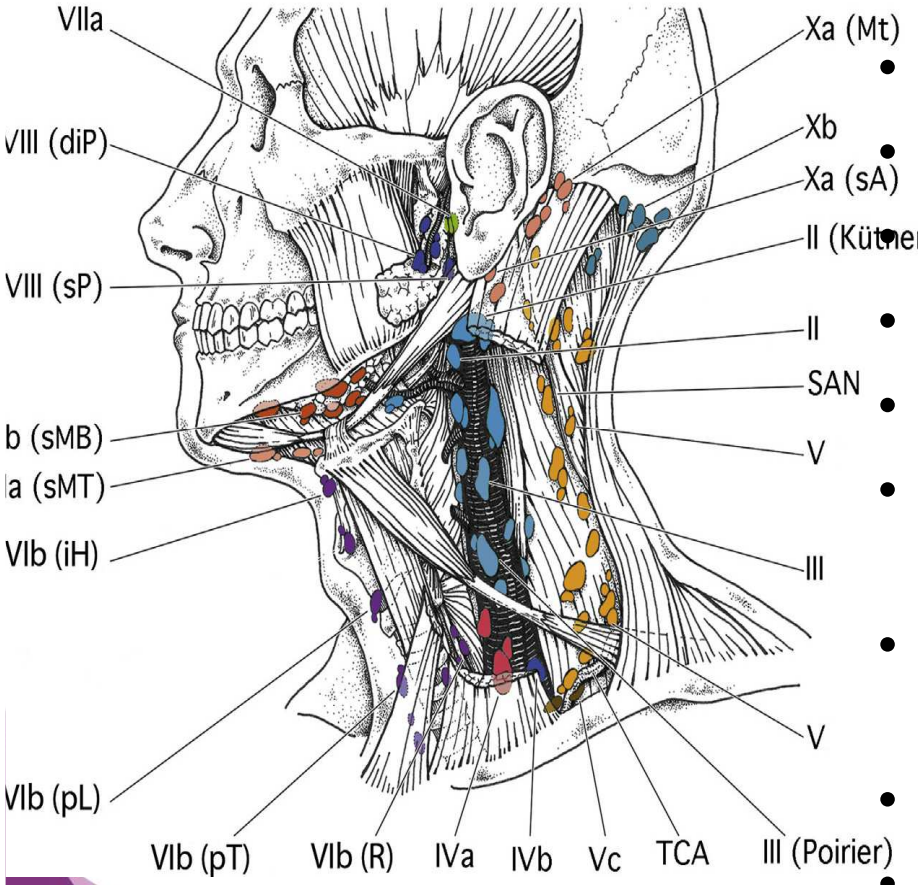

Gregoire et al. *Delineation of the neck node levels for head and neck tumors: A 2013 update. DAHANCA, EORTC, HKNPCSG, NCIC CTG, NCRI, RTOG, TROG consensus guidelines* Radiotherapy and

- Ia Submental group
- Ib Submandibular group
- II Upper jugular group
- III Middle jugular group
- IVa Lower jugular group
- IVb Medial supraclavicular group
- Va - Upper posterior triangle nodes
- Vb - Lower posterior triangle nodes
- Vc Lateral supraclavicular group
- VIa Anterior jugular nodes
- VIb - Prelaryngeal, pretracheal, &

ESTRO School

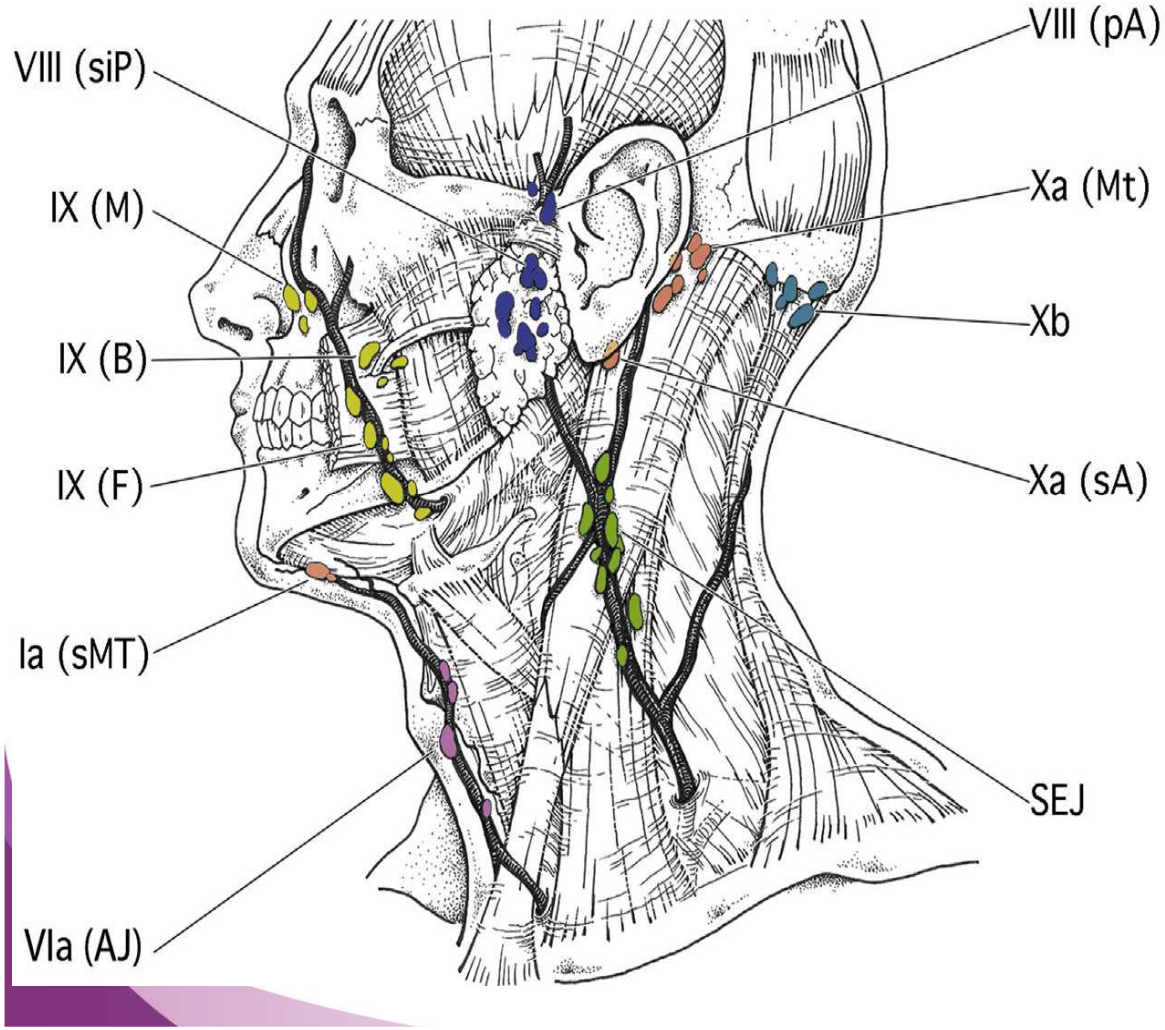

- VIII Parotid group
- IX Bucco-facial group
- X Posterior skull group:
  - Xa - Retroauricular & subauricular nodes
  - Xb - Occipital nodes

ESTRO School

Level VII retropharyngeal nodes

- In retropharyngeal space from skull base to upper border of hyoid. VIIa: medial; VIIb lateral
- Bordered laterally by medial wall of carotid artery

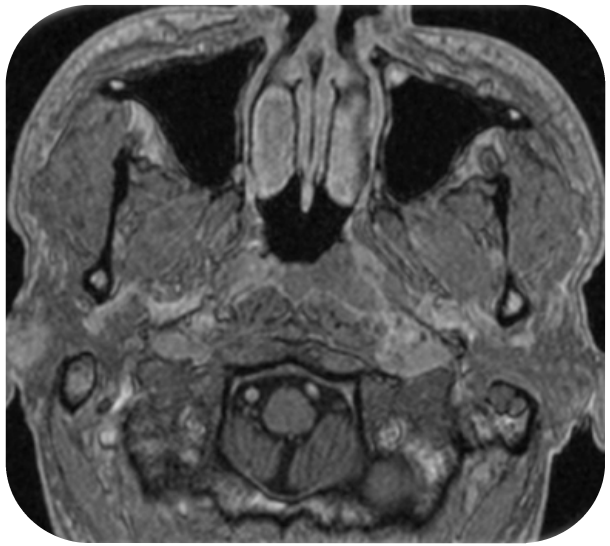

ESTRO School

Diagnostic vs. Planning CT

- Small field of view
- IV contrast
- Optimised scan planes

- Large field of view
- Often no contrast
- Strictly transverse planes

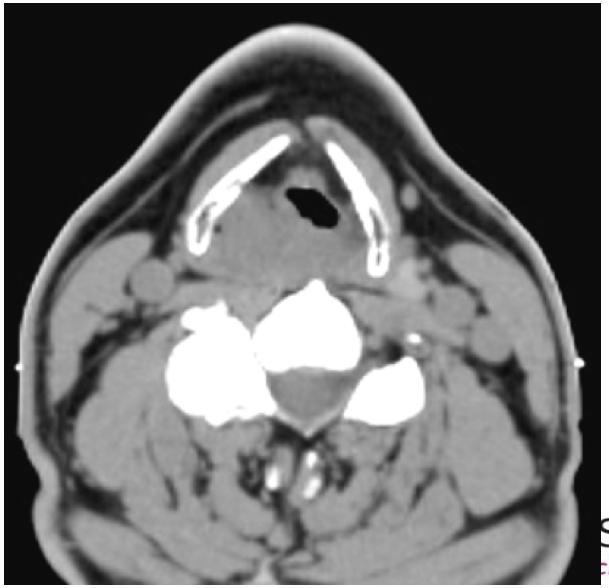

STRO
chool

Thank you for your attention

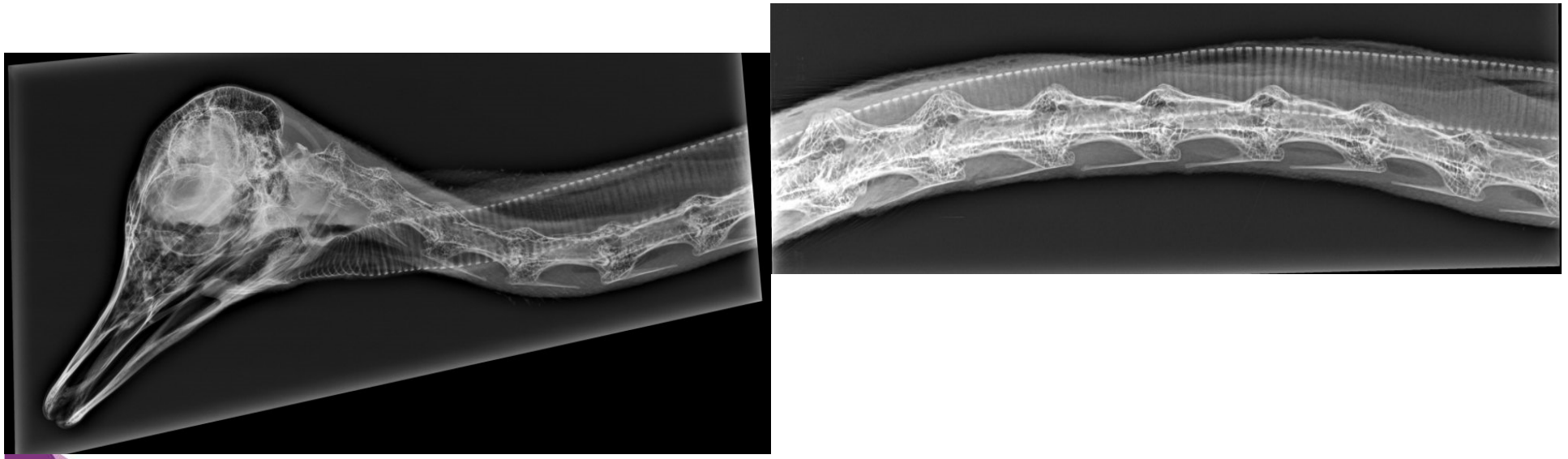

ESTRO School

ESTRO School

WWW.ESTRO.ORG/SCHOOL

The GTV/CTV of the primary tumor & metastatic lymph node/s Organs-at-risk in head-and-neck cancer

ESTRO Teaching Course

"Target Volume Determination: from Imaging to Margins"

Lisbon, Portugal, June 26, 2017

Indira Madani, M.D., Ph.D.

Nothing to disclose

ESTRO School

Questions

1. How to define the GTV in head-and-neck cancer?
2. How to define the CTV in head-and-neck cancer?
3. What are the GTV and CTV
    - after induction chemotherapy
    - in re-irradiation
    - in adaptive radiation therapy?
4. What are organs-at-risk and how to delineate them?

ESTRO School

Defining the GTV

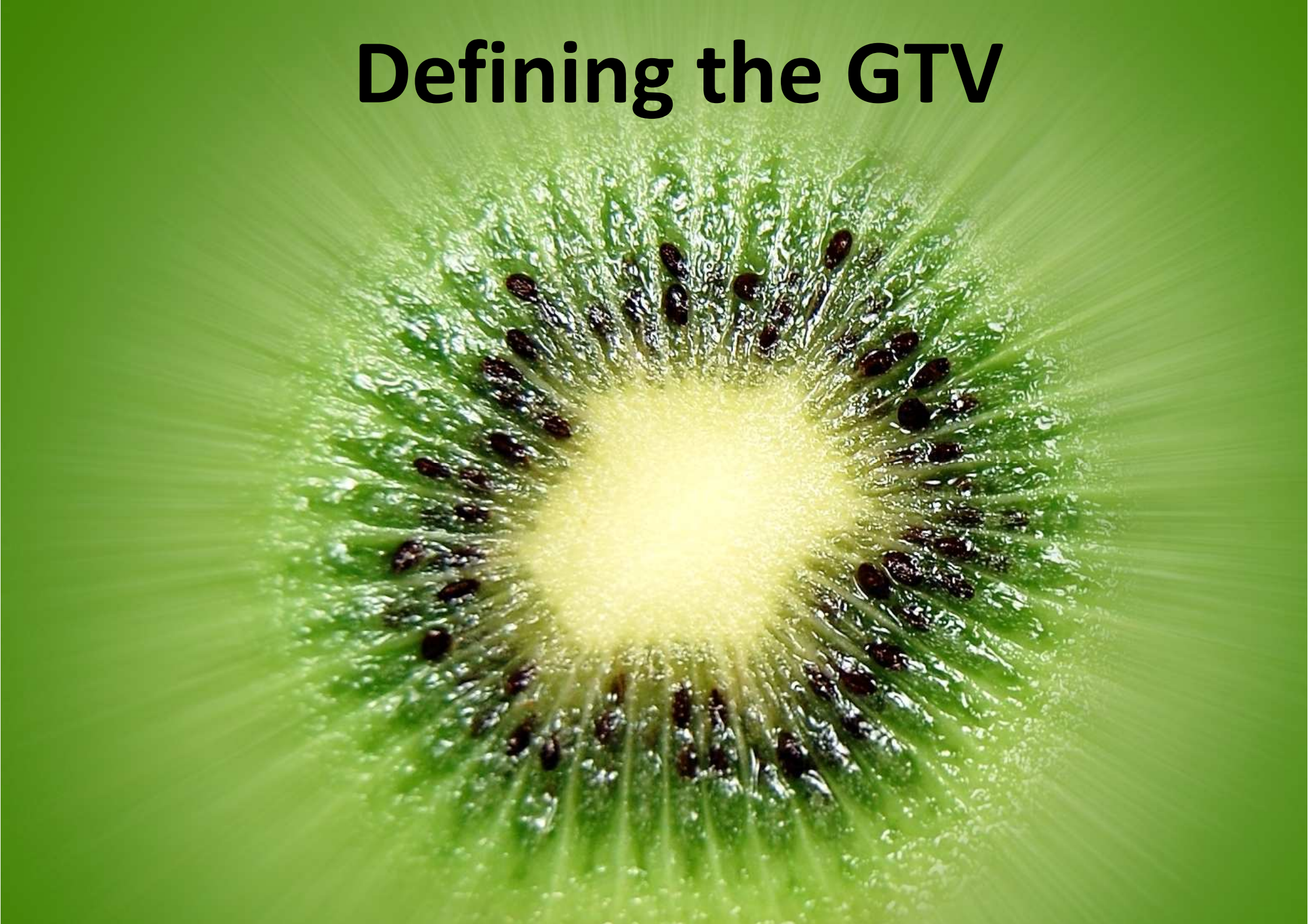

The GTV in head-and-neck cancer

- What imaging modality to use?
  - Modalities and techniques: CT (contrast-enhanced), MR, FDG-PET
    - Imaging-based volume vs. pathology-based volume
    - Topography of the primary tumor/lymph node metastasis recurrence
    - Clinical importance
- Interpreting images
  - Delineation guidelines as the part of treatment protocols

ESTRO School

Imaging-based vs. pathology-based GTV-T

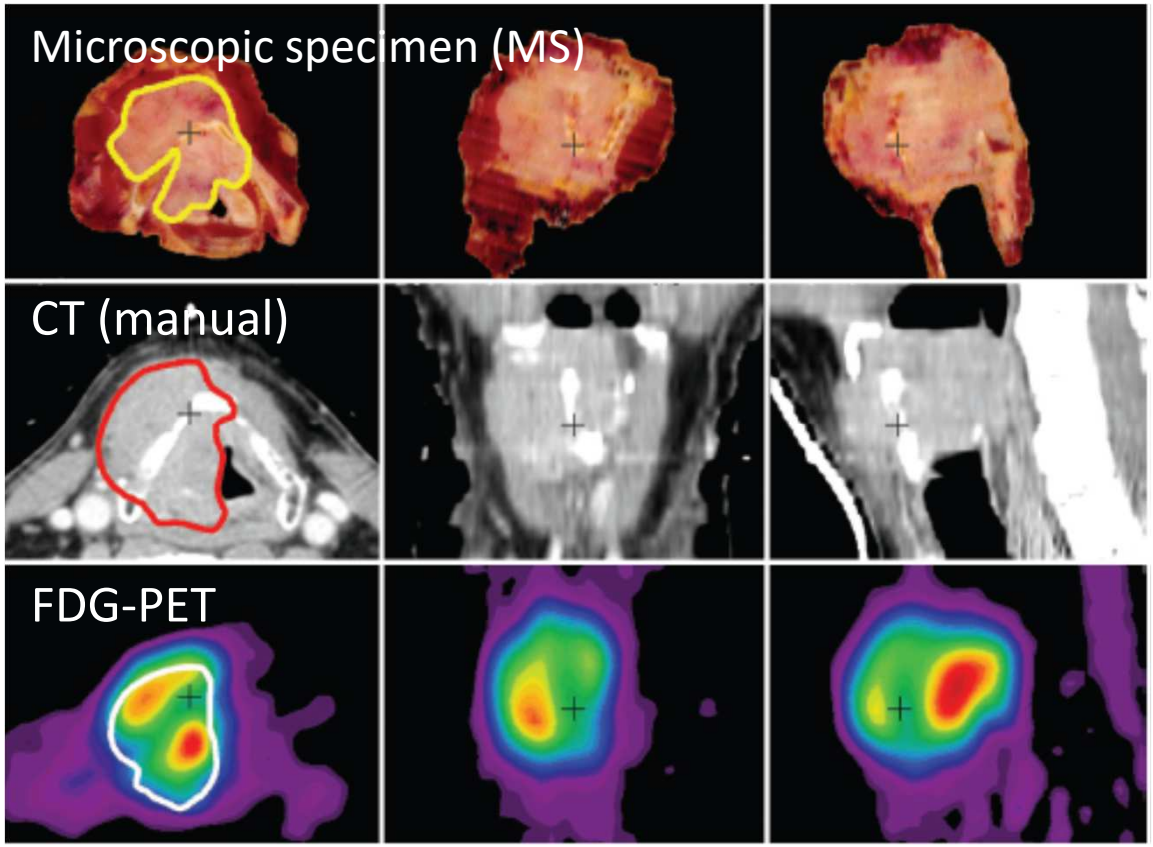

- 9 pts
  - SCC of the oro- and hypopharynx and larynx
  - Total laryngectomy
  - GTV-T (FDG-PET) autosegmentation: gradient-based method

Daisne et al. *Radiology* 2004;233:93-100.

ESTRO School

Imaging-based vs. pathology-based GTV-T

	Median GTV (cm3)	Δ (%)
Microscopic specimen	12.6	-
CT	20.8	+65
MR	23.8	+89
FDG-PET	16.3	+29

- GTV-T (FDG-PET) is smallest and closest to the “true” GTV followed by CT and MR.

Daisne et al. *Radiology* 2004;233:93-100.

ESTRO School

Imaging-based vs. pathology-based GTV-T

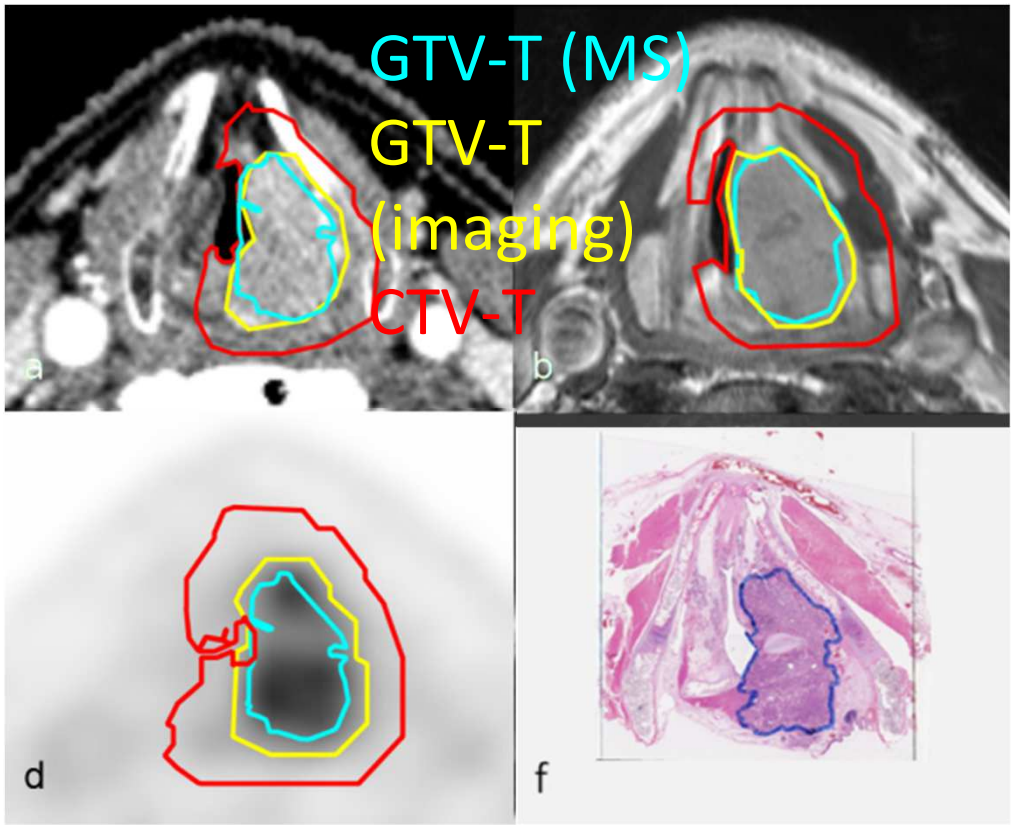

- 36 pts
  - T3-4 SCC of the hypopharynx or larynx
  - Total laryngectomy
  - GTV-T (FDG-PET) autosegmentation: Gaussian mixture model

Ligtenberg et al. *Radiat Oncol* 2017;123:63-70.

Imaging-based vs. pathology-based GTV-T

	Mean GTV (cm3)	Δ (%)
Microscopic specimen	15.7	-
CT	25.6	+63
MR	21.4	+36
FDG-PET	21.1	+34

- GTV-T (FDG-PET) is smallest and closest to the “true” GTV followed by MR and CT.

Ligtenberg et al. *Radiat Oncol* 2017;123:63-70.

ESTRO School

Topography of the GTV recurrence

- 39 pts
  - SCC of the oral cavity, pharynx or larynx
  - GTV (FDG-PET): manual delineation for treatment planning and autosegmentation for recurrence
  - 41 locoregional recurrences

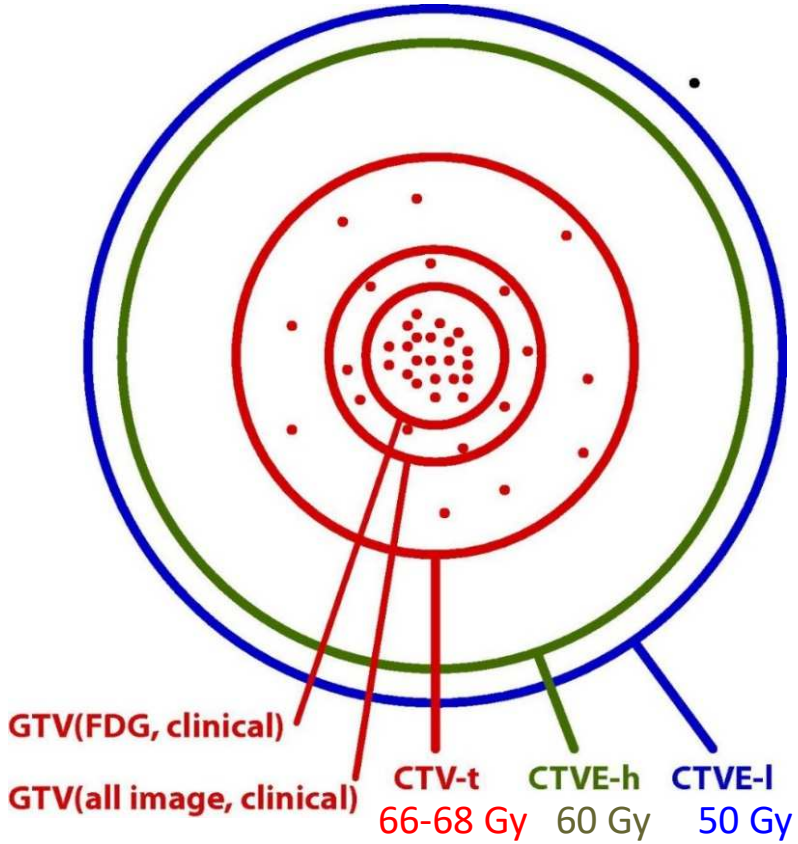

- 96% recurrences inside the ≥66 Gy volume
- 54% recurrences inside the GTV (FDG-PET)

Due et al. *Radiat Oncol* 2014;111:365-5.

ESTRO School

FDG-uptake and the GTV recurrence

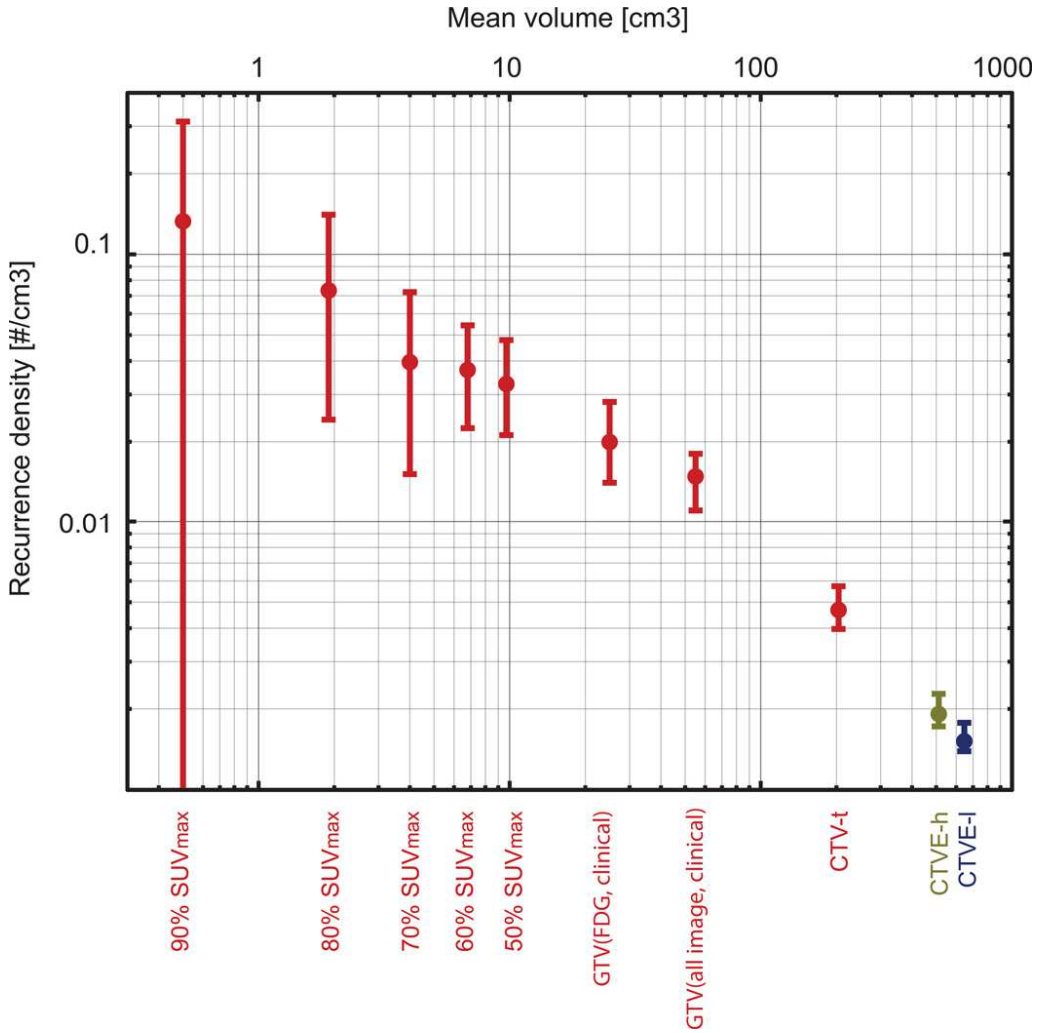

- Tumor recurrence occurs mainly in the most FDG-avid part of the GTV.

Due et al. *Radiat Oncol* 2014;111:365-5.

How to delineate the GTV (FDG-PET)

1. Manual:
    - Simple BUT
        - Time
        - Window-level settings
        - Inter- and intra-observer variability
        - MD specialty and experience

2. Autosegmentation:
    - Threshold-based (converting PET image voxels into SUV): simple and efficient BUT
        - SUV cut-off values
        - Partial volume effect, tumor heterogeneity, motion artefacts

Zaidi & Naqa. *Eur J Nucl Med Mol Imaging*:2010;37:2165-87.

ESTRO School

Threshold-based autosegmentation of the GTV-T (FDG-PET)

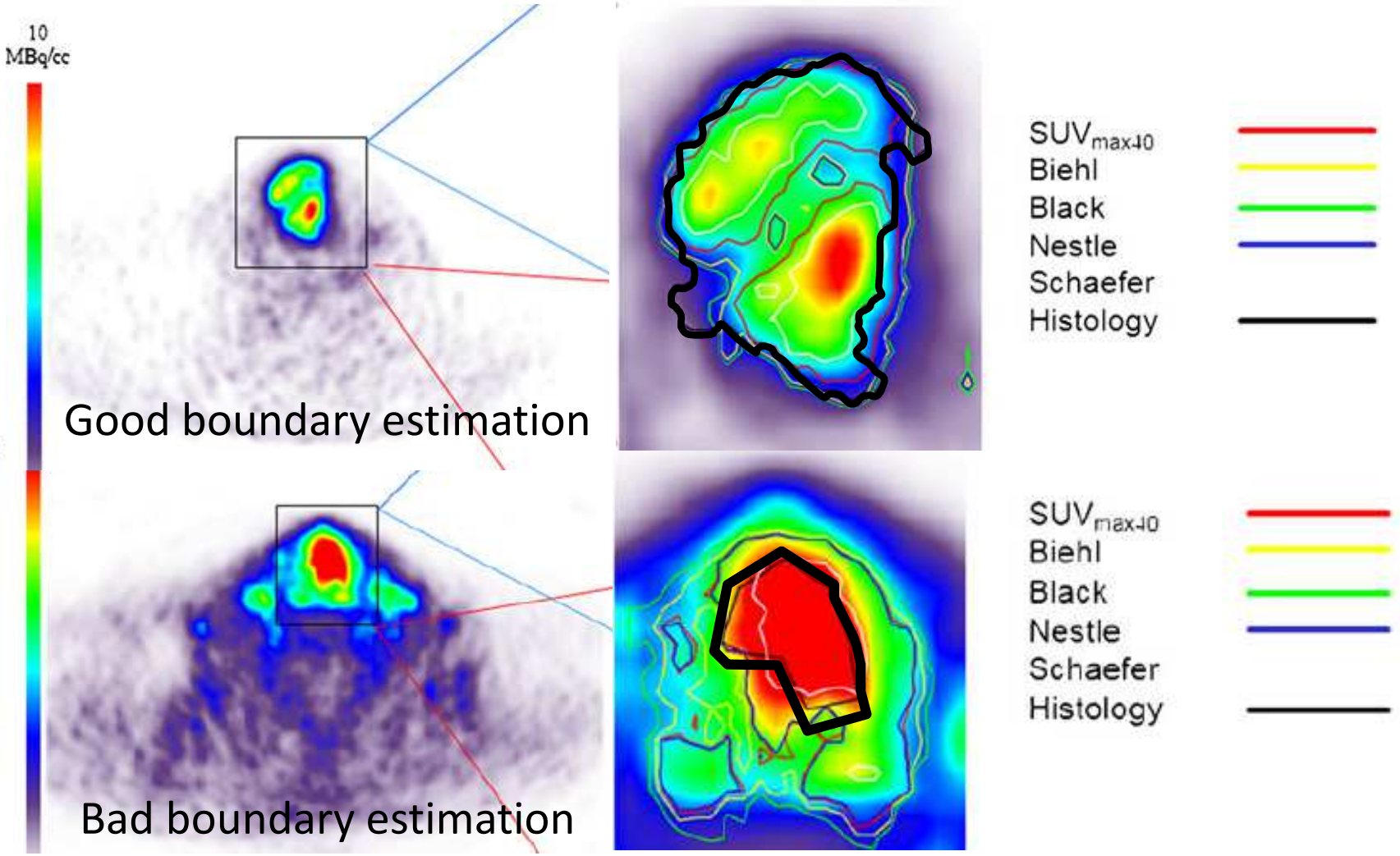

- FDG-PET should not be used on its own.

Zaidi et al. *Eur J Nucl Med Mol Imaging* 2012;39:881-91.

ESTRO School

What to consider in PET/CT radiation therapy planning

- Scanning protocol:
  - Patient preparation
- Acquisition:
  - Patient treatment positioning
- Reconstruction
- Analysis
- Treatment planning:
  - Target definition:
    - Registration errors – benchmark algorithms.

Jeraj et al. *J Nucl Med* 2015;56:1752-65.

ESTRO School

Value of FDG-PET for the GTV-T definition

- Pretreatment FDG-PET (SUV, uptake pattern, …) correlates with:
  - Local control
  - Disease-specific survival
  - Disease-free survival
- GTV delineation:
  - Manual: boundary definition of the GTV combined with CT and/or MR
  - Threshold-based: subvolume boost
- Smaller FDG-PET-based GTV-T
  - Smaller CTV-T and PTV-T
    - Better sparing of OARs
- Dose prescription:
  - Dose painting

Allal et al. *IJROBP* 2004;59:1295-300.
Koyasu et al. *AJR Am J Roentgenol* 2014;202:851-8.
Jeraj et al. *J Nucl Med* 2015;56:1752-65.
Gregoire et al. *JCO* 2015;33:3277-84.

Imaging-based vs. pathology-based GTV-N

- 12 pts/28 lymph node metastases
  - SCC of head-and-neck
  - Lymph node dissection
  - GTV-N (FDG-PET): manual delineation (PET_{VIS}) and threshold-based autosegmentation (PET_{SUV})

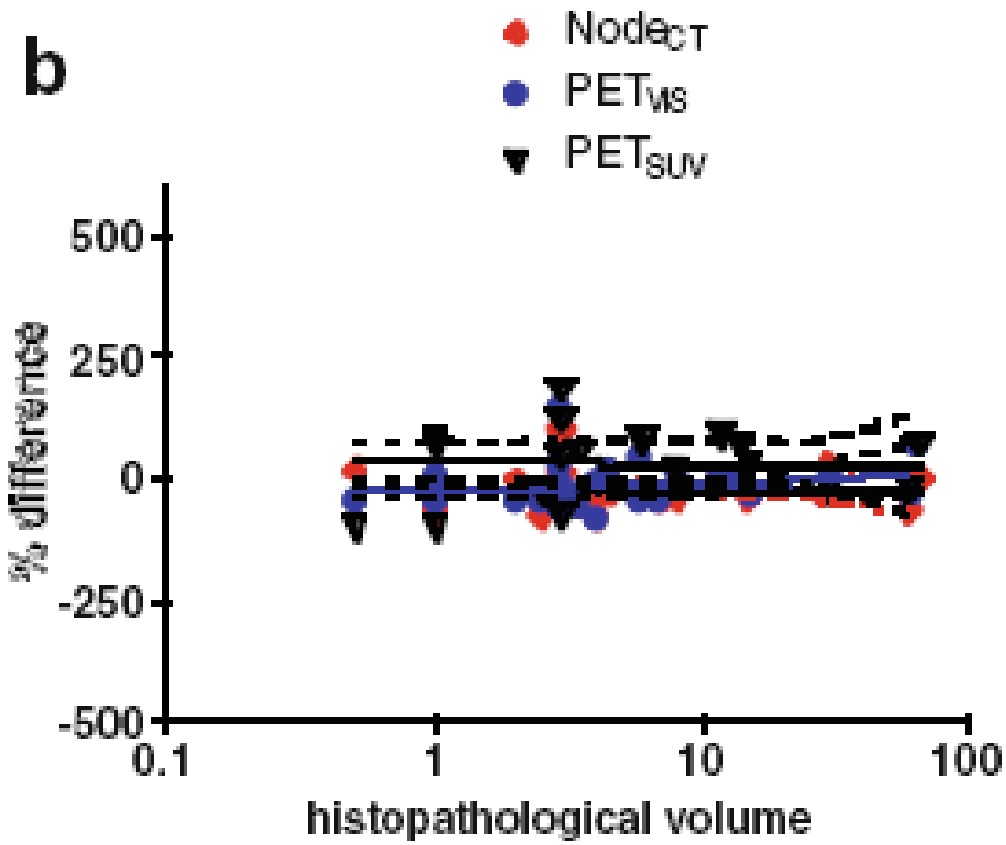

- FDG-PET slightly overestimates the volume of the GTV-N.
- The GTV-N (CT) is closest to the “true” GTV-N.

Schinagl et al. *Eur J Nucl Med Mol Imaging* 2013;40:1828-35.

ESTRO School

Defining the CTV

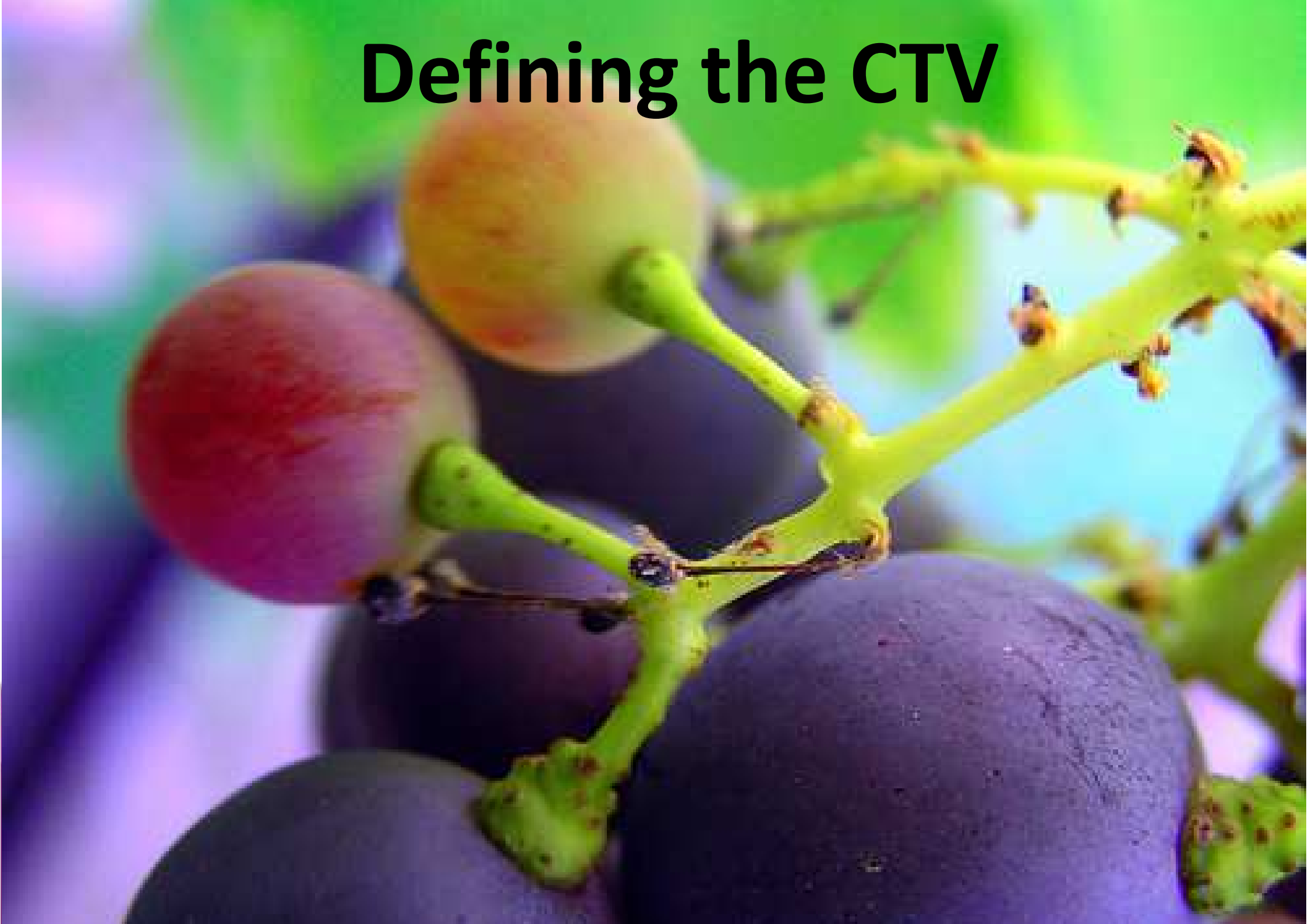

The CTV in head-and-neck cancer

- ‘‘Delineation of the CTV is currently based on clinical experience”.

- Imaging-based volume vs. pathology-based volume:
  - Microscopic disease – “tumor cells lying outside the gross tumor that could only be identified at a microscopic level”.
  - Microscopic disease probability 5-10%
  - Margins

- Delineation methods:
  - Volumetric (isotropic) expansion using margins.
  - Anatomic/compartmental: including anatomic compartments bounded by anatomic barriers.

ICRU report 83. 2010;10:41-46.
Camplbell et al. *IJROBP* 2012;82:574-81.

ESTRO School

Microscopic disease: implications for the CTV-T

- 10 pts
  - T1-3 SCC of the oral cavity

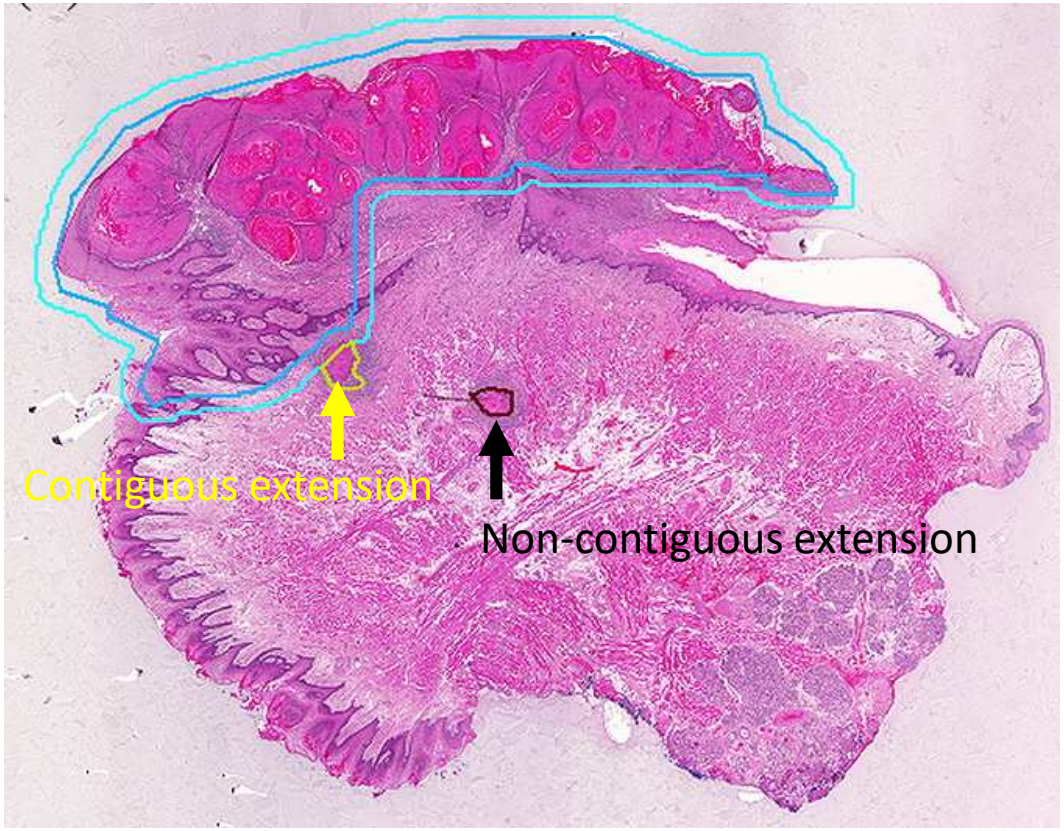

- 50% of pts had microscopic disease.
- 26.7% of pts had no-contiguous microscopic disease.

Camplbell et al. *IJROBP* 2012;82:574-81.

ESTRO School

Microscopic disease: implications for the CTV-T

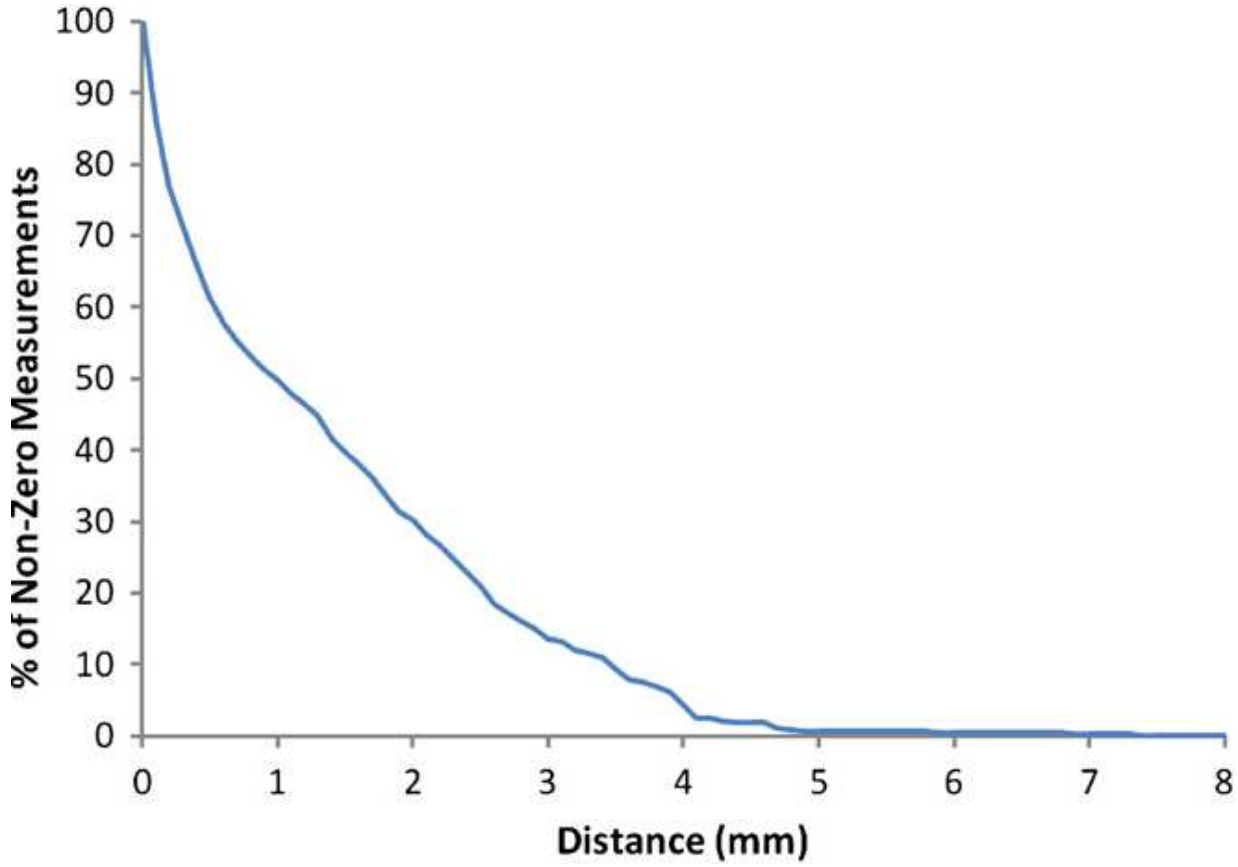

- A 3.95 mm margin - 95% of patients with microscopic disease.
- 4.75 mm margin - 99% of patients with microscopic disease.

Camplbell et al. *IJROBP* 2012;82:574-81.

ESTRO School

Microscopic disease: implications for the GTV-T

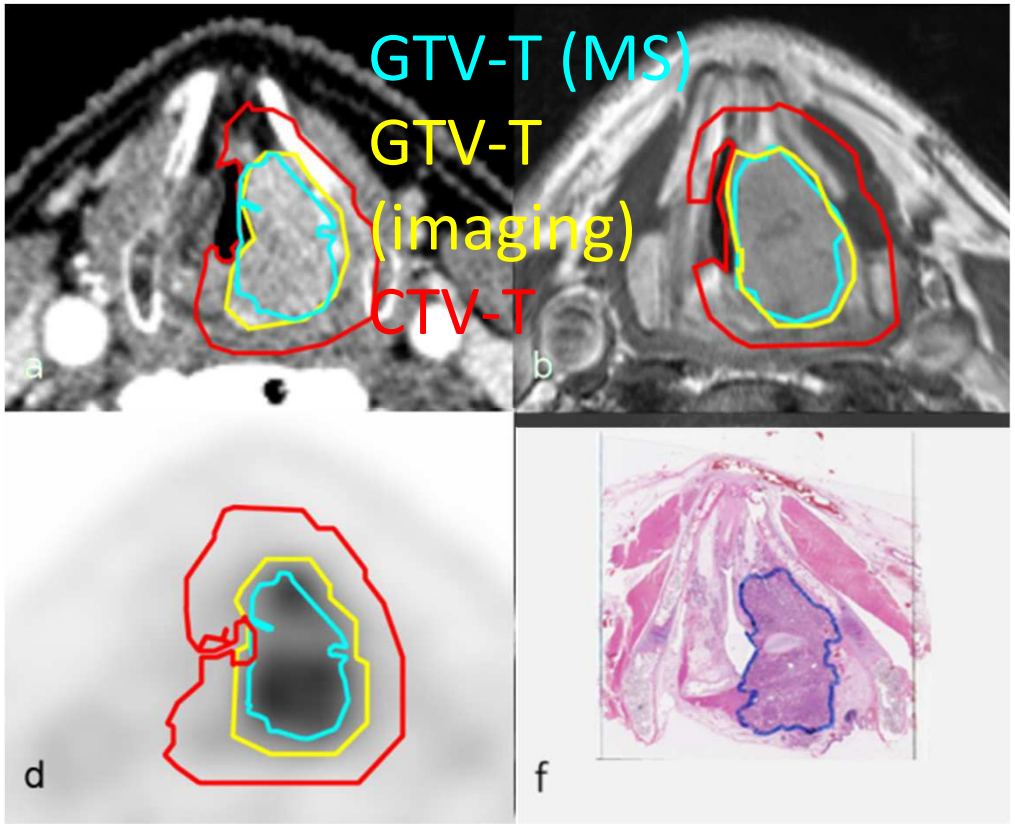

- 36 pts
  - T3-4 SCC of the hypopharynx or larynx
  - Total laryngectomy
  - Margin – 95% coverage of GTV-T (MS) not included in GTV-T (CT,MR,FDG-PET) in 95% of pts.

Ligtenberg et al. *Radiat Oncol* 2017;123:63-70.

ESTRO School

The pathology-based CTV margins

	Margin (mm)	Mean volume (ml)	Δ (%)
Pathology-based GTV	-	15.7	-
CTV-T (CT) clinical	10	90.6	477
CTV-T (CT)	4.3	54.5	247
CTV-T (MR)	6.1	58.8	275
CTV-T (FDG-PET)	5.2	50	218

- Tumor volume not included in the imaging-based CTV <0.01 ml.
- No no-contiguous microscopic disease.

Ligtenberg et al. *Radiat Oncol* 2017;123:63-70.

ESTRO School

Microscopic disease: implications for the CTV-N

- 96 cervical lymph node metastases
  - SCC of head-and-neck
  - Extracapsular extension
  - GTV-N ≤3 cm

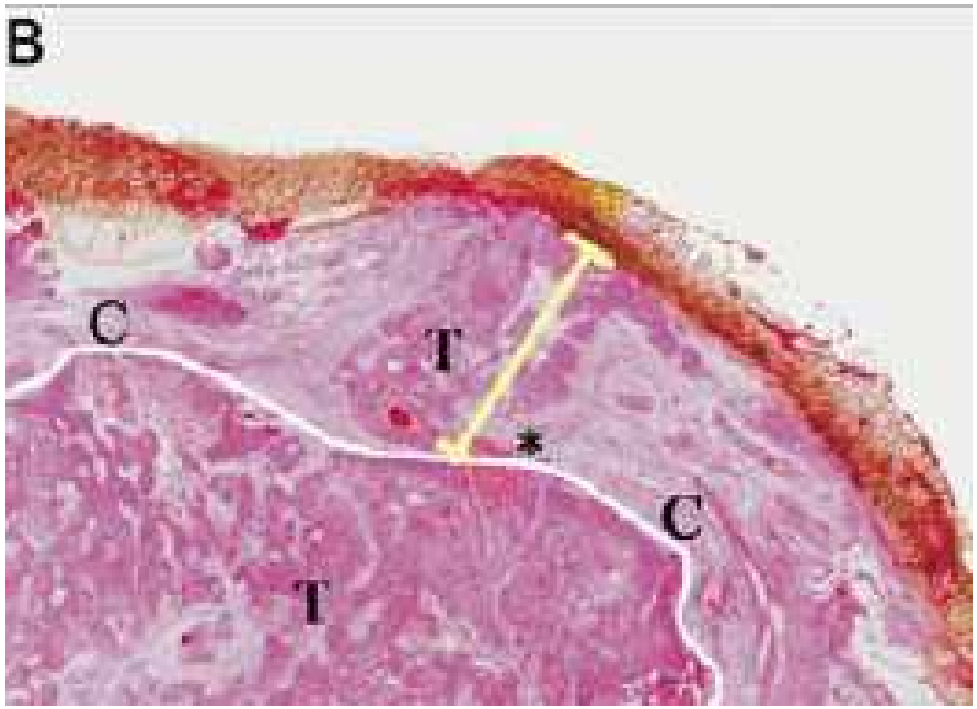

- Mean ECE 2.2 mm, median ECE 1.6 mm.
- 96% of lymph nodes had ECE <5 mm.

Apisarnthanarax et al. *IJROBP* 2006;64:678-83.

ESTRO School

Microscopic disease: implications for the CTV-N

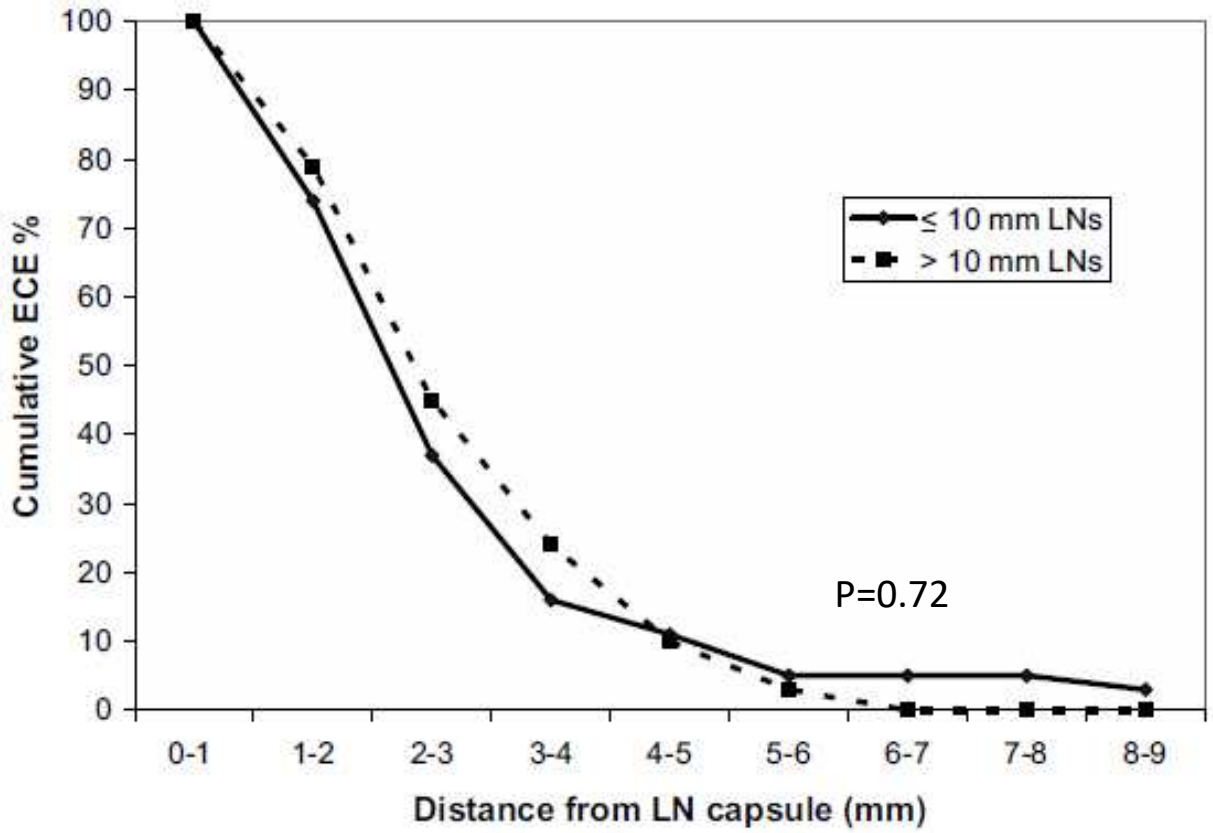

- A 10 mm margin is sufficient for IMRT.
- A 13-15 mm margin from the block edges - for 3D-CRT.

Apisarnthanarax et al. *IJROBP* 2006;64:678-83.

ESTRO School

Induction Chemotherapy
Re-Irradiation

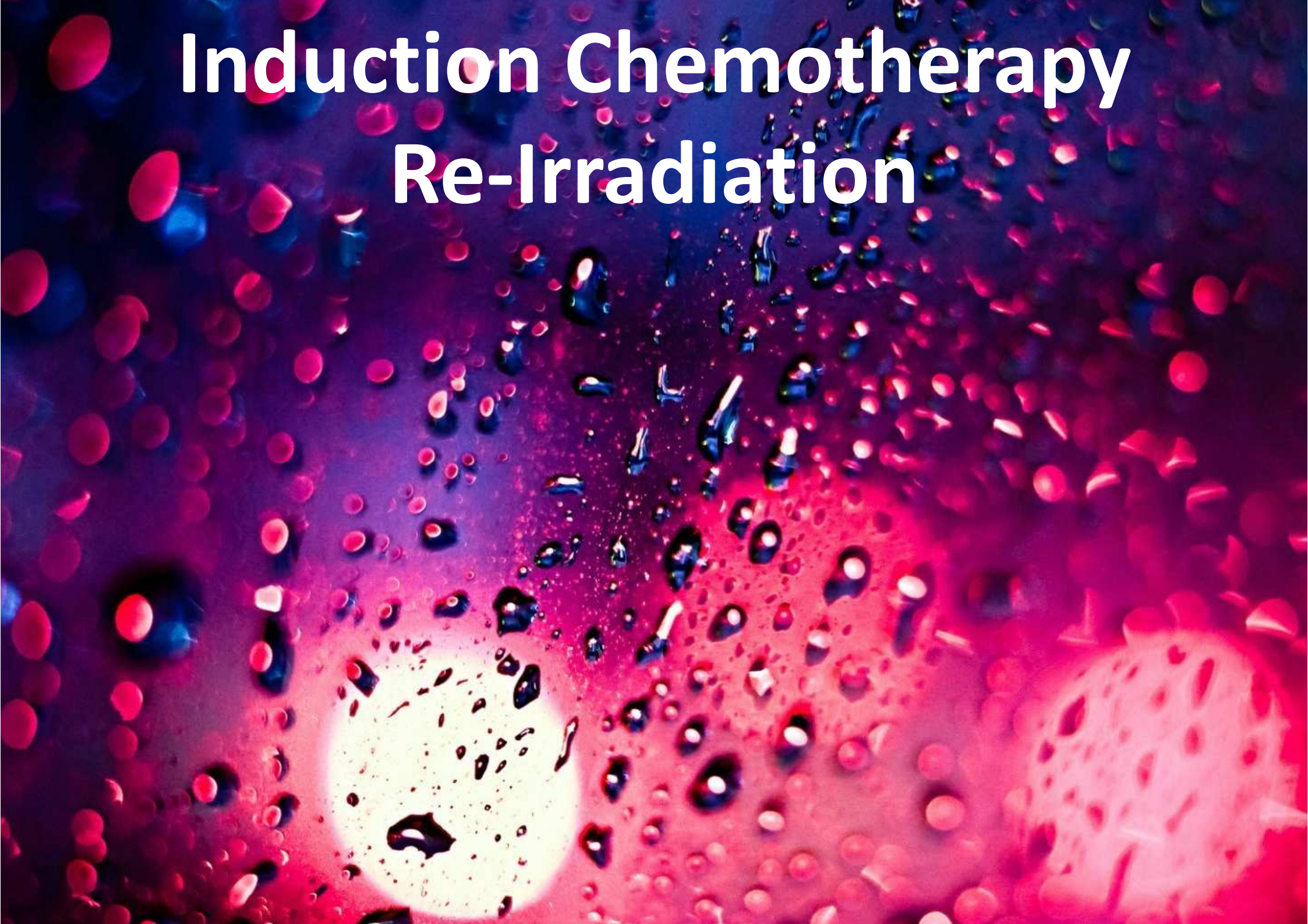

The GTV and CTV after induction chemotherapy (IC)

ELSEVIER

Int. J. Radiation Oncology Biol. Phys., Vol. 75, No. 3, pp. 725–733, 2009
Copyright © 2009 Elsevier Inc.
Printed in the USA. All rights reserved
0360-3016/09/$–see front matter

doi:10.1016/j.ijrobp.2008.11.059

CLINICAL INVESTIGATION **Head and Neck**

CLINICAL PRACTICE GUIDANCE FOR RADIOTHERAPY PLANNING AFTER INDUCTION CHEMOTHERAPY IN LOCOREGIONALLY ADVANCED HEAD-AND-NECK CANCER

JOSEPH K. SALAMA, M.D.,* ROBERT I. HADDAD, M.D.,† MERRIL S. KIES, M.D.,‡ PAUL M. BUSSE, M.D., PH.D.,§ LEI DONG, PH.D.,‡ DAVID M. BRIZEL, M.D.,¶ AVRAHAM EISBRUCH, M.D.,‖ ROY B. TISHLER, M.D., PH.D.,† ANDY M. TROTTI, M.D.,# AND ADAM S. GARDEN, M.D.‡

- The pre-IC GTV/CTV of the primary tumor & metastatic lymph node.
- All structures involved by the tumor before IC, should be included.

ESTRO School

The GTV and CTV in re-irradiation

Recurrent and second primary squamous cell carcinoma of the head and neck: When and how to reirradiate

Primož Strojan, MD, PhD,[1] June Corry, MD,[2] Avraham Eisbruch, MD,[3] Jan B. Vermorken, MD, PhD,[4] William M. Mendenhall, MD,[5] Anne W. M. Lee, MD, FRCR, FHKCR, FHKAM,[6] Missak Haigentz Jr, MD,[7] Jonathan J. Beitler, MD,[8] Remco de Bree, MD, PhD,[9] Robert P. Takes, MD, PhD,[10] Vinidh Paleri, MS, FRCS (ORL-HNS),[11] Charles G. Kelly, MB, ChB, MSc, FRCP, FRCR,[12] Eric M. Genden, MD,[13] Carol R. Bradford, MD,[14] Louis B. Harrison, MD,[15] Alessandra Rinaldo, MD, FRCSEd ad hominem, FRCS (Eng, Ir) ad eundem, FRCSGlasg,[16] Alfio Ferlito, MD, DLO, DPath, FRCSEd ad hominem, FRCS (Eng, Glasg, Ir) ad eundem, FDSRCS ad eundem, FHKCORL, FRCPath, FASCP, IFCAP[16*]

- The GTV as any GTV-T and/or GTV-N.
- The CTV: no or a ~5 mm margin.

Strojan et al. *Head Neck* 2015;37:134-50.

ESTRO School

Adaptation

GTV (CT) volume changes during treatment

Reference	Radiotherapy technique	Per-treatment imaging time	Δ per-treatment volume/ pretreatment volume
Fang 2001	2DRT/3DCRT	Week 5	GTV-T: -62% GTV-N: -76%
Barker 2004	2DRT/3DCRT/IMRT	3/week	GTV-T: -1.7%/day GTV-N: -1.7%/day
Yang 2010	IMRT	Week 4-5	GTVsum:-36-47%
Height 2010	IMRT	Week 5	GTV-T: -50% GTV-N: -74%

Fang et al. *IJROBP* 2001;50:961-9.
Barker et al. *IJROBP* 2004;59:960-70.
Yang et al. *IJROBP* 2011;79:1096-103.
Height et al. *J Med Imaging Radiat Oncol* 2010;54:497-504.

ESTRO School

GTV-T (FDG-PET/CT) volume changes during adaptive IMRT

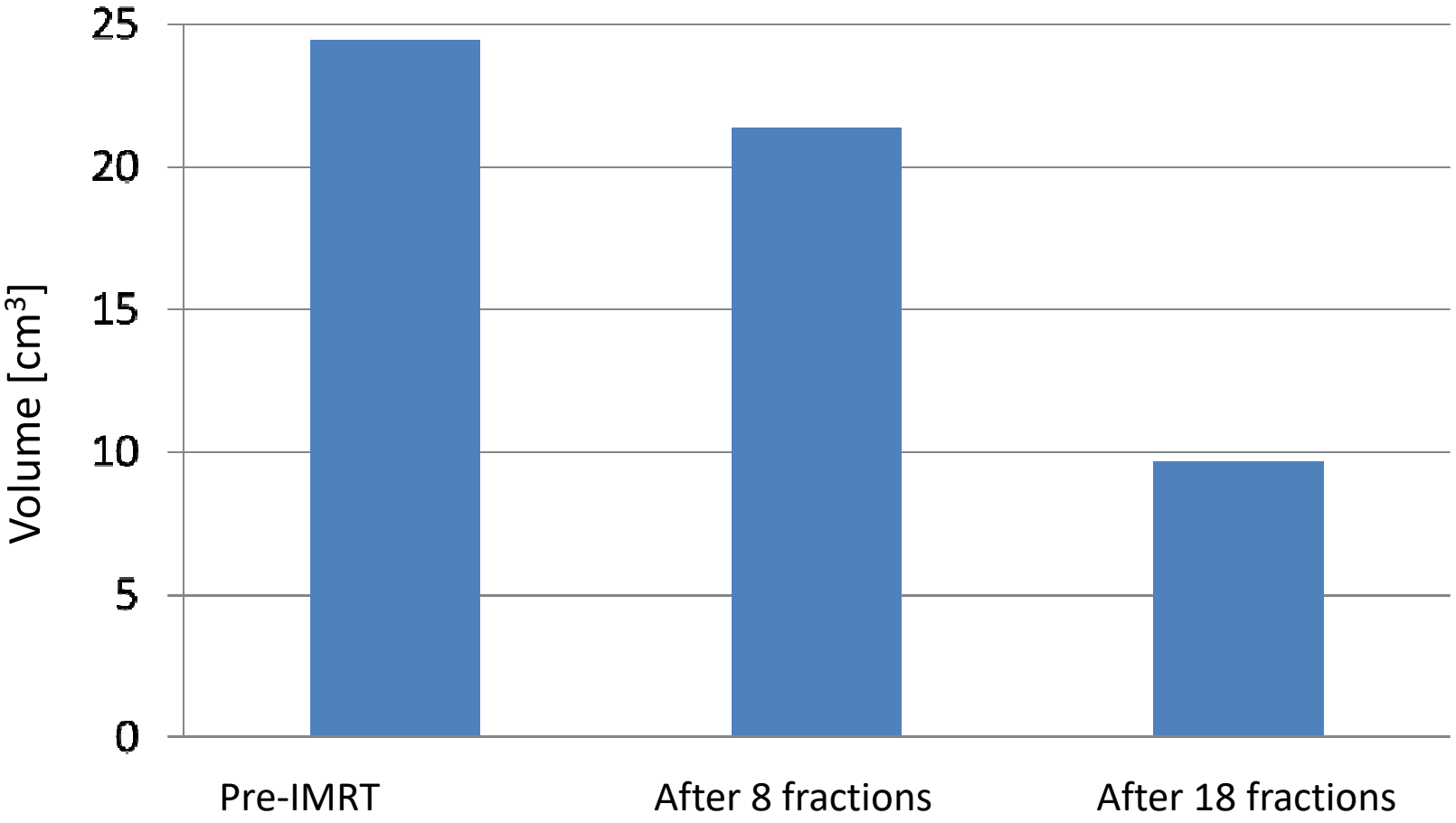

Berwouts et al. *Radiat Oncol* 2013;107:310-6.

Parotid gland volume changes during treatment

Reference	Radiotherapy technique	Per-treatment imaging time	Δ pretreatment volume/ per-treatment volume
Barker 2004	2DRT/3DCRT/IMRT	3/week	-0.6%/day
Nishimura 2006	IMRT	Week 3-4	-25%
Castadot 2010	IMRT	Week 2,3,4,5	Ipsilateral: -0.9%/day Contralateral: -1%/day
Ahn 2010	IMRT	Week 3	-24%

Barker et al. *IJROBP* 2004;59:960-70.
Nishimura et al. *IJROBP* 2006;64:355-62.
Castadot et al. *Radiother Oncol* 2010;95:209-17.
Ahn et al. *IJROBP* 2010;80:677-85.

ESTRO School

Adaptive radiation therapy

- Adaptive radiation therapy -

"a close-loop radiation treatment process where the treatment plan can be modified using a systematic feedback of measurements."

- Measurements:
    - Anatomic: position, shape and volume
    - Dosimetric
    - Biologic: defined by multi-parameter biologic imaging

Yan et al. *Phys Med Biol* 1997;42:123-32.

ESTRO School

Adaptive IMRT: Triggered (anatomic changes)

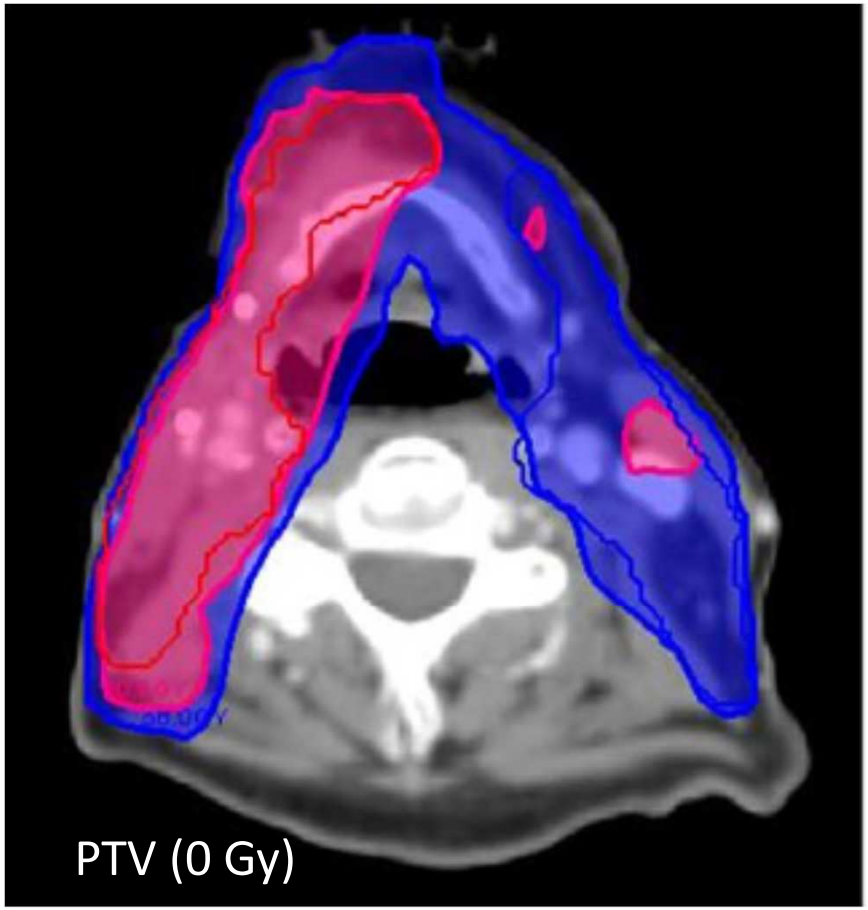

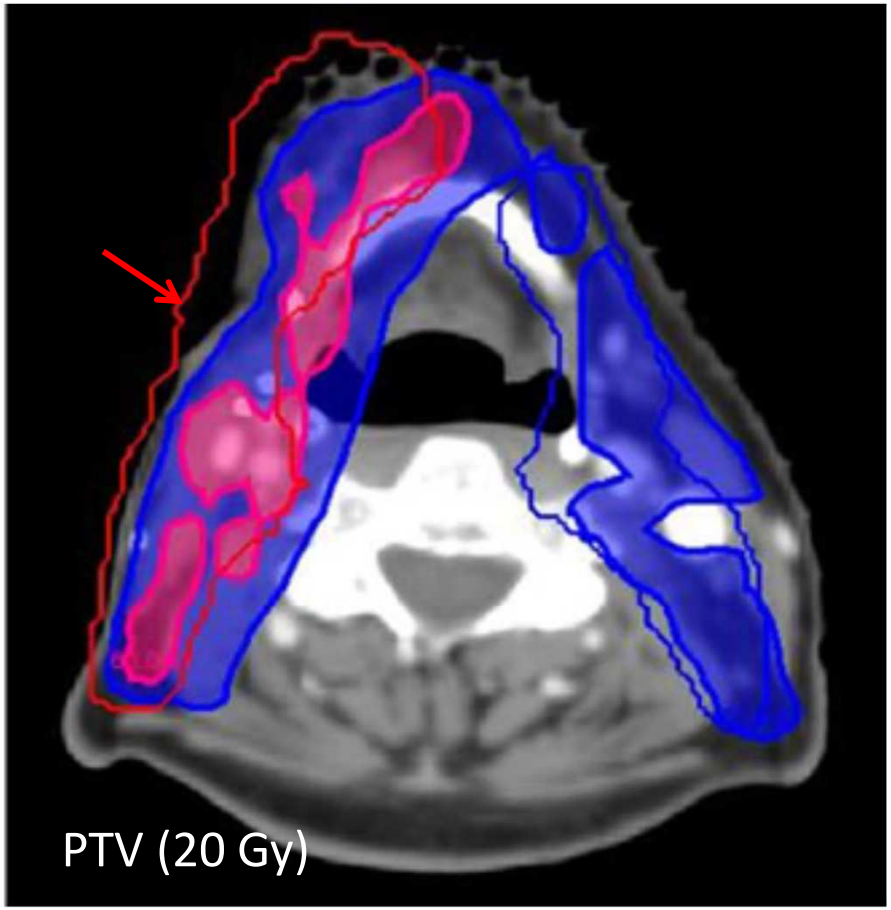

Chen et al. *Head Neck* 2014; 83:986-93.

ESTRO School

Adaptive IMRT: Triggered (dosimetric changes)

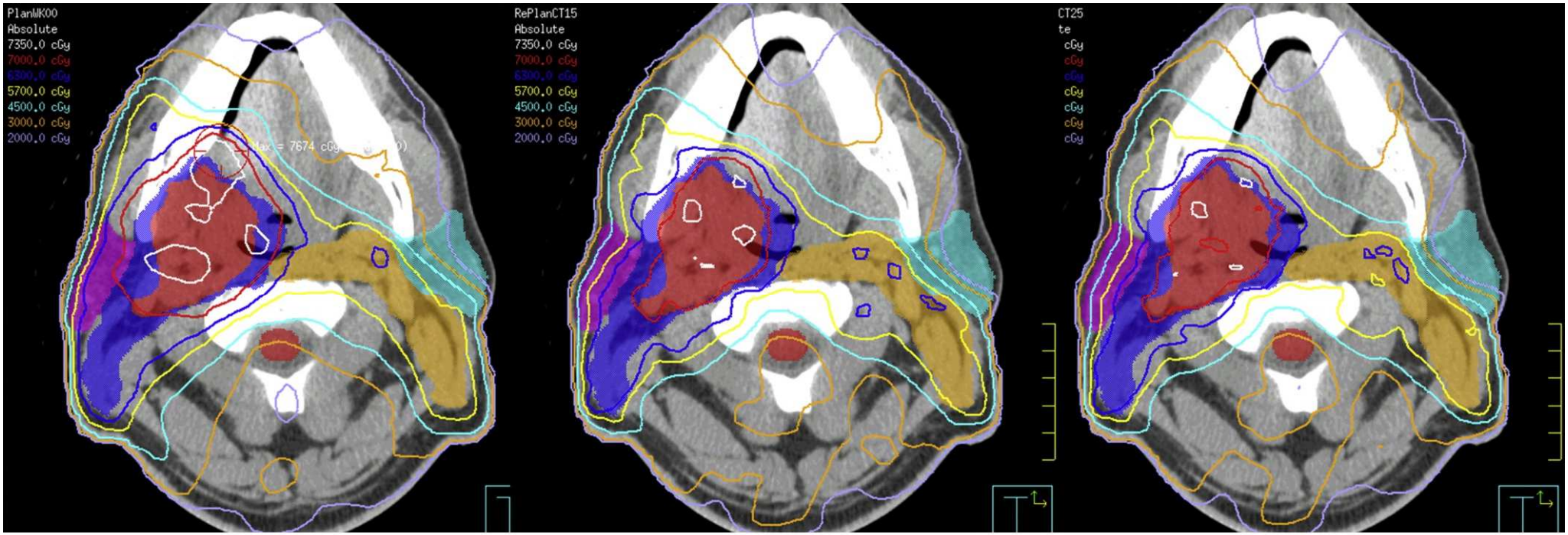

Orig.plan | 1st replan | 2nd replan

Schwartz et al. *IJROBP* 2012;83:986-93.

ESTRO School

Adaptive IMRT: Planned (biologic changes)

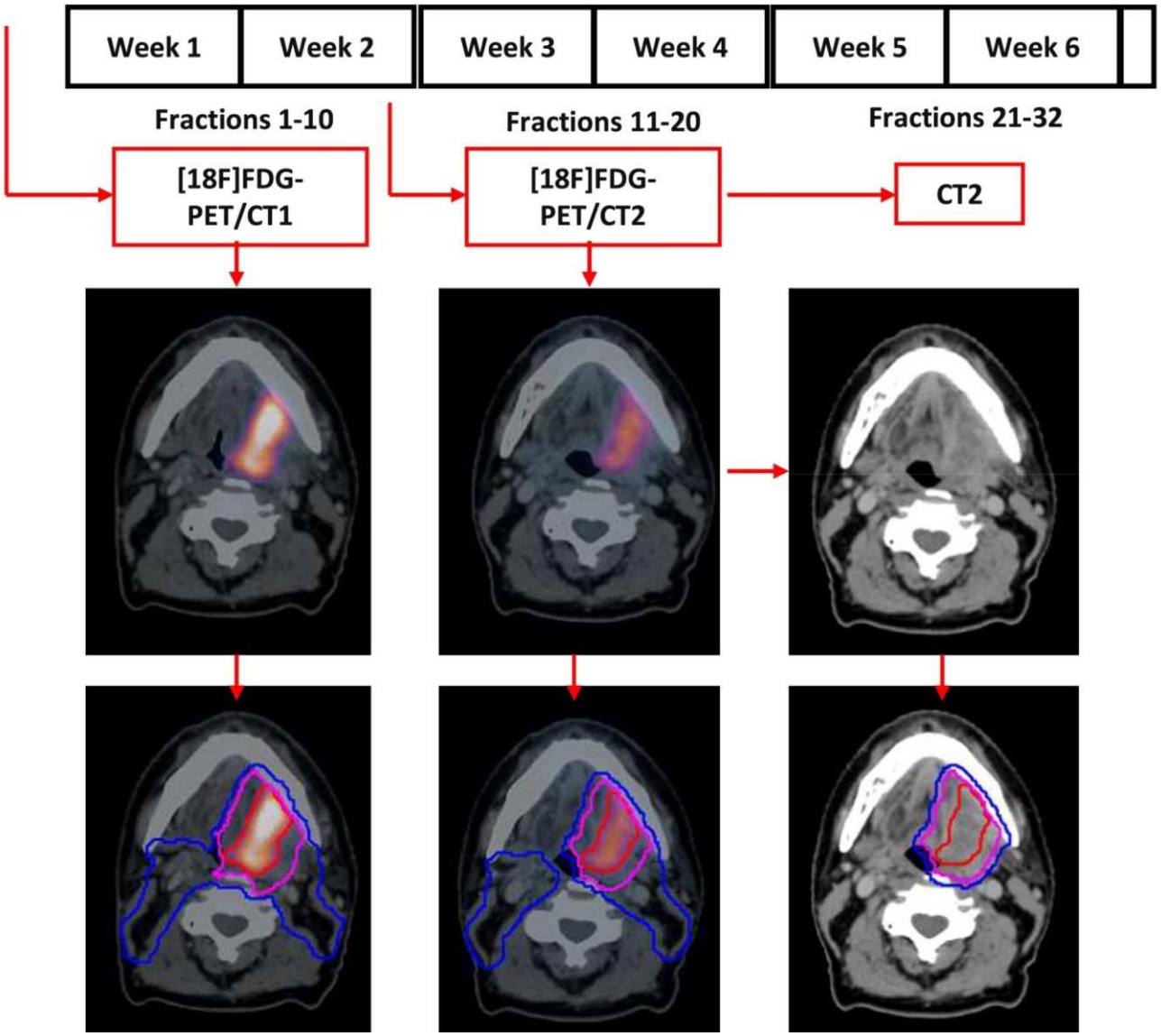

Duprez et al. *IJROBP* 2011;80:1045-55.

Adaptive IMRT

End-point/measurement	Triggered		Planned
	Anatomic	Dosimetric	Biologic
	n = 51	*n*=22	*n* = 21
Tumor site: oropharynx	22 (43%)	22 (100%)	11 (52%)
Other	29 (57%)	-	10 (48%)
Median follow-up (month)	30	31	25
2-year local control	-	100%	95%
2-year regional control	-	95%	93%
2-year locoregional control	78%	-	-
Topography of locoregional recurrence	4 high-dose PTV	Not reported	2 GTV (PET) 1 Elective neck

Chen at al. *Head Neck* 2014;83:986-93.
Schwartz et al. *IJROBP* 2012;83:986-93.
Madani et al. *Radiother Oncol* 2011;80:1045-55.

ESTRO School

Adaptive radiation therapy: what to consider

- Choosing measurements:
  - Anatomic changes
  - Biologic changes
  - Dosimetric changes
- Defining target volumes:
  - The pretreatment GTV/CTV adapted to changed OARs
  - The new GTV & the pretreatment CTV
  - The new GTV/CTV
- Delineation method:
  - Manual
  - Autopropagation (autosegmentation)
- Treatment planning, dose accumulation & reporting
- Logistics and resources

ESTRO School

Organs at Risk

Organs-at-risk (OARs): 2015 guidelines

Radiotherapy and Oncology xxx (2015) xxx–xxx

Contents lists available at ScienceDirect

Radiotherapy and Oncology

journal homepage: www.thegreenjournal.com

Original article

CT-based delineation of organs at risk in the head and neck region: DAHANCA, EORTC, GORTEC, HKNPCSG, NCIC CTG, NCRI, NRG Oncology and TROG consensus guidelines

Charlotte L. Brouwer [a,*,1], Roel J.H.M. Steenbakkers [a,1], Jean Bourhis [b], Wilfried Budach [c], Cai Grau [d], Vincent Grégoire [e], Marcel van Herk [f], Anne Lee [g], Philippe Maingon [h], Chris Nutting [i], Brian O'Sullivan [j], Sandro V. Porceddu [k], David I. Rosenthal [l], Nanna M. Sijtsema [a], Johannes A. Langendijk [a]

ESTRO School

OAR	PRV	Imaging	Delineation method
Spinal cord itself	Yes	CT/MR	Manual/autosegmentation
Brainstem itself	Yes	CT/MR	Manual/autosegmentation
Parotid/submandibular glands	No	CT/MR	Manual/autosegmentation
Mandible	No	CT	Manual/autosegmentation
Retina, optic nerve, optic chiasm	Yes	CT/MR	Manual
Lacrimal glands	No	CT/MR	Manual
Brain/brain structures	No	CT/MR	Manual/autosegmentation
Swallowing structures	No	CT/MR	Manual
Thyroid gland	No	CT	Manual
Oral cavity	No	CT/MR	Manual
Middle/inner ear	No	CT	Manual
Temporomandibular joint, masseter & pterygoid muscles	No	CT	Manual
Brachial plexus	Yes?	CT/MR	Manual
Cranial nerves	Yes?	CT/MR	Manual
Lungs & trachea	No	CT	Manual/autosegmentation
Carotid arteries	No	CT	Manual/autosegmentation

PRV = Planning organ-at-Risk Volume

ESTRO School

OARs: manual delineation or autosegmentation?

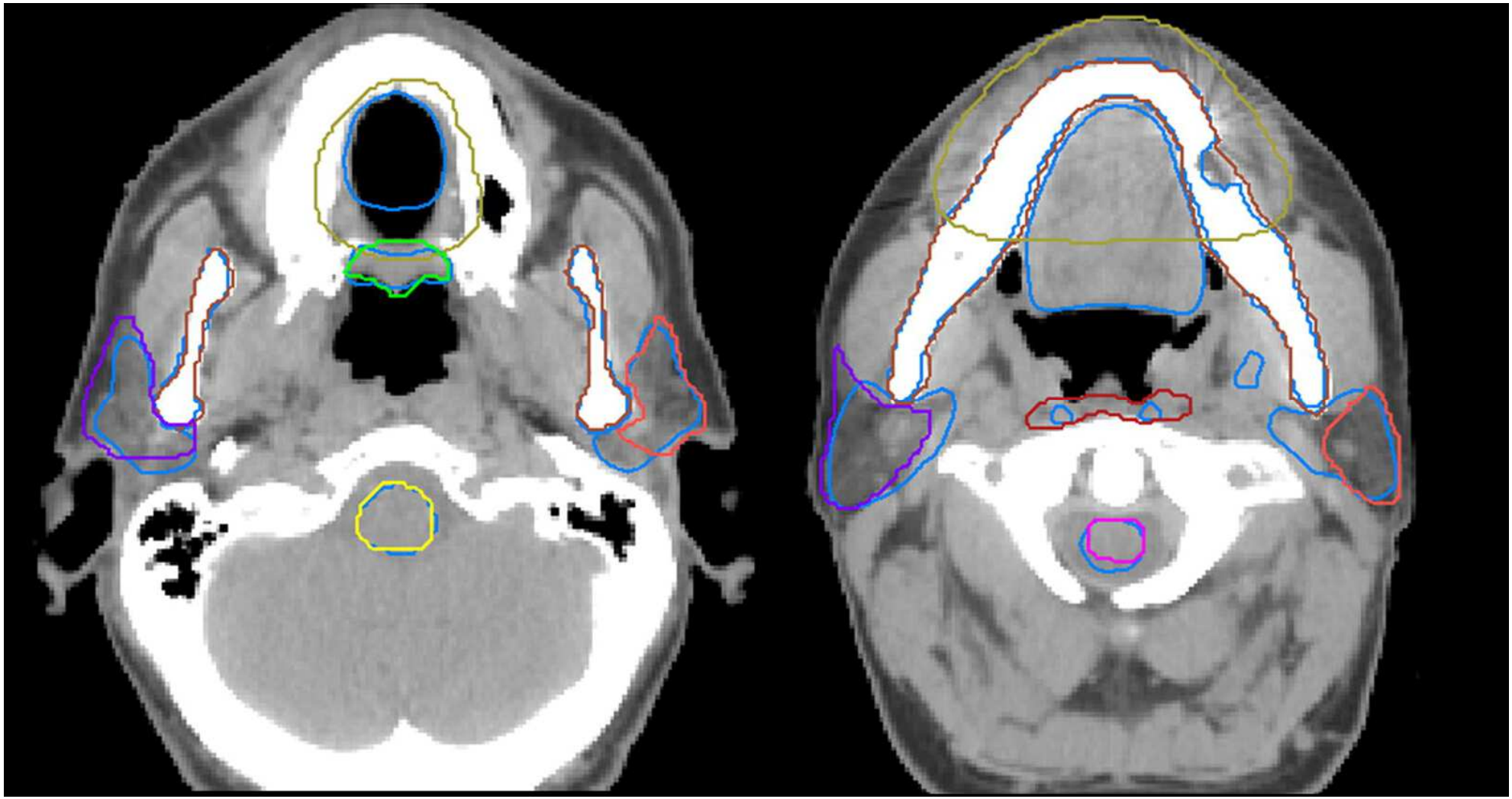

Walker et al. *Radiother Oncol* 2014;112:321-5.

ESTRO School

OARs: manual delineation or autosegmentation?

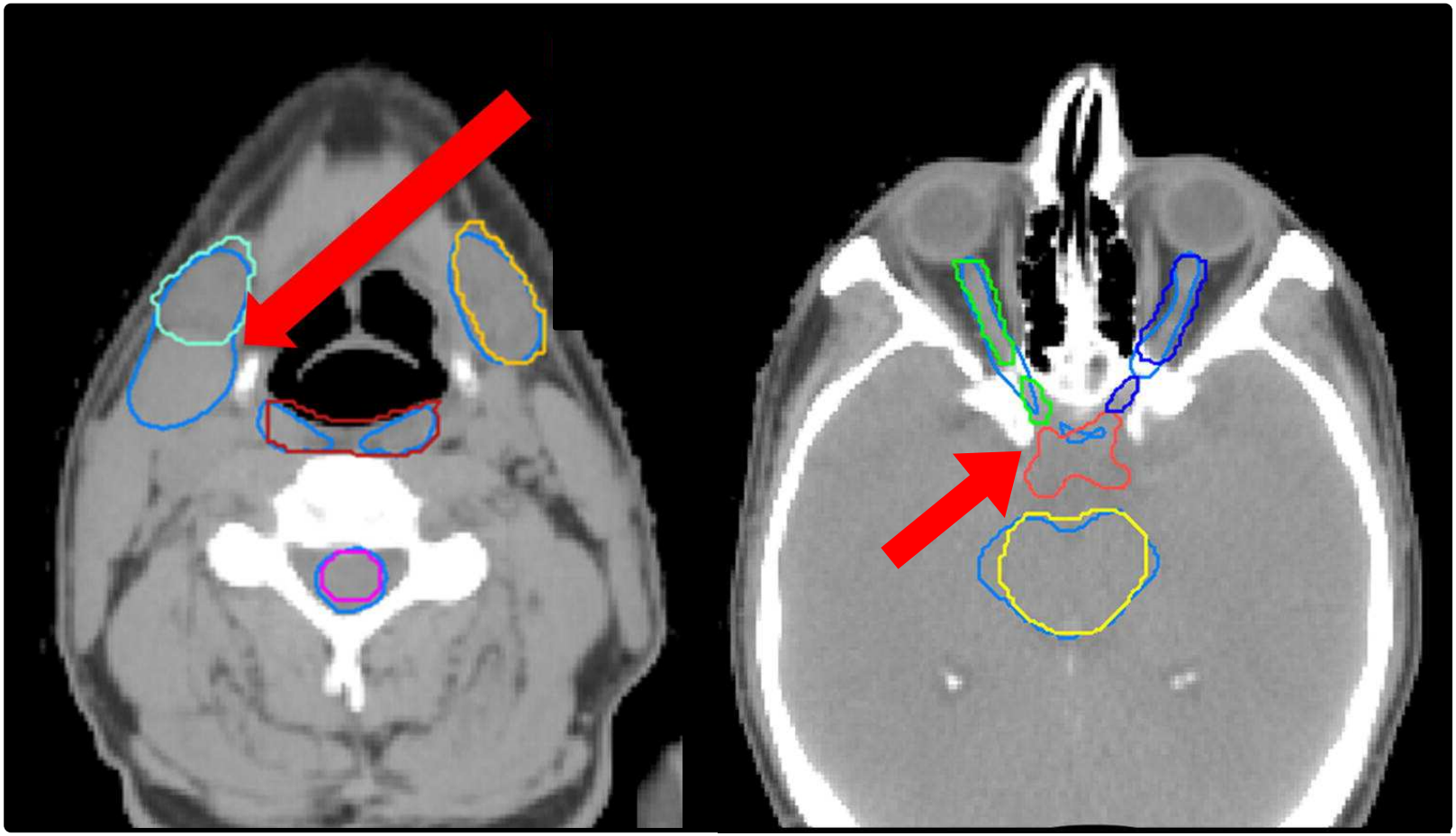

- Autosegmentation requires visual inspection and editing!

Walker et al. *Radiother Oncol* 2014;112:321-5.

ESTRO School

Take home messages

1. FDG-PET is value-added to define the GTV-T.
2. Contrast-enhanced CT is sufficient to define the GTV-N.
3. CTV-T margins are ≤10 mm.
4. The CTV-N margins are 10 mm for IMRT and 13-15 mm for 3D-CRT.
5. The GTV/CTV after induction chemotherapy are based on pretreatment imaging.
6. The CTV margins in re-irradiation are 0-5 mm.
7. Adaptive radiotherapy should become a standard, though a comprehensive treatment protocol should be thought out first.
8. OARs are delineated in accordance with the consensus 2015 guidelines.

ESTRO School

Post Scriptum

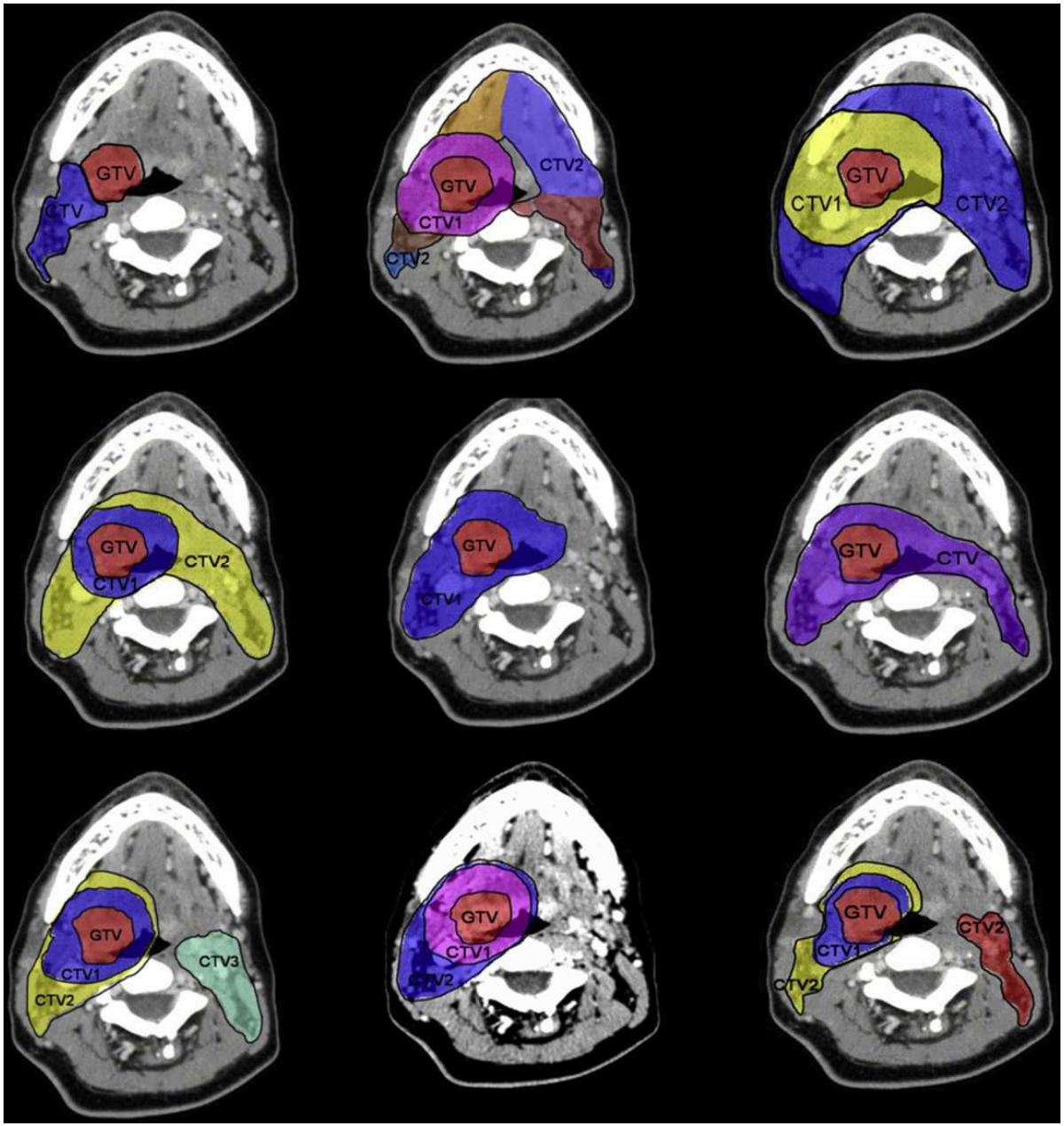

Hong, Tome, Harari. *Radiat Oncol* 2012;103:92-8.

ESTRO School

ESTRO School

WWW.ESTRO.ORG/SCHOOL

The clinical target volume (CTV) in elective neck irradiation for head-and-neck cancer

ESTRO Teaching Course
"Target Volume Determination: from Imaging to Margins"

Lisbon, Portugal, June 26, 2017

Indira Madani, M.D., Ph.D.

Nothing to disclose

ESTRO School

Elective

ADJECTIVE

(of surgical or medical treatment) chosen by the patient (doctor) rather than urgently necessary.

“elective surgery”

elective neck dissection

“elective irradiation”

elective neck irradiation

https://en.oxforddictionaries.com/definition/elective

ESTRO School

Lymph nodes of the extracranial head-and-neck

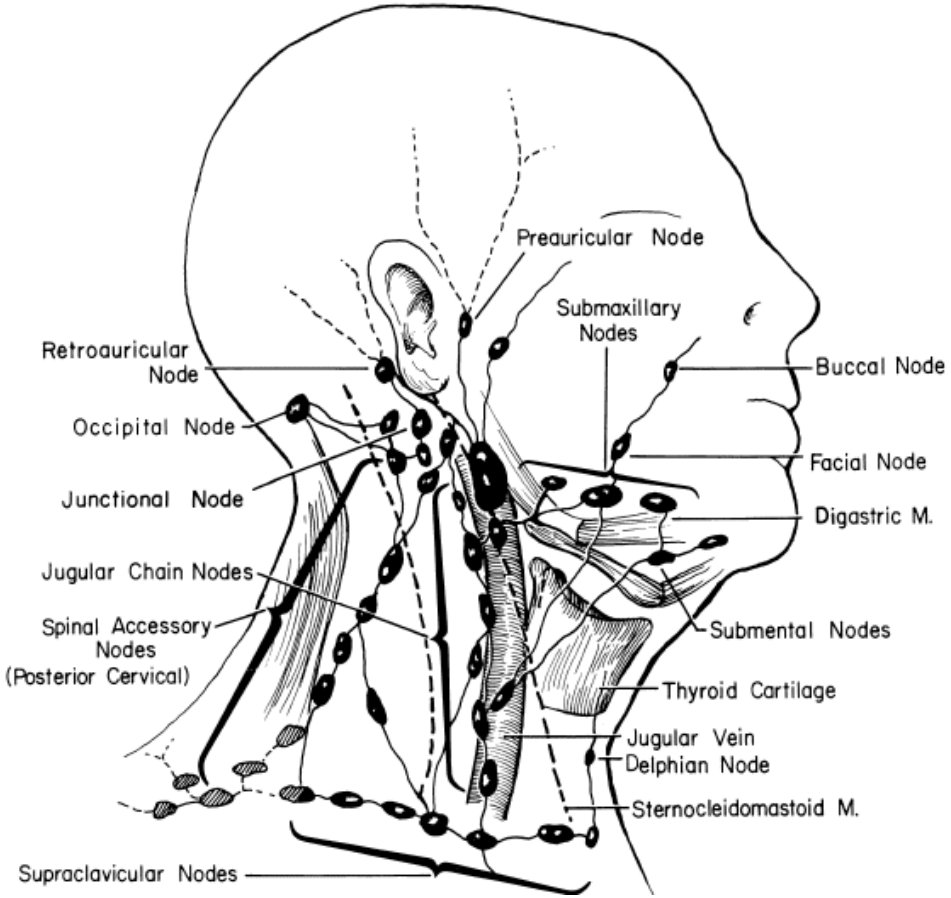

- >300 lymph nodes.
- Sequential & predictable patterns of metastasis.

Cervical lymph node metastases (Appendix 1)

- N0: treatment?

- N1-3 (N+): treatment!
- The neck minus N+: treatment?

AJCC Cancer Staging Atlas: A Companion to the Seventh Editions of the AJCC Cancer Staging Manual and Handbook. 2012.

Risks of no treatment of the “negative” neck

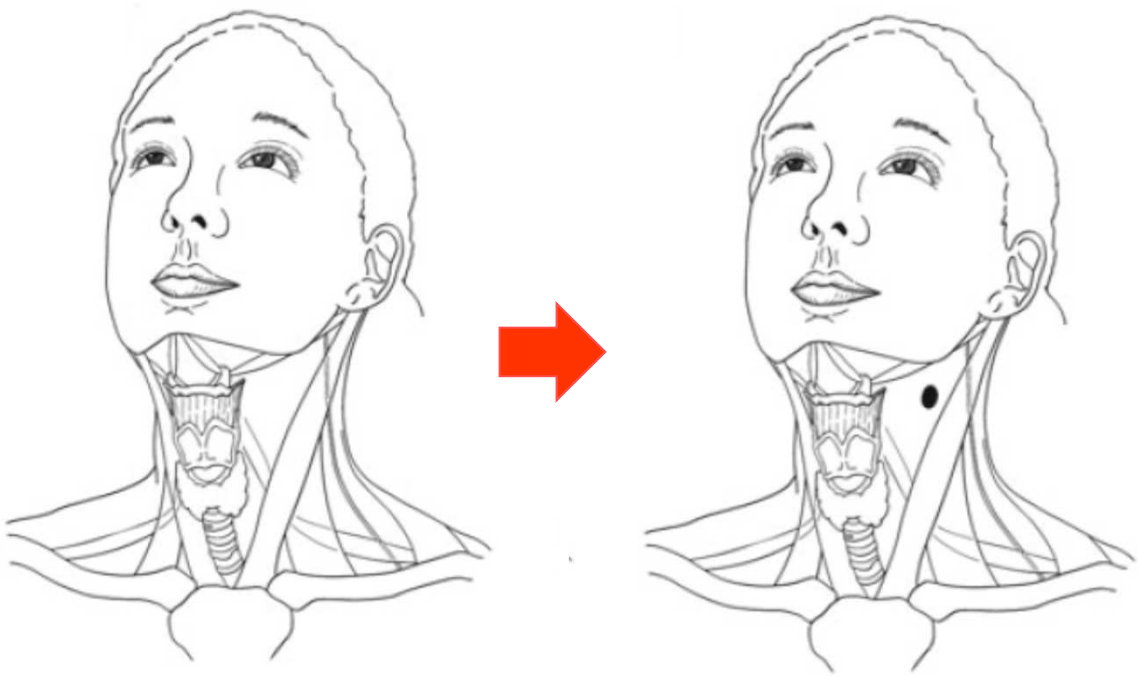

- Regional failure;
- Occult lymph node metastases.

E.g., SCC of the supraglottis:

- Up to 33% N0 became N+ without treatment.
- Up to 26% cN0 became pN+ after lymph node dissection.

Mendenhall et al. *Head Neck Surg* 1980; 3:15-20.

ESTRO School

Management of the “negative” neck

- Elective lymph node dissection:
    - Threshold >20%
- Elective neck irradiation:
    - Threshold 5-10%
- No elective treatment:
    - Glottic cancer T1-2 N0
    - Sinonasal tumors

Weiss, Harrison, Isaacs. *Arch Otolaryngol Head Neck Surg* 1994;120:699–702.
Gregoire et al. *Radiat Oncol* 2000;56;135-50.

CTV in elective neck irradiation

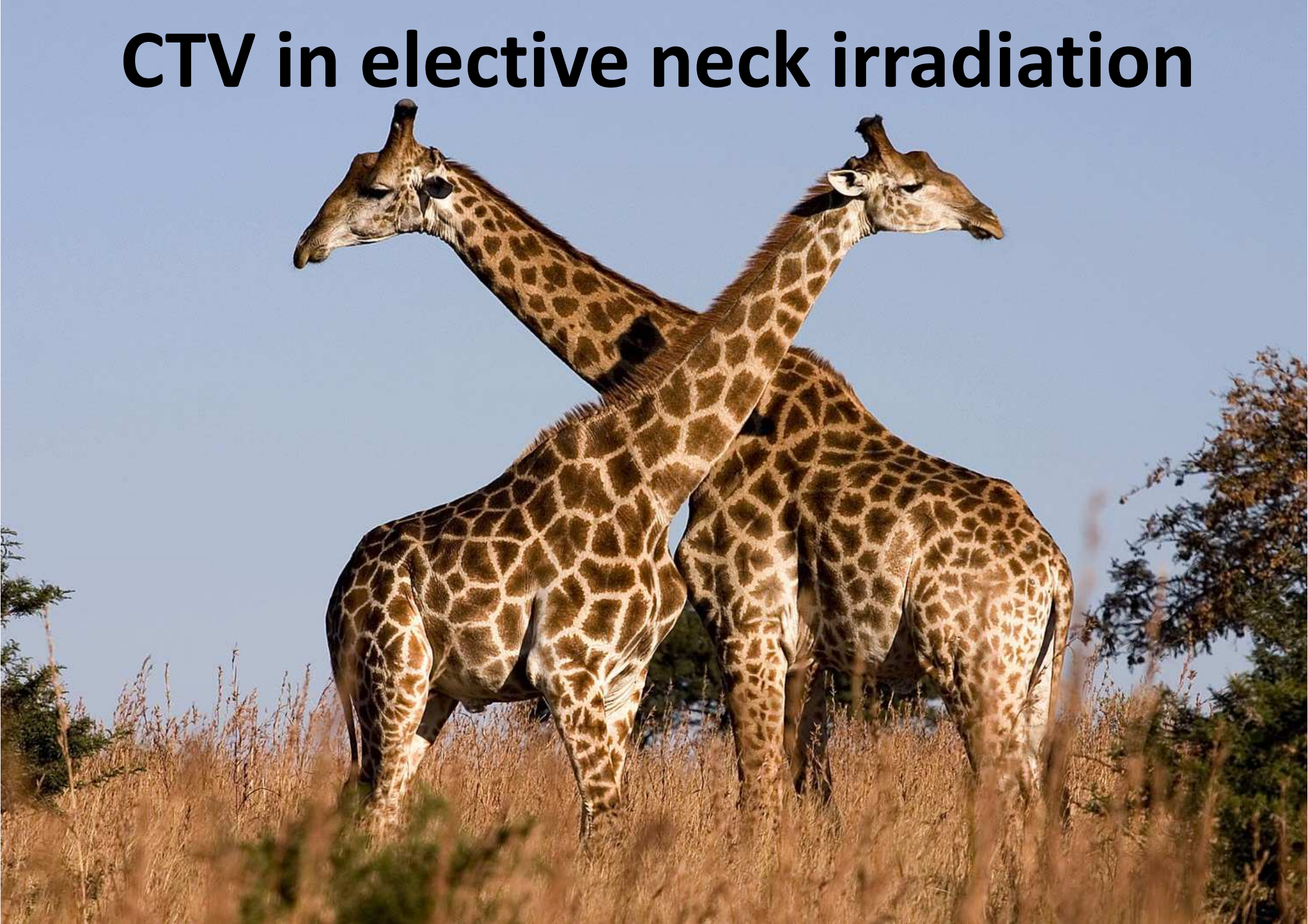

What is the target in elective neck irradiation?

- Cervical lymph node levels -

"groups the lymph nodes based on anatomic landmarks that can be consistently identified on cross-sectional imaging".

- Cervical lymph node levels:
  - Surgery (Shah et al. *Clin Bull* 1981)
  - Radiology (Som et al. *Arch Otolaryngol Head Neck Surg* 1999)
  - Radiation therapy (Gregoire et al. *Radiat Oncol* 2003)

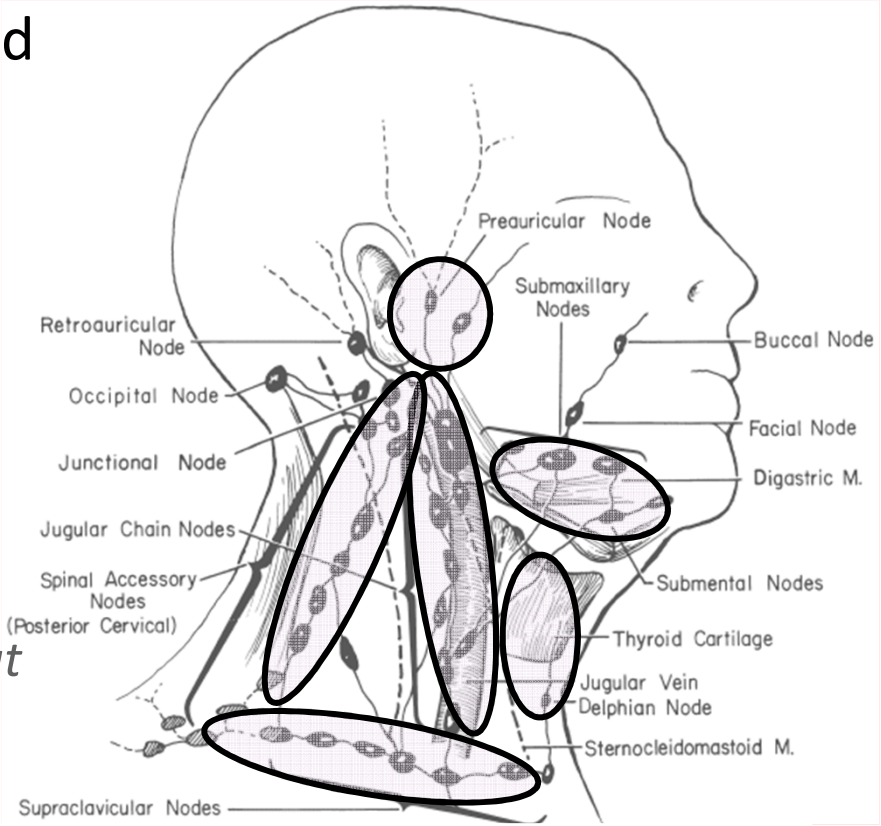

Guidelines 2003: N0

ELSEVIER

Radiotherapy and Oncology 69 (2003) 227–236

RADIOTHERAPY & ONCOLOGY
JOURNAL OF THE EUROPEAN SOCIETY FOR THERAPEUTIC RADIOLOGY AND ONCOLOGY

www.elsevier.com/locate/radonline

CT-based delineation of lymph node levels and related CTVs in the node-negative neck: DAHANCA, EORTC, GORTEC, NCIC, RTOG consensus guidelines

Vincent Grégoire[a,*,1], Peter Levendag[b,1], Kian K. Ang[c], Jacques Bernier[d], Marijel Braaksma[b], Volker Budach[e], Cliff Chao[c], Emmanuel Coche[f], Jay S. Cooper[c], Guy Cosnard[f], Avraham Eisbruch[c], Samy El-Sayed[g], Bahman Emami[c], Cai Grau[h], Marc Hamoir[i], Nancy Lee[c], Philippe Maingon[j], Karin Muller[b], Hervé Reychler[k]

[a]*Radiation Oncology Dept. and Laboratory of Radiobiology, Université Catholique de Louvain, St-Luc University Hospital, B-1200 Brussels, Belgium*
[b]*Radiation Oncology Dept., Erasmus Medical Center Daniel den Hoed Cancer Center, Rotterdam, The Netherlands*
[c]*Head and Neck group, RTOG, 1101 Market Street, 14th Floor, Philadelphia, PA 19107, USA*
[d]*Head and Neck group, EORTC, Avenue E. Mounier, 83/11, B-1200 Brussels, Belgium*
[e]*Radiotherapy group, EORTC, Avenue E. Mounier, 83/11, B-1200 Brussels, Belgium*
[f]*Radiology Dept., Université Catholique de Louvain, St-Luc University Hospital, B-1200 Brussels, Belgium*
[g]*Head and Neck DSG, NCIC-CTG, 10 Alcorn Avenue, Suite 200, Toronto, Ont., Canada, M4V 3B1*
[h]*DAHANCA, Norrebrogade 44, 8000 Aarhus C, Denmark*
[i]*Head and Neck Surgery Dept., Université Catholique de Louvain, St-Luc University Hospital, B-1200 Brussels, Belgium*
[j]*GORTEC, Rue C. Desmoulins, 39, 94805, Villejuif, France*
[k]*Maxillo-Facial Surgery Dept., Université Catholique de Louvain, St-Luc University Hospital, B-1200 Brussels, Belgium*

ESTRO School

Guidelines 2003: N0 (Appendix 2)

- 6 node levels (Ia, Ib, IIa, IIb, III-VI) and retropharyngeal nodes.
- CT-based boundaries of each node level as a part of the CTV.
- Conformal (3DCRT and/or IMRT) radiation therapy.
- Not for diagnosis, surgery or prediction of nodal involvement.

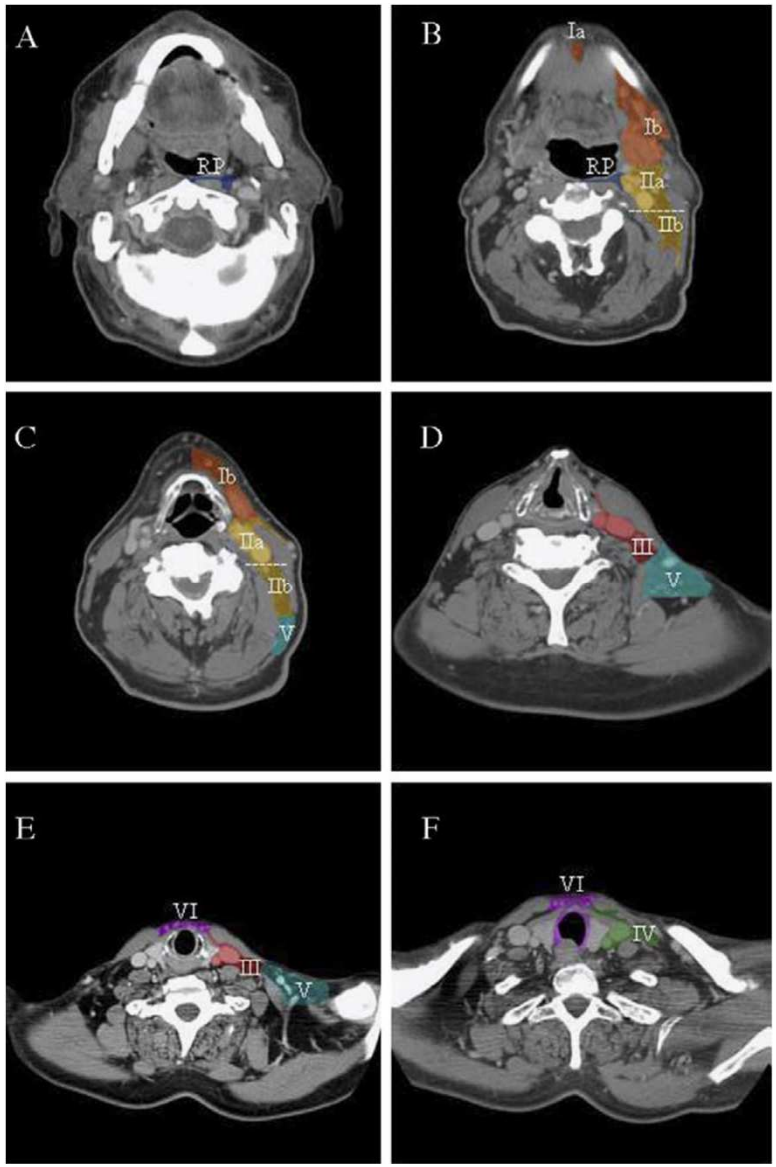

ESTRO School

Guidelines 2013: N≥0

Contents lists available at ScienceDirect

Radiotherapy and Oncology

journal homepage: www.thegreenjournal.com

Guidelines

Delineation of the neck node levels for head and neck tumors: A 2013 update. DAHANCA, EORTC, HKNPCSG, NCIC CTG, NCRI, RTOG, TROG consensus guidelines ☆

Vincent Grégoire [a,*], Kian Ang [b], Wilfried Budach [c], Cai Grau [d], Marc Hamoir [e], Johannes A. Langendijk [f], Anne Lee [g], Quynh-Thu Le [h,i], Philippe Maingon [j], Chris Nutting [k], Brian O'Sullivan [l], Sandro V. Porceddu [m], Benoit Lengele [n]

[a] *Cancer Center and Department of Radiation Oncology, Clinical and Experimental Research Institute, Université Catholique de Louvain, Cliniques Universitaires St-Luc, Brussels, Belgium;* [b] *Department of Radiation Oncology, The University of Texas MD Anderson Cancer Center, Houston, USA;* [c] *Department of Radiation Oncology, University Hospital Düsseldorf, Germany;* [d] *Department of Oncology, Aarhus University Hospital, Denmark;* [e] *Cancer Center and Department of Otorhinolaryngology, Head and Neck Surgery, Institut de Recherche Experimentale et Clinique, Université Catholique de Louvain, Cliniques Universitaires St-Luc, Brussels, Belgium;* [f] *Department of Radiation Oncology, University Medical Center Groningen, University of Groningen, The Netherlands;* [g] *Department of Clinical Oncology, The University of Hong Kong (Shenzhen) Hospital, China;* [h] *Department of Radiation Oncology, Stanford University School of Medicine, Stanford Cancer Center, Stanford;* [i] *Radiation Therapy Oncology Group (RTOG), USA;* [j] *Department of Radiation Oncology, Centre Georges-François Leclerc, Dijon, France;* [k] *Department of Radiation Oncology, Royal Marsden Hospital and Institute of Cancer Research, London, UK;* [l] *Department of Radiation Oncology, Princess Margaret Hospital, University of Toronto, Canada;* [m] *Cancer Services, Princess Alexandra Hospital, Brisbane, Australia;* [n] *Cancer Center and Department of Human Anatomy and Plastic & Reconstructive Surgery, Institut de Recherche Experimentale et Clinique, Université Catholique de Louvain, Cliniques Universitaires St-Luc, Brussels, Belgium*

ESTRO School

Guidelines 2013: what is new?

VIIa	lateral retropharyngeal; **NO** medial retropharyngeal
VIIb	retrostyloid
VIII	parotid
IX	buccofacial
Xa	mastoid
Xb	occipital

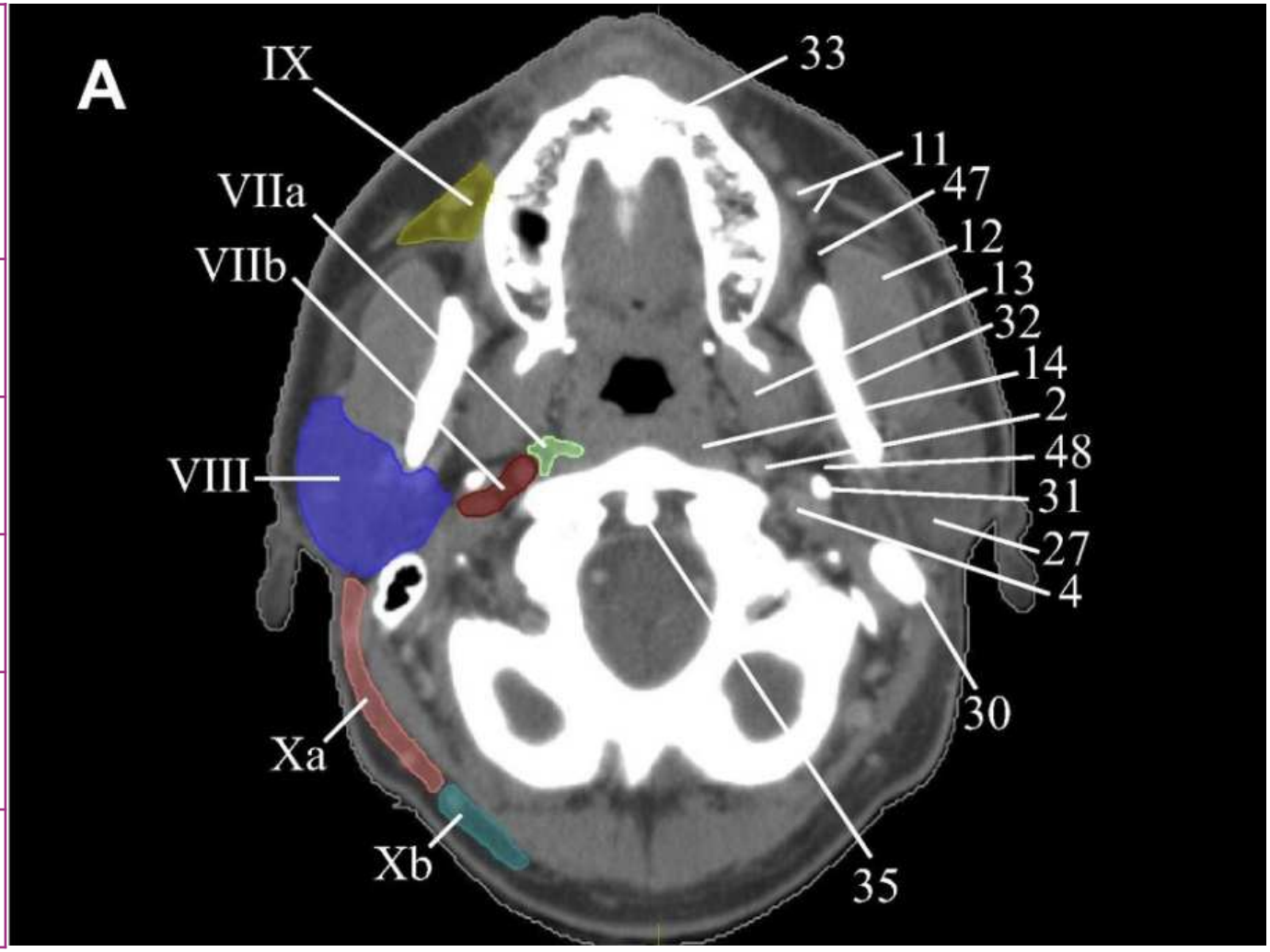

Gregoire et al. *Radiother Oncol* 2014;110:172-81.

ESTRO School

Guidelines 2013: what is new?

IVa	Lower jugular
IVb	Medial supraclavicular
Va-b	Upper & lower posterior triangle
Vc	Lateral supraclavicular
VIa	Anterior jugular
VIb	Prelaryngeal, pretracheal, & paratracheal

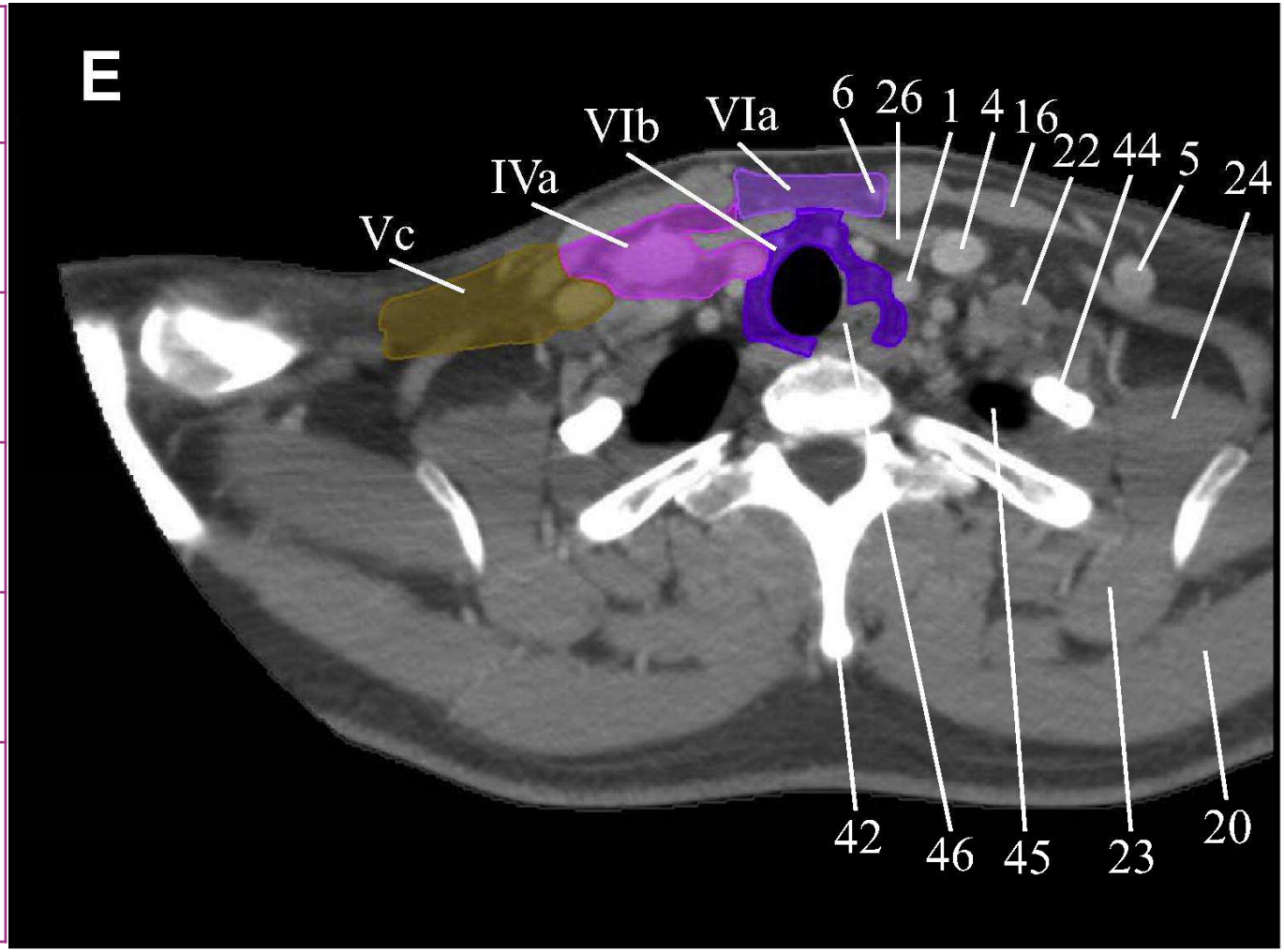

Gregoire et al. *Radiother Oncol* 2014;110:172-81.

ESTRO School

Guidelines 2013: what is new?

IVa	Lower jugular
IVb	Medial supraclavicular
Va-b	Upper & lower posterior triangle
Vc	Lateral supraclavicular
VIa	Anterior jugular
VIb	Prelaryngeal, pretracheal, & paratracheal

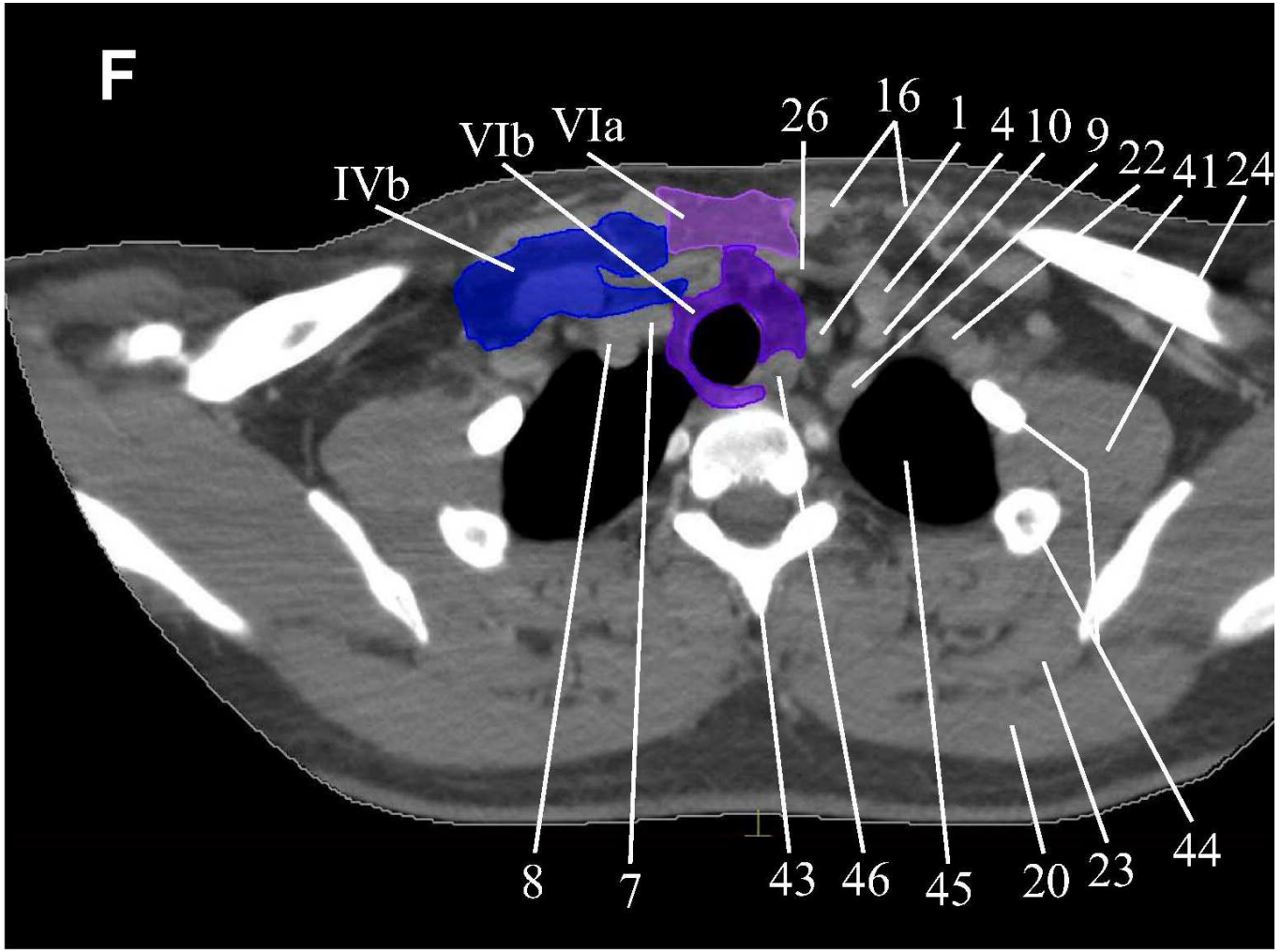

Gregoire et al. *Radiother Oncol* 2014;110:172-81.

ESTRO School

Selecting node levels



Selecting node level to include in the CTV

cN0 neck in head-and-neck cancer per node level [%]

Tumor site	Level I	Level II	Level III	Level IV	Level V	Others
Oral cavity	58/96.5*	21/92	82/97	95/99	99/0	98.6/99.7
Oropharynx	87/98	19/76	77/95	91/97.5	87/97	98/99
Hypopharynx	98/100	20/87	49/96	80/97	76/98	97/99
Supraglottis	98/100	29/79	52/90	82/93	85/96	98/100
Nasopharynx	91/95	29/44	64/68	78/85	68/74	85/90

*ipsilateral/contralateral cervical lymph nodes

Gregoire et al. *Radiother Oncol* 2000; 56:135-50.

ESTRO School

Selecting node level to include in the CTV

E.g., SCC of the supraglottis, N0:

	Level I	Level II	Level III	Level IV	Level V	Others
N0 [%]	98/100*	29/79	52/90	82/93	85/96	98/100
Ipsilateral nodes Contralateral nodes	*100-98=2* *100-100=0*	*100-29=71* *100-79=21*	*100-52=48* *100-90=10*	*100-82=18* *100-93=7*	*100-85=15* *100-96=4*	*100-98=2* *100-100=0*
Probability of occult nodal metastases	<5%	>5% ips/con	>5% ips/con	>5% ips/con	>5% ips	<5%
To be included in the CTV	-	**+/+**	**+/+**	**+/+**	**+/-**	-

*ipsilateral/contralateral cervical lymph nodes

Gregoire et al. *Radiother Oncol* 2000; 56:135-50.
Eisbruch et al. *Semin Radiat Oncol* 2002;12:2380-49.

ESTRO School

Selecting node level to include in the CTV in N0-1

Tumor site	Level I	Level II	Level III	Level IV	Level V	Retropharyngeal
Oral cavity	+	+	+	+[a]	-	-
Oropharynx	-	+	+	+	-	+[b]
Hypopharynx[c]	-	+	+	+	-	-
Larynx[d]	-	+	+	+	-	-
Nasopharynx	-	+	+	+	+	+

[a] For tumors of the anterior tongue.
[b] For tumors of the posterior pharyngeal wall.
[c] Level VI for for esophageal extension.
[d] Level VI for transglottic and subglottic tumors.

Gregoire et al. *Radiother Oncol* 2000; 56:135-50.
Eisbruch et al. *Semin Radiat Oncol* 2002;12:2380-49.

ESTRO School

Selecting node level to include in the CTV in N2b

Tumor site	Level I	Level II	Level III	Level IV	Level V	Retropharyngeal
Oral cavity	+	+	+	+	+[a]	-
Oropharynx	+	+	+	+	+	+
Hypopharynx[b]	+	+	+	+	+	+
Larynx[c]	±	+	+	+	+	-
Nasopharynx	+	+	+	+	+	+

[a]May be omitted if only levels I-III are involved.
[b]Level VI for for esophageal extension.
[c]Level VI for transglottic and subglottic tumors.

Gregoire et al. *Radiother Oncol* 2000; 56:135-50.
Eisbruch et al. *Semin Radiat Oncol* 2002;12:2380-49.

ESTRO School

Guidelines 2006: N+ and post-operative neck

Radiotherapy and Oncology 79 (2006) 15–20
www.thegreenjournal.com

Target volume delineation

Proposal for the delineation of the nodal CTV in the node-positive and the post-operative neck

Vincent Grégoire[a,*], Avraham Eisbruch[b], Marc Hamoir[c], Peter Levendag[d]

[a]*Department of Radiation Oncology, Head and Neck Oncology Program and Center for Molecular Imaging and Experimental Radiation Oncology, Université Catholique de Louvain, Brussels, Belgium,* [b]*Department of Radiation Oncology, University of Michigan, Ann Arbor, MI, USA,* [c]*Department of Head and Neck Surgery and Head and Neck Oncology Program, Université Catholique de Louvain, Brussels, Belgium,* [d]*Department of Radiation Oncology, Rotterdam, The Netherlands*

ESTRO School

Selecting node level to include in the CTV, if N+

1. At (upper) node level II:
   - VII b (retrostyloid).

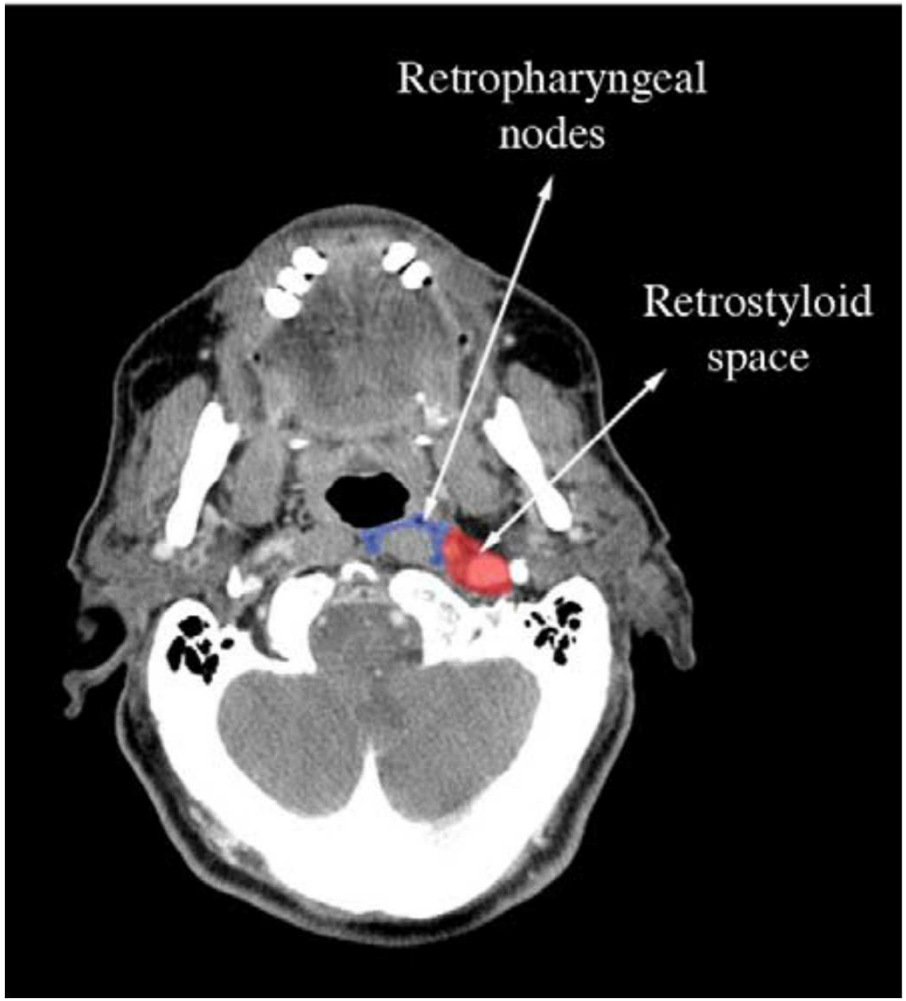

Gregoire et al. *Radiother Oncol* 2006; 79:15-20.
Gregoire et al. *Radiother Oncol* 2014;110:172-81.

ESTRO School

Selecting node level to include in the CTV, if N+

1. At (upper) node level II:
   - VII b (retrostyloid).
2. At node level IV-V:
   - IVb & Vc (supraclavicular fossa).

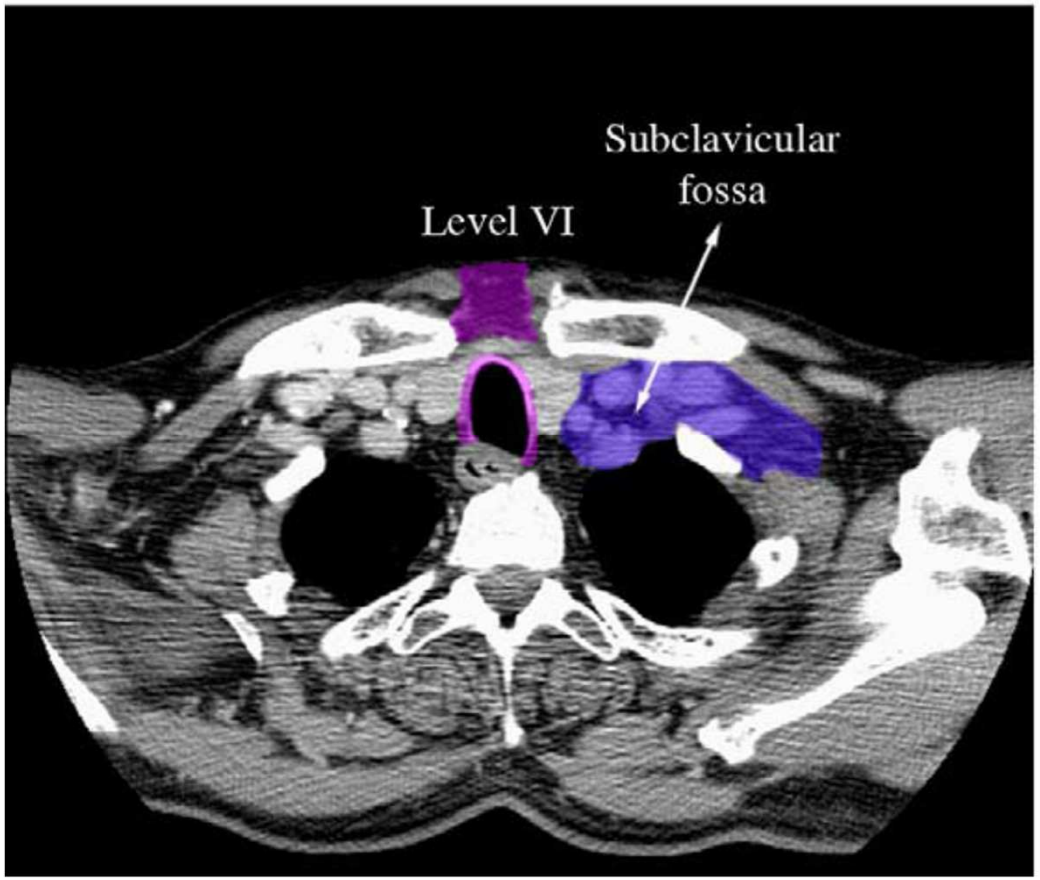

Gregoire et al. *Radiother Oncol* 2006; 79:15-20.
Gregoire et al. *Radiother Oncol* 2014;110:172-81.

ESTRO School

Selecting node level to include in the CTV, if N+

1. At (upper) node level II:
   - VII b (retrostyloid).
2. At node level IV-V:
   - IVb & Vc (supraclavicular fossa).
3. At the boundary with another level:
   - Both node levels.

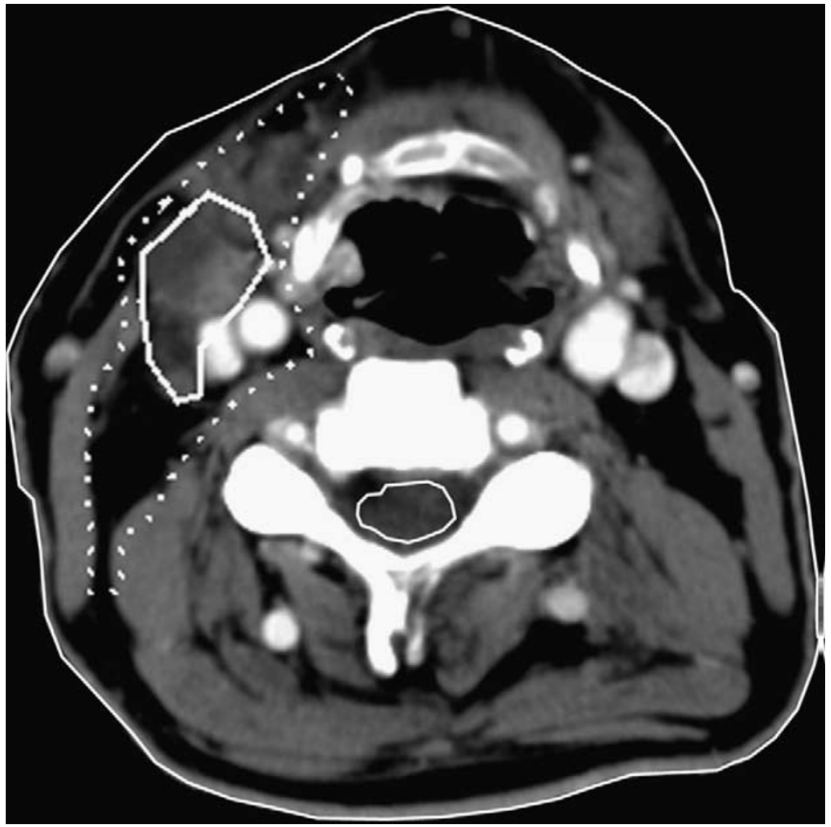

Gregoire et al. *Radiother Oncol* 2006; 79:15-20.
Gregoire et al. *Radiother Oncol* 2014;110:172-81.

Selecting node level to include in the CTV, if N+

1. At (upper) node level II:
   - VII b (retrostyloid).
2. At node level IV-V:
   - IVb & Vc (supraclavicular fossa).
3. At the boundary with another level:
   - Both node levels.
4. Abutting a muscle :
   - A 1-2 cm 3D-expansion into the muscle.

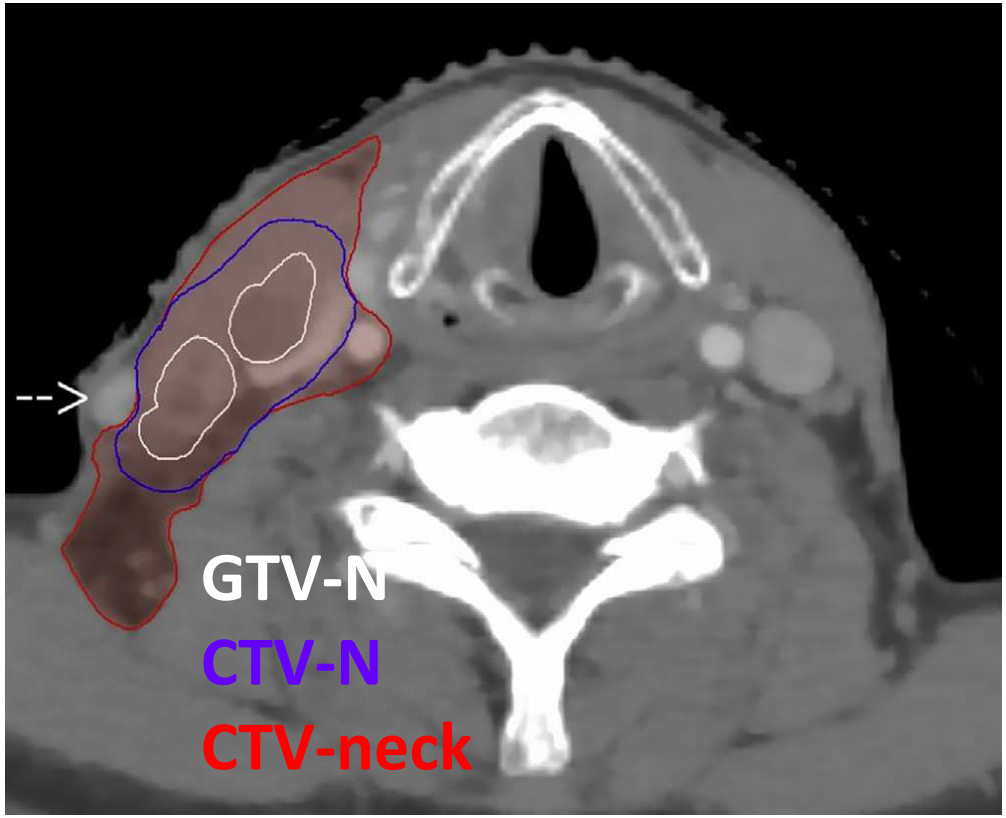

Gregoire et al. *Radiother Oncol* 2006; 79:15-20.
Gregoire et al. *Radiother Oncol* 2014;110:172-81.

ESTRO School

How to delineate the CTV

How to improve the results of elective neck irradiation

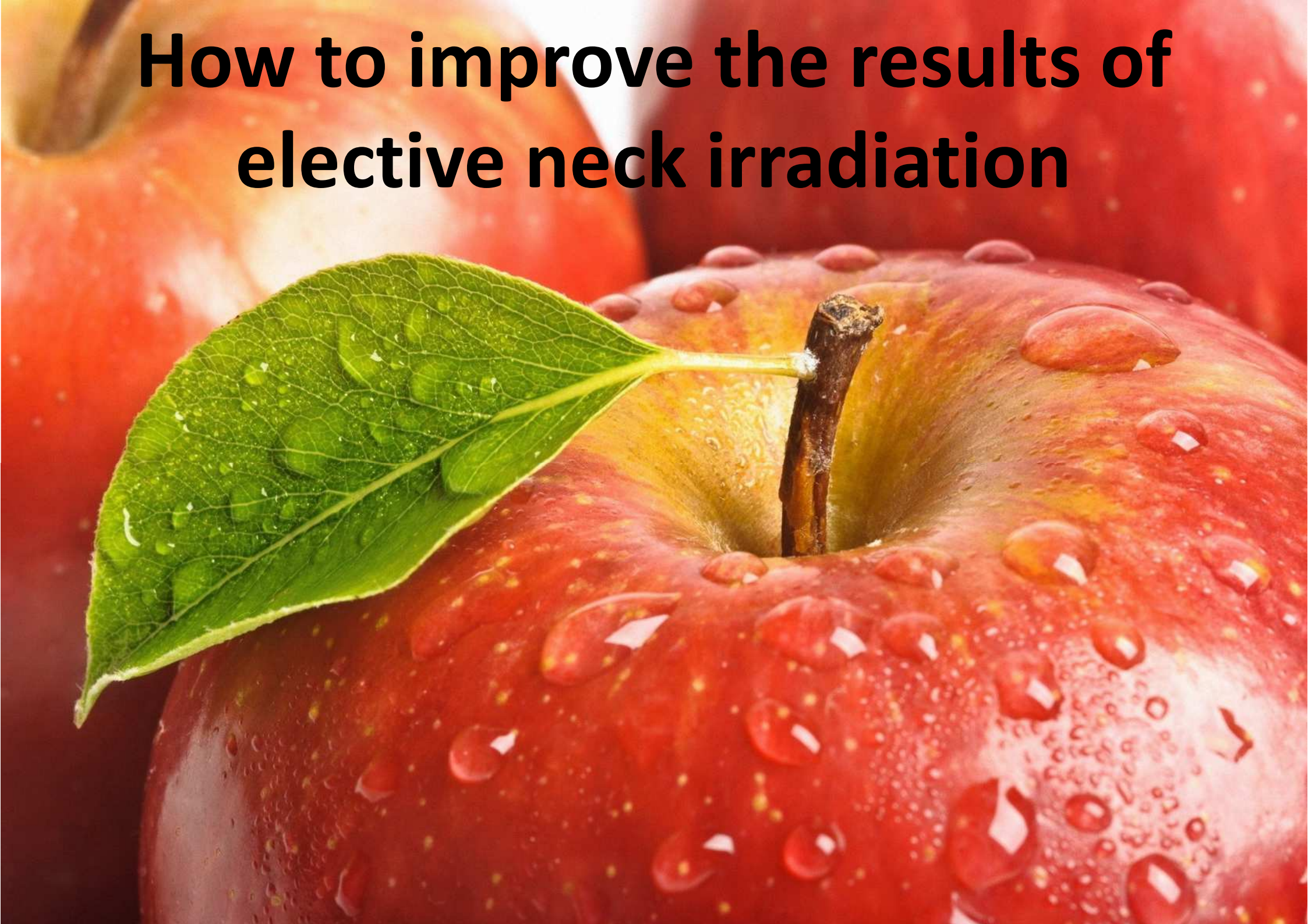

Current status of elective neck irradiation

- IMRT
  - PTV1: node level/s, where N+ (high-risk PTV); dose 50-66 Gy.
  - PTV2: node levels, where N0 (low-risk PTV); dose ~50 Gy.
- Regional recurrence
  - Isolated in the “elective” neck <5%.
- Toxicity
  - Xerostomia Grade 3 ≤3%, no Grade 4.
    - Parotid glands (spared)
    - Submandibular glands (usually not spared)
    - Sublingual glands and oral cavity (usually not spared)
  - Late swallowing disturbances up to 50%.

Duprez et al. *IJROBP* 2011; 79:450-8.
Wang, Eisbruch. *J Radiat Res* 2016; 57 Suppl 1:i69-i75.
Nguyen et al. *Eur J Radiol* 2006;59:453-9.

Trend: de-intensification of elective neck irradiation

- Target volume reduction:
    1. Omitting medial retropharyngeal lymph nodes.
    2. Omitting contralateral retropharyngeal lymph nodes and contralateral high node level II.
    3. Omitting elective neck irradiation contralaterally.
    4. Omitting elective neck irradiation after induction chemotherapy.
- Dose de-escalation
- Target volume reduction & dose de-escalation

ESTRO School

Target volume reduction (1)

- 73 patients (prospective trial):
  - Oropharyngeal cancer stage III-IV
- IMRT + concurrent chemo:
  - 63 Gy/35 fractions to the PTV1-”elective” neck;
  - 59.5 Gy/35 fractions to the PTV2-”elective” neck.
  - Limiting dose to the oral cavity and swallowing structures-minus-PTV-T/N.
- Omitting medial retropharyngeal lymph nodes from the CTV of “elective” neck.

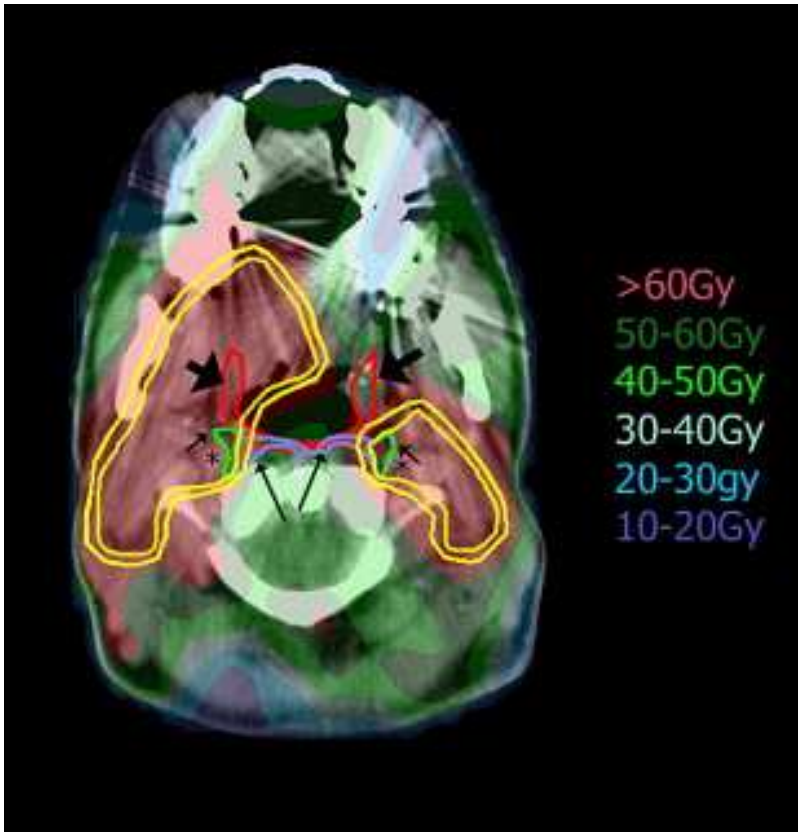

Feng et al. *IJROBP* 2007;28:2732-8.
Feng et al. *J Clin Oncol* 2010;28:2732-8.

ESTRO School

Target volume reduction (1)

- Median follow-up 36 months.
- Locoregional disease-free survival 96% at 3 years.

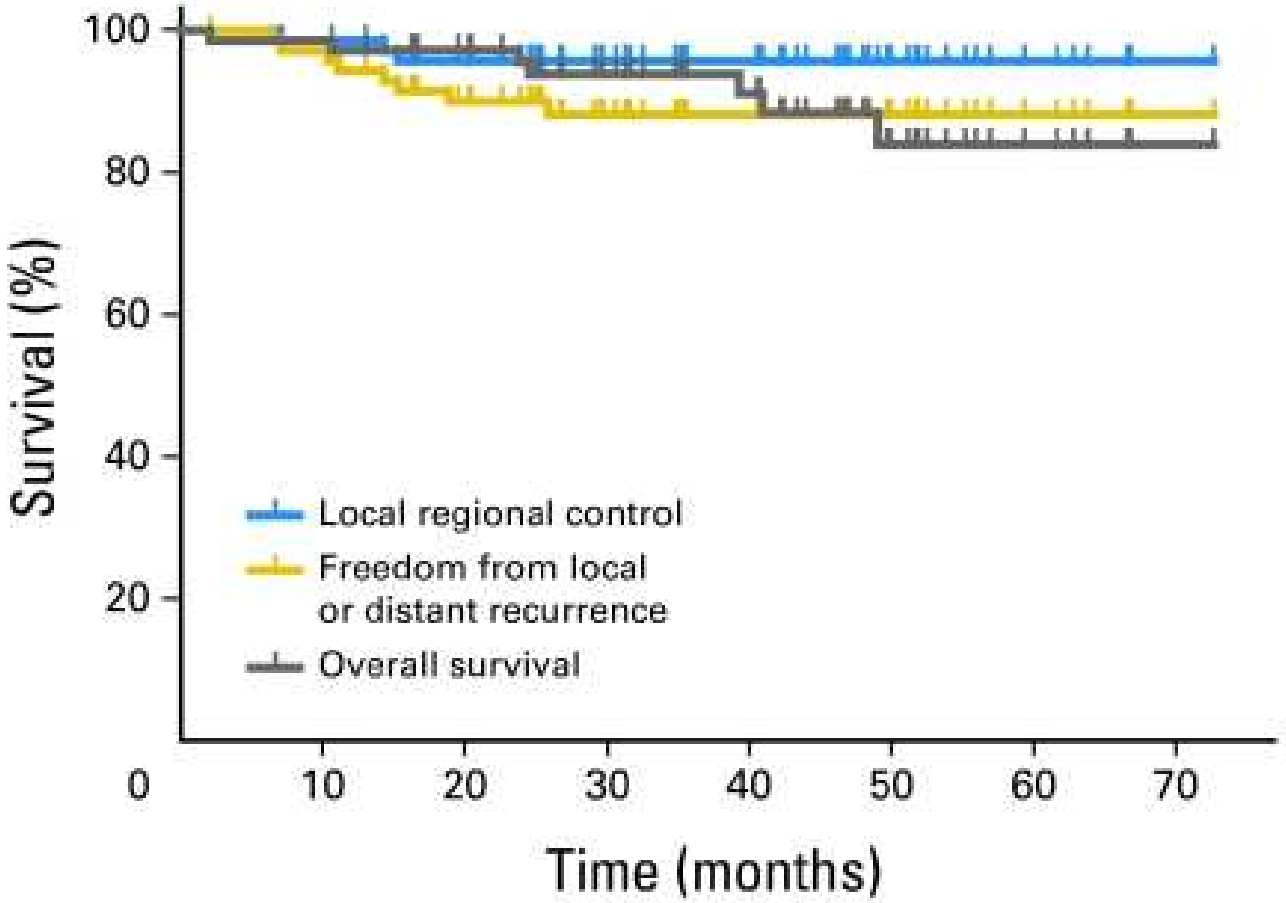

Feng et al. *IJROBP* 2007;28:2732-8.
Feng et al. *J Clin Oncol* 2010;28:2732-8.

ESTRO School

Target volume reduction (1)

- Median follow-up 49 months.
- Aspiration pneumonia 20% at 3 years.

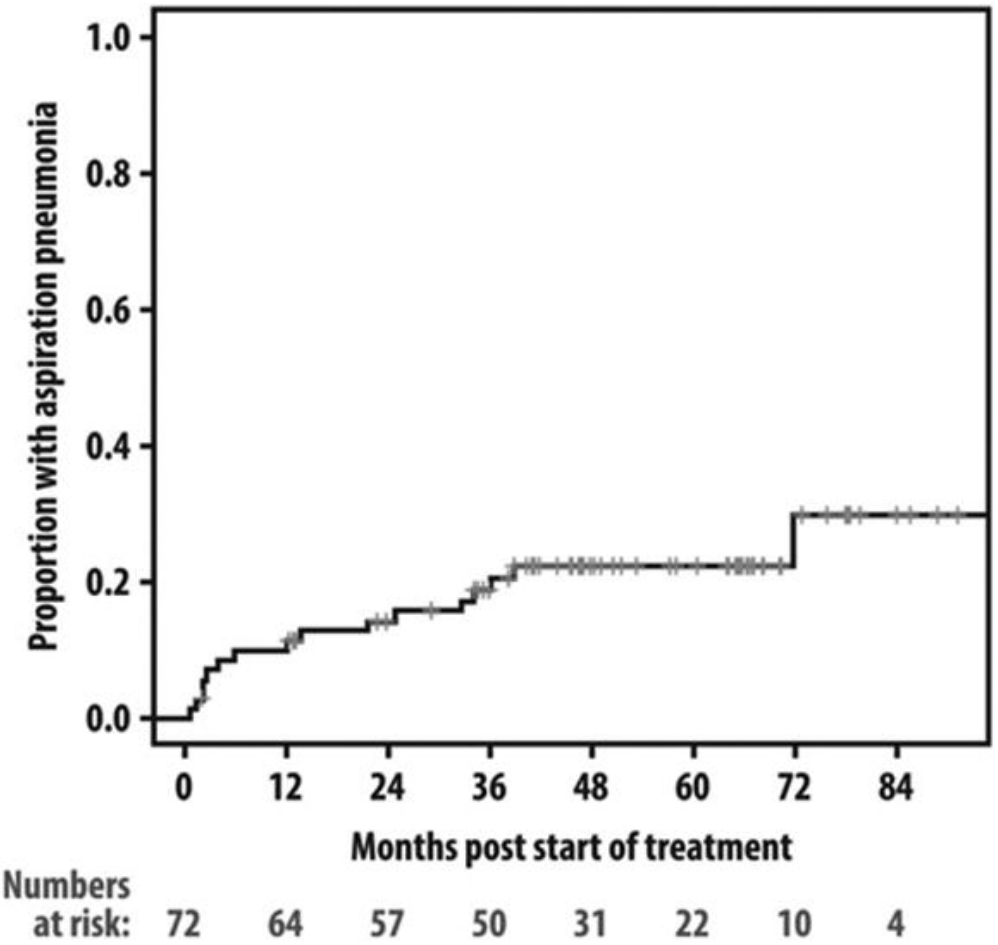

Hunter et al. *Head Neck* 2014;36:120-5.

ESTRO School

Target volume reduction (2)

- 406 pts (retrospective studies):
  - SCC of head-and-neck
- IMRT ± concurrent chemo:
  - 56 Gy/35 fr. to the PTV2 of the “elective” neck.
- 2 groups:
  - Omitting contralateral high node level II : 172 pts.
  - Omitting contralateral high node level II and retropharyngeal lymph nodes: 234 pts.

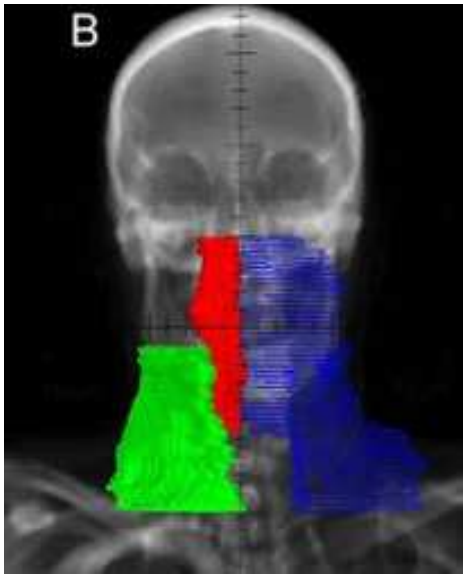

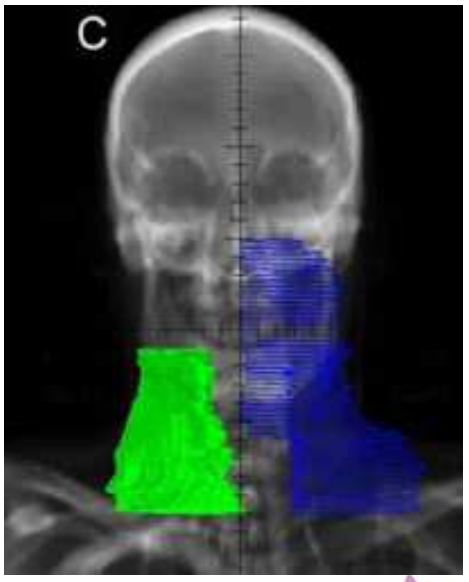

Spencer et al. *Cancer* 2014; 120:3994-4002.

ESTRO School

Target volume reduction (2)

- Median follow-up 37 months.
- Locoregional recurrence at 2 years:
  - Pts with omitted contralateral high node level II 19.2%
  - Pts with omitted contralateral high node level II and retropharyngeal lymph nodes 19%.
    - No regional recurrence in the omitted contralateral high node level II.
    - No regional recurrence in the omitted contralateral retropharyngeal lymph nodes.

Spencer et al. *Cancer* 2014; 120:3994-4002.

ESTRO School

Target volume reduction (3)

HEAD & NECK
JOURNAL OF THE SCIENCES AND SPECIALTIES OF THE HEAD AND NECK

ACR APPROPRIATENESS CRITERIA® IPSILATERAL RADIATION FOR SQUAMOUS CELL CARCINOMA OF THE TONSIL

Expert Panel on Radiation Oncology—Head & Neck Cancer: Anamaria Reyna Yeung, MD,[1] Madhur Kumar Garg, MD,[2] Joshua Lawson, MD,[3] Mark W. McDonald, MD,[4] Harry Quon, MD, MS,[5] John A. Ridge, MD, PhD,[6] Nabil Saba, MD,[7] Joseph K. Salama, MD,[8] Richard V. Smith, MD,[9] Sue S. Yom, MD, PhD,[10] Jonathan J. Beitler, MD[11]

- SCC of the tonsil
  - Tumor invasion into the soft palate or base of tongue <1 cm
  - N0-1
- Ipsilateral elective neck irradiation

Head Neck 2012;34:613-6.

Target volume reduction (4)

- 89 patients (Phase I/II clinical trial):
  - Induction chemo (cisplatin + paclitaxel + cetuximab ± everolimus)
  - IMRT + concurrent chemo
- Response-adapted volume de-escalation:
  - >50% reduction after chemo (good response): 37 pts
    - No elective neck irradiation
  - <50% reduction after chemo (no response): 52 pts
    - Elective neck irradiation 45 Gy/bid/15 fr.

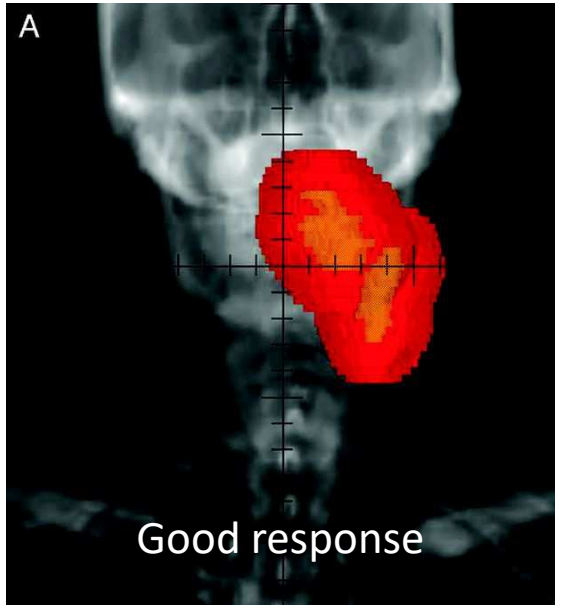

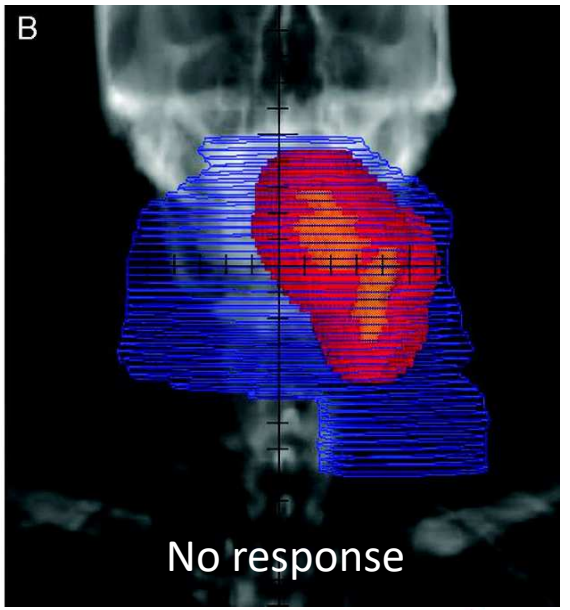

Villaflor et al. *Ann Oncol* 2016; 27:908-13

Target volume reduction (4)

- Mean follow-up 24 months.

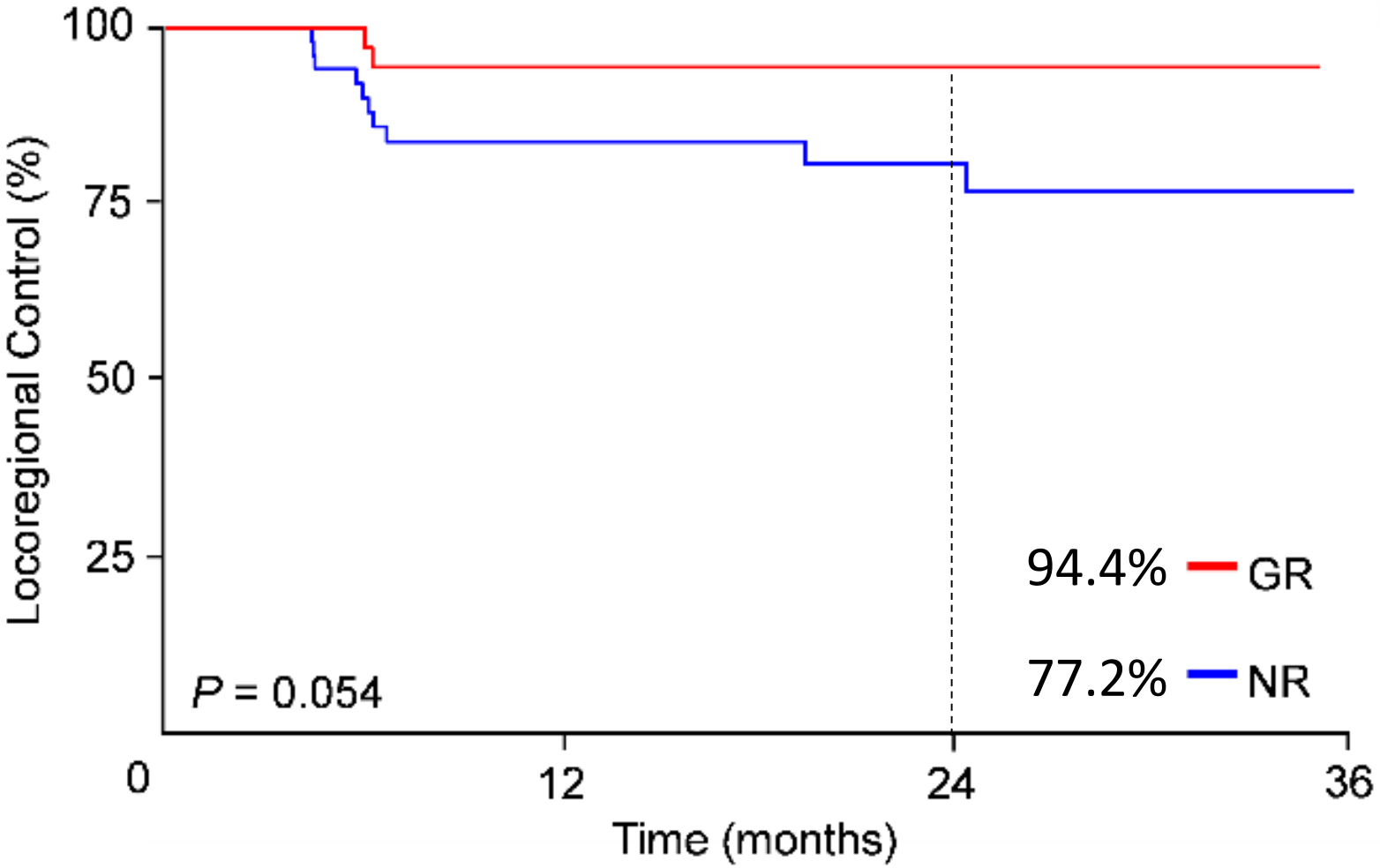

Villaflor et al. *Ann Oncol* 2016; 27:908-13

ESTRO School

Target volume reduction (4)

- G-tube placement during treatment:
  - Good response: 50%
  - No response: 73.5%
- G-tube dependence:
  - At 6 months
    - Good response 5.7%
    - No response 32.6%
  - At 12 months
    - Good response 0%
    - No response 8.6%

Villaflor et al. *Ann Oncol* 2016; 27:908-13

ESTRO School

Dose de-escalation

- 233 patients (3 prospective clinical trials):
  - SCC of head-and-neck
  - IMRT ± concurrent chemo
- Elective neck irradiation:
  - 40 Gy (EQD2Gy)
- Median follow-up 26 months
- Regional control 89.2% at 2 years
- Isolated regional recurrence in the “elective” neck 1/233 pts (0.4%)
- Recurrence rates in the “elective” neck 3.9% at 2 years

Nevens et al. *Radiother Oncol* 2017:Mar 22.

ESTRO School

Take home messages

1. SCC of head-and-neck requires elective neck irradiation.
2. The 2013 guidelines should be used to specify neck node levels.
3. Tumor site and N-stage are the principle factors in selection node levels for elective neck irradiation of SCC of head-and-neck.
4. De-intensification is a new paradigm in elective neck irradiation.

ESTRO School

Post Scriptum

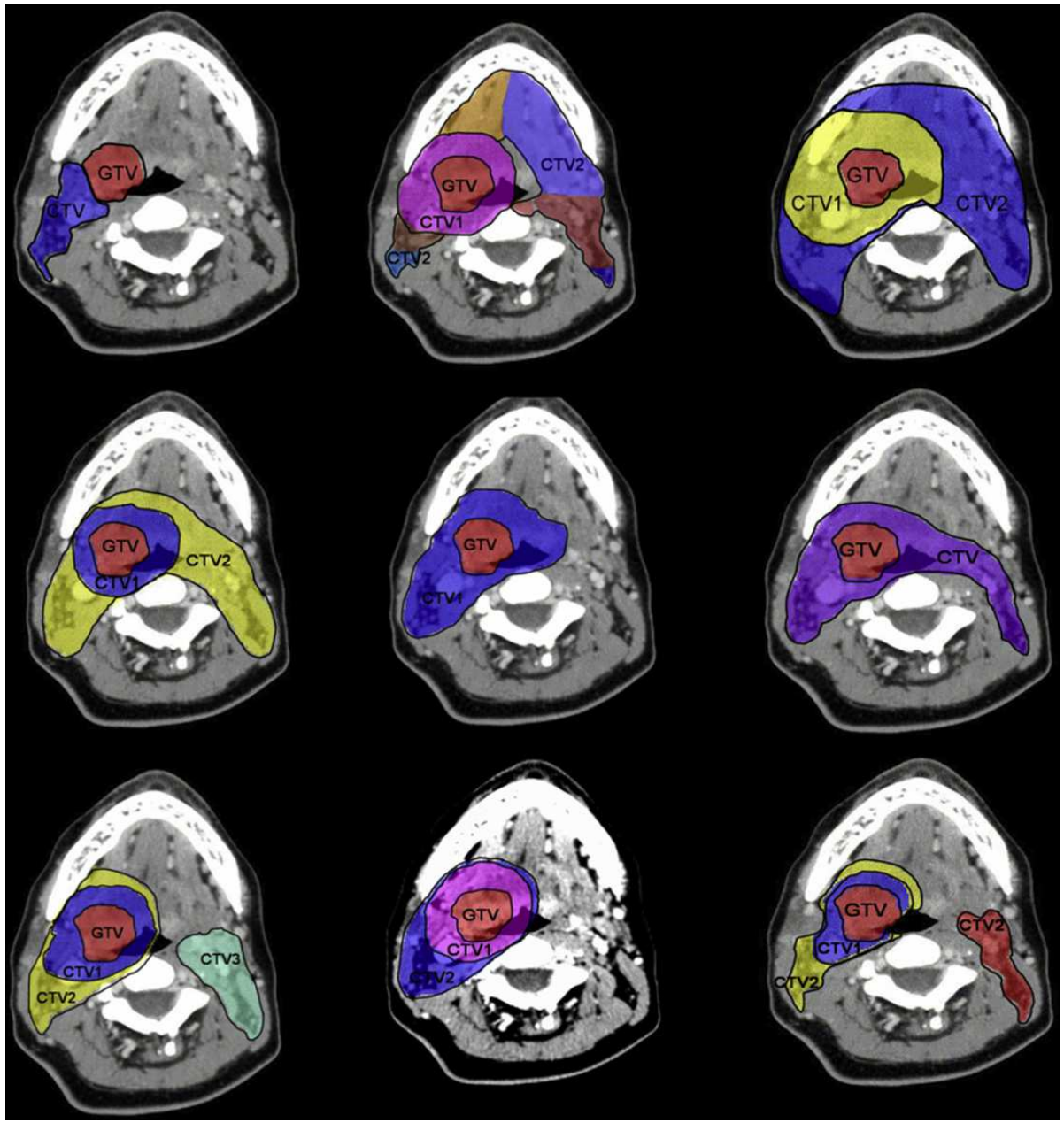

Hong, Tome, Harari. *Radiat Oncol* 2012;103:92-8.

ESTRO School

Appendix 1

Nodal (N) stage in head-and-neck cancer

(except tumors of the nasopharynx and thyroid gland)

Nodal (N) stage in head-and-neck cancer

(except tumors of the nasopharynx and thyroid gland)

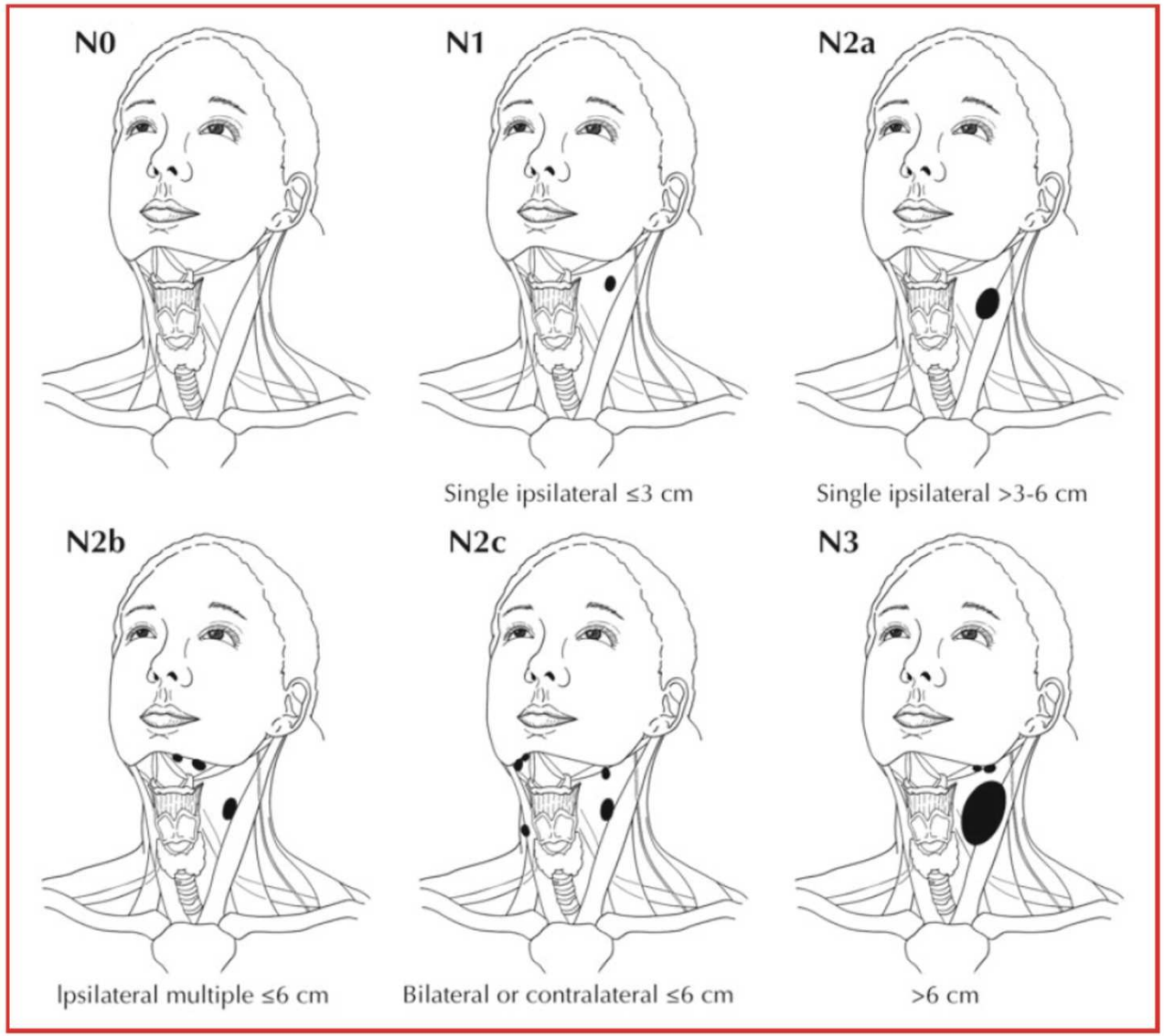

AJCC Cancer Staging Atlas: A Companion to the Seventh Editions of the AJCC Cancer Staging Manual and Handbook. 2012.

ESTRO School

Appendix 2

http://www.rtog.org/CoreLab/ContouringAtlases/HNAtlases.aspx

CT-based definition of nodal target volumes

ANATOMICAL BOUNDARIES						
LEVEL	**CRANIAL**	**CAUDAL**	**ANTERIOR**	**POSTERIOR**	**LATERAL**	**MEDIAL**
Ia	Geniohyoid m., plane tangent to basilar edge of mandible	Plane tangent to body of hyoid bone	Symphysis menti, platysma m.	Body of hyoid bone	Medial edge of ant. Belly of digastric m.	n.a.[a]
Ib	Mylohyoid m., cranial edge of submandibular gland	Plane through central part of hyoid bone	Symphysis menti, platysma m.	Posterior edge of submandibular gland	Basilar edge/innerside of mandible, platysma m., skin	Lateral edge of ant. Belly of digastric m.
IIa	Caudal edge of lateral process of C1	Caudal edge of the body of hyoid bone	Post. Edge of submandibular gland; ant. Edge of int. carotid artery; post edge of post. belly of digastric m.	Post. border of int. jugular vein	Medial edge of sternocleidomastoid	Medial edge of int. carotid artery, paraspinal (levator scapulae) m.
IIb	Caudal edge of lateral process of C1	Caudal edge of the body of hyoid bone	Post. border of int. jugular vein	Post. border of sternocleidoma stoid	Medial edge of sternocleidomastoid	Medial edge of int. carotid artery, paraspinal (levator scapulae) m.

ESTRO School

CT-based definition of nodal target volumes

ANATOMICAL BOUNDARIES						
LEVEL	**CRANIAL**	**CAUDAL**	**ANTERIOR**	**POSTERIOR**	**LATERAL**	**MEDIAL**
III	Caudal edge of the bosy of hyoid bone	Caudal edge of cricoid cartilage	Posterior-lateral edge of the sternohyoid m.; ant. edge of sternocleidomastoid m.	Post. edge of sternocleidomastoid m.	Medial edge of sternocleidomastoid	Medial edge of int. carotid artery, paraspinal (scalenius) m.
IV	Caudal edge of cricoid cartilage	2 cm cranial to sternoclavicular joint	Anteromedial edge of sternocleidomastoid m.	Post. edge of sternocleidomastoid m.	Medial edge of sternocleidomastoid	Medial edge of int. carotid artery, paraspinal (scalenius) m.
V	Cranial edge of body of hyoid bone	CT slice encompassing the transverse cervical vessels[b]	Post. edge of sternocleidomastoid m.	Ant. Border of the trapezius m.	Platysma m., skin	Paraspinal (levator scapulae, scalenius) m.
VI	Caudal edge of body of thyroid cartilage[c]	Sternal manubrium	skin; platysma m.	Separation between trachea and esophagus[d]	Medial edges of thyroid gland, skin and ant.-medial edge of sternocleidomastoid m.	NA

ESTRO School

CT-based definition of nodal target volumes

ANATOMICAL BOUNDARIES						
LEVEL	**CRANIAL**	**CAUDAL**	**ANTERIOR**	**POSTERIOR**	**LATERAL**	**MEDIAL**
VI	Caudal edge of body of thyroid cartilage[c]	Sternal manubrium	skin; platysma m.	Separation between trachea and esophagus[d]	Medial edges of thyroid gland, skin and ant.-medial edge of sternocleidomastoid m.	NA
R.	base of skull	Cranial edge of the body of hyoid bone	Fascia under the pharyngeal mucosa	Prevertebral m. (longus colli, longus capitis)	Median edge of the int. carotid artery	Midline

R.: retropharyngeal.

NA: not available.

[a] midline structure lying between the medial borders of the anterior bellies of the digastric muscles.

[b] fatty planes below and around the clavicle down to the trapezius muscle.

[c] for paratracheal and recurrent nodes, the cranial border is the caudal edge of the cricoid cartilage.

[d] for pretracheal nodes, trachea and anterior edge of cricoid cartilage.

ESTRO School



ESTRO

School

WWW.ESTRO.ORG/SCHOOL

H&N - Lower GI (Rectal and Anal) - Anatomy and Nodal drainage

Julien Dinkel

University Hospital of Munich

Department of Radiology

Germany

ESTRO School

Teaching points

- To understand of the lower GI anatomy
- To know the best imaging methods for lower GI
- To understand the basics of nodal drainage in lower GI

ESTRO School

MRI vs CT

- MRI is the modality of choice
- With 3T the resolution is far better than with 1.5T
- Usefull in assessing the mesorectal invasion
- Stratifying of T3 tumours
- The use of an endorectal probe is not necessary
- The MRI protocol should not exceed 25 minutes

ESTRO School

MRI -Protocol

- 3 mm T2w TSE (sagittal, axial, coronal)
- 3D GRE T1w FS pre and post contrast (LN)
- (DWI axial)
- Buscopan

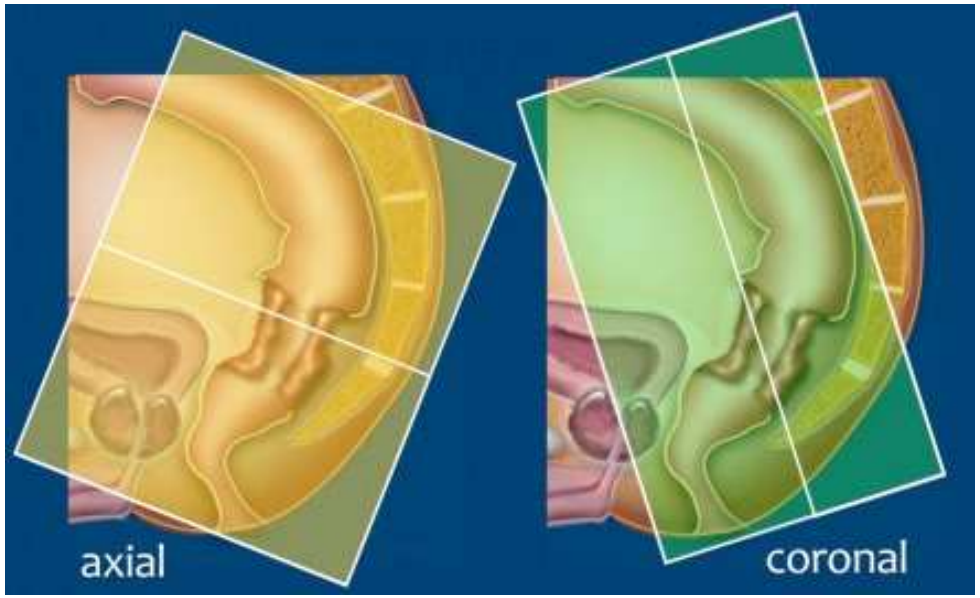

Influence of angulation

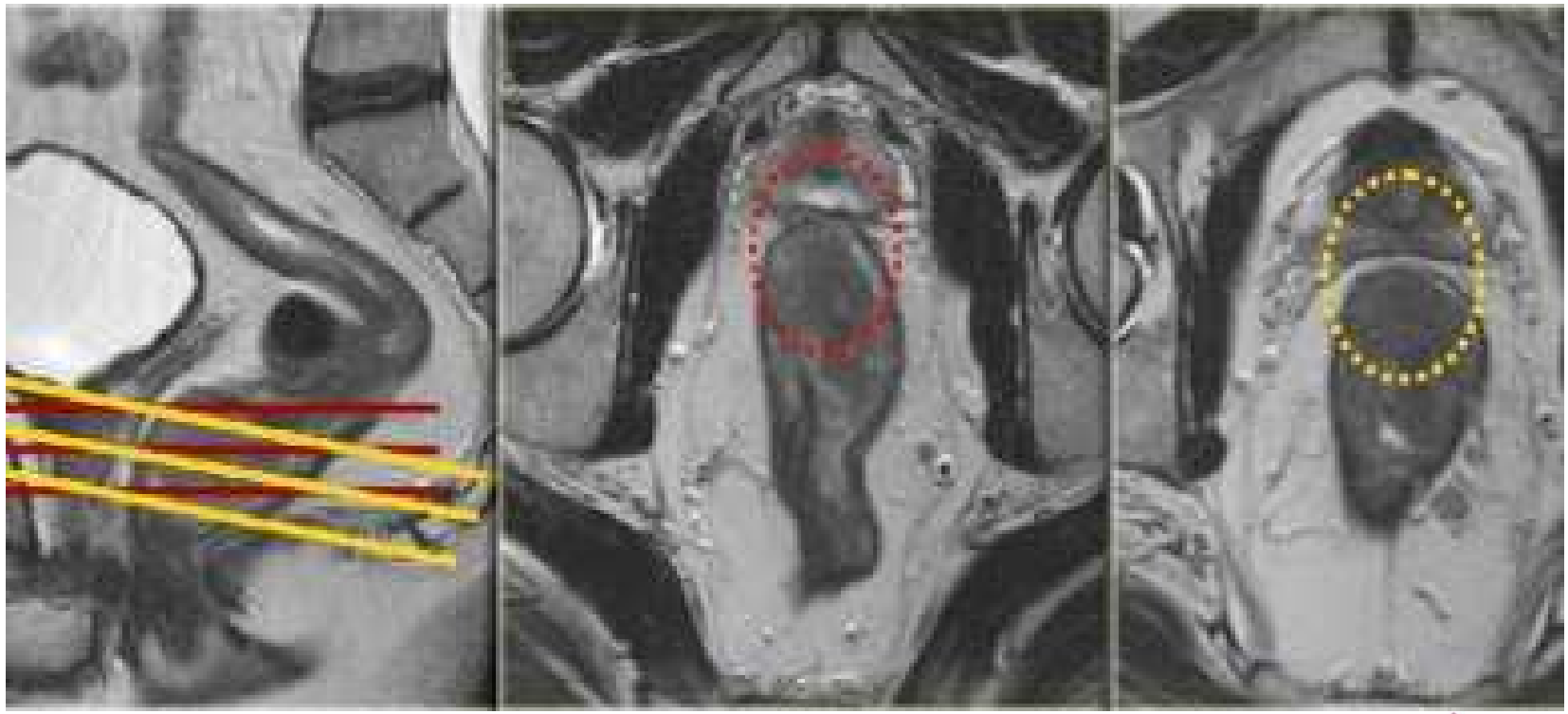

Pelvic / lower GI anatomy

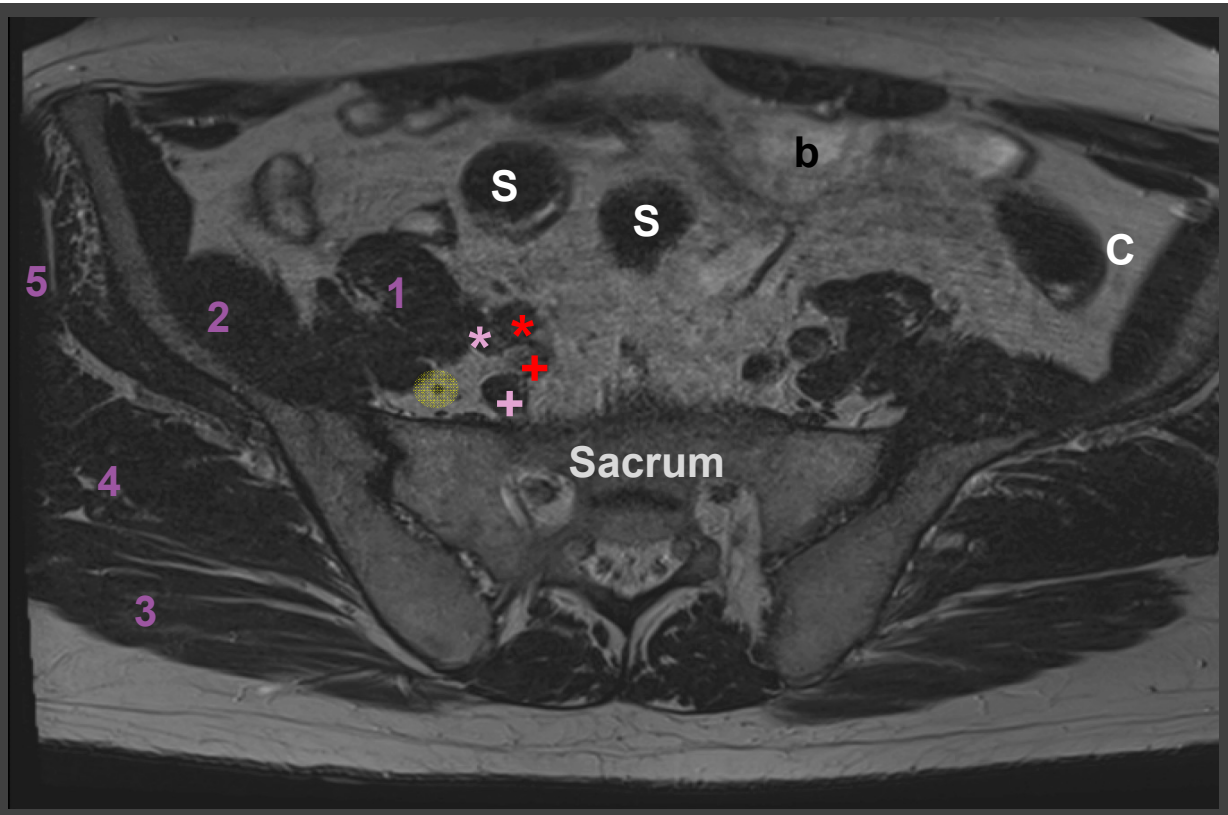

1. M. psoas
2. M. iliacus
3. M. gluteus maximus
4. M. gluteus medius
5. M. gluteus minimus

b Bowel

C Colon

S Sigma

/ A. / V. iliaca externa

+/+ A. / V. iliaca interna

° obturatorius N

Pelvic / lower GI anatomy

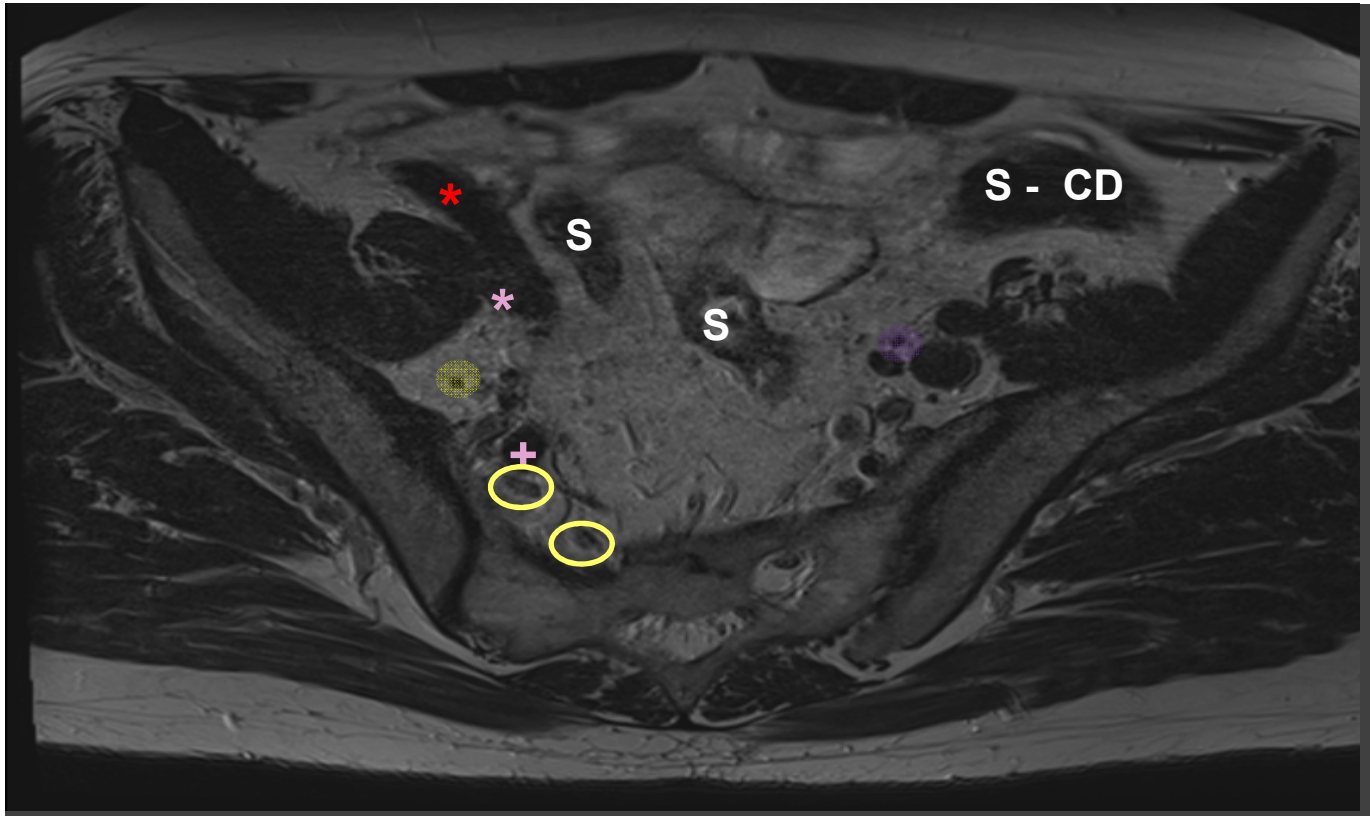

S Sigma

C Colon

/ A. / V. iliaca externa

+/+ A. / V. iliaca interna

° Nervus obturatorius

° Ureter

N. ischiadic N (L4-S3)

Pelvic / lower GI anatomy

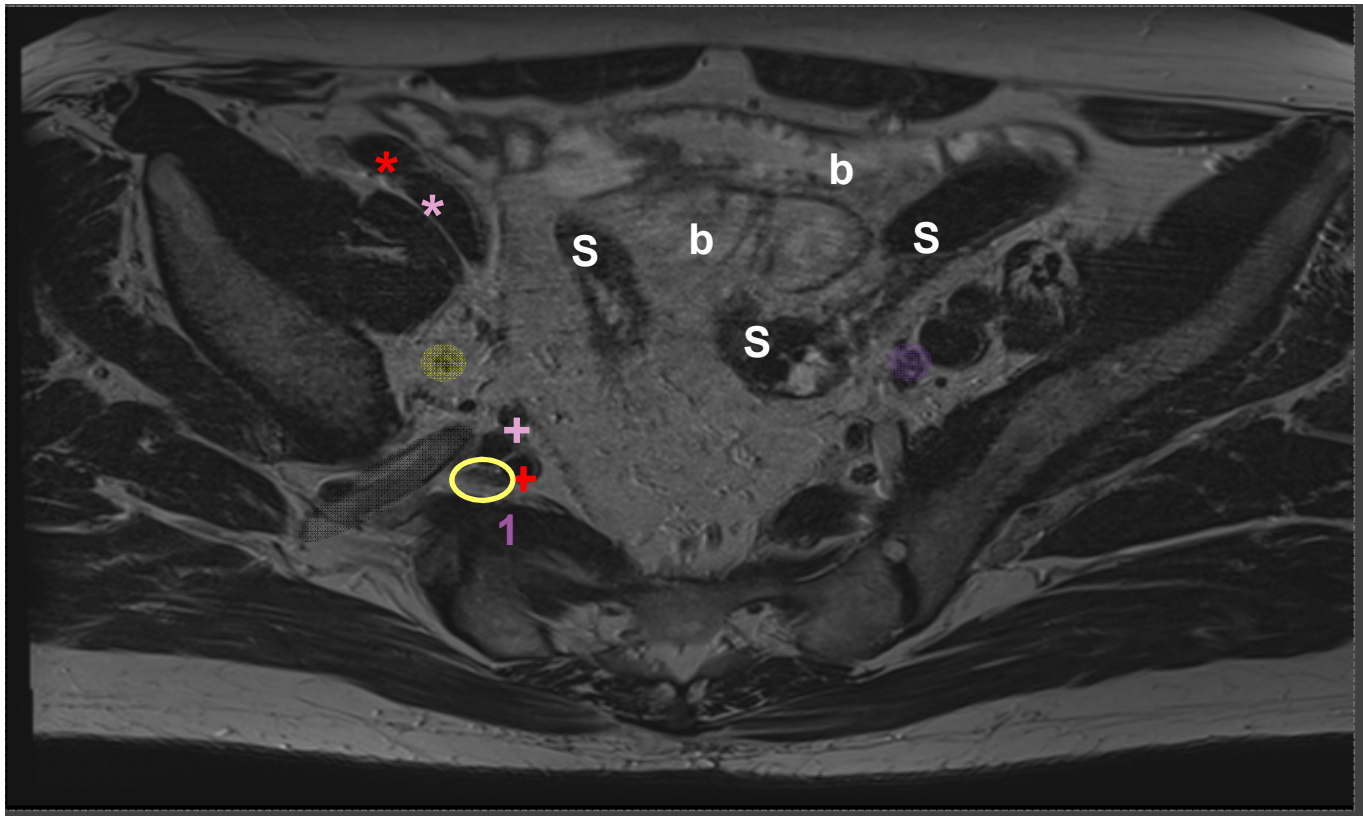

1. M. piriformis

b Bowel

S Sigma

° Nervus obturatorius

° Ureter

N. ischiadicus (L4-S3)

Pelvic / lower GI anatomy

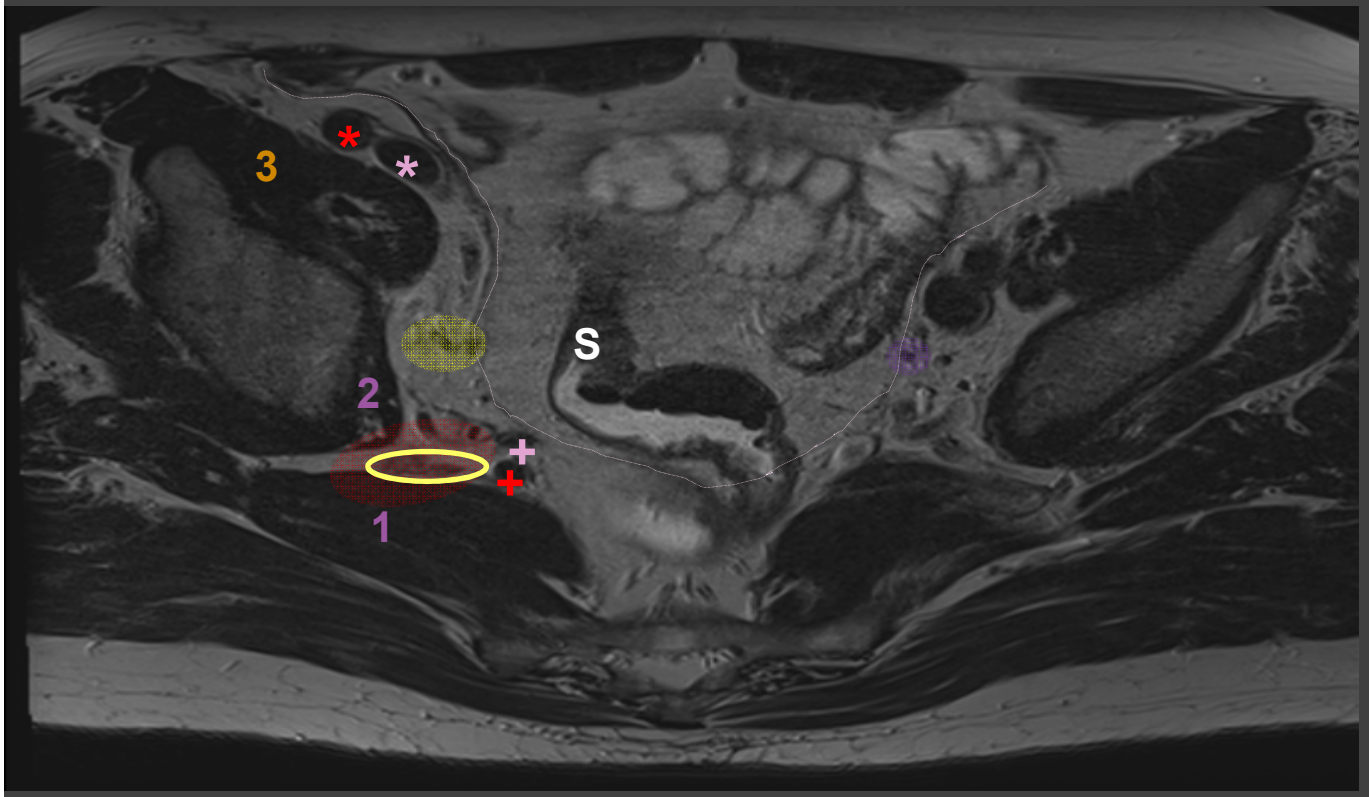

1. M. piriformis
2. M. obturatorius internus
3. M. iliopsoas

- Foramen infrapiriforme

  A. /V. /N. gluteus inferior

  N. ischiadicus

  N. pudendus

° Nervus obturatorius

° Ureter

Pelvic / lower GI anatomy

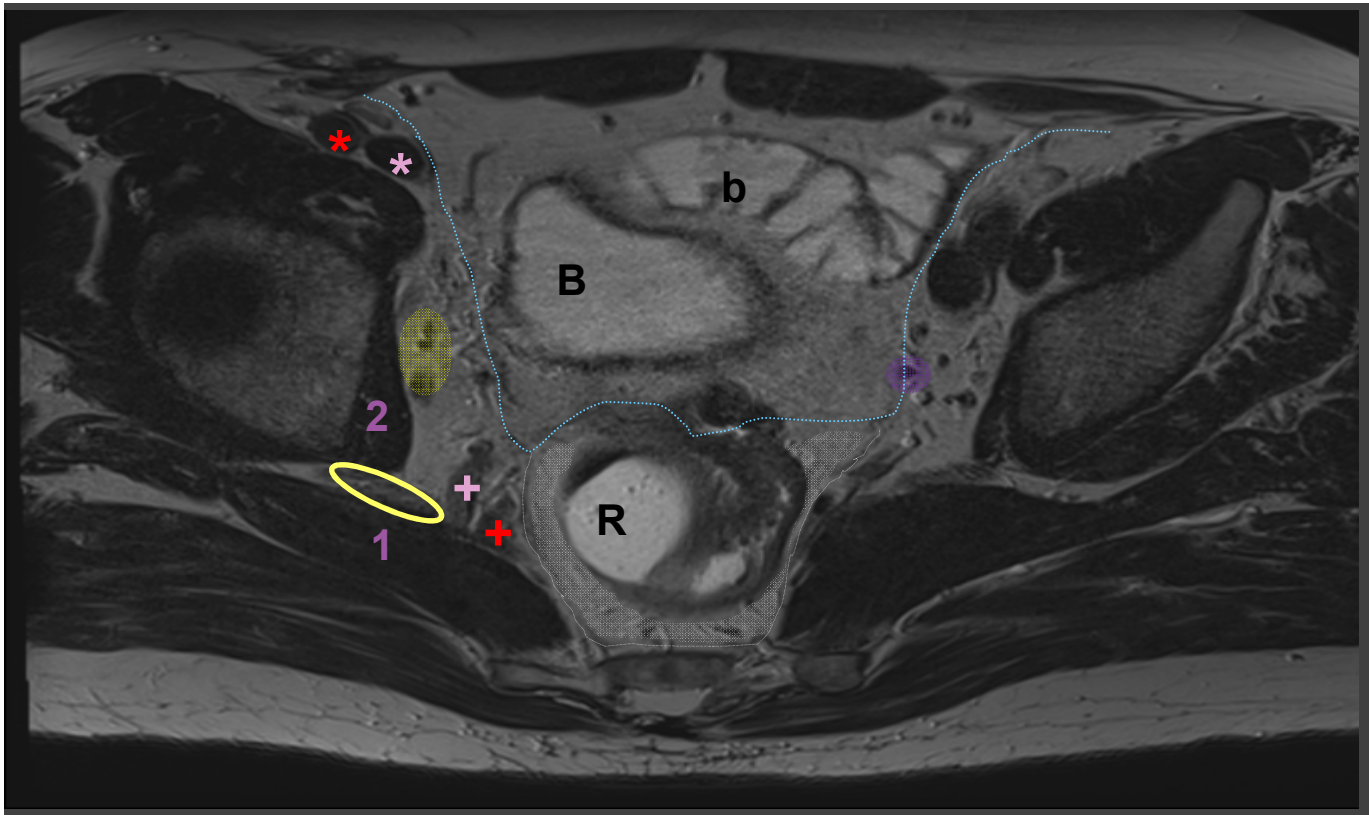

1. M. piriformis
2. M. obturatorius internus

bowel

Bladder

Rectum

N. ischiadicus

° N/A/V obturatorius

° Ureter

… Peritoneum ….

... Mesorectal fascia …

/ A. / V. iliaca externa

+/+ A. / V. iliaca interna

Peritoneal fold

„seagull sign“ peritoneal fold

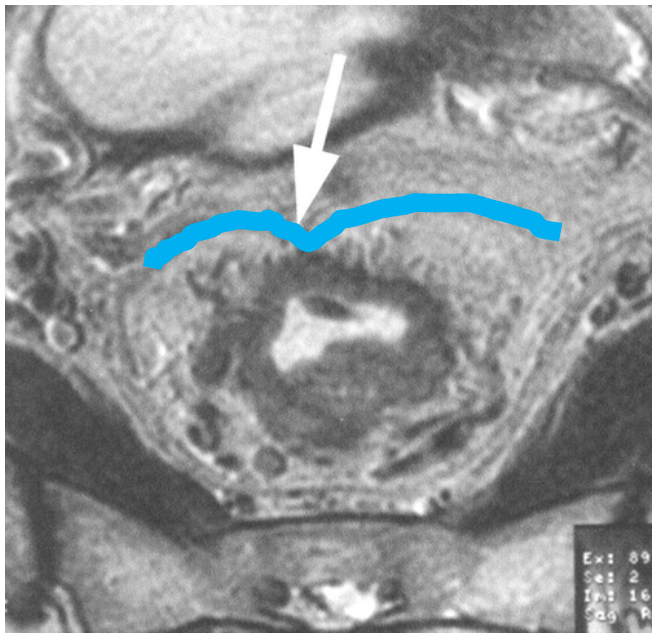

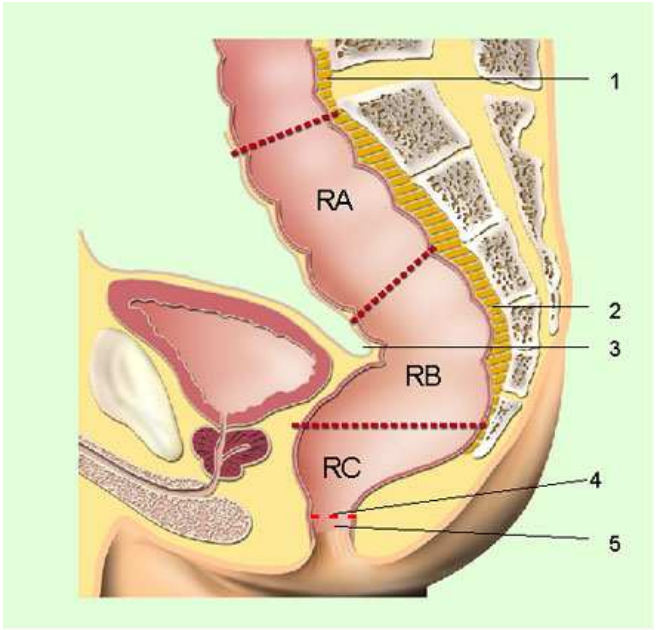

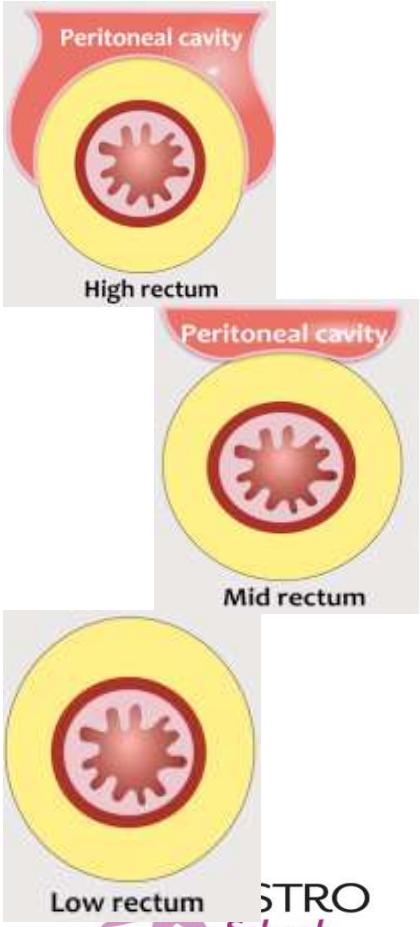

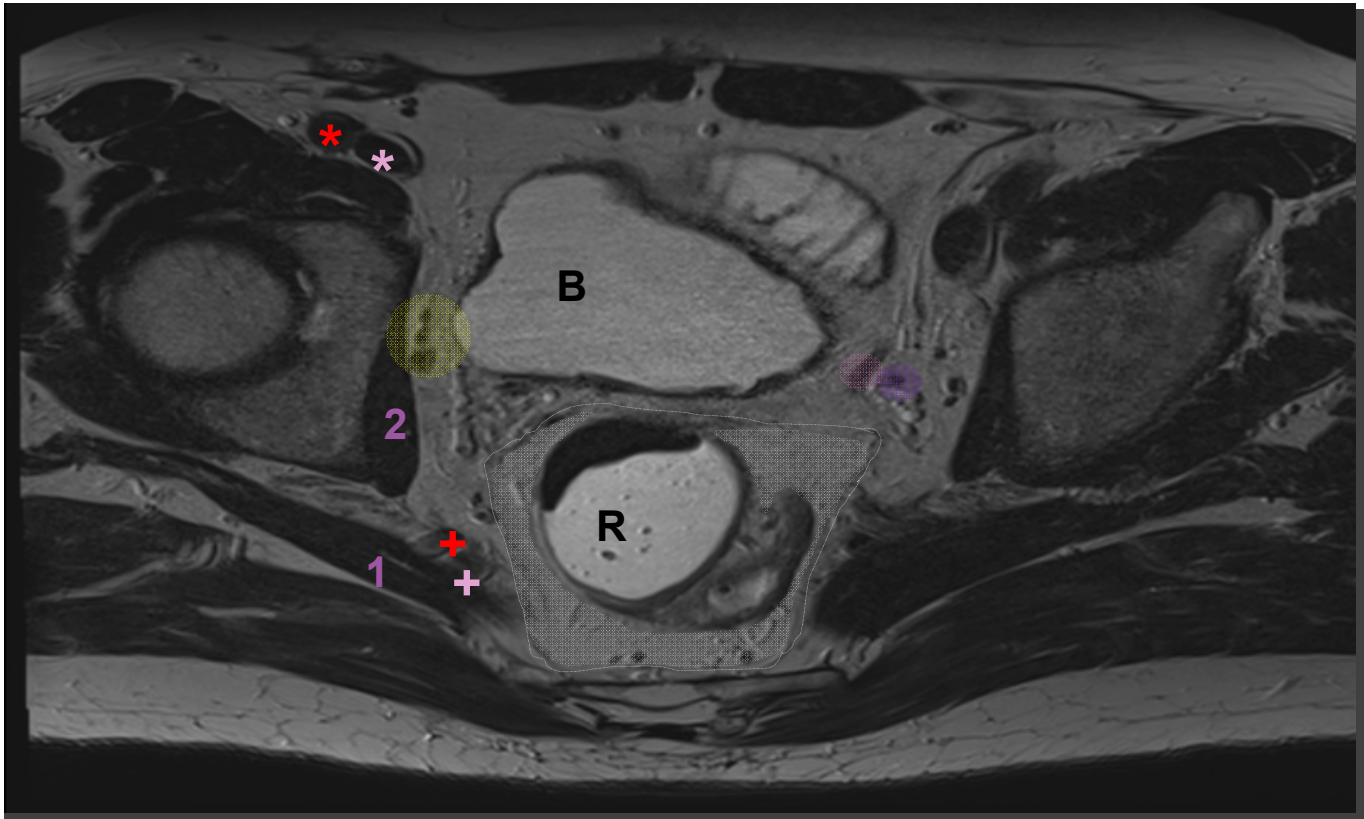

1. M. piriformis
2. M. obturatorius internus

° Ureter

° N/A/V obturatorius

… Peritoneum ….

... Mesorectal fascia …

/ A. / V. iliaca externa

+/+ A. / V. iliaca interna

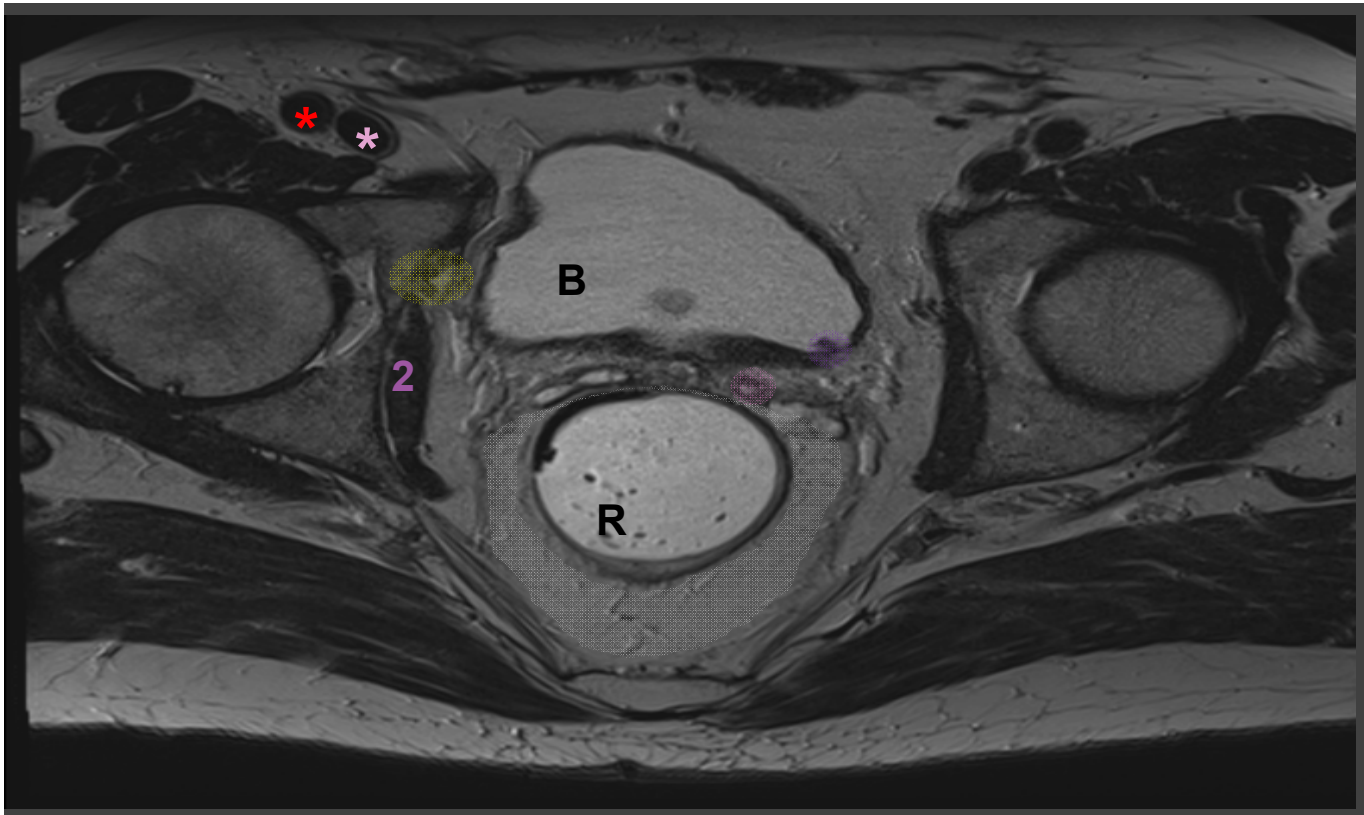

2. M. obturatorius internus

Bladder

Seminal glands

Rectum

° Ureter

Ductus deferens

° N/A/V obturatorius

Mesorectal fat

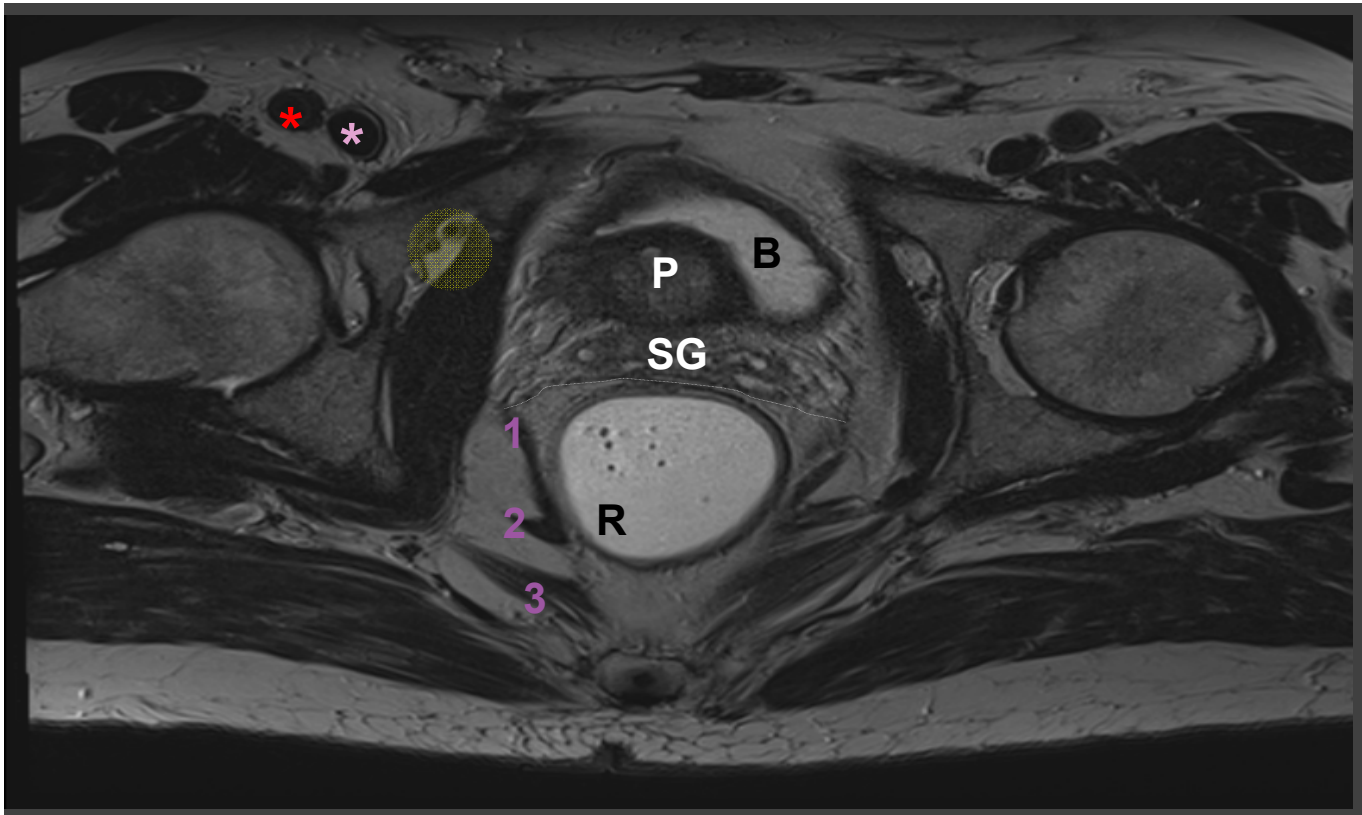

1. M. pubococcygeus
2. M. iliococcygeus
3. M. ischiococcygeus

Bladder

Prostate

Seminal glands

Rectum

° Nervus obturatorius

Mesorectal Fascia

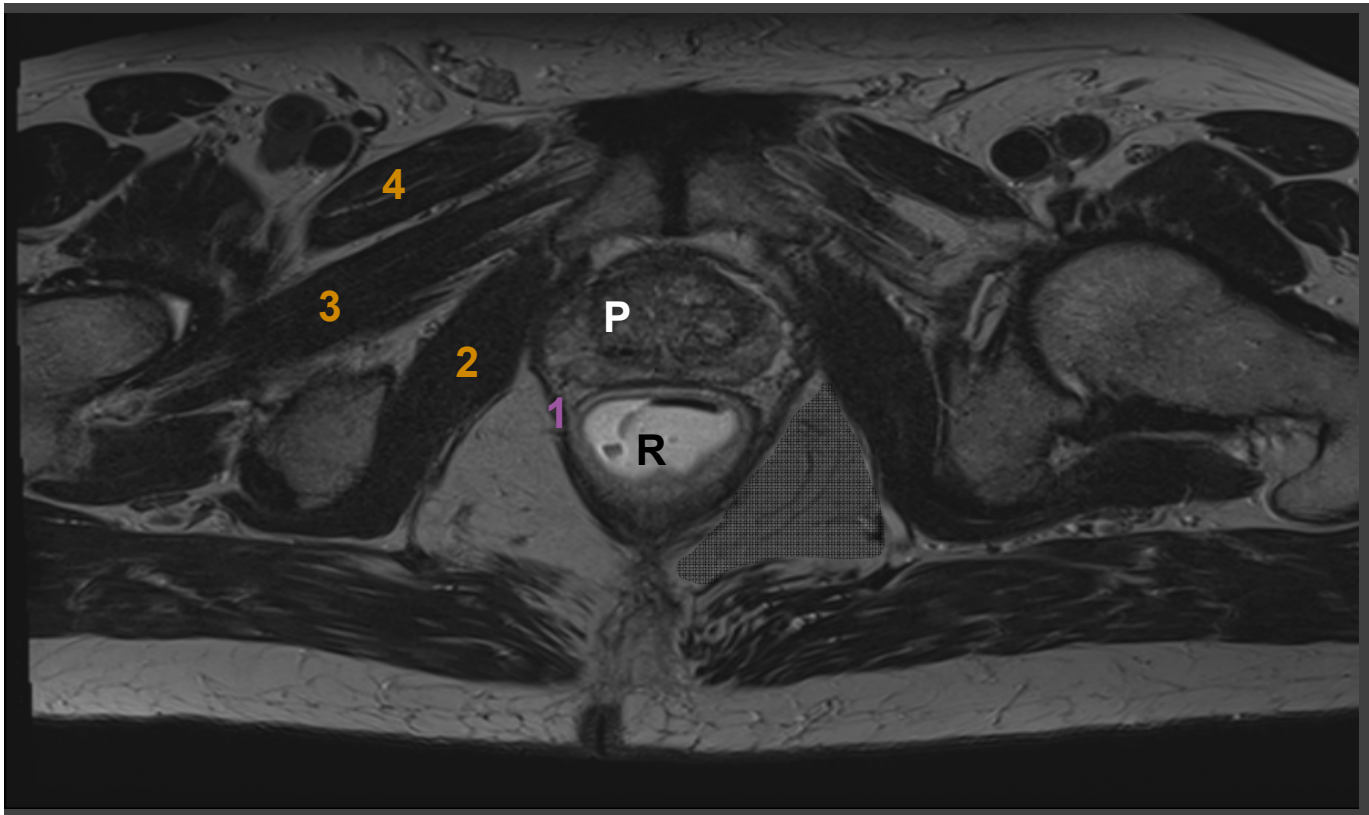

1. M. levator ani
2. M. obturatorius internus
3. M. obturatorius externus
4. M. pectineus

Prostata

Rectum

Fossa ischiorectalis/
ischioanalis

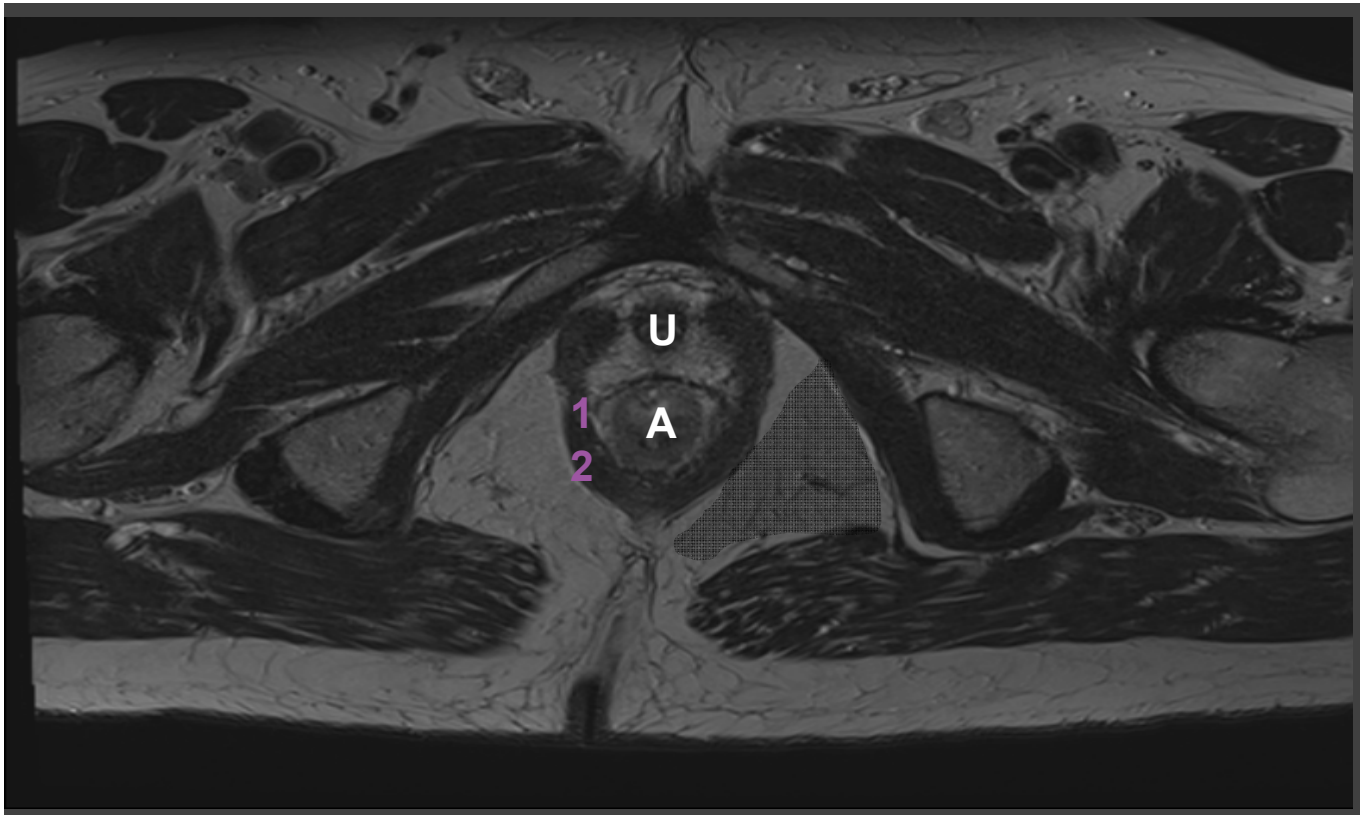

1. M. levator ani
2. M. puborectalis

Urethra

Anal canal

Fossa ischiorectalis/
ischioanalis

Anal canal

- The anal canal extends from the perineal skin to the linea dentata.

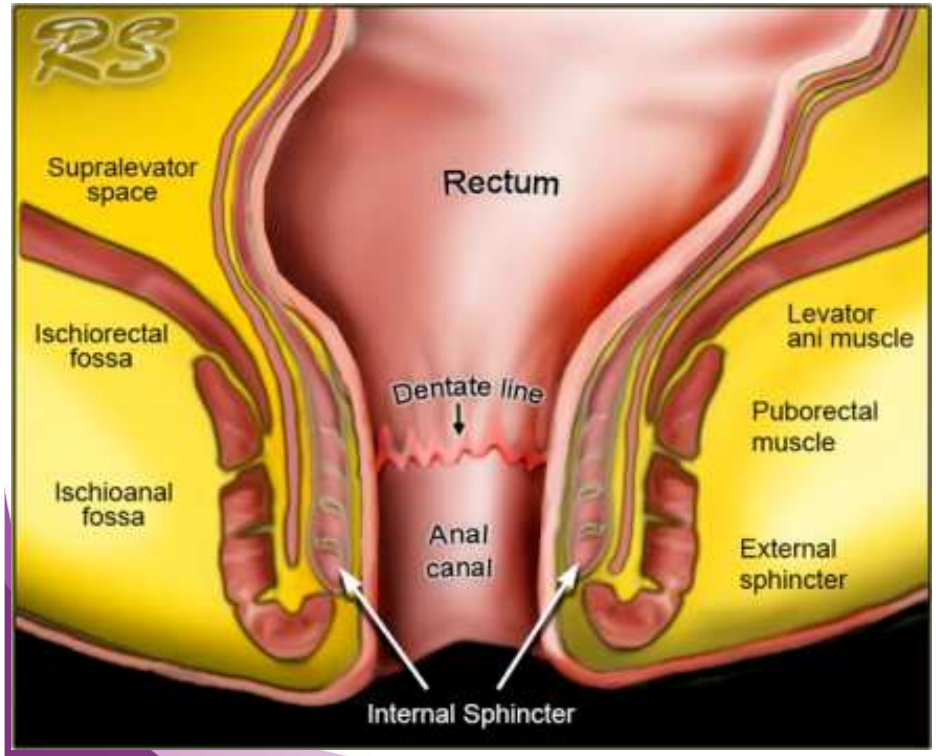

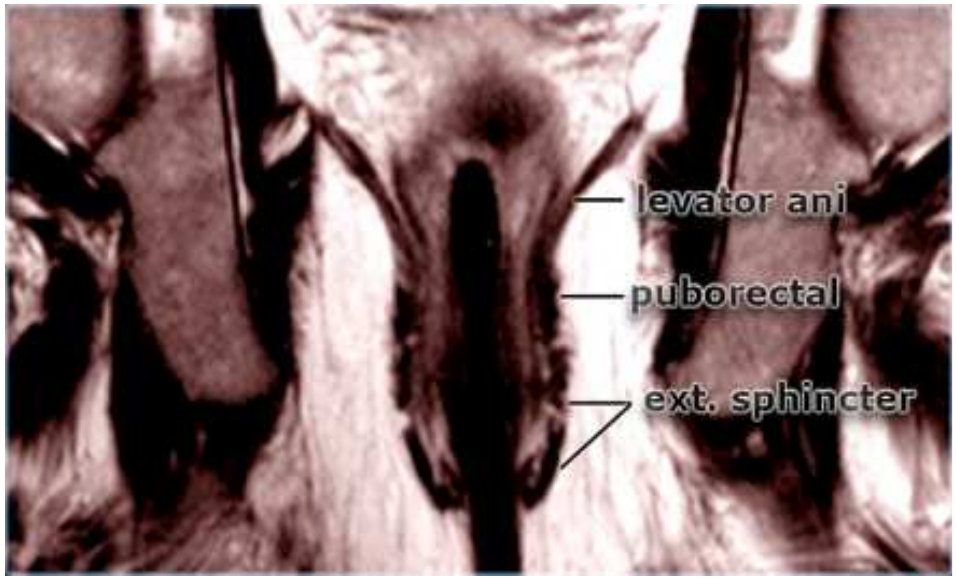

http://www.radiologyassistant.nl

ESTRO School

The TNM stage depends on the degree of Infiltration of the bowel wall and wether the MRF is involved

The microanatomy of the rectum wall is only seen on high resolution T2w

From inside to outside

- Mucosa
- Submucosa
- Muscularis propria
- Mesorectal fat



Rectal cancer in MRI

- In T2w rectal cancer have higher Signal than the mucosa but lower signal than the submucosa
- Higher enhancement of the mucosa after CA

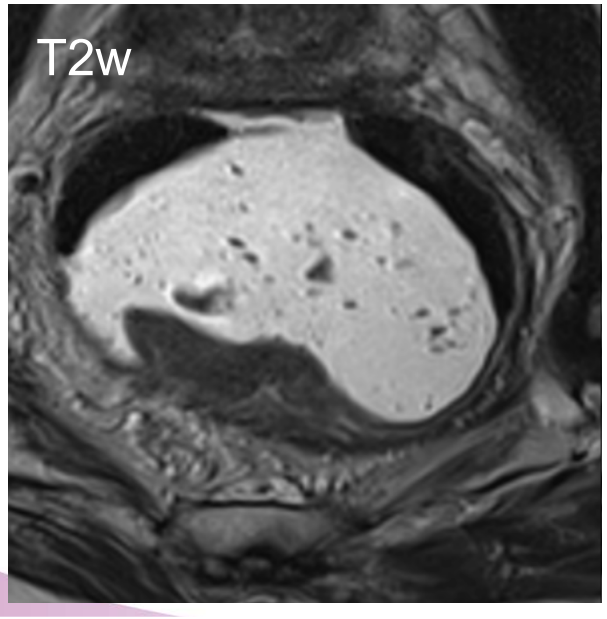

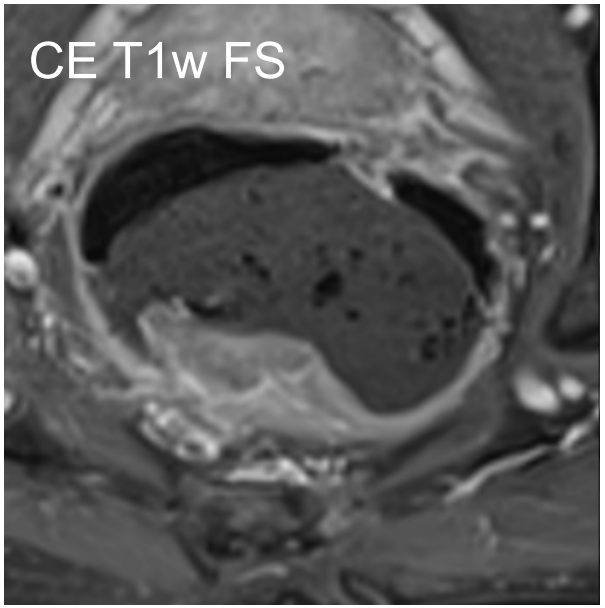

ESTRO School

T-stage in MRI

T1: infiltration of the mucosa / submucosa

T2: infiltration of the muscularis propria

T3: infiltration of the MRF

T4: peritoneal / organ infiltration

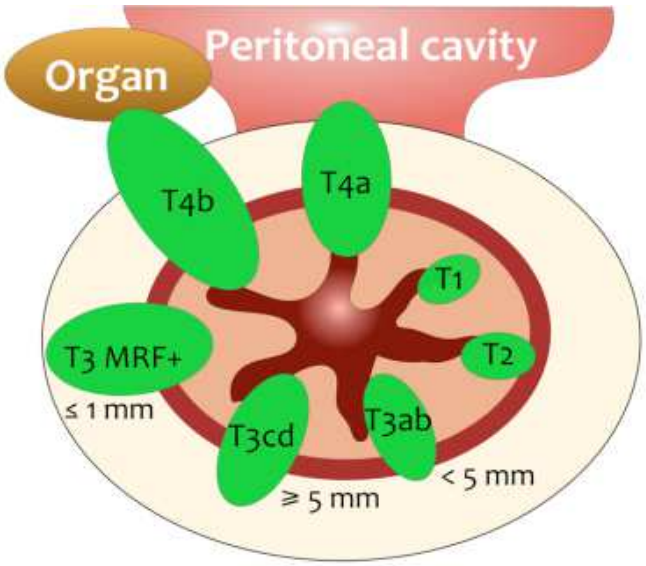

T-Stadium

Sensitivität 87%
Spezifität 75%

Al Sukhni et al. 2012 (21 Studien zwischen 2000 und 2011)

http://www.radiologyassistant.nl

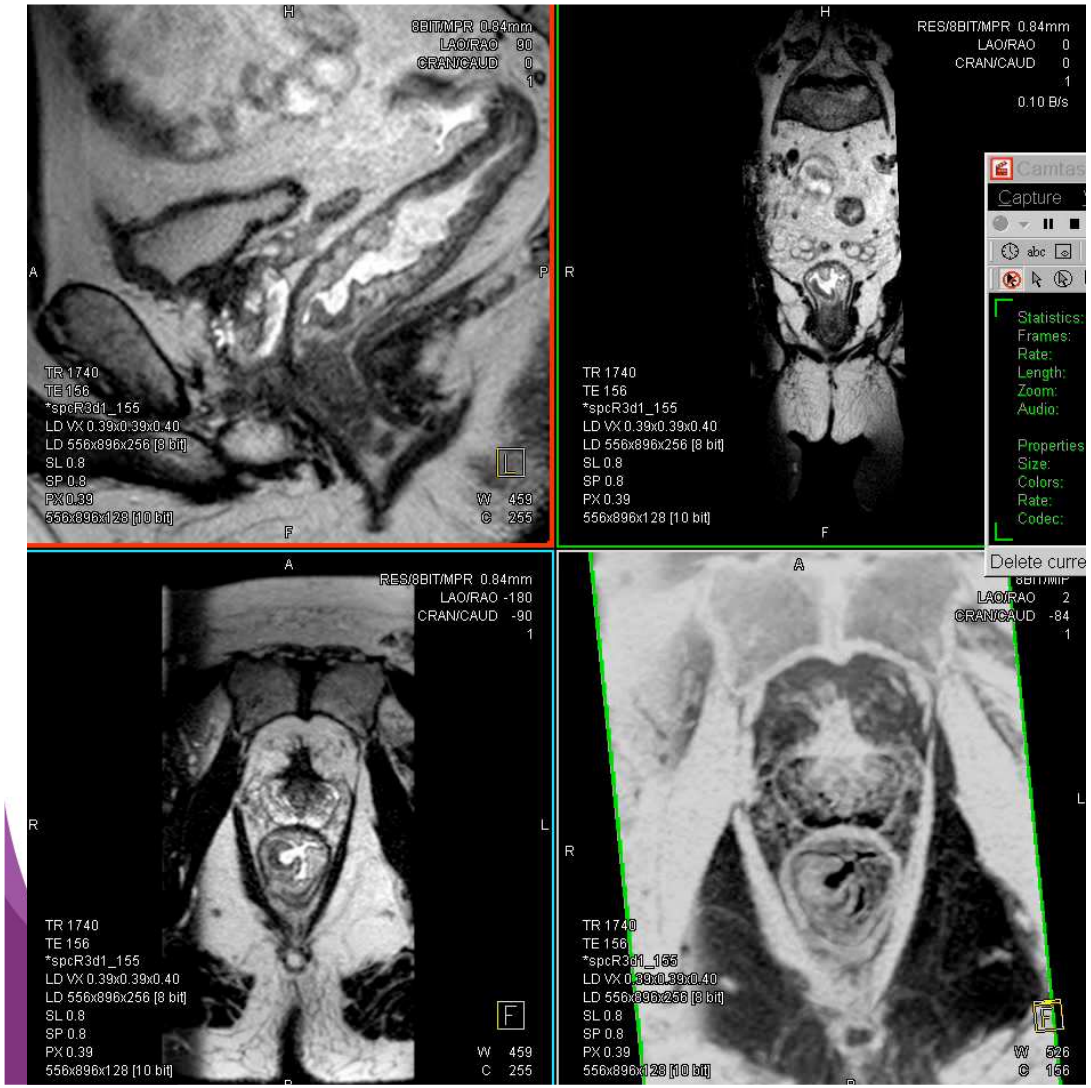

T1

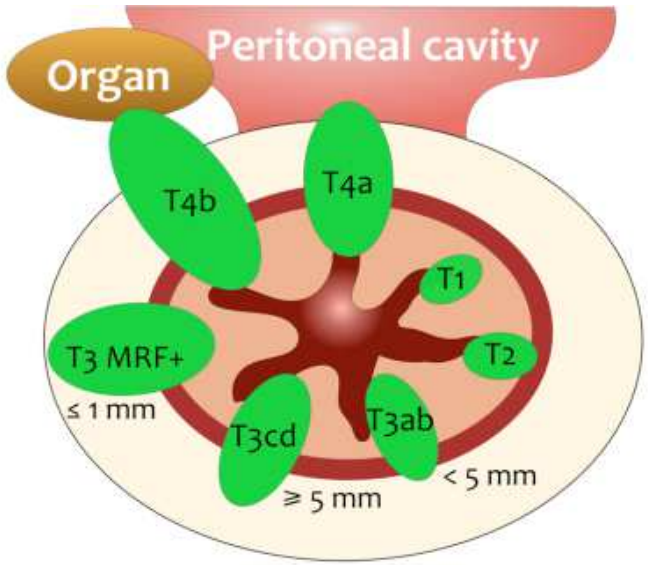

T-Stadium

Sensitivität 87%
Spezifität 75%

Al Sukhni et al. 2012 (21 Studien zwischen 2000 und 2011)

http://www.radiologyassistant.nl

ESTRO School

T-stage in MRI

T1: infiltration of the mucosa / submucosa

T2: infiltration of the muscularis propria

T3: infiltration of the MRF

T4: peritoneal / organ infiltration

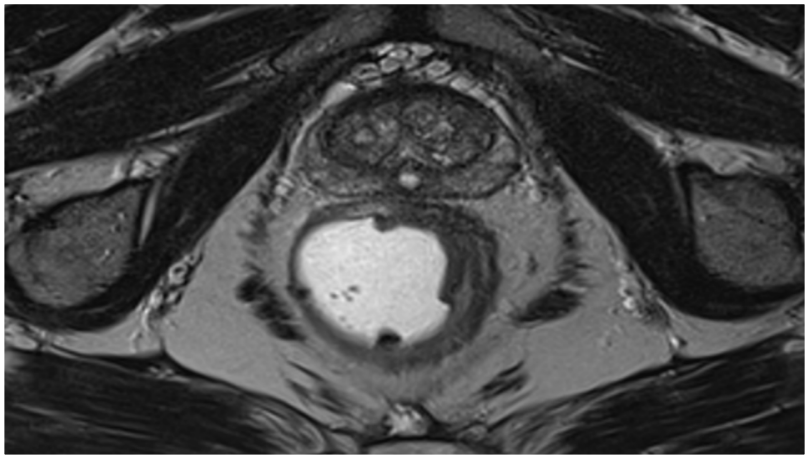

T2

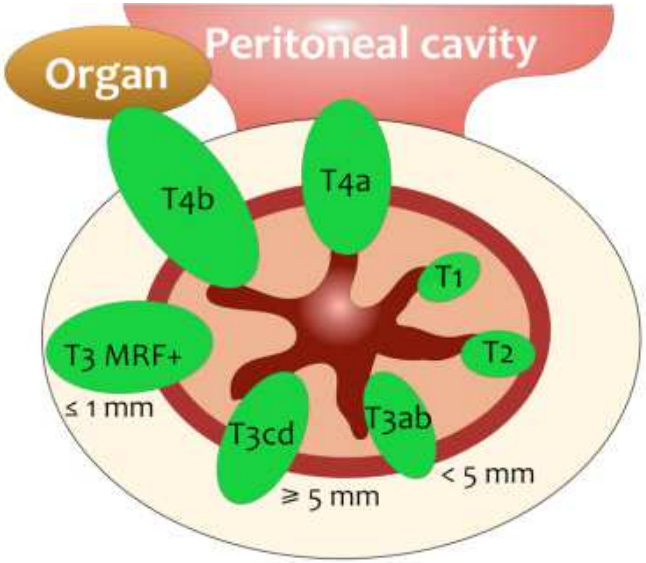

T-Stadium

Sensitivität 87%
Spezifität 75%

Al Sukhni et al. 2012 (21 Studien zwischen 2000 und 2011)

http://www.radiologyassistant.nl

ESTRO School

T-stage in MRI

T1: infiltration of the mucosa / submucosa

T2: infiltration of the muscularis propria

T3: infiltration of the MR fat

T4: peritoneal / organ infiltration

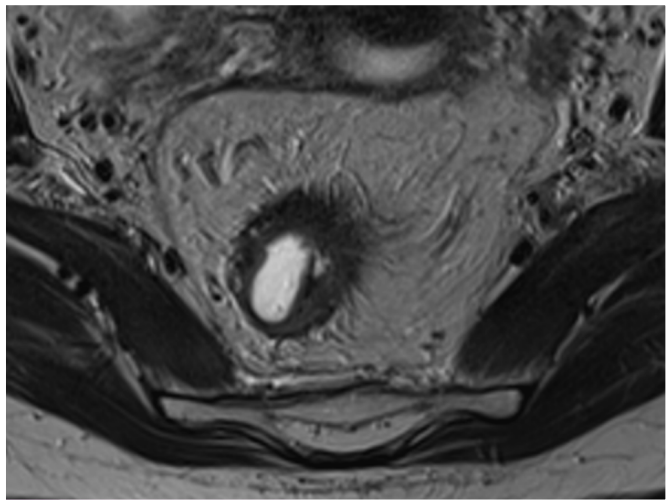

T3

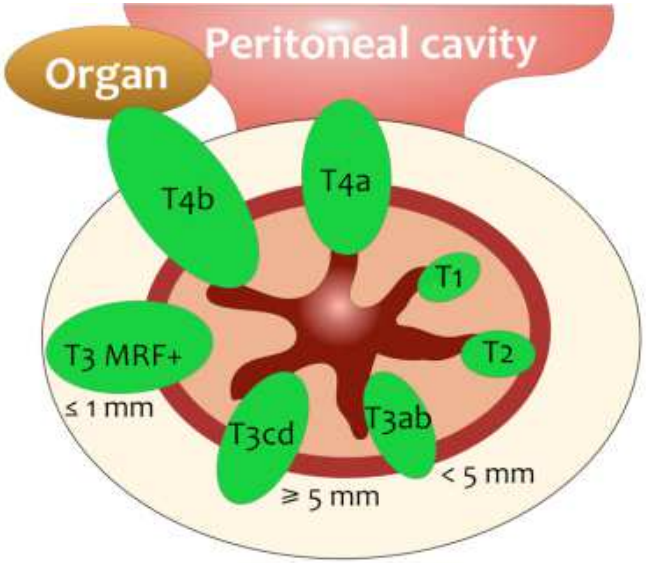

T-Stadium

Sensitivität 87%
Spezifität 75%

Al Sukhni et al. 2012 (21 Studien zwischen 2000 und 2011)

ESTRO School

T-stage in MRI

T1: infiltration of the mucosa / submucosa

T2: infiltration of the muscularis propria

T3: infiltration of the MRF

T4: peritoneal / organ infiltration

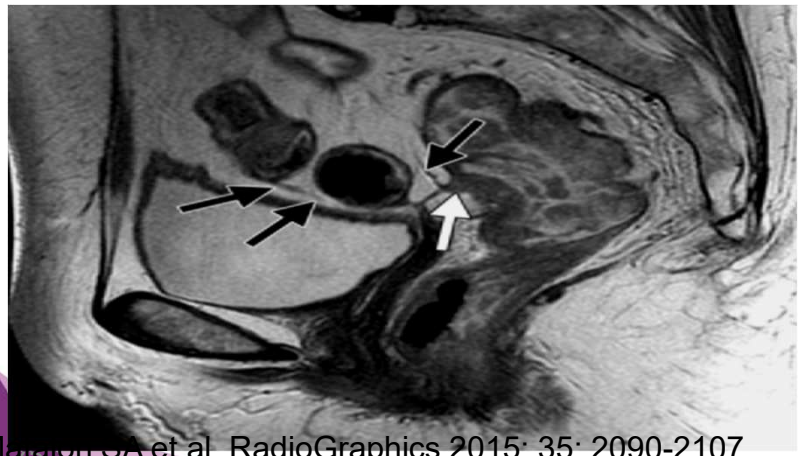

Matalon SA et al. RadioGraphics 2015; 35: 2090-2107

T4a

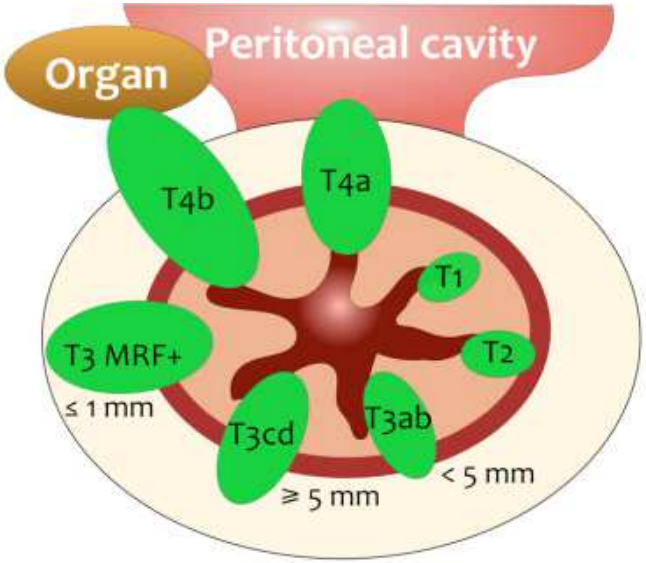

T-Stadium

Sensitivität 87%
Spezifität 75%

Al Sukhni et al. 2012 (21 Studien zwischen 2000 und 2011)

ESTRO School

T-stage in MRI

T1: infiltration of the mucosa / submucosa

T2: infiltration of the muscularis propria

T3: infiltration of the MRF

T4: peritoneal / organ infiltration

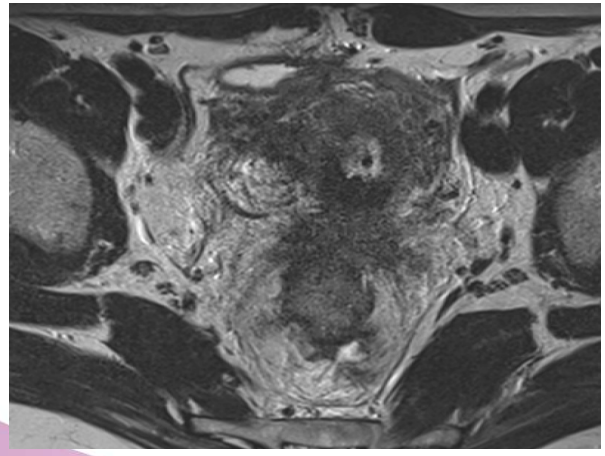

T4b

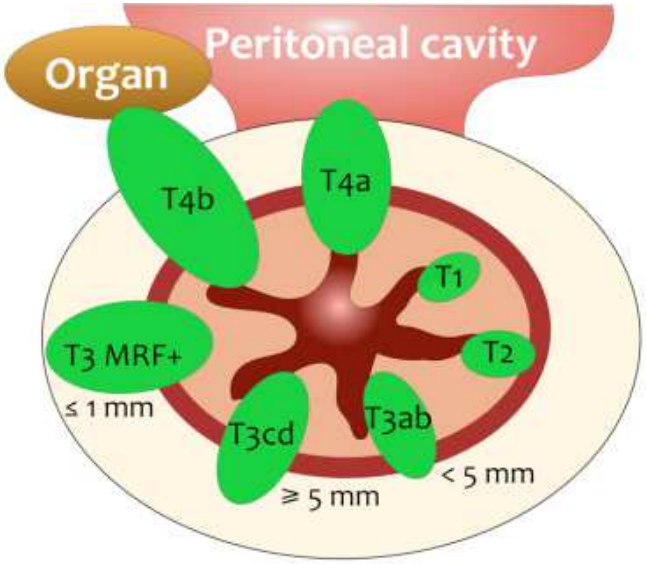

T-Stadium

Sensitivität 87%
Spezifität 75%

Al Sukhni et al. 2012 (21 Studien zwischen 2000 und 2011)

ESTRO School

EMVI

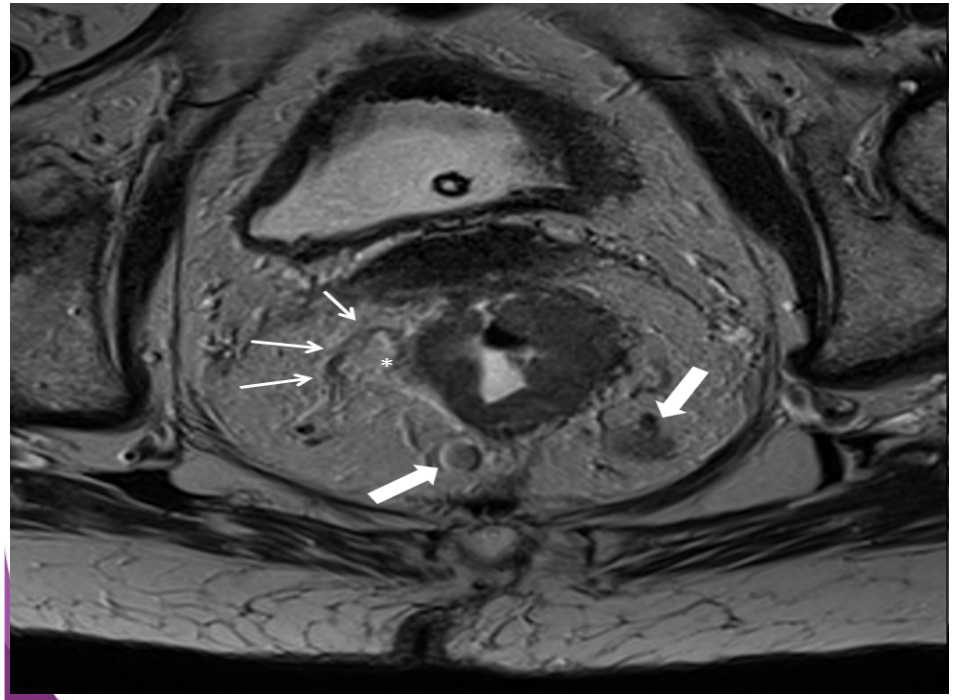

- Extramural vessel infiltration
- Usually veins close to the muscularis propria
- T2 dark spicular infiltration
- Vessel dilatation (thrombosis)

ESTRO School

EMVI

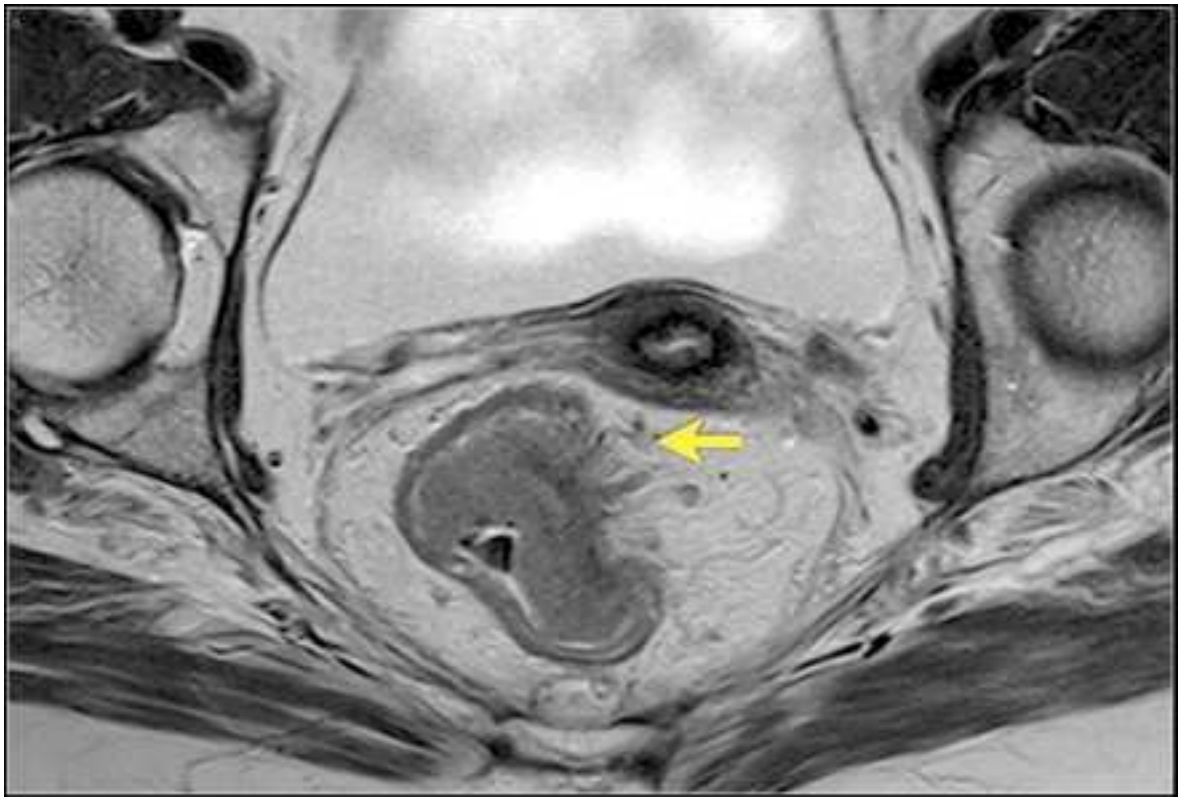

Perirectal stranding

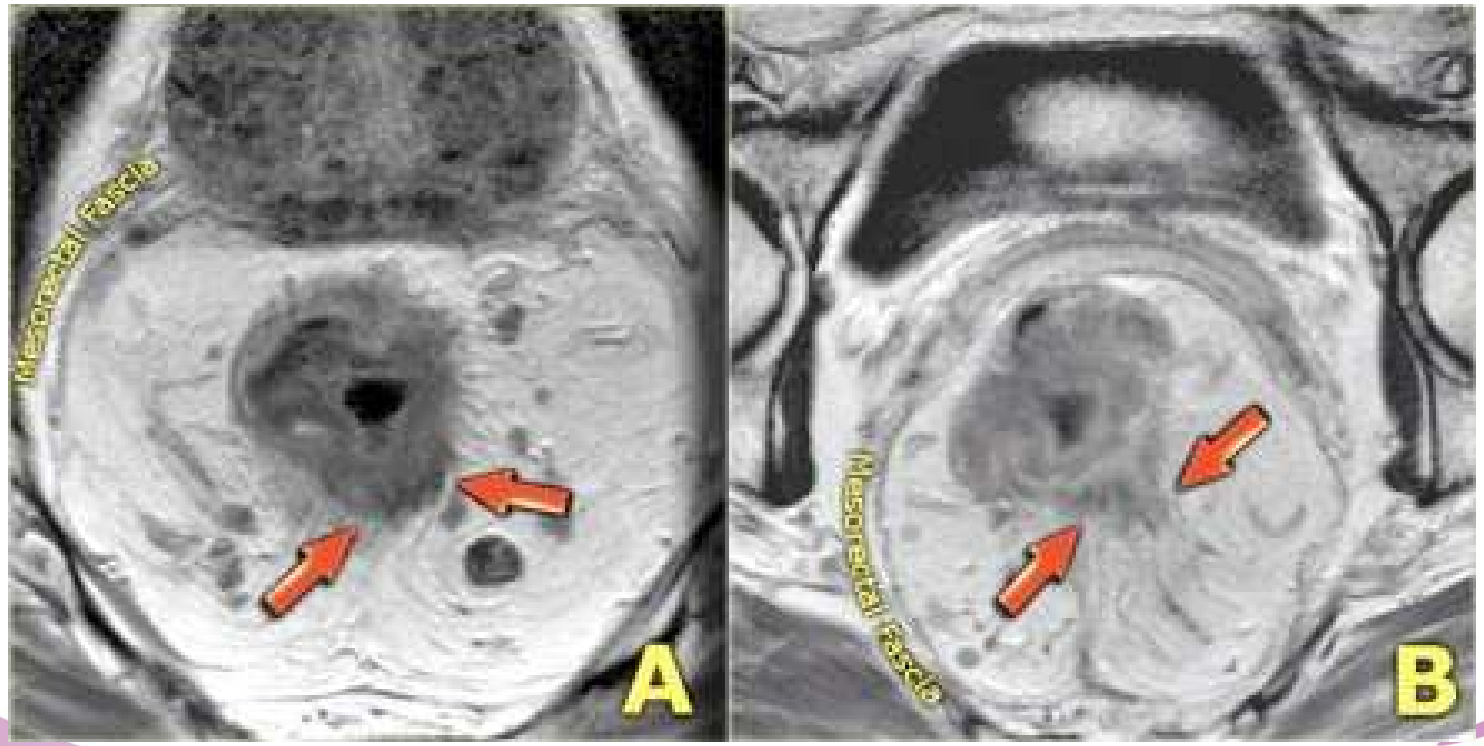

http://www.radiologyassistant.nl

ESTRO School

Infiltration of the intersphincteric space

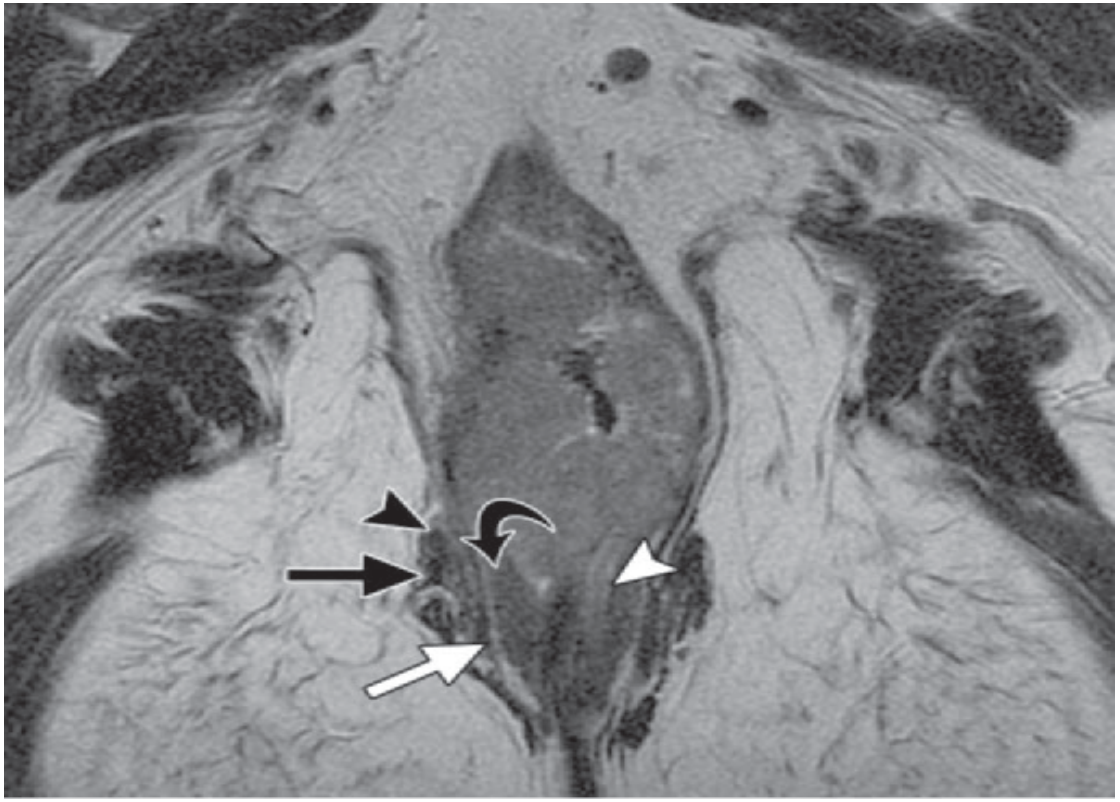

Kaur H et al. RadioGraphics 2012; 32: 389-409

ESTRO School

http://www.radiologyassistant.nl

ESTRO School

Anal cancer

Primary tumor (T)	
TX	Primary tumor cannot be assessed
T0	No evidence of a primary tumor
Tis	Carcinoma in situ
T1	Tumor 2 cm or less in greatest dimension
T2	Tumor more than 2 cm but not more than 5 cm in greatest dimension
T3	Tumor more than 5 cm in greatest dimension
T4	Tumor of any size that invades adjacent organs

ESTRO School

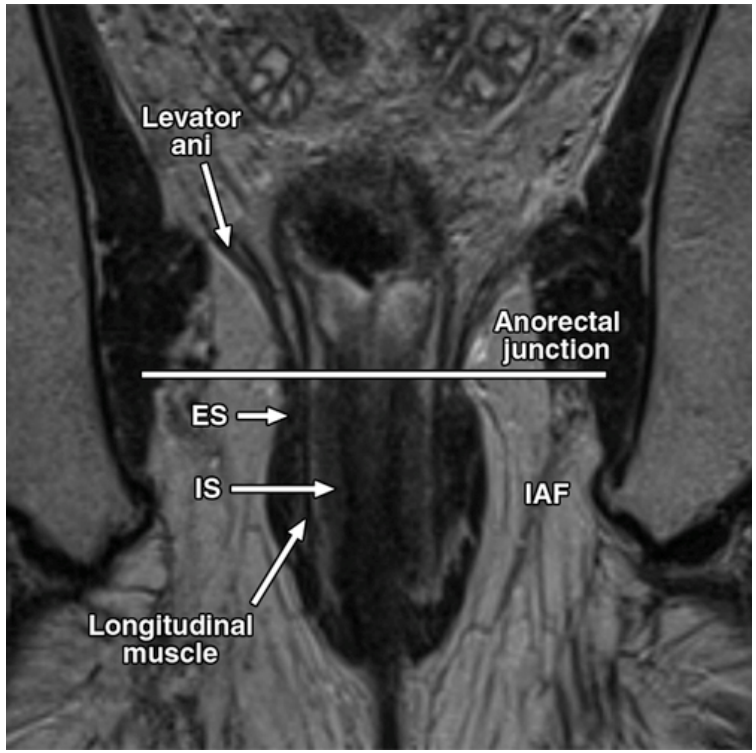

Kochhar et al Imaging of Anal Carcinoma AJR 2012

ESTRO School

T1 tumor

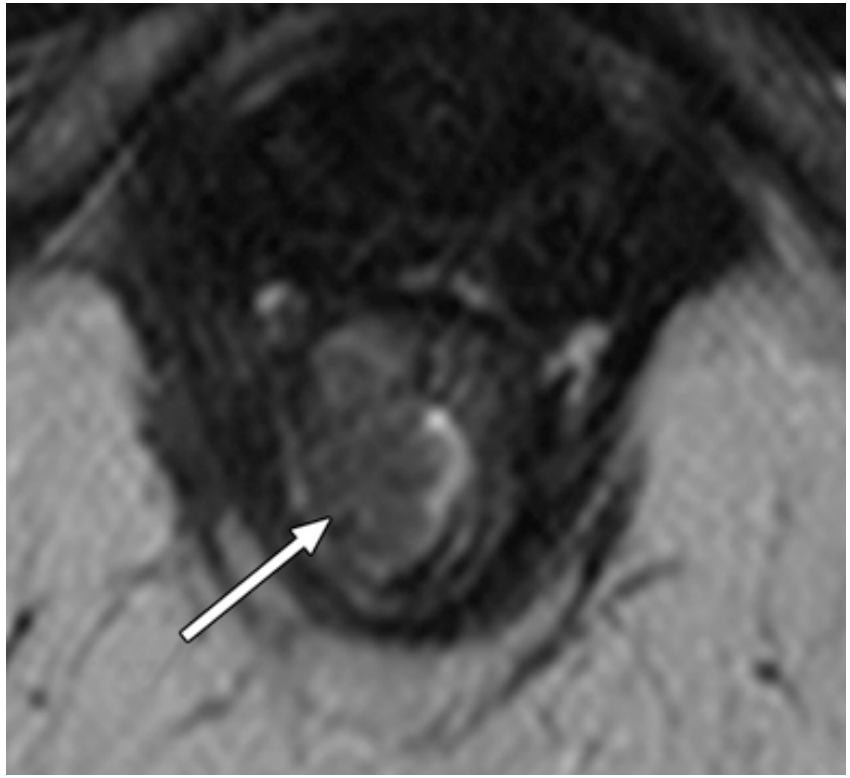

Kochhar et al Imaging of Anal Carcinoma AJR 2012

ESTRO School

T3 anal cancer

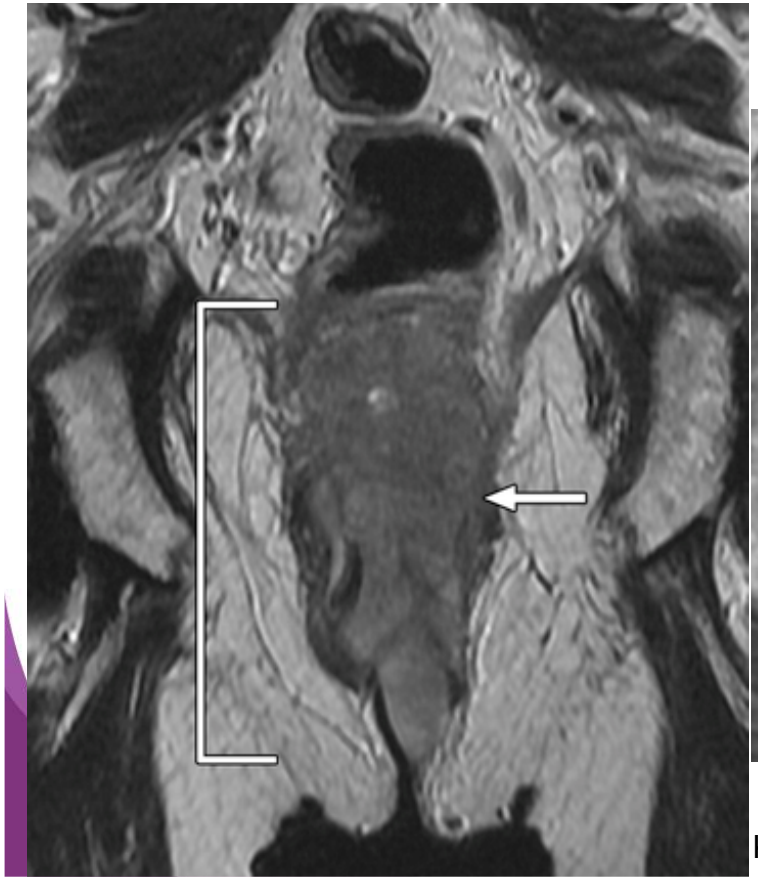

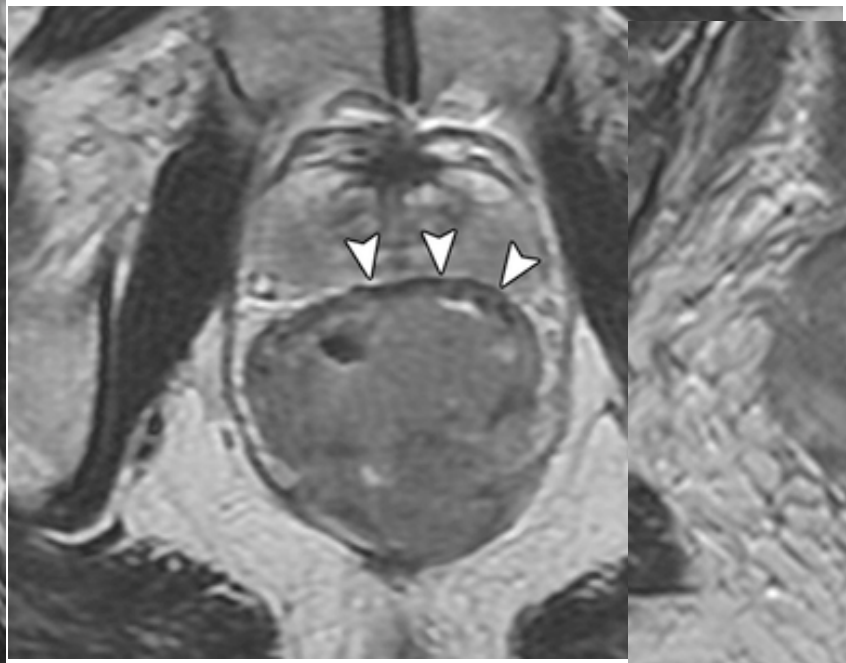

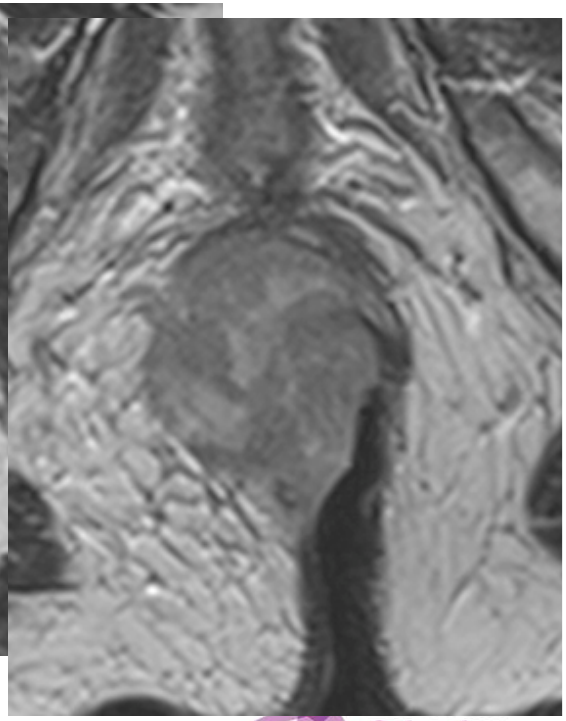

Kochhar et al Imaging of Anal Carcinoma AJR 2012

T4 tumor

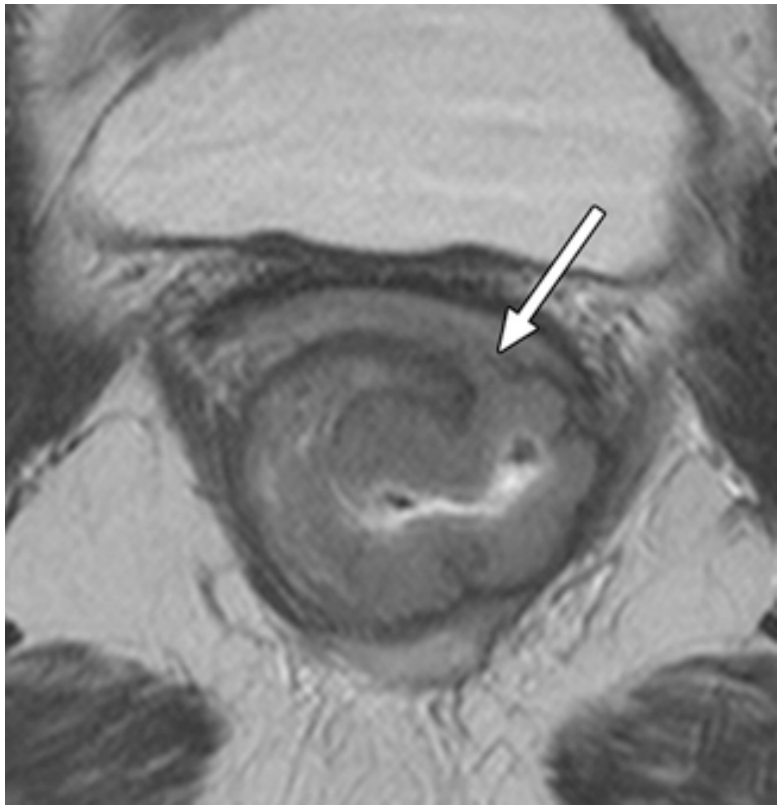

Kochhar et al Imaging of Anal Carcinoma AJR 2012

ESTRO School

N-Stage

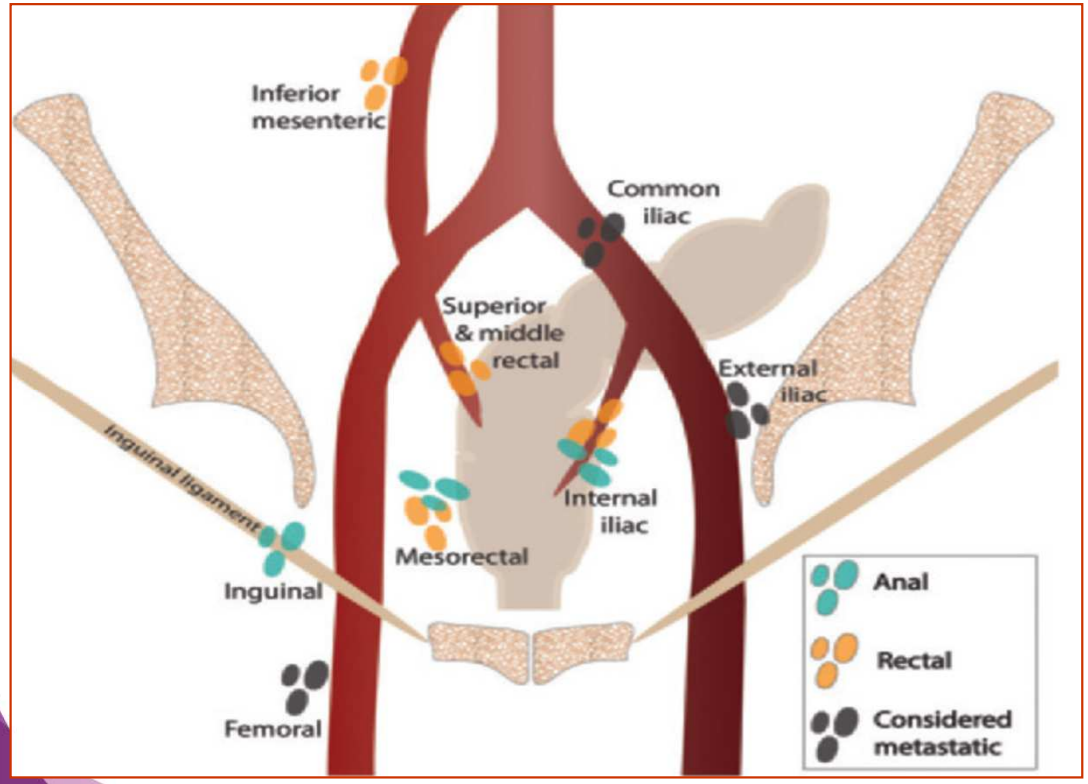

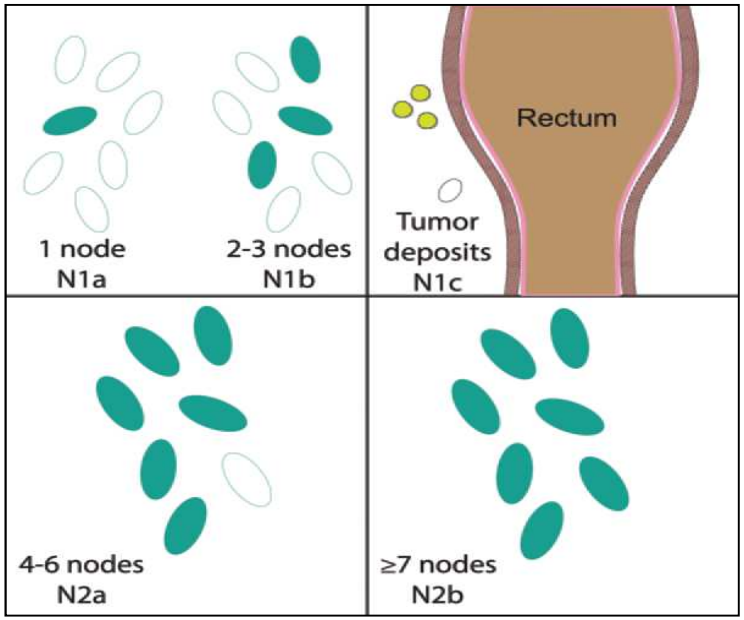

Matalon et al. RadioGraphics 2015; 35: 2090-2107

ESTRO School

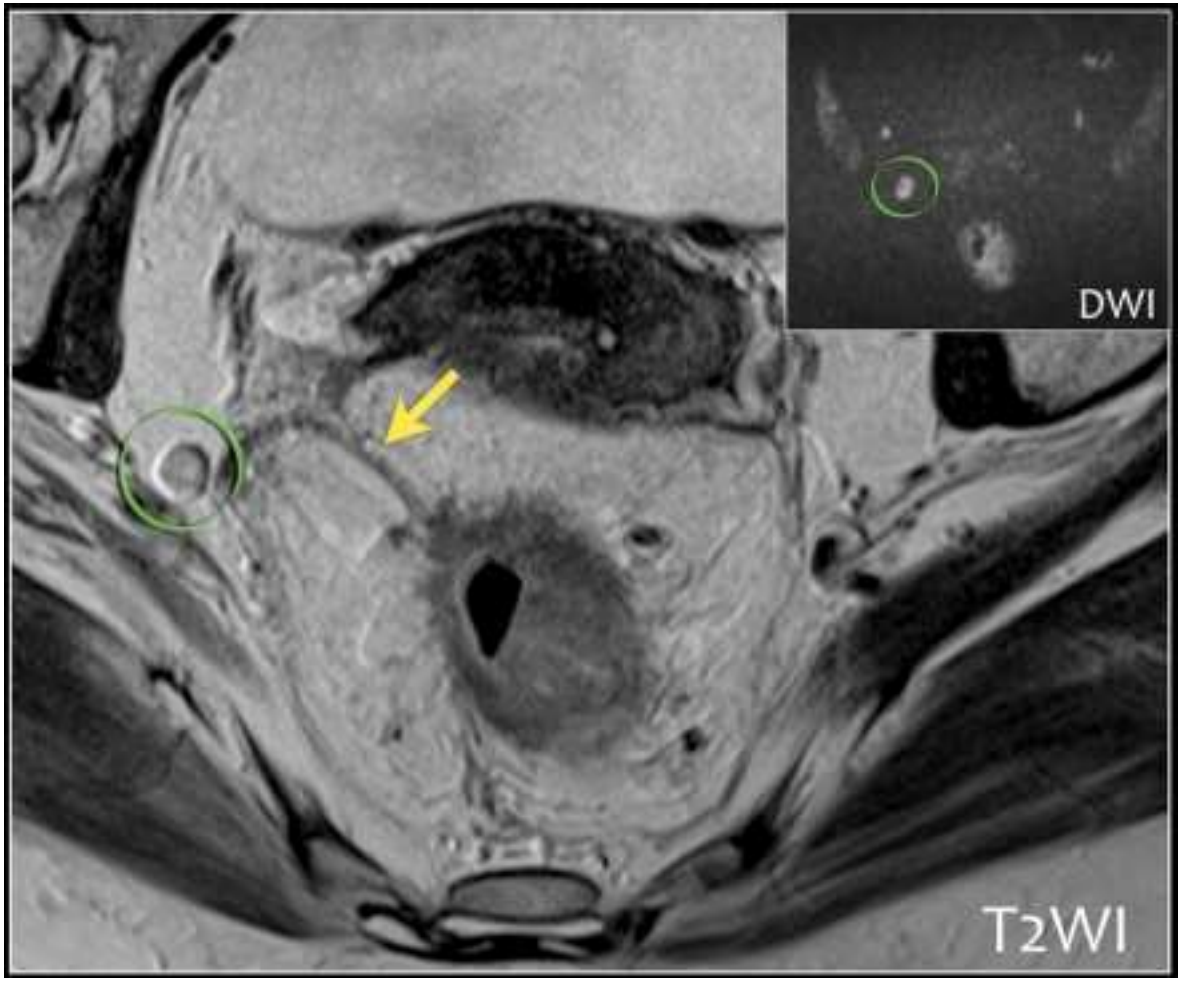

- EMVI

http://www.radiologyassistant.nl

ESTRO School

N-Stage

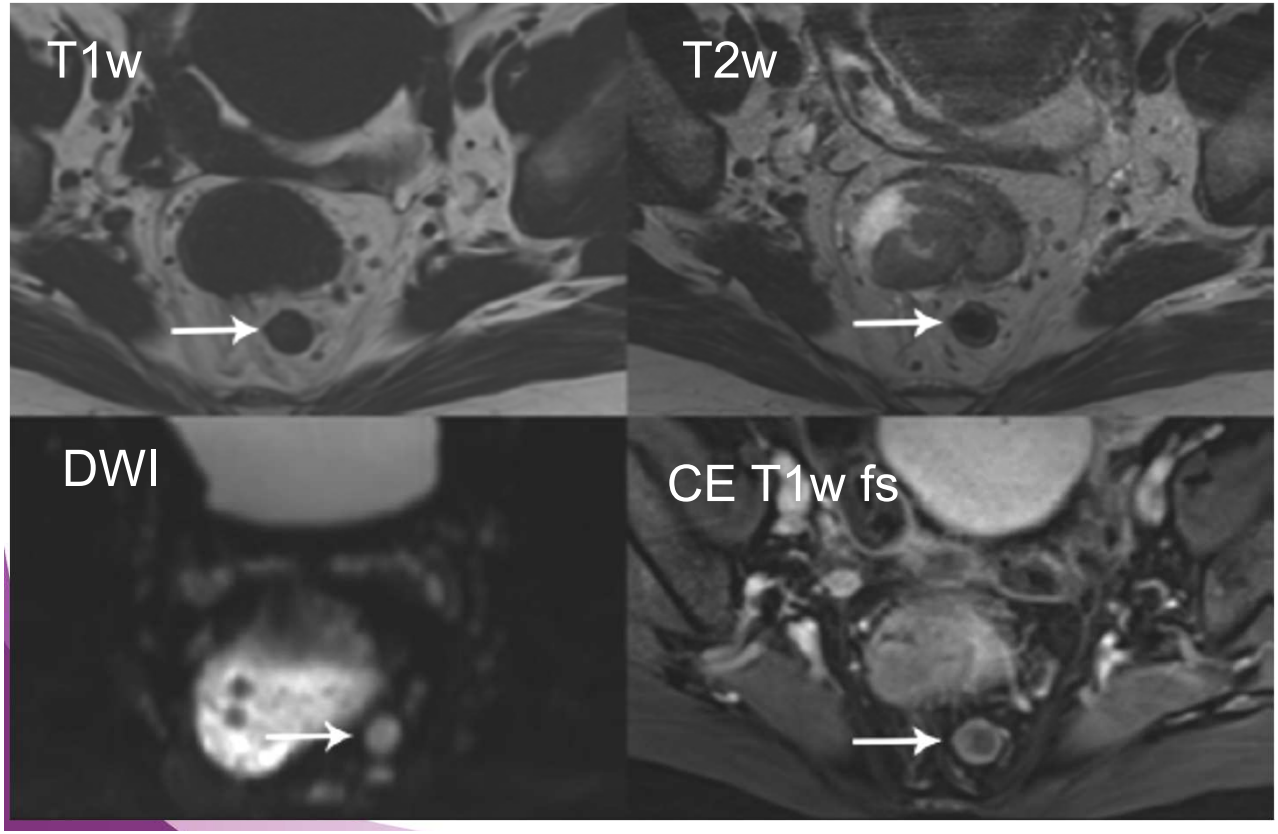

> **5 mm**

Sensitivität 66%

Spezifität 76%

(Brown et a1. 2003)

Heterogeneous

DWI

ESTRO School

N-stage - suspicious nodes

Malignant characteristics	Indistinct	Heterogeneous	Round
	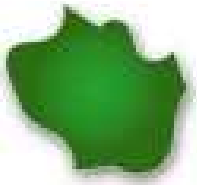		
Short axis	- < 5mm : needs 3 malignant characteristics - 5 -9mm : needs 2 malignant characteristic - > 9mm : always suspicious		

PET CT

http://www.radiologyassistant.nl

ESTRO School

Outlook

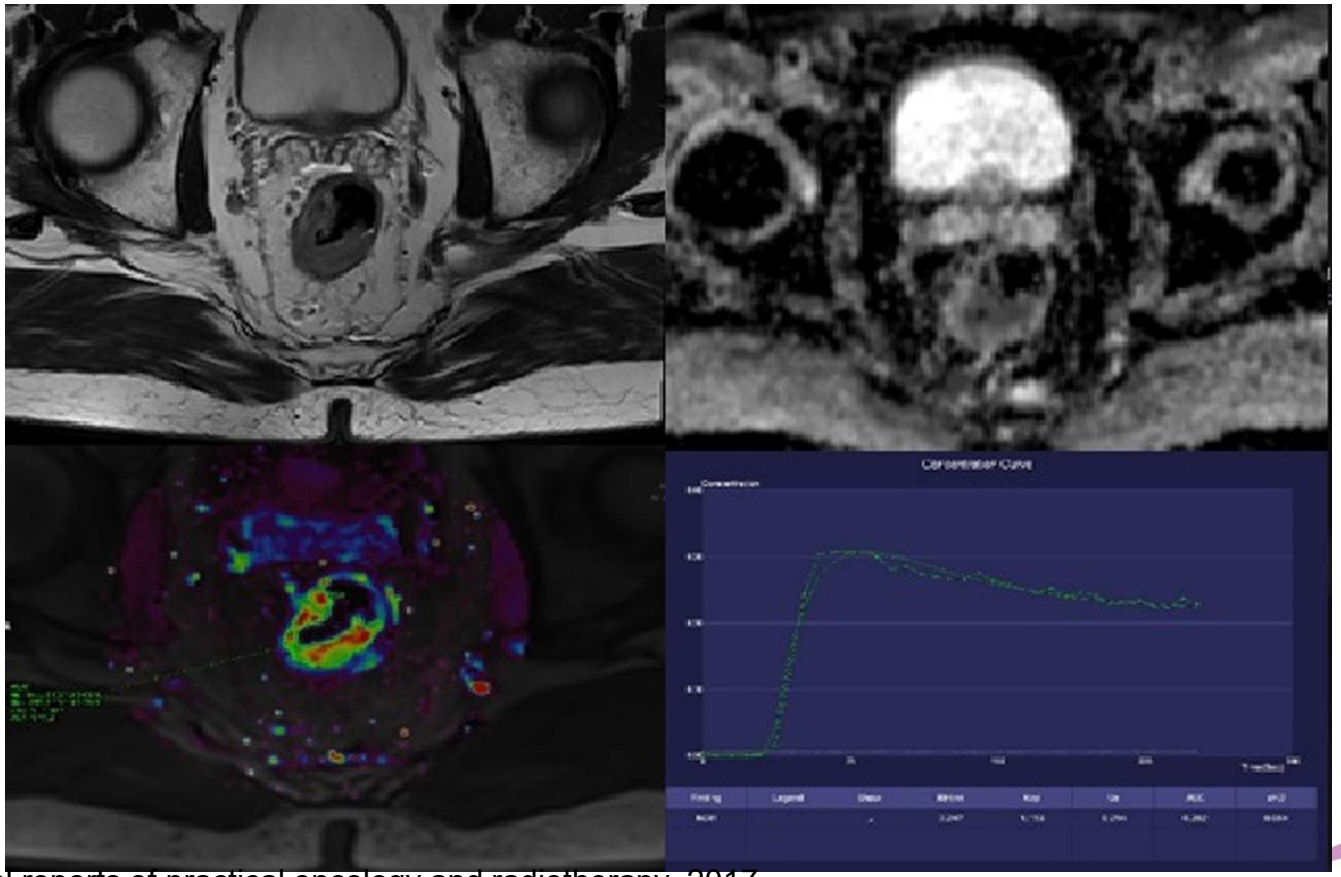

Vojtíseka et al reports of practical oncology and radiotherapy 2017

ESTRO School

ESTRO School

Target Volume Determination

From Imaging to Margins

Lisbon, 25-28 June 2017

Rectal Cancer: GTV, CTV and OAR

Maria Antonietta Gambacorta

Radiotherapy Department

Università Cattolica del Sacro Cuore

Rome Italy

Gemelli ART Advanced Radiation Therapy

SHORT COURSE
LONG COURSE

after 2000 randomized trials

Trial	Pre ERT	Winner
German trial	Pre RT+ vs Post RT	Pre RT

Trial	Short ERT	Winner
Duch Trial	SC RT+TME vs TME	SC RT
MRC C07	SC RT+TME vs TME	SC RT

Trial	Long ERT	Winner
EORTC 22921	LC RT vs C-RT	C-RT
FFCD 9203	LC RT vs C-RT	C-RT
Scandinavian	LC RT vs C-RT	C-RT

Trial	Short vs Long	Winner
Polish Trial	SC RT vs C-RT	=
TROG Trial	SC RT vs C-RT	C-RT

after 2000 randomized trials

SURVIVAL
no improvement

Local control
improvement

Toxicity
increased

Radiotherapy modalities

Short course immediate surgery



25 Gy; 5 Gy/day; 5 days

Long course delayed surgery



5 weeks

Gemelli ART Advanced Radiation Therapy

Role of Radiotherapy

LOCALCONTROL

Short course

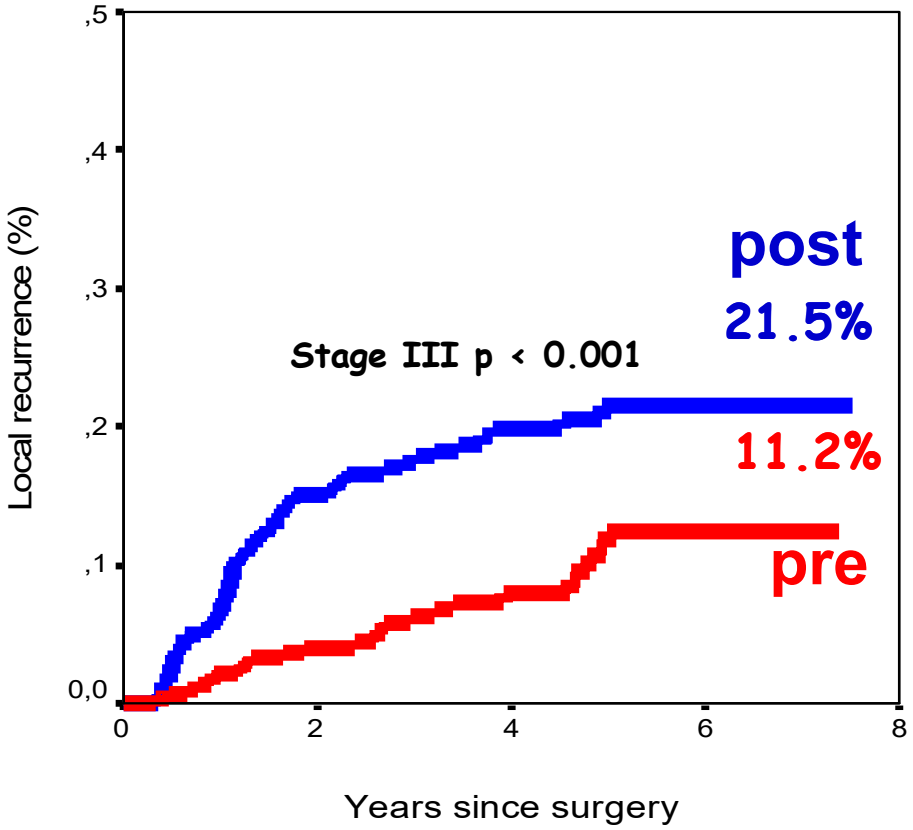

Long course

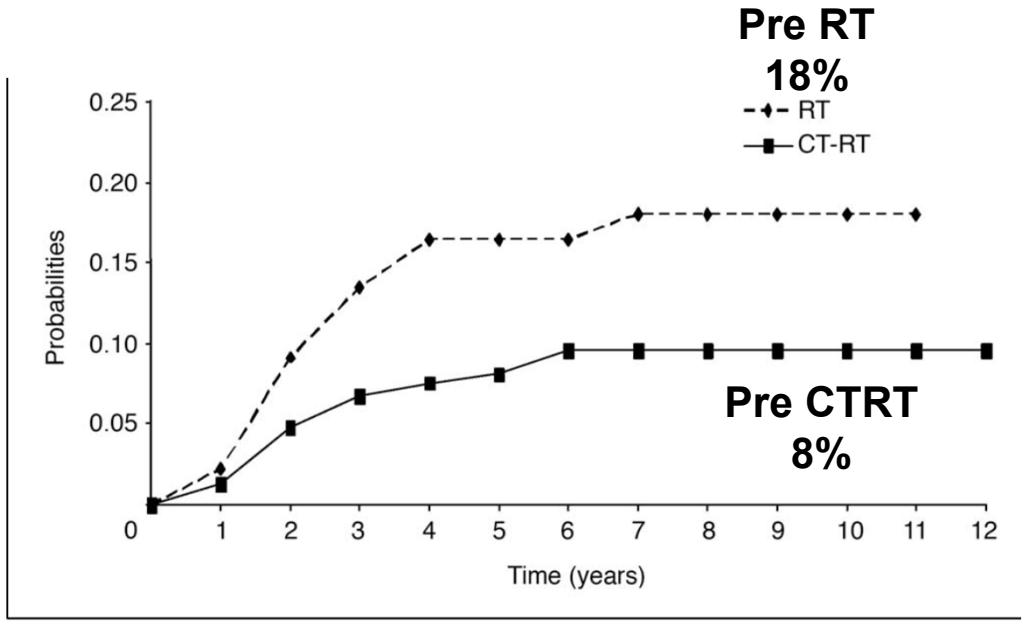

Peeters KC et AL – Ann Surg – 2007

Gérard JP et AL – JCO– 2006

Circurferential Resection Margin

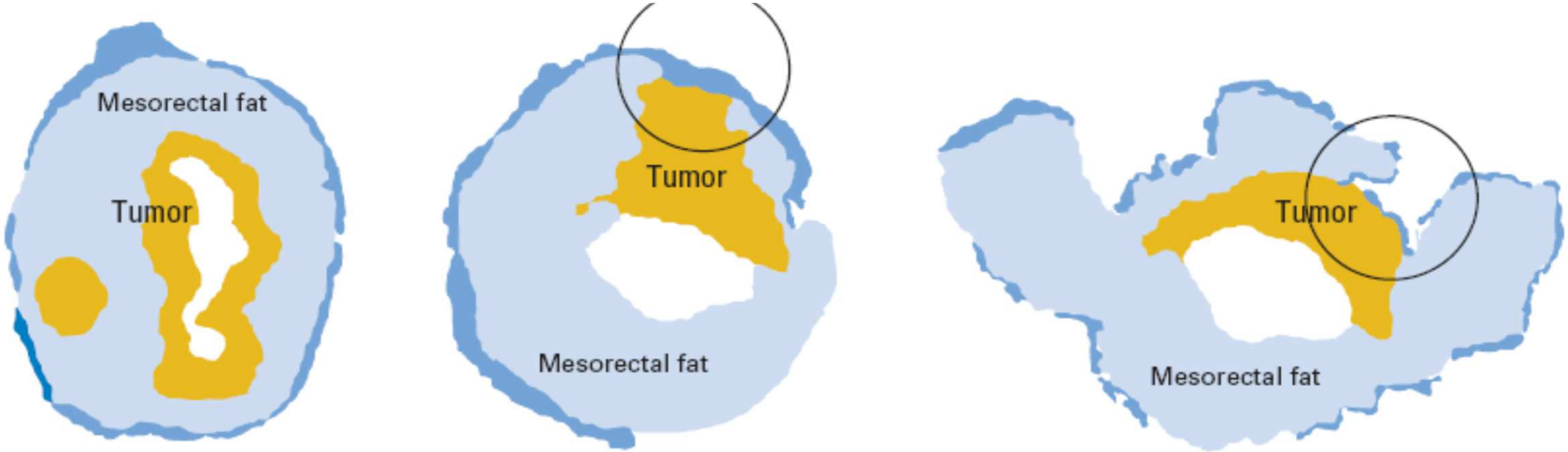

Naagtegaal et al. JCO 2009

CRM and Oucomes

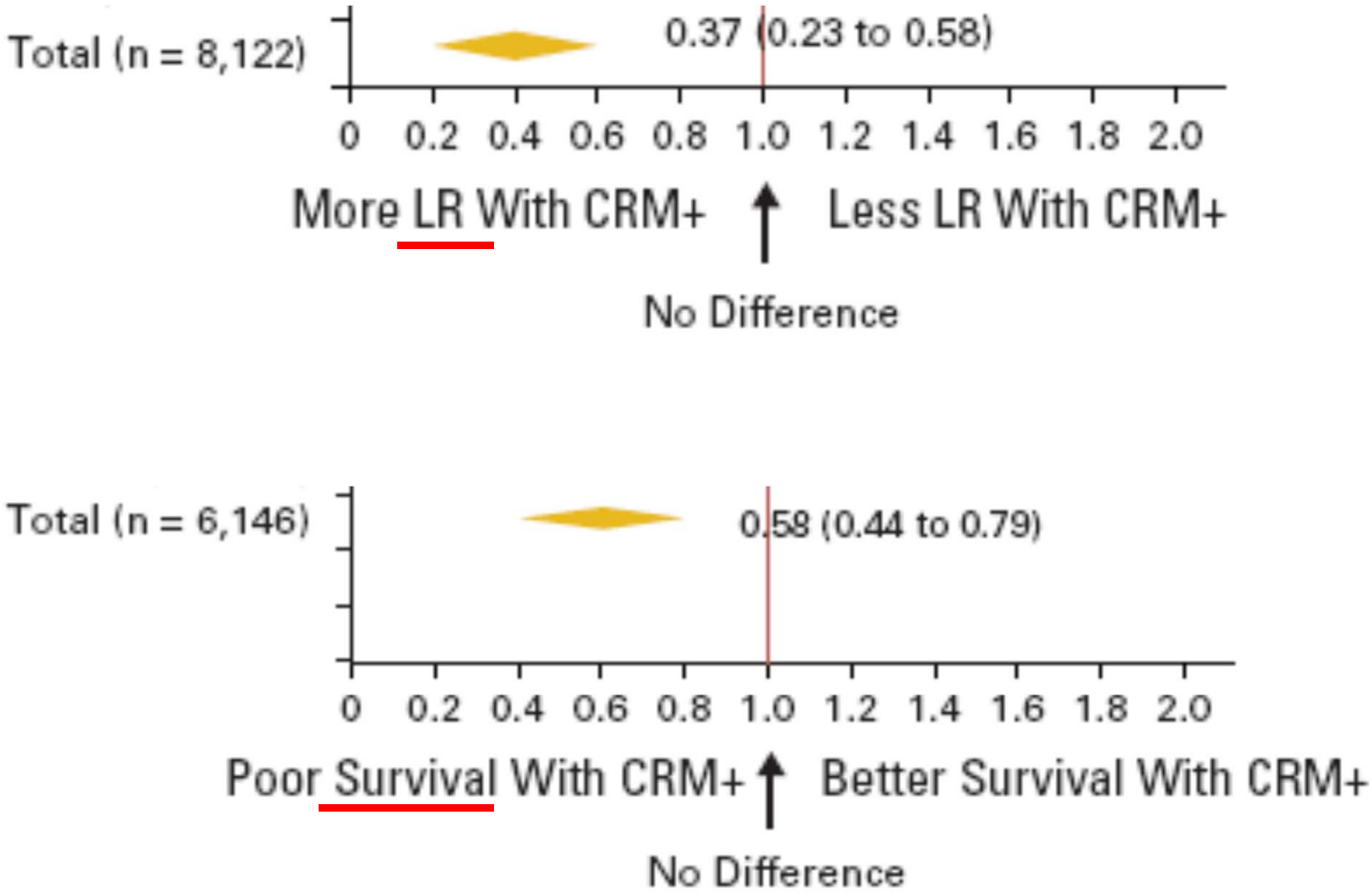

Naagtegaal et al. JCO 2009

Role of Radiotherapy

TUMOR DOWNSTAGING

preradiation

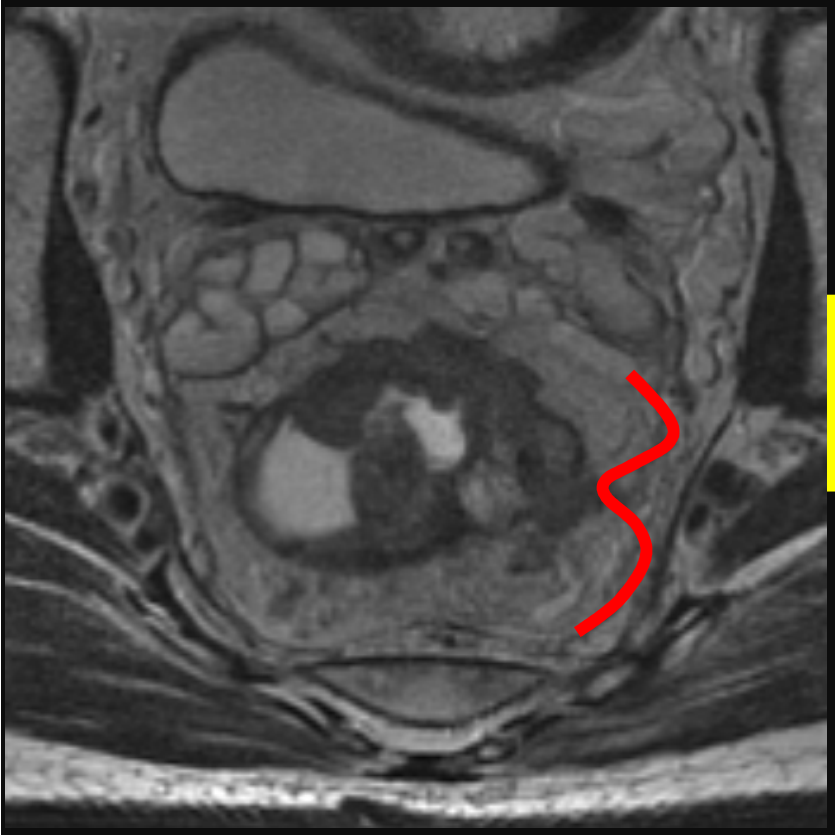

LC-CRT

postradiation

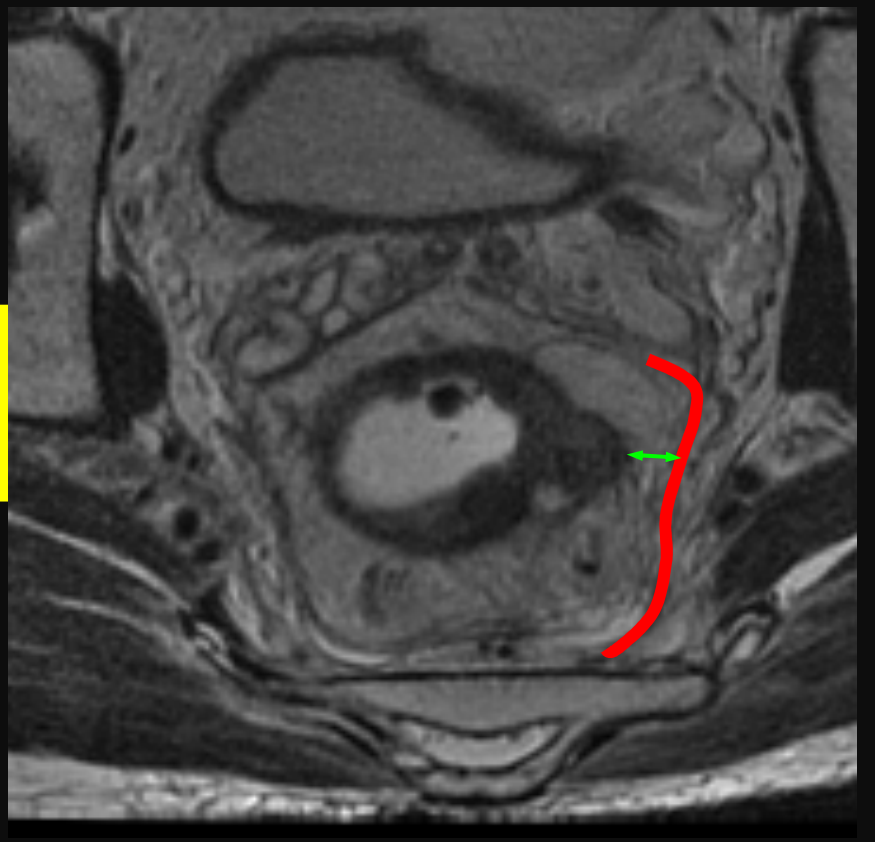

Role of Radiotherapy

	Preop **Short RT**	Preop **Long RTCH**
pCRM+	**13 %**	**4 %**

p = 0.017

Bujko K et al, Radioth Oncol 2006

Radiotherapy aims

Short course immediate surgery

Downstaging NOT needed

Long course delayed surgery

Downstaging needed

Radiotherapy technique

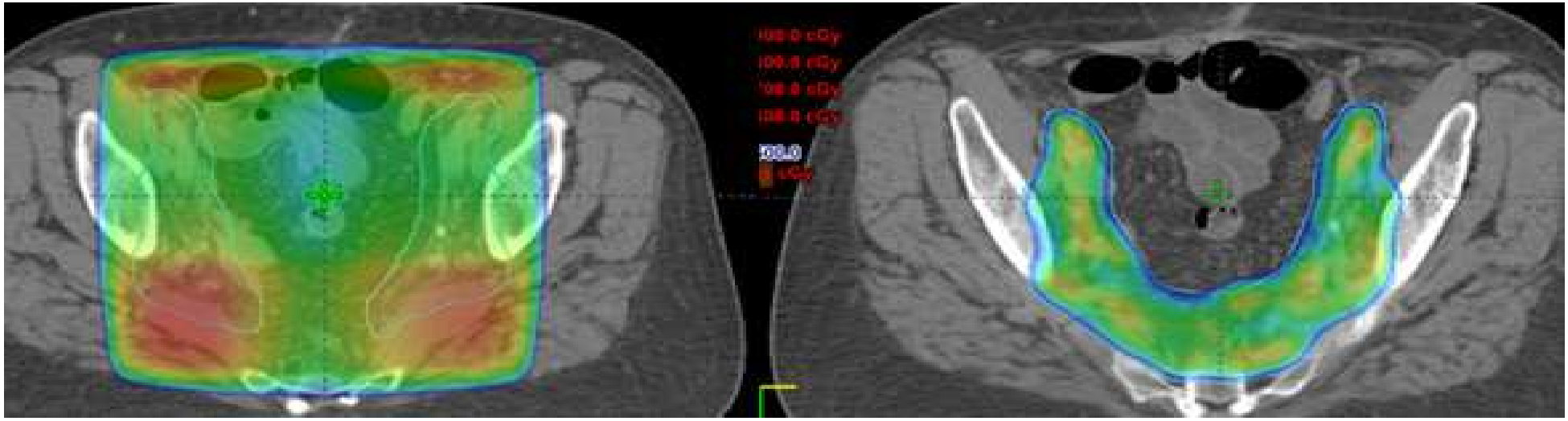

The need for guidelines

NO

GL

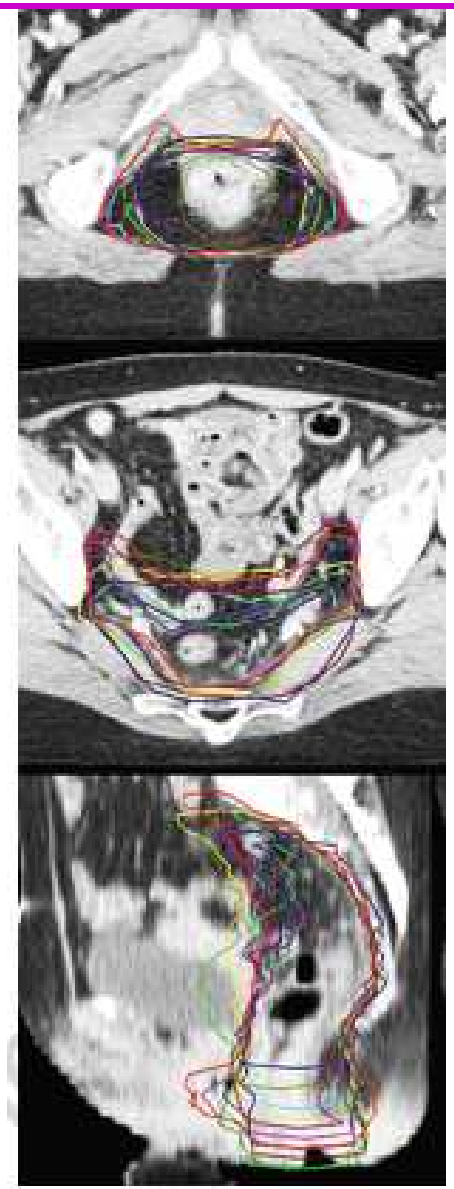

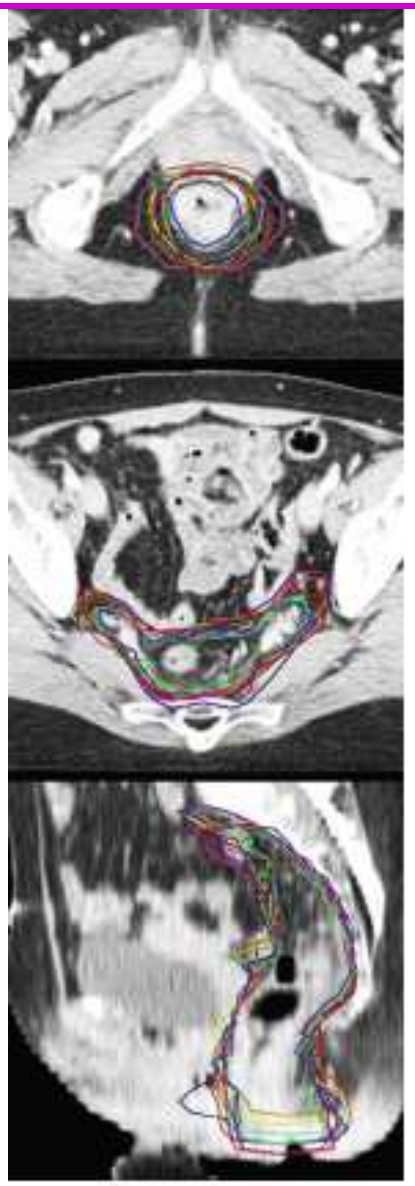

YES

GL

Nijkamp J et al. Multidisciplinary Magement of Rectal Cancer 2012

Guidelines: Multiple publications

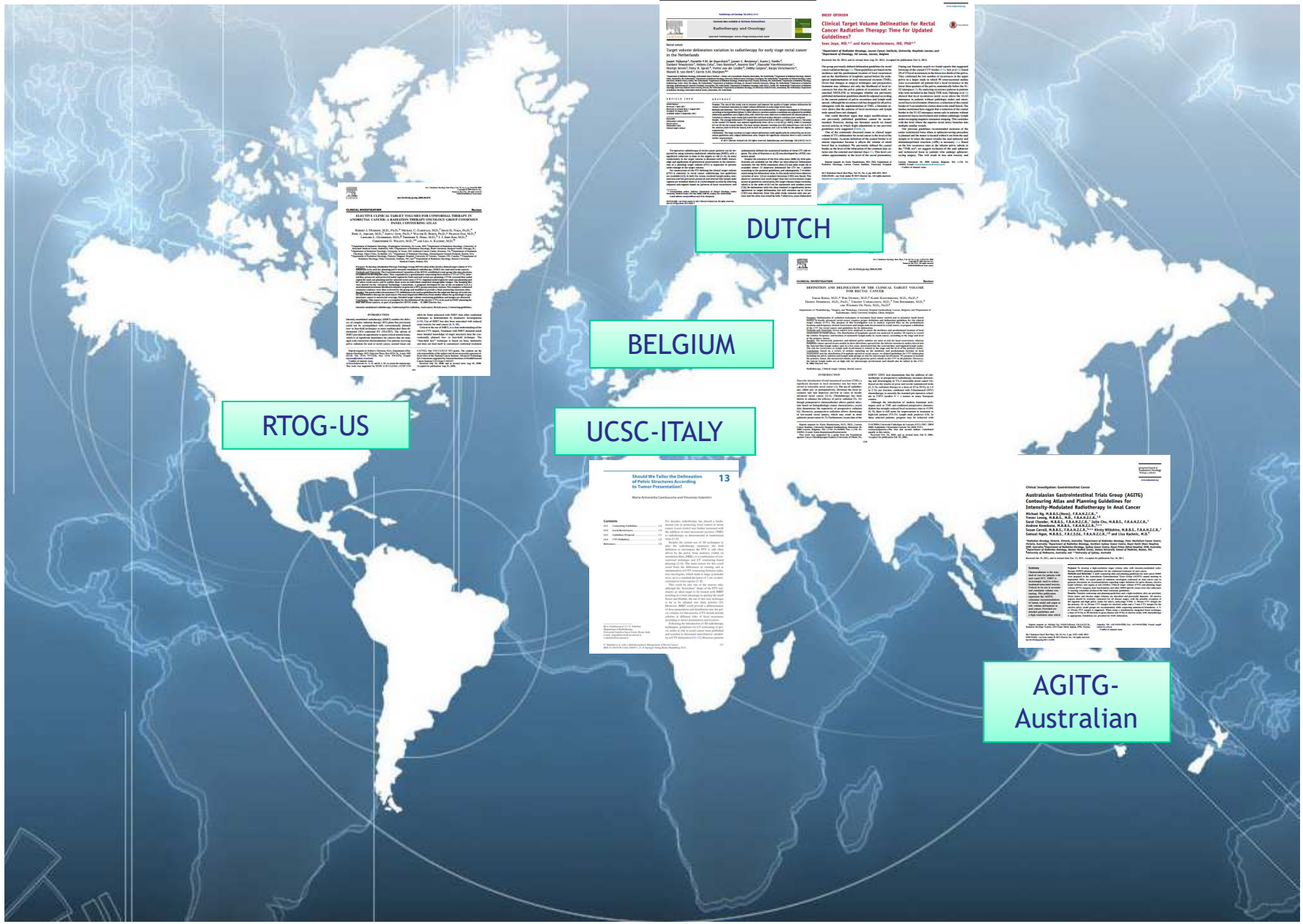

An **Inter-Society** Consensus in rectal cancer delineation

V. Valentini C. Marijnen

ESTRO
European Society for
RADIOTHERAPY
& ONCOLOGY

P. Das L. Kachnic

ASTRO
TARGETING CANCER CARE

P. Maingon K.Haustermans

EORTC
European Organisation for Research
and Treatment of Cancer

S. Ngan

The Royal Australian
and New Zealand
College of Radiologists

and the support of M.A. Gambacorta, G. Chiloiro and I. Joye

Radiotherapy and Oncology 120 (2016) 195–201

Contents lists available at ScienceDirect

Radiotherapy and Oncology

journal homepage: www.thegreenjournal.com

Rectal cancer guidelines

International consensus guidelines on Clinical Target Volume delineation in rectal cancer

Vincenzo Valentini [a], Maria Antonietta Gambacorta [a,*], Brunella Barbaro [b], Giuditta Chiloiro [a], Claudio Coco [c], Prajnan Das [d], Francesco Fanfani [e], Ines Joye [f], Lisa Kachnic [g], Philippe Maingon [h], Corrie Marijnen [i], Samuel Ngan [j], Karin Haustermans [f]

[a] *Università Cattolica del Sacro Cuore, Radiation Oncology Department;* [b] *Università Cattolica del Sacro Cuore, Department of Radiological Sciences;* [c] *Università Cattolica del Sacro*

An **Inter-Society** Consensus in rectal cancer delineation

the process

- Step 1: comparison of the current and available published guidelines.
- Step 2: selection of RC cases with different clinical stages and tumor location for delineation agreement exercises on the Falcon platform.
- Step 3: selection of CT scan slices considered significant in terms of potential disagreement for each case and delineation of RC cases following previously published guidelines.
- Step 4: meeting to discuss the results of the first delineation round, followed by a CTV proposal based on new anatomical boundaries. During this meeting, the pelvic anatomy was reviewed with the aid of a surgeon and a radiologist, both experts in rectal and gynecological cancer.
- Step 5: peer review of the agreed consensus.
- Step 6: meeting to validate the final consensus guidelines.
- Step 7: completion of RC delineation atlases for publication on the Falcon platform.

Step 1: Guidelines comparison

GL	METHOD	TUMOR SITE	T-stage	IMAGING	POSITION	SUBSITES
UCSC Italy 2004-2012	Experts review	Rectum	none	CT-visible human	Prone	yes
BELGIUM 2006-2015	Site of recurrence Expert review	Rectum	none	CT-MR	Supine	yes
RTOG-USA 2009	Delineation comnparison Consensus	Ano-Rectum	cT3N2	CT	Prone	CTV
AGITG-Australia 2012	Consensus	Anus	cT2N0 anus	CT	Supine	yes GTV OAR
DUTCH 2012	Delineation comparison Consensus	Rectum	Early stage	CT-MR	Supine	yes

Guidelines comparison

GL	METHOD	TUMOR SITE	T-stage	IMAGING	POSITION	SUBSITES
UCSC Italy 2004-2012	Expert review	Rectum	none	CT-visible human	Prone	yes
BELGIUM 2006-2015	Site of recurrence Expert review	Rectum	none	CT-MR	Supine	yes
RTOG-USA 2009	Delineation comnparison Consensus	Ano-Rectum	cT3N2	CT	Prone	CTV
AGITG-Australia 2012	Consensus	Anus	cT2N0 anus	CT	Supine	yes GTV OAR
DUTCH 2012	Delineation comparison Consensus	Rectum	Early stage	CT-MR	Supine	yes

Guidelines comparison

GL	METHOD	TUMOR SITE	T-stage	IMAGING	POSITION	SUBSITES
UCSC Italy 2004-2012	Experts review	Rectum	none	CT-visible human	Prone	yes
BELGIUM 2006-2015	Site of recurrence Expert review	Rectum	none	CT-MR	Supine	yes
RTOG-USA 2009	Delineation comnparison Consensus	Ano-Rectum	cT3N2	CT	Prone	CTV
AGITG-Australia 2012	Consensus	Anus	cT2N0 anus	CT	Supine	yes GTV OAR
DUTCH 2012	Delineation comparison Consensus	Rectum	Early stage	CT-MR	Supine	yes

Guidelines comparison

GL	METHOD	TUMOR SITE	T-stage	IMAGING	POSITION	SUBSITES
UCSC Italy 2004-2012	Experts review	Rectum	none	CT-visible human	Prone	yes
BELGIUM 2006-2015	Site of recurrence Expert review	Rectum	none	CT-MR	Supine	yes
RTOG-USA 2009	Delineation comnparison Consensus	Ano-Rectum	cT3N2	CT	Prone	CTV
AGITG-Australia 2012	Consensus	Anus	cT2N0 anus	CT	Supine	yes GTV OAR
DUTCH 2012	Delineation comparison Consensus	Rectum	Early stage	CT-MR	Supine	yes

Guidelines comparison

GL	METHOD	TUMOR SITE	T-stage	IMAGING	POSITION	SUBSITES
UCSC Italy 2004-2012	Experts review	Rectum	none	CT-visible human	Prone	yes
BELGIUM 2006-2015	Site of recurrence Expert review	Rectum	none	CT-MR	Supine	yes
RTOG-USA 2009	Delineation comnparison Consensus	Ano-Rectum	cT3N2	CT	Prone	CTV
AGITG-Australia 2012	Consensus	Anus	cT2N0 anus	CT	Supine	yes GTV OAR
DUTCH 2012	Delineation comparison Consensus	Rectum	Early stage	CT-MR	Supine	yes

Guidelines comparison

GL	METHOD	TUMOR SITE	T-stage	IMAGING	POSITION	SUBSITES
UCSC Italy 2004-2012	Experts review	Rectum	none	CT-visible human	Prone	yes
BELGIUM 2006-2015	Site of recurrence Expert review	Rectum	none	CT-MR	Supine	yes
RTOG-USA 2009	Delineation comnparison Consensus	Ano-Rectum	cT3N2	CT	Prone	CTV
AGITG-Australia 2012	Consensus	Anus	cT2N0 anus	CT	Supine	yes GTV OAR
DUTCH 2012	Delineation comparison Consensus	Rectum	Early stage	CT-MR	Supine	yes

Guidelines comparison

GL	Subsites							
	Mesorectum	Presacral space	SC and IRF	Lateral nodes	Intiernal iliac nodes	Obturator nodes	External iliac nodes	Inguinal nodes
UCSC Italy	+	+	+	Internal-obturator-external nodes	+	+	+	-
BELGIUM	+	+	+	+	Lateral nodes	Lateral nodes	-	-
RTOG-USA	CTVA	CTVA	CTVA	CTVA CTVB	CTVA	CTVA	CTVB	CTVC
AGITG-Australia	+	+	+	Internal-obturator-external nodes	+	+	+	+
DUTCH 2012	+	+	Mesorectum	Internal-obturator nodes	+	+	+	-

Guidelines differences

GL	Subsites							
	Mesorectum	Presacral space	SC and IRF	Lateral nodes	Intiernal iliac nodes	Obturator nodes	External iliac nodes	Inguinal nodes
UCSC Italy	+	+	+	Internal-obturator-external nodes	+	+	+	-
BELGIUM	+	+	+	+	Lateral nodes	Lateral nodes	-	-
RTOG-USA	CTVA	CTVA	CTVA	CTVA CTVB	CTVA	CTVA	CTVB	CTVC
AGITG-Australia	+	+	+	Internal-obturator-external nodes	+	+	+	+
DUTCH 2012	+	+	Mesorectum	Internal-obturator nodes	+	+	+	-

Guidelines comparison

GL	Subsites							
	Mesorectum	Presacral space	SC and IRF	Lateral nodes	Intiernal iliac nodes	Obturator nodes	External iliac nodes	Inguinal nodes
UCSC Italy	+	+	+	Internal-obturator-external nodes	+	+	+	-
BELGIUM	+	+	+	+	Lateral nodes	Lateral nodes	-	-
RTOG-USA	CTVA	CTVA	CTVA	CTVA CTVB	CTVA	CTVA	CTVB	CTVC
AGITG-Australia	+	+	+	Internal-obturator-external nodes	+	+	+	+
DUTCH 2012	+	+	Mesorectum	Internal-obturator nodes	+	+	+	-

Guideline comparison on clinical cases

Rectal Cancer cases	Slices to be delineated
cT4 (anterior pelvic organ)	60- 84 -90 -101- 114- 116
cT3 (MRF+)	79- 82- 93- 100- 112- 120
cT3 low-rectum (MRF-)	51- 58- 70- 79- 91- 99
cT4 (anal sphincter)	16- 19- 25- 29- 34- 42- 45
Extra mesorectal node	16- 17- 24- 27- 32- 41
cT3 mid-rectum (MRF-)	58- 70- 78- 86- 91- 96- 102
cT4 infiltration of ext anal sphincter	all

Guidelines comparison

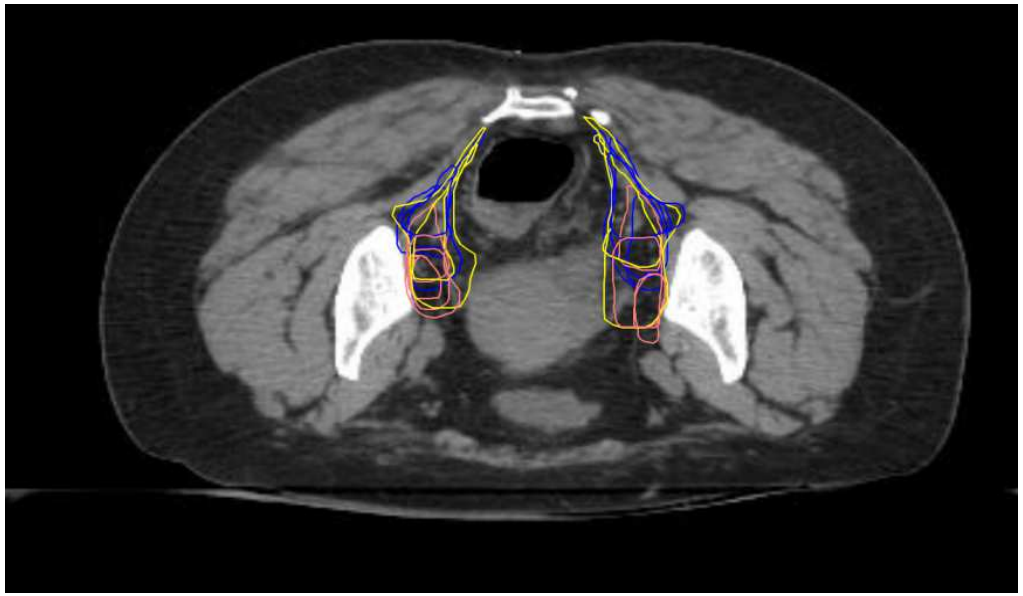

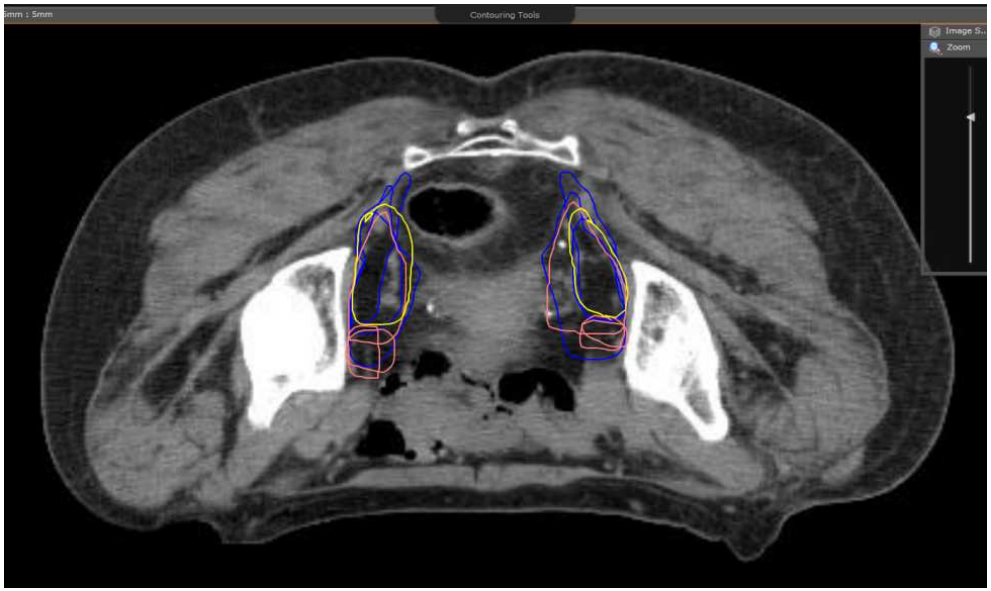

Published Guidelines
Leading Experts in RC

An **Inter-Society** Consensus in rectal cancer delineation

Review risk for each subsite

Review subsite anatomy with surgeons

Review vascular tree by imaging

Review delineation exercise

Review risk for each subsite

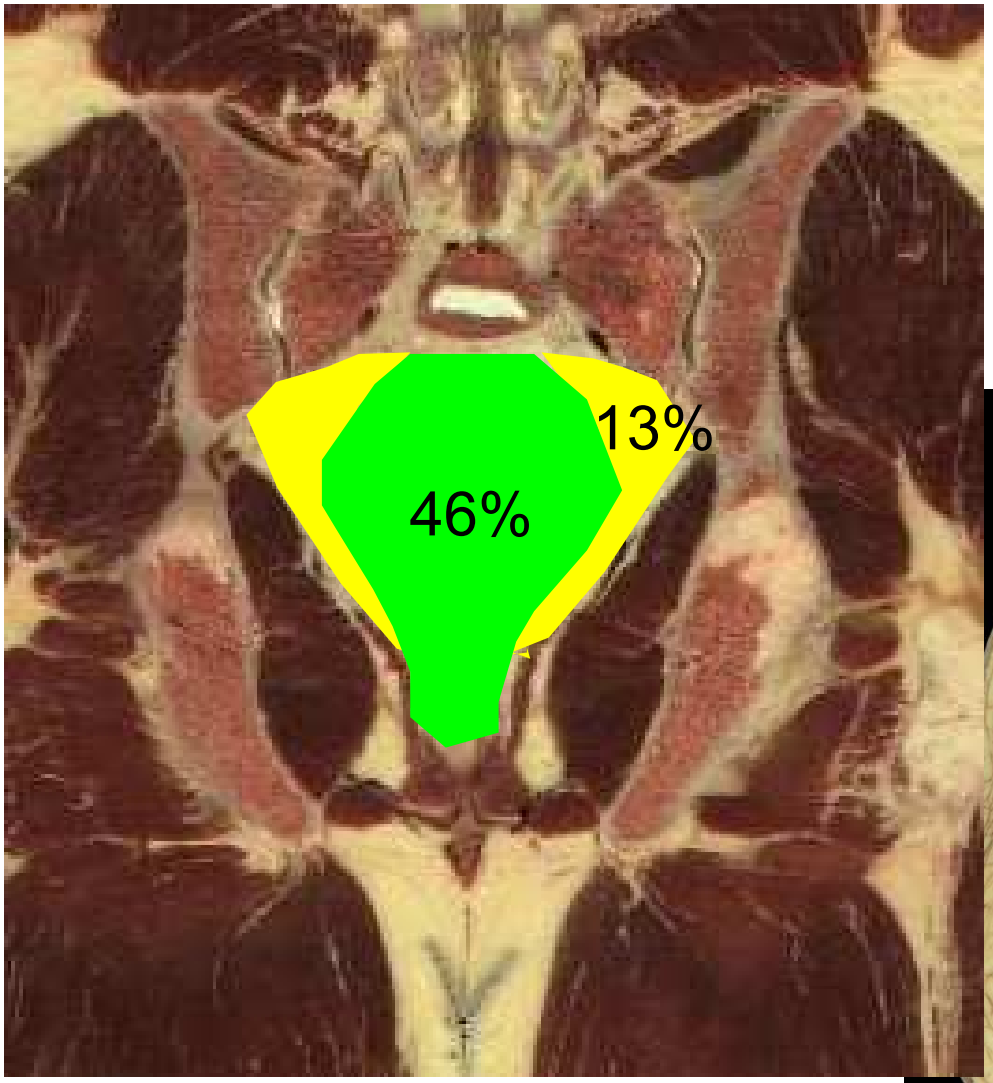

Mesorectal subsite: 46%

Posterior pelvic subsite: 22%

Lateral pelvic subsite: 13%

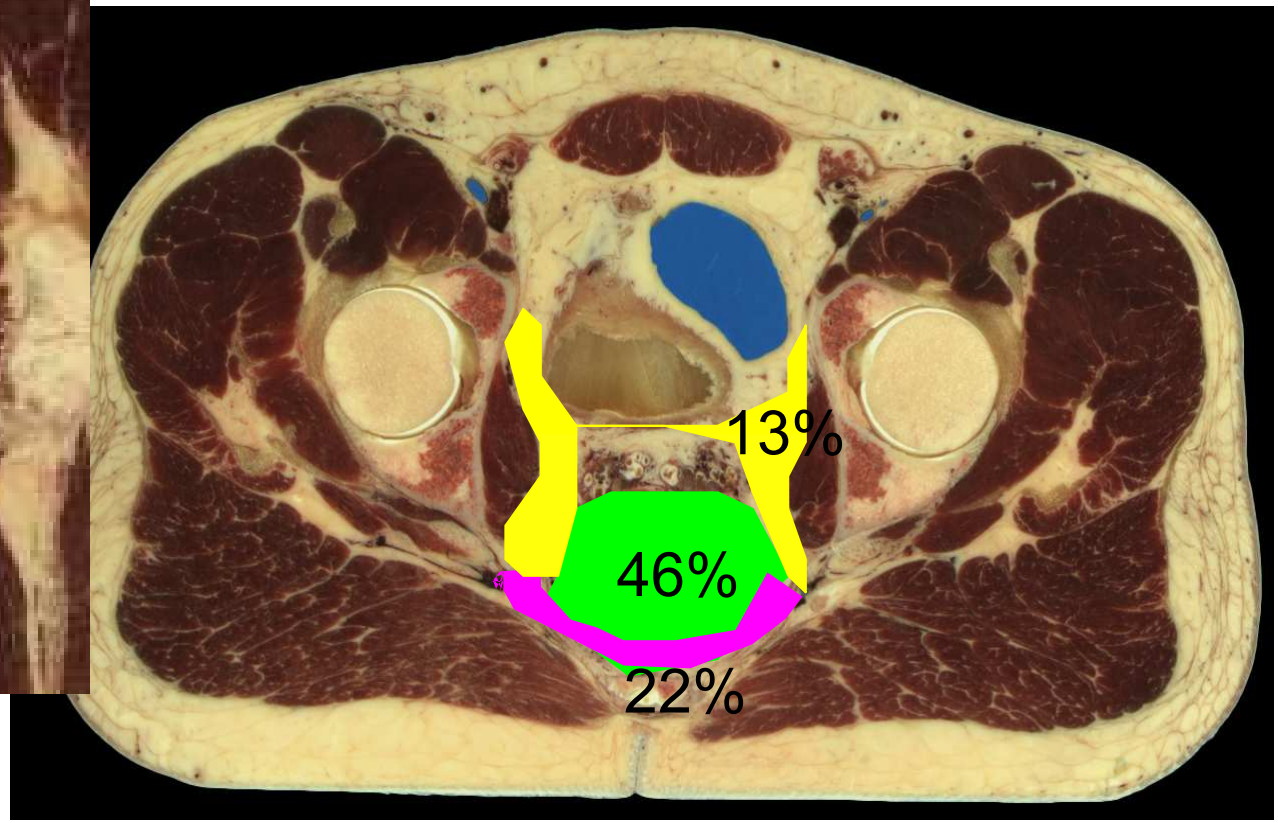

Roels S et Al - IJROBP - 2006

Review risk for each subsite

- **After TME** the risk for **local recurrence** has **dropped** for all pelvic subregions
- TME has not changed the **patterns of local recurrences**

	risk	involvement
PPS	3%	34%
LPS	2%	24%
Anastomotic region	2%	25%
APS	1%	17%
IPS	1%	10%

Joye I et Al - IJROBP - 2015

Review risk for each subsite

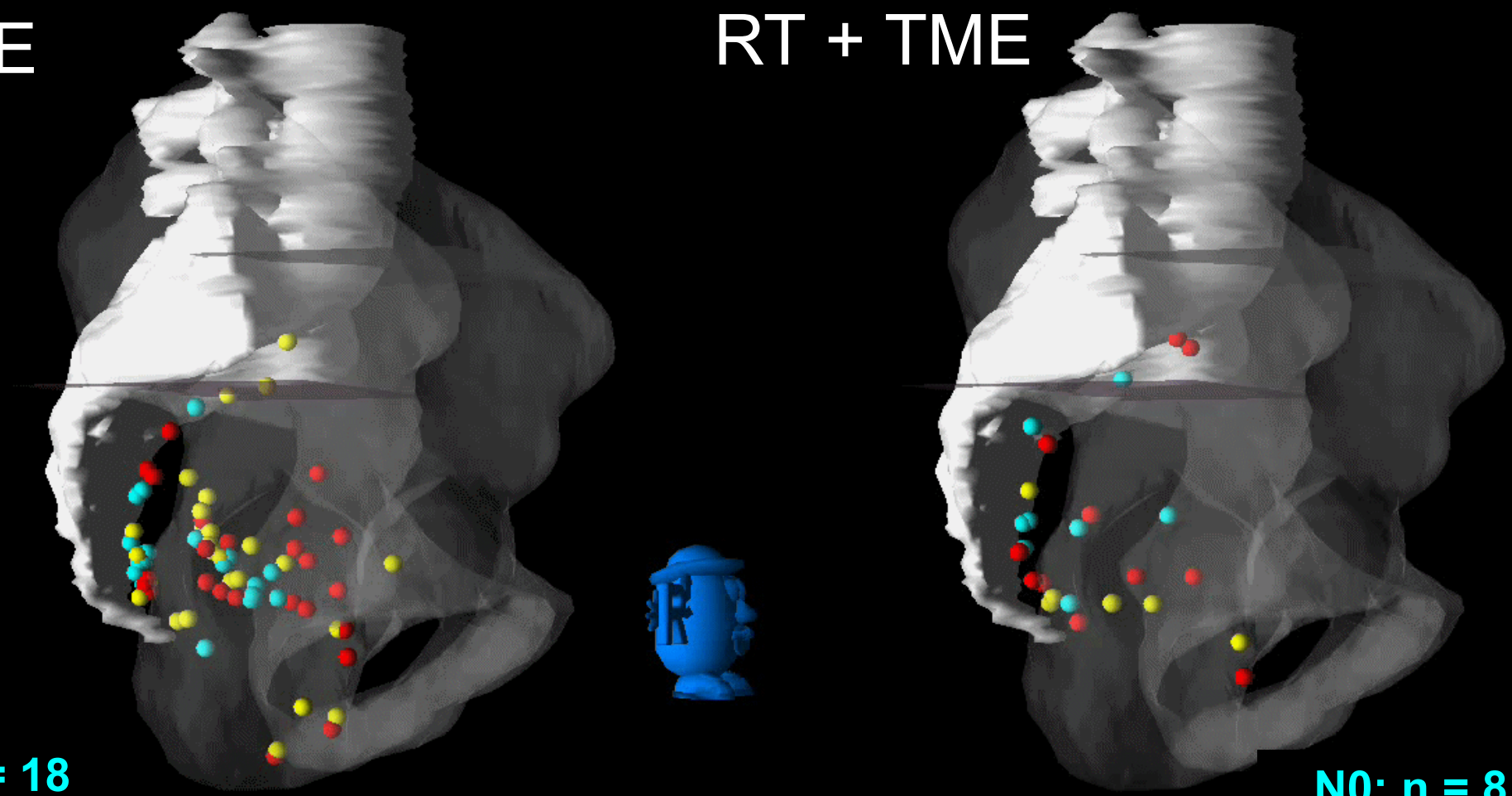

N0: n = 18

N1: n = 27

N2: n = 24

Nijkamp J et Al - IJROBP - 2011
by the courtesy of C.Marijnen

N0: n = 8

N1: n = 6

N2: n = 11

Review risk for each subsite

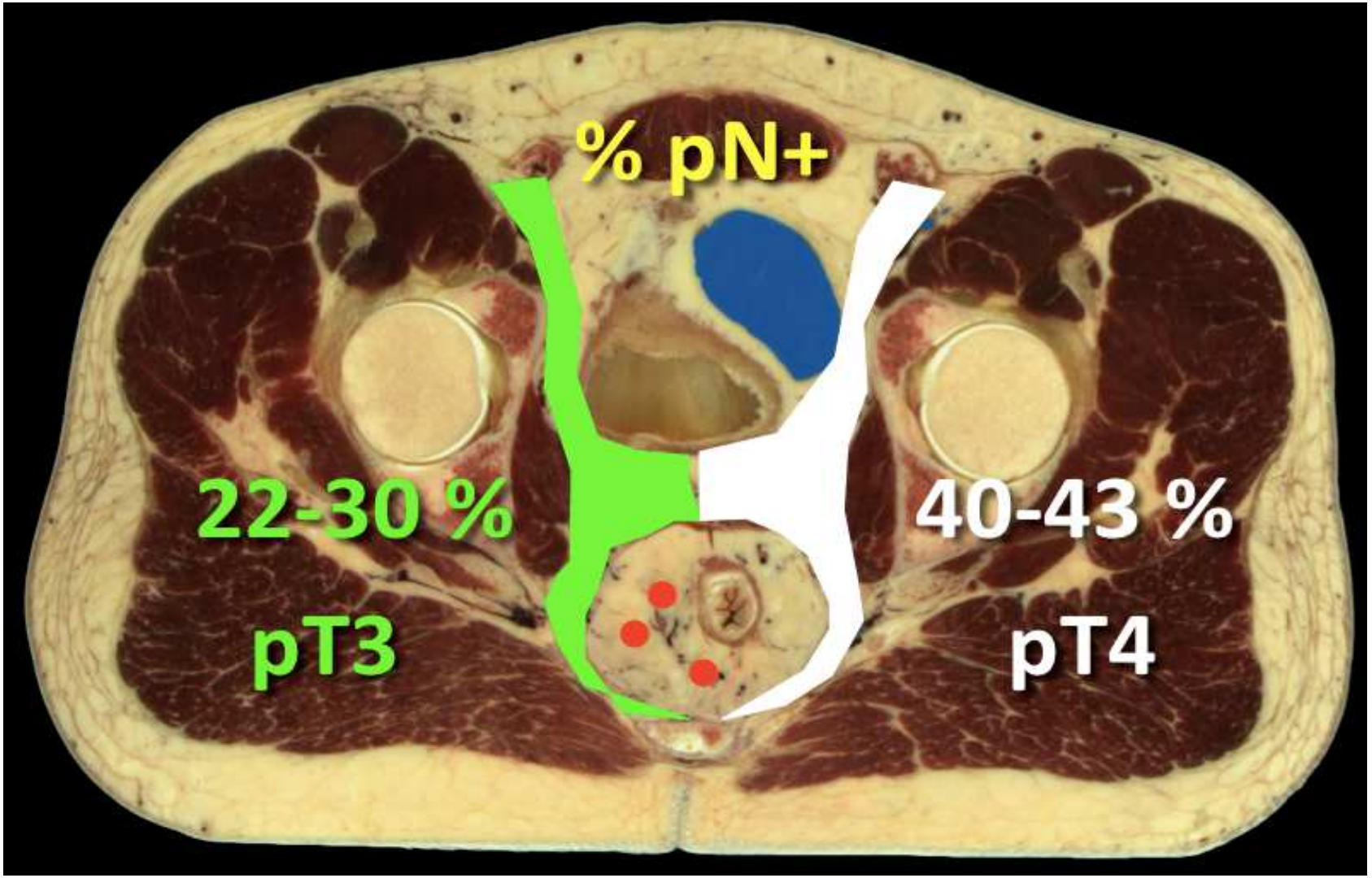

Moriya Y et Al - World J Surg - 1997
Hida J et Al -J Am Coll Surg - 1997

CTV: what to include

1. GTV

2. MESORECTM and PRESACRAL SPACE

3. LATERAL NODES

4. Sphincter Complex & Inguinal Nodes

An **Inter-Society** Consensus in rectal cancer delineation

7 subsites were identified:

1. presacral space (PS)
2. mesorectum (M)
3. lateral lymph nodes (LLN)
4. external iliac nodes (EIN)
5. inguinal nodes (IN),
6. ischiorectal fossa (IRF)
7. sphincter complex (SC)

Guidelines: the Presacral Space

subsite **limits** **image** **recommendations**

Sub-sites		Limits	Image	Recommendations
Presacral space	Abdominal	**Cranial:** bifurcation of the aorta in common iliac arteries or 5 mm above the most cranial positive lymph-node		Include it in case of **positive abdominal PN.**
		Caudal: sacral promontory		
		Anterior: 1 cm ventral to the lumbar vertebrae		
		Posterior: anterior wall of the lumbar vertebrae		
		Medial: --		
		Lateral: lateral surface of the common iliac vessels		
	Pelvic	**Cranial:** bifurcation of the common iliac arteries into the external and internal iliac artery/sacral promontory	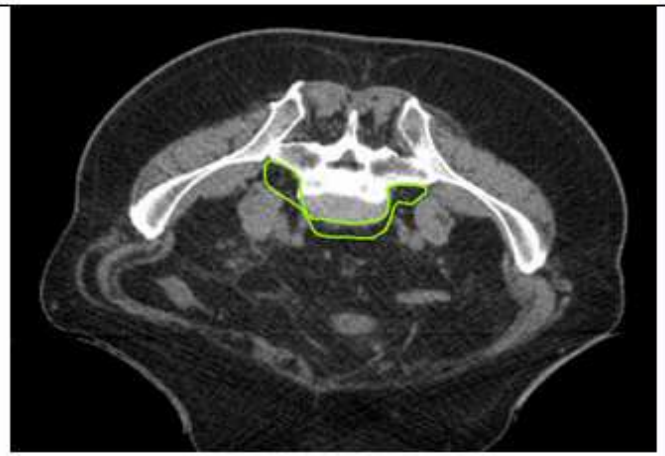	1. This is a virtual space that in the **current GL** is **included** in the delineation of **Mesorectum** and **Lateral Lymph Nodes** subsites, when the presacral space is at the level of these 2 structures. In all other cases the presacral space must be contoured separately. 2. Neuroforamina should not be included, unless there is direct tumoral infiltration or close proximity of the tumor
		Caudal: caudal border of the Mesorectum		
		Anterior: 1 cm ventral to the lumbar vertebrae		
		Posterior: anterior wall of the lumbar vertebrae		
		Medial: --		
		Lateral: Sacroiliac joints		

Guidelines: the Mesorectum

subsite		limits	image	recommendations
Mesorectum		**Cranial:** bifurcation of the inferior mesenteric artery (IMA) in sigmoid artery (SA) and superior rectal artery (SRA)	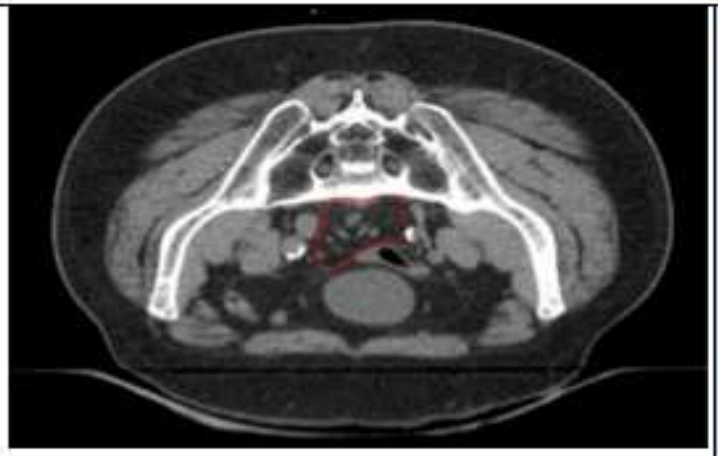	Consider anisotropic CTV-PTV margins anteriorly to account for bladder/uterus movement
		Caudal: insertion of the levator ani muscle into the external sphincter muscles (disappearing of the mesorectal fat around the rectum)	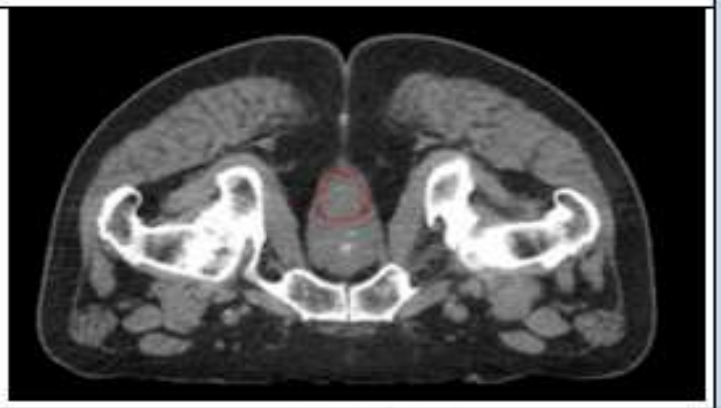	
		Anterior **Superior:** 7 mm beyond SRA excluding bowel structures **Mid/inferior:** mesorectal fascia, posterior border of the anterior pelvic organs	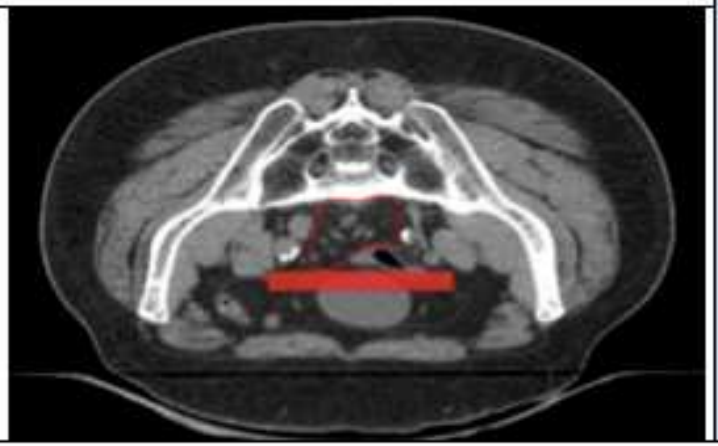	
		Posterior: Anterior surface of the sacrum and coccyx to the level		

Limits modulation: Superior

pT3N1 and/or CRM

pT3N0, CRM-

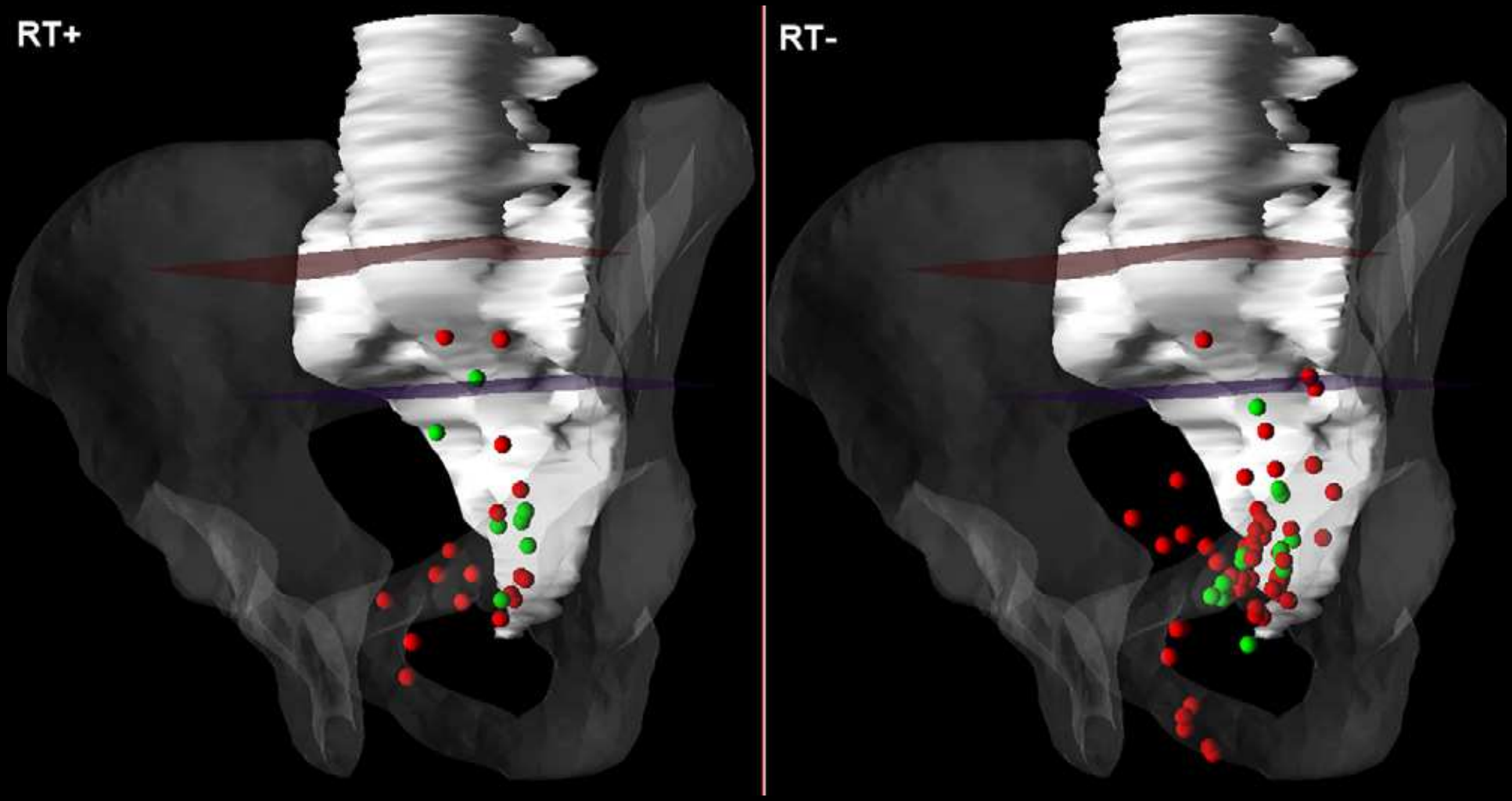

Nijkamp J et Al - IJROBP - 2011
by the courtesy of C.Marijnen

CTV modulation: Superior Limit

cT3N0, MRF-: superior limit of the CTV at the starting of the mesorectum

More advanced cases: superior limit at the bifurcation of Common Iliac Vessels

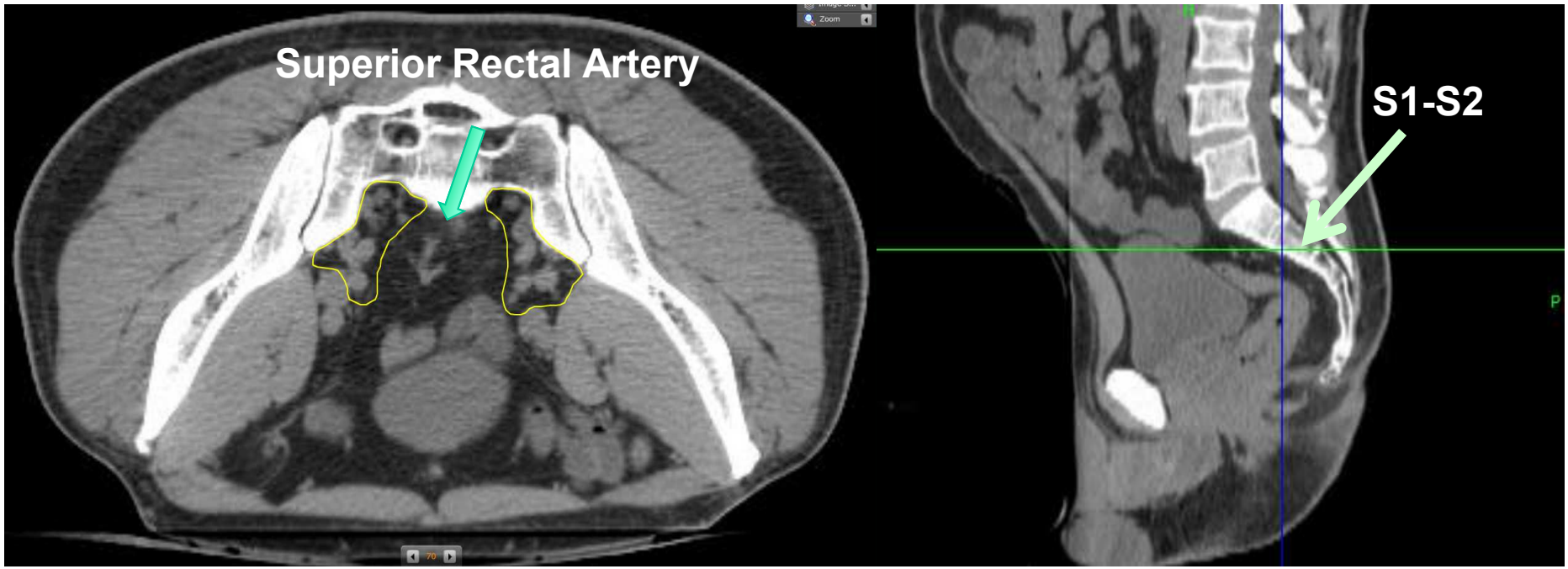

Anatomy review

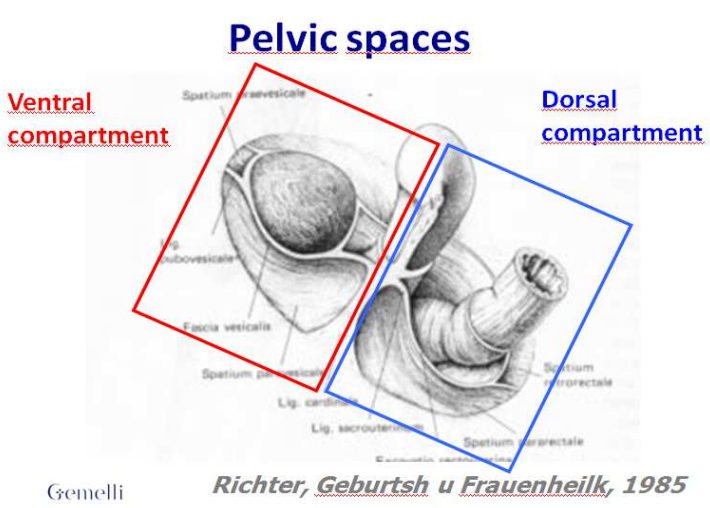

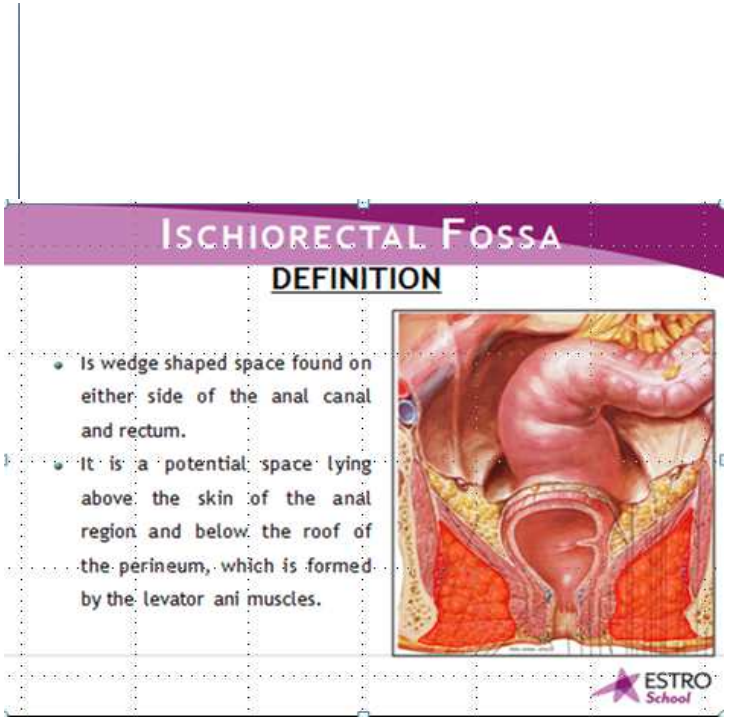

Consultants:

Radiologist

GI surgeon

GYN surgeon

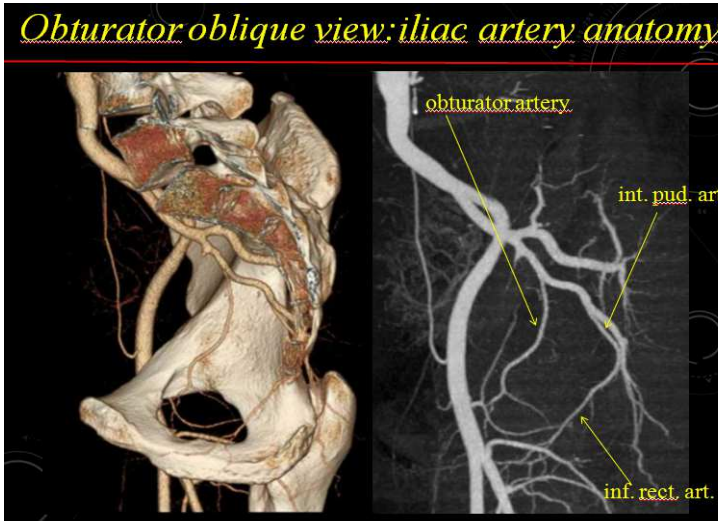

Review subsite anatomy with surgeons

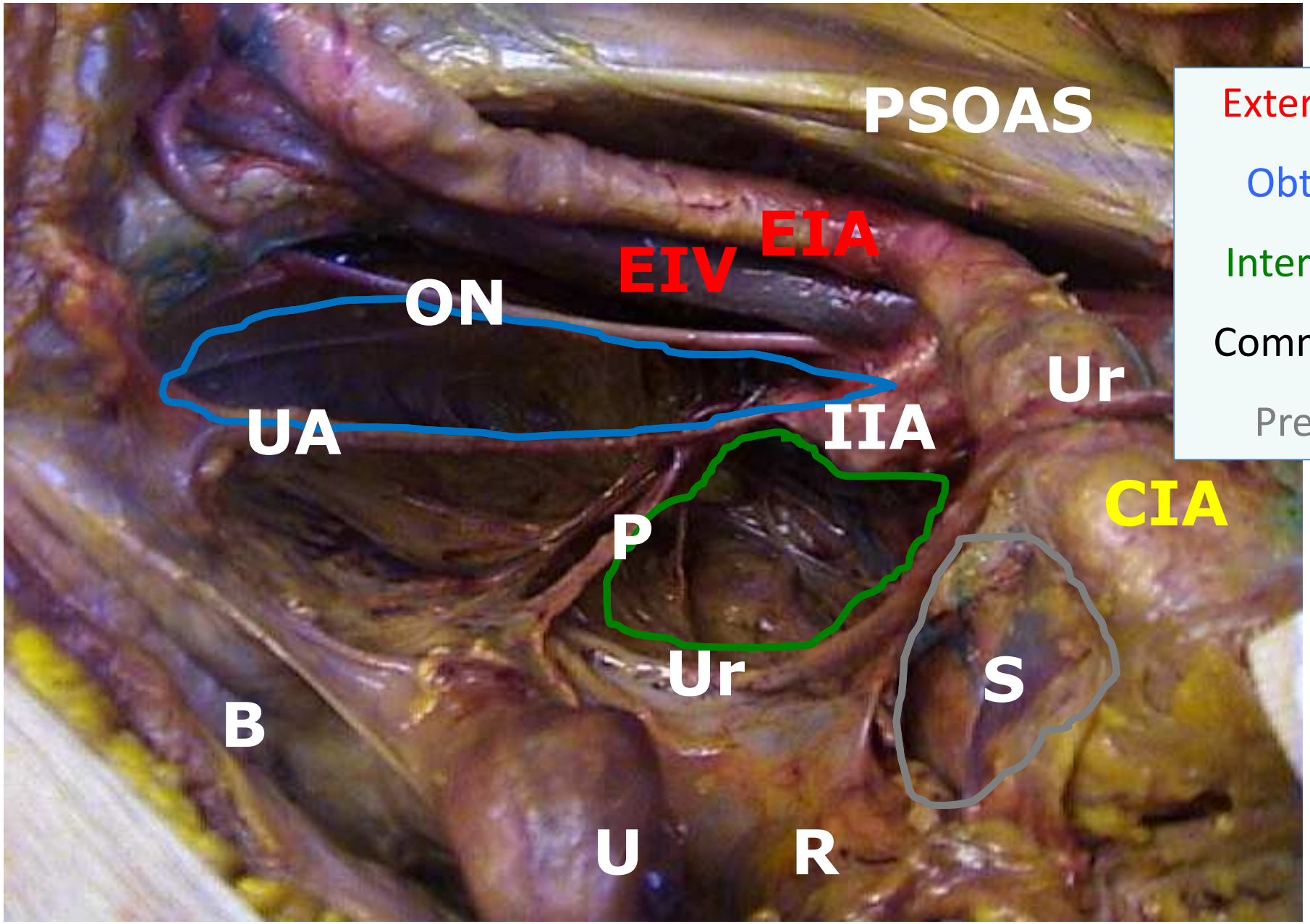

External iliac region

Obturator region

Internal iliac region

Common iliac region

Presacral region

Cibula-Abu Rustum, Gynecol Oncol 2010

Guidelines: Lateral Lymph Nodes→ posterior

subsite		limits	image	recommendations
Lateral lymph nodes	Posterior (ex internal iliac nodes)	**Cranial:** Bifurcation of common iliac artery into internal and external iliac arteries	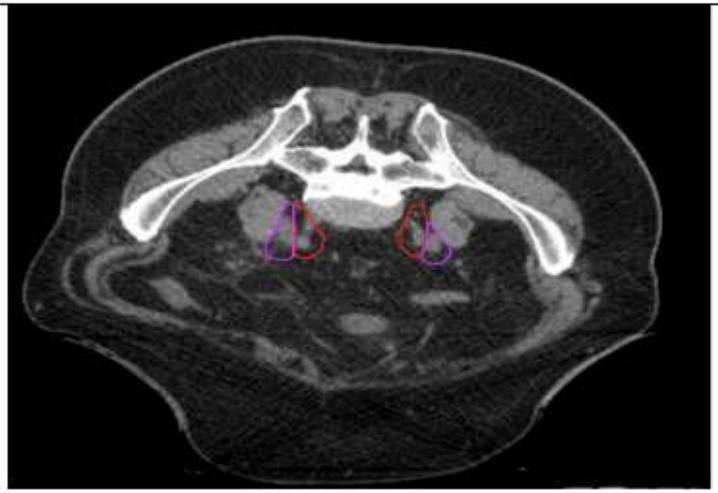	**Cranial limit:** 1) In cT3N0, MRF-, the cranial limit may be lowered at the level of the bifurcation of the inferior mesenteric artery in sigmoid artery and superior rectal artery (corresponding to the cranial limit of the Mesorectum). 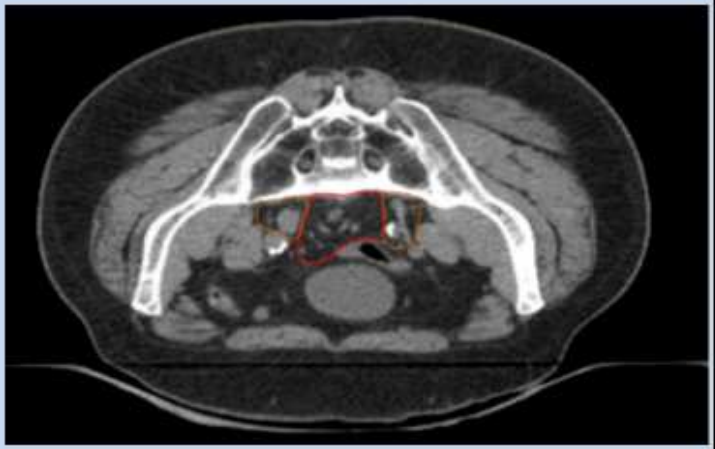 2) In all other cases (MRF+ or cT4 or N+) consider the anatomical limit of the bifurcation of the common iliac arteries in to internal iliac and external iliac arteries (corresponding to the cranial limit of the Lateral Lymph Nodes)
		Caudal: insertion of the levator ani muscle into the external sphincter muscles (pelvic floor)	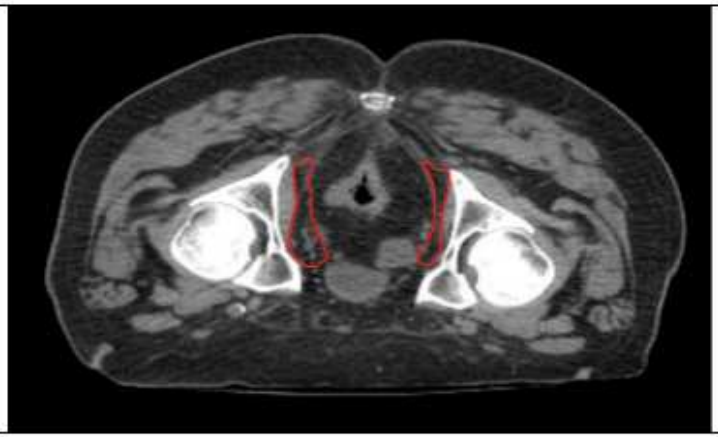	

Guidelines: Lateral Lymph Nodes→ Posterior

Anterior

Upper pelvis:
7 mm around the vessel.

Mid pelvis:
A virtual coronal plane crossing the anterior wall of the ureters when they join the bladder and the posterior aspect of the external iliac vessels cranially

Inferior pelvis:
Posterior limit of the obturator fossa

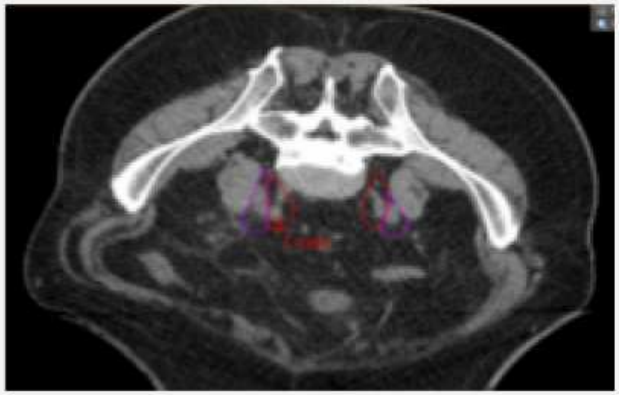

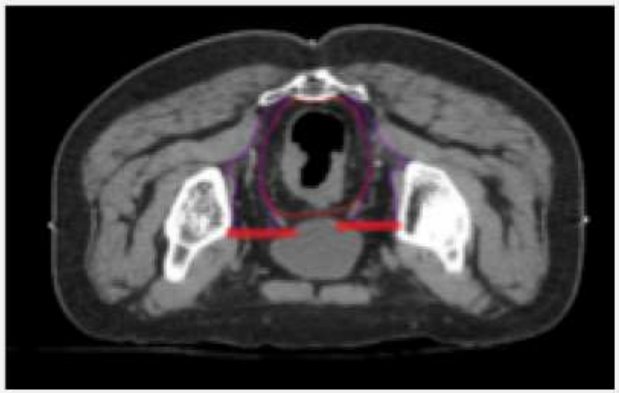

Posterior: Lateral edge of the sacro-iliac joint

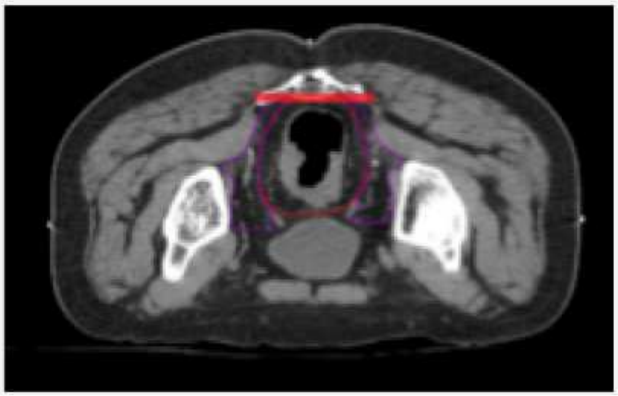

Guidelines: Lateral Lymph Nodes→ Anterior

Anterior Limit
Mid pelvic

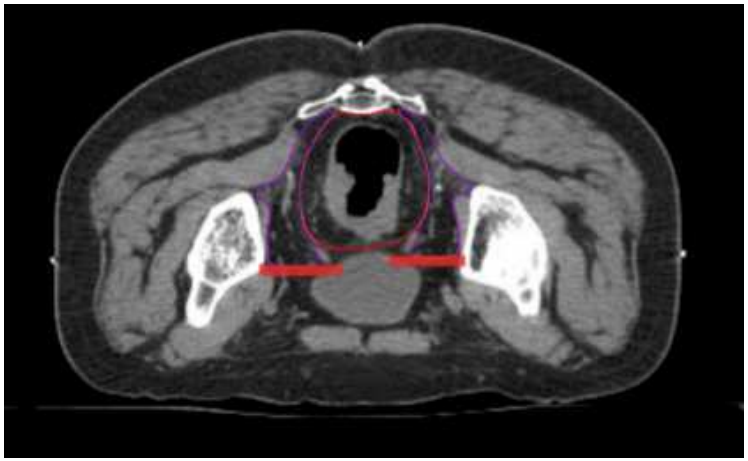

subsite	limits	image	recommendations
Anterior (ex obturator nodes)	**Anterior** **Mid pelvis:** Posterior wall of the external iliac vessels **Low pelvis** (when external iliac vessels leave the pelvis): Anterior surface of obturator artery	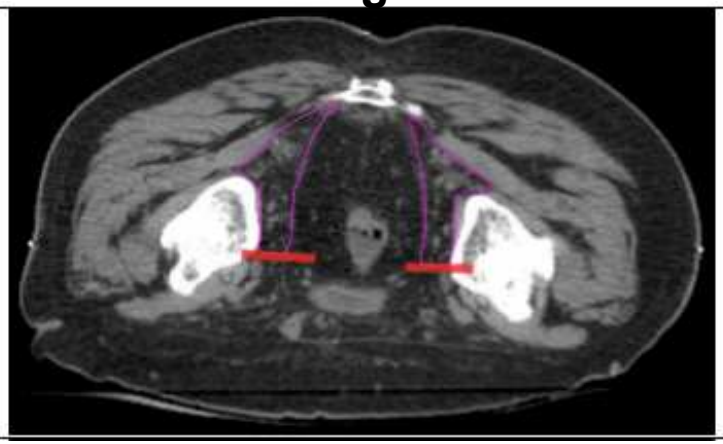	Include in case of: 1) positive nodes in the posterior lateral lymph nodes (internal iliac); 2) cT4; 3) numerous mesorectal nodes (cN2).

Review vascular tree by imaging

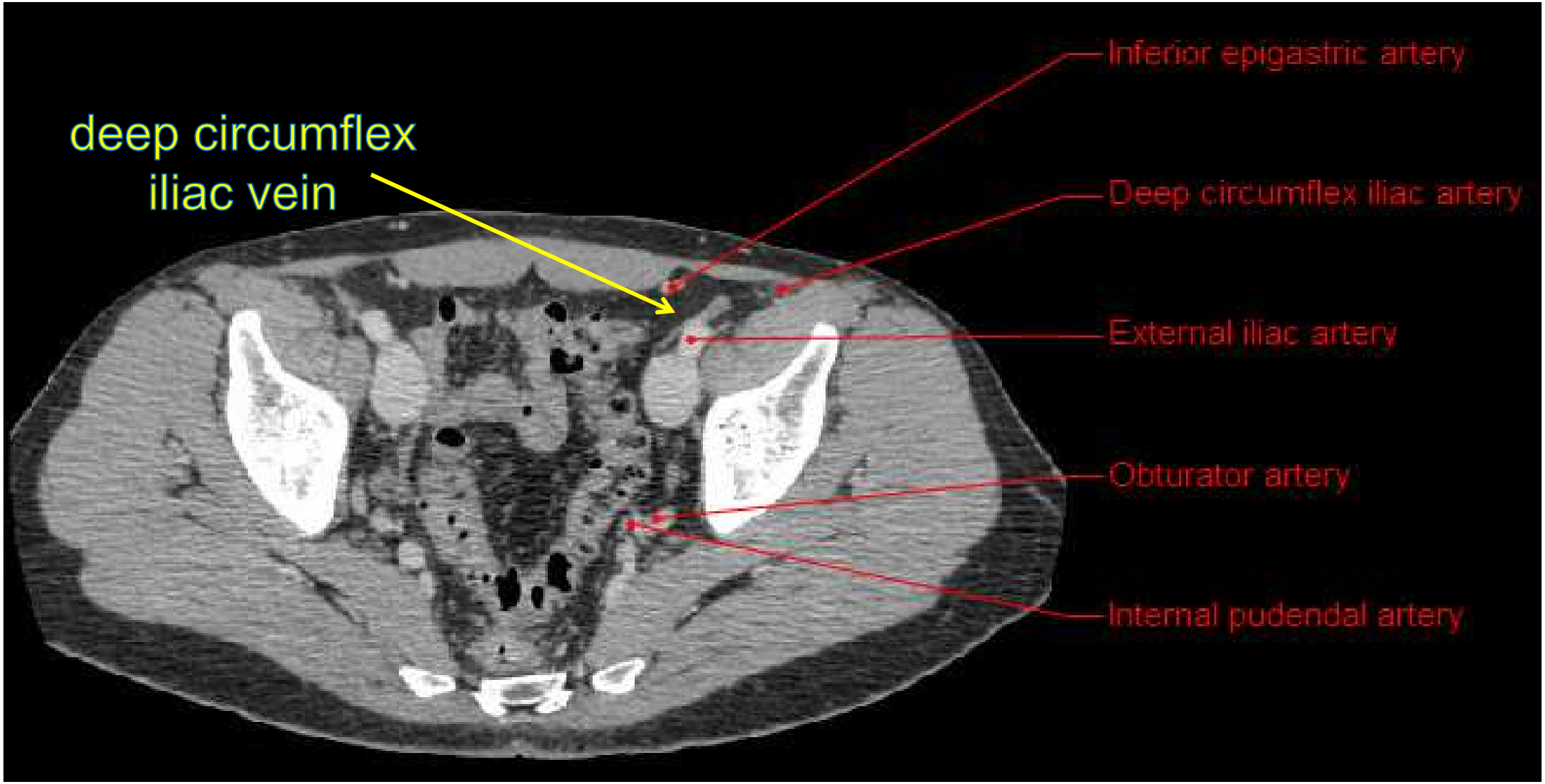

Guidelines: External Iliac Nodes

subsite	limits	image	recommendations
External iliac nodes	**Cranial:** Bifurcation of common iliac artery into internal and external iliac arteries	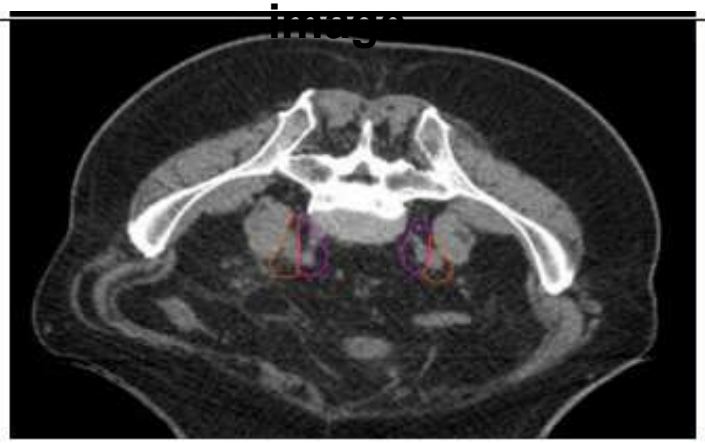	Include in case of: 1) cT4 tumors; 2) positive anterior lateral lymph nodes (ex obturator).
	Caudal: Where the deep circumflex vein crosses the external iliac artery. Alternatively (if difficult detection on CT images) between the acetabulum roof and the superior pubic rami	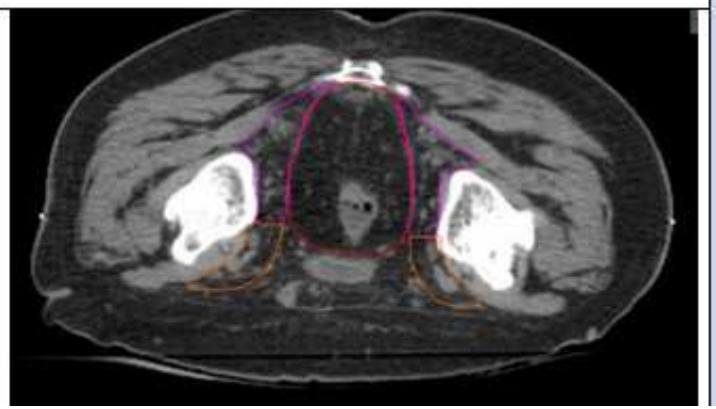	
	Anterior: 0.7 cm anterior to the vessels. 1.5 cm antero-laterally along the iliopsoas muscle to include the antero-lateral nodes		
	Posterior: posterior border of the external iliac vein		

CTV modulation: Anterior Limit

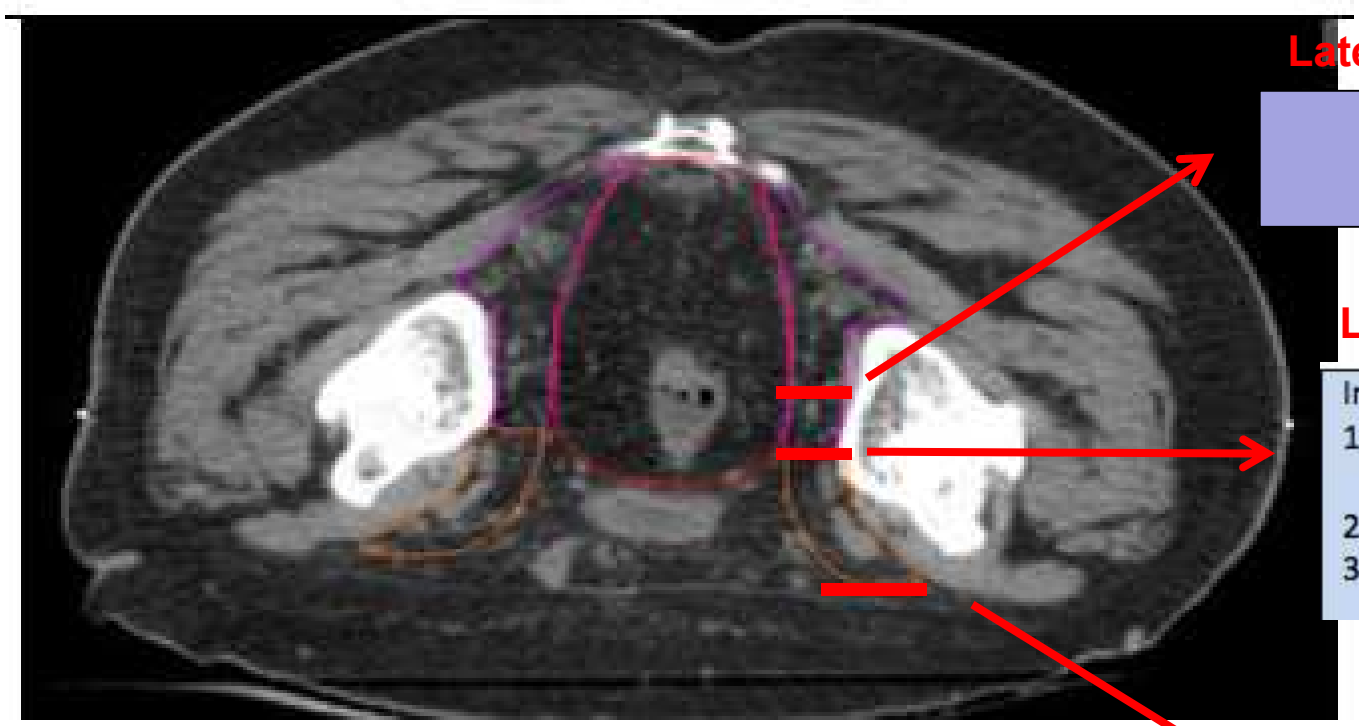

Lateral posterior

always

Lateral anterior

Include in case of:

1) positive nodes in the posterior lateral lymph nodes (internal iliac);
2) cT4;
3) numerous mesorectal nodes (cN2).

External Iliac

Include in case of:

1) cT4 tumors;
2) positive anterior lateral lymph nodes (ex obturator).

Review vascular tree by imaging

Iliac Fossa

↓

Ischio-Rectal Fossa

Posterior view

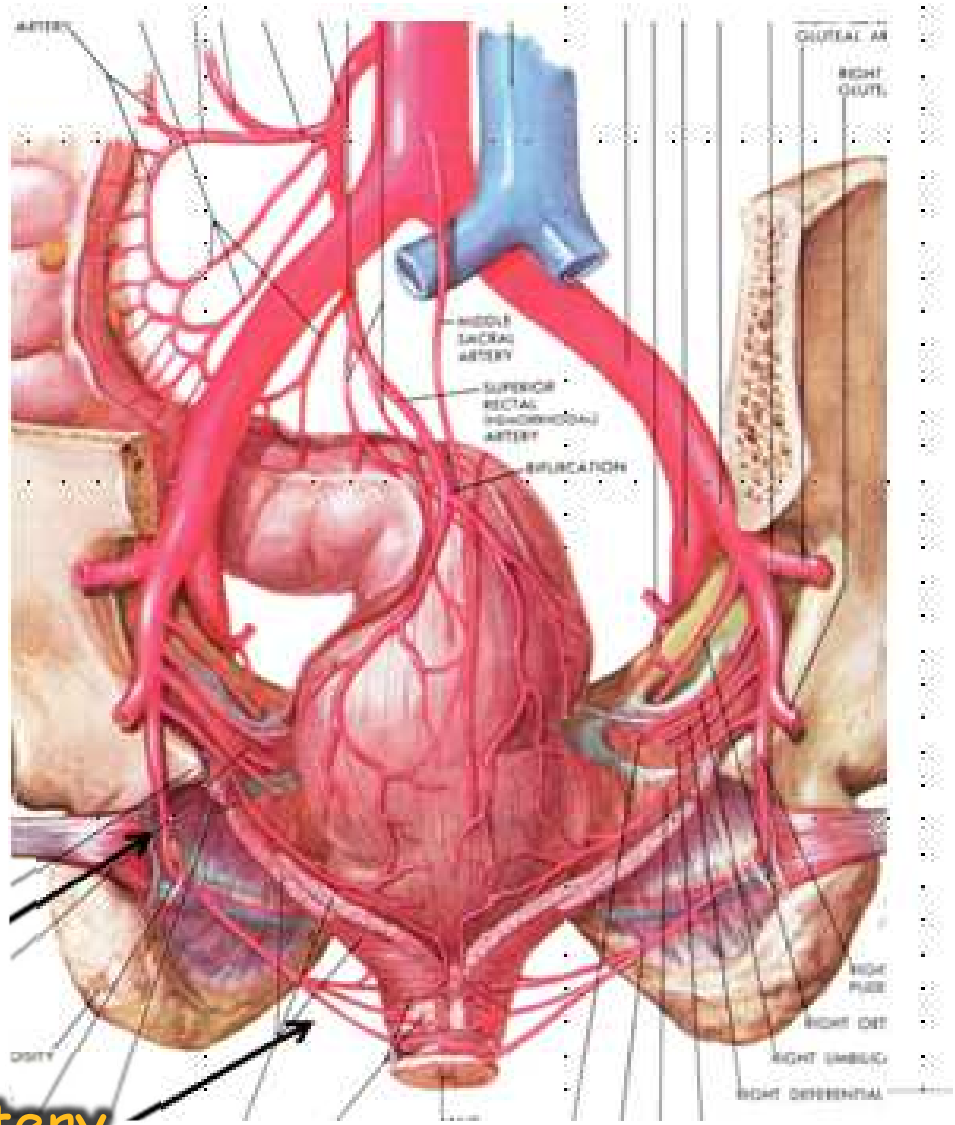

Pudendal artery

inferior rectal artery

Review vascular tree by imaging

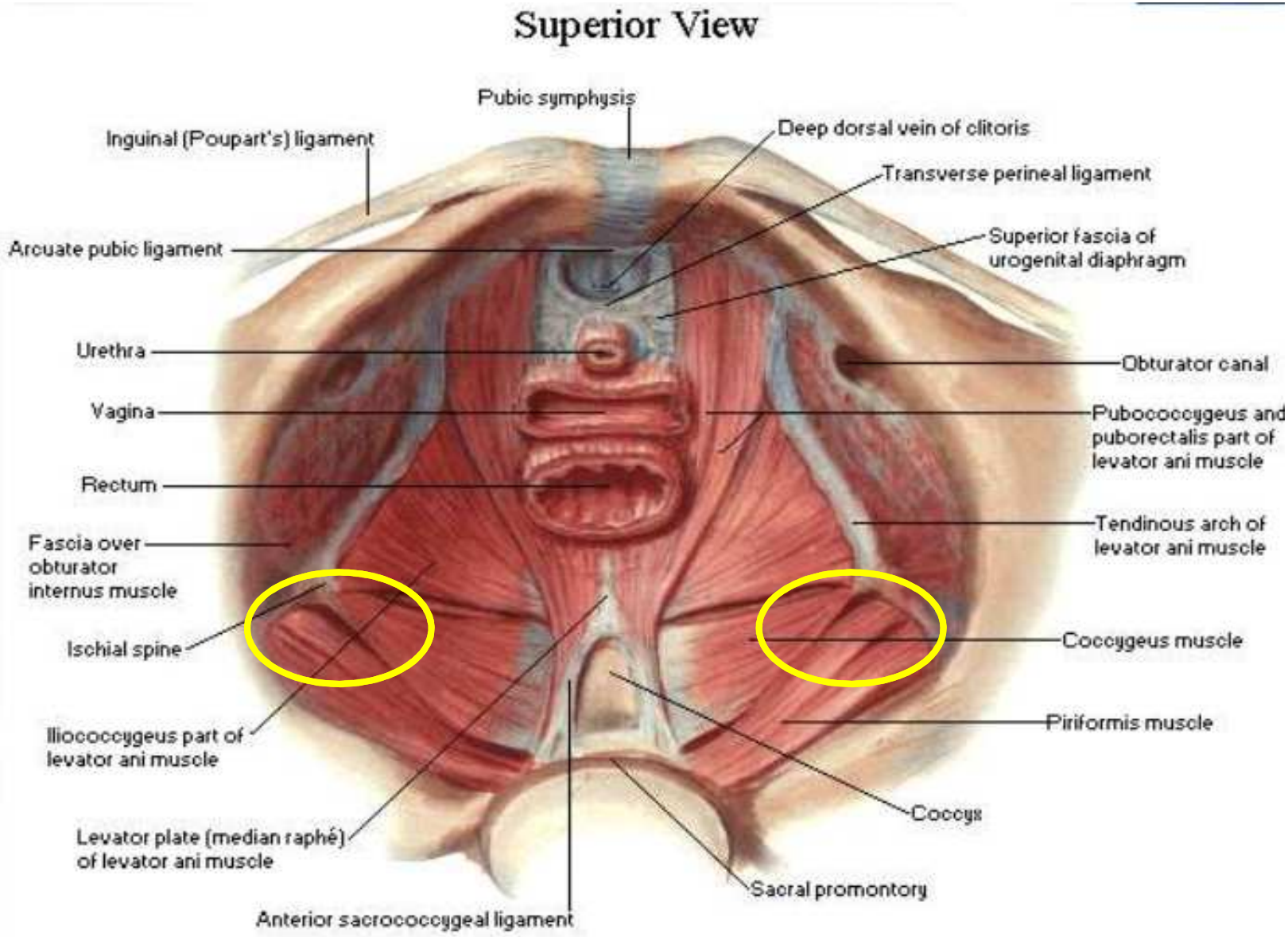

pudendal artery leaves the pelvis (ischial tuberosity, internal obturator mule, gluteus maximus muscle)

Review vascular tree by imaging

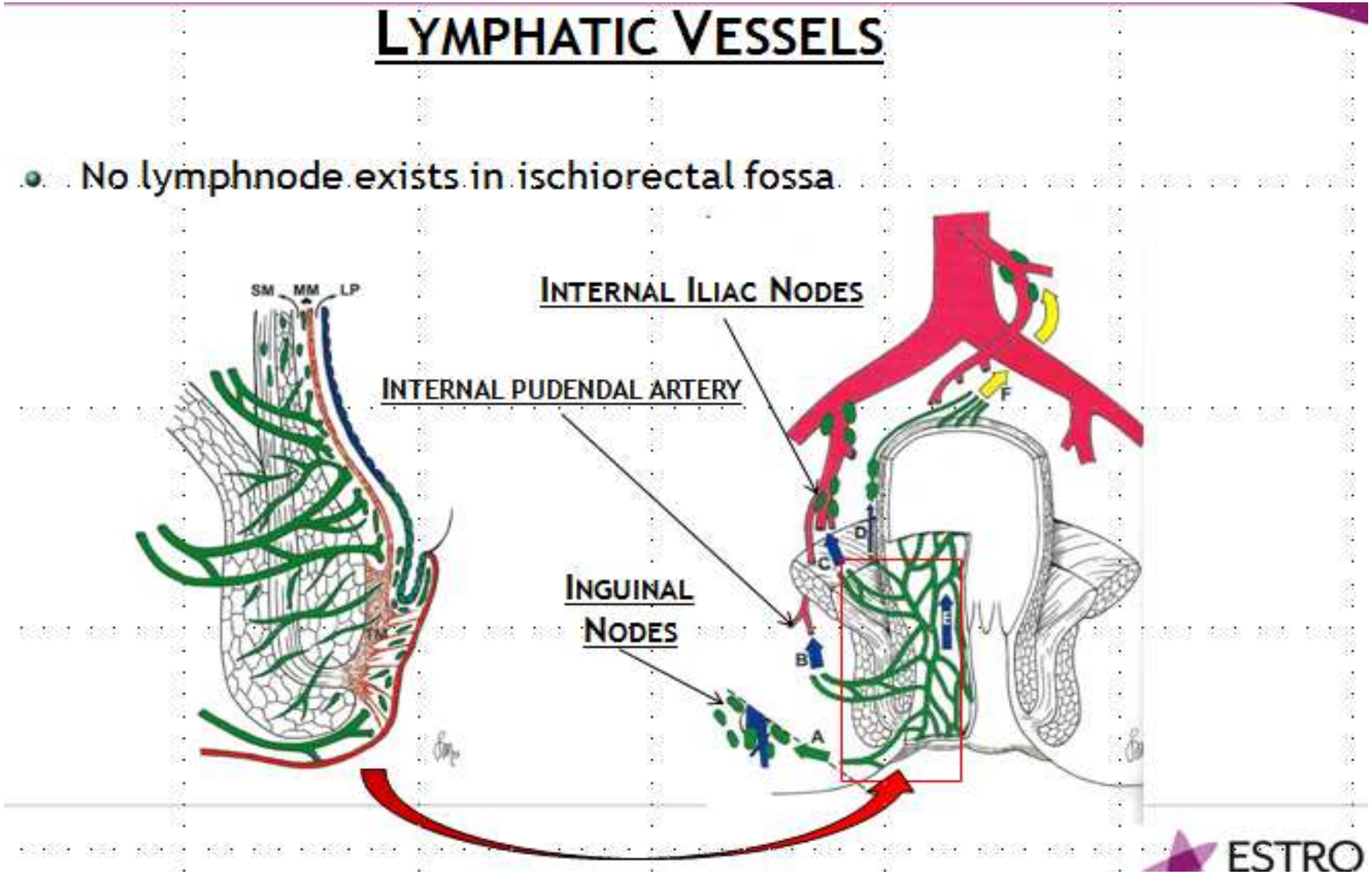

Review vascular tree by imaging

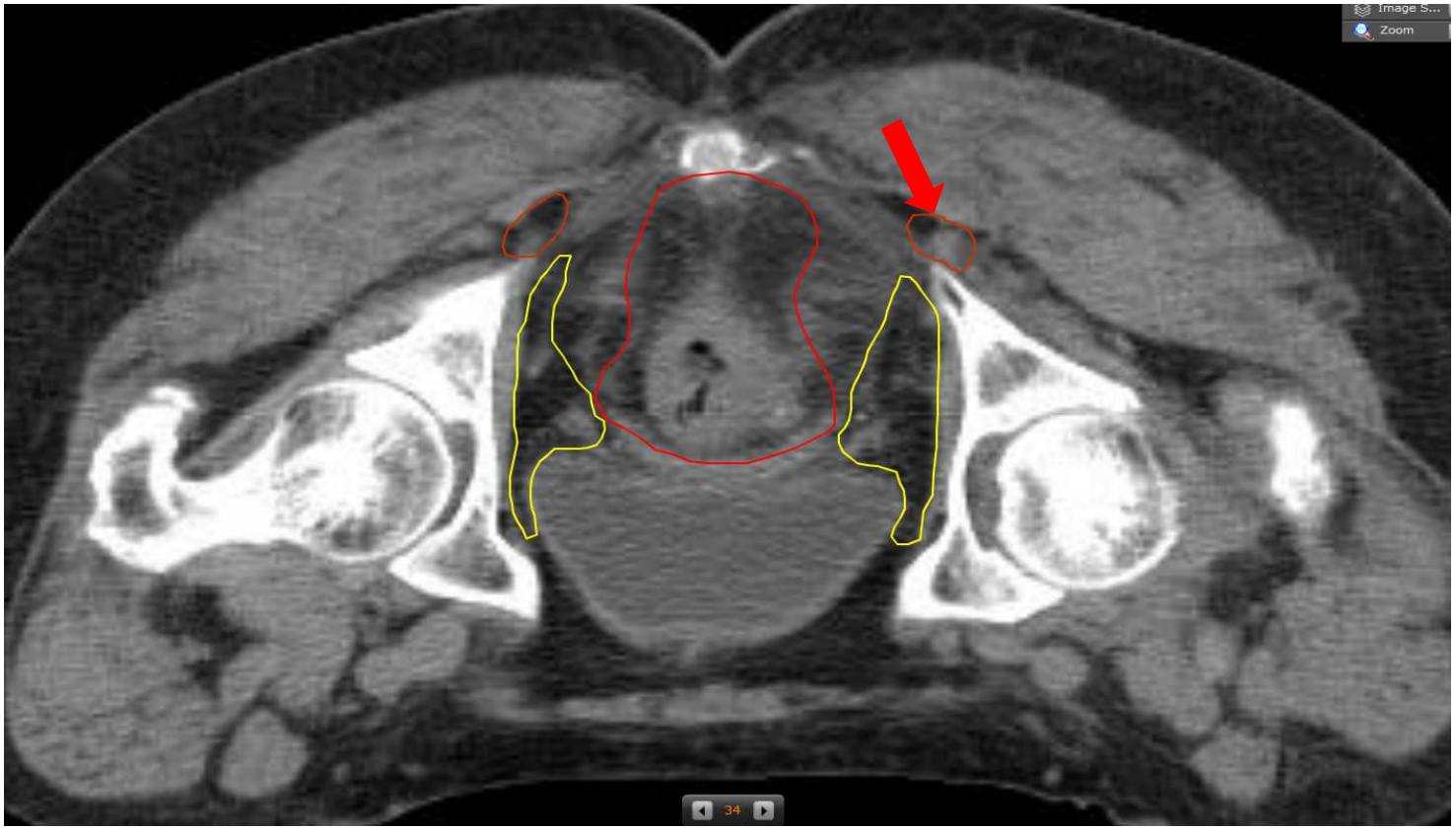

Cranial limit: Where the inferior pudendal artery leaves the pelvis (ischial tuberosity, internal obturator muscle, gluteus maximus muscle)

Guidelines: Ischio Rectal Fossa

subsite	limits	image	recommendations
	or iliopsoas muscles		
IRF	**Cranial:** Where the inferior pudendal artery leaves the pelvis (ischial tuberosity, internal obturator muscle, gluteus maximus muscle)	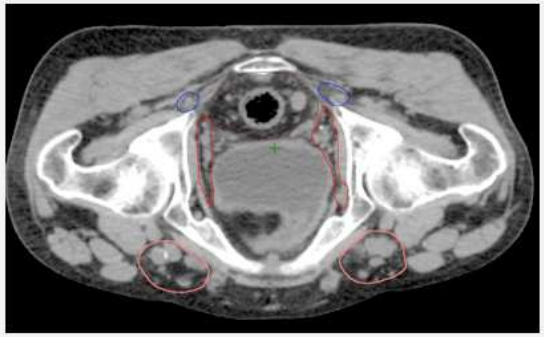	Include when there is infiltration of the external anal sphincter or the ischio-rectal fossa
	Caudal: oblique plane joining the inferior level of SC and the ischial tuberosity.	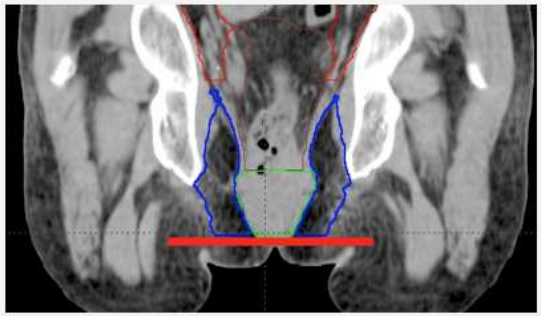	
	Anterior: Triangle between internal obturator muscle and levator ani muscle	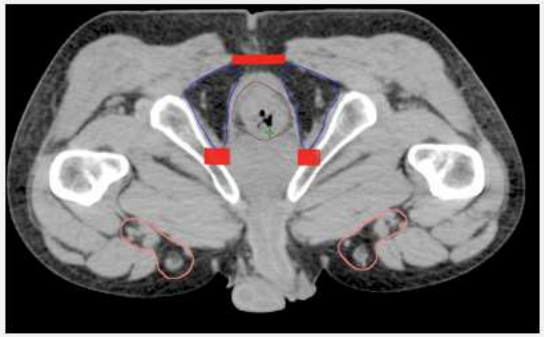	

Guidelines: Ischio Rectal Fossa

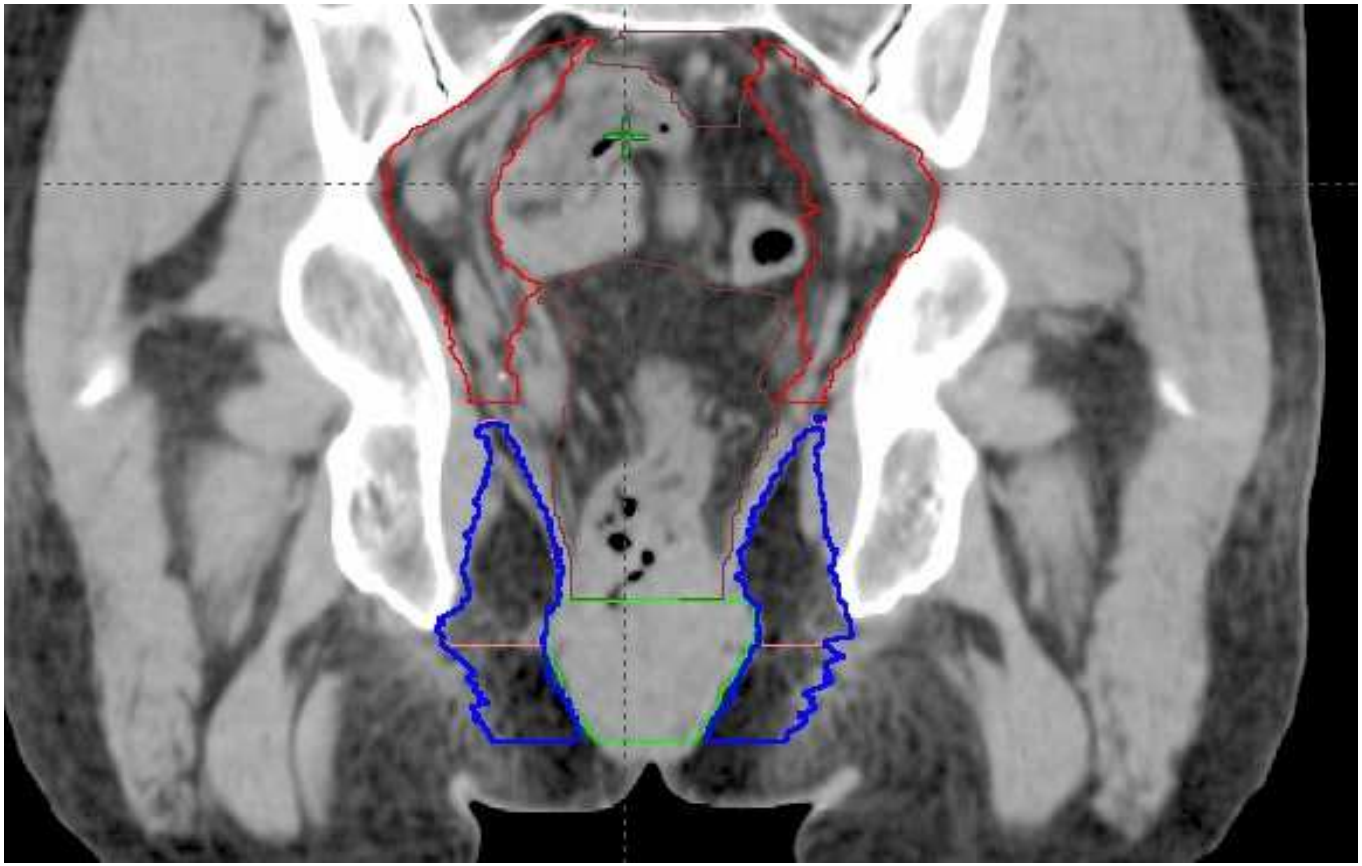

Guidelines: Sphincter Complex

subsite		limits	image	recommendations
Sphincter complex		From the anal-rectal junction. Around the sphincter	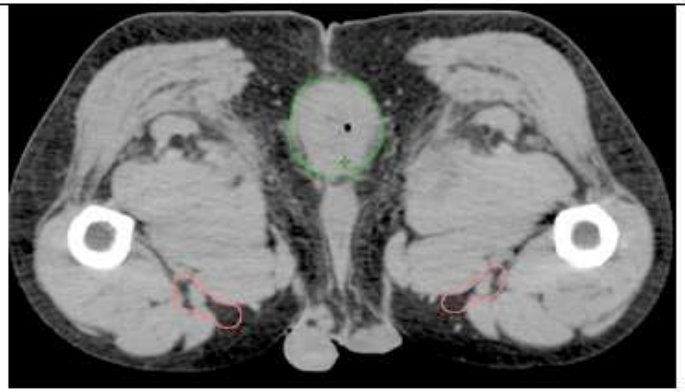	To include in case of sphincter infiltration

Guidelines: Inguinal nodes

subsite	limits	image	recommendations
Inguinal nodes	**Cranial:** Where the deep circumflex vein crosses the external iliac artery. Alternatively (if difficult detection on CT images) between the acetabulum roof and the superior pubic rami **Caudal:** Where the great saphenous vein enters the femoral vein **Anterior:** At least 20 mm margin around inguinal vessels including any visible lymph nodes or lymphocoeles **Posterior:** The femoral triangle formed by iliopsoas, pectineus and abductor longus muscles **Medial:** 10-20 mm margin around the femoral vessels including any visible lymph nodes or lymphocoeles **Lateral:** Medial edge of the sartorius or iliopsoas muscles	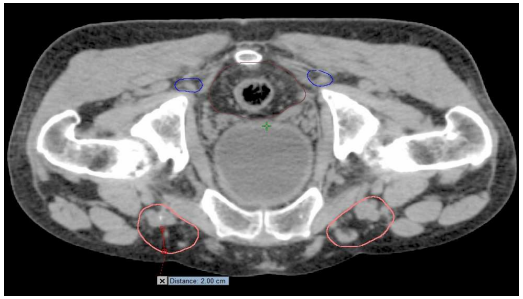 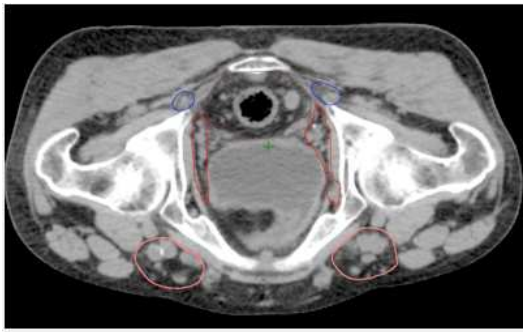	Include when there is infiltration of the external anal sphincter or the ischio-rectal fossa

Recommendations

PS abdominal nodes: This a new sub-volume. It should only be included when it harbors **positive nodes**

CTV cranial border: In case of **cT3, cN0 , MRF-**, the upper border of the LLN can be **lowered to the cranial border of the M**, corresponding with the bifurcation of the superior rectal artery

LLN modulation(posterior and anterior)

include the **anterior LLN in case of cT4, cN2**, positive node in the posterior LLN

Ischio-rectal fossa: include when **infiltrated** (no nodes, sphincter is a barrier)

when **external anal sphincter infiltration** (blood supply from inferior rectal artery)

Subsites inclusion recommendations

	Mesorectum	Presacral space		Lateral Lymph Nodes		External iliac nodes	Ischiorectal fossa	Inguinal nodes	Sphincter complex
		Pelvic	Abdominal	Post	Ant				
cT3	+	+	When abdominal PN+	+	+ in case of numerous mesorectum nodes (N2)				
Extra mesorectal node	+	+	When LN+	+	+	+			
cT4 (anterior pelvic organ)	+	+	When LN+	+	+	+		+ in case of infiltration of inferior third of vagina	
cT4 (anal sphincter)	+	+	When LN+	+	+	+	+ (when direct tumor infiltration of IRF or external anal sphincter)		+

Subsites inclusion recommendations

	Mesorectum	Presacral space		Lateral Lymph Nodes		External iliac nodes	Ischiorectal fossa	Inguinal nodes	Sphincter complex
		Pelvic	Abdominal	Post	Ant				
cT3	+	+	When abdominal PN+	+	+ in case of numerous mesorectum nodes (N2)				
Extra mesorectal node	+	+	When LN+	+	+	+			
cT4 (anterior pelvic organ)	+	+	When LN+	+	+	+		+ in case of infiltration of inferior third of vagina	
cT4 (anal sphincter)	+	+	When LN+	+	+	+	+ (when direct tumor infiltration of IRF or external anal sphincter)		+

Subsites inclusion recommendations

	Mesorectum	Presacral space		Lateral Lymph Nodes		External iliac nodes	Ischiorectal fossa	Inguinal nodes	Sphincter complex
		Pelvic	Abdominal	Post	Ant				
cT3	+	+	When abdominal PN+	+	+ in case of numerous mesorectum nodes (N2)				
Extra mesorectal node	+	+	When LN+	+	+	+			
cT4 (anterior pelvic organ)	+	+	When LN+	+	+	+		+ in case of infiltration of inferior third of vagina	
cT4 (anal sphincter)	+	+	When LN+	+	+	+	+ (when direct tumor infiltration of IRF or external anal sphincter)		+

Subsites inclusion recommendations

	Mesorectum	Presacral space		Lateral Lymph Nodes		External iliac nodes	Ischiorectal fossa	Inguinal nodes	Sphincter complex
		Pelvic	Abdominal	Post	Ant				
cT3	+	+	When abdominal PN+	+	+ in case of numerous mesorectum nodes (N2)				
Extra mesorectal node	+	+	When LN+	+	+	+			
cT4 (anterior pelvic organ)	+	+	When LN+	+	+	+		+ in case of infiltration of inferior third of vagina	
cT4 (anal sphincter)	+	+	When LN+	+	+	+	+ (when direct tumor infiltration of IRF or external anal sphincter)		+

Review delineation exercise

Pre Consensus Guidelines

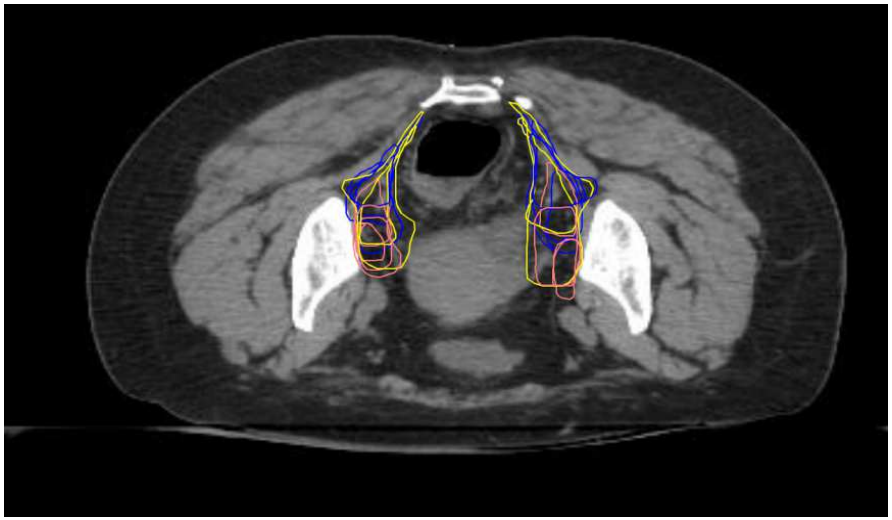

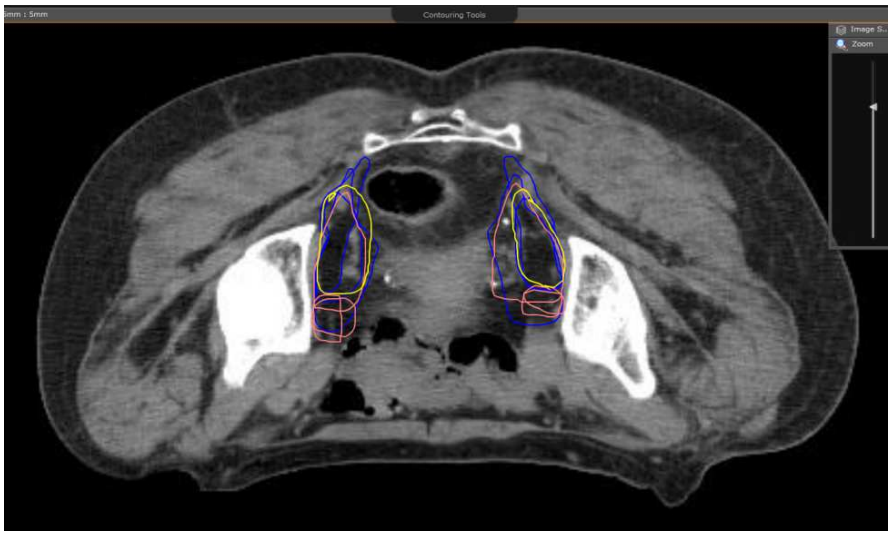

Post Consensus Guidelines

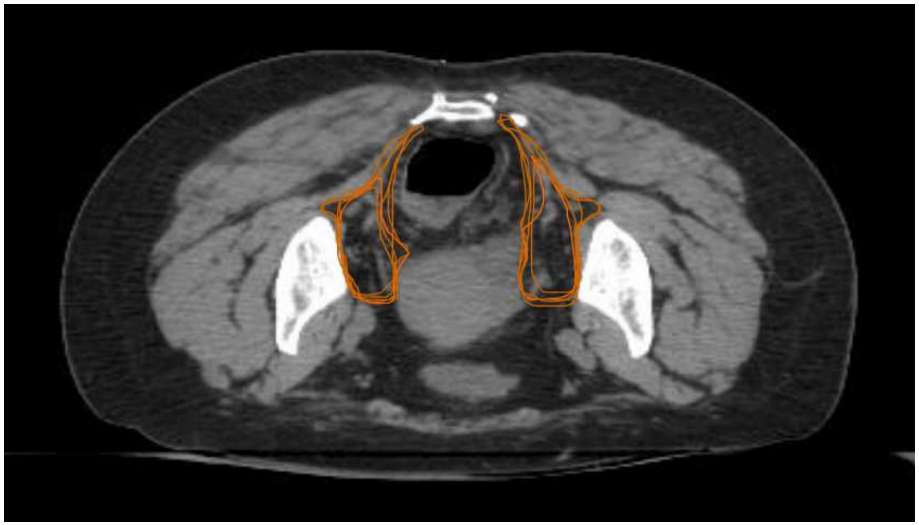

Rectal cancer guidelines

Server locations: **US**

Contoured Structures: BODY, Mesorectum, Sphicter, complex, LLN, GL, PS, GL, EIN, GL, IN, GL, IRF, GL

cT4 (anterior pelvic organ)

View Details | Launch the Case Viewer

Resource files:

Clinical History

Falcon Disclaimer

FALCON-EduCase User Guide

Uploaded: 10/24/14 18:09 ESTRO Admin

Viewed: **341** times — Category: Rectal Guidelines

Emailed: **0** times — Groups : 2014_Rectal_Guidelines

Total Slices: **205** — Image Modalities: **CT, MR**

Server locations: **US**

Contoured Structures: EIN, IIN, ON, M, PS, LLN, CTV, A, CTV, B, CTV, C, IRF/IPS, CG, Presacral, 9 more structures...

7 cases

cT3 (MRF+)

View Details | Launch the Case Viewer

Resource files:

Clinical History

Falcon Disclaimer

FALCON-EduCase User Guide

Uploaded: 10/24/14 17:51 ESTRO Admin

Viewed: **234** times — Category: Rectal Guidelines

Emailed: **0** times — Groups : 2014_Rectal_Guidelines

Total Slices: **201** — Image Modalities: **CT, MR**

Server locations: **US**

Brachy Prostate - Brussels 2017(2)
Past Courses(306)
Online Workshops(0)
Lung(0)
Lymphoma(1)
Head and Neck(1)
Past Workshops(37)
ESTRO Conferences(0)
Intraprostatic Relapses(1)
Liver SBRT(1)
Anal Canal(1)
Spine SBRT(1)
Past Conferences(26)
Member Cases(0)
Free Cases(10)
Cases(1)
Faculty Review(0)
Breast Consensus(2)
GI Consensus(4)
Head and Neck Guidelines(1)
Oesophagus Guidelines(6)
Prostate Consensus(1)
Rectal Guidelines(7)
Past Cases(3)
External Cases(0)
HYPO-01(3)
IAEA ICARO2(7)
IAEA QA Protocol - 2016/17(10)
ILROG - Lugano 2017(5)
Isle of Ireland - 2017(2)
PLATO(2)
RANZCR(1)
RCR17(1)

GTV

GTV: the tumor

GTV: removed by surgery

Long course RT-CT and delayed surgery

Boost: shrinkage/regression

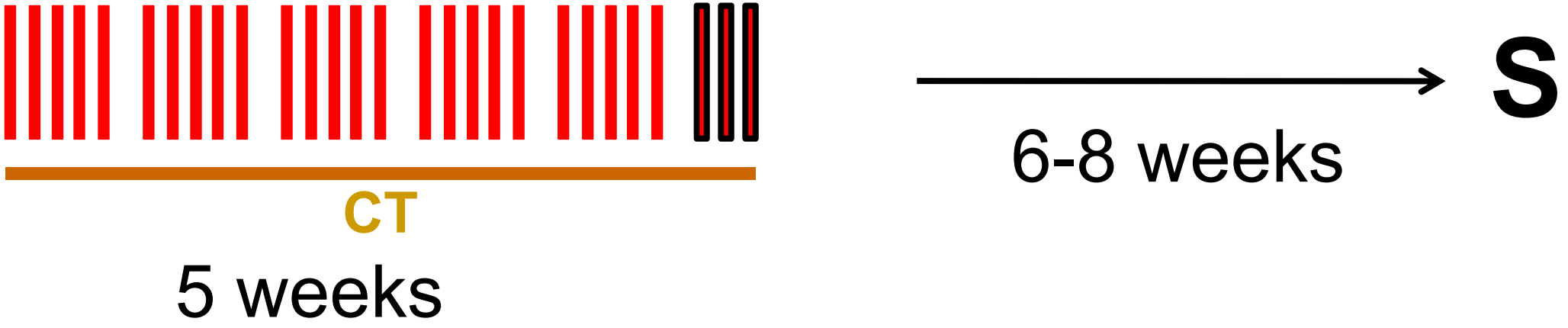

GTV-CTV margin

No consensus! No Guidelines!

GTV

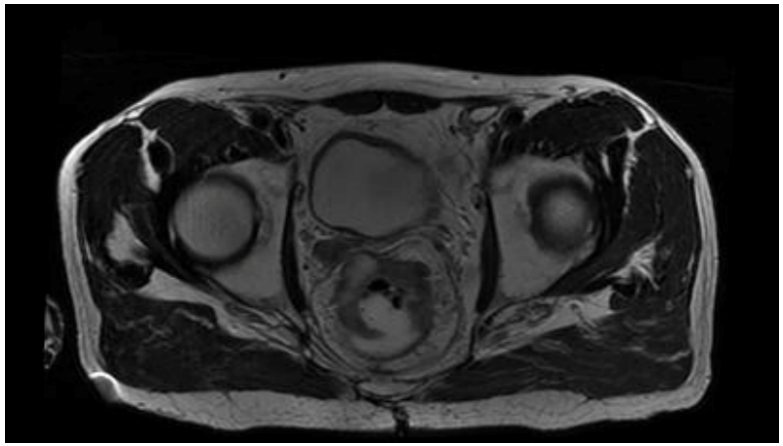

CTV

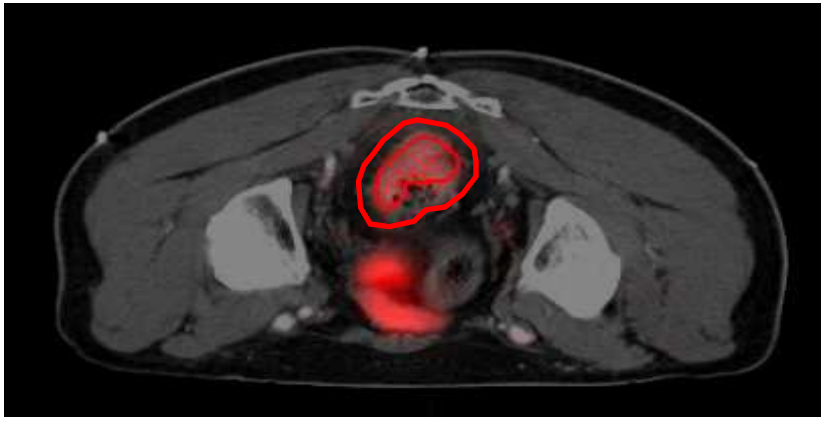

GTV + margin

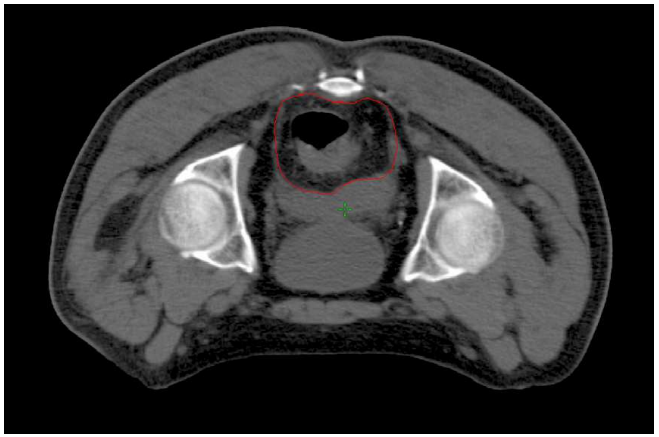

GTV + corresponding mesorectum

Myerson et al IJROBP 2009

GTV-CTV margin

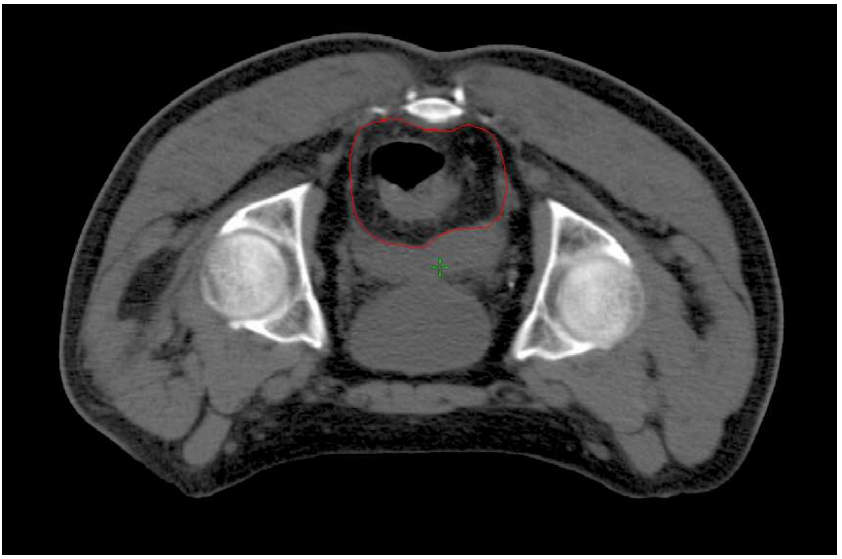

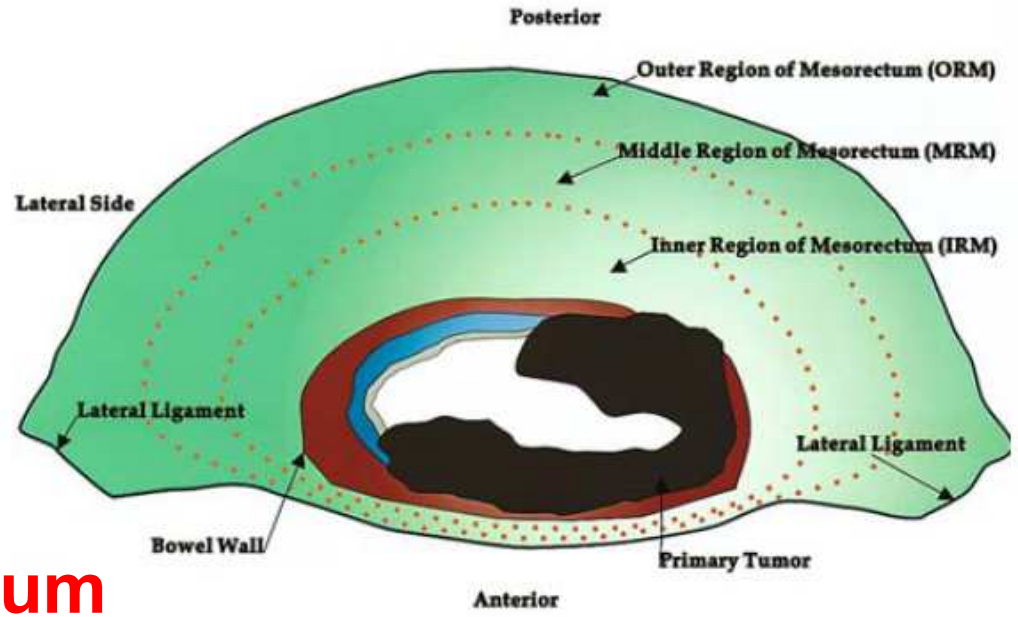

GTV + corresponding mesorectum

Microscopic tumor deposits in the Mesorectum: **38%**

Outer Region of the Mesorectum: **25%**

Distal tumor deposits in the mesorectal fat **3 cm** from the cancer: **6.5%**

Prevent target missing related to movement (ITV)

Myerson et al IJROBP 2009

Wang et al. Int J Colorectal dis 2005

CTV-PTV margin

Shape variation

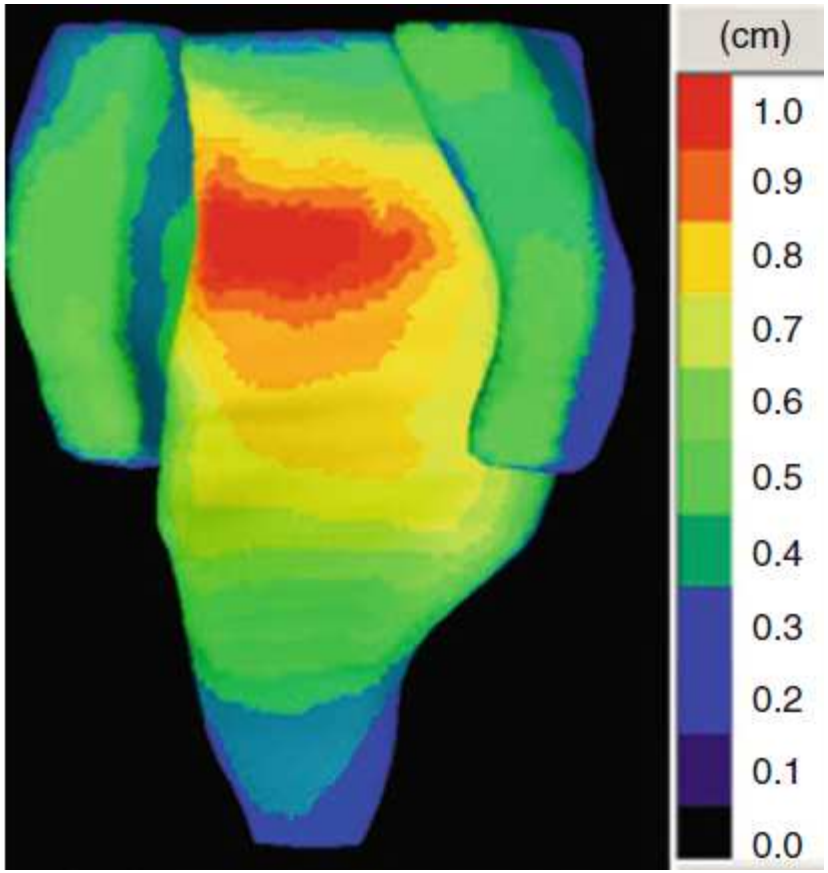

CTV moves due to the rectum filling

Repeated CT scan during treatment

Systematic SD

0.8 cm upper-anterior

0.2 cm anus

Nijkamp J et al. Radiother Oncol 2009

Modification along therapy

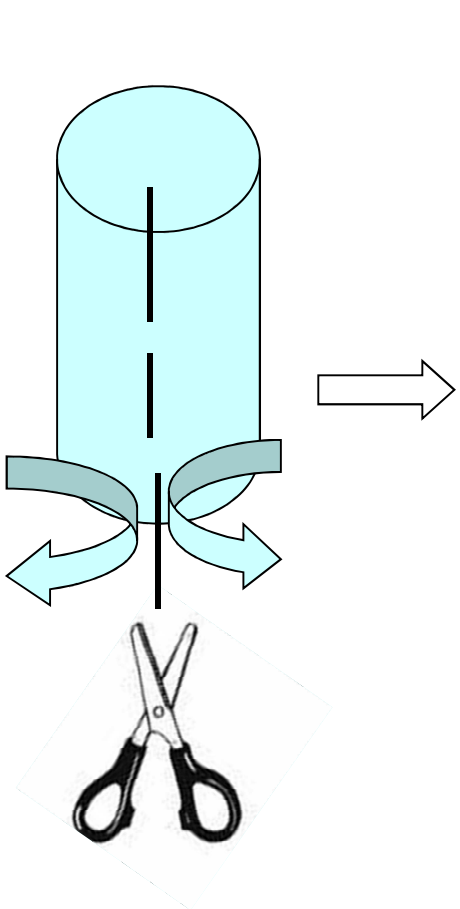

cranial

caudal

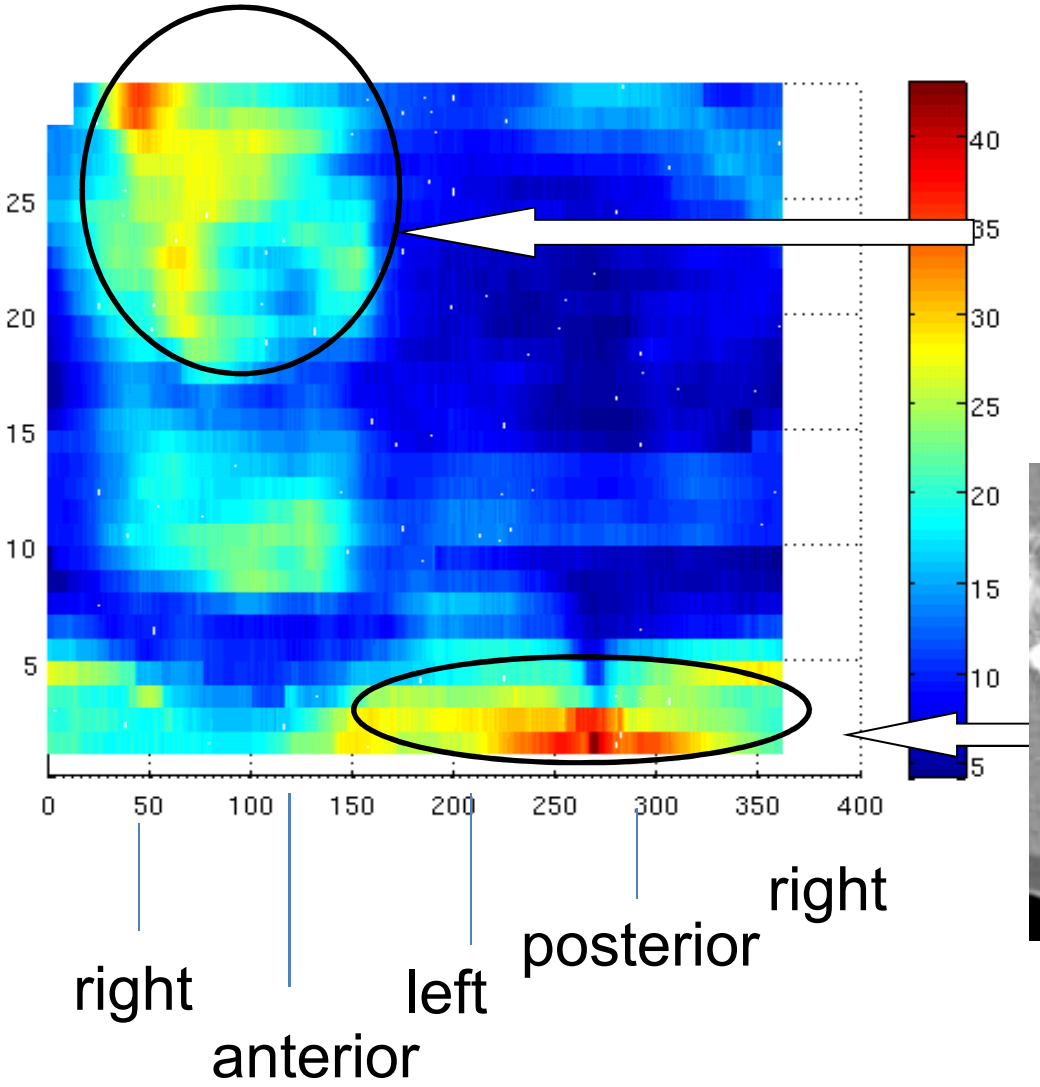

Ippolito E et al - Acta Oncol - 2009

Modification along therapy

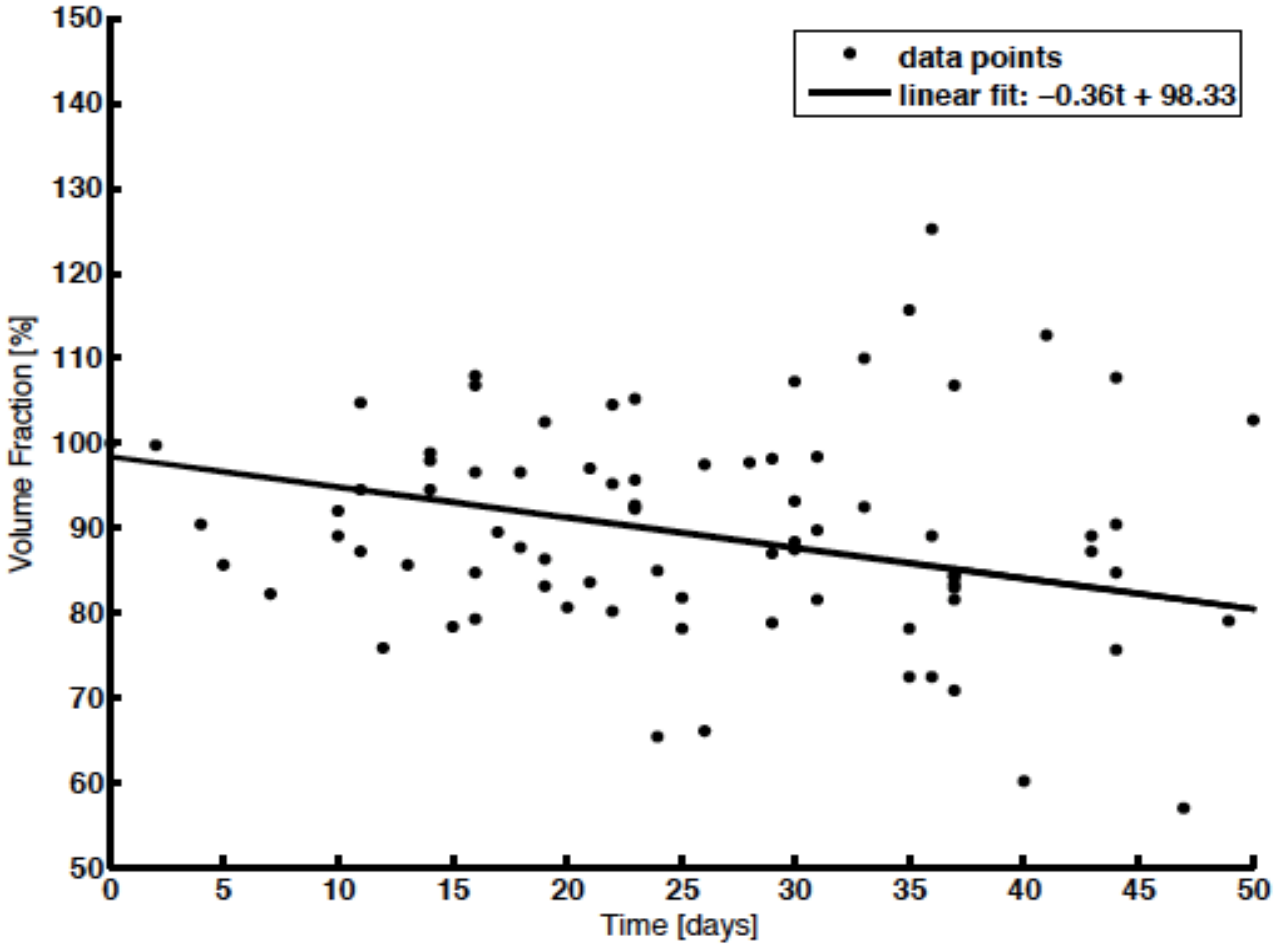

Ippolito E et al - Acta Oncol - 2009

Set-up errors

Position

Left-right direction

Prone up to 0.24 cm SD

Supine < 0.1 cm SD

Pts are more stable!

Nijkamp J et al. Radiother Oncol 2009

Organ at Risk

Small bowel

OARs: Small Bowel

Acute SB toxicity

- Any grade **20-70%**
- **G3+ up to 20-25%** in Chemoradiation

Late SB toxicity

- Any grade: **5-30%**
- **65%** long survivor patients

Acute Small Bowel toxicity

Onset: 2nd week of treatment → 15-20 days after treatment

Most frequent site in pelvic RT: ileum

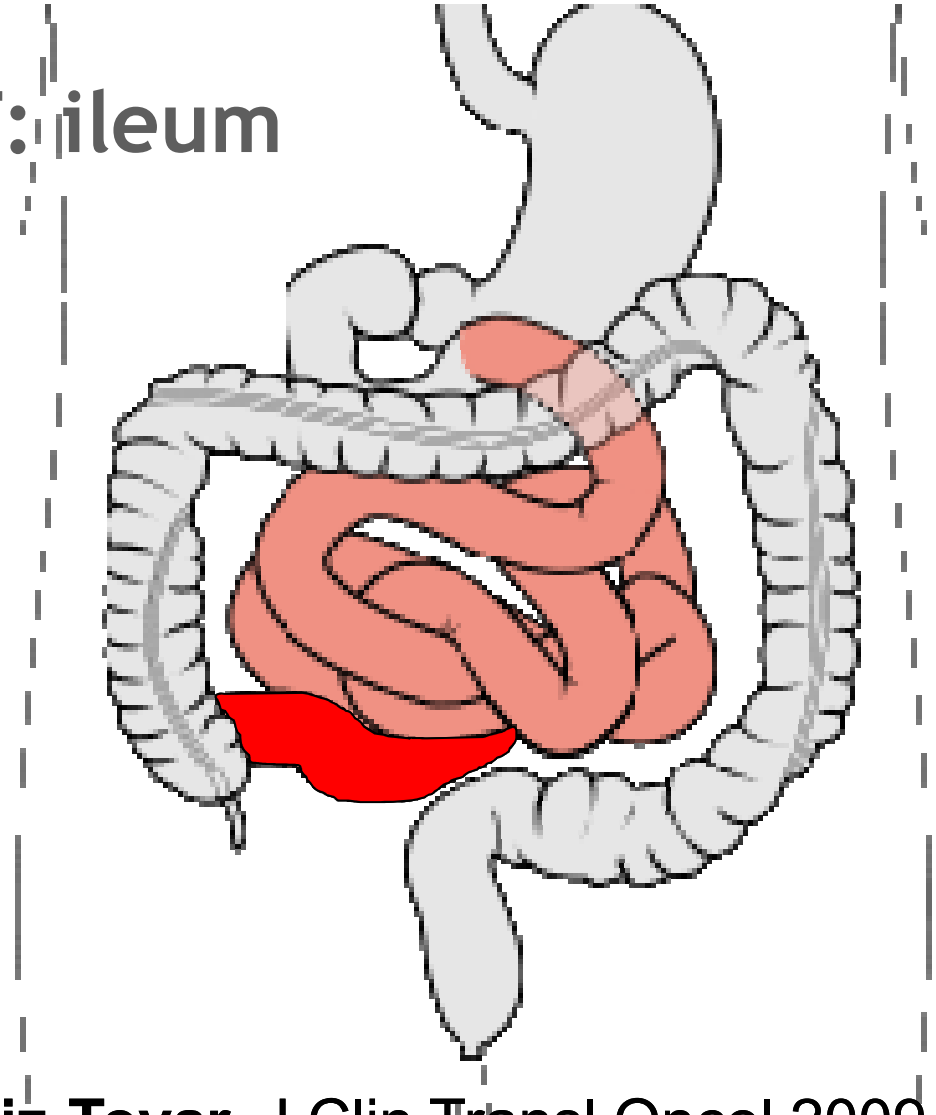

Symptoms:

Abdominal pain (cramps)

Diarrhea

Nausea

Lack of appetite

Weight loss

Andreyev HJ. Clin Oncol.2007 **Ruiz-Tovar.** J,Clin Transl Oncol 2009

Late Small Bowel toxicity

Onset: 18 mths - 6 yrs after treatment.

Incidence: increased with survival, reported 1/5 patients

Underreported

Cause: RT dose and volumes

Medical treatment: 55% of symptomatic pts requires medical treatments

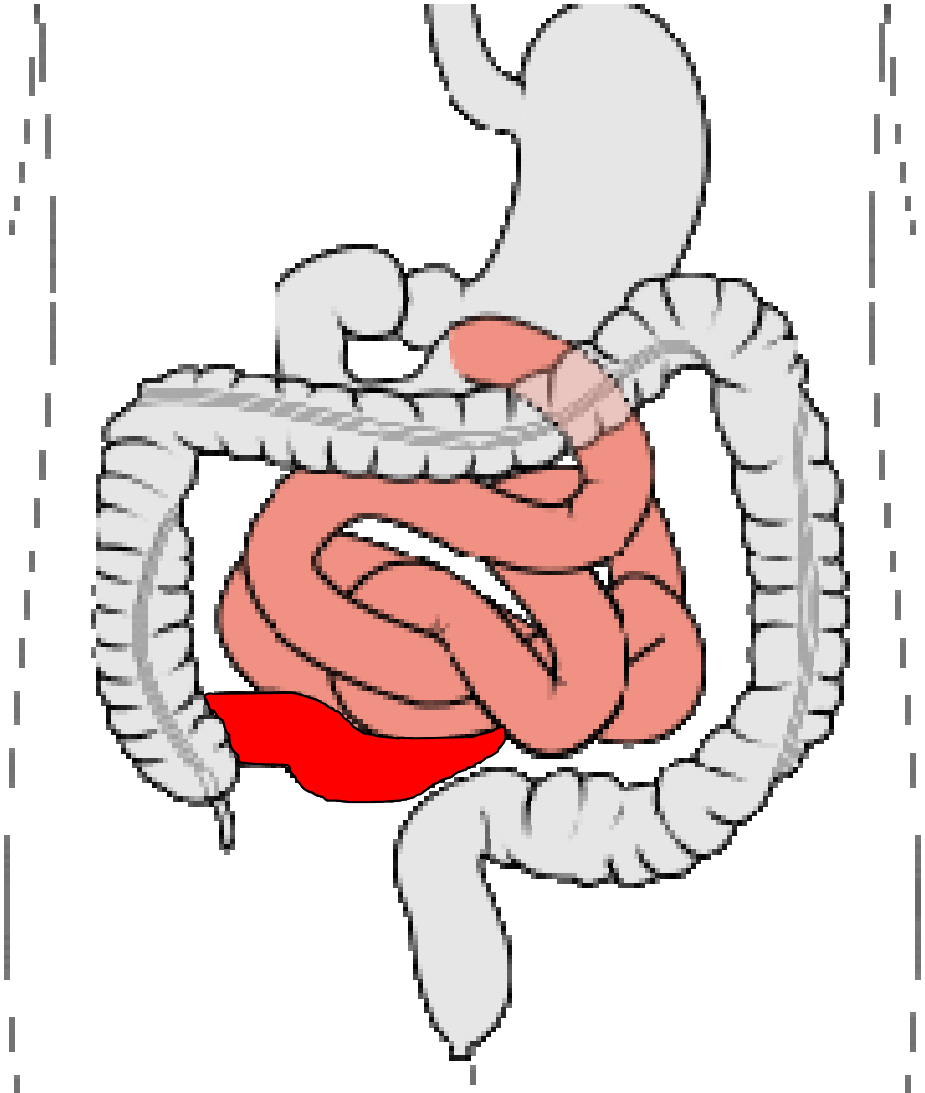

Game B. Aliment Pharmacol Ther 2003

Prevention: Dose constraints

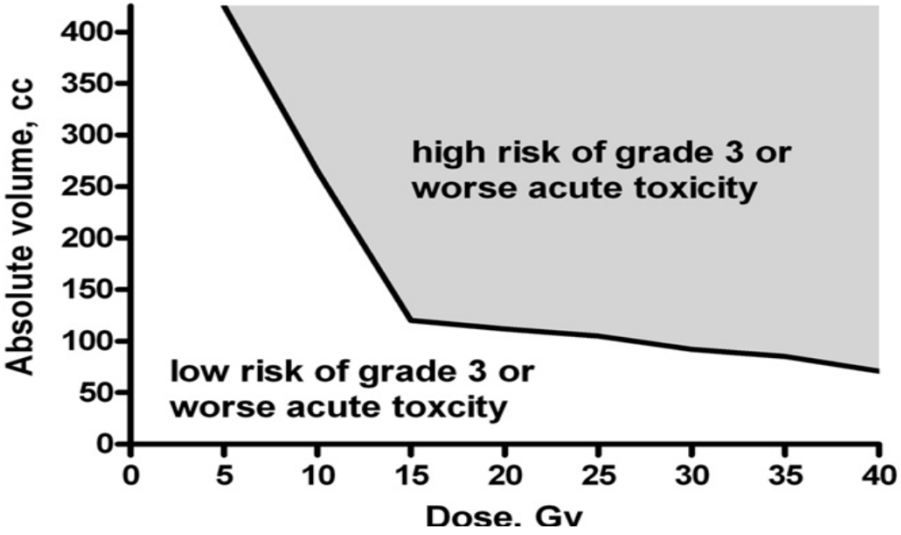

Planning

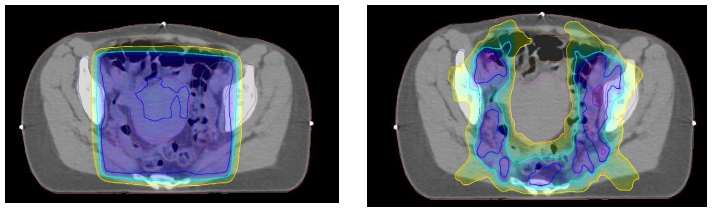

SET-UP

Bowel loops

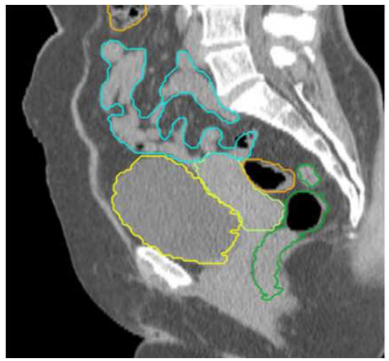

V15 = 120 cc

Bowel bag

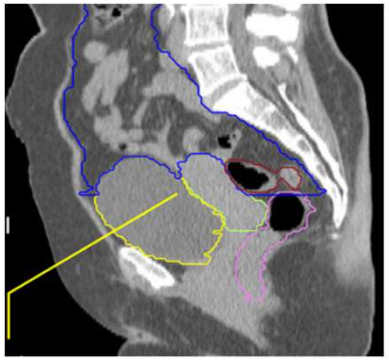

V45 = 195 cc

DELINEATION

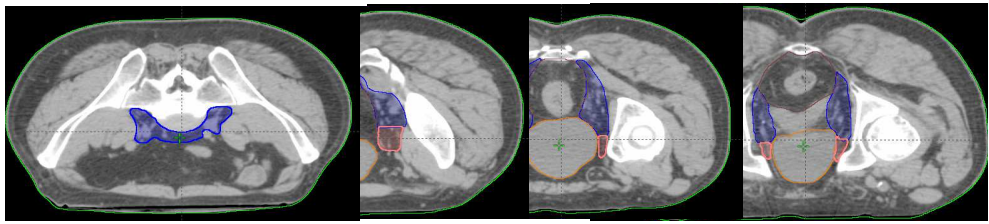

Small bowel displacement

full bladder

belly board/false table-top

Small bowel displacement

prone

FB

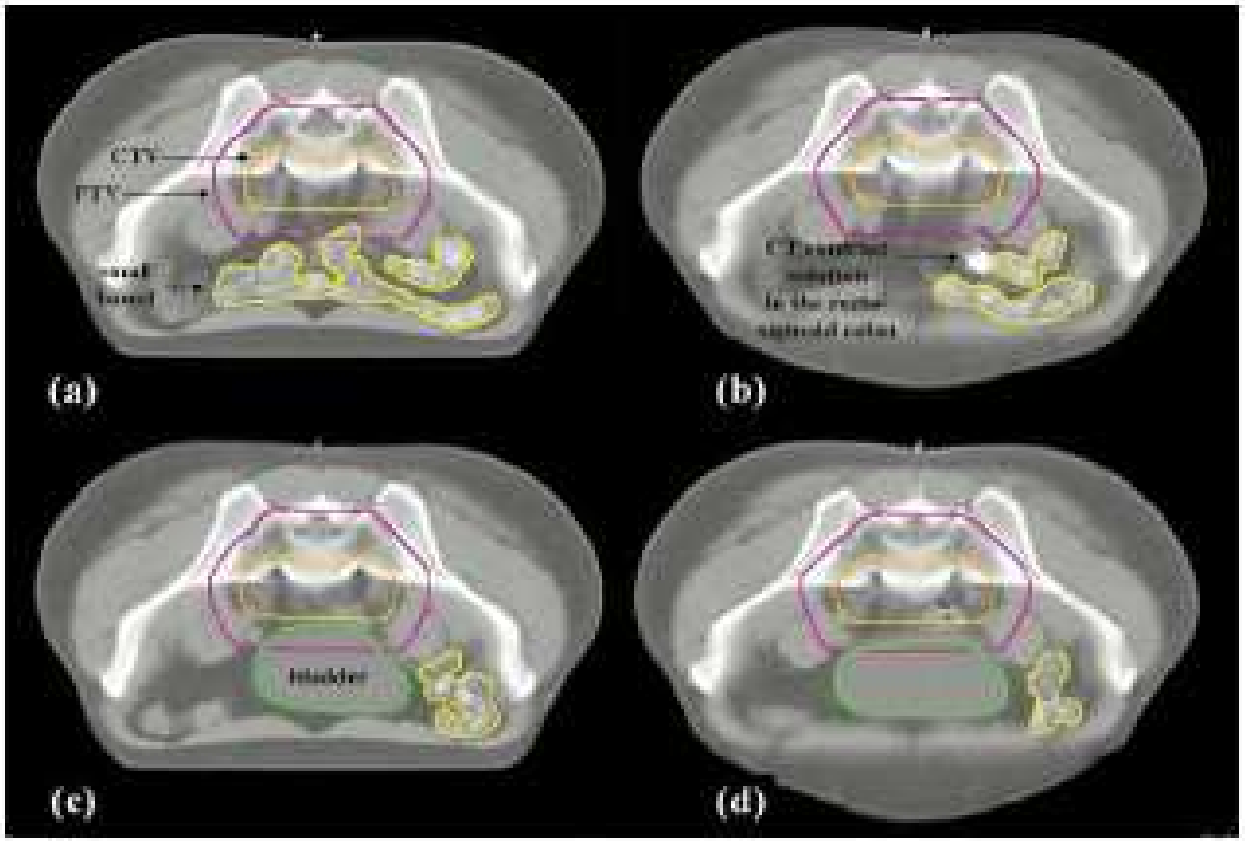

BBD

FB & BBD

PRE-operative RT

Kim TH. IJROBP 2005

Small bowel displacement

belly board vs full bladder:

Belly-Board+Full-Bladder >Full-Bladder > Belly-Board

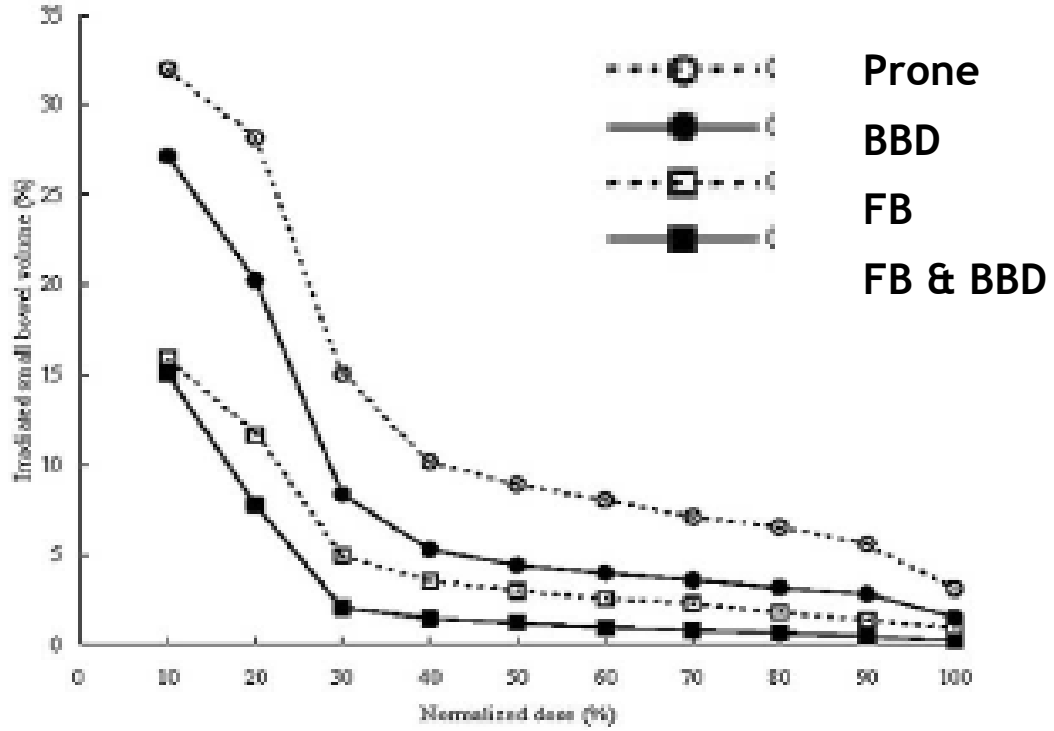

PRE-operative

Kim TH. IJROBP 2005

CTV reduction

Local recurrences: 2/3 in the lower of the pelvis.
CRM- and NODE NEGATIVE: all LR below S2-3 interspace

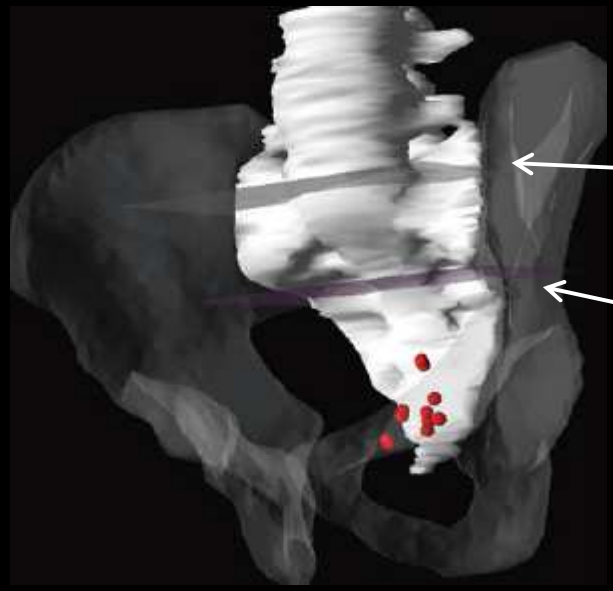

Superior border of RT field

S2-3 interspace

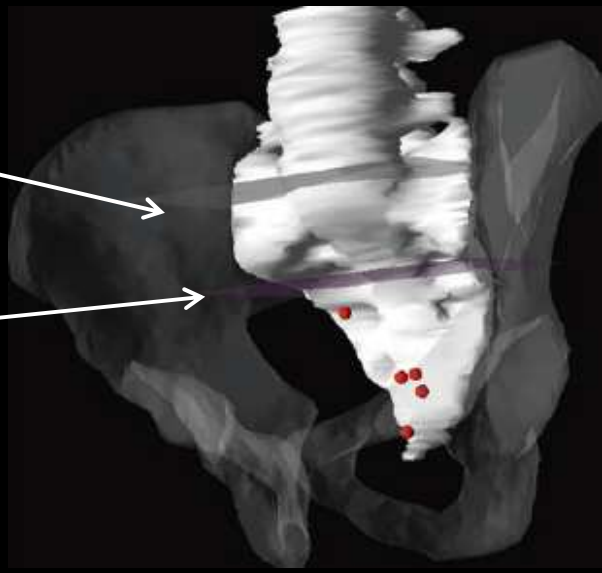

TME

RT + TME

Nijkamp et al IJROBP 2011

CTV reduction

cranial border to S2-S3 interspace → **reduction of 60% of SB exposure at doses 15-35 Gy**

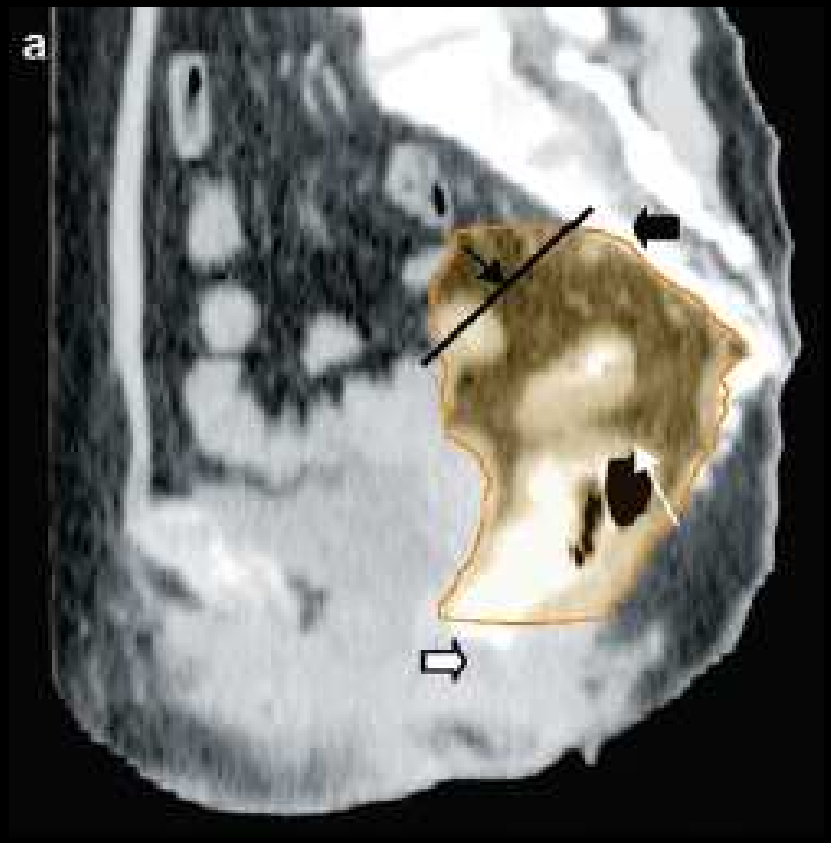

INCONTINENCE

Unintentional release of stool: TME vs RT-TME

MRC-CR07 trial

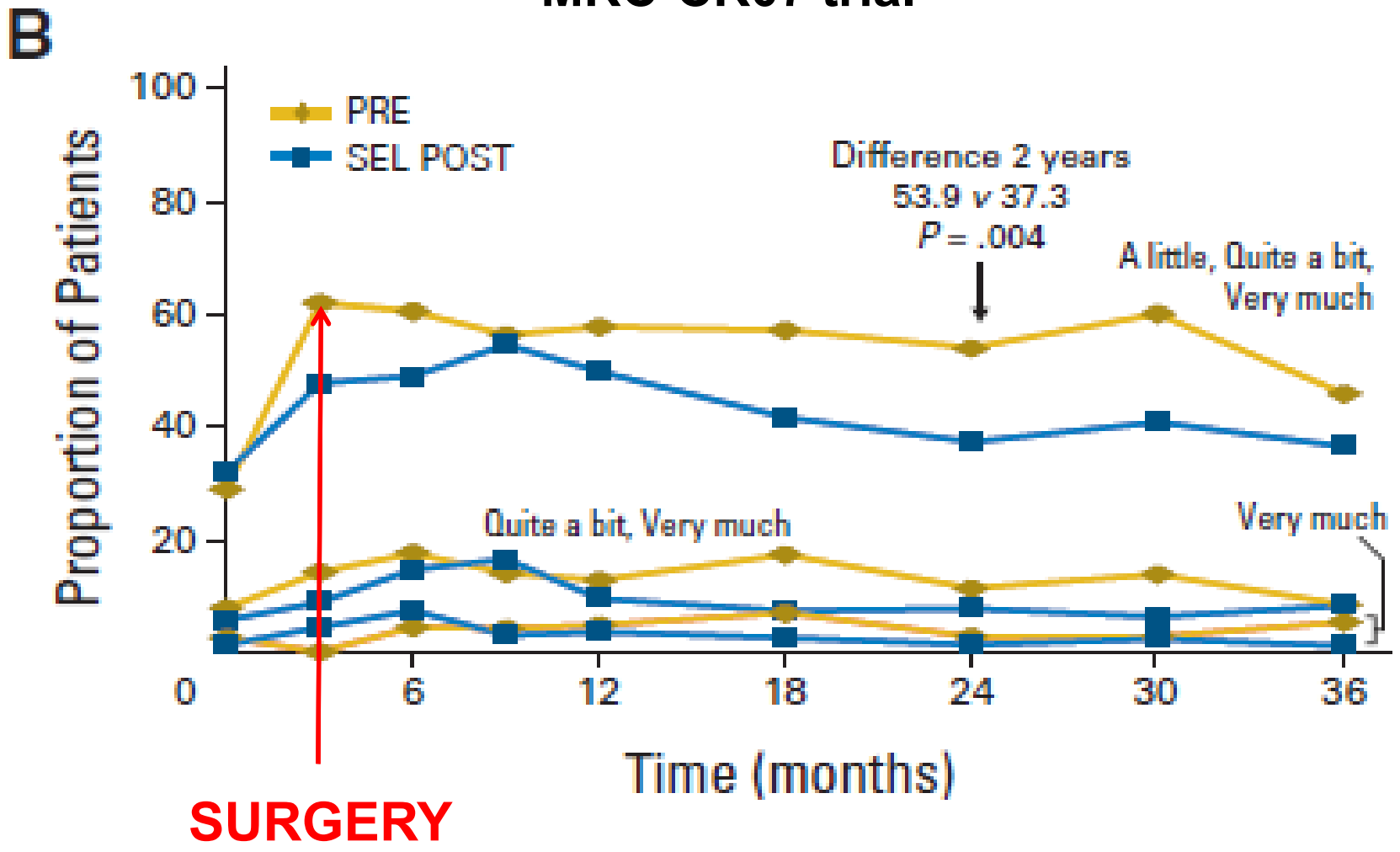

Stephens et al JCO 2010

Bowel funtion and incontinence: TME vs RT-TME

Dutch Trial

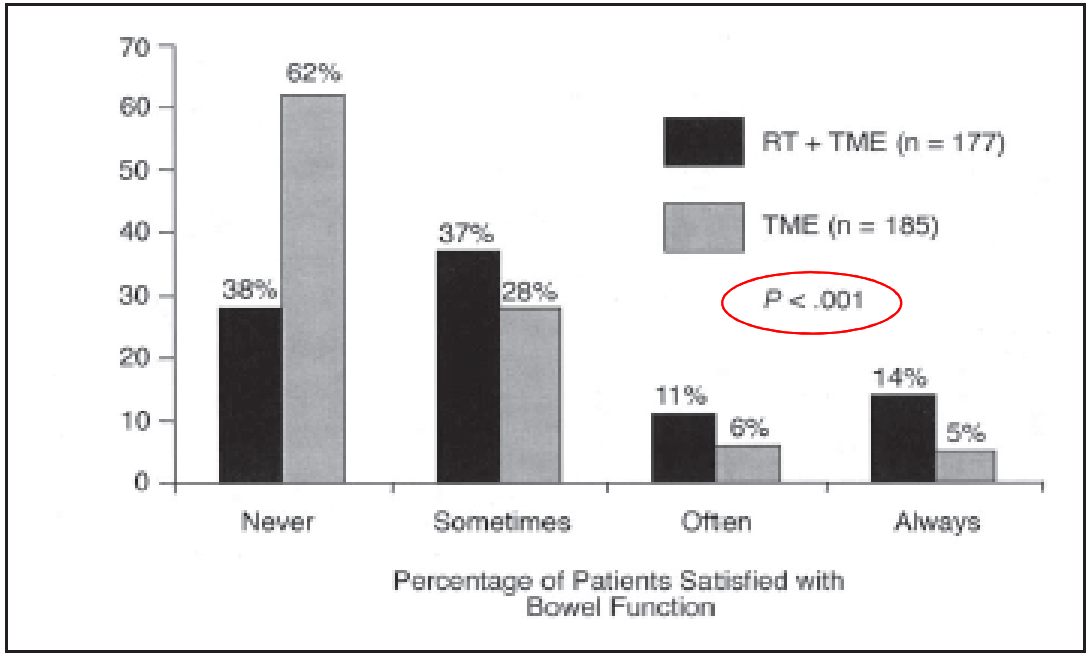

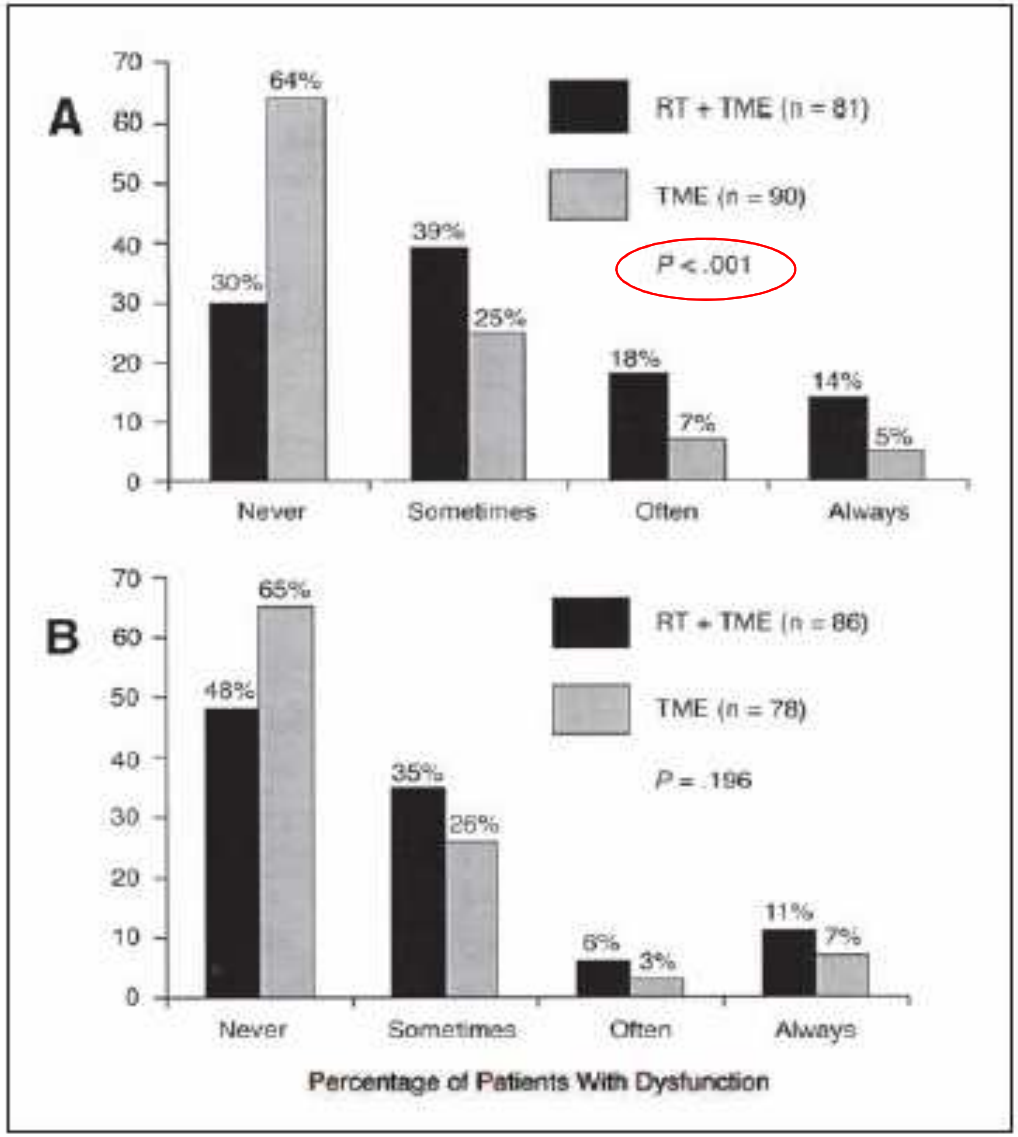

A: mid rectum (5-10 cm)
B: high rectum (10-15 cm)

Peeters et al JCO

CTV reduction: sphincter

Anal canal inclusion in CTV → incontinence

Anal canal in CTV	Y	N	p
incontinence	93%	65%	0.059

Inferior limit → avoid anal sphincter and IRF when not invaded

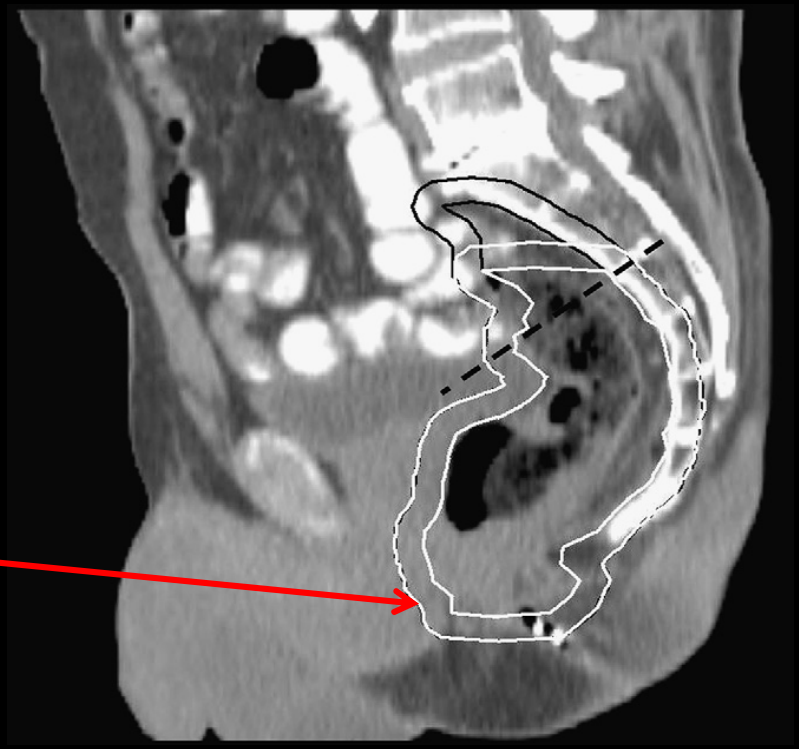

Lange MM et al.Br J Surg 2007
Nijkamp et al IJROBP 2011
Bujiko *Multidisciplinary Management of Rectal Cancer 2012*

SEXUAL FUNCTION

MRC-CR07 trial

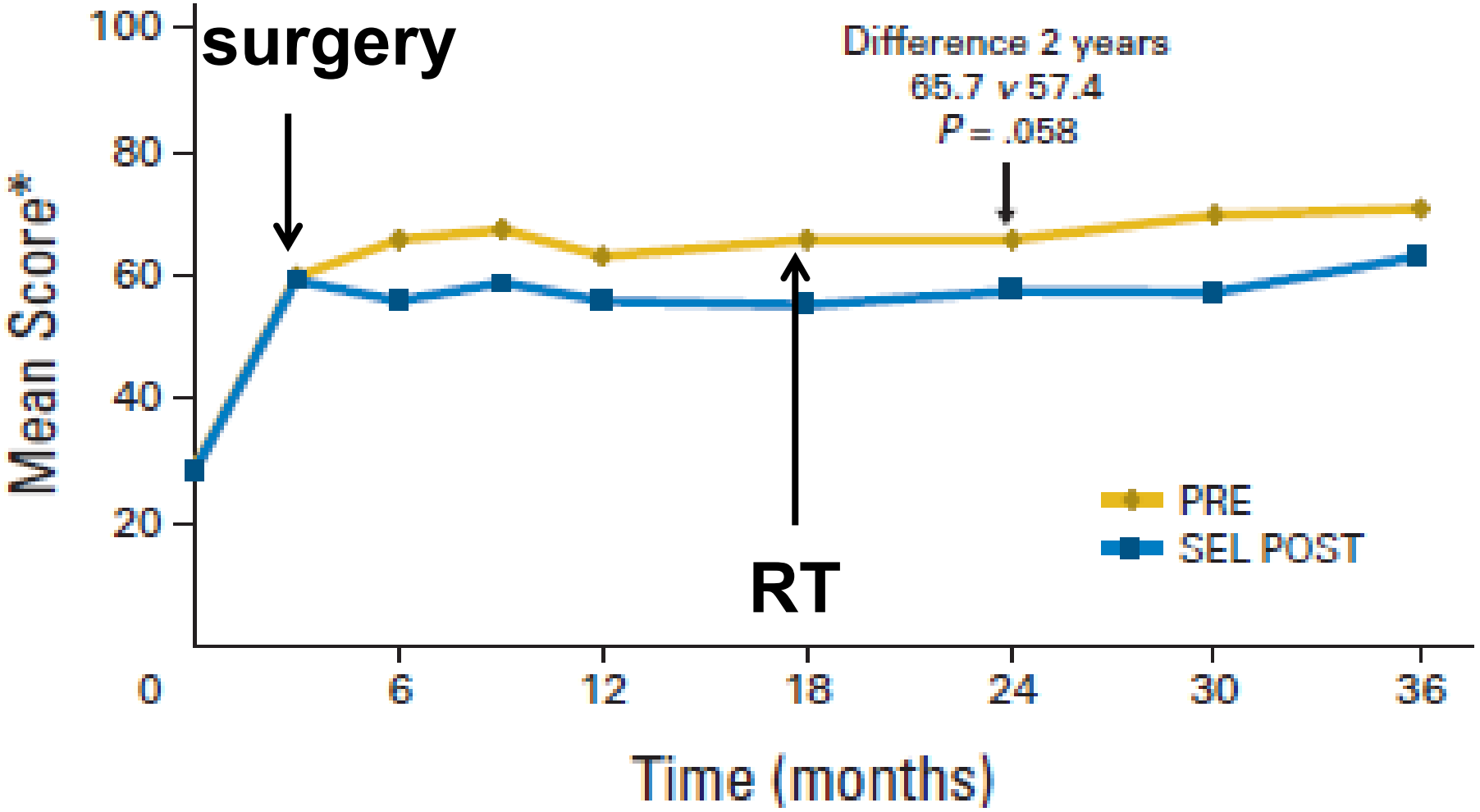

*Only 11% of women completed the questionnaire at 2 yrs

Stephens et al JCO 2010

Sexual function: TME vs RT-TME

Dutch trial

SEXUAL ACTIVITY (pts active before therapy)	Sex	TME	RT-TME	p
	Male	76%	67%	0.06
	Female	90%	72%	0.01

Marijnen et al JCO 2005

Female sexual function

- < 50% sexually active during the last month
- Vaginal dryness/pain during intercourse
- Low interest in sex
- Sex doesn’t affect their life

Braendegen et al IJROBP 2011

CTV: sexual

Anterior limit

Exclude inferior part of the vagina
(Bartolini glands)

Inferior limit: penile bulb

D 70	Erectile dysfunction
0-40 Gy	0%
40-70 Gy	80%
>70 Gy	100%

Fish et al Urology 2001

Bujiko *Multidisciplinary Management of Rectal Cancer 2012*

Conclusion

CTV:

Refer to GL to reduce variability → now available common GL in RC

CTV can be modulated according to tumor presentation

PTV:

Account for shape variation→ anterior superior part of the mesorectum

Prone position with belly board and full bladder decreases SB dose → 3D

Supine position is more stable than prone → IMRT

ESTRO School

WWW.ESTRO.ORG/SCHOOL

Delineation of Clinical Target Volume (CTV) in Gynecology Cancer

Gonçalo Fernandez

Serviço de Radioterapia
Instituto Português de Oncologia de Lisboa - Francisco Gentil
R. Prof. Lima Basto, 1099-023 Lisboa
Phone: +351 217 200 454
Fax: +351 217 229 889
E-mail: goncalo_fernandez@sapo.pt

ESTRO School

Cervix - Primary disease GTV, CTV & OARs

1) INRODUCTION
2) CTV **NODAL** DELINEATION
3) CTV DELINEATION FOR **POST-OPERATIVE** GYNECOLOGY CANCER
4) CTV DELINEATION FOR **INTACT CARCINOMA OF THE CERVIX**
5) ITV FOR INTACT **CARCINOMA OF THE CERVIX**
6) CTV DELINEATION FOR **3D-BRACHYTHERAPY**
7) CONCLUSIONS

ESTRO School

1) INTRODUCTION

- Treatment in cervical and endometrial cancer includes EBRT (External Beam Radiotherapy) and BT (Brachytherapy)
- 3D-EBRT vs. IMRT – *reduced toxicity but increased risk of geographic miss*
- Importance of Guidelines: volume definition
- Although remains a degree of non-uniformity and consensus

ESTRO School

2) CTV NODAL DELINEATION

Table 2. Lymph node contours covered by margin around blood vessels

Lymph node group	3 mm (%)	5 mm (%)	7 mm (%)	10 mm (%)	15 mm (%)
Common iliac (n = 135)	41 (30.3)	90 (66.7)	123 (91.1)	135 (100)	135 (100)
Medial external iliac (n = 196)	122 (62.2)	167 (85.2)	193 (98.4)	196 (100)	196 (100)
Anterior external iliac (n = 241)	124 (51.4)	190 (78.8)	88%	241 (100)	241 (100)
Lateral external iliac (n = 190)	16 (8.4)	41 (21.6)		123 (64.7)	178 (93.7)
Obturator (n = 303)	275 (90.1)	295 (97.3)	302 (99.7)	303 (100)	303 (100)
Internal iliac (n = 144)	105 (72.9)	135 (93.8)	142 (98.6)	144 (100)	144 (100)
Presacral (n = 7)	0 (0)	0 (0)	3 (42.9)	3 (42.9)	3 (42.9)
Total (n = 1216)	683 (56.2)	918 (75.7)	1066 (87.7)	1145 (94.2)	1200 (98.7)

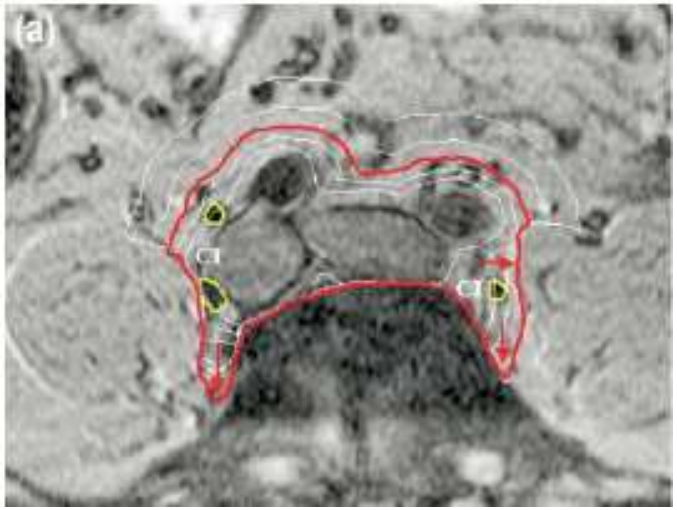

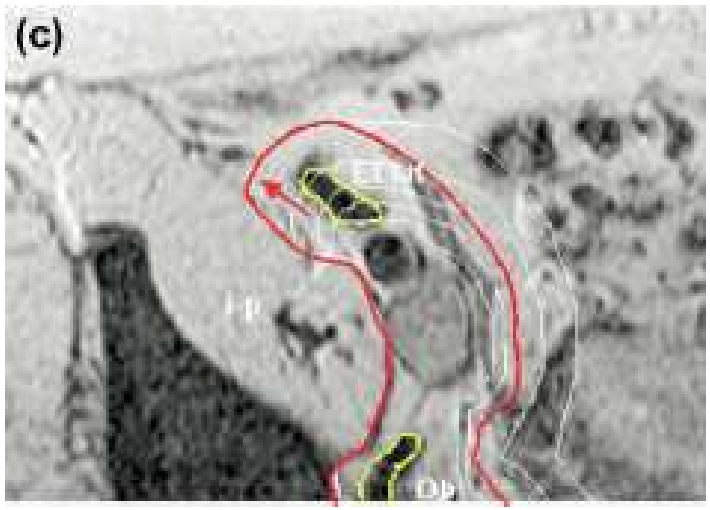

Taylor, A., et al. 2005

ESTRO School

2) CTV NODAL DELINEATION

Original Article

An Atlas of the Pelvic Lymph Node Regions to Aid Radiotherapy Target Volume Definition

A. Taylor*, A. G. Rockall†, M. E. B. Powell*

*Department of Radiotherapy, St Bartholomew's Hospital, London, UK; †Department of Radiology, St Bartholomew's Hospital, London, UK

- Accurate and reproducible delineation of target volumes recommendations
- Selection which nodal groups need to be covered depending on tumour site and stage
- Reference CT images of the pelvis were generated, illustrating the nodal regions and a typical target volume for adjuvant pelvic radiotherapy for **gynaecological cancer**.

ESTRO School

2) CTV NODAL DELINEATION

COMMON ILIAC

Non-uniform margin:

7 mm around vessels. Extend posterior and lateral borders to psoas and vertebral body

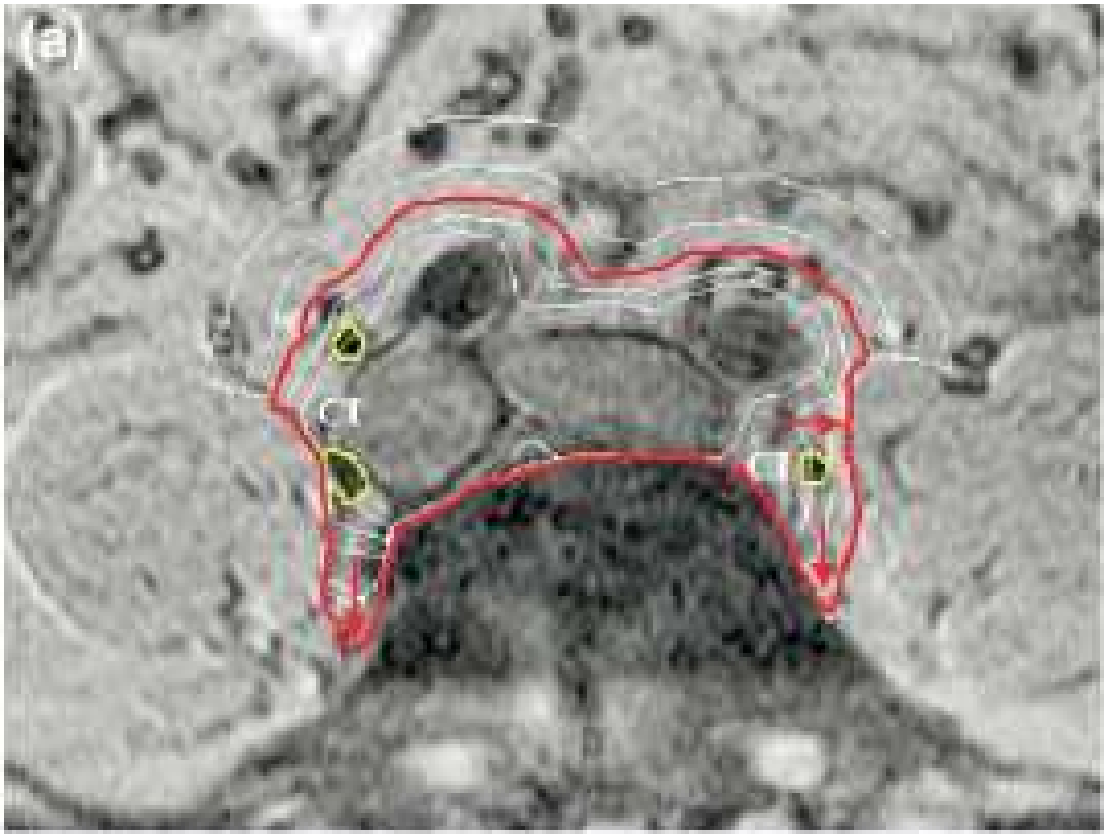

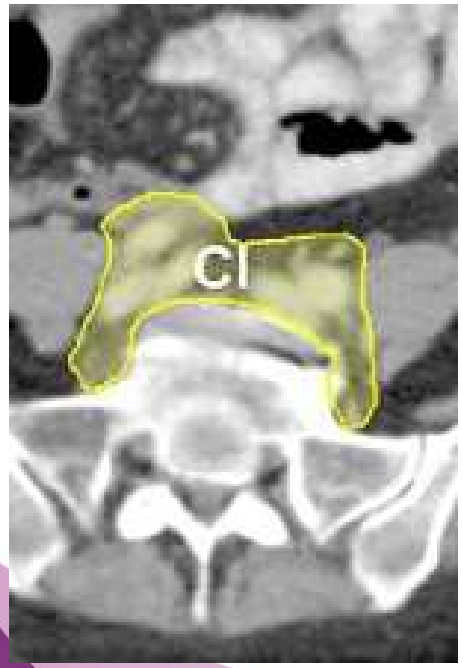

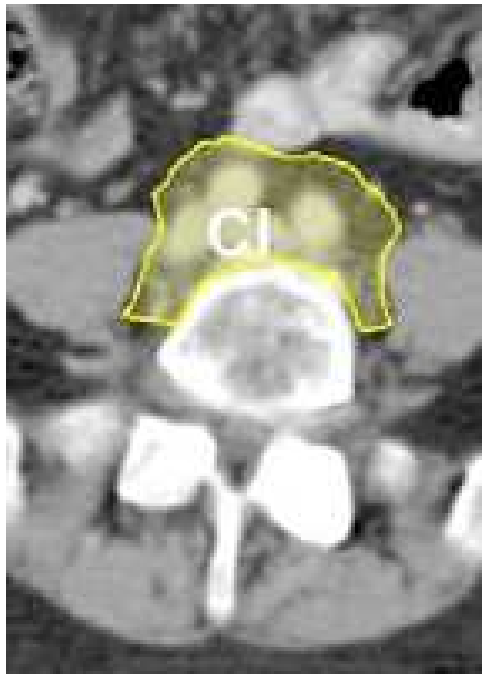

Taylor, A., et al. 2007

ESTRO School

2) CTV NODAL DELINEATION

EXTERNAL ILIAC

Non-uniform margin:

7 mm margin around vessels.
Extend anterior border by a further 10 mm anterolaterally along the iliopsoas muscle to include the lateral external iliac nodes

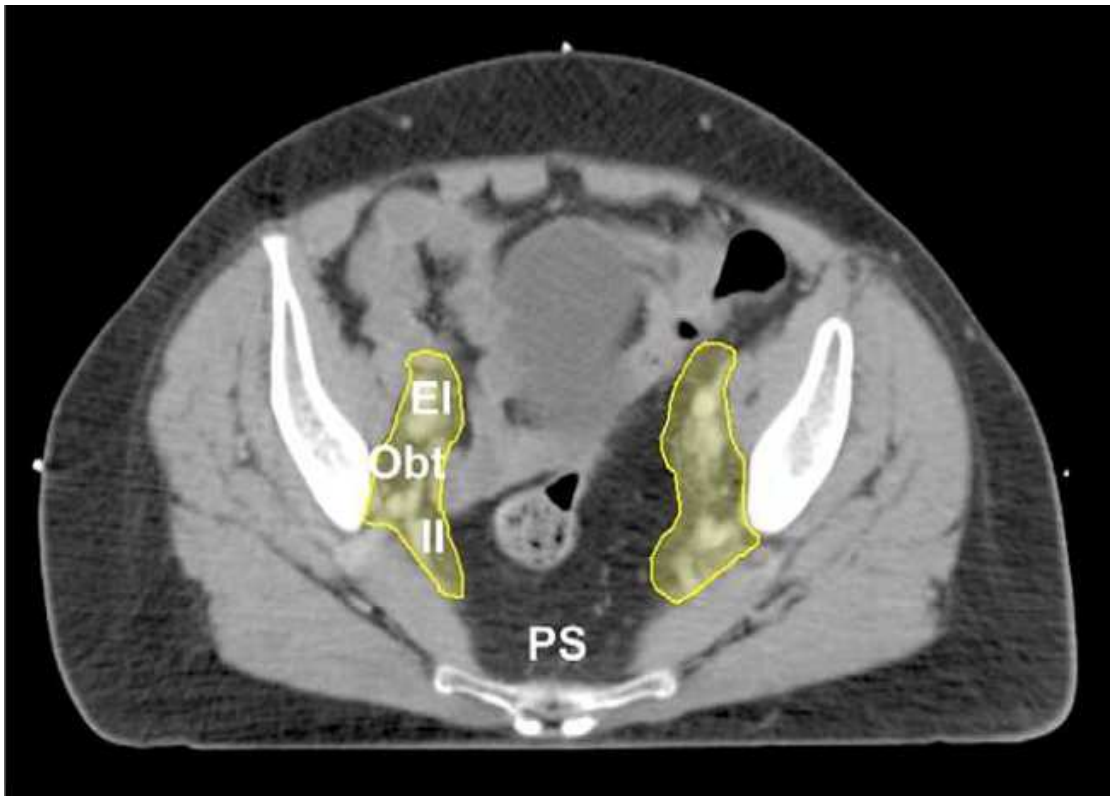

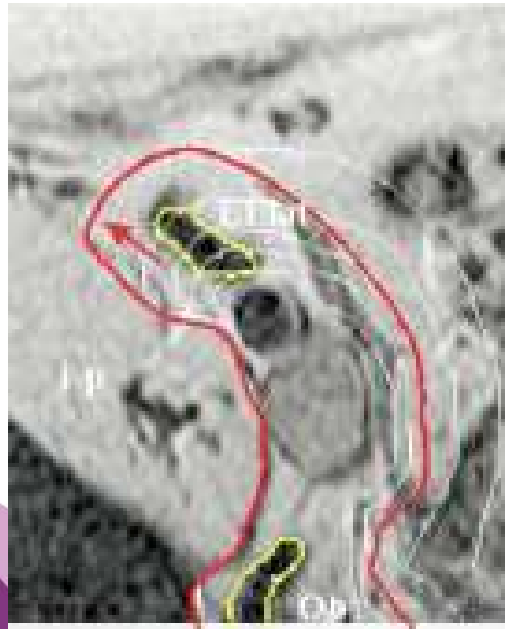

Taylor, A., et al. 2007

ESTRO School

2) CTV NODAL DELINEATION

INTERNAL ILIAC

7 mm margin around vessels.
Extend lateral borders to pelvic side wall

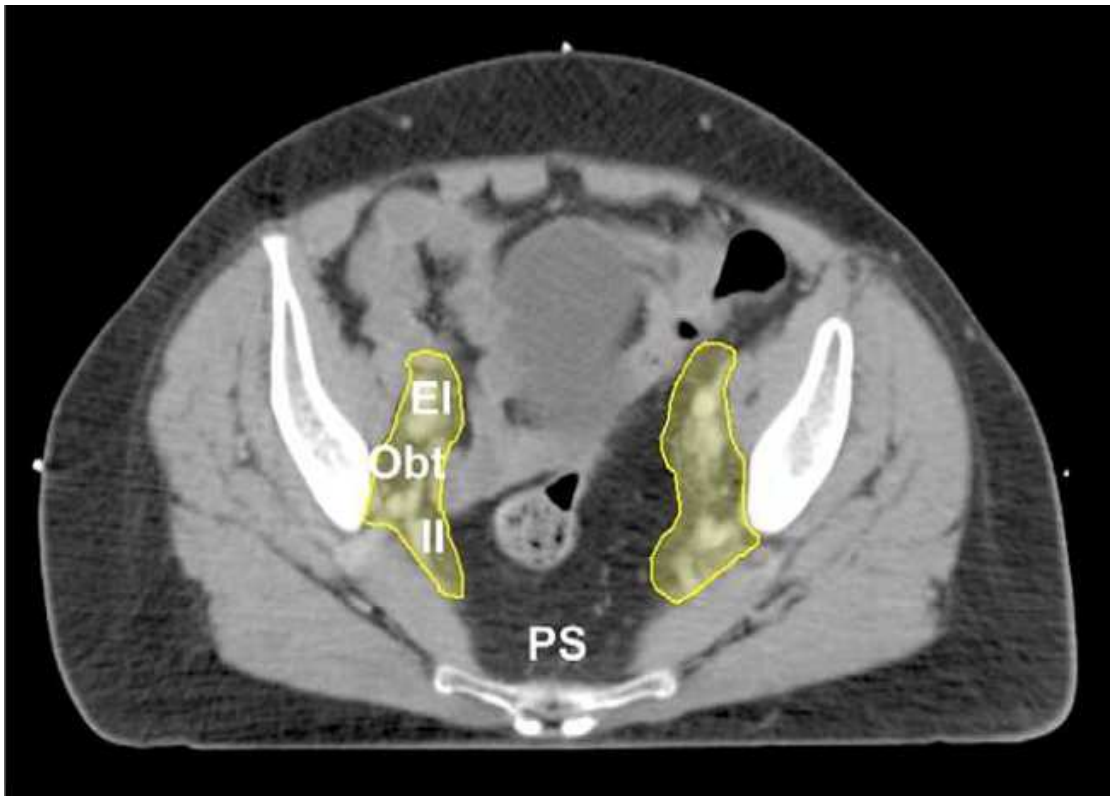

Taylor, A., et al. 2007

ESTRO School

2) CTV NODAL DELINEATION

OBTURATOR

Join external and internal iliac regions with a 17 mm wide strip along the pelvic side wall

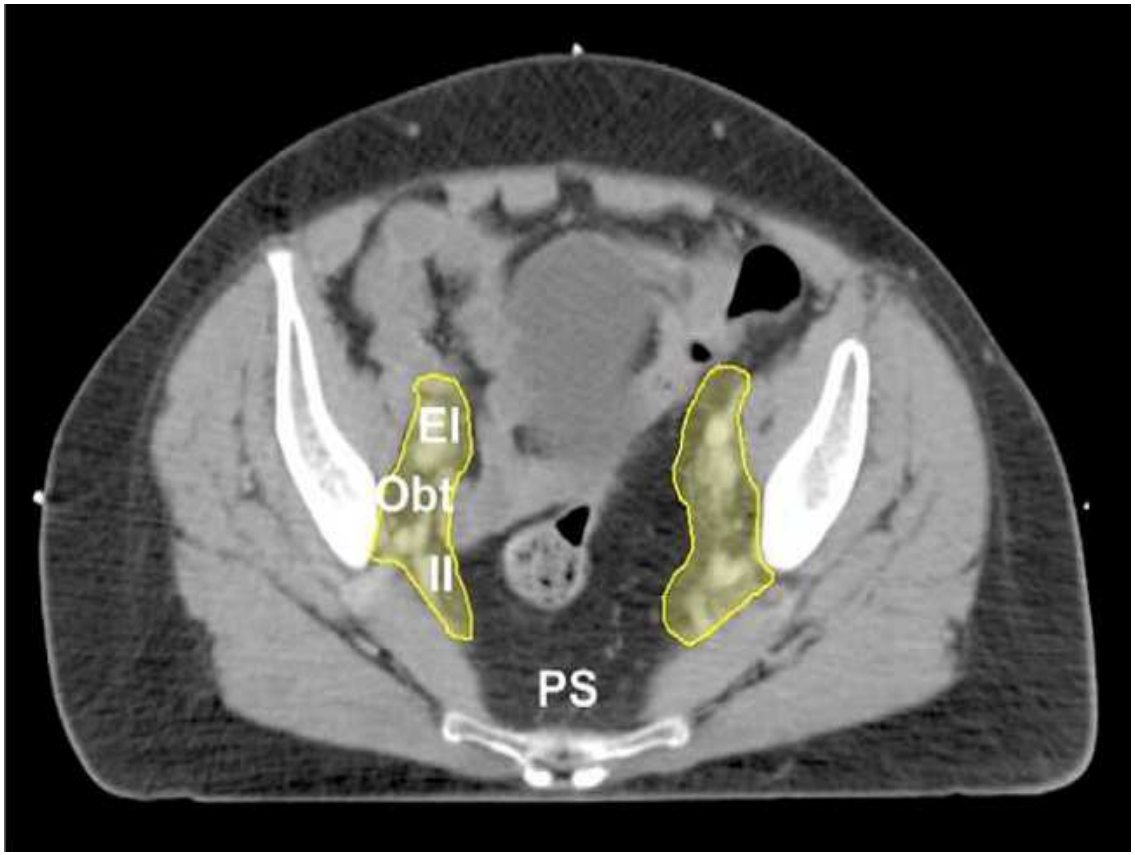

Taylor, A., et al. 2007

ESTRO School

2) CTV NODAL DELINEATION

PRE-SACRAL

Subaortic: 10 mm strip over anterior sacrum

Mesorectal: cover entire mesorectal space

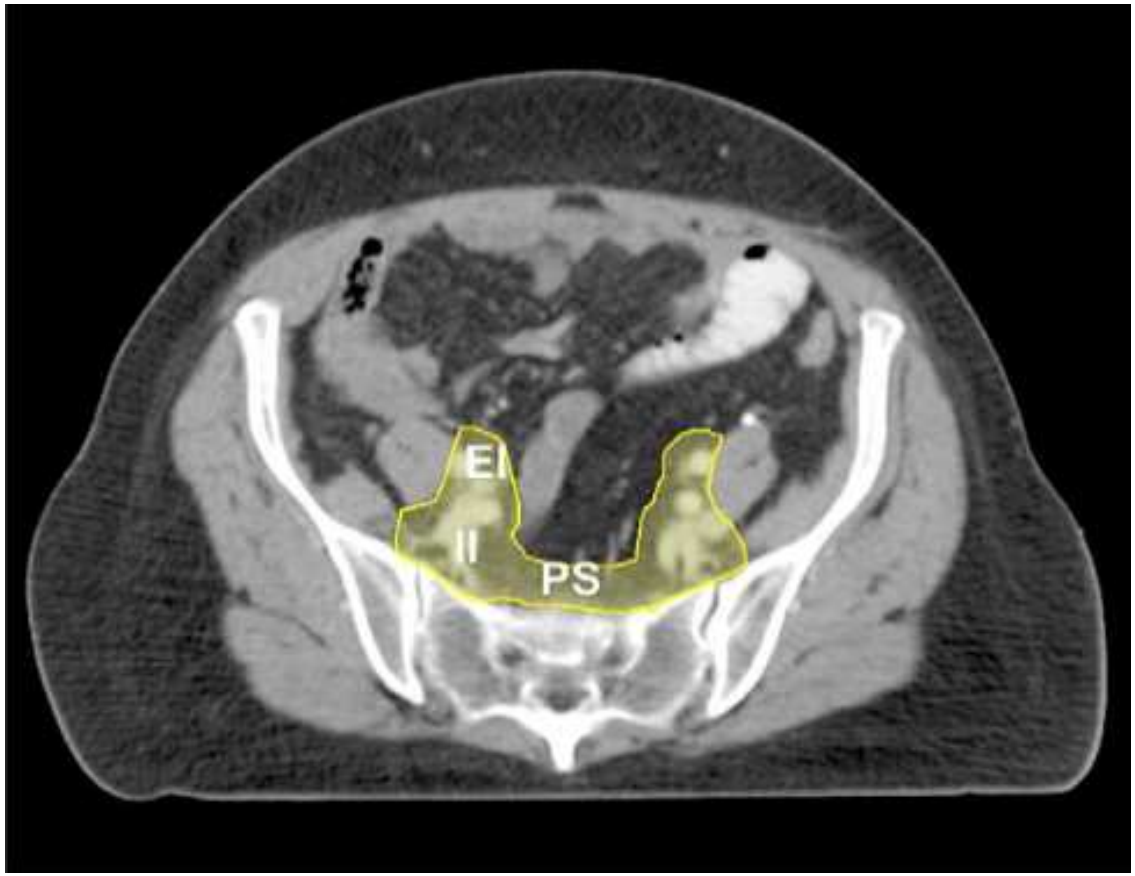

Taylor, A., et al. 2007

ESTRO School

2) CTV NODAL DELINEATION

PARA-AORTIC

Spatial distribution of this high-risk nodal volume by analyzing lymph nodes (LNs) on PET/CT scans

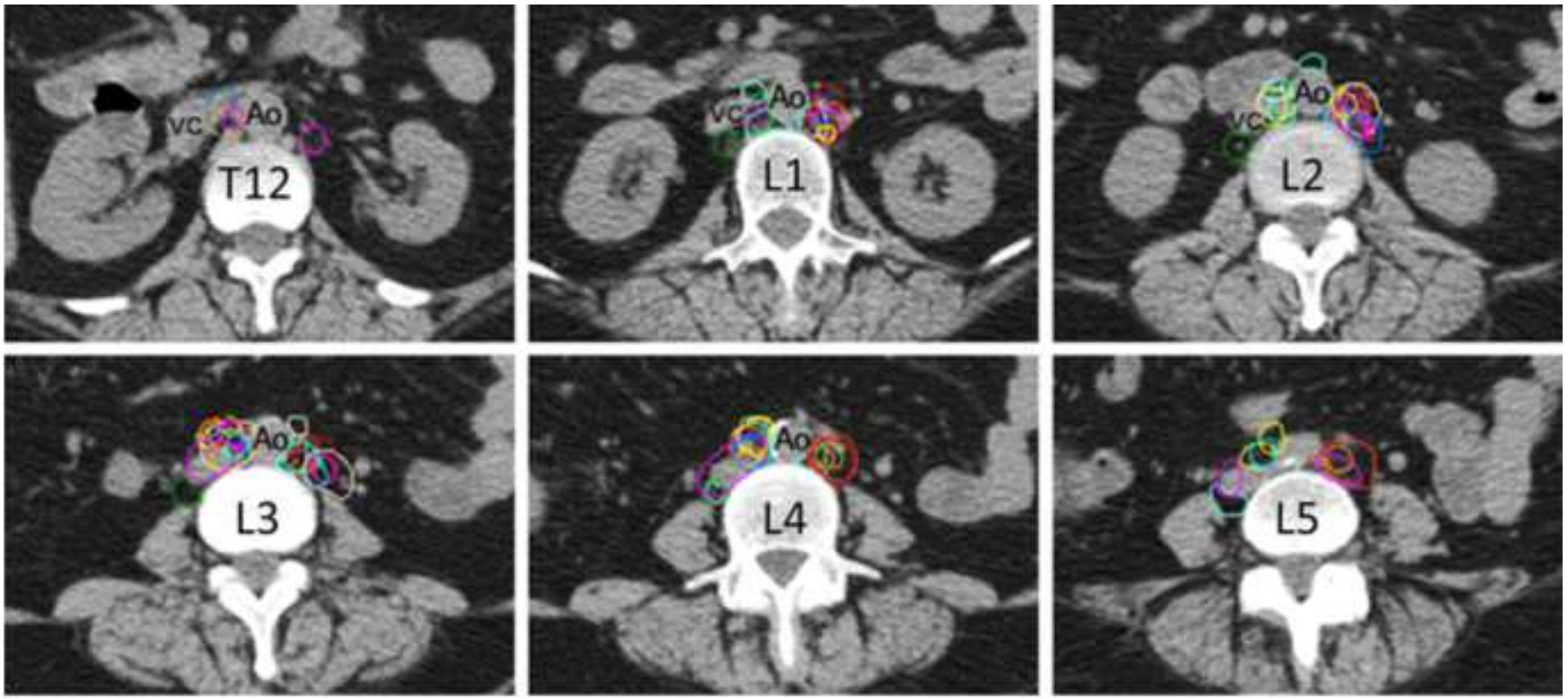

V. Takiar, 2012

ESTRO School

2) CTV NODAL DELINEATION

PARA-AORTIC

There is an increased risk of involvement of the para-aortic lymph nodes to the **left of the aorta** or the **aortocaval nodes** relative to nodes to the right of the vena cava, demonstrating that there is an **asymmetric** distribution of para-aortic lymph node involvement in cervical cancer.

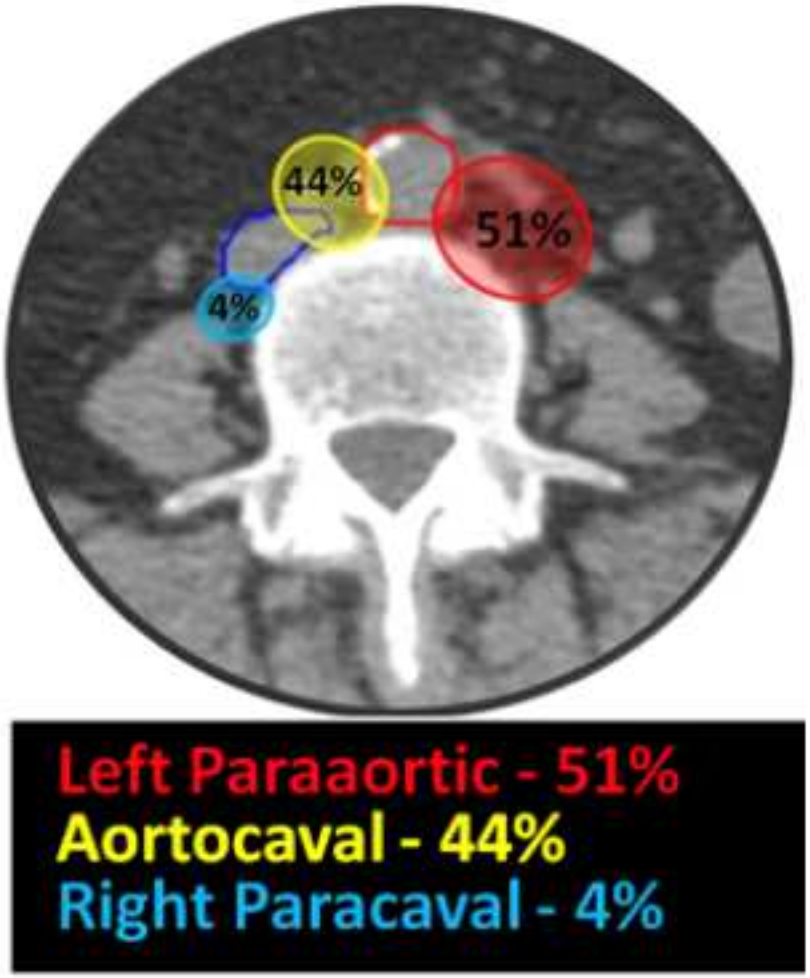

V. Takiar, 2012

ESTRO School

2) CTV NODAL DELINEATION

PARA-AORTIC

V. Takiar, 2012

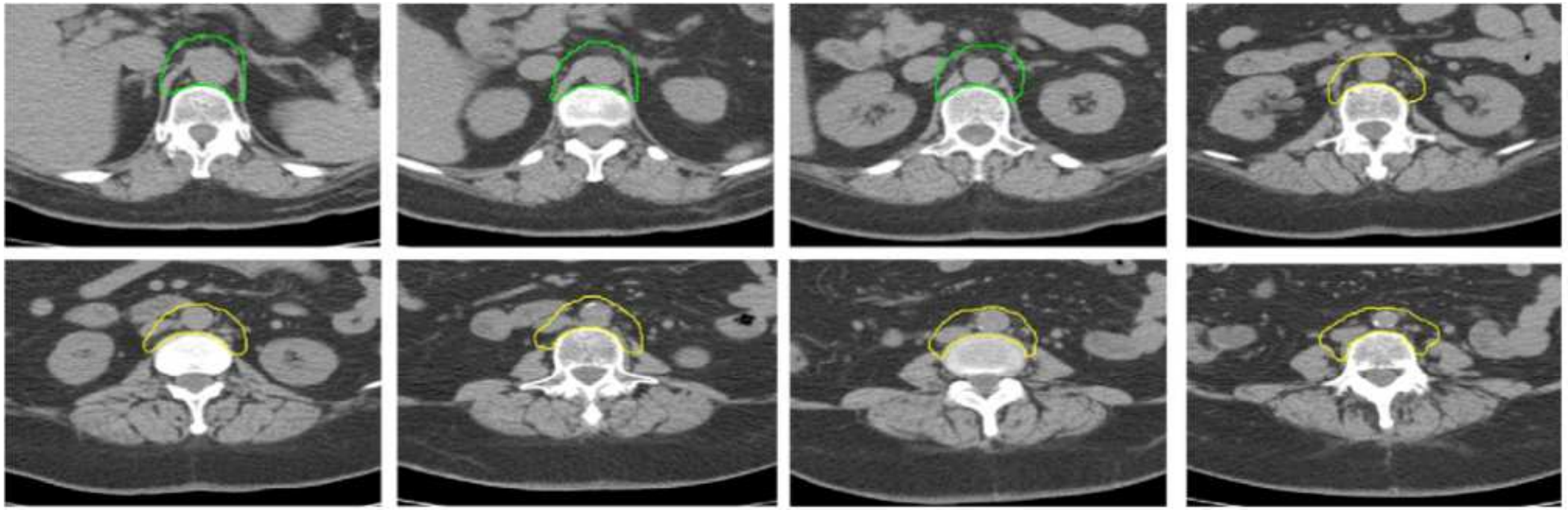

Non-uniform margins: larger margin to the left of the aorta, The contour should broaden to cover the region to the right of the IVC as it approaches the bifurcation.

ESTRO School

3) CTV DELINEATION FOR **POST-OPERATIVE**

CONSENSUS GUIDELINES FOR DELINEATION OF CLINICAL TARGET VOLUME FOR INTENSITY-MODULATED PELVIC RADIOTHERAPY IN POSTOPERATIVE TREATMENT OF ENDOMETRIAL AND CERVICAL CANCER

William Small, Jr., M.D.,* Loren K. Mell, M.D.,† Penny Anderson, M.D.,‡ Carien Creutzberg, M.D.,§ Jennifer De Los Santos, M.D.,¶ David Gaffney, M.D., Ph.D.,‖ Anuja Jhingran, M.D.,# Lorraine Portelance, M.D.,** Tracey Schefter, M.D.,†† Revathy Iyer, M.D.,‡‡ Mahesh Varia, M.D.,§§ Kathryn Winter, M.S.,¶¶ and Arno J. Mundt, M.D.‖‖

*Department of Radiation Oncology, Robert H. Lurie Comprehensive Cancer Center, Northwestern University, Chicago, IL; †Department of Radiation and Cellular Oncology, University of Chicago Pritzker School of Medicine, Chicago, IL; ‡Department of Radiation Oncology, Fox Chase Cancer Center, Philadelphia, PA; §Department of Clinical Oncology, Leiden University Medical Center, Leiden, The Netherlands; ¶Department of Radiation Oncology, University of Alabama at Birmingham, Birmingham, AL; ‖Department of Radiation Oncology, Huntsman Cancer Institute, University of Utah, Salt Lake City, UT; #Department of Radiation Oncology, M.D. Anderson Cancer Center, Houston, TX; **Department of Radiation Oncology, McGill University Health Center, Quebec, ON, Canada; ††Department of Radiation Oncology, University of Colorado, Aurora, CO; ‡‡Department of Radiology, M.D. Anderson Cancer Center, Houston, TX; §§Department of Radiation Oncology, University of North Carolina, Chapel Hill, NC; ¶¶Statistical Section, Radiation Therapy Oncology Group, Philadelphia, PA; and ‖‖Department of Radiation Oncology, University of California, San Diego, School of Medicine, La Jolla, CA

- Critical use of IMRT of a standard option for post-operative therapy for endometrial and cervical cancer RTOG 0418 Atlas
- Primary objective: determine the transportability of IMRT to a multi-institucional setting

ESTRO School

3) CTV DELINEATION FOR **POST-OPERATIVE**

Table 1. Consensus clinical target volume for adjuvant (postoperative) radiotherapy for cervical and endometrial cancer

Target site	Definition
Common iliac lymph nodes	From 7 mm below L4–L5 interspace to level of bifurcation of common iliac arteries into external and internal iliac arteries
External iliac lymph nodes	From level of bifurcation of common iliac artery into external artery to level of superior aspect of femoral head where it becomes femoral artery
Internal iliac lymph nodes	From level of bifurcation of common iliac artery into internal artery, along its branches (obturator, hypogastric) terminating in paravaginal tissues at level of vaginal cuff
Upper vagina	Vaginal cuff and 3 cm of vagina inferior to cuff
Parametrial/paravaginal tissue	From vaginal cuff to medial edge of internal obturator muscle/ischial ramus on each side
Presacral lymph nodes*	Lymph node region anterior to S1and S2 region

* If patient has cervical cancer or endometrial cancer with cervical stromal invasion.

- The committee achieved a consensus CTV definition
- The CTV should include the common, external, and internal iliac lymph node regions
- The CTV should be extended to include any adjacent visible or suspicious lymph nodes, lymphoceles, and pertinent surgical clips

Taylor, A., et al. 2007

ESTRO School

3) CTV DELINEATION FOR **POST-OPERATIVE**

CTV

Inferior extent of vaginal cuff can be identified by **vaginal marker**

The **vaginal cuff tissue** frequently extends superiorly, (should be included in the CTV)

Generally, the tissue to be included above the vaginal marker is ***0.5–2 cm****.*

ESTRO School

3) CTV DELINEATION FOR **POST-OPERATIVE**

CTV

The rectum, bladder, bone, and muscle should be excluded from the CTV.

When the vaginal cuff becomes visible, this volume can be conjoined with the two converging perivascular ("nodal") volumes to make a single CTV

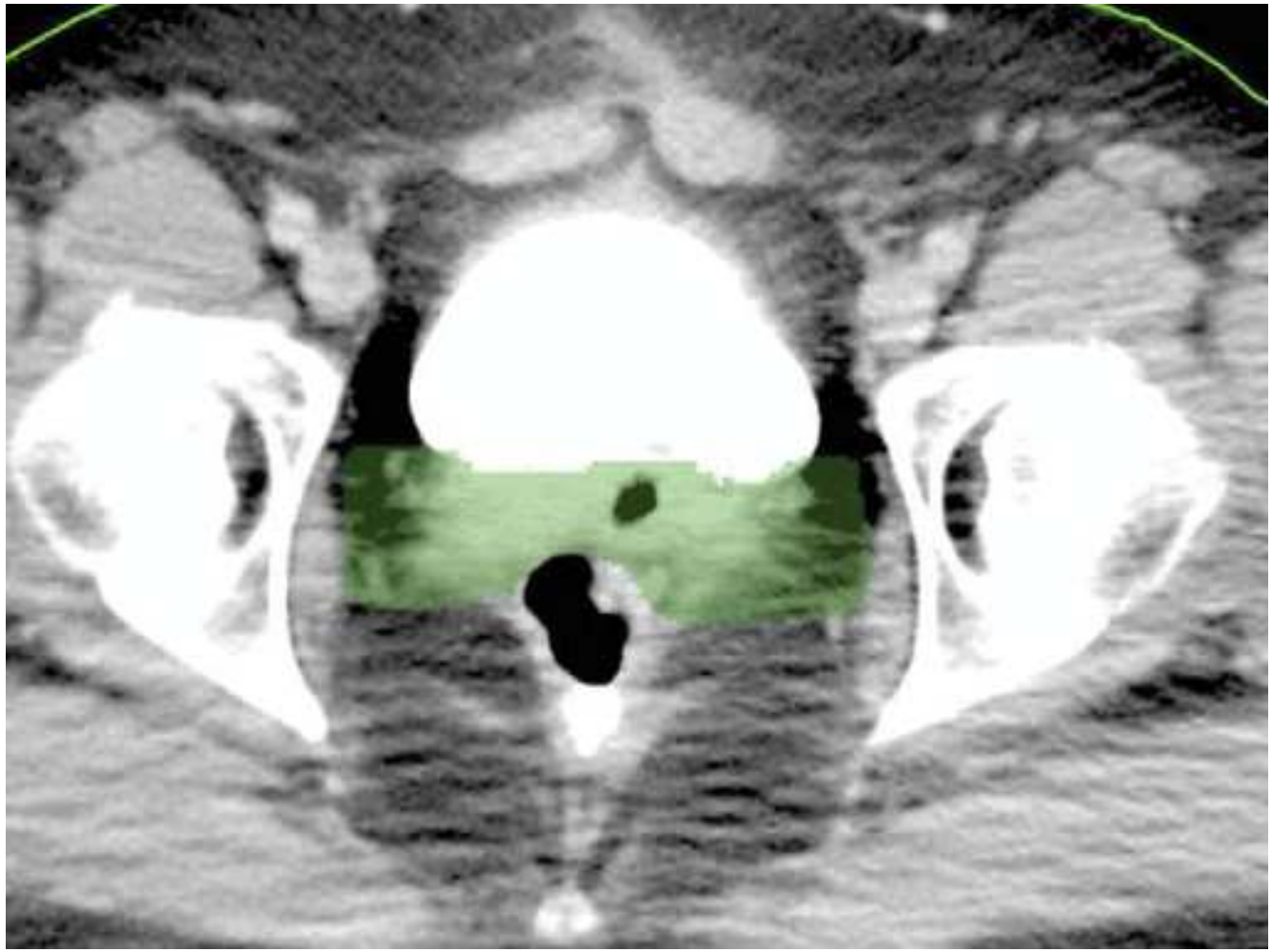

ESTRO School

3) CTV DELINEATION FOR **POST-OPERATIVE**

CTV

CTV should include the vagina and parametrial (approximately 0.5 cm) margin that can extend into the perivesicular or perirectal fat

The CTV should end 3.0 cm below the vaginal marker, or 1.0 cm above the bottom of the obturator foramen (whichever is most inferior)

ESTRO School

3) CTV DELINEATION FOR **POST-OPERATIVE**

CTV

If cervical cancer, or endometrial cancer with cervical stromal invasion, it was also recommended that the CTV include the **presacral lymph** node region

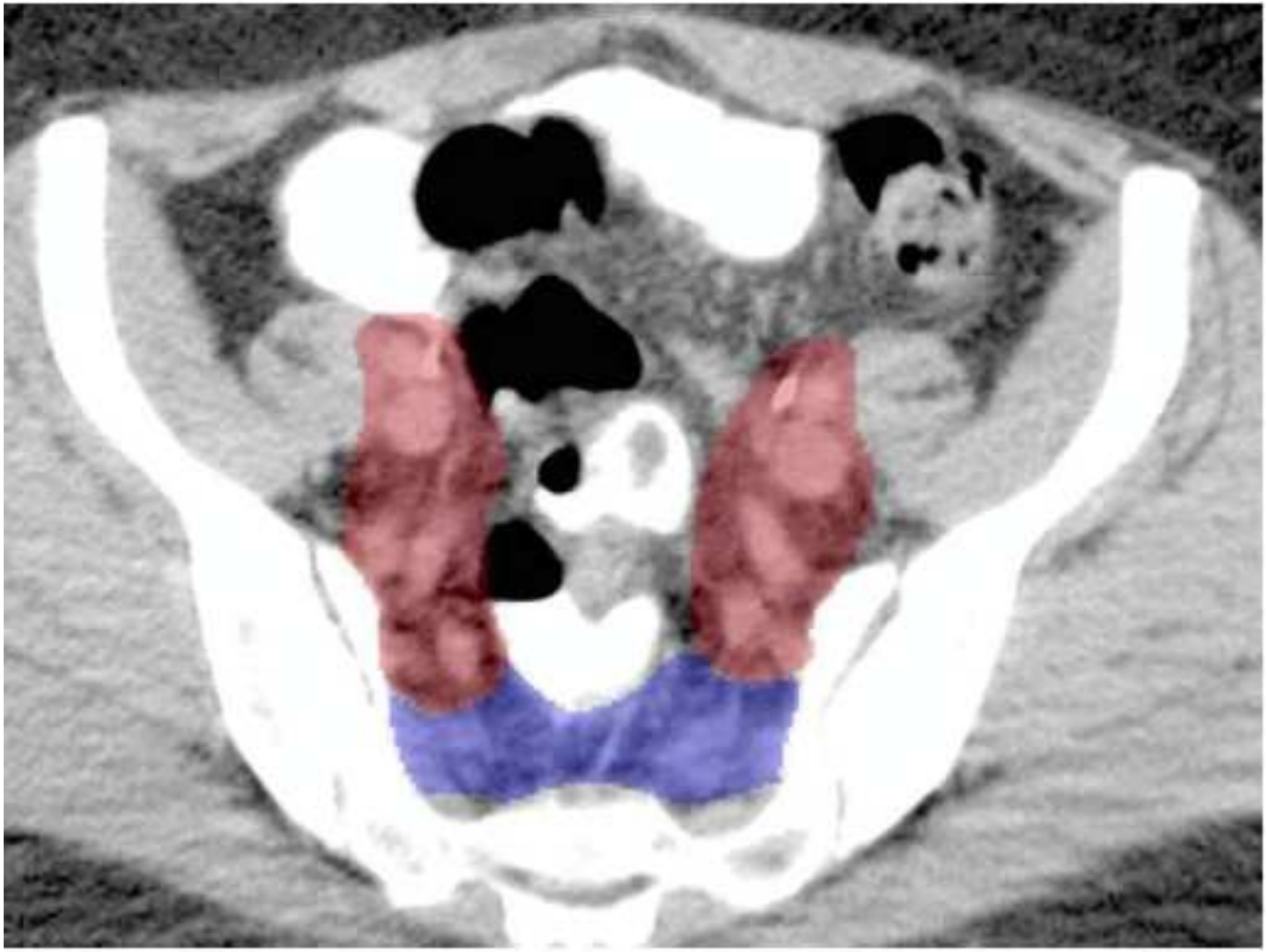

Lymph node region anterior to S1 and S2 region

ESTRO School

4) **CTV** FOR INTACT CARCINOMA OF THE CERVIX

- Combination of macroscopic tumor (primary and lymph node metastases) and a large elective area (uterus, parametria, vagina, lympatics)
- Internal motion of primary tumor and organs at risk
- Tumor regression during treatment
- Large difference between tolerance dose to organs at risk (small bowel) and required dose to GTV

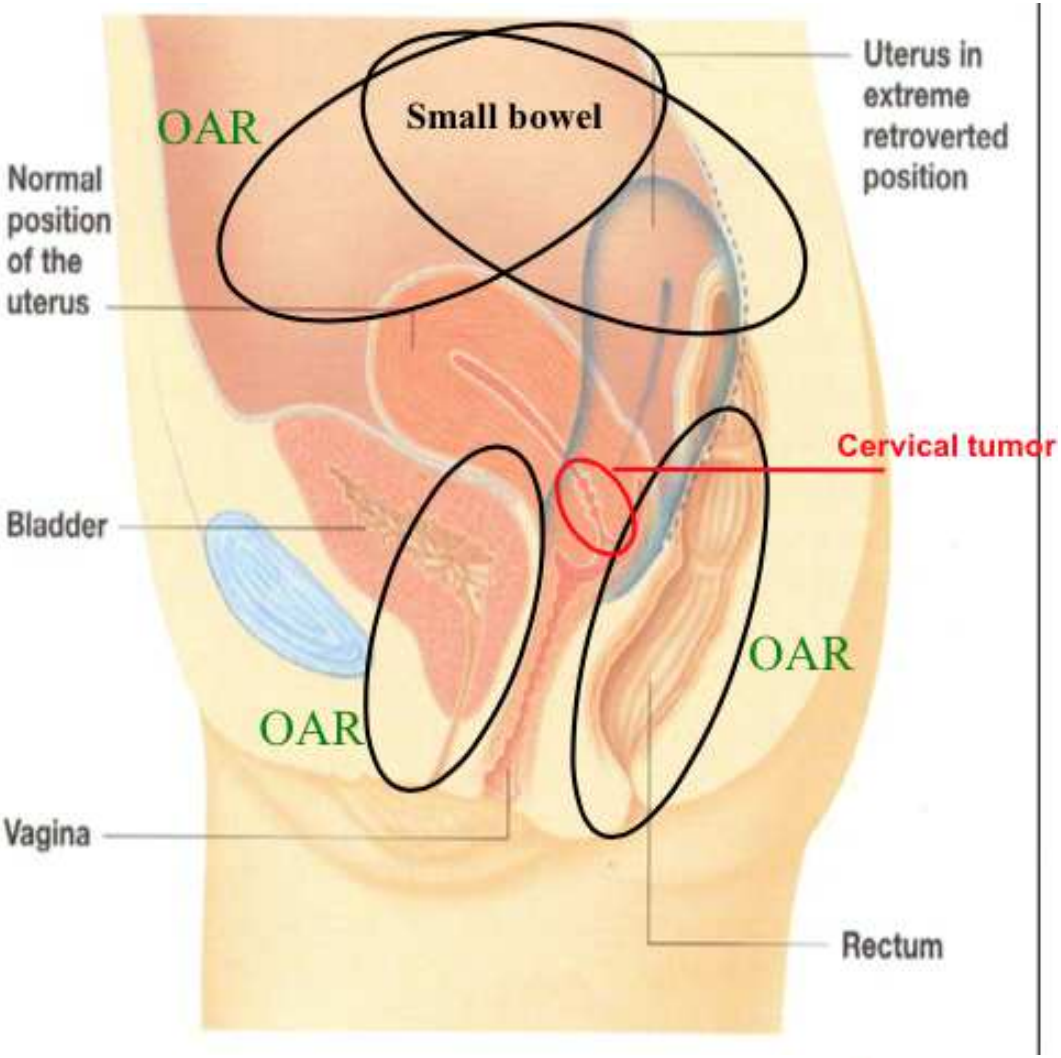

ESTRO School

1) **CTV** FOR INTACT CARCINOMA OF THE CERVIX

In general

- GTV + parametria, uterus, vagina, ovaries
- Affected lymphnodes and draining lymphatics

Tumor stage related

- FIGO I, II and IIIB
  - GTV + parametria, uterus, ovaries, upper part of vagina
- FIGO IIIA
  - Lower part of vagina additionally
- FIGO IVA
  - Involved organ(s) additionally

ESTRO School

4) **CTV** FOR INTACT CARCINOMA OF THE CERVIX

CLINICAL INVESTIGATION Cervix

CONSENSUS GUIDELINES FOR DELINEATION OF CLINICAL TARGET VOLUME FOR INTENSITY-MODULATED PELVIC RADIOTHERAPY FOR THE DEFINITIVE TREATMENT OF CERVIX CANCER

KAREN LIM, M.B.B.S.,* WILLIAM SMALL, JR., M.D.,[y] LORRAINE PORTELANCE, M.D.,[z] CARIEN CREUTZBERG, M.D., PH.D.,[x] INA M. JÜRGENLIEMK-SCHULZ, M.D., PH.D.,[k] ARNO MUNDT, M.D.,[{] LOREN K. MELL, M.D.,[{] NINA MAYR, M.D.,** AKILA VISWANATHAN, M.D.,[yy] ANUJA JHINGRAN, M.D.,[zz] BETH ERICKSON, M.D.,[xx] JENNIFER DE LOS SANTOS, M.D.,[kk] DAVID GAFFNEY, M.D., PH.D.,[{{] CATHERYN YASHAR, M.D.,[{] SUSHIL BERIWAL, M.D.,*** AARON WOLFSON, M.D.,[yyy] ALEXANDRA TAYLOR, F.R.C.R.,[zzz] WALTER BOSCH, PH.D.,[xxx] ISSAM EL NAQA, PH.D.,[xxx] AND ANTHONY FYLES, M.D. * FOR THE GYN IMRT CONSORTIUM.

- High amount of organ motion, tumor regression, and deformation in cervix cancer patients
- 16 members from the Consortium were surveyed for delineation consensus
- 19 experts in in gynecological radiation oncology generated contours on pelvis MRI

ESTRO School

4) **CTV** FOR INTACT CARCINOMA OF THE CERVIX

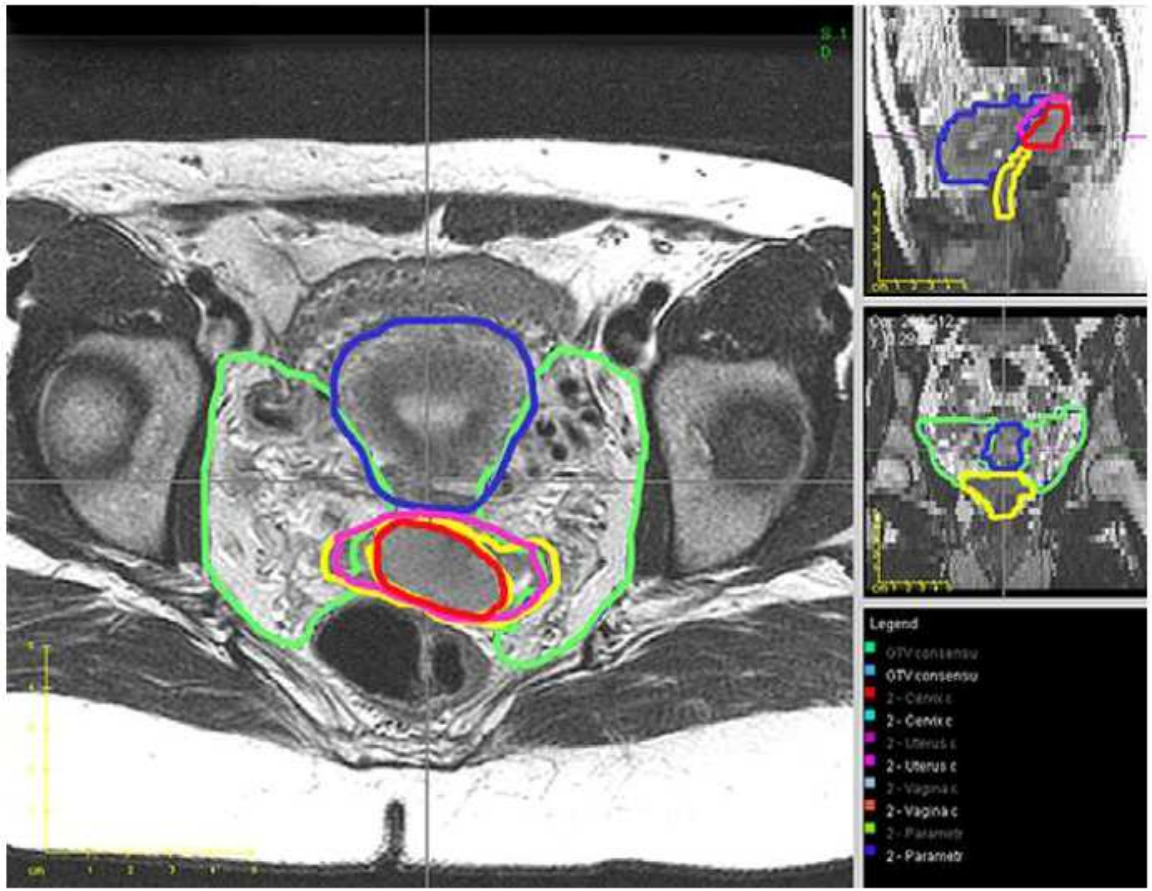

- Agreement sensibility in GTV contour
- Moderate agreement in delineation of cervix, uterus, vagina and parametria

K. Lim et al. 2011

ESTRO School

4) **CTV** FOR INTACT CARCINOMA OF THE CERVIX

GTV

Entire GTV; intermediate/high signal seen on T2-weighted MR images

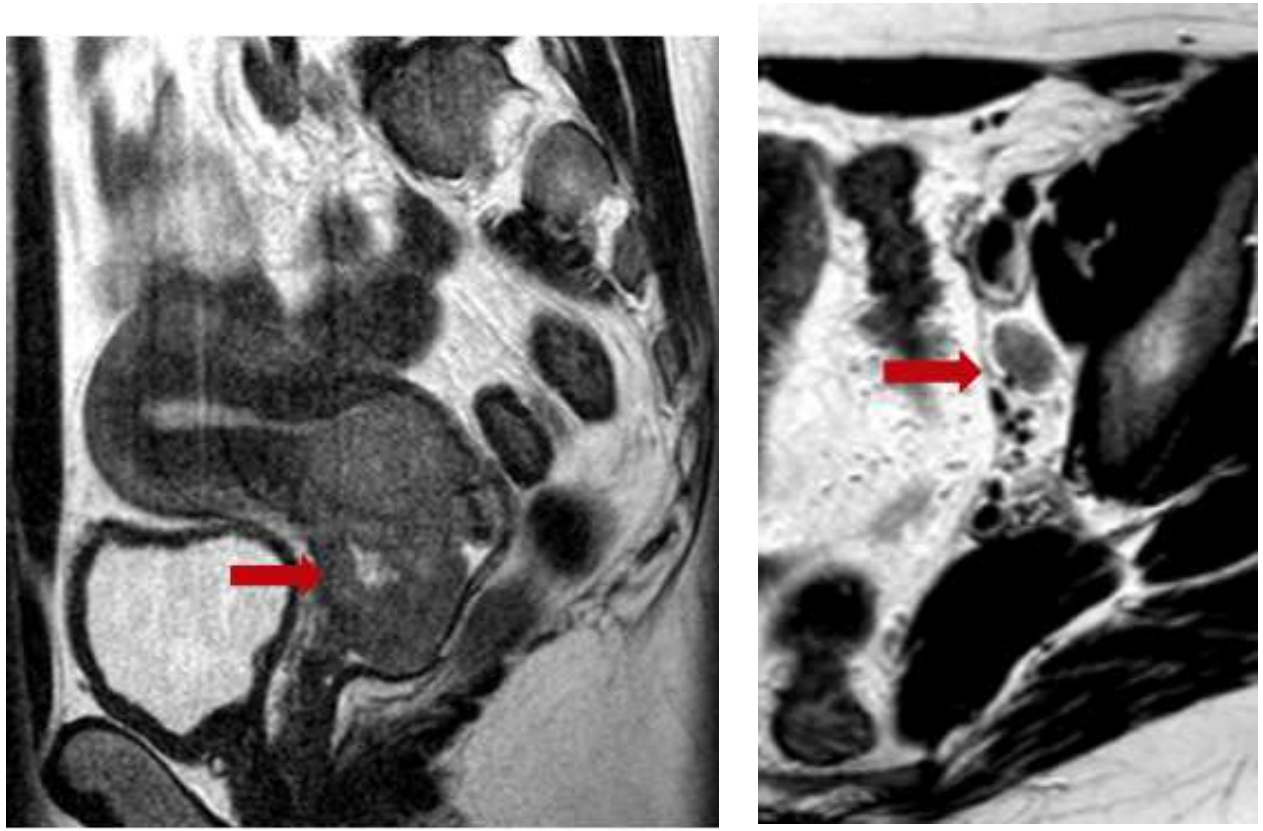

K. Lim et al. 2011

CERVIX

Entire cervix; *if not already included within GTV contour*

ESTRO School

4) **CTV** FOR INTACT CARCINOMA OF THE CERVIX

UTERUS

Entire UTERUS should be included in the CTV

Reasons for including entire uterus:

- *Uterus and cervix are embryologically one unit*
- *No clear separating fascial plane*
- *Myometrial invasion radiologically or clinically can be difficult*
- *Recurrence rates after radical trachelectomy (up to 10%) for tumor > 2 cm or with LVI*

Infiltration into upper uterine segment

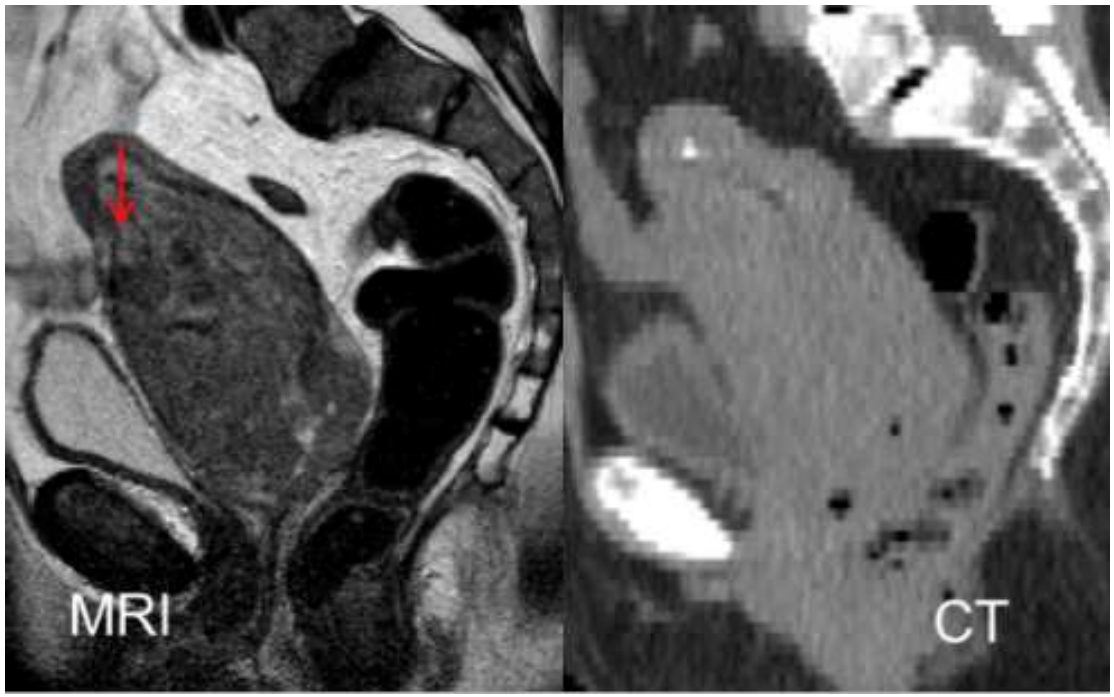

K. Lim et al. 2011

ESTRO School

4) **CTV** FOR INTACT CARCINOMA OF THE CERVIX

PARAMETRIUM

Entire parametrium, including ovaries;

Entire mesorectum if uterosacral ligament involved

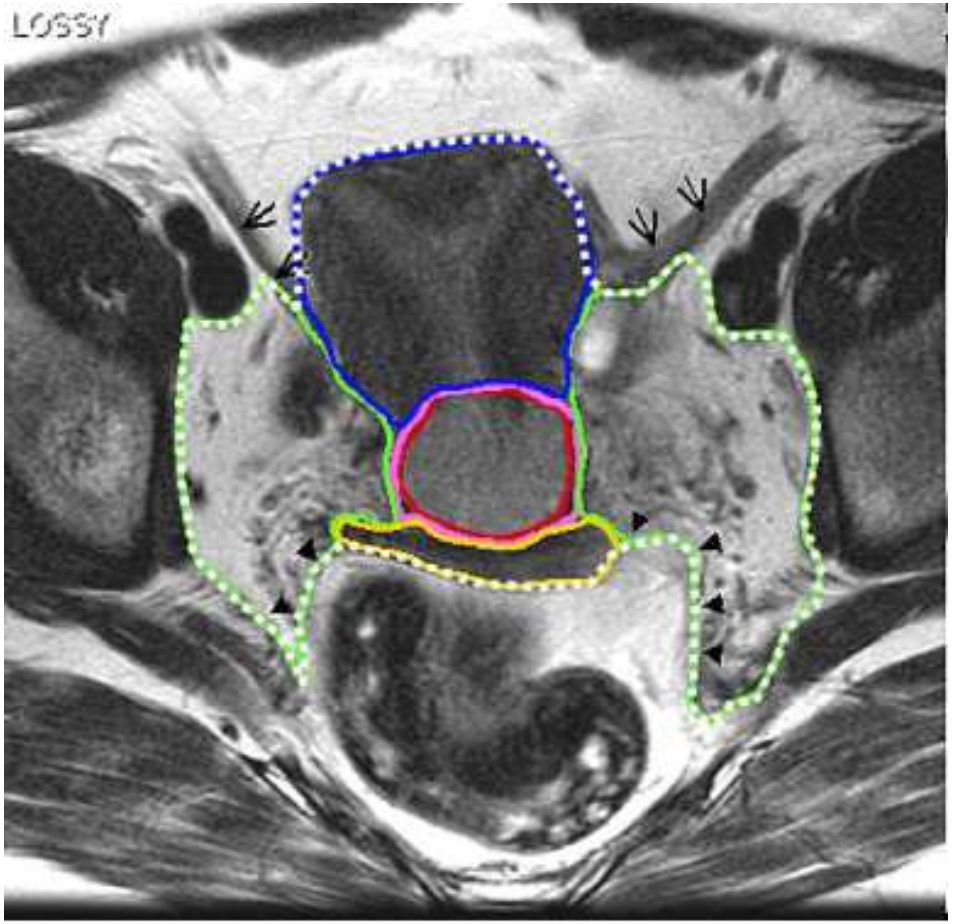

K. Lim et al. 2011

ESTRO School

4) **CTV** FOR INTACT CARCINOMA OF THE CERVIX

PARAMETRIUM

Table 3. Anatomical boundaries of parametria

Location	Anatomic structures
Anteriorly	Posterior wall of bladder or posterior border of external iliac vessel
Posteriorly	Uterosacral ligaments and mesorectal fascia
Laterally	Medial edge of internal obturator muscle/ ischial ramus bilaterally
Superiorly	Top of fallopian tube/ broad ligament. Depending on degree of uterus flexion, this may also form the anterior boundary of parametrial tissue.
Inferiorly	Urogenital diaphragm

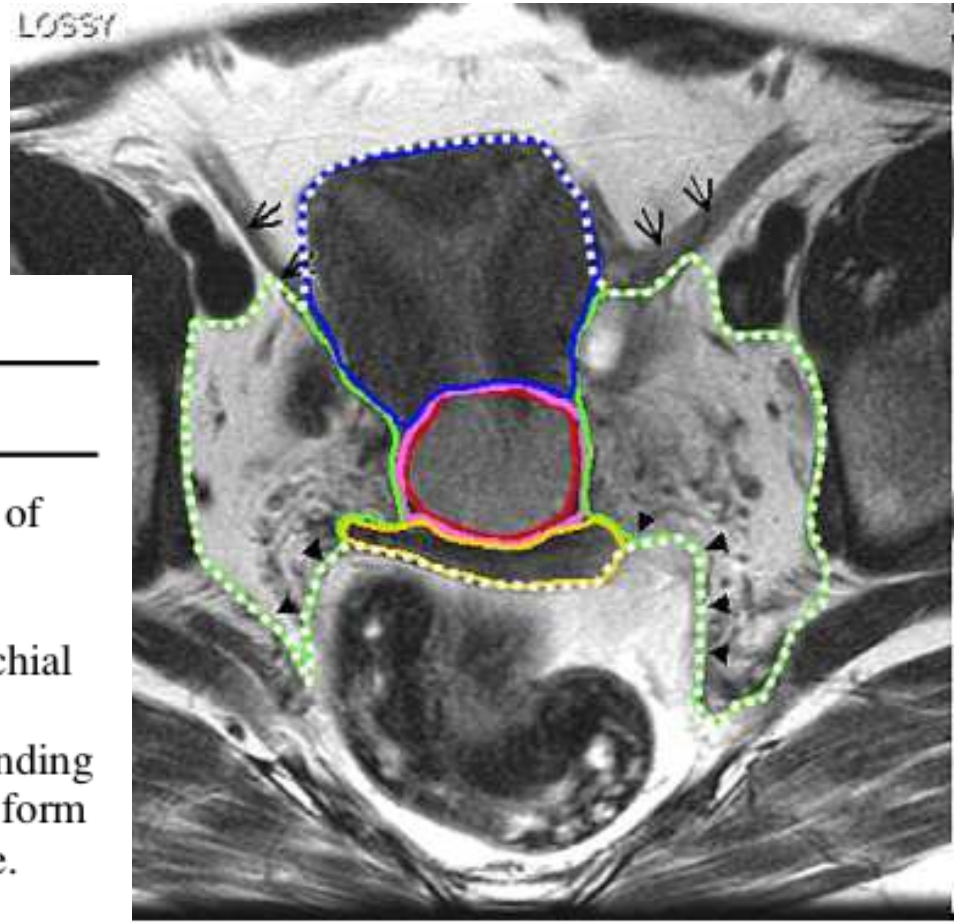

K. Lim et al. 2011

ESTRO School

4) **CTV** FOR INTACT CARCINOMA OF THE CERVIX

PARAMETRIUM

Table 3. Anatomical boundaries of parametria

Location	Anatomic structures
Anteriorly	Posterior wall of bladder or posterior border of external iliac vessel
Posteriorly	Uterosacral ligaments and mesorectal fascia
Laterally	Medial edge of internal obturator muscle/ ischial ramus bilaterally
Superiorly	Top of fallopian tube/ broad ligament. Depending on degree of uterus flexion, this may also form the anterior boundary of parametrial tissue.
Inferiorly	Urogenital diaphragm

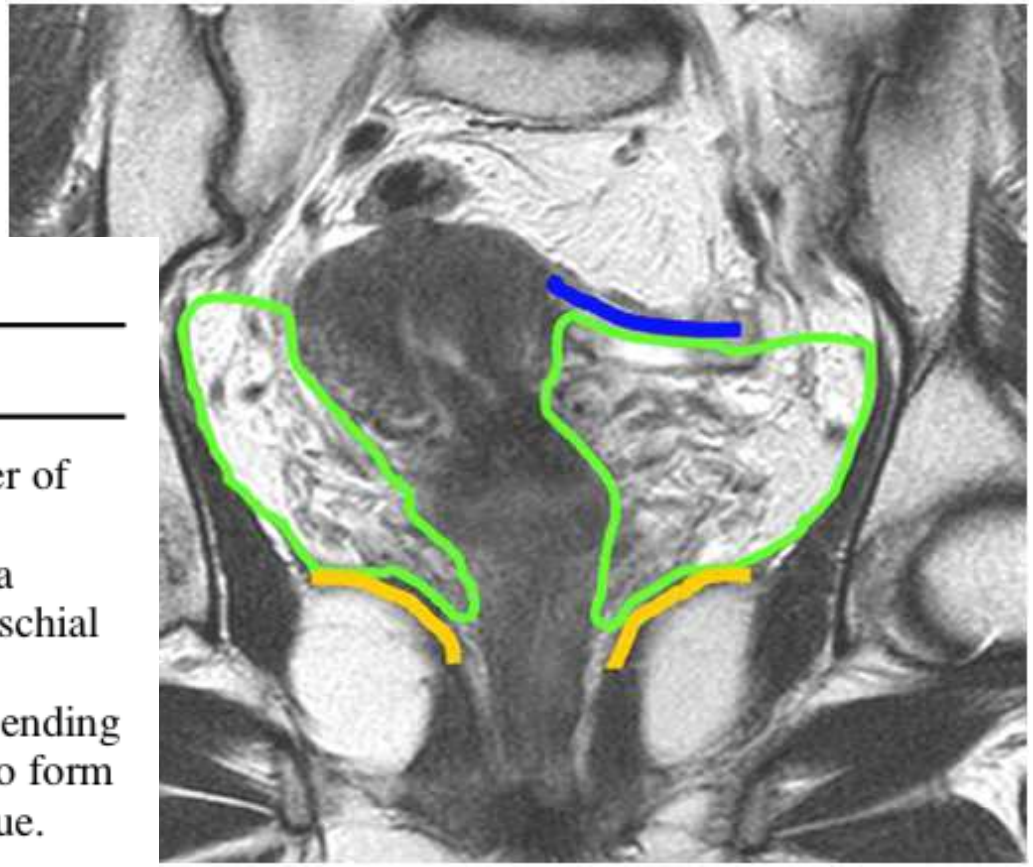

K. Lim et al. 2011

ESTRO School

4) **CTV** FOR INTACT CARCINOMA OF THE CERVIX

VAGINA

- **Minimal or no vaginal extension:** upper half of the vagina
- **Upper vaginal involvement:** upper two-thirds of the vagina
- **Extensive vaginal involvement:** entire vagina

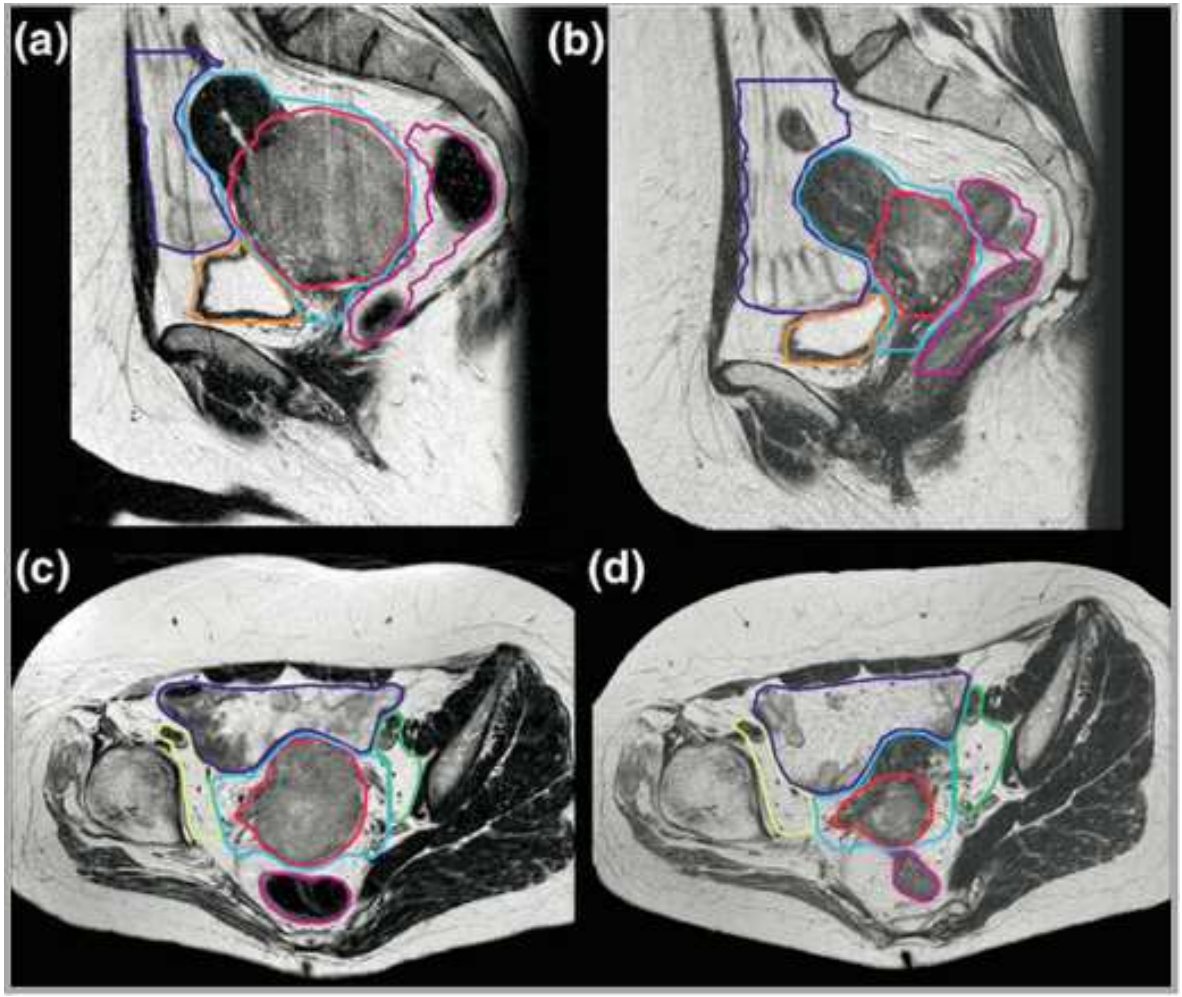

K. Lim et al. 2011

ESTRO School

4) **CTV** FOR INTACT CARCINOMA OF THE CERVIX

- **Reason to include adjacent organ**

  - If organ wall is infiltrated chance on microscopic spread

- **Reason to include mesorectum**

  - If mesorectal fascia infiltrated chance of microscopic spread in whole mesorectum

- **Reason to include whole vagina**

  - If more than half vagina is infiltrated chance of distal submucosal extension

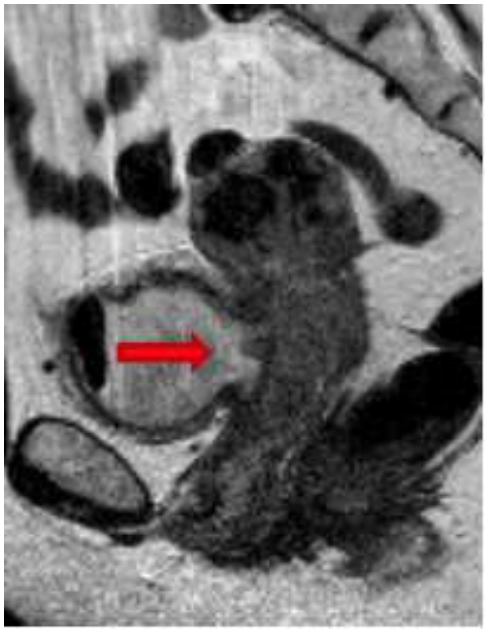

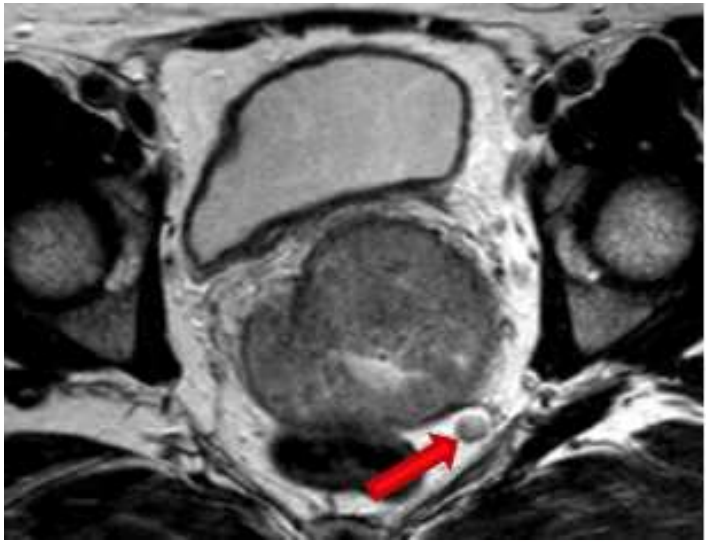

4) **CTV** FOR INTACT CARCINOMA OF THE CERVIX

A Consensus-based Guideline Defining Clinical Target Volume for Primary Disease in External Beam Radiotherapy for Intact Uterine Cervical Cancer

Takafumi Toita[1,*], Tatsuya Ohno[2], Yuko Kaneyasu[3], Tomoyasu Kato[4], Takashi Uno[5], Kazuo Hatano[6], Yoshiki Norihisa[7], Takahiro Kasamatsu[4], Takeshi Kodaira[8], Ryoichi Yoshimura[9,10], Satoshi Ishikura[11] and Masahiro Hiraoka[7] for the JCOG Radiation Therapy Study Group

- To develop a consensus-based guideline to define clinical target volume
- The group consisted of 10 radiation oncologists and 2 gynecologic oncologists.
- Comprehensive literature review that included primary research articles and textbooks as well as information on surgical procedures

ESTRO School

4) **CTV** FOR INTACT CARCINOMA OF THE CERVIX

GTV

Entire GTV; intermediate/high signal seen on T2-weighted MR images

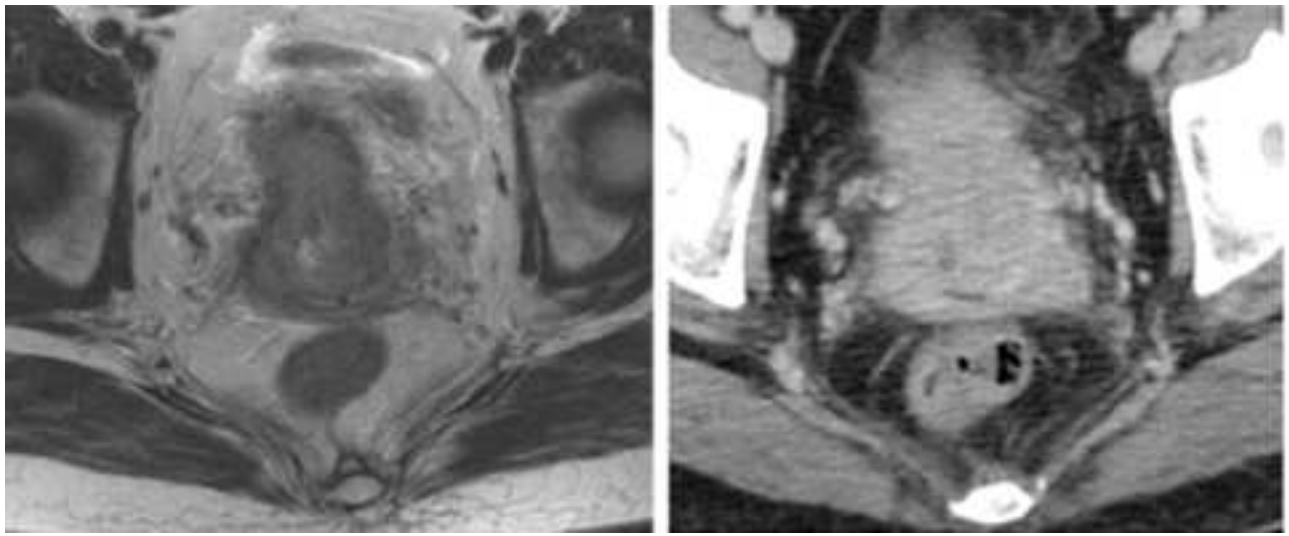

CERVIX

Entire cervix; *if not already included within GTV contour*

The cranial margin is defined at the level at which the uterine arteries enter the uterus (same level of the superior border of the parametrium CTV).

T. Toita et al. 2011

ESTRO School

4) **CTV** FOR INTACT CARCINOMA OF THE CERVIX

UTERUS

No CTV margin should be added to the visualized corpus on CT images

Reasons for <u>not</u> including entire uterus:

the majority of the uterine corpus is suspended within the pelvic cavity without surrounding the connective tissue

T. Toita et al. 2011

ESTRO School

4) **CTV** FOR INTACT CARCINOMA OF THE CERVIX

PARAMETRIUM

Table 1. Anatomical boundaries of clinical target volume for parametrium

Margin	Structures
Cranial	Isthmus of uterus (=level where uterine artery drains into)
	*Contouring would stop at the level where bowel loops are seen
Caudal	Medial boarder of levator ani (Fig. 5)
Anterior	Posterior boarder of bladder or posterior boarder of external iliac vessels
Posterior	Anterior part (semicircular) of mesorectal fascia
	*In case with bulky central tumor or significant parametrial invasion, some modification would be considered (Figs 3 and 4)
Lateral	Medial edge of internal obturator muscle, piriformis muscle, coccygeus muscle and ischial ramus

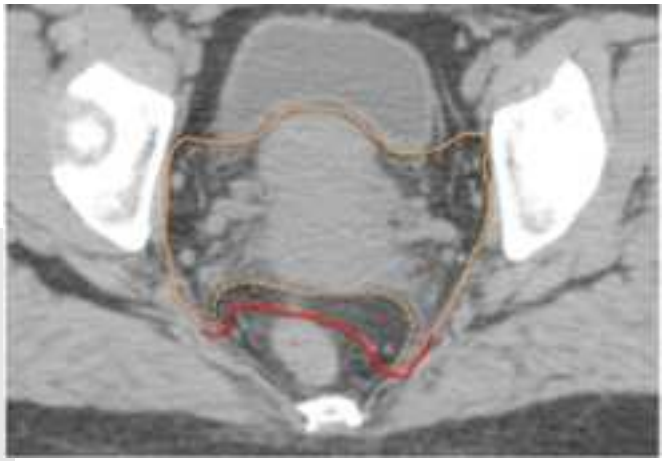

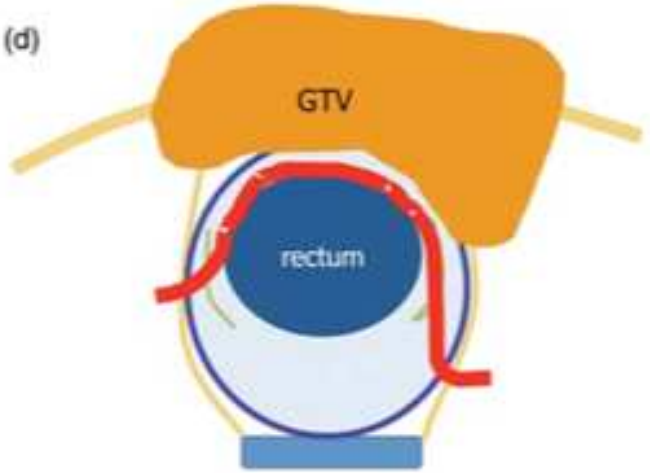

T. Toita et al. 2011

ESTRO School

4) **CTV** FOR INTACT CARCINOMA OF THE CERVIX

OVARY

Ovaries visible on the CT/MRI would be included.

A consensus was not reached regarding the possibility of excluding the ovaries in selected cases (i.e. non-bulky Stage I or II cases with squamous cell carcinoma)

Landoni et al: IA2 –IIA
SCC: 0,5%; ADC 2,4%

T. Toita et al. 2011

ESTRO School

5) **ITV** FOR INTACT CARCINOMA OF THE CERVIX

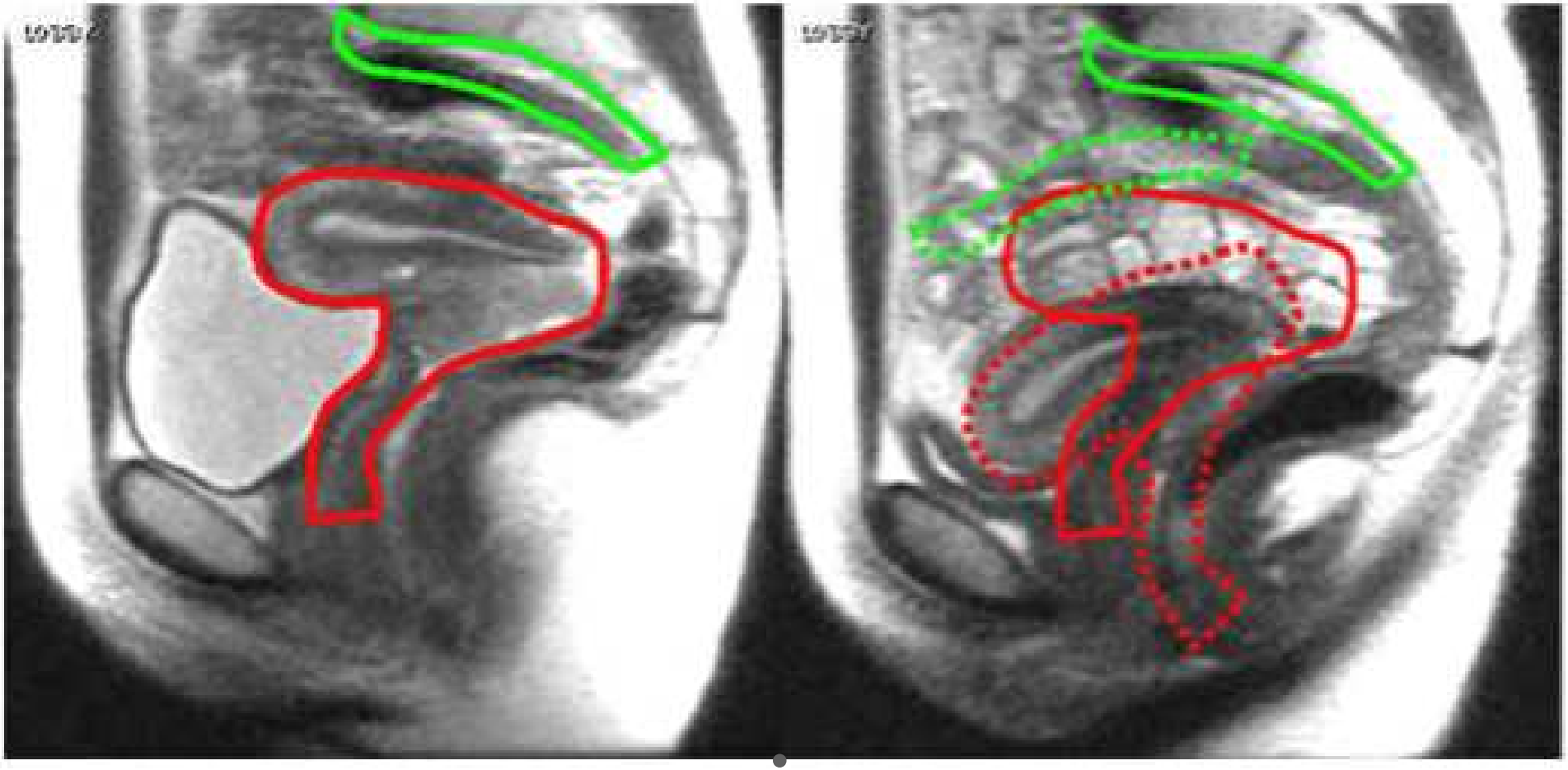

Different studies deal with internal motion, deformation and correlation with organ filling

ESTRO School

5) **ITV** FOR INTACT CARCINOMA OF THE CERVIX

INTERNAL MOBILITY OF TARGETS AND OAR

- 2 MR images, pre- and during EBRT
- Mobility of uterine corpus upwards 3-15 mm, cervix 1-6 mm
- Changes in cervico-uterine angle 0.1-67.8°

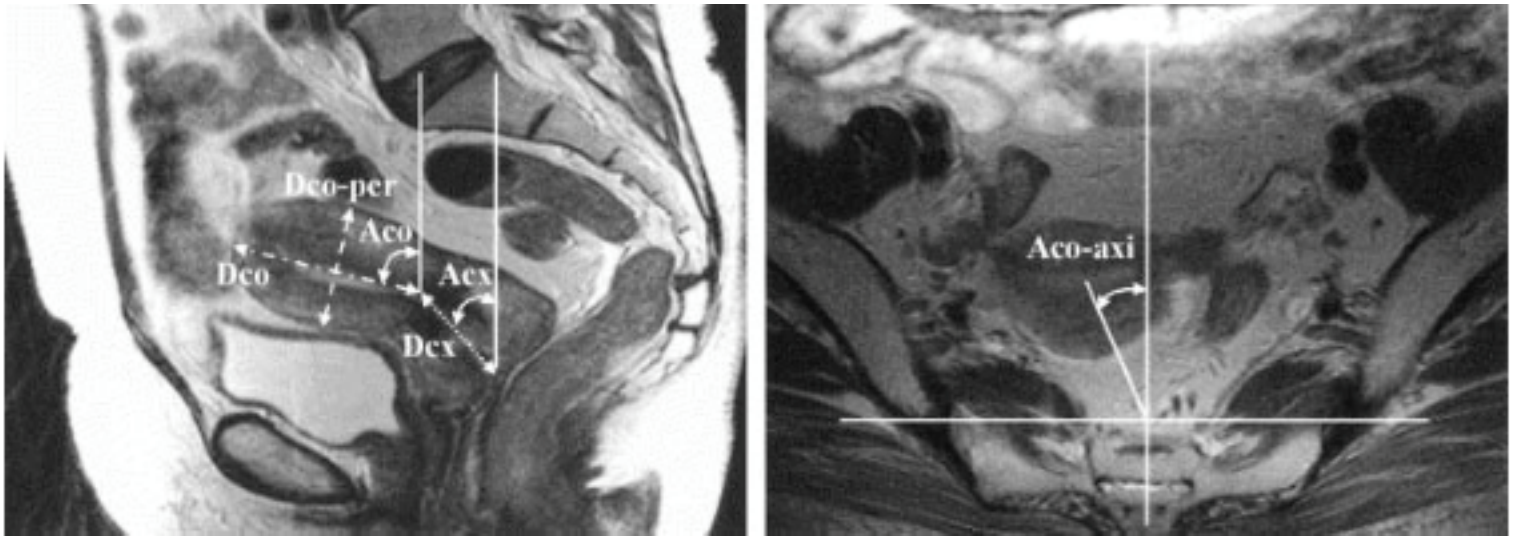

- Weak relation between bladder filling and organ dose
- No relation between rectum filling and organ dose

Buchali 1999, Huh 2004

ESTRO School

5) **ITV** FOR INTACT CARCINOMA OF THE CERVIX

BLADDER VOLUME CHANGES AND TARGET MOTION:

- Target position can be related to bladder filling
- Motion of the cervix-uterus due to bladder filling variations can be very large (up to 65 mm) or almost absent
- **Large individual differences**
- With drinking instructions still large mean systematic set-up errors (up to 30 mm)
- Variable bladder filling CT scans can predict target motion ranges

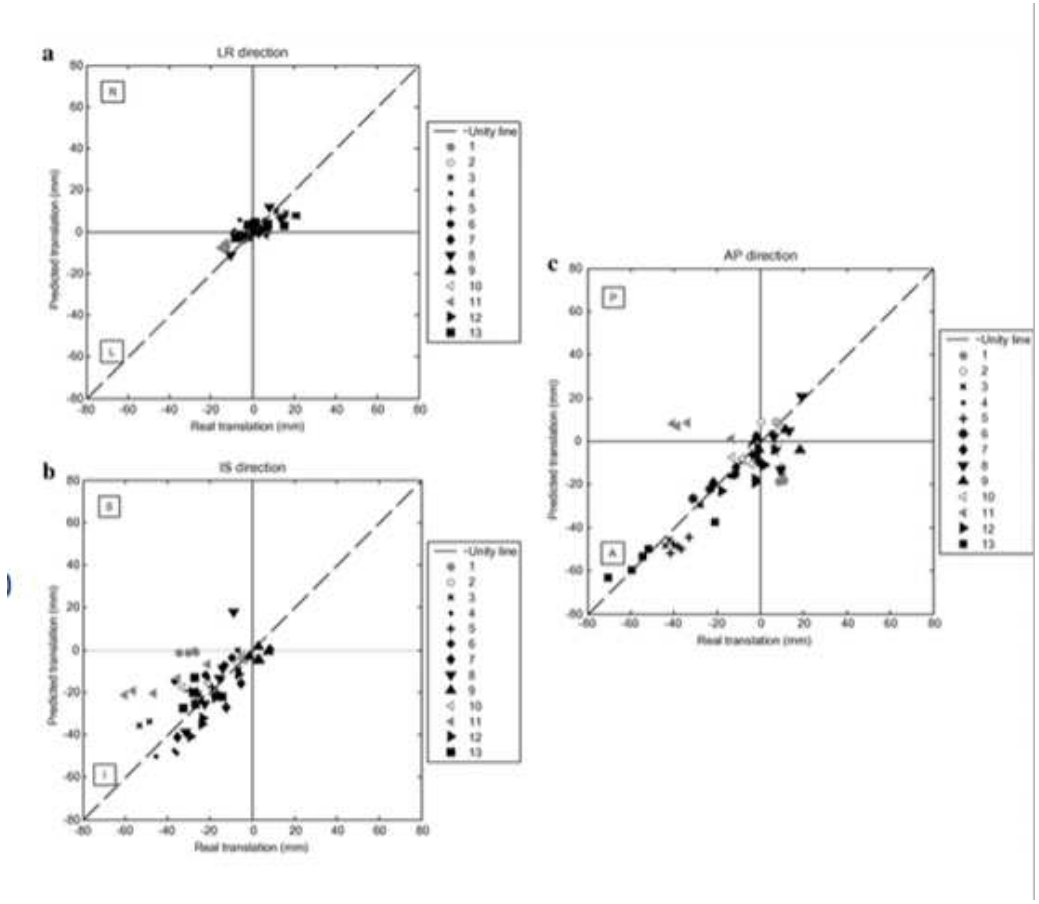

Taylor 2008

ESTRO School

5) ITV FOR INTACT CARCINOMA OF THE CERVIX

BLADDER/RECTAL VOLUME CHANGES UNDERSTANDING PATTERNS AND RECOMMENDED PATIENT PREPARATION:

- A bladder volume difference > 130cm^3 from planning ->PTV not covering the CTV
- Planning bladder > 300cm^3 were no reproductible during treatment
- The risk of the PTV not covering the CTV is higher if the rectum is larger during treatment planning
- Ideal Planning Bladder Volume of **150cm^3 – 300cm^3**
- Shorter waiting time on post-chemotherapy days
- Laxatives at planning and throughout treatment may also be beneficial

REGULAR IMAGING IS VITAL WHEN IMPLEMENTING ADVANCED RT TECHNIQUES IN GYNECOLOGY CANCER

Eminocwicz, 2016

ESTRO School

5) ITV FOR INTACT CARCINOMA OF THE CERVIX

INTER-FRACTION MOTION OF PRIMARY GTV:

- Extreme difference in bladder filling
- Extreme difference in position of the uterus
- 6 – 40 mm in different publications

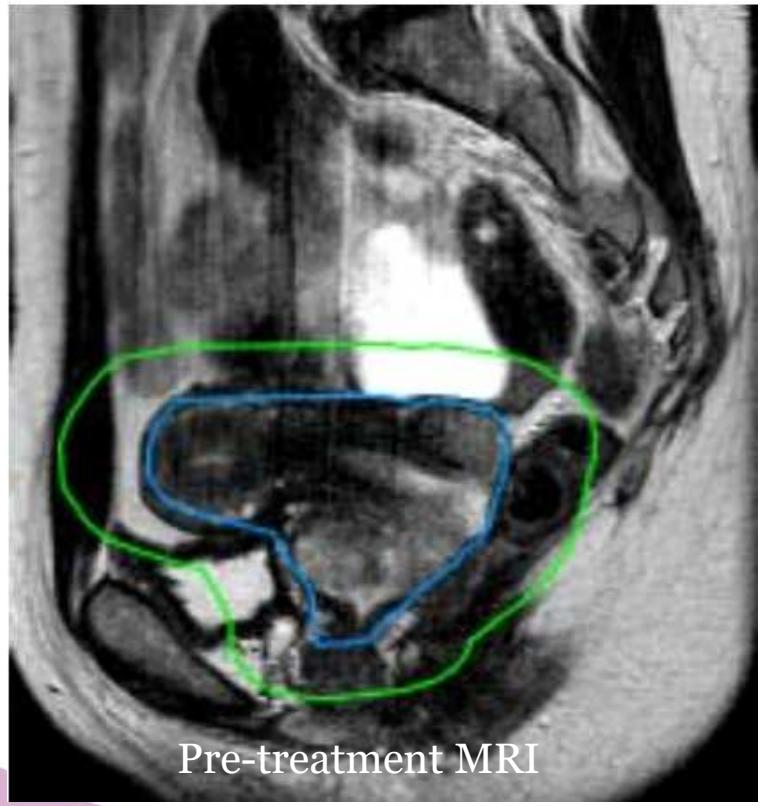
Pre-treatment MRI

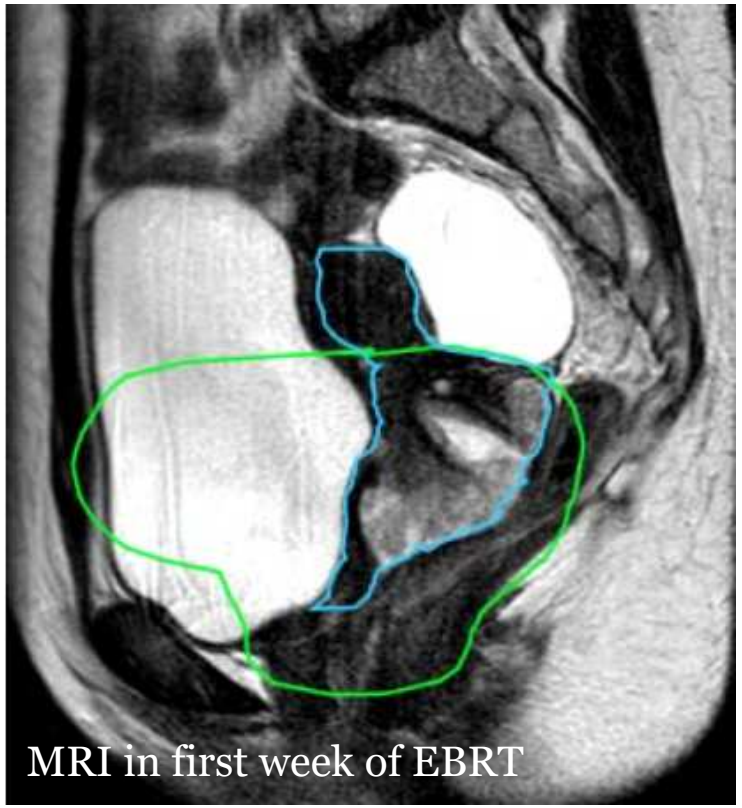
MRI in first week of EBRT

ESTRO School

5) ITV FOR INTACT CARCINOMA OF THE CERVIX

INTRA-FRACTION MOTION OF PRIMARY GTV:

Daily soft tissue registration:

- Midsagittal primary CTV can move considerably (≥10 mm)
- Significant weak relation with bladder filling
- Intra-fraction rigid registration of bony anatomy does not correct for this CTV motion
- Rigid soft tissue registration does correct with a maximum residual CTV motion of about 4.0 mm

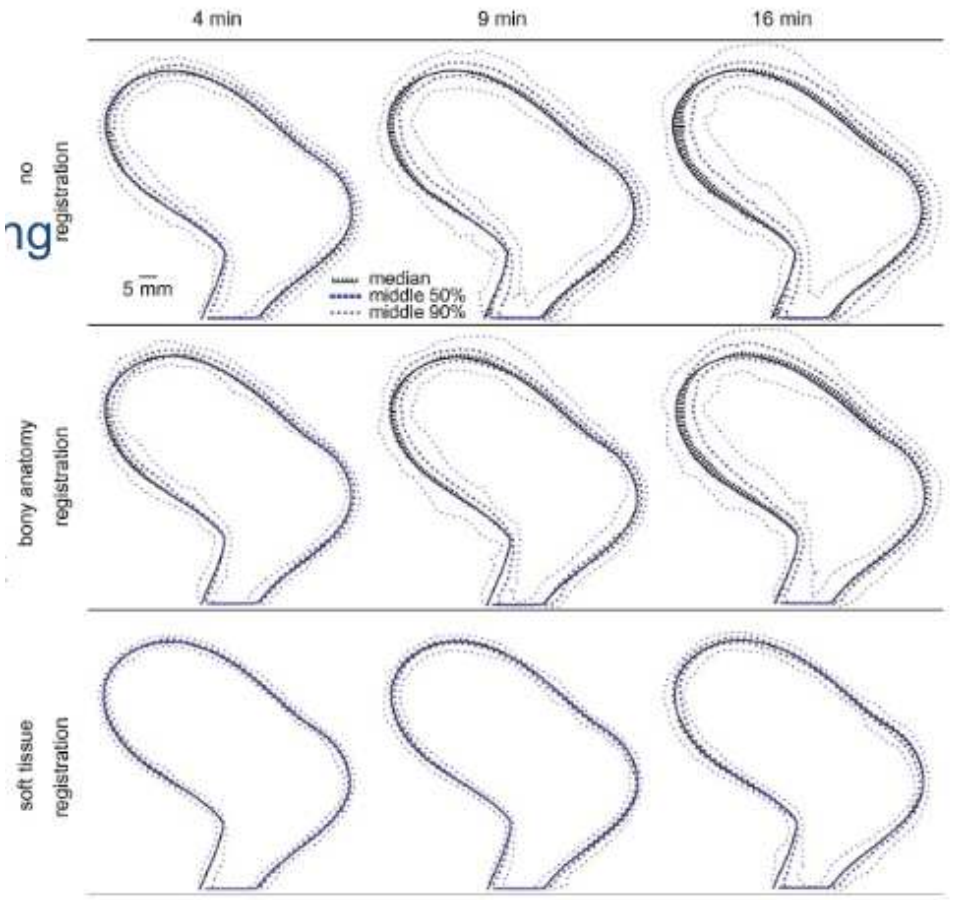

(Kerhof 2009)

ESTRO School

5) ITV FOR INTACT CARCINOMA OF THE CERVIX

INTRA-FRACTION MOTION OF <u>NODAL</u> GTV:

- Affected nodes also change their position
- Order of magnitude lower than for primary GTV (< 10 mm)

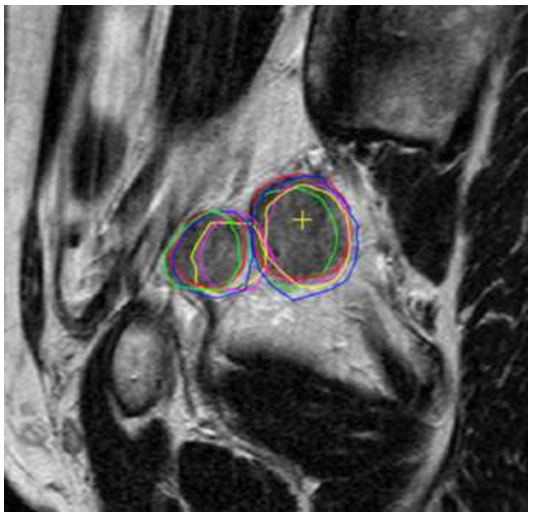

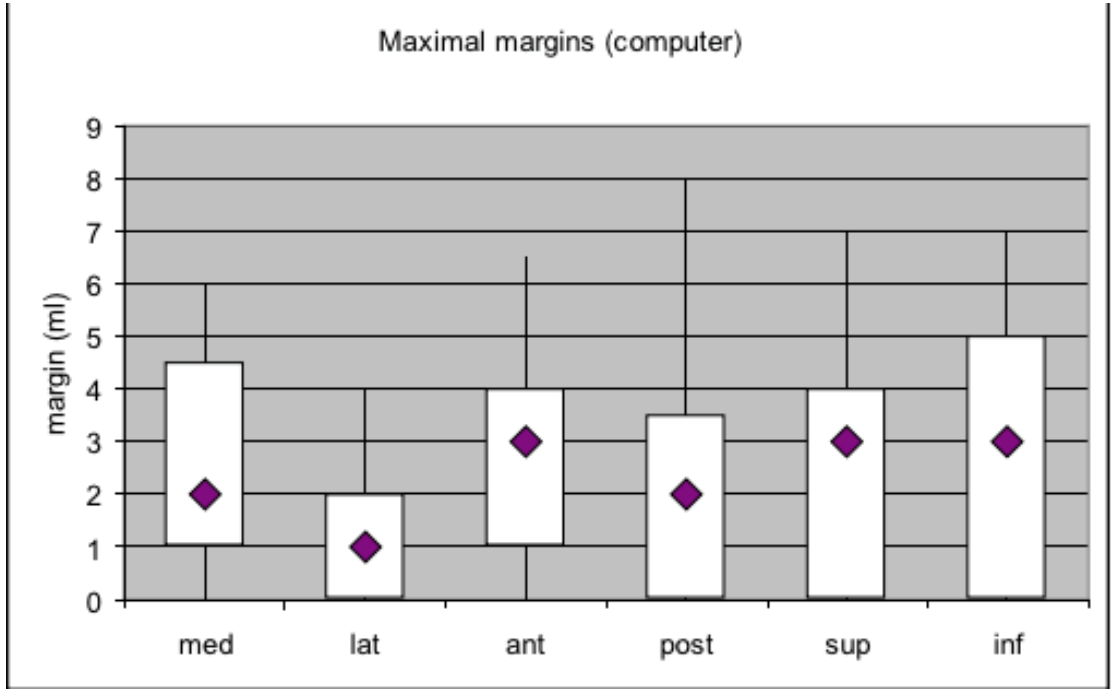

(Schippers 2011)

ESTRO School

5) ITV FOR INTACT CARCINOMA OF THE CERVIX

TUMOR REGRESSION = DEFORMATION

- Primary tumors individually shrink during EBRT
- Impact on elective CTV and PTV is low

Average decrease in volume after 30 Gy:

GTV	49,2%
CTV	13,4%
PTV	9,7%

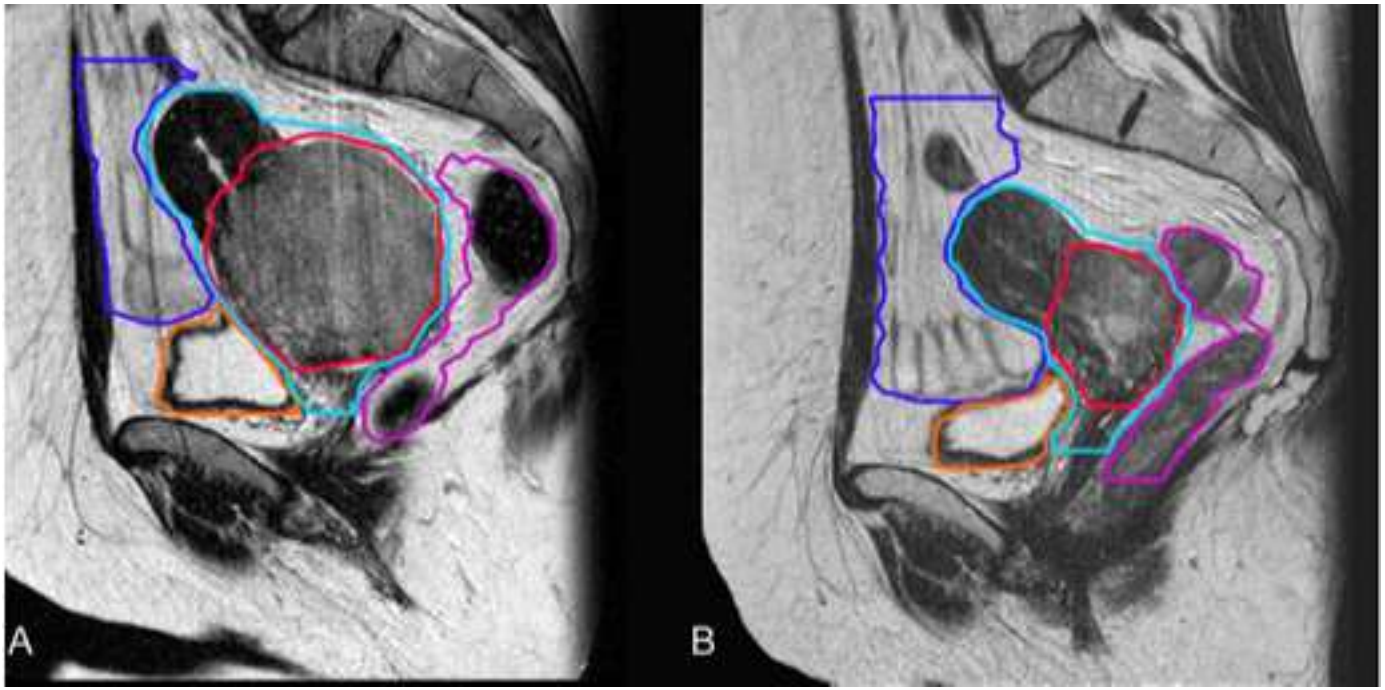

(van de Bunt 2006

)

ESTRO School

5) ITV FOR INTACT CARCINOMA OF THE CERVIX

TUMOR REGRESSION = DEFORMATION

- Adapting treatment after tumor regression
- Might contribute to organ sparing
- No clinical experience so far

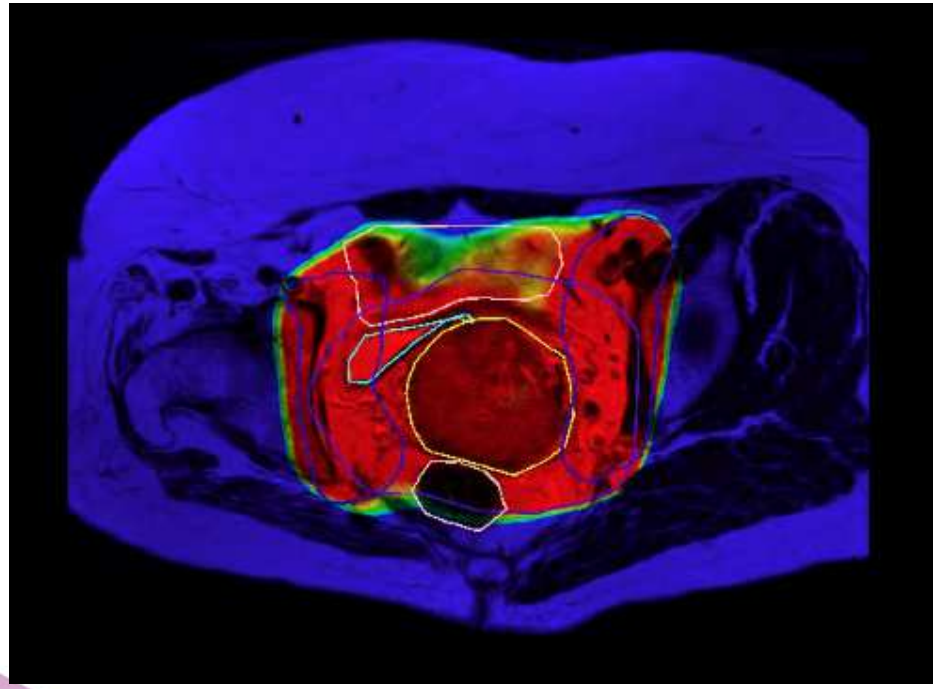

Initial IMRT

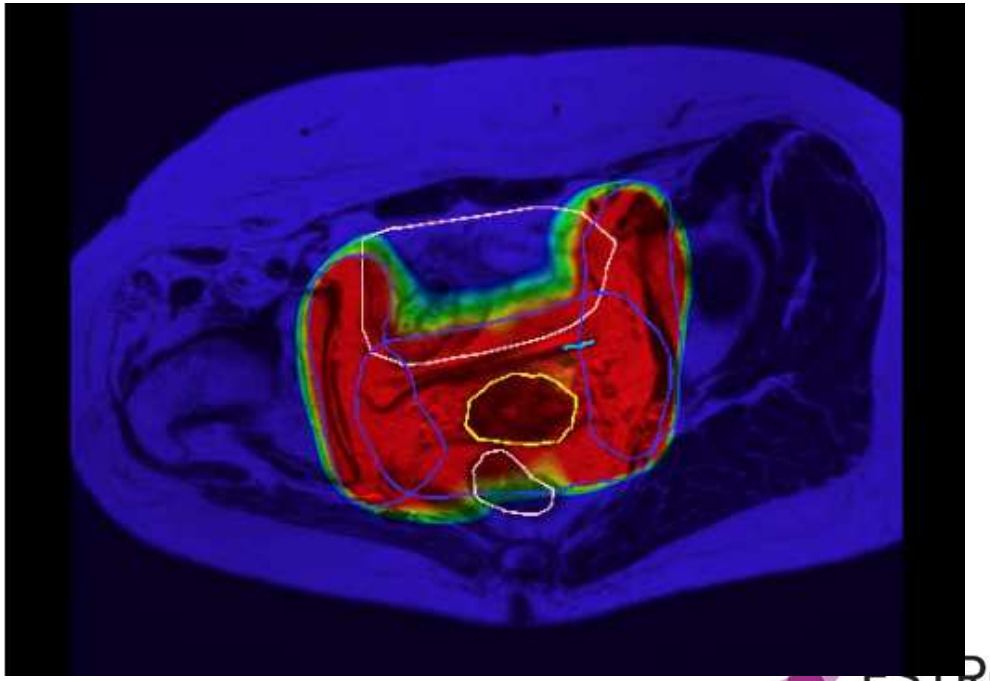

Adapted IMRT after 30Gy

ESTRO School

5) ITV FOR INTACT CARCINOMA OF THE CERVIX

Recommended CTV-PTV margins for conformal EBRT:

- Compensate internal motion and deformation and set-up errors
- For primary CTV 15 - 20 mm
- For nodal regions 7 - 10 mm
- Usually position verification on bony landmarks, off-line protocol
- So far no recommendations for CTV-ITV margins

ESTRO School

6) CTV DELINEATION FOR **3D-BRACHYTHERAPY**

ICRU 38 (1985
ICRU 58 (1997)

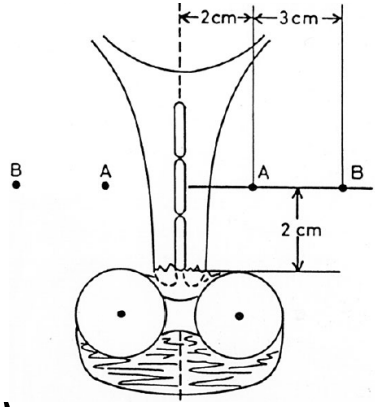

EMBRACE
study (2008)

GEC-ESTRO
recommendations
(2005-2012)

ICRU 89 (2016)

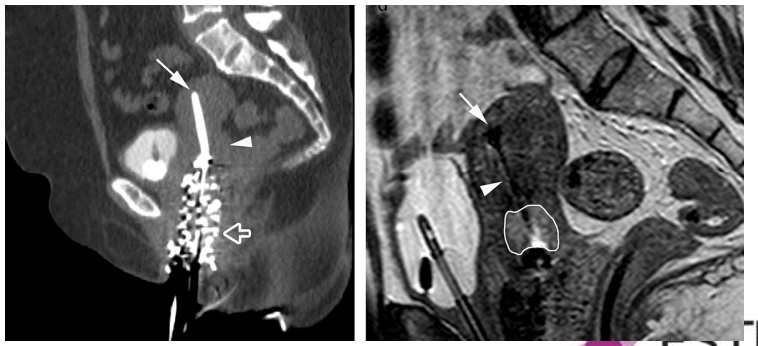

ESTRO School

6) CTV DELINEATION FOR **3D-BRACHYTHERAPY**

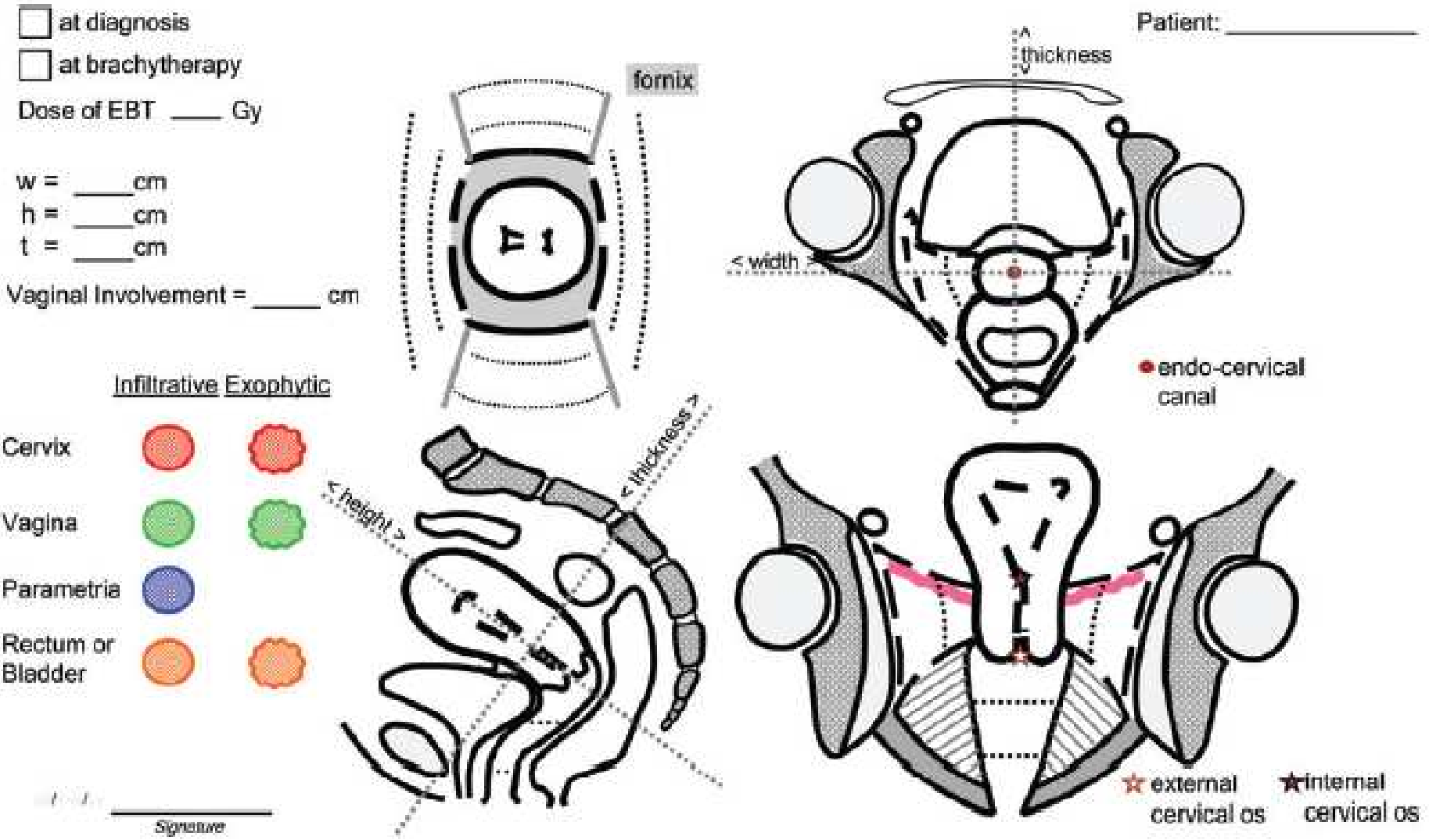

ESTRO School

6) CTV DELINEATION FOR **3D-BRACHYTHERAPY**

GTV-T_{init}

Macroscopic tumor extension at diagnosis, proven by histology as detected by clinical examination (GTV-T_{clin}) and as visualized as a high-signal intensity mass using T2-weighted MRI (GTV-T_{MRI}).

GTV-T_{res}

Remaining tumor at the time of brachytherapy application, determined using the same clinical or imaging investigations, after treatment assumed sufficient to control microscopic disease.

*Can have undergone inflammatory reactions with edema and fibrotic remodeling ("**gray zones**"), might or might not contain macroscopic or microscopic tumor.*

ESTRO School

6) CTV DELINEATION FOR **3D-BRACHYTHERAPY**

When using clinical drawings and CT images for treatment planning in locally advanced disease, the **GTV** can be reliably described only based on **clinical examination** with regard to **cervical, parametrial, and vaginal extension (not for infiltration into the uterine corpus)**, as **CT at present is not recognized as a reliable and valid method to assess the advanced macroscopic tumor of the cervix**.

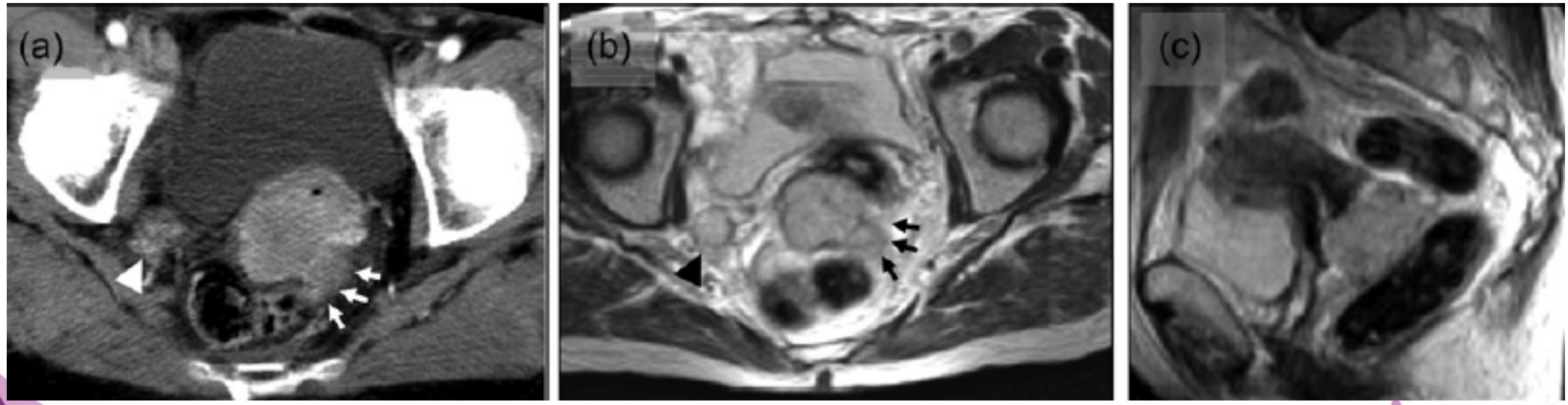

ESTRO School

6) CTV DELINEATION FOR **3D-BRACHYTHERAPY**

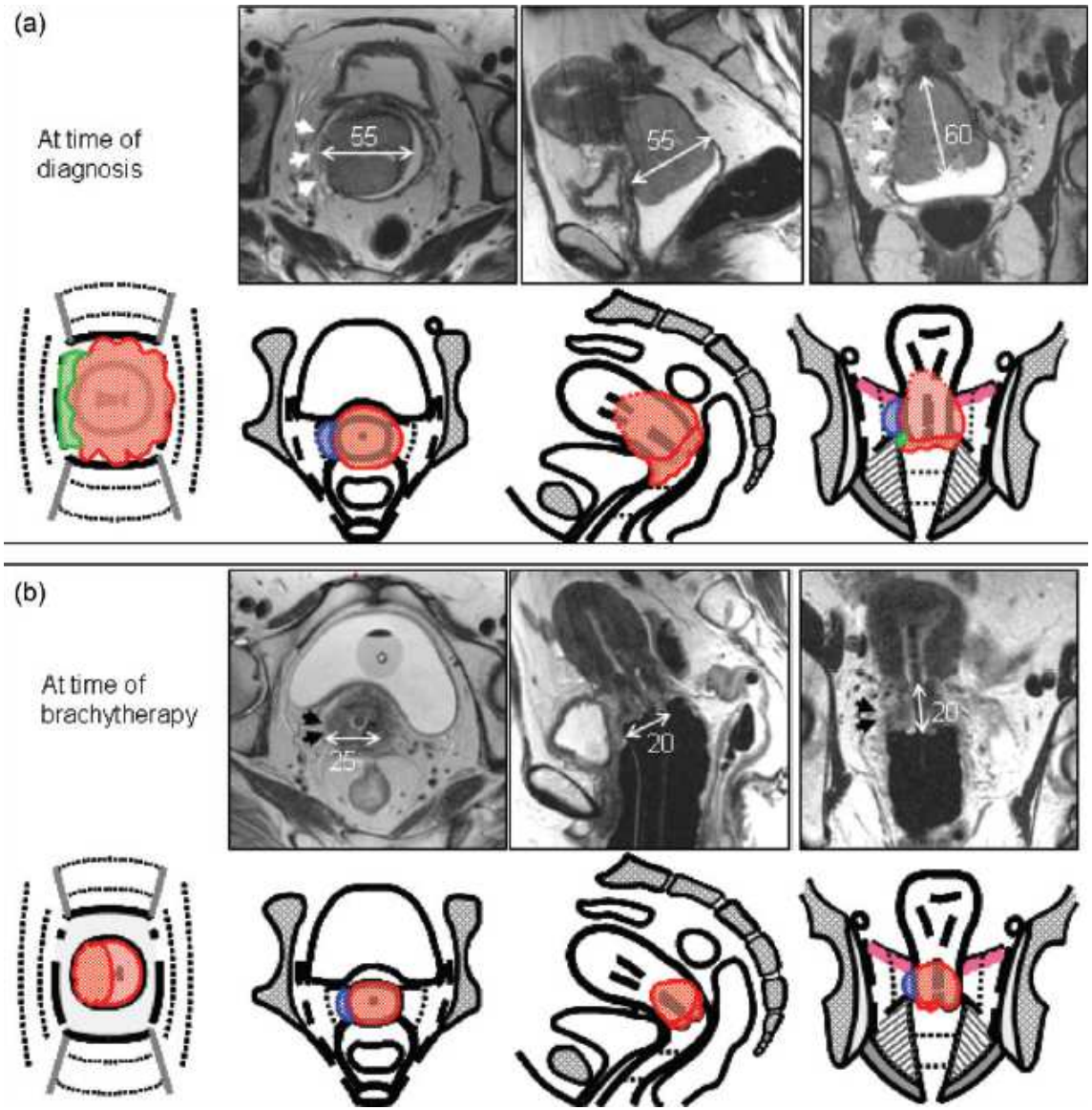

ESTRO School

6) CTV DELINEATION FOR **3D-BRACHYTHERAPY**

CTV

Includes the GTV-T and a volume of surrounding tissue in which the risk of **microscopic disease** is deemed so high that this region should be treated with a dose sufficient to control microscopic disease.

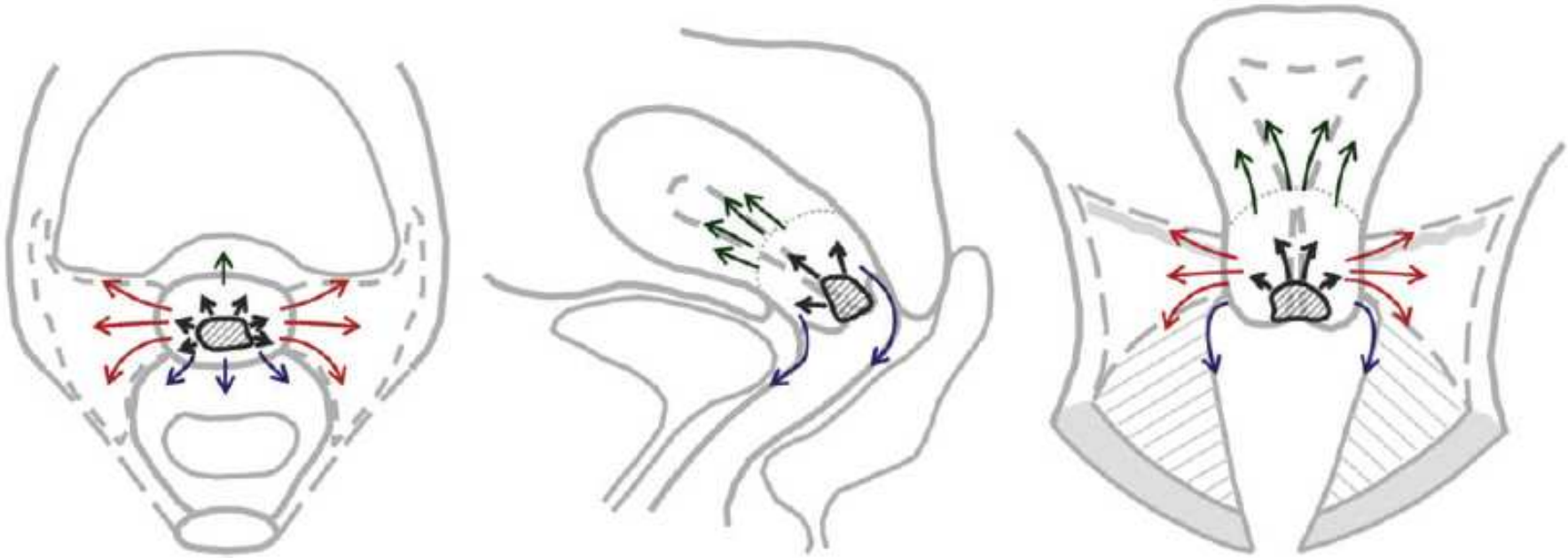

ESTRO School

$CTV_{HR}/CTV\text{-}T_1$

$GTV\text{-}T_{res}$

Whole cervix

Adjacent residual pathologic tissue

- Residual palpable mass
- Residual visible mucosal changes
- Pathologic indurations
- Residual gray zones (MRI)

$CTV_{IR}/CTV\text{-}T_2$

$GTV\text{-}T_{init}$

Margins around the CTV-T_{HR}

- 10mm lateral and cranio-caudal
- 5mm anterior-posterior

$CTV_{LR}/CTV\text{-}T_3$

Whole uterus

Whole parametria

Upper third/half of the vagina

Anterior/Posterior spaces toward the bladder and rectum

Mainly treated by EBRT

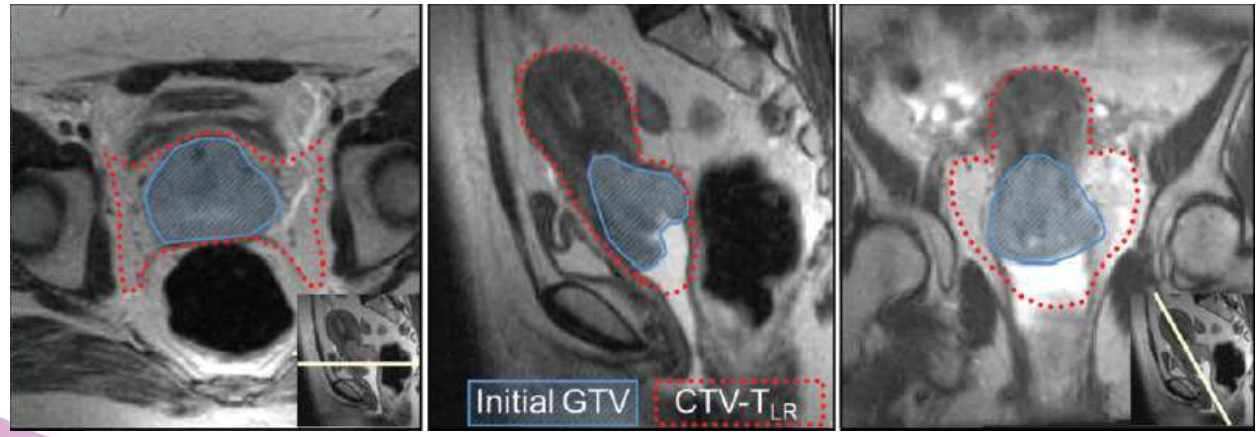

ESTRO School

6) CTV DELINEATION FOR **3D-BRACHYTHERAPY**

CTV-HR

If CT-guided brachytherapy:

- **Advanced disease (IB2-IVA):** inclusion of at least **two-thirds** of the uterus;
- **Limited disease (IB1):** inclusion of only **half** of the uterus in the CTV-HR.

Hegazy et al. 2013

CTV-IR

- Must not include any OAR besides the vagina;

- **Rectal/bladder invasion**: margins should not go into the organ lumen.

ESTRO School

6) CTV DELINEATION FOR **3D-BRACHYTHERAPY**

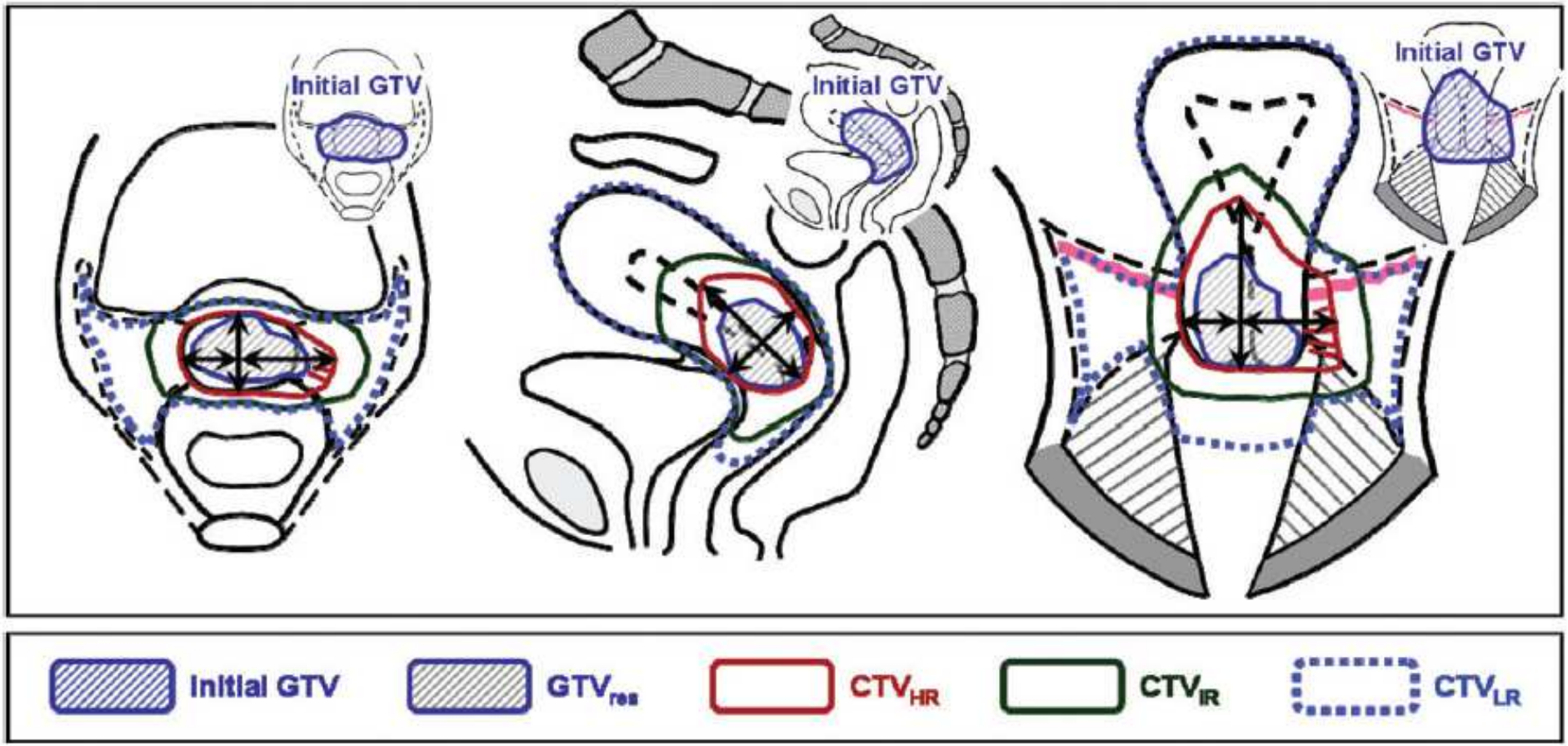

IIB

6) CTV DELINEATION FOR **3D-BRACHYTHERAPY**

PTV

Generally **not** recommended…

…can be considered along the **longitudina** axis of the tandem.

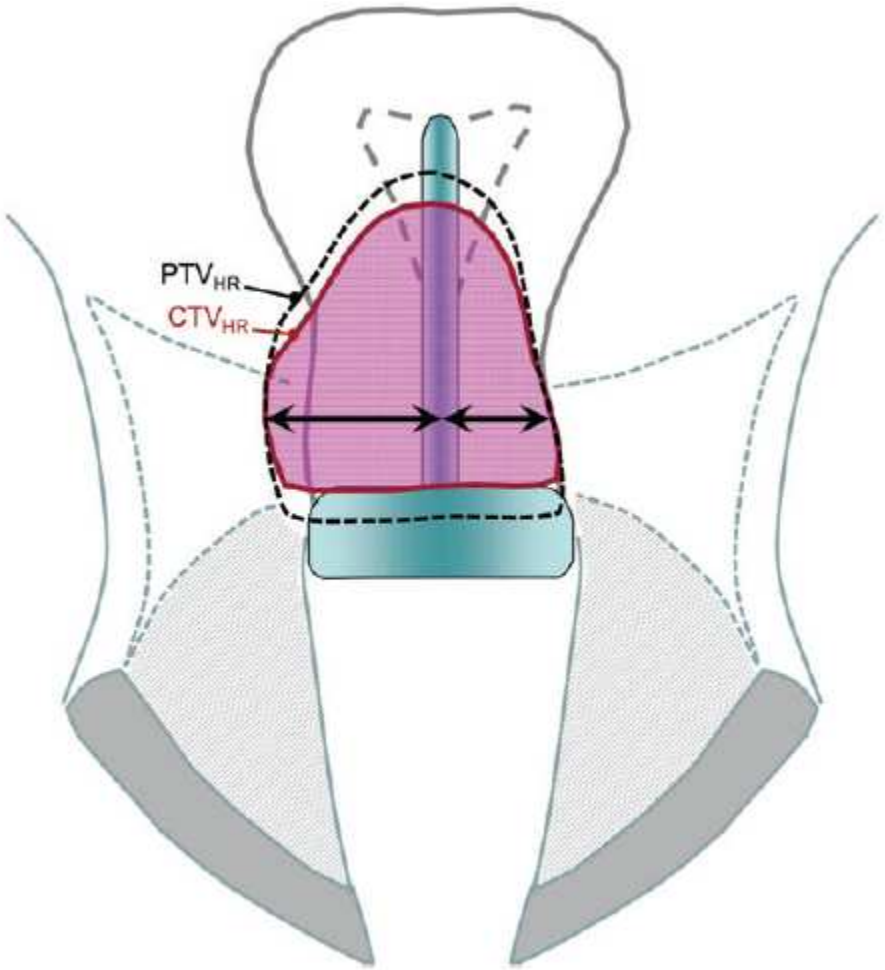

ESTRO School

6) CTV DELINEATION FOR **3D-BRACHYTHERAPY**

It seems sufficient to delineate the regions adjacent to the applicator with **one outer contour.**

0.1 cm³
2.0 cm³

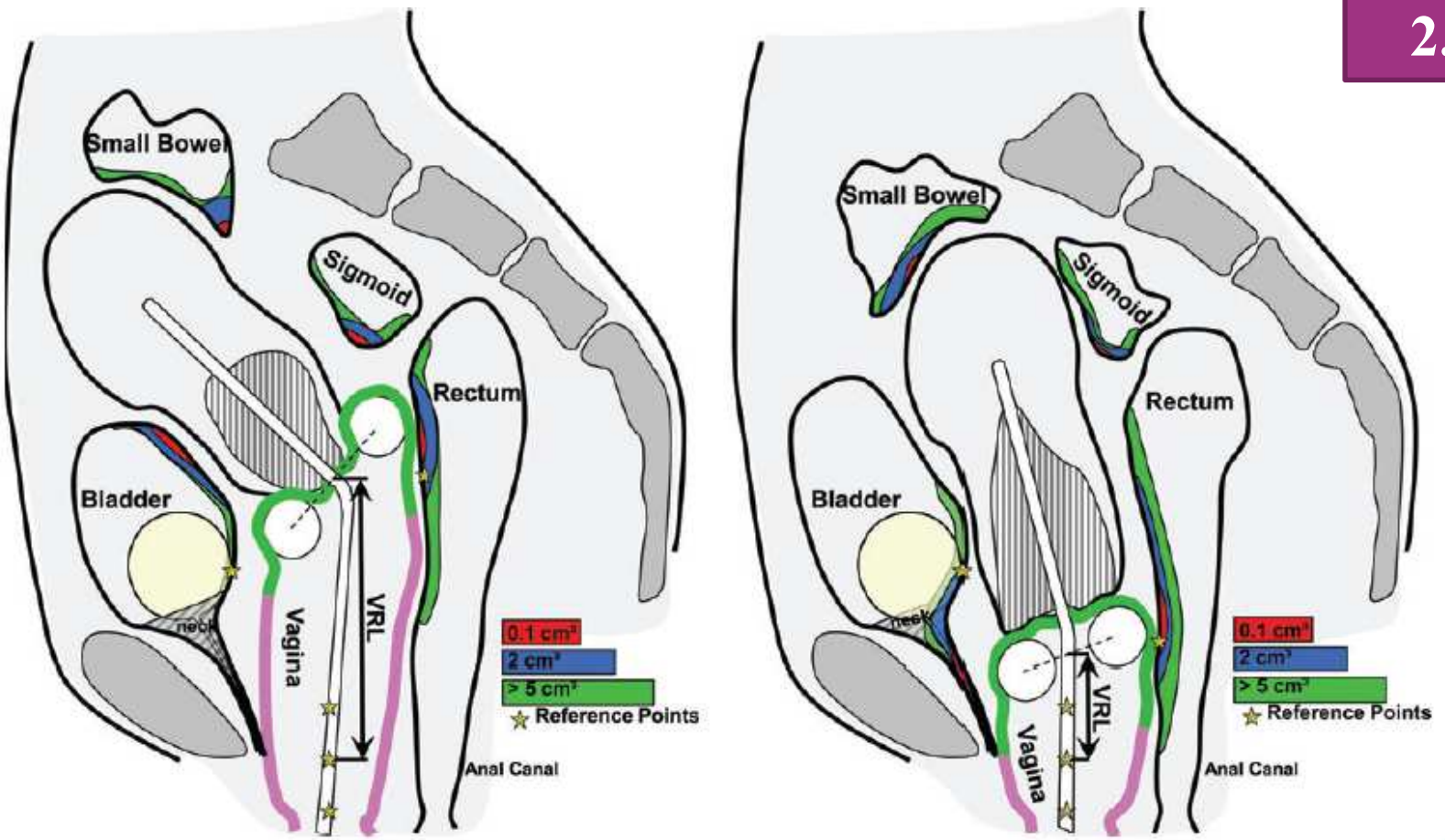

ESTRO School

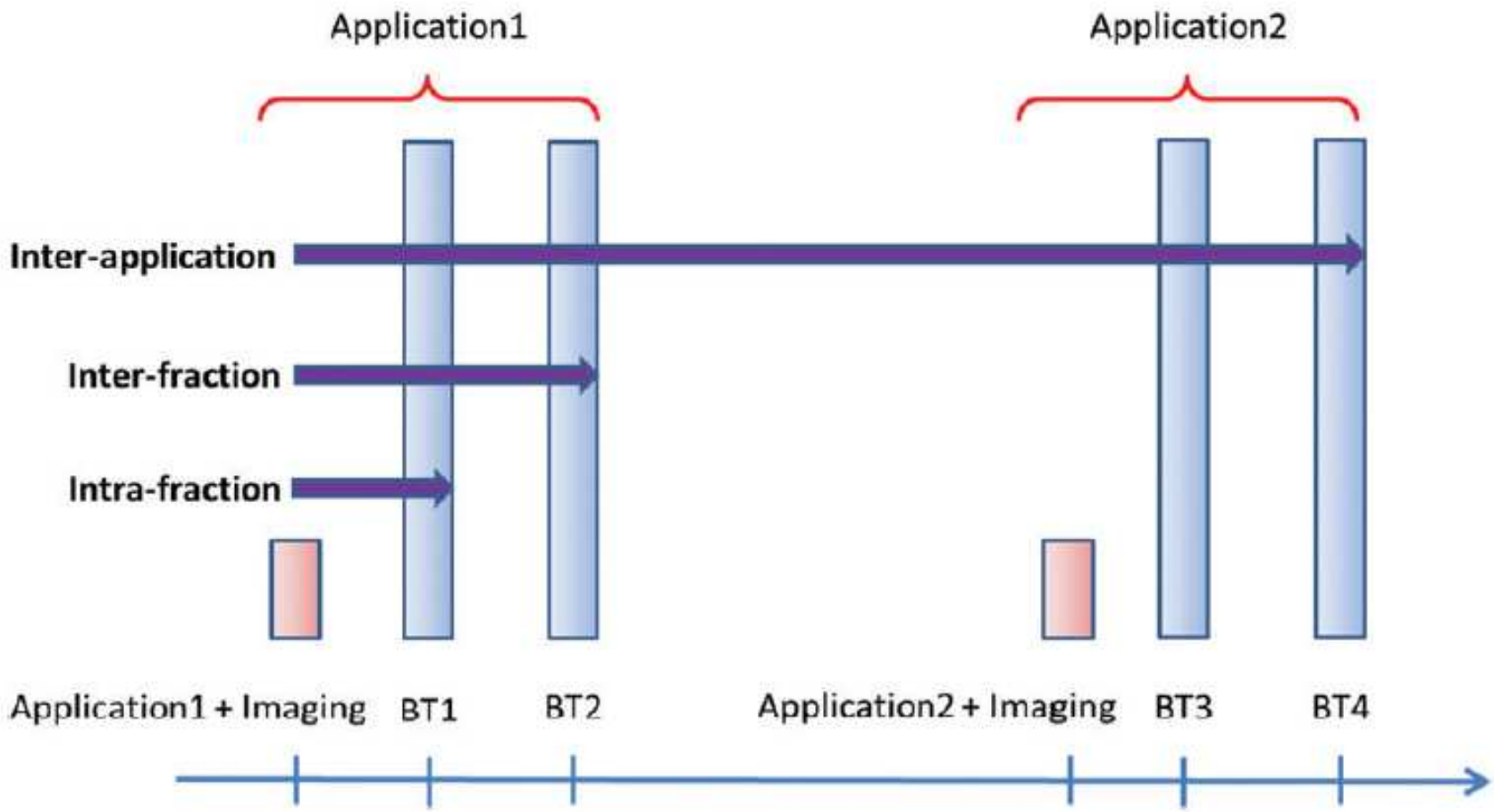

Dose deviations associated with both intra- and inter-fraction uncertainties:

- 20-25 % for **organs at risk**
- 10 % for the **target (CTV-HR)**

ESTRO School

7) CONCLUSION

- Additional discussion is still required to achieve a consensus regarding how much individualization will be permissible within the guideline
- To perform appropriate IMRT, as well as accurate CTV contouring, consensus on the delineation of the OARs is important
- Management of organ movement and tumor shrinkage over the treatment course represent additional challenges
- Regular imaging is vital when implementing advanced RT techniques in gynecology cancer

7) CONCLUSION

- **GTV-CTV-ITV** concept in cervical cancer quite complex
- **GTV** has primary and lymphatic component
  - Primary GTV often gets brachy boost
  - Node GTV gets EBRT boost
- **CTV** has primary and lymphatic component
  - CTV needs elective EBRT
- **ITV** includes total CTV
  - Gets elective EBRT
  - CTV-ITV margin compensates for internal mobility and deformation
  - Extent of CTV-ITV margin depends on position verification method

ESTRO School

ESTRO School

WWW.ESTRO.ORG/SCHOOL

Imaging for Determining the Gross Tumor Volume (GTV): Prostate Cancer

Stefan Delorme

Learning Objectives

- To understand prostate anatomy
- To comprehend the staging system for prostate cancer
- To appreciate potentials and shortcomings of imaging method for GTV delineation
  - CT
  - MRI
- To be aware of functional imaging modalities
  - Dynamic CE MRI
  - MRS
  - DWI
  - PET

ESTRO School

Anatomy

- Yellow: Peripheral gland
- Blue: Transitional zone
- Red: Central gland
- Green: Anterior fibromuscular zone

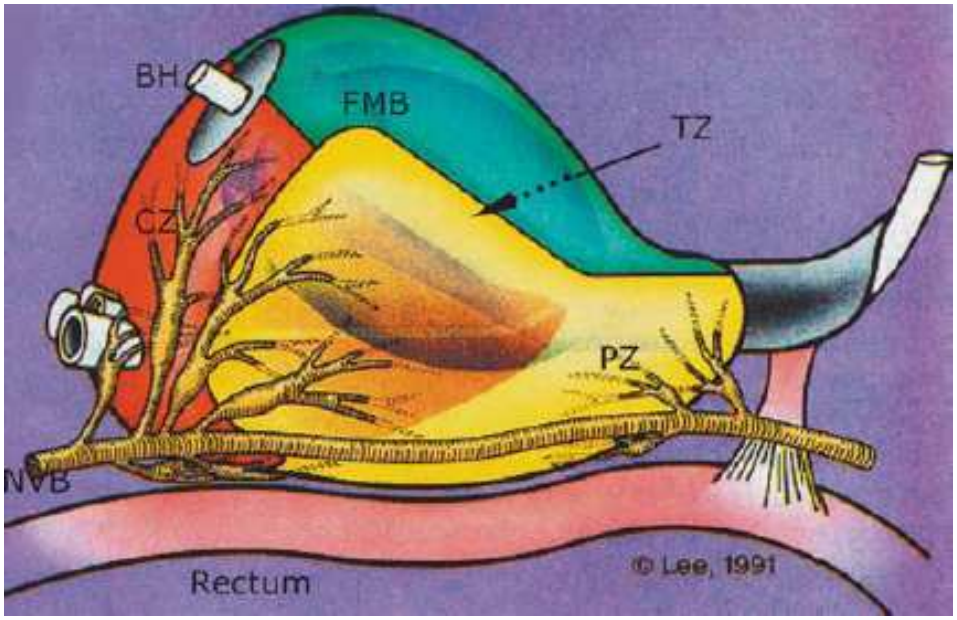

ESTRO School

CT above the bladder

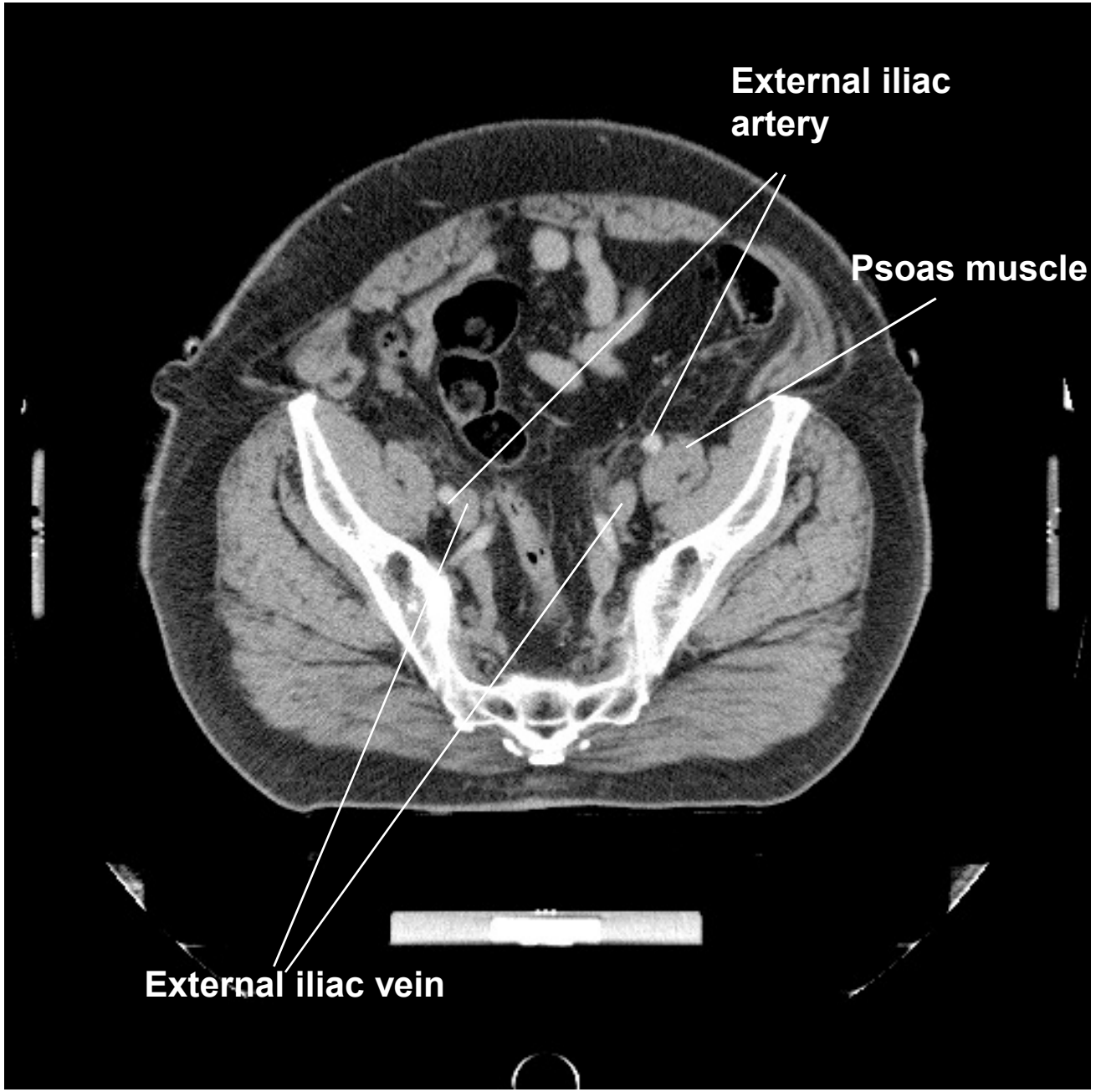

Roof of the bladder

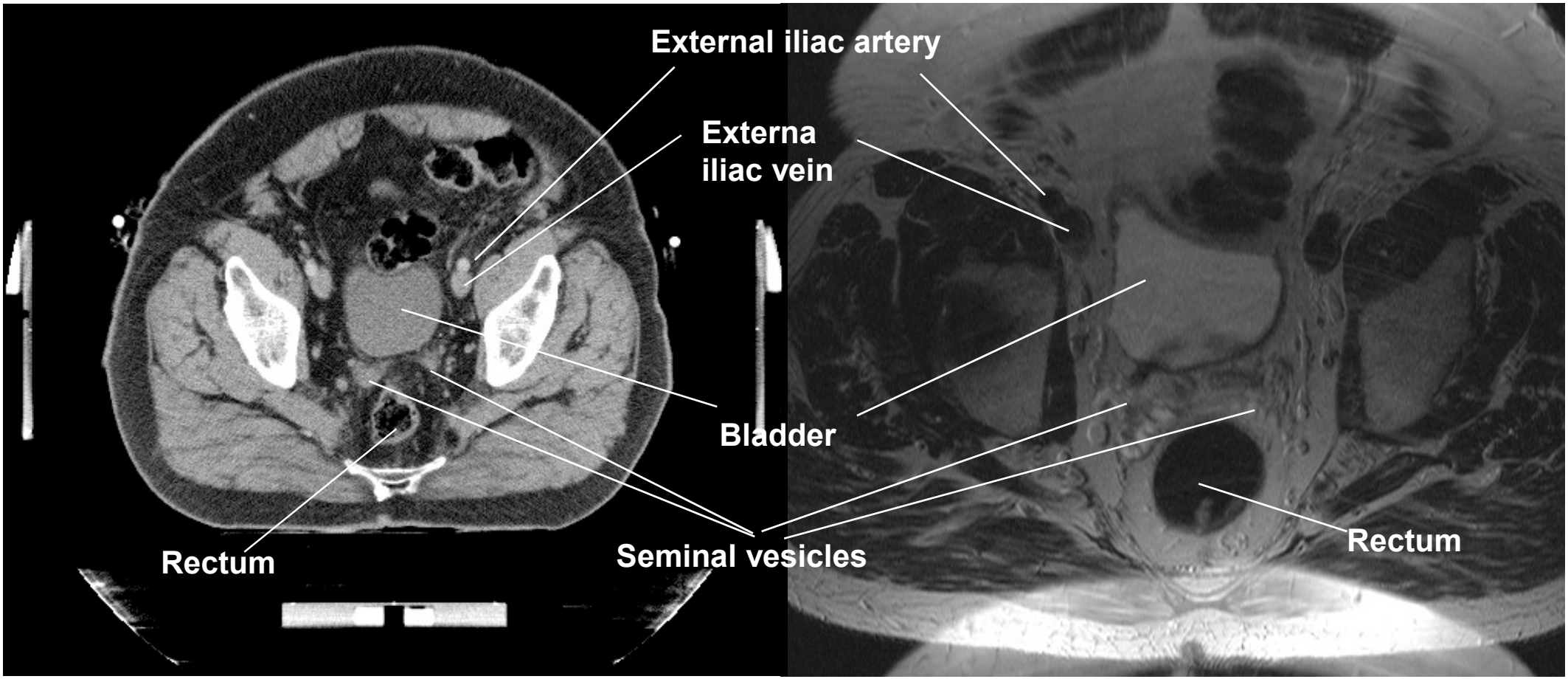

Floor of bladder I

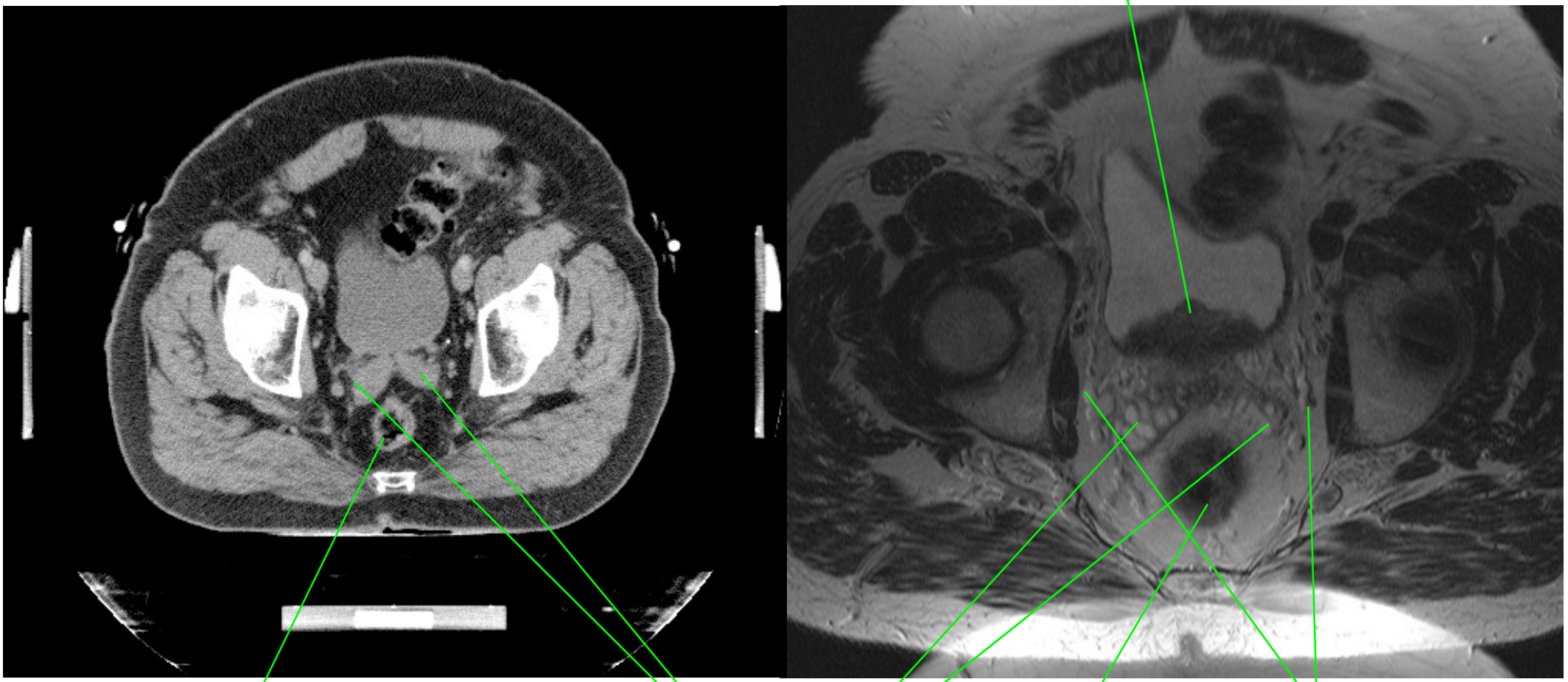

ESTRO School

Floor of the bladder II

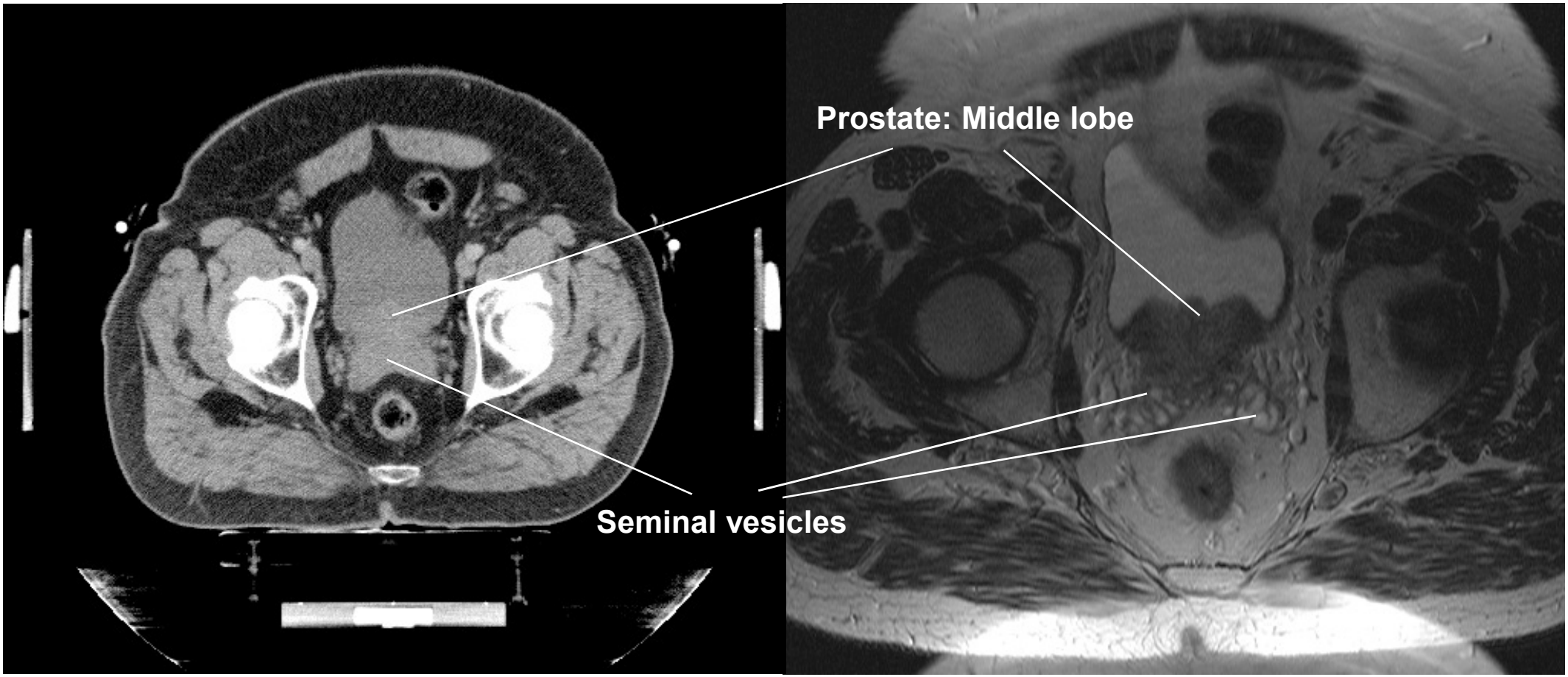

ESTRO School

Prostate: Middle portion I

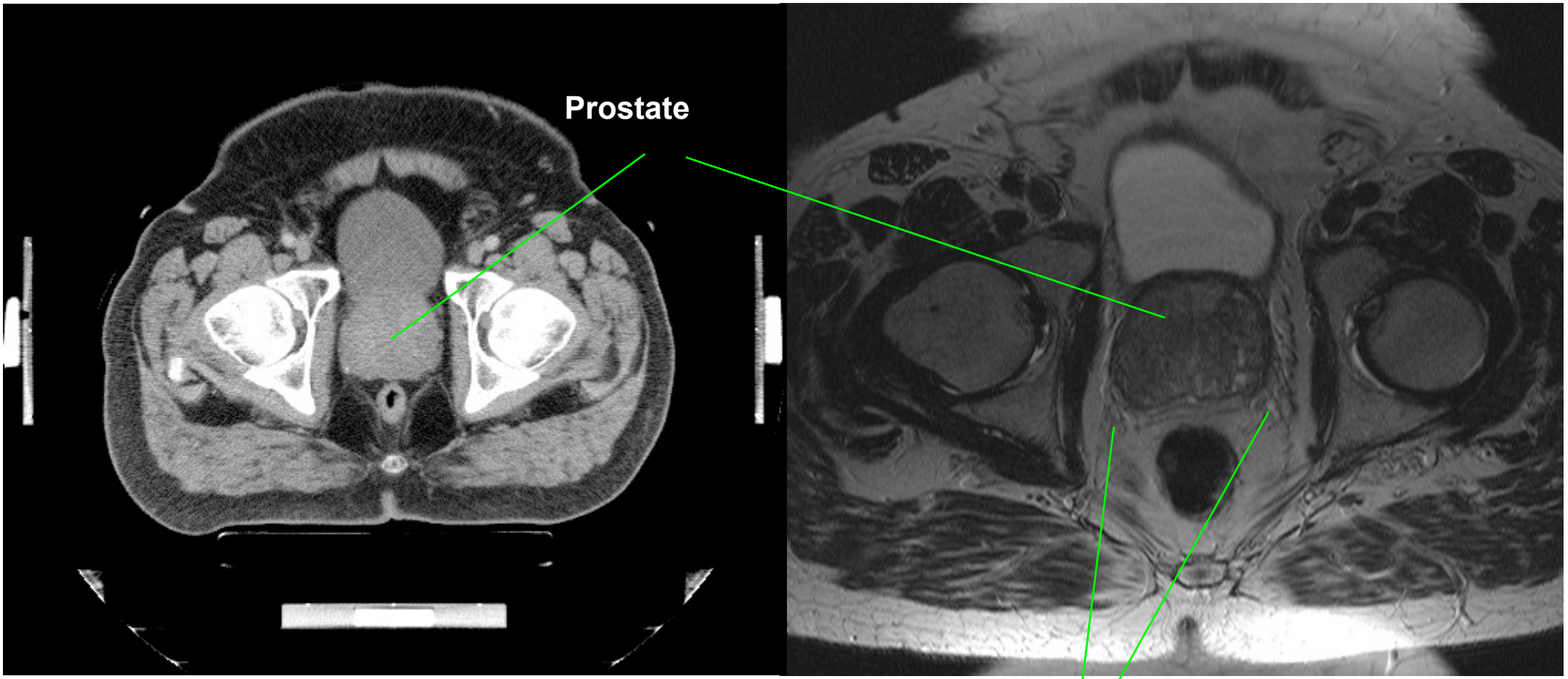

ESTRO School

Prostate: Middle portion II

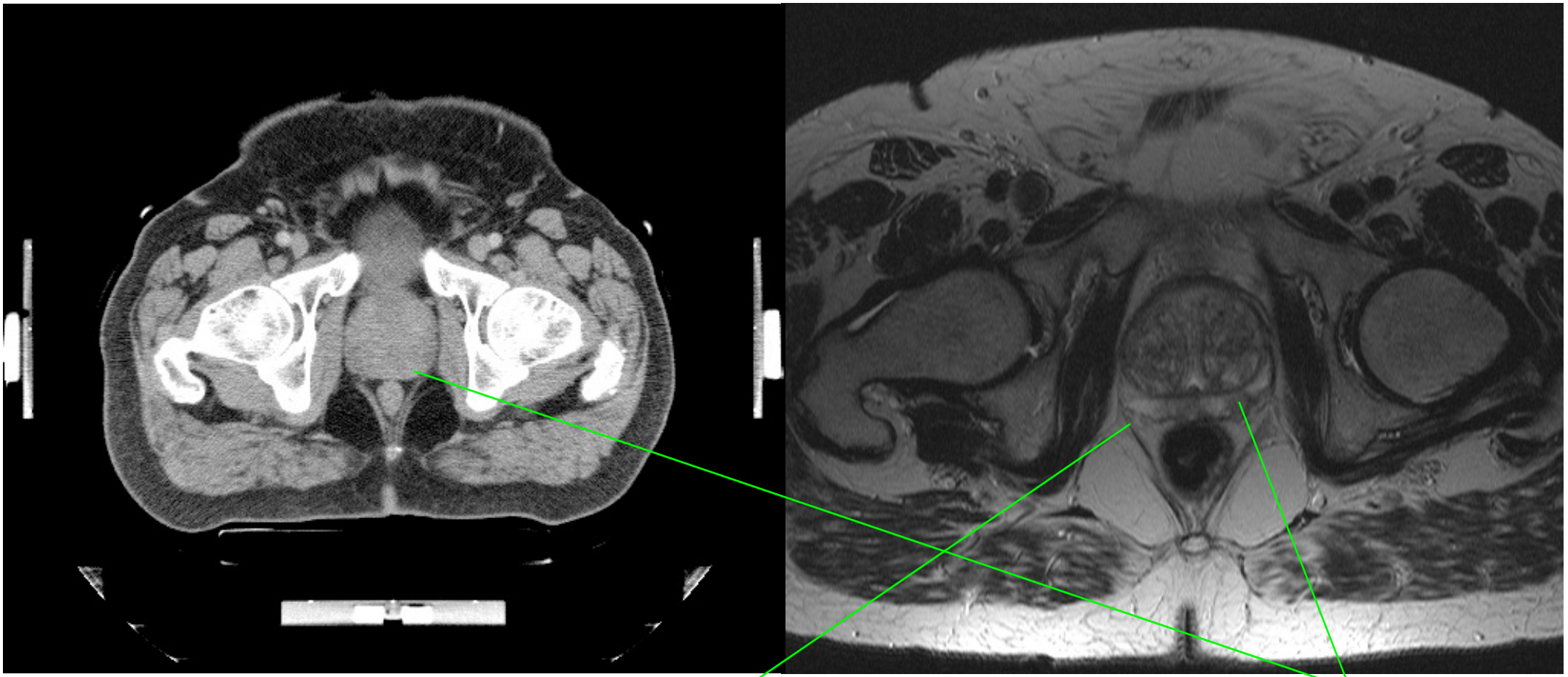

ESTRO School

Prostate: Apex

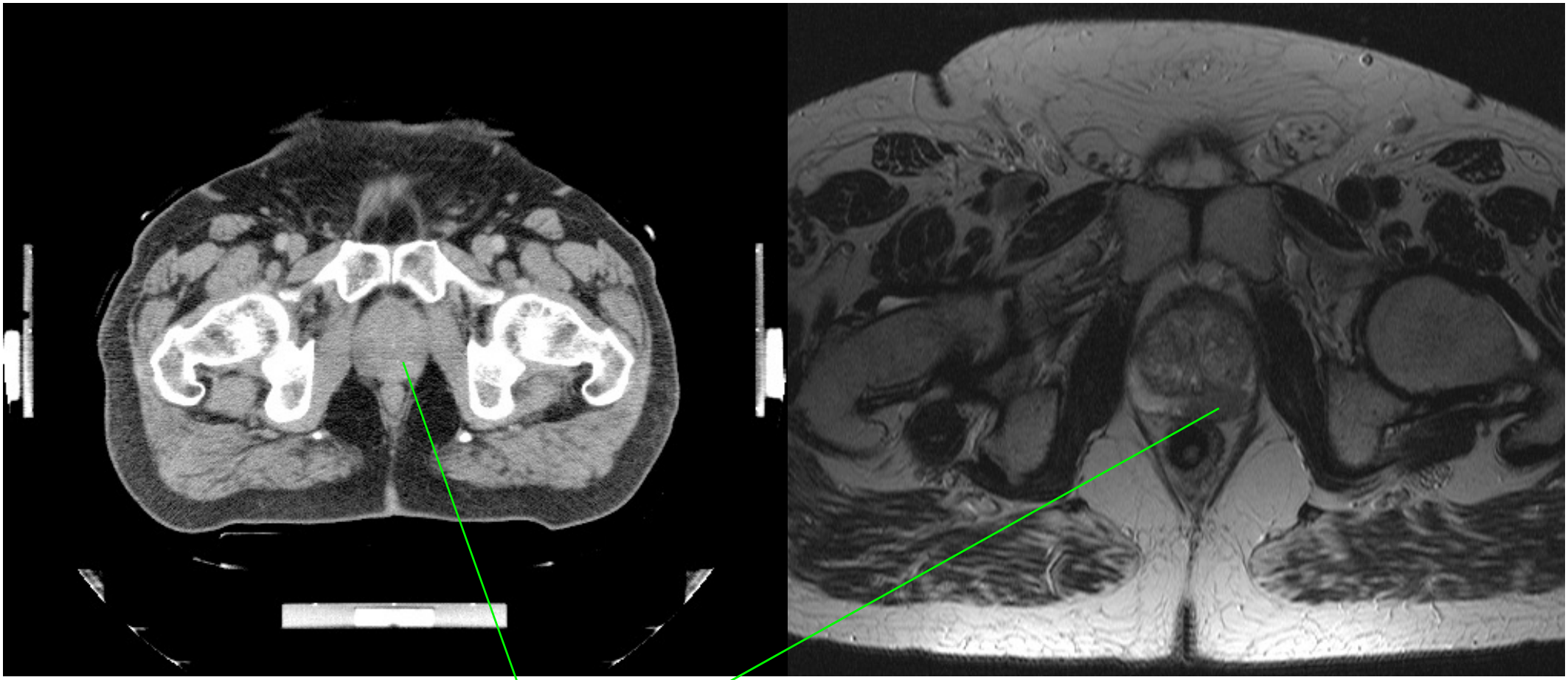

ESTRO School

Anatomy of the Prostate: MRI

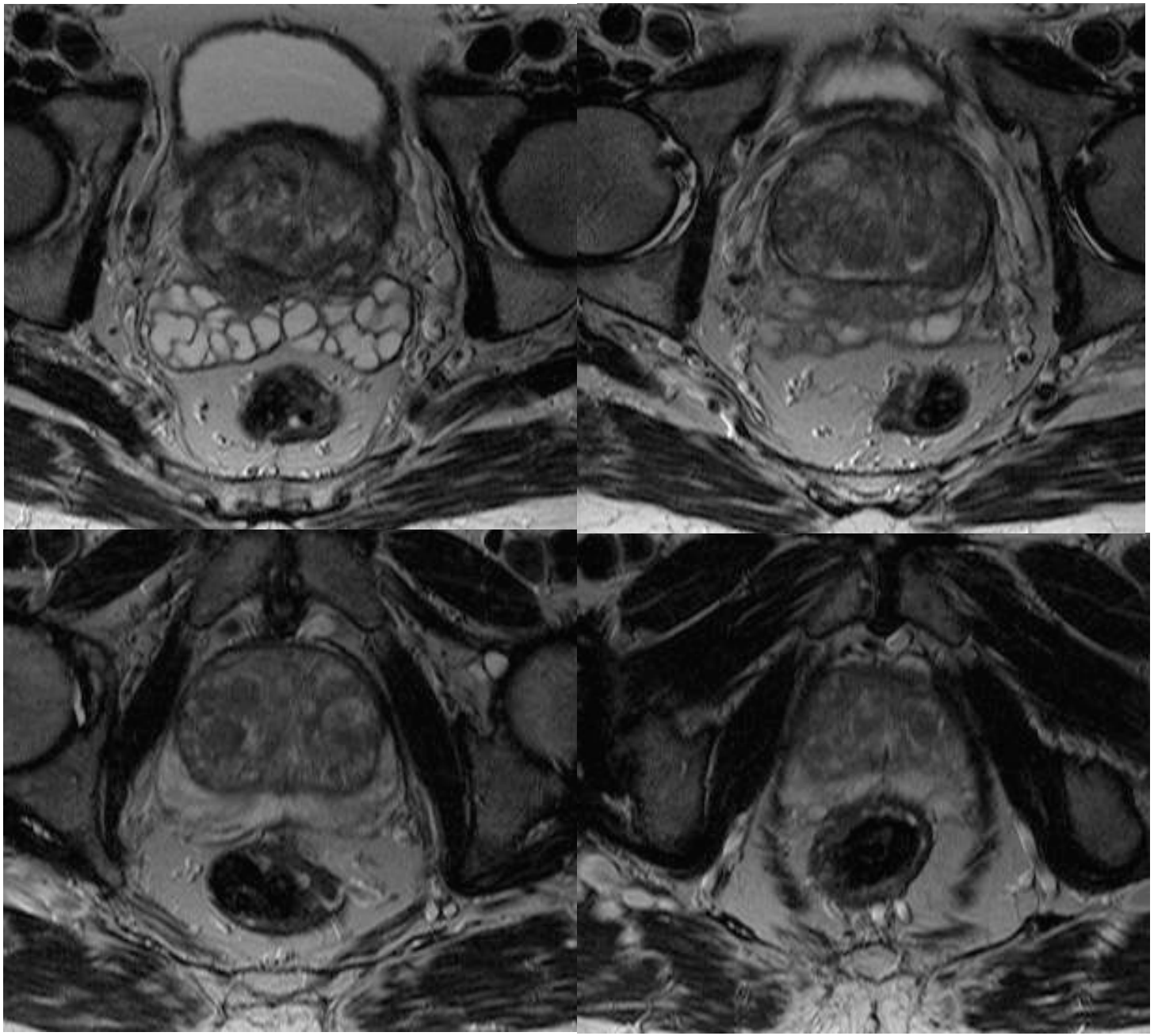

ESTRO School

TNM Stages

- T1 Not palpable
  - T1a <5% of resected tissue involved
  - T1b > 5% of resected tissue involved
  - T1c Diagnosed by punch biopsy
- T2 Limited to prostate
  - T2a less than half lobe involved
  - T2b More than half lobe involved
  - T2c Bilateral tumour
- T3 Extracapsular extension
  - T3a Not involving seminal vesicles
  - T3b Involving seminal vesicles
- T4 Tumour fixed or invading other organs

ESTRO School

CT

- T-Staging: Detection
  - T 1 – not palpable — not detectable
  - T 2 – confined to prostate — not detectable
  - T 3/4 – extracapsular extension: infiltration of seminal vesicles, neurovascular bundle, rectum, bladder — difficult
- Grading: not possible

→ **CT not the method of choice**

ESTRO School

MRI

Benign Hyperplasia

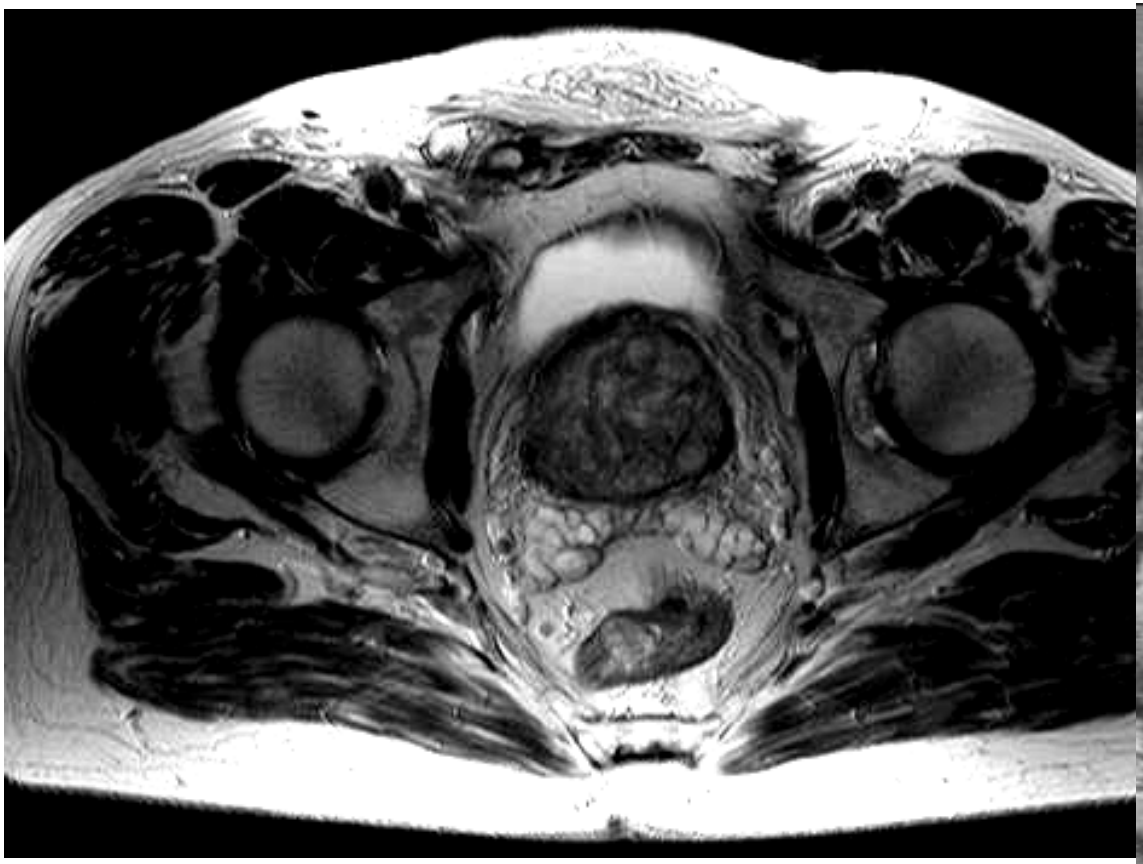

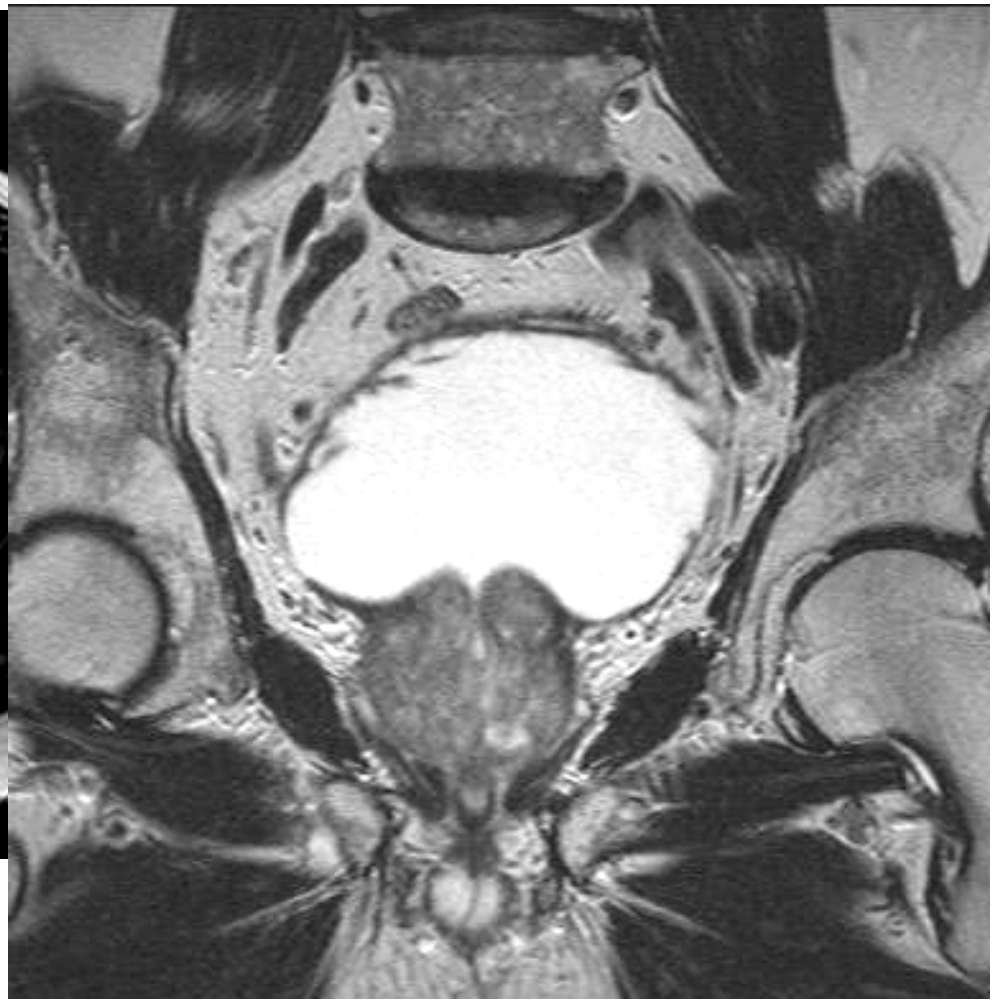

- Origin in central gland
- Elevation of bladder
- Protrusion of middle lobe
- Confined within capsule

ESTRO School

Prostate Carcinoma

T2a (<50% 1 lobe)

T2b (>50% 1 lobe)

T2c (both lobes)

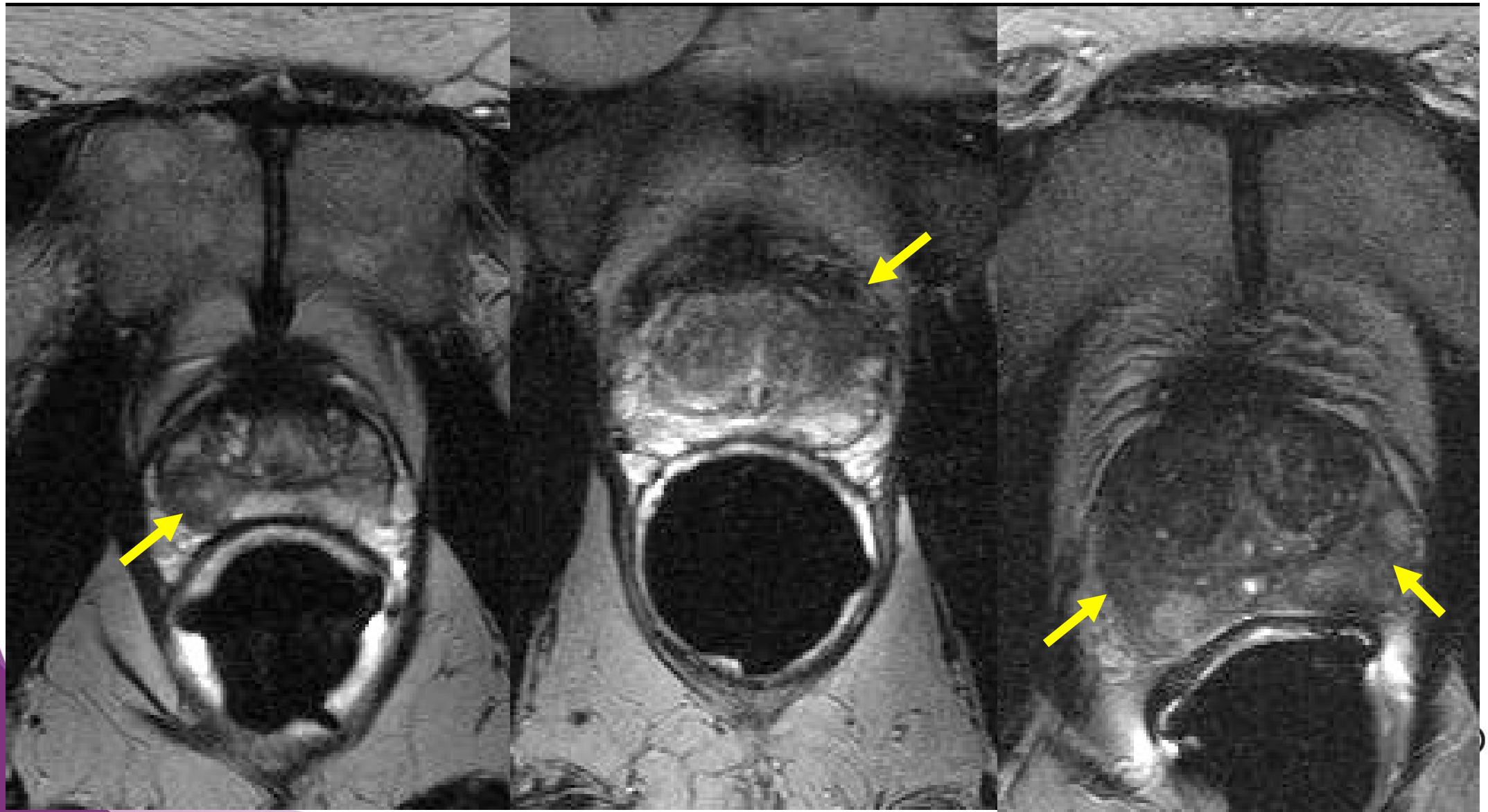

Prostate Carcinoma

T3b

extracapsular extension + infiltration of seminal vesicles

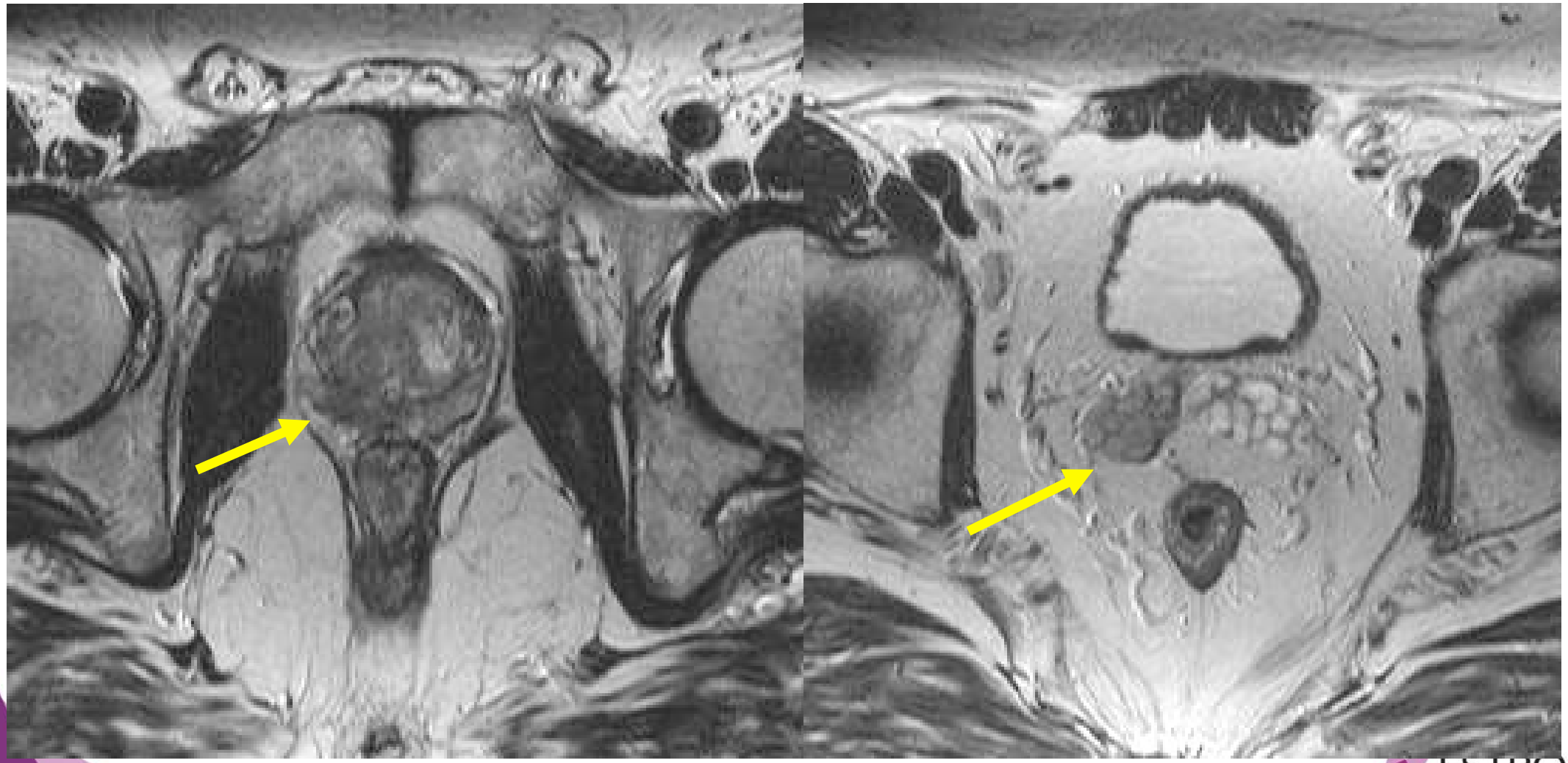

ESTRO School

Extracapsular Extension

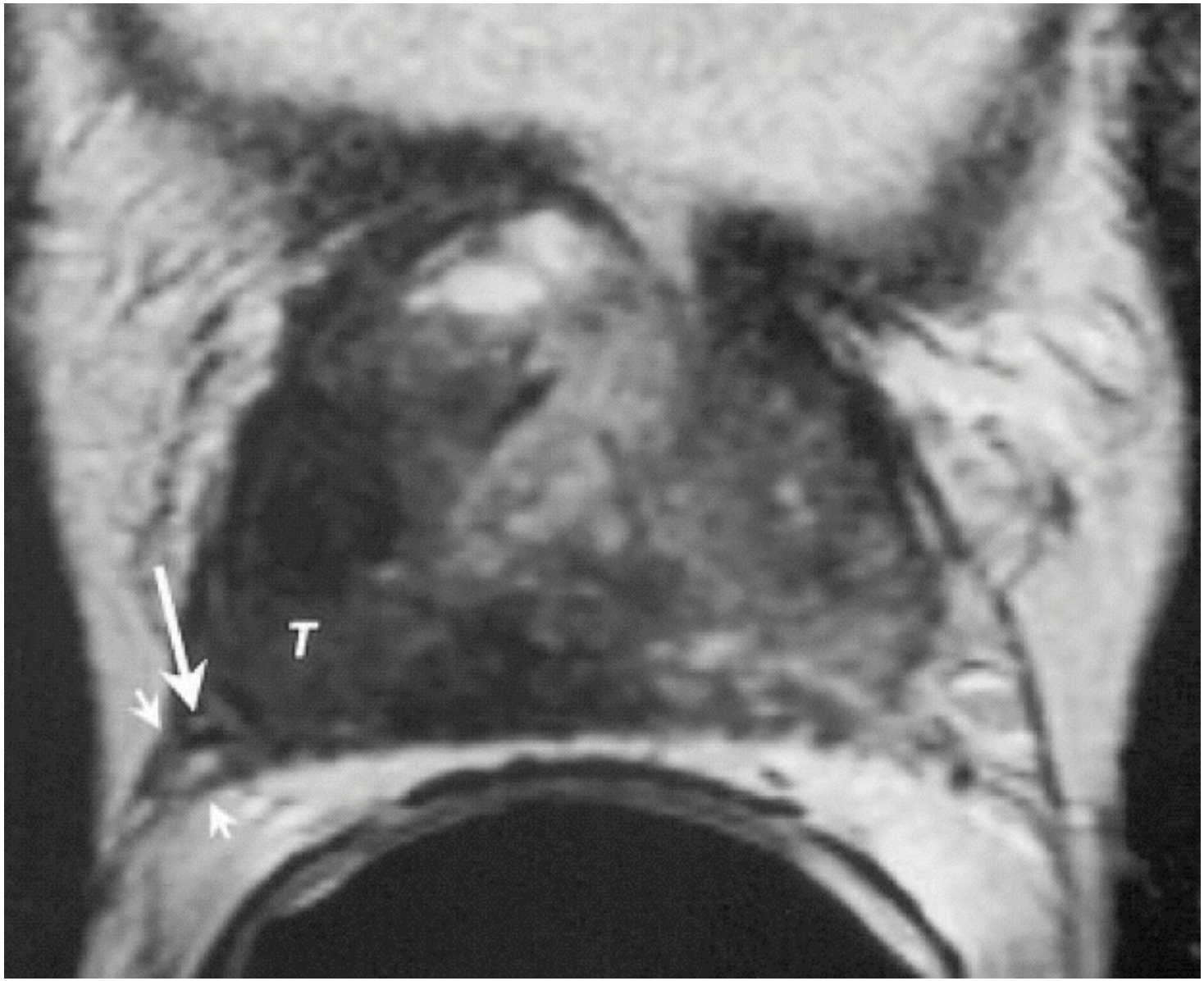

Hricak H, Cancer 2004

ESTRO School

MRI

- T-Staging: Detection
  - T1 – not palpable — difficult
  - T 2 – confined to prostate — easily detectable
  - T 3/4 – extracapsular extension: infiltration of neurovascular bundle, seminal vesicles, rectum, bladder — superior to CT
- Grading: Characterization — not possible (yet?)

ESTRO School

REALITY

Where is the tumour?

T2w MRI

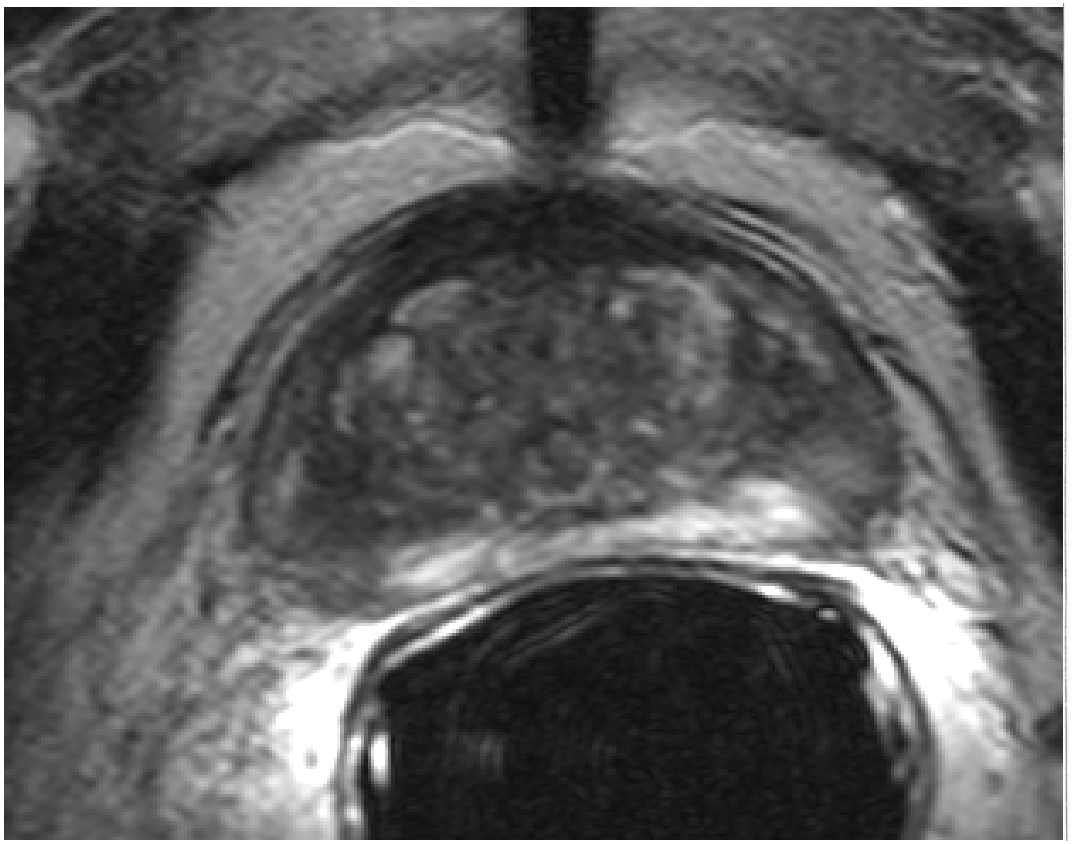

Histology

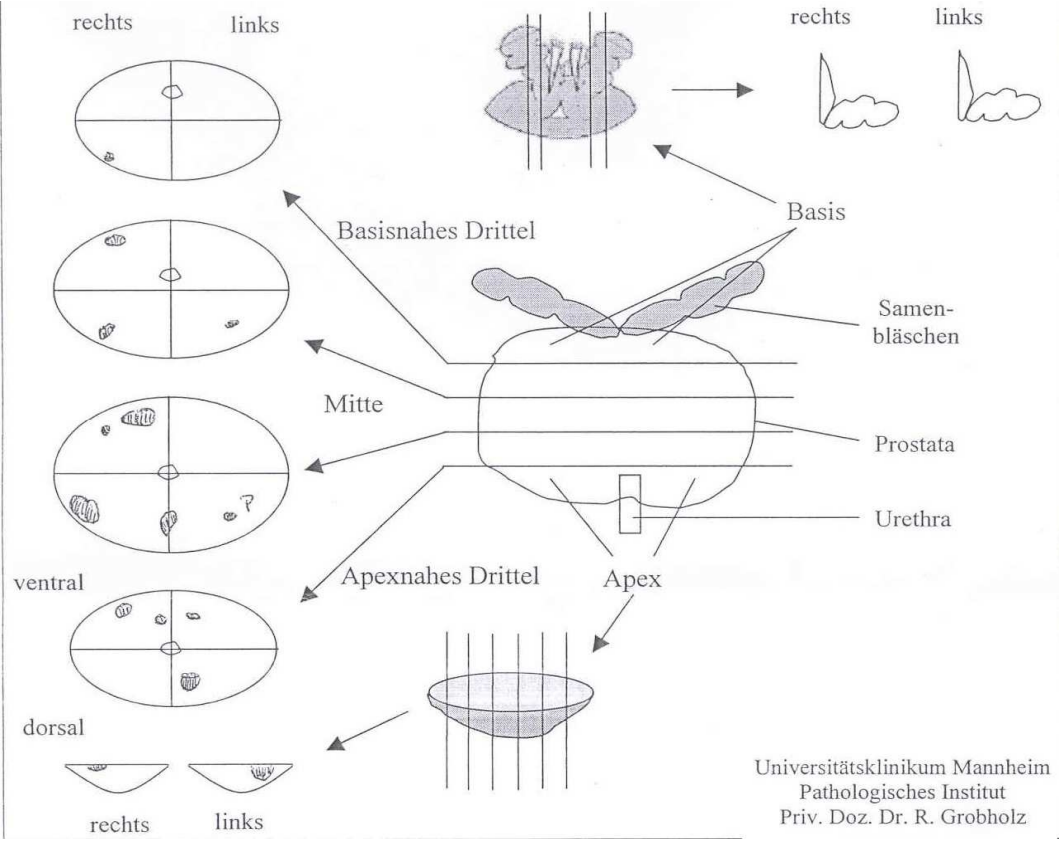

ESTRO School

Differential Diagnosis

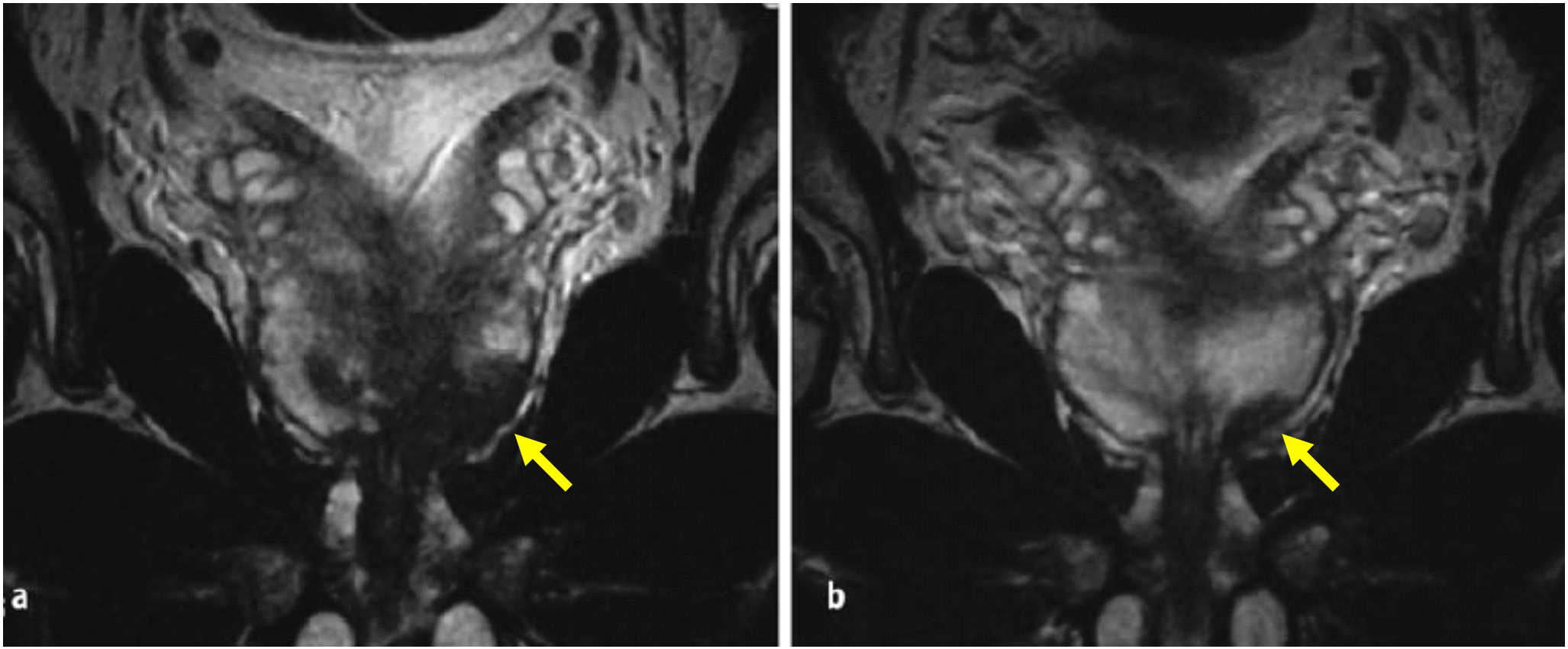

Chronic Prostatitis:

Low intensity areas decreased after 3 months of antibiotics

ESTRO School

Extracapsular Extension

Presurgical Variable	Sensitivity	Specificity
Serum PSA level*	27.7 (23/83)	87.4 (228/261)
Gleason score†	30.1 (25/83)	90.4 (236/261)
Clinical stage of tumor‡	56.6 (47/83)	60.9 (159/261)
Greatest percentage of cancer in all core biopsy specimens§	36.1 (30/83)	89.6 (232/259)
Percentage of cancer-positive core specimens in all core biopsy specimens§	35.0 (28/80)	81.0 (196/242)
PNI presence at needle biopsy‖	25.3 (21/83)	89.7 (234/261)
Endorectal MR imaging findings#	42.2 (35/83)	95.4 (249/261)

Wang L, Radiology 2004

ESTRO School

Extracapsular Extension

Percent probability of organ-confined tumor		Appropriate post-MRI altered surgical plans
Probability	No. of NVB	No. of NVB (%)
> 75%	47	6/9 (67%)
51–74%	127	22/36 (61%)
26–50%	60	26/32 (81%)
< 25%	36	26/28 (93%)
Totals	266	80/104 (77%)

Lymph node drainage

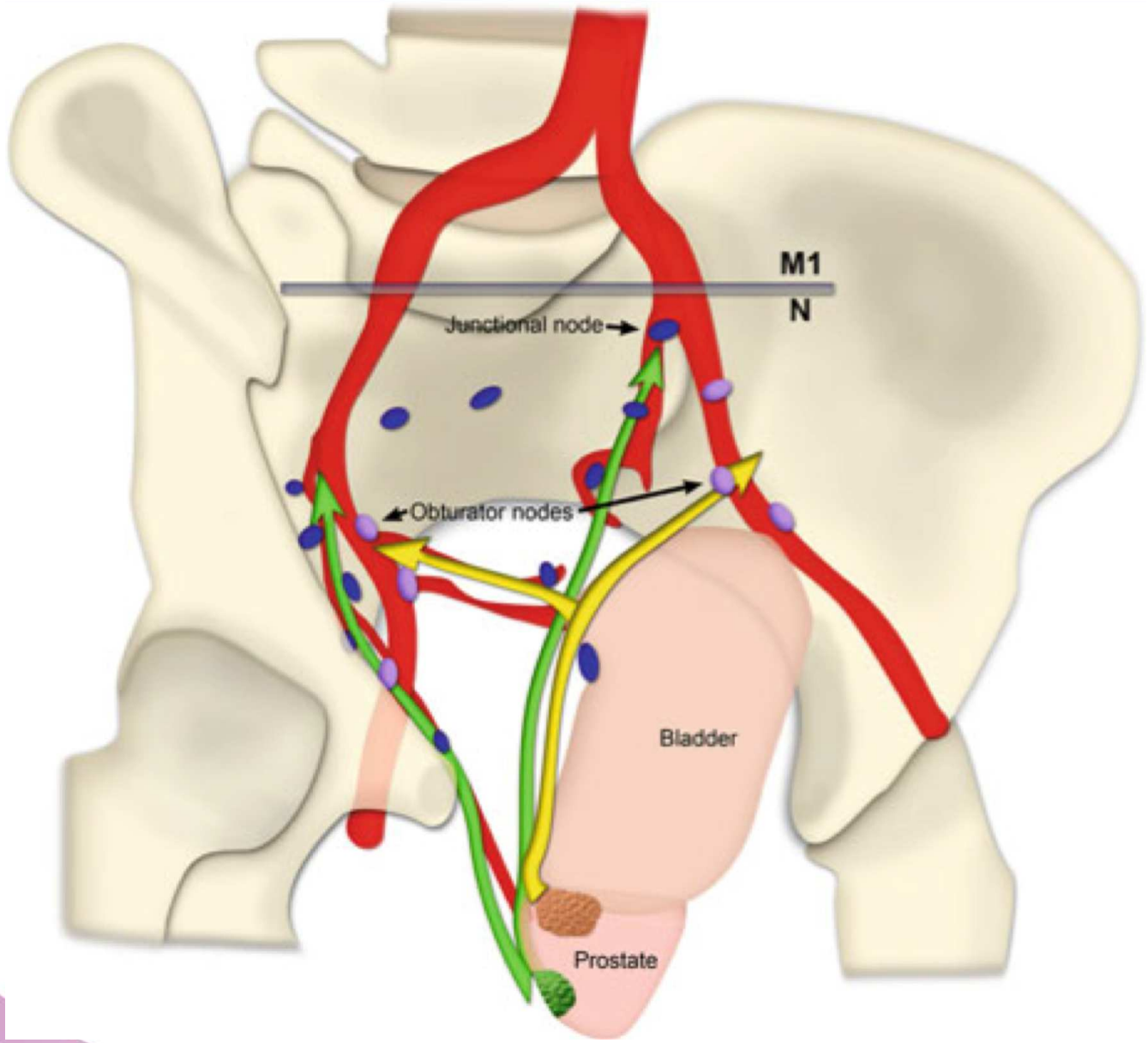

Yellow
-> External iliac LN

Green
-> Internal iliac LN

ESTRO School

Obturator lymph nodes

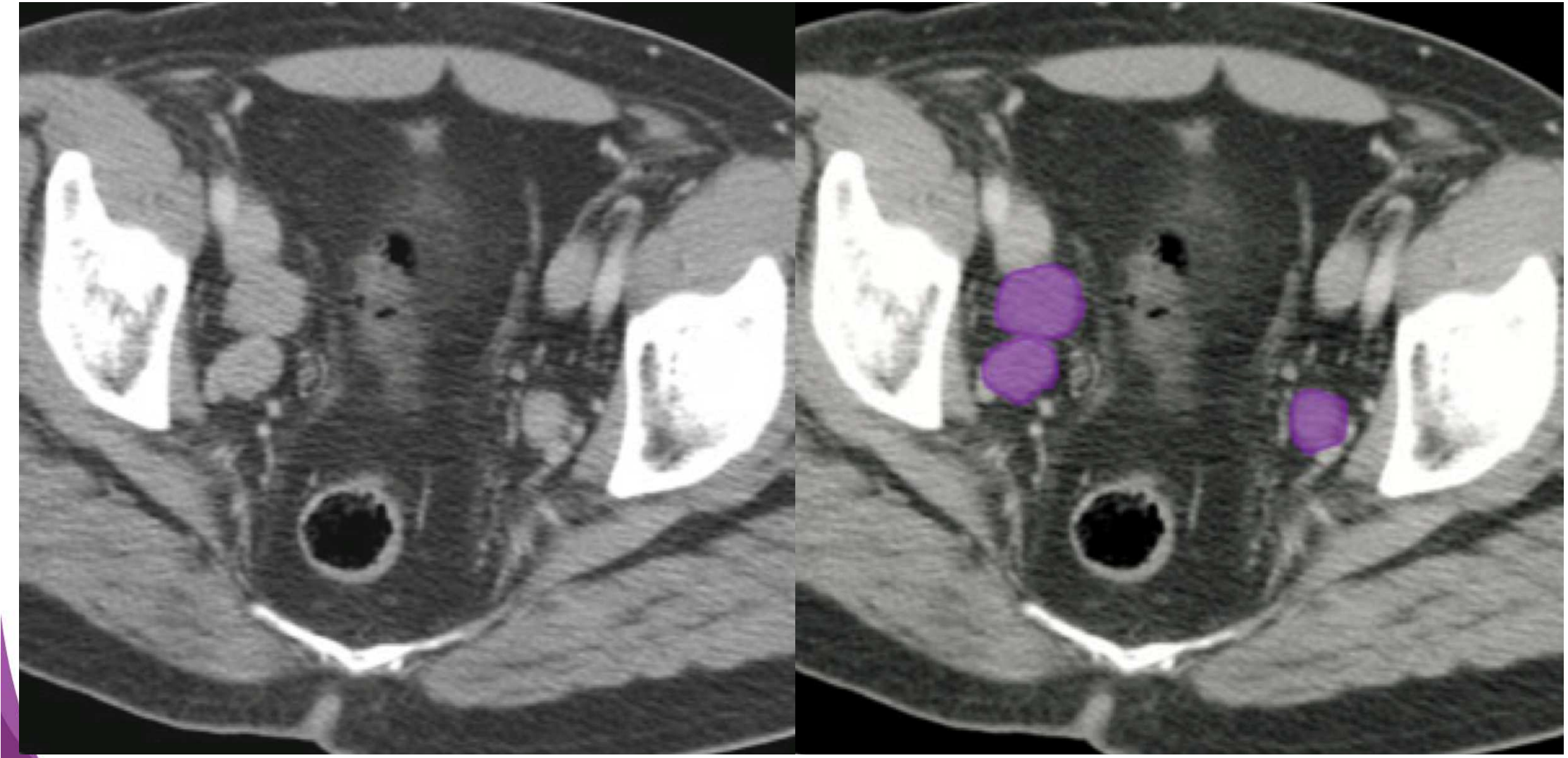

Obturator lymph node

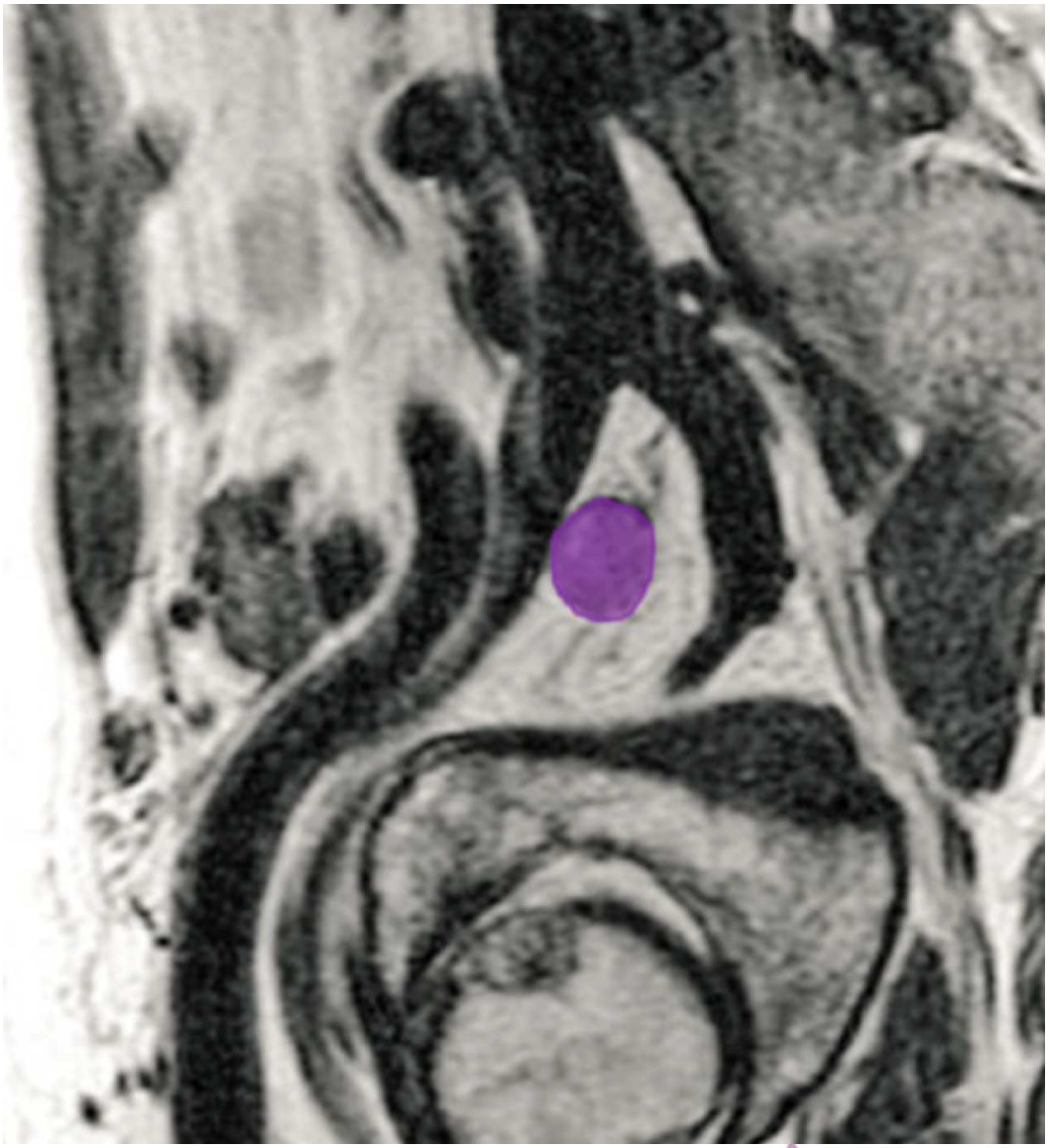

ESTRO School

External iliac lymph node

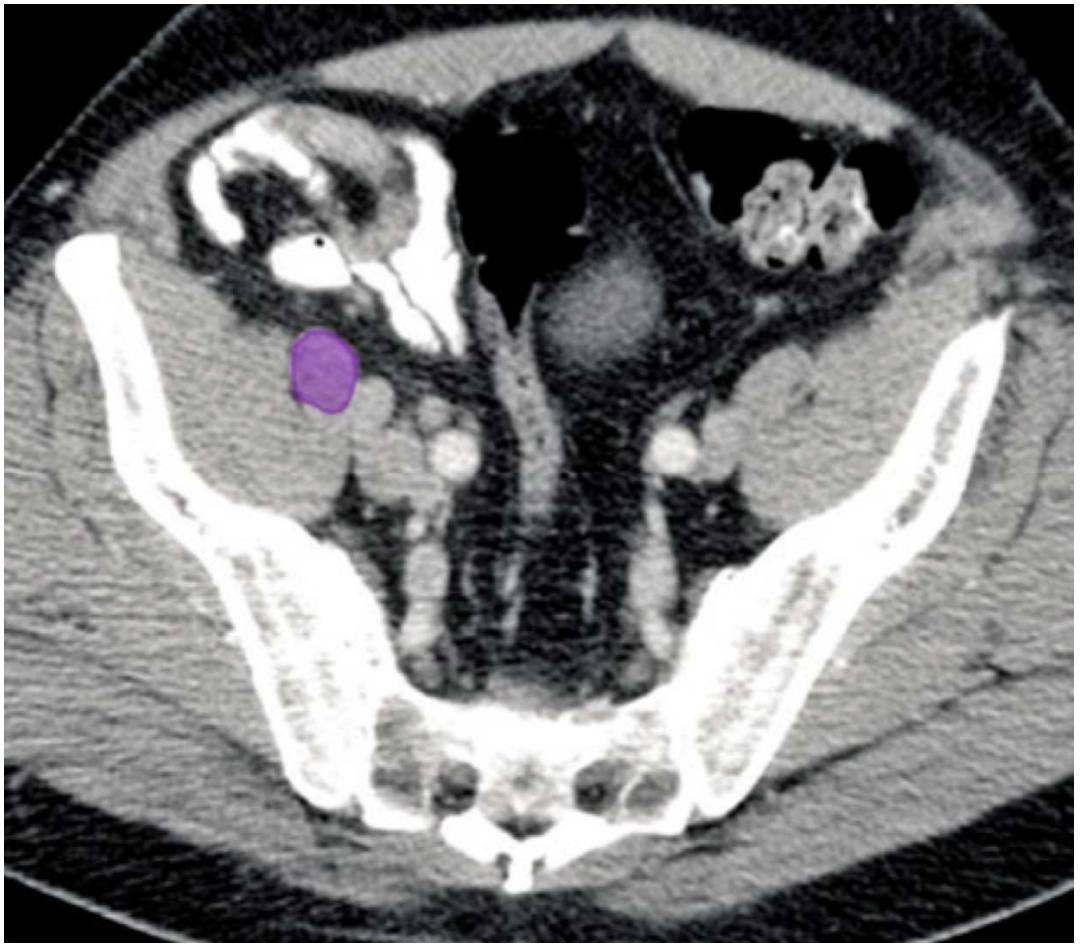

Internal iliac lymph node

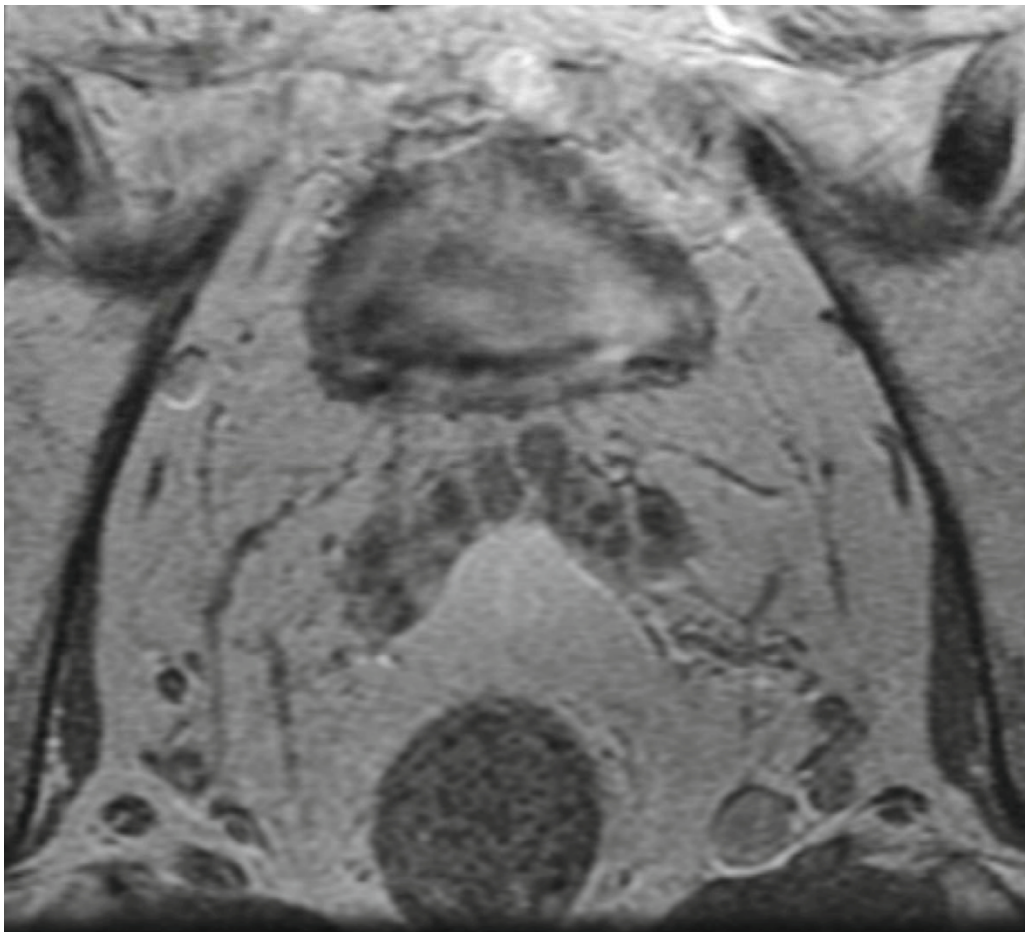

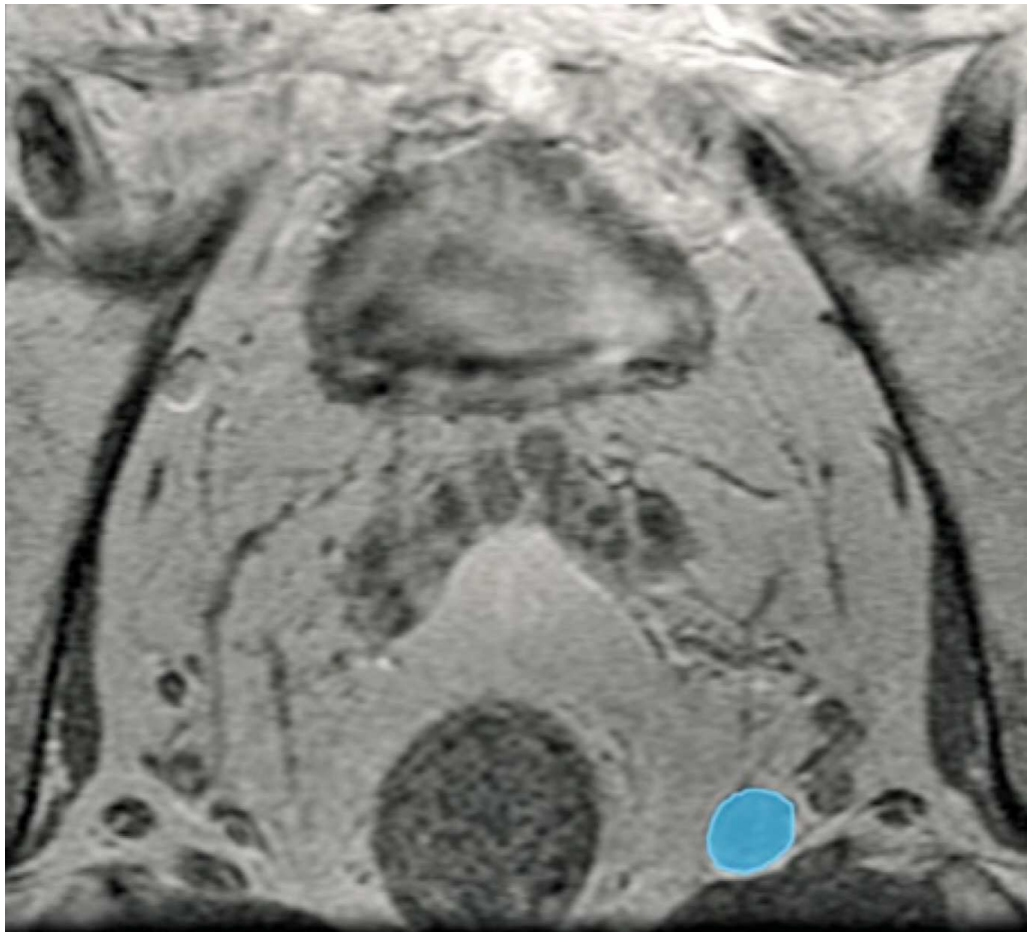

ESTRO School

Presacral lymph node

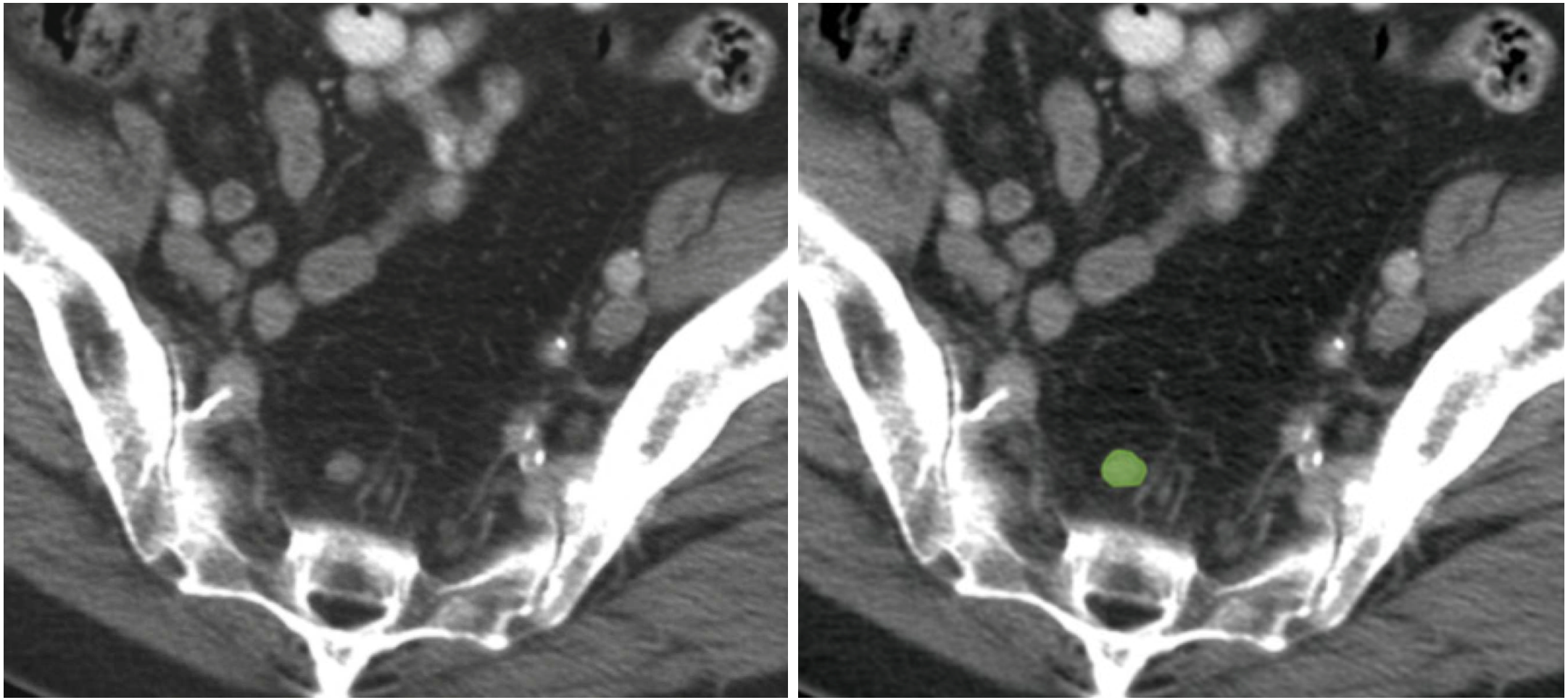

Common iliac lymph node: M1

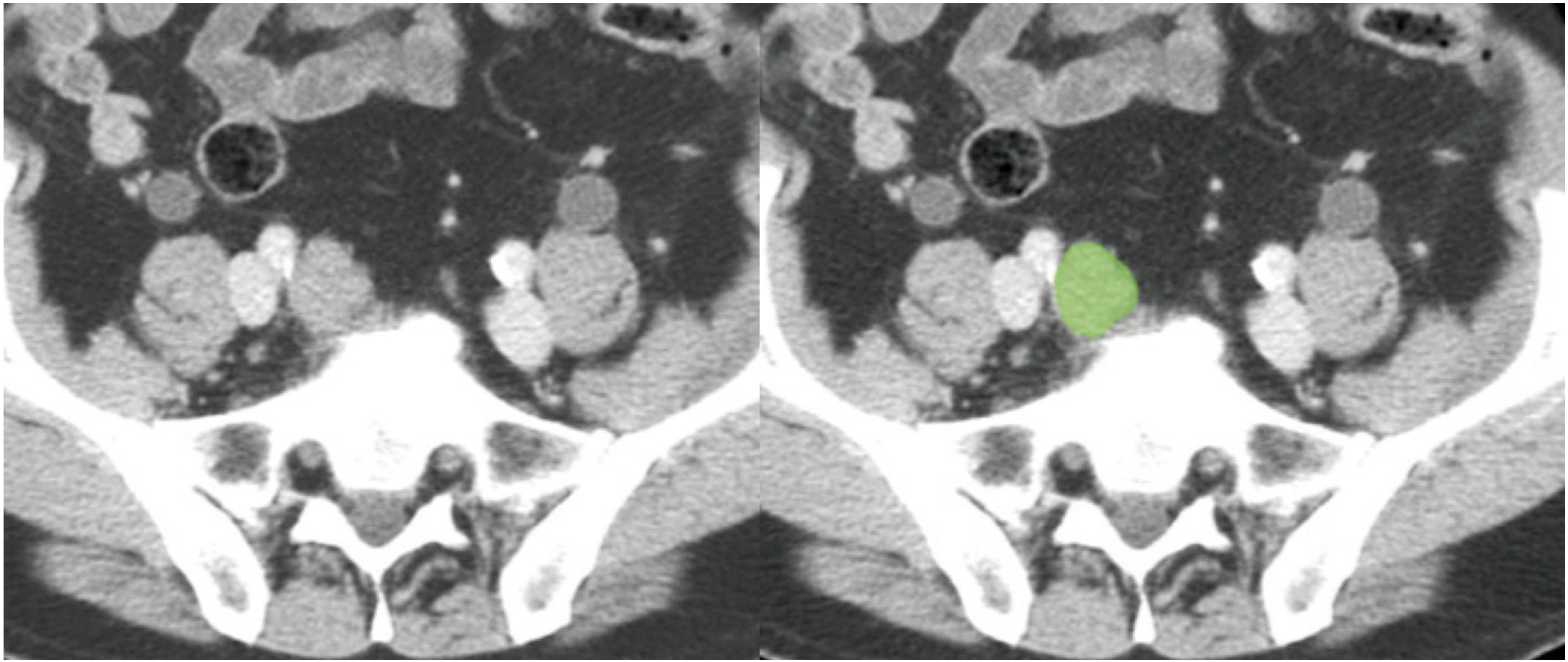

Accuracy for lymph node metastases

50 : 50

ESTRO School

POSSIBLE REMEDIES

Dynamic, contrast-enhanced MRI

- Description of signal time curve
- Pharmacokinetic 2-compartmental model

Prostate carcinoma



Benign hyperplasia

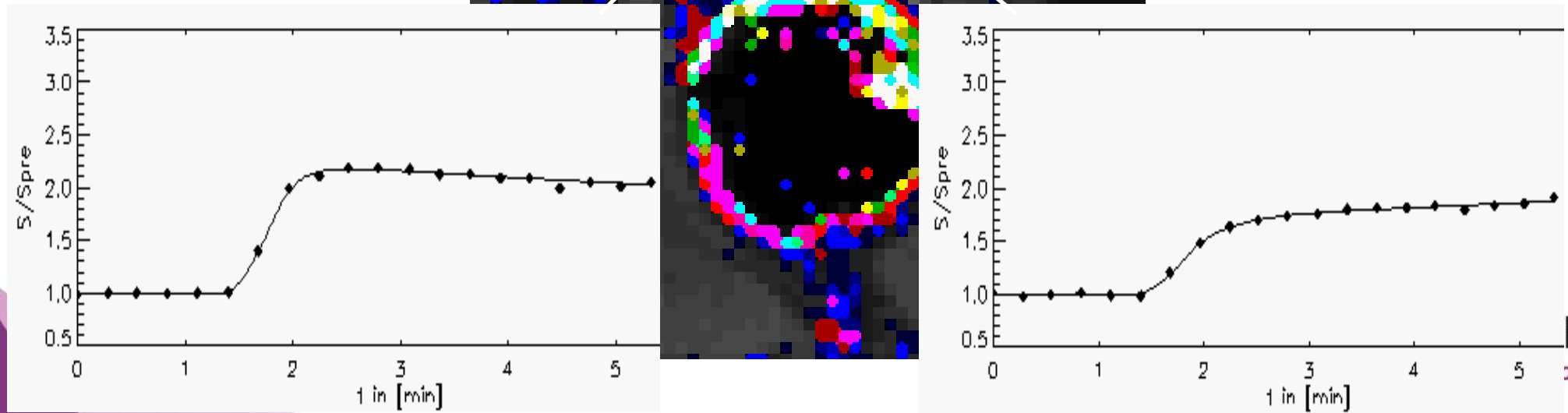

High-resolution Contrast MRI

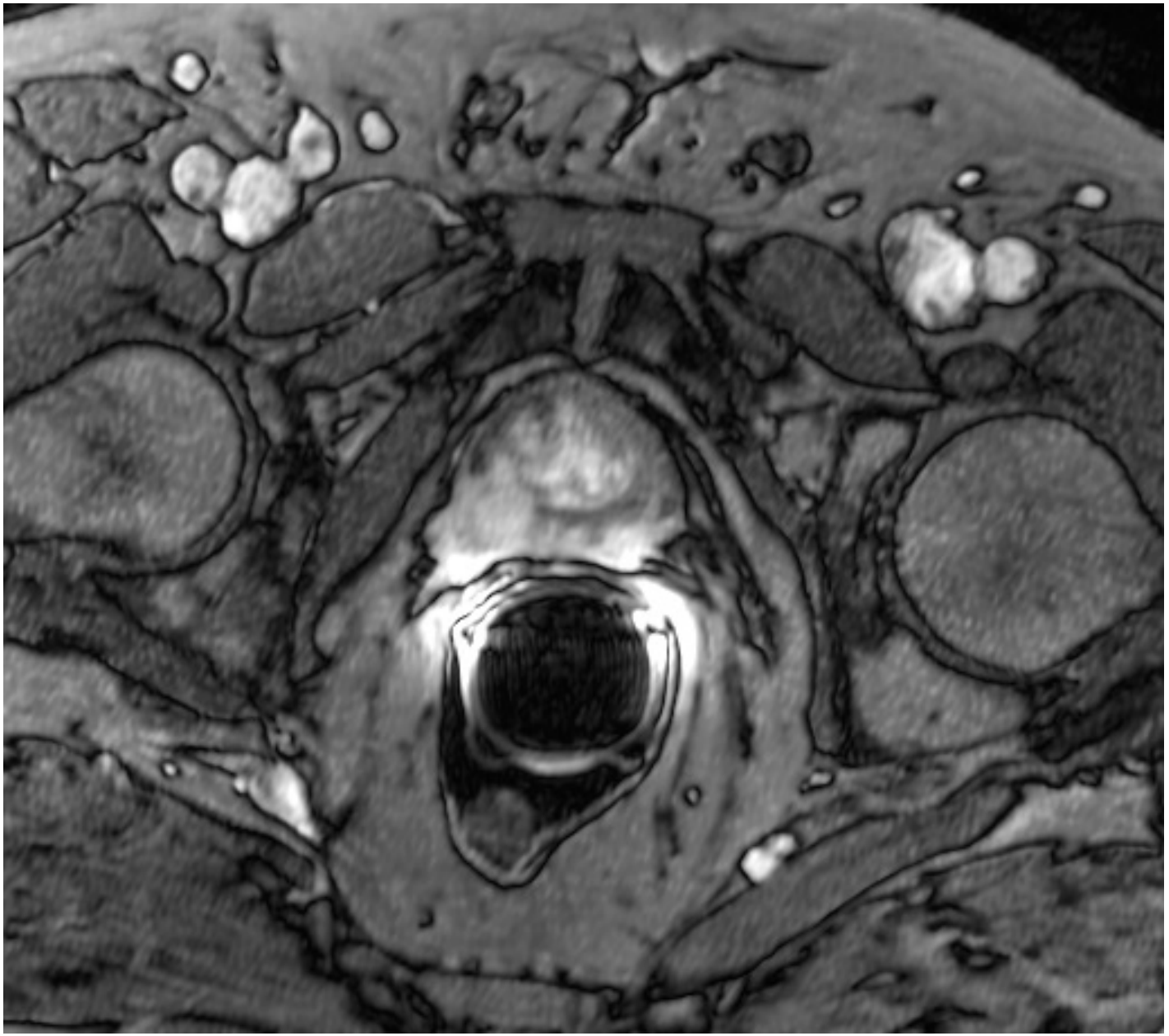

ESTRO School

Spectroscopy

- Metabolites:
  - Choline (Cho) = Proliferation marker
  - Citrate (Ci), produced by prostatic cell
    = specific marker for vital glandular tissue
  - BPH: Citrate moderately decreased
  - Carcinoma: Citrate decreased, choline increased

ESTRO School

MRS in prostate cancer

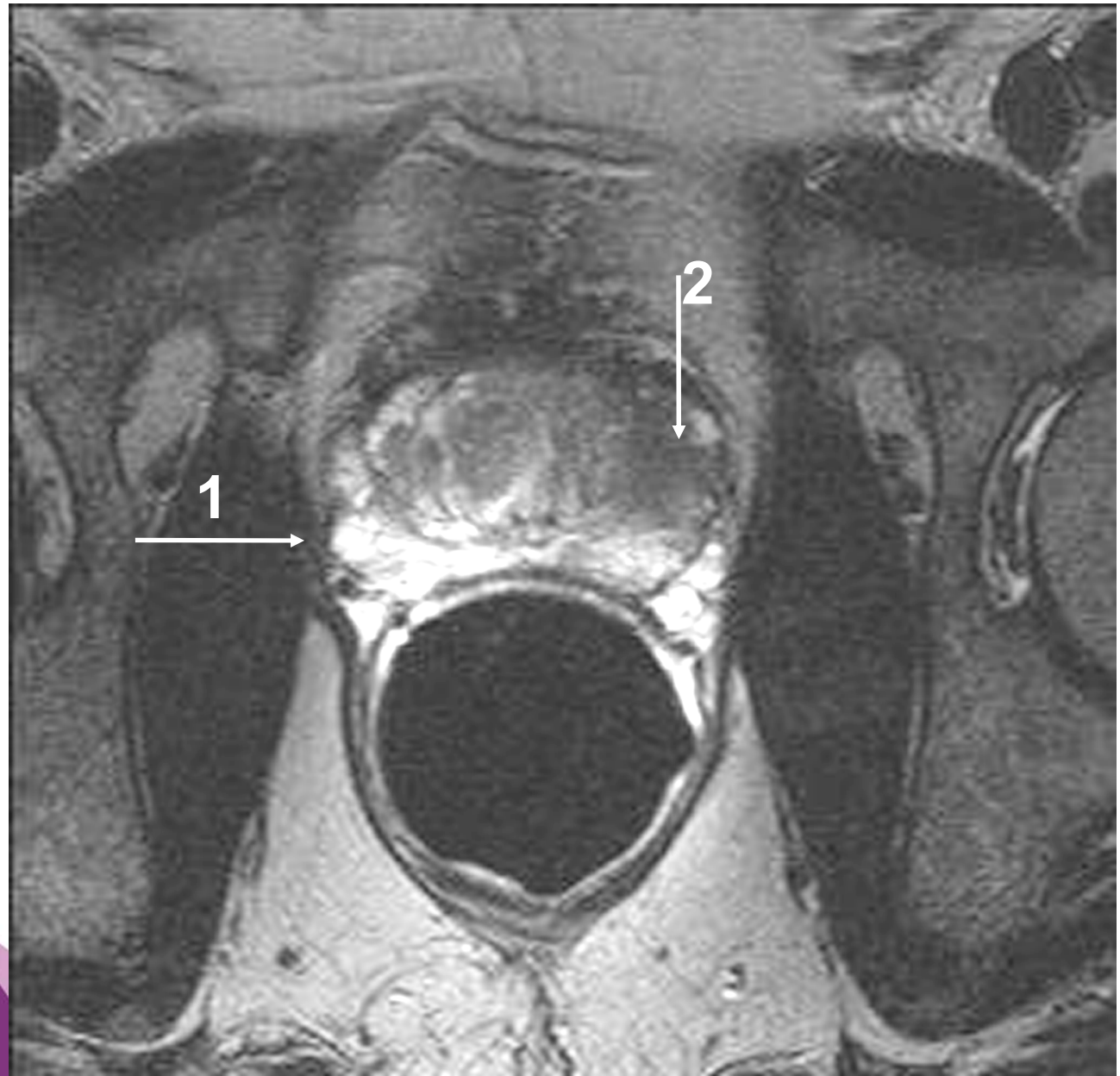

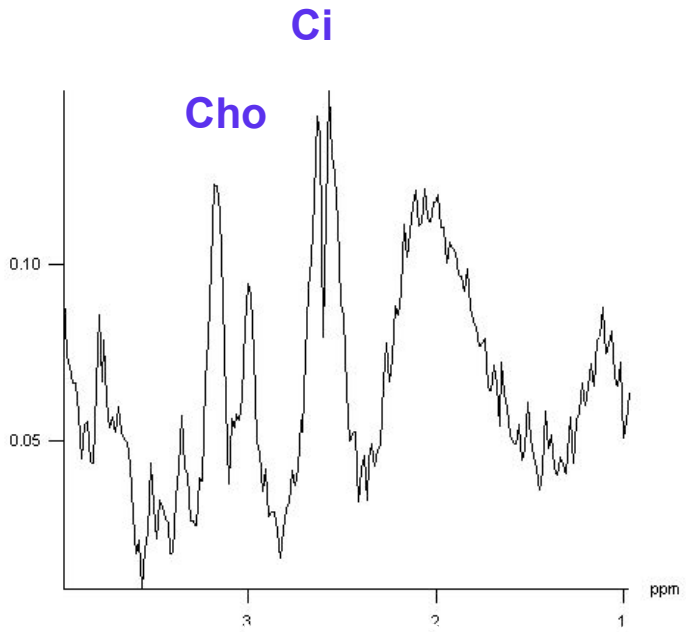

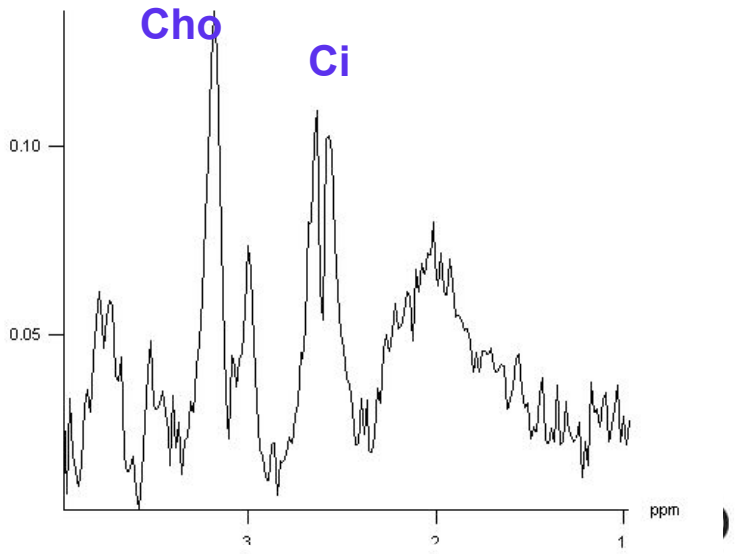

Prostate carcinoma: T2

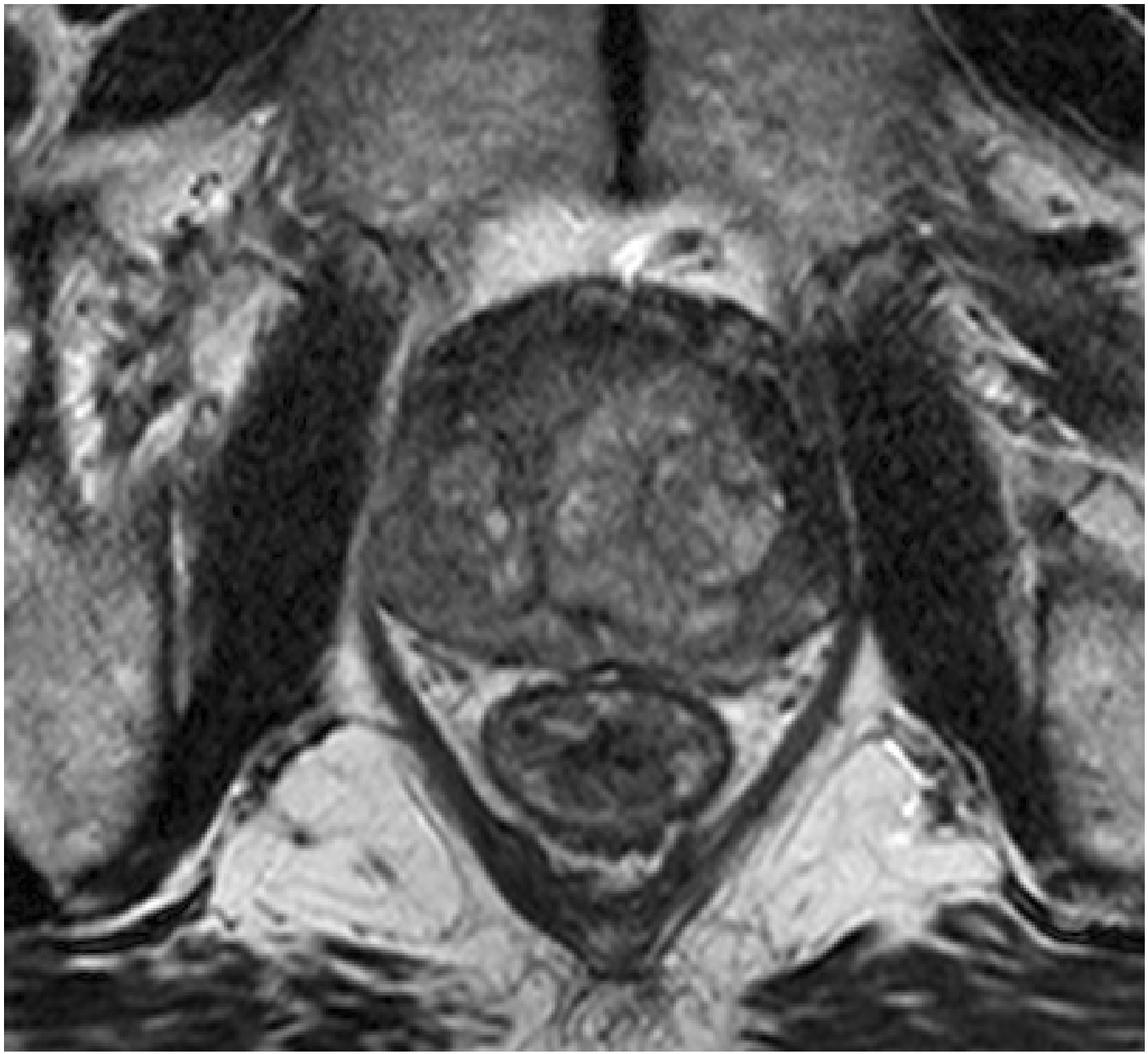

Prostate carcinoma: DCE-MRI

Prostate carcinoma: DWI (ADC map)

ESTRO School

FDG-PET

- T-Staging: Detection
- Sensitivity
  - localized disease 67%
  - advanced disease 92%
- Limitations
  - Low glucose uptake
  - Large overlap between tumor and benign hyperplasia
  - Renal excretion of FDG into the bladder

Choline PET

- Better than FDG-PET
- Still overlap between tumor and benign hyperplasia
- N-Staging
  - Sensitivity 80%,
  - Specificity 96%
  - CT+MRI: Sensitivity 47%, specificity 98%

ESTRO School

PSMA PET

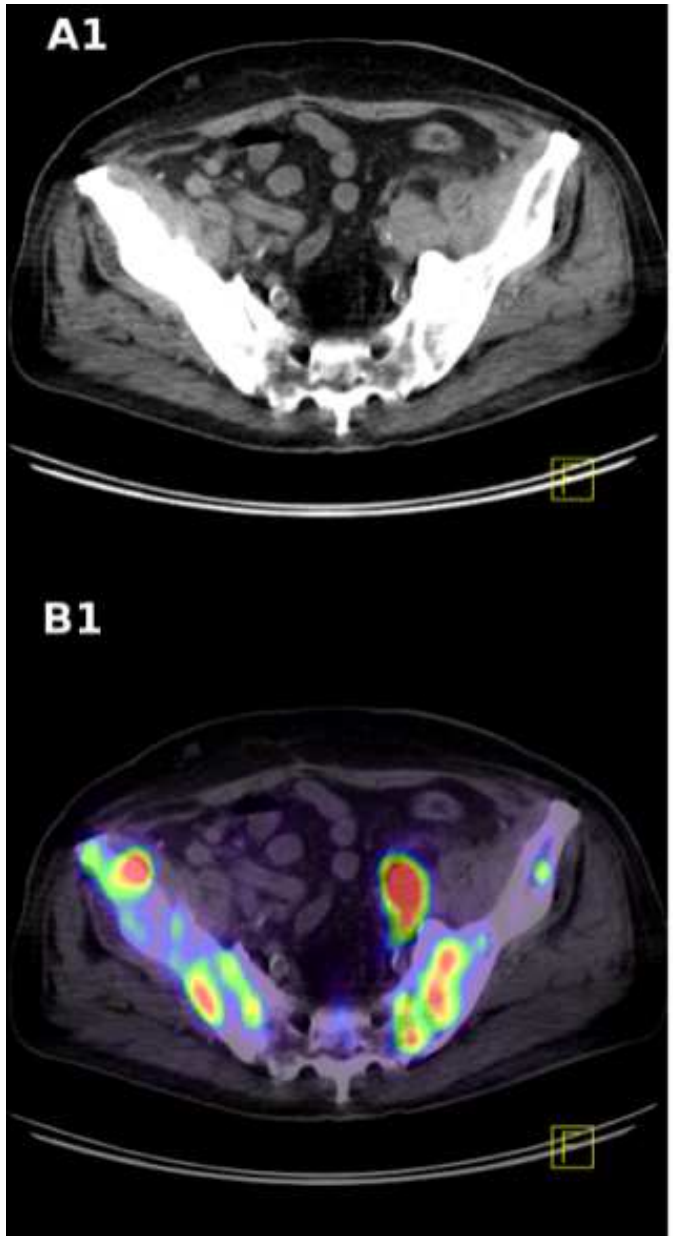

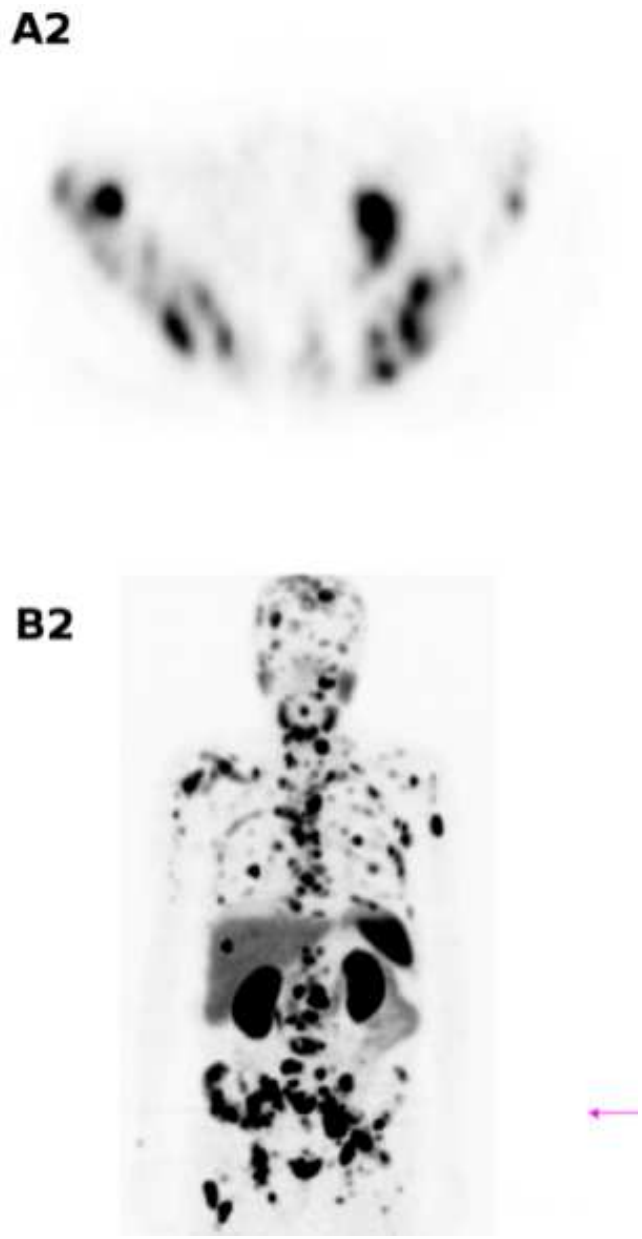

Eder M et al. Bioconjugate Chem 2012; 23: 688-697.
Afshar-Oromieh A et al. Eur J Nucl Med Mol Imaging 2013; 40: 486-495.

ESTRO School

New methods - new love

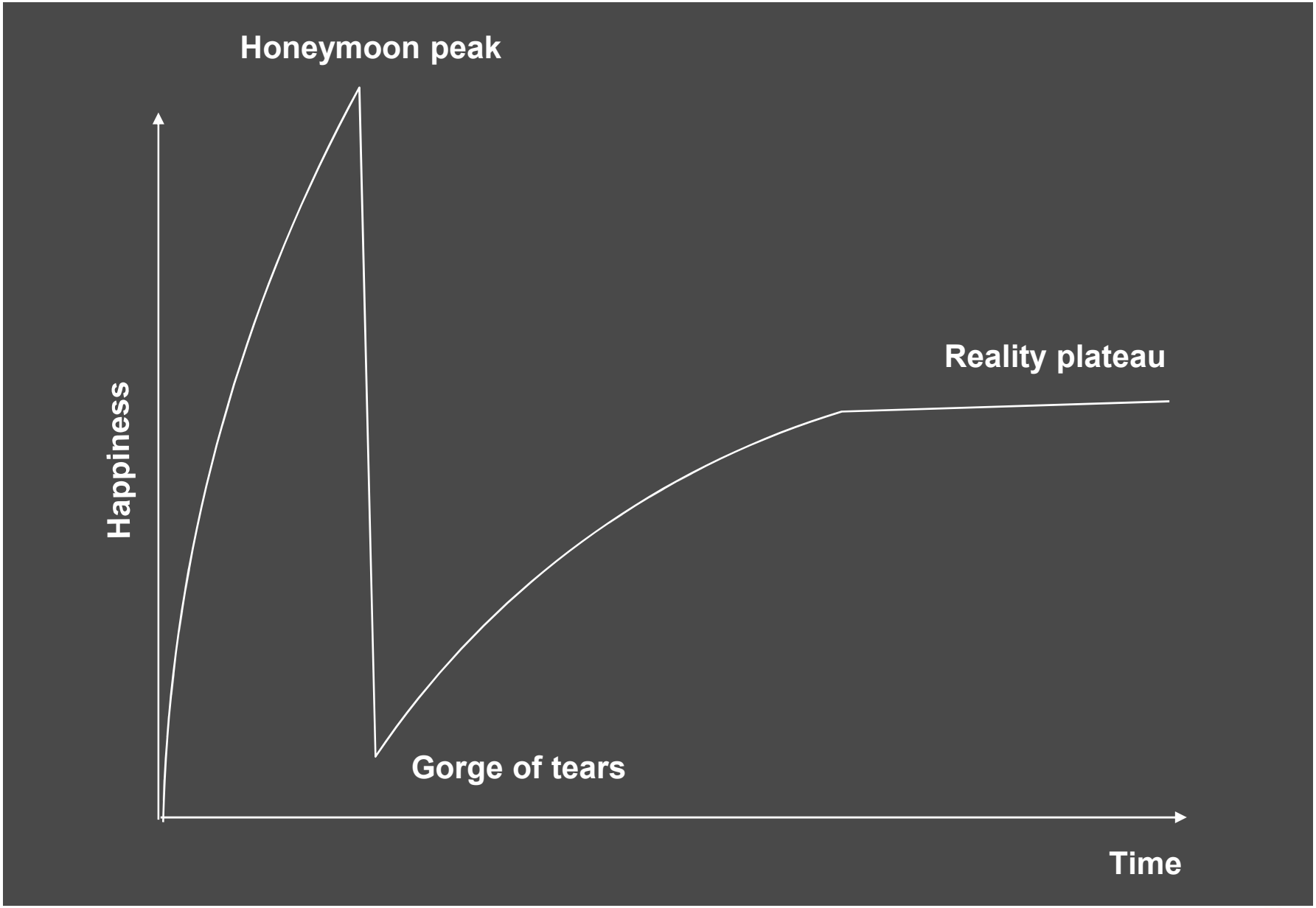

ESTRO School

DIFFICULT CASES

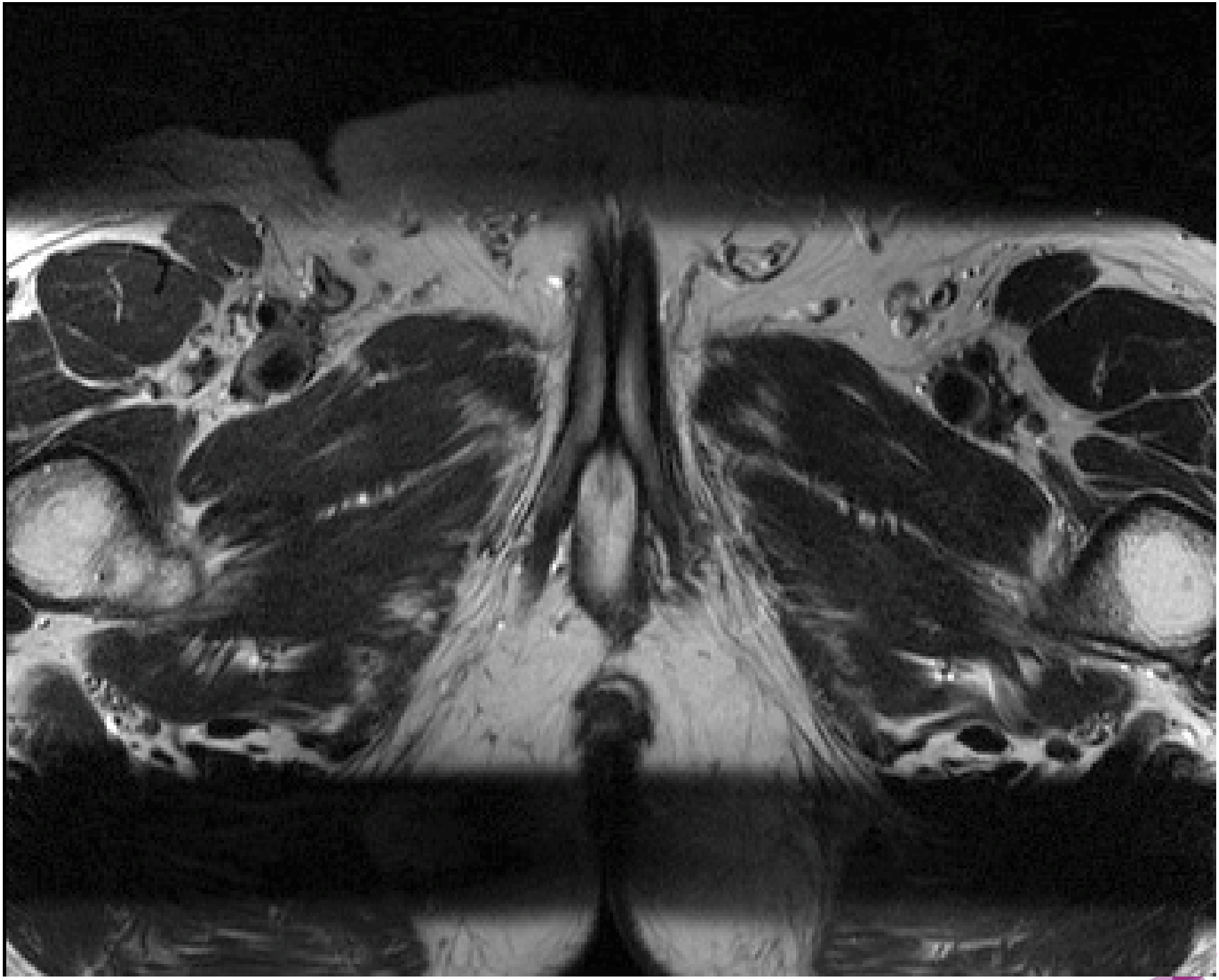

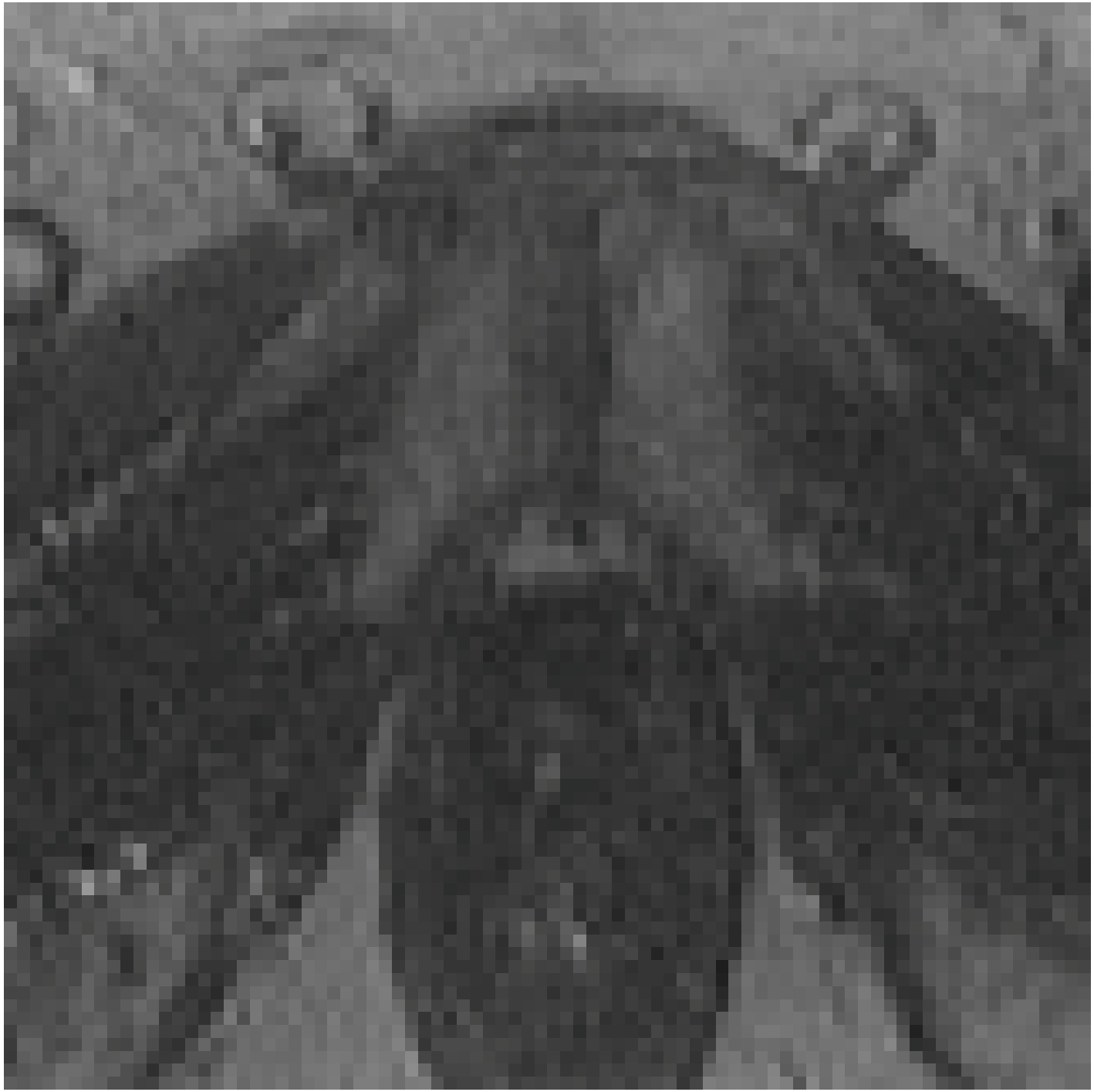

ESTRO School

I don’t see a forest - too many trees!

Second look

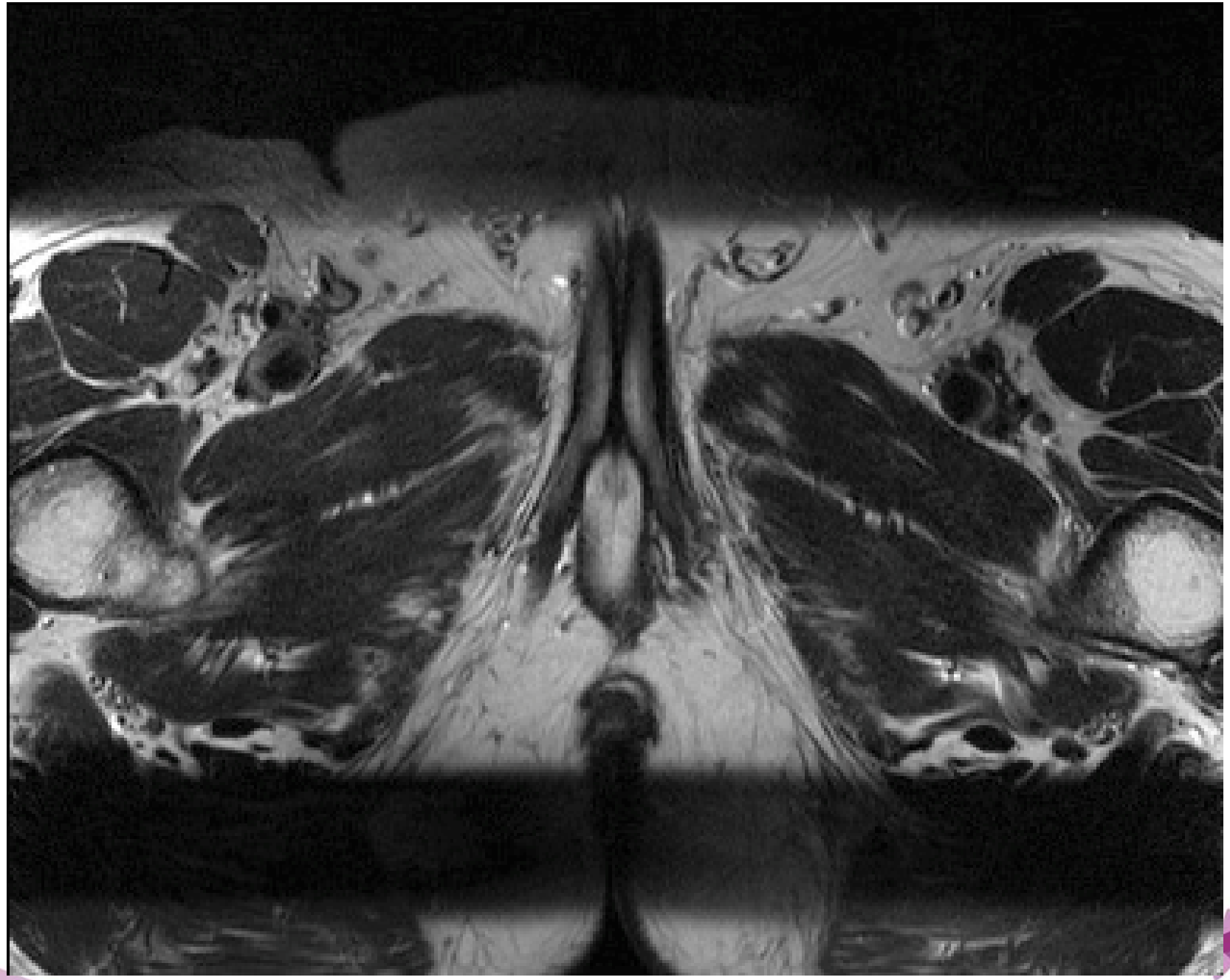

ESTRO School

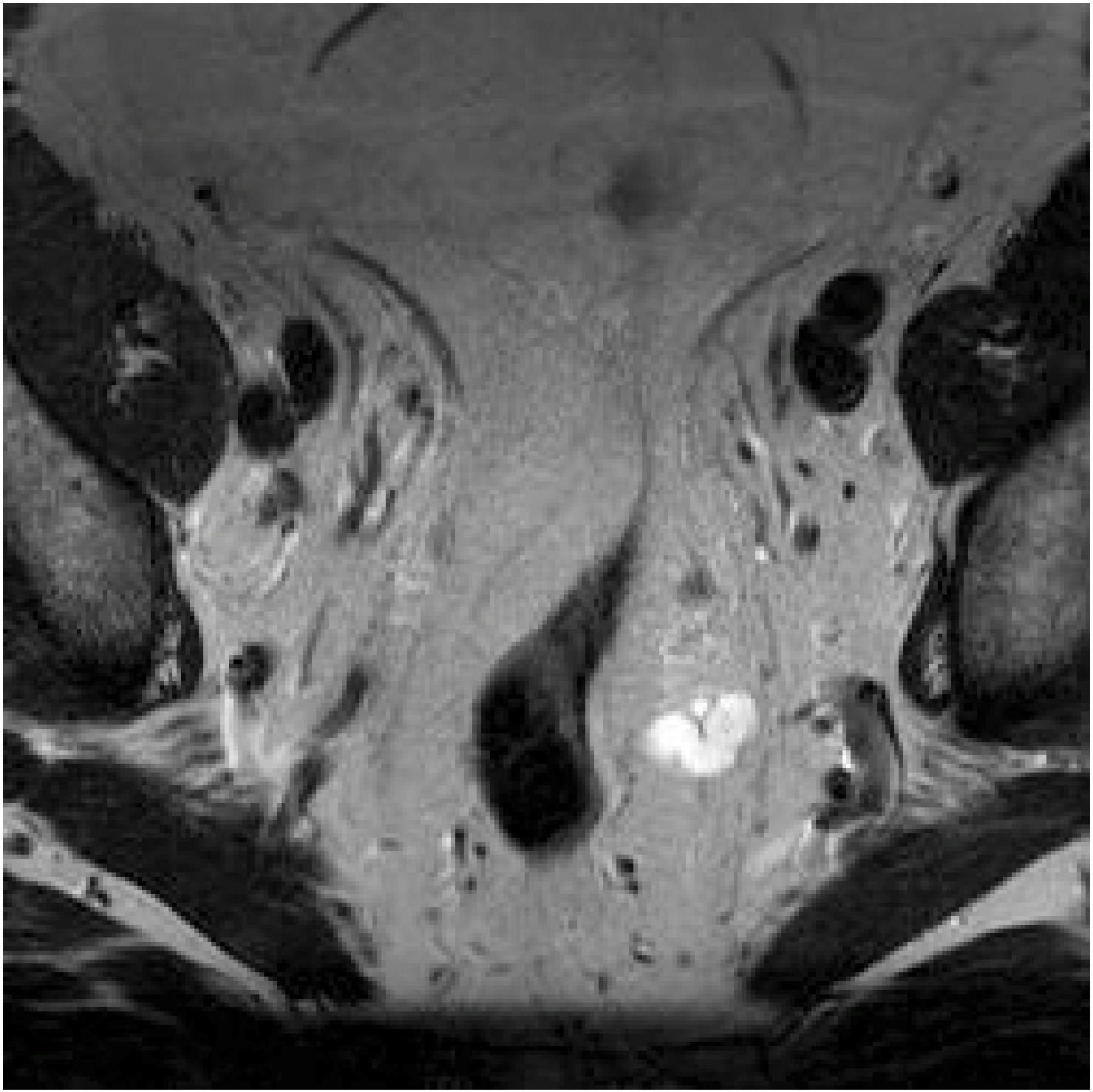

ESTRO School

Ventral prostate carcinoma

Needle in a haystack

ESTRO School

Very small carcinoma

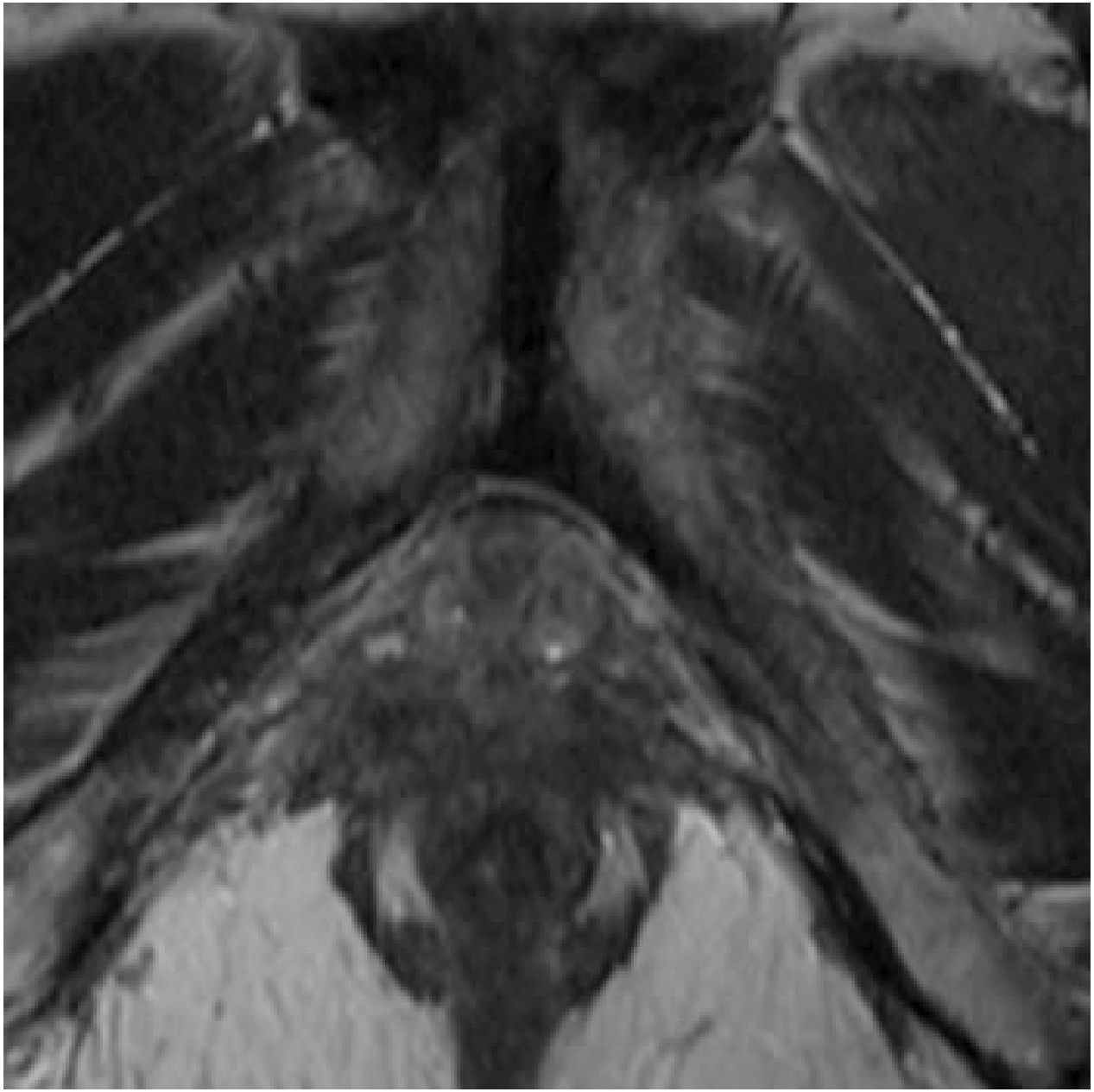

Very small carcinoma

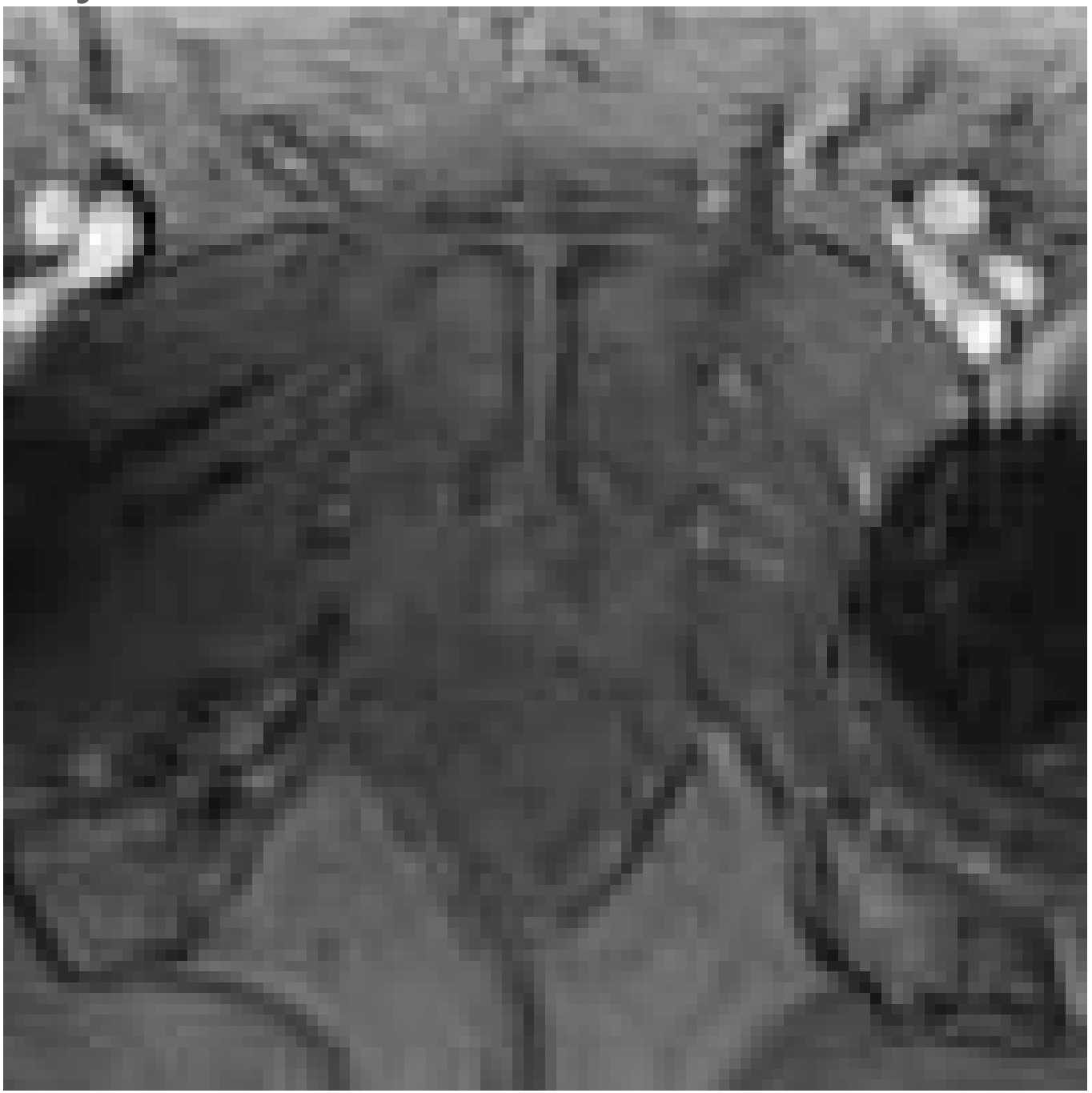

ESTRO School

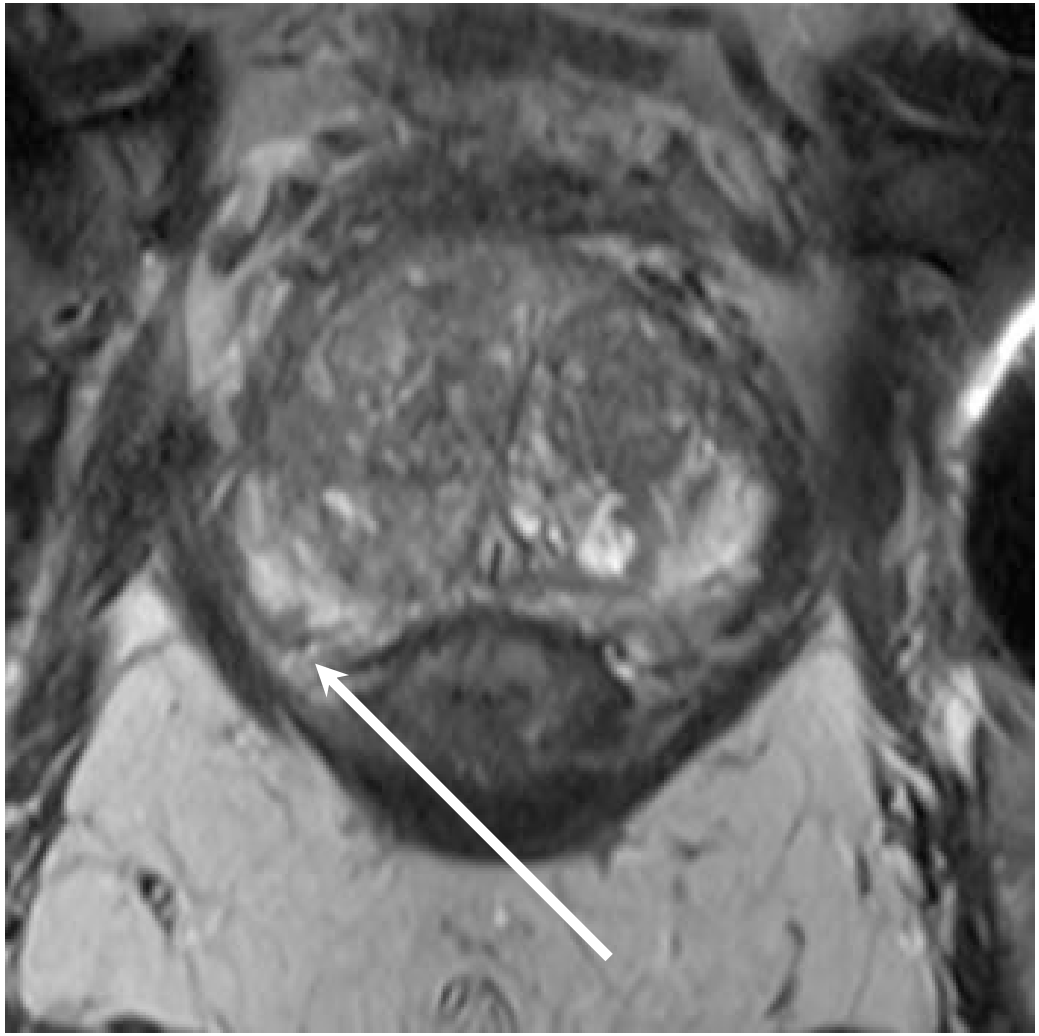

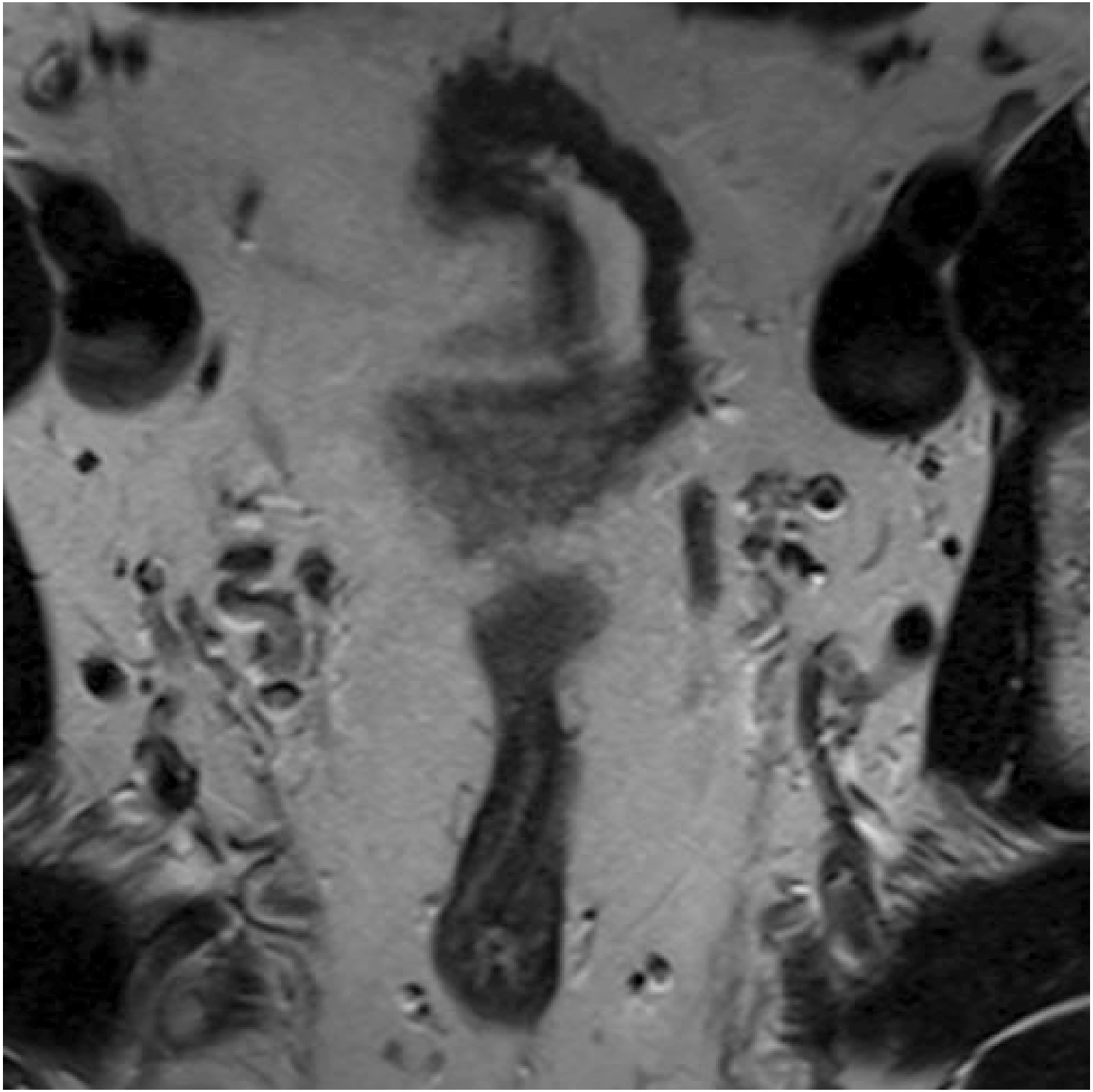

ESTRO School

Central prostate carcinoma

Mimickry

Response assessment: What we would expect

- T2: Reduced conspicuity
  - Loss of tumor mass
  - Reduced water content of peripheral zone
- DCE MRI: Reduction of CM uptake
  - Decreased angiogenesis
  - … But counteracted by inflammation
- DWI: Reduced conspicuity, increase in ADC
  - Loss of cellular density
  - … But contaminated by T2 effects

T2

DCE MRI

DWI

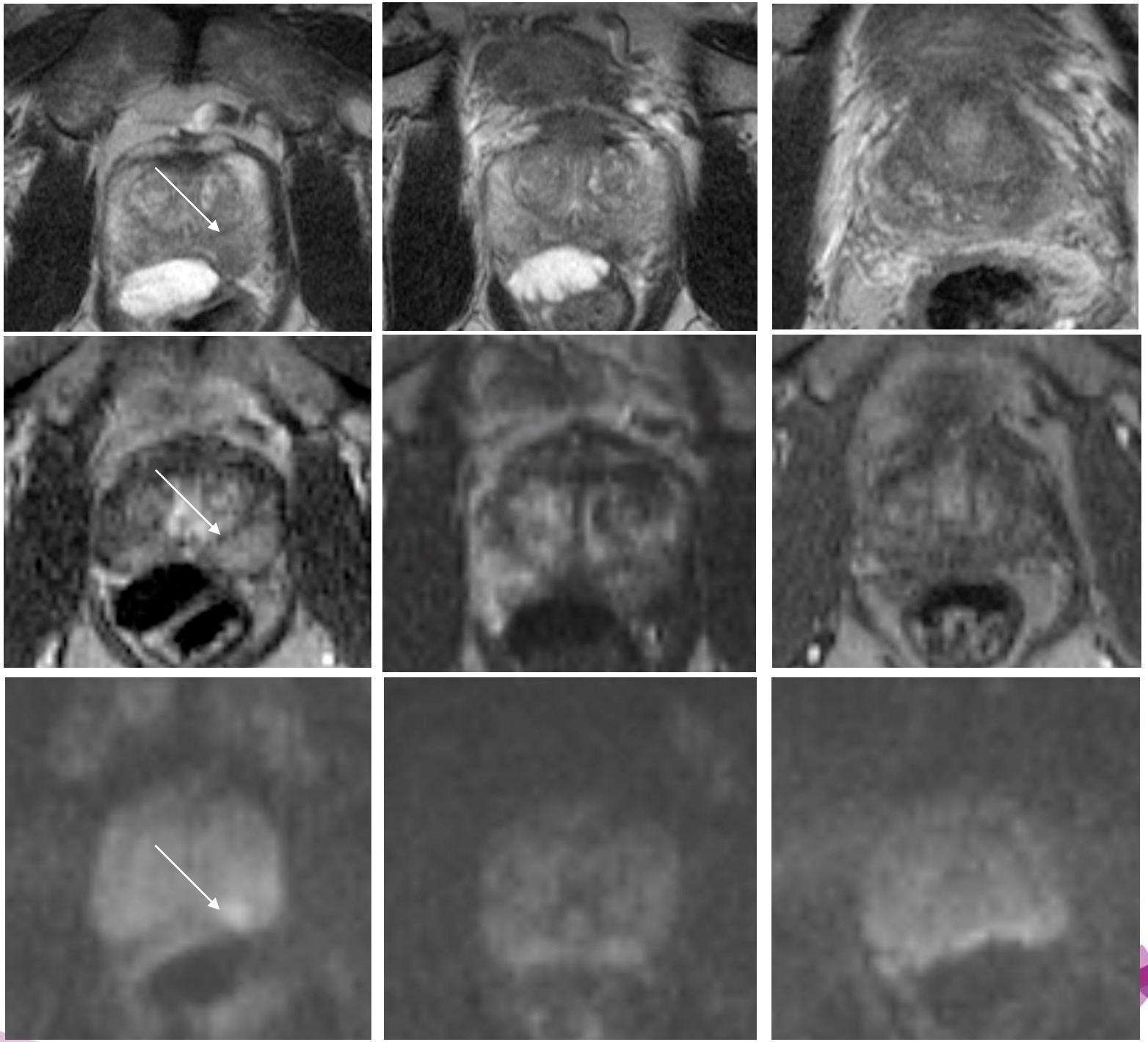

ESTRO School

T2 pre and post radiation

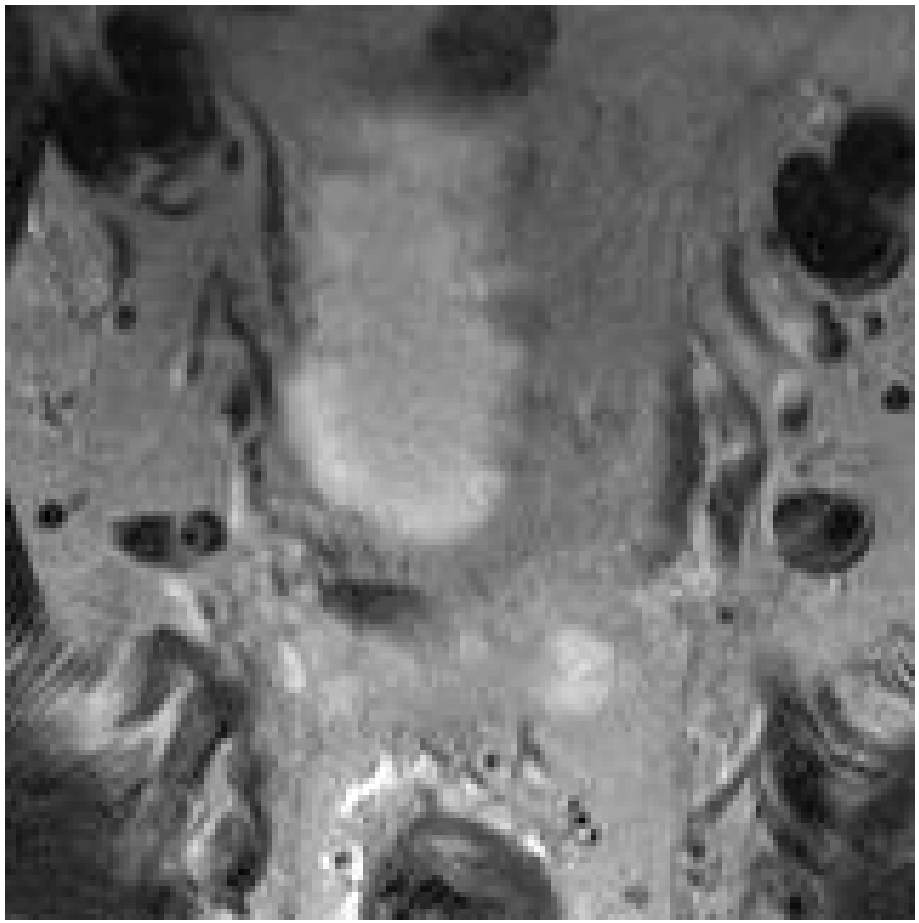

Pre

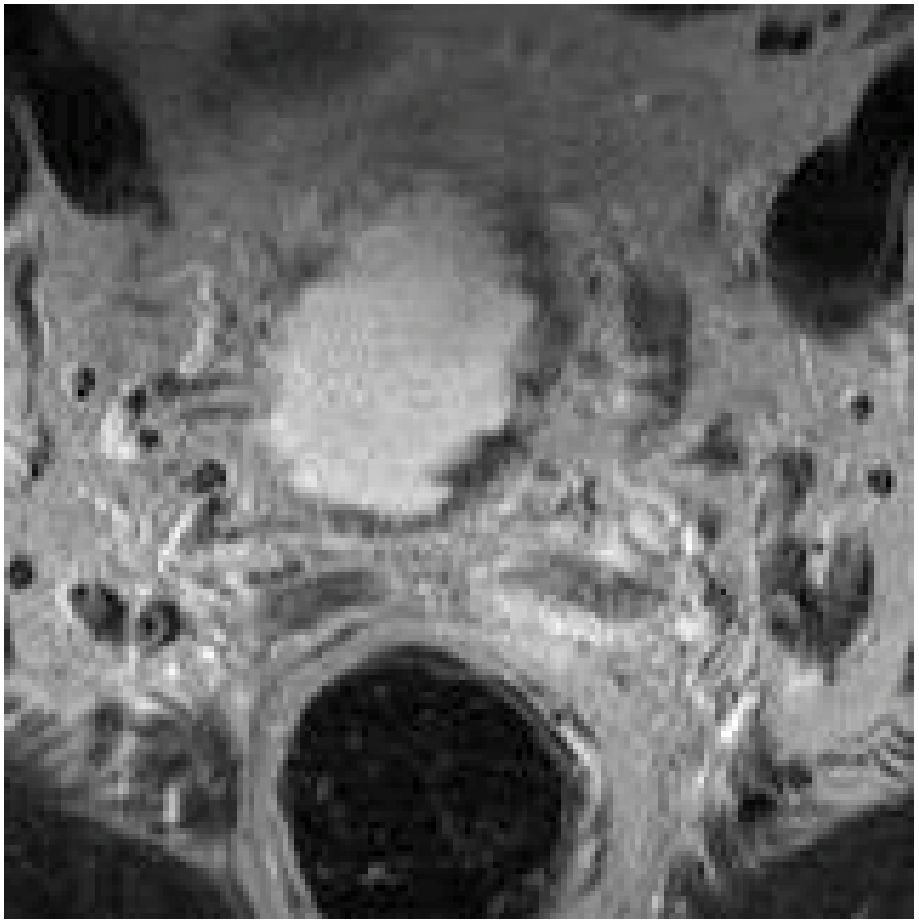

Post

ESTRO School

DWI pre and post radiation

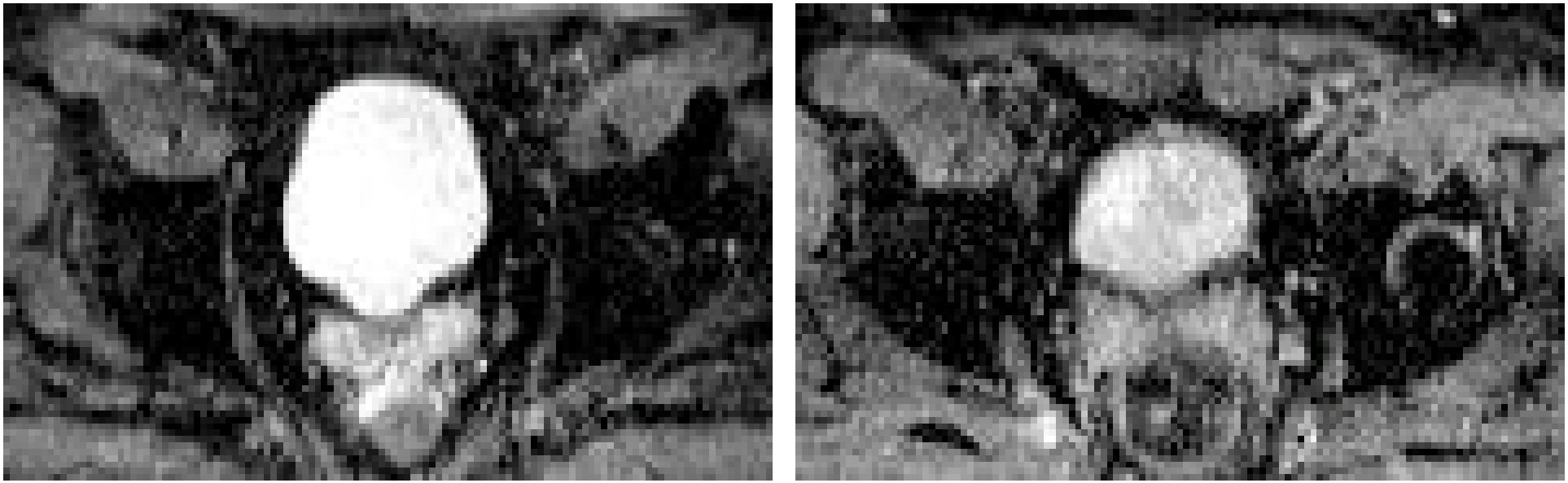

Radiation-induced changes

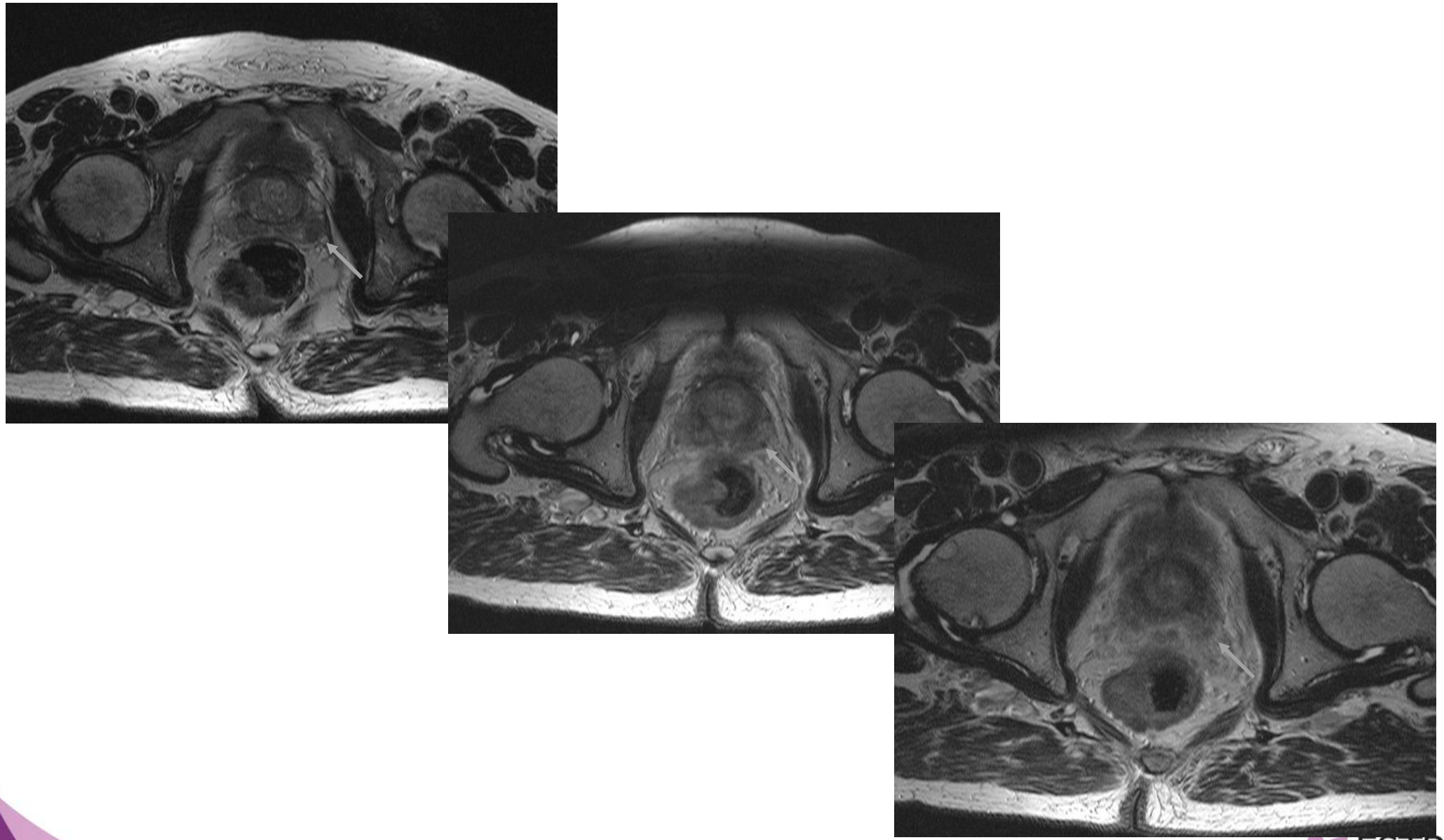

Oncological Guidelines: Imaging

- CT of the abdomen
- MRI of the pelvis
- Chest x-ray if PSA > 20 ng/ml, or high risk patients
- Bone scintigraphy if PSA > 10 ng/ml

Take home

- CT is limited for
  - T-stage
  - Extracapsular extension
  - N-stage
- MRI method of choice for
  - T-stage
  - Extracapsular extension
  - Localization of leading tumor mass, if present
- PET requires dedicated tracers for improved T- and N-staging
  - C-11 Choline
  - Ga 68 PSMA

ESTRO Course: TVD from Imaging to Margins – Lisbon 2017

CTV for Prostate Cancer & OARs Primary Setting

VINCENT KHOO

Royal Marsden Hospital & Institute of Cancer Research
St George's Hospital & University of London
ONJCC & Austin Health, University of Melbourne & Monash University

THE ROYAL MARSDEN

St George's Healthcare NHS Trust

Austin Health

ICR The Institute of Cancer Research

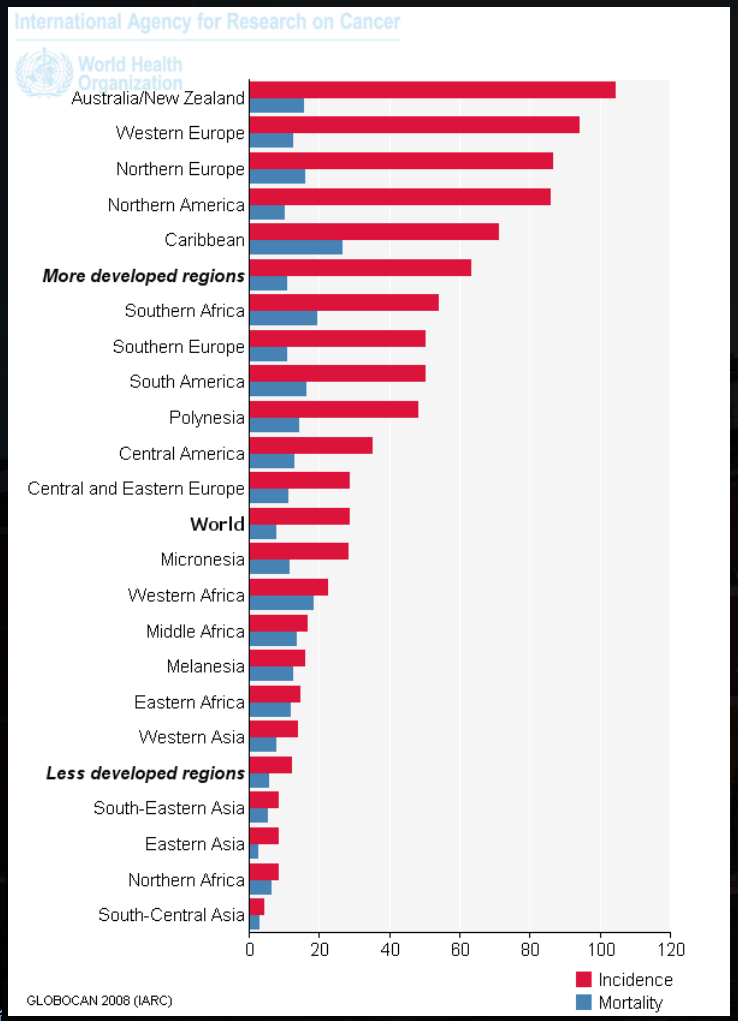

PC Statistics

- 2nd most diagnosed cancer in men
- 5th most common cancer overall
- 6th most common cause of death in men

Incidence:

- Western societies: 104 per 100,000
- South Central Asia: 4 per 100,000
- Variation in incidence (25x) different from mortality (10x)

WHO 2008

THE ROYAL MARSDEN

Target Volume(s) in Prostate Cancer

- **WHY** do we want to treat?
- **WHEN** do we want to treat?
- **HOW** do we want to treat?
- **WHAT** do we want to treat?

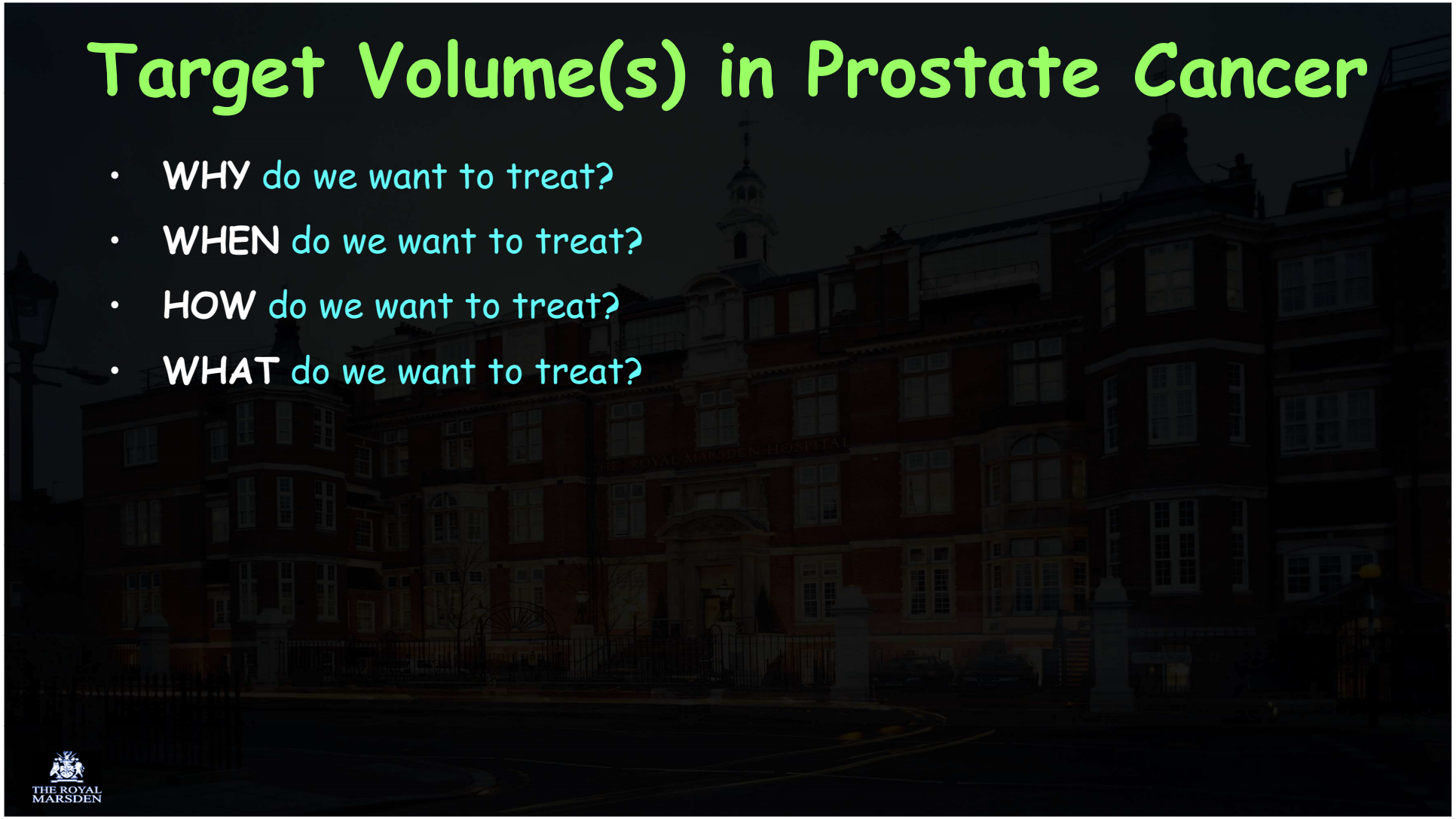

THE ROYAL MARSDEN

Target Volume(s) in Prostate Cancer

- **WHY** do we want to treat?

PC Stage IIIA
EORTC 22863 Trial

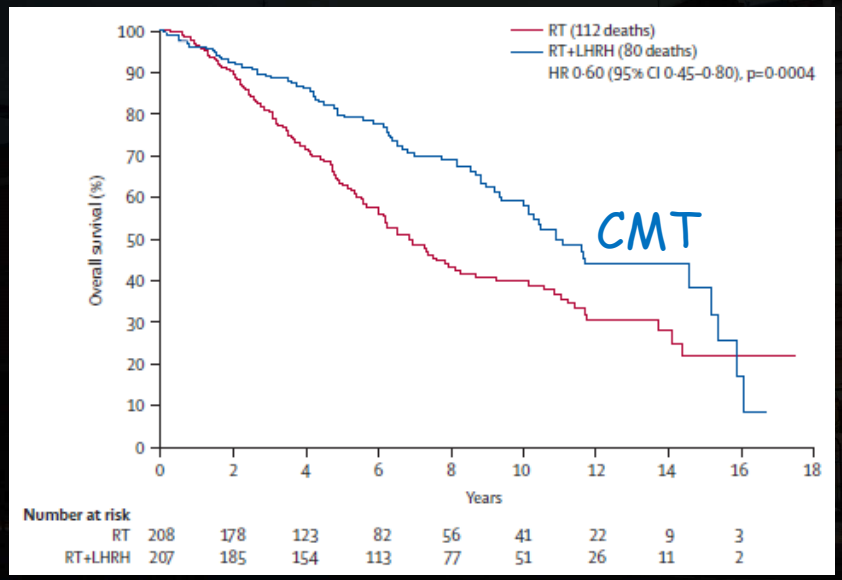

Bolla et al Lancet Oncol 2010

PC T1-2, PSA ≤10, GI ≤6
RTOG 0415 Trial

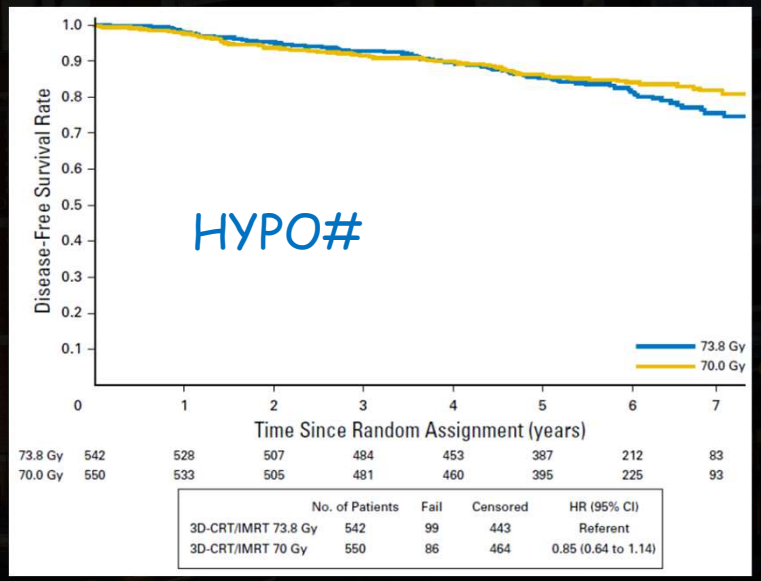

Lee et al JCO 2016

THE ROYAL MARSDEN

Target Volume(s) in Prostate Cancer

- **WHEN** do we want to treat …….?

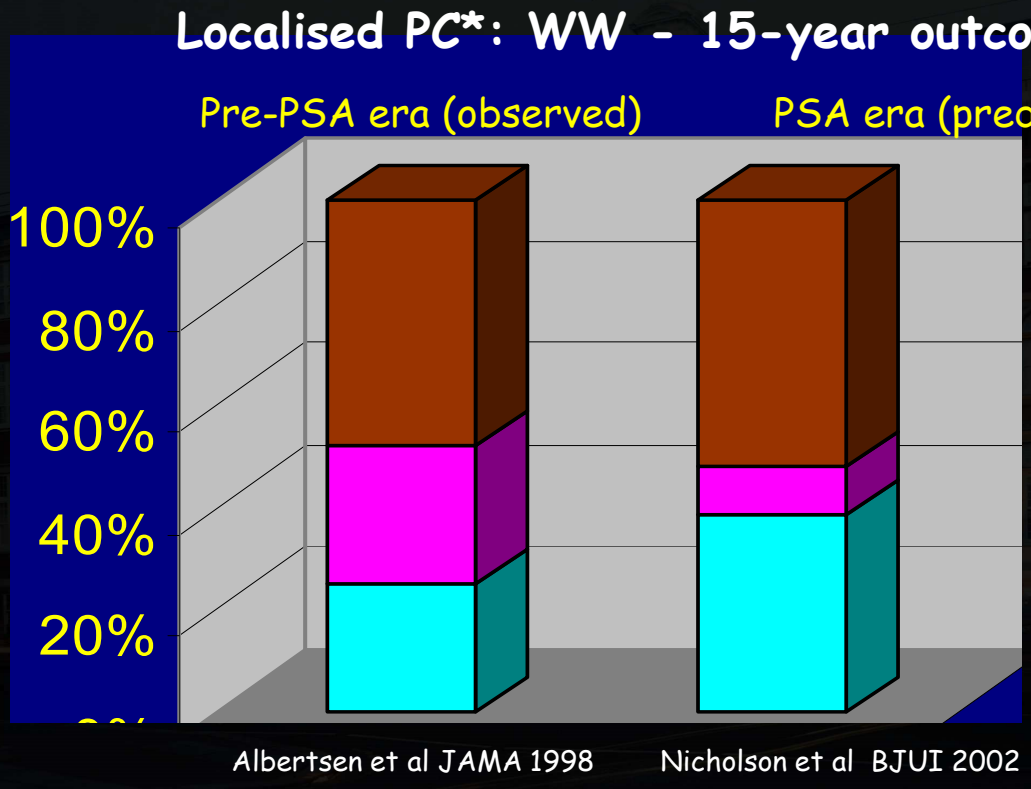

- Gleason 6
- age 65-70 at diagnosis

THE ROYAL MARSDEN

PC: Metastatic Origins

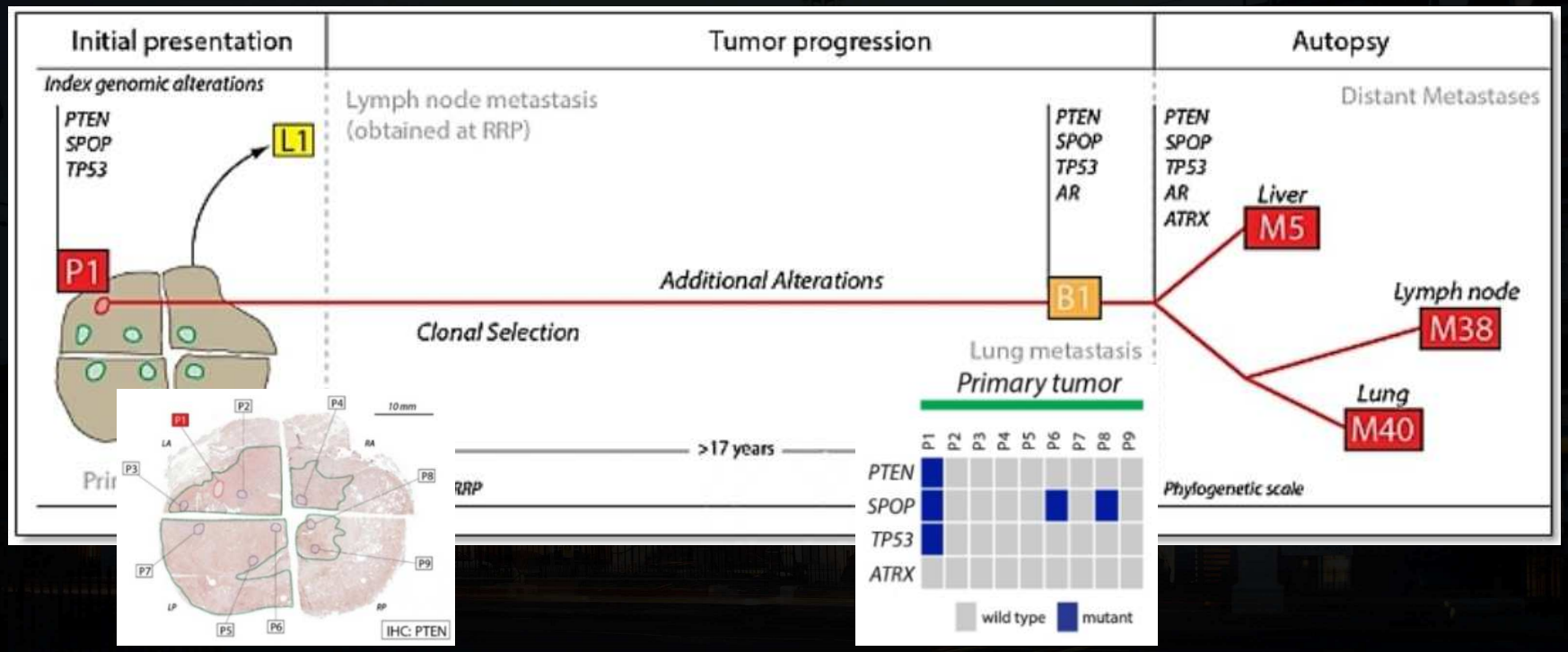

Haffner et al. JCI 2013

THE ROYAL MARSDEN

CTV in Prostate Cancer

- WHY do we want to treat?
- WHEN do we want to treat?
- **HOW** do we want to treat?
  - Best RT method available with your expertise and at your centre
  - (Brachy, CFRT, IMRT, IGRT, ART …. ?Protons, ?Light Ions)

THE ROYAL MARSDEN

CTV in Prostate Cancer

- WHY do we want to treat?
- WHEN do we want to treat?
- HOW do we want to treat it?
- **WHAT** do we want to treat?
  - ICRU's GTV concept for PC:
  - GTV ≈ CTV
  - Other considerations
    - Inclusion of seminal vesicles?
    - Inclusion of pelvic nodes?

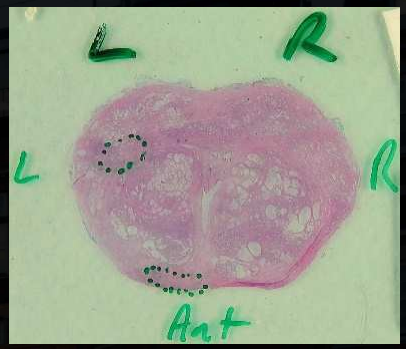

THE ROYAL MARSDEN

CT for Prostate RTP



THE ROYAL MARSDEN

Prostate-Rectal Interface

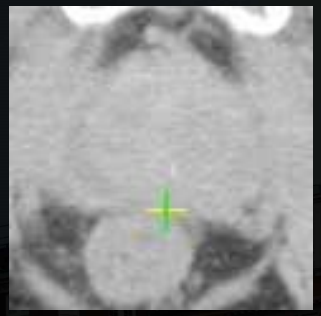
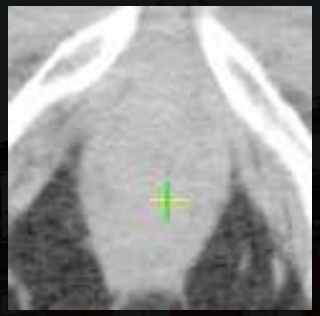
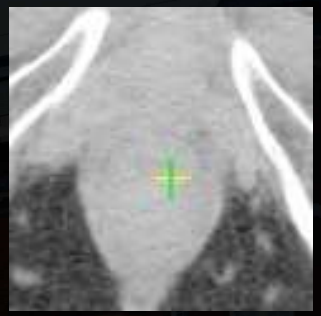
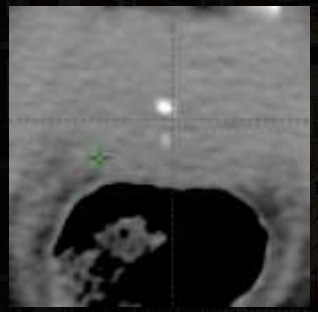
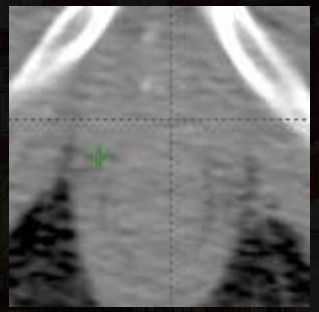

Central Slice Inferior Slice Apex

THE ROYAL MARSDEN

Prostate Volumes: Difficulties?

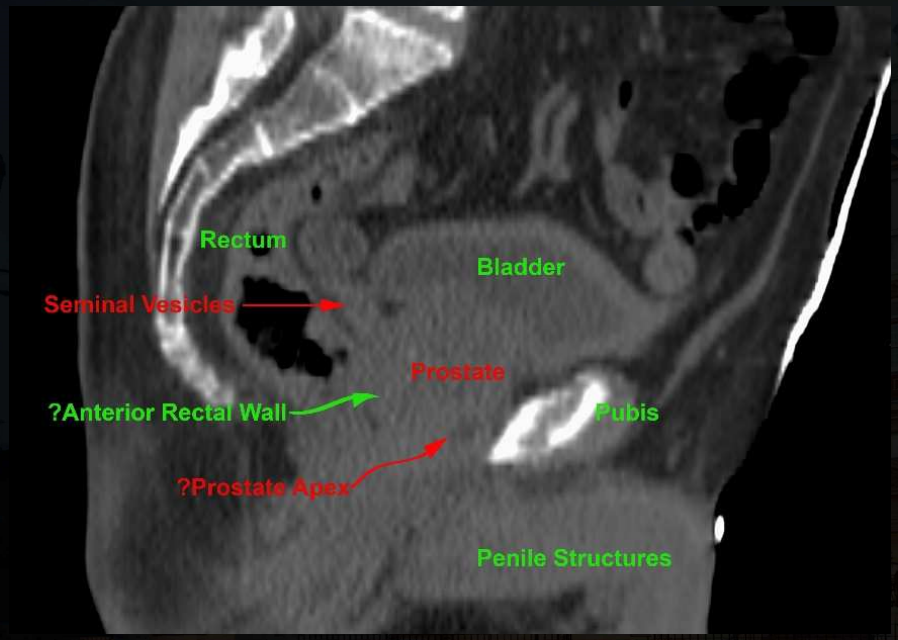

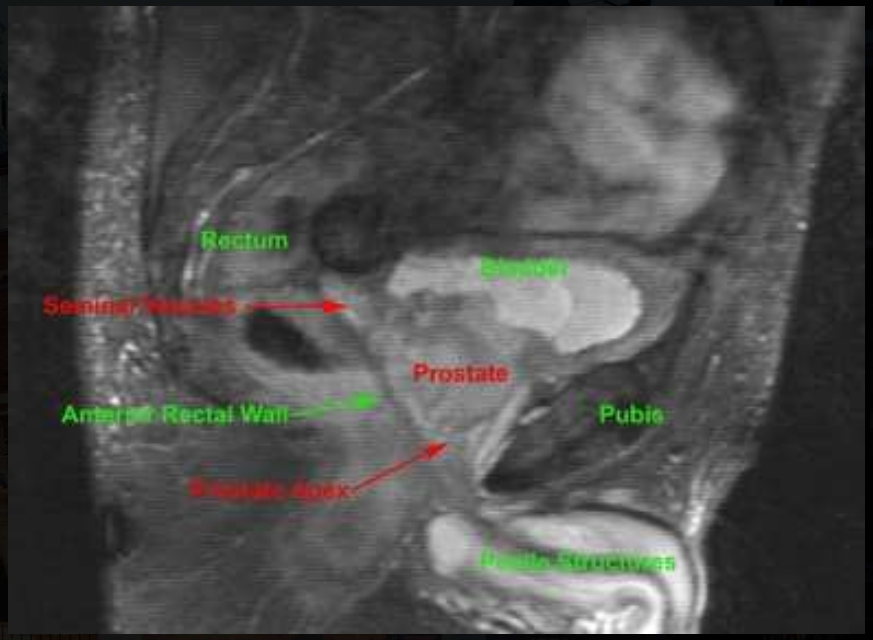

THE ROYAL MARSDEN

JARROC

Khoo & Joon BJR 2006

Prostate planning volume studies
CT vs MRI

Study	No	CTV	CT (cm^3)	MRI (cm^3)	Diff (%)
Roach et al (IJROBP 96)	10	p	38.4	29.6	32
Kagawa et al (IJROBP 97)	22	p ± sv	63	50.9	27
Rasch et al (IJROBP 99)	18	P	63.7	44.5	43
Sannazzari et al (BJR 2002)	8	p ± sv	85.8	63.9	34

THE ROYAL MARSDEN

Value of Appropriate Target Volumes

RMH: Conventional vs. Conformal Trial

PC: T1-4 N0 M0, N = 225

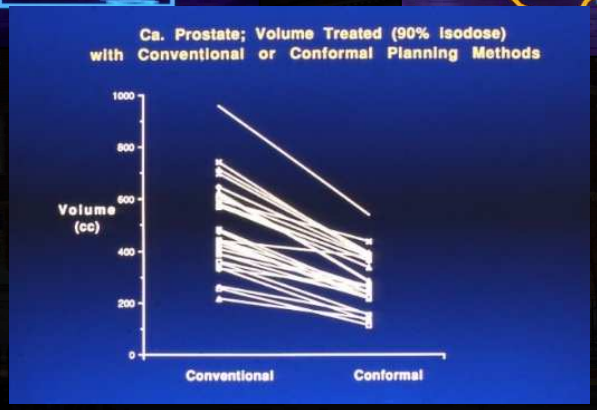

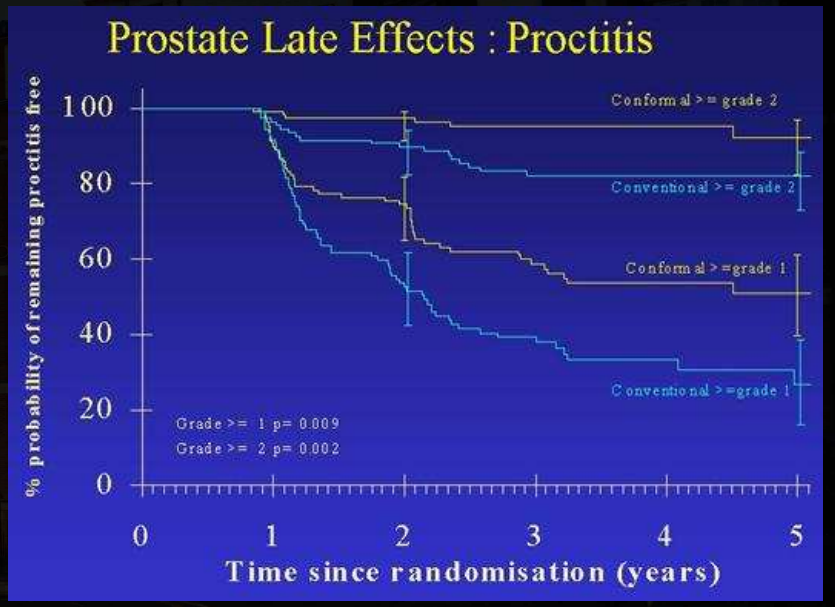

THE ROYAL MARSDEN

Dearnaley et al Lancet 353:267, 1999

RT-01 Trial: Clinician QA: Results

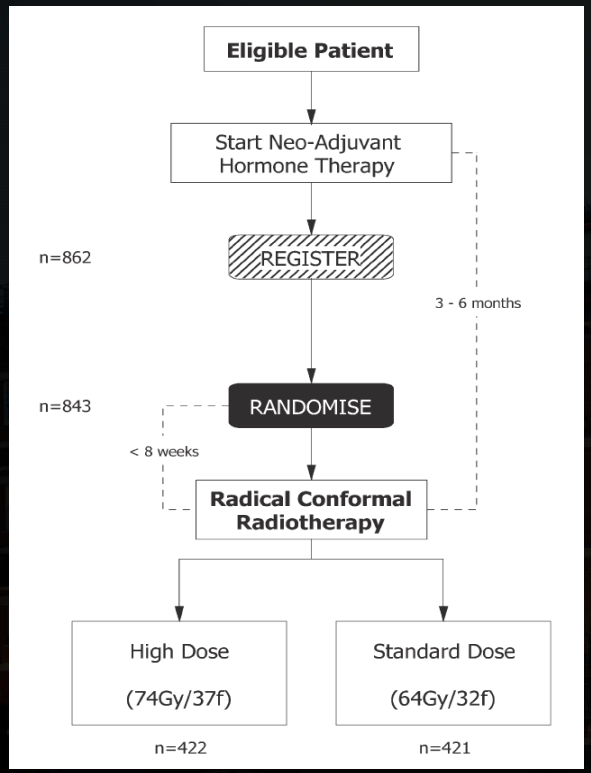

Seddon et al. RO 2000

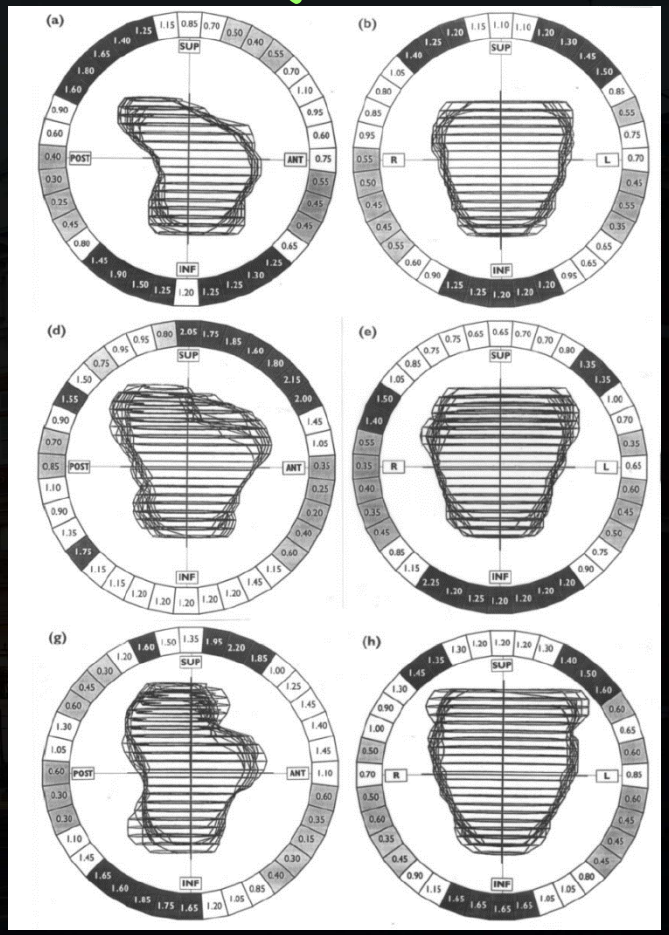

THE ROYAL MARSDEN

TVD Issues: PC & Rectum

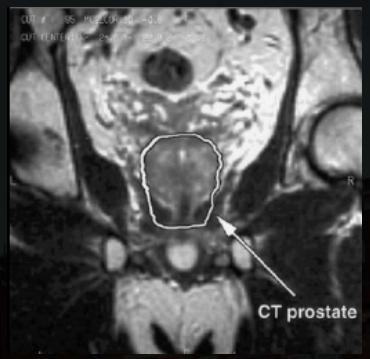

CT vs MRI types
PC RTP

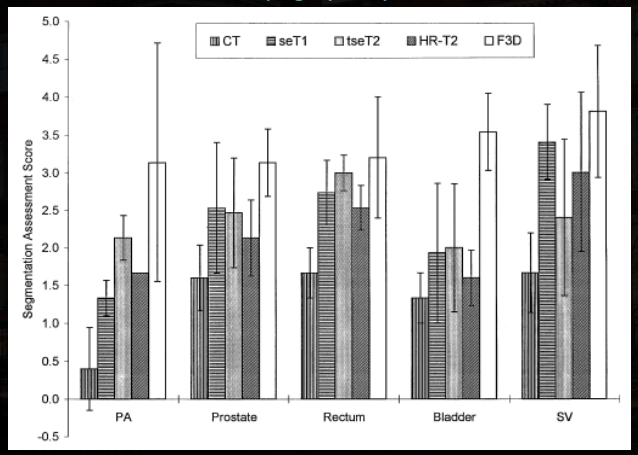

Khoo et al BJR 1999

Inter-observer variation:
Ant rectal wall

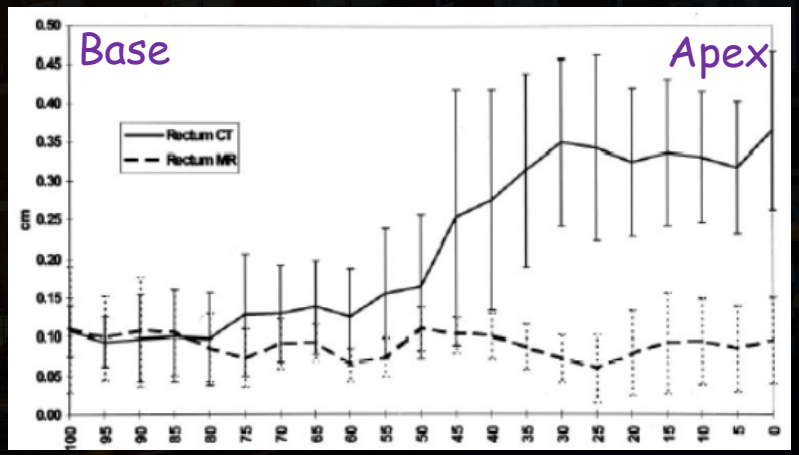

Dubois et al IJROBP 1999

THE ROYAL MARSDEN

A 'not uncommon' situation!

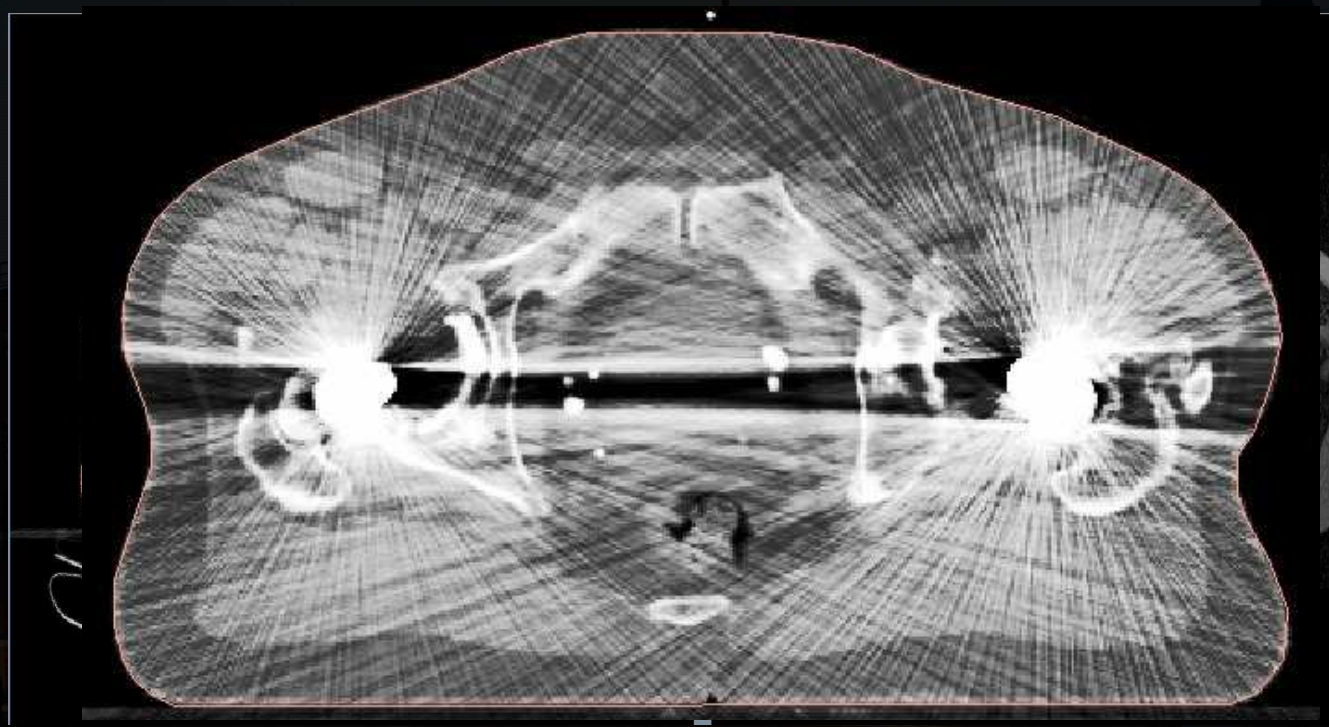

THE ROYAL MARSDEN

MR Issues for XRT planning
System & Object Distortion



Khoo et al. Radiother Oncol 1997

THE ROYAL MARSDEN

PC: Staging & Risk Stratification

- TNM
- TNM Groupings
- D'Amico Groupings

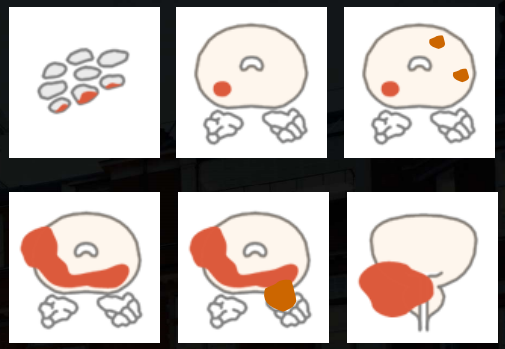

- NCCN Classification

Factor	Low	Intermediate	High	Very High
T stage	T1c-T2a	T2b-T2c	T3a	T3b-T4
PSA	< 10	10-20	>20	Any
Gleason	≤ 6	7	8-10	Any

THE ROYAL MARSDEN

www.nccn.org

THE ROYAL MARSDEN

PC: Extracapsular Disease

- Clinico-pathological correlations & clinical nomograms can estimate disease & aid TVD
- One example is Partin's Tables (see Appendix 2)
- Other examples: clinical nomograms
  - UCSF
    - P Capsule + : 3/2(PSA) + (Gleason score – 6)x10

      Roach III. J Urol 150: 1923-24, 1993
  - Kattan's etc
    - Nomogram Table

      Ohori et al. J Urol 171, 1844-1849, 2004.

THE ROYAL MARSDEN

Coverage for Extracapsular Disease

- Radical prostatectomy: path review series
  - 185/712 (26%) ECE +ve
  - Median ECE distance = 2 mm
    - range 0.5-12 mm
    - measured radially from capsule
  - Mean ECE distance = 2.93 mm
    - SD ± 2.3 mm
  - All clinical subgroups (except PSA < 4) had some cases where ECE was > 5mm

Teh et al J Cancer 2003

THE ROYAL MARSDEN

Coverage for Extracapsular Disease

- Radical prostatectomy: path review series
  - 121/371(33%) ECE +ve
    - 60:40 (Unilat v Bilat)
  - Median ECE distance = 2.4 mm
    - Range 0.05-7 mm
    - 90% of cases ≤ 5.0 mm
  - Risk factors: PSA ≥ 10 or GI ≥ 7
    - Either factor: 21% ECE ≥ 2 mm & 5% ≥ 4 mm
    - Both factors: 49% ECE ≥ 2 mm & 21% ≥ 4 mm
  - NB: All post-lat along NV bundle

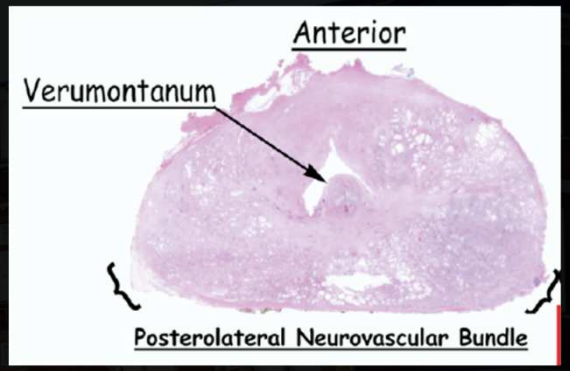

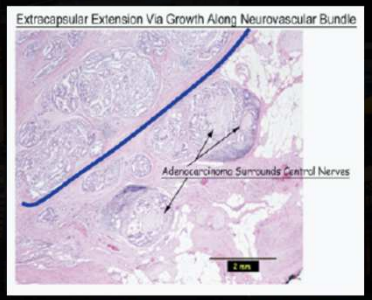

Chao et al J Cancer 2003

THE ROYAL MARSDEN

PC: TVD of ECE

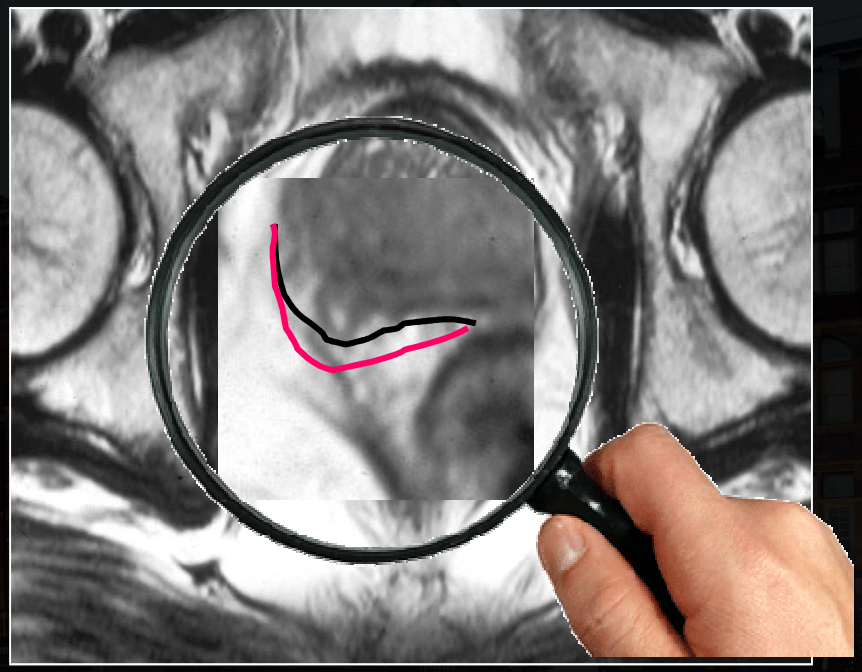

THE ROYAL MARSDEN

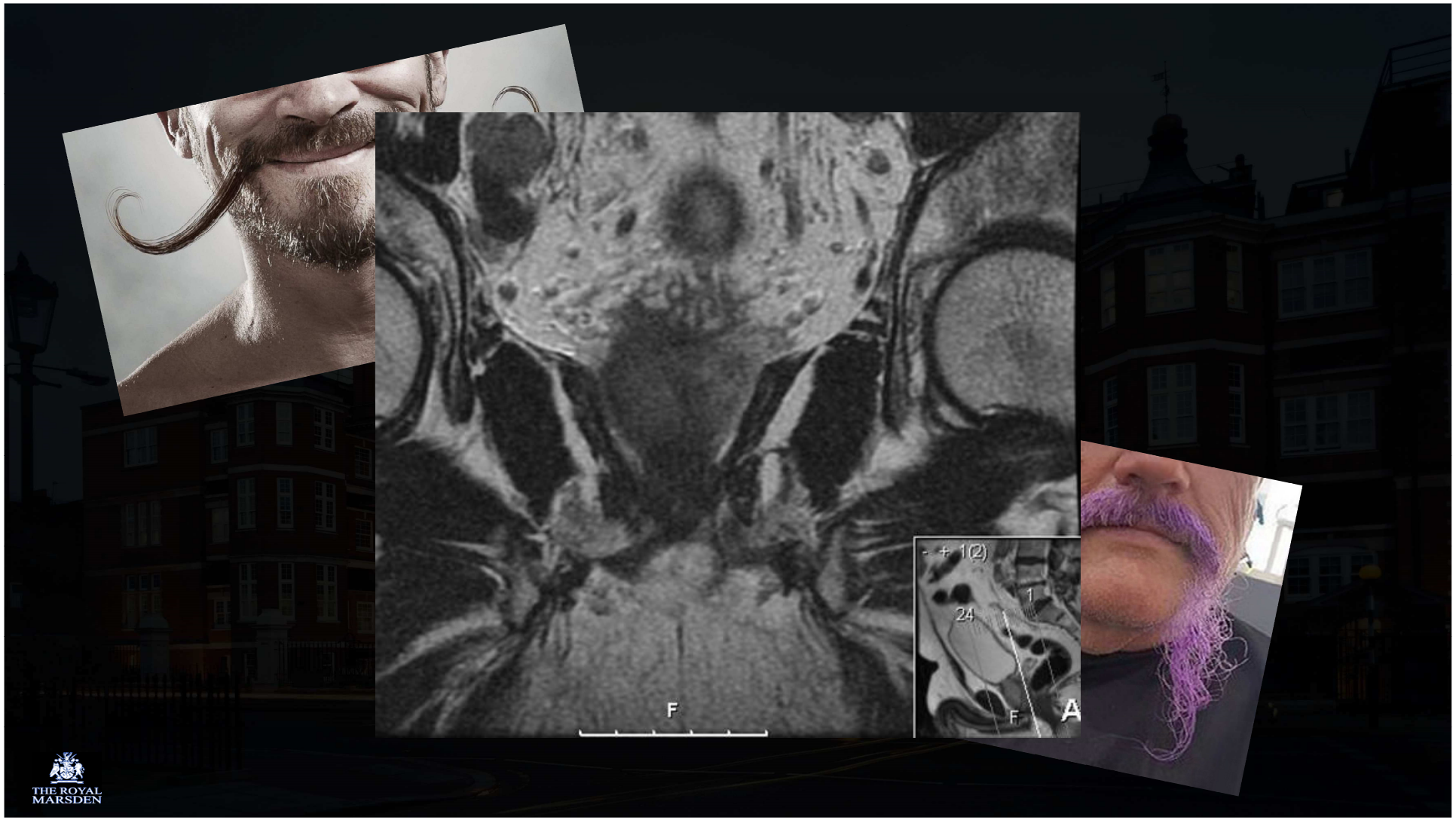

THE ROYAL MARSDEN

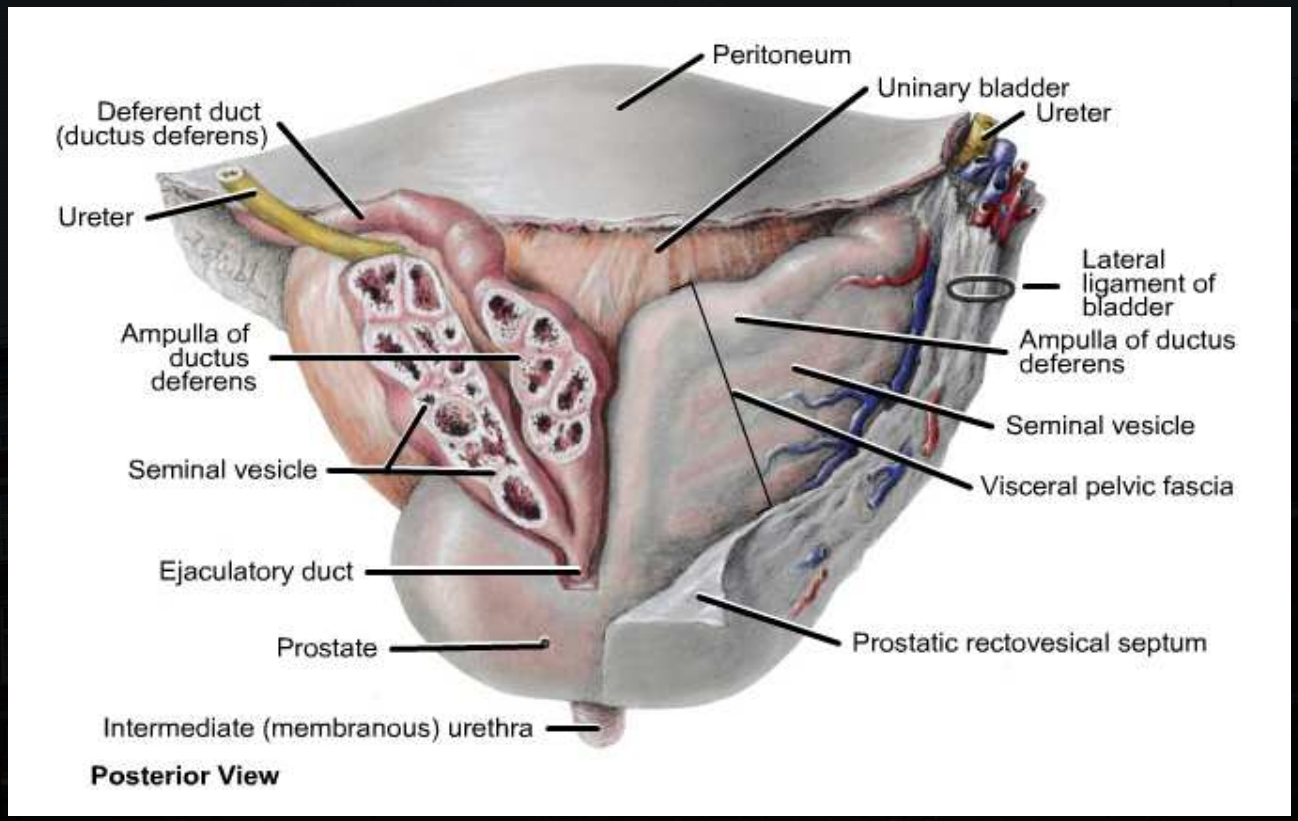

Appendix

Grant's Anatomy 2005

THE ROYAL MARSDEN

Coverage of SV

- Much controversy between clinicians
- Depends on
  - estimated clinical risk of involvement
  - disease extent on imaging
  - treatment strategies
- SV+ : (PSA) + (Gleason score – 6)x10

  Roach III. J Urol 150: 1923-24, 1993
- Nomogram Table

  Koh et al. J Urol 170, 1203-1208. 2003

THE ROYAL MARSDEN

Coverage of SV

WBH path series: 51/344 (15%). Clinical Risk stratification

1 risk factor ≈ 15% risk SV + and 3 risk factors ≈ 60% risk SV +

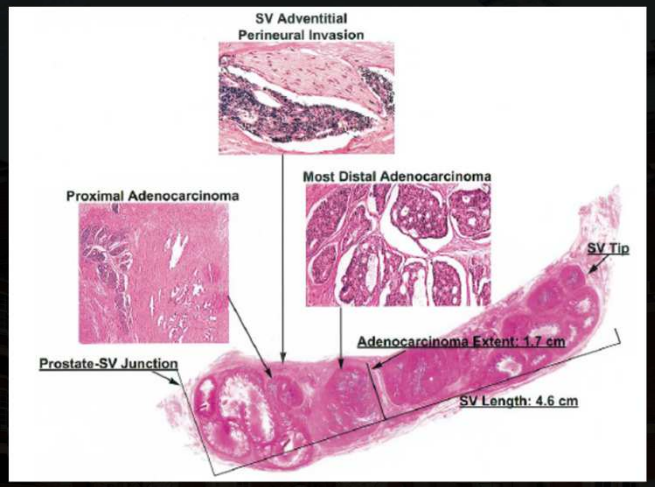

Median distances

Of SV ≈ 3.5 cm

Of SV invasion ≈ 1 cm

SV +ve beyond 1 cm ≈ 7% of cases

SV +ve beyond 2 cm ≈ 1% of cases

Kestin et al IJROBP 2002

My recommendation:

Include proximal 2/3 length or 2-2.5 cm for intermediate-high risk CTV

THE ROYAL MARSDEN

Coverage of SV

SV recommended guidelines (EORTC & RTOG 0815)

- EORTC Guidelines
  - Intermediate Risk SV: proximal 1 cm
  - High Risk SV: proximal 2 cm
- RTOG 08-15 Protocol
  - Intermediate Risk Dose escalated Trial ± ADT
  - SV guideline: to include only proximal 1 cm SV in radial (in plane) and superior (out of plane) extent

Boehmer et al Radiothr Onc 2006.
www.rtog.org/ClinicalTrials/

THE ROYAL MARSDEN

Coverage of SV

Review: SV recommended guidelines (EORTC & RTOG 0815) with anatomy

N=114
1mm CT slices

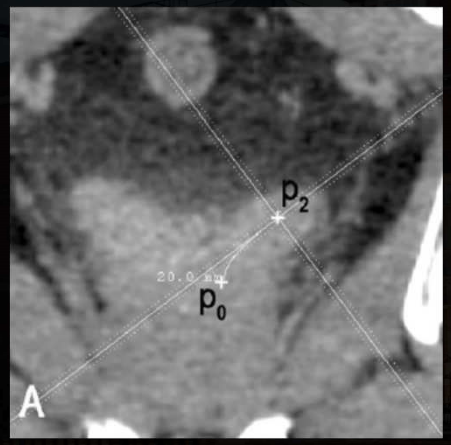



Figure 3 Different volumes of proximal SV CTV. Yellow line indicates V_{ANAT-1}, red line indicates V_{RTOG}, dark green line indicates $V_{EORTC-1}$, orange line indicates V_{ANAT-2}, blue line indicates $V_{EORTC-2}$, and light green line indicates the prostate.

Using axial slices:
IR = 1.4cm
HR = 2.2cm

Qi et al Rad Onc 2014

THE ROYAL MARSDEN

Example

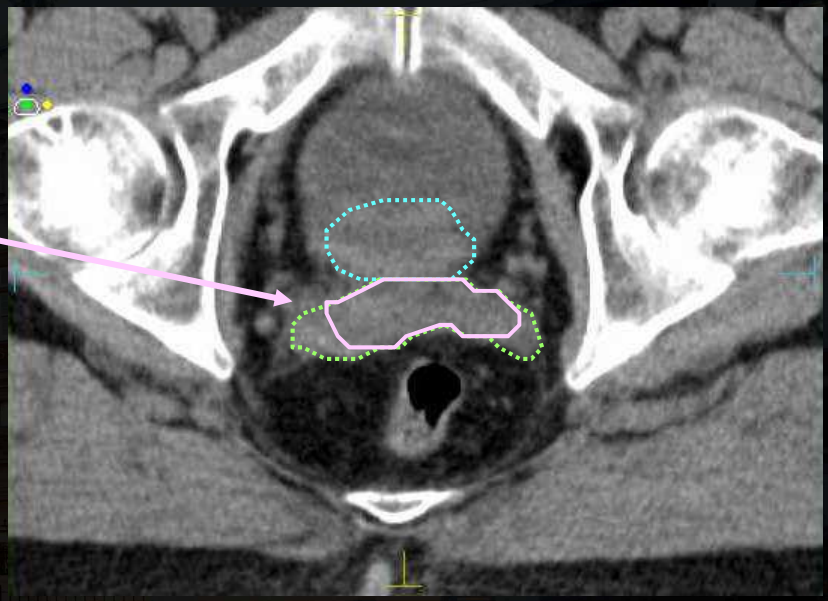

THE ROYAL MARSDEN

PC: Hypofractionation

CHHiP (N=3216): T1b-T3a N0M0. PSA ≤30, LN risk ≤30%, Medium FU 62m

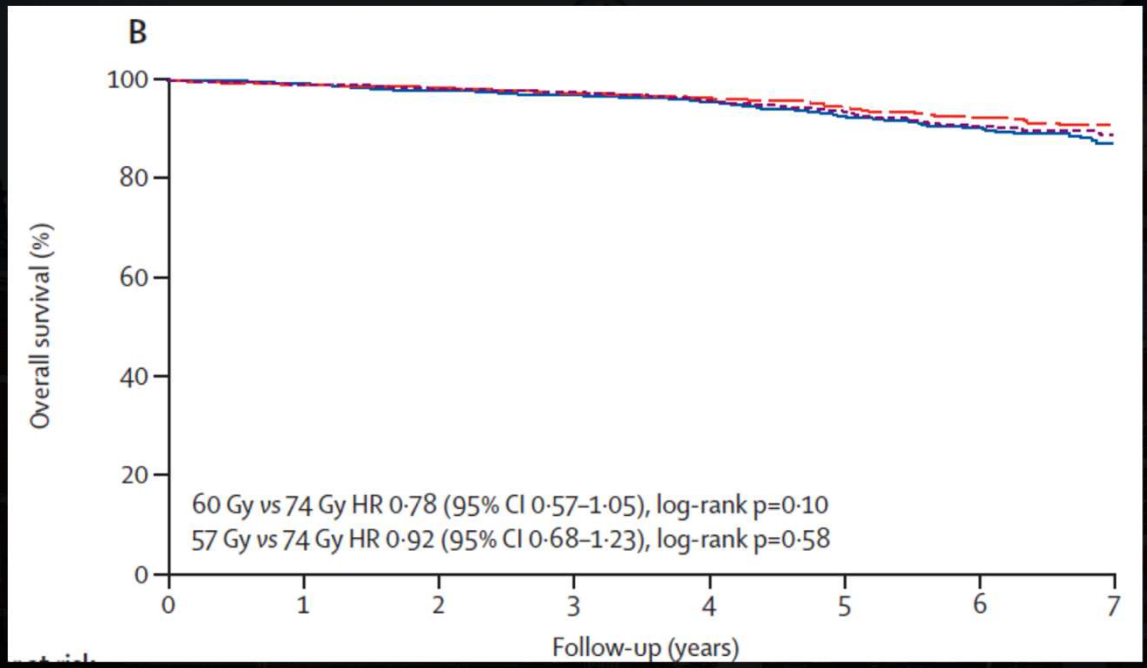

Trial Endpoint: Non-Inferiority Outcome

THE ROYAL MARSDEN

Dearnaley et al Lanc Oncol 2016

PC: Hypofractionation

CHHiP (N=3216): T1b-T3a N0M0. PSA ≤30, LN risk ≤30%, Medium FU 62m

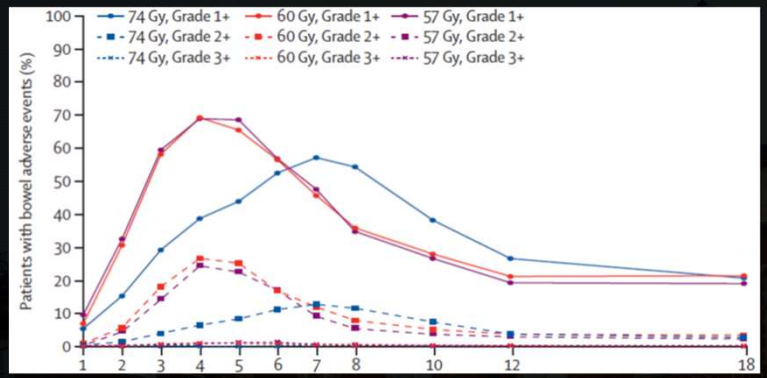

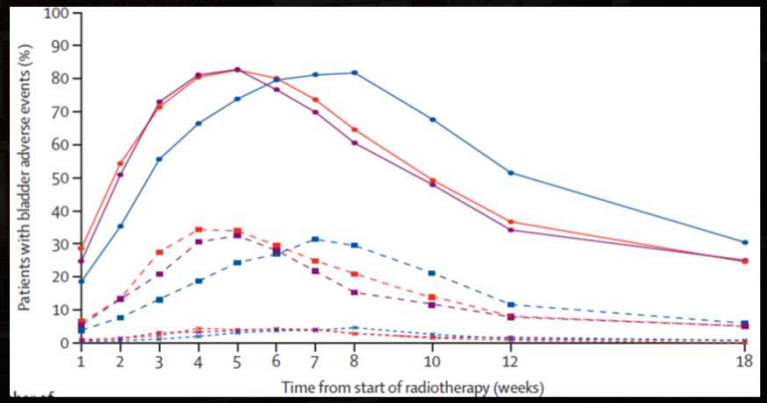

THE ROYAL MARSDEN

Dearnaley et al Lanc Oncol 2016

Pelvic OARs

Using CHHiP Protocol

- Rectum
  - Outlined from anus (at the level of the ischial tuberosity or 1cm below the lower margin of the PTV whichever is more inferior) to the recta-sigmoid junction.
  - The R-S junction is usually on the axial CT slice where the rectum turns anteriorly and to the left
  - Usually a length of 10-12 cm
- Bowel
- Bladder
  - From base to dome
- Femoral Heads
- Penile Bulb
  - Bulb like expansion of corpus spongiosum

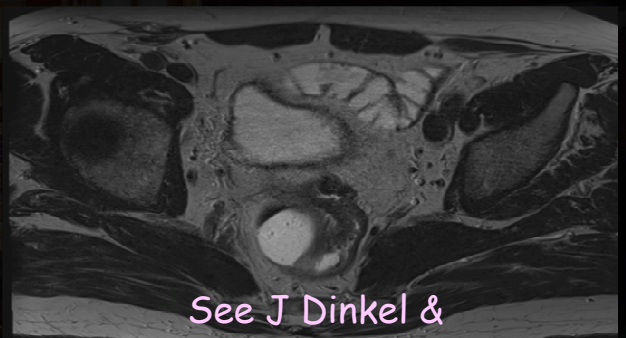

See J Dinkel &
N Gambacorta's Rectal Lectures

THE ROYAL MARSDEN

Pelvic OARs

Using CHHiP Protocol

- **Penile Bulb**
  - Bulb like expansion of corpus spongiosum

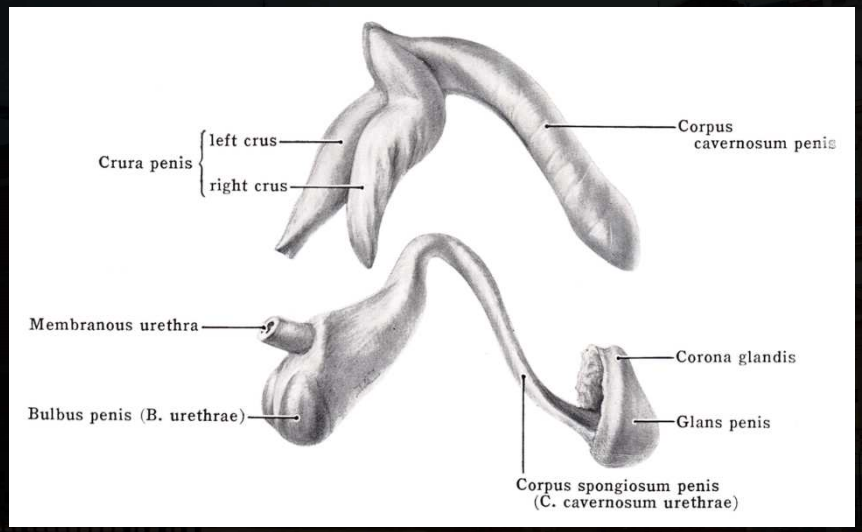

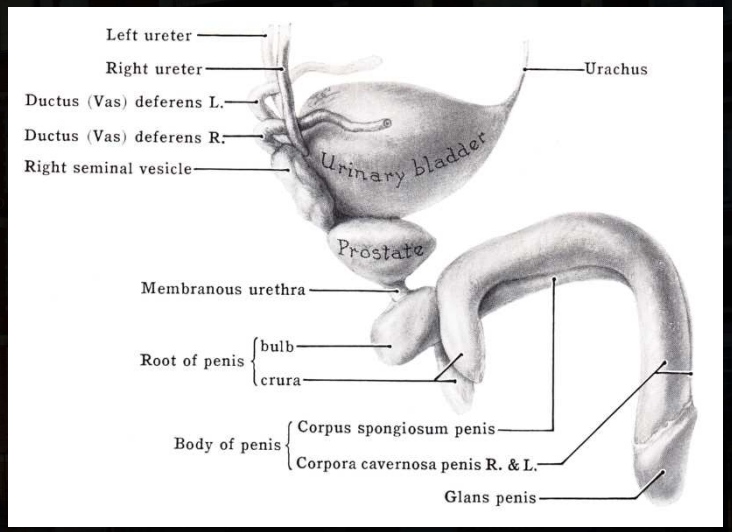

Grant's Atlas 1962

Pelvic OARs

CHHiP Protocol

NT dose constraints	Dose 2Gy/#	Dose (%)	Max Vol (%/cc)
Rectum	30	41	80%
	40	54	70%
	50	68	60%
	60	81	50%
	65	88	30%
	70	95	15%
	74	100	3%
Bladder	50	68	50%
	60	81	25%
	74	100	5%
Femoral Heads	50	68	50%
Bowel	50	68	17cc
Penile Bulb	50	68	50%
	60	81	10%

THE ROYAL MARSDEN

Patterns of Failure

- 118 cases ADT & EBRT
  - median FU 45m
  - Assess: DRE, TRUS ± MRI

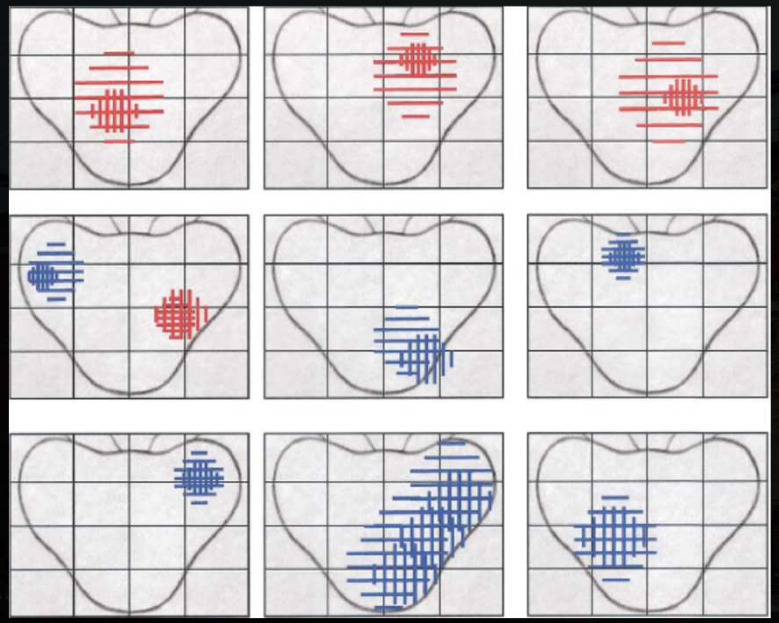

Cellini et al IJROBP 2002

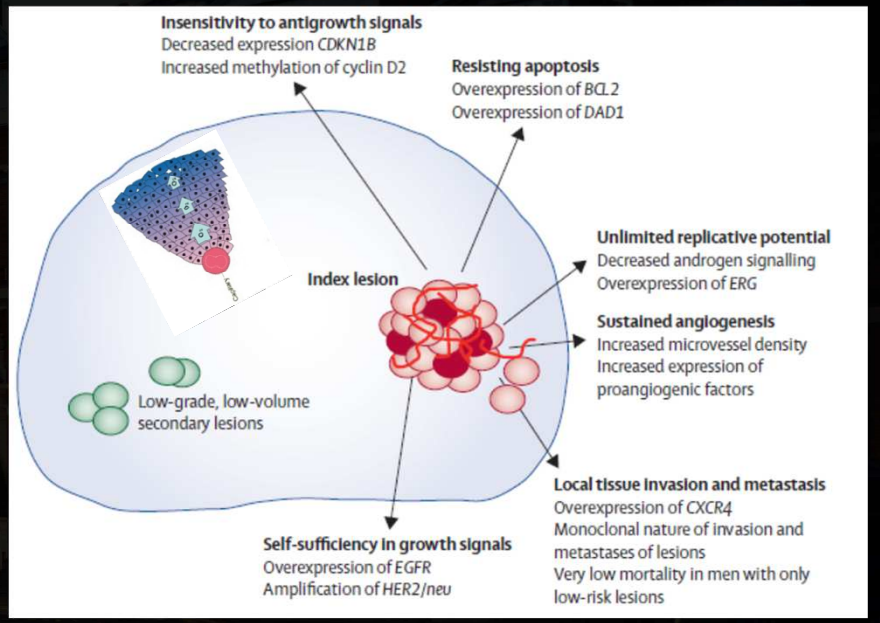

Ahmed et al Lanc Oncol 2012

THE ROYAL MARSDEN

PC: dwMRI

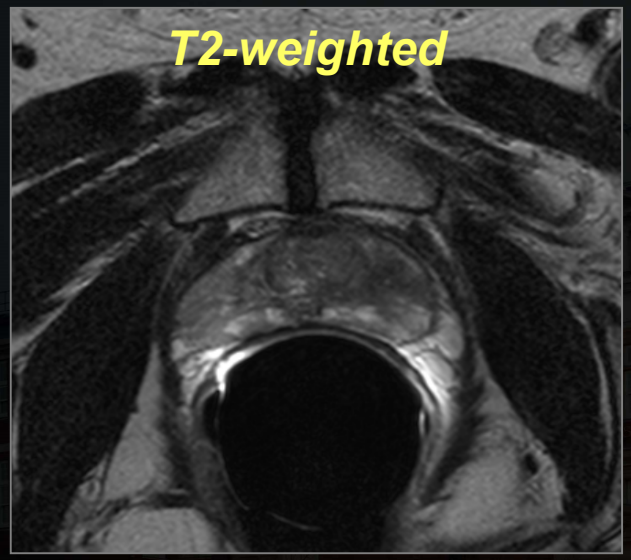

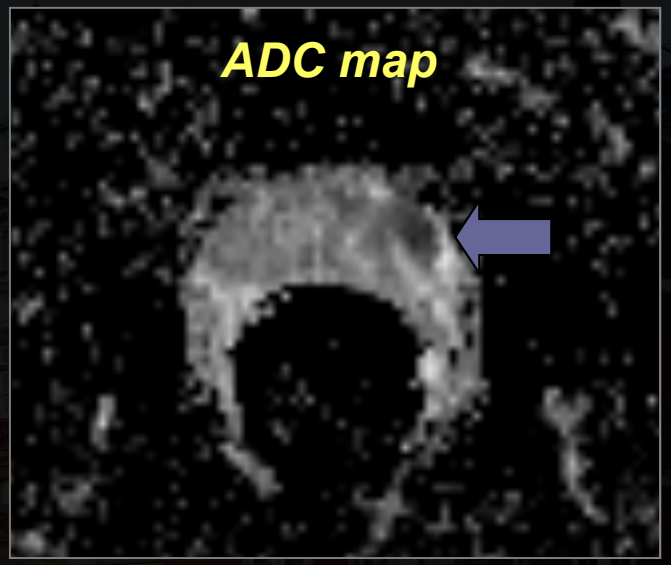

Improves tumour detection
Can help '<u>guide</u>' delineation

Courtesy: D-M Koh

THE ROYAL MARSDEN

PC: DIL TVD using mpMRI

Inter-Obs variability & Pathology. N=20. Obs = 6 teams (DR+RO)

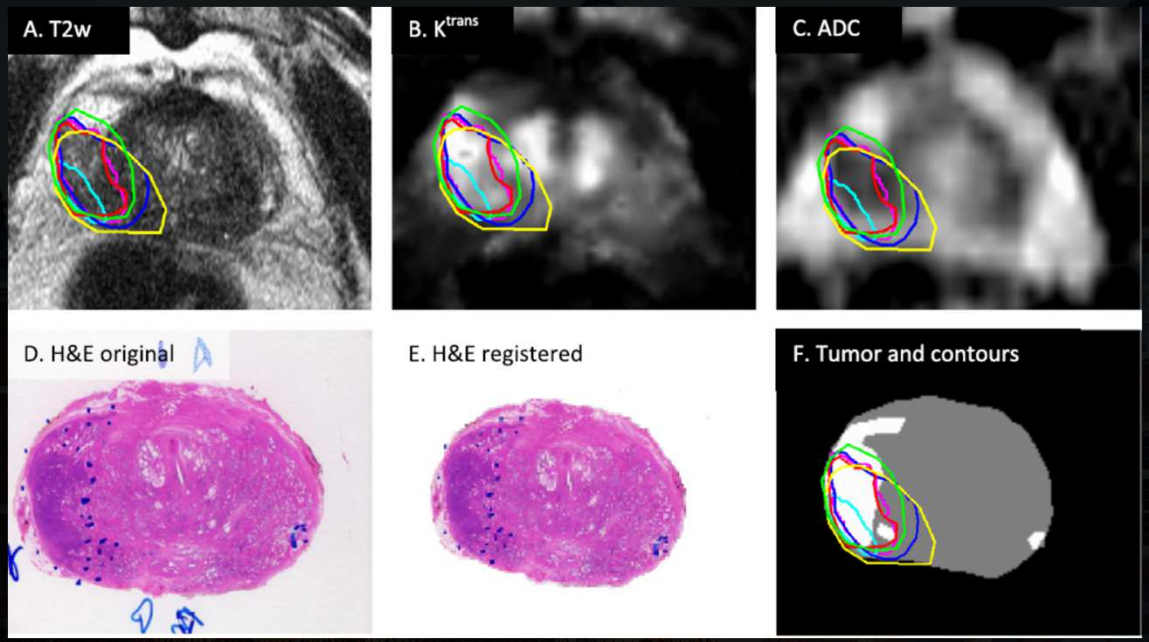

18/20 verified DIL were found. 66/69 satellites (≤ 0.4mm) missed.

Inter-Obs SD for DIL = 2.3 mm

THE ROYAL MARSDEN

Steenbergen et al Radiother Oncol 2015

Validation: ^{11}C-choline PET & Histopath

Intermediate & High risk PC. N=8. Dominant intraprostatic lesion (DIL)

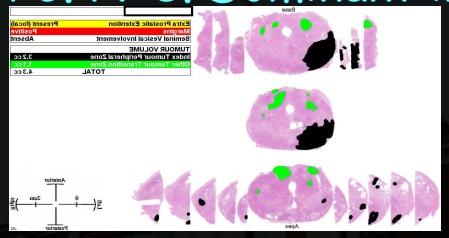

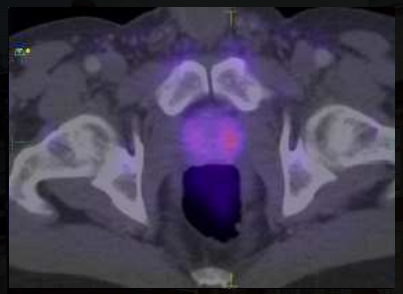

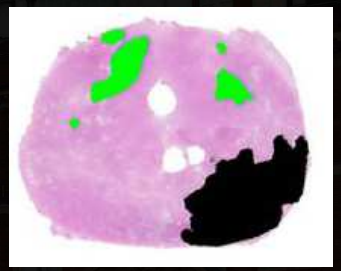

Method	Contour name(s)
Visual method	VM
PET edge	PE
Region grow	RG
Absolute SUV thresholding	$SUV_{1.5}$, $SUV_{2.0}$, $SUV_{2.5}$, $SUV_{3.0}$
Relative SUV thresholding	$SUV_{40\%}$, $SUV_{50\%}$, $SUV_{60\%}$, $SUV_{70\%}$

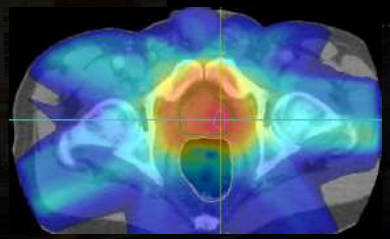

THE ROYAL MARSDEN

JARROC

Chang et al. RO 2011

FLAME Trial

PhIII. N=571 (2009-2015). 1° EP: 5y PSA control
77Gy/35# ± boost mpMRI DIL to 95Gy. Median FU 28m

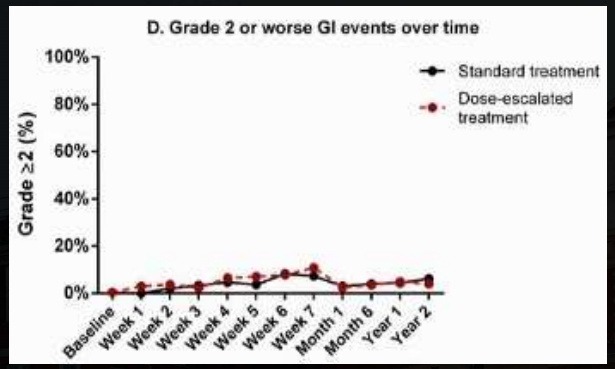

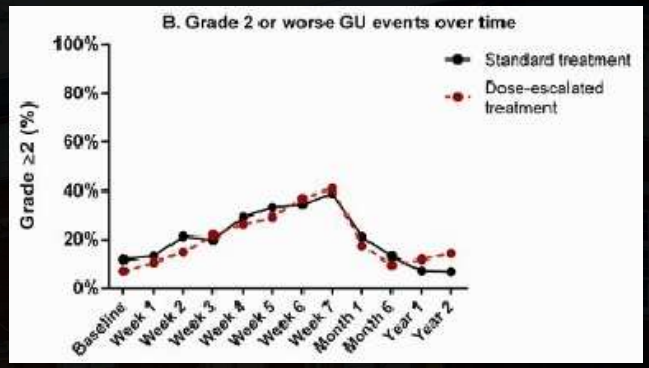

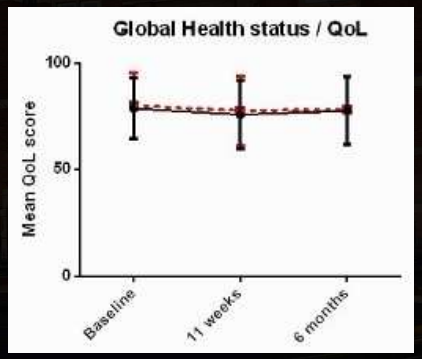

THE ROYAL MARSDEN

Courtesy of M van Vulpen et al ESTRO 2016

Take Home Message

- What we currently define for prostate RT is a 'CTV'
- Level 1 evidence for shaping target volumes
- 3D shaping permits CFRT and IMRT
- Boosting the DIL remains under investigation as are Focal Therapy strategies. Best assessed within appropriate trials.
- To maintain the therapeutic ratio, it is important to identify BOTH the CTV and all OAR appropriately

THE ROYAL MARSDEN

Take Home Message

- Inter-observer & Intra-observer variability
  - Remains a significant factor
  - Can be reduced by better imaging
- Gold standard for pelvic imaging
  - Diagnosis: MRI
  - TVD: MRI (co-registration where possible)
- RTP
  - Still mainly CT based & is a limitation
  - Ideally CT-MRI image registration but if not then 'cognitive' or 'eye-ball' method
- Issues
  - Accuracy/Reliability of image registration
  - 4D effects

THE ROYAL MARSDEN

Take Home Message

- CTV for extra-capsular extension or SV
  - Depends on clinical scenario
  - Use biopsy information
  - Use imaging information
  - Apply clinical nomograms (review several)

- There remains some controversy regarding seminal vesicles inclusion and its extent or volume for RT
  - Risk dependant stratification

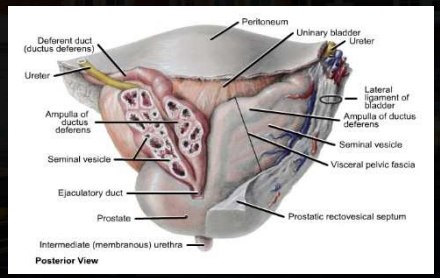

THE ROYAL MARSDEN

Know your patients, their disease & your capabilities

- Patient related factors
  - Symptoms, age, co-morbidity, erectile function, life expectancy, expectations
- Tumour related factors
  - Stage, Gleason score, biopsy profile, presenting PSA, PSA density & velocity (if available)
  - Eg: D'Amico grouping, NCCN (www.nccn.org)
- Treatment related factors
  - XRT methods (XRT, BT, CFRT, IMRT), strategies (± hormone therapy, ± brachytherapy), dose-fractionation
  - Resource factors: expertise, infra-structure, equipment

THE ROYAL MARSDEN

Thank you
THE ROYAL MARSDEN

ESTRO Course: TVD from Imaging to Margins – Lisbon 2017

CTV for Salvage Prostate RT Post-operative Setting

VINCENT KHOO

Royal Marsden Hospital & Institute of Cancer Research
St George's Hospital & University of London
ONJCC & Austin Health, University of Melbourne & Monash University

THE ROYAL MARSDEN

St George's Healthcare NHS Trust

Austin Health

ICR The Institute of Cancer Research

RALP

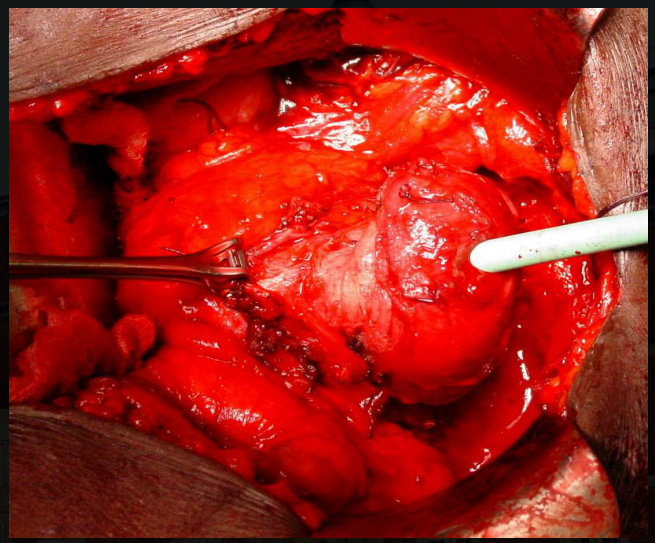

THE ROYAL MARSDEN

Target Volume(s): Salvage RT

- **WHY** do we want to treat?
- **WHEN** do we want to treat?
- **HOW** do we want to treat?
- **WHAT** do we want to treat?

THE ROYAL MARSDEN

Target Volume(s): Salvage RT

- **WHY** do we want to treat?

Table 3 – Guidelines on treatment options for prostate-specific antigen relapse following local treatment

Recommendations	GR
• Local recurrences are best treated by salvage RT with 64–66 Gy at a PSA serum level ≤0.5 ng/ml.	B
• Expectant management is an option for patients with presumed local recurrence who are too unfit or unwilling to undergo RT.	B
• PSA recurrence indicative of systemic relapse is best treated by early ADT, resulting in decreased frequency of clinical metastases if poor prognostic risk factors such as PSA DT <12 mo or Gleason score 8–10 are present.	B
• Luteinising hormone-releasing hormone analogues/antagonists/orchiectomy or bicalutamide 150 mg/d when hormonal therapy is indicated.	A
Local recurrences can be treated with salvage RP in carefully selected patients, who presumably have organ-confined disease, that is, PSA <10 ng/mL, PSA DT >12 mo, low-dose brachytherapy, biopsy Gleason score <7.	B
Cryosurgical ablation of the prostate and interstitial brachytherapy are alternative procedures in patients not suitable for surgery.	B
HIFU may be an alternative option. However, patients must be informed about the experimental nature of this treatment modality due to the short follow-up periods reported.	B
In patients with presumed systemic relapse, ADT may be offered.	C

ADT = androgen deprivation therapy; GR = grade of recommendation; HIFU = high-intensity focused ultrasound; PSA DT = prostate-specific antigen doubling time; RP = radical prostatectomy; RT = radiation therapy.

- Chance of a "second cure"
- Success = 2/3

THE ROYAL MARSDEN

Target Volume(s): Salvage RT

- **WHY** do we want to treat?
- **WHEN** do we want to treat?

Retrospective Review 17 centres (USA)
N = 1603. 1987-2005. Median FU = 53m

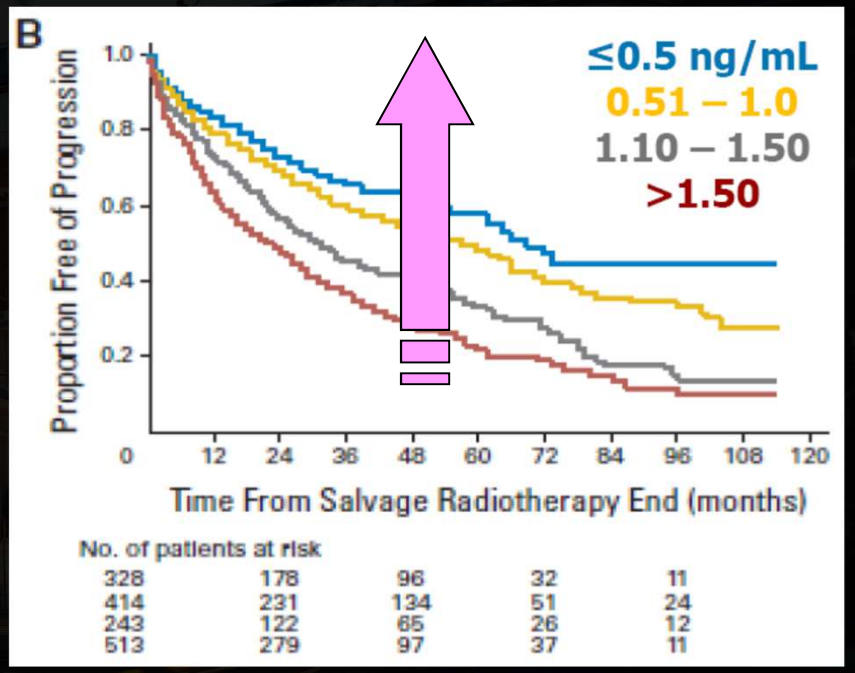

Stephenson et al JCO 2007

THE ROYAL MARSDEN

PC: Post-op XRT
Adjuvant & Early Rationale

Estimation of Effect

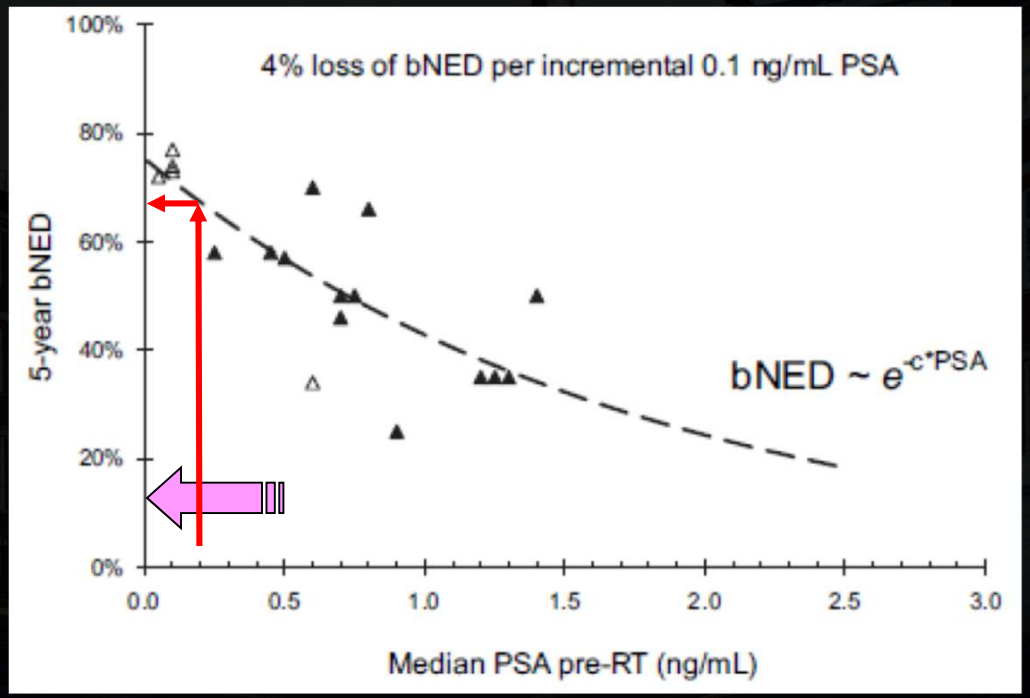

King et al, IJROBP 2011

THE ROYAL MARSDEN

RALP

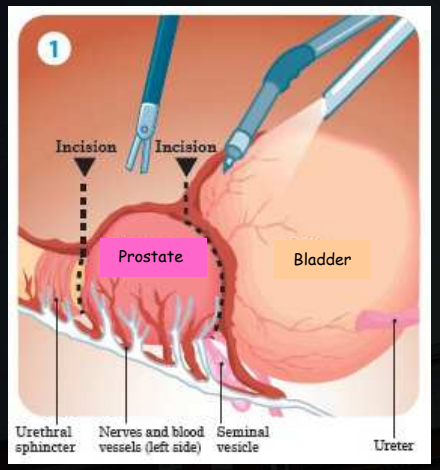

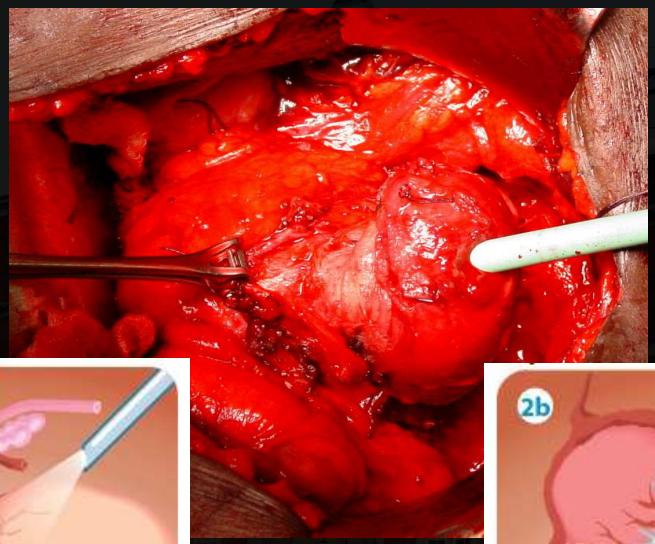

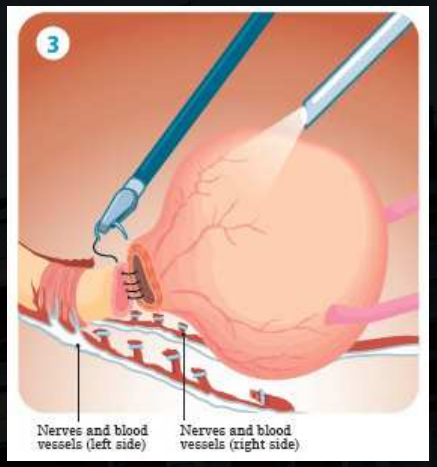

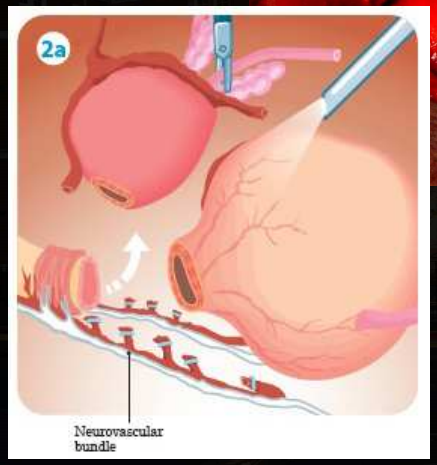

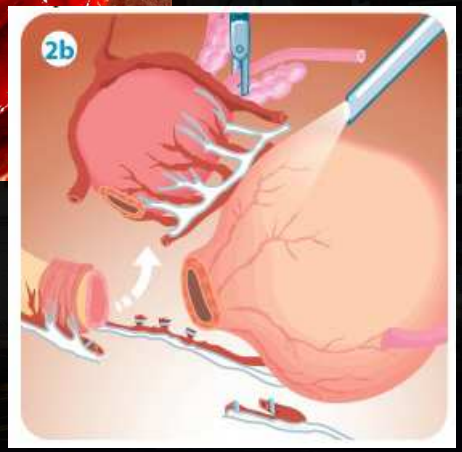

THE ROYAL MARSDEN

Post-op: Patterns of Local Failure

EORTC Review: Biopsy proven recurrences

Location of the local relapses in the prostatic bed after radical prostatectomy

	Patients	Diagnosis	Anastomosis		Other sites
Silverman [38]	31	Clinically detected or PSA rising, biopsy confirmed	31	Posterior: 16 Anterior: 9 Combination: 6	–
Connolly [10]	61	PSA rising biopsy confirmed	42	Posterior: 26 Anterior: 5 Lateral: 11	Retrovesical: 8 Bladder neck: 10 Combination: 1
Leventis [24]	31	Clinically detected or PSA rising, biopsy confirmed	17		Retrovesical: 2 Bladder neck: 7 Combination: 5
Sella [36]	39	MRI detected (15/39 biopsy confirmed)	12		Retrovesical: 17 Residual SV: 9 Combination: 1
Total	162		102 (63%)		Retrovesical: 27 (17%) Bladder neck: 17 (10%) Other: 16 (10%)

1 = Anastomosis (63%) **2 = Retrovesical (17%)** **3 = Bladder neck (10%)**

THE ROYAL MARSDEN

Poortmans et al R&O 2007

Post-op: Patterns of Local Failure

UCSF. N= 114 cases. Using TRUS guided biopsies (x156)
54%+ biopsied LF (66% with margins+ and 20% organ confined disease)

Sites of LF: anastomosis 66%, bladder neck 16%, posterior trigone 13%

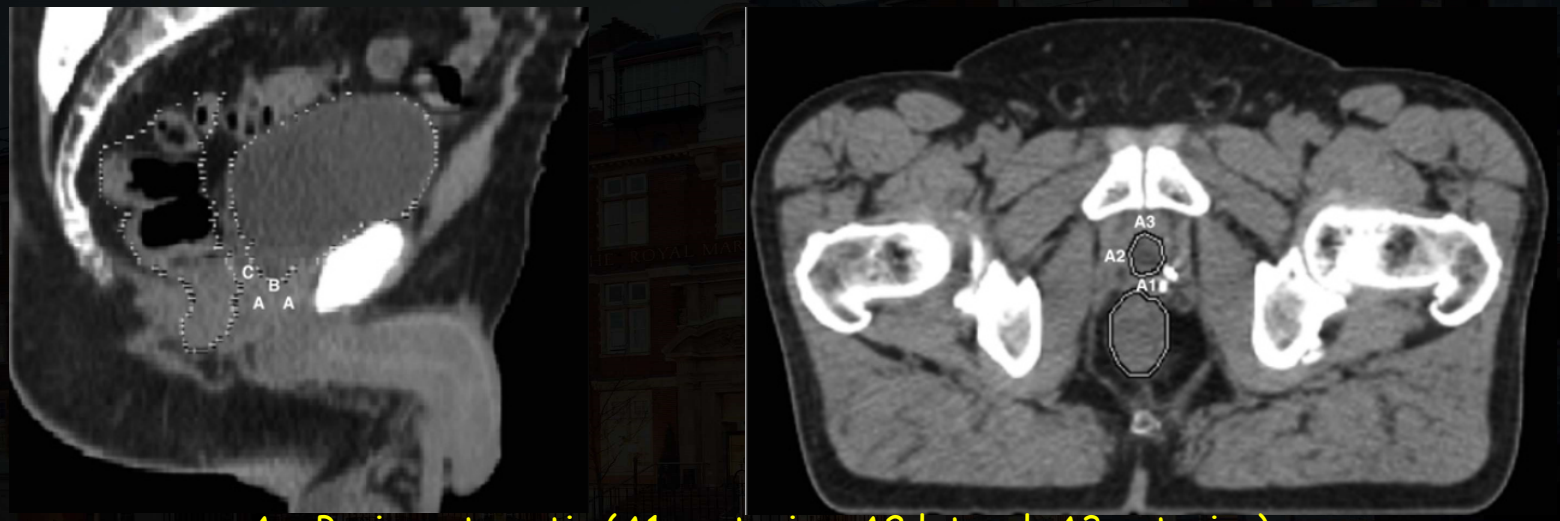

A = Perianastomotic (A1 posterior, A2 lateral, A3 anterior)
B = Bladder neck, C = Retrovesical

Connolly et al Urology 1996

THE ROYAL MARSDEN

PC: Post-op XRT

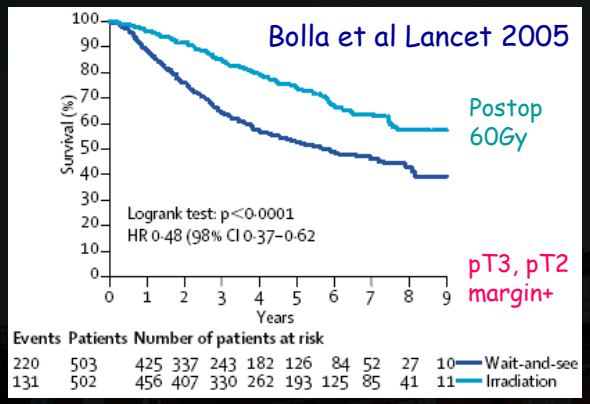

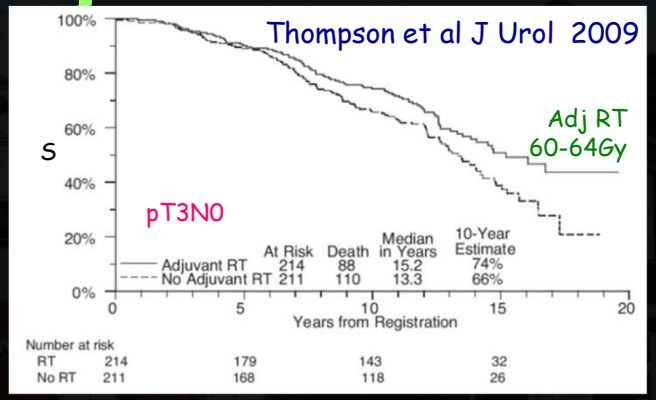

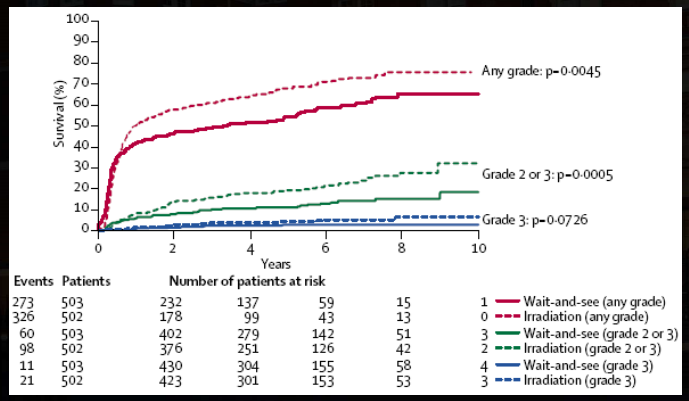

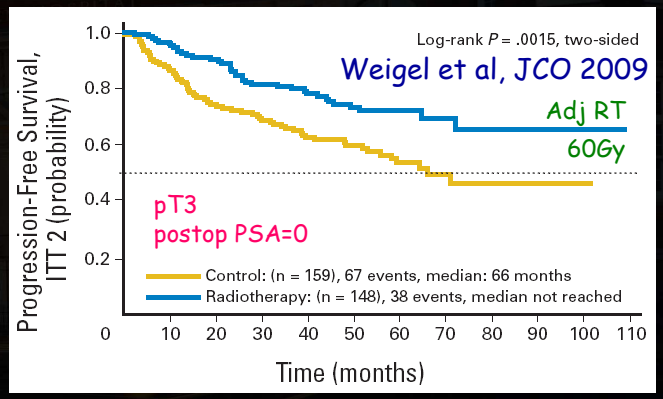

THE ROYAL MARSDEN

PC: Post-op XRT – Adjuvant vs Salvage

- RAVES
  - RT – Adjuvant Vs Early Salvage RT. No ADT (TROG 0803)
    - Pearse et al. BJUI 2014.
    - T3, +SM. N = 258/470 in Oct 2013.
    - RT ≤ 4m postop or PSA >0.2
- GETUG-17
  - Immediate Adj vs Delayed RT with 6m ADT
    - N = 718.
    - RT ≤ 6m postop or PSA >0.2 & < 2.0
- RADICALS-RT
  - RT & ADT In Combination After Local Surgery
    - N ≈ 4000
    - RT timing arm (N = 1061/1250, Jul 2015)
    - Closed HD arm (N ≈ 3000, Jul 2015)

THE ROYAL MARSDEN

RTOG: Postop XRT

Below the superior edge of the symphysis pubis	
Anterior	Posterior edge of pubic bone
Posterior	Anterior rectal wall
Inferior	8–12 mm below vesicourethral anastomosis
Lateral	Levator ani muscles, obturator internus
Above the superior edge of the symphysis pubis	
Anterior	Posterior 1–2 cm of bladder wall
Posterior	Mesorectal fascia
Superior	Level of cut end of vas deferens or 3–4 cm above top of symphysis
Lateral	Sacrorectogenitopubic fascia

THE ROYAL MARSDEN

Michalski et al IJROBP 2010

RTOG: Postop XRT

Case: Postop PSA +ve with apical margin +ve

Case: Postop ECE +ve with SV +ve

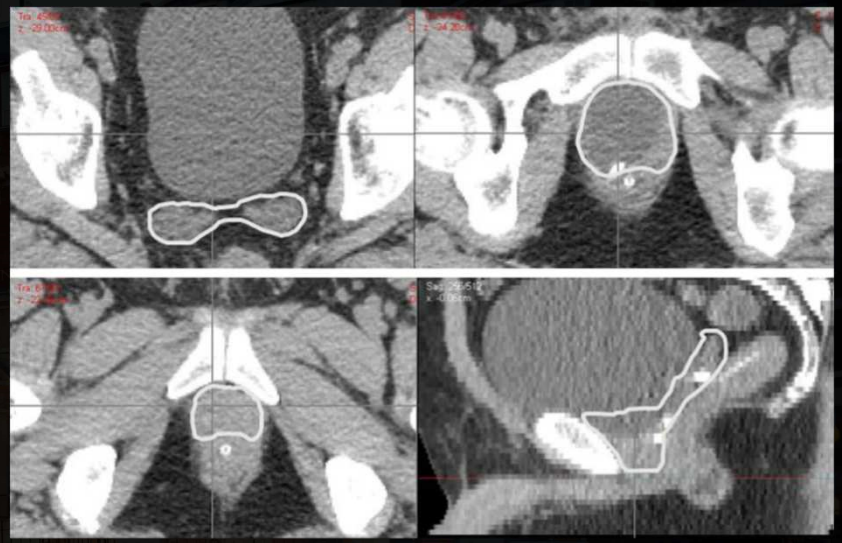

THE ROYAL MARSDEN

Michalski et al IJROBP 2010

EORTC: Post-op XRT CTV

- Recommendations for Prostate Bed CTV
  - Centrally: anastomosis
  - Inf: include the apex (about 15mm cranial from penile bulb)
  - Ant: include the anastomosis and urethral axis
  - Post: up to but not including outer rectal wall, cranially to include the posterior part of the bladder neck
  - Lat: up to neurovascular bundles or ilio-obturatic muscles
  - Sup: Bladder neck (posterior portion)

- Margins
  - 5 mm in directions for microscopic extension
  - 5 mm in posterior & lateral in presence of margin+ but exclude rectal wall

THE ROYAL MARSDEN

Poortmans et al R&O 2007

EORTC: Post-op XRT CTV

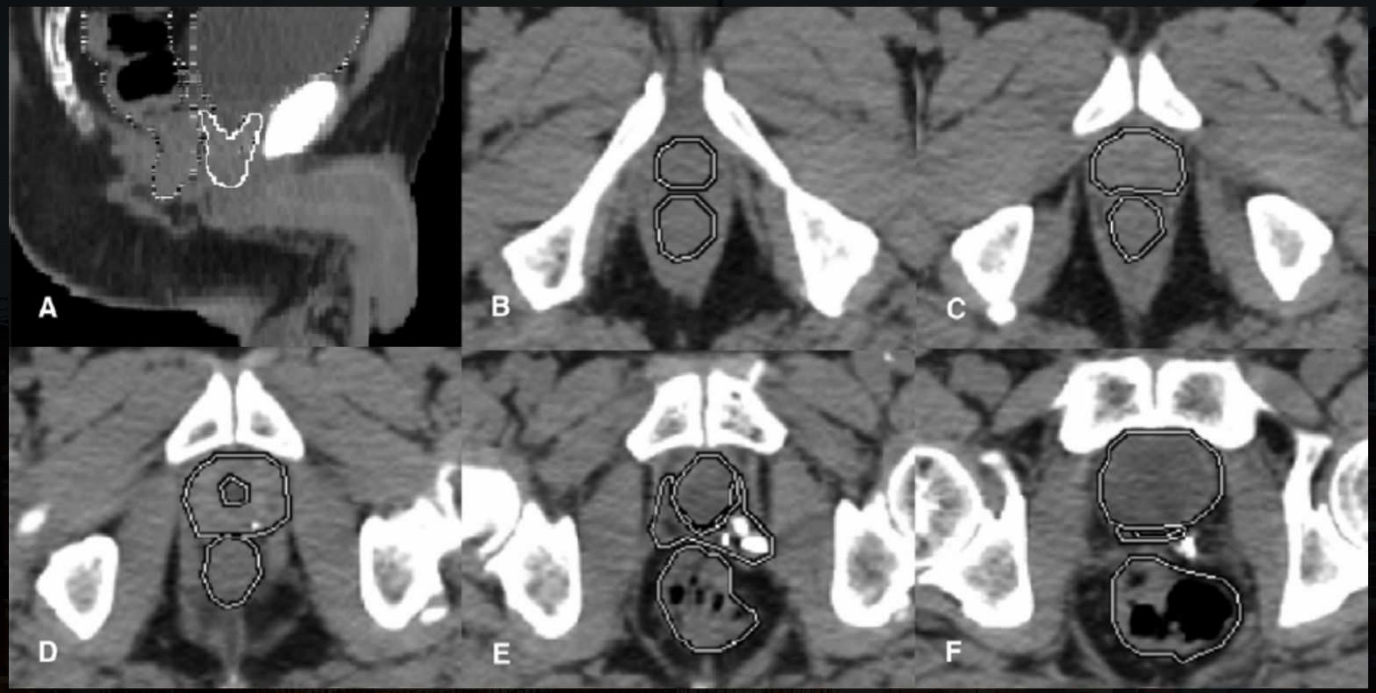

Fig. 2. Contouring example for a patient scheduled for postoperative radiotherapy on the base of extracapsular extension. A = longitudinal view; B–F = transverse slices in caudo-cranial direction. Margins to CTV and PTV have to be added as described in the text.

THE ROYAL MARSDEN

Poortmans et al R&O 2007

EORTC: Post-op XRT CTV

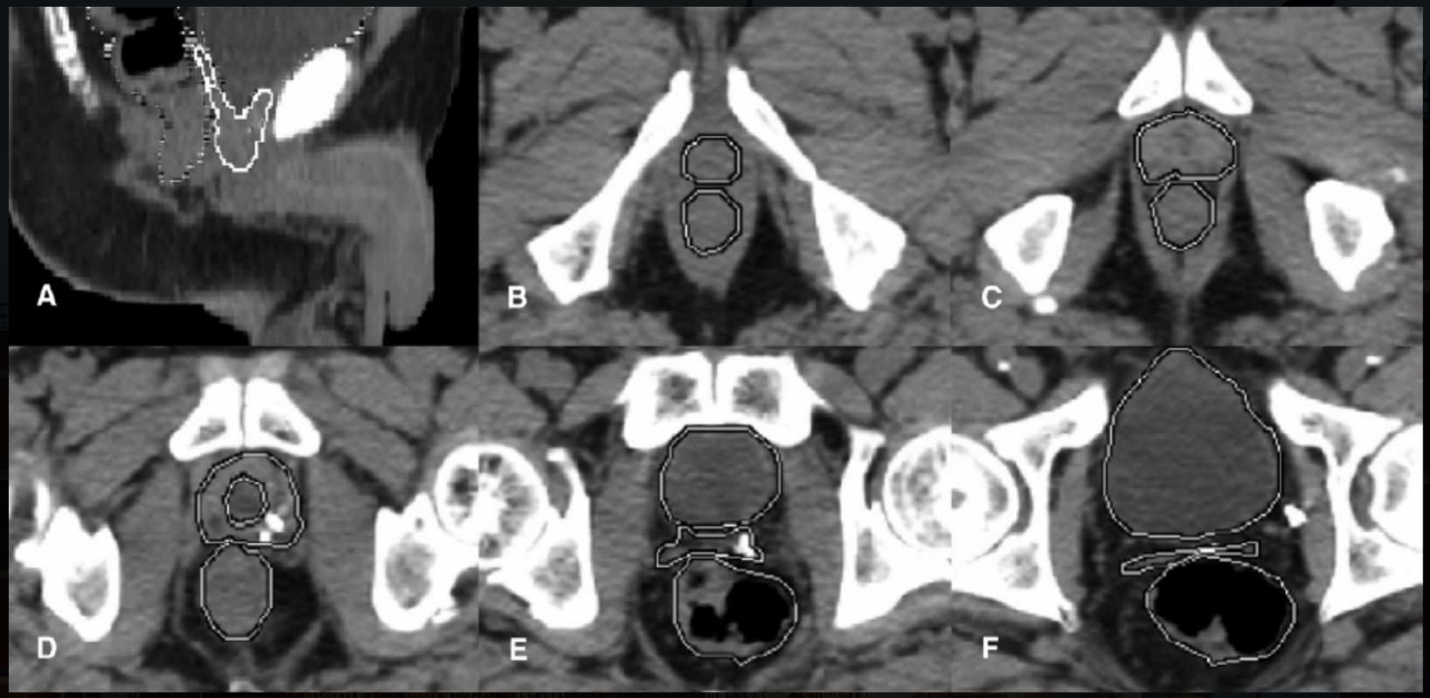

Fig. 3. Contouring example for a patient scheduled for postoperative radiotherapy on the base of invasion of the seminal vesicles. A = longitudinal view; B–F = transverse slices in caudo-cranial direction. Margins to CTV and PTV have to be added as described in the text.

THE ROYAL MARSDEN

Poortmans et al R&O 2007

RADICALS
- overall design

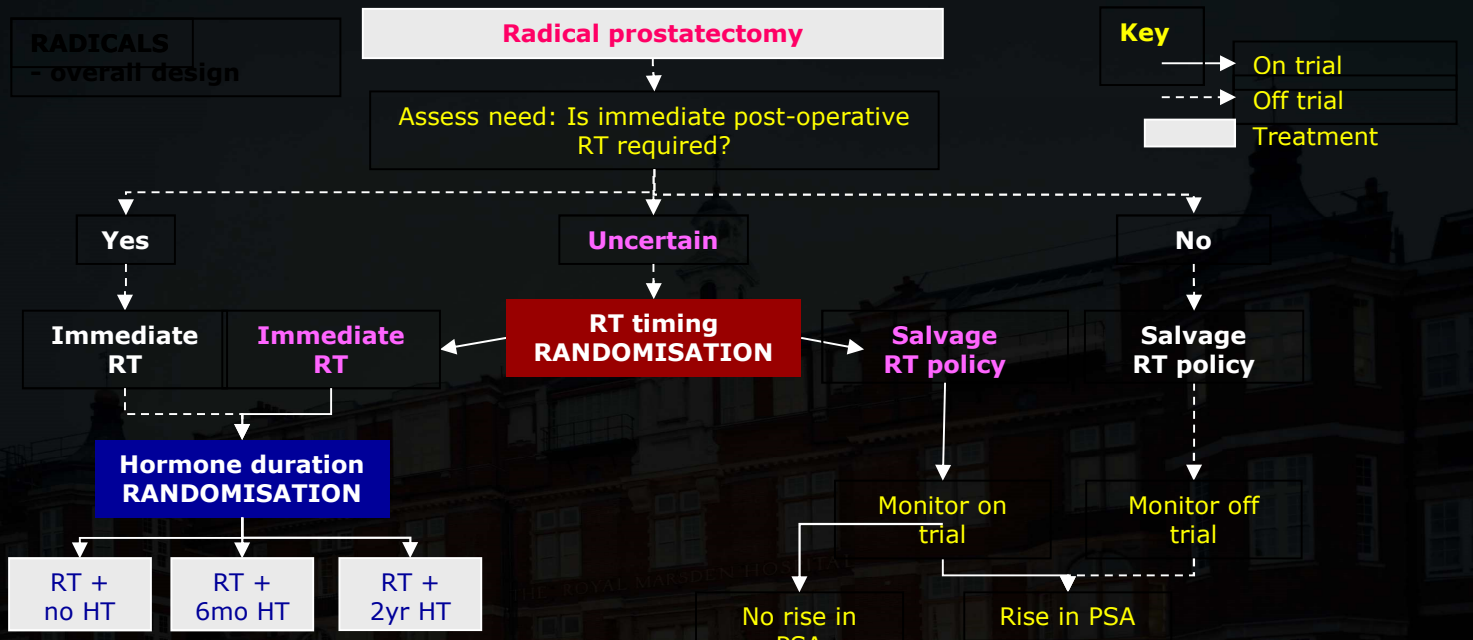

To address 2 important post-op XRT issues

- Need for and timing of post-op XRT
  - **immediate** (adjuvant)
  - **salvage** (deferred / early salvage)
- Use and duration of hormones & post-op XRT
  - **none** (0 months)
  - **short** (6 months)
  - **long** (24 months)

THE ROYAL MARSDEN

MRC & NCIC Collaborative: RADICALS Trial (CI: C Parker)

RADICALS: Post-op XRT CTV

- Use histopath, pre-op or post-op imaging information, clinical parameters (nomograms)

- Prostate Bed
  - Inf: 5mm cranial to sup penile bulb
  - Ant: caudally < 2cm sup to anastomosis (post pub sym) & cranially > 2cm to anastomosis (post 1/3 bladder wall)
  - Post: anterior rectal wall
  - Lat: medial border obturator internus & levator ani
  - Sup: dependant if SV removed; if SV present then treat according to clinical risk & if removed + involved, treat according to pre-op position

- Pelvic Nodes (clinician preference)
  - Obturator, internal iliac, external iliac, pre-sacral, pre-sciatic nodes

THE ROYAL MARSDEN

Take Home Message

- Adjuvant if ECE or T3
- Early if rising PSA ≥ 0.2 ng/ml
- Consider neo-adjuvant hormone therapy
- Cover SV region if involved or elements of SV remaining
- Value of adjuvant pelvic nodes coverage remains uncertain

THE ROYAL MARSDEN

Thank you
THE ROYAL MARSDEN

ESTRO Course: TVD from Imaging to Margins – Lisbon 2017

TVD for Pelvic Nodal CTV in Prostate Cancer

VINCENT KHOO

Royal Marsden Hospital & Institute of Cancer Research

St George's Hospital & University of London

ONJCC & Austin Health, University of Melbourne & Monash University

THE ROYAL MARSDEN

St George's Healthcare NHS Trust

Austin Health

ICR The Institute of Cancer Research

Pelvic Nodal Drainage

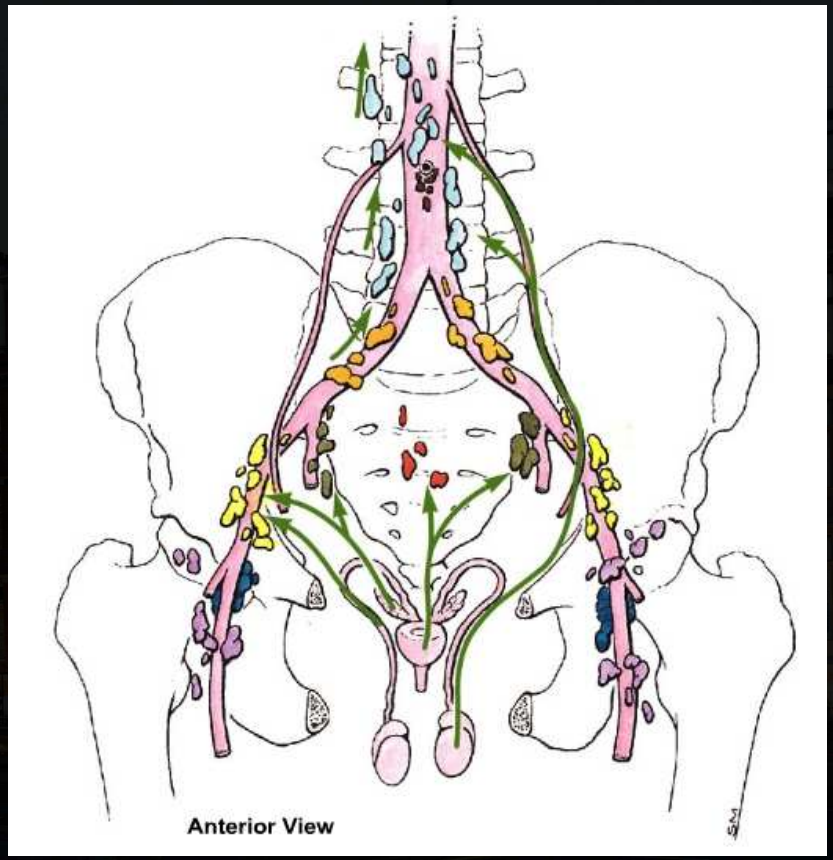

THE ROYAL MARSDEN

PC: Pelvic XRT

RTOG 94-13. No = 1323. Follow-up 59m

Median PSA 22ng/ml, 2/3 cases had T2-T4, Gl 7-10.

WP (50.4Gy/28#) + P (19.8Gy/12#) vs PO (70.2Gy/40#)

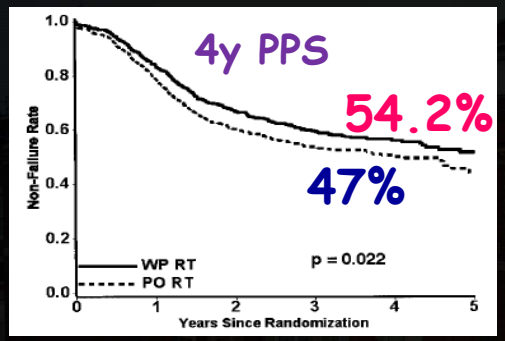

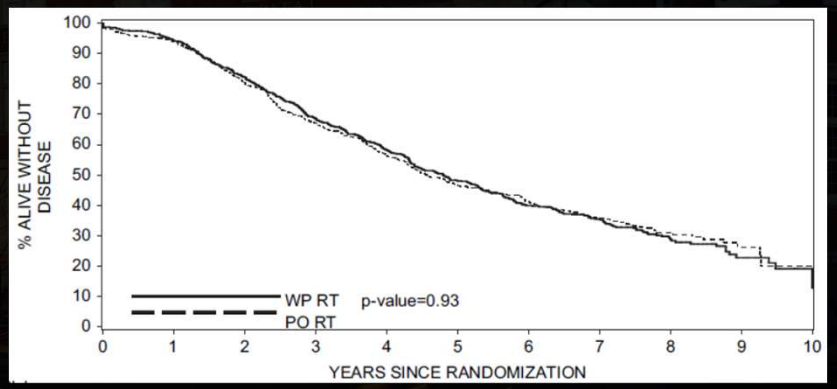

THE ROYAL MARSDEN

Roach et al JCO 2003 & Lawton et al IJROBP 2003

PC: Pelvic XRT

GETUG-01. No = 444. Follow-up 42m

T1b-T3 N0 pNx M0, PSA 11-12ng/ml, Gl 7

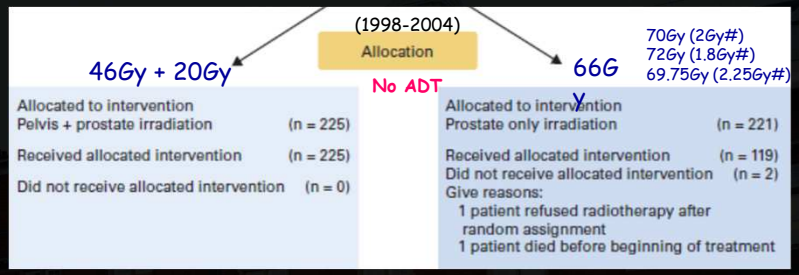

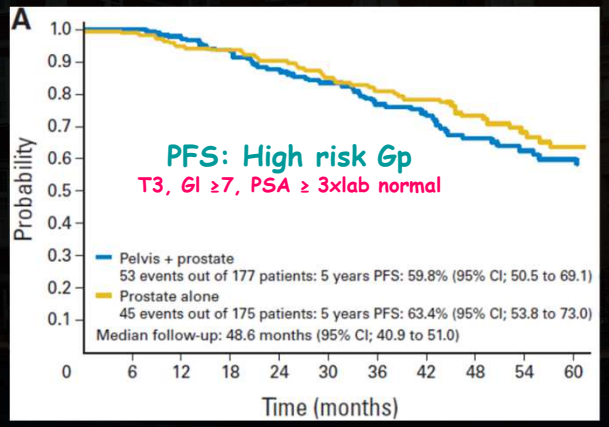

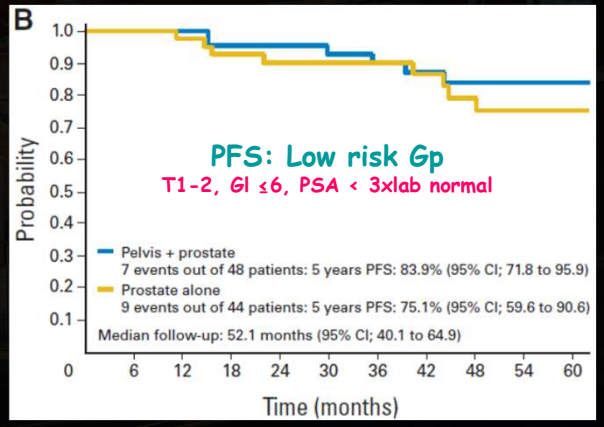

THE ROYAL MARSDEN

Pommier et al JCO 2007

PC: 'missing' dose

Dutch RCT (T1-T4 N0M0). No = 164/266. Follow-up 34m

Rectangular (N=79) vs CFRT (N=85)

Dose 66 Gy P+SV Margin 15mm

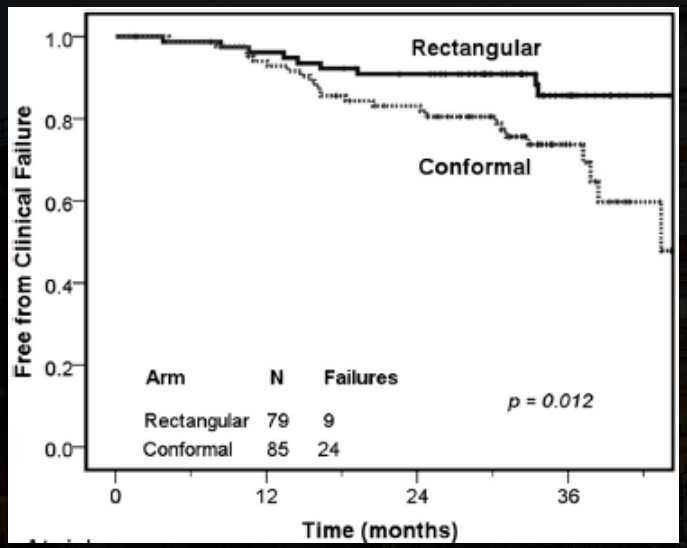

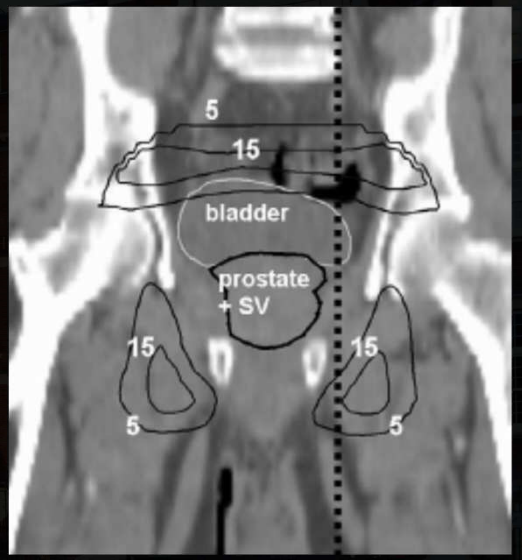

THE ROYAL MARSDEN

Heemsbergen et al RO 2013

PC: Nomograms for TVD

Estimated risks of Pelvic Nodal Disease

- Partin's Tables

  Partin et al. JAMA 277(18):1445-51, 1997

- Nodes +ve : 2/3(PSA) + (Gleason score – 6)x10

  Roach III. J Urol 150: 1923-24, 1993

- Nomogram Table

  Cagiannos I, et al: J Urol, 170: 1798–1803, 2003

THE ROYAL MARSDEN

Nomograms: PC Nodal Disease

Estimated risks of PC Nodal Disease:
Eg: iPSA 5, cT1, Gl 4+3

LN Estimator	Predicted Risk
Partin's Tables	3%
MSKCC nomogram	2.3%
Briganti / Milano nomogram	15%
Roach / UCSF nomogram [2/3(PSA) + (Gl – 6)x10]	13%

Partins (updated): http://urology.jhu.edu/prostate/partintables.php
MSKCC: http://nomograms.mskcc.org/Prostate/PreTreatment.aspx

Briganti et al. Eur Urol 49: 1019-26, 2006
Roach et al. J Urol 150: 1923-24, 1993

THE ROYAL MARSDEN

Clinical correlation with pN+ status

Series		PLND	No LN	Low Risk	Interm Risk	High Risk
Kawakami	2006	Ltd	5.7	0.87%	2%	7%
Abdollah	2010	Ltd	6.4	0.2%	1.5%	7.1%

THE ROYAL MARSDEN

Clinical correlation with pN+ status

Series		PLND	No LN	Low Risk	Interm Risk	High Risk
Kawakami	2006	Ltd	5.7	0.87%	2%	7%
Abdollah	2010	Ltd	6.4	0.2%	1.5%	7.1%
Heidenriech	2008	Ext	21	5.8%	20%	55%
Studer	2008	Ext	20	3%		
Briganti	2009	Ext	17.3	1.8%	8.2%	34%
Abdollah	2012	Ext	17.4	3.3%	8.7%	32%
Godoy	2011	Ext	16	1.7%	8.6%	24%
			Mean occult +nodes approx:	3%	11%	36%

THE ROYAL MARSDEN

Nomograms: PC Nodal Disease

Estimated risks of PC Nodal Disease:
Eg: iPSA 5, cT1, Gl 4+3

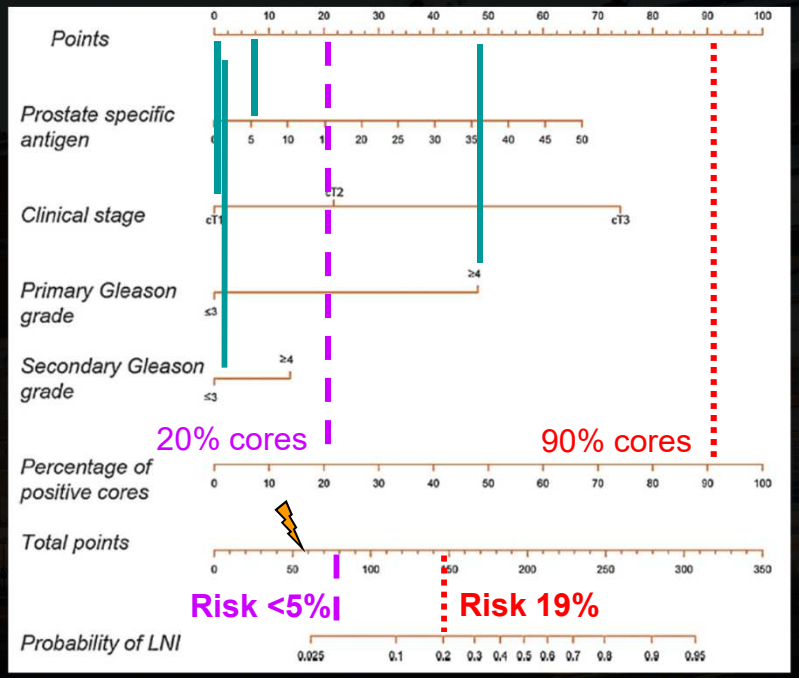

Briganti et al. Eur Urol 61: 480-7, 2012

THE ROYAL MARSDEN

Clinical Correlation of LNs at Diagnosis

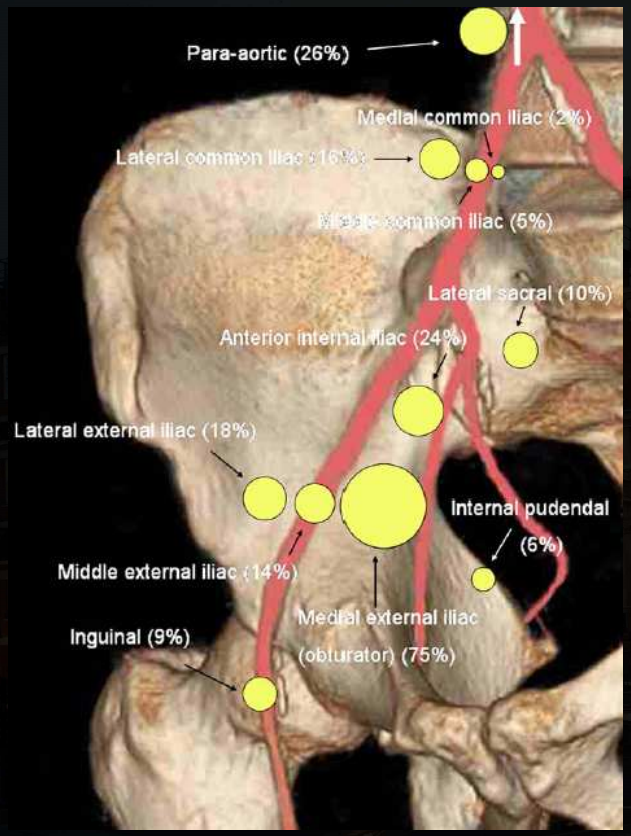

1996-2003: 54/141 cases w/o bone/visceral mets + available scans

T3-4 (62%)

Gl 8-10 (44%)

Median PSA 42 (5-965)

- Predicted LN risk: 41% (median)
- Mean/median No. LN+ve: 2
- Unilateral: 48%
- Bilateral: 52%

Jackson et al, Clin Oncol 2006

THE ROYAL MARSDEN

N-Staging: Different PET Tracers

Tracer	Clinical Case	% detected
FDG	RP	6%
	RT	12%
Choline	RP	25%
	RT	28%
Acetate	RP	20%
	RT	30%
PSMA	RP	45%
	RT	62%

Yu et al AJNMMI 2014

THE ROYAL MARSDEN

What needs to be in the nodal CTV

- The internal iliac (hypogastric) lymph nodes, including the pre-sciatic, obturator and internal pudental nodes
- The external iliac lymph nodes (medial & central chains mainly with some coverage of lateral chain if within pelvic brim)
- Pre-sacral lymph nodes anterior to the first three sacral segments.
- Some may also include all or part of the common iliac nodes (medial group anterior to sacral promontory)

THE ROYAL MARSDEN

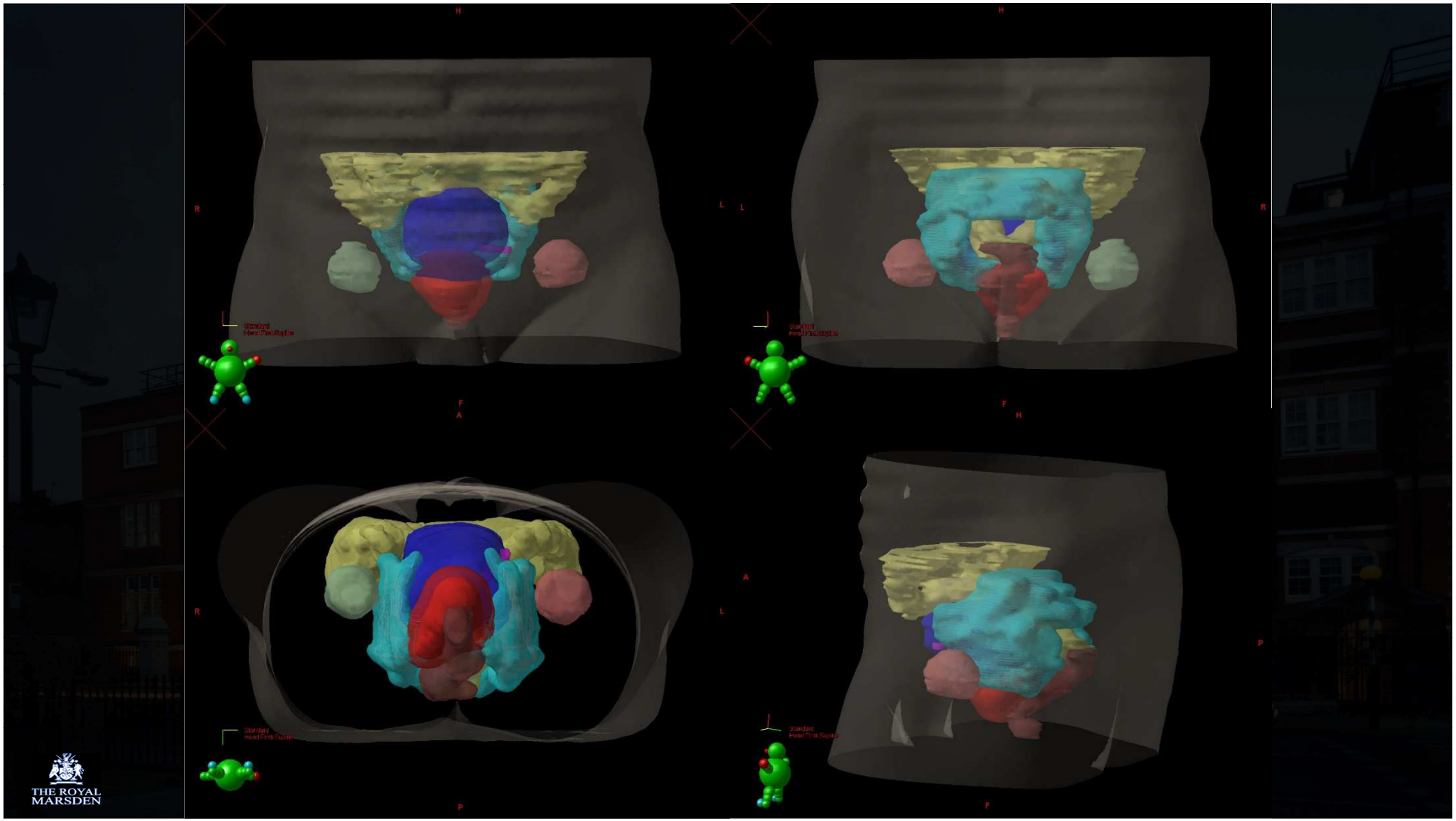
THE ROYAL
MARSDEN

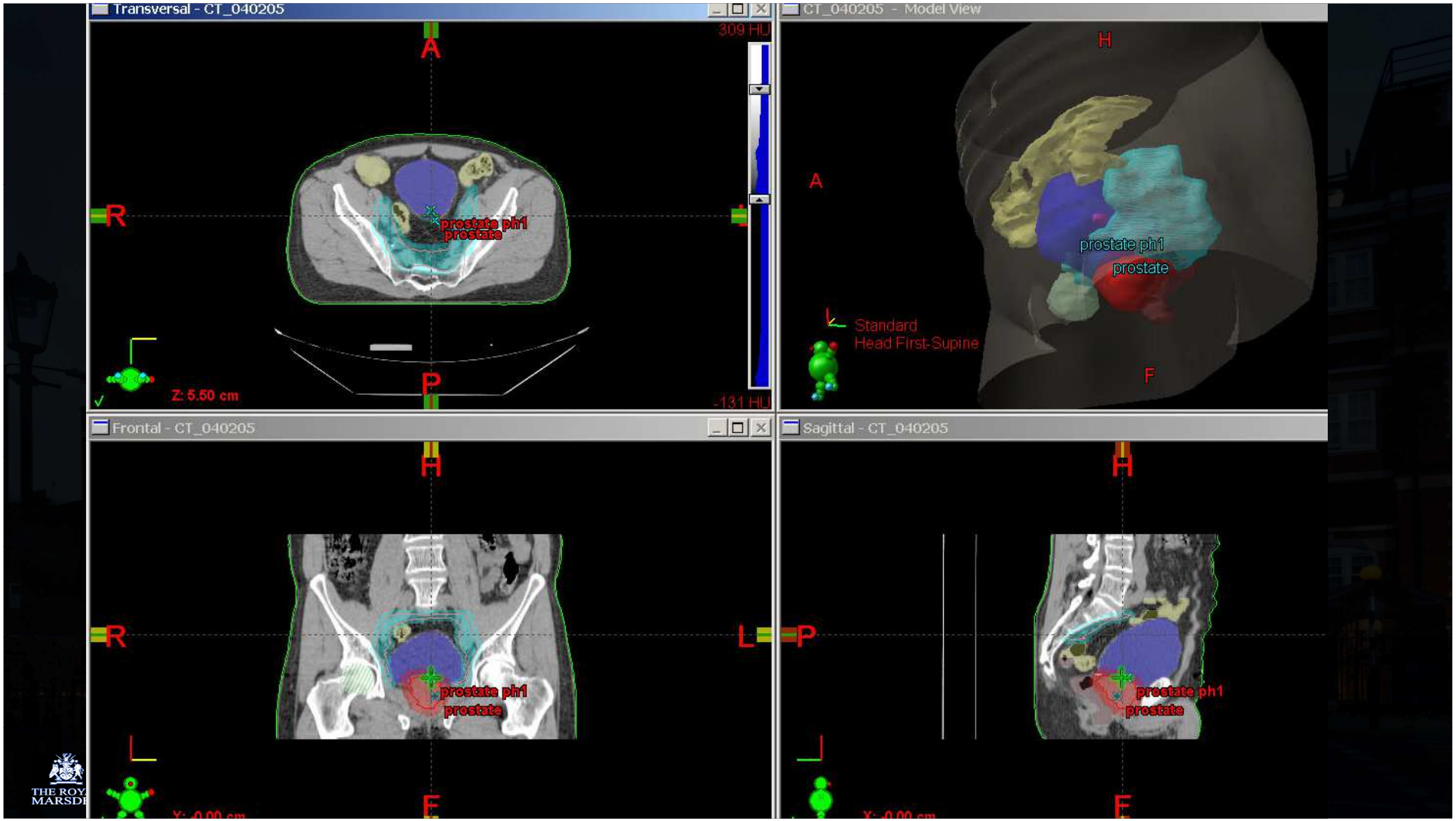
Transversal - CT_040205
309 HU
A
R
P
prostate ph1
prostate
Z: 5.50 cm
-131 HU
CT_040205 - Model View
H
A
prostate ph1
prostate
Standard
Head First-Supine
F
Frontal - CT_040205
H
R
L
prostate ph1
prostate
F
Sagittal - CT_040205
H
P
prostate ph1
prostate
F

PC: Pelvic Nodal TVD

Table 4 Comparison of different LN CTV contouring techniques

Study (ref)	Vascular expansion margin around vessels	Obturator nodal volume	Presacral nodal volume
Taylor et al (13)	7 mm with minor manual modification	18 mm medial to pelvic side wall	10-mm strip anterior to sacrum
Dinniwell et al (14)	Common iliac, 10 mm; Ext iliac, 9 mm; Int iliac, 10 mm	22 mm medial to pelvic side wall	12-mm strip anterior to sacrum
Shih et al (15)	20 mm	20 mm around ext iliac (90 mm inf to CI bifurcation); 20 mm around int iliac (85 mm inf to CI bifurcation)	Not specified
Lawton et al (16) (RTOG technique)	7 mm	Not specified	10-mm strip anterior to sacrum
RMH technique (18)	NA (freehand technique)	Freehand, to include vessels, nodes, and small white dots	15-mm strip anterior to sacrum
PIVOTAL technique	7 mm (laterally and A-P with sup/inf extent formalized)	18 mm medial to pelvic side wall	12-mm strip anterior to sacrum

Abbreviations: A-P = anteroposterior; CI = 95% confidence interval; CTV = clinical target volume; Ext = external; inf = inferior; Int = internal; LN = lymph node; NA = not applicable; PIVOTAL = Prostate and pelvIs Versus prOsTate Alone treatment for Locally advanced prostate cancer; RMH = Royal Marsden Hospital; RTOG = Radiation Therapy Oncology Group; sup = superior.

THE ROYAL MARSDEN

Harris et al IJROBP 2015

PC: PIVOTAL Nodal TVD

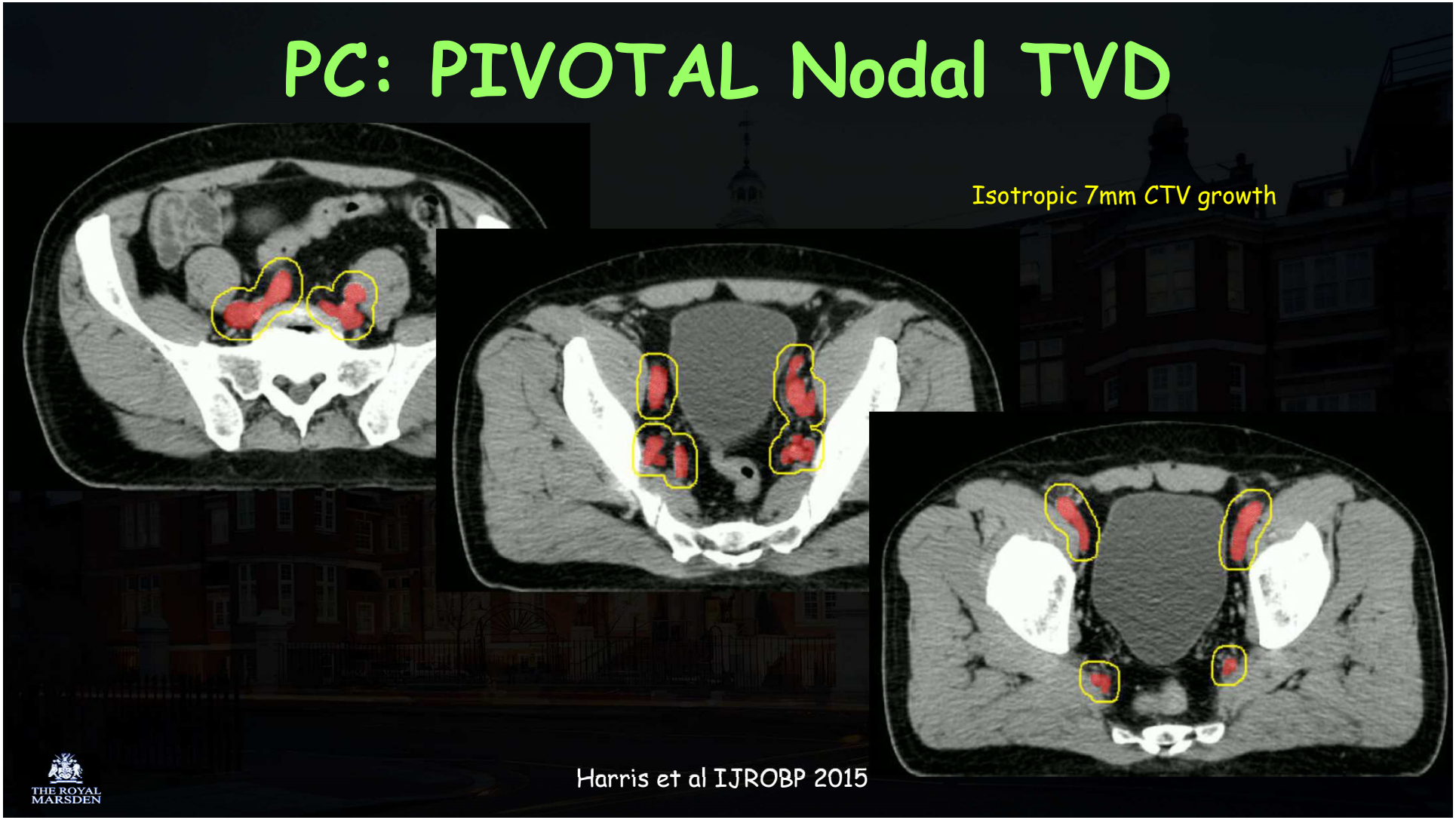

PC: PIVOTAL Nodal TVD

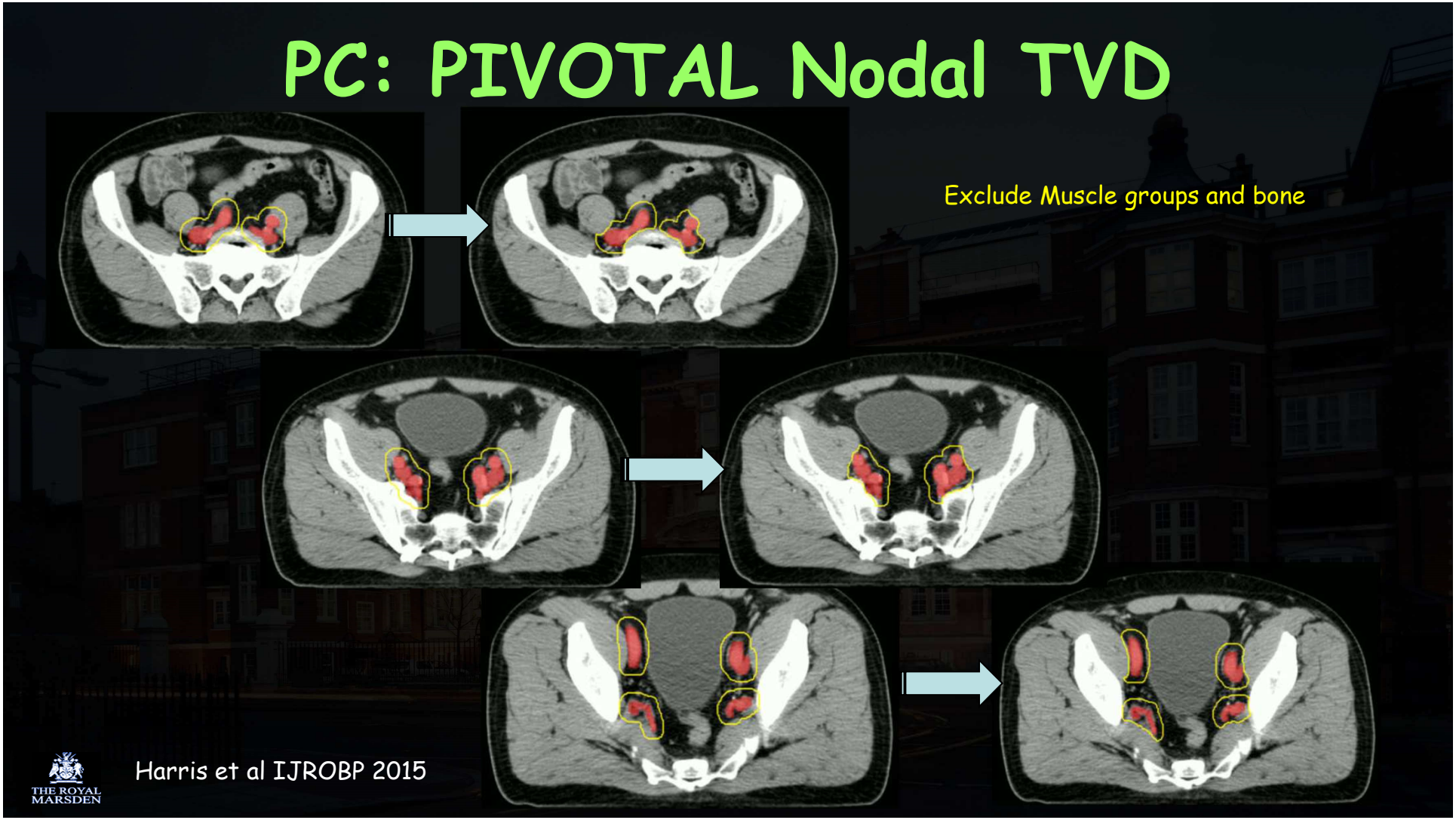

PC: PIVOTAL Nodal TVD

12 mm rollerball
Along anterior S1-S3

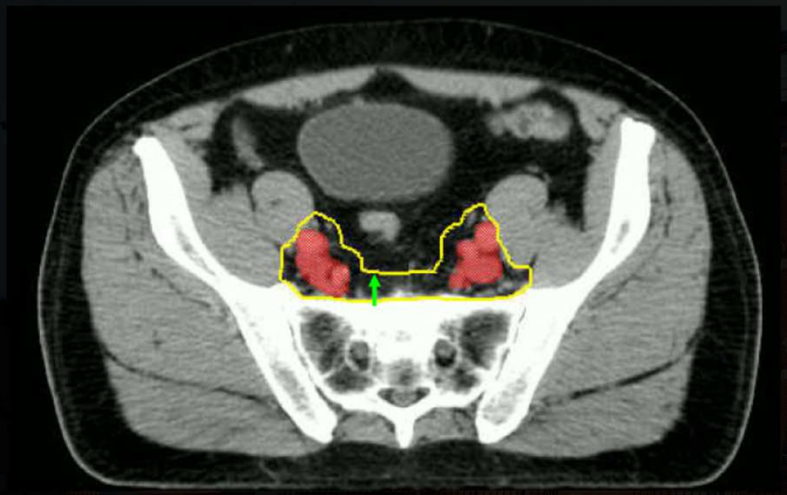

Exclude Muscle groups

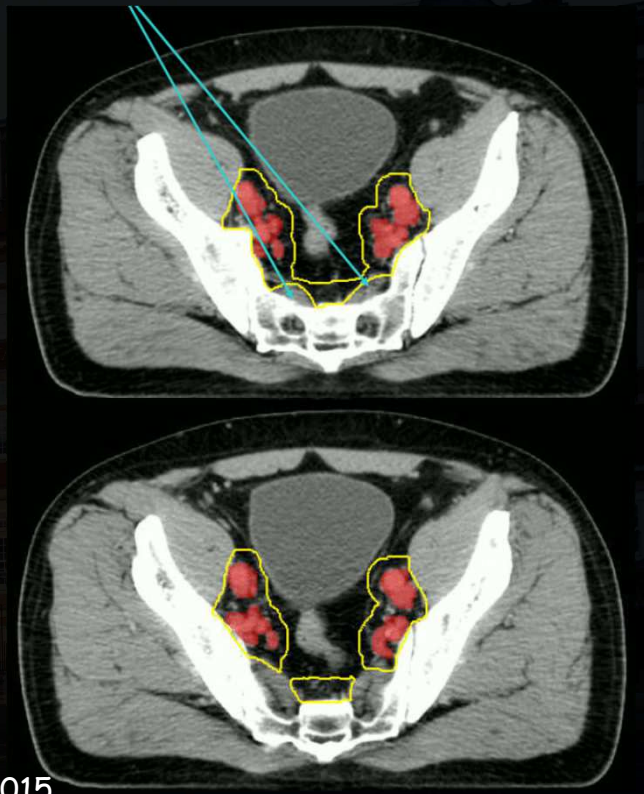

Harris et al IJROBP 2015

THE ROYAL MARSDEN

PC: PIVOTAL Nodal TVD

18 mm rollerball
Along inner surface of bony pelvis
Exclude muscle groups

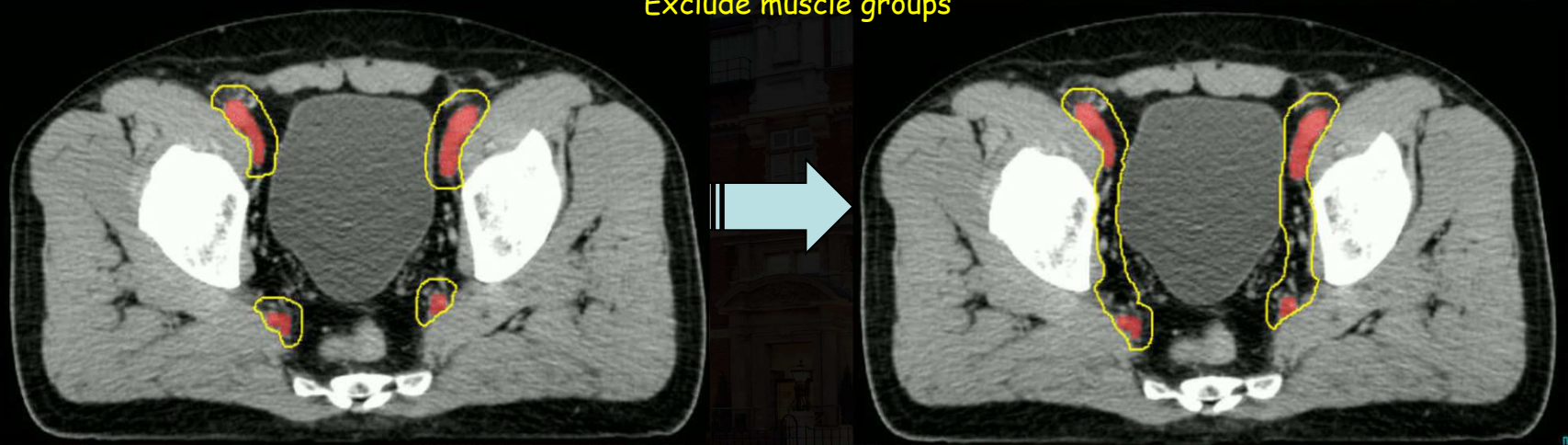

Harris et al IJROBP 2015

THE ROYAL MARSDEN

PC: PIVOTAL Nodal TVD

Expand bowel by 3mm (BEM = Bowel expansion margin)
Edit LN CTV to exclude BEM, Bladder and Rectum

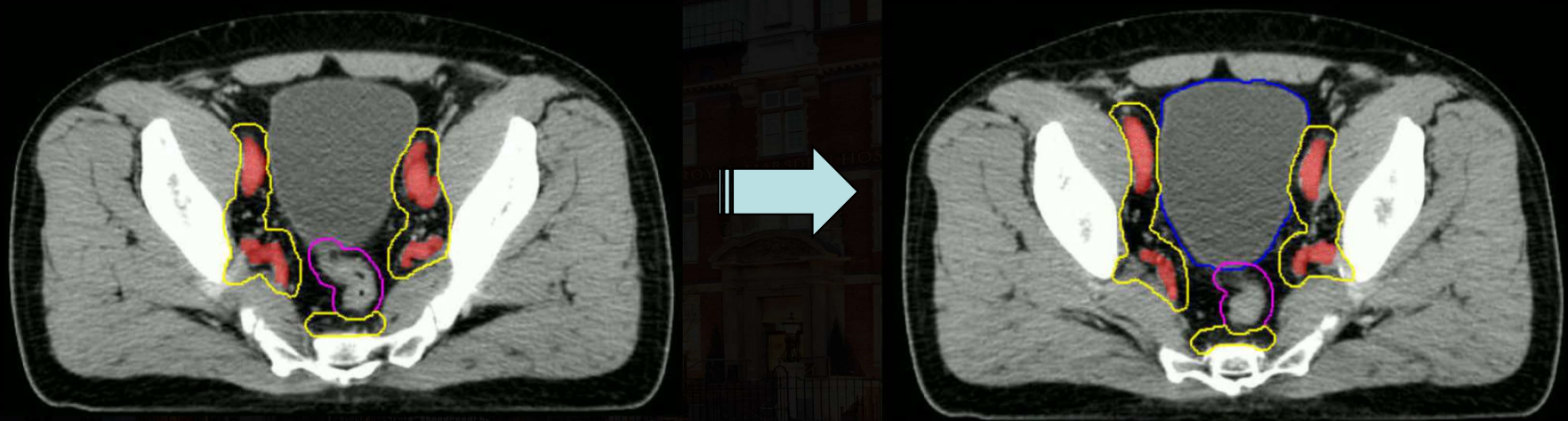

Harris et al IJROBP 2015

THE ROYAL MARSDEN

PC: PIVOTAL Nodal TVD

At top of femoral heads, the external iliac vessels are no longer included
Volumes then include the obturator regions inferiorly until 1m above pubic symphysis

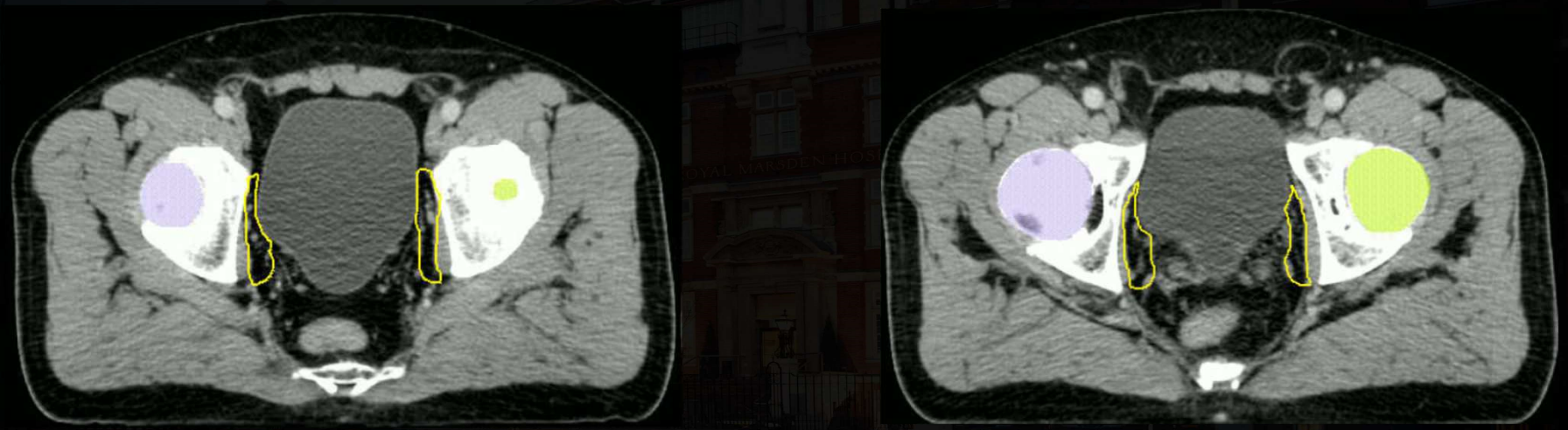

Harris et al IJROBP 2015

THE ROYAL MARSDEN

Take Home Message

- Increasing rationale but controversial for including pelvic nodes in prostate XRT
  - need to define levels of 'risk'
- Already clinically indicated in other pelvic cancers
  - need to participate in 'clinical trials'
- Be aware of the volume effect
- New technology to improve XRT therapeutic ratio
  - USPIO agents to identify nodes
  - dw-MRI and dceMRI
  - PET (Choline/PSMA) for biological information
  - IMRT to reduce toxicity and enable target boosting
  - 4D assessments for PTV (IM & SM) & IGRT

THE ROYAL MARSDEN

Thank you
THE ROYAL MARSDEN

ESTRO School

WWW.ESTRO.ORG/SCHOOL

Imaging for Determining the Gross Tumor Volume (GTV): CNS Tumors

Stefan Delorme

Learning Objectives

- To understand potential and limitations of CT, MRI and PET for detection and characterization of CNS tumors
- CT
- MRI
- PET/CT
- Functional imaging

ESTRO School

MODALITIES AND ANATOMY

ESTRO School

CT

- Not state-of-the-art for diagnosis, esp. low grade glioma
- For planning purposes and emergencies
- Only if MRI not possible or available
- Exceptions:
  - ➢ High grade glioma
  - ➢ Meningioma
  - ➢ AVMs

Slice orientation

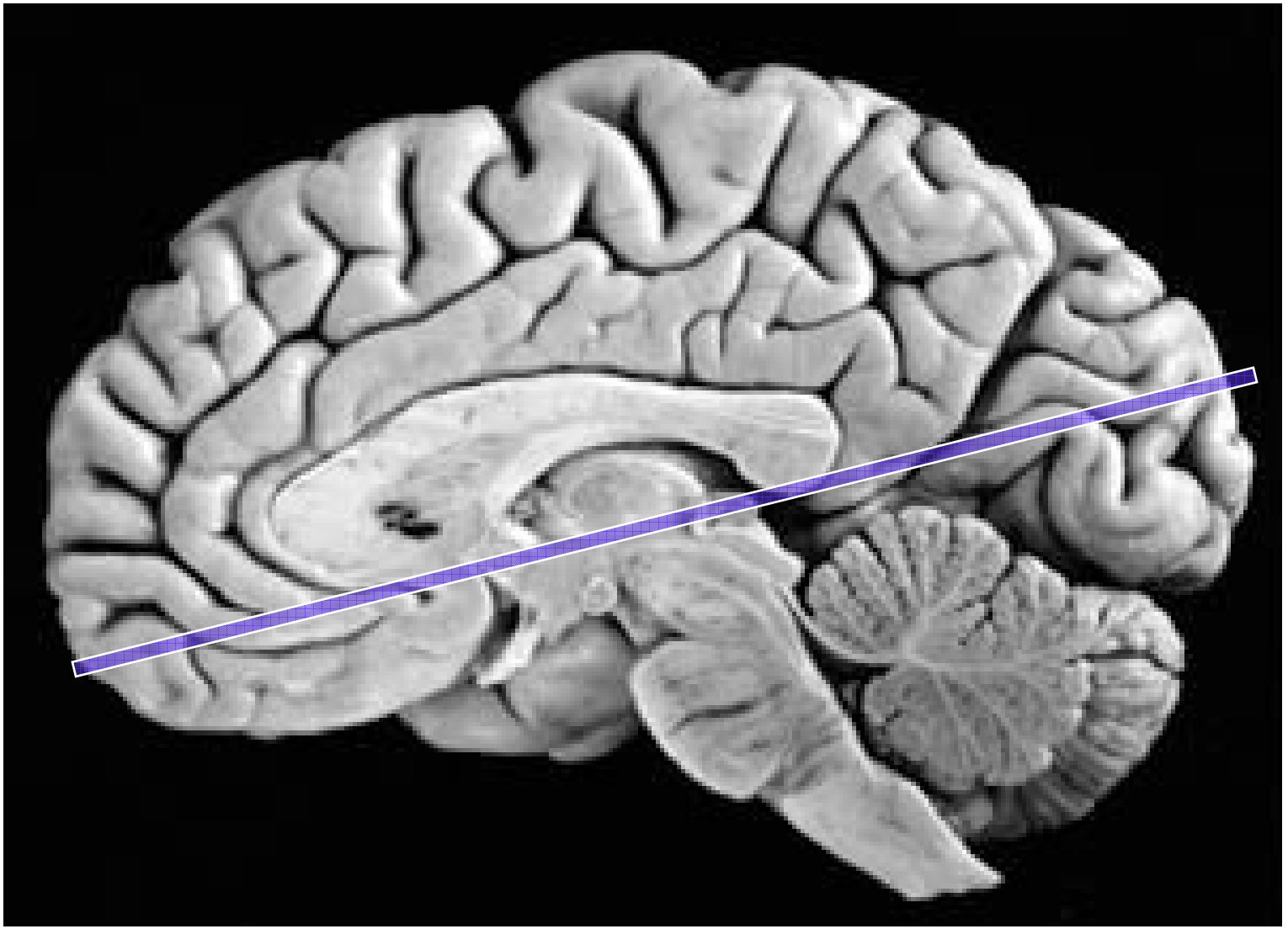

ESTRO School

Image contrasts

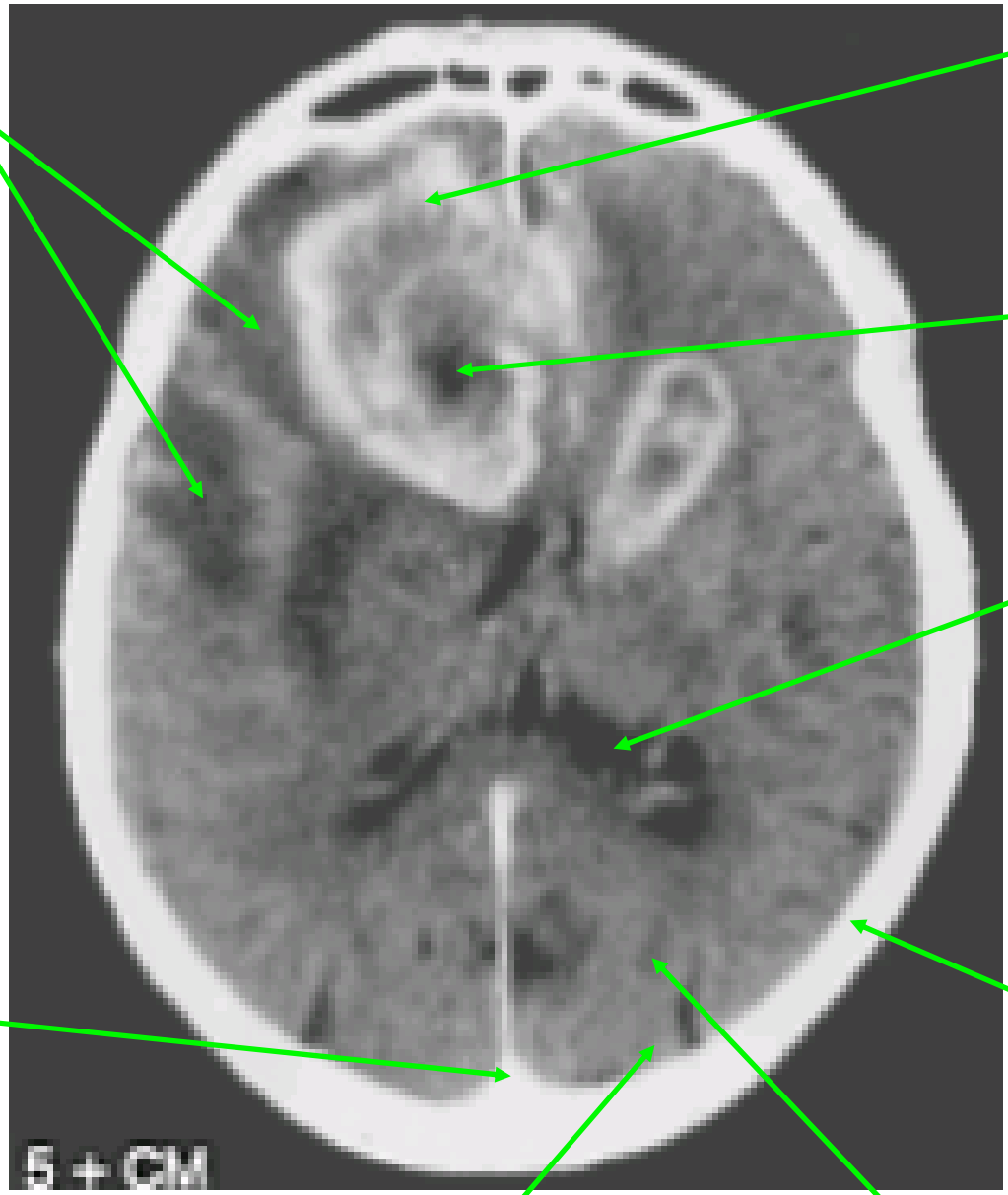

Tumour

Oedema

Necrosis

CSF

Contrast medium

Bone

Grey matter

ESTRO School

Slice by slice...

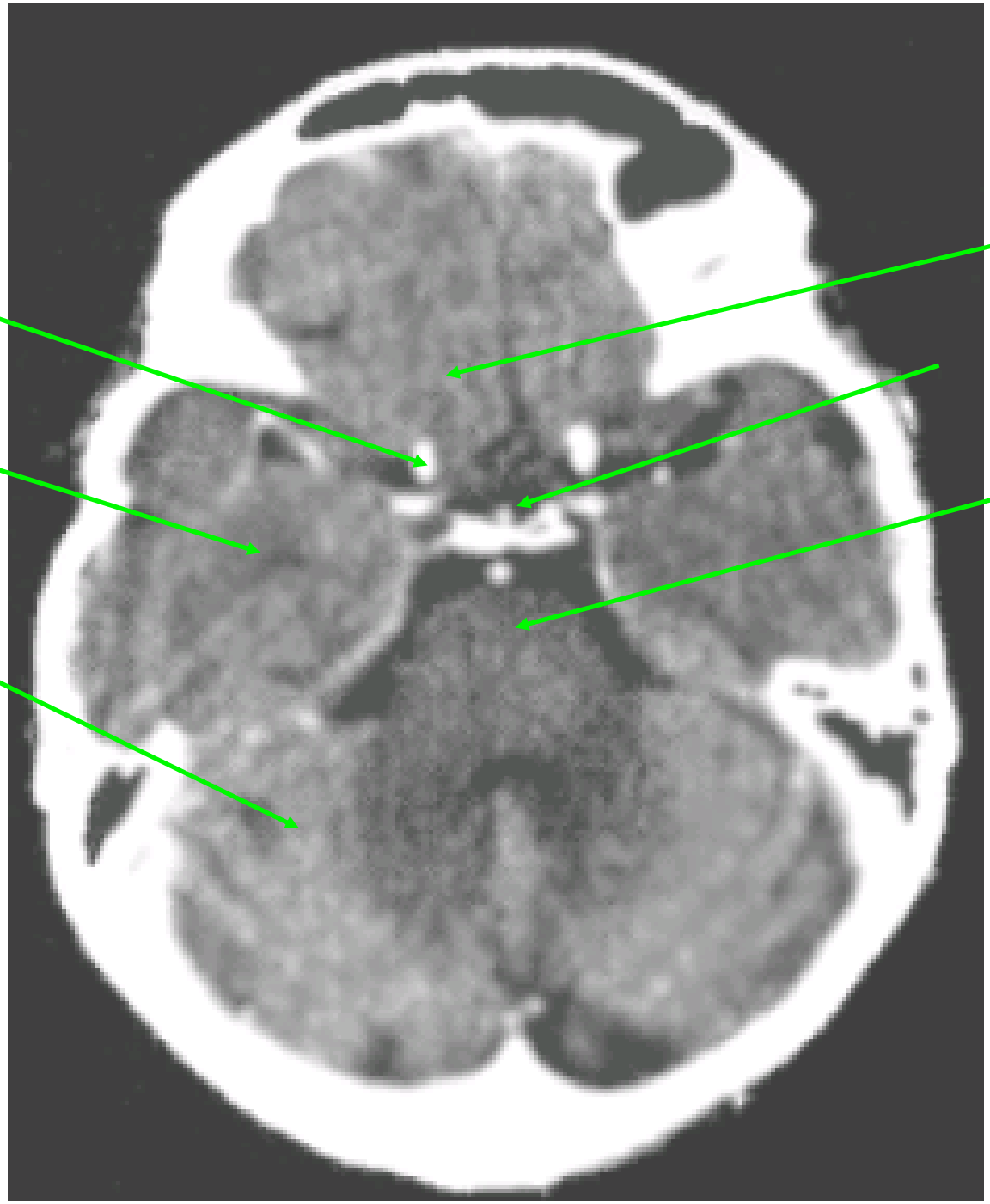

ESTRO School

Slice by slice...

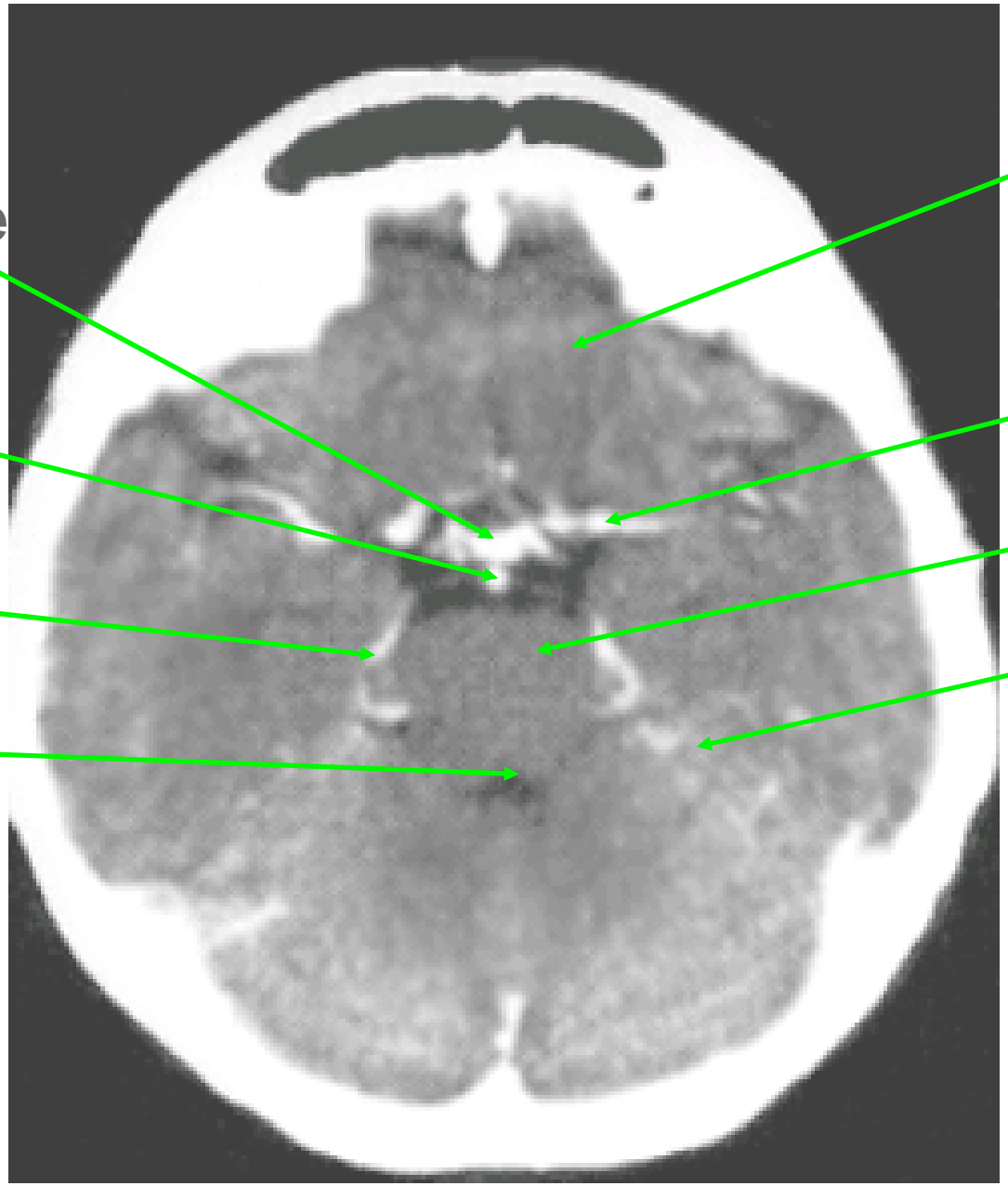

ESTRO School

Slice by slice...

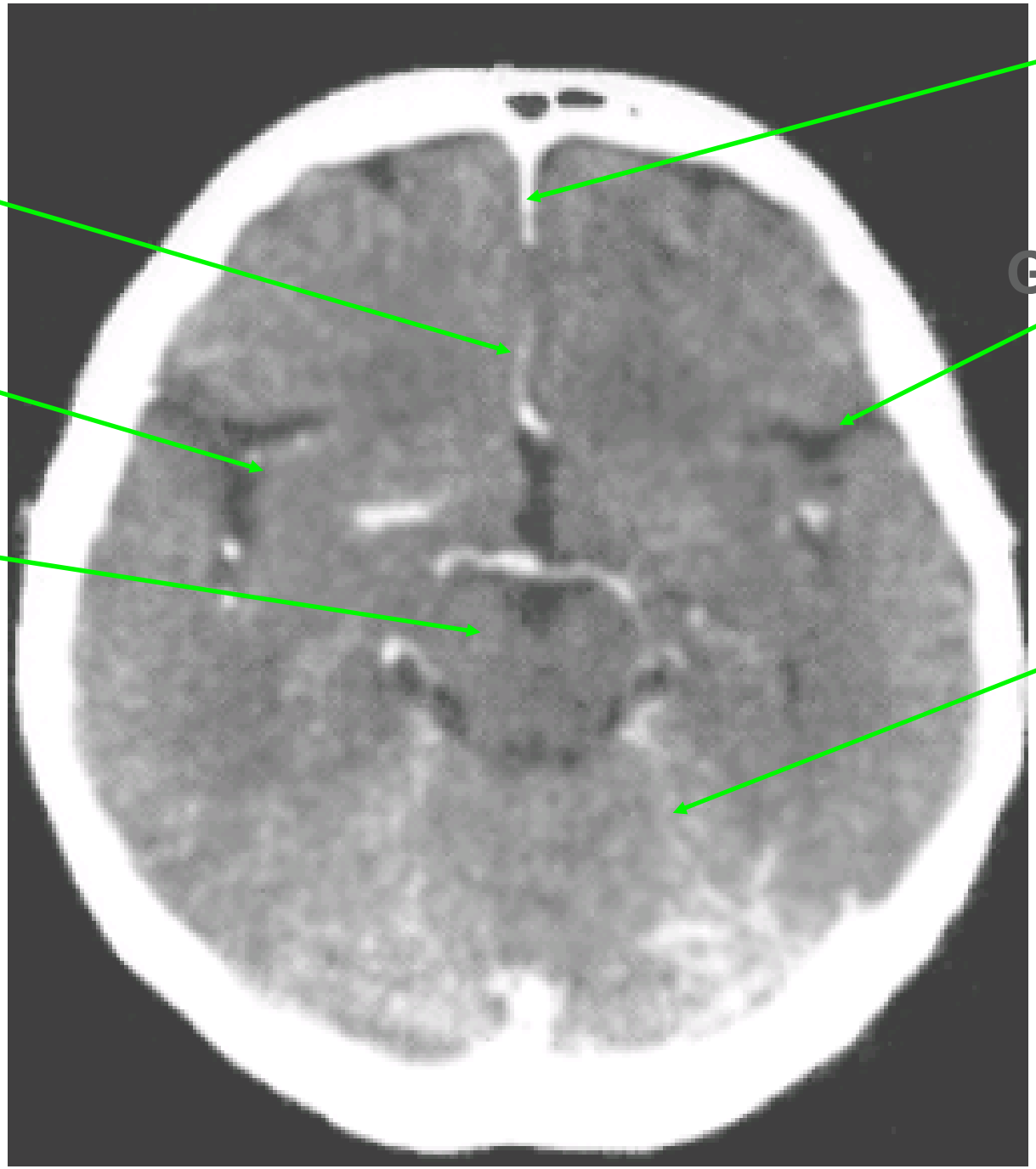

ESTRO School

Slice by slice

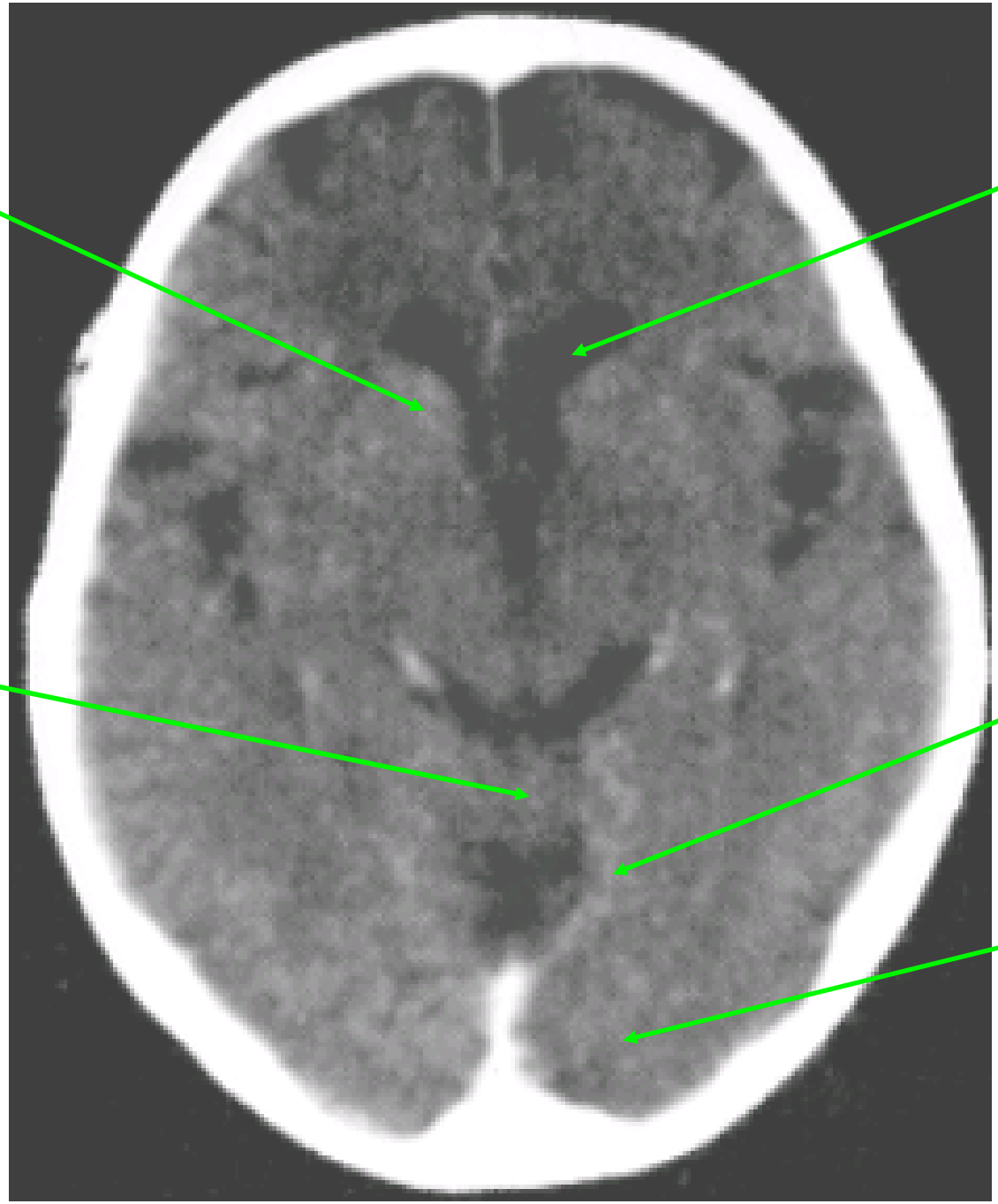

ESTRO School

Slice by slice...

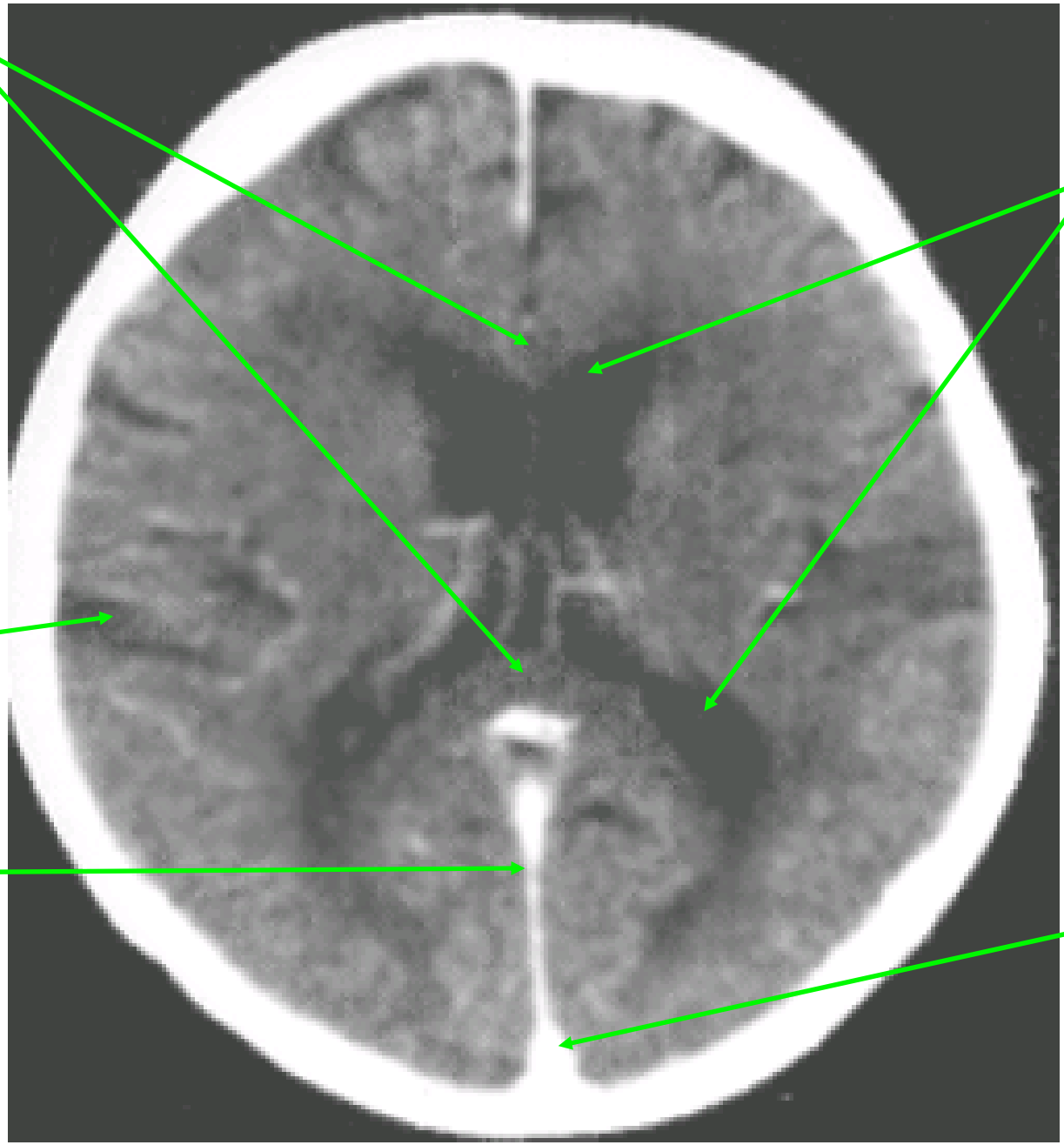

ESTRO School

Slice by slice...

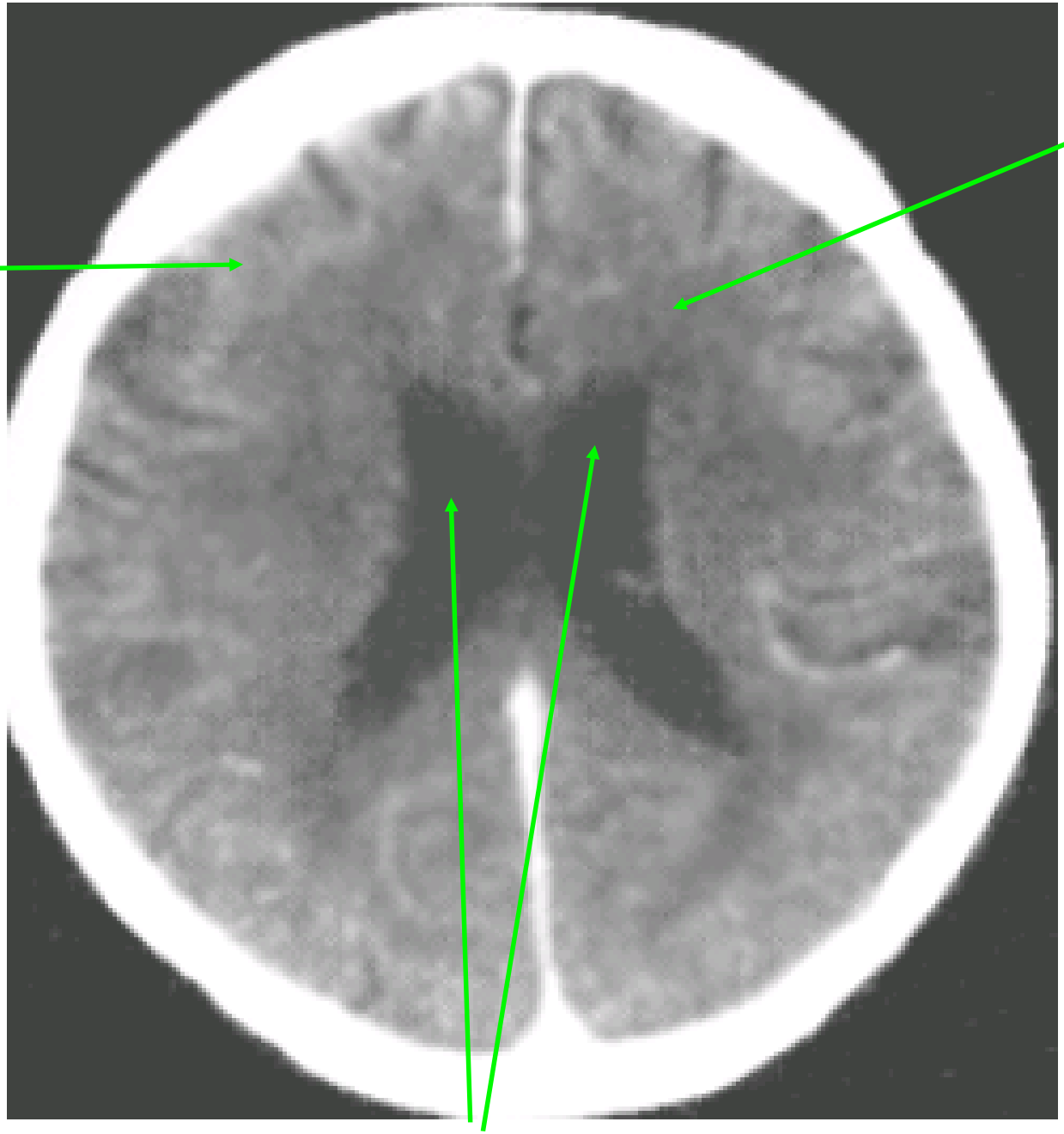

Glioma

MRI

- State-of-the art for detection, delineation, and characterization
- Functional imaging, incl.
  - MR angiography
  - Perfusion
  - Flow
  - Neurofunctional MRI (BOLD)
  - Diffusion imaging (DWI+DTI)
  - MR spectroscopy

Image contrasts: T1-weighted

Bright:

- **Short T1:**
  - **Fat**
  - **Hematoma (depending on age !)**
  - **Contrast medium: Disturbance of blood-brain barrier**
  - **Proteins**

Dark:

- **Long T1:**
  - **Water**
  - **Bone, Calcium**
- **Moving blood**
- **Air**

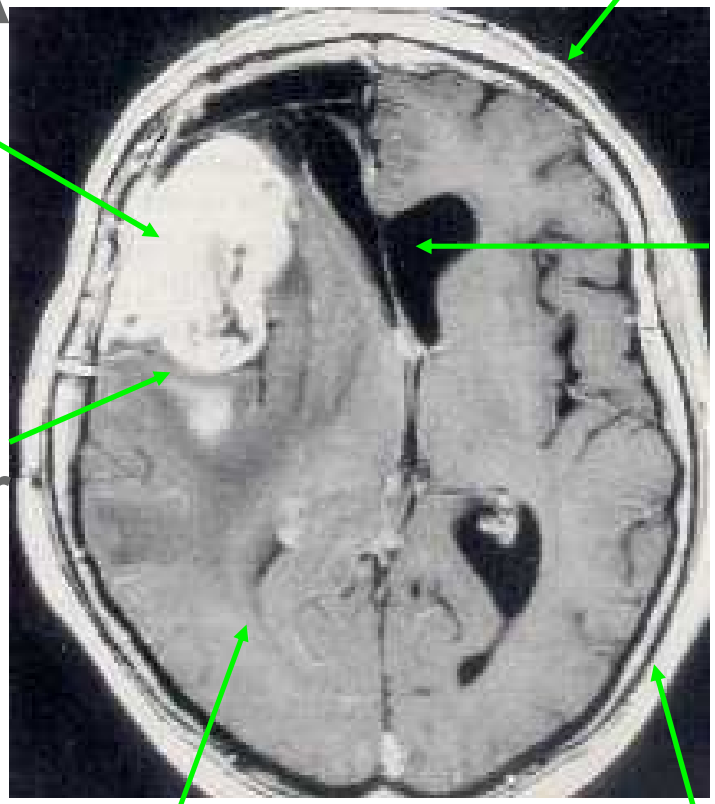

ESTRO School

Image contrasts: T2-weighted

Bright:

- Long T2:
  - Fat
  - Hematoma (Methemoglobin)
  - Fluid
  - Most tumours

Dark:

- Short T2:
  - Contrast medium
  - Bone, Calcium
  - Hematoma (Hämosiderine)
- Moving blood
- Air

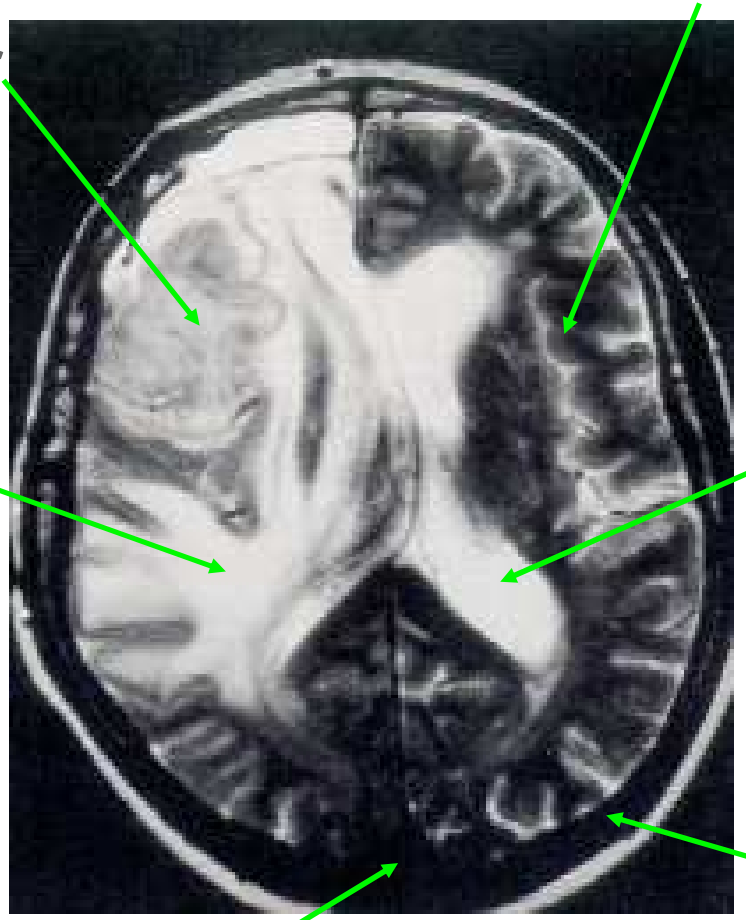

Image Contrasts: FLAIR

FL uid
A ttenuated
I nversion
R ecovery

= T2 with dark fluid

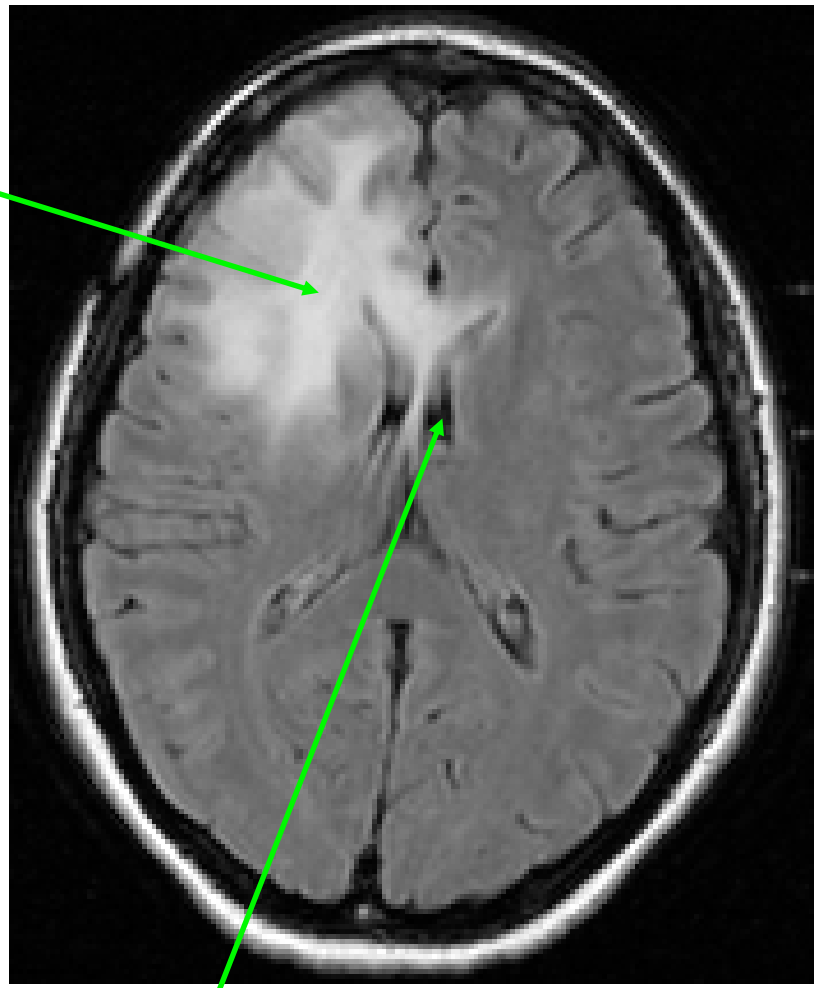

ESTRO School

Image contrasts: Proton-weighted

Bright:

- Fat
- Fluid
- Tumours

Dark:

- Blood flow
- Air
- Bone

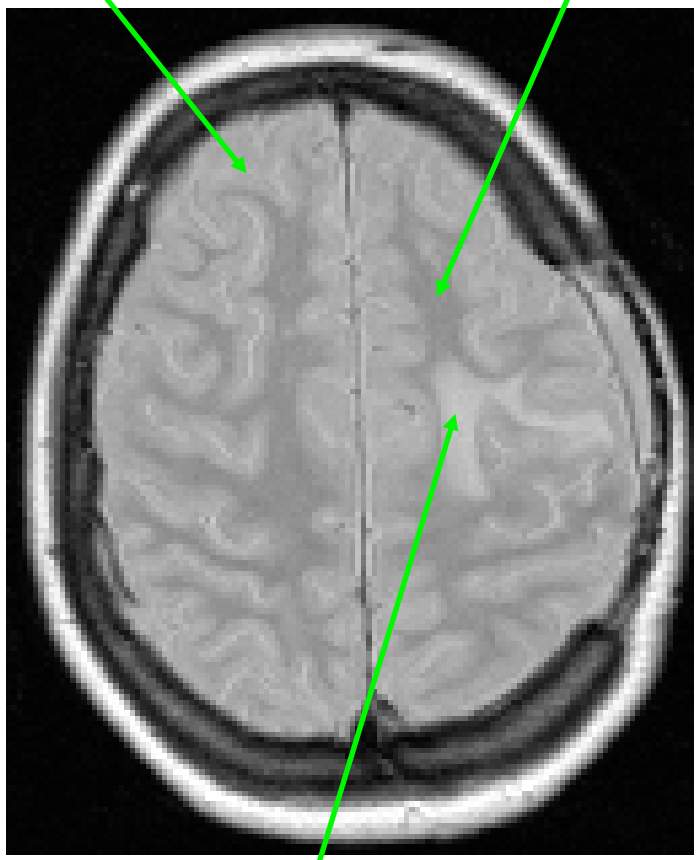

ESTRO School

Intracranial tumors

- Intraaxial
  - Supratentorial
    - » Glioma
    - » Lymphoma
    - » Metastases
  - Infratentorial
    - » Glioma
    - » Medulloblastoma
    - » Ependymoma
    - » Hemangioblastoma
- Extraaxial

  Supratentorial
  - » Meningioma
  - » Pituitary adenoma
  - » Bone tumors
  - » Meningial metastases
  - Infratentorial
    - » Schwannoma
    - » Meningioma
    - » Epidermoid
    - » Chordoma

ESTRO School

CT and MRI

- Grade II glioma, supratentorial, intraaxial

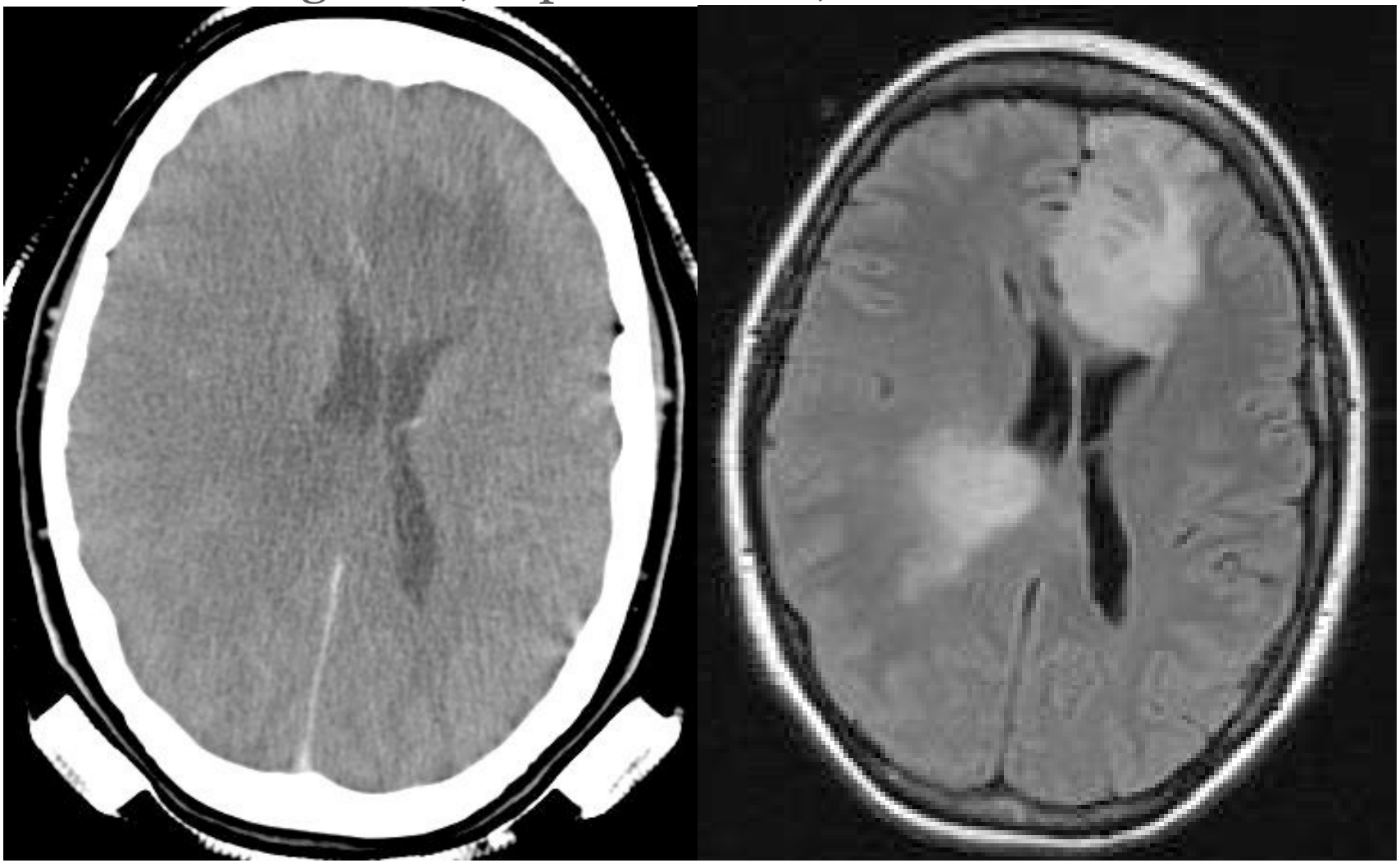

ESTRO School

CT and MRI

- Oligodendroglioma, supratentorial, intraaxial

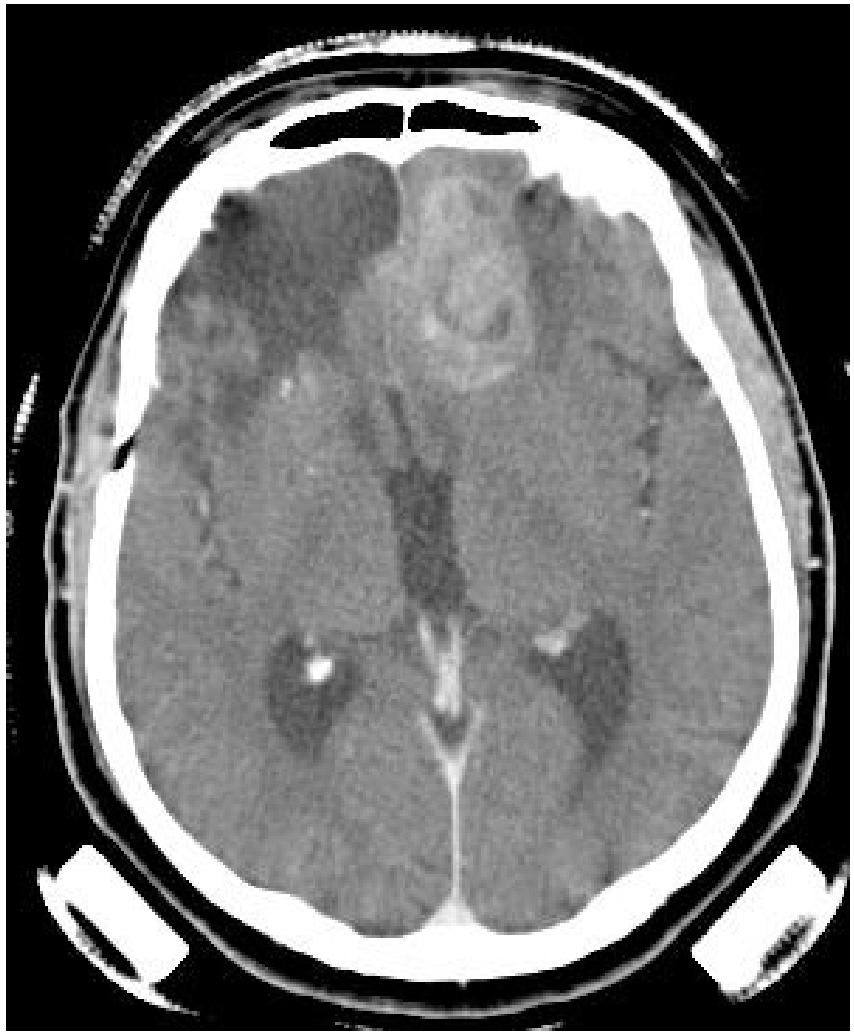

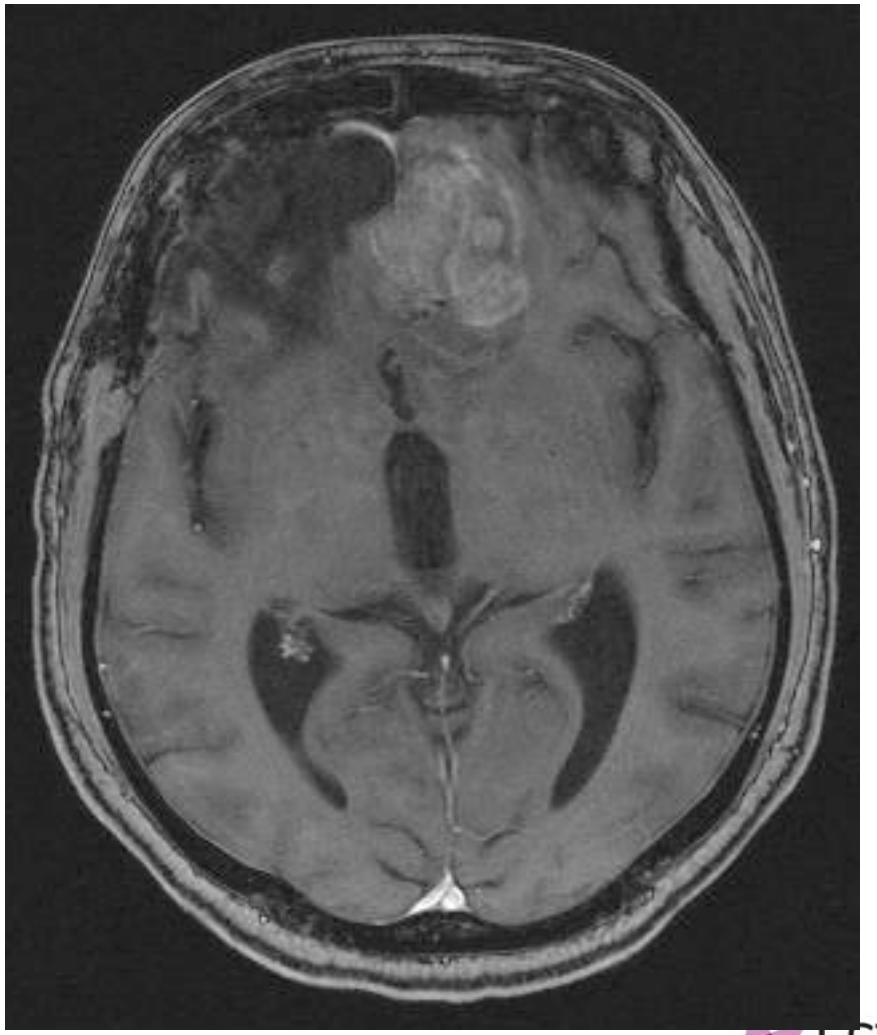

ESTRO School

CT and MRI

- Metastasis, supratentorial, intraaxial

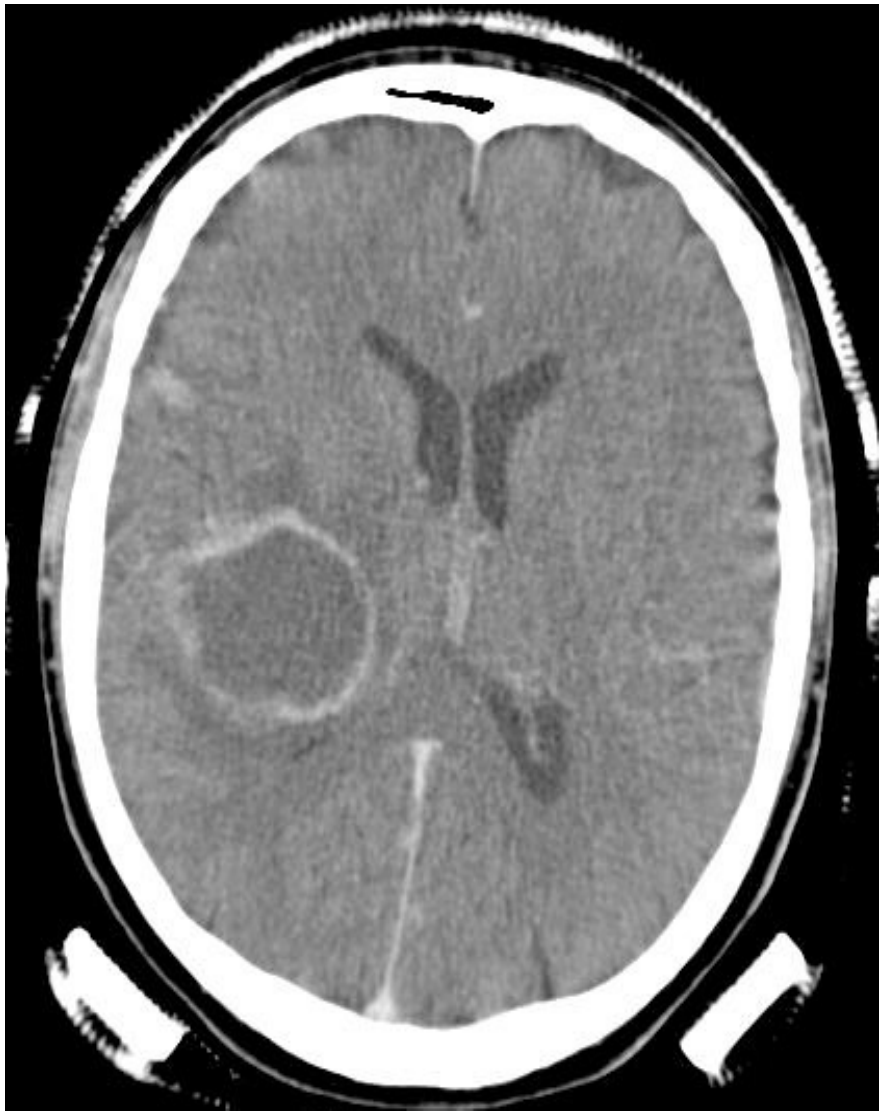

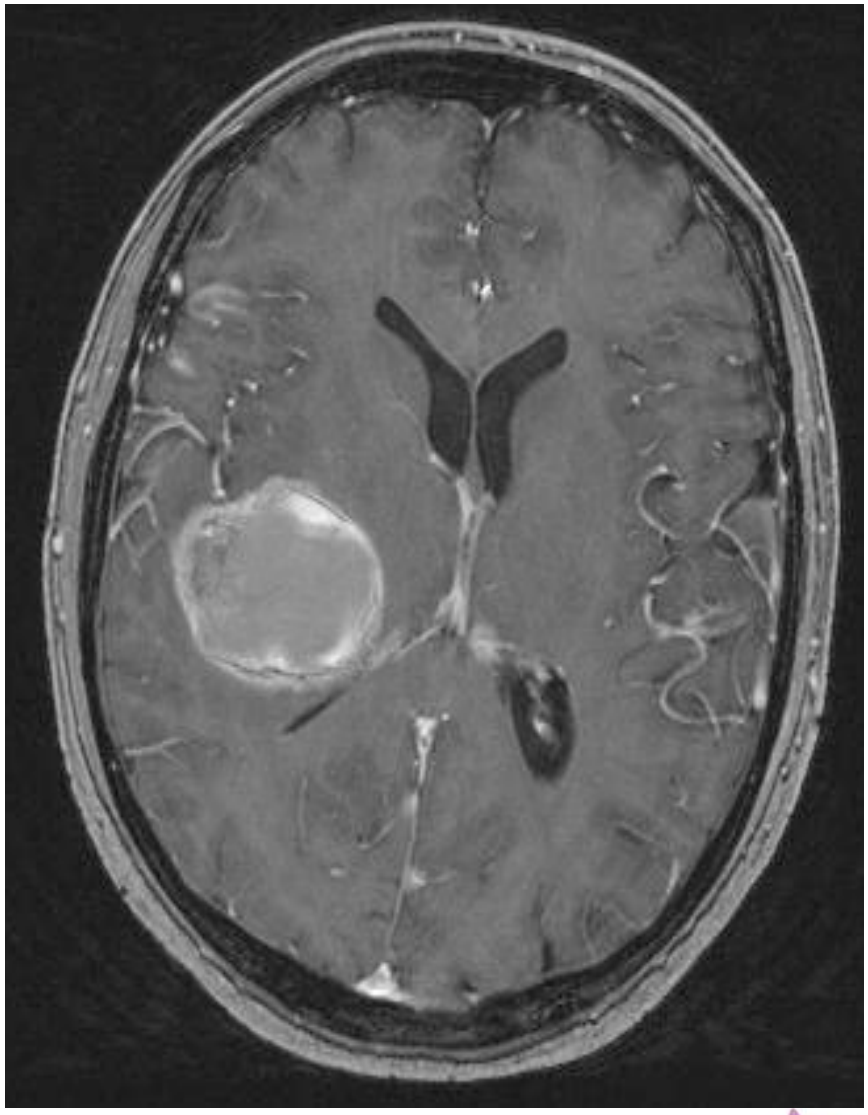

MRI Melanotic brain metastasis

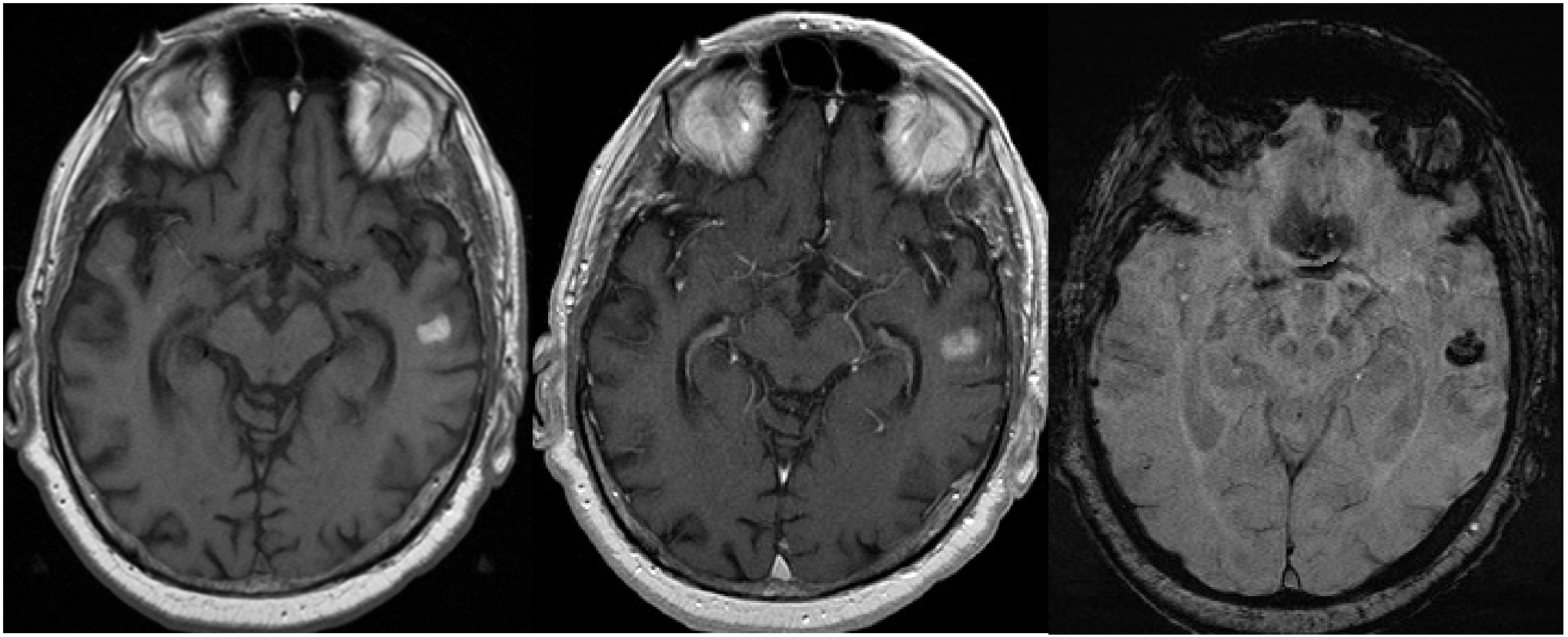

T1 unenhanced **T1 + CM** **SWI**

MRI: Amelanotic metastasis from melanoma

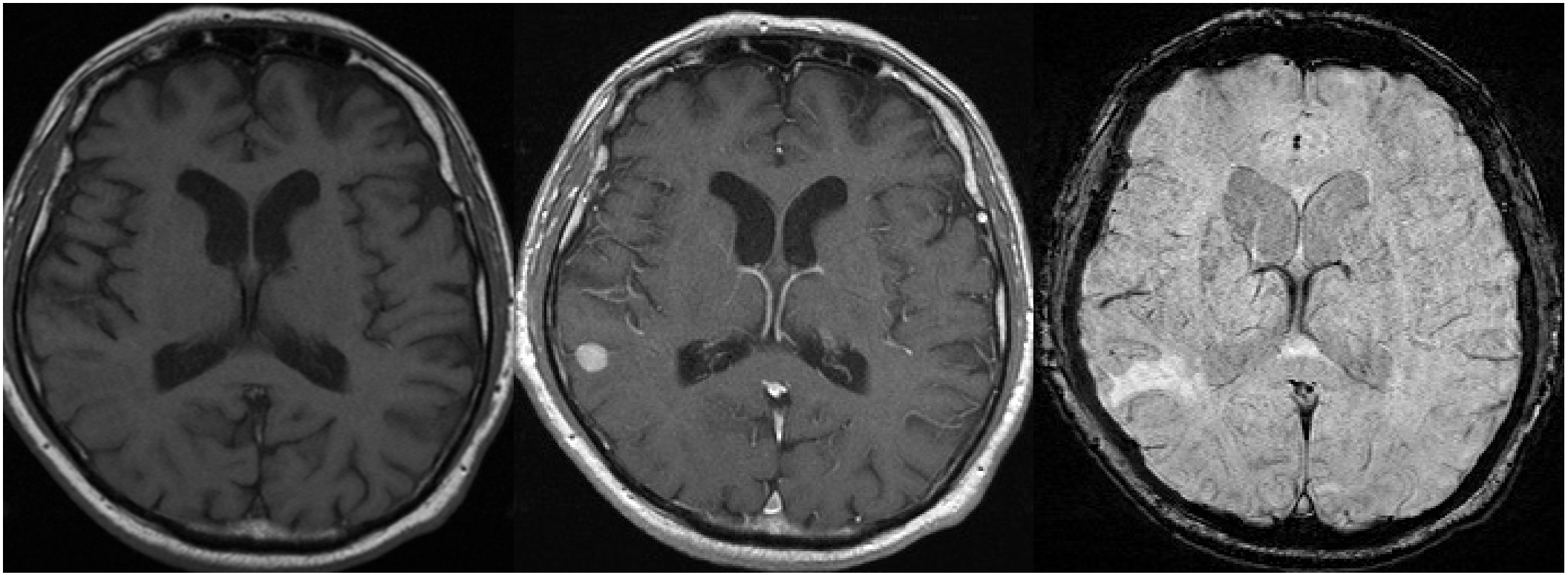

T1 unenhanced **T1 + CM** **SWI**

MRI: Hemorrhagic brain metastasis

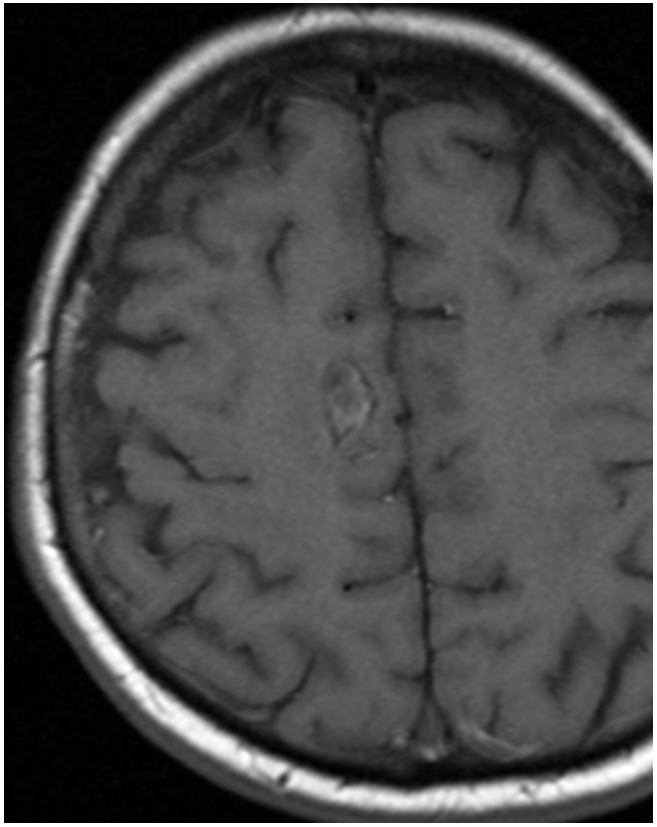

T1 unenhanced

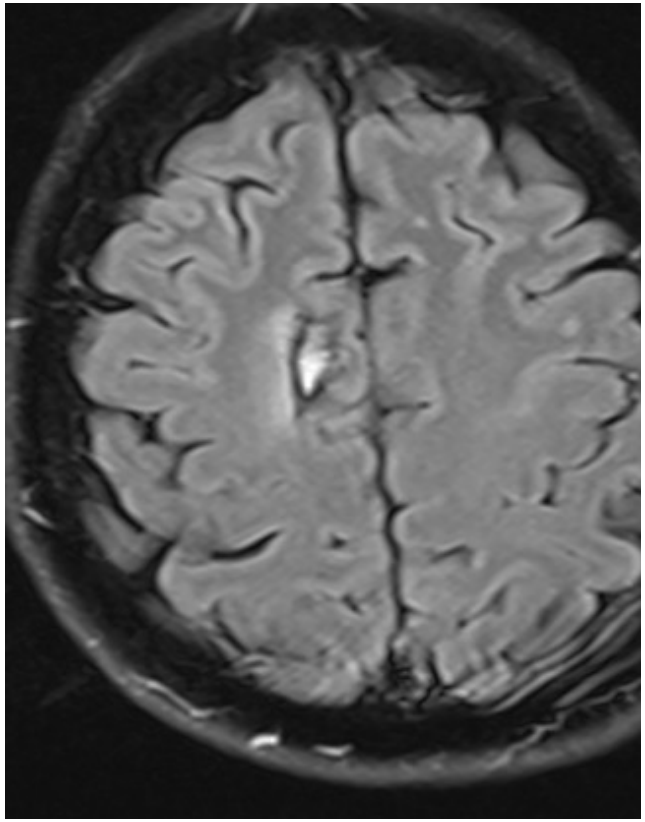

FLAIR

SWI

ESTRO School

CT and MRI

- Meningioma, supratentorial, extraaxial

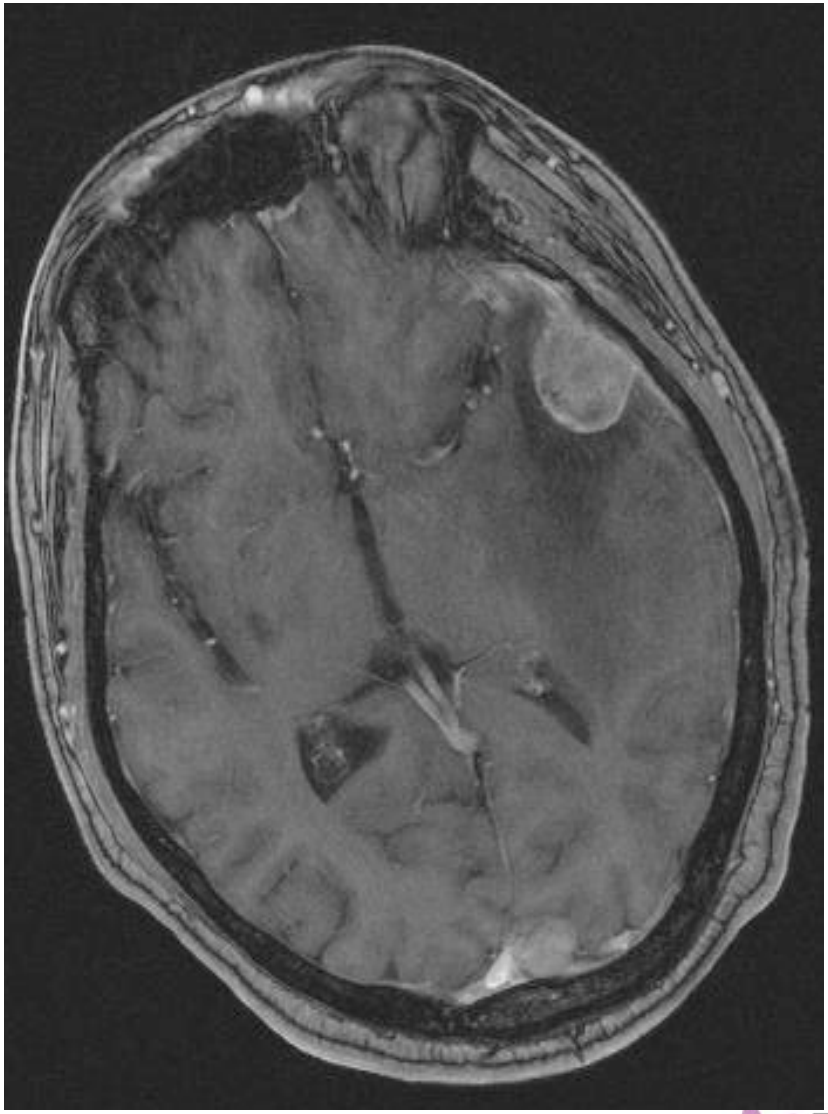

ESTRO School

MRI: Acoustic Schwannoma

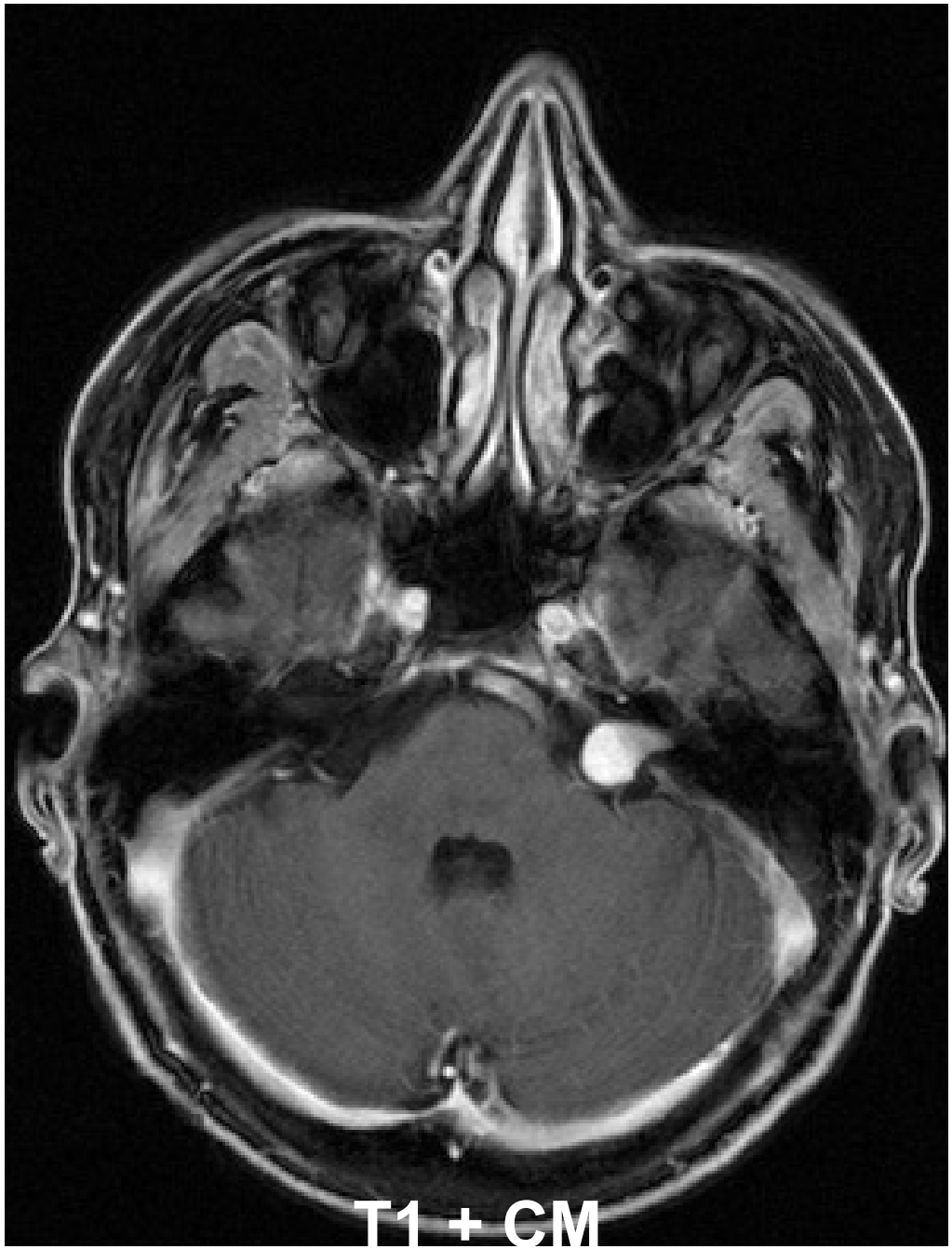

ESTRO School

MRI: Value of FLAIR

- Delineation: recurrent glioma

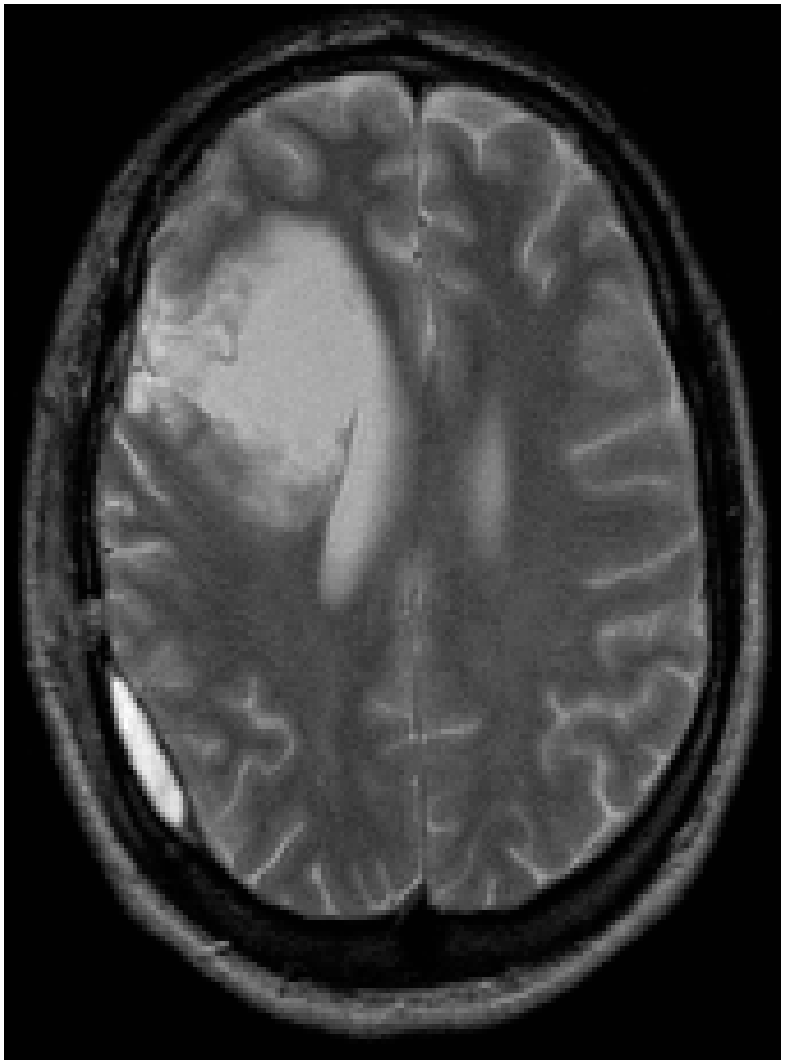

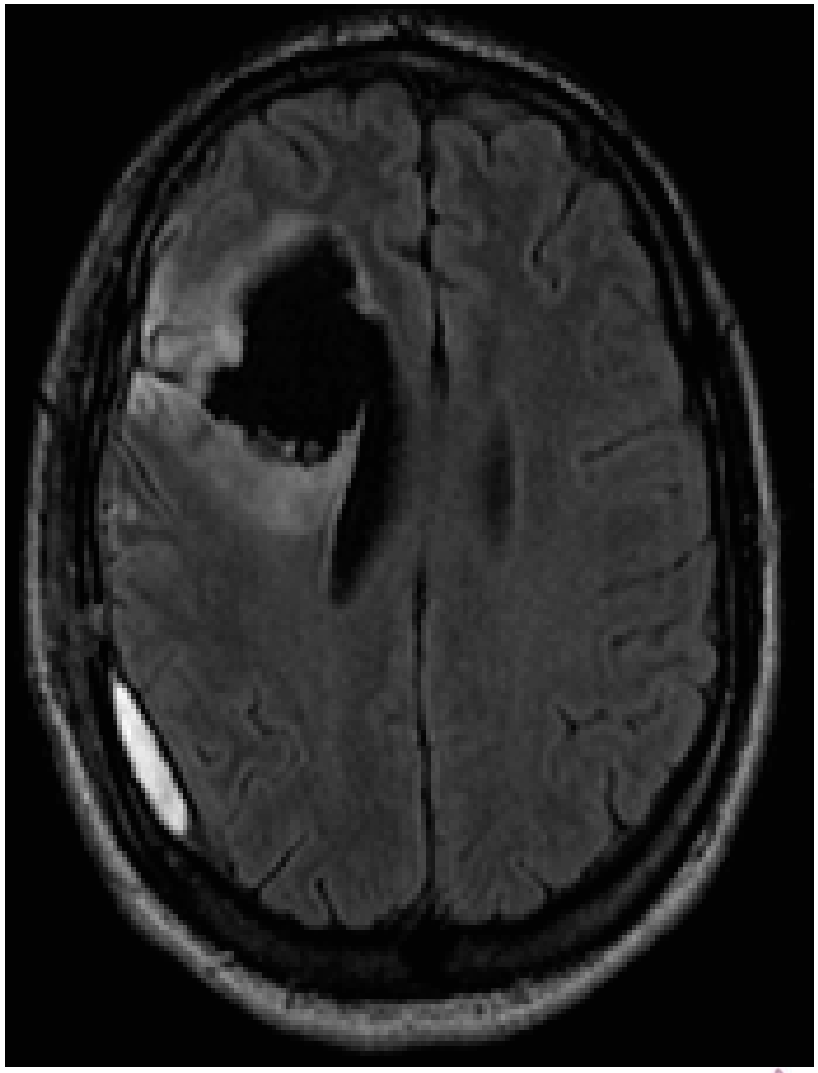

ESTRO School

GRADING OF GLIOMAS

ESTRO School

Pilocytic Astrocytoma (WHO I)

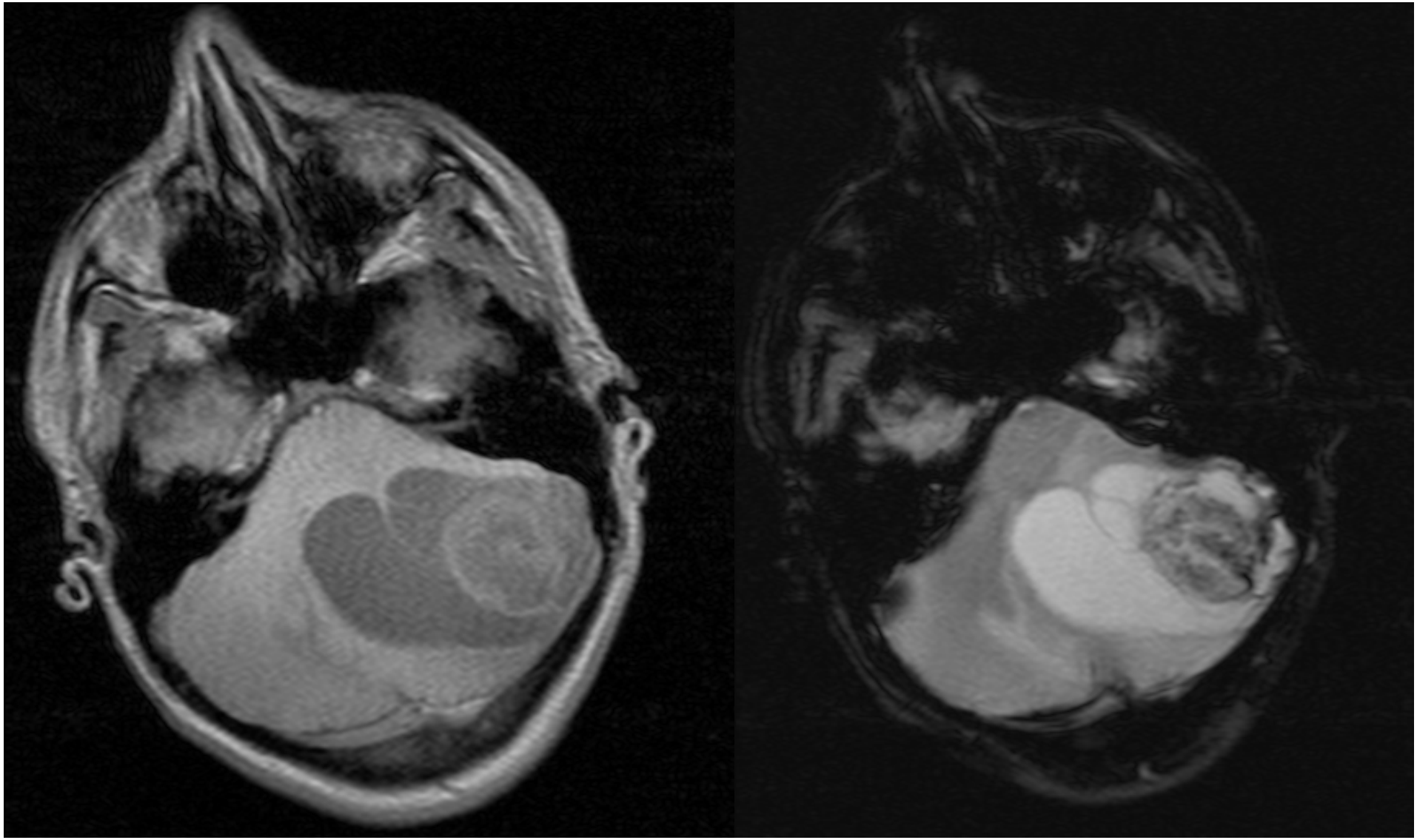

Pilocytic astrocytoma (WHO I)

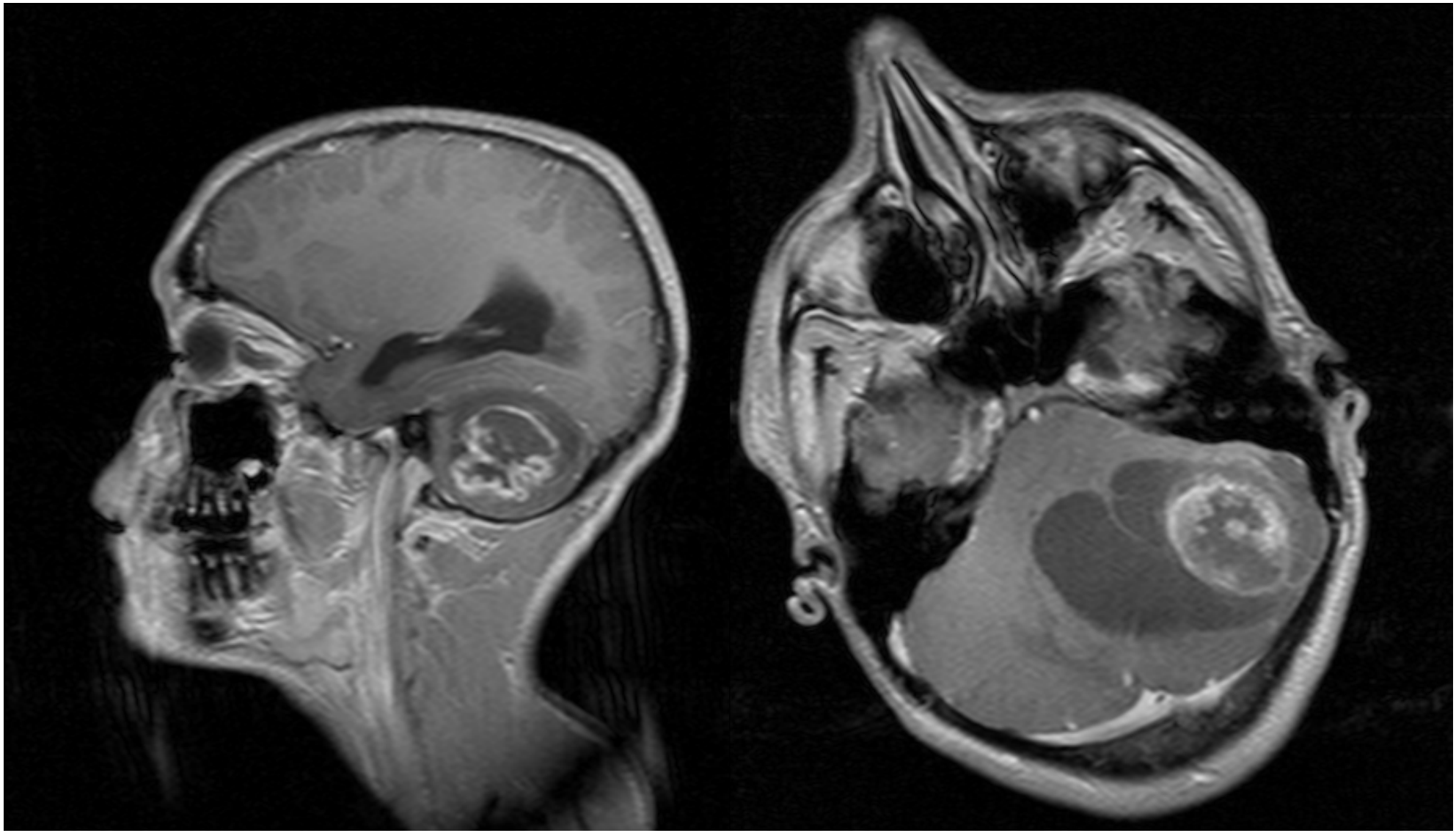

Fibrillary Astrocytoma (WHO II)

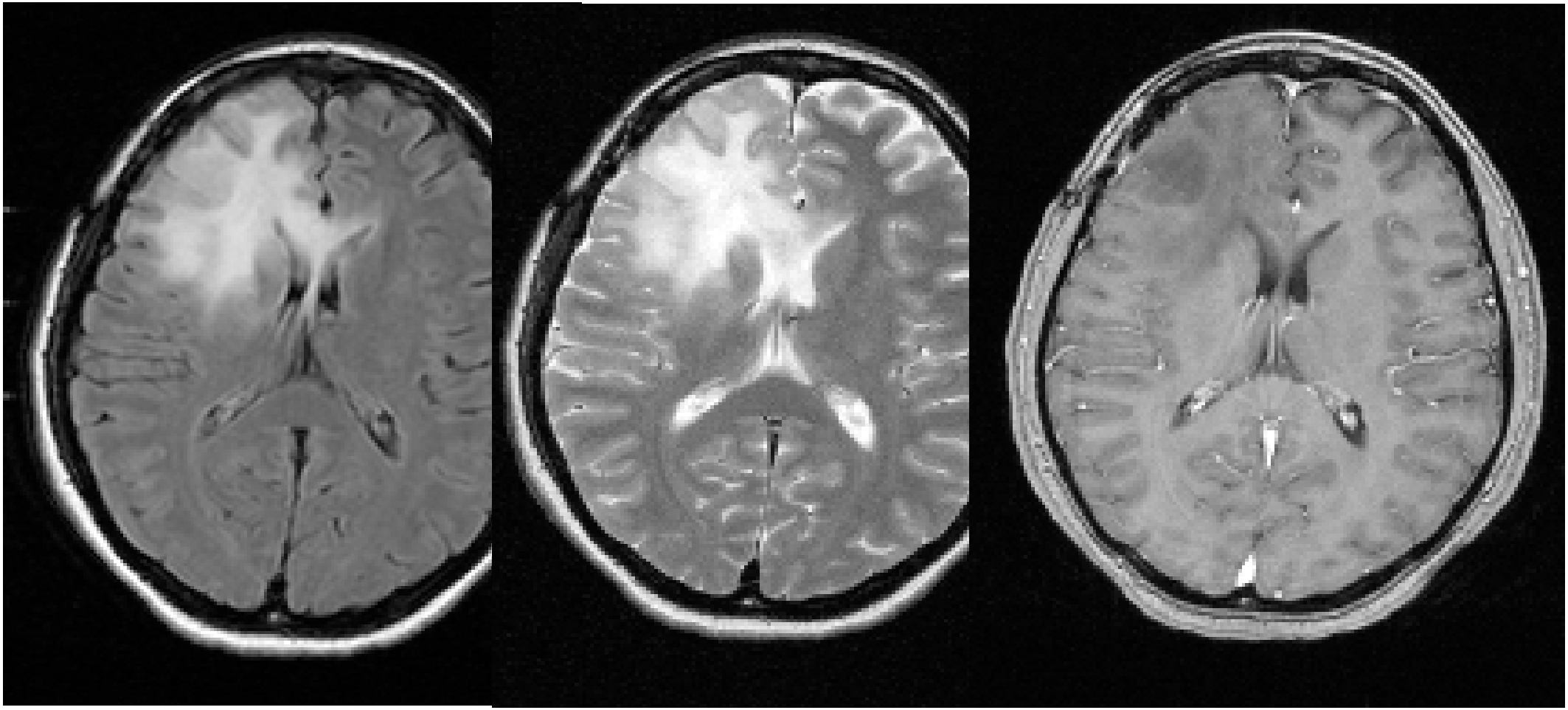

ESTRO School

Oligodendroglioma (WHO II)

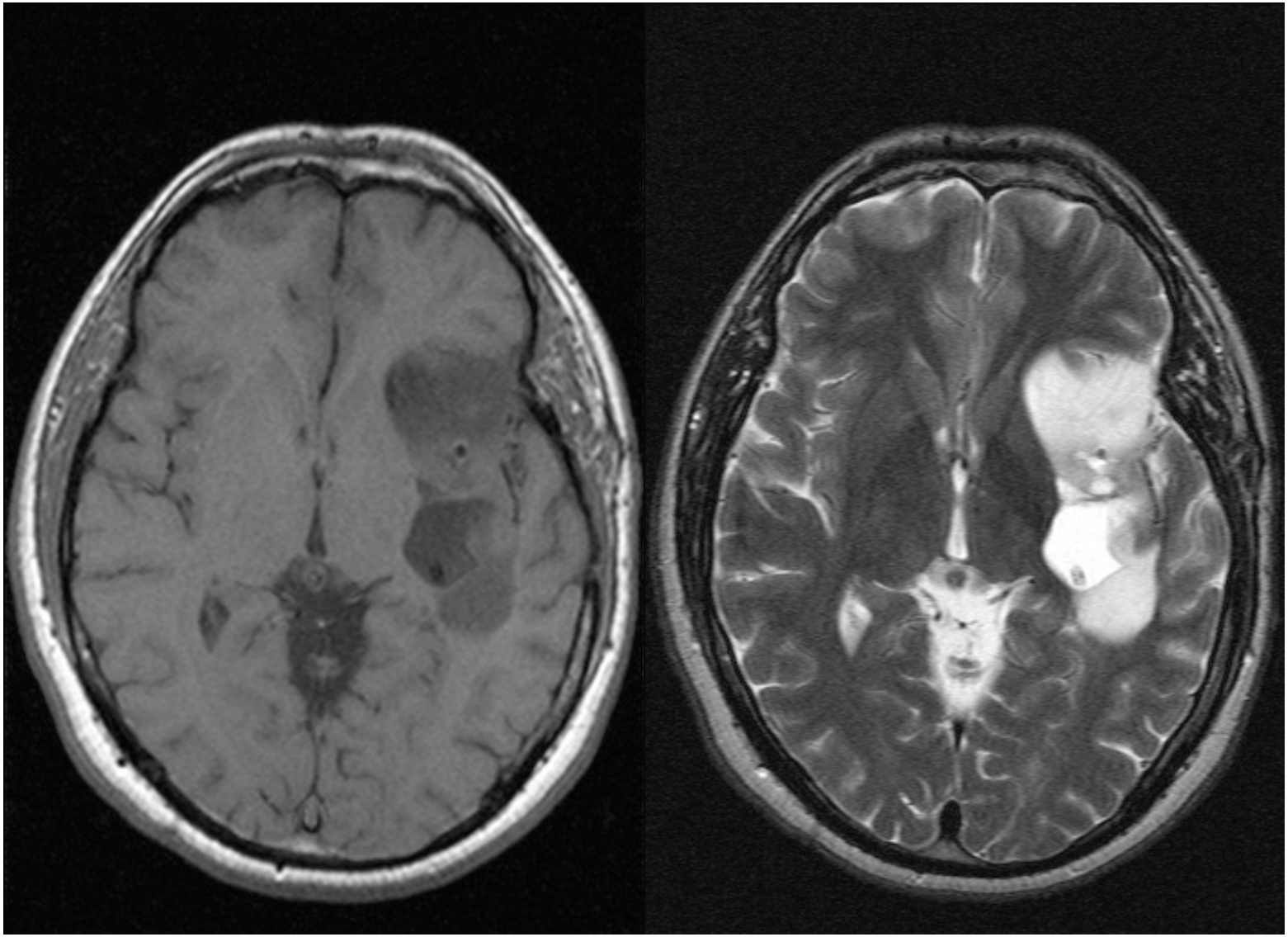

Oligodendroglioma (WHO II)

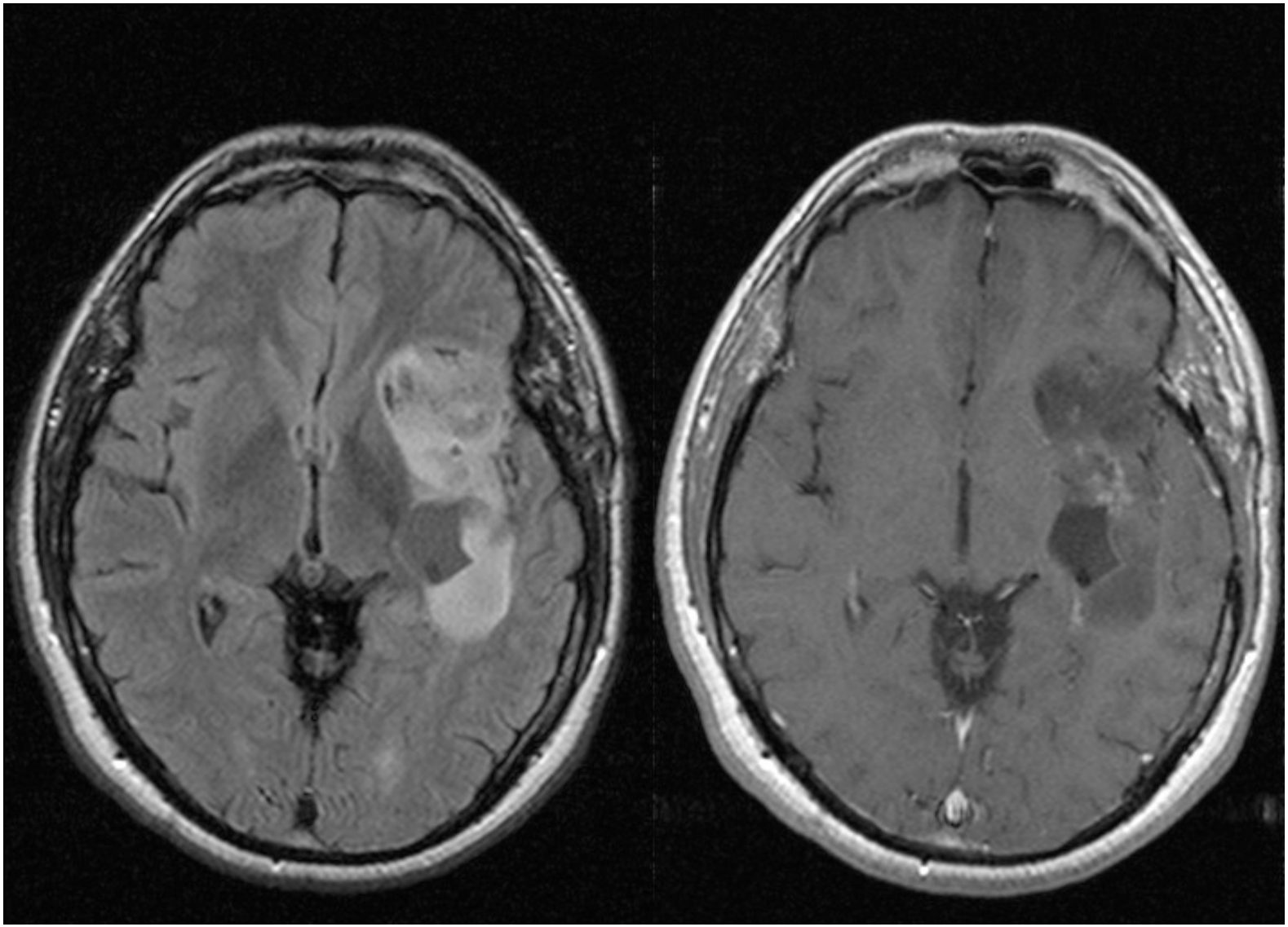

Anaplastic Astrocytoma (WHO III)

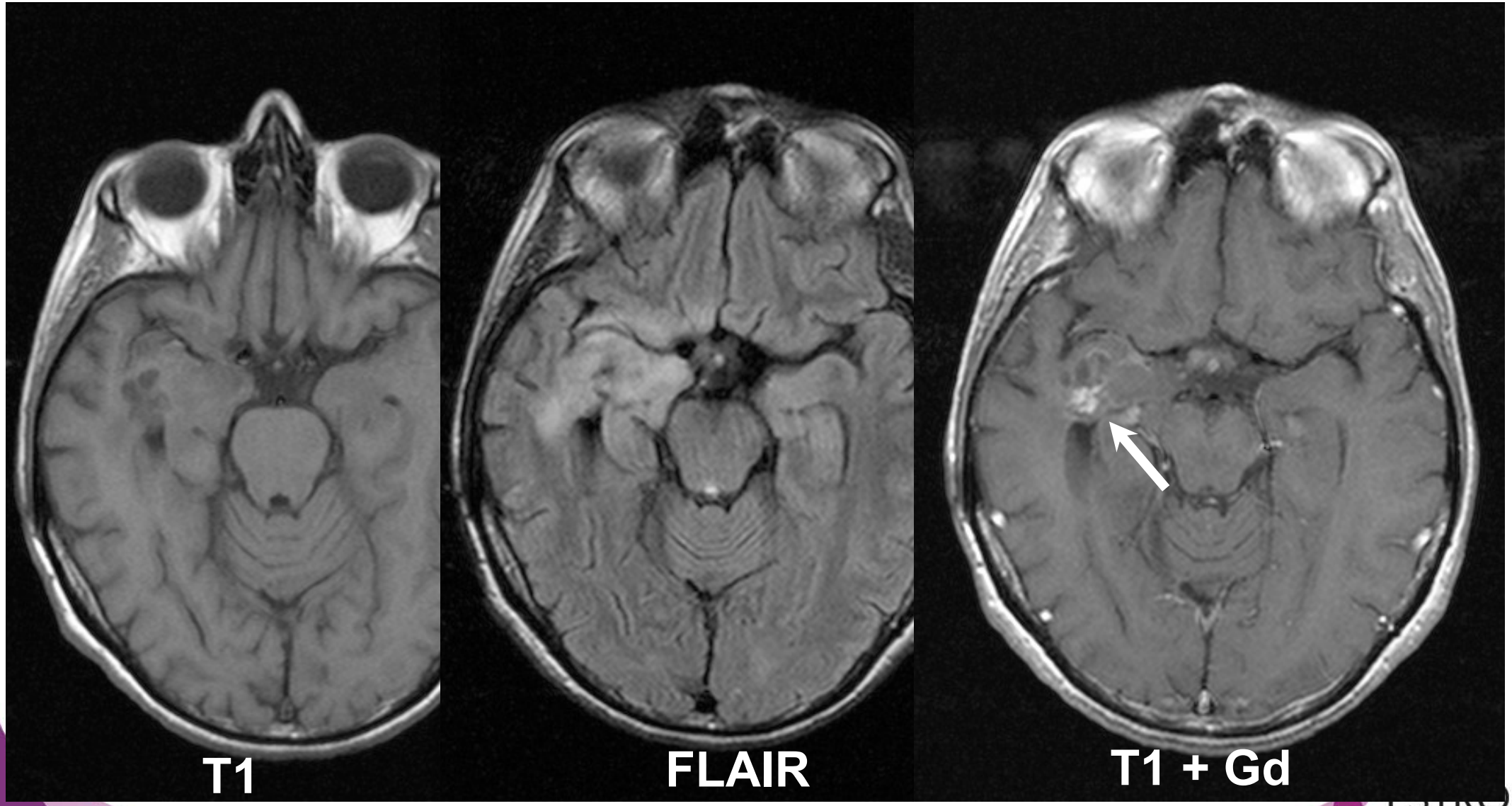

Glioblastoma = Astrocytoma WHO IV

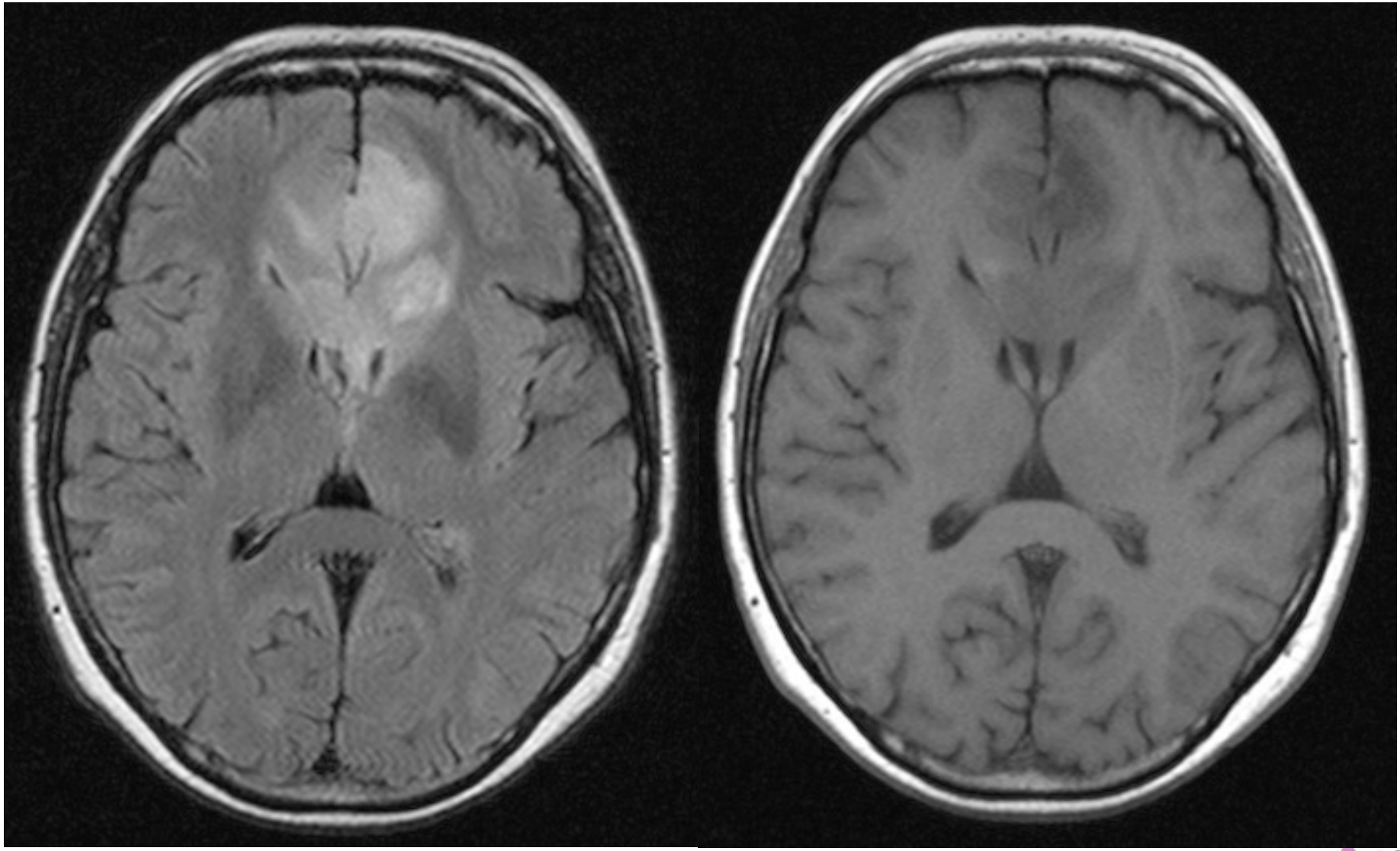

ESTRO School

Glioblastoma

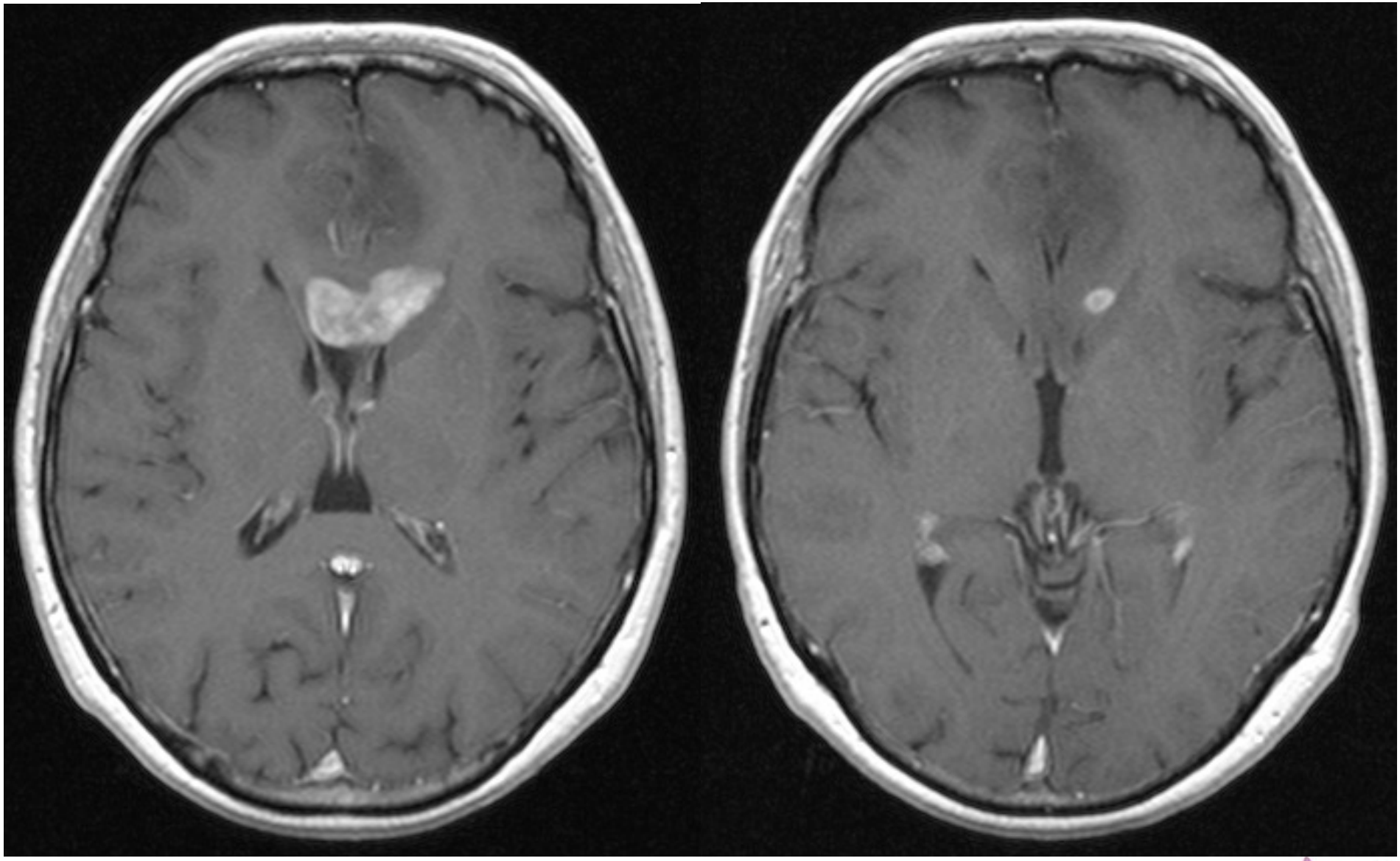

Glioblastoma

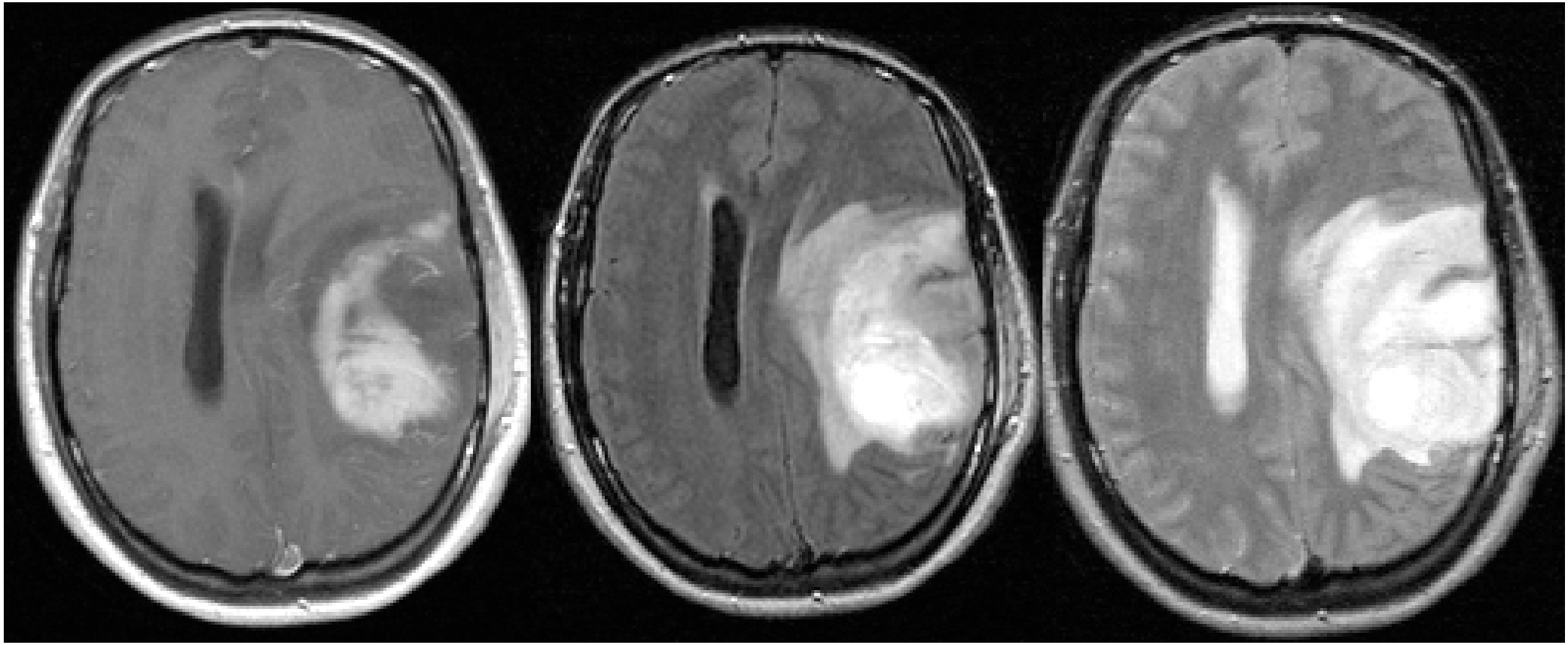

Recurrent glioblastoma

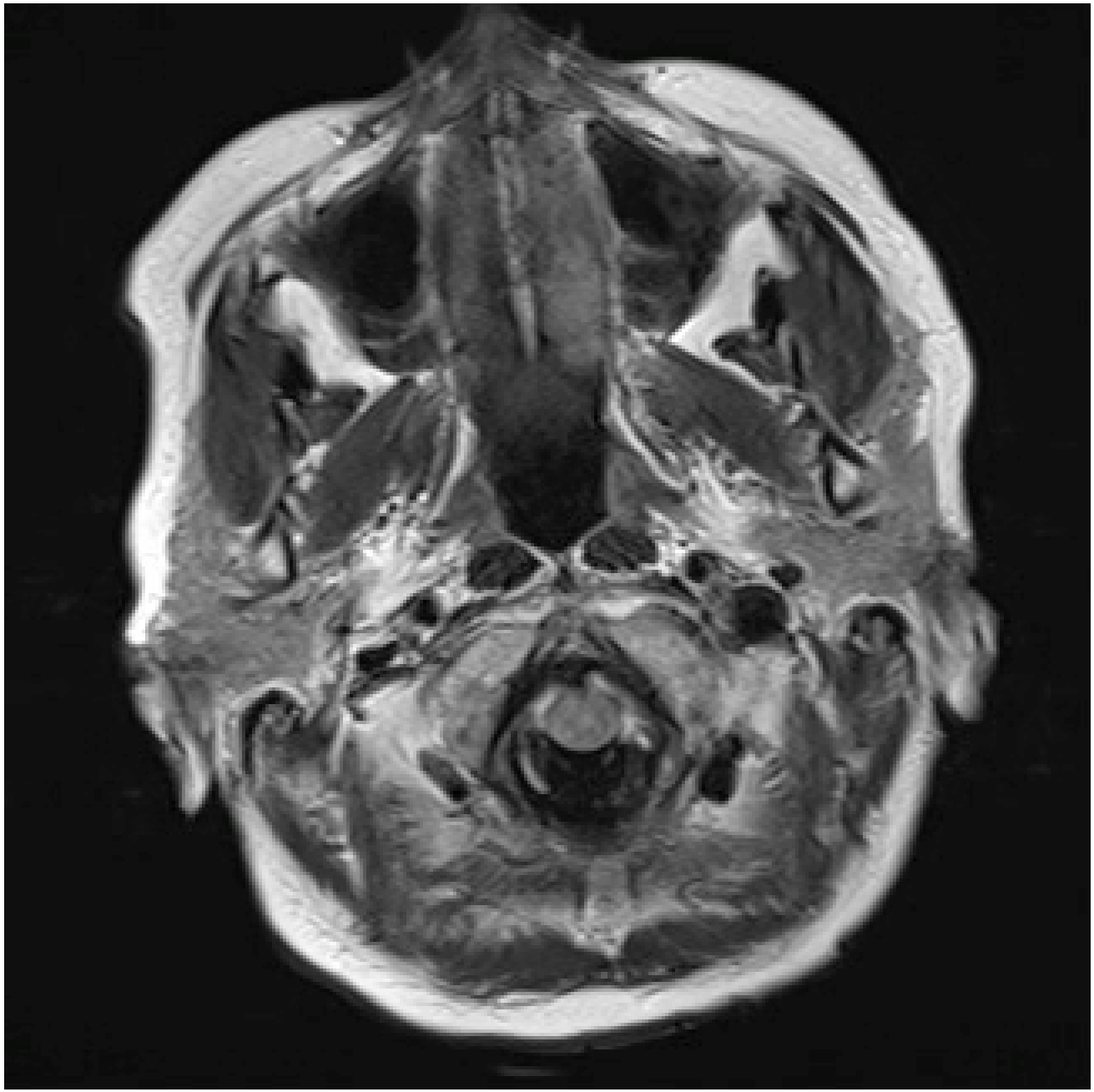

ESTRO School

Recurrent glioblastoma

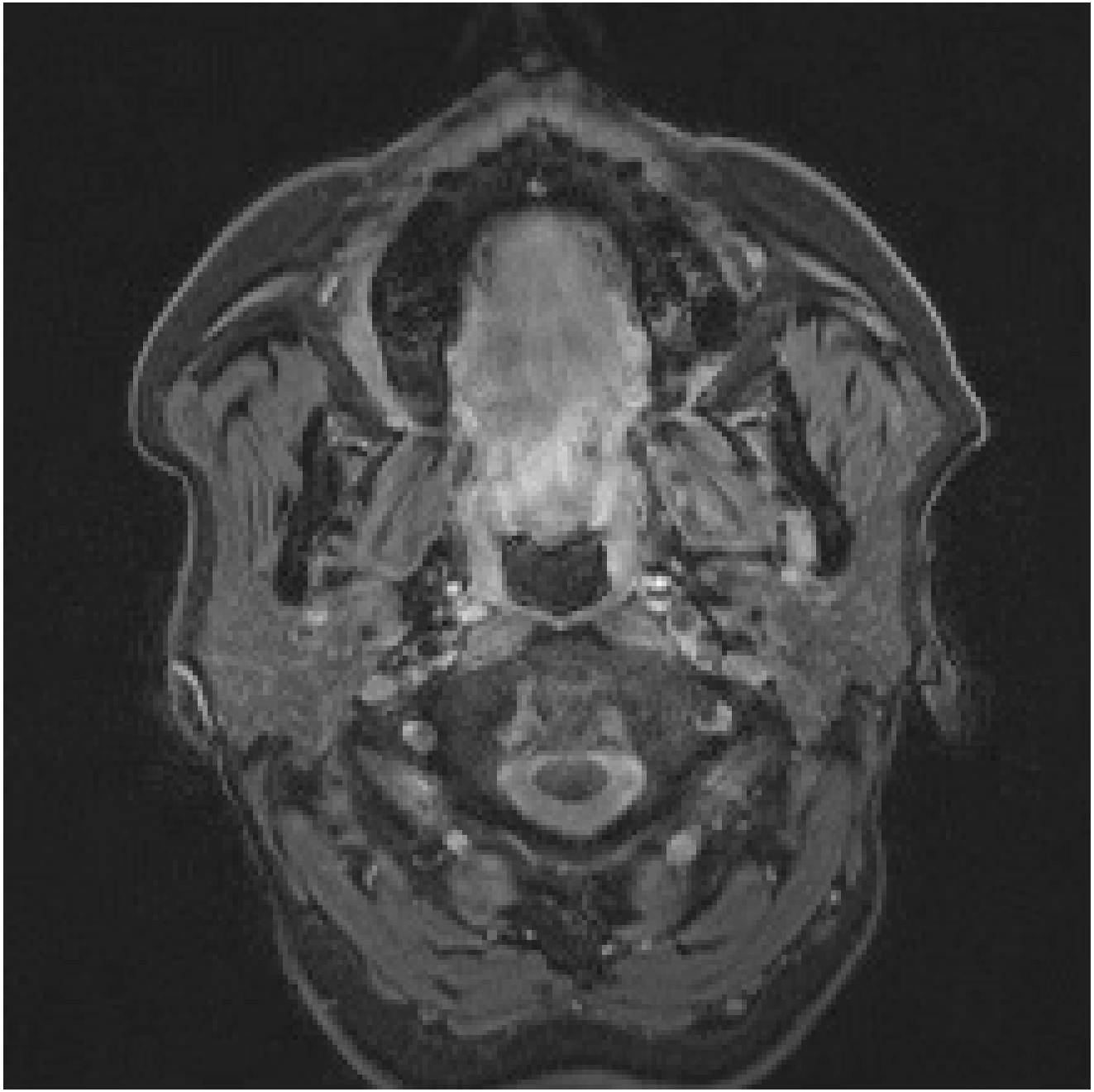

ESTRO School

Recurrent glioblastoma with herniation

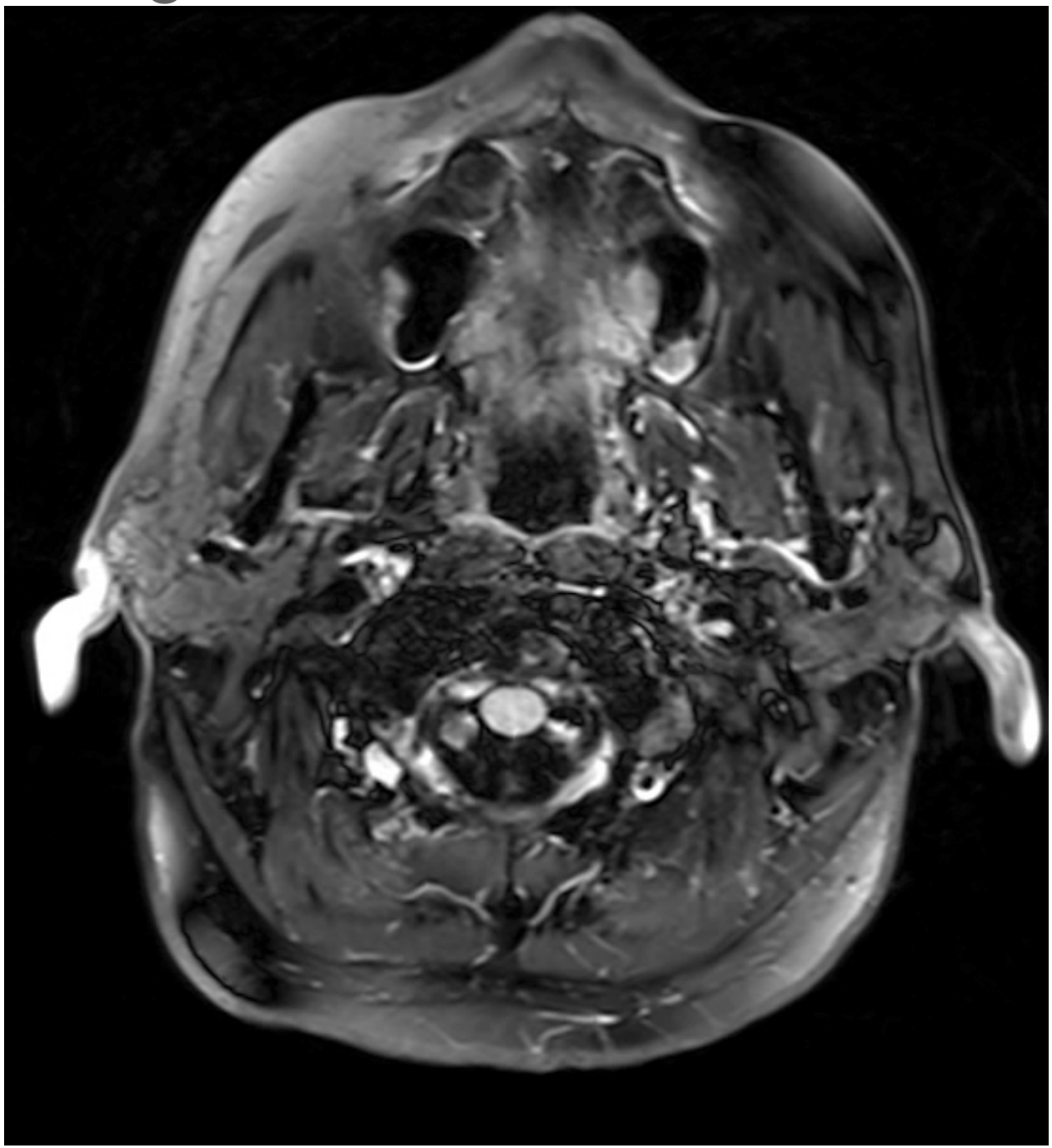

Recurrent glioblastoma with herniation

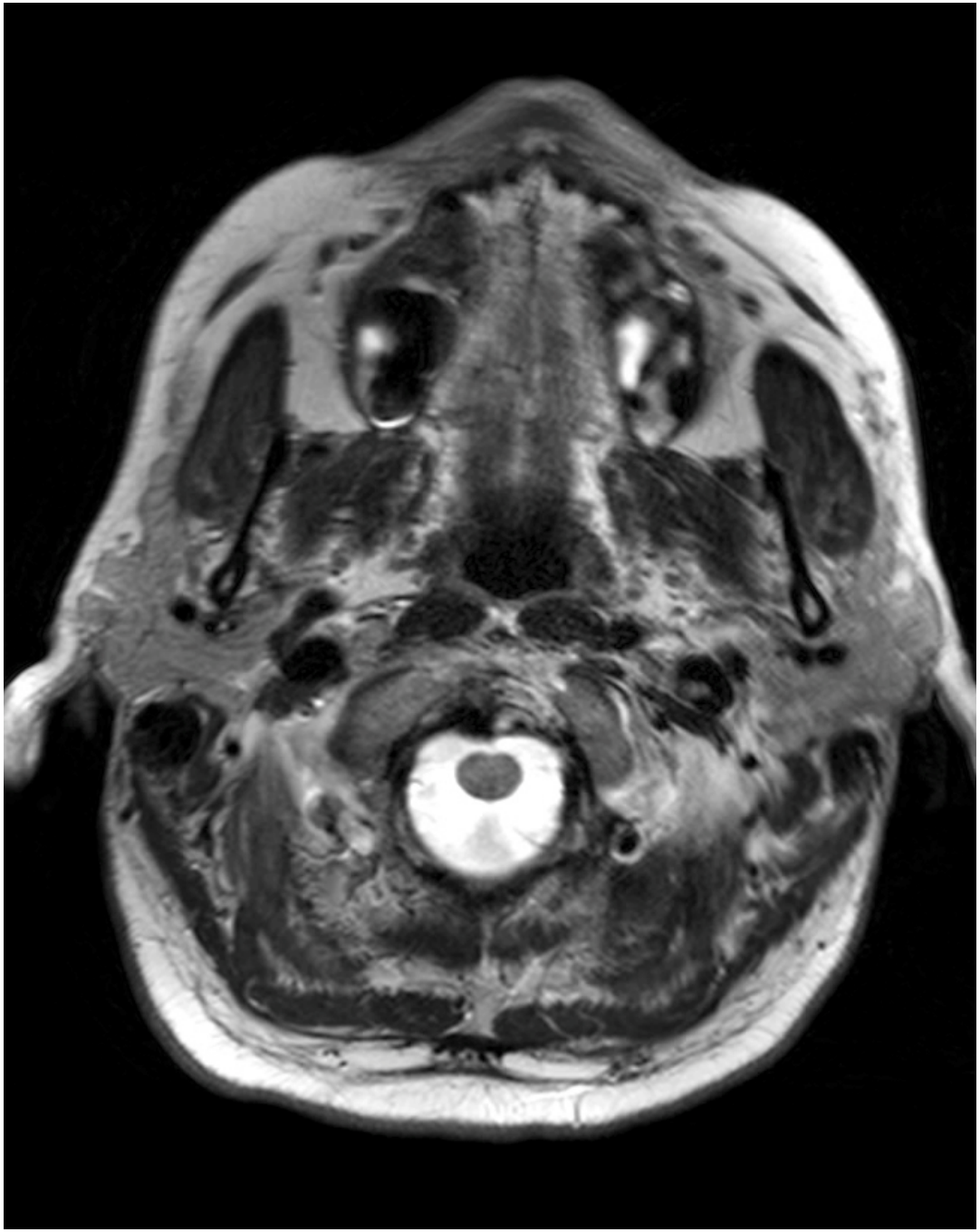

Major problems

- True extent of tumour
  - Oedema or Tumor?
  - Tumour in seemingly normal brain tissue?
- Heterogeneity of tumours
  - Grade III components without BBB disturbance
  - BBB disturbance or neovascular changes?
- Treatment-induced changes
  - T2 hyperintensities
  - BBB disturbance

ESTRO School

True extent of tumour

- Gliomas:
  - Grade II: Everything that is T2 hyperintense is tumour!
  - Grade III and IV:
    - GTV: Contrast-enhancing area
    - T2-hyperintensities: Grade II components plus edema -> CTV
    - Tumour to be expected even in seemingly normal brain
- Metastases:
  - Tumor confined to contrast-enhancing area
  - T2 hyperintensities are oedema!
- Lymphoma:
  - Is a generalised CNS disease

ESTRO School

Some little helpers...

- Dynamic contrast-enhanced T1w imaging
  - Malignant and vital foci
- Dynamic contrast-enhanced susceptibiltity imaging
  - Malignant foci in non-enhancing gliomas
- Spectroscopy
  - Malignant and vital foci
  - DD tumor vs. Oedema
- PET with 18-FDG, 18-FET, or 11-C-Methionine
  - Metabolically active tumour

DYNAMIC CONTRAST-ENHANCED T1W IMAGING

ESTRO School

DCE MRI of Glioma

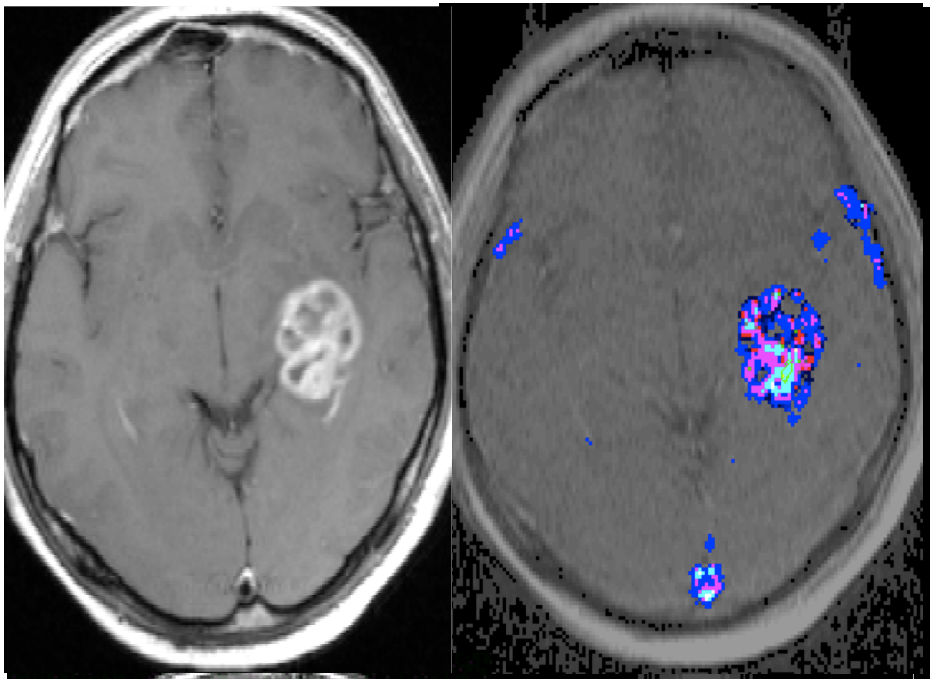

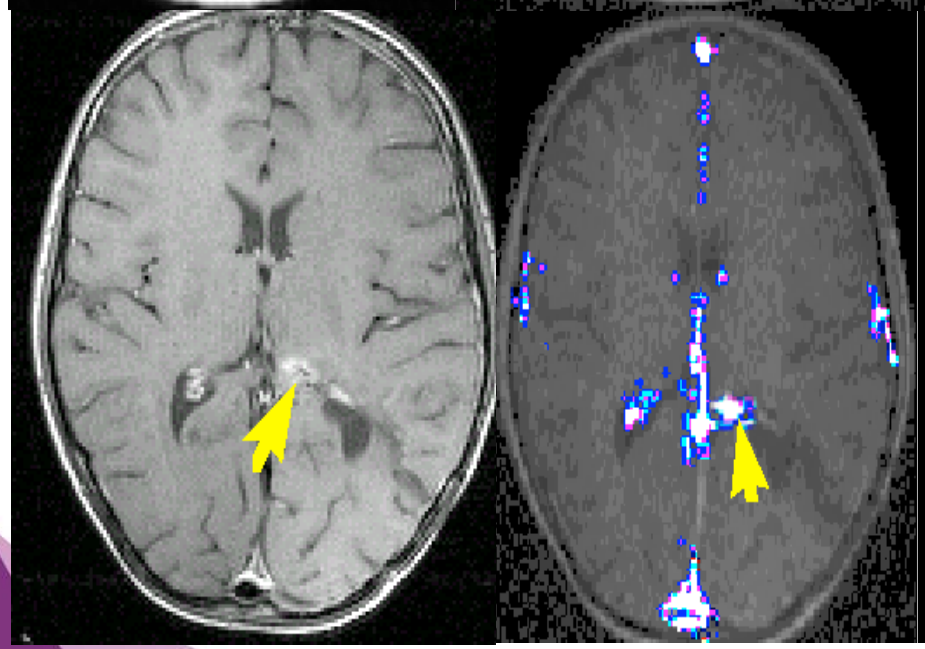

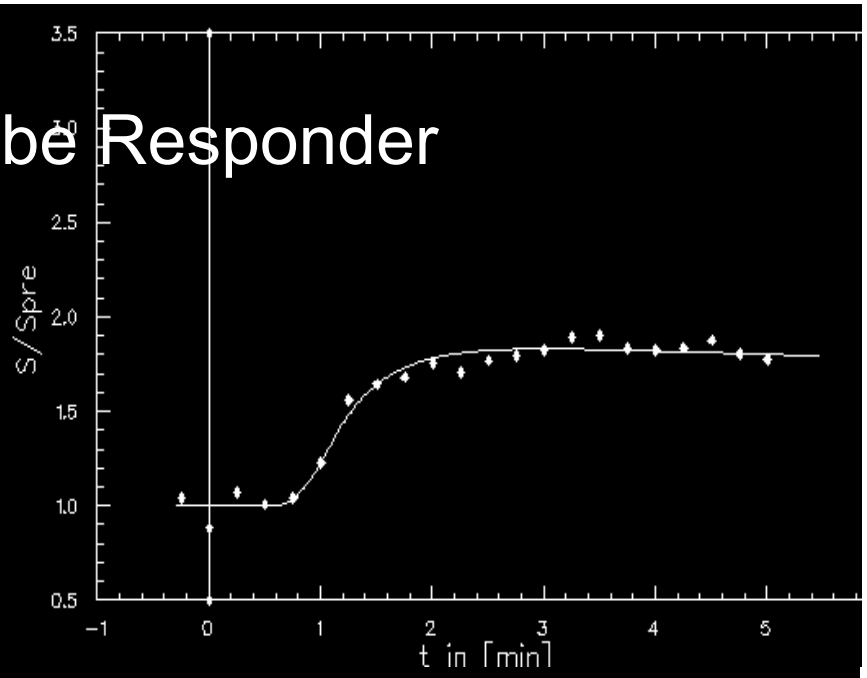

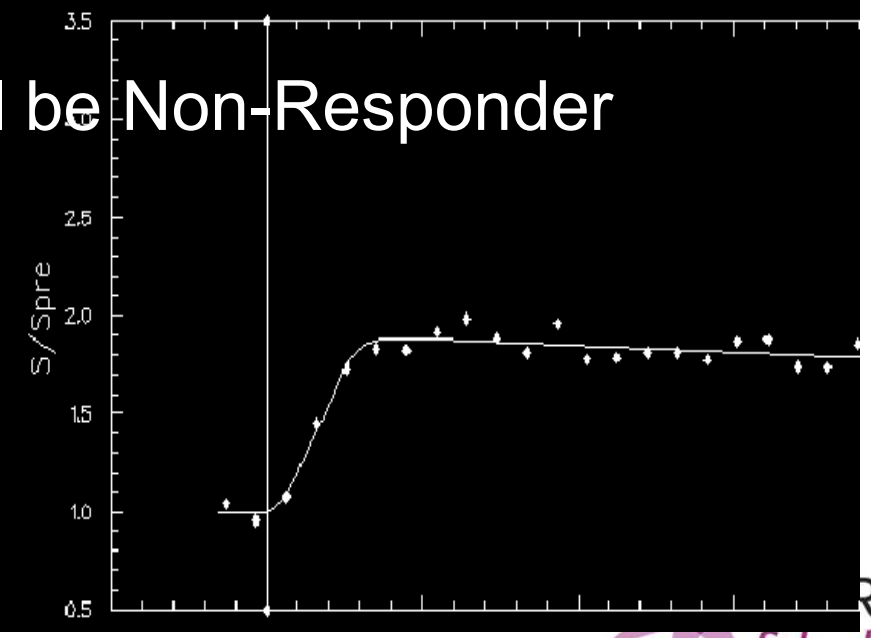

DCE MRI of Glioma

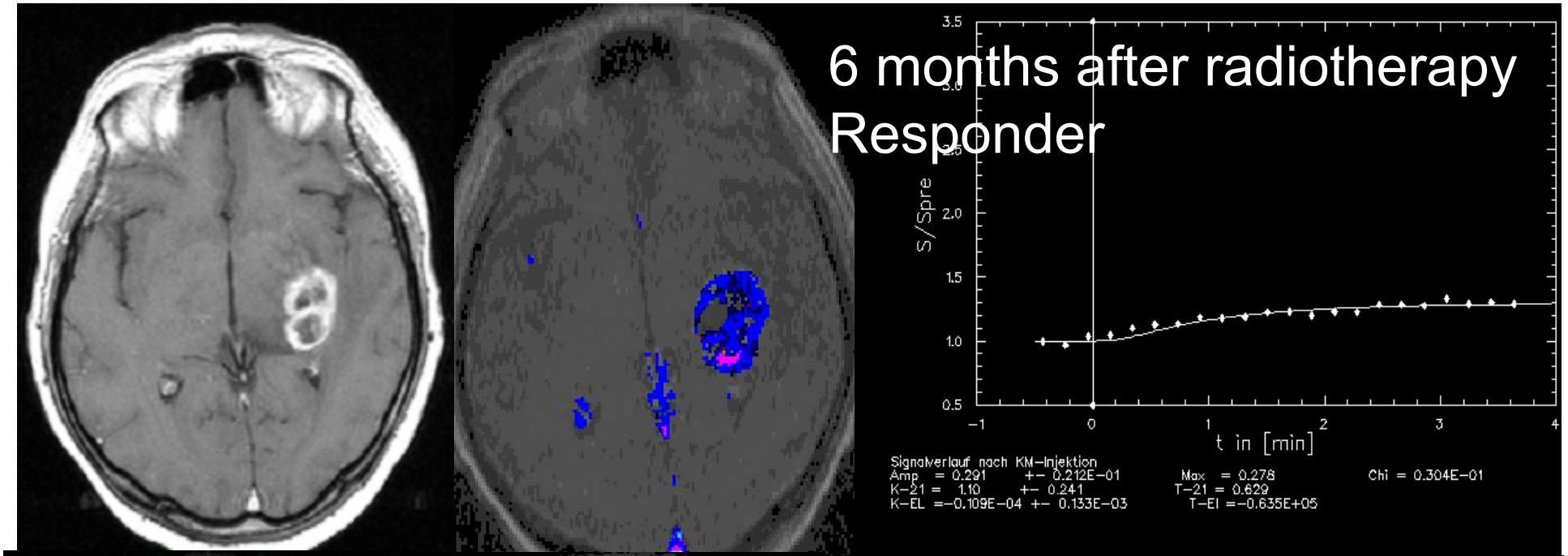

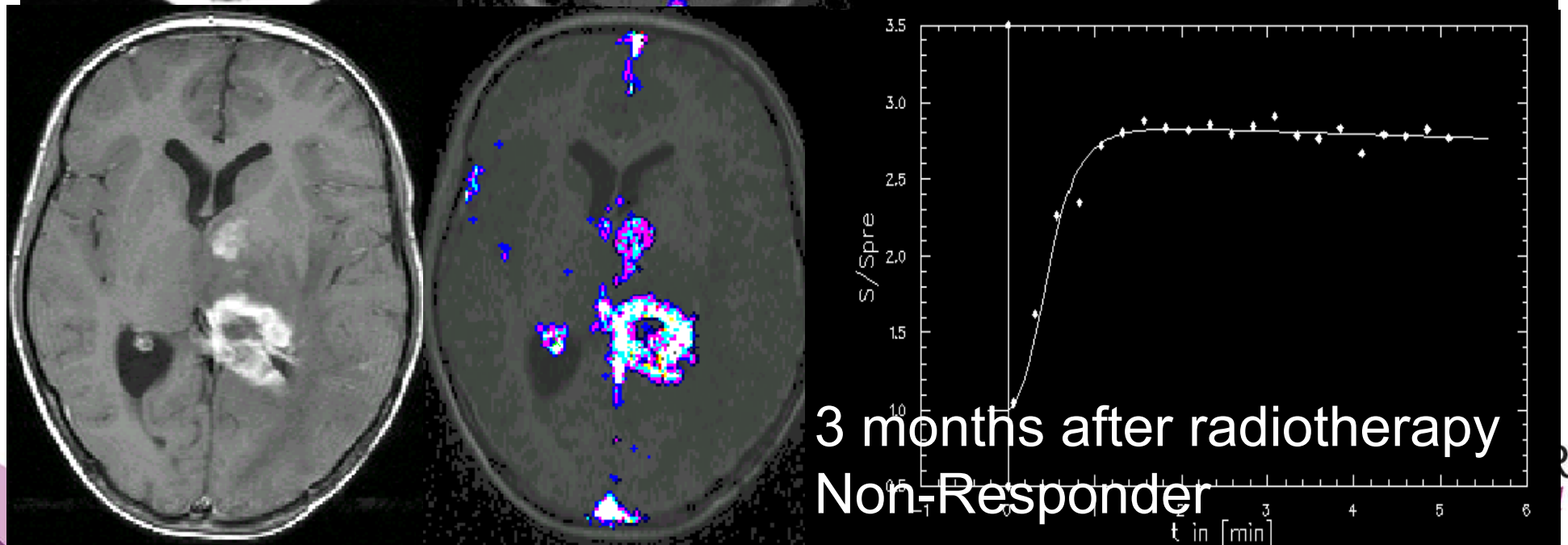

DYNAMIC CONTRAST-ENHANCED SUSCEPTIBILITY IMAGING („PERFUSION MRI“)

Perfusion MRI

- Grade II or Grade III?

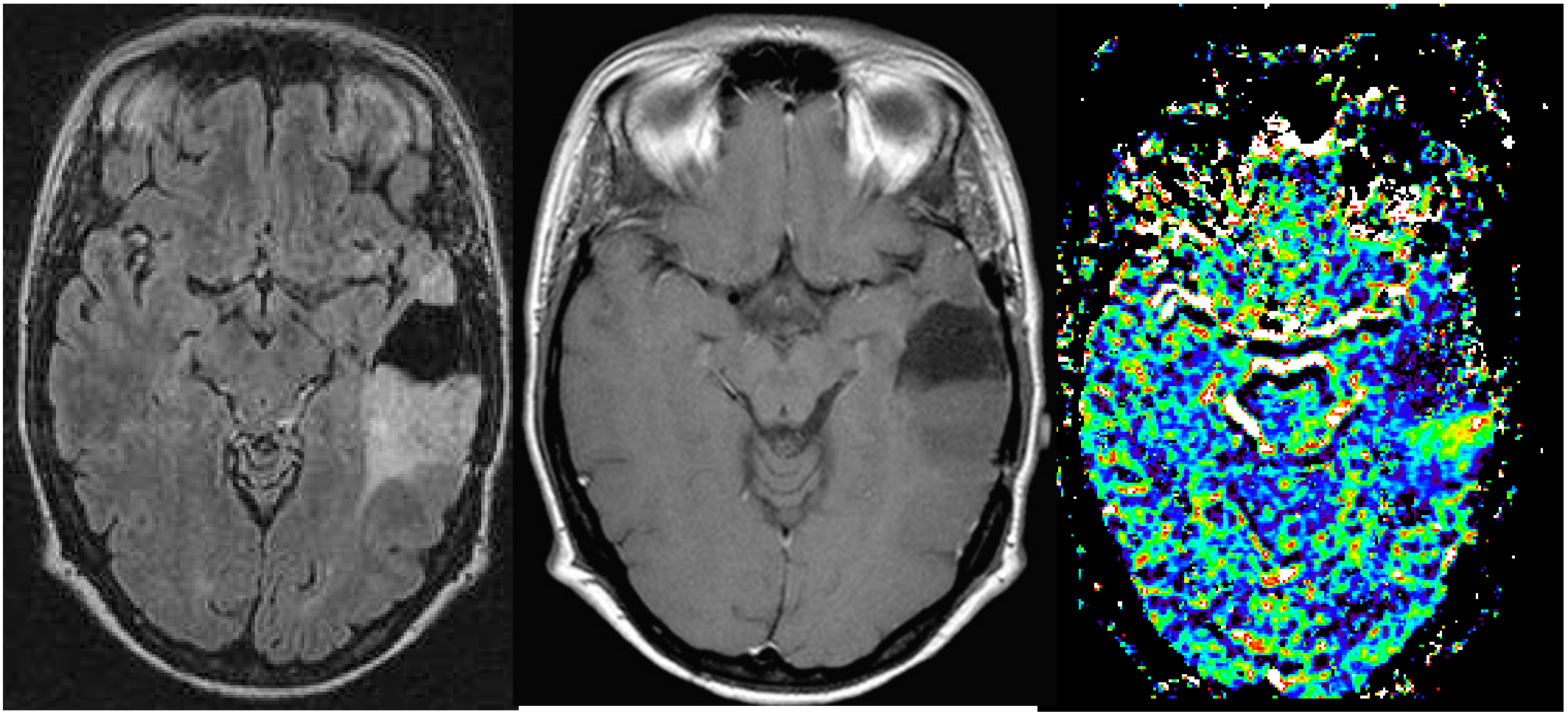

ESTRO School

MRI Perfusion of Grade II Glioma

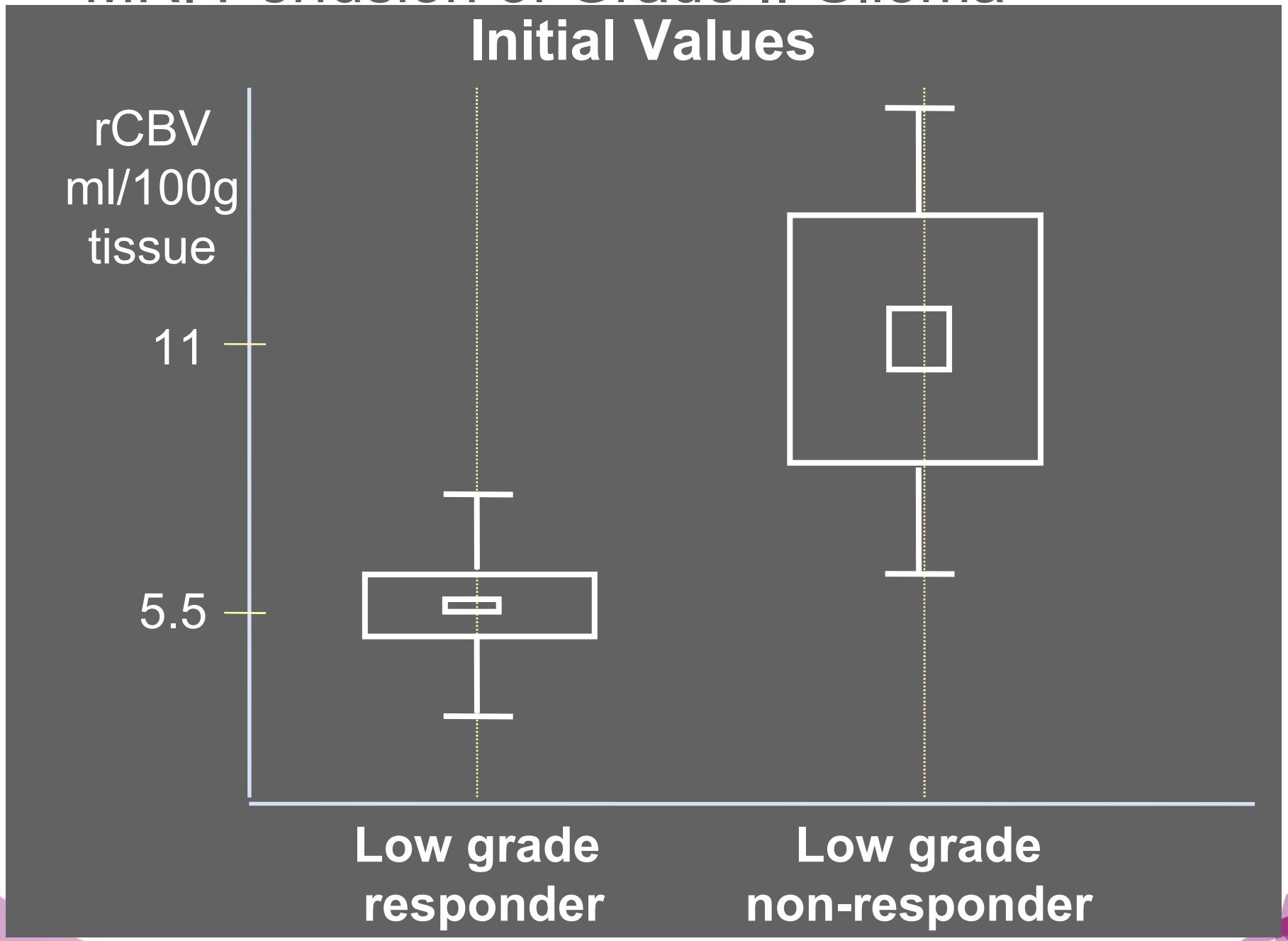

ESTRO School

SPECTROSCOPY

ESTRO School

Spectroscopic imaging

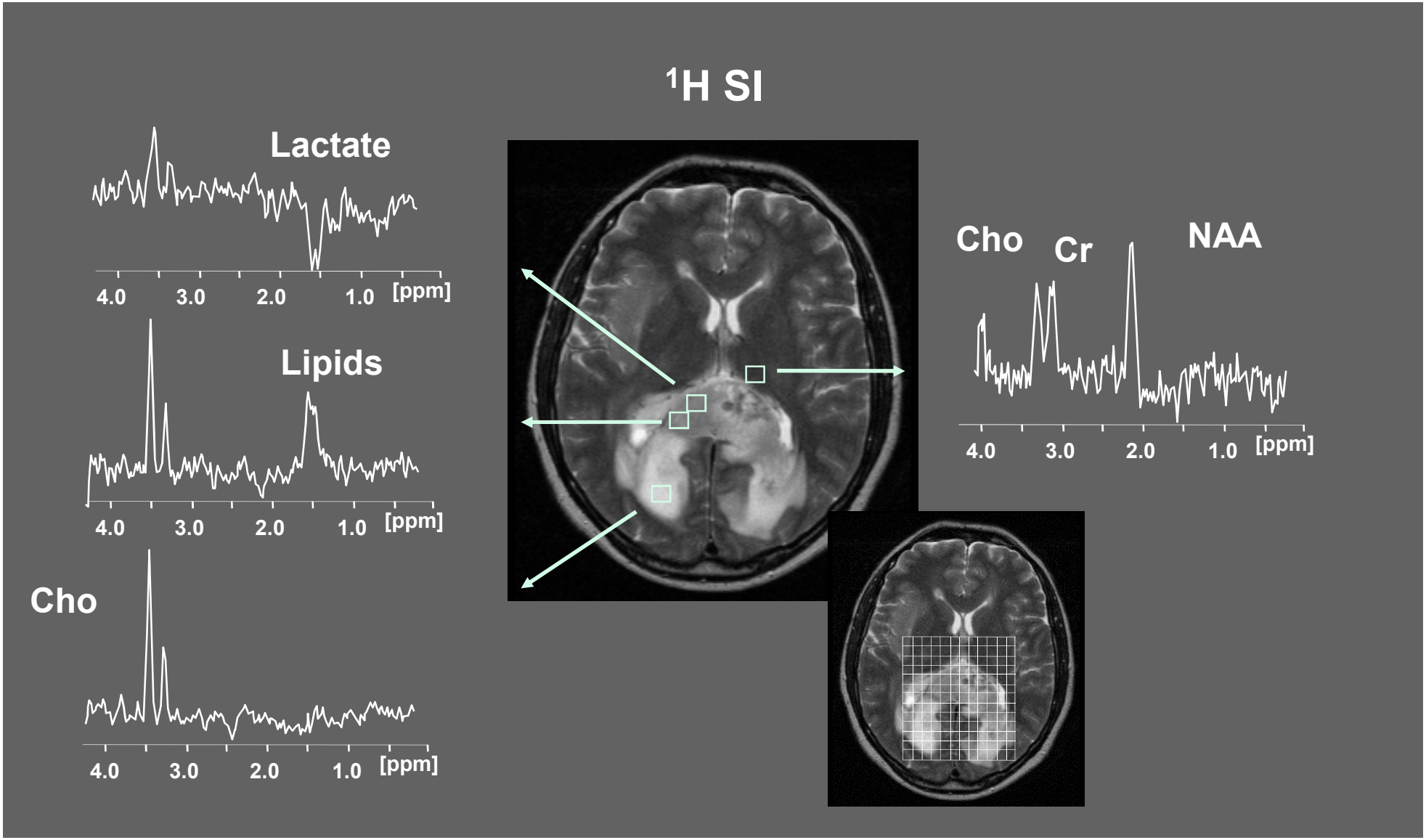

MR Spectroscopy

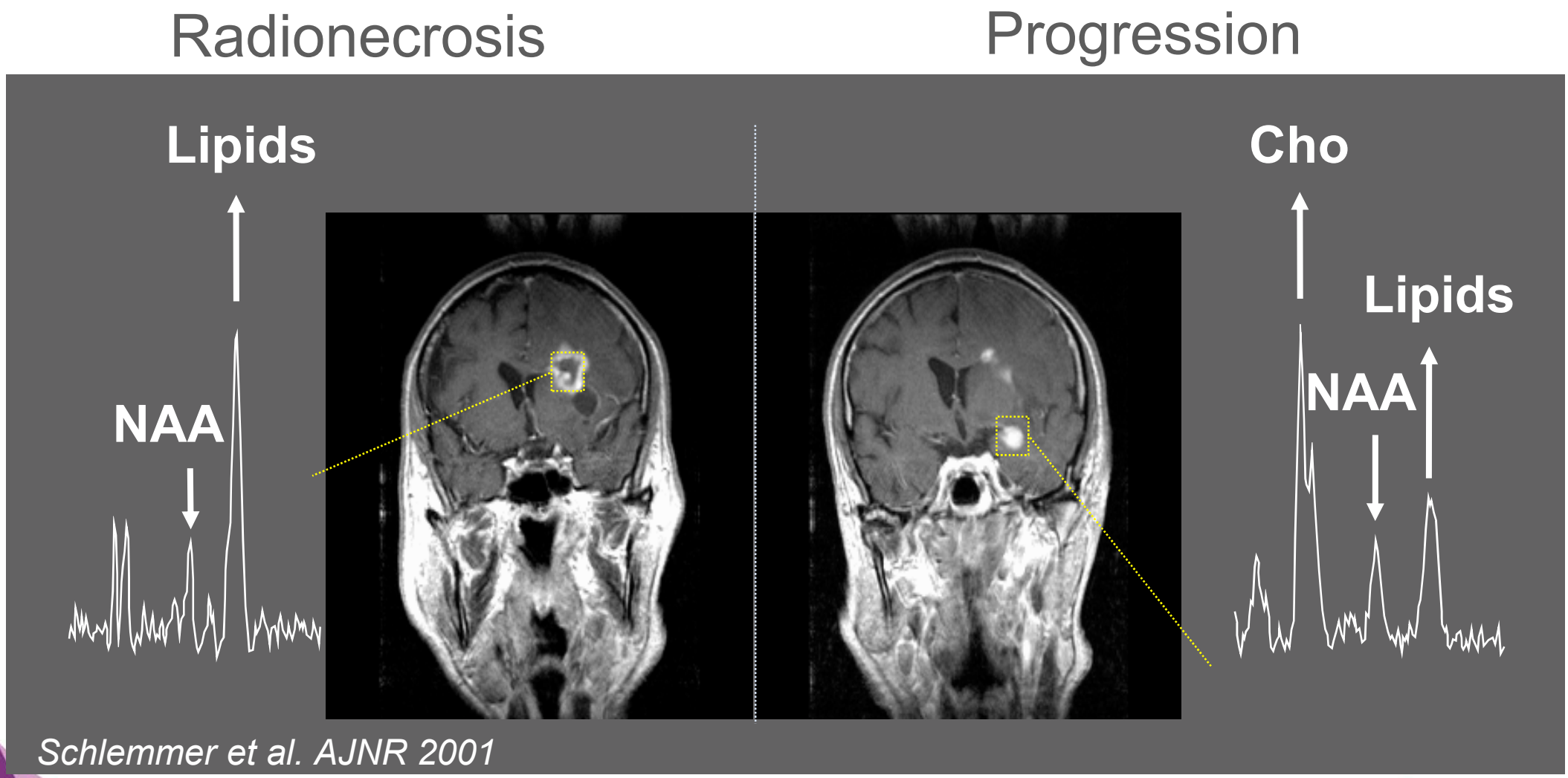

ESTRO School

Pseudoresponse

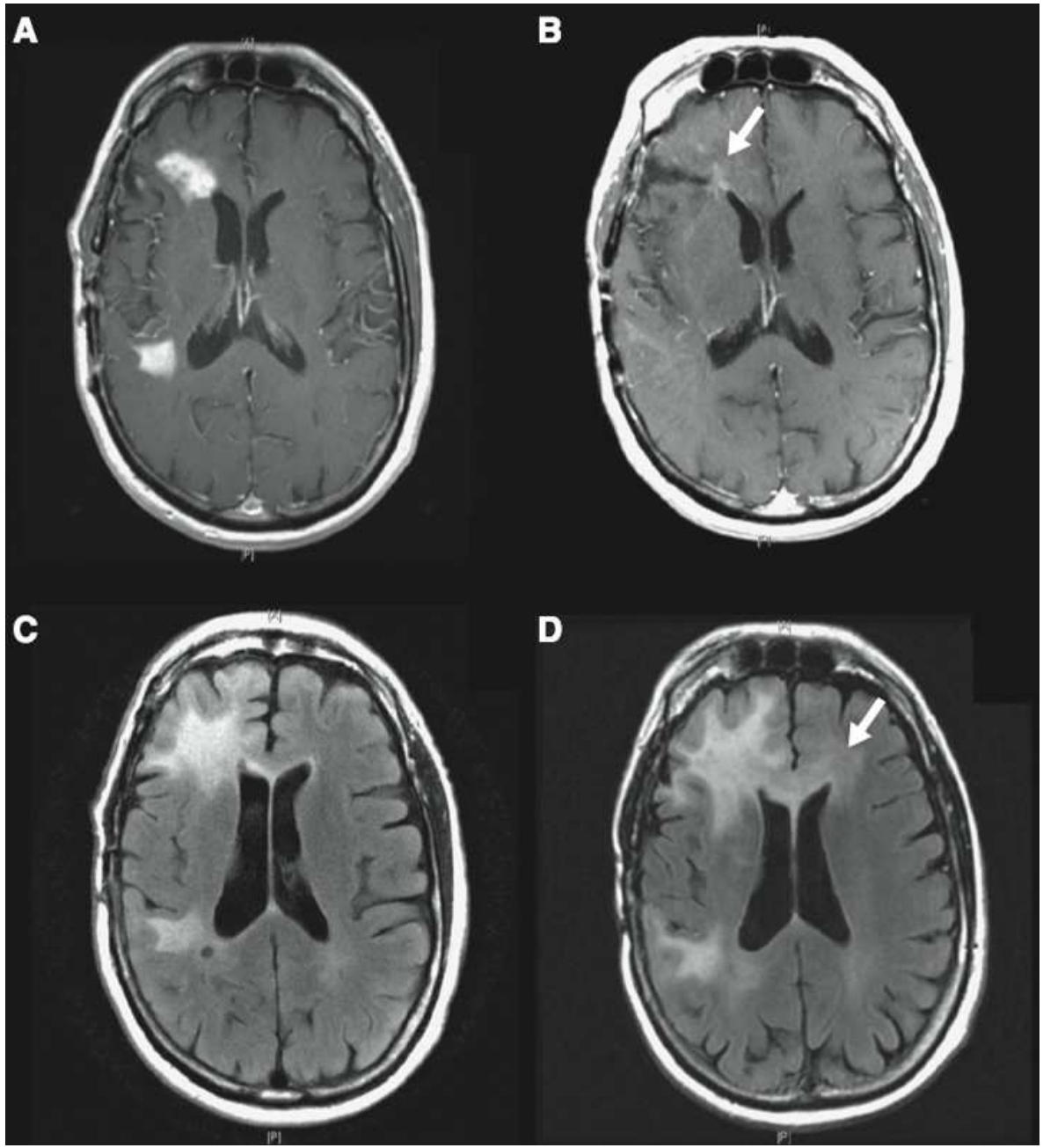

ESTRO School

RANO* Response criteria in CNS tumors

Criterion	CR	PR	SD	PD
T1 Gd-enhancing disease	None	≥50% decrease	<50% decrease but <25% increase	≥25% incrase
T2/FLAIR lesion	Stable or decreased	Stable or decreased	Stable or decreased	Increased
New lesion	None	None	None	Present
Corticosteroids needed	None	Stable or less	Stable or less	N/A or more
Clinical status	Stable or improved	Stable or improved	Stable or improved	Deteriorated
Requirement for response	All	All	All	Any

** RANO = Response assessment in neuro-oncology*

ESTRO School

PET/CT and PET/MRI

- Grading: Characterization by different tracers
  - 11C-methionine (MET),
  - 18F-fluoroethyl-L-tyrosine (FET)
- FDG often unreliable due to high uptake of normal brain

ESTRO School

Why amino acids and not ^{18}FDG?

Recurrent astrocytoma

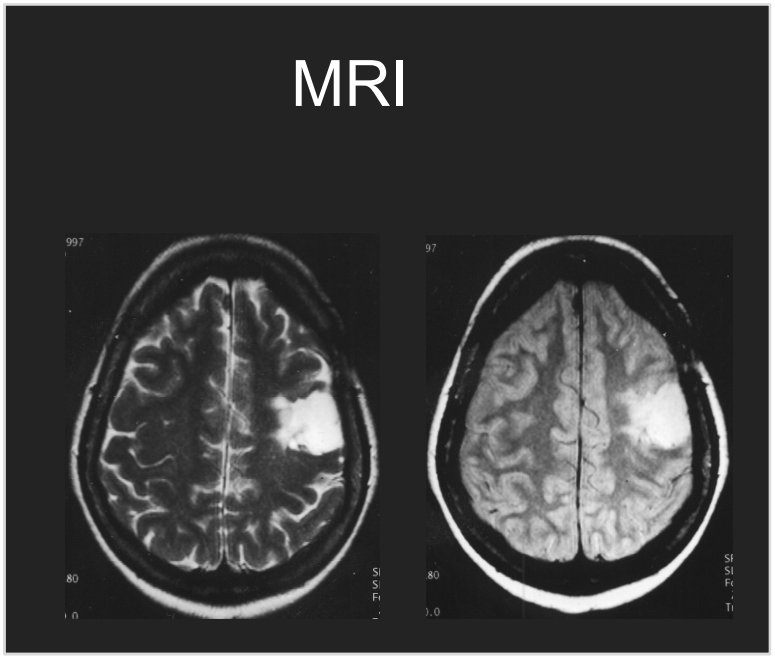

Courtesy by B. Beuthien-Baumann, Heidelberg

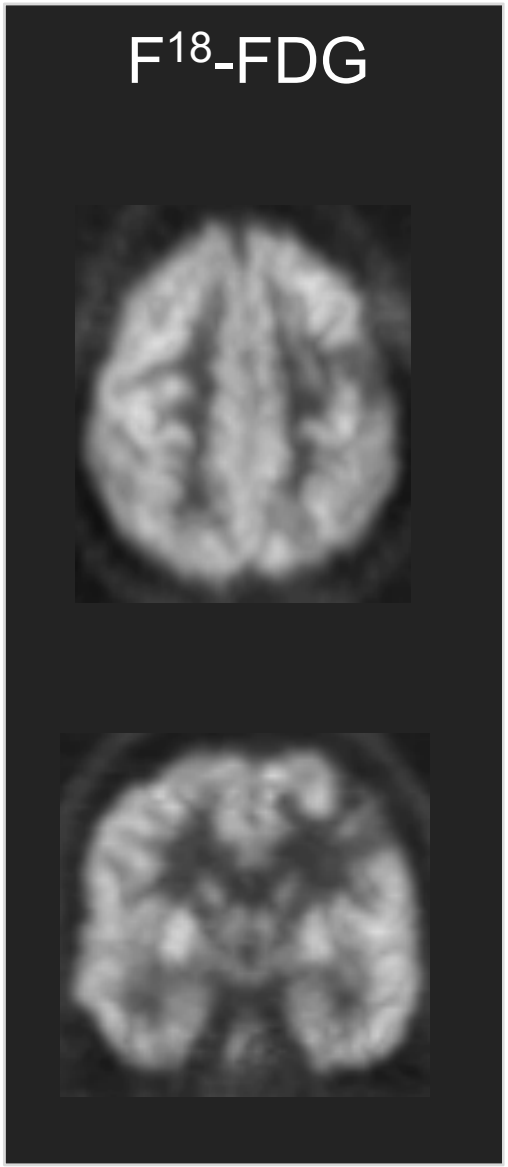

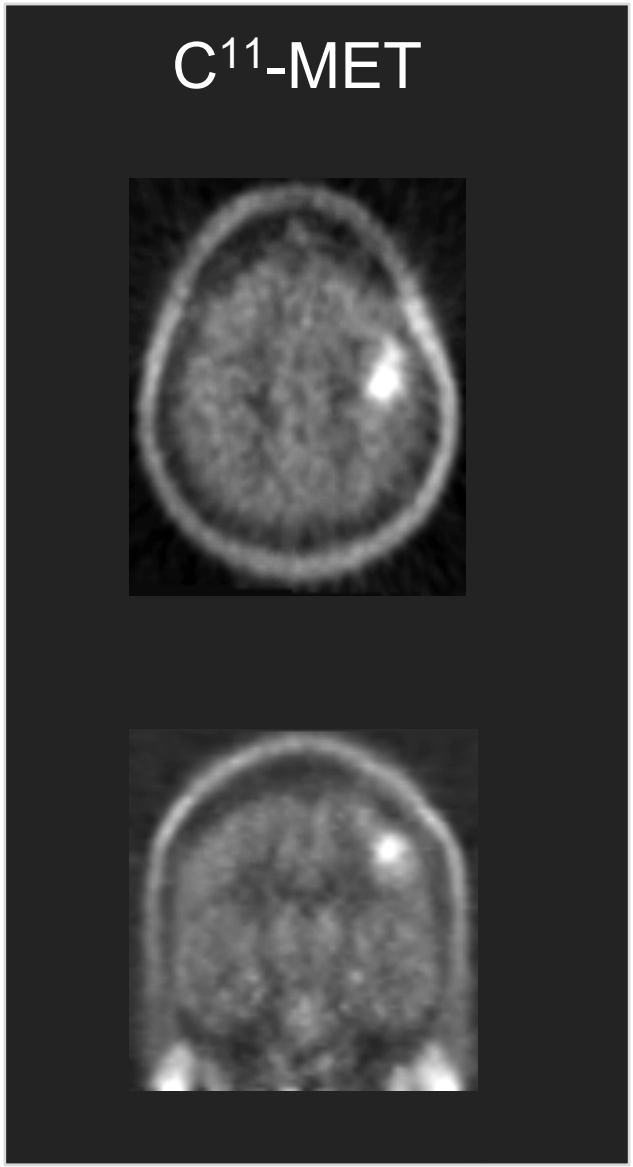

ESTRO School

C-11 Methionin PET: Residual Tumour

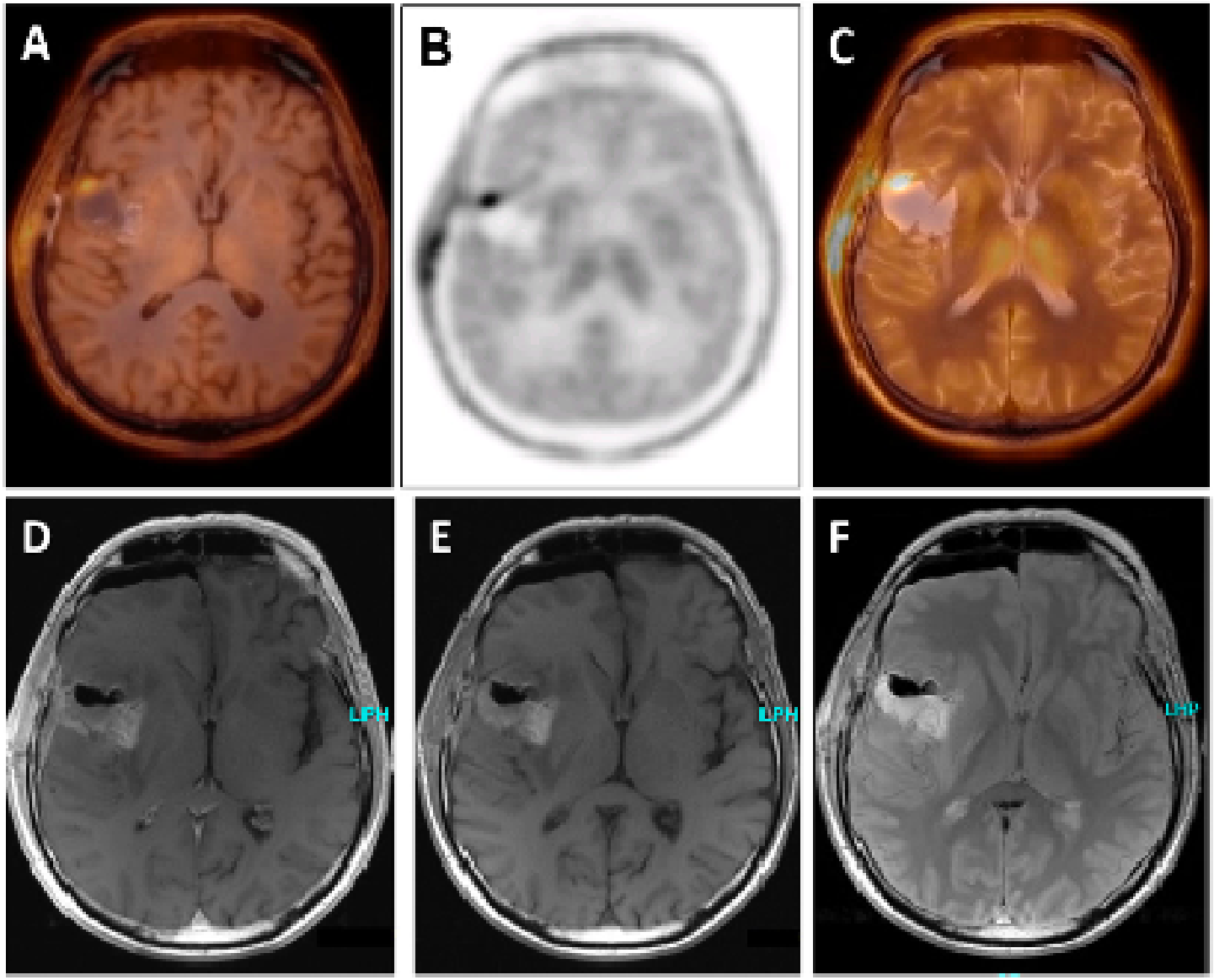

C. von Neubeck, A. Seidlitz, H. Kitzler, B. Beuthien-Baumann, M. Krause. Br J Radiol 2015, 88: 20150354

ESTRO School

Take home

- CT for dose calculation
- MRI for determination of GTV and grading
- Software-based CT/MRI fusion for planning
- PET under investigation for delineation
- Evaluation of additional contributions by functional/metabolic MRI and PET (different tracers) ongoing

ESTRO School

WWW.ESTRO.ORG/SCHOOL

CTV for Gliomas

Sarah Jefferies

University of Cambridge Department of Oncology,

Oncology Centre, Addenbrooke's Hospital, Cambridge, UK

ESTRO School

CNS Tumours

Introduction

High Grade Glioma (HGG)

GTV and CTV

Low grade Glioma (LGG)

GTV and CTV

Normal tissue tolerance

High Grade Glioma (HGG)

HGG:

Grade III = anaplastic astrocytoma

Grade IV = glioblastoma

Management principles somewhat different

(molecular pathology now being included in grading and management decisions)

CTV margins are typically the same

HGG

HGGs are intrinsic tumours

They infiltrate widely at a microscopic level

There are very few barriers to spread

CNS tumour spread is the cause of all our problems with HGG



Tumour Spread

Tumours can spread along white matter tracts

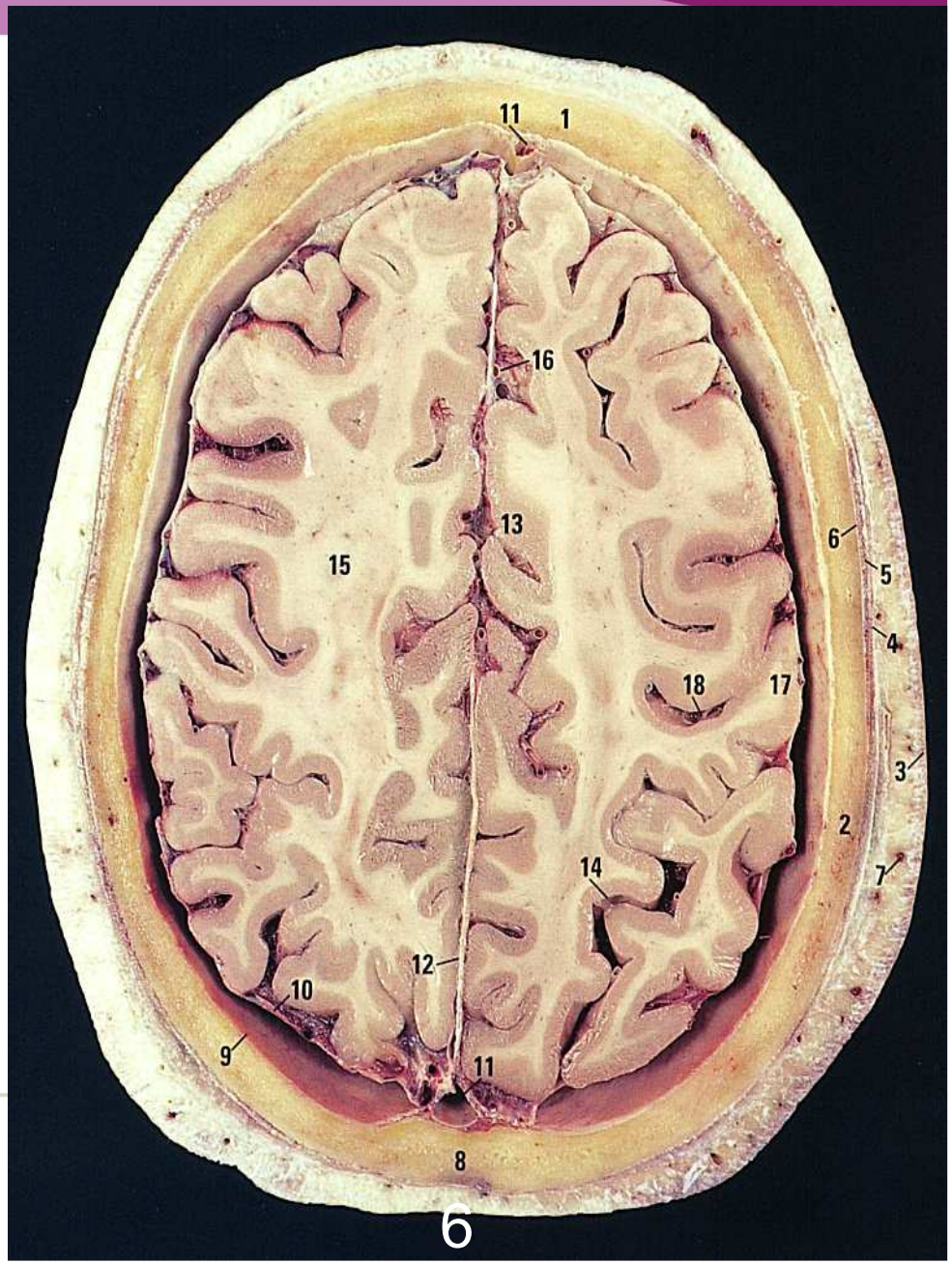

Tumour Spread

Gliomas “surf” along white matter tracts

ESTRO School

Tumour Spread

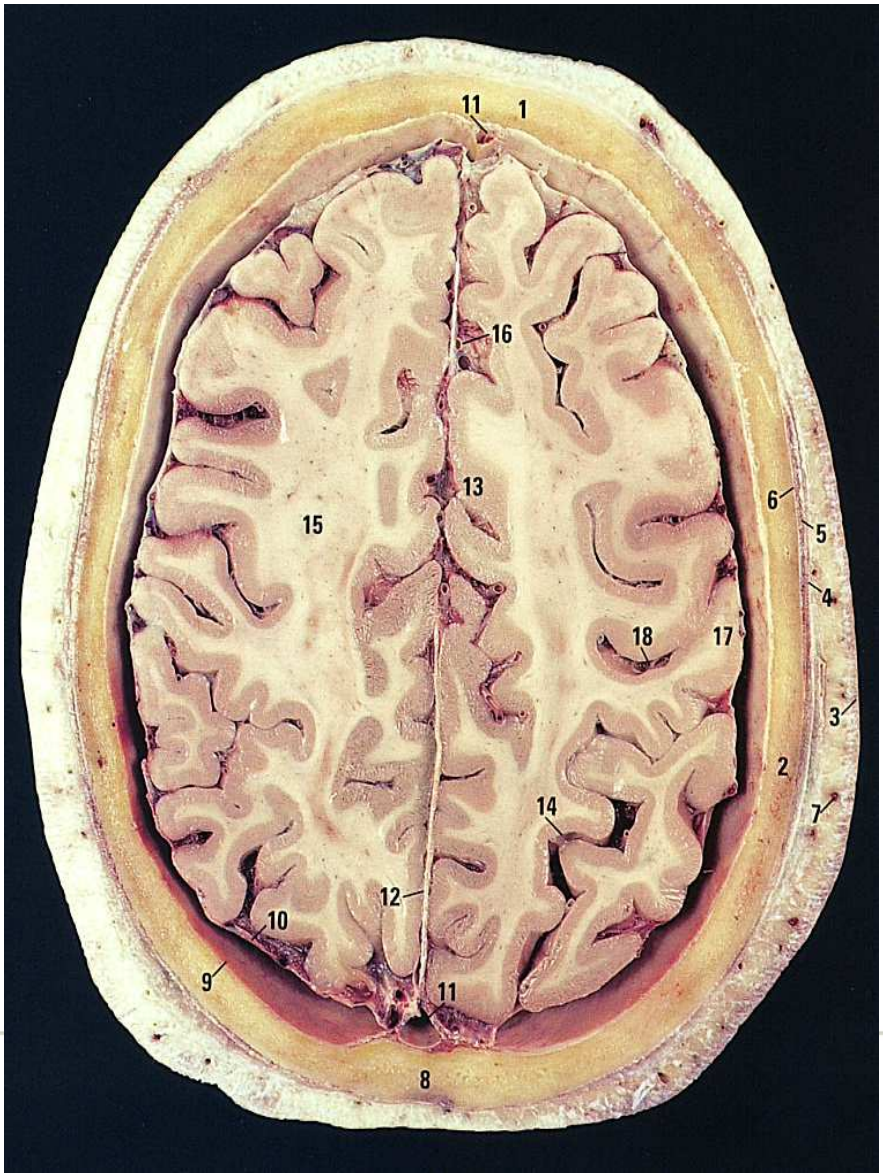

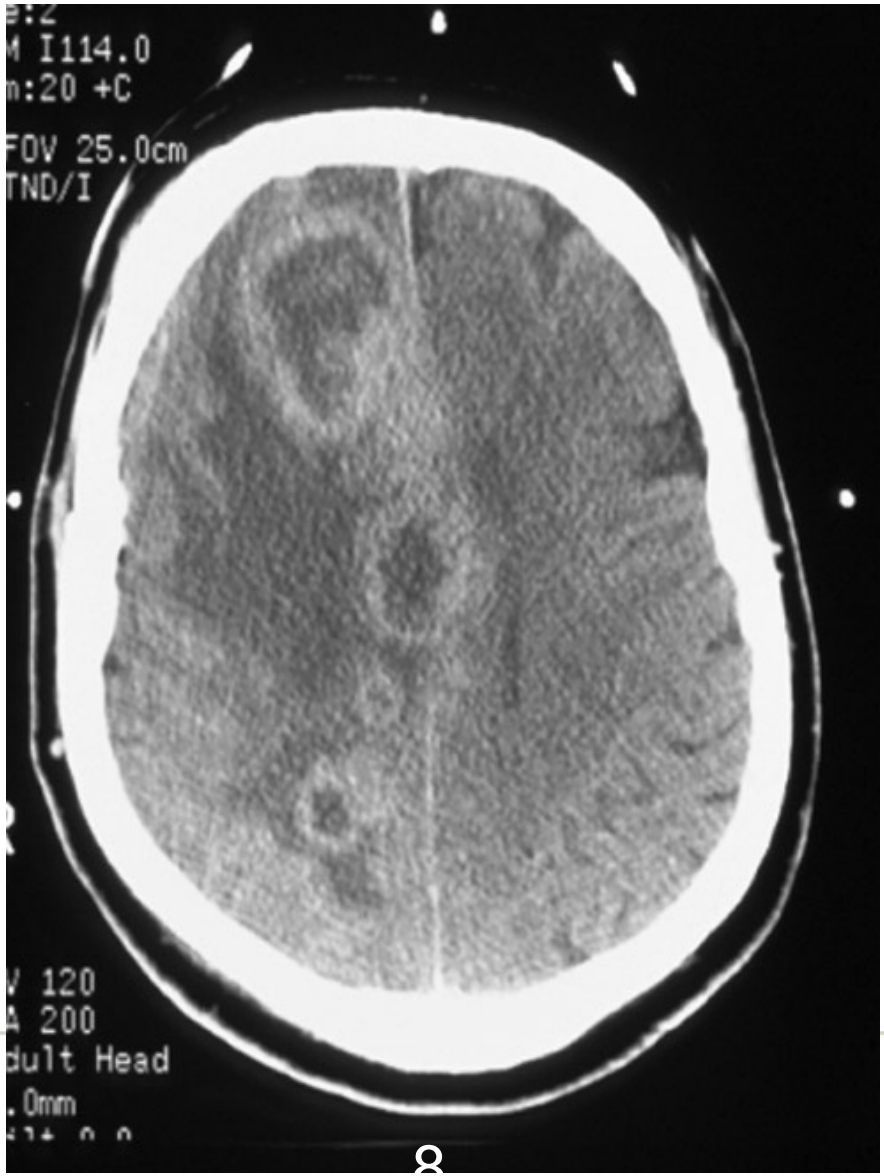

Tumour Spread

The corpus callosum is important for tumour spread

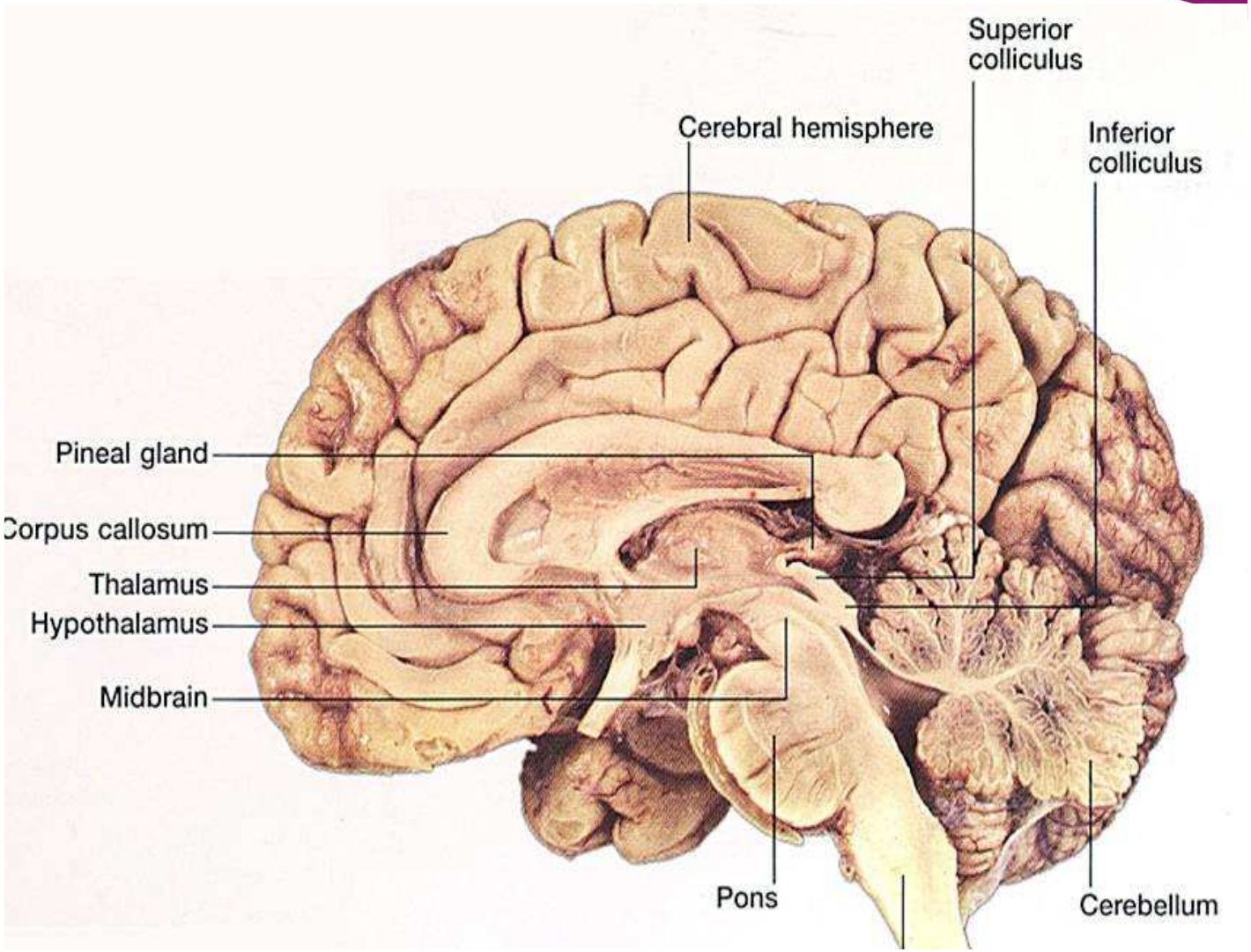

Tumour spread

ESTRO School

Tumour spread

- Bi-frontal GBM
- Spread through corpus callosum
- Early dementia
- (*Not* for radical treatment)

Tumour spread

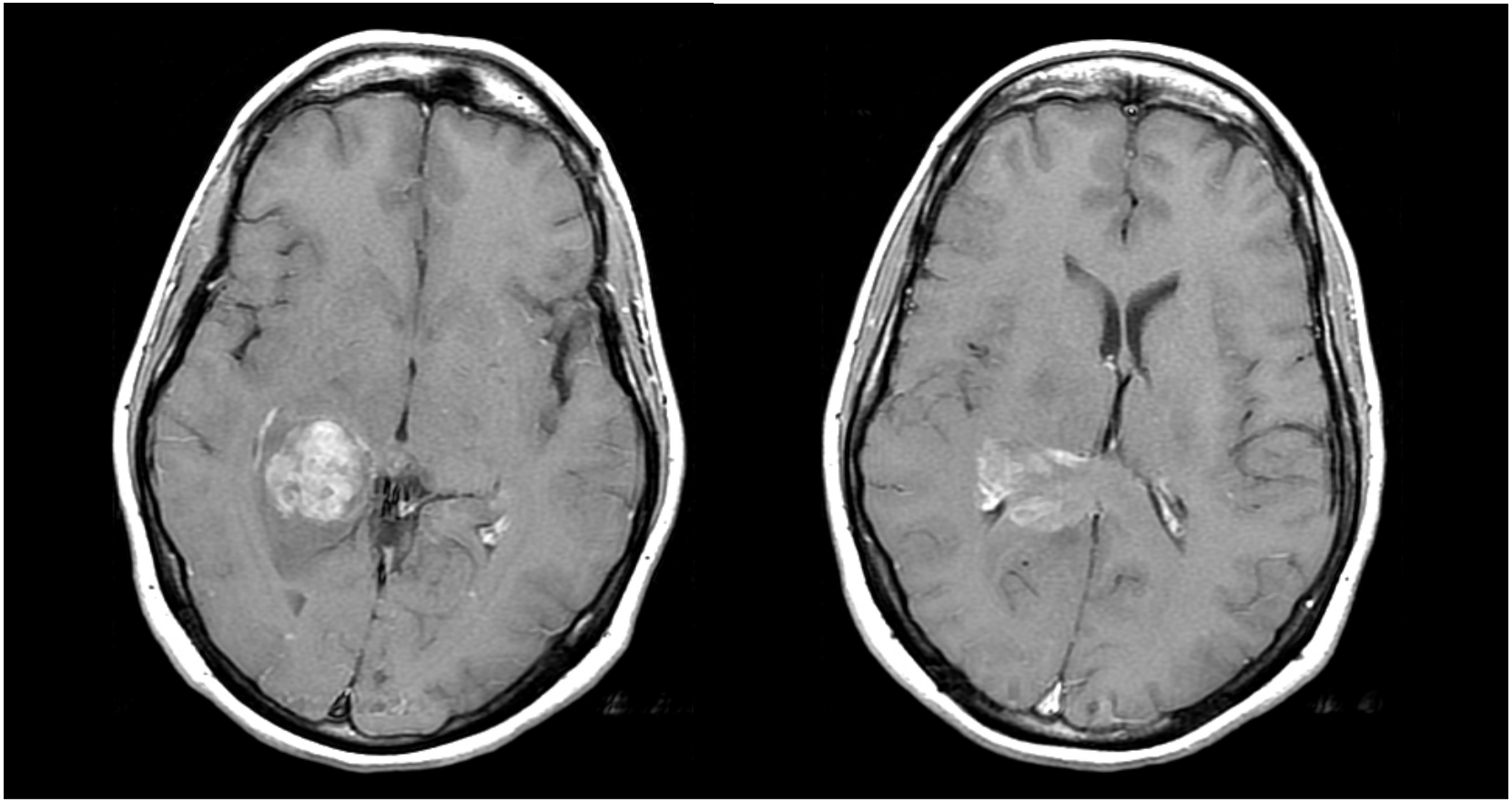

Spread through posterior corpus callosum

No barrier inferiorly, & excellent white matter pathway

ESTRO School

Barriers

Gliomas spread through the brain

Tumours can spread up and down – as well as front to back and across

The skull, falx and tent prevent spread

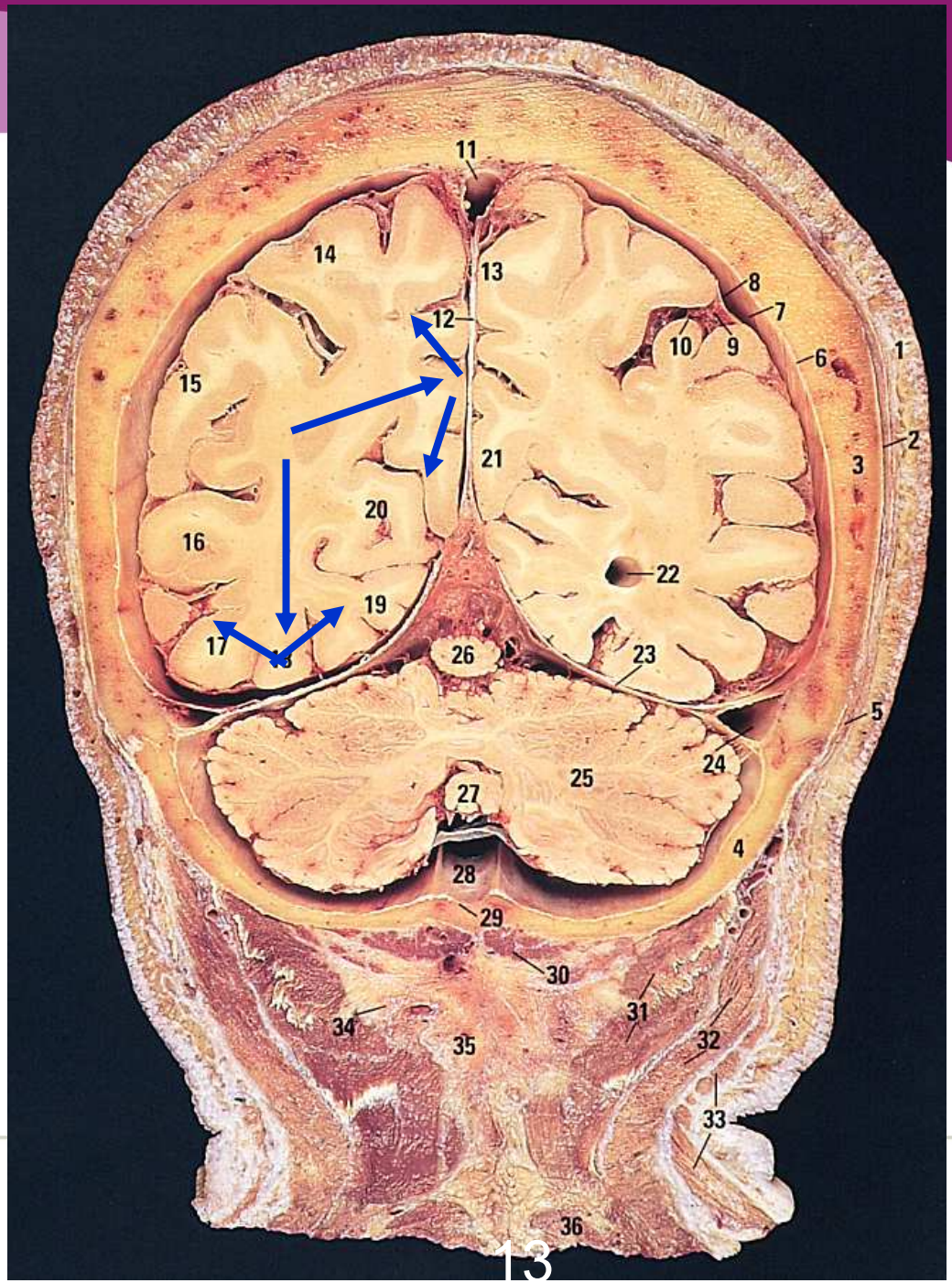

Tumour spread

Spread into corpus callosum and brain stem

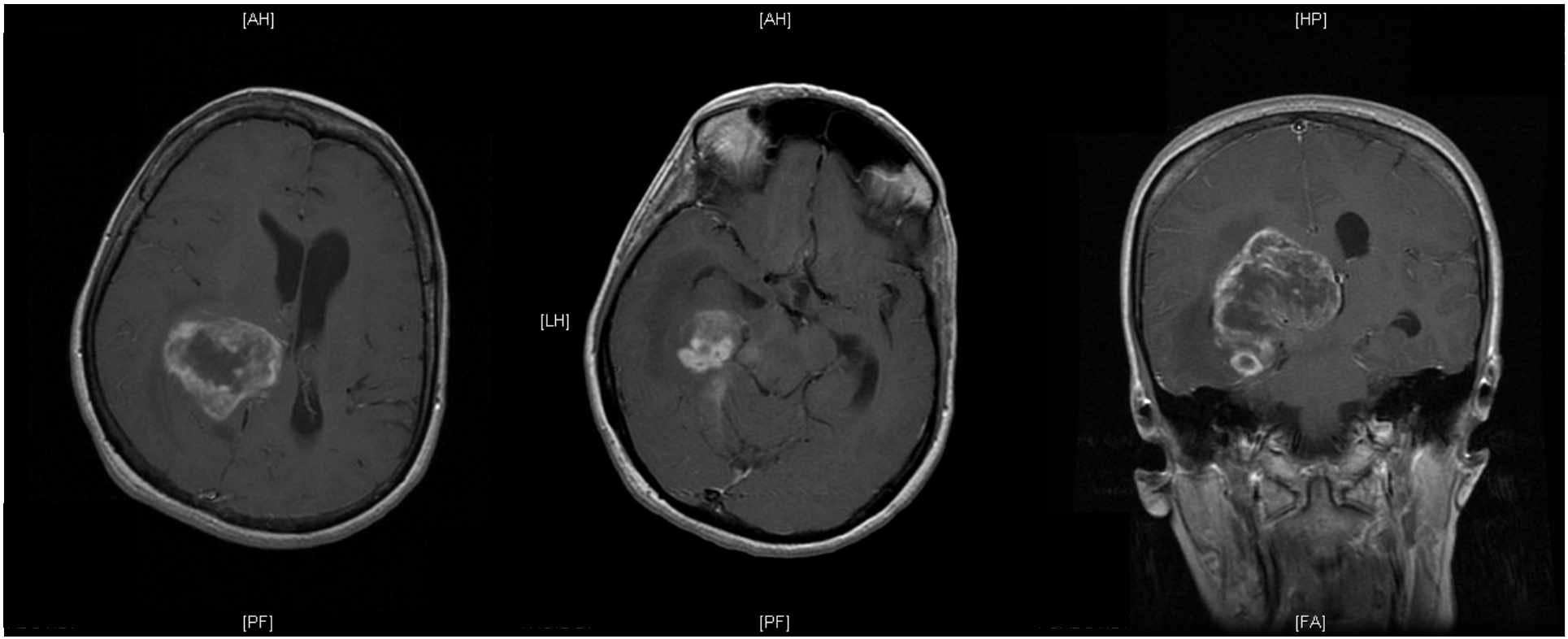

Inter-thalamic adhesion

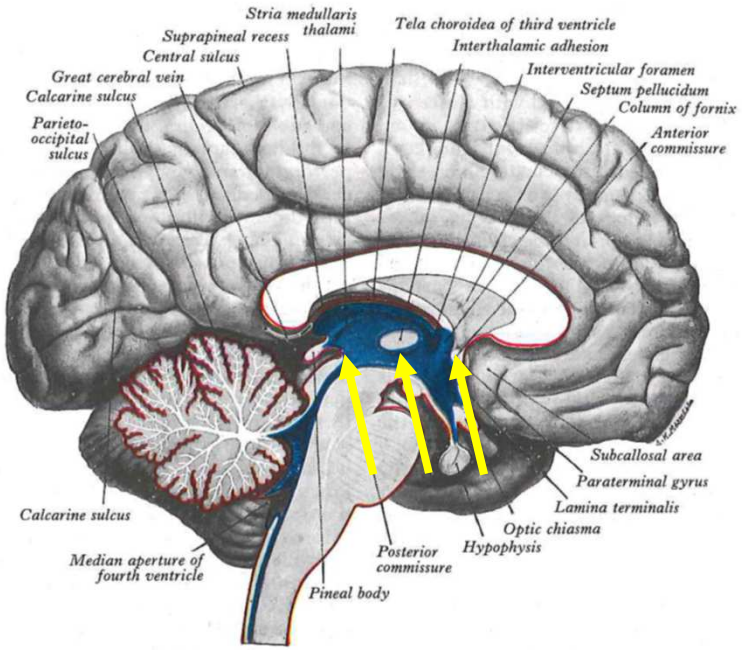

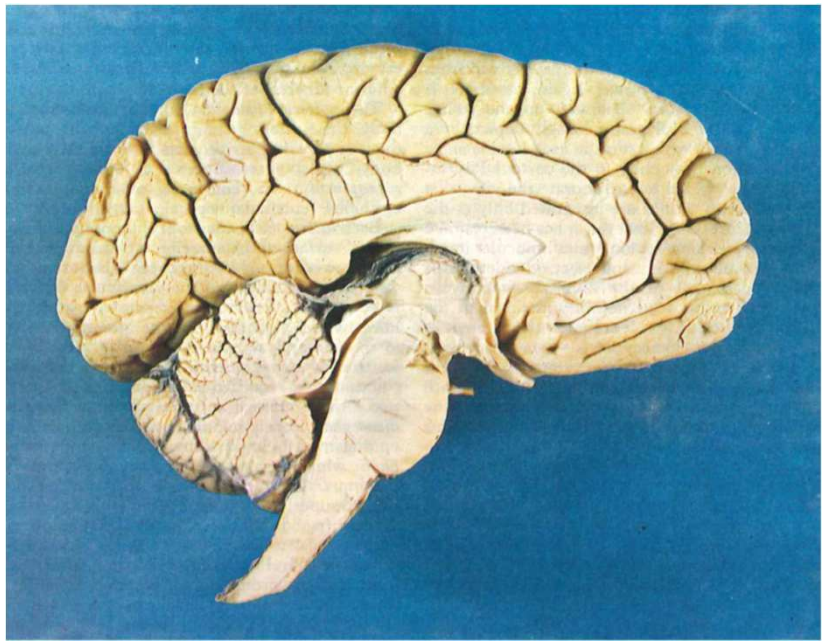

Inter-thalamic adhesion

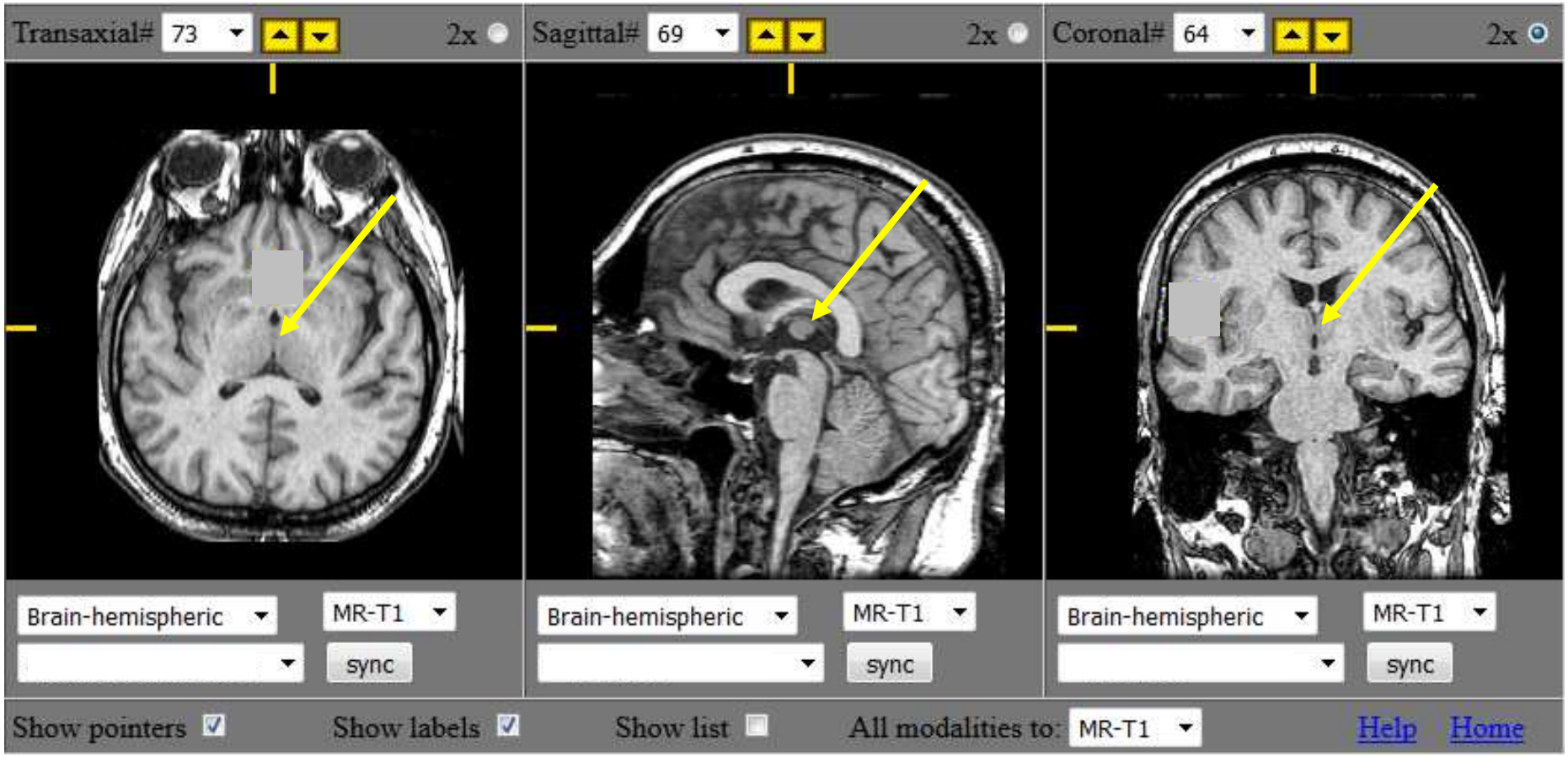

http://www.med.harvard.edu/AANLIB/cases/caseNA/pb9.htm

ESTRO School

Tumour Spread

Tumour spread is the reason for large target volumes (ie the CTV margin) for patients with HGG

It is not as useful as you might think because of the pathways for potential spread, especially along white matter tracts

Editing CTV against anatomical boundaries makes sense

HGG - CTV

Imaging shows gross tumour well (GTV)

Microscopic CTV not seen at all

Use optimal imaging

Need careful preparation for target volume delineation

Essentials

CT for dose calculation

MRI for GTV (select optimum sequences)

Software for CT/MRI fusion for planning

Check fusion (clinician role)

HGG - GTV

Post operative imaging is preferable

- Within 72 hours can assess residual gross tumour

Debulking surgery

- Reduces the volume of the GTV
- Reduces displacement of brain

Steroids also reduce mass effect by reducing oedema

- The effect is progressive

GBM early post-op imaging

Post surgical MRI – should be within 24-72 hours

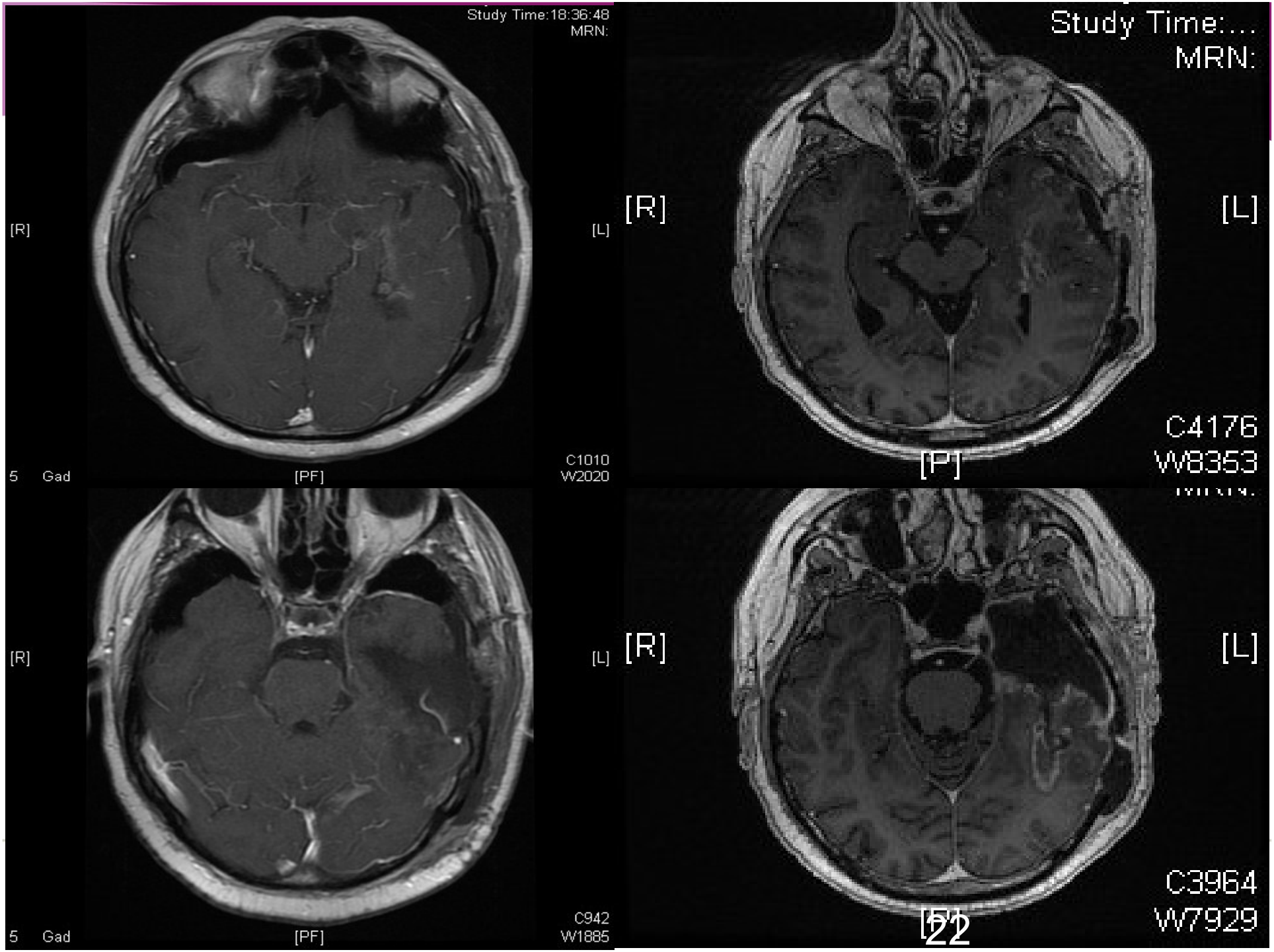
Study Time:18:36:48
MRN:
[R]
[L]
5 Gad
[PF]
C1010
W2020
Study Time:...
MRN:
[R]
[L]
[P]
C4176
W8353
[R]
[L]
5 Gad
[PF]
C942
W1885
[R]
[L]
[P]
C3964
W7929

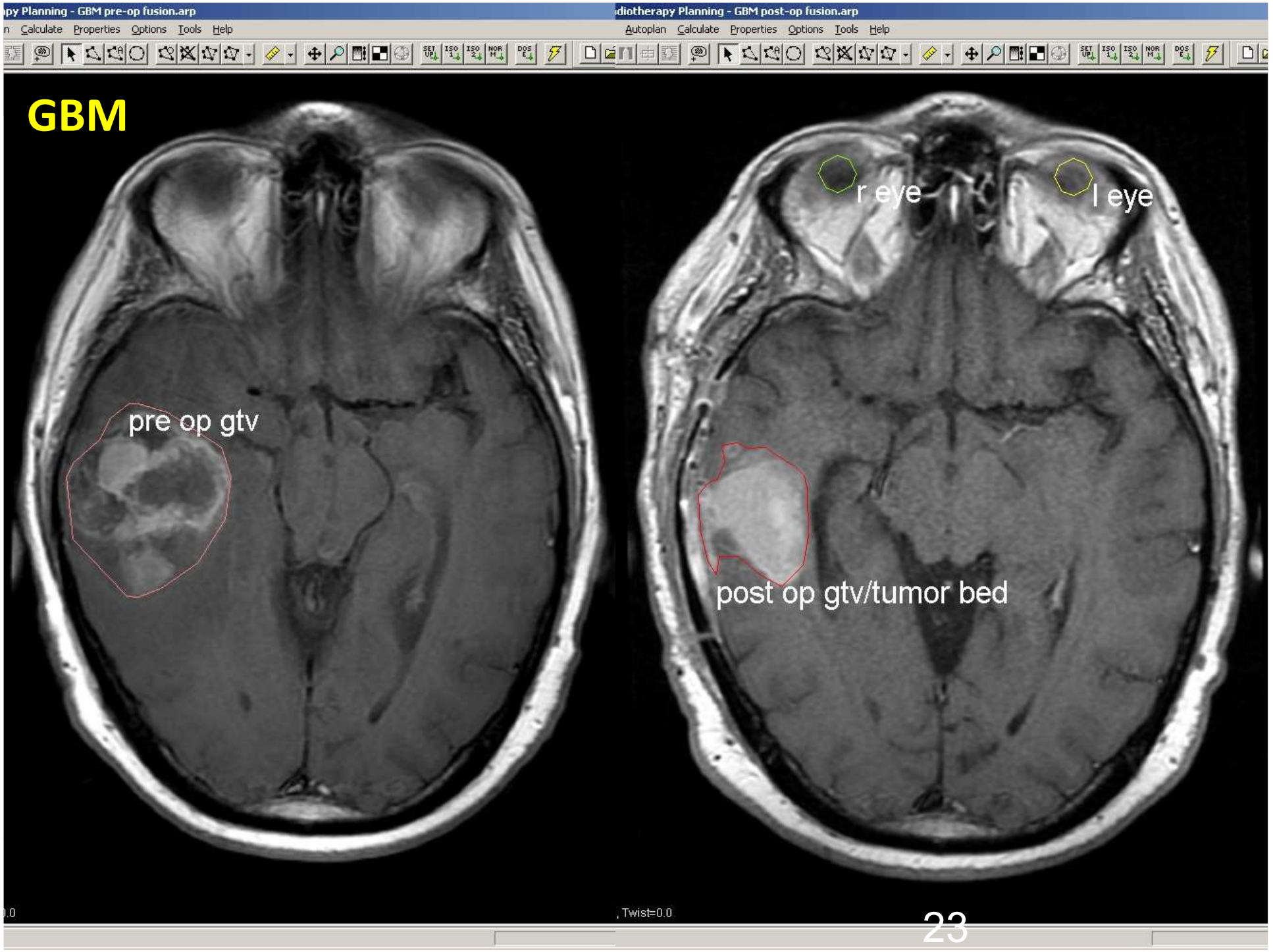
py Planning - GBM pre-op fusion.arp
n Calculate Properties Options Tools Help
diotherapy Planning - GBM post-op fusion.arp
Autoplan Calculate Properties Options Tools Help
GBM
pre op gtv
r eye
l eye
post op gtv/tumor bed
, Twist=0.0

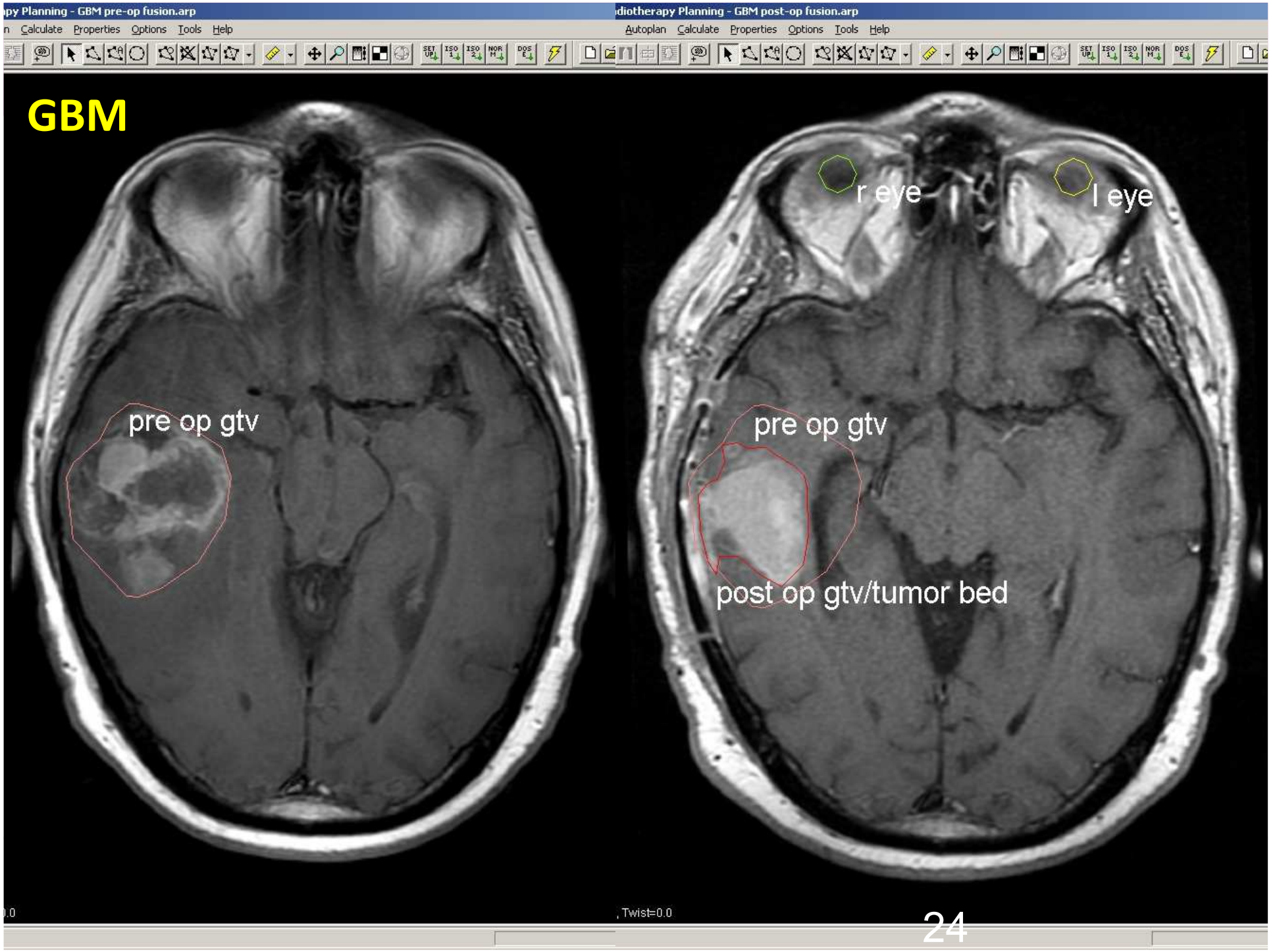
py Planning - GBM pre-op fusion.arp
n Calculate Properties Options Tools Help
diotherapy Planning - GBM post-op fusion.arp
Autoplan Calculate Properties Options Tools Help
GBM
pre op gtv
r eye
l eye
pre op gtv
post op gtv/tumor bed
, Twist=0.0

GBM

- Significant reduction in volume
- Also reduction in brain shift
- Note reduction superiorly

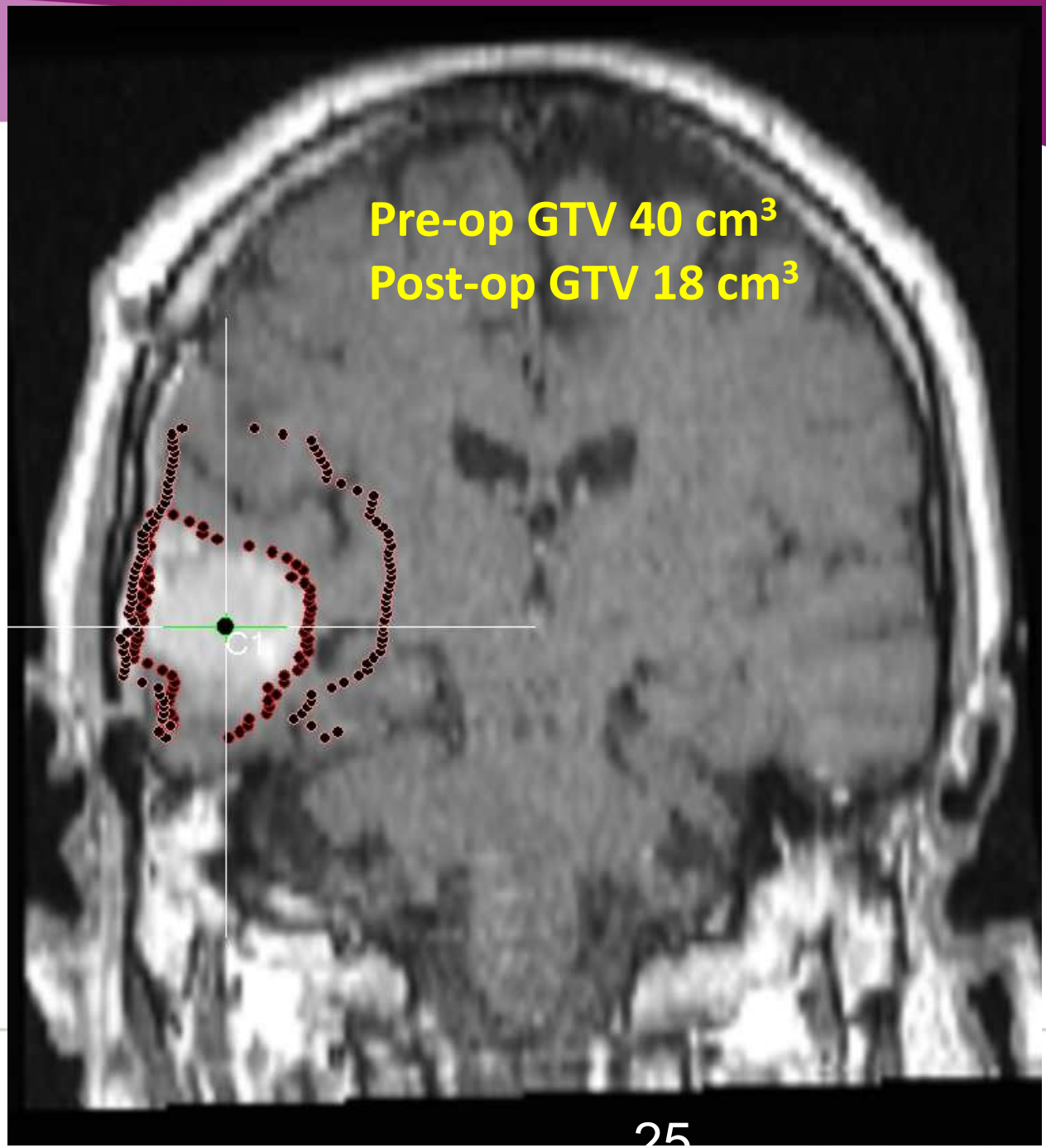

HGG - GTV

For high grade tumour, beware rapid growth

Scan near to the start of RT

Example scans ....

HGG - GTV

Small GBM in man of 50

MRI at time of initial Presentation

HGG - GTV

RT planning scan 3 weeks later

Target volume now very different

RT Planning Scan

MRI

- Within 2 weeks of intended treatment
- 3mm slices
- Sequences:
  - T1 with gadolinium
  - Flair sequences

HGG – GTV definitions

MRI – T1 with contrast

GTV = Contrast-enhancing edge

or = Contrast-enhancing edge + surgical cavity

MRI – Flair

GTV – include if secondary GBM

Surgical Cavity

- Original resection (temporal lobectomy) 1992
- Routine follow up

ESTRO School

HGG – GTV / CTV

Recurrence in ‘empty’ temporal fossa

Initially observed for 4 months

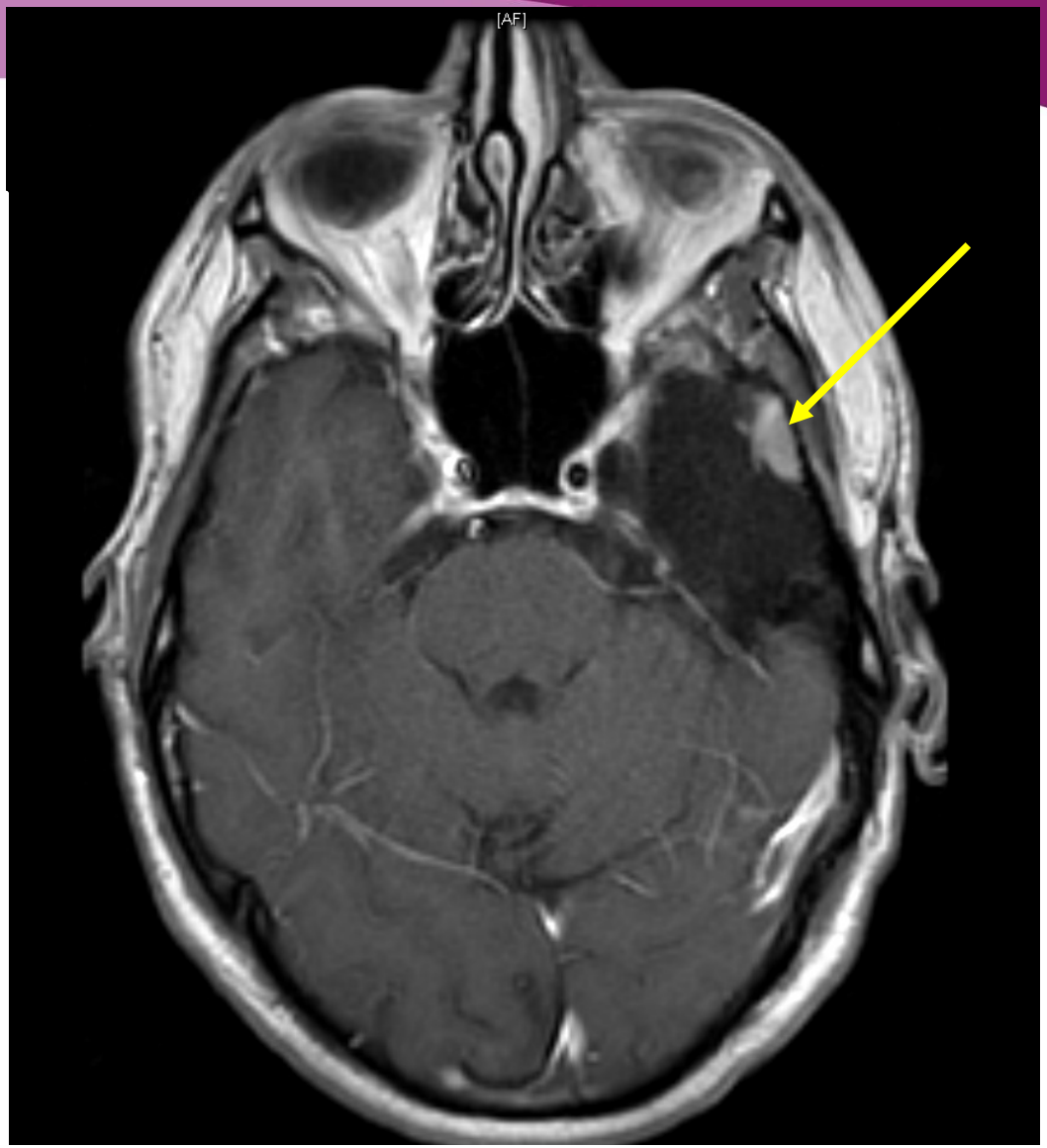

ESTRO School

HGG – GTV / CTV

Low grade glioma

Recurrence in temporal fossa

Now HGG

Cavity should be in target – GTV or CTV?

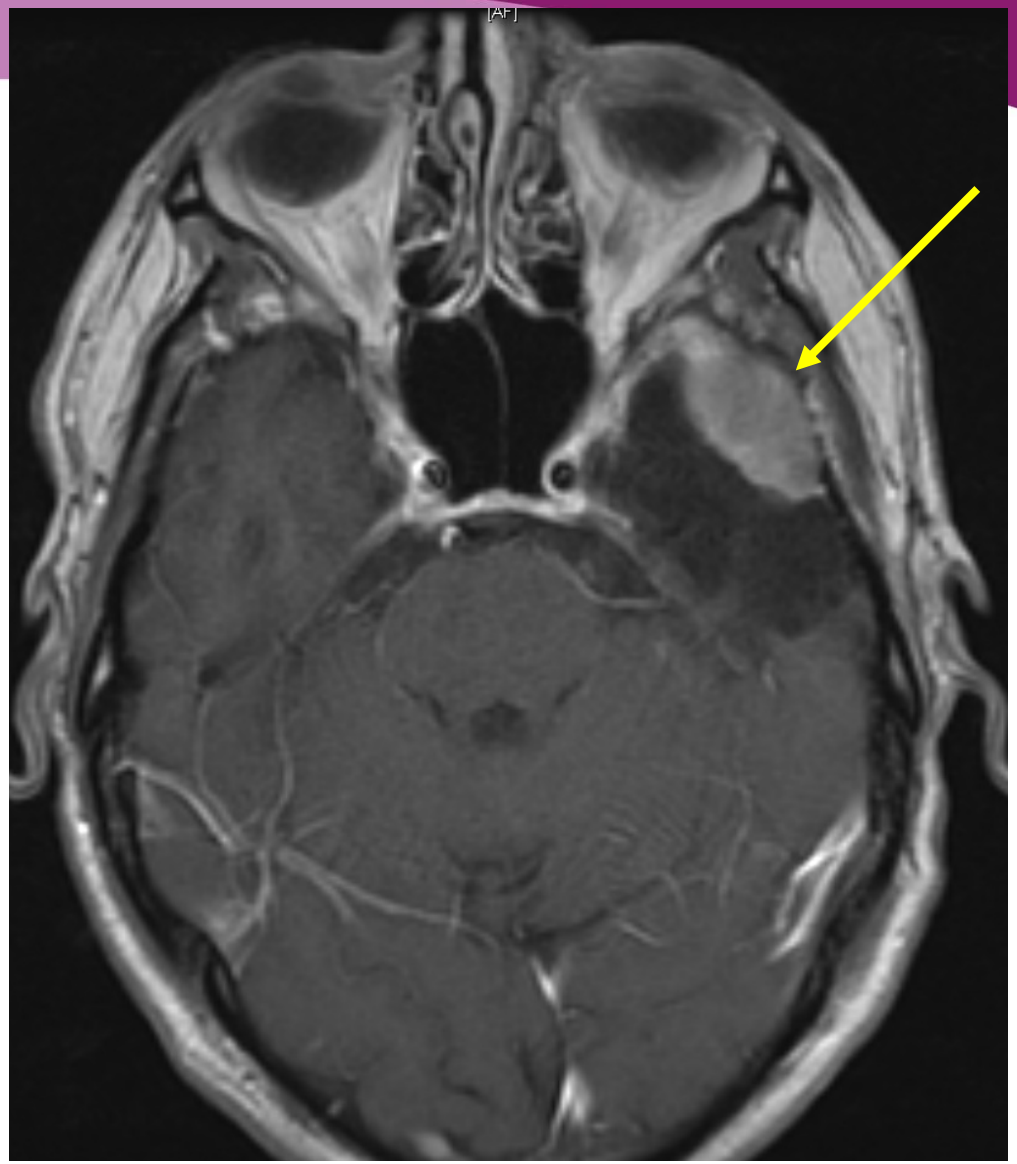

Planning CT

(+ contrast)

MR co-registered

T1 + Gd

CT +MRI

Starting delineation

GTV

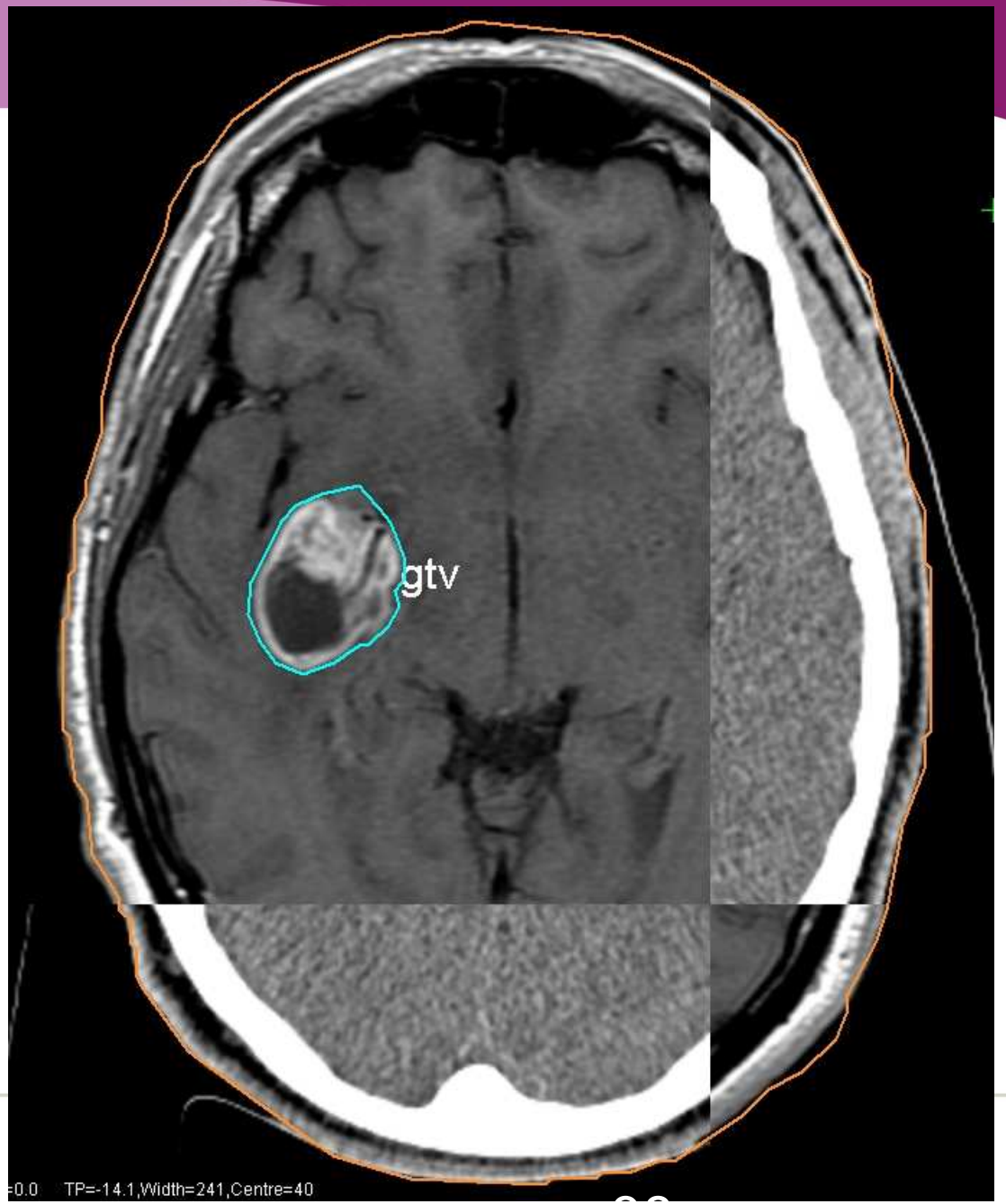

From GTV to CTV

Vincent van Gogh
The Starry Night 1889

ESTRO School

HGG – CTV Suggested margins

- Whole brain or localised RT?
- Outcome studies suggest localised RT is as good for TCP

Marsa et al 256 pts, Cancer 1975; 36: 1681-89
Shapiro et al 571 pts randomised, J Neurosurg 1989; 71: 1-9
Kita et al 43 pts randomised, Gan No Rinsho 1989; 35: 1289-94

GBM - Effect of volume irradiated on survival

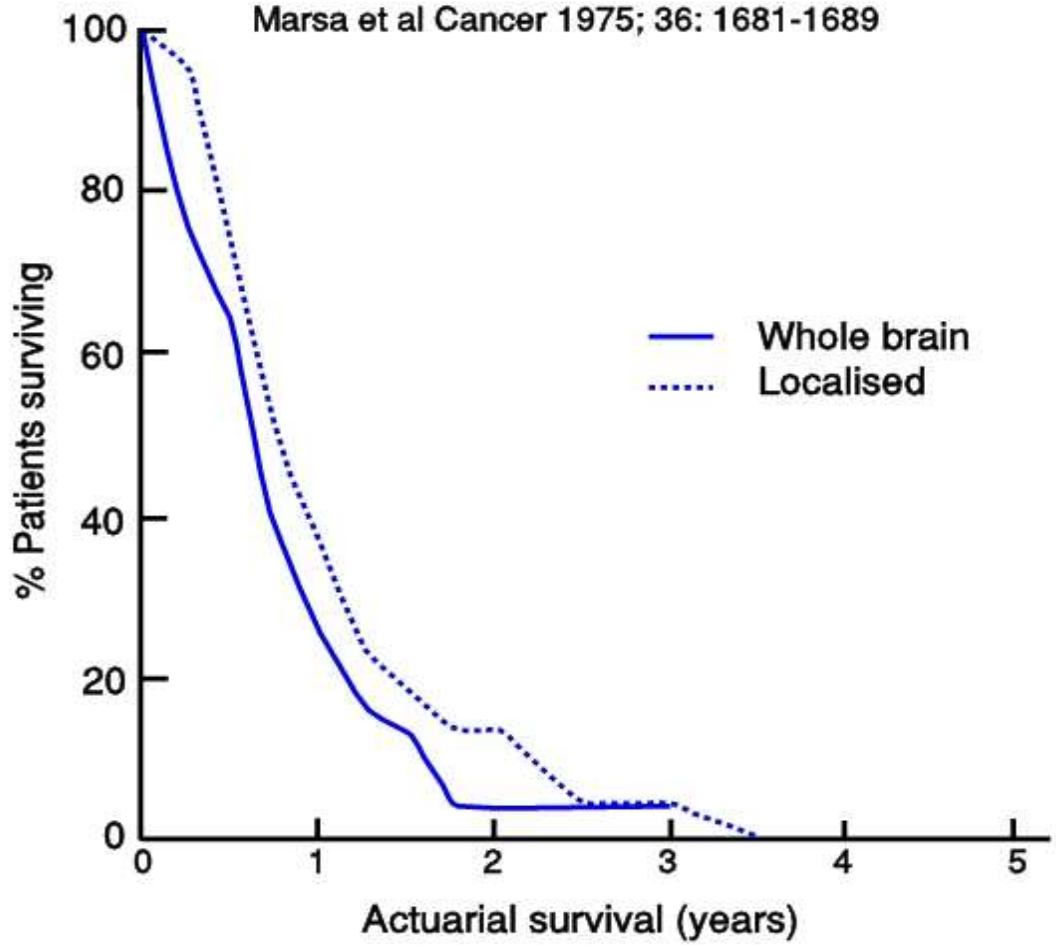

HGG - CTV

- Data exist to guide margins from:
  - post mortem studies
  - biopsy studies
  - clinical experience of recurrence patterns

Jansen EP et al. Radiother Oncol 2000; 56: 151-166

Recurrence Patterns

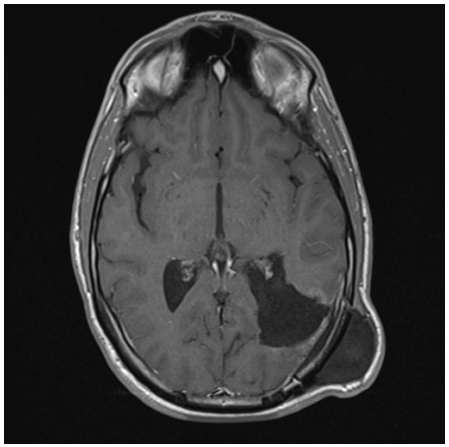

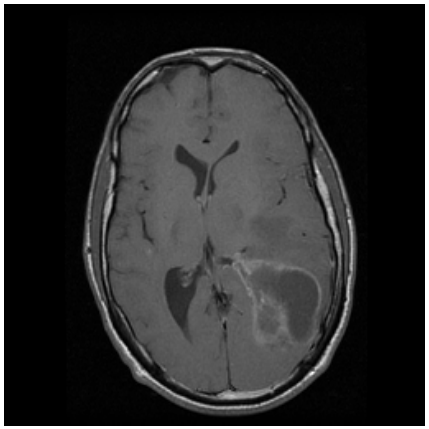

80-90% of recurrence is at the site of initial disease

10-20%

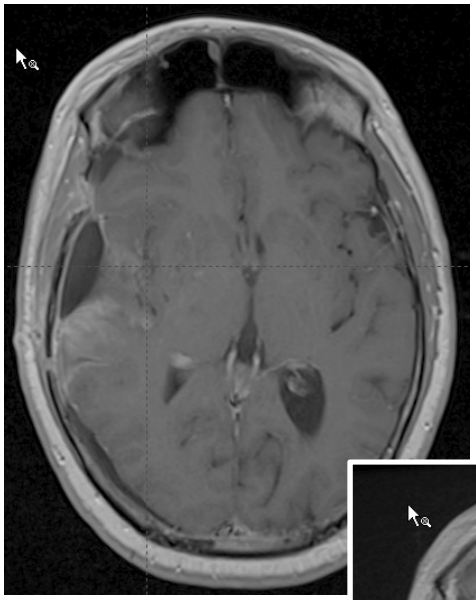

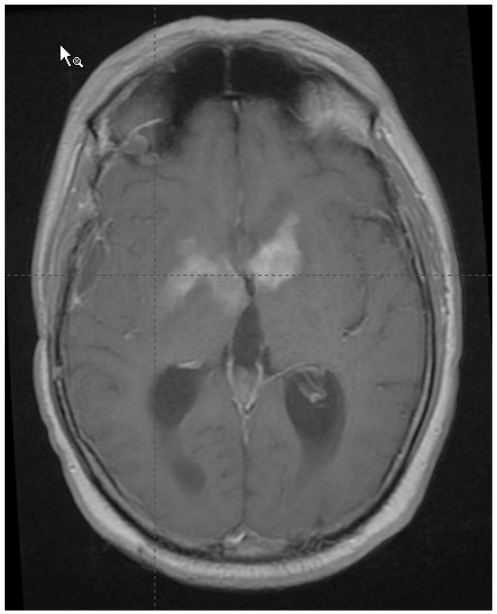

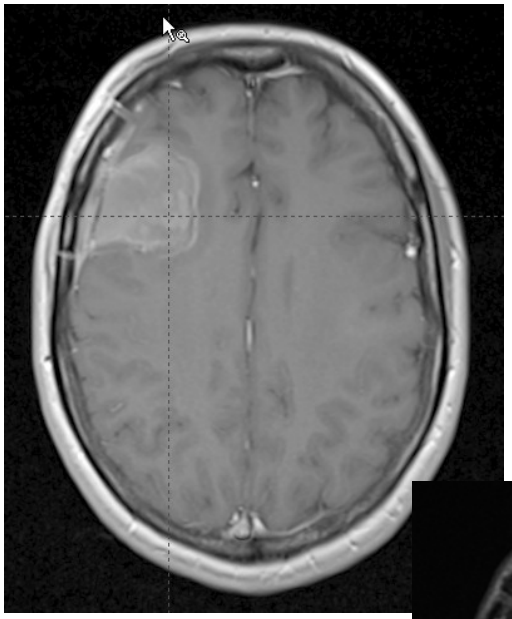

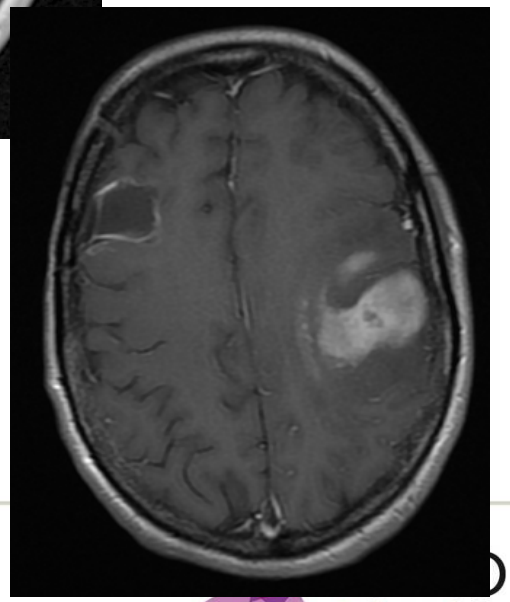

Data from East Anglia

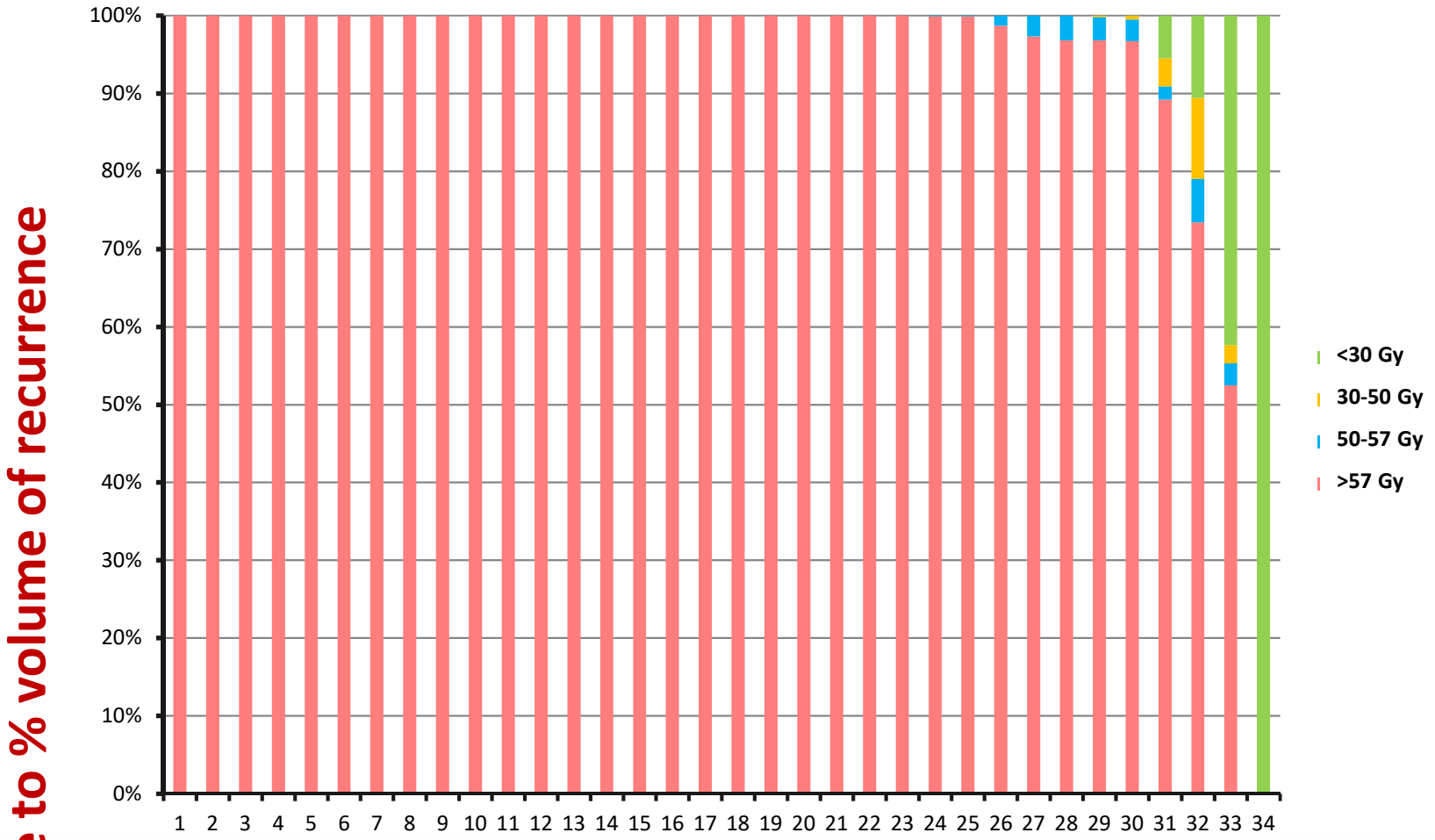

Patients data sets 1-34

ESTRO School

HGG - CTV

- In 80 - 90% of cases in studies of post mortem, biopsy, or recurrence, tumour extends up to ≈ 2 cm from edge of gross tumour (ie GTV)
- This suggests a CTV margin : 2 (to 3) cm
- ***Not*** necessary to include all oedema

Oedema

- Oedema is an unreliable measure of tumour spread
  - It does contain tumour cells
- Steroids reduce oedema
  - Progressive effect
  - Not an antitumour effect
- Not recommended as basis for CTV

Oedema reduced by steroids

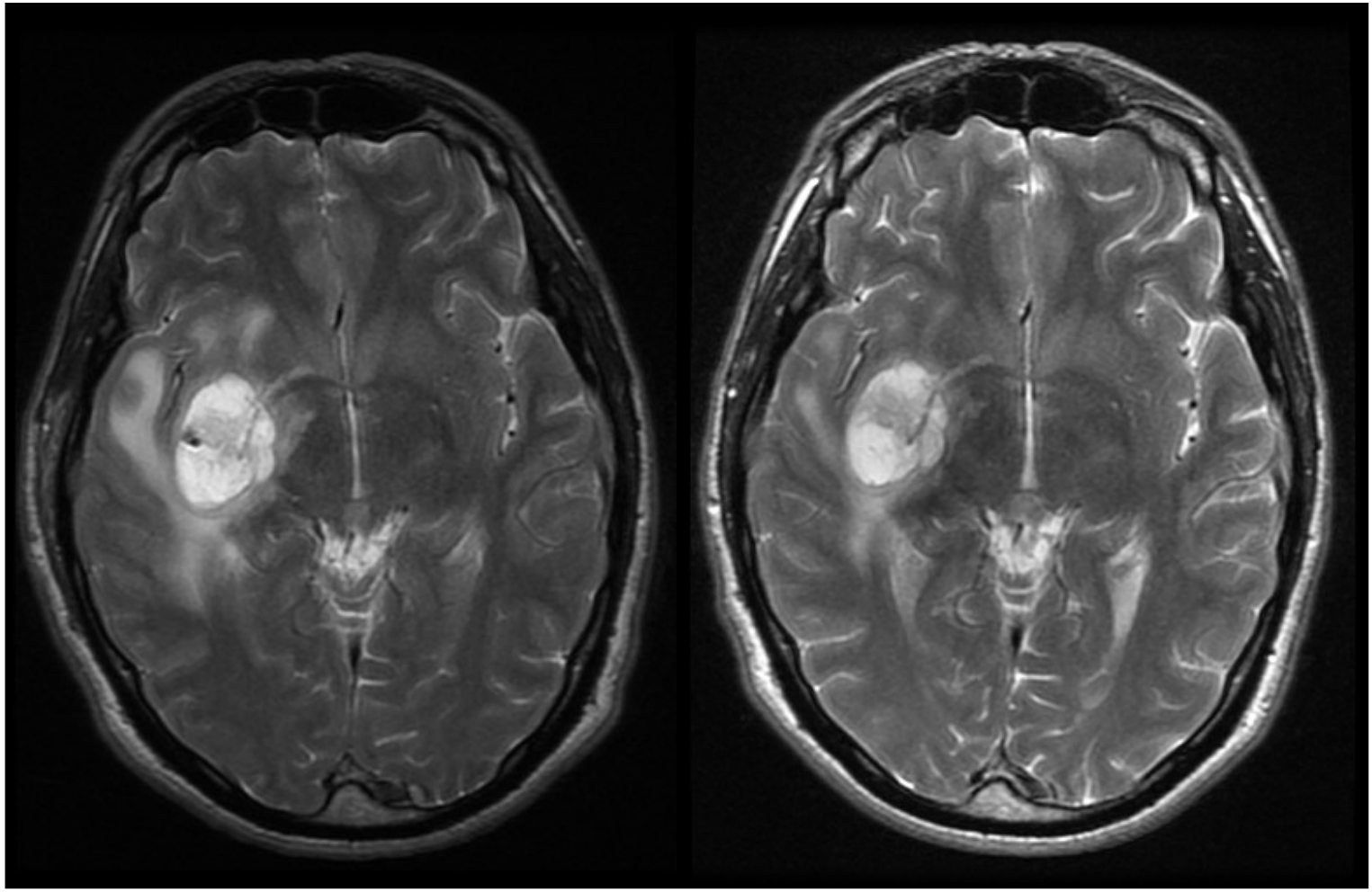

1 week post op (biopsy)

1 week later – RT planning

ESTRO School

HGG - CTV

- Some study protocols require inclusion of all oedema
- GTV defined as abnormal signal on FLAIR
- Then CTV adds further 2 cm
- This gives very large volumes:

Glioblastoma

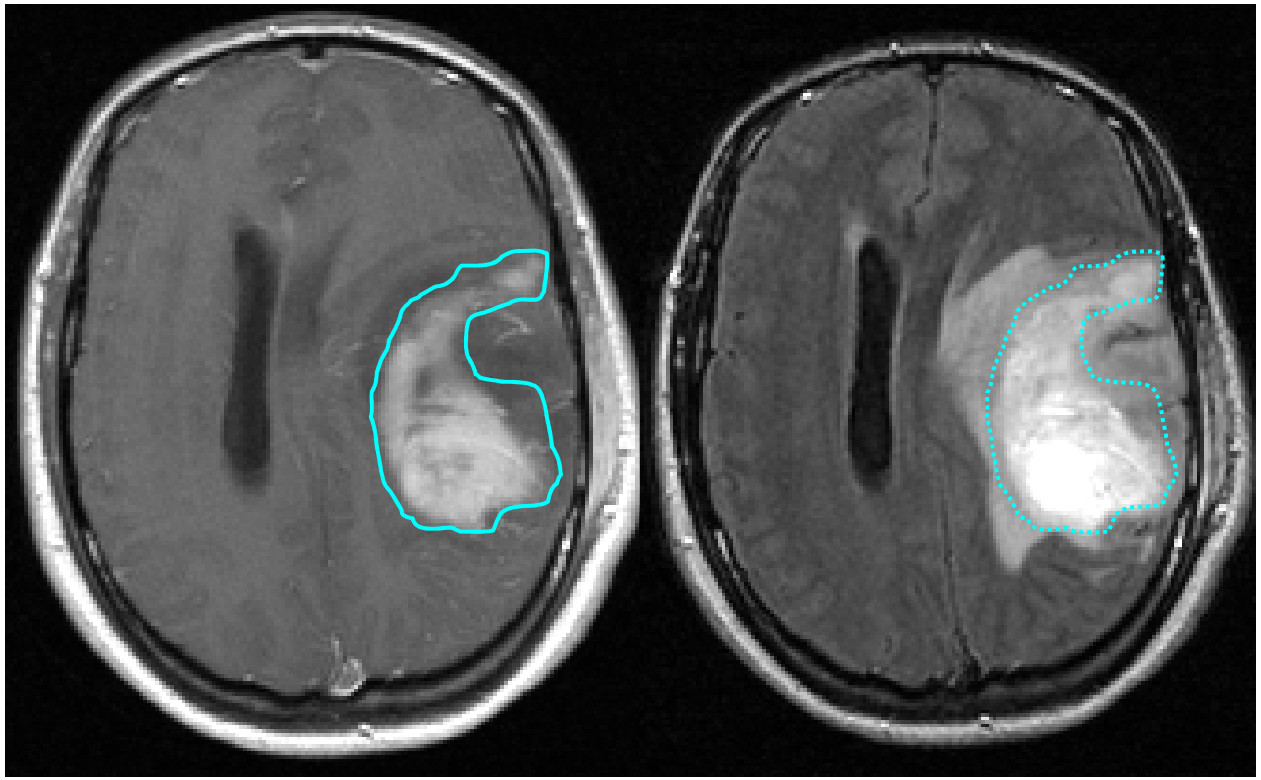

T1 + Gd **FLAIR + Gd**

GTV definition
- T1 + Gd
- FLAIR

Glioblastoma

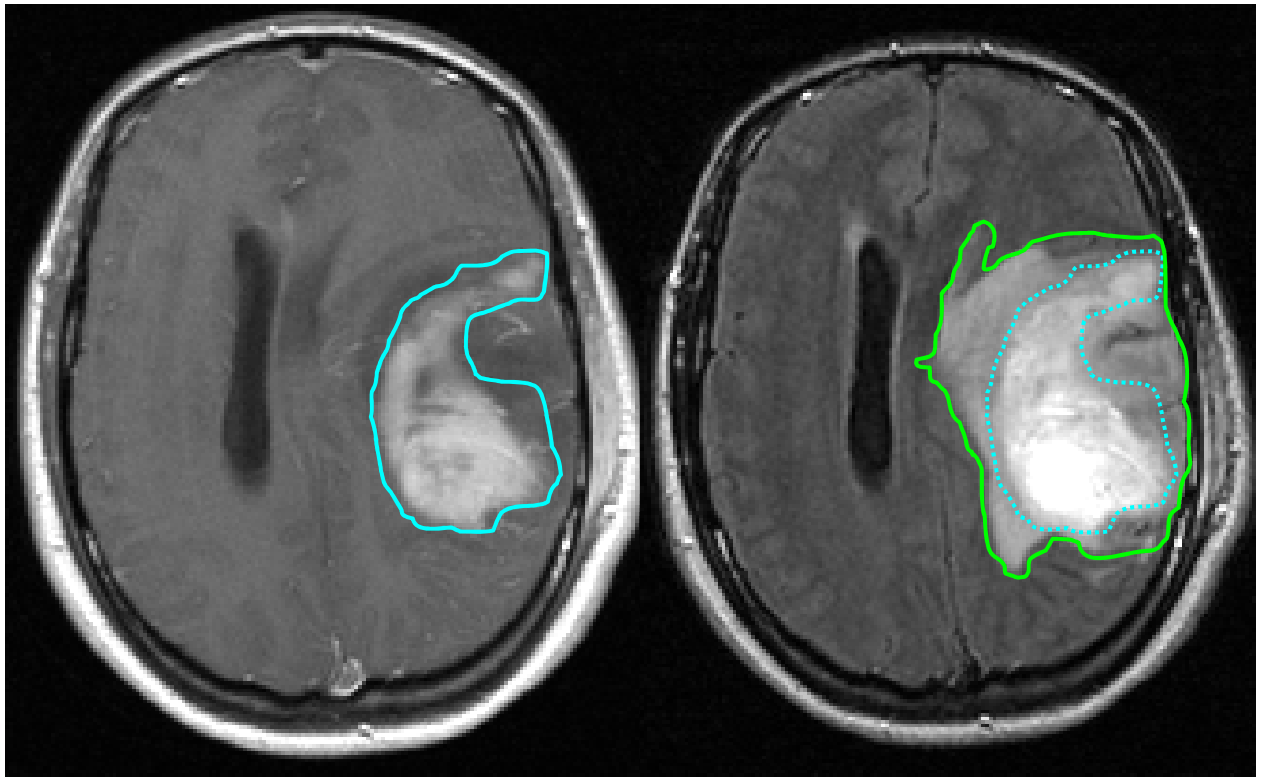

T1 + Gd **FLAIR + Gd**

GTV definition
- T1 + Gd
- FLAIR

Glioblastoma

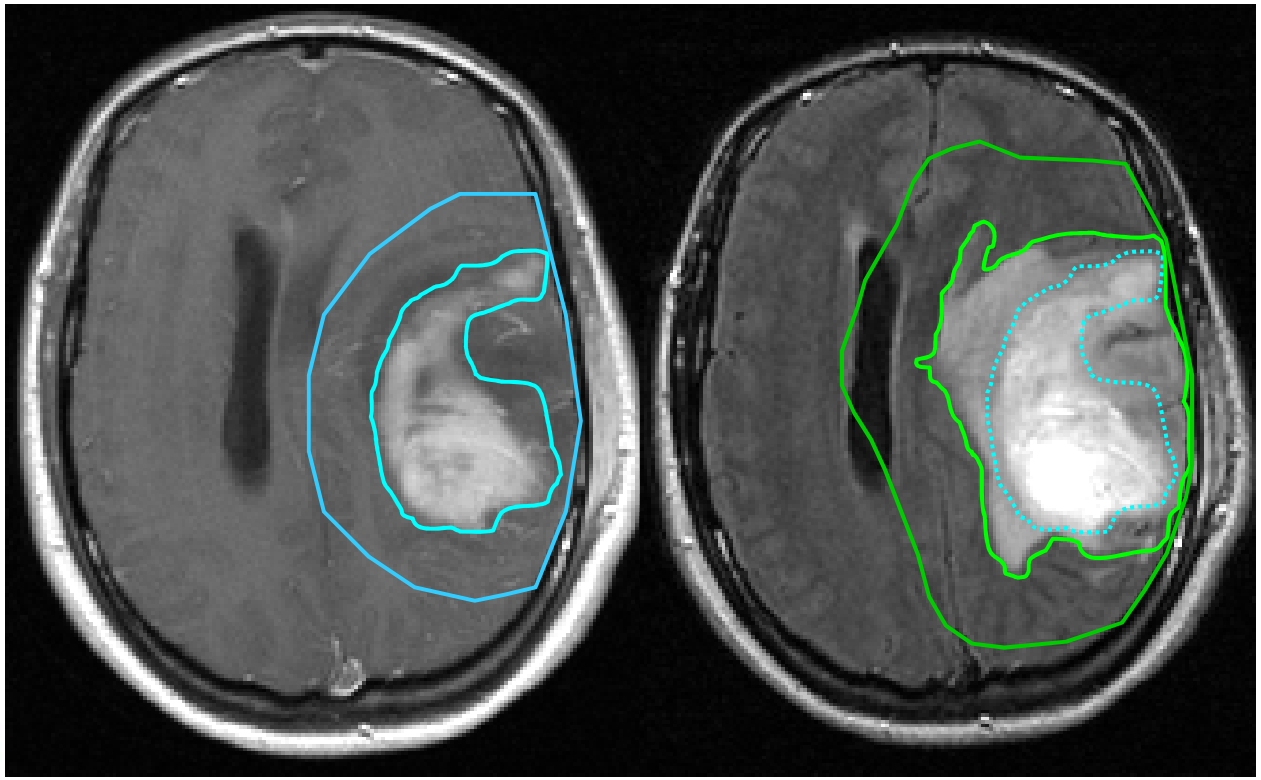

T1 + Gd **FLAIR + Gd**

GTV definition
- T1 + Gd
- FLAIR

Evidence:
- T1 + Gd

Volume:
- T1 + Gd

Oedema – include or not?

48 patients GBM

Treated with RT – 2cm margin for CTV (as per EORTC)

All recurred

Replanned – including oedema as per RTOG protocol

Chang et al., 2007 Int J Radiat Oncol Biol Phys 2007

Oedema – include or not?

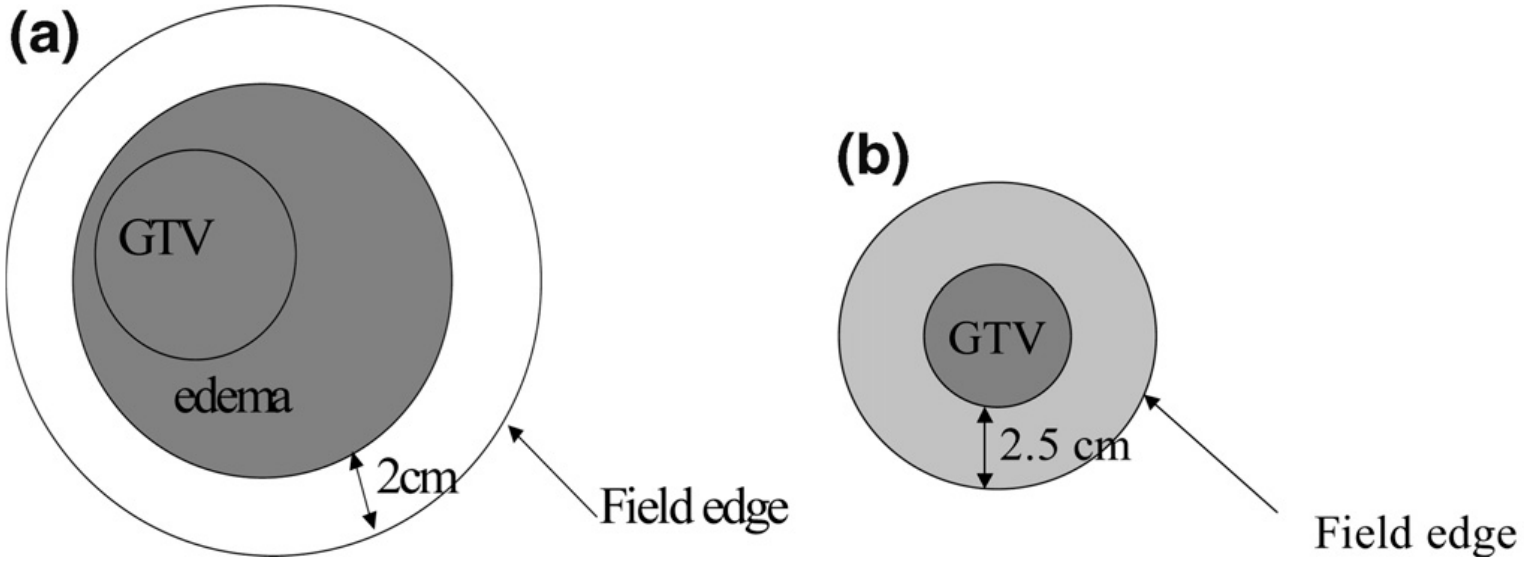

Oedema – include or not?

Pattern of failure was **identical** between the two sets of plans

- 40 central
- 3 in-field
- 3 marginal
- 2 distant recurrence

With 2-cm margin

- smaller median % volume of brain irradiated to 30 Gy, 46 Gy, and 50 Gy

Minniti et al. Radiother Oncol 2010; 97: 377-381

ESTRO School

GTV - T1+Gd or oedema

Minniti et al. Radiother Oncol. 2010; 97(3): 377-81

Contents lists available at ScienceDirect

Radiotherapy and Oncology

journal homepage: www.thegreenjournal.com

CNS radiotherapy

Patterns of failure and comparison of different target volume delineations in patients with glioblastoma treated with conformal radiotherapy plus concomitant and adjuvant temozolomide

Giuseppe Minniti [a,b,*], Dante Amelio [c], Maurizio Amichetti [c], Maurizio Salvati [b], Roberta Muni [a], Alessandro Bozzao [d], Gaetano Lanzetta [b], Stefania Scarpino [e], Antonella Arcella [b], Riccardo Maurizi Enrici [a]

NO difference in recurrence patterns whichever approach would have been used

No difference in recurrence patterns with TMZ

ESTRO School

HGG - CTV

Select best imaging

GTV = Contrast-enhancing edge

or = Contrast-enhancing edge + surgical cavity *

CTV = GTV plus 2.0 cm

* applies principally to temporal fossa after lobectomy

CT +MR

Starting delineation

GTV

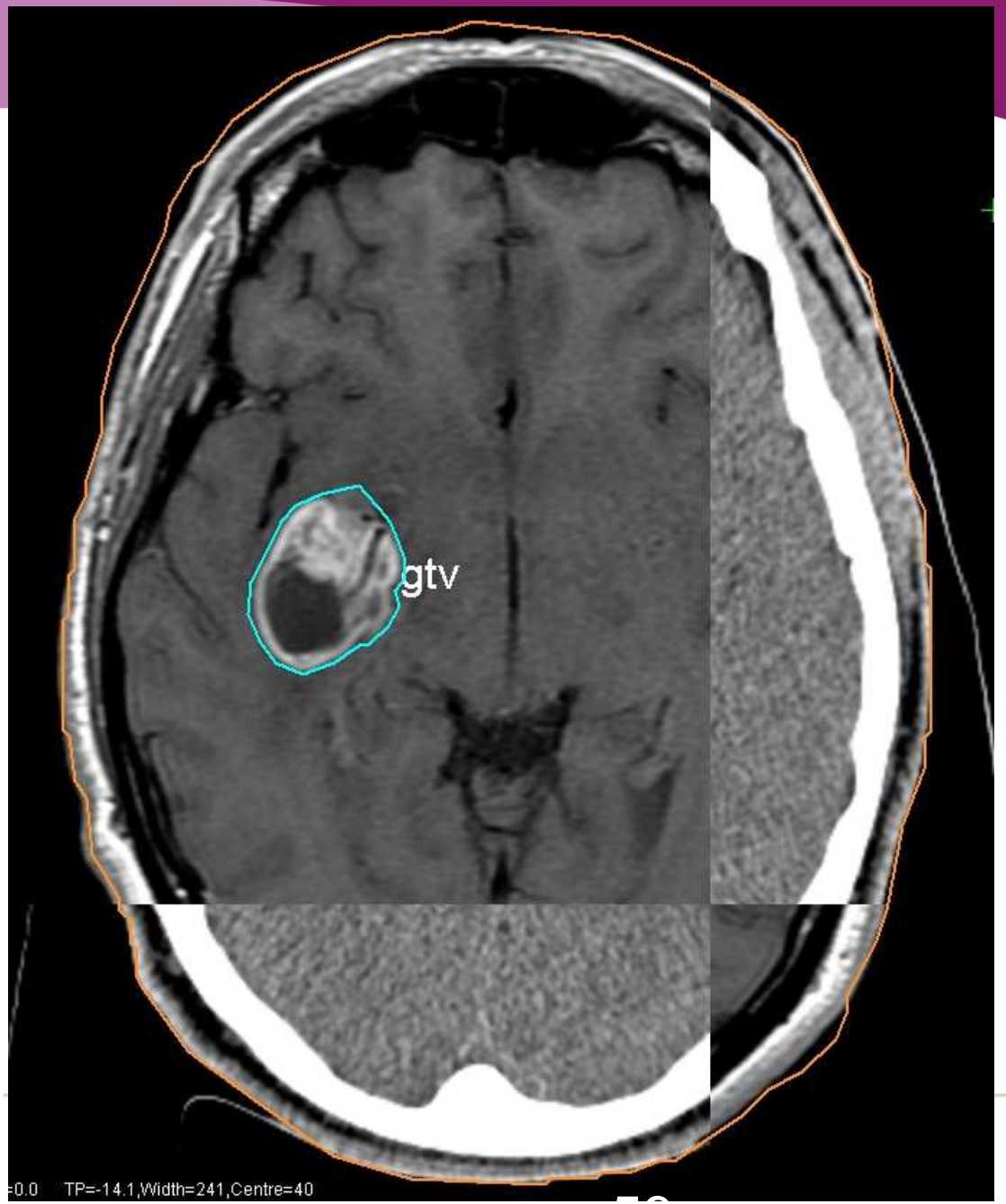

CTV added

Margin = 2.5 cm

Grown
isotropically,
up to skull

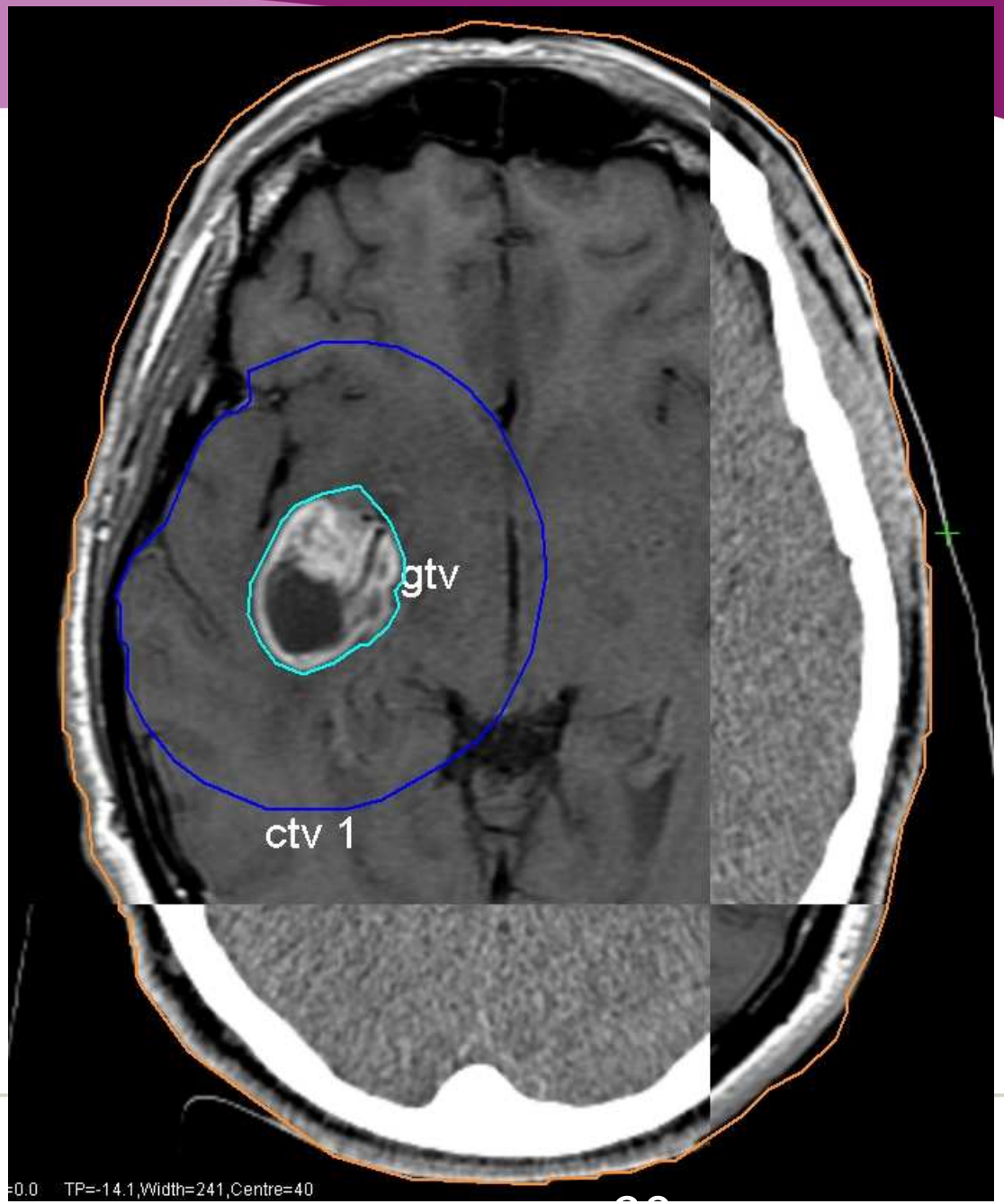

Editing CTV boundaries - suggestions

Skull – 0mm (bony window)

Visual apparatus – 0mm

Falx/Tentorium – 5mm

Ventricles – 5mm

High grade glioma - PTV

Use the ‘Margin Recipe’ - PTV = $2.5\Sigma + 0.7\sigma$

Measure the standard deviations in each department

Our dept – PTV margin = 0.3 cm with IGRT

Systematic errors (mm)			
Gaussian			
∑doctor	0.0	0.0	0.0
∑motion	0.0	0.0	0.0
∑transfer	0.1	0.1	0.1
∑set-up	0.25	0.25	0.25
Σ(combined)	**0.3**	**0.3**	**0.3**
Linear			
b	0.0	0.0	0.0
a	0.0	0.0	0.0
Treatment Execution errors			
Gaussian			
σset-up	0.3	0.3	0.3
σmotion(target shape)	0.0	0.0	0.0
σp	5.5	5.5	5.5
σ(combined)	**5.5**	**5.5**	**5.5**
Planning parameter (β)	1.64	1.64	1.64
Semi-sides			
systematic	0.7	0.7	0.7
execution	9.0	9.0	9.0
breathing	0.0	0.0	0.0
scalar (a-βσp)	-9.0	-9.0	-9.0
Total CTV-PTV margin	**0.7**	**0.7**	**0.7**

Skull shown

Auto-outlined using CT

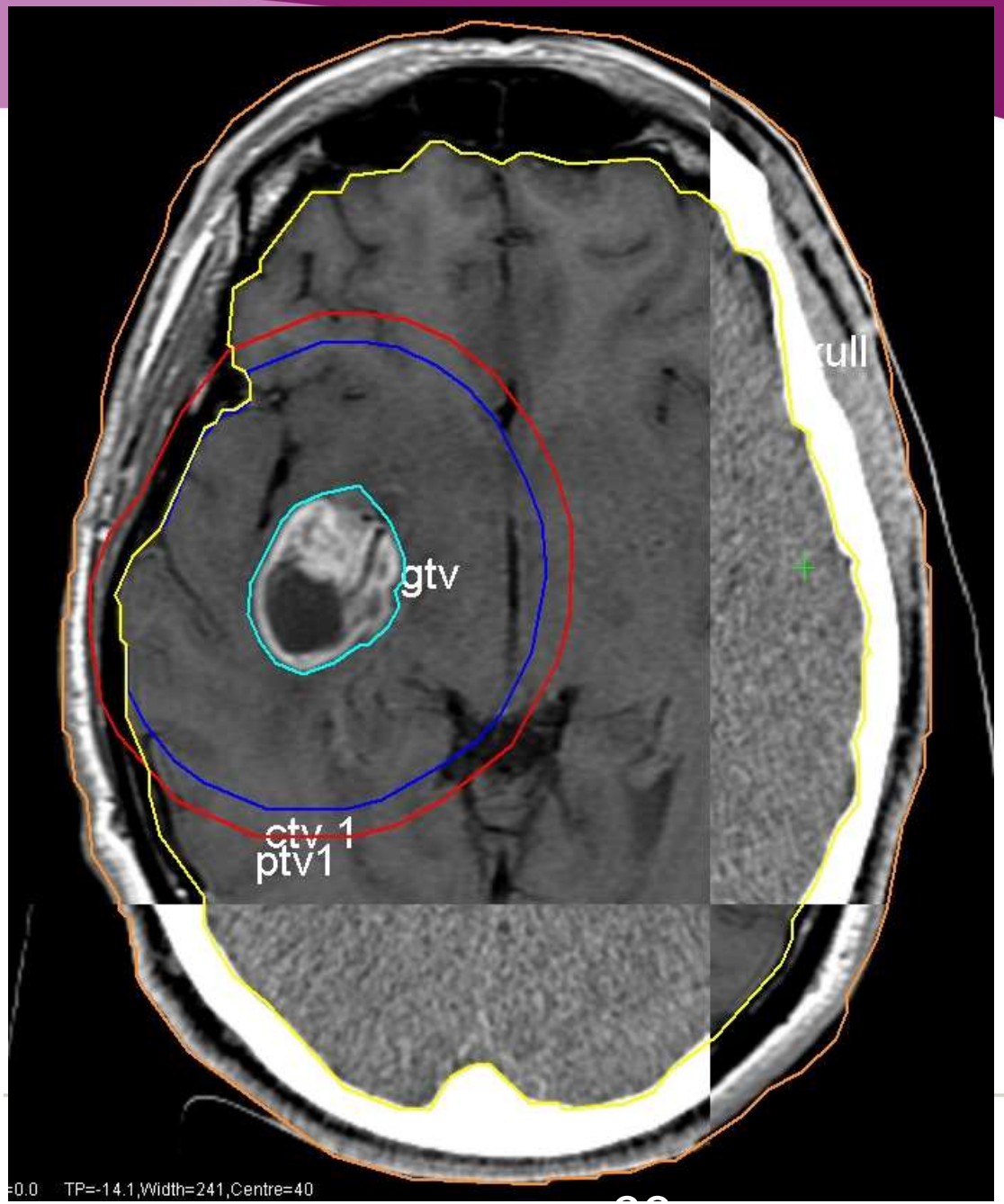

Final volumes on CT

GTV

CTV

PTV

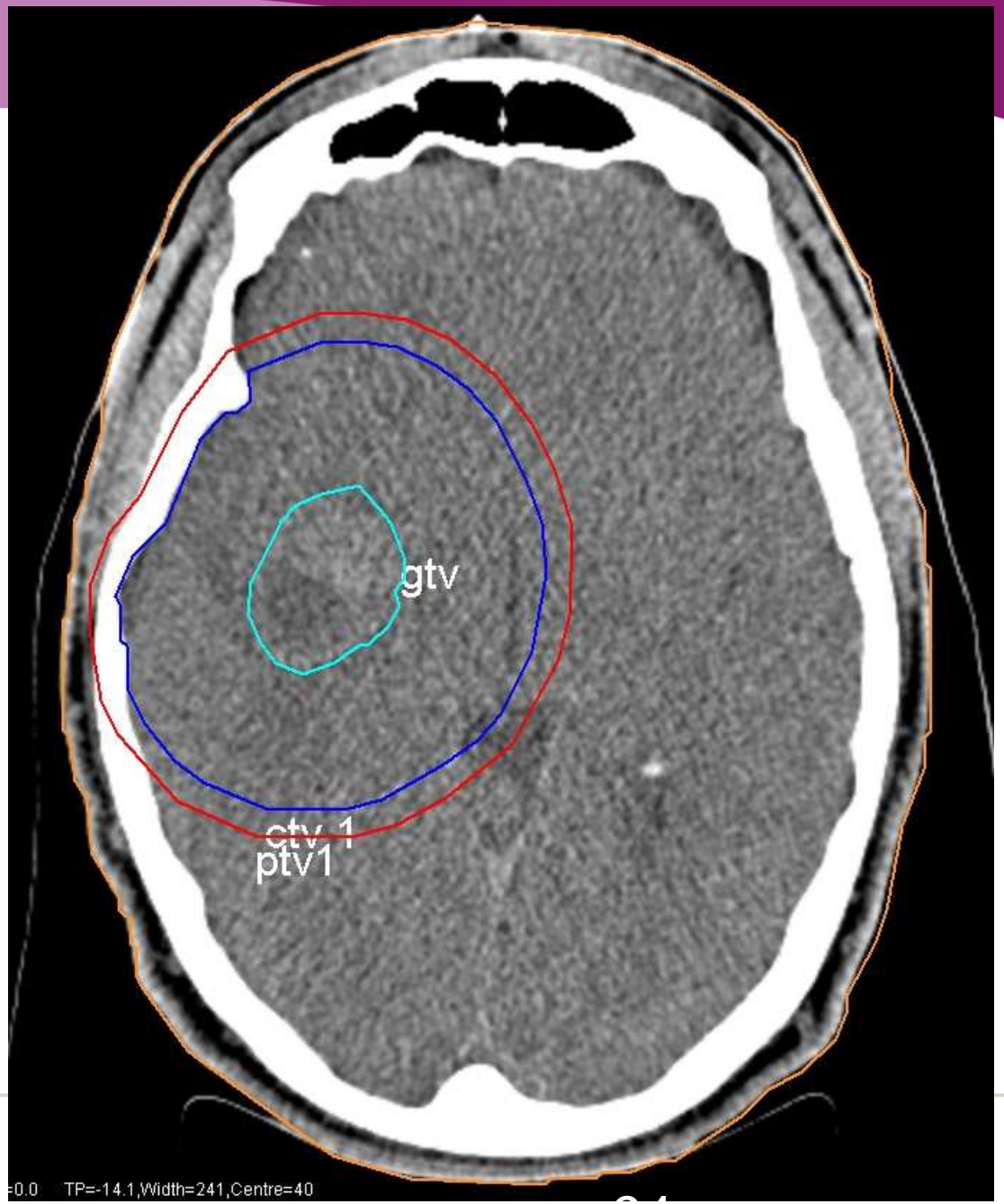

Summary

Key slide

GBM

- GTV Enhancing tumour edge on CT/MRI
- CTV 2.0 cm

Total dose 60 Gy / 30#

+ Temozolomide (TMZ) – concurrent + adjuvant

ESTRO-ACROP Guidelines

Key slide

Radiotherapy and Oncology 118 (2016) 35–42

Contents lists available at ScienceDirect

Radiotherapy and Oncology

journal homepage: www.thegreenjournal.com



ESTRO-ACROP guidelines: Gliobastoma

ESTRO-ACROP guideline "target delineation of glioblastomas"

Maximilian Niyazi [a,*], Michael Brada [b], Anthony J. Chalmers [c], Stephanie E. Combs [d], Sara C. Erridge [e], Alba Fiorentino [f], Anca L. Grosu [g], Frank J. Lagerwaard [h], Giuseppe Minniti [i], René-Olivier Mirimanoff [j], Umberto Ricardi [k], Susan C. Short [l], Damien C. Weber [m,n], Claus Belka [a]

[a] *Department of Radiation Oncology, University of Munich, München, Germany;* [b] *Department of Molecular and Clinical Cancer Medicine, Liverpool;* [c] *Institute of Cancer Sciences, University of Glasgow, UK;* [d] *Department of Radiation Oncology, Klinikum rechts der Isar, Technische Universität München, Institut für Innovative Radiotherapy (iRT), Germany;* [e] *Edinburgh Centre for Neuro-Oncology, University of Edinburgh, Western General Hospital, UK;* [f] *Department of Radiation Oncology, Sacro Cuore Hospital, Negrar-Verona, Italy;* [g] *Department of Radiation Oncology, University Medical Center Freiburg, Germany;* [h] *Department of Radiation Oncology, VU University Medical Center, Amsterdam, The Netherlands;* [i] *Unit of Radiation Oncology, Sant'Andrea Hospital, University of Rome Sapienza, Italy;* [j] *Radiation Oncology, Faculty of Biology and Medicine, University of Lausanne, Switzerland;* [k] *Department of Oncology, University of Turin, Italy;* [l] *Leeds Institute of Cancer and Pathology, St James's University Hospital, UK;* [m] *Center for Proton Therapy, Paul Scherrer Institute, Switzerland; and* [n] *University of Zürich, Switzerland*

ESTRO School

The Bridge of Sighs Cambridge (not Venice)

Low Grade Glioma (LGG)

Low grade glioma

RT has an important role

Progression is delayed, overall survival unchanged

- Timing of RT may be discussed with patient

In LGG neurological deficits may ***improve*** with RT

Low grade glioma

Late effects of RT on cognition unclear

Role of chemotherapy compared to RT has been evaluated in BR13– early results do not show an advantage for chemotherapy over RT

LGG - Timing of RT

CLINICAL INVESTIGATION **Brain**

RANDOMIZED TRIAL ON THE EFFICACY OF RADIOTHERAPY FOR CEREBRAL LOW-GRADE GLIOMA IN THE ADULT: EUROPEAN ORGANIZATION FOR RESEARCH AND TREATMENT OF CANCER STUDY 22845 WITH THE MEDICAL RESEARCH COUNCIL STUDY BRO4: AN INTERIM ANALYSIS

Early postoperative conventional RT improves the time to progression (progression-free survival)

Overall survival time ***same***

Karim AB et al. IJROBP 2002; 52(2): 316-24

ESTRO School

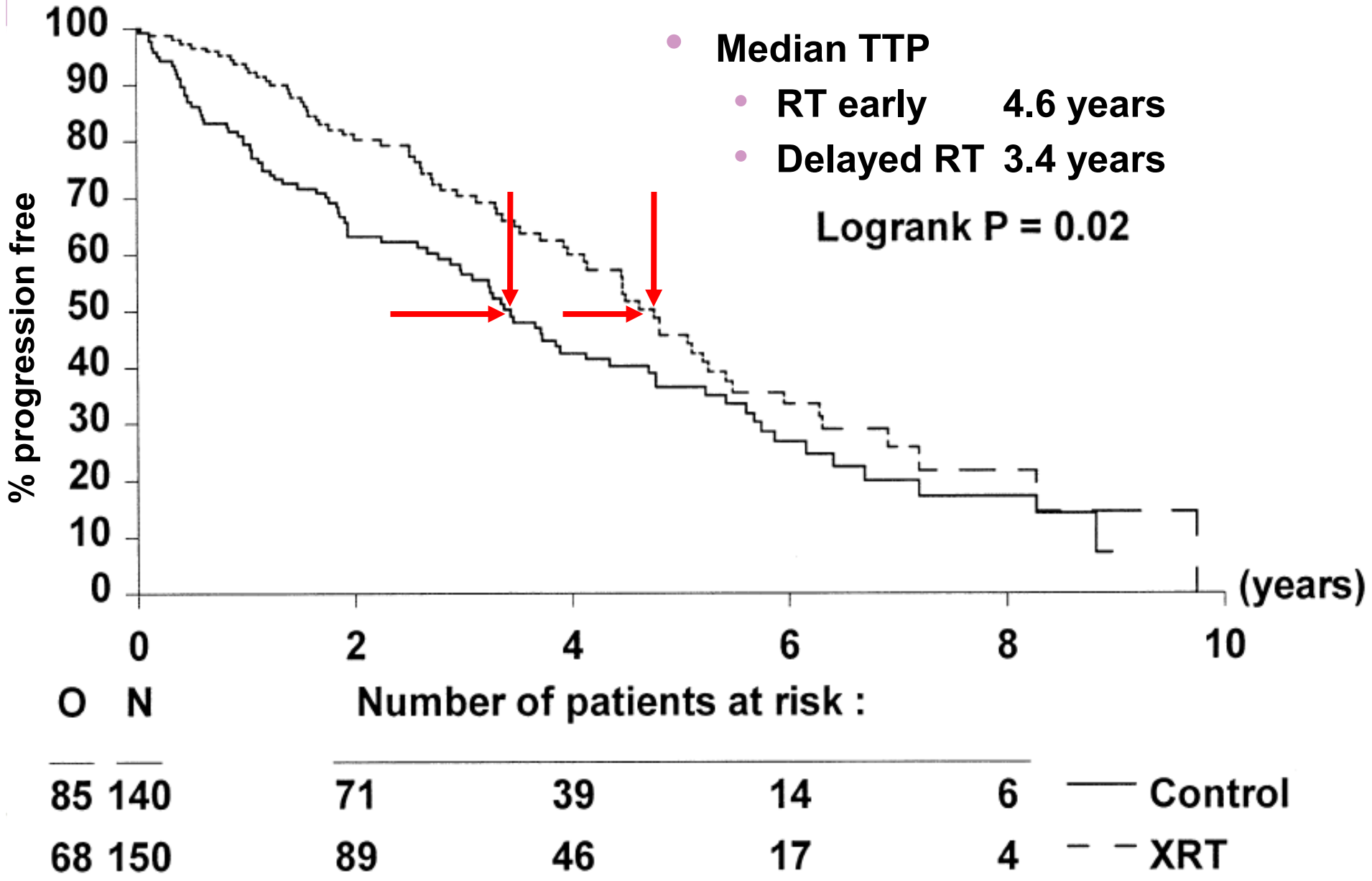
Median TTP
RT early 4.6 years
Delayed RT 3.4 years
Logrank P = 0.02
% progression free
100
90
80
70
60
50
40
30
20
10
0
0
2
4
6
8
10
(years)
O N
Number of patients at risk :
85 140 71 39 14 6 Control
68 150 89 46 17 4 XRT

LGG – RT dose

Dose of RT (EORTC 22844)

Randomised : 45 Gy : 59.4 Gy (@ 1.8 Gy/#)

5 year survival - *no* difference - 58% : 59%

Toxicity worse with 59.4 Gy

(Is this real, or a small study effect?)

Suggested doses

Single phase

Total dose : 45 Gy – 50.4 – 54 Gy – 59.6 Gy

25 – 28 – 30 – 33 #

LGG - GTV

Diffuse pattern of infiltration

Best shown on MRI, especially T2W or FLAIR

MRI shows lesion slightly larger than CT

Infiltrates into functioning brain (unlike HGG which is destructive)

True extent of tumour

Key slide

- Gliomas:
  - Grade II: Everything that is T2 hyperintense is tumour!

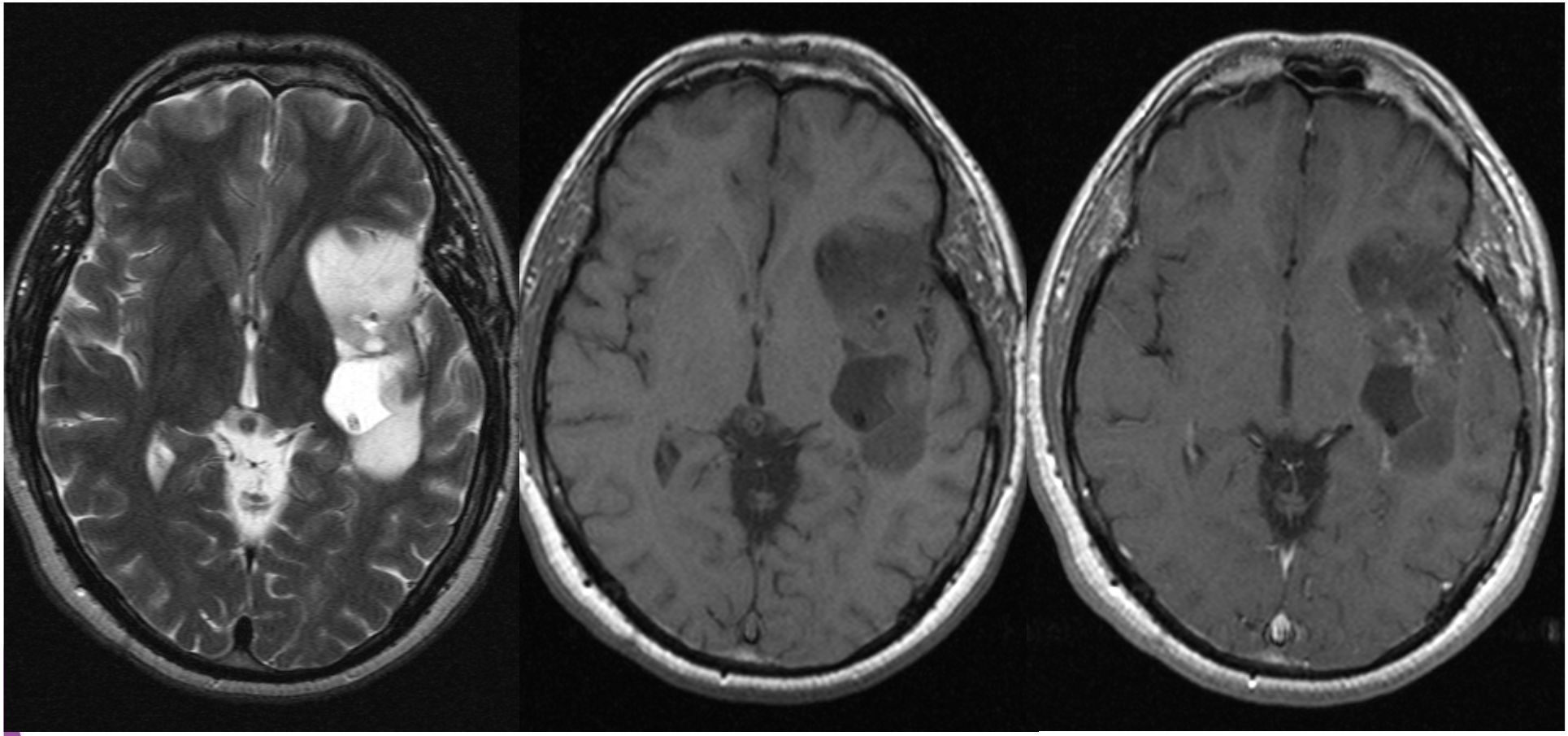

T2 T1 T1 + Gd

ESTRO School

Fibrillary Astrocytoma (WHO II)

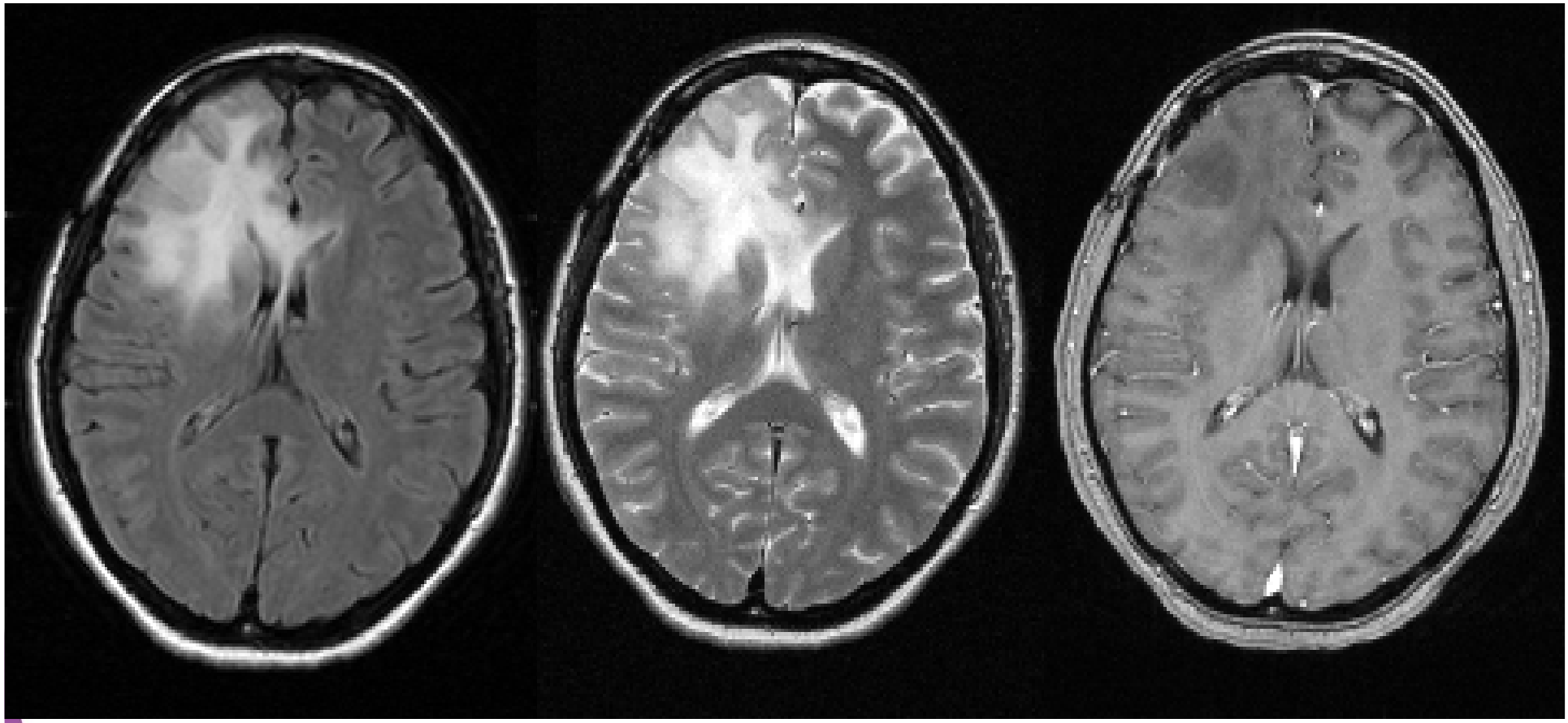

FLAIR T2 T1 + Gd

ESTRO School

Recurrence patterns

Pu et al, IJROBP 1995; 31(3): 461-466

11 patients

Tumour (GTV) defined as T2 signal abnormality

All recurred

All recurrences within GTV

Grade II oligodendroglioma

Calcification seen on CT

Little change due to rest of tumour

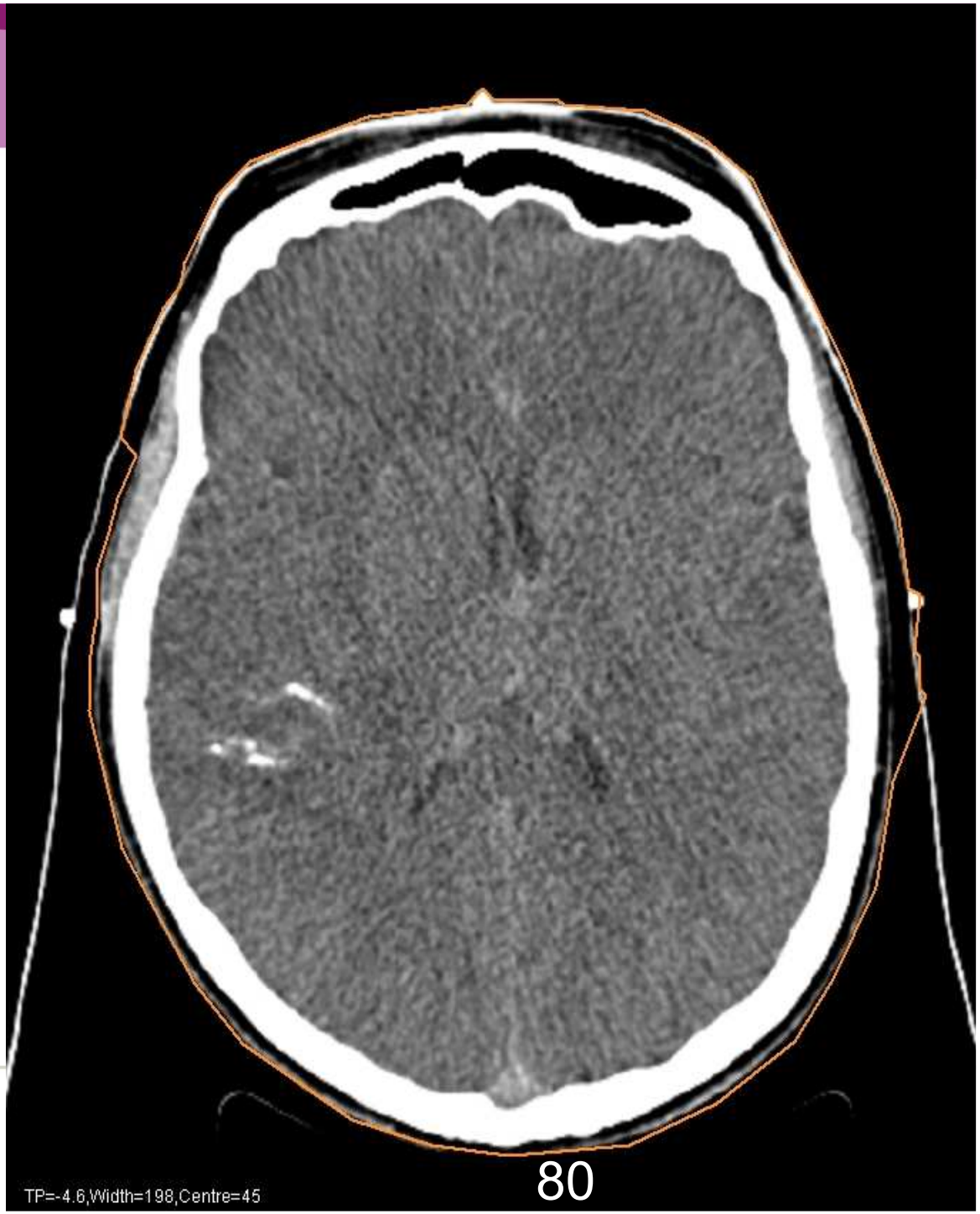

LGG

Whole tumour visible on MR

T2 (or FLAIR)

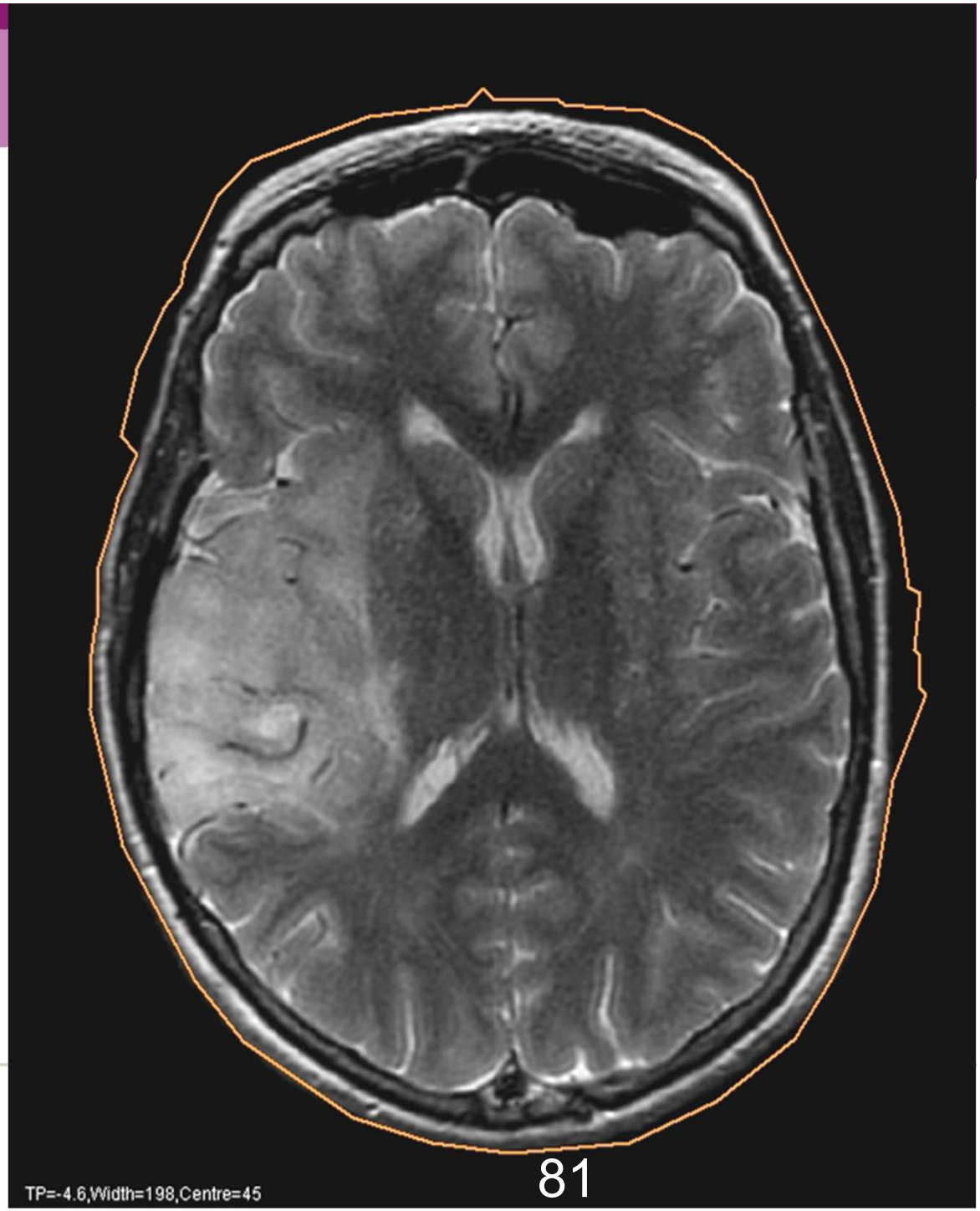

CT:MR

co-registered for planning

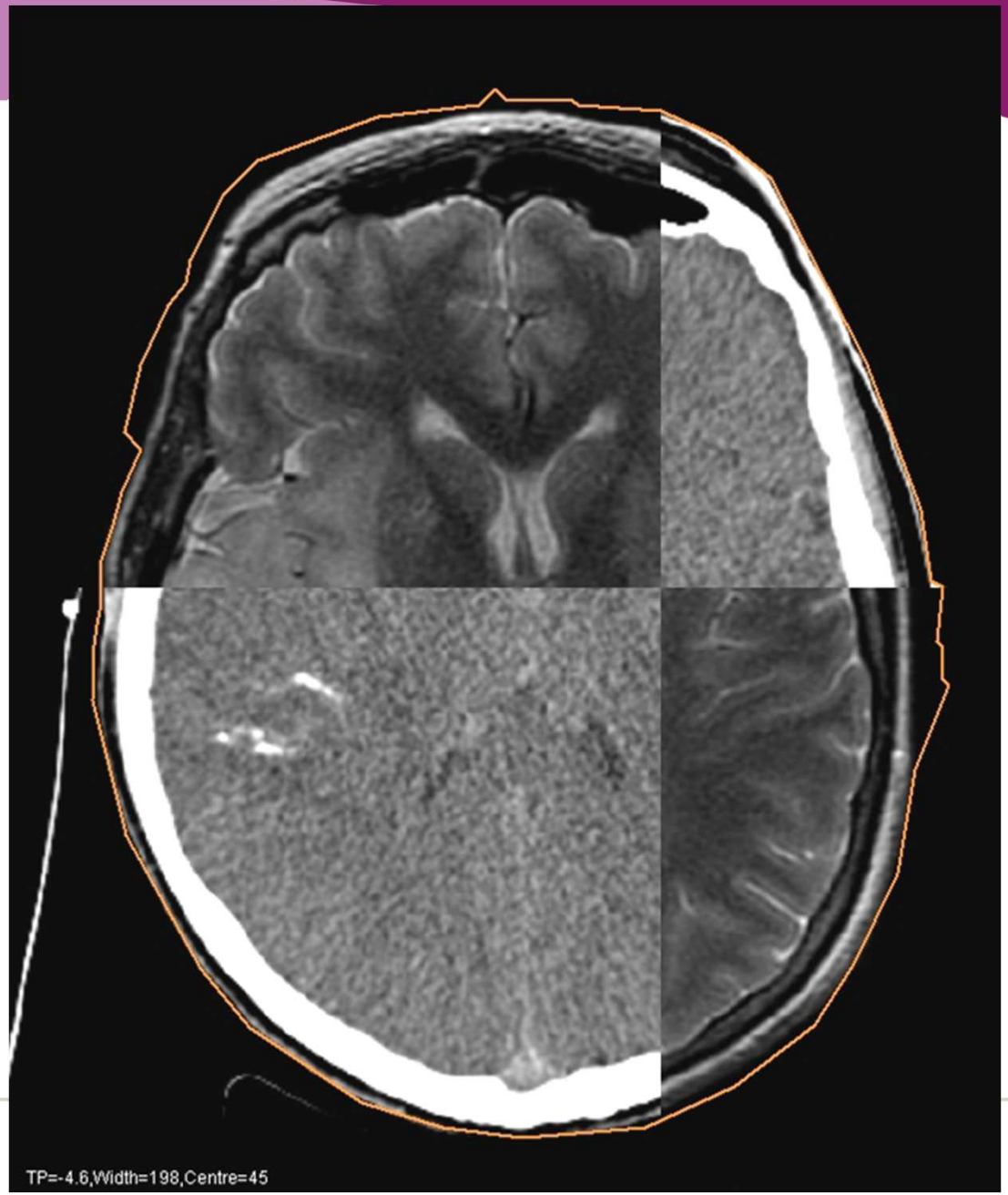

GTV defined as T2 abnormality

Some areas of edge still difficult to define

(deliberately not drawn exactly onto skull)

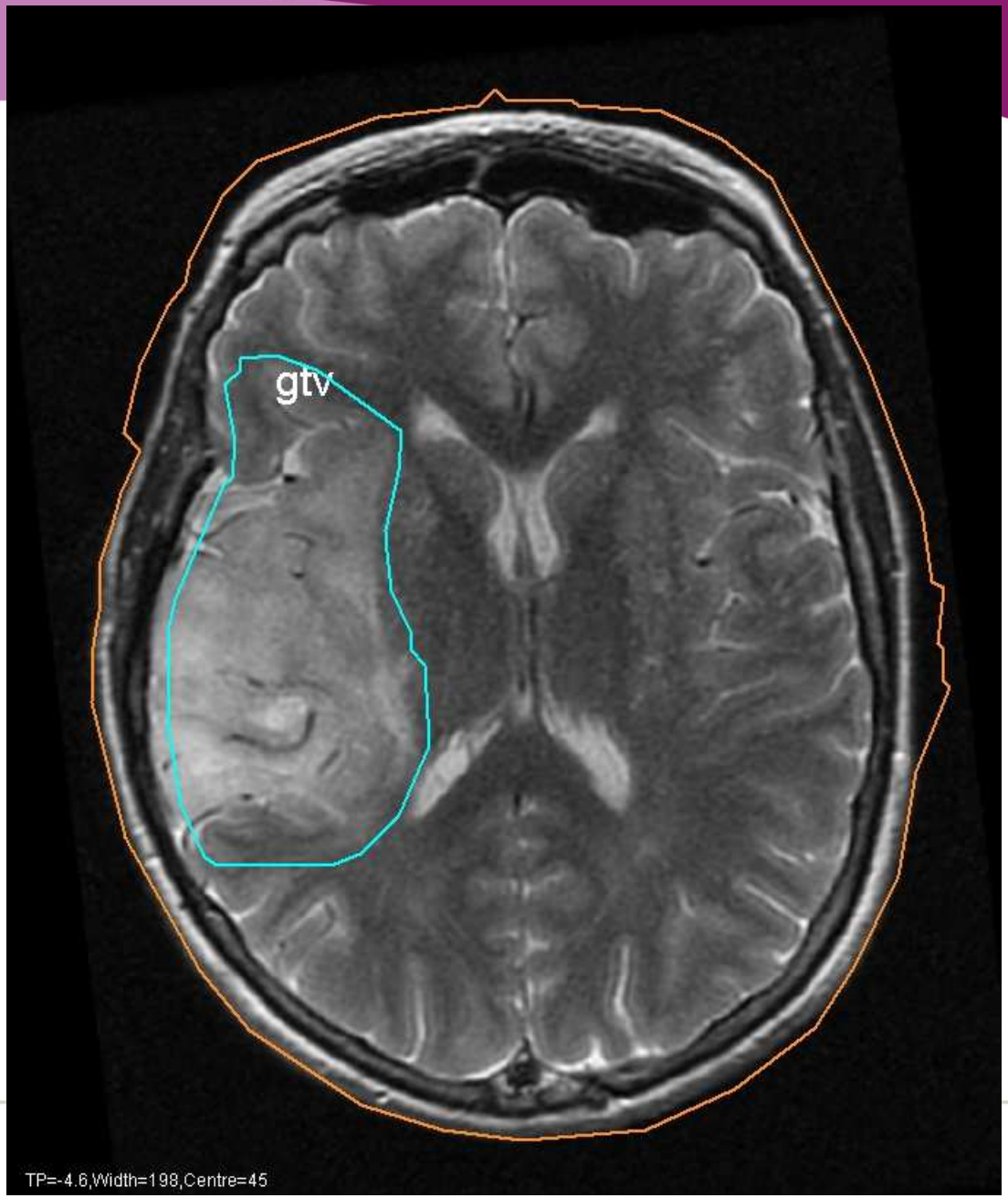

CTV added

Margin = 1.5 cm

Grown
isotropically,
up to skull

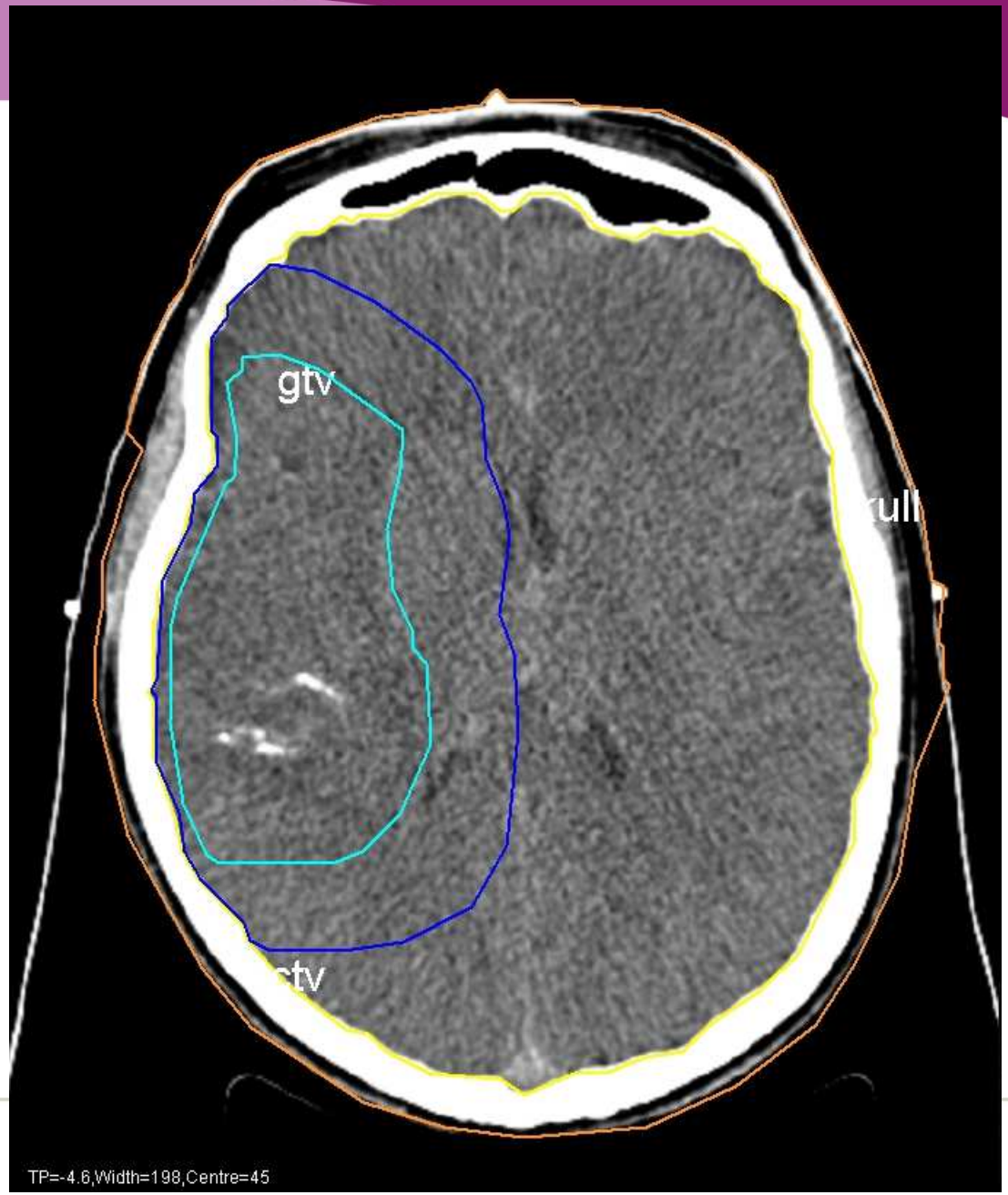

LGG – CTV Suggested margins

GTV = edge of low density on CT and/or high signal on T2W MRI/Flair

CTV = GTV plus 1.5 cm (1 - 2 cm)

Low grade gliomas

- GTV MR T2W/Flair
- CTV 1.5 cm
- PTV 0.3-0.5 cm

LGG cases

Deliver single phase

50.4-54 Gy/28-30# standard tumours

55 Gy/33# very large, brain stem

An example plan

- Excellent dose homogeneity
- Multiple OARs considered
- Generally good OAR sparing

1

Brainstem glioma – radiological grade II

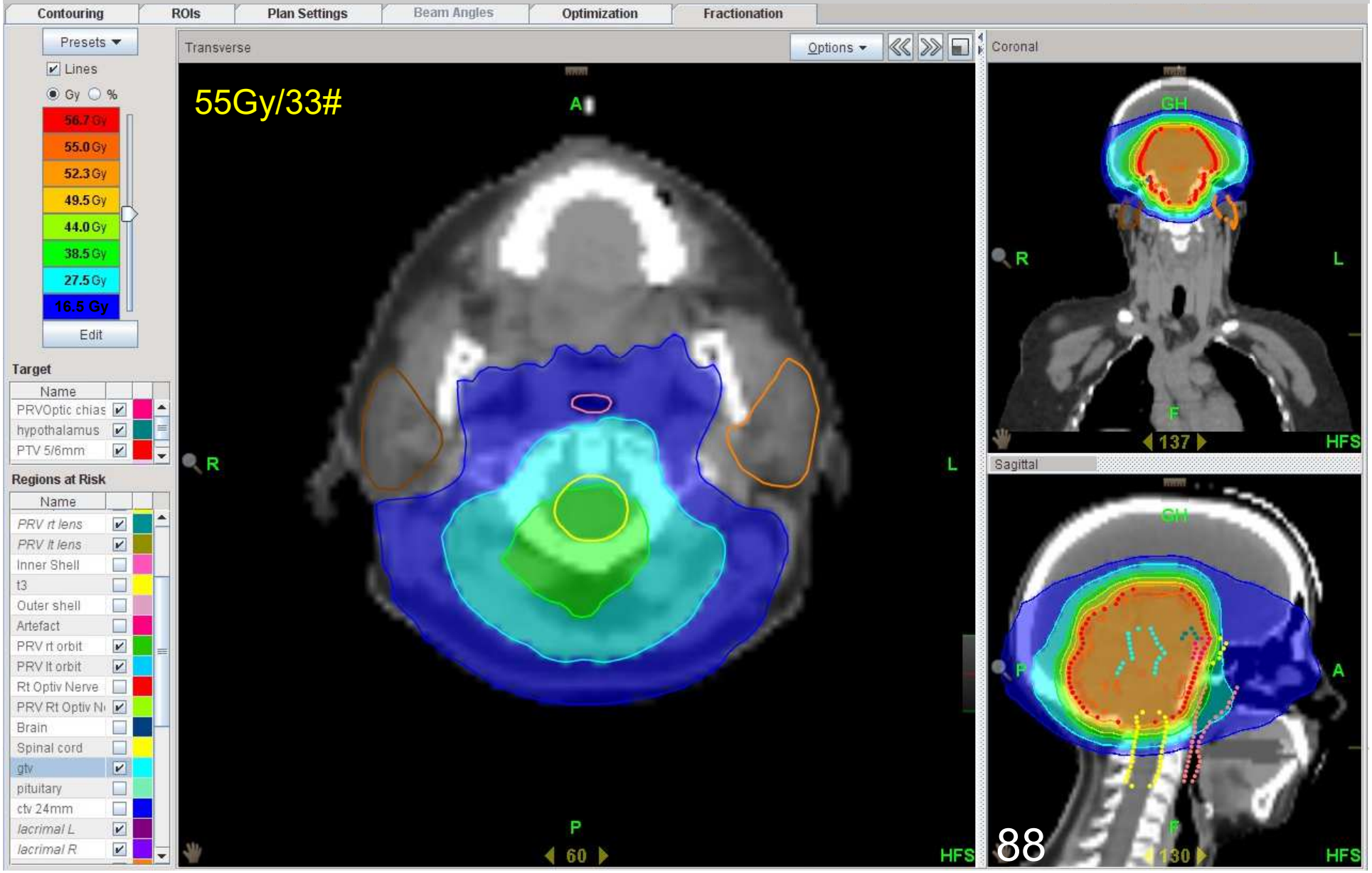

1

Brainstem glioma – radiological grade II

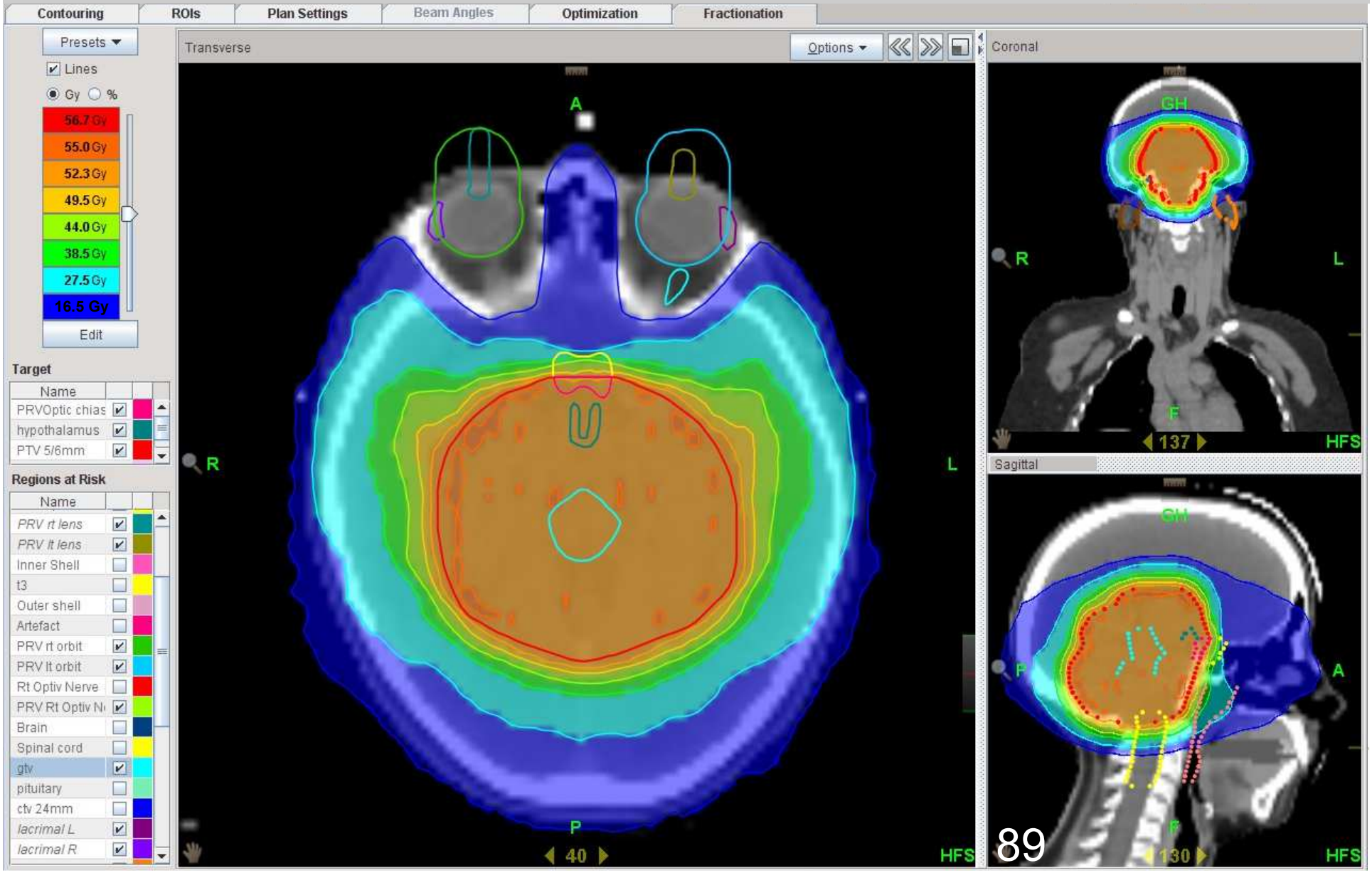

1

Brainstem glioma – radiological grade II

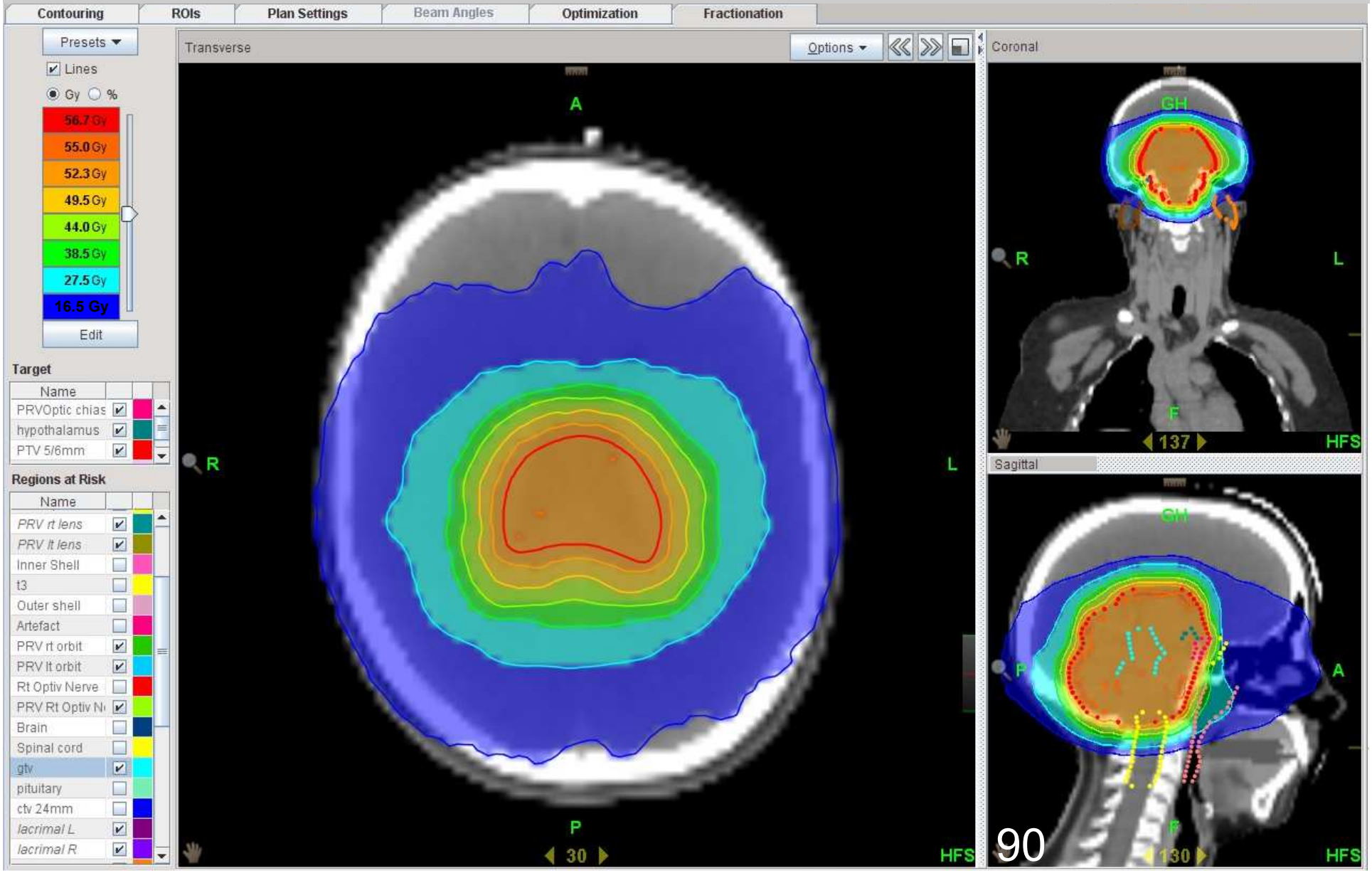

1

Brainstem glioma – radiological grade II

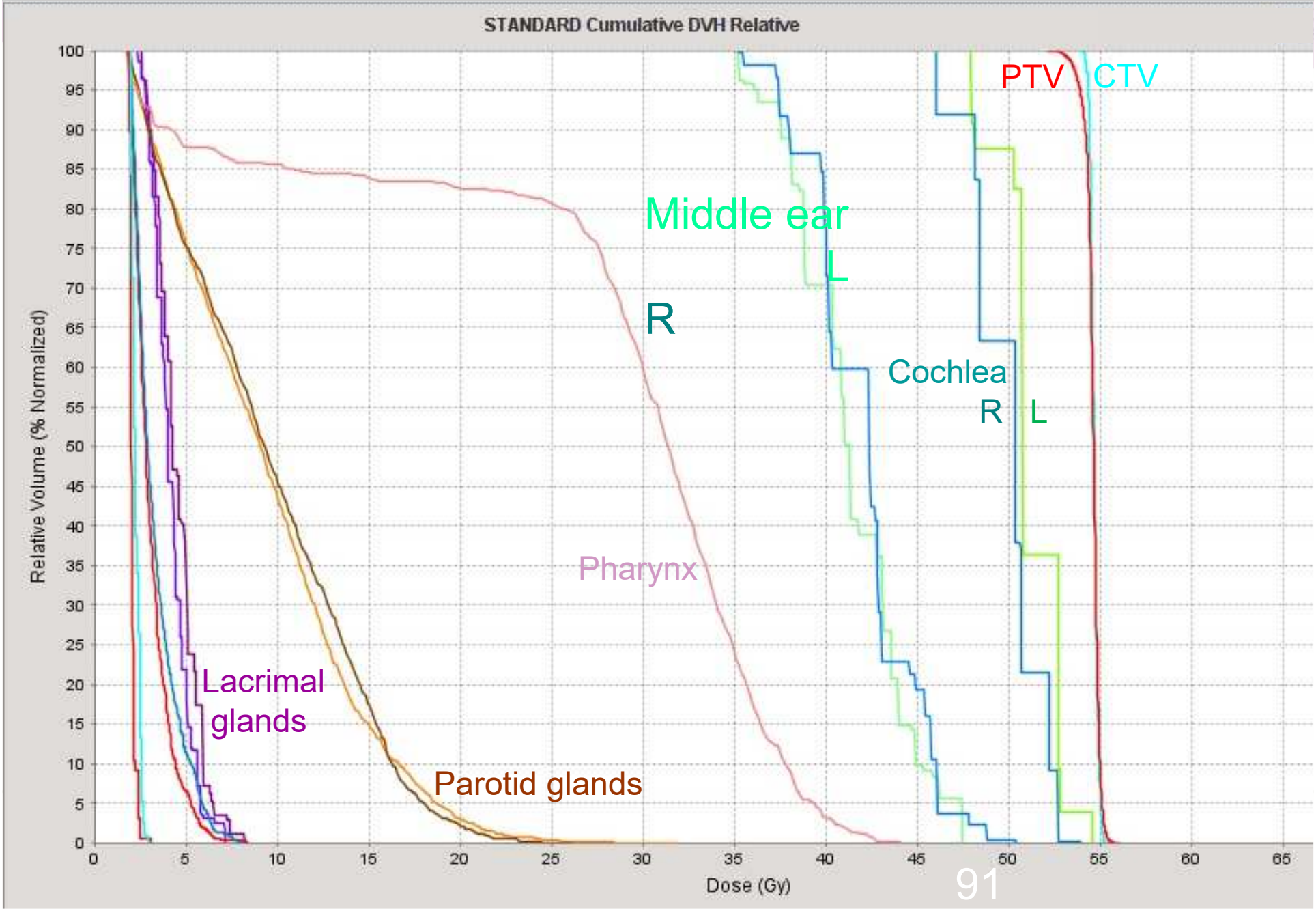

Normal tissue tolerance

ESTRO School

New Guidelines for OAR

Key slide

Click on Tools to convert files to PDF.

Radiotherapy and Oncology 114 (2015) 230–238

Contents lists available at ScienceDirect

Radiotherapy and Oncology

journal homepage: www.thegreenjournal.com

Dose constrains in brain

Organs at risk in the brain and their dose-constraints in adults and in children: A radiation oncologist's guide for delineation in everyday practice

Silvia Scoccianti [a,*], Beatrice Detti [a], Davide Gadda [b], Daniela Greto [a], Ilaria Furfaro [a], Fiammetta Meacci [a], Gabriele Simontacchi [a], Lucia Di Brina [a], Pierluigi Bonomo [a], Irene Giacomelli [a], Icro Meattini [a], Monica Mangoni [a], Sabrina Cappelli [a], Sara Cassani [a], Cinzia Talamonti [c], Lorenzo Bordi [d], Lorenzo Livi [a]

[a] Radiation Oncology; [b] Neuroradiology Unit; [c] Medical Physics; and [d] Neurosurgery, Azienda Universitaria Ospedaliera Careggi, Florence, Italy

Normal tissue tolerance limits RT doses

RT ‘tolerance’ depends on context

- What is an acceptable risk depends on the tumour
- Higher risk, from higher dose, is acceptable where risk of disease recurrence is high – like GBM

But

- As survival increases, same risk may be less acceptable

Optic nerve tolerance & risk

What is the tolerance of the optic pathway ?

Might tolerance be altered by concurrent TMZ ?

Optic nerve tolerance & risk

Emami 1991 – (blindness within 5 years)

Probably too conservative

5% risk 50 Gy **50%** risk 65 Gy

Mayo 2010 – for 2.0 Gy/#

50 Gy "**near zero**" incidence

55 – 60 Gy **3 – 7%** risk

(Tolerance ***might*** be lower with co-morbidity)

Emami B et al IJROBP 1991; 21: 109-122

Mayo C et al IJROBP 2010; 76(3 Suppl): S28–S35 (QUANTEC)

ESTRO School

Chemo + RT for GBM

Lancet Oncol 2009; 10: 459–66

Stupp et al.

~ 20% 3 year survival ~10% 5 year survival

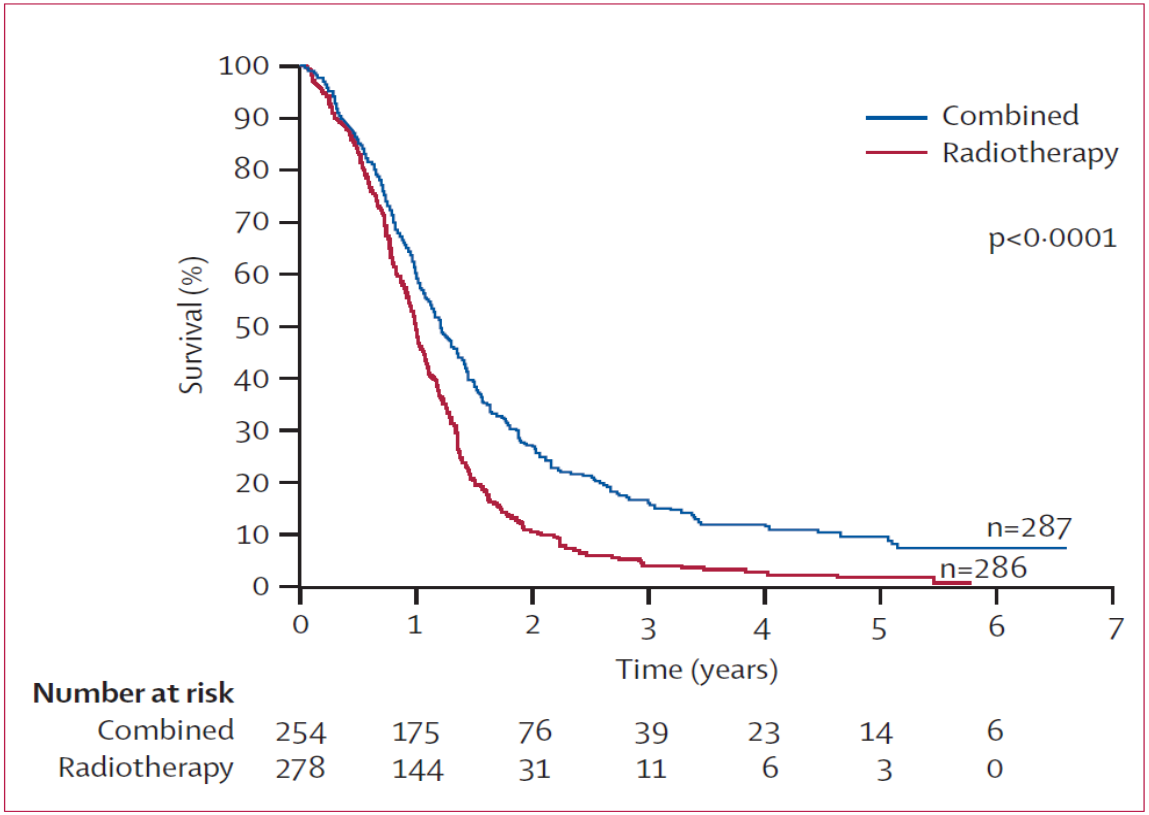

Figure 2: Kaplan-Meier estimates of overall survival by treatment group

ESTRO School

Optic nerve tolerance & risk

Stupp trial (Ataman EJC 2004)

The recommended maximum doses were below 55 Gy for the optic chiasm (and brainstem)

In QA on 53 cases; optic chiasm dose known in 48

Max dose > 55 Gy in 10/48 cases (i.e. ~ 20%)

Ataman Eur J Cancer 2004: 40: 1724-1730

ESTRO School

Optic nerve tolerance & risk

Stupp 2009 - risk with 55/60 Gy + TMZ

1 patient affected ~ 20% - dose assumed to be 60 Gy

~ 200 alive at risk at 9 months

~ 100 alive at risk at 2 years

~ 20 pts at risk

Therefore risk ~ 1 in 20 = 5%

But 17pts alive @ 5 years

Optic nerve tolerance & risk

Emami et al IJROBP 1991

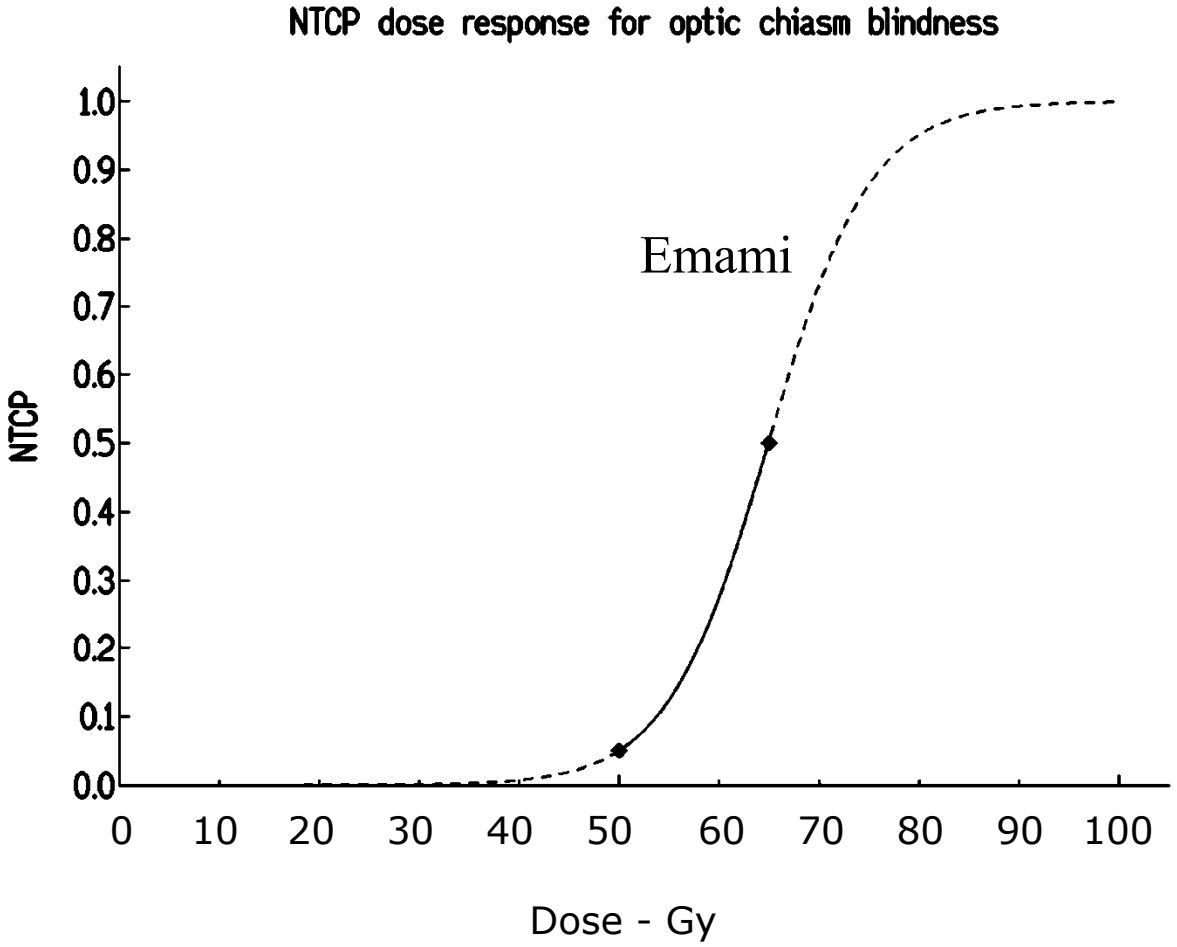

Optic nerve tolerance & risk

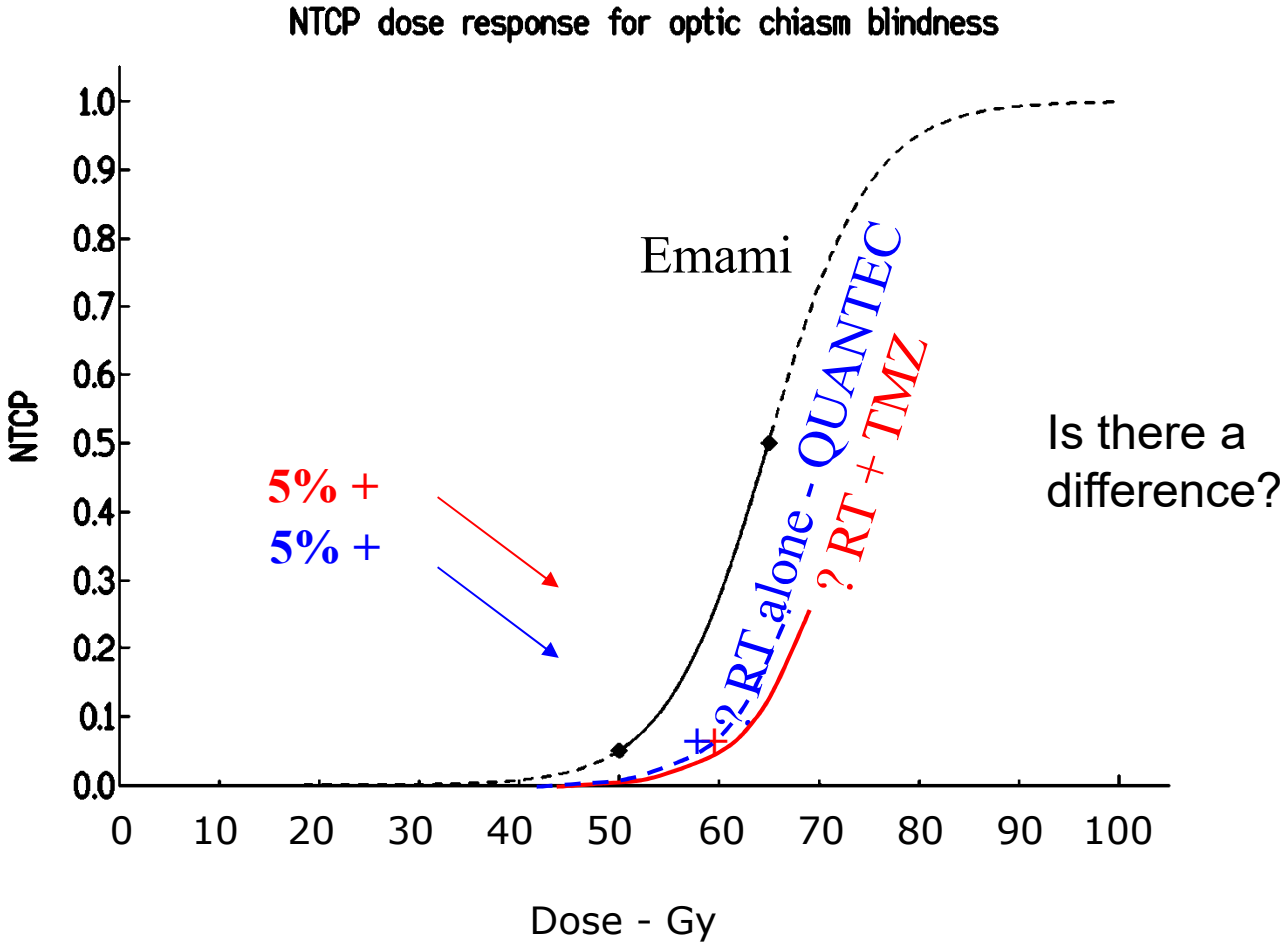

Optic nerve tolerance & risk

Comparing review with trial data suggests ***no*** increase in risk from the addition of TMZ to RT

Therefore the risk can be considered – recommended maximum doses

- Optic pathway – 55Gy
- Brainstem - 55Gy

In some cases higher doses can be considered

Thank you !

ESTRO School

Anal cancer: primary GTV, CTV, OARs

Maria Antonietta Gambacorta
Radiation Oncology Department
Fondazione Policlinico Universitario A. Gemelli

Gemelli ART Advanced Radiation Therapy

ESTRO School



Radiotherapy and Oncology
June 2014 111(3):330–339,

clinical practice guidelines

Annals of Oncology 00: 1–11, 2014
doi:10.1093/annonc/mdu159

Anal cancer: ESMO-ESSO-ESTRO Clinical Practice Guidelines for diagnosis, treatment and follow-up†

R. Glynne-Jones[1], P. J. Nilsson[2], C. Aschele[3], V. Goh[4], D. Peiffert[5], A. Cervantes[6] & D. Arnold[7*]

[1]*Centre for Cancer Treatment, Mount Vernon Hospital, Northwood, Middlesex, UK;* [2]*Department of Molecular Medicine and Surgery, Karolinska Institutet and Center for Surgical Gastroenterology, Karolinska University Hospital, Stockholm, Sweden;* [3]*Medical Oncology and Hematology, Felettino Hospital, La Spezia, Italy;* [4]*Division of Imaging Sciences and Biomedical Engineering, King's College London, London, UK;* [5] *Department of Radiotherapy, Centre Alexis Vautrin, Vandoeuvre-lès-Nancy, France;* [6]*Department of Hematology and Medical Oncology, INCLIVA, University of Valencia, Valencia, Spain;* [7]*Klinik für Tumorbiologie, Freiburg, Germany*

The anal canal extends from the anorectal junction to the anal margin

The columnar, or cylindric, epithelium of the rectum extends to about 1 cm above the dentate line where the anal transitional zone begins.

Below the dentate line the **epithelium is all squamous**

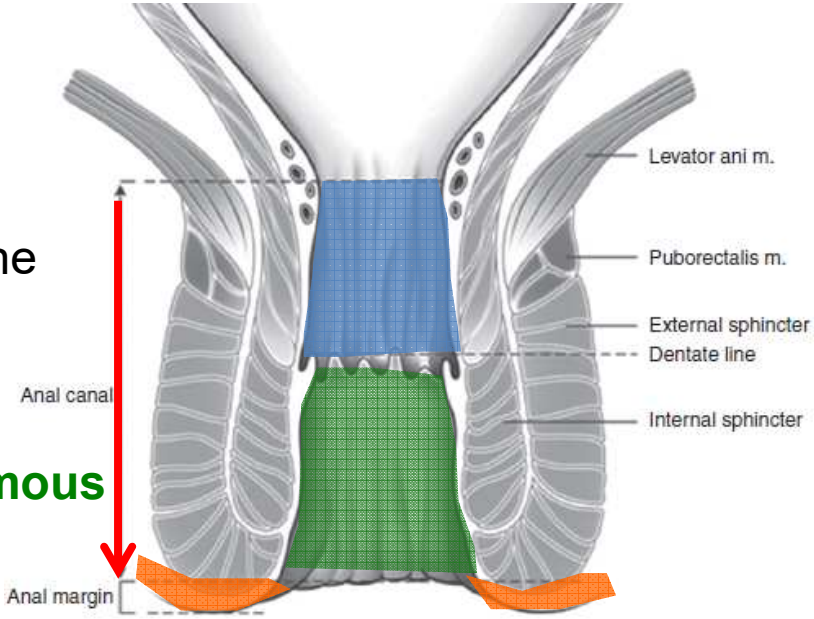

The anal margin is the pigmented **skin** immediately surrounding the anal orifice, extending laterally to a radius of approximately **5 cm.**

LYMPHATIC PATHWAYS

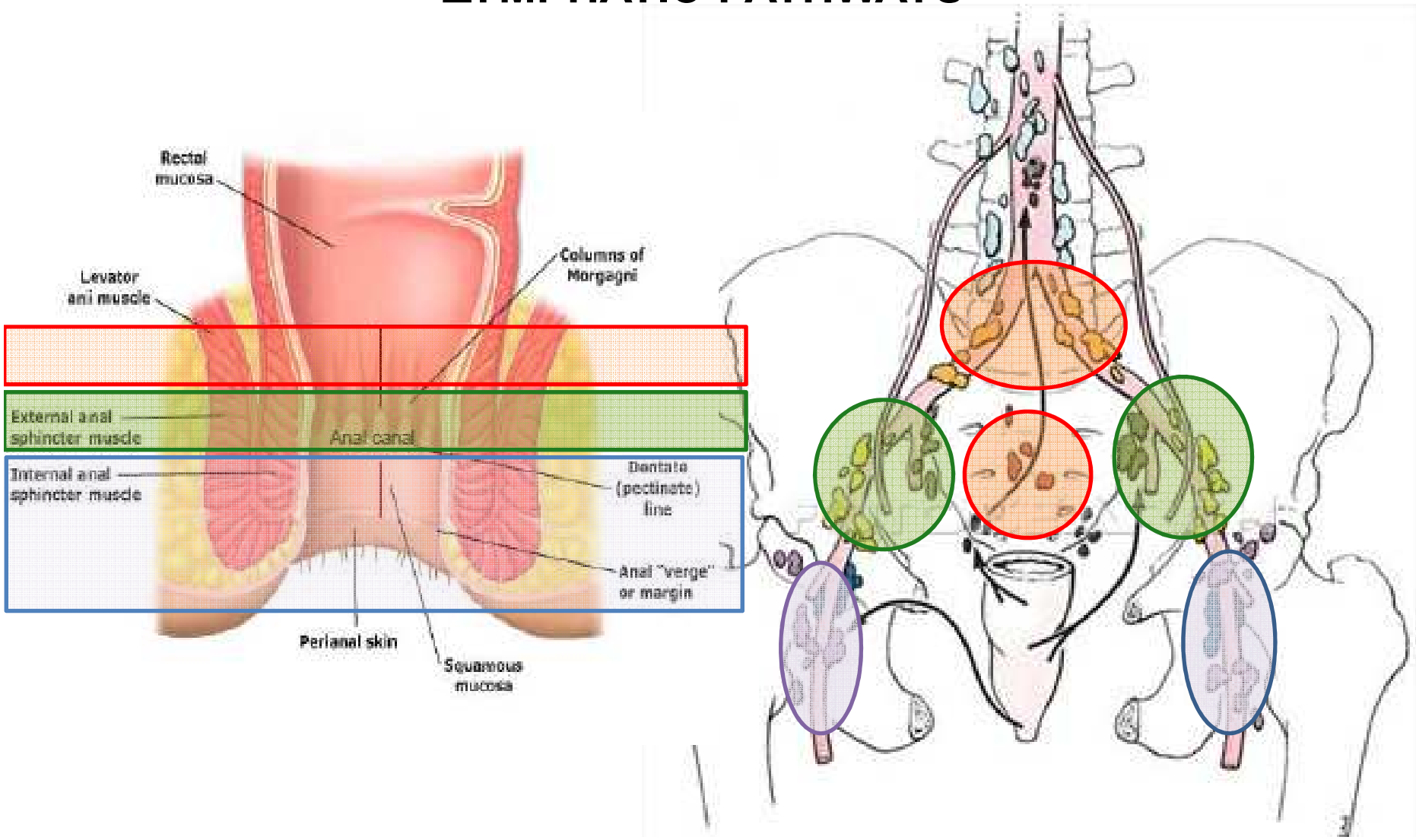

Perirectal, superior hemorroidal and inferior mesenteric nodes

Internal pudendal, hypogastric and obturator nodes

Inguinal, femoral and external iliac nodes

The overall risk of **regional nodal involvement** at diagnosis is about **25%**.

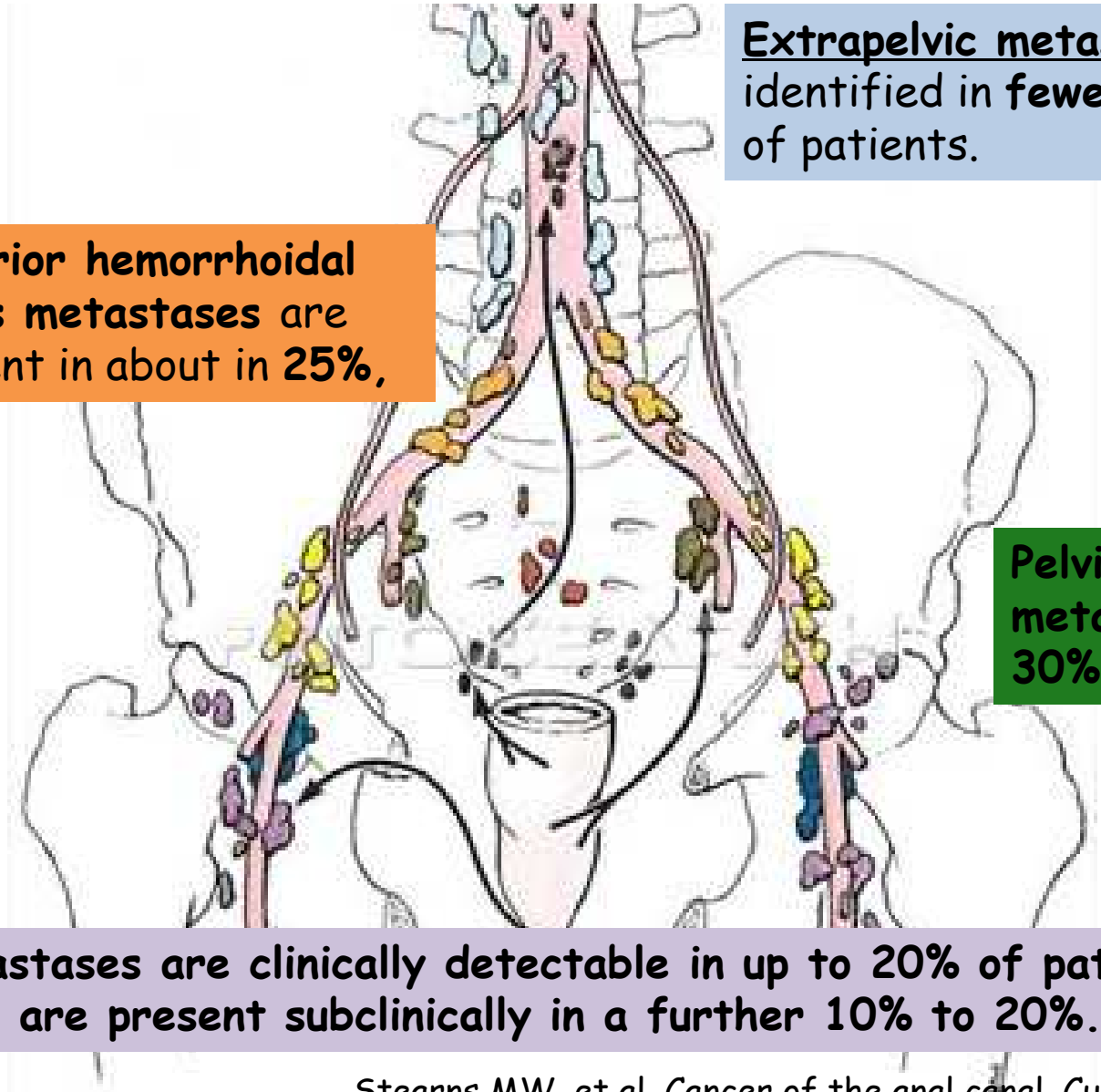

Extrapelvic metastases are identified in **fewer than 10%** of patients.

Superior hemorrhoidal nodes metastases are present in about in **25%,**

Pelvic nodes metastases in **30%**

Inguinal metastases are clinically detectable in up to 20% of patients at initial diagnosis and are present subclinically in a further 10% to 20%.

Stearns MW, et al. Cancer of the anal canal. Curr Probl Cancer 1980

The finding in surgical series of histopathologically verified metastases in the **pararectal and internal iliac nodes in up to 30%** and in **inguinal nodes in up to 20%** has encouraged most centers to irradiate these node groups electively.

As a result, planning target volumes may be extensive.

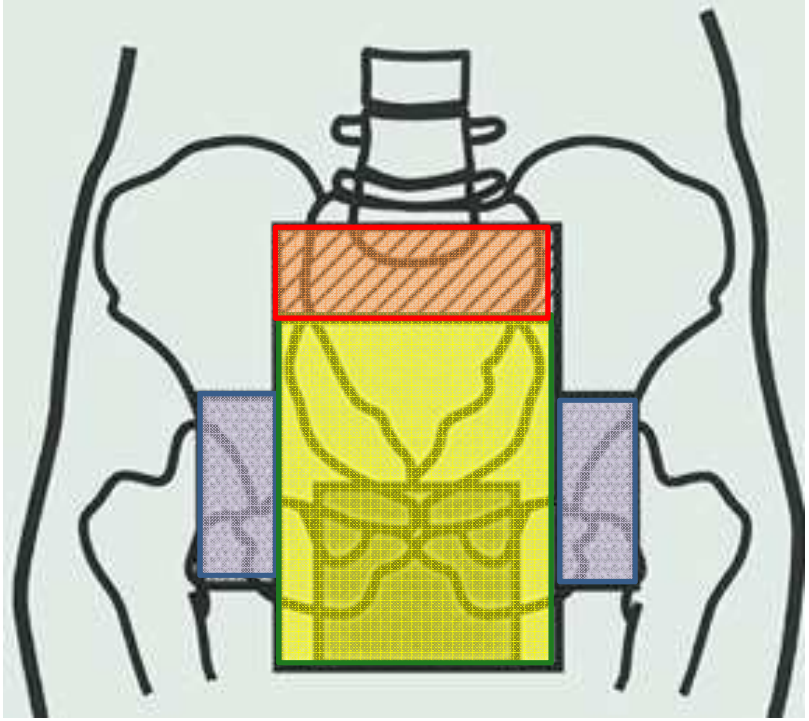

Only well-differentiated squamous cell cancers **<2 cm** in size situated in the distal canal appear to have a **risk of nodal metastases <5%.**

PATTERNS OF RECURRENCE

180 SCCAC patients, retrospectively reviewed
(173 patients mitomycin-based CHT-RT)
January 1990 - March 2007
Memorial Sloan-Kettering Cancer Center
Median primary tumor dose = **45 Gy**
3-year LRF = 23%.

78% local failure
56% had local-only failure

22% had both local and regional failure

44% regional failure
22% had regional-only failure.

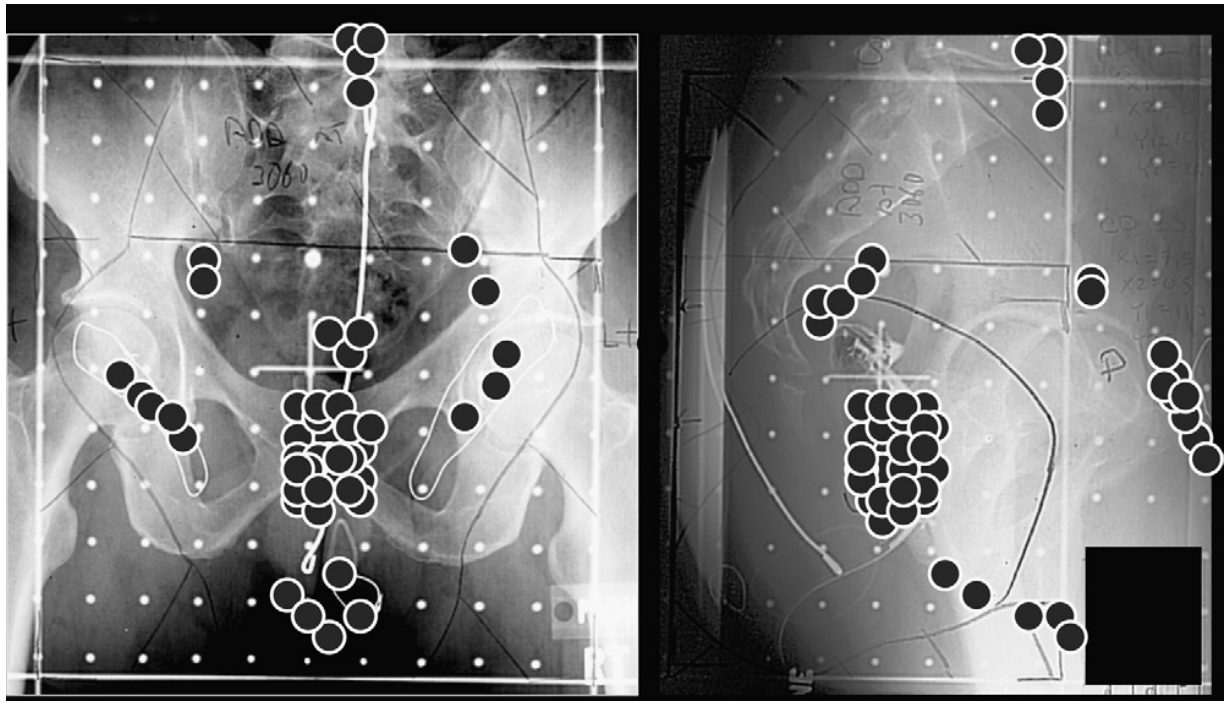

J. L. Wright et al, Int. J. Radiation Oncology Biol. Phys. 2010

PATTERNS OF RECURRENCE

167 SCCAC patients CHT-RT

September 1992 and August 2004
M. D. Anderson Cancer Center

Median primary tumor dose = **55 Gy**
LRF=14%
estimated 3-year LRC = 81%.

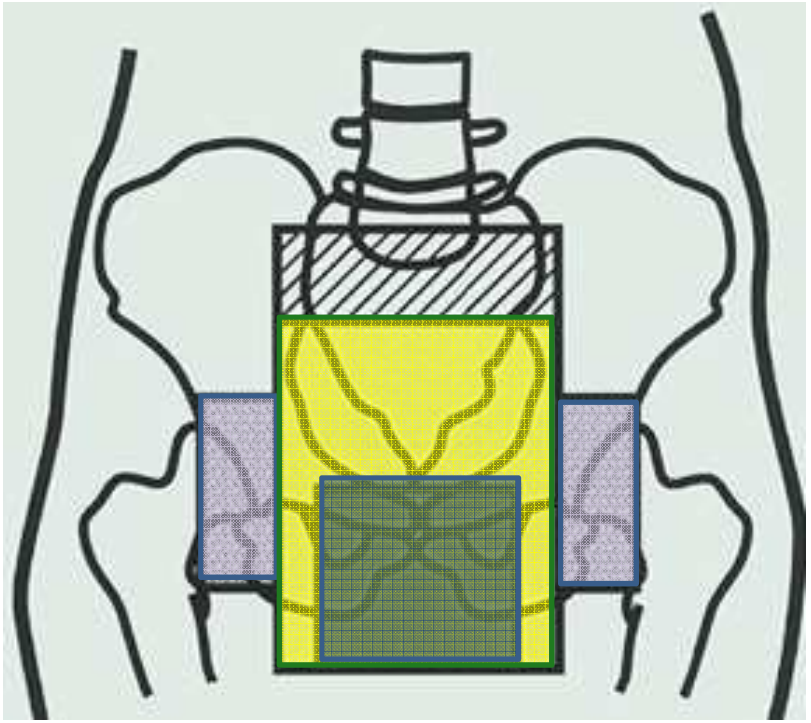

Site	Number of failures (%)
Anus/rectum	18 (75)
Presacral/iliac	5 (21)
Inguinal	1 (4)

P. Das et al, Int. J. Radiation Oncology Biol. Phys. 2007

Critical issues: inguinal nodes

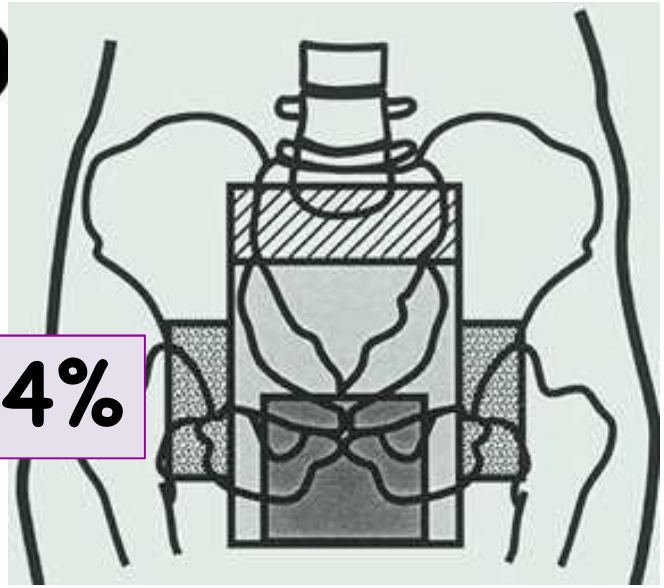

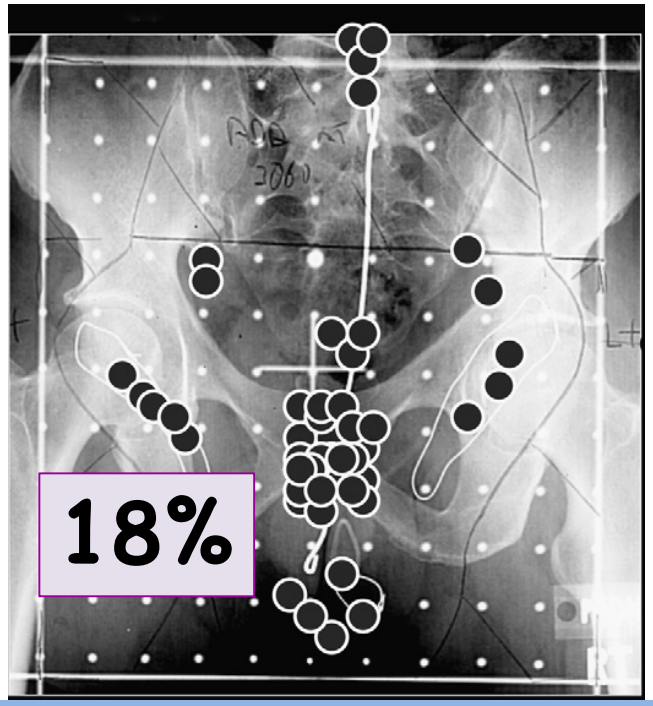

This difference may be related to the higher dose delivered to **involved inguinal nodes** in study of Das P. et al **55 Gy** vs the prescribed dose to the inguinal nodes in all inguinal failures in the study of Wright et al. was **45 Gy**.

J. L. Wright et al, Int. J. Radiation Oncology Biol. Phys. 2010

P. Das et al, Int. J. Radiation Oncology Biol. Phys. 2007

PROPHYLACTIC INGUINAL IRRADIATION

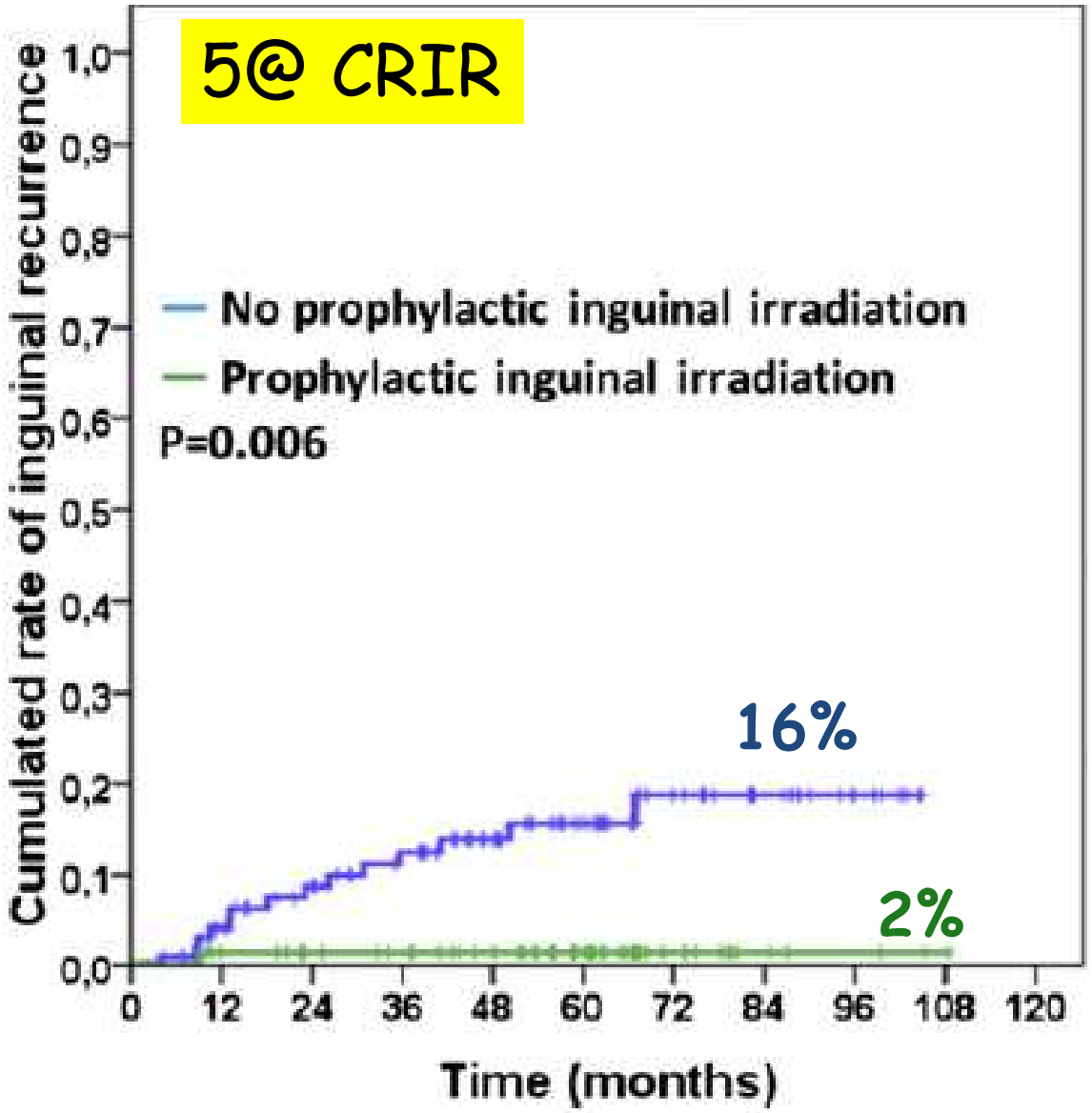

In the PII group 5-year CRIR was significantly lower (p= 0.006)

In the PII group, no Grade >2 toxicity of the lower extremity was observed

In the **no PII group**, the 5-year CRIR was **12%** and **30%** for **T1-T2** and **T3-T4** respectively (p = 0.02).

In the **PII group**, the 5-year CRIR was not different in **T1-2 vs T3-4 (0% vs 3%)**

PII didn't affect OS and DFS

C. ORTHOLAN et al. Int. J. Radiation Oncology Biol. Phys., 2012

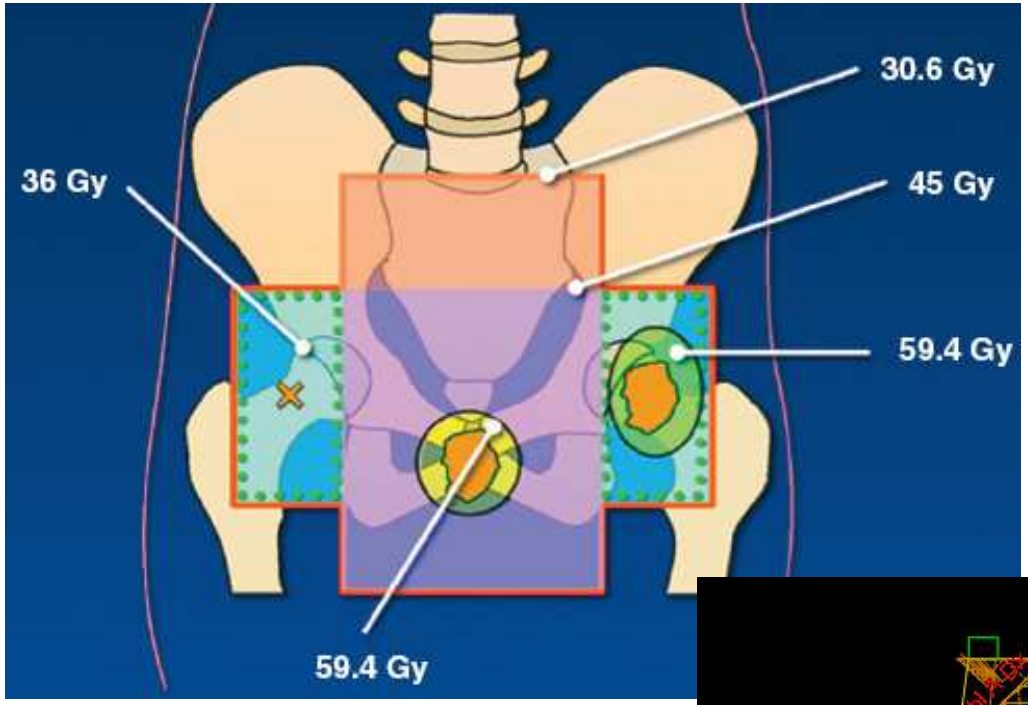

With the advent of CT-planning and conformal radiation techniques including **IMRT**, comes the **prerequisite** for **accurate and consistent contouring of target volumes.**

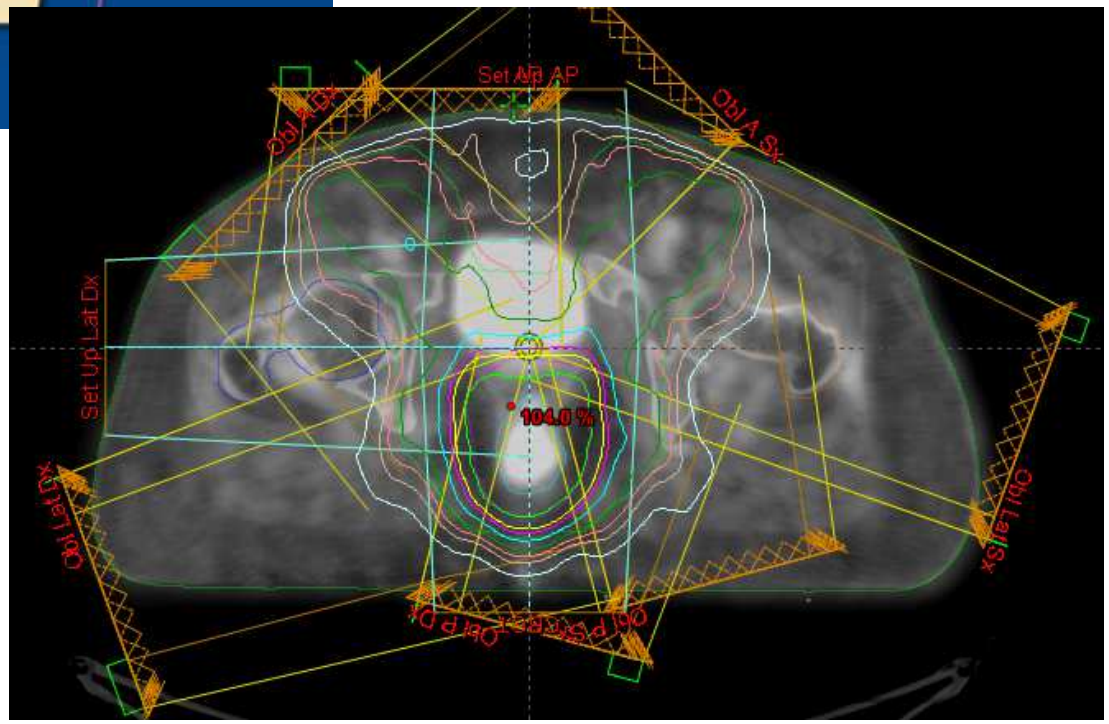

Clinical Investigation: Gastrointestinal Cancer

RTOG 0529: A Phase 2 Evaluation of Dose-Painted Intensity Modulated Radiation Therapy in Combination With 5-Fluorouracil and Mitomycin-C for the Reduction of Acute Morbidity in Carcinoma of the Anal Canal

Kachnic LA, Winter K, Myerson RJ, et al. Int J Radiat Oncol Biol Phys. 2013

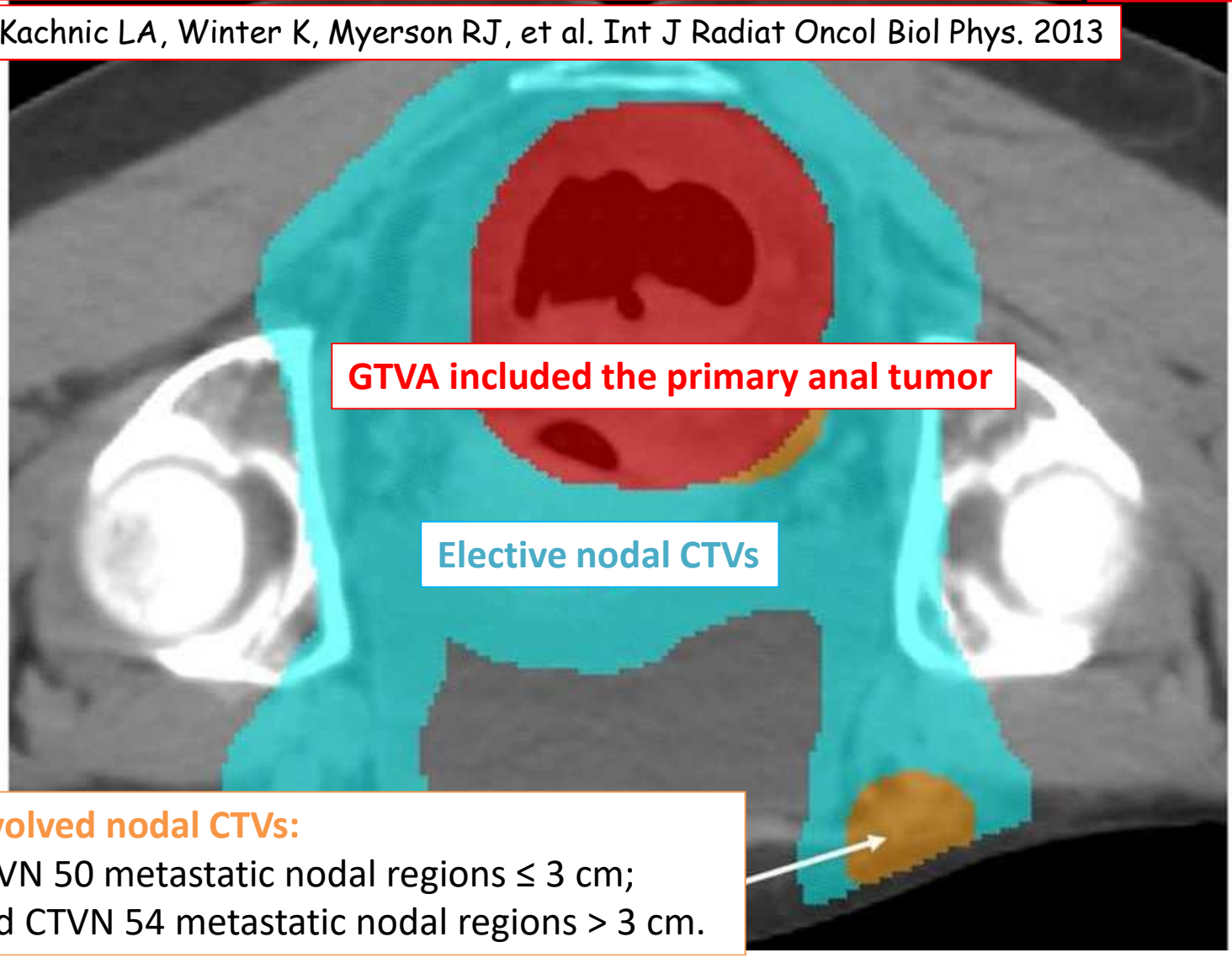

Involved nodal CTVs:

CTVN 50 metastatic nodal regions ≤ 3 cm;
and CTVN 54 metastatic nodal regions > 3 cm.

Clinical Investigation: Gastrointestinal Cancer

RTOG 0529: A Phase 2 Evaluation of Dose-Painted Intensity Modulated Radiation Therapy in Combination With 5-Fluorouracil and Mitomycin-C for the Reduction of Acute Morbidity in Carcinoma of the Anal Canal

Kachnic LA, Winter K, Myerson RJ, et al. Int J Radiat Oncol Biol Phys. 2013

Radiation Planning Quali

Of the 52 DP-
submission. 4
investigator c
of elective noc
nodal groups
bowel 45%). E
normal tissue
dosing, and 39
coverage. On
dosing, and or
who did not at
reproducible i

n initial
assed. Incorrect
), miscontouring
33%, iliac
el 60%, large
ption and
ent for tumor
femoral head
cerning target
investigators
s considered

Incorrect contouring (81%)

GTV: 21%

CTV elective N:

Mesorectum	55%
Presacrum	43%
Inguinal fossa	33%
Iliac nodes	31%

CLINICAL INVESTIGATION Rectum

ELECTIVE CLINICAL TARGET VOLUMES FOR CONFORMAL THERAPY IN ANORECTAL CANCER: A RADIATION THERAPY ONCOLOGY GROUP CONSENSUS PANEL CONTOURING ATLAS

Elective nodal CTVs

CTVA: internal iliac, pre-sacral, peri-rectal.
CTVB: external iliac nodal region
CTVC: inguinal nodal region

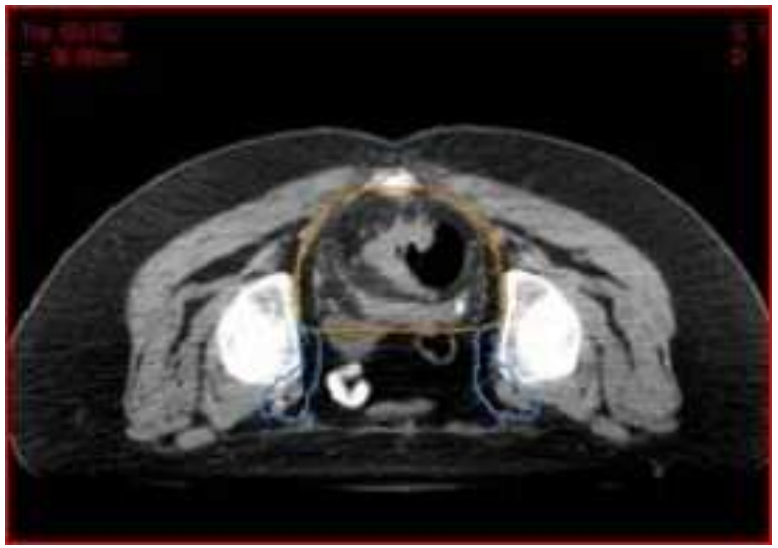

LIMITATIONS:
no clear definition of the different anatomical boundaries

Myerson RJ, Garofalo MC, El Naqa I, et al. Int J Radiat Oncol Biol Phys. 2009

CLINICAL INVESTIGATION Rectum

ELECTIVE CLINICAL TARGET VOLUMES FOR CONFORMAL THERAPY IN ANORECTAL CANCER: A RADIATION THERAPY ONCOLOGY GROUP CONSENSUS PANEL CONTOURING ATLAS

CTVA: internal iliac, pre-sacral, peri-rectal

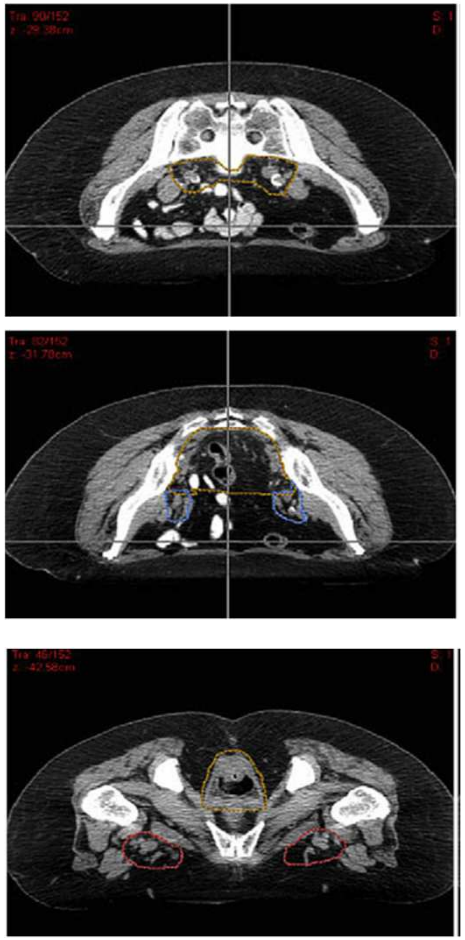

Cranial:

- Bifurcation of the common iliac vessels into external/internal iliacs (bony landmark: sacral promontory)
- Recto-sigmoid junction

Anterior:

- 1 cm anterior to the sacrum
- Perirectal fascia
- **1 cm into the bladder**
- Pelvic organs

sup

inf

Lateral and posterior:

- Pelvic side-wall muscles or bones

Caudal: for anal cancer

Anal canal + 2 cm around, the anal verge

Anal skin involved + 2 cm beyond

Myerson RJ, Garofalo MC, El Naqa I, et al. Int J Radiat Oncol Biol Phys. 2009

CLINICAL INVESTIGATION Rectum

ELECTIVE CLINICAL TARGET VOLUMES FOR CONFORMAL THERAPY IN ANORECTAL CANCER: A RADIATION THERAPY ONCOLOGY GROUP CONSENSUS PANEL CONTOURING ATLAS

CTVB: external iliac nodal region

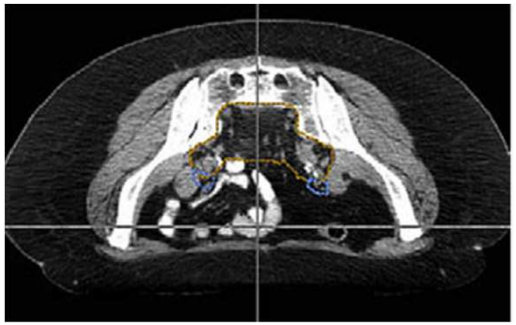

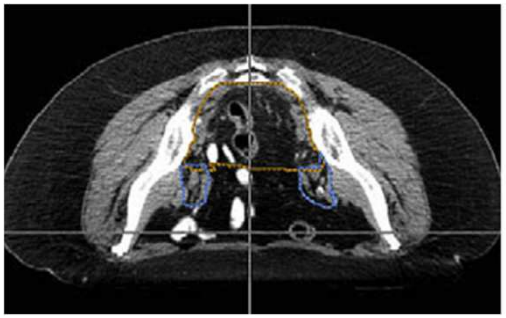

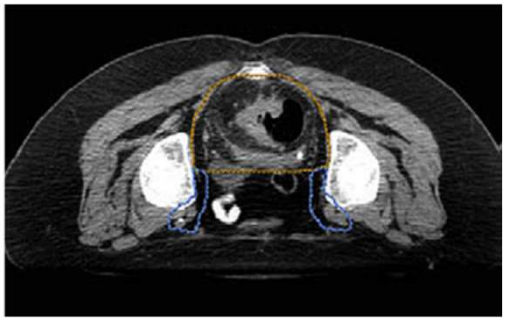

Cranial:

Bifurcation of the common iliac vessels into external/internal iliacs

(bony landmark: sacral promontory)

Anterior-medial:

0.7-0.8 cm around the vessels

≥1 cm antero-laterally in case of small vessels or nodes are identified in this area

Lateral:

Muscles and pelvic bones

Posterior:

CTVA

Caudal: caudad edge of internal obturator vessels

(bony landmark: **upper edge of the superior rami pubic)**

Myerson RJ, Garofalo MC, El Naqa I, et al. Int J Radiat Oncol Biol Phys. 2009

CLINICAL INVESTIGATION Rectum

ELECTIVE CLINICAL TARGET VOLUMES FOR CONFORMAL THERAPY IN ANORECTAL CANCER: A RADIATION THERAPY ONCOLOGY GROUP CONSENSUS PANEL CONTOURING ATLAS

CTVC: inguinal nodal region

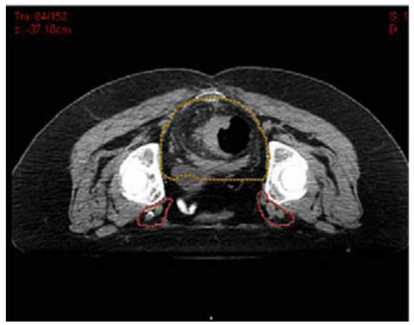

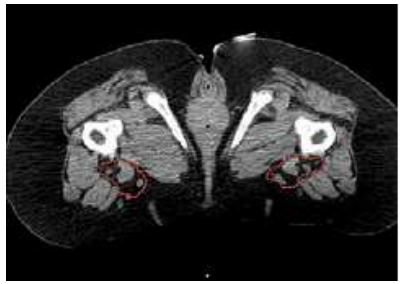

Cranial:

caudad edge of internal obturator vessels (bony landmark: upper edge of the superior rami pubic)

Caudal:

2 cm below the saphenous-femural junction

Margin around the vessels:

The inguinal femural region should be contoured as a compartment with any identified nodes (expecially in the lateral inguinal region) included

IF AUTOMATED EXPANSION ARE USED, THE CTV SHOULD BE TRIMMED OFF UNINVOLVED BONE AND MUSCLES

Myerson RJ, Garofalo MC, El Naqa I, et al. Int J Radiat Oncol Biol Phys. 2009

Clinical Investigation: Gastrointestinal Cancer

Australasian Gastrointestinal Trials Group (AGITG) Contouring Atlas and Planning Guidelines for Intensity-Modulated Radiotherapy in Anal Cancer

M. Ng, et al. (AGITG) Int J Radiation Oncol Biol Phys, 2012

ELECTIVE NODAL VOLUMES

mesorectum

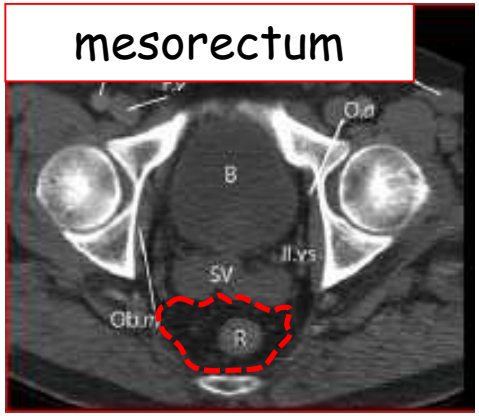

presacral space

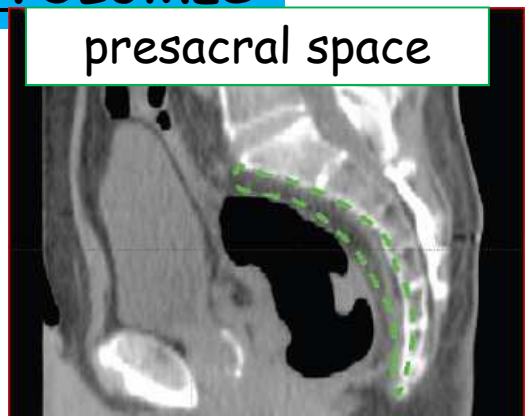

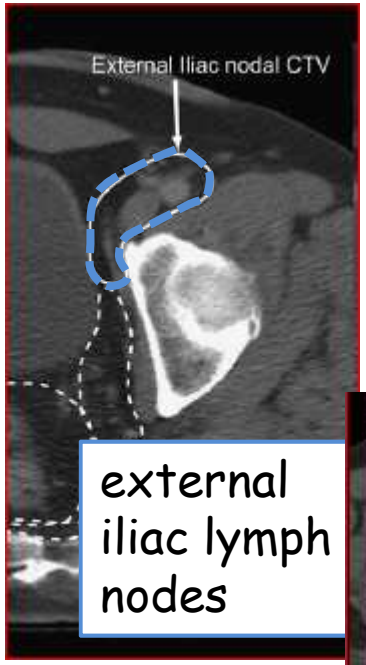

external iliac lymph nodes

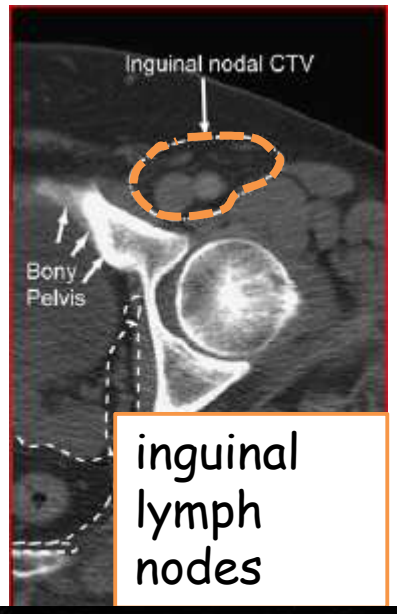

inguinal lymph nodes

ischiorectal fossa

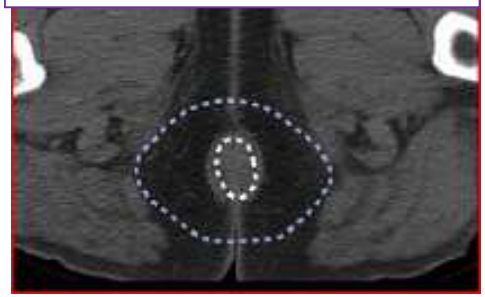

internal iliac lymph nodes

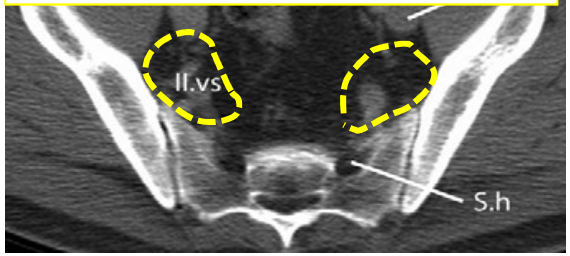

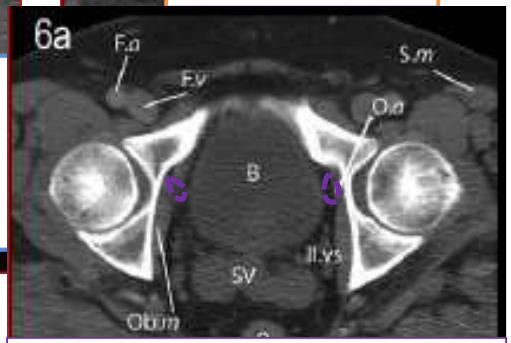

obturator lymph nodes

CTV borders for individual nodal groups

PRESACRAL SPACE

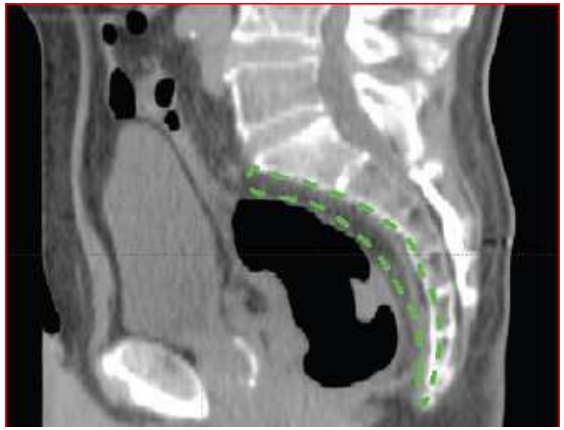

Cranial: The sacral promontory.

Caudal: The inferior edge of the coccyx

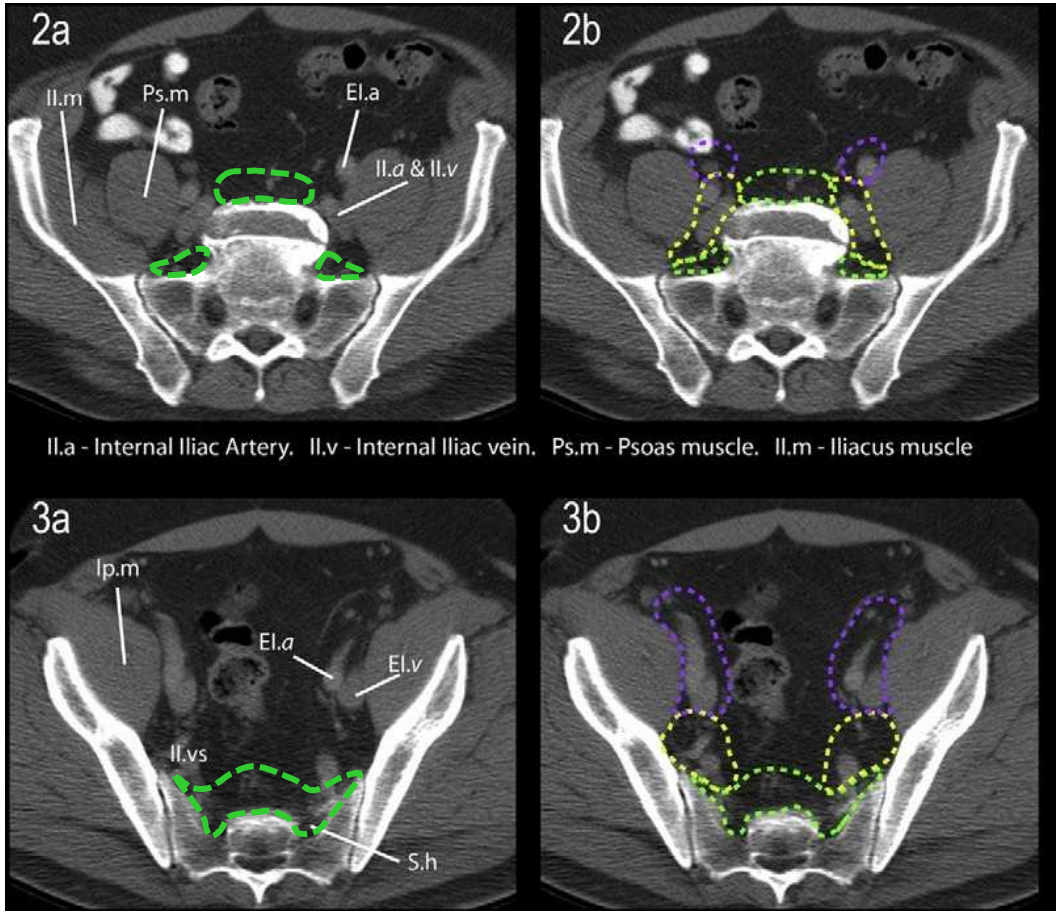

Lateral: The sacro-iliac joints.

Anterior: 10 mm anterior to the anterior sacral border.

Posterior: The anterior border of the sacral bone.

Taylor A et al. Clin Oncol (R Coll Radiol). 2007

M. Ng, et al. (AGITG) Int J Radiation Oncol Biol Phys, 2012

MESORECTUM

Cranial =the recto-sigmoid junction

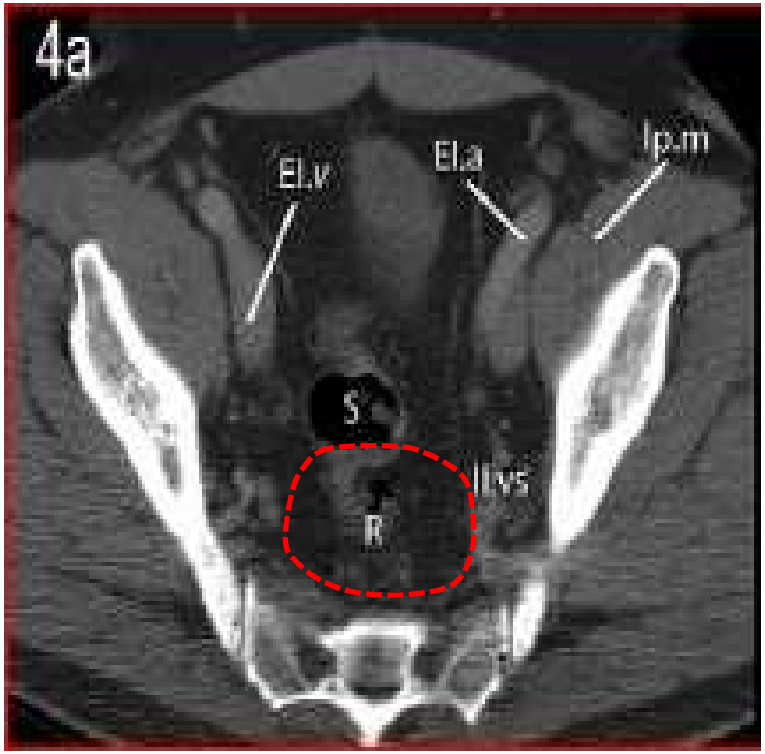

Cranial = superior rectal artery bending anteriorly

M. Ng, et al. (AGITG) Int J Radiation Oncol Biol Phys, 2012

S. Roels Int. J. Radiation Oncology Biol. Phys., 2006

MESORECTUM

Caudal =the ano-rectal junction

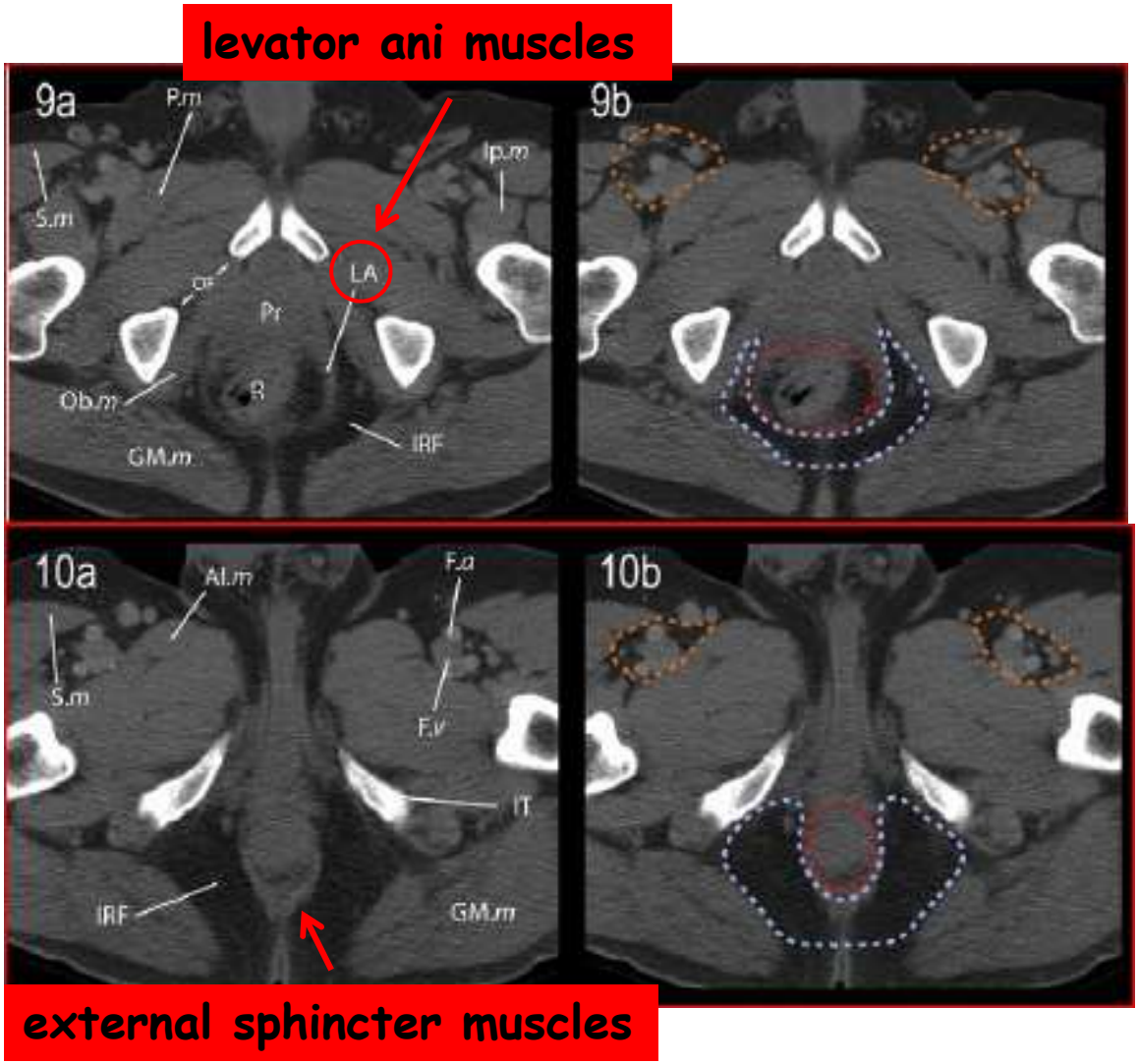

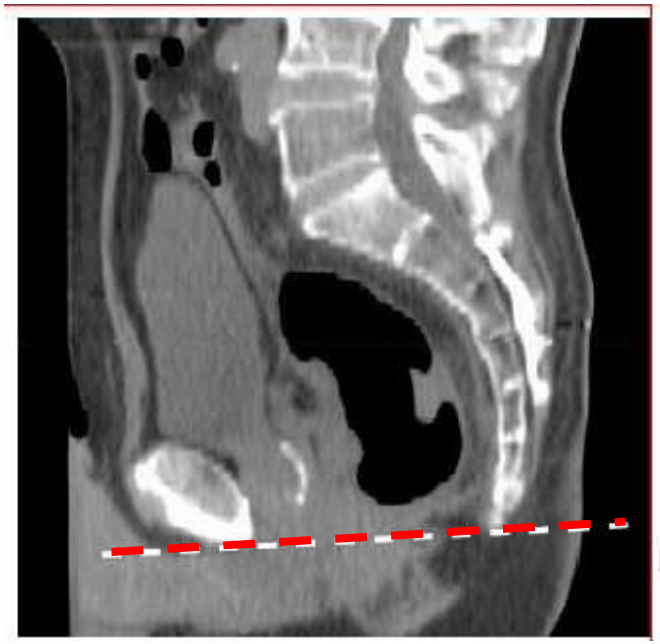

M. Ng, et al. (AGITG) Int J Radiation Oncol Biol Phys, 2012

ISCHIORECTAL FOSSA

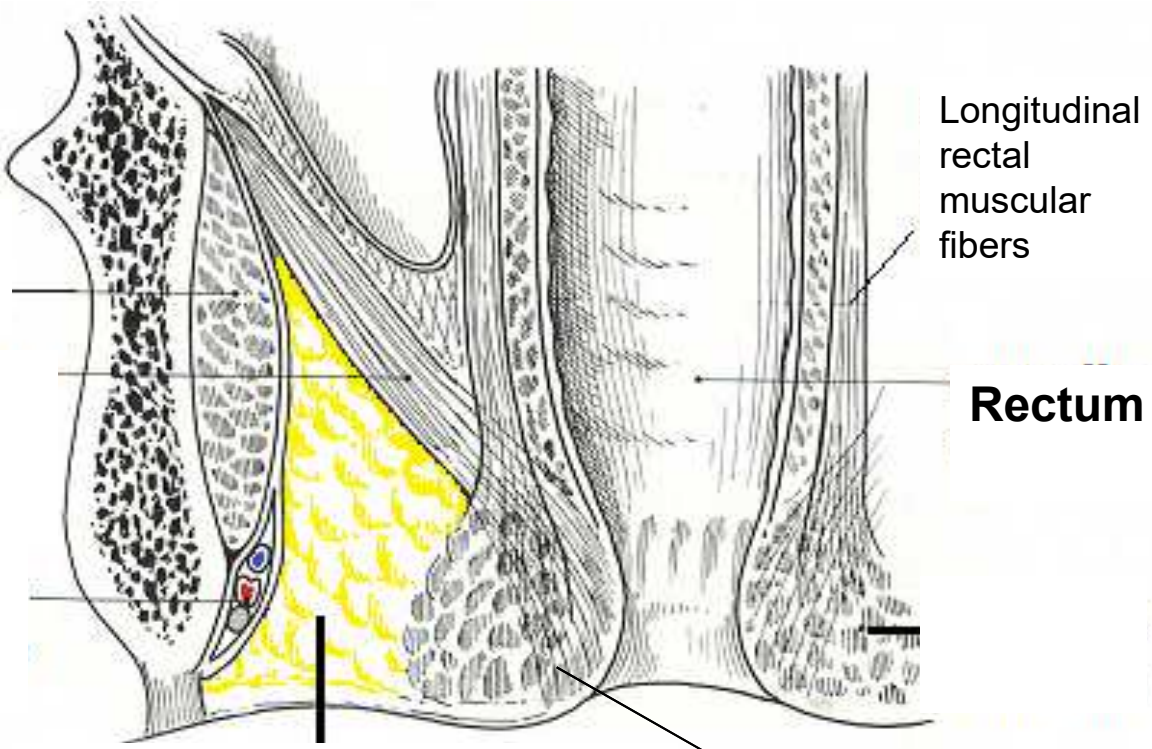

ISCHIORECTAL FOSSA

Cranial =the apex of the IRF is formed by levator ani, gluteus maximus, and obturator internus muscles

Anterior = at the level where the obturator internus muscle, levator ani, and anal sphincter muscles fuse.
Inferiorly, at least 10- to 20-mm anterior to the sphincter muscles.

Posterior = a transverse plane joining the anterior edge of the medial walls of the gluteus maximus muscle.

Lateral =, obturator internus, ischial tuberosity and gluteus maximus muscles

Caudal =at the level of the anal verge

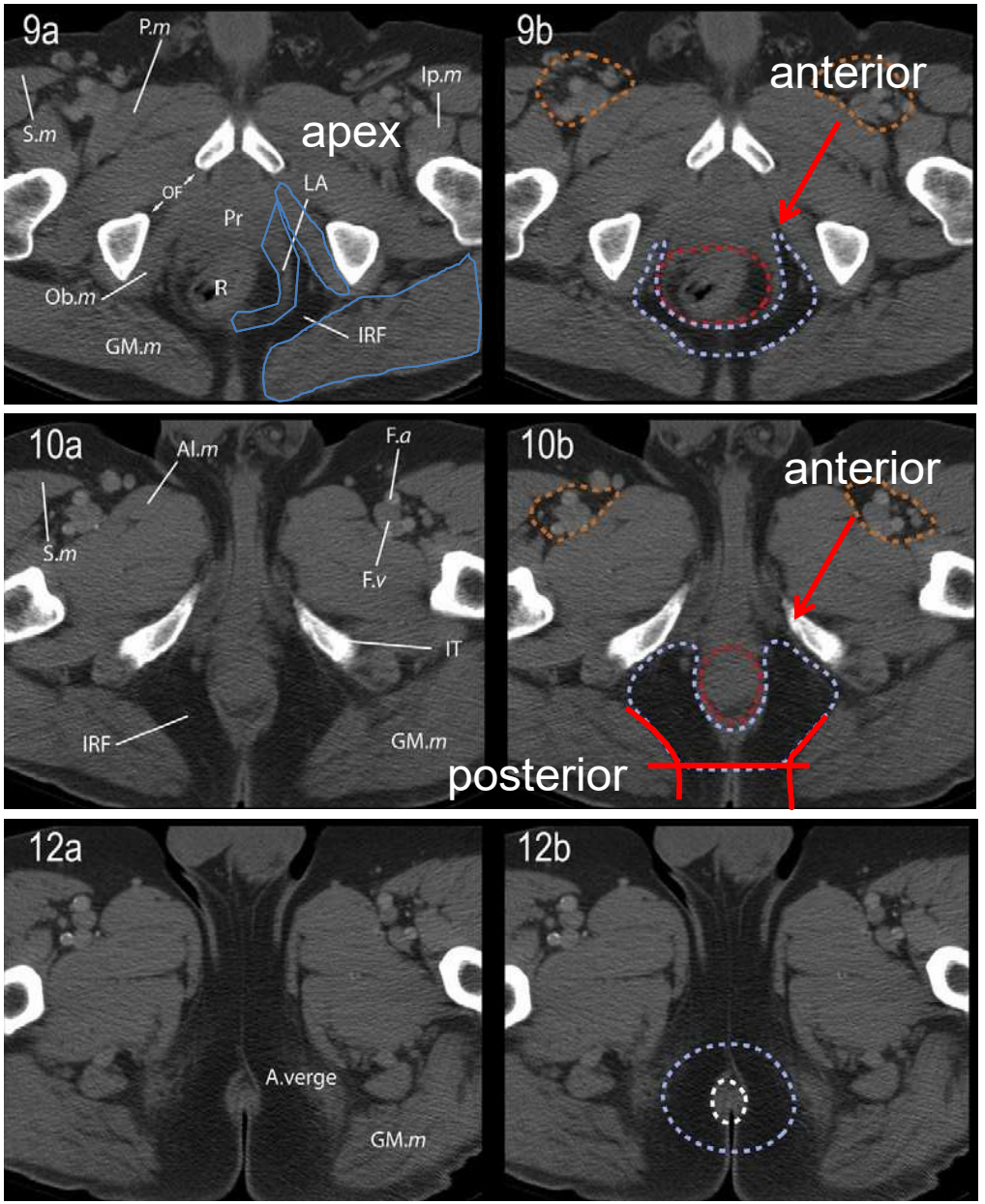

M. Ng, et al. (AGITG) Int J Radiation Oncol Biol Phys, 2012

Nodes

internal iliac lymph nodes

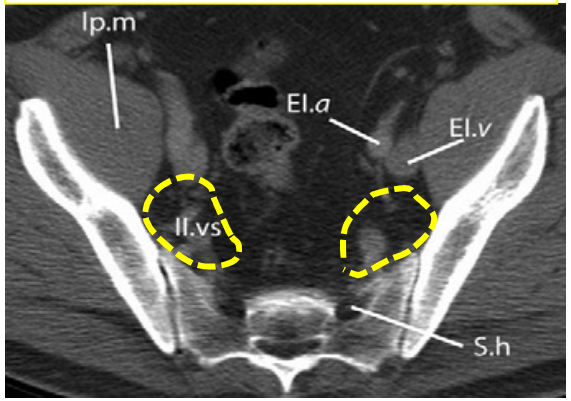

obturator lymph nodes

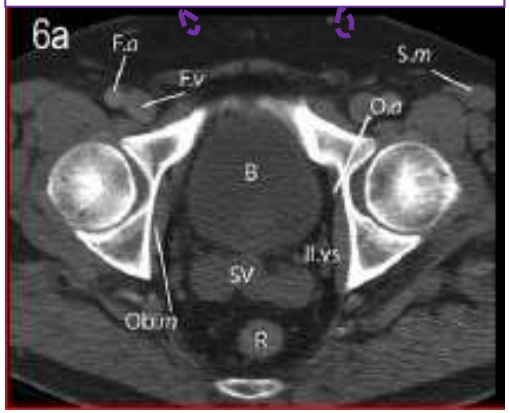

external iliac lymph nodes

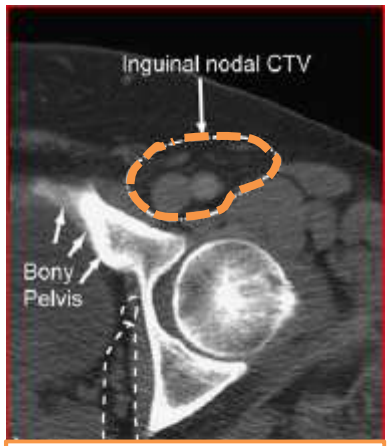

inguinal lymph nodes

M. Ng, et al. (AGITG) Int J Radiation Oncol Biol Phys, 2012

INTERNAL AND EXTERNAL ILIAC NODES

Cranial = Bifurcation of the common iliac artery into the external and internal iliac arteries (usually corresponds to the L5-S1 interspace level).

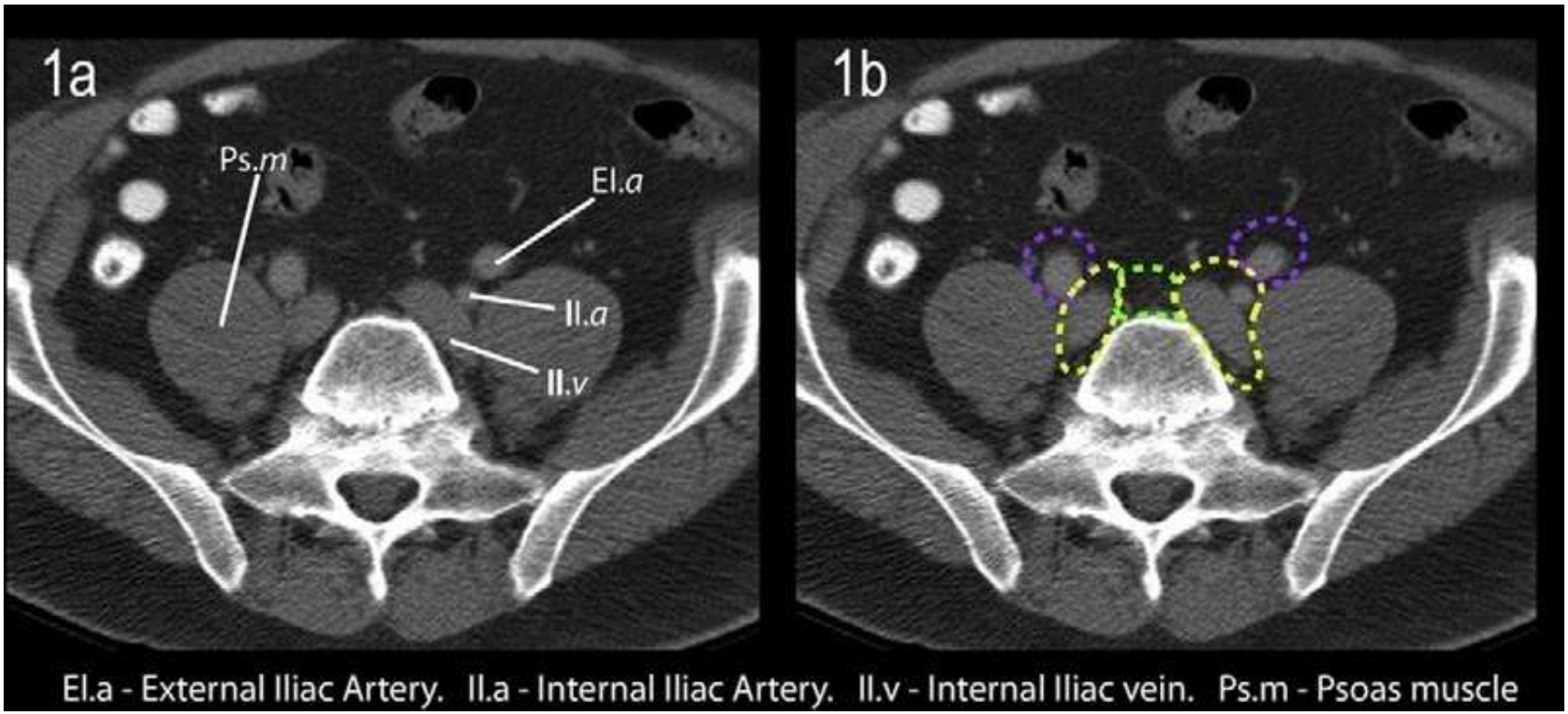

M. Ng, et al. (AGITG) Int J Radiation Oncol Biol Phys, 2012

INTERNAL ILIAC NODES

Caudal = where the fibers of the levator ani insert into the obturator fascia and obturator internus muscle, at the level of the obturator canal, or at the **level where there is no space between the obturator internus muscle and the midline organs (bladder, SV)**

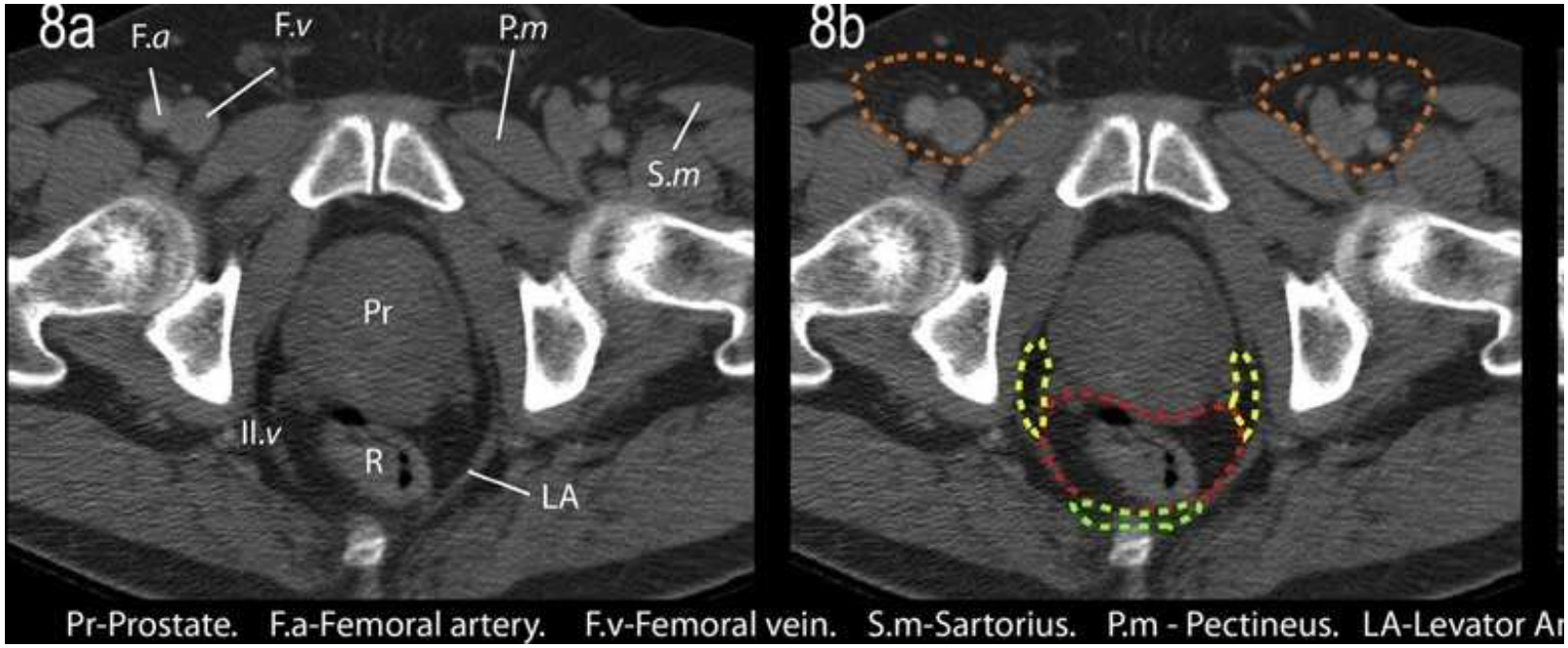

M. Ng, et al. (AGITG) Int J Radiation Oncol Biol Phys, 2012

EXTERNAL ILIAC LYMPH NODES

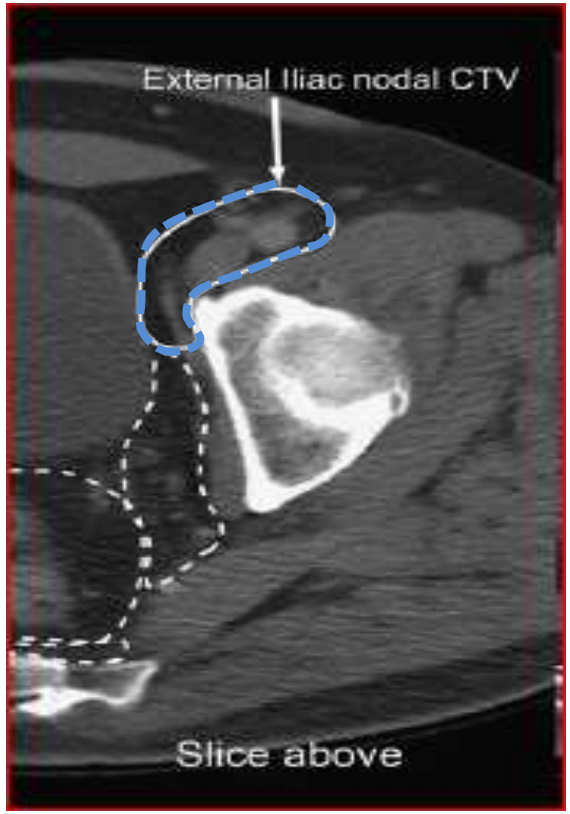

Caudal =The level where the external iliac vessels are **still located within the bony pelvis** before continuing as the femoral. This transition usually occurs **between the acetabulum's roof and the superior pubic rami**

Taylor A et al. Clin Oncol (R Coll Radiol). 2007
M. Ng, et al. (AGITG) Int J Radiation Oncol Biol Phys, 2012

OBTURATOR LYMPH NODES

Along the obturator artery, a branch of the internal iliac artery that usually **starts at the level of the acetabulum, and exits via the obturator canal.**

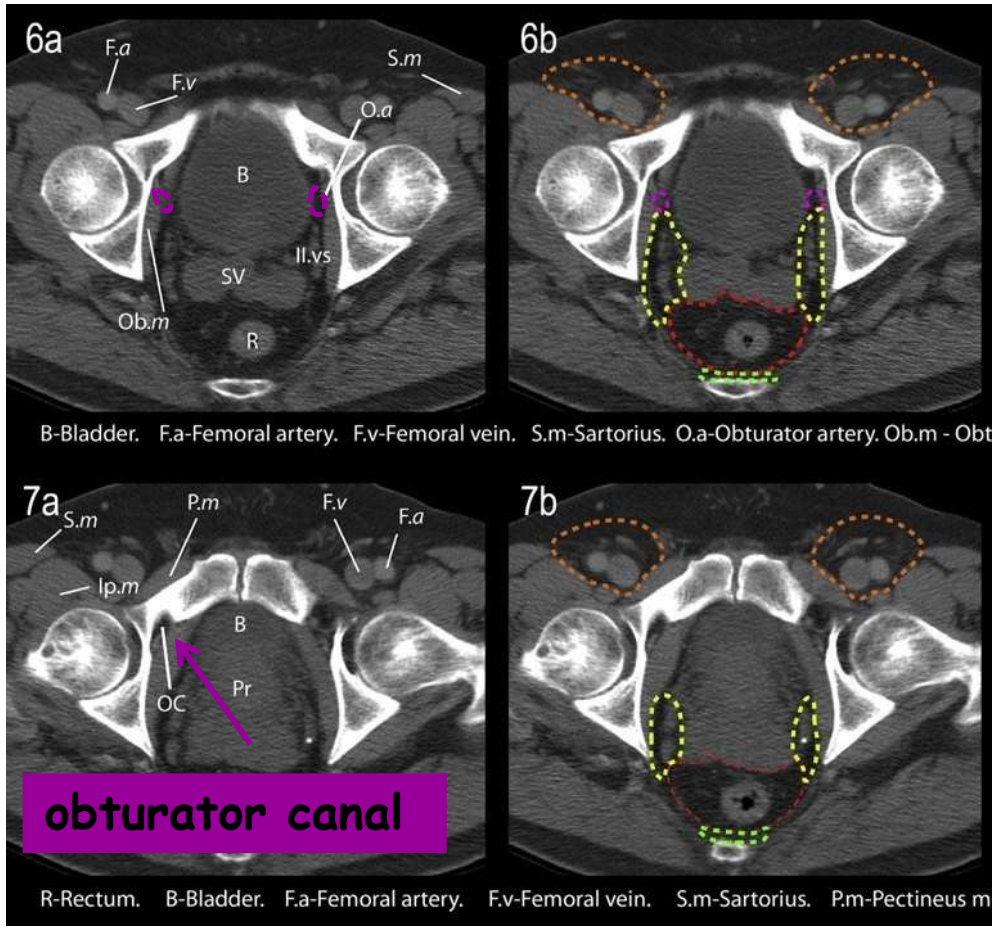

Cranial = 3 to 5 mm cranial to the obturator canal where the obturator artery is sometimes visible.

Caudal =The obturator canal,where the obturator artery has exited the pelvis.

Anterior = The anterior extent of the obturator internus muscle.

Posterior = The internal iliac lymph node group.

Lateral = The obturator internus muscle.

Medial = The bladder.

M. Ng, et al. (AGITG) Int J Radiation Oncol Biol Phys, 2012

INGUINAL LYMPH NODES

- Is an area bounded posteriorly by triangle formed by ilio-psoas, pectineus and abductor longus muscles
- At least a margin of 1-2 cm around the vessels antero-laterally should be added
- Superficial and deep nodes and any visible node or lymphcoeles outside the folowing boundaries should be included

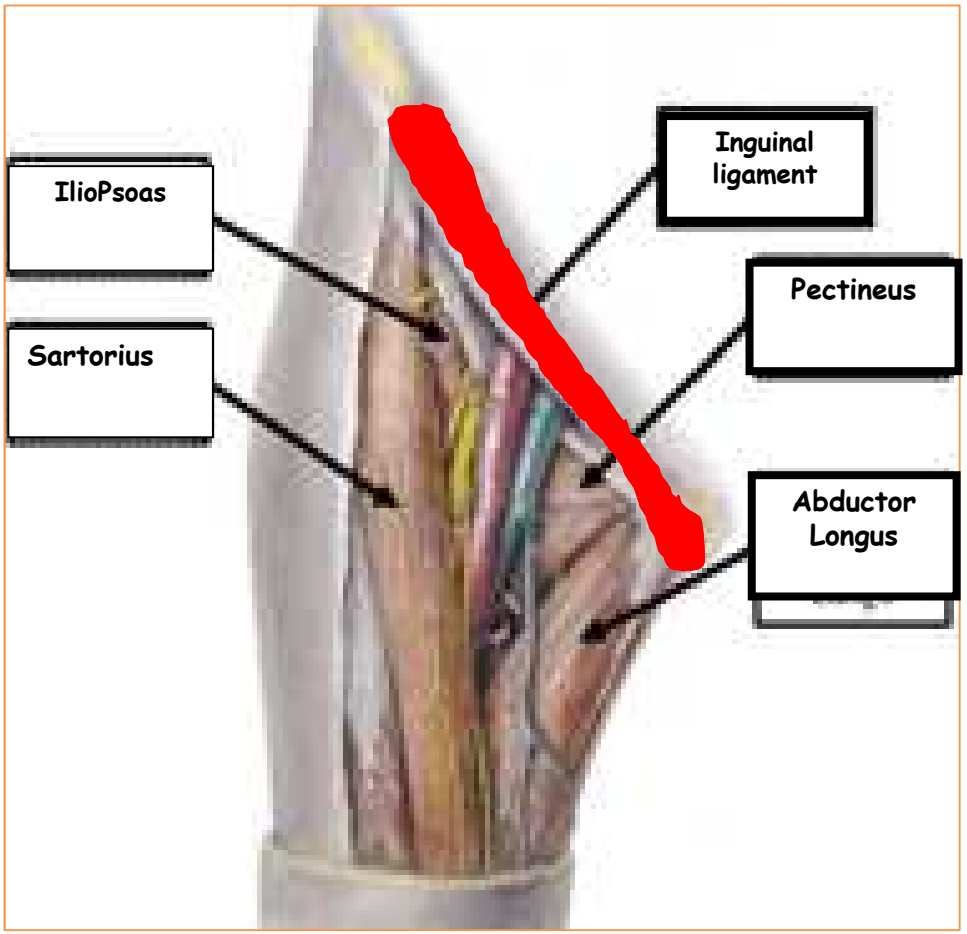

Taylor A et al. Clin Oncol (R Coll Radiol). 2007
M. Ng, et al. (AGITG) Int J Radiation Oncol Biol Phys, 2012

INGUINAL LYMPH NODES

Cranial =The level where the external iliac artery leaves the bony pelvis to become the femoral artery (**acetabulum roof and superior pubic rami**)

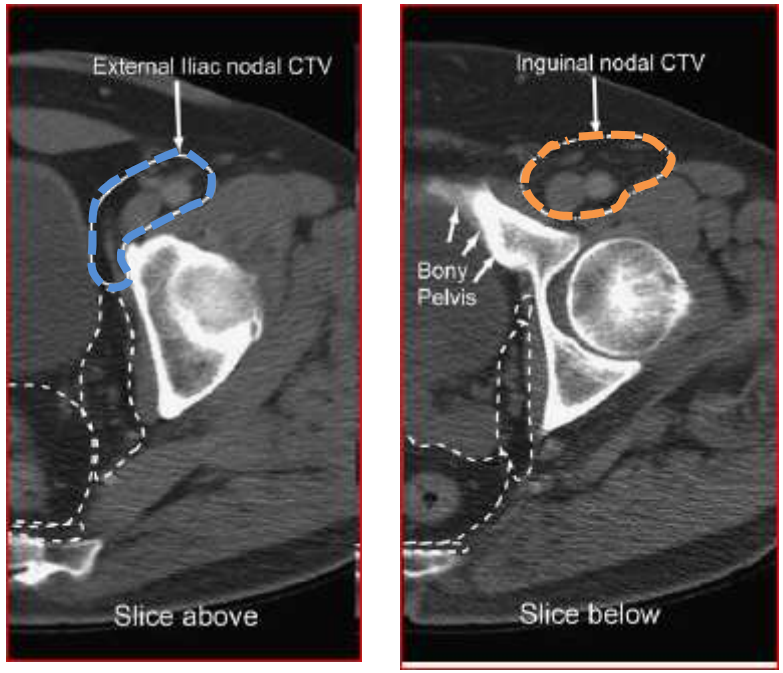

Caudal = lower edge of the **ischial tuberosities**

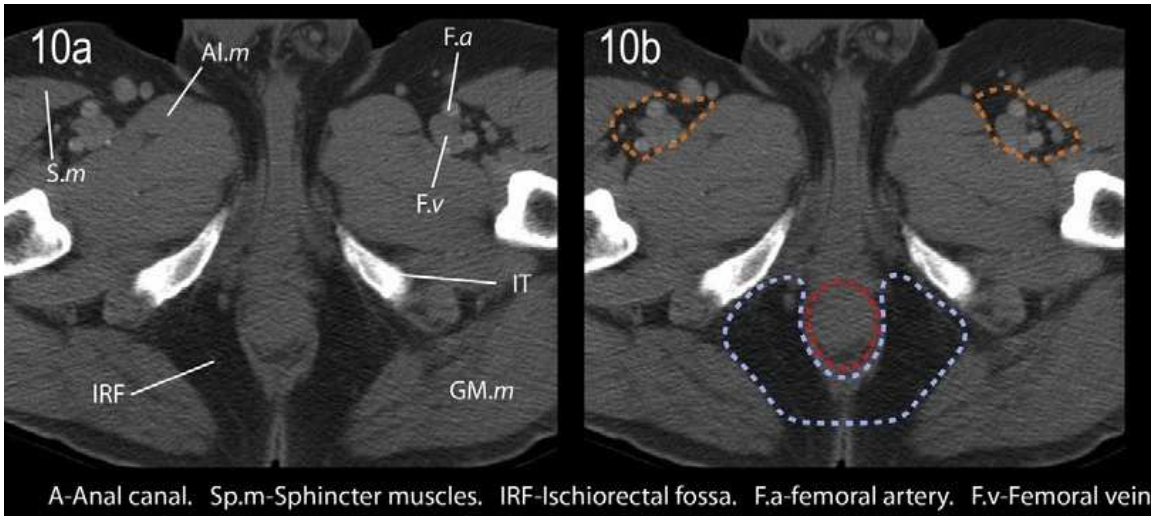

Taylor A et al. Clin Oncol (R Coll Radiol). 2007

M. Ng, et al. (AGITG) Int J Radiation Oncol Biol Phys, 2012

INGUINAL LYMPH NODES

Posterior =The bed of the femoral triangle is formed by **the iliopsoas, pectineus, and adductor longus muscles**.

Anterior = on the inguinal vessels + 20 mm, inclusive of any visible lymph nodes or lymphocoeles

Lateral = The medial edge of sartorius or iliopsoas

Medial = A 10- to 20-mm margin around the femoral vessels. The medial third to half of the **pectineus or adductor longus** muscle serves as an approximate border

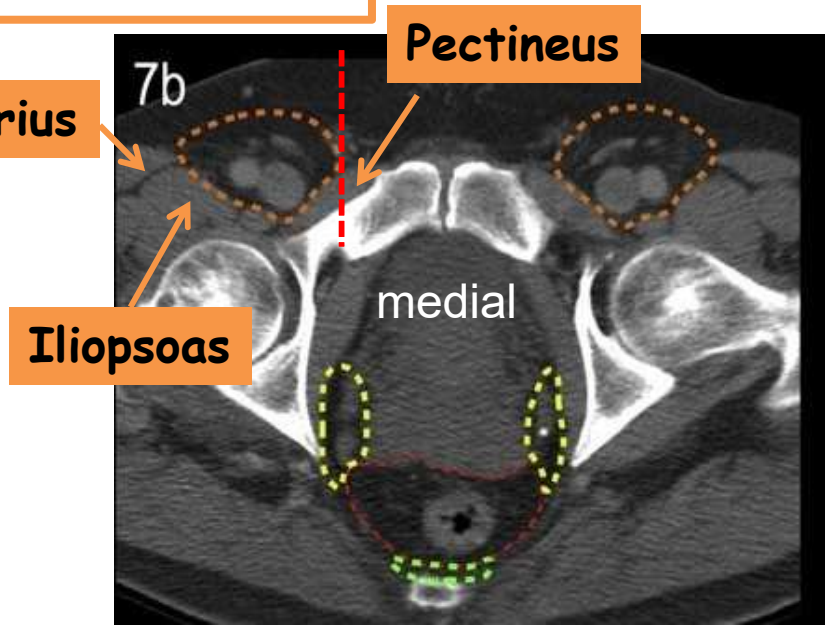

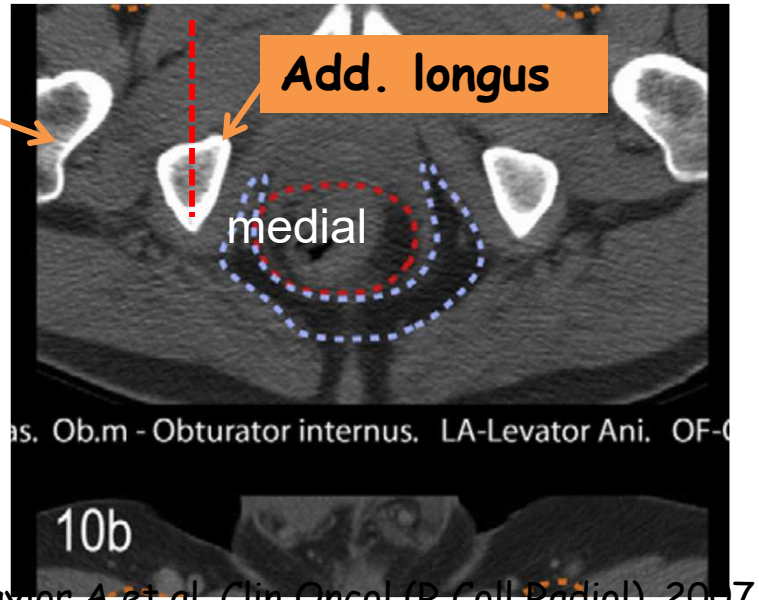

Taylor A et al. Clin Oncol (R Coll Radiol). 2007

M. Ng, et al. (AGITG) Int J Radiation Oncol Biol Phys, 2012

CTV COMBINED

Mesorectum

Anterior Border

An **internal margin of 1 cm** should be added to the anterior mesorectal border to account for bladder volume variation

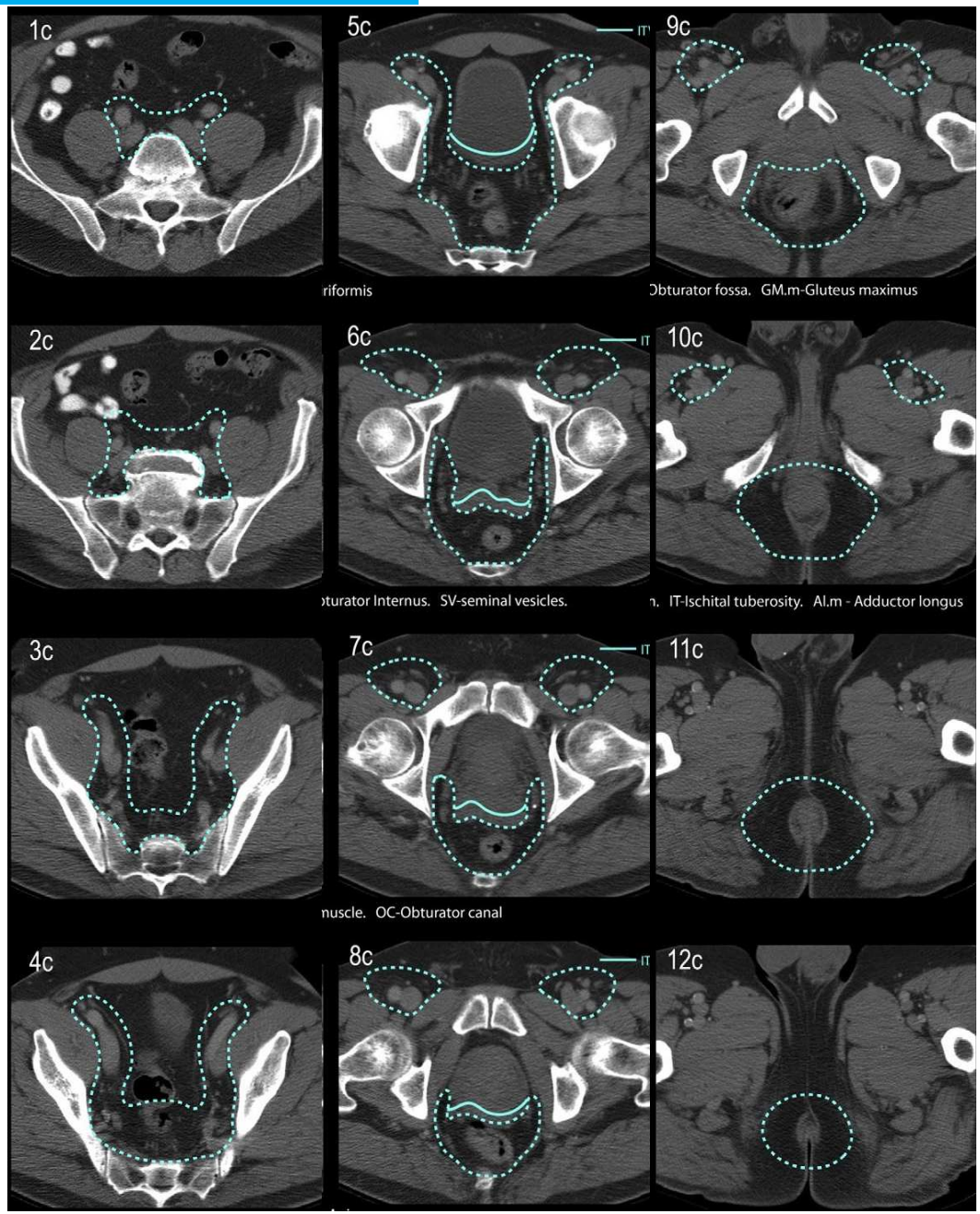

Clinical Investigation: Gastrointestinal Cancer

Australasian Gastrointestinal Trials Group (AGITG) Contouring Atlas and Planning Guidelines for Intensity-Modulated Radiotherapy in Anal Cancer

M. Ng, et al. (AGITG) Int J Radiation Oncol Biol Phys, 2012

CLINICAL TARGET VOLUME FOR GROSS DISEASE

PRIMARY TUMOR

CTV=
GTV + entire anal canal + sphincter muscles
+
20 mm isotropic margin

while respecting anatomical boudaries

M. Ng, et al. (AGITG) Int J Radiation Oncol Biol Phys, 2012

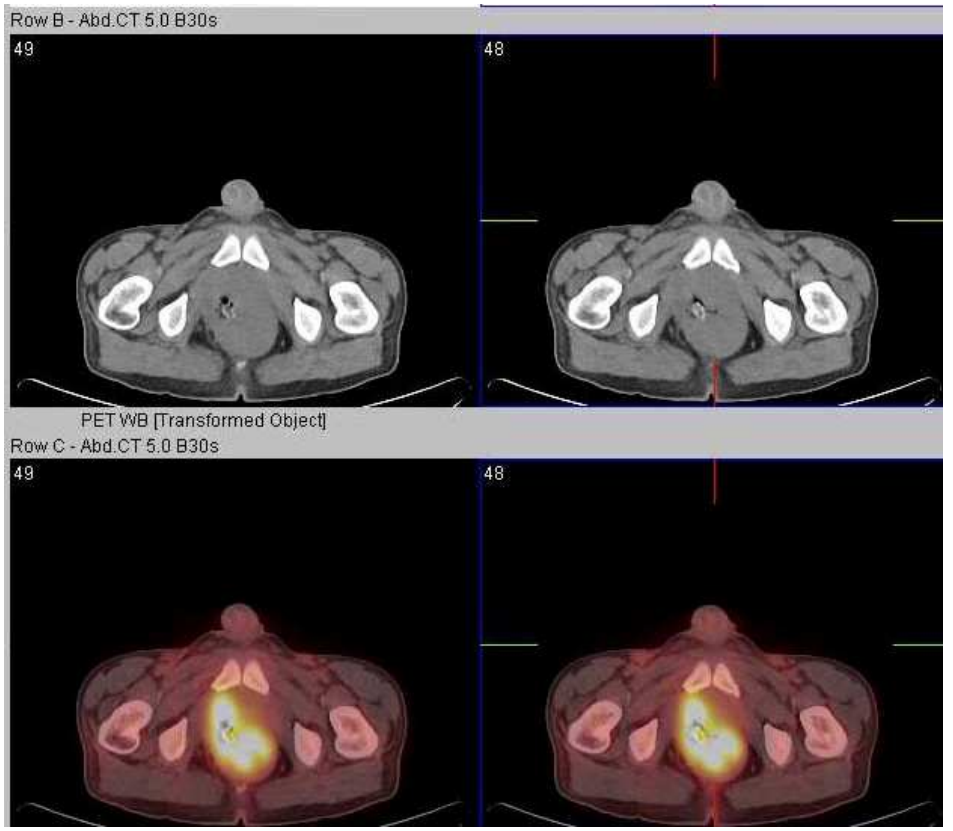

For very **advanced anal** or rectal cancers, extending through the mesorectum or the levators, the group's recommendation is to add ~2 cm margin up to bone wherever the cancer extends beyond the usual compartments.

Better defined on MRI and/or PET/CT.

Myerson RJ, Garofalo MC, El Naqa I, et al. Int J Radiat Oncol Biol Phys. 2009

Clinical Investigation: Gastrointestinal Cancer

Australasian Gastrointestinal Trials Group (AGITG) Contouring Atlas and Planning Guidelines for Intensity-Modulated Radiotherapy in Anal Cancer

M. Ng, et al. (AGITG) Int J Radiation Oncol Biol Phys, 2012

CLINICAL TARGET VOLUME FOR GROSS DISEASE

INVOLVED NODE(S)

CTV = **Involved nodes** + 10-20 mm ispotropic margin, respecting anatomical boundaries.

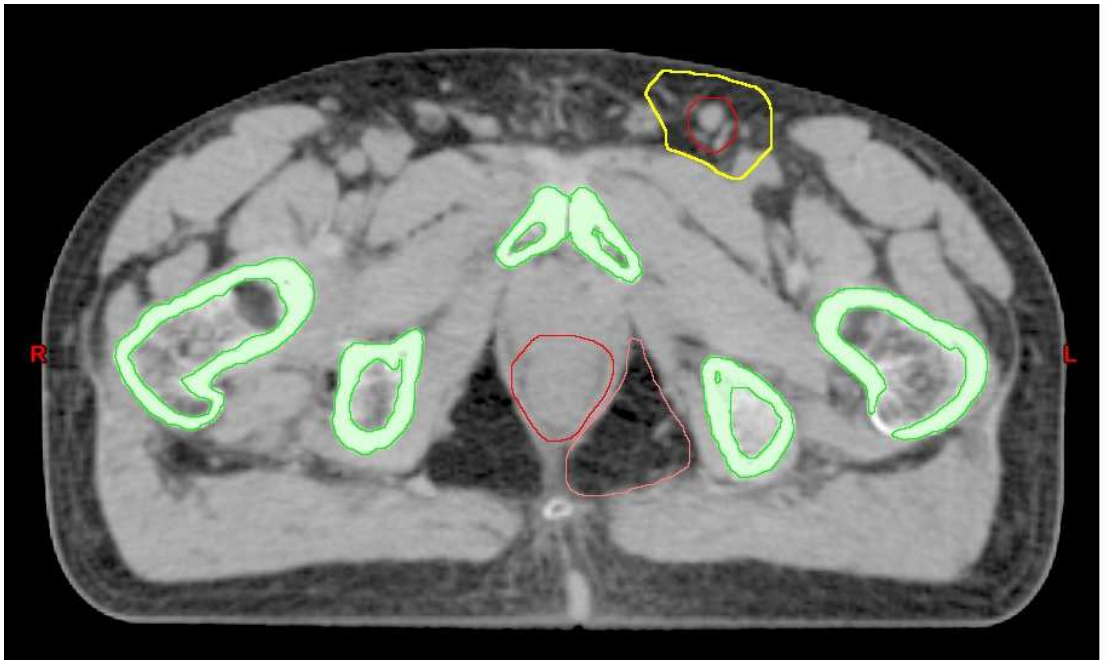

M. Ng, et al. (AGITG) Int J Radiation Oncol Biol Phys, 2012

Critical issues

Anterior CTV border of the **MESORECTUM**.

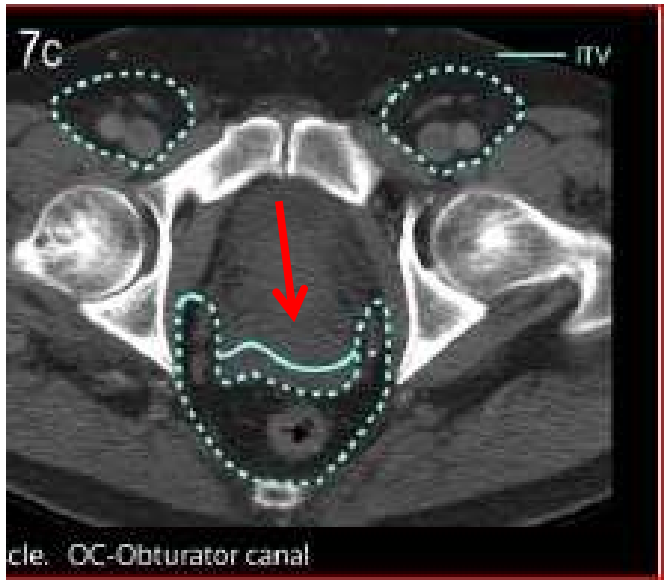

AGITG atlas have addressed this issue by using ICRU63 definitions where we describe an internal margin of 10-mm to be added to the CTV at the levels of the bladder to form an internal target volume.

Nuyttens JJ, et al. Int J Radiat Oncol Biol Phys 2002
M. Ng, et al. (AGITG) Int J Radiation Oncol Biol Phys, 2012

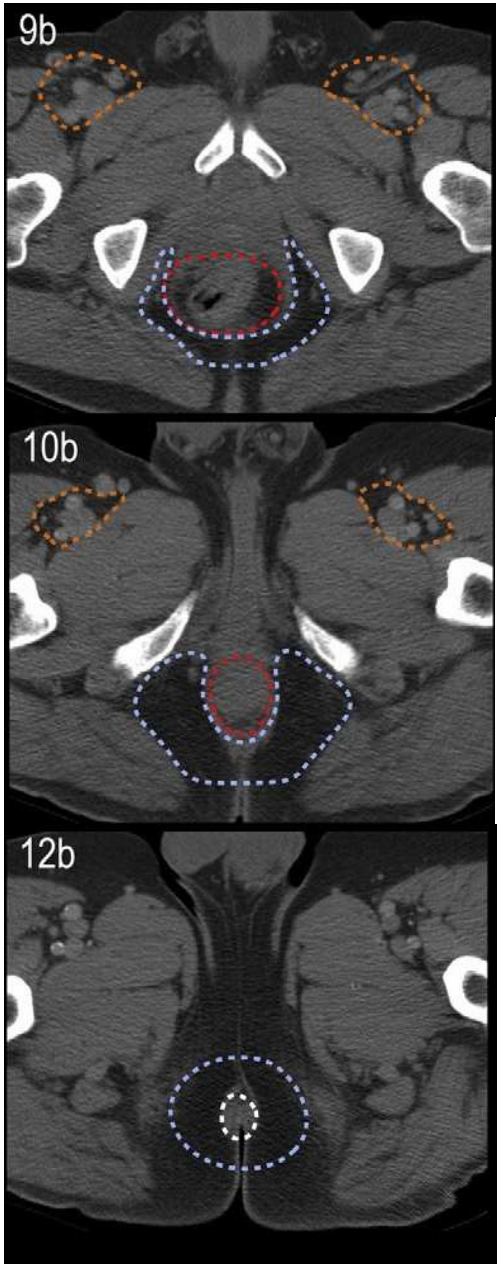

Critical issues

ISCHIORECTAL FOSSA

The RTOG guidelines do not consider the IRF to be an area at risk.

However, because traditional 2D pelvic fields from previous randomized controlled trials encompassed the entire IRF, AGITG guidelines recommends the inclusion of this area in the CTVe

Myerson RJ, Garofalo MC, El Naqa I, et al. Int J Radiat Oncol Biol Phys. 2009
M. Ng, et al. (AGITG) Int J Radiation Oncol Biol Phys, 2012

Critical issues

INGUINAL LYMPH NODES

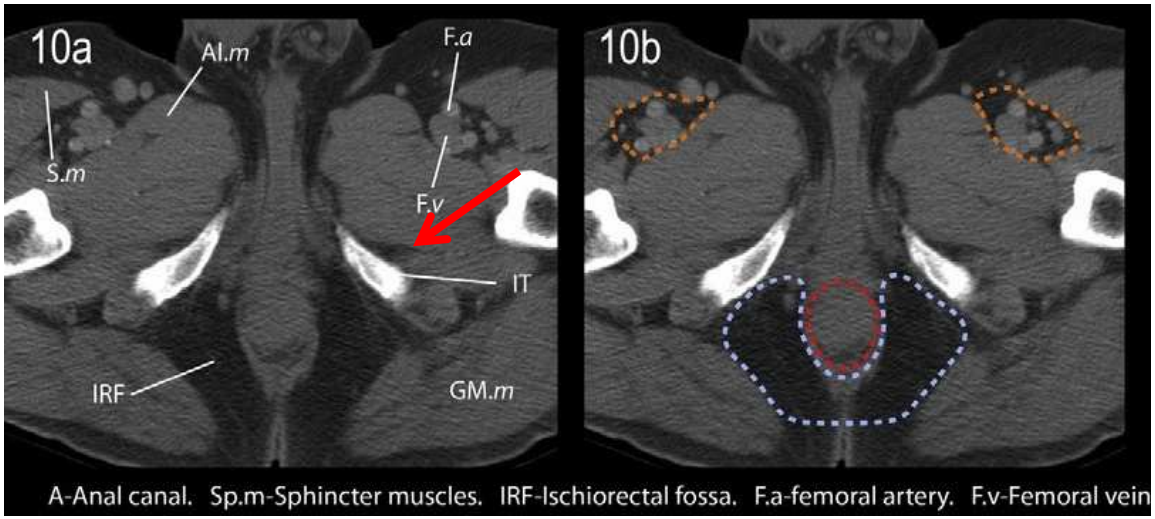

The inguinal lymph node group: applying a "margin rules" for femoral vessels has its limitations, given that **there is no clear anatomical compartment** and that variation is seen with **different body habitus**.
A combination of landmark-based boundaries and margins when no anatomical boundaries exist was reccomendated.
The inferior edge of the ischial tuberosity was selected as the caudal level for contouring the inguinal fossa.

M. Ng, et al. (AGITG) Int J Radiation Oncol Biol Phys, 2012

Critical issues

CLINICAL TARGET VOLUME FOR GROSS DISEASE

CTV for gross disease: 2D fields have recommended a 20- to 30-mm margin for the field edge around gross disease for the "boost" volume.

The consensus for this boost volume was to include the **entire anal canal** and **sphincter muscles with a further margin**.
There was variation in this expansion margin with a range of 10- to 20-mm.

Similarly, there was a variation of 10- to 20-mm for the CTV margin around **involved nodes** to account for extracapsular extension (ECE).
A minimum of 10-mm was based on pathological studies on ECE of metastatic lymph nodes in head-and-neck squamous cell carcinoma

M. Ng, et al. (AGITG) Int J Radiation Oncol Biol Phys, 2012

PTV

- An isotropic 10-mm expansion is recommended on CTVs to generate PTVs.

- Daily image guidance is recommended for IMRT, especially prone patients, which may allow CTVePTV margin reduction to 5- to 7-mm.

M. Ng, et al. (AGITG) Int J Radiation Oncol Biol Phys, 2012

Organ at Risk

Organ at Risk

Anal cancer treatment:

Exclusive chemoradiation

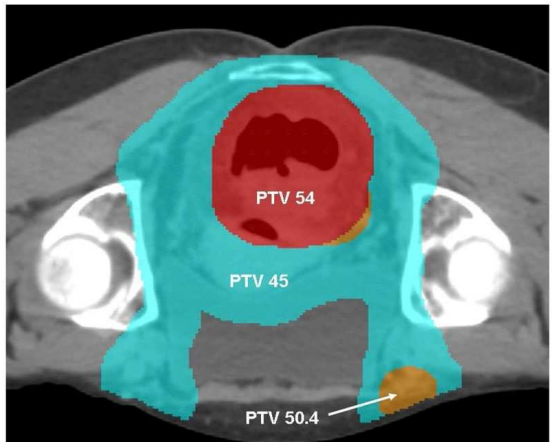

- Large volumes
- High doses
- OAR surrounded by PTV
- Myelotoxic conc CT (mytomicin or cisplatin +5FU)

Clinical Investigation: Gastrointestinal Cancer

Australasian Gastrointestinal Trials Group (AGITG) Contouring Atlas and Planning Guidelines for Intensity-Modulated Radiotherapy in Anal Cancer

M. Ng, et al. (AGITG) Int J Radiation Oncol Biol Phys, 2012

Organs at risk (OAR)

Clinical Investigation: Genitourinary Cancer

Pelvic Normal Tissue Contouring Guidelines for Radiation Therapy: A Radiation Therapy Oncology Group Consensus Panel Atlas

Gay HA et al. Int J Radiat Oncol Biol Phys. 2012

Organs at risk (OAR)

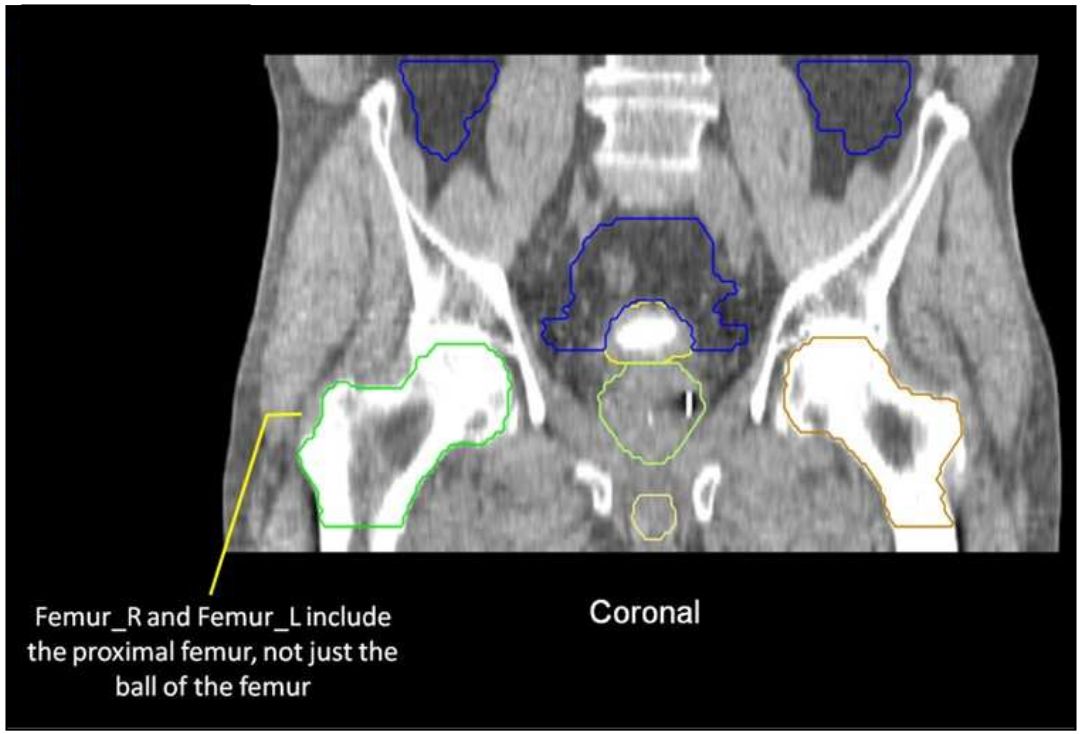

Femoral head and neck: The entire femoral **head and neck** should be contoured. **The inferior extent** is the cranial edge of the lesser trochanter.

Urinary bladder: The entire external outline of the bladder wall should be contoured.

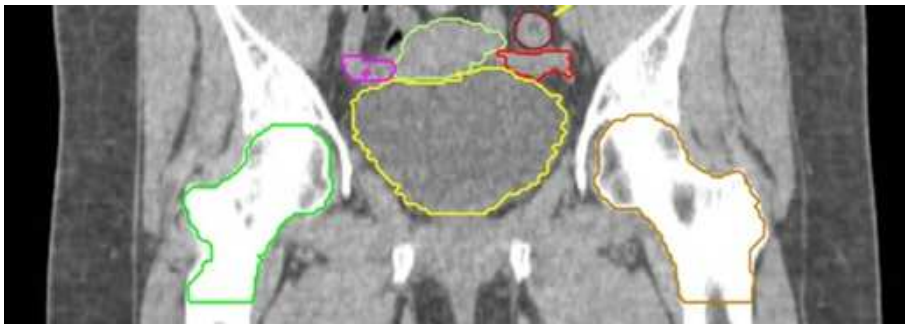

Gay HA et al. Int J Radiat Oncol Biol Phys. 2012
M. Ng, et al. (AGITG) Int J Radiation Oncol Biol Phys, 2012

Clinical Investigation: Gastrointestinal Cancer

Australasian Gastrointestinal Trials Group (AGITG) Contouring Atlas and Planning Guidelines for Intensity-Modulated Radiotherapy in Anal Cancer

M. Ng, et al. (AGITG) Int J Radiation Oncol Biol Phys, 2012

Organs at risk (OAR)

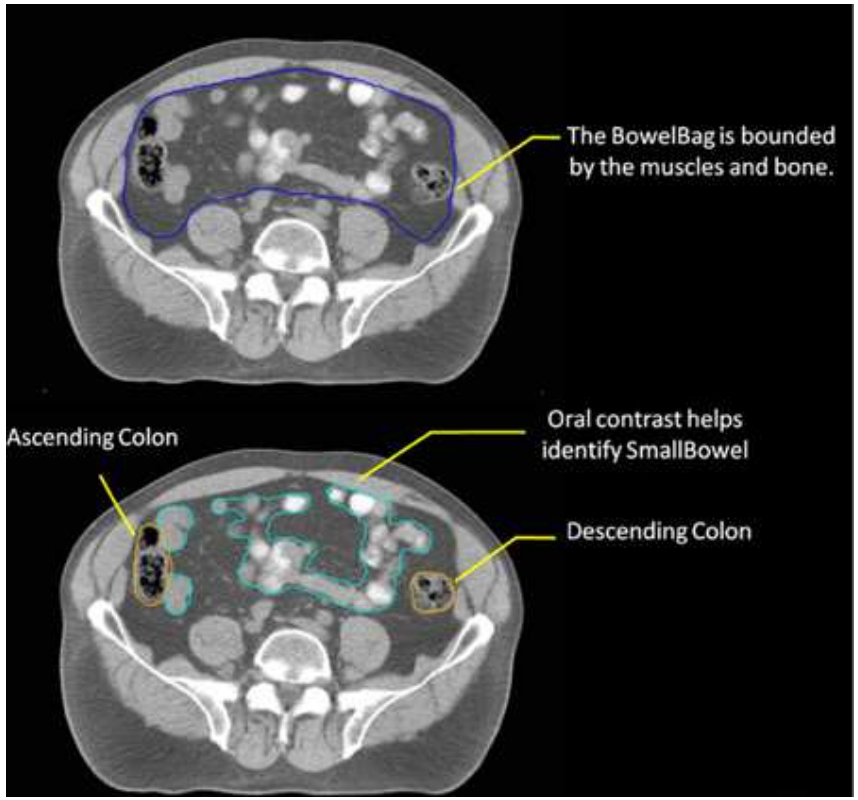

Gay HA et al. Int J Radiat Oncol Biol Phys. 2012

Bowel: Small bowel and large bowel, opacified or nonopacified, should be delineated **from 15-mm superior to the cranial aspect of the PTV, extending inferiorly to the recto-sigmoid junction.**

Devisetty K, et al. Radiother Oncol 2009

Bowel NOS: Peritoneal space occupied or potentially occupied by bowel,large or small.
Small bowel: **To distinguish from large bowel, the use of o.c., administered 30 minutes before scanning, is encouraged**. The small bowel can be outlined as loops containing contrast.
Large boweld: All intestine seen above the rectum; usually delineated as the bowel starting with noncircular or oval structures or above 15 cm.

M. Ng, et al. (AGITG) Int J Radiation Oncol Biol Phys, 2012

Clinical Investigation: Gastrointestinal Cancer

Australasian Gastrointestinal Trials Group (AGITG) Contouring Atlas and Planning Guidelines for Intensity-Modulated Radiotherapy in Anal Cancer

M. Ng, et al. (AGITG) Int J Radiation Oncol Biol Phys, 2012

Organs at risk (OAR)

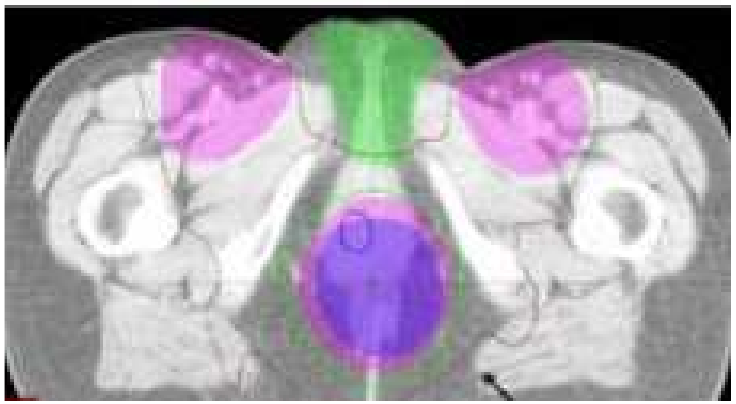

External genitalia and perineum

In **FEMALES**:
clitoris,
labia majora and minora
area including skin and fat anterior to pubic symphysis.

In **MALES**:
bulb penis
scrotum
area including skin and fat anterior to the pubic symphysis

The **cranial extent** of this volume is the caudal edge of the pubic symphysis.

Gay HA et al. Int J Radiat Oncol Biol Phys. 2012
Brooks C et al. Br J Cancer 2015
M. Ng, et al. (AGITG) Int J Radiation Oncol Biol Phys, 2012

Clinical Investigation: Gastrointestinal Cancer

Australasian Gastrointestinal Trials Group (AGITG) Contouring Atlas and Planning Guidelines for Intensity-Modulated Radiotherapy in Anal Cancer

M. Ng, et al. (AGITG) Int J Radiation Oncol Biol Phys, 2012

Organs at risk (OAR)

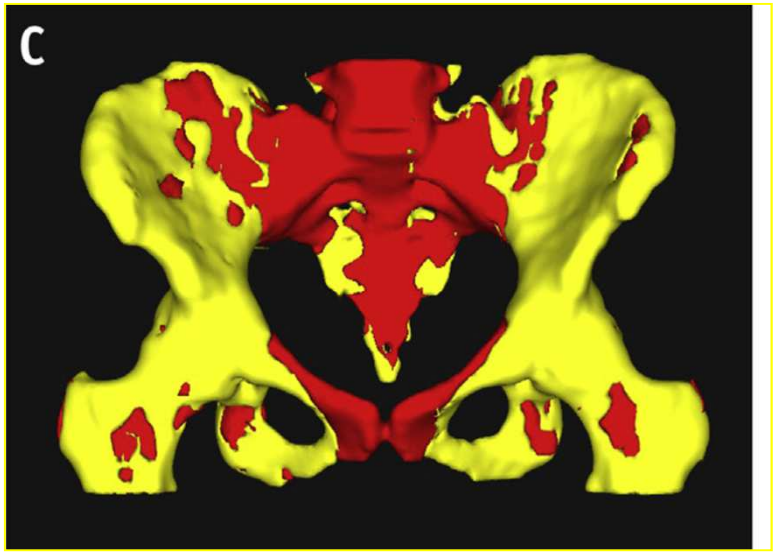

Bone marrow: Both iliac crests will be used to define "bone marrow." Delineation will extend cranially from the top of the iliac crests to the superior part of the acetabulum caudally. The left and right iliac crests are combined into one volume

M. Ng, et al. (AGITG) Int J Radiation Oncol Biol Phys, 2012

Clinical Investigation

International Journal of Radiation Oncology biology • physics

www.redjournal.org

Hematologic Nadirs During Chemoradiation for Anal Cancer: Temporal Characterization and Dosimetric Predictors

Andrew Y. Lee, MD,* Daniel W. Golden, MD,* Jose G. Bazan, MD,† Malgorzata Kopec, CMD,* Charles A. Pelizzari, PhD,* Sonya Aggarwal, BA,‡ Daniel T. Chang, MD,‡ and Stanley L. Liauw, MD*

*Department of Radiation and Cellular Oncology, University of Chicago, Chicago, Illinois; †Department of Radiation Oncology, The Ohio State University, Columbus, Ohio; and ‡Department of Radiation Oncology, Stanford University, Stanford, California

Table 1 Patient characteristics

Characteristic	n (%)	IMRT (n=49) n (%)	3D conformal (n=7) n (%)
Sex			
Female	37 (66)	30 (61)	7 (100)
Male	19 (34)	19 (39)	0 (0)
Age, y			
<60	32 (57)	27 (55)	5 (71)
≥60	24 (43)	22 (45)	2 (29)
Body mass index, kg/m^2			
<25	29 (48)	24 (49)	5 (71)
≥25	27 (52)	25 (51)	2 (29)

Abbreviations: 3D = 3-dimensional; IMRT = intensity modulated radiation therapy.

Baseline patient characteristics are presented for the entire cohort, and separately for patients treated with IMRT and 3D conformal therapy.

Distribution of blood counts during CRT

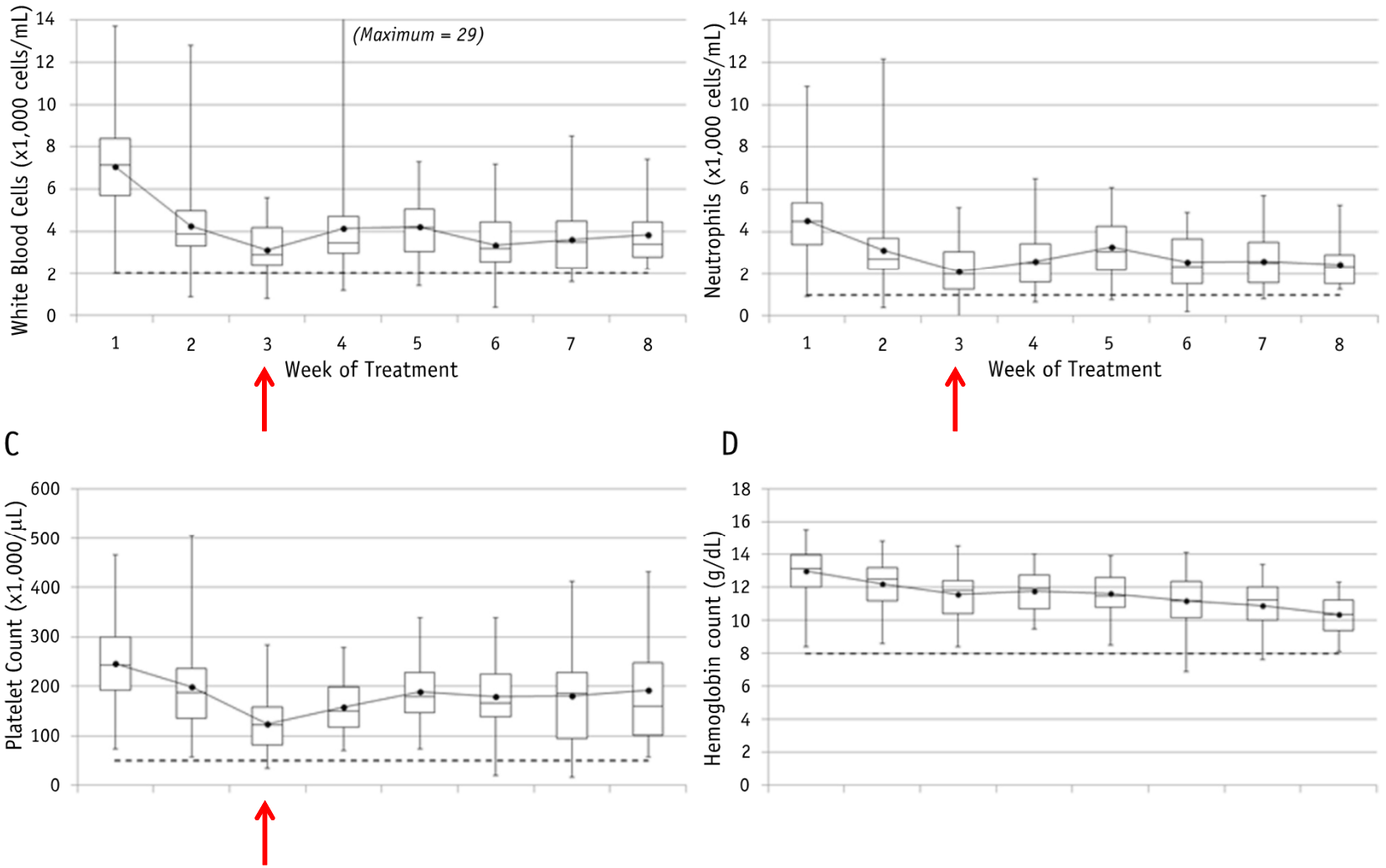

Andrew YL et al. Int J Radiat Oncol Biol Phys

Bone marrow sparing metric	toxicity	
	At week 3	At any time
If ≥750 cc of marrow is spared from ≥30 Gy	0%	5%
vs <750 cc	32% ($P = .008$)	54% ($P < .01$)
If LP V40 Gy <23%	8%	22%
vs ≥23%	35% ($P = .04$)	52% ($P = .03$)

Abbreviation: LP = lower pelvic bone marrow.

The rates of grade 3+ hematologic toxicity at week 3 of treatment and at any time throughout treatment are presented based on whether

Andrew YL et al. Int J Radiat Oncol Biol Phys

INSTITUT
JULES BORDET
INSTITUUT

From GTV to PTV

based on the ACROP guidelines in preparation

Van Houtte P
Institut Bordet
Université Libre Bruxelles

ULB iris

No conflict of interest except I am….

Omegang : the entrance of Charles V in Brussels

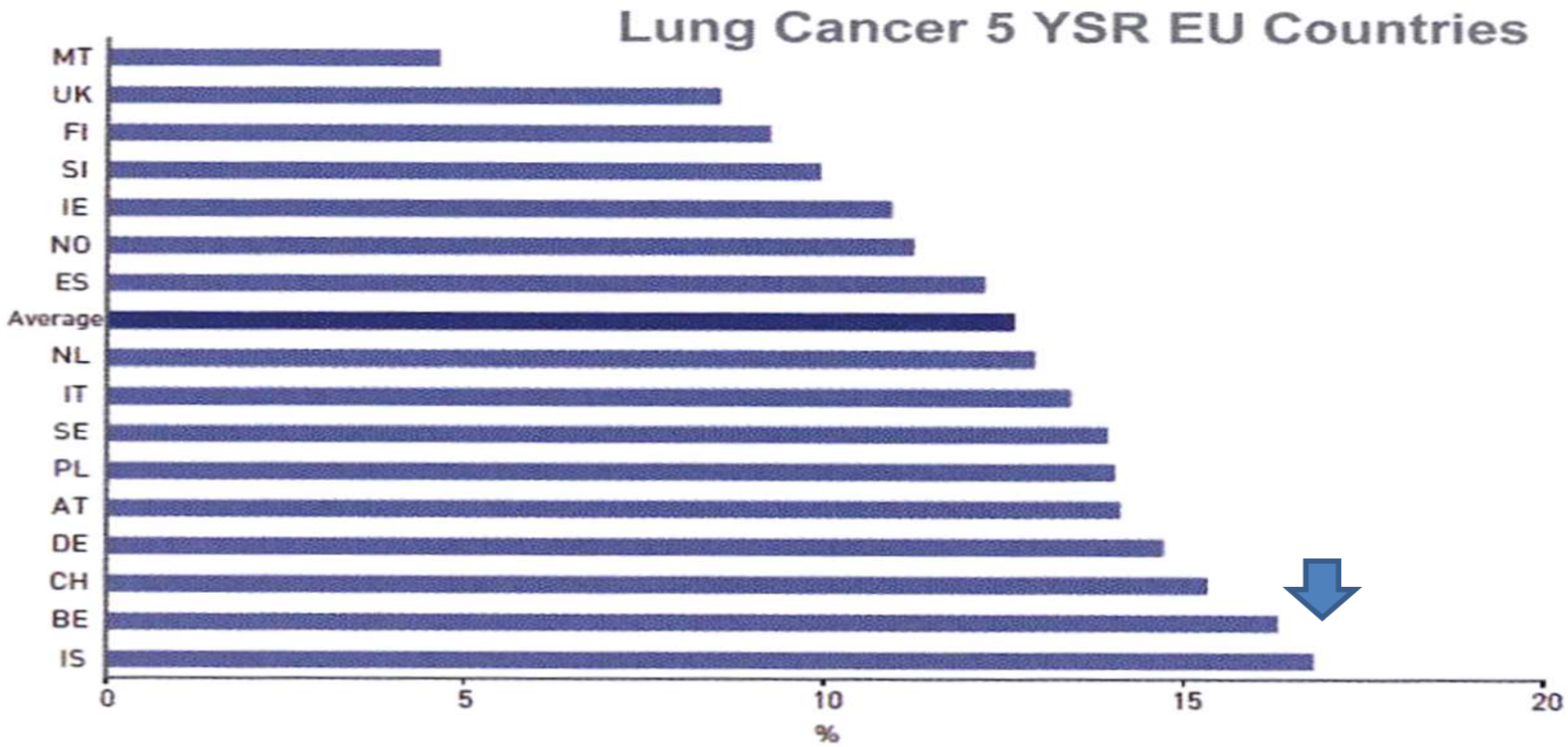

Figure 4 – Age-adjusted 5-year survival from lung cancer in selected European countries among patients diagnosed 2000–2002 relative to that of the general population. Survival for the UK has been derived from estimates for England, Scotland, Wales and Northern Ireland and the average independently calculated. Data from EUROCARE-4 study (www.eurocare.it).

PREVENTION : THE KEY MESSAGE

The mortality by lung ca is going down

But the production of cigarettes Worldwide is not decreasing !

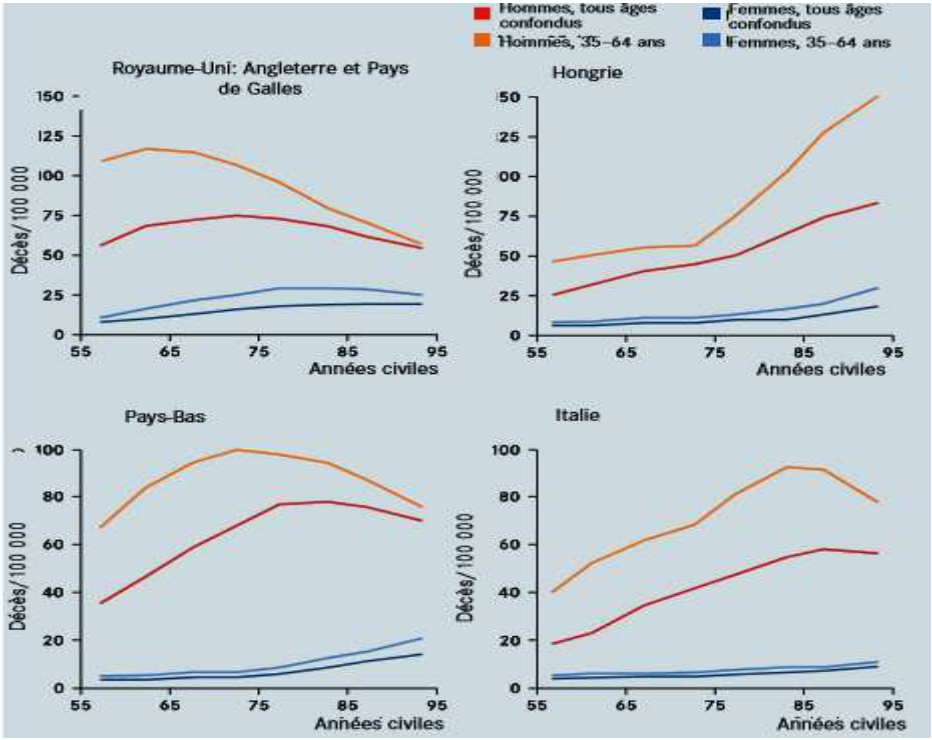

INSTITUT JULES BORDET INSTITUUT

ULB iris

And yes we are still smoking a lot even MD
and young people

ACROP Guidelines for locally advanced NSCLC

- From imaging to contouring
- NSCLC
- SCLC
- Induction chemotherapy
- Adaptative Radiotherapy
- Postoperative radiotherapy
- « Special ACROP guidelines for SBRT in preparation »

Diagnostic imaging

Diagnostic CT with i.v. contrast (M)

PET-CT (M) within 3 weeks before RT start (R)

For sequential Radio-chemotherapy: repeat CT with i.v. contrast (M)

Consider MRI for superior sulcus or paraspinal tumours (O)

Additional imaging

Planning PET-CT in radiotherapy position (R)

4D PET(CT) in treatment position is optional (e.g. differentiation of atelectasis, diaphragm) (O)

Registration of images? (side by side vs. deformable)

Implications of Delayed Initiation of Radiotherapy after an induction chemotherapy
Chen et al JTO 2011

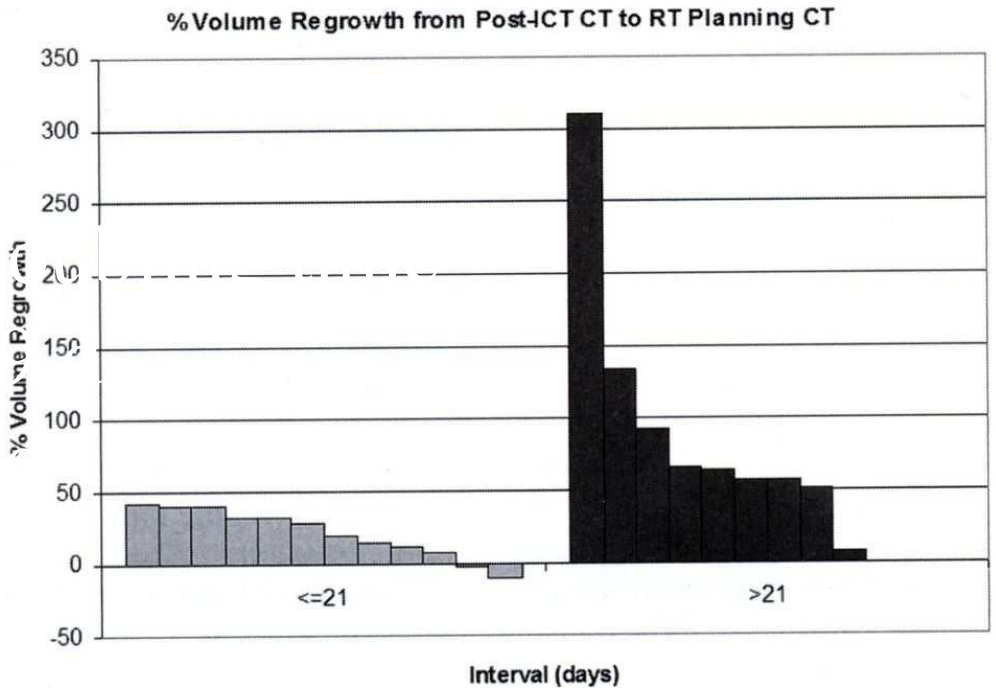

Stage Migration in Planning PET/CT in Patients Due to Receive Radiotherapy for Non–Small-Cell Lung Ca
Geiger G et al Clinical Lung Ca 2014

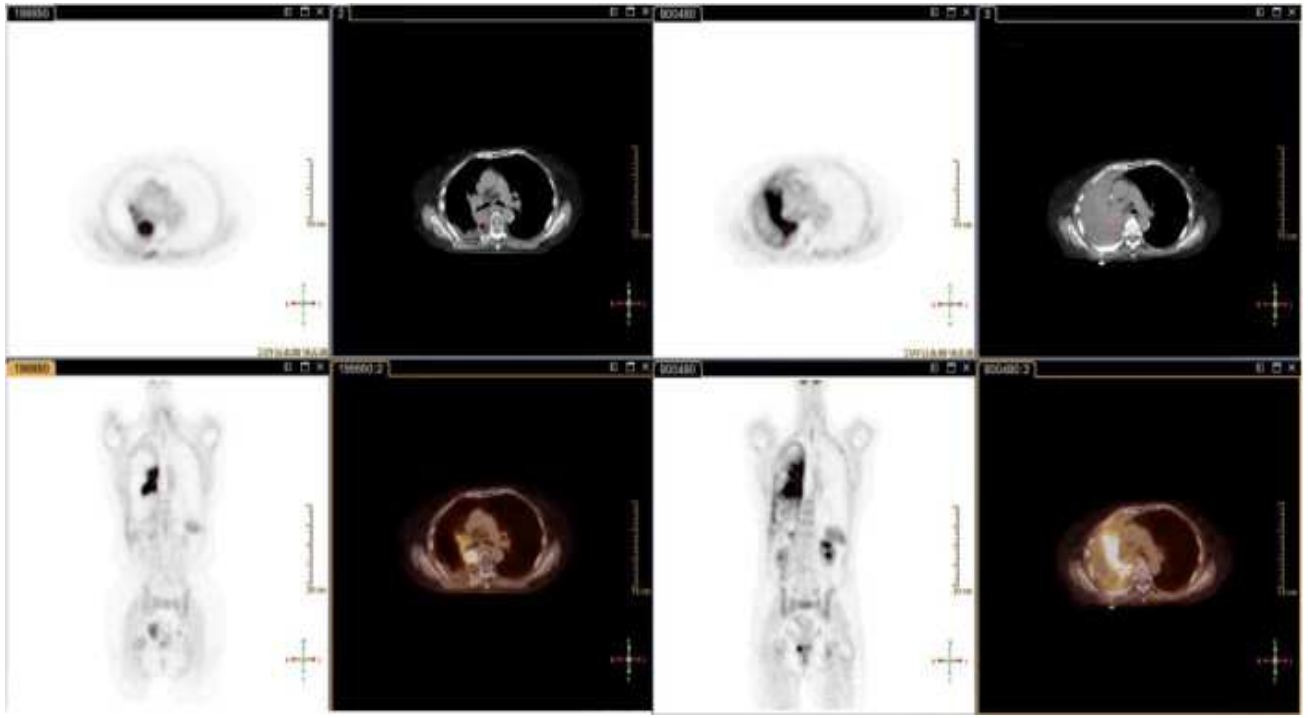

INSTITUT
JULES BORDET
INSTITUUT

ULB iris

PET-CT & Lung Cancer

Work up according to presumptive initial staging

- Patient eligible for curative treatment ?

PET-CT

- discloses previously unsuspected mets in 6-37% of cases
- Less futile thoracotomies
- Less futile high dose radiotherapies
- Accuracy PET-CT > CT abdomen + bone scan
- Impact in radiotherapy planning
- Be aware of the limits :
  - False negative (small or less avide T)
  - False positive (inflammatory lesions)
  - No image of the lower legs usually

Imaging and Nodal staging

For mediastinal nodes with a short axis≥ 1 cm

Criteria	CT	PET-CT
Sensitivity	55 %	62 %
Specificity	81 %	90 %
PPV	58 %	63 %
NPV	83 %	90 %

37 % of nodes between 2 and 4 cm are non metastatic (Mc Loud)

A pathological confirmation highly recommended

Silvestri GA, Chest 2013
De Leyn P, Eur J Cardiothorac Surg 2014
Mc Loud Radiology 1992

INSTITUT JULES BORDET INSTITUUT

ULB iris

Lymph nodes

Lymph nodes >1cm short axis or FDG+
→ consider Bx (R) if it has impact on TVD

Depending on location: EBUS, EUS,
Mediastinoscopy, US-guided

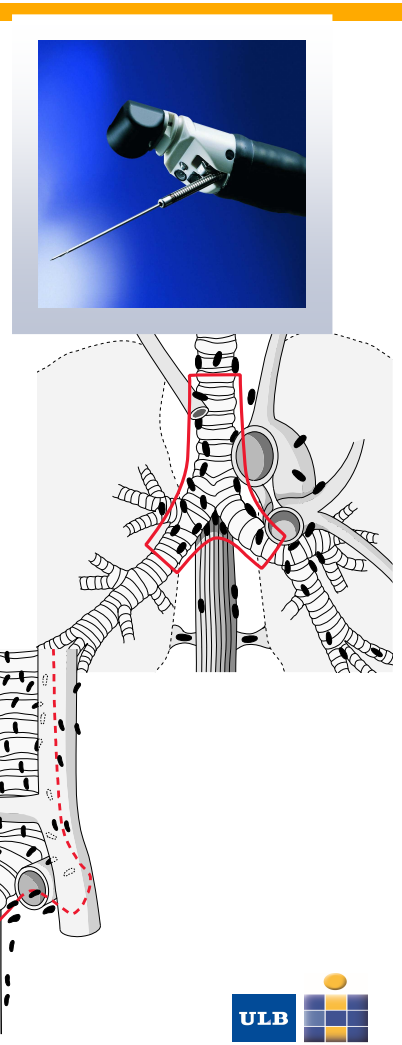

INSTITUT JULES BORDET INSTITUUT

ULB iris

CORRELATION PET-CT and PATHOLOGY
Analysed by nodal station

Billé et al

- 1001 nodal stations evaluated histologically
- 71 positive
- PET-CT identified 41 metastatic L.N. 57.7%

  19 N1 22 N2
- PET False negative : 30 nodal stations

  5 N1 24 N2 1 N3
- PET False positive : 14 nodal stations

  5 N1 9 N2

INSTITUT JULES BORDET INSTITUUT

ULB iris

3 NPV values compared*

Technique	N2 prevalence	Negative predictive value
Mediasti-noscopy	0.64	0.87 (0.78-0.93)
EBUS	0.50	0.85 (0.68-0.94)
EBUS/EUS	0.49	0.95 (0.81-0.99)

*Salamanca University Hospital 2012

Proposition of algorithm determining when to include LN in GTV based on expected prevalence of cancer for ≠ constellations of CT, PET, & E(B)US in literature

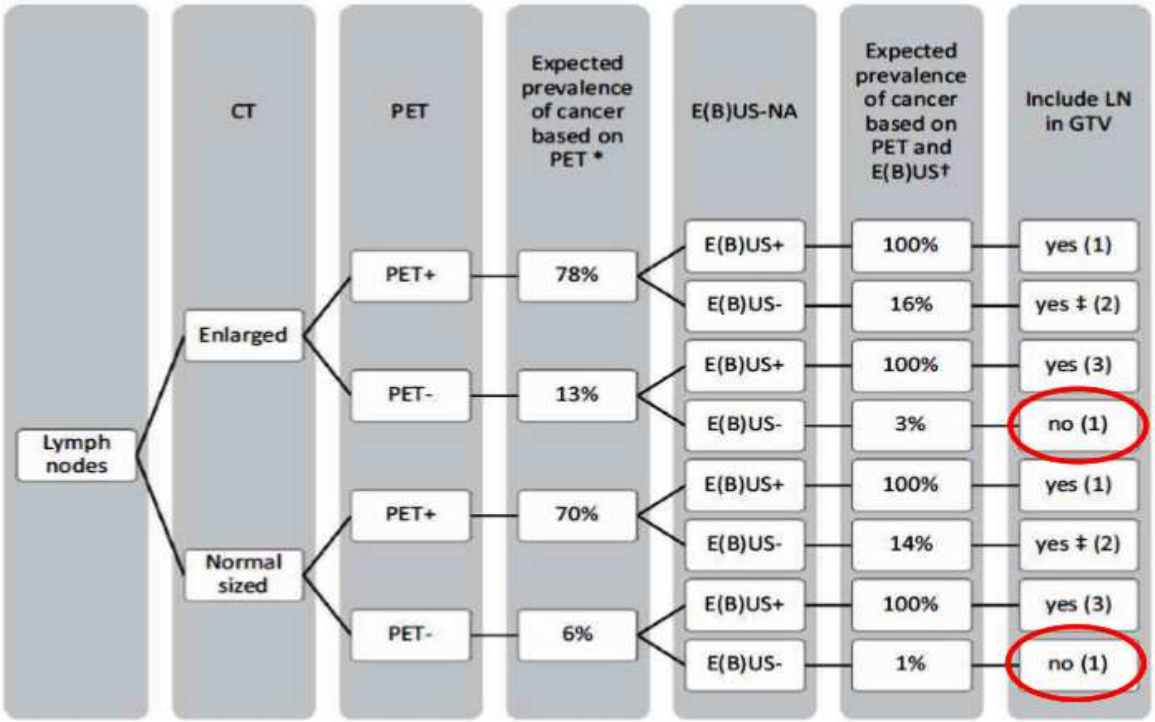

- Adding E(B)US to PET-CT decreases FN rate
- For PET (+) & E(B)US (-) LN, FN rates are still 14 to 16%
- Compared to PET-CT-based delineation only, adding E(B)US can increase but not decrease nodal GTV volume (unless valid benign reason for PET (+) at pathological examination in case of symmetrical PET (+) LN

Peeters S. T. et al. Radiotherapy & Oncology 2016; 120:273-278

GTV N propositions

Lymph nodes which are proven malignant by biopsy or considered pathologic on PET (focal accumulation above blood pool) are delineated as GTV. With respect to the inter-observer variation of reporting FDG-positive mediastinal nodes, in doubt, a node should rather be included

Lymph nodes that are FDG-PET-positive and EBUS/EUS-negative or negative in mediastinoscopy should be included in the GTV as the false negative rates of EBUS/EUS and mediastinoscopy are high

PET positive nodes may only be omitted, if there is clear non-malignant biopsy explanation for the FDG positivity GTV Nor if a mediastinoscopy has been performed showing no malingnancy in the nodes.

Possible additional tests

- Pulmonary volumes
- DLCO
- Exercise test if the above are <60%

3D CRT & LUNG CA RISK of RADIATION PNEUMONITIS

M. Graham experience Int.J.Rad. 45, 1999

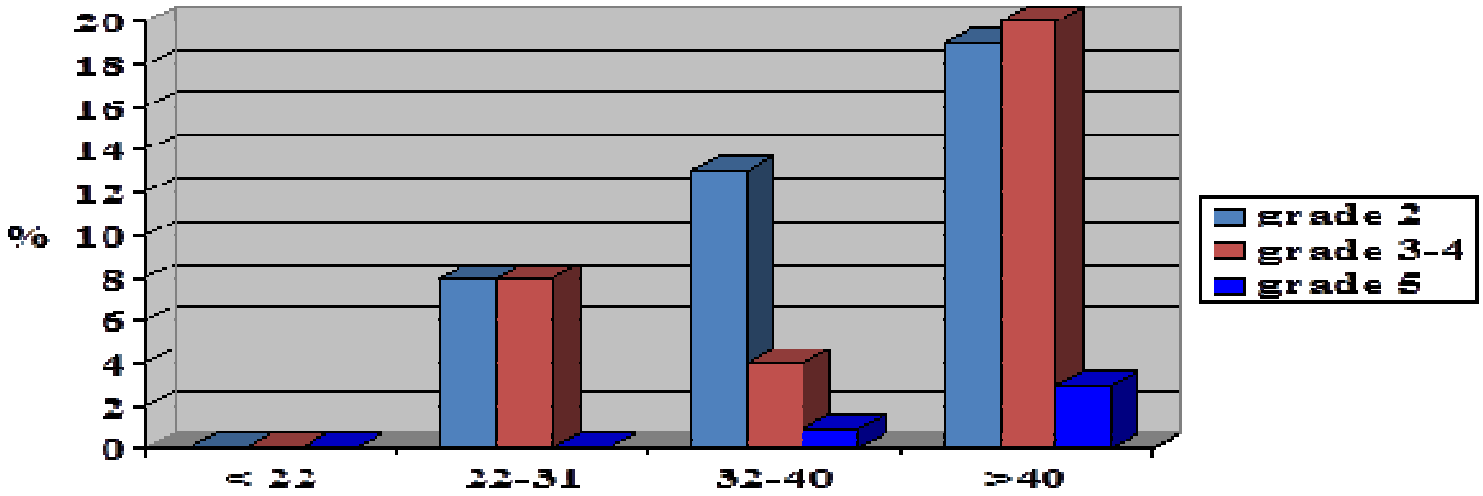

V_{20} (%)

This is only pure volumes and not functions

INSTITUT JULES BORDET INSTITUUT

ULB iris

Optimizing RT using lung perfusion information Seppenwoolde RO 2002

Pre-Rt perfusion distribution

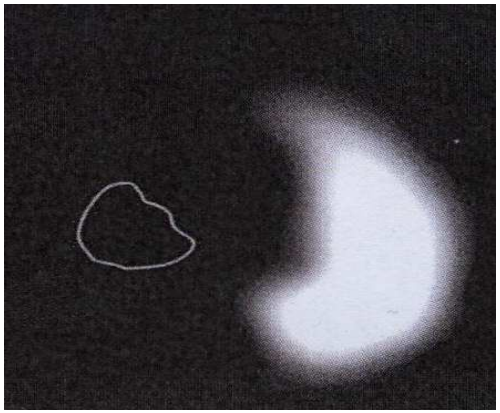

4 field technique

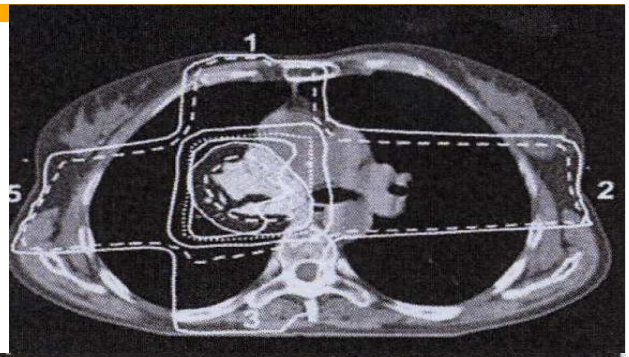

Optimized for the MLD

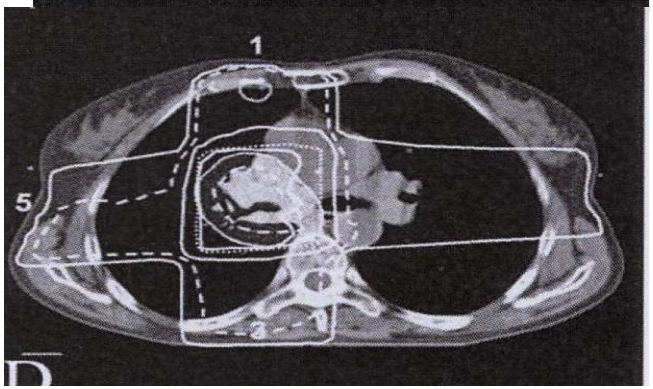

Optimized for the perfused MLD

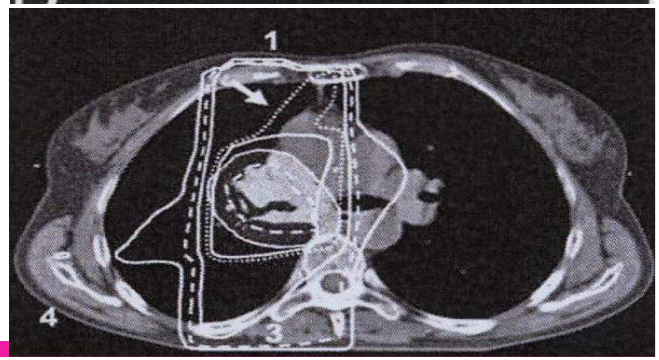

INSTITUT JULES BORDET INSTITUUT

Spect and Radiation pneumonitis
Farr et al Radioth Oncol 2015

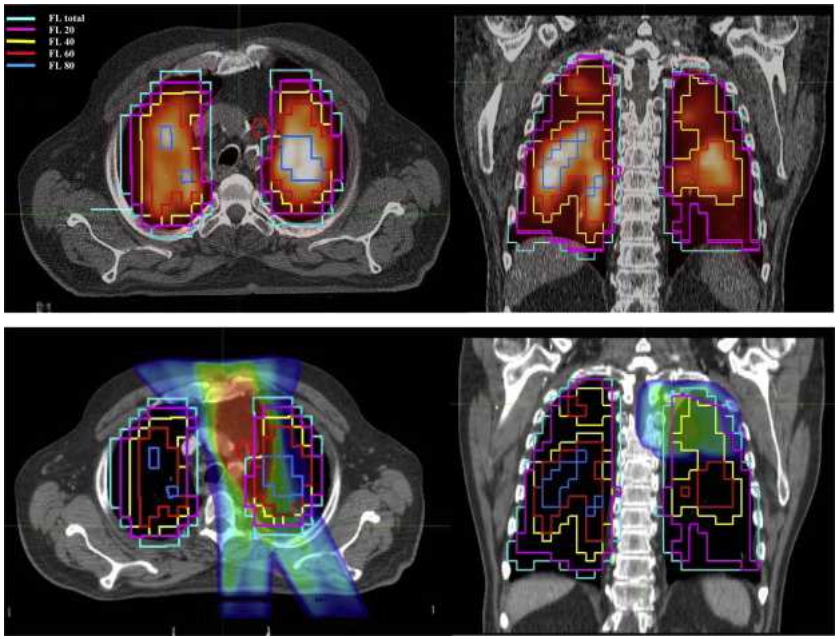

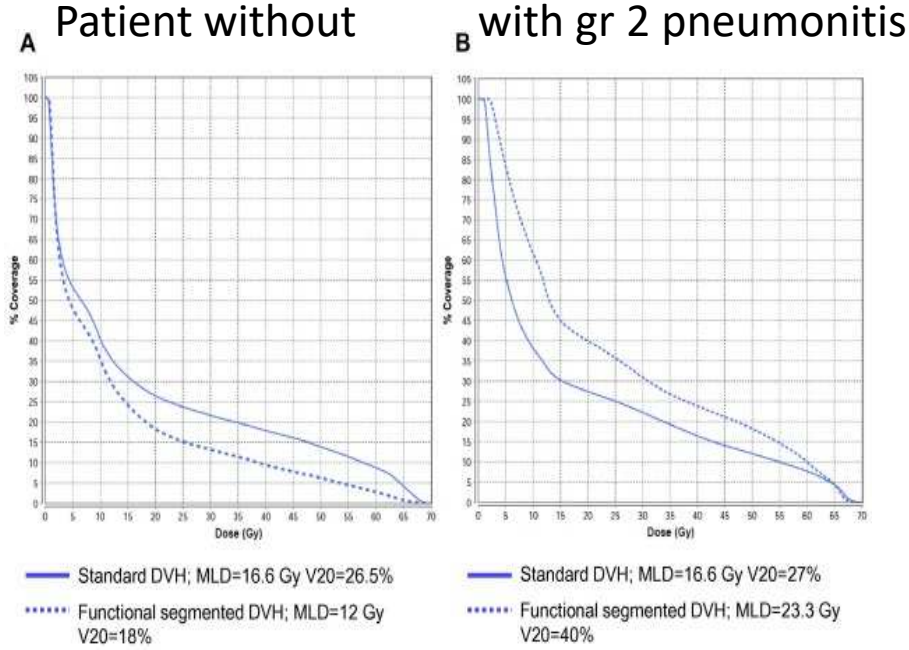

INSTITUT JULES BORDET INSTITUUT

ULB iris

PET & MR and GTV Contouring

ESTRO Lung Course

INSTITUT
JULES BORDET
INSTITUUT

ULB iris

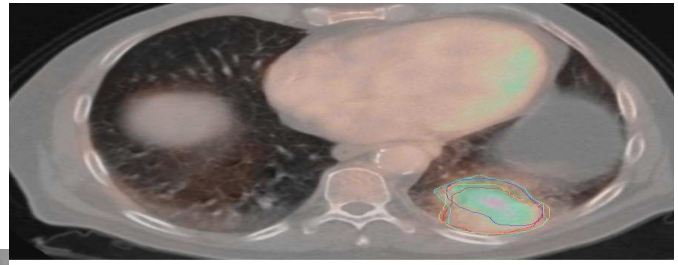

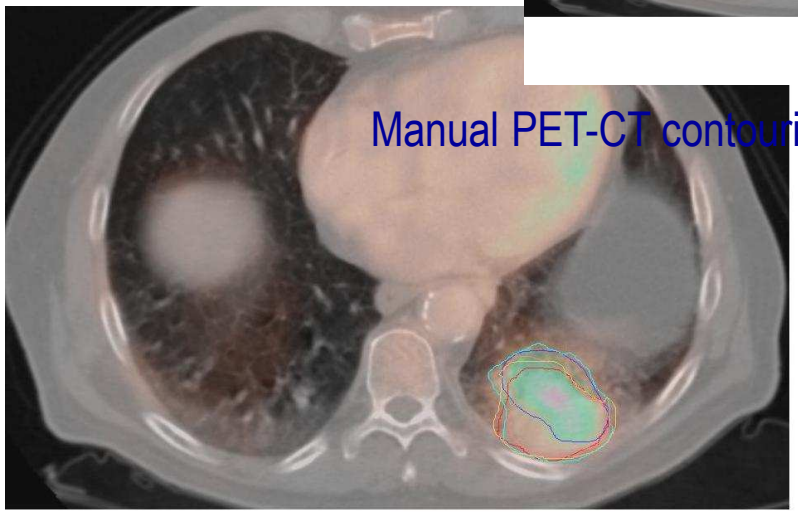

Manual PET-CT contouring

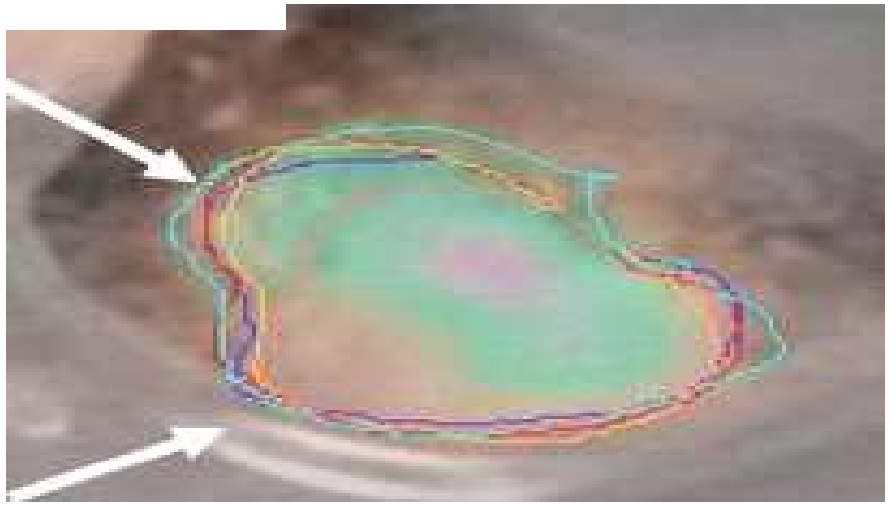

Automatic PET-CT contouring
+ manual editing

INSTITUT
JULES BORDET
INSTITUUT

van Baardwijk et al. Int J Radiat Oncol Biol Phys 2007

ULB iris

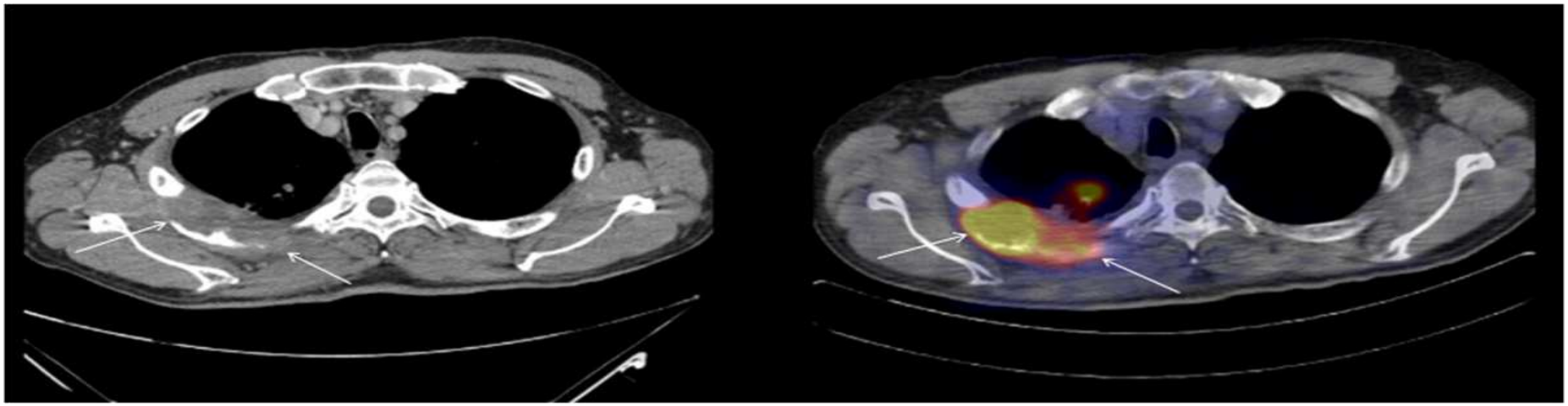

INSTITUT
JULES BORDET
INSTITUUT

ULB iris

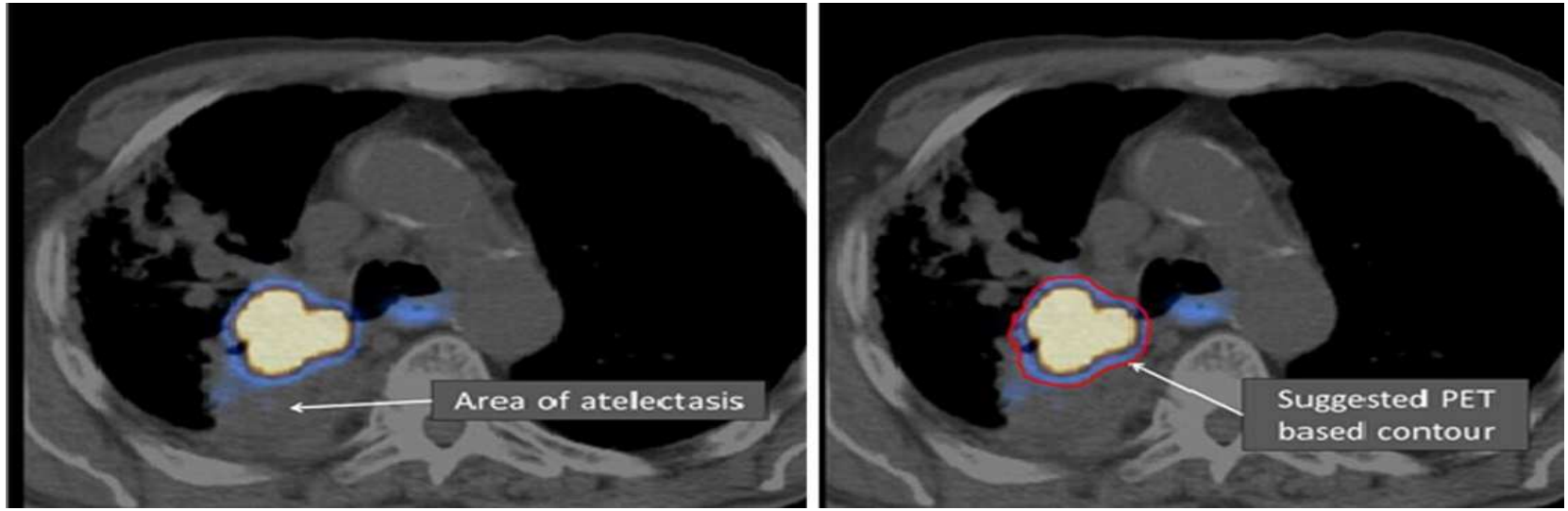
Area of atelectasis
Suggested PET based contour

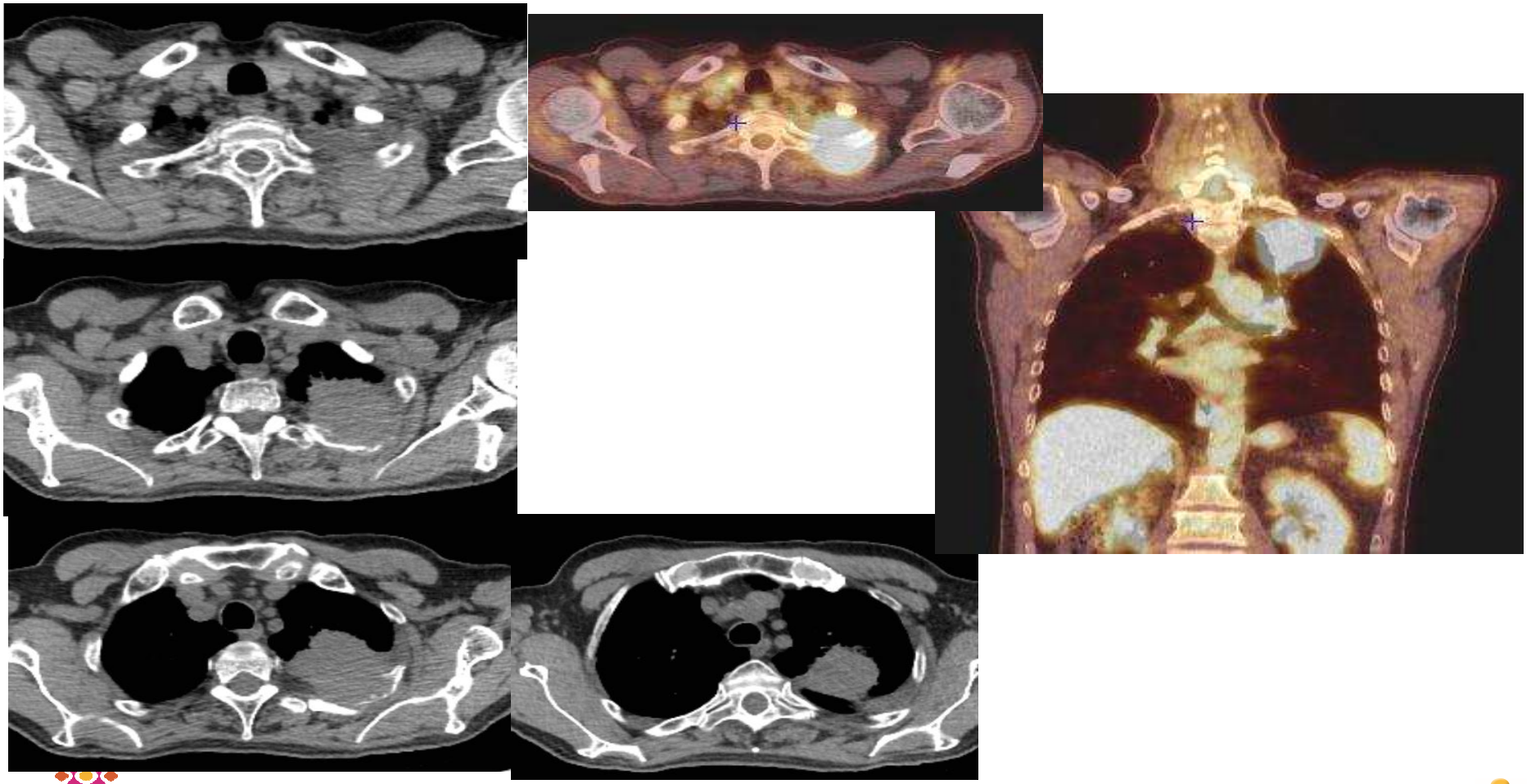

INSTITUT
JULES BORDET
INSTITUUT

ULB iris

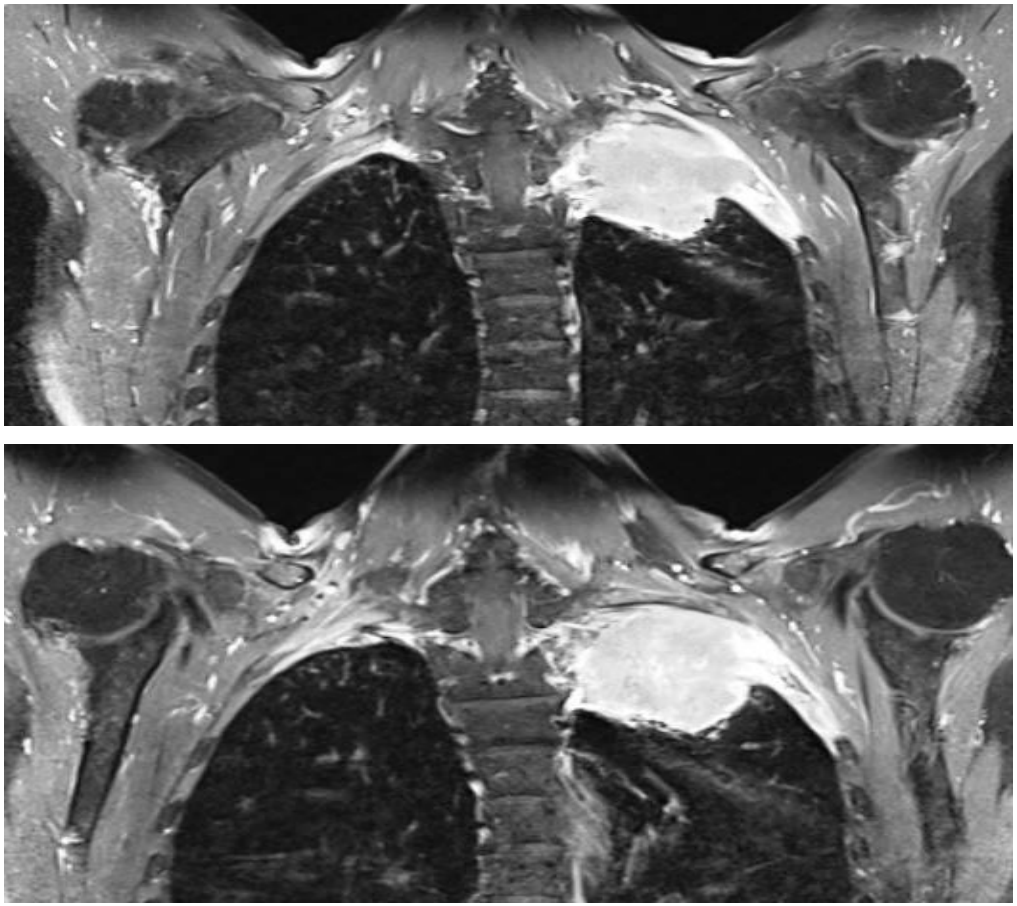

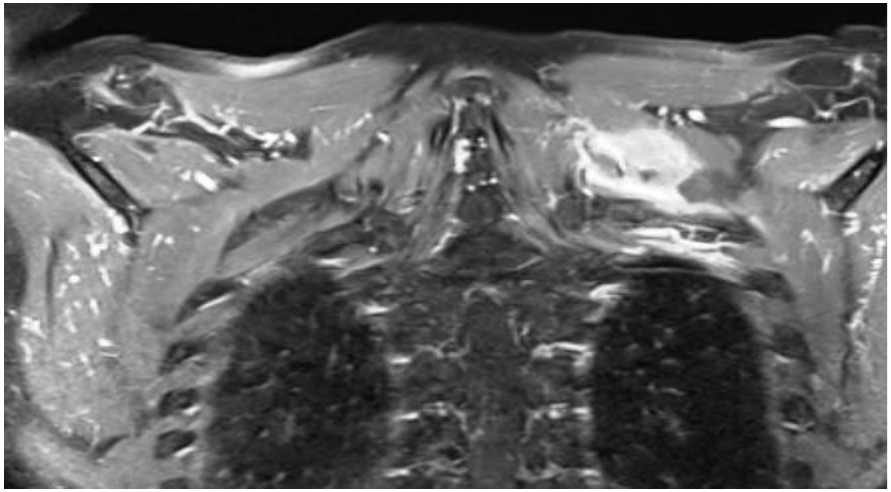

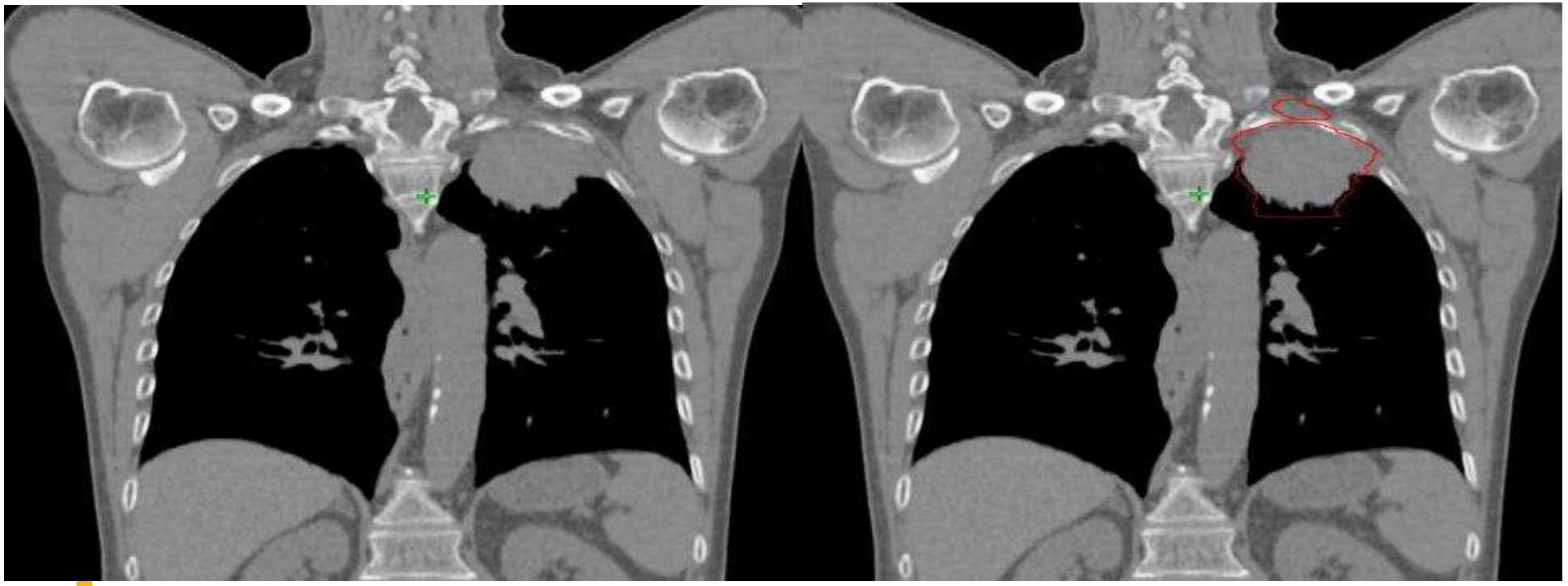

INSTITUT
JULES BORDET
INSTITUUT

ULB iris

Planning CT

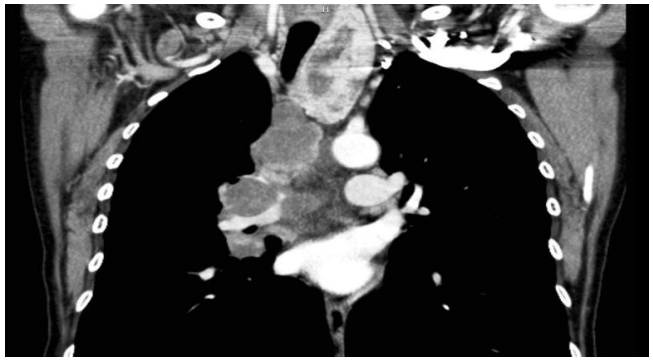

cricoid to mid-abdomen
2-3 mm
i.v. contrast

4D-CT with 8-10 phases

(Slow CT)

INSTITUT JULES BORDET INSTITUUT

ULB iris

GTV

On Planning-CT
Separate T and N
Post-chemo in lung
Pre-chemo in mediastinum
Mediastinum: W=400, L=20
Lung: W=1600, L=-600
Exclude atelectasis (PET)

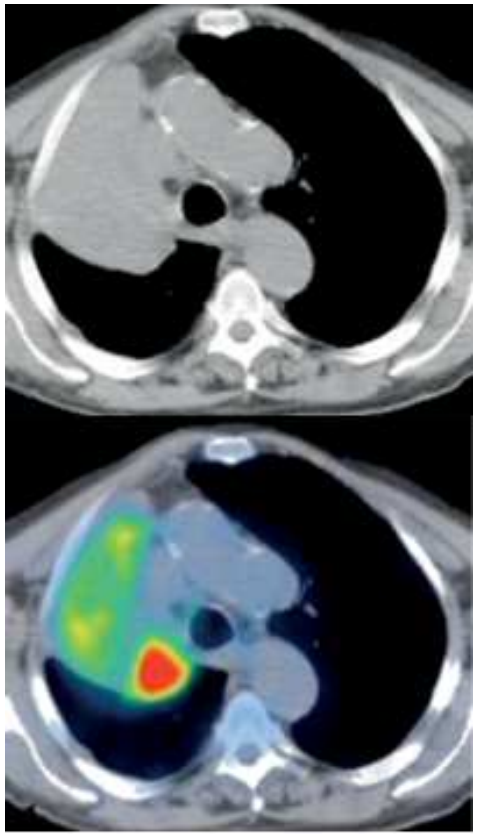

CTV primary

- Add 5-7 mm to GTV
- Exclude natural barriers (e.g. bone)

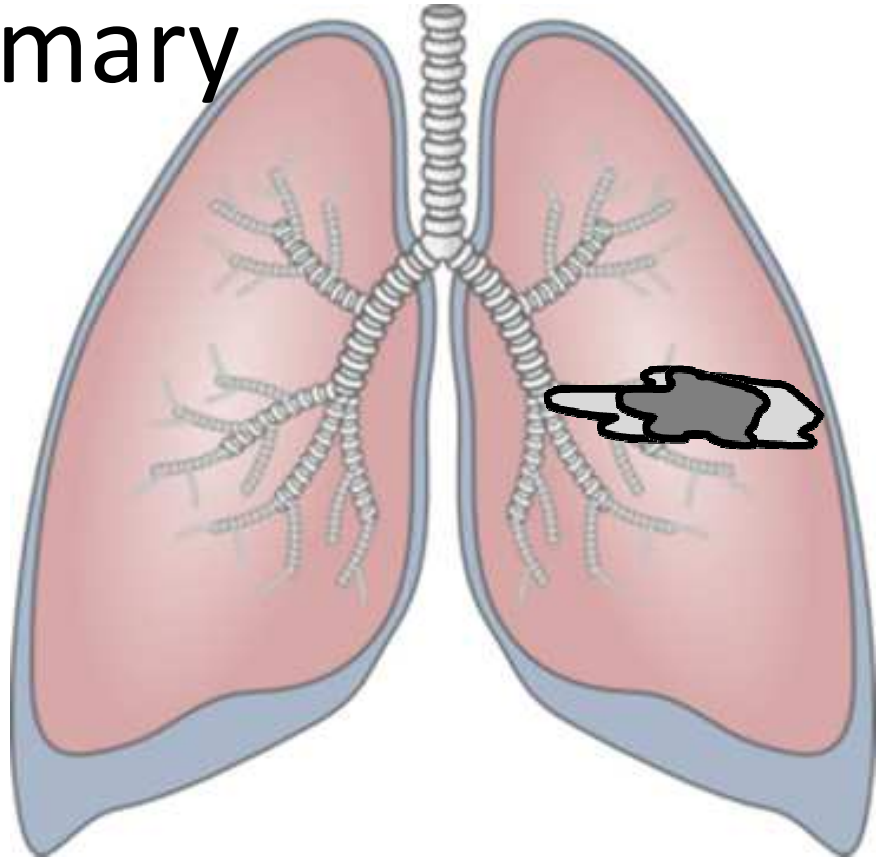

INSTITUUT JULES BORDET INSTITUUT

ULB iris

Microscopic tumor extension
Giraud et al Int.J.Radiat.2000
70 surgical resection

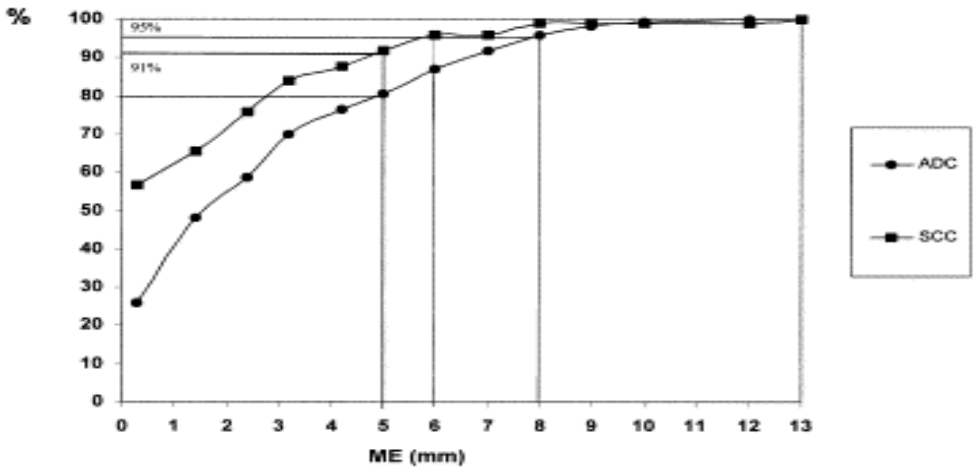

Adenoca

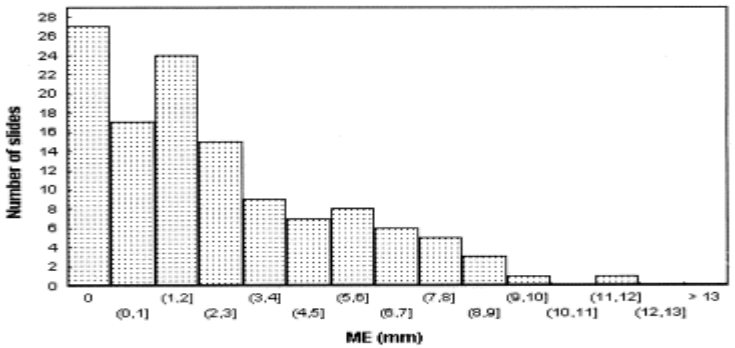

Squamous C

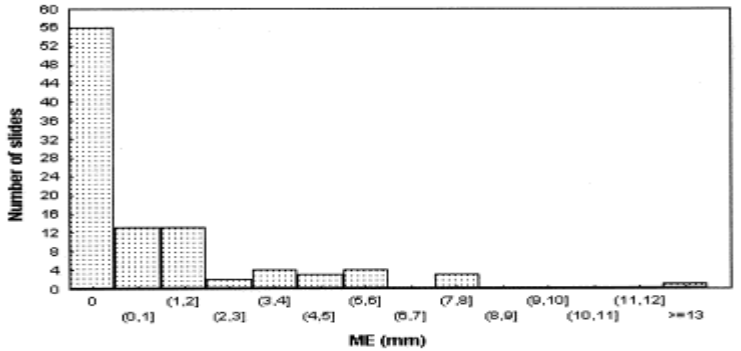

INSTITUT
JULES BORDET
INSTITUUT

ULB iris

Do you agree with this CTV ?

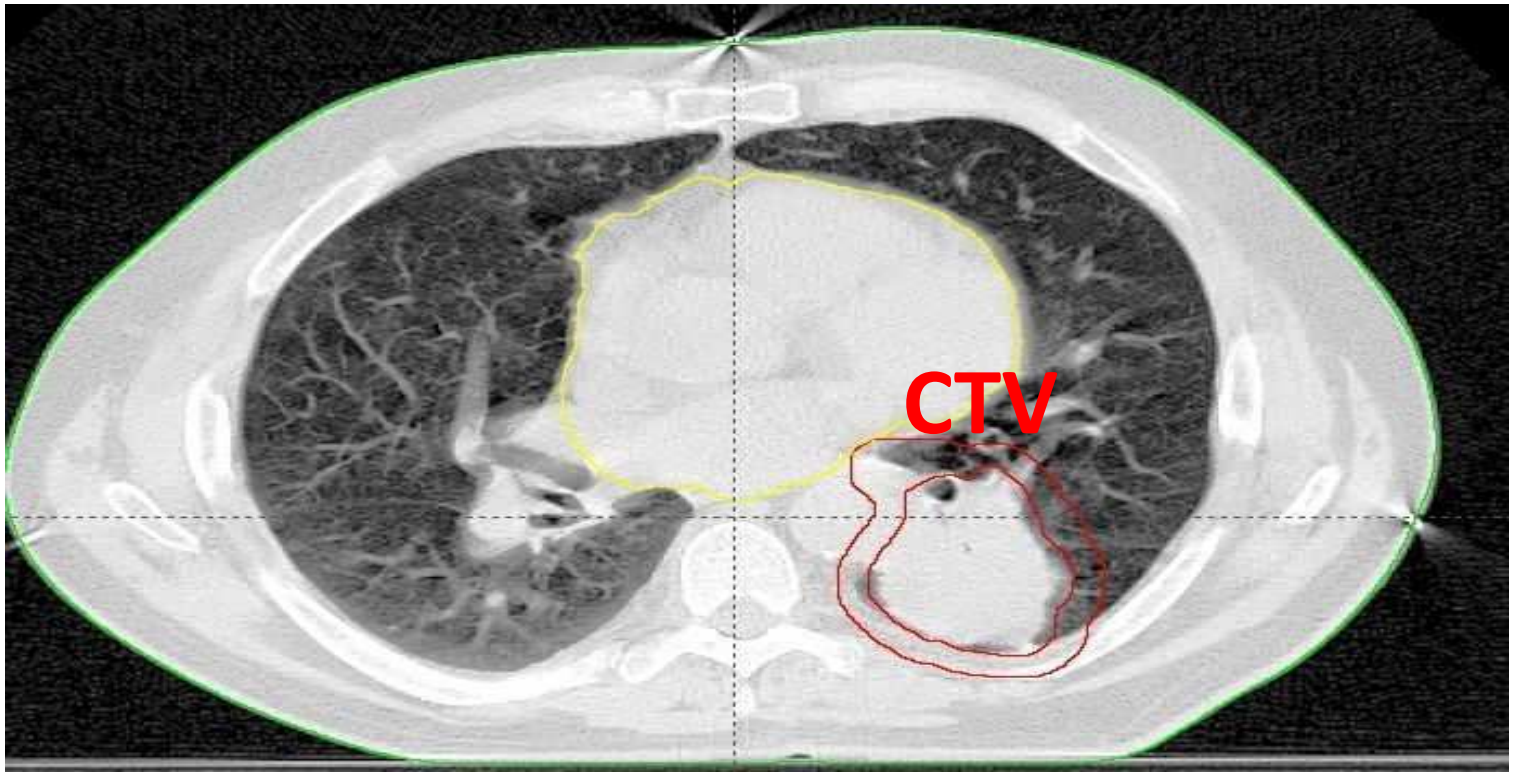

INSTITUT
JULES BORDET
INSTITUUT

ULB iris

NSCLC
ELECTIVE NODAL RT

- Large fields irradiation: classical approach in the past, very effective to control microscopic disease but

✓ A major limitation to escalate the dose (larger volume of irradiated normal tissue)

✓ Isolated mediastinal failure is an uncommon
The major issue: GTV disease control

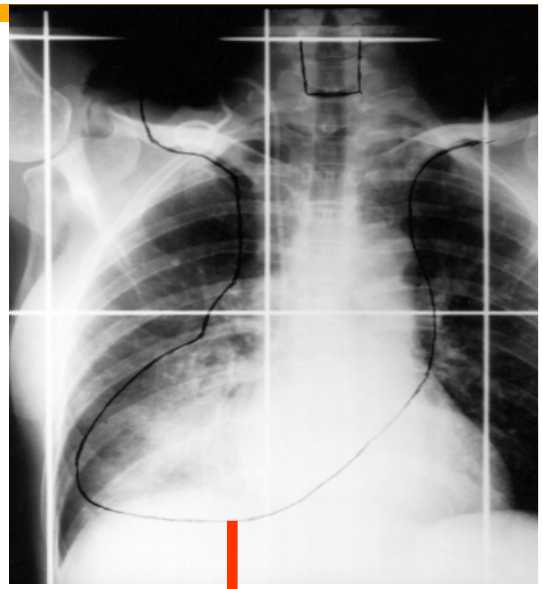



INSTITUT
JULES BORDET
INSTITUUT

NSCLC Lung Cancer Patterns of Local Failure Dosimetric Analysis Moreno-Jiménez et al RO 2008

- Induction chemotherapy followed by concurrent chemoradiotherapy
- 65 patients with 36 ENI and 29 IFI
- First documented site of progression : 18 local failure
- Failures were compared to the initial treatment planning and a GT recuurence was drawn
- Reference was the 95 % ICRU prescription dose

Failure	N	Def.
Central	9	> 80 %
Marginal	8	20 – 80 %
Outside	1	< 20 %

No isolated nodal failure

INSTITUT JULES BORDET INSTITUUT

ULB iris

3D CONFORMAL RT : LUNG CA

Elective Nodal Irradiation Rosenzweig et al

2 Y local control : 38 %
2 Y Elective nodal control : 91 %

Nodal R	N° Pts	Dose Median	Dose >40 Gy	N° failure
• Ipsil. Supracl.	125	0	8%	2
• Contralat supracl.	132	0	0	4
• Ipsilat sup.med.	115	18	34%	0
• Contralat sup.med	129	5	8%	1
• Ipsilat.inf.med.	59	60	63%	2
• Contral.inf.med.	121	18	21%	2
• Subcarinal	91	32	41%	2

INSTITUT JULES BORDET INSTITUUT

ULB iris

Involved field or Elective Nodal RT
A Phase III trial in NSCLC
Yuan et al Am.J.Clin.Oncol.

Chemotherapy
DDP 25 mg/m^2 d1-3 q 3w
VP16 75 mg/m^2 d1-5

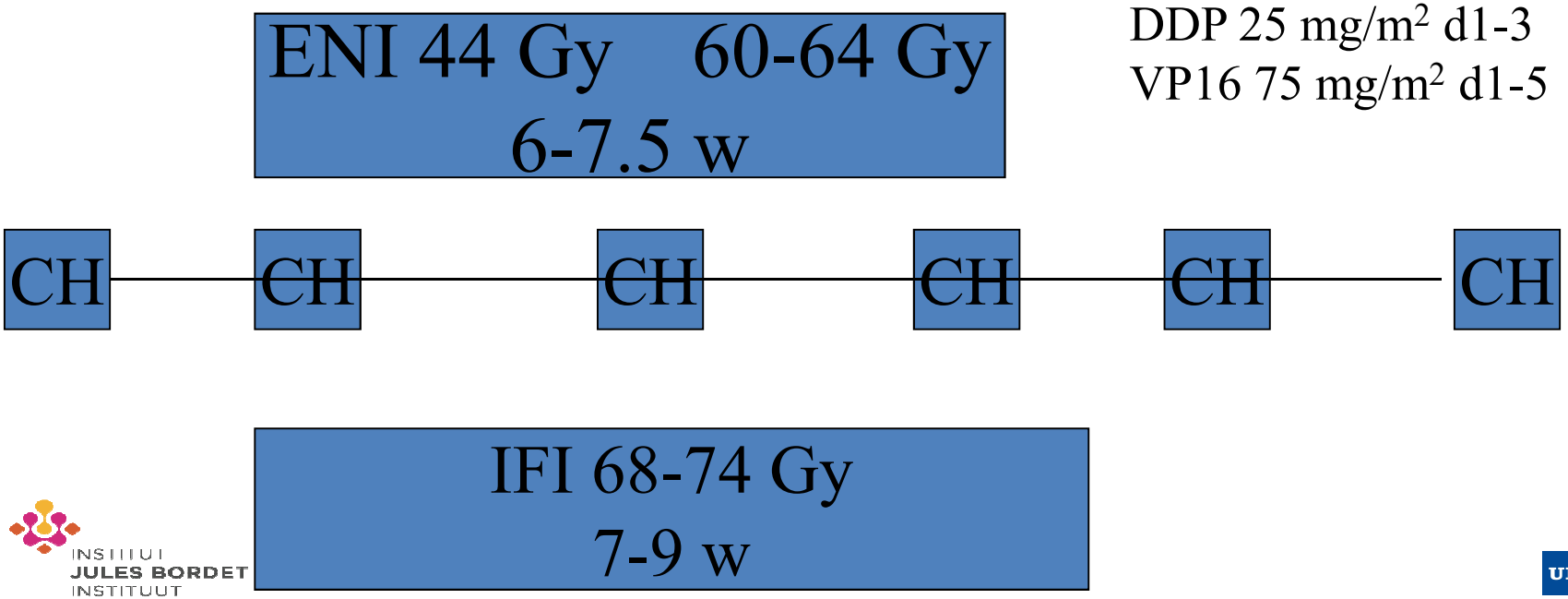

INSTITUT JULES BORDET INSTITUUT

ULB iris

Involved field or Elective Nodal RT A phase III trial

Lung Toxicity *Yuan et al Am.J.Clin.Oncol*

Lung V_{20}	ENI %	IFI %	p
< 20 %	45	75	< 0.001
20-25 %	35	18	0.007
26-30 %	15	6	0.04
> 30 %	6	1	0.056

	ENI %	IFI %	p
Radiation Pneumitis	29	17	0.044
Gr 1	8	6	0.579
Gr 2	18	10	0.103
Gr 3	3	1	
Gr 4	0	0	

INSTITUT JULES BORDET INSTITUUT

ULB iris

Involved field or Elective Nodal RT A Phase III trial in NSCLC
Local Control & Survival
Yuan et al Am.J.Clin.Oncol.

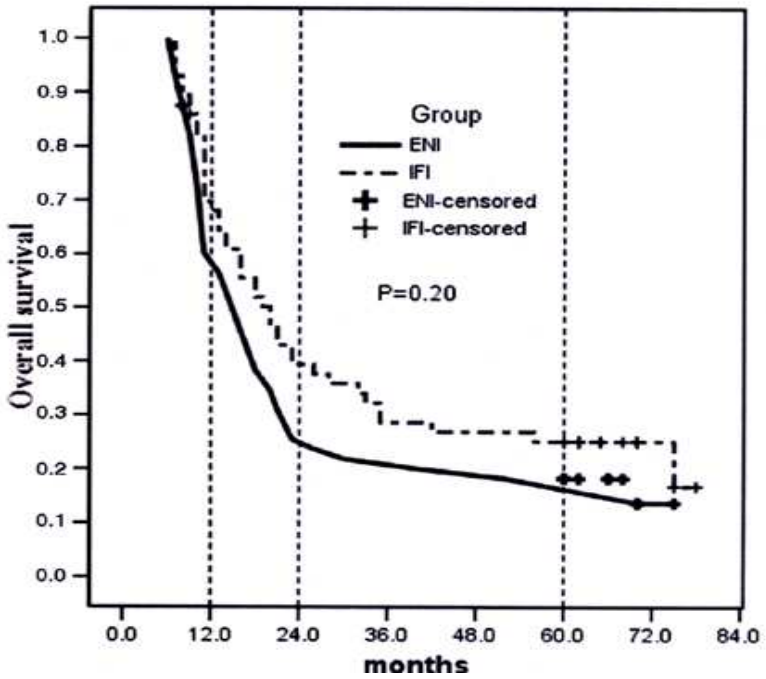

	ENI	IFI
N patients	100	100
Local Control		
1 Y	73 %	81 %
2 Y	51 %	59 %
5 Y	36 %	51 %
Failure		
Elective nodal	4 %	7 %
Involved field	55 %	38 %

INSTITUT JULES BORDET INSTITUUT

ULB iris

Lymphadenectomy

N1: Intrapulmonary, lobar, hilar

N2:: 3 stations (lobe-dependent)

RUL and ML	7 + 2 among 2,3,4
RLL	7+4 + (8 o 9)
LUL	7 + 5 + 6
LLL	7 + 8 + 9

6 nodes: 3 N1 + 3 N2

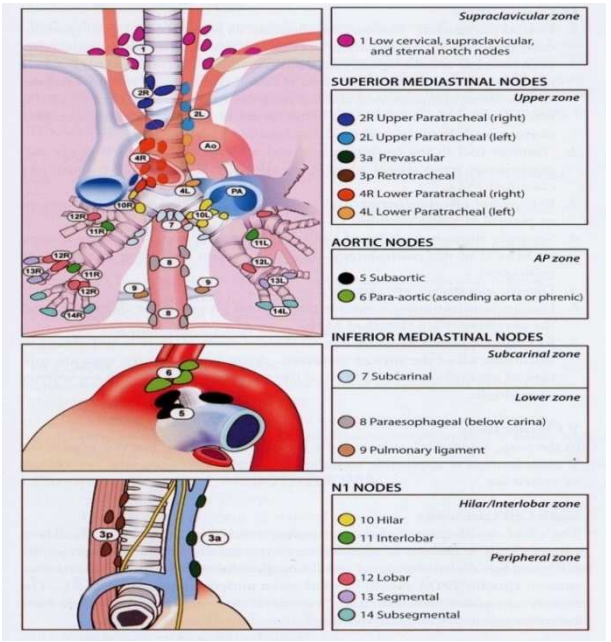

ESTS/IASLC guidelines, 2006

ESTRO School

Complete resection in lung cancer surgery: proposed definition

Ramón Rami-Porta[a,*], Christian Wittekind[b], Peter Goldstraw[c]

for the International Association for the Study of Lung Cancer (IASLC) Staging Committee[1]

1. Free resection margins (macro and microscopic) at the bronchial, peribronchial tissue, vascular (venous and arterial, and any peripheral or adjacent organ resected tissue
2. Systematic or lobe-specific nodal dissection including at least 6 node stations (3 hilar and 3 mediastinal including No. 7)
3. No extracapsular node involvement
4. The highest mediastinal node must be negative

Lung Cancer, 2005

The CTV N

INSTITUT
JULES BORDET
INSTITUUT

ULB iris

Microscopic extracapuslar extensionin NSCLC

Yuan S Int J Radiat Oncol Biol Phys 2007

ECE 101/243 patients

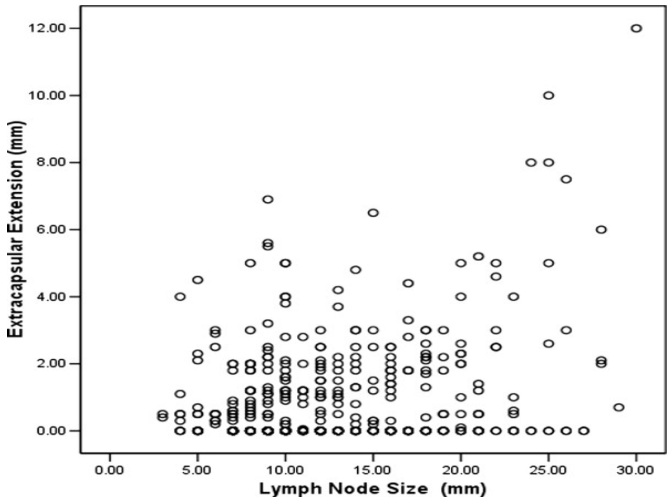

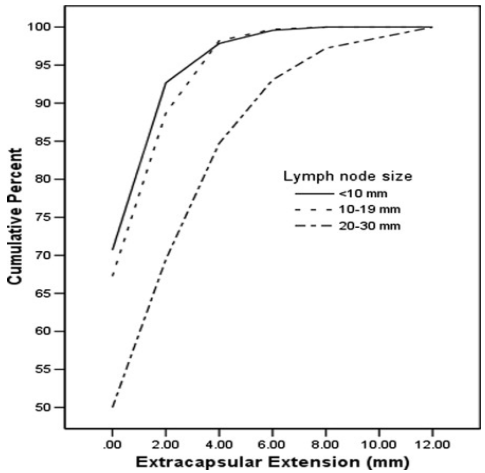

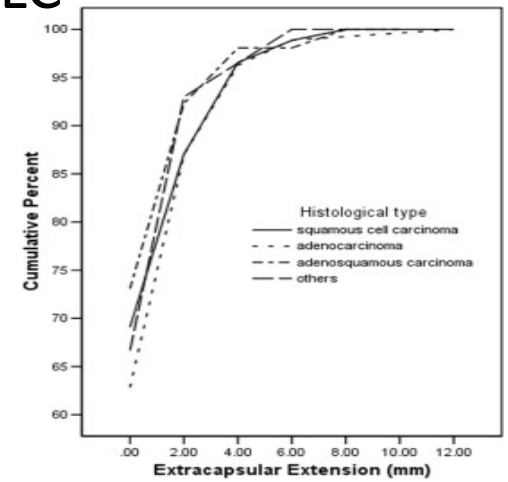

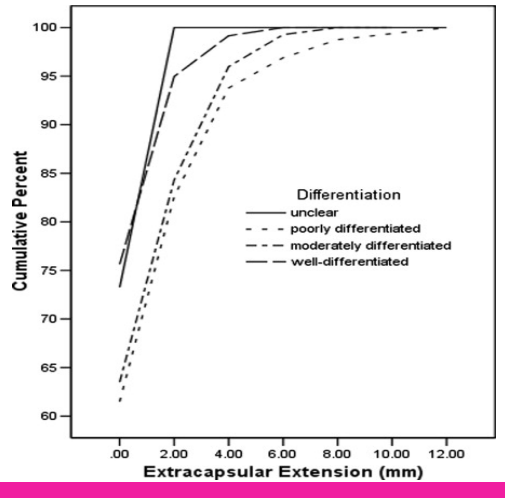

Conclusion : margins 3 mm LN< 20 mm

> ? LN ≥ 20 mm

INSTITUT JULES BORDET INSTITUUT

CTV N

Affected Lymph node station



INSTITUT
JULES BORDET
INSTITUUT

ULB iris

CTV N

Affected Lymph node station

2nd choice: 5-7 mm margin

nodal irradation

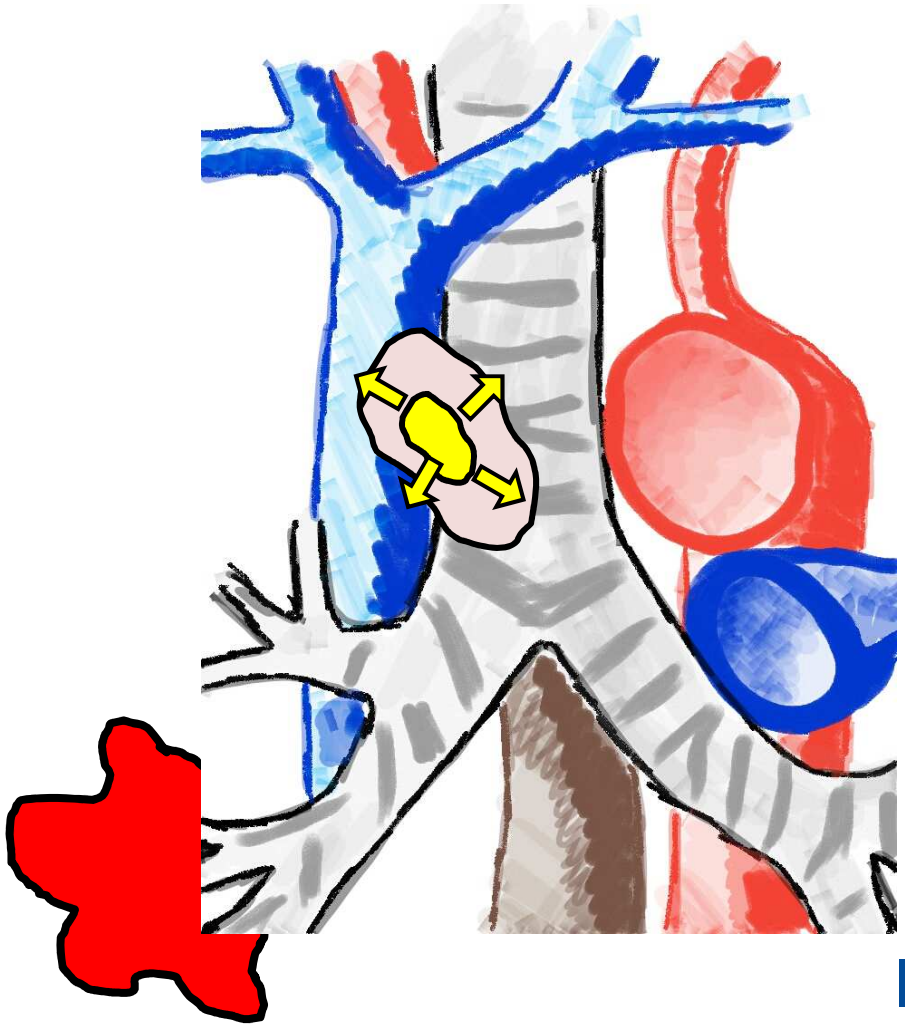

INSTITUT JULES BORDET INSTITUUT

ULB iris

CTV lymph nodes

Affected Lymph node station

2nd choice: 5-7 mm margin

5-7 mm beyond level

No elective nodal irradiation

Optional:

- **neighbouring**
- **hilar**
- **In-between**



INSTITUT JULES BORDET INSTITUUT

ULB iris

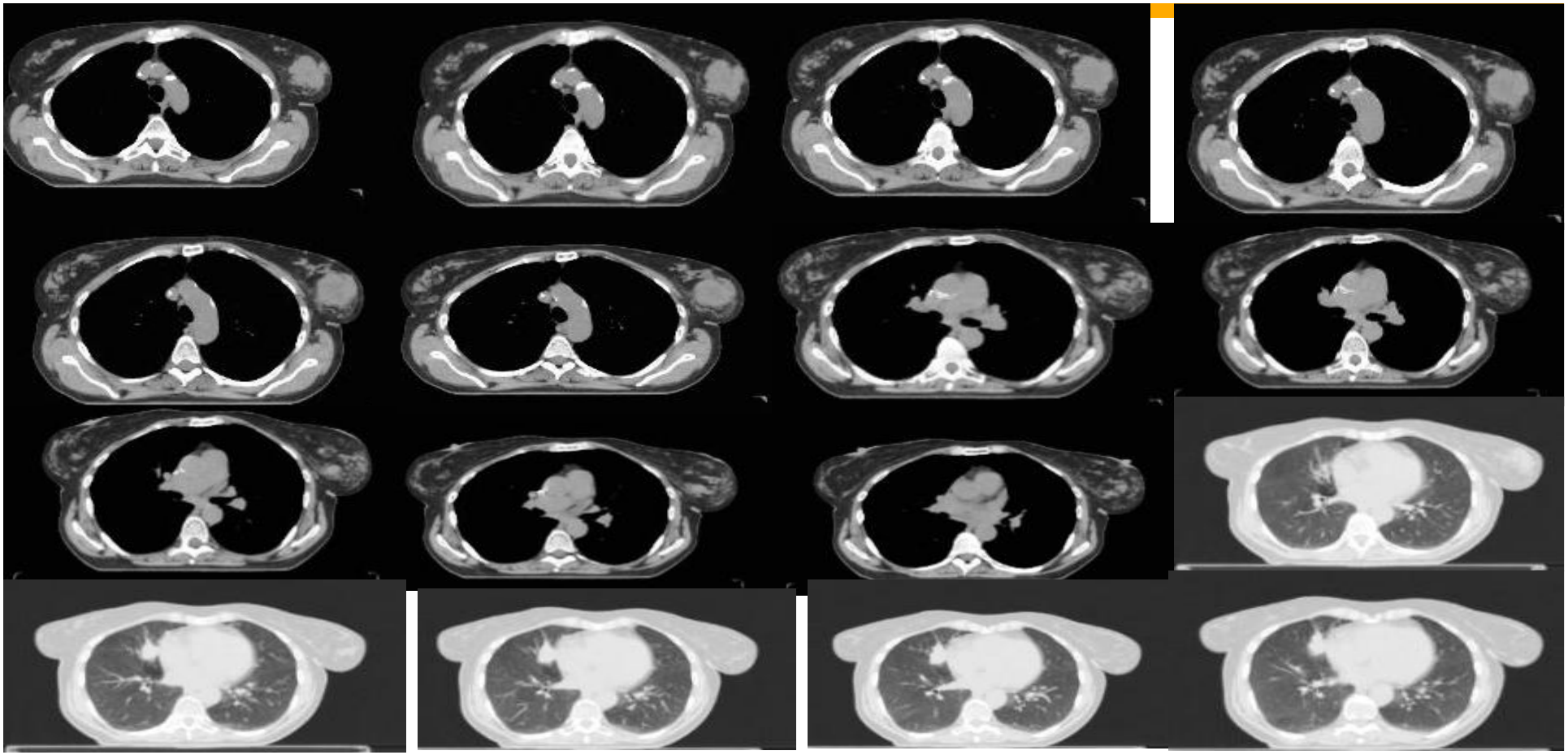

INSTITUT
JULES BORDET
INSTITUUT

ULB iris

A problem with no consnensus

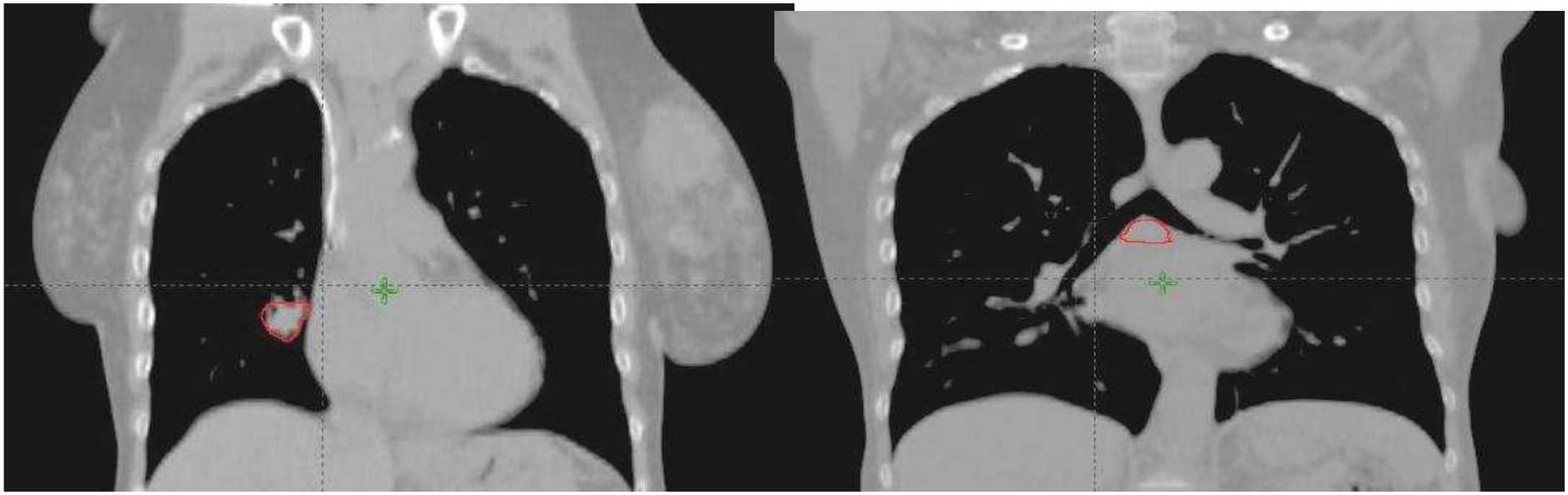

To treat or not the area between T and N

INSTITUT
JULES BORDET
INSTITUUT

ULB iris

ITV

- Based on tumour position from all breathing phases (iGTV or CTV variation – both an option)
- or
- Mid-ventilation + Margins (derived from 4DCT)
- Tracking/gating – “not routine”

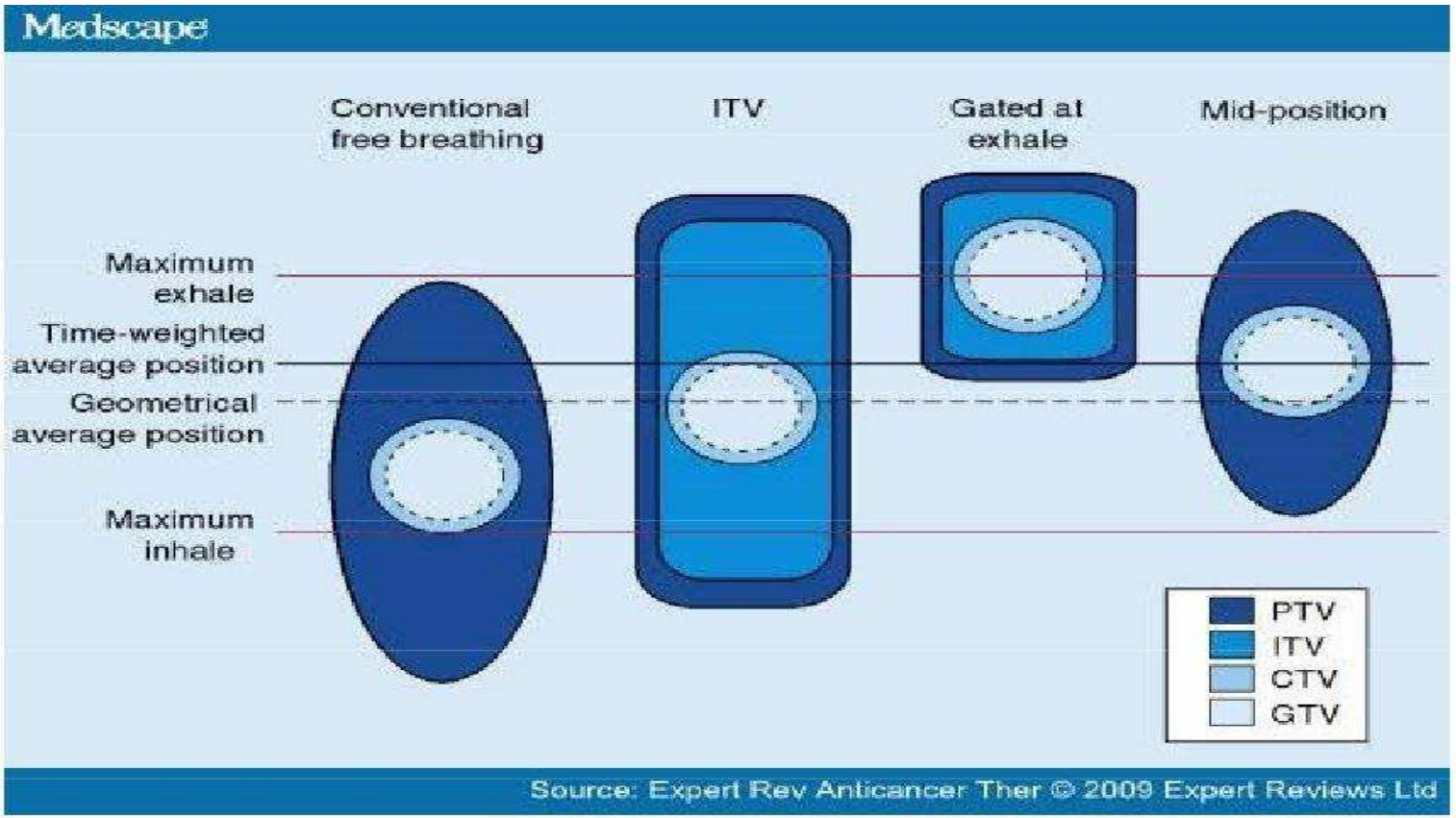

INSTITUT JULES BORDET INSTITUUT

ULB iris

DOSE RESPONSE RTOG TRIAL
Cancer 1980

Schedule	Loc Rel %	Med Surv Weeks
40 Gy/ 10 fr split	44	36
40 Gy/ 20 fr / 4 w	48	45
50 Gy/ 25 fr / 5 w	38	41
60 Gy/ 30 fr / 6 w	27	47

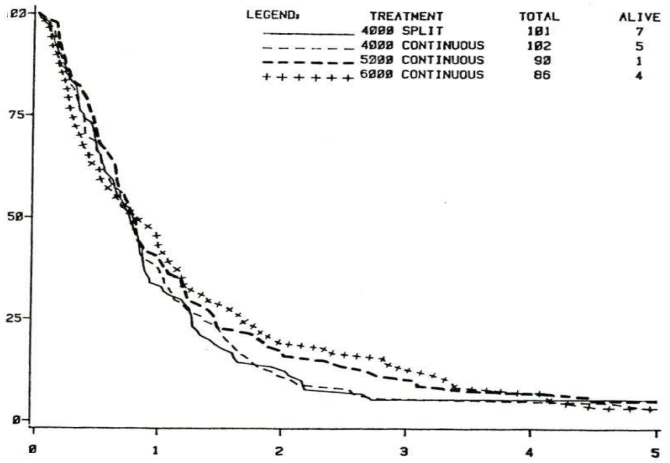

60 Gy in 6 weeks
The gold standard

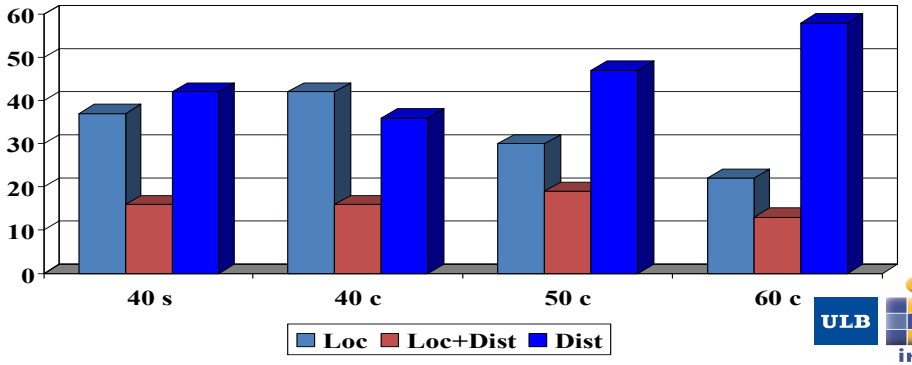

INSTITUT JULES BORDET INSTITUUT

ULB iris

RTOG III trial

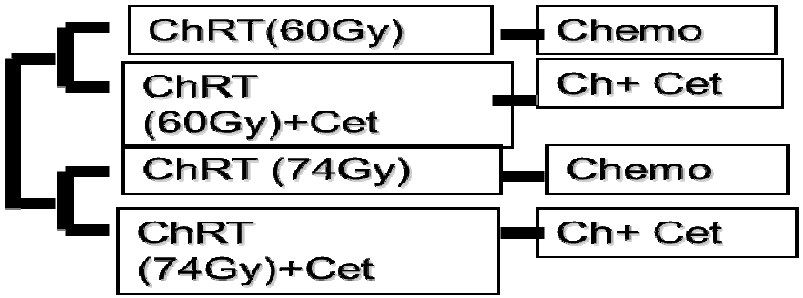

2 Y survival 50 %
More relapse after 74 Gy

Bradley Lancet Oncology

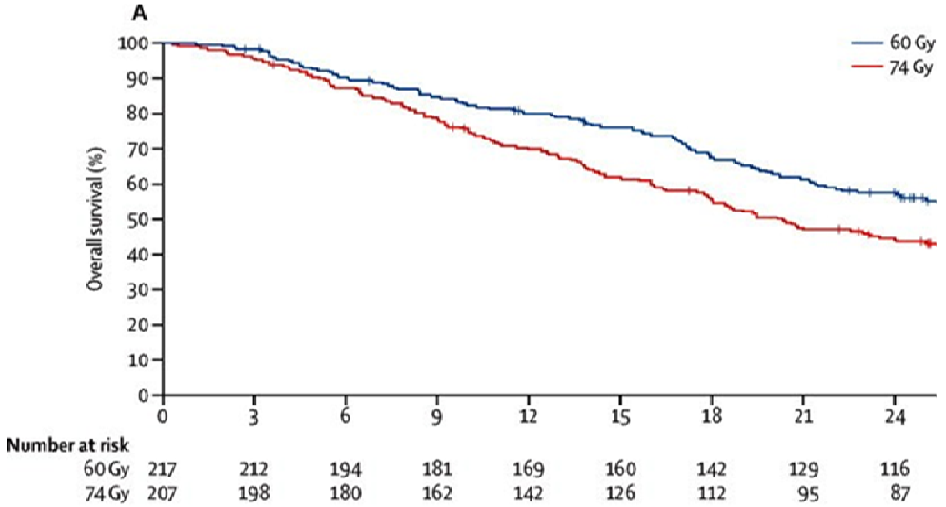

2 Years locoregional relpase rate

60 Gy 30.7% 74 Gy 38.6%

But 60 % of patients introduced by centre including less than 4 patients

INSTITUT JULES BORDET INSTITUUT

ULB iris

Is IMRT safe for Stage III NSCLC
A subgroup analysis of RTOG 0617

Characteristic	3D-CRT	IMRT	P-Value
Stage IIIB	30 %	39 %	0.056
PTV	427 mL	486 mL	0.005
PTV:lung ratio	0.13	0.15	0.013

More advanced T with IMRT
Larger volume irradiated

2 Y Outcome	OR (95% CI)	P-value
Overall survival	1.01 (0.8-1.28)	0.95
Progression free surv	1.12 (0.91-1.39)	0.28
Local control	0.91 (0.67-1.23)	0.54
Distant metastatic free	0.92 (0.71-1.19)	0.52

No difference in outcome even for more advanced cases

Outcome	3D-CRT	IMRT	P-value
Grade 3+ pneumonitis	8 %	3.5 %	0.0462
Heart V40	11.4 %	6.8 %	0.0026
Full consolidative chemo.	29 %	37 %	0.05

V20 important prognostic factor and not V5

INSTITUT JULES BORDET INSTITUUT

No difference in esophagitis, weight loss cardiovascular effects

ULB iris

Organs at risk *ACROP guidelines*

Standard:

Lung (single & both) – GTV

Spinal canal (as safety surrogate for spinal cord)

Whole heart, Oesophagus

Individual:

Brachial plexus, Lungs-PTV

Not required:

Chest wall, central bronchial tree

Atlas :Examples

Lymph nodes

Lynch R et al. Pract Radiat Oncol. 2013;3:54-66

Organs at risk

Ritter T et al. IJROBP 2011;81:1442-57.
Feng M Kong et al. IJROBP 2011;79:10-8

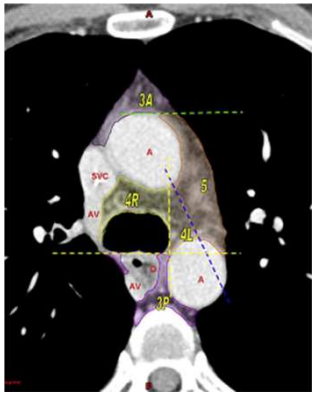

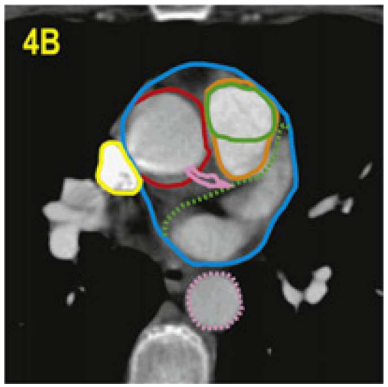

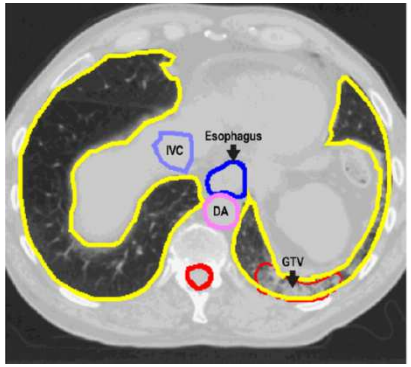

INSTITUUT JULES BORDET INSTITUUT

ULB iris

RTOG®
RADIATION THERAPY ONCOLOGY GROUP

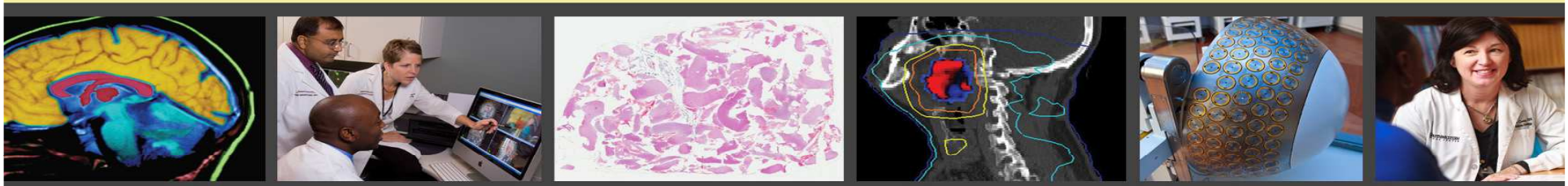

Atlases for Organs at Risk (OARs) in Thoracic Radiation Therapy

Feng-Ming (Spring) Kong MD PhD
Leslie Quint MD
Mitchell Machtay MD
Jeffrey Bradley MD

ACR® AMERICAN COLLEGE OF RADIOLOGY

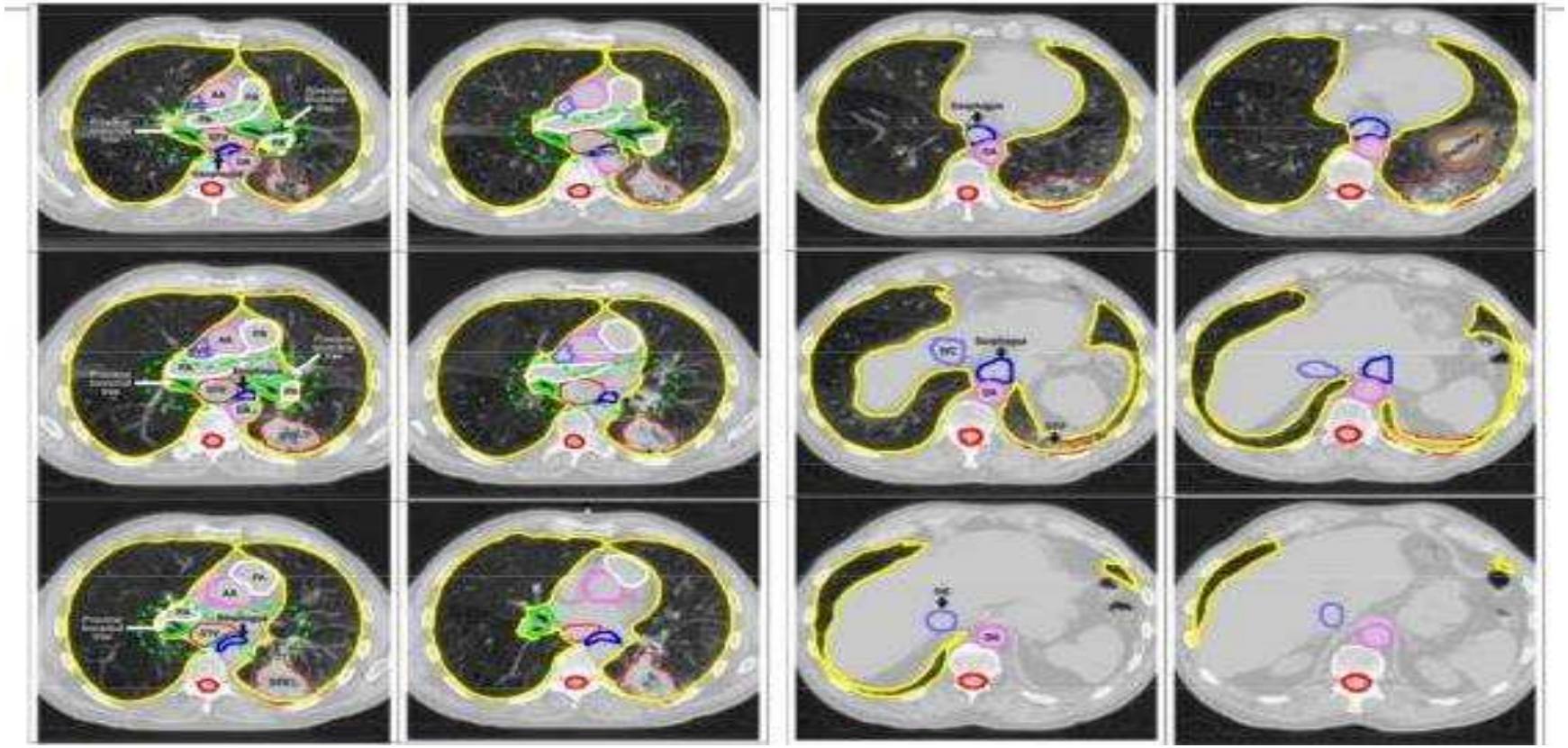

INSTITUT
JULES BORDET
INSTITUUT

ULB iris

Cardiac toxicity after radiochemotherapy for stage III NSCLC treated at University of North Carolina Wang WCLC 2016 & JCO 2017

RTOG trial (Bradley) : cardiac toxicity related to the dose to the heart

RT Dose

70 - 90 Gy

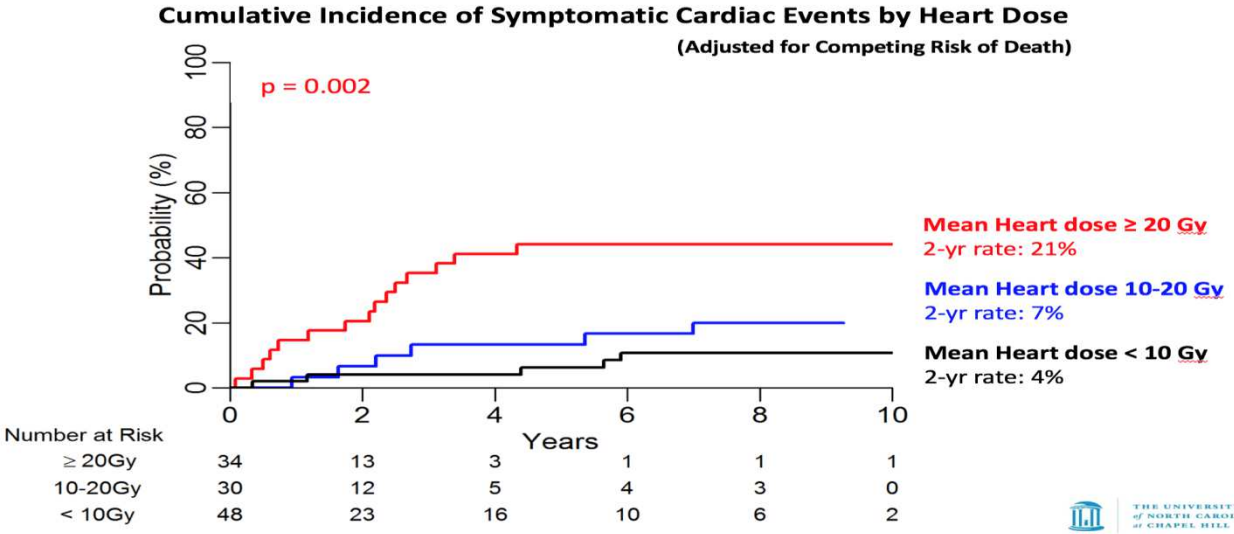

INSTITUT JULES BORDET INSTITUUT

THE UNIVERSITY of NORTH CAROLINA at CHAPEL HILL

ULB iris

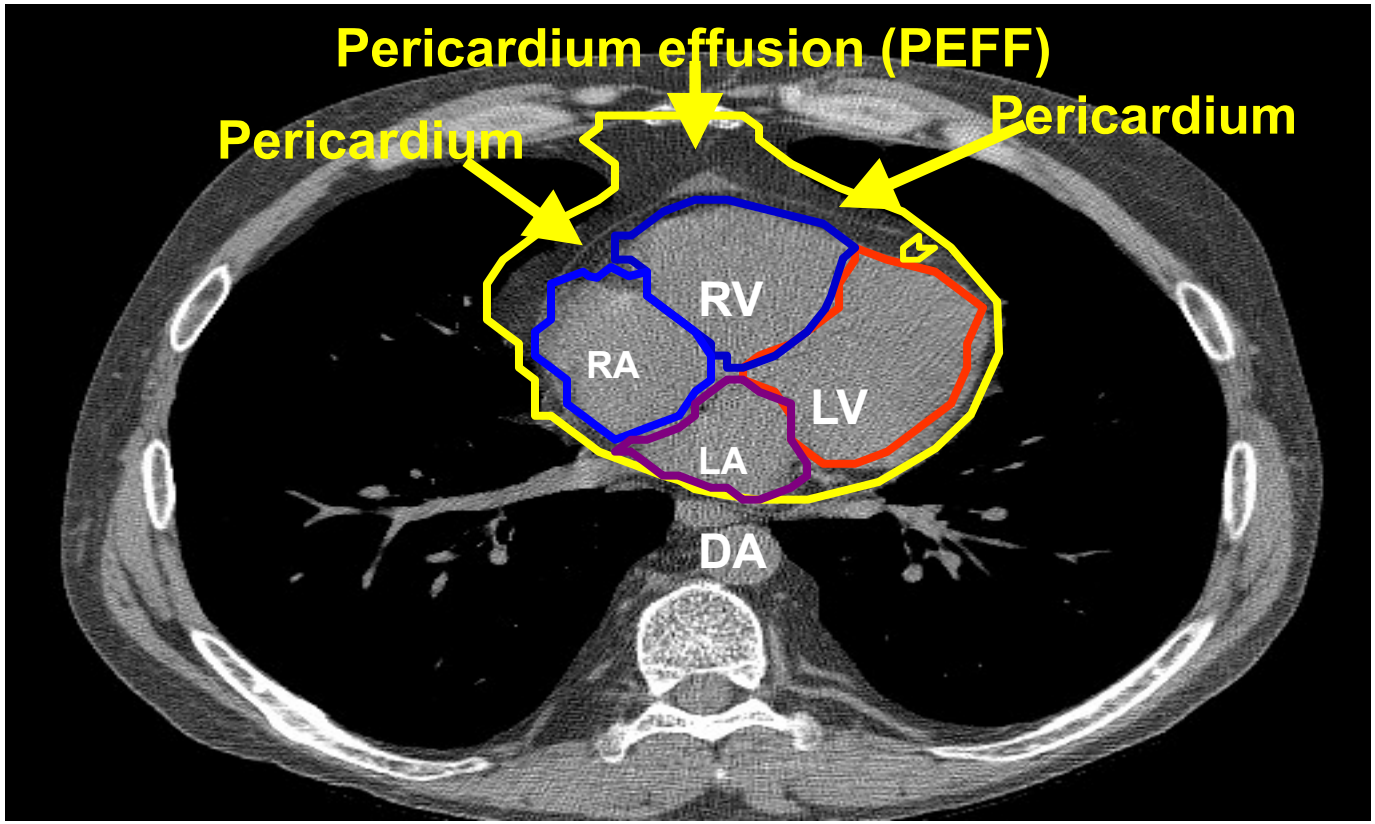

RA=right atrium, RV=right ventricle, LV=left ventricle, LA=Left atrium, AA=aortic arch

The problem of contouring Esophagus from Kong et al

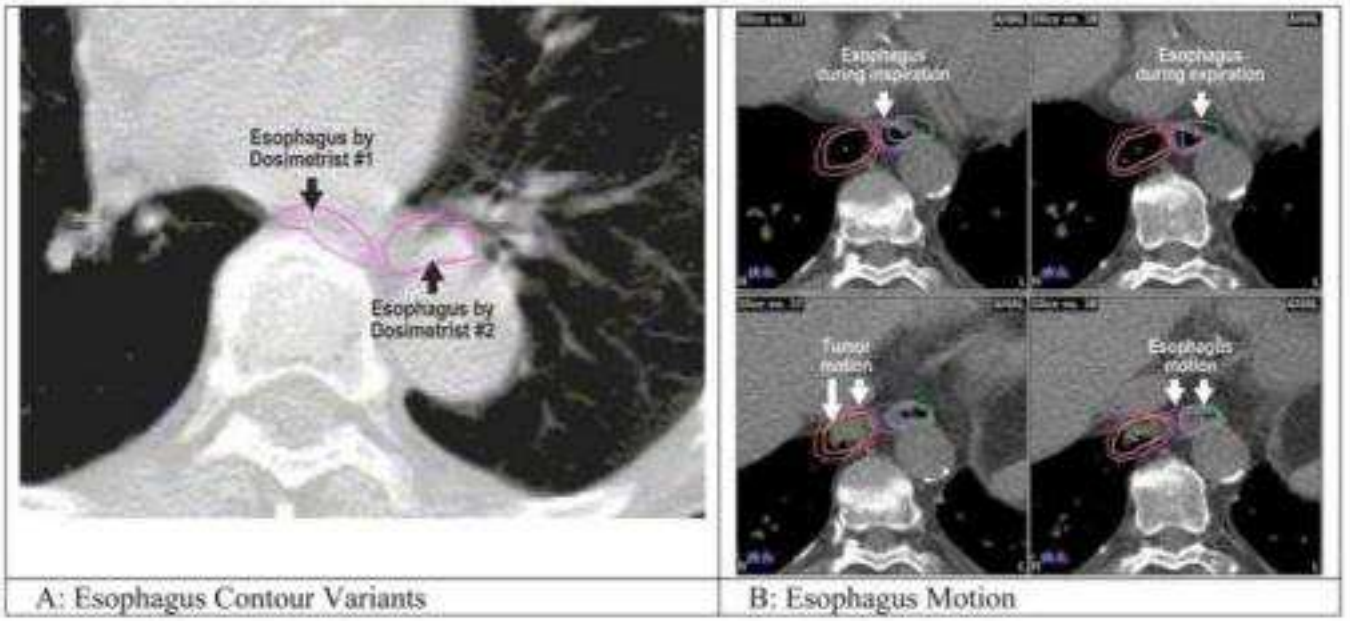

INSTITUT JULES BORDET INSTITUUT

ULB iris

Chest Wall (CW) RTOG

CW refers to CW 2cm which include intercostal muscles, nerves exclude vertebral bodies, sternum and skin. This can be accomplished through auto-expansion of the ipsilateral lung (within 3 cm range of PTV)

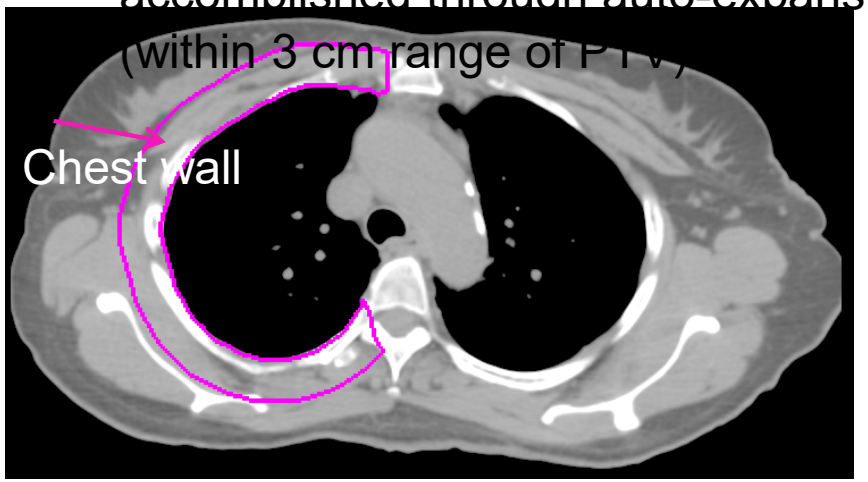

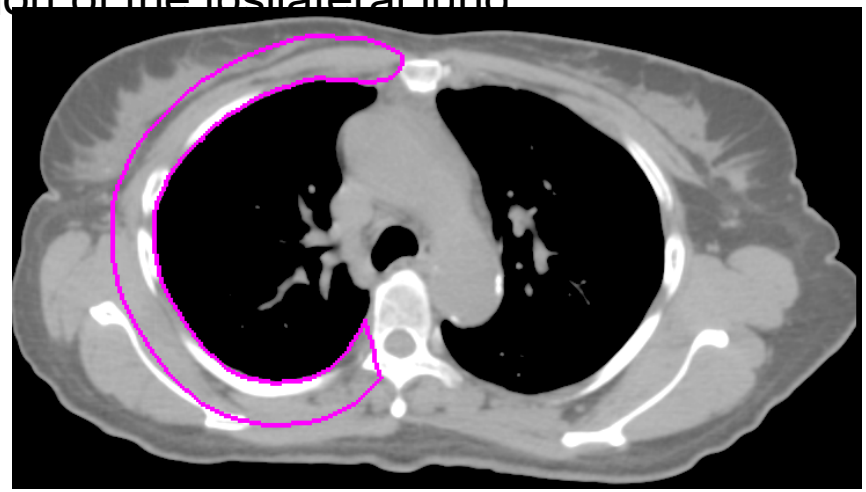

CW contouring starts at 3 cm above the PTV

INSTITUT JULES BORDET INSTITUUT

ULB iris

SBRT for LUNG CANCER Brachial Plexopathy
Forquet et al RO 2009

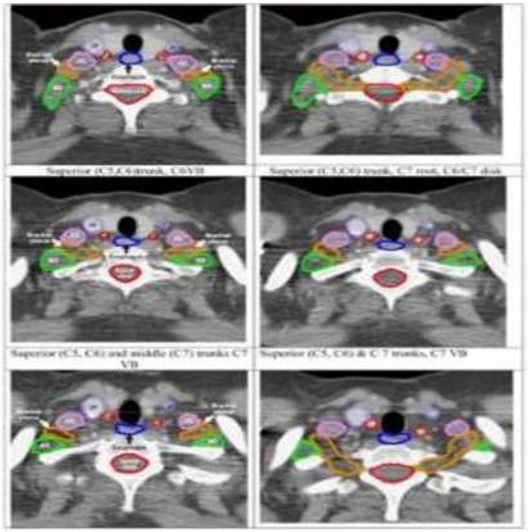

37 apical lesions
Total dose : 30-72 Gy
Fractions : 3-4
Brachial plexopathy: 7/37
Safe Dose : < 26 Gy

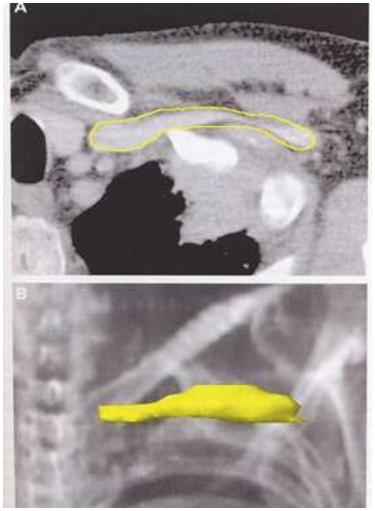

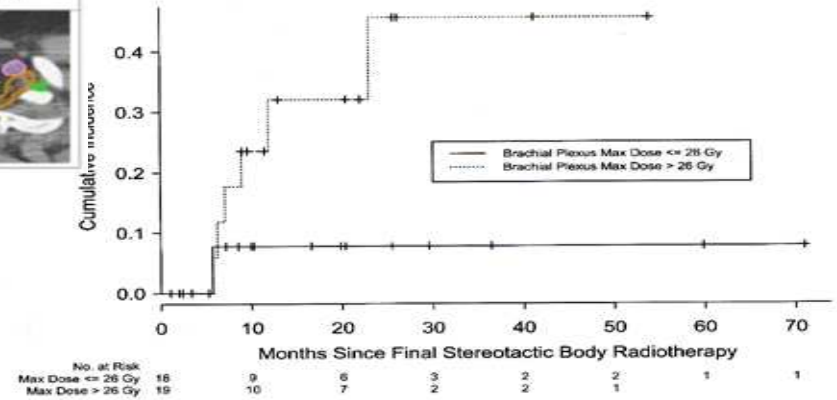

INSTITUT
JULES BORDET
INSTITUUT

ULB iris

Toxicity of Central Lung SBRT

- Timmerman, et al. *JCO* 2006
- 70 pts
- 20 Gy x 3 or 22 Gy x 3
- 14 patients had Grade 3 to 5 toxicity
  - 8 Grade 3/4 - ↓PFT's, effusion, pneumonia
  - 6 toxic deaths – pneumonia, pericardial effusion, hemoptysis
  - Central tumors more likely to have toxicity

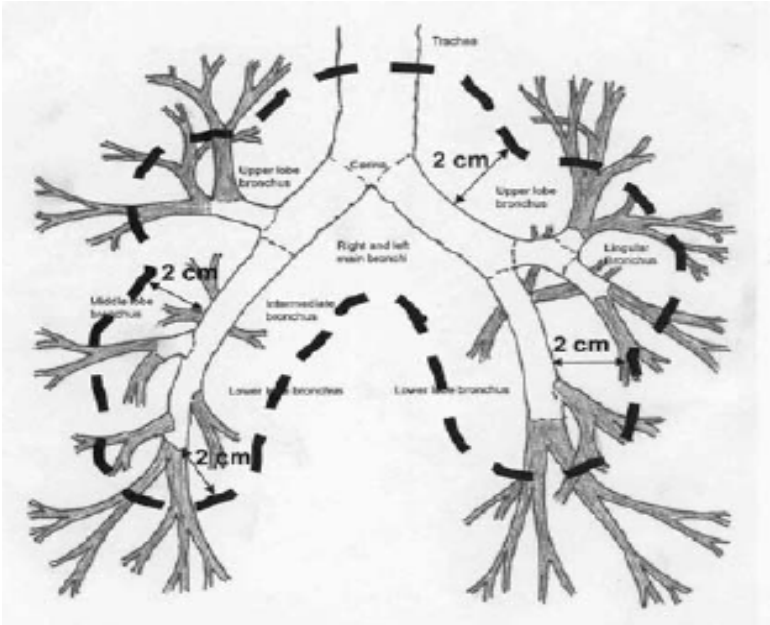

RTOG 0813

PTV

- Accounts for geometric uncertainties
- e.g. delineation errors, patient (setup) and tumour (baseline shift), and tumour motion-related errors..
- ideally be quantified in each individual RT department **(5-10 mm)**

Adaptative Radiotherapy

- Cone beam CT performed during the course of radiotherapy:

- Improve the precision of the set-up
- Allow to check the intrafraction variation
- Allow to see the tumor response and to eventually modify the treatment

Anatomical Changes During Radiotherapy of Lung Cancer
Van Zwienen M. (AVL Amsterdam)

- 114 consecutive patients
- RT 45 to 88 Gy
- CBCT each treatment week
- 47 patients anatomical changes
- Tumor regression 37 patients
- Tumor progression 1 patients
- Changes in atelectasis 26 patients including 20 dissolving
- **CBCT let to re-planning for 6 patients**

Tumor regregression during radiochemoth of NSCLC
Lim G. J Thorac Oncol 2011

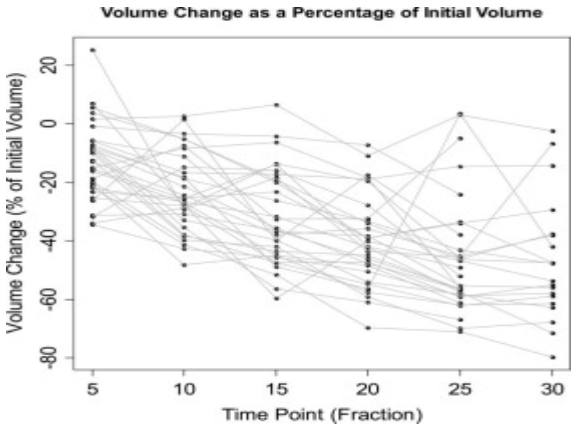

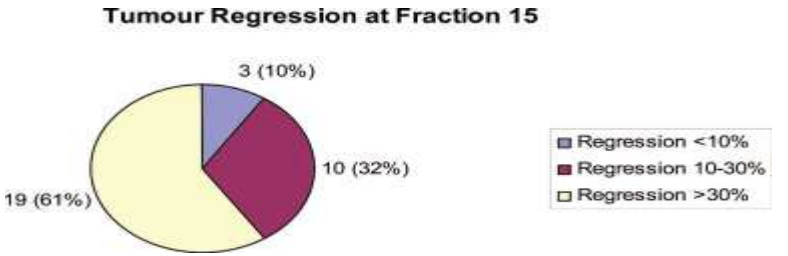

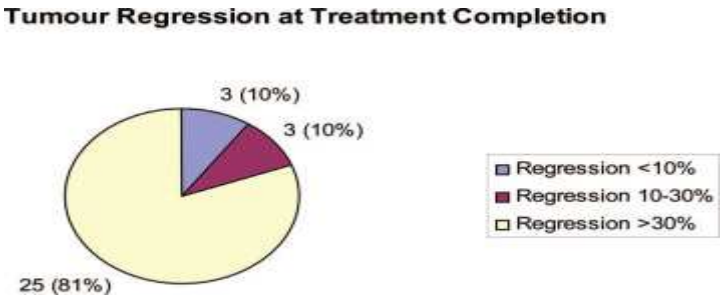

INSTITUT
JULES BORDET
INSTITUUT

ULB
iris

RE-PLANNING

- Adaptive re-planning advised on an individual basis (O)

- If CBCT reveals relevant change

Radiotherapy for SCLC

- Pre or postchemotherapy volume
- Elective nodal RT : See report of Videtic et al Int.J.Radiat. Oncol.Biol.Phys: 72, 327 2008
- Is it safe to avoid an elective nodal RT in our current daily practice ?

INSTITUT JULES BORDET INSTITUUT

ULB iris

Omitting elective nodal RT for limited SCLC
Evidence from a phase II trial
Colaco et al Lung Cancer 2012

2 patients out of 36 isolated nodal failure outside the PTV
Both at also distant relapse

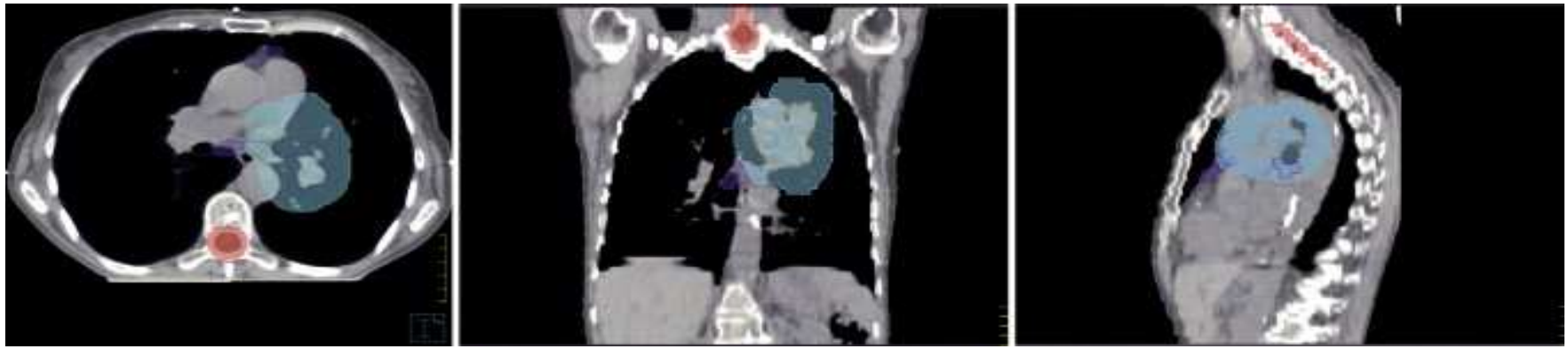

INSTITUT
JULES BORDET
INSTITUUT

ULB iris

Elective nodal Irradiation or not
Retrospective study of Han
Jpn J Clin Oncol 2012

- 80 patients
- 50 treated with involved field
- 3 Y survival rate : 44 and 54 % (no difference)
- Isolated nodal failure :
- 0 % ENI vs 6 % involved field
- All isolated nodal failure were seen in patients not staged with PET

Pre or postchemotherapy volume : a phase III trial
Hu X. et al Cancer 2011

2 cycles of DDP-VP-16 followed by Concurrent chemoRT
45 Gy /30 fr/19 days No elective nodal RT and
3 additional cycles RT PCI for CR

	Post chemotherapy	Prechemotherapy
N	42	43
Local relapse	12	12
Isolated nodal failure*	1	1
Survival		
1 Year	80.6 %	78.9 %
3 Year	36.2 %	36.4 %

INSTITUT JULES BORDET INSTITUUT

* = isolated supraclavicular N

ULB iris

Volumes to be treated
Current recommendations

- **After initial chemotherapy**

For the T : after chemotherapy, the residual tumor volume

For the N : the station involved before chemotherapy

- **Concurrent initial chemo-Rt**

The CTV and GTV as for NSCLC

This is only valid for a staging including a PET-CT

The current trend is to approach SCLC like a NSCLC

POSTOPERATIVE ADJUVANT TREATMENT For LUNG CANCER Is it still a question ?

INSTITUT JULES BORDET INSTITUUT

ULB iris

Modern Postoperative Radiotherapy for Stage III NSCLC may improve **local control** and survival: a metaanalysis

C. Billiet et al Radioth.Oncol.2014

Overall survival function of beam quality

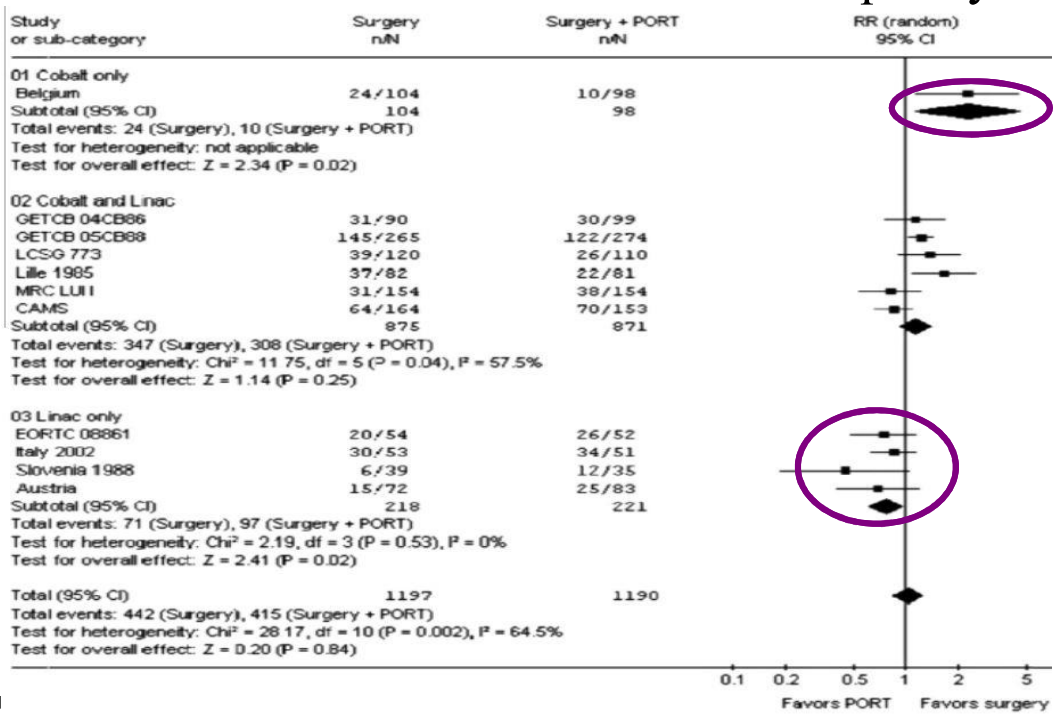

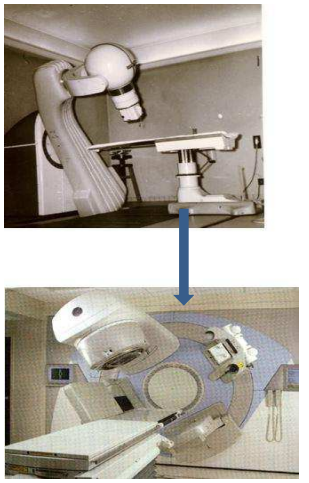

PORT ONLY improved OS with LINAC (***RR 0.76 and p= 0.02***)

Target volume definition

ELECTIVE NODAL RT

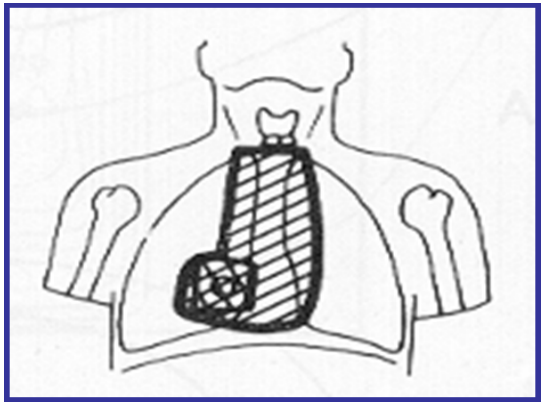

The common DOGMA is to treat all potential sites of microscopic disease within the thorax, which would include the bronchial stamp, ipsilateral hilum, entire mediastinum and perhaps the supraclavicular fossa.
BUT
Mortality is strongly dependent on **FIELD SIZE**, which may be partly offsett the overall survival benefit afforded by PORT

Should be adapted to the pattern of failure

INSTITUT JULES BORDET INSTITUUT

ULB iris

Technical issues
Dose / Volume

- The PORT trial : ipsilateral hilum + positive station + one station above the last involved
- Dose : range between 50 and 60 Gy (56 Gy for PORT)
- Conventional fractionation
- 3D treatment planning

Variation in Volume Definition for Postoperative RT in Stage III NSCLC An international contouring study Int.J.Radiat.Oncol.Biol.Ph 2010

17 thoracic radiation oncologists contoured routinely or per protocol

	lobectomy		Pneumonectomy	
	Routine	Protocol	Routine	Protocol
Planning target vol.cc	143-1342	297-382	187-1262	275-308
Lung				
Mean dose (Gy)	8-26	11.6-15.3	3.4-13.4	4-4.1
V20 (%)	12.7-54	20.6-29.2	1.5-20.6	2.1-2.9
Heart				
V45 (%)	0-20.5	1.6-5.1	4.3-37	7.1-10
Esophagus				
Length 45 Gy (cm)	4.5-11.5	6.8-9.5	5.8-12	7.5-10.8

Examples of CTV according to Lung Art protocol

4R positive

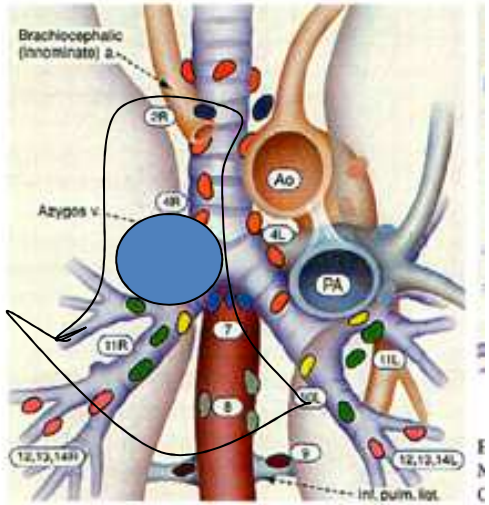

Stations treated : 2R,4R,7,10R

6 positive

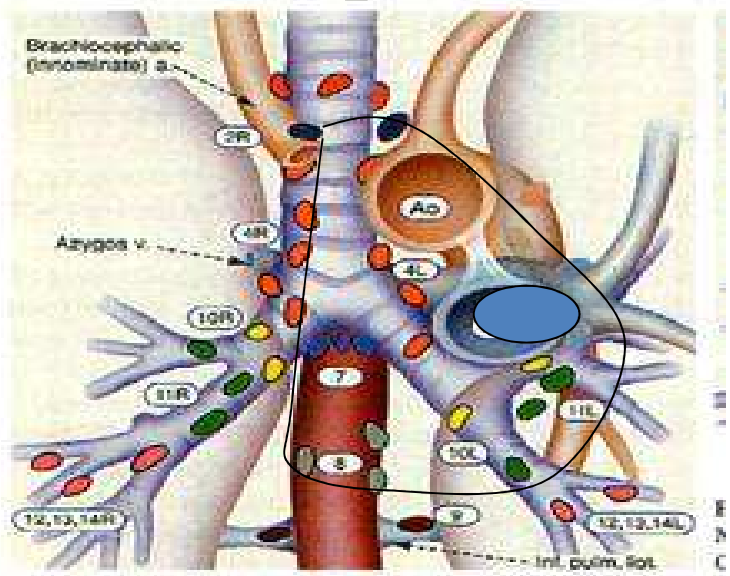

Stations treated : 2L,4L,5,6,7

INSTITUT JULES BORDET INSTITUUT

ULB iris

Patterns Loco-Regional Failure in Completely Resected NSCLC
Implications for PORT Clinical Target Volume Design
Feng, Int Jour Radiat Oncol Biol Phys 2014
250 PATIENTS WHO DID NOT RECEIVED PORT
85% receiving CT
173/250 experienced disease recurrence

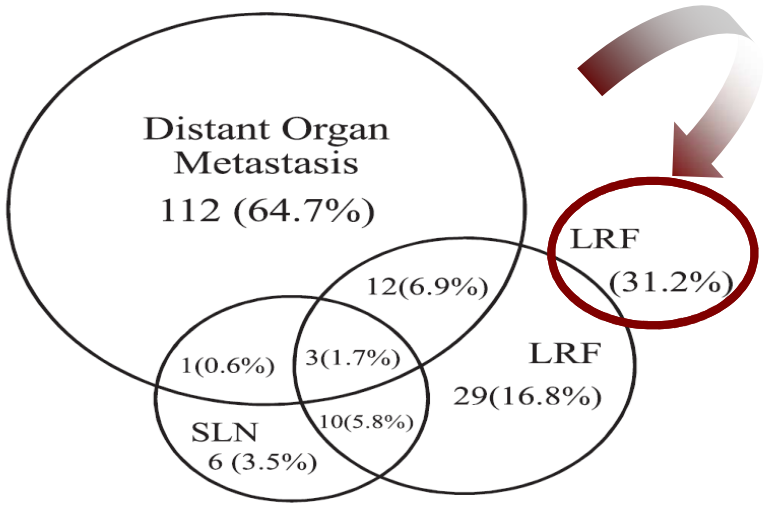

INSTITUT JULES BORDET INSTITUUT

ULB iris

Patterns Loco-Regional Failure in Completely Resected NSCLC
Implications for PORT Clinical Target Volume Design

Feng, Int Jour Radiat Oncol Biol Phys 2014



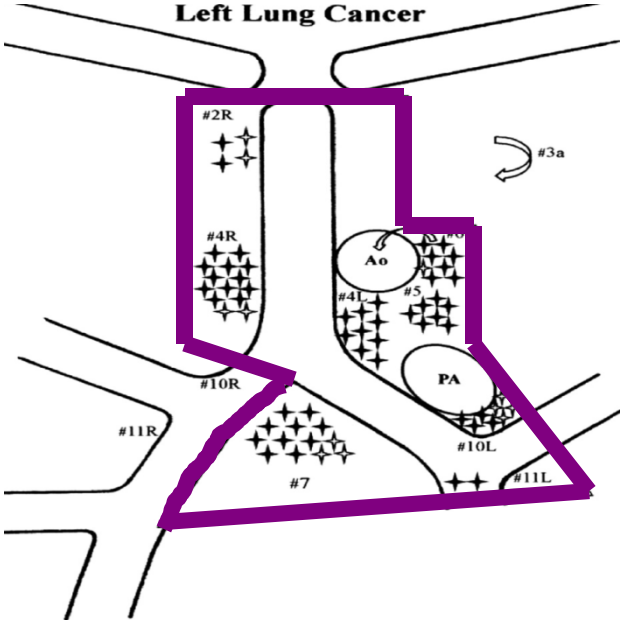

For left sided T 100% had locoregional failure (LRF) within the proposed PORT CTV

Patterns Loco-Regional Failure in Completely Resected NSCLC
Implications for PORT Clinical Target Volume Design
Feng, Int Jour Radiat Oncol Biol Phys 2014

RIGHT

2R:26%
4R:19%
10R:19%
7: 15%

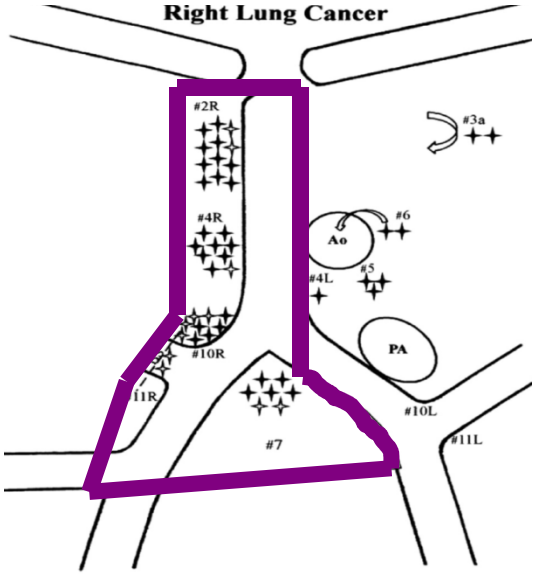

For patients with right sided T 74% had locoregional failure (LRF) within the proposed PORT CTV, 26% had multiple sites of LRF within and outside CTV and concurrent distant M+

INSTITUT JULES BORDET INSTITUUT

ULB iris

Organisation and responsibilities

- Departmental instructions for delineation (M), preferably according to published atlases (R)
- Supervision of trainees (M)
- OARs by RTTs optional, final approval by RO
- Additional review by other radiation oncologists (R!)

Radiation quality program

- Important matter
  - The right answer to a question
  - Remember the Australian study
  - Also important in daily practice

The goal is for each individual patient to have the right treatment regardless of the center, physician or even the day

TROG trial and Tyrapazamine in Head and Neck Cancers

Quality audit on Radiotherapy (JCO)

Number of patients	Major protocol deviation
1-4	29,8
5-9	21,5
10-19	11,8
>20	5,5

Major violation : poor coverage of the T or N leading to a lower survival and no impact of the drug but in patients well treated, the drug

LOCOREGIONAL RELAPSE		
Compliance to RT	**RT+DDP**	**RT+DDP/TPZ**
Dose < 60 Gy	**36 %**	**42.7 %**
Dose > 60 Gy	**23.8 %**	**18 %**

Conclusions

- For NSCLC and SCLC no elective nodal RT if PET-CT
- Use CT with IV contrast for planning
- Do not match a PET-CT if not taken in treatment position
- In case of induction chemotherapy, repeat CT with IV contrast
- Be aware delay between PET-CT and Radiotherapy
- Repeat planning in case of major changes (atelectasis)
- Postop RT : limit the elective RT according to guidelines

Thank you

INSTITUUT
JULES BORDET
INSTITUUT

ULB iris

EFFICACY of PET-CT

	Procedures	Se	Sp	NPV	PPV
Bone	Bone scan PET-CT	78-93% 93-94%	97-98% 94-99%	97% 98-99%	25-76% 76-90%
Liver	CT PET-CT	62% 100%	99% 100%	55% 100%	99% 100%
Lung	CT PET-CT	78% 95%	98% 98%	83% 89%	97% 99%
Adrenals	CT PET-CT	72% 97%	98% 94%	57% 95%	99% 94%

Bone: Min, J Korean Med Sci 2009,
Song, Lung Cancer 2009
Liver & lung:Nosotti 2008
Adrenals: Nosotti 2008, Lu 2010

INSTITUT JULES BORDET INSTITUUT

ULB iris

Four-dimensional Gallium-68 perfusion PET/CT scans can improve radiotherapy planning through functional avoidance of lung

Shankar Siva Peter MacCallum Cancer Centre Melbourne

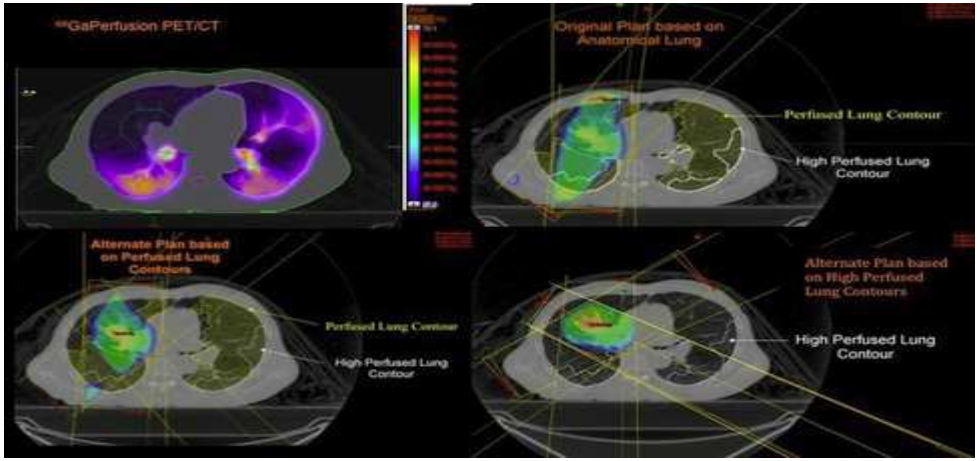

14 patients
RT plan optimised to spare functionaly perfused and high perfused lung volume

Conclusion : a large improvement was observed mainly for the treatment plan optimized to the high perfused lung volume

INSTITUT JULES BORDET INSTITUUT

ULB iris

ESTRO School

Target Volume Determination

From Imaging to Margins

Lisbon 25-28 June 2017

Oesophageal and gastric cancer GTV & CTV OARs

Maria Antonietta Gambacorta

Radiotherapy Dept.

Università Cattolica del Sacro Cuore

Rome

Esophageal cancer

- Treatment approaches
- Sites of recurrences
- Target volume delineation

Esophageal cancer

- Treatment approaches
- Sites of recurrences
- Target volume delineation

Treatment indications

Locally advanced **Esophageal cancer**

- **Resectable cancer, Fit patient** → **CT-RT ⟶ SURG**
- **Unresectable cancer, Fit patient** → **Exclusive CT-RT**
- **Unfit patient** → **Exclusive RT**

NCCN guidelines -2015

Treatment approaches

Surgery vs **pre-op Chemoradiation**

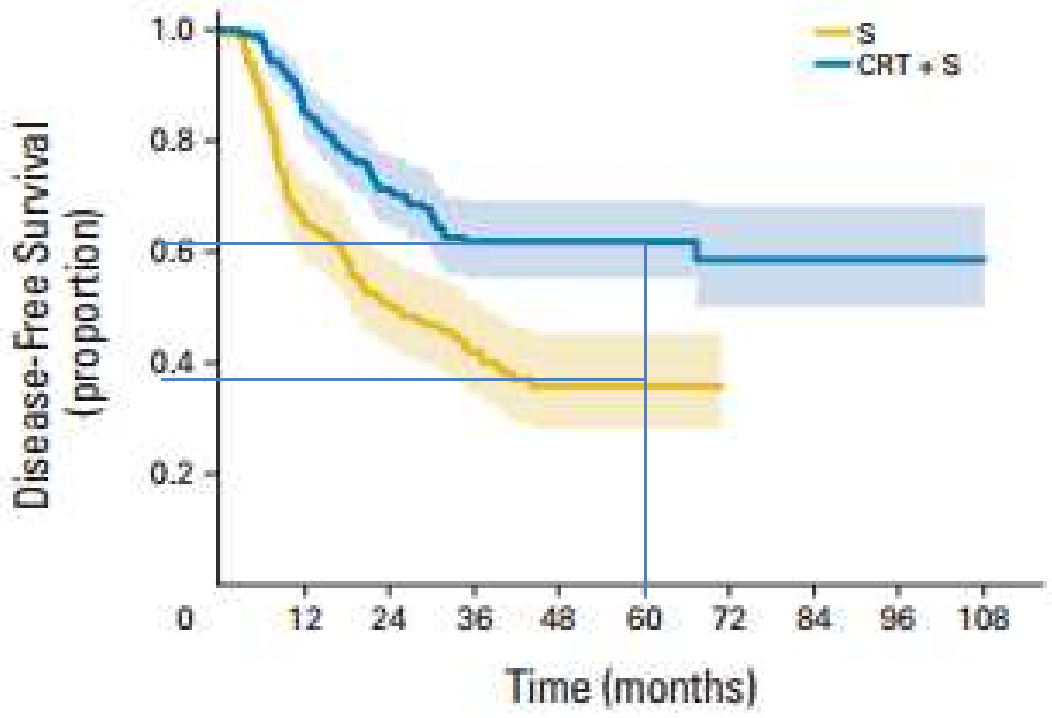

Oppedijk V et al- JCO-2014

Treatment approaches

Surgery vs **RT alone** vs **Chemoradiation**

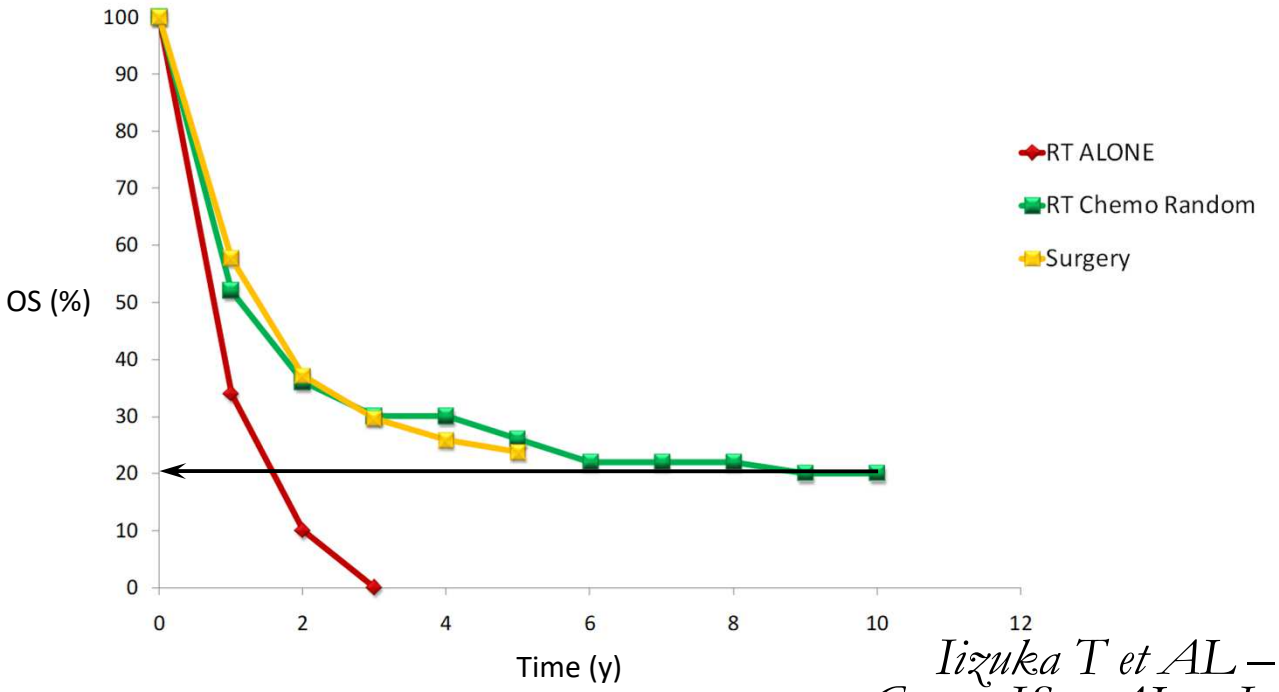

Iizuka T et AL – Chest– 1989
Cooper JS et AL – JAMA – 1999

Esophageal cancer

- Treatment approaches
- Sites of recurrences
- Target volume delineation

Sites of recurrence

Surgery vs Pre-op chemoradiation

Table 2. Results of Univariable Cox Regression Analysis of RFS Time per Treatment Arm in Patients Undergoing Resection (n = 374)

Site of Recurrence	S Arm (n = 161) No.	S Arm (n = 161) %	CRT + S Arm (n = 213) No.	CRT + S Arm (n = 213) %	HR	95% CI	P
Anastomosis	14	8.7	6	2.8	0.28	0.11 to 0.72	**.008**
Mediastinum	33	20.5	15	7.0	0.29	0.16 to 0.53	**< .001**
Supraclavicular	7	4.3	9	4.2	0.83	0.31 to 2.2	.71
Celiac axis	11	6.9	8	3.8	0.42	0.17 to 1.04	.06
Para-aortic	17	10.6	14	6.6	0.53	0.26 to 1.1	.08
Peritoneal carcinomatosis	22	13.7	9	4.2	0.27	0.12 to 0.58	**.01**
Hematogenous	57	35.4	61	28.6	0.67	0.46 to 0.96	**.03**

NOTE. Bold font indicates significance.
Abbreviations: CRT, chemoradiotherapy; HR, hazard ratio; RFS, recurrence-free survival; S, surgery.

40%

31%

DM

DM

Oppedijk V et al- JCO-2014

Esophageal cancer

- Treatment approaches
- Sites of recurrences
- Target volume delineation:
  - **GTV**
  - **CTV:**
    - **T-N**
    - **CTV elective nodes**

Gross Tumor Volume

GTV definition

- Esophagogram
- EUS
- CT
- PET

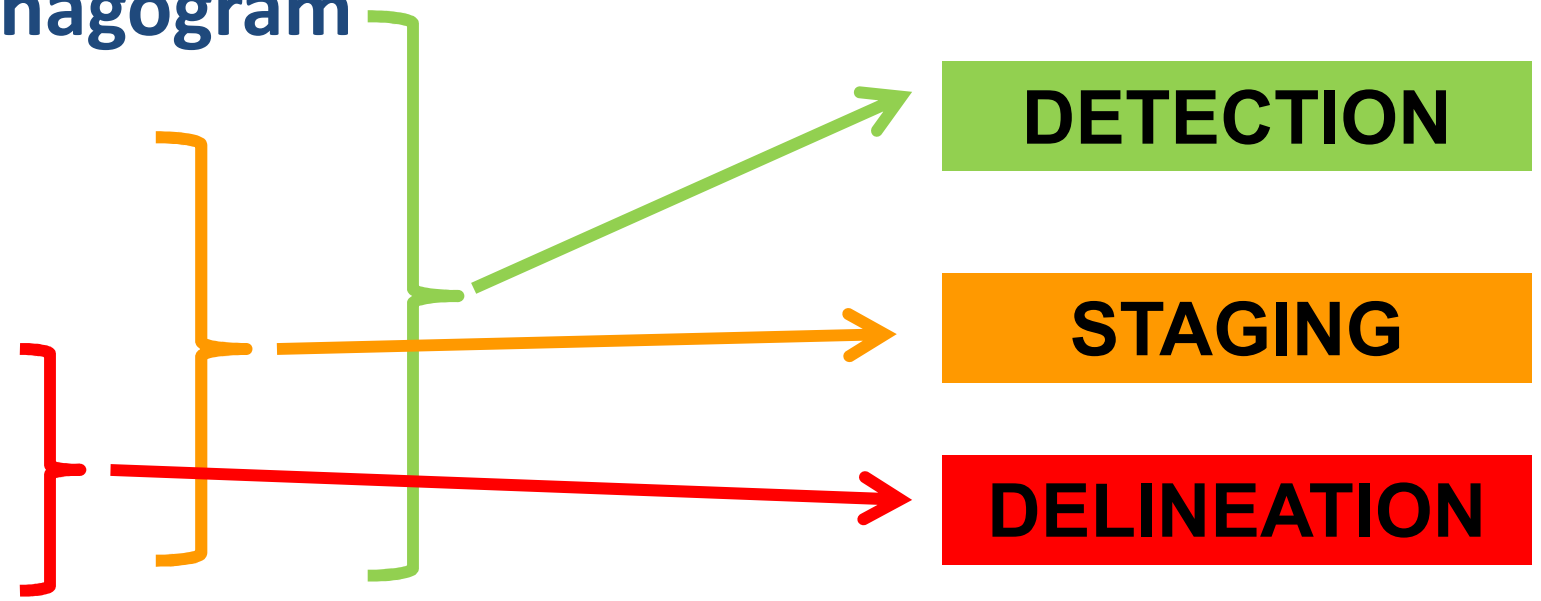

GTV definition: imaging

CT scan

PET & PET CT

} **GTV delineation**

+

information from other imaging modalities

- Esophagography: intra-luminal tumor, early tumors, CC extension, under-estimates GTV, **no co-registration**, 2D treatment
- EUS & EUS-FNA: T wall infiltration; adjacent N+, **no co-registration**
- Endoscopy (esophagoscopy, bronchoscopy): T extension, bronchus invasion, **no co-registration**

Plukker JThM – Best Pract Res Clin Gastroenterol – 2006
Fiore D – Radiol Med – 2006

GTV-T definition:CT Scan

TUMOR

- **Definition of extension based on wall thickness:**
  - common with benign disease (esophagitis, hypertrophy due to obstruction, fluid/food, others)

- **Definition of mediastinal invasion based on fat invasion:**
  - frequently **impossible to distinguish normal fat planes** for mid-esophageal area; underweights patients; GEJ loss of esophageal fat

- **Definition of tumor volume in the lower part hampered by motion artifacts (heart), paucity of fat**

Plukker JThM – Best Pract Res Clin Gastroenterol – 2006

CT-scan for GTV-T definition: infiltration of adjacent organs

no infiltration **???** **infiltration**

Picus D – Radiology – 1983

CT-scan for GTV-N definition

NODES: **Size, border, density, central fatty hilum**

LIMITATIONS:

- Reported overall accuracy < 60% for mediastinal lymph nodes, from 39% to 74% in coeliac and abdominal lymph nodes

- **Lymphnoda**l metastases **adjacent** to the esophageal wall are **not visible**

- **Dimensional criterion** can be not sufficient for all cases:
  - **Metastases** have been found in **lymphnodes lower than 7mm** in larger diameter
  - **Lymphnodes > 1 cm** may be enlarged by **inflammation**

Picus D – Radiology – 1983

Patel AN – Surg Clin North Am – 2005

Plukker JThM – Best Pract Res Clin Gastroenterol – 2006

How to improve GTV definition

- **PET & CT-PET**
- **Distant occult metastases**:

  Exclusion of curative treatments

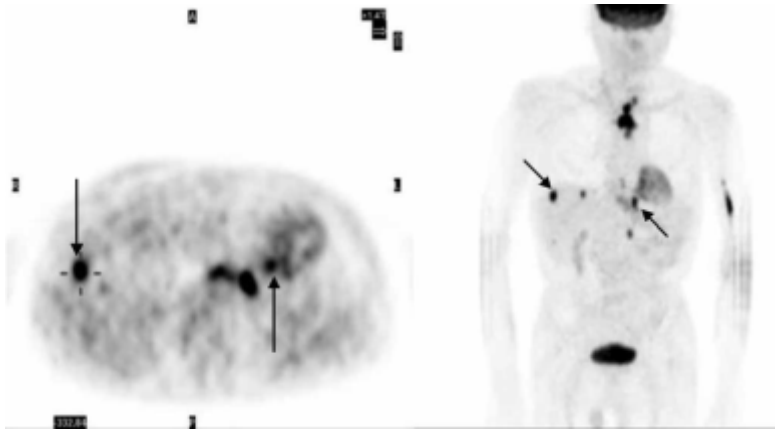

- **Local staging**
  - **Detection of primary tumor**
  - **Uncertain nodes far from T**

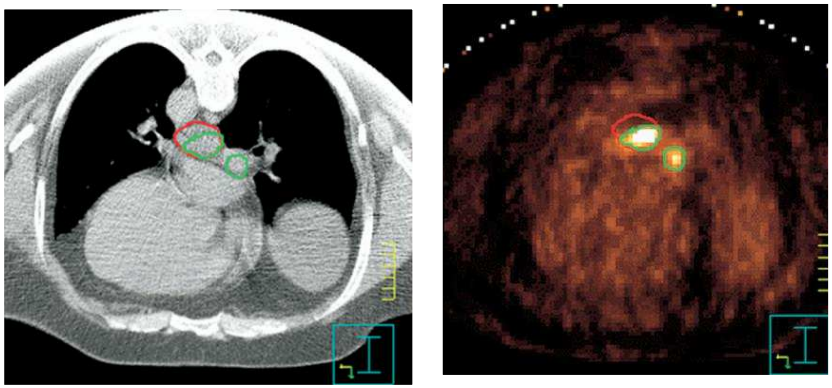

Gondi V – IJROBP– 2007

Use of PET for treatment planning

1. **GTV delineation**
2. **Inter-Intra observer varialbility**

GTV delineation: PET vs CT & pathology

PET-CT delineation | **Pathology** | **Overlapping measurements**

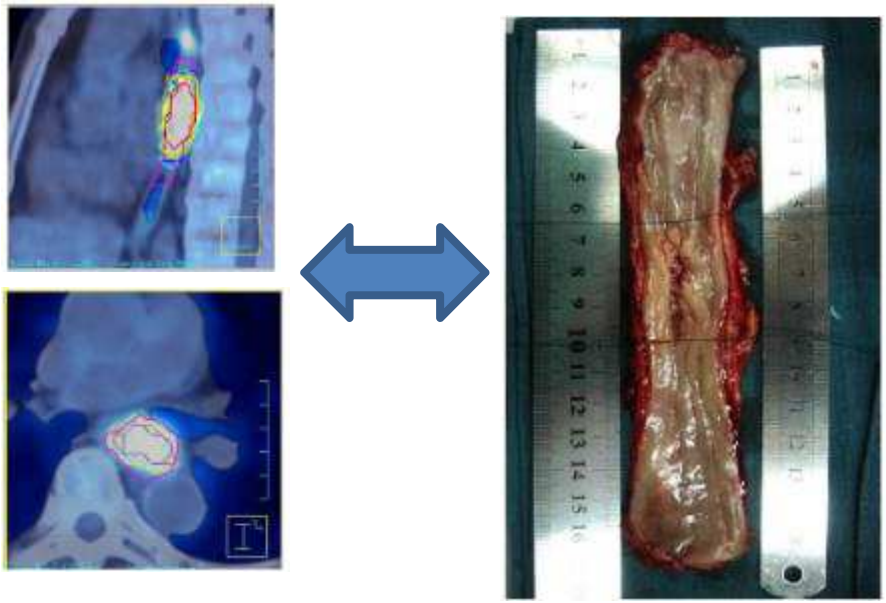

Delineation modalities:

1. CT: **manual**
2. SUV bcg + 20% (SUV max – SUV bcg)
3. SUV bcg + 40% (SUV max – SUV bcg)
4. SUV 2.5;
5. 40% SUV max

automatic

lenght

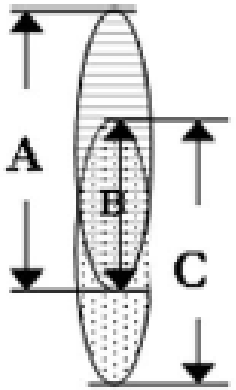

$CI' = B^2/(A*C)$

$A = L_{ct}$

$B = Intersection$

$C = L_{path}$

GTV volume

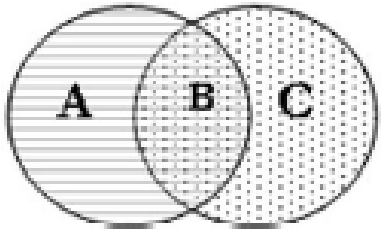

$CI = B^2/(A*C)$

$A = GTV_{ct}$

$B = Intersection$

$C = GTV_{path}$

Yu V. et al – Radiother Oncol. – 2009

GTV delineation:
PET vs CT & pathology

Lenght: PET 20% threshold

Mean lengths of the esophageal tumor measured by different methods and the corresponding CI's.

	L_{CT}	$L_{20\%}$	$L_{40\%}$	$L_{2.5}$	$L_{40\%M}$	L_{path}
Mean ± SD (cm)	6.30 ± 2.69	5.55 ± 2.48	6.80 ± 2.92	6.65 ± 2.66	4.88 ± 1.99	5.90 ± 2.38
P value (L_x vs. L_{path})	0.4140	0.1051	0.0454	0.0757	0.0001	–
$CI'_{x\&path}$	0.68 ± 0.16	0.84 ± 0.17	0.76 ± 0.14	0.78 ± 0.15	0.80 ± 0.11	–
P value ($CI'_{CT\&path}$ vs. $CI'_{x\&path}$)	–	0.0002	NS	NS	0.0291	–
P value ($CI'_{20\%\&path}$ vs. $CI'_{x\&path}$)	–	–	NS	NS	NS	–
P value ($CI'_{40\%\&path}$ vs. $CI'_{x\&path}$)	–	–	–	NS	NS	–
P value ($CI'_{2.5\&path}$ vs. $CI'_{x\&path}$)	–	–	–	–	NS	–

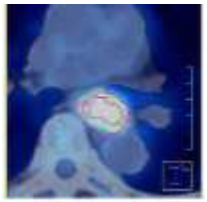

GTV volume: CT scan

Mean GTVs of the esophageal tumor measured by different methods and the corresponding CIs.

	GTV_{CT}	$GTV_{20\%}$	$GTV_{40\%}$	$GTV_{2.5}$	$GTV_{40\%M}$	GTV_{path}
Mean ± SD (cm^3)	29.16 ± 18.56	18.75 ± 12.37	12.52 ± 8.08	22.69 ± 14.84	9.18 ± 5.96	28.16 ± 17.02
P value (GTV_x vs. GTV_{path})	0.4339	0.0000	0.0000	0.0008	0.0000	–
$CI_{x\&path}$	0.77 ± 0.17	0.52 ± 0.16	0.27 ± 0.09	0.52 ± 0.20	0.28 ± 0.08	–
P value ($CI_{CT\&path}$ vs. $CI_{x\&path}$)	–	0.0000	0.0000	0.0000	0.0000	–
P value ($CI_{20\%\&path}$ vs. $CI_{x\&path}$)	–	–	0.0000	NS	0.0000	–
P value ($CI_{40\%\&path}$ vs. $CI_{x\&path}$)	–	–	–	0.0000	NS	–
P value ($CI_{2.5\&path}$ vs. $CI_{x\&path}$)	–	–	–	–	0.0000	–

Yu V. et al – Radiother Oncol. – 2009

GTV delineation: PET & variability

- 10 GEJ ca undergoing RT
- 6 Radiation Oncologists
- CT alone vs PET-CT (manual)
- **Median observer overlap analysis** (bars = Observer Agreement Index)
- Plans using PET-CT **reduced both interobserver and intraobserver variability**

Inter-observer variability

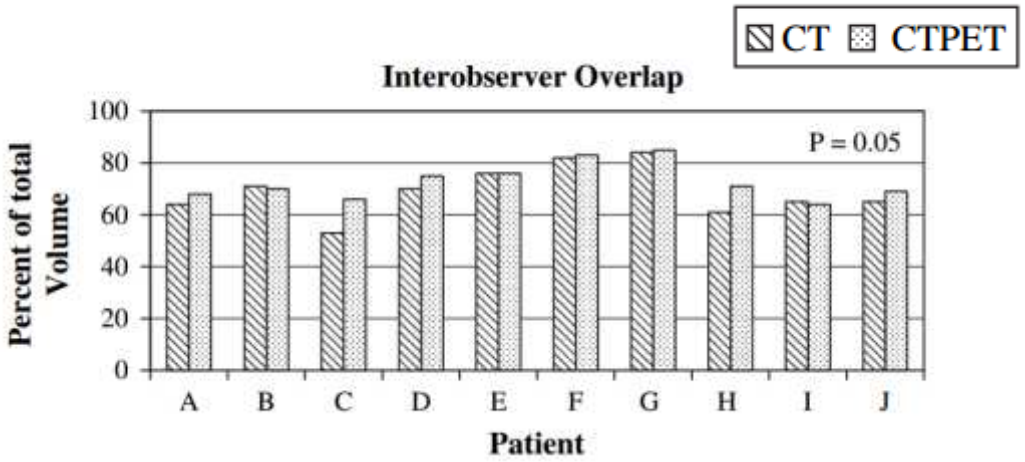

PET-CT vs CT: 72.7% vs 69.1%

Intra-observer variability



PET-CT vs CT: 78.7% vs 76.1%

Vesprini D. et al – Radiother Oncol. – 2010

GTV delineation: PET & variability

- 10 GEJ ca undergoing RT
- 6 Radiation Oncologists
- CT alone vs PET-CT (manual)
- **Median observer overlap analysis** (bars = Observer Agreement Index)
- Plans using PET-CT **reduced both interobserver and intraobserver variability**

Inter-observer variability



Intra-observer variability

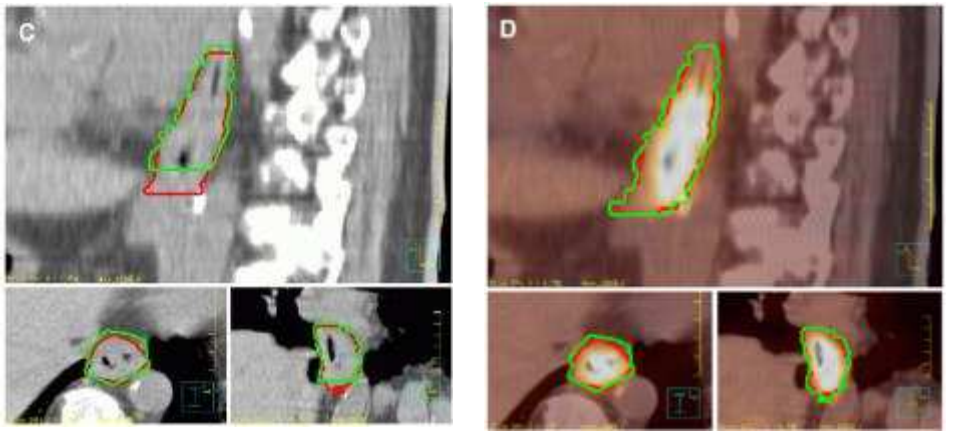

Vesprini D. et al – Radiother Oncol. – 2010

PET for GTV definition: summary

- **GTV-T:**
  - accurate in definition of **length** with threshold (GTV 20%)
  - Decrease observer **variability** (inter-intra)
- **GTV-N:**
  - high specificity **90%**
  - low sensitivity **57%:**
    - Poor spatial resolution (axial extension/nodes adjacent to the primary)
    - Partial volume effect (size 5-10mm)

GTV delineation: summary



- **GTV should be delineated on CT**
- **GTV should be increased to incorporate FDG-PET avid disease**
- **GTV should not be decreased because of lack of PET avidity (absolute volume, nodes)**
- **Take information from other imaging modalities (i.e.EUS)**

Clinical Target Volume
GTV-CTV margin

CTV-T: which margin around the GTV?

Longitudinal

Analysis of surgical specimens of esophageal **SCC** (n=34) and gastroesophageal junction **adenocarcinoma** (n=32) to define the extension of **microscopic spread**

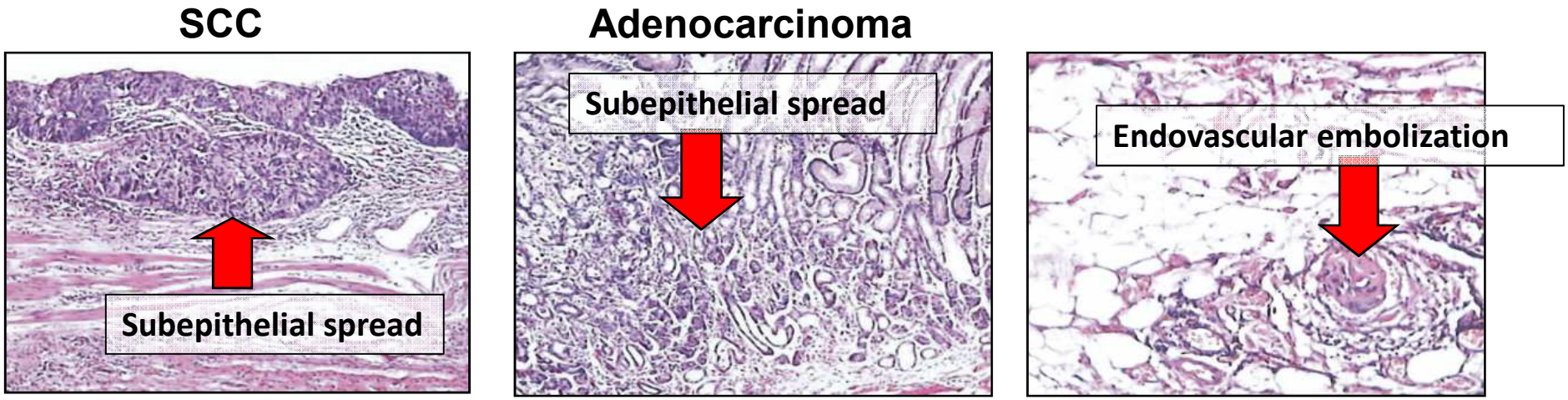

Gao XS – IJROBP– 2007

CTV-T Length along esophagus

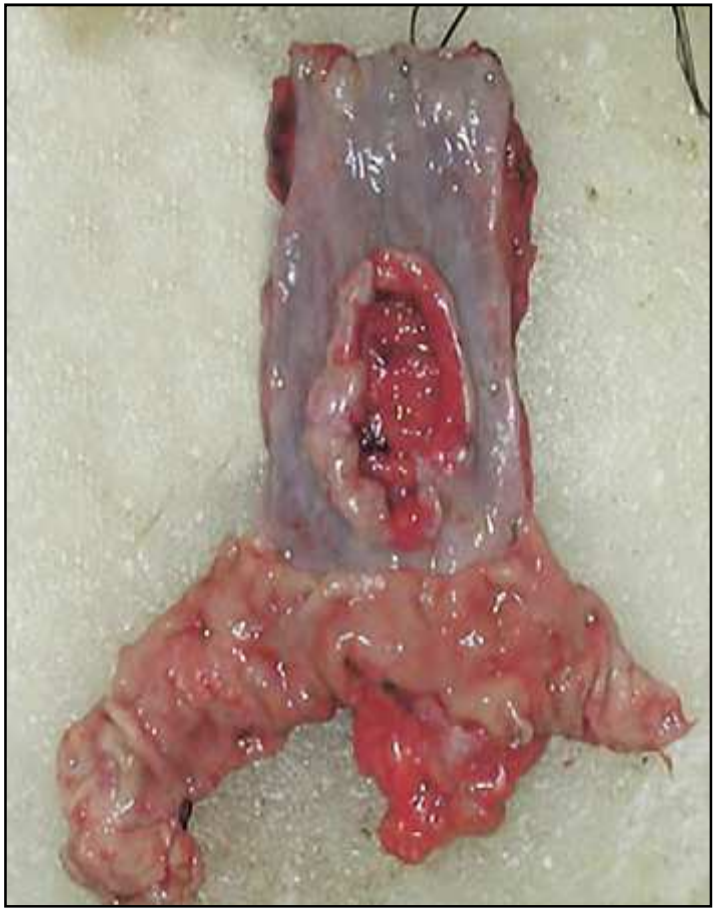

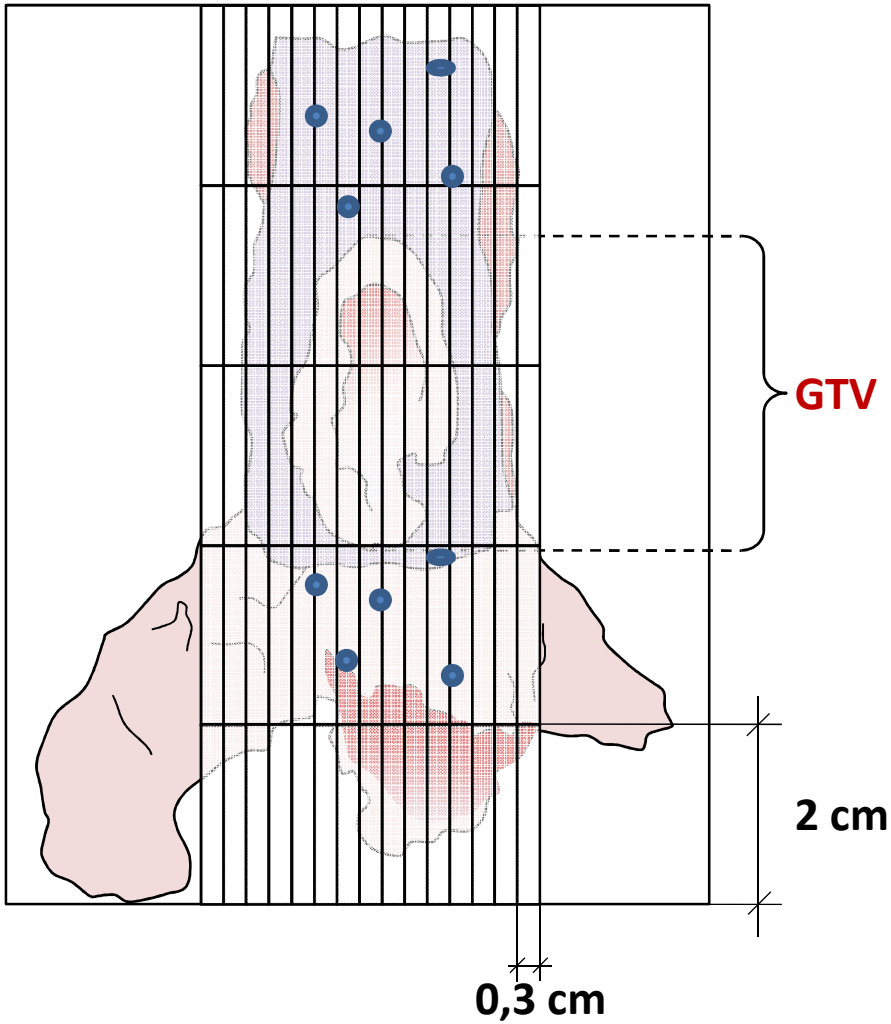

Gao XS – IJROBP– 2007

CTV longitudinal margins

- **SCC (mean microscopic distance from GTV):**
  10.5 ± 13.5 mm proximally → 94% within **30 mm**
  10.6 ± 8.1 mm distally
  N+ 35%

- **Adenoca GEJ (mean micro distance from GTV):**
  10.3 ± 7.2 mm proximally → 94% within
  18.3 ± 16.3 mm distally → **30 mm proximal**
  N+ 47% → **50 mm distal**

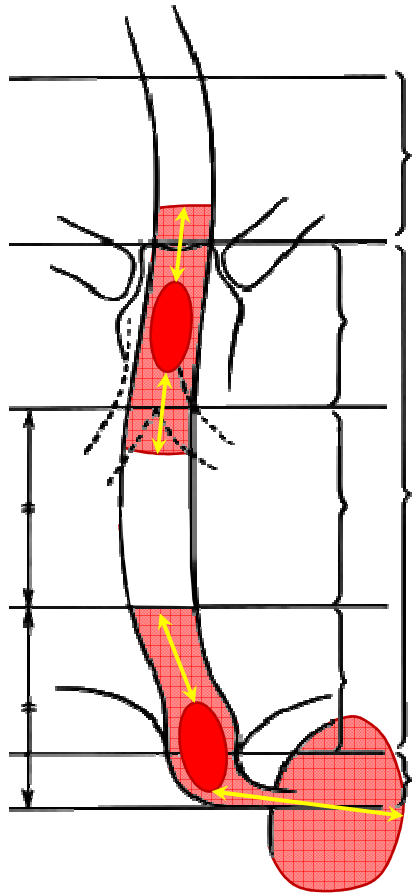

Gao XS – IJROBP– 2007

CTV radial margins

GTV (T and N+) + 1 cm margin, modified according to anatomical structures

This margin includes microscopic spread and paraesophageal nodes

Wu AJ et Al – Int J Radiat Oncol Biol Phys– 2015

GTV –CTV margin

Longitudinal

- **SCC** → GTV + 3 cm proximal and distal
- **ADC** → GTV + 3 cm proximal and 5 cm distal (if doses > 45Gy limit to 2 cm in the stomach)*
- 1 cm above any **involved nodes**, whichever is more cephalad
- For **proximal tumor** the upper border should not extent above of the **cricoid cartilage** unless there is gross disease at that level
- This margin should be oriented **along the esophageal mucosa**

Wu AJ et Al – Int J Radiat Oncol Biol Phys– 2015

GTV –CTV margin

Radial

→ **GTV-T + 1 cm** (mod according anatomy)

→ Heart level + **0,5 cm** into cardiac tissue (in the absence of gross invasion)

→ Liver level + **0,5 cm** into uninvolved liver

Wu AJ et Al – Int J Radiat Oncol Biol Phys– 2015

GTV-CTV margin

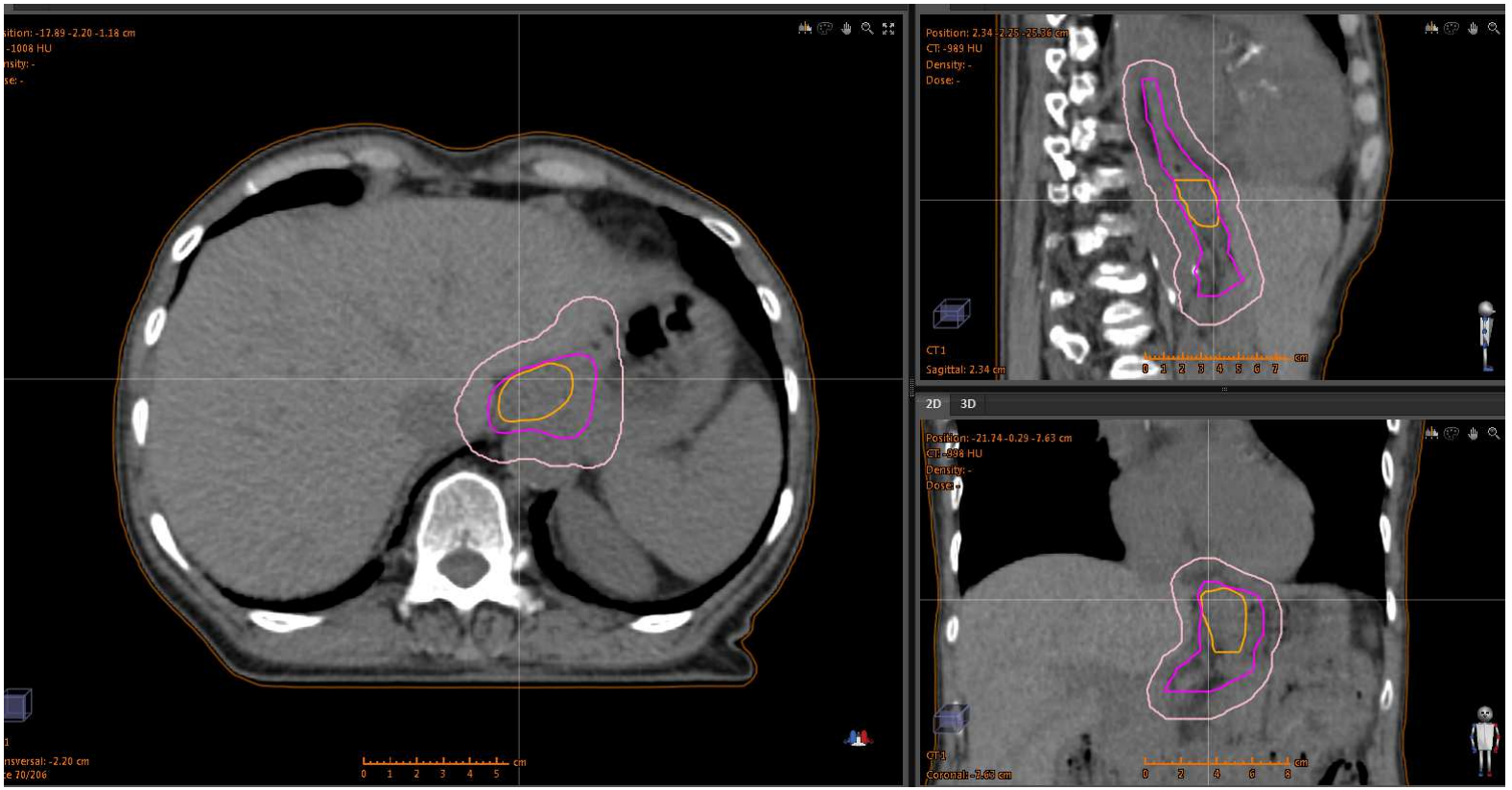

Clinical Target Volume
Elective Nodes

My CTV-elective is

- All supraclavicular-mediastinal-upper abdominal nodes
- Only peri- esophageal
- Changes according tumor location
- GTV + margin

Lymphatic drainage

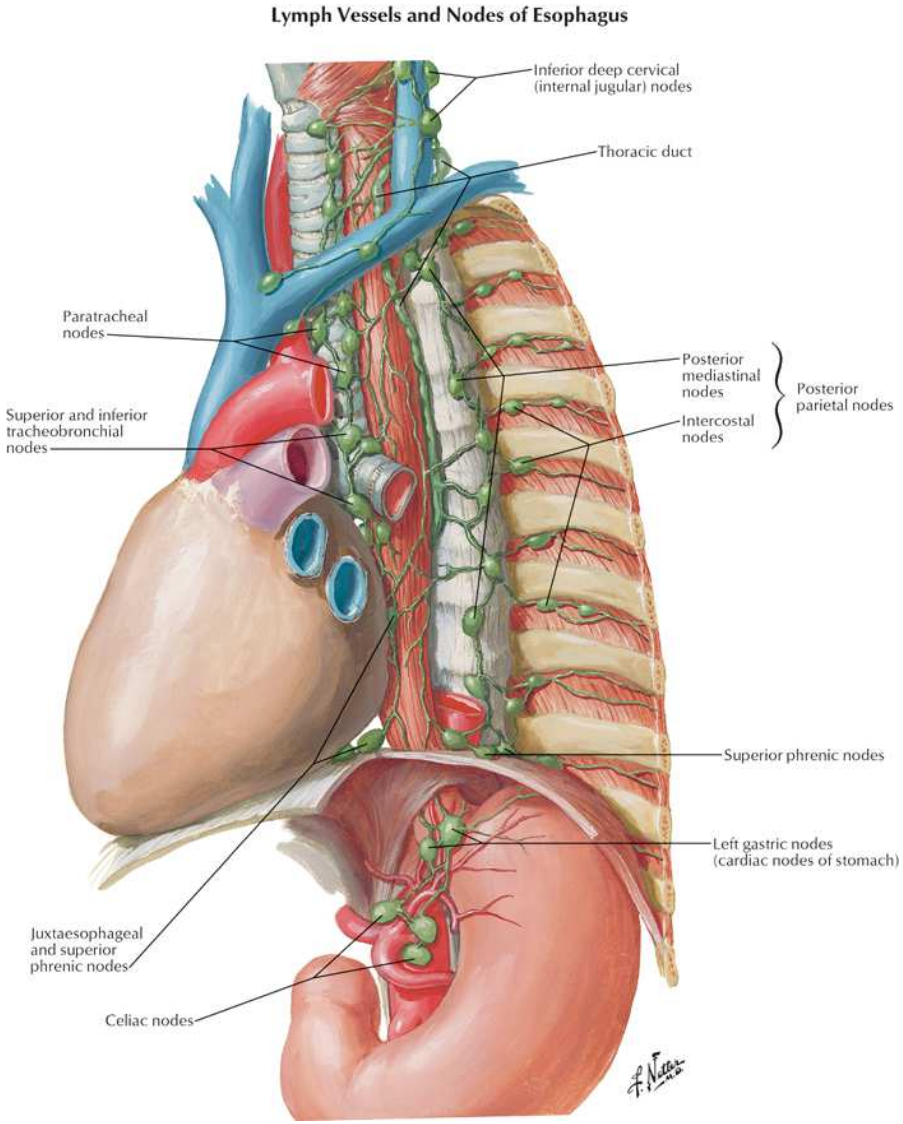

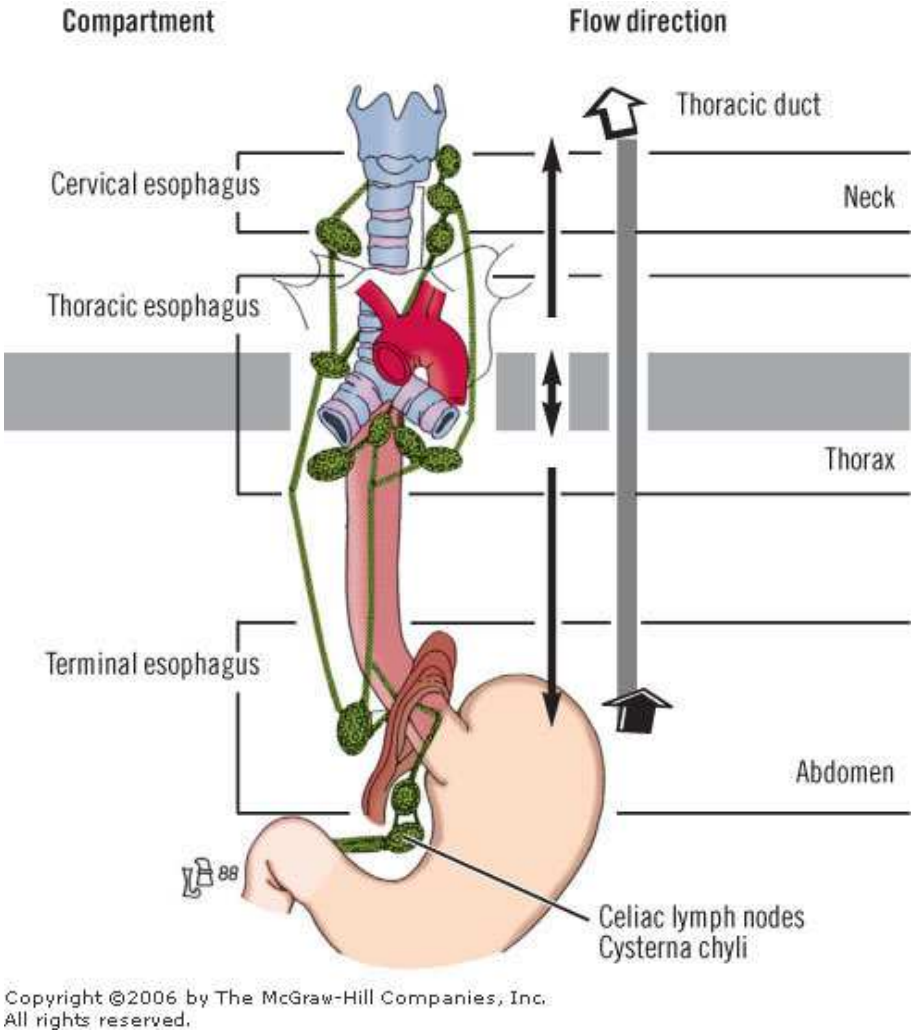

Copyright ©2006 by The McGraw-Hill Companies, Inc.
All rights reserved.

Lymphatic drainage (2)

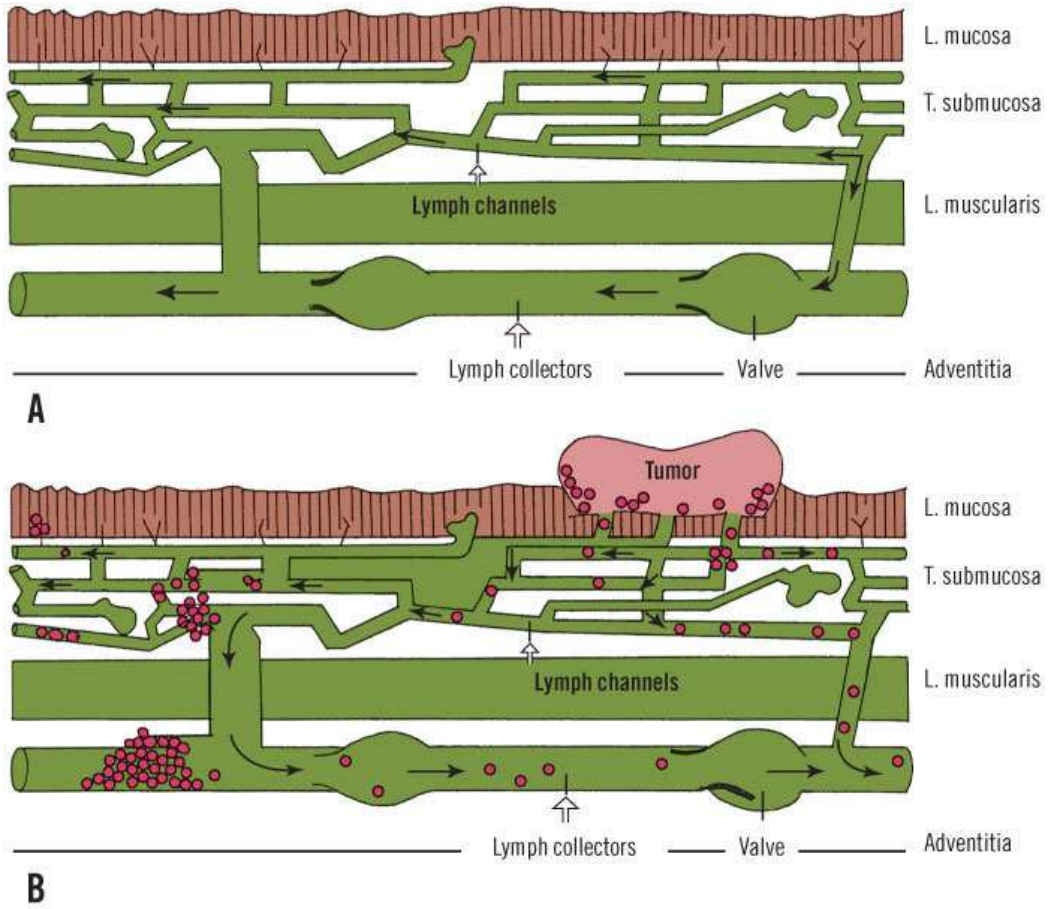

Copyright ©2006 by The McGraw-Hill Companies, Inc.
All rights reserved.

Regional lymph node involvement and CTV

- Tis 0%
- T1b 31-56%
- T2 58-78%
- T3 83-100%

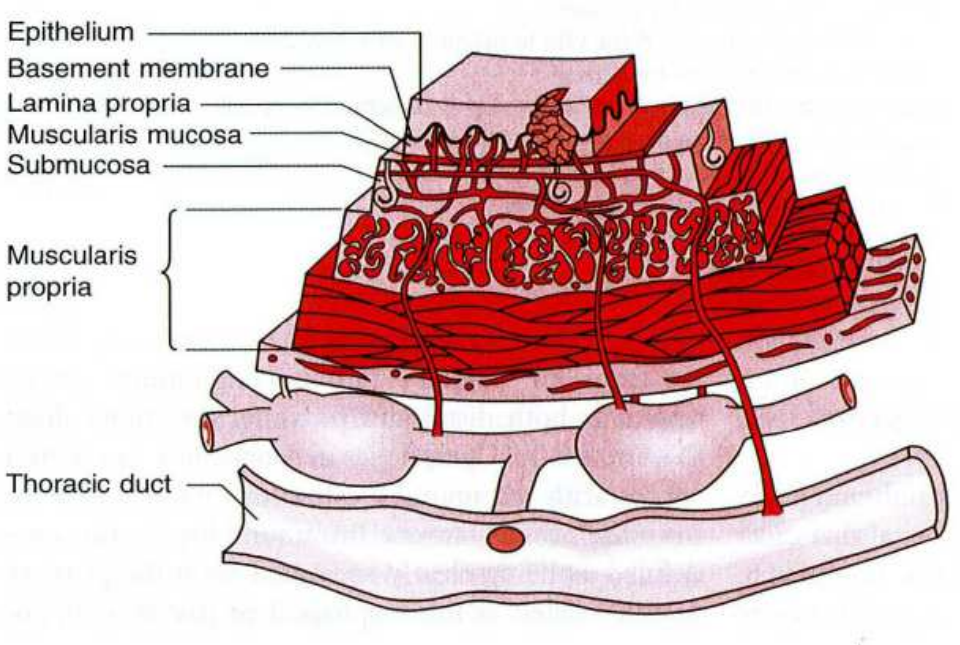

Distant lymph node metastasis

'Skip metastasis'

Lymphnodal spread according to T location

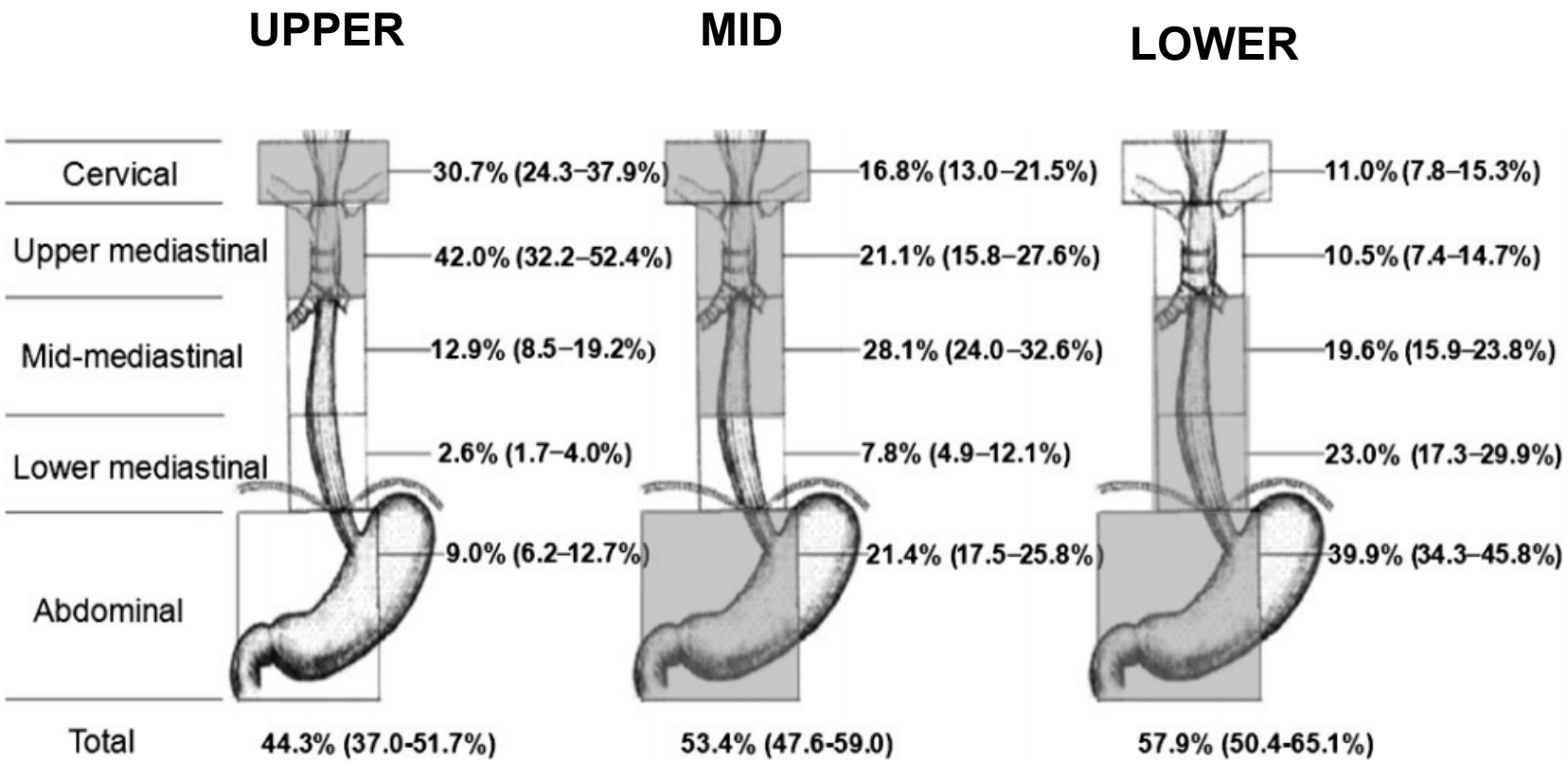

Metanalysis of 45 surgical studies (n 18.415)

Ding XET et Al – Br J Radiol– 2012

Lymphnodes classification

- Divided in 3 levels:
  - Cervical (‘Grégoire’)
  - Thoracic (IASLC)
  - Abdominal (JGCA)

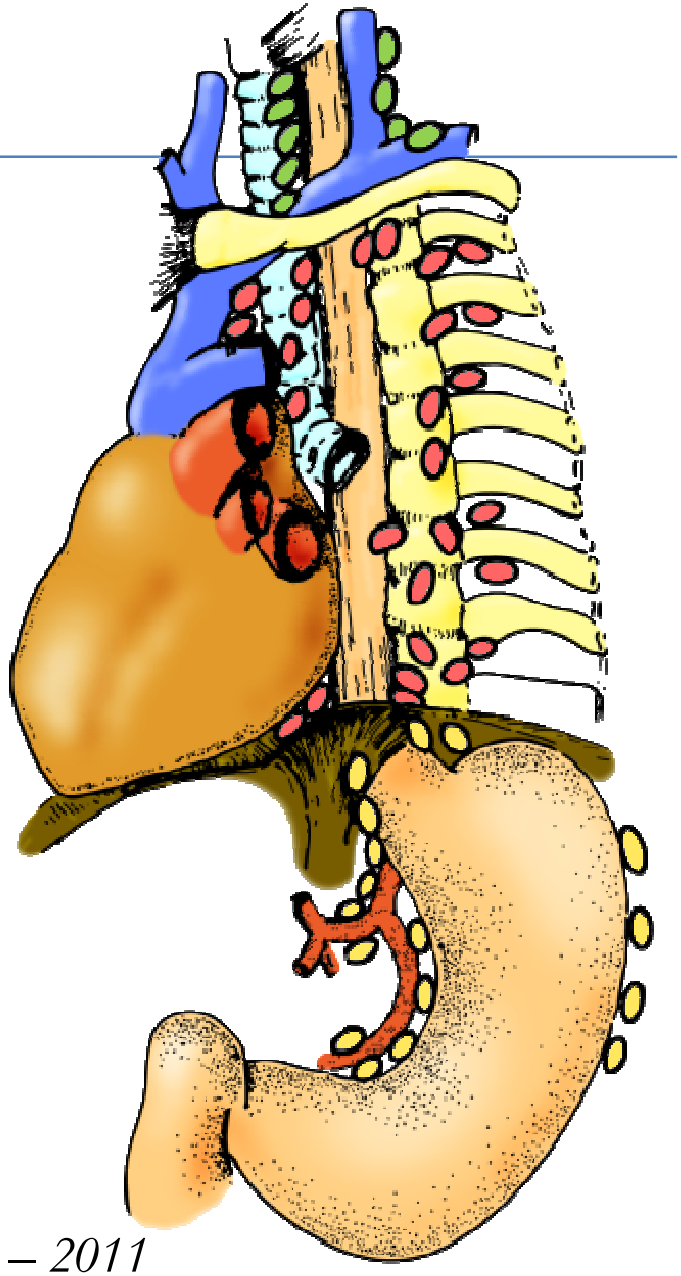

Grégoire et al. –Radiother Oncol – 2013
Rush VW et al– J Thor Oncs– 2009
Japanese Society for Esophageal Diseases – Esophagus – 2011

Cervical level

- Deep nodes

Dahanca, EORTC, HKNPCSG, NCIC CTG, NCRI, RTOG
IV a lower jugular lymph-nodes
IV b medial supra-clavicular nodes

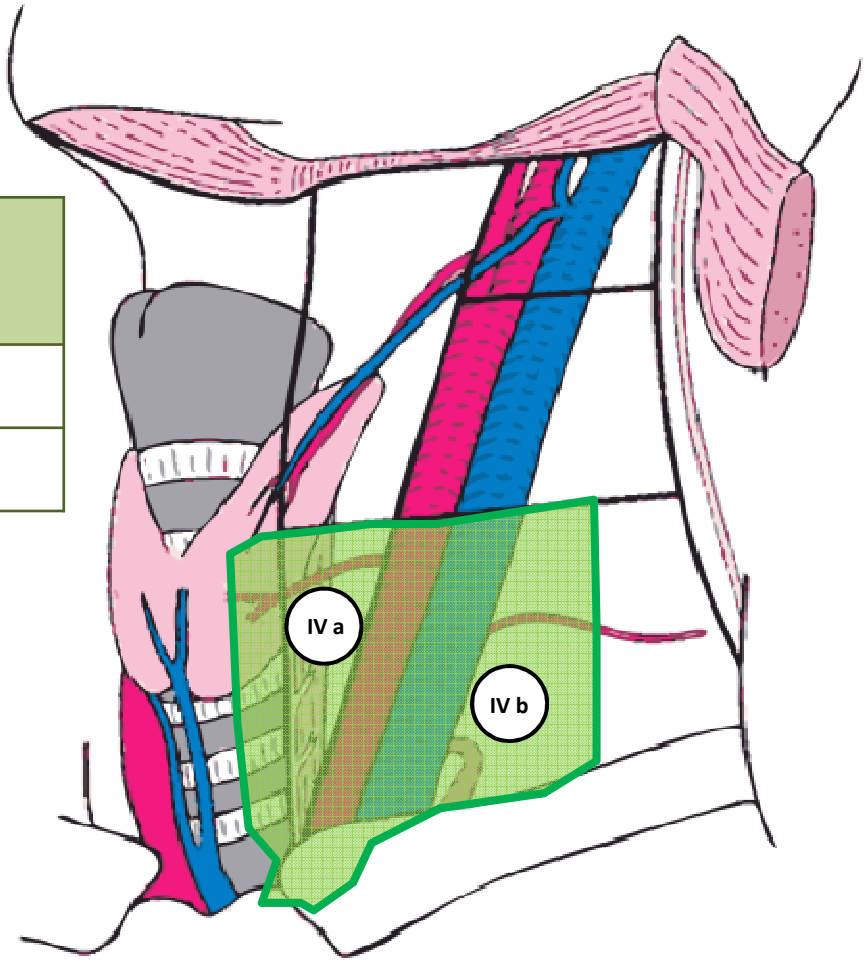

Grégoire et al. –Radiother Oncol – 2013

Thoracic level: IASLC

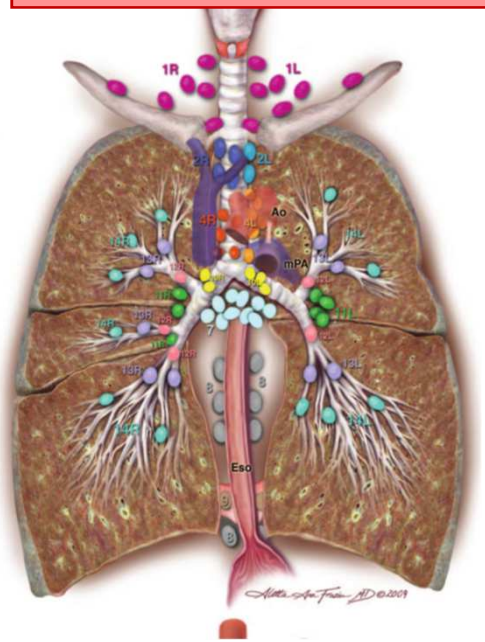

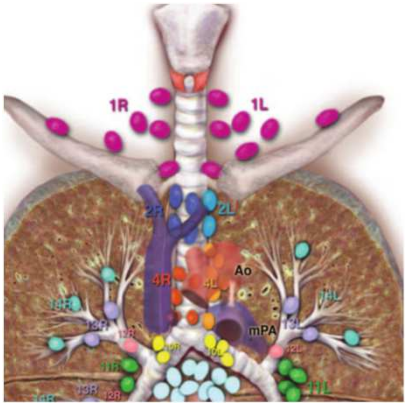

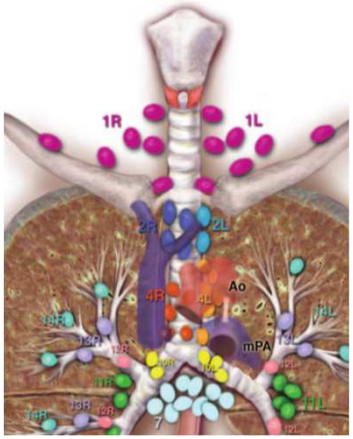

AORTIC NODES

AP zone

- 5 Subaortic
- 6 Para-aortic (ascending aorta or phrenic)

INFERIOR MEDIASTINAL NODES

Subcarinal zone

- 7 Subcarinal

Supraclavicular zone

- 1 Low cervical, supraclavicular, and sternal notch nodes

SUPERIOR MEDIASTINAL NODES

Upper zone

- 2R Upper Paratracheal (right)
- 2L Upper Paratracheal (left)
- 3a Prevascular
- 3p Retrotracheal
- 4R Lower Paratracheal (right)
- 4L Lower Paratracheal (left)

Rusch V W et al– J Thor Oncs– 2009

Abdominal level

JSED Classification
1 Right cardiac
2 Left cardial
3 Lesser curvature
7 Left gastric artery
8 Common hepatic art
9 Celiac artery
11 splenic artery
16a1 para-aortic

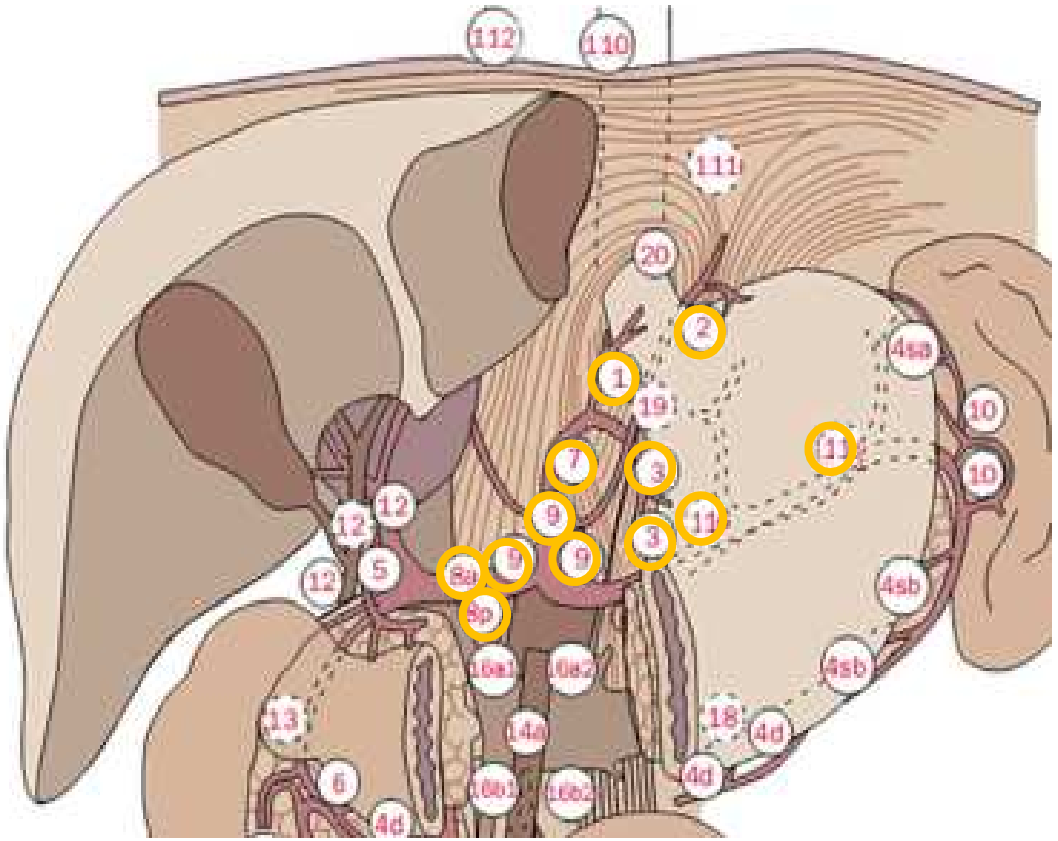

Japanese Society for Esophageal Diseases – Esophagus – 2004

Guidelines

International Journal of Radiation Oncology biology • physics

www.redjournal.org

Clinical Investigation

Expert Consensus Contouring Guidelines for Intensity Modulated Radiation Therapy in Esophageal and Gastroesophageal Junction Cancer

Abraham J. Wu, MD,* Walter R. Bosch, DSc,† Daniel T. Chang, MD,‡ Theodore S. Hong, MD,§ Salma K. Jabbour, MD,|| Lawrence R. Kleinberg, MD,¶ Harvey J. Mamon, MD, PhD,# Charles R. Thomas Jr, MD,** and Karyn A. Goodman, MD*

**Memorial Sloan-Kettering Cancer Center, New York, New York; †Washington University, St. Louis, Missouri; ‡Stanford Cancer Institute, Stanford, California; §Massachusetts General Hospital, Boston, Massachusetts; ||Rutgers Cancer Institute of New Jersey, New Brunswick, New Jersey; ¶Johns Hopkins Medical Center, Baltimore, Maryland; #Brigham and Women's Hospital, Boston, Massachusetts; and **Knight Cancer Institute, Oregon Health & Sciences University, Portland, Oregon*

Received Nov 16, 2014, and in revised form Mar 24, 2015. Accepted for publication Mar 26, 2015.

CTV proximal tumor

1. **GTV + 3-4 cm longitudinal** along mucosa. For very proximal tumors, the upper border **should not extend above the level of the cricoid cartilage** unless there is gross disease at that level.

2. **GTV + 1 cm radial**: microscopic spread + para-esophageal **St.8 (IASLC)**.
   Heart level + **0,5 cm** into cardiac tissue (in the absence of gross invasion)

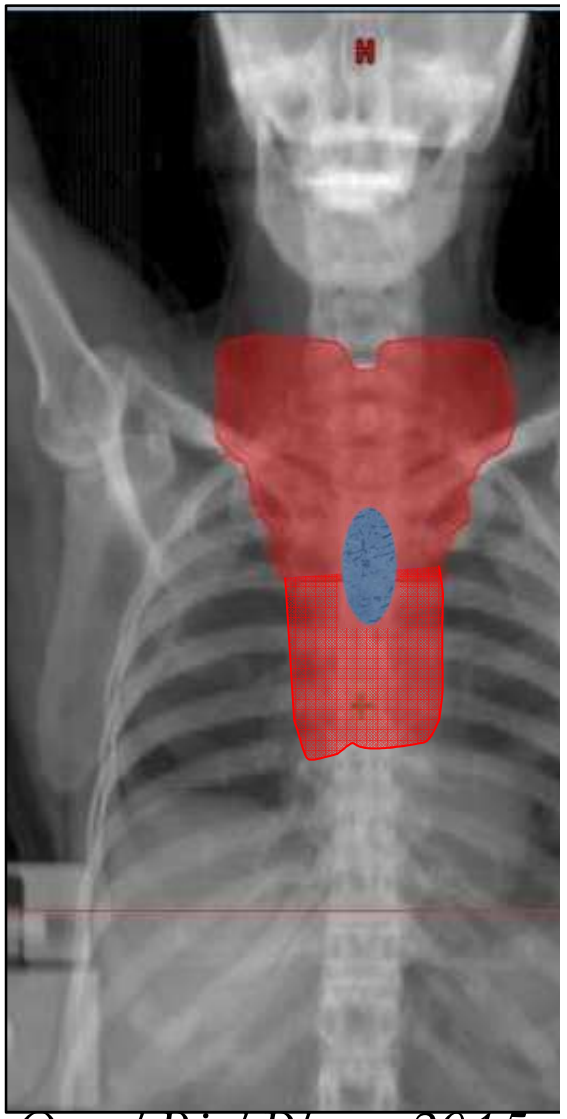

Wu AJ et Al – Int J Radiat Oncol Biol Phys– 2015

CTVe proximal tumor

3. Supra-clavicular nodes:

- **Station IVa-b** (Grégoire); **exlcude trachea** up to the **thorac inlet**

4. Peri-esophageal nodes (st8 IASLC) along the expansion of GTV

5. Mediastinal nodes:

- **above the AORTIC ARCH**: prevascular nodes (IASLC st 3), anterior border of the CTV can be extended toward the sternum and clavicular heads, including the trachea
- **Aortic arch→CARINA**: **exclude the prevascular nodes** upper and lower paratracheal St 2 and 4 R-L (IASLC), subcarinal nodes St 7 (IALSC)
- **Below the carina**: NO mediastinal nodes, only peri-esophageal

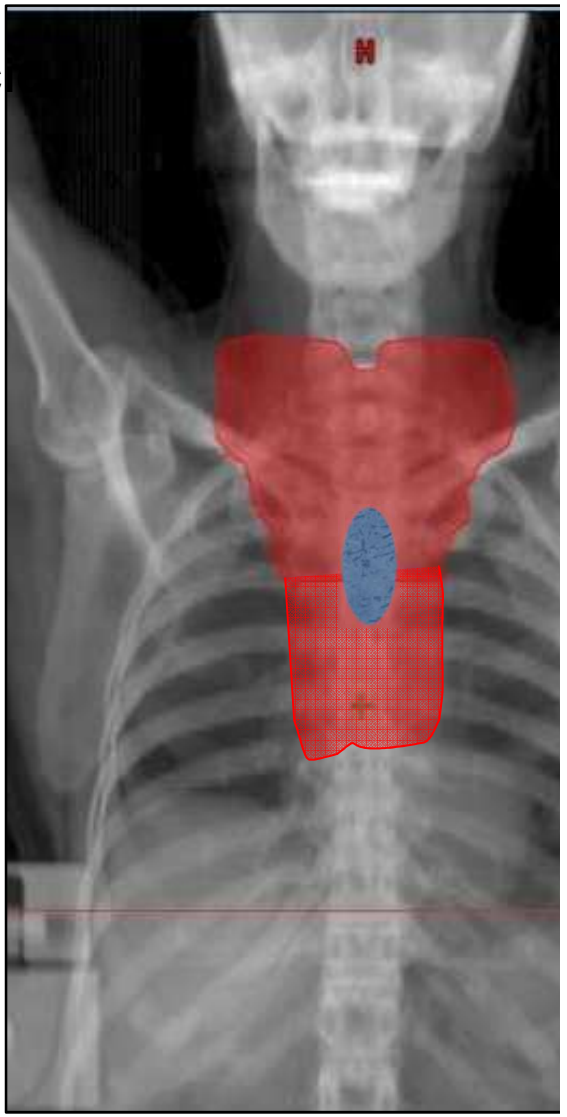

Wu AJ et Al – Int J Radiat Oncol Biol Phys– 2015

CTV proximal tumor

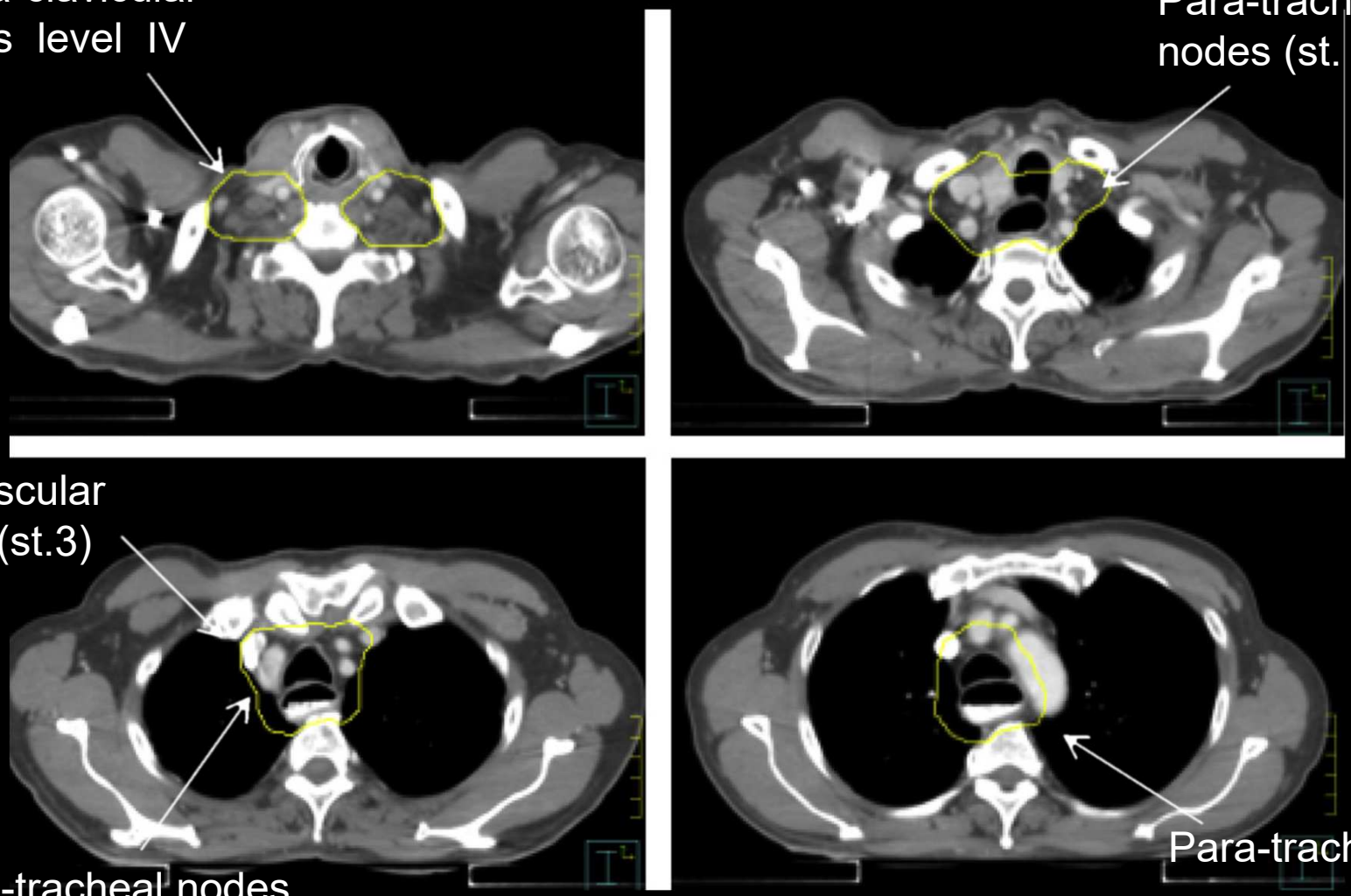

Wu AJ et Al – Int J Radiat Oncol Biol Phys– 2015

CTV proximal tumor

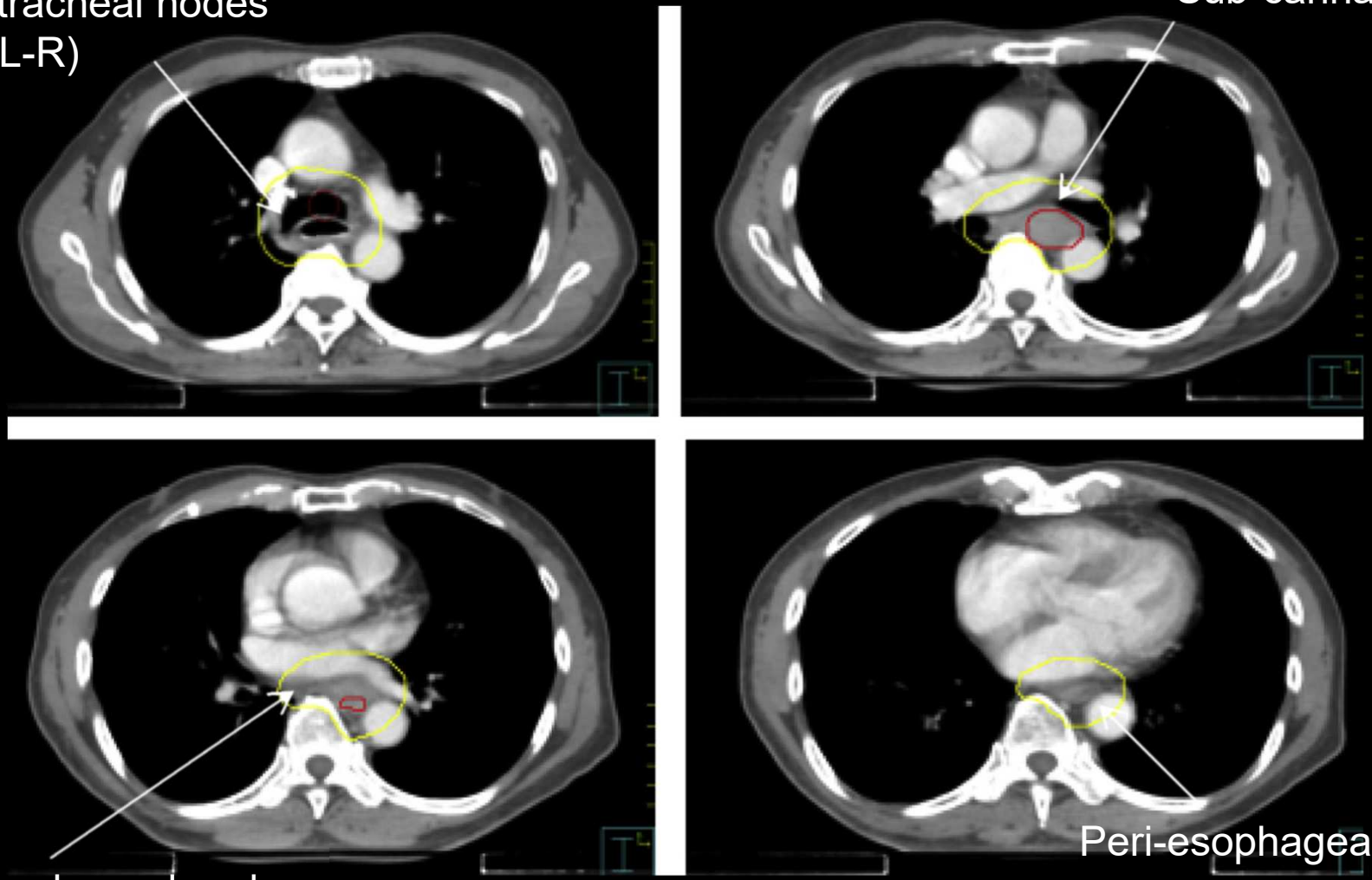

Wu AJ et Al – Int J Radiat Oncol Biol Phys– 2015

CTV distal tumor

1. **GTV**

   + 3-4 cm longitudinal (proximal) along mucosa, included also St. 8 para-esophageal (IASLC)

   + 2-5 cm on the gastric mucosa depending on the dose (45 Gy or 50 Gy)

2. **Mediastinal nodes:**

   Only para esophageal nodes along the expansion of GTV

3. **Abdominal nodes:** para-cardial st.1-2 coeliac st 9, para-aortic st. 16a1, gastro-hepatic ligament (L gastric st 7; lesser curv st.3) + splenic nodes st 11 (if massive gastric infiltration) (JSED)

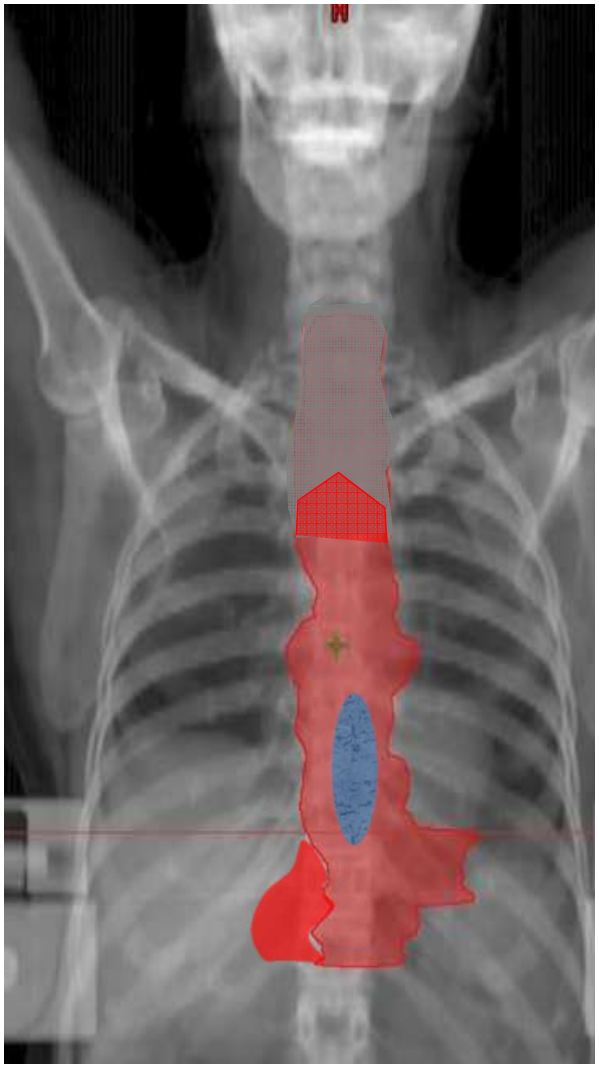

Wu AJ et Al – Int J Radiat Oncol Biol Phys– 2015

CTV distal tumor

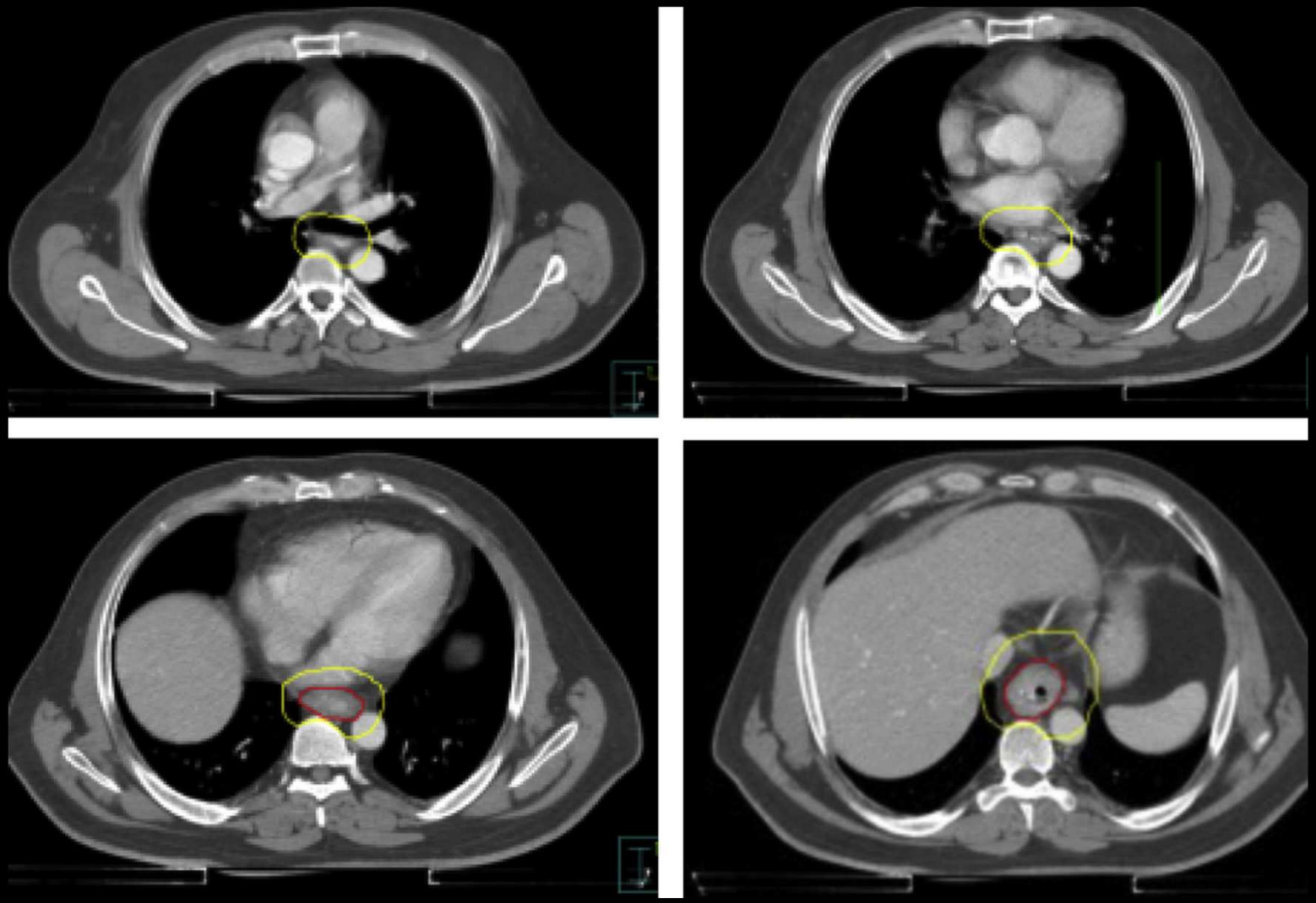

Wu AJ et Al – Int J Radiat Oncol Biol Phys– 2015

CTV distal tumor

Para-cardial nodes sta (1-2 JSED) + 2-5 cm of gastric wall

Gastro-hepatic ligament (st 3 lesser curv and 7 left gastric artery JSED)

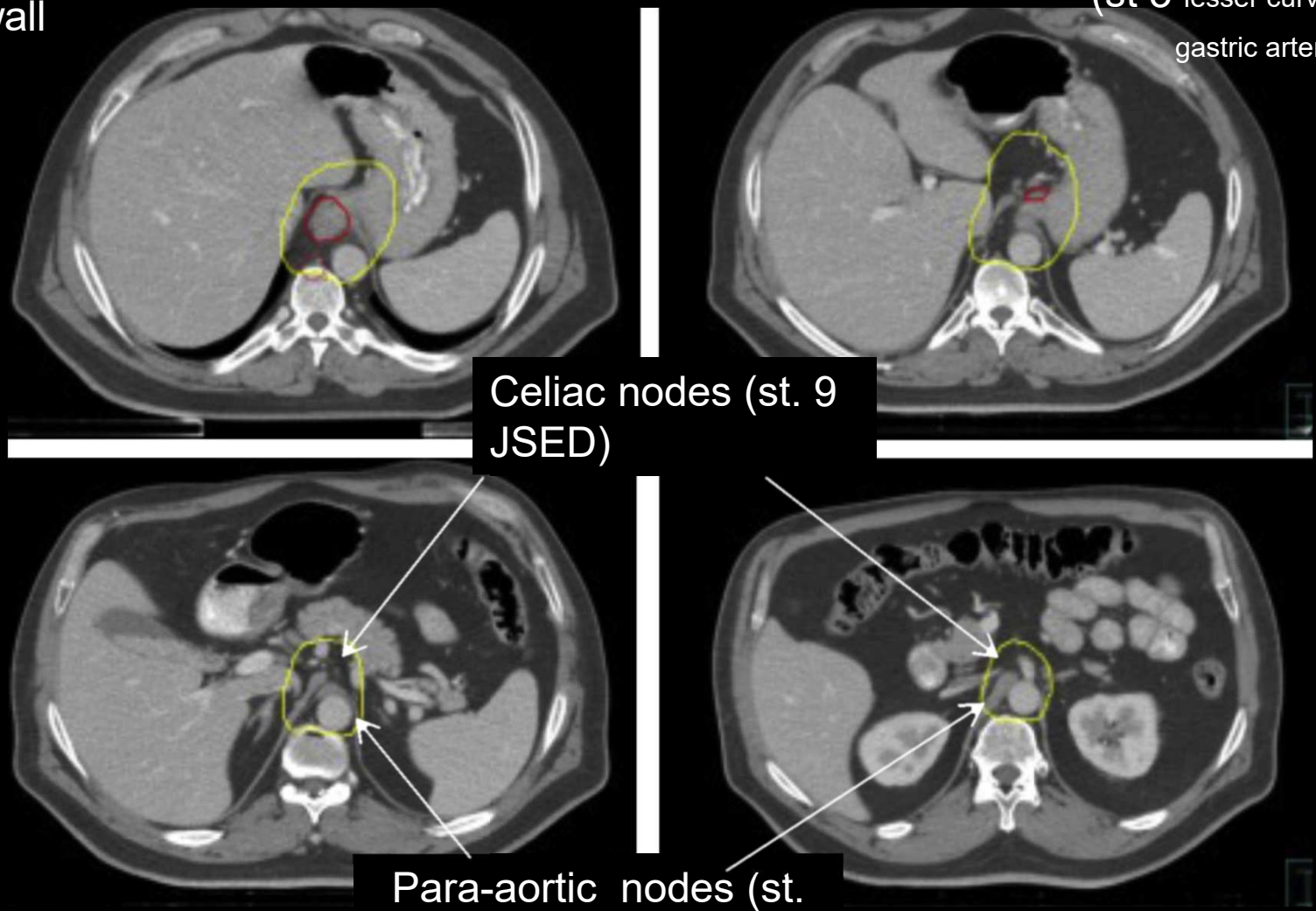

Celiac nodes (st. 9 JSED)

Para-aortic nodes (st. 16a1 JSED)

Wu AJ et Al – Int J Radiat Oncol Biol Phys– 2015

CTV

- **GTV + margin**
- **Nodes with positive possibility of ≥ 20%**
- **Depends on tumor site**

Planning Target Volume

Mobility of oesophagus

Courtesy from Oscar Matzinger

Effect of breathing on oesophagus

	Thoracic part	Abdominal part
Yaremko 2008	8 mm	10 mm
Welch 1982	4 mm	6 mm
Dieleman 2007	7 mm	9 mm

Courtesy from Oscar Matzinger

Relative marker displacement during breathing

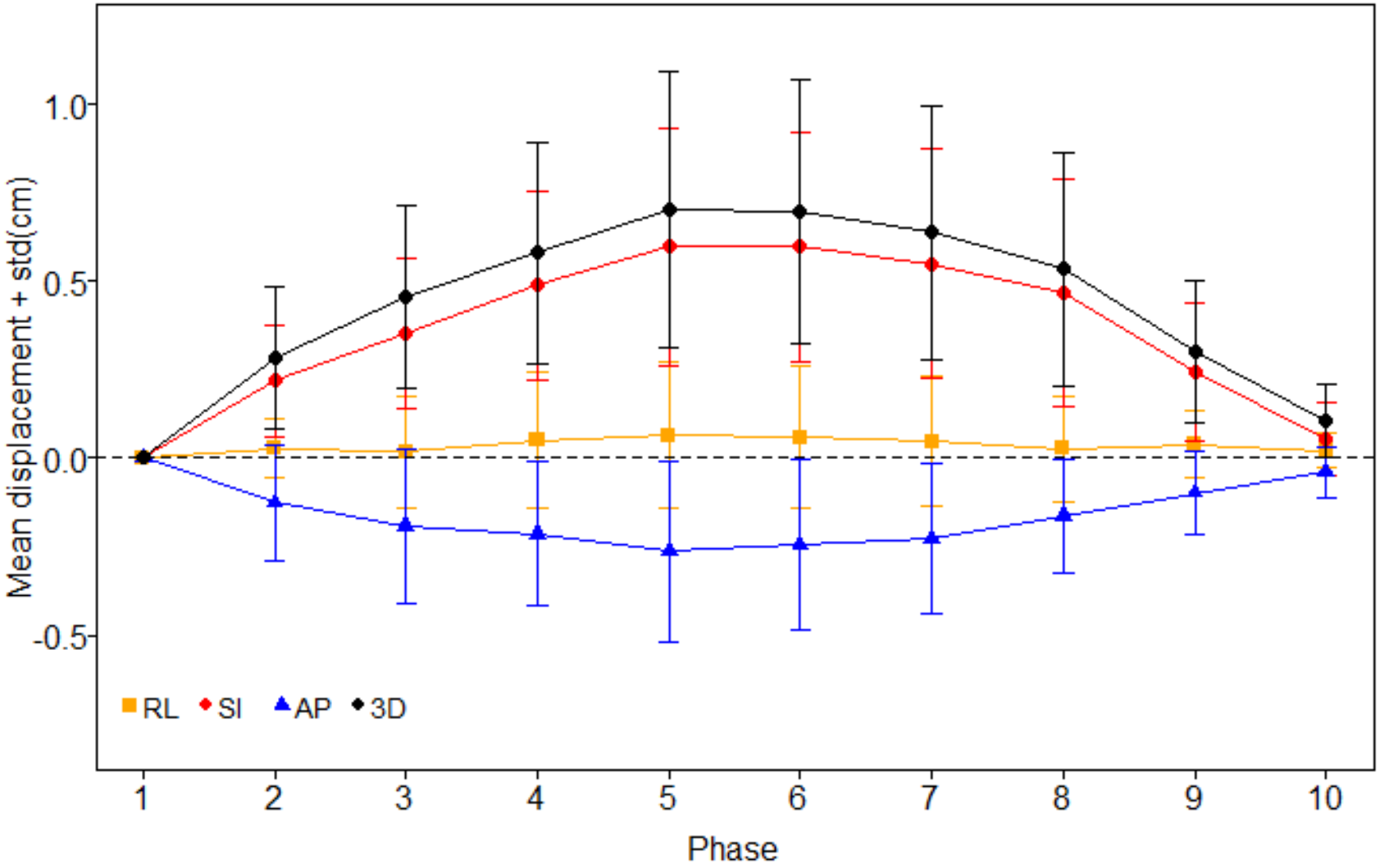

Courtesy from Maarten C C M Hulshof

Results

- ***Motion in each phase***
- CC > LR & AP
- Lower > Upper
- Exhalation
  - To left
  - To cranial
  - To posterior
- Induced by respiration

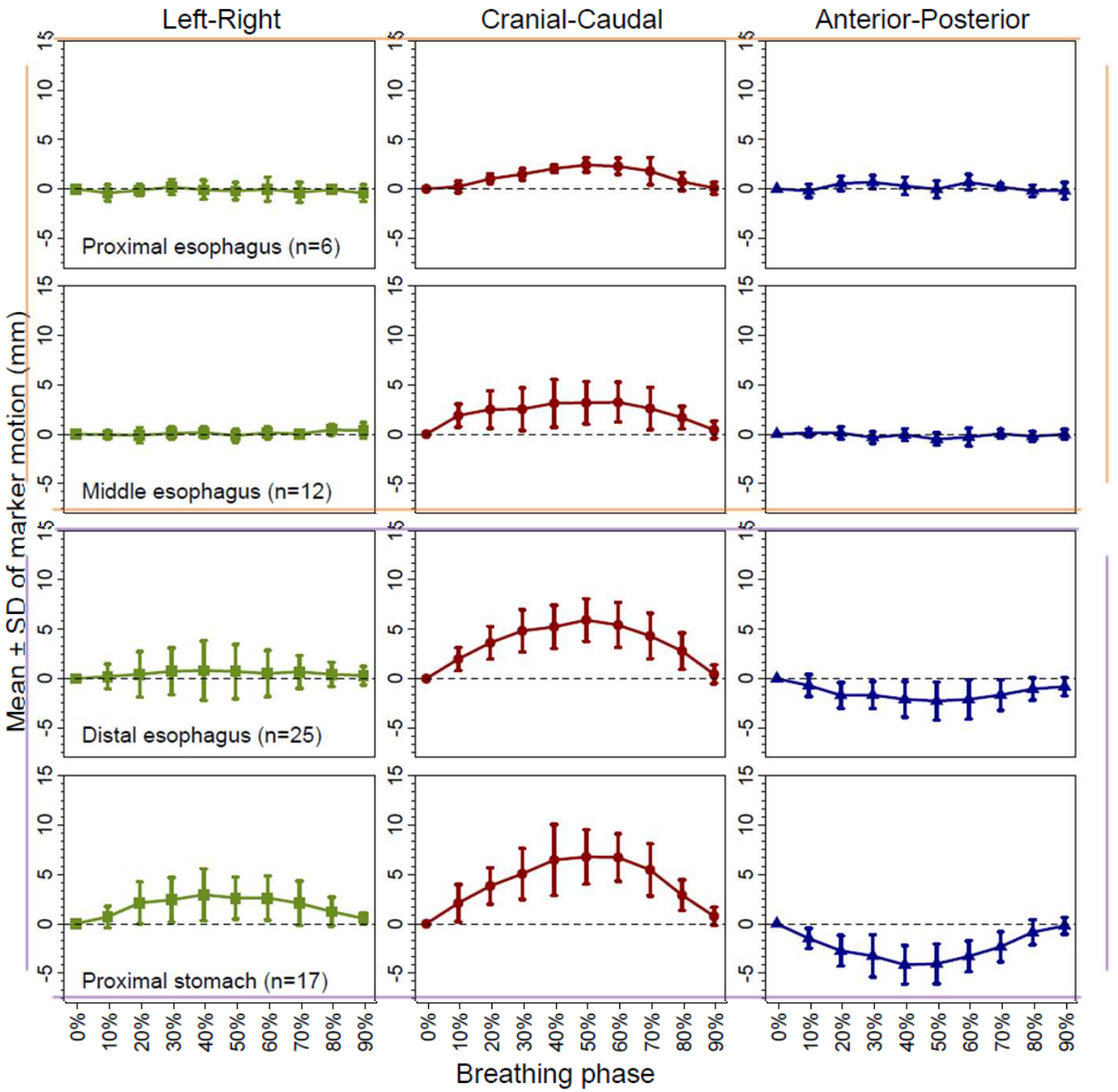

CTV-ITV margin proximal and mid-esophageal tumors

- APPA: 7-8 mm
- Lateral: 5-7 mm
- Cranio-caudal: 10 mm

PTV

- **CTV + 0.5-1 cm in all directions**
- **Distal tumors:**

→respiratory motion (3D or IMRT)

  – 4D CT imaging for superior-inferior motion

  – If > 1 cm: Respiratory gating or abdominal compression

→ Gastric filling: intra-fraction movements

Nothing by mouth before simulation and each treatment

Wu AJ et Al – Int J Radiat Oncol Biol Phys– 2015

Take home

- **RT (with chemo)** has an important role in esophagus cancer treatment
- **GTV definition**: **on CT**, **PET** might help for **localization-length-variability**, **never decrease** CTVs according to PET
- **CTV-T:** longitudinal **3-5 cm** according hystology
- **CTV-N:** include always paraesophageal, any positive + area delineation
- **CTV-elective:** modulated according **tumor site**

OARs constraints and delineation

organ	Toxicity	dosimetric parameters	delineation
	Myelopathy	Dmax < 45 Gy Dmax < 40Gy (when conc CT)	2 cm above and belove the CTV
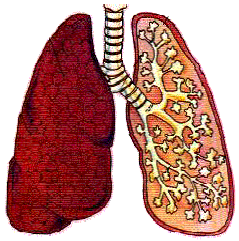	Post-op Pneumonitis ARDS	V10Gy < 40% V15 Gy < 30% V20 Gy < 40% V5 Gy < 2300 cc	Both lungs
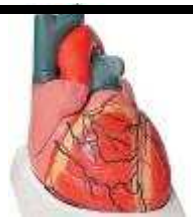	Pericardium Myocardium Coronary reduction EF	V25 Gy< 50% V40 Gy < 30%	Entire heart
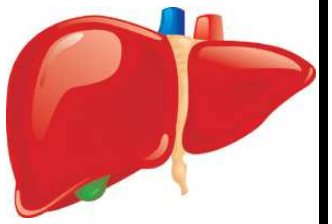	Radiation Induced Liver Disease	V30 Gy < 30%	Entire liver

QUANTEC– IJROBP- 2010

OARs not preventable toxicities

Esophagus:
Is the target!!
stenosis at the level of the previuos tumor

DYSPHAGIA: 16%

Thyroid:
in cervical and upper esophagus
entire prescribed dose

HYPOTHIROIDISM: 36%
Dose > 30Gy

Fujiwara M et al. – J Rad Res- 2015

ESTRO School

WWW.ESTRO.ORG/SCHOOL

Anatomy and lymph node drainage for breast cancer

Stefan Delorme

ESTRO School

Outline

- Types of breast cancer
- Imaging methods and features
  - ➢Mammography
  - ➢Ultrasound
  - ➢CT
  - ➢MRI
- T stages
- Nodal drainage and N Stages
- Treated breast cancer

ESTRO School

Outline

- Types of breast cancer
- Imaging methods and features
  - ➢Mammography
  - ➢Ultrasound
  - ➢CT
  - ➢MRI
- T stages
- Nodal drainage and N Stages
- Treated breast cancer

ESTRO School

Breast cancer: Classification

Criterion	*Types*
According to origin	- *Ductal* - *Lobular*
According to invasiveness	- *In situ* - *Invasive*
According to differentiation	- *G1 Low-grade* - *G2 Intermediate grade* - *G3 High-grade*
According to receptor status	- *Estrogen receptor + / -* - *Progesteron receptor + / -*
According to mutation status	- *Her-2-neu positive* - *Her-2-neu negative*

ESTRO School

Anatomy of the breast

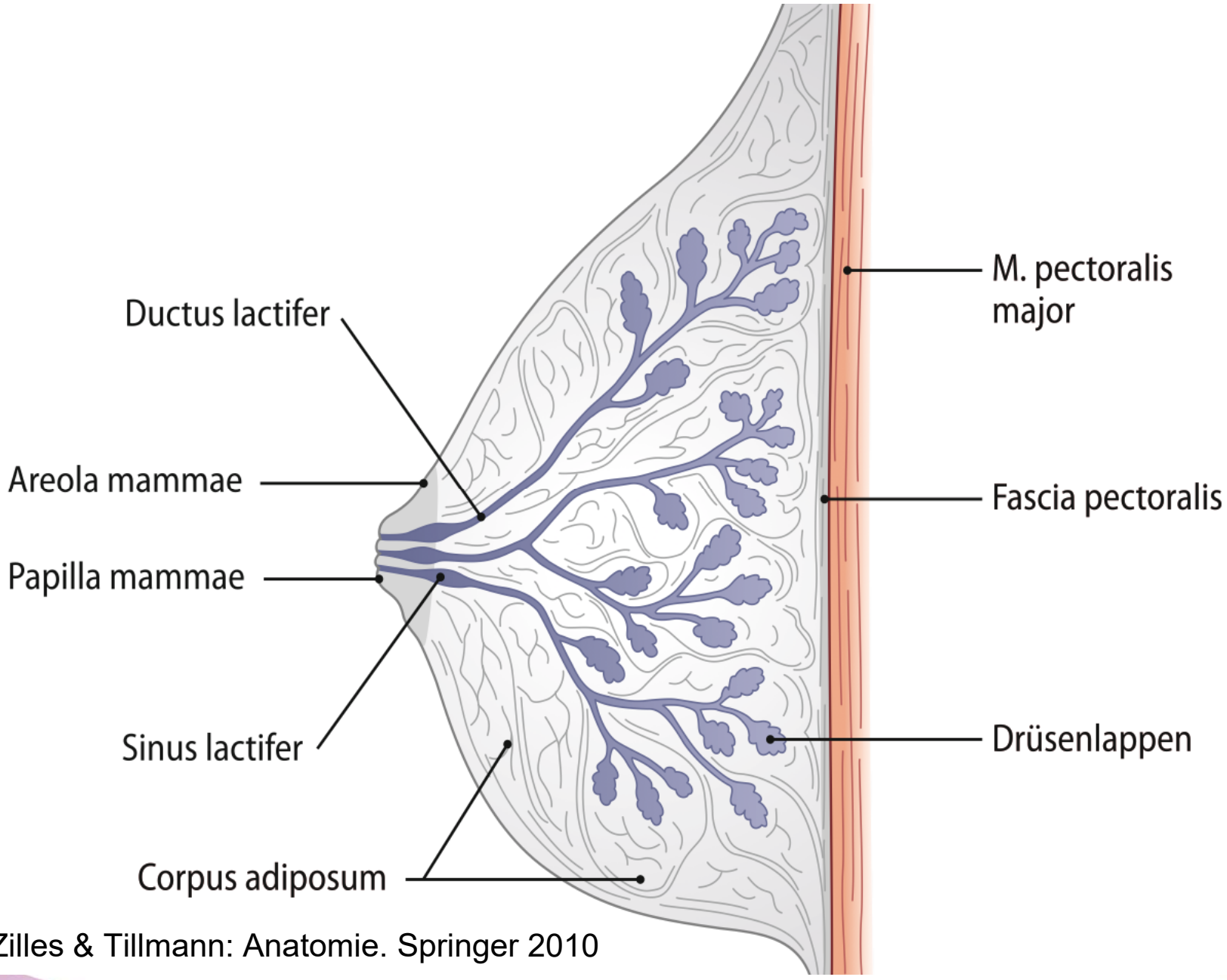

Zilles & Tillmann: Anatomie. Springer 2010

ESTRO School

Anatomy of the breast

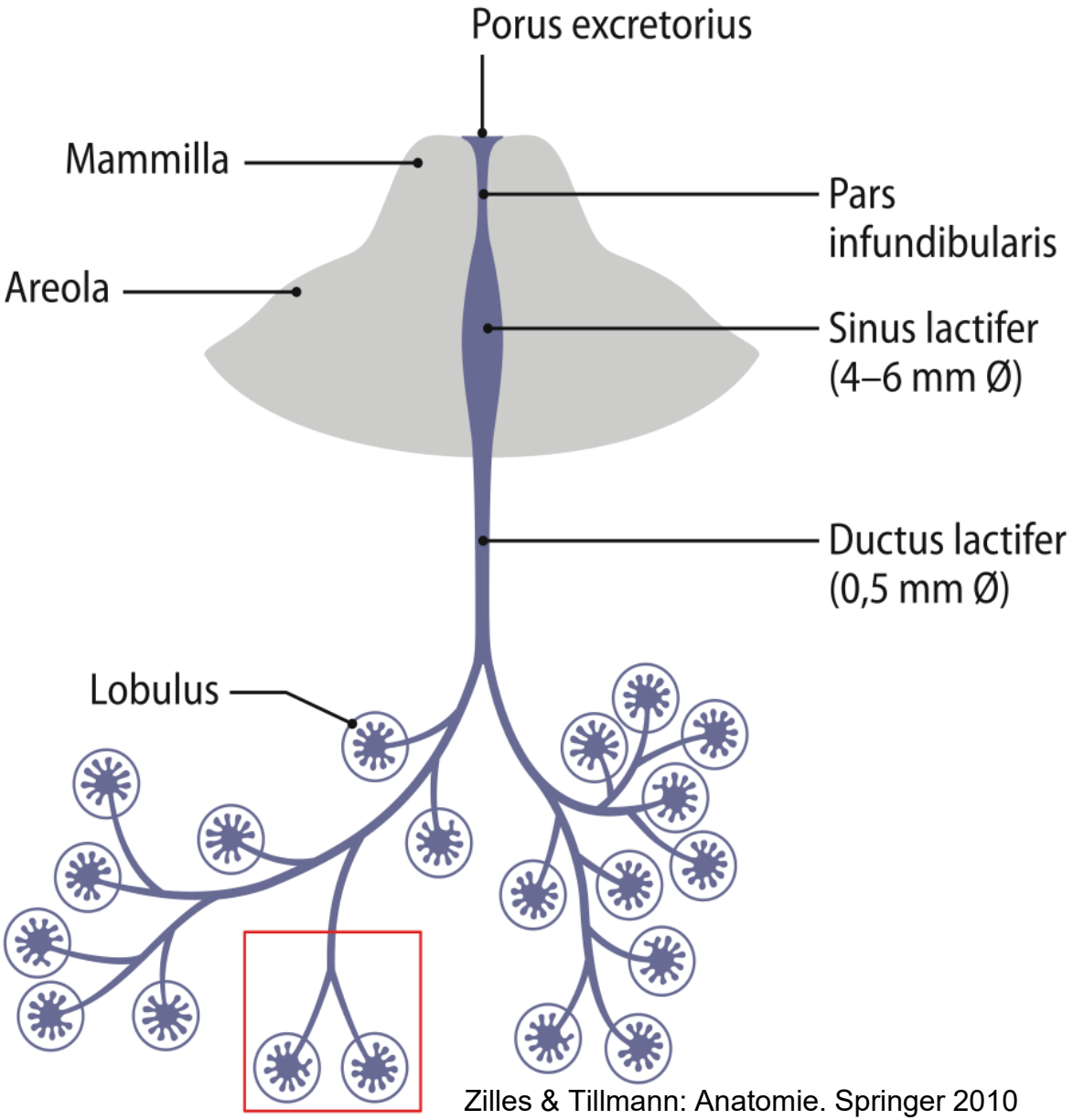

Zilles & Tillmann: Anatomie. Springer 2010

ESTRO School

Anatomy of the breast

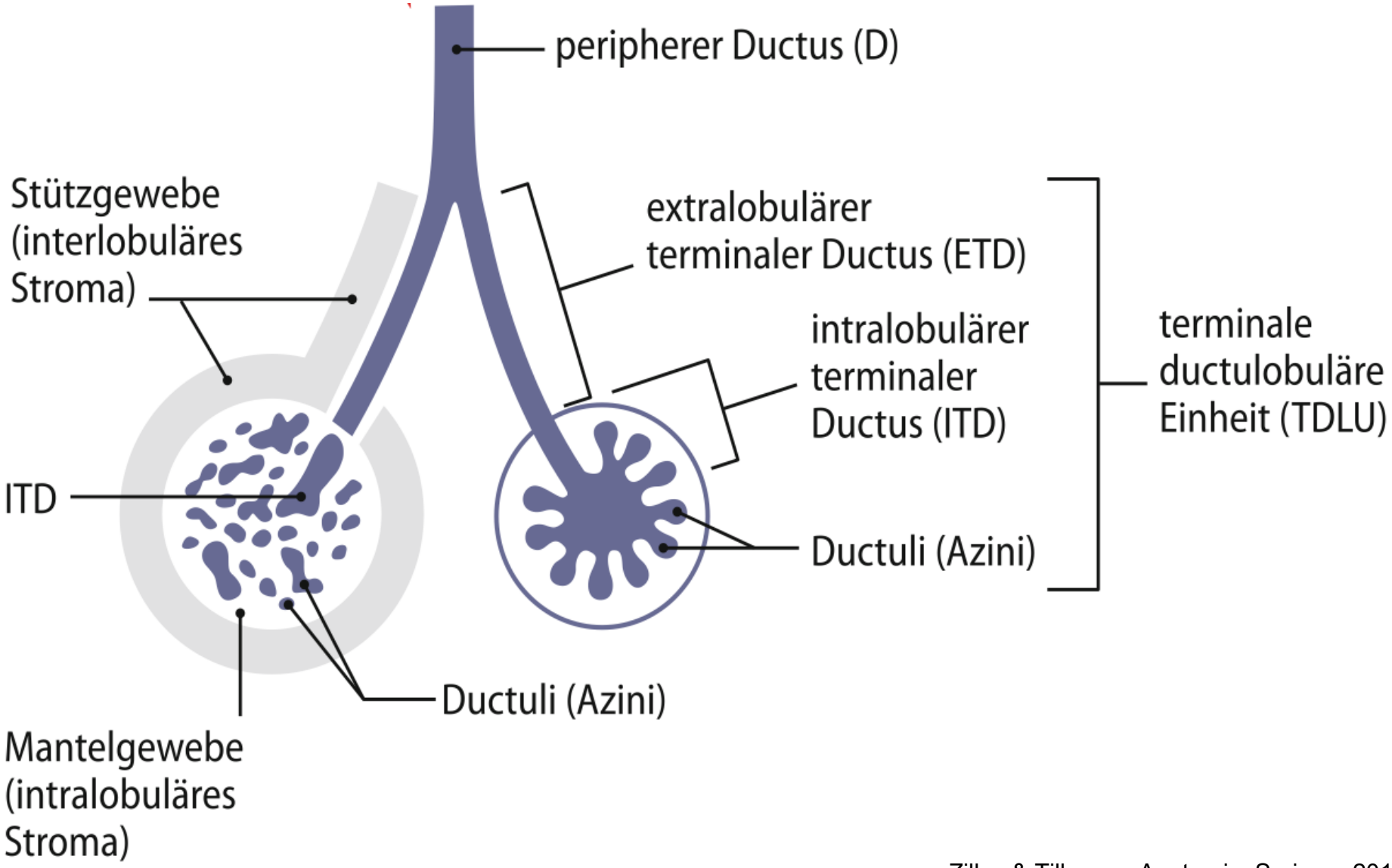

Zilles & Tillmann: Anatomie. Springer 2010

Breast cancer: Growth patterns

- Ductal carcinoma
  - ➢Ductal carcinoma in situ (DCIS)
    - Thin extensions
    - Microcalcifications
  - ➢Invasive foci
    - Solitary
    - Multifocal
- Lobular carcinoma
  - ➢Lobular carcinoma in situ (LCIS)
  - ➢Lobular invasive carcinoma
    - Single-cell invasion pattern
- Medullary carcinoma
  - ➢Smooth lump
- Inflammatory carcinoma
  - ➢Extensive lymphangitic and skin infiltration

ESTRO School

DCIS

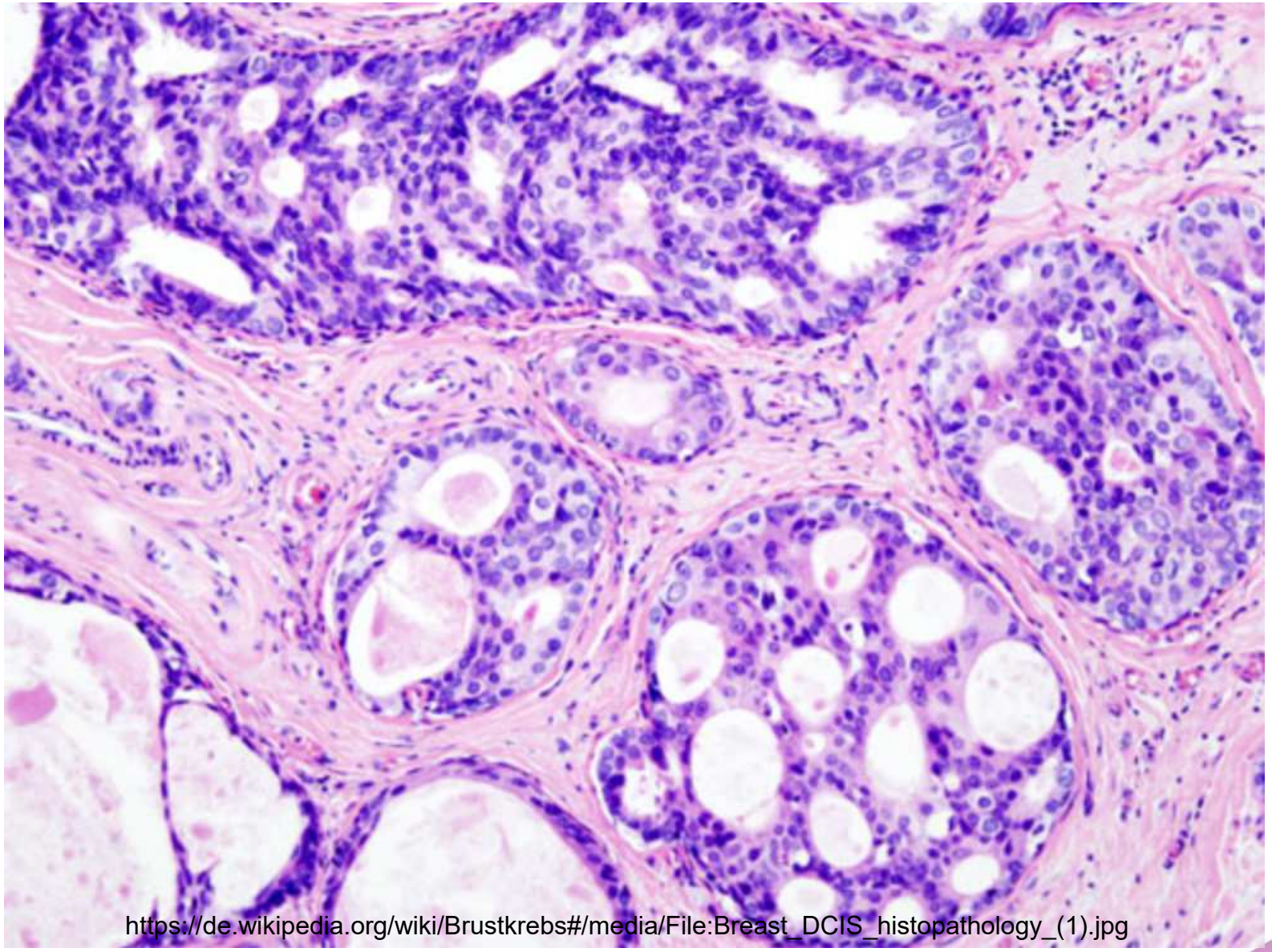

https://de.wikipedia.org/wiki/Brustkrebs#/media/File:Breast_DCIS_histopathology_(1).jpg

ESTRO School

Ductal invasive carcinoma

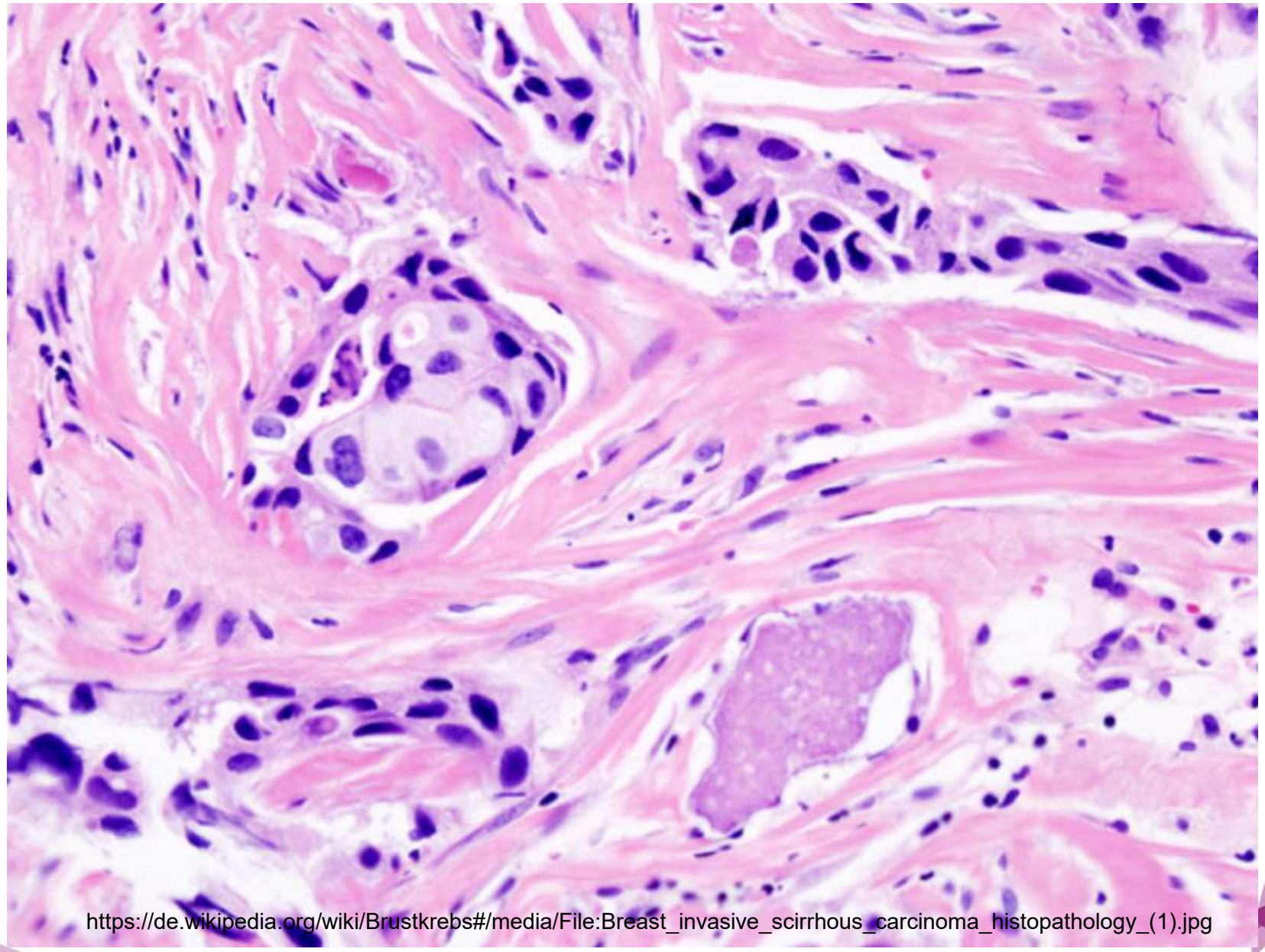

https://de.wikipedia.org/wiki/Brustkrebs#/media/File:Breast_invasive_scirrhous_carcinoma_histopathology_(1).jpg

ESTRO School

Growth patterns

Solitary solid

Interstitial (esp. in LIC)

DCIS

Multifocal DIC with extensive intraductal component (EIC)

ESTRO School

Outline

- Types of breast cancer
- Imaging methods and features
  - ➢Mammography
  - ➢Ultrasound
  - ➢CT
  - ➢MRI
- T stages
- Nodal drainage and N Stages
- Treated breast cancer

ESTRO School

Signs of breast cancer on mammography

- Mass
  - ➢Dense
  - ➢Unsharp
  - ➢Irregular or speculated
  - ➢Smooth (rare)
- Architectural distortion
  - ➢Concentric
  - ➢Retraction of surface of glandular body
- Ductal microcalcifications
- Skin thickening

ESTRO School

Calcifications



Macrocalcification: Benign

Tea saucer calcium: Benign

Acinar arrangement: Benign

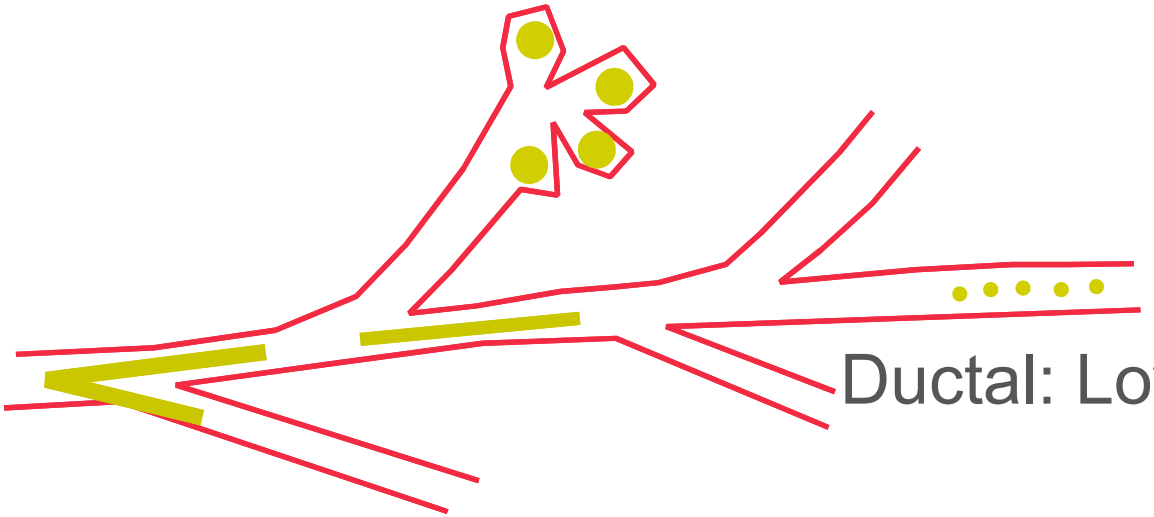

Ductal: Low-grade DCIS

Ductal: High-grade DCIS

ESTRO School

Invasive breast cancer with DCIS

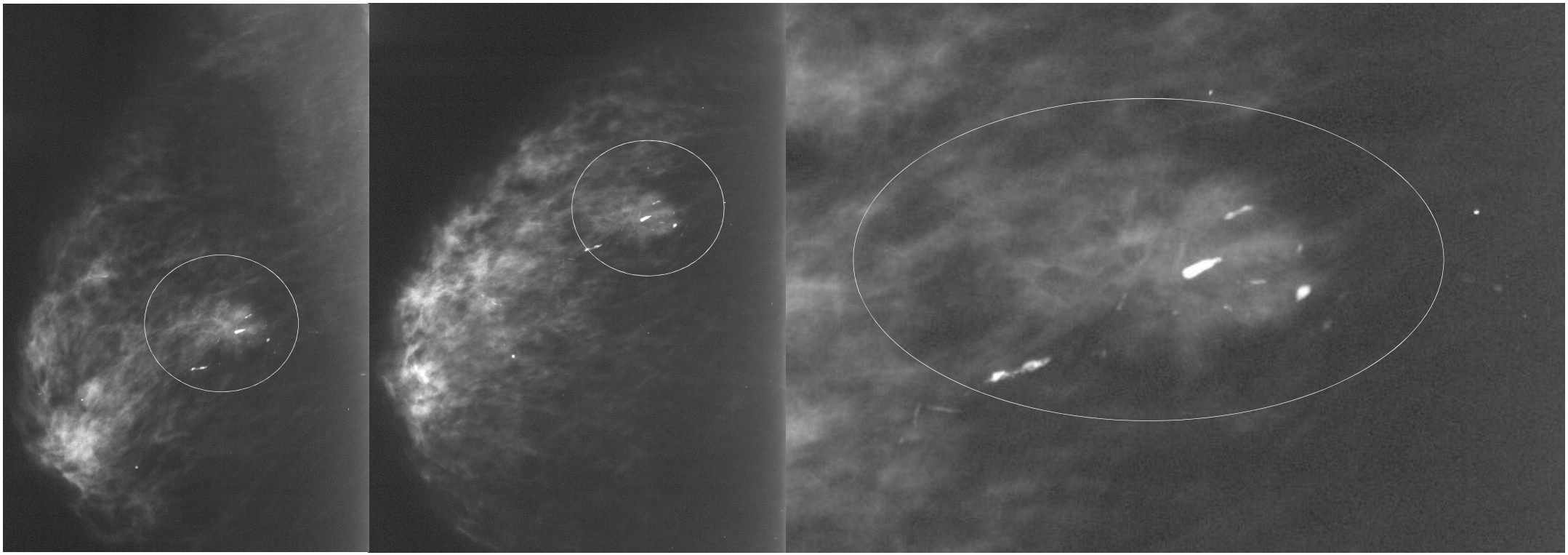

Invasive breast cancer

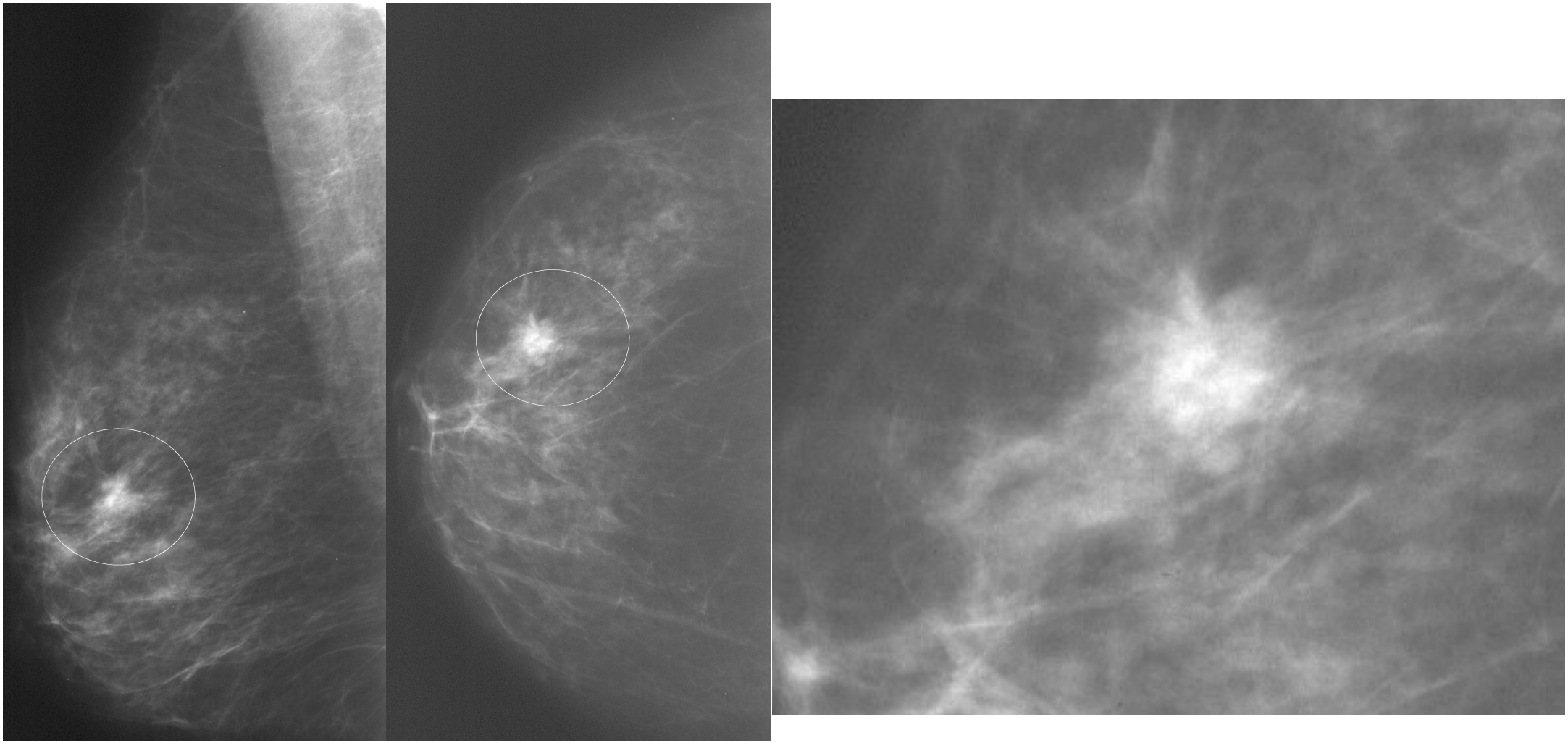

Breast cancer

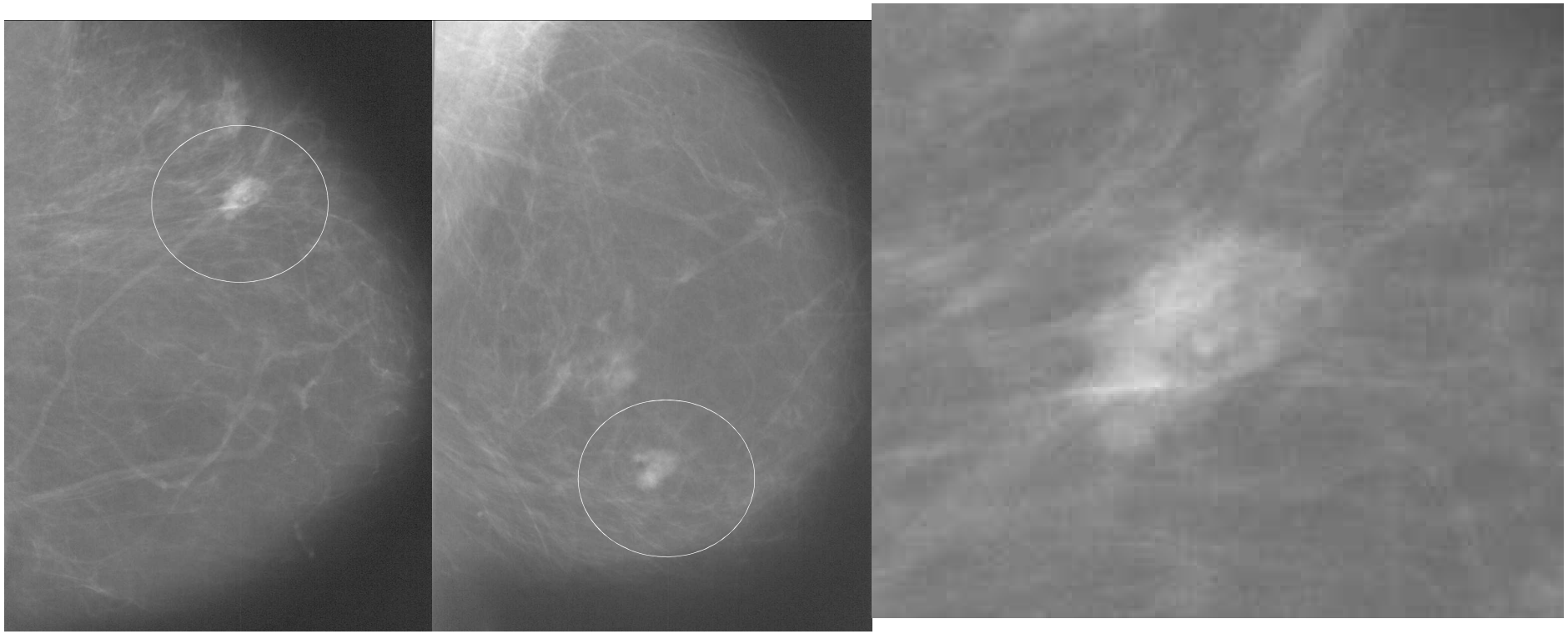

DCIS

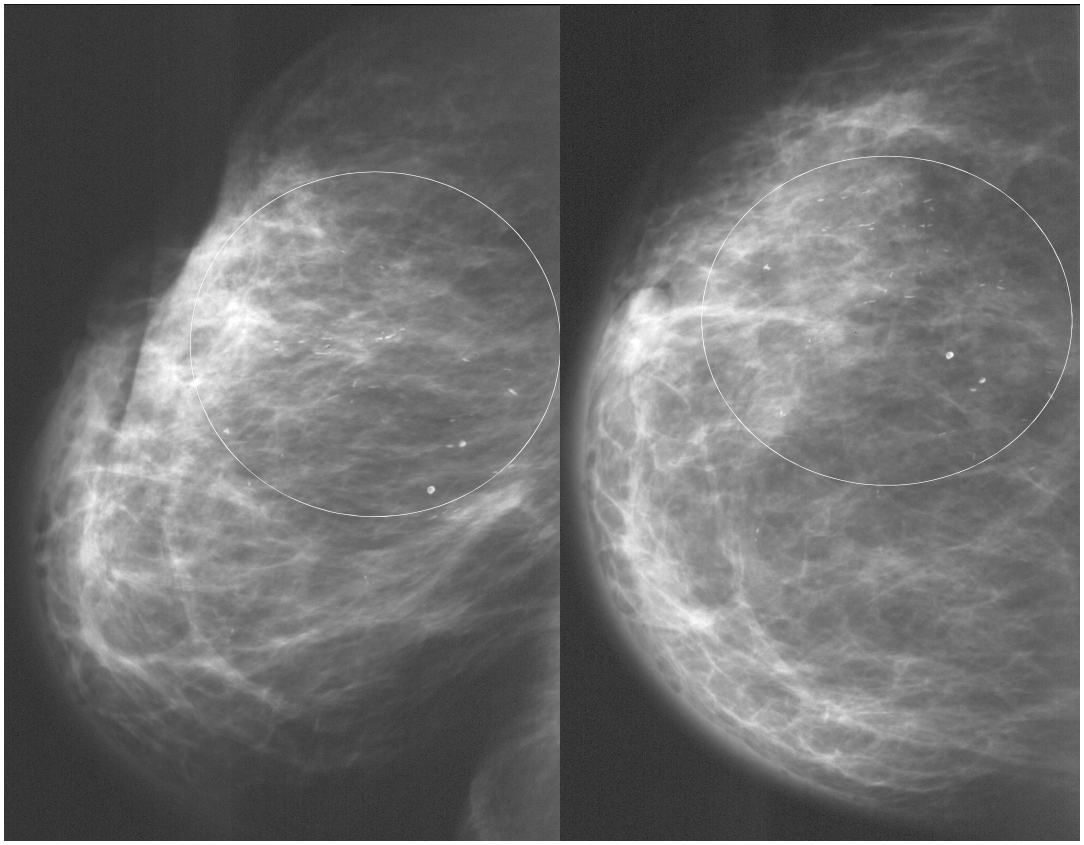

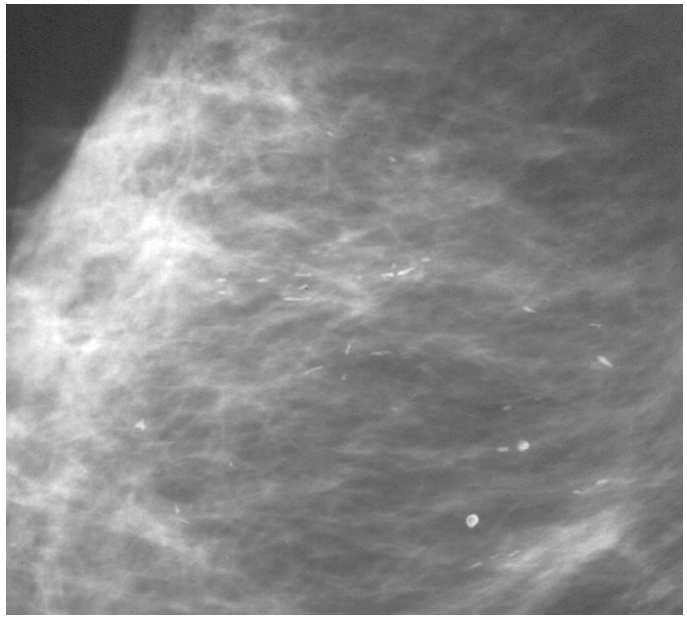

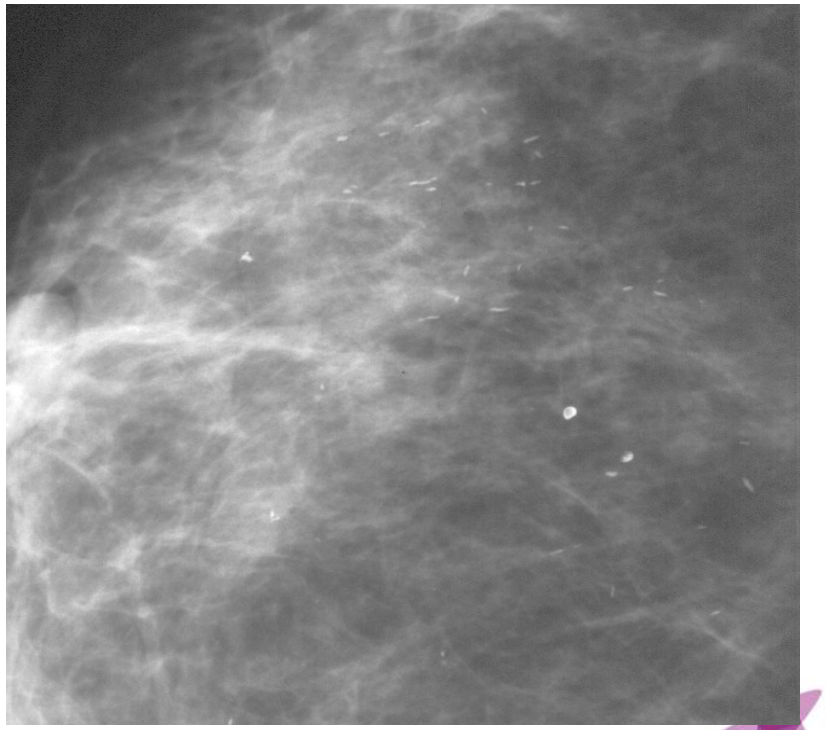

ESTRO School

DCIS

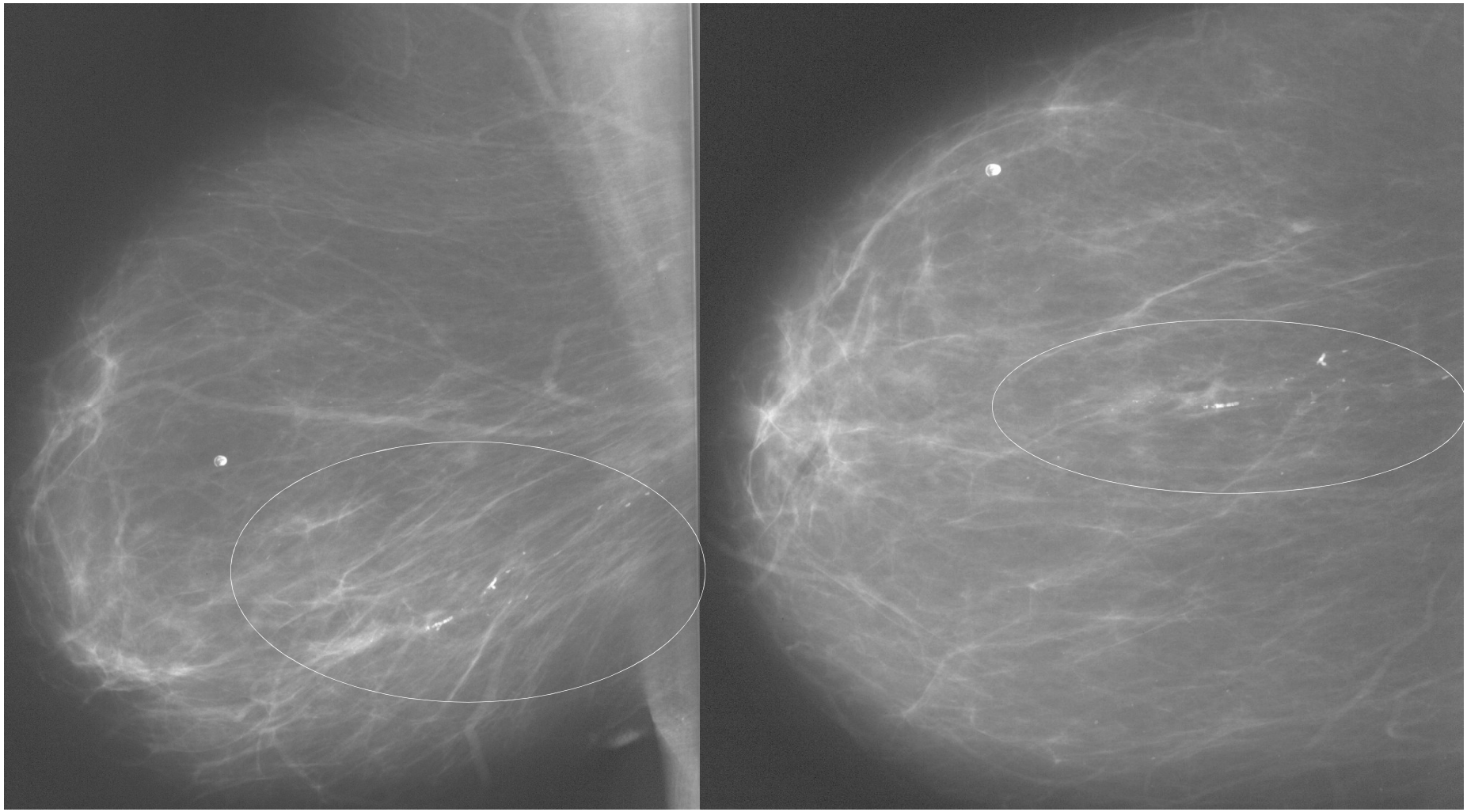

High-grade DCIS

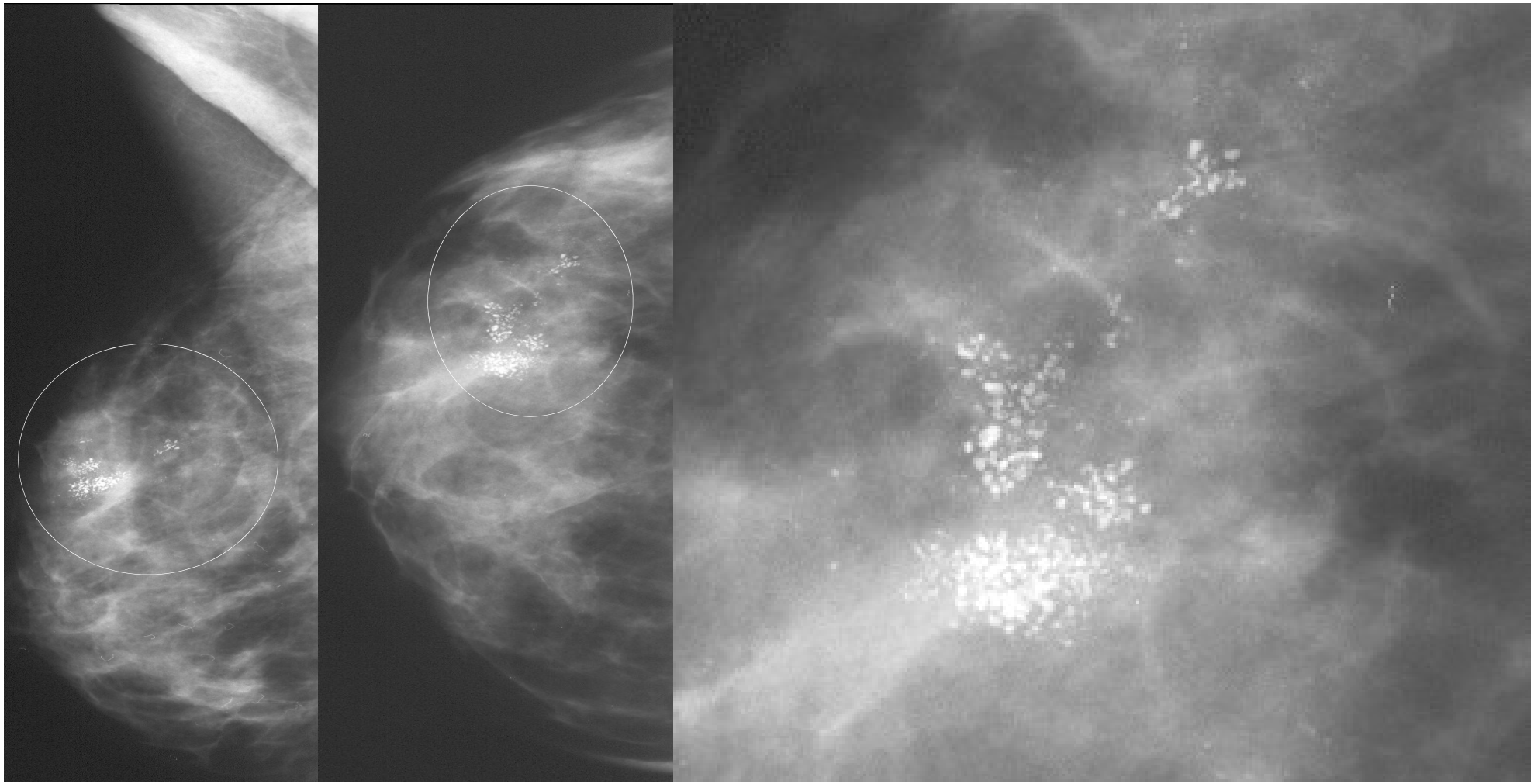

Benign proliferative changes

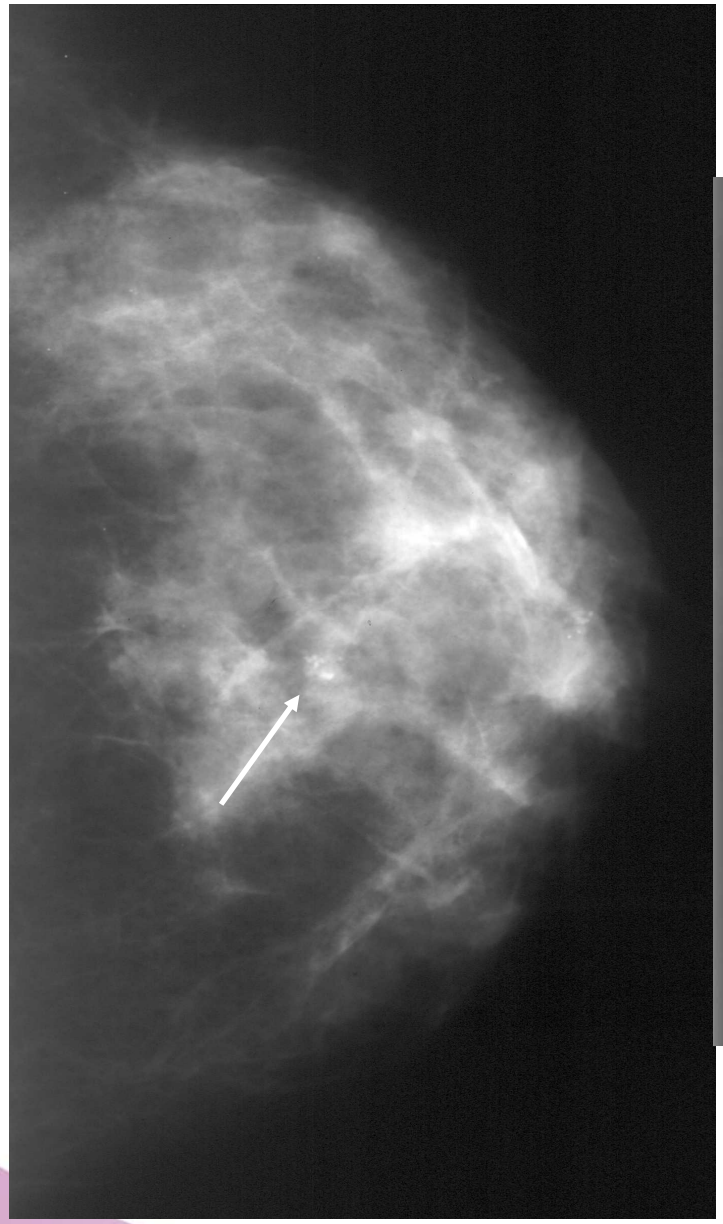

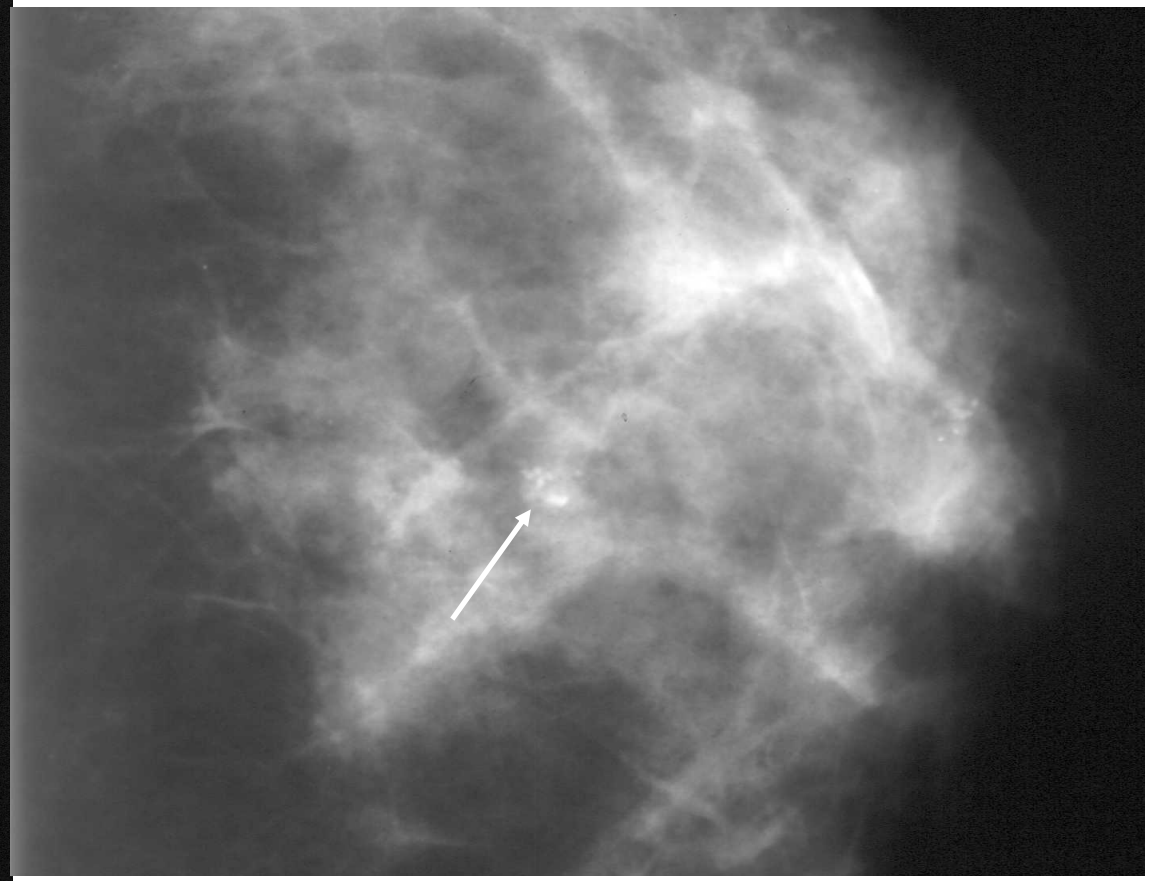

Outline

- Types of breast cancer
- Imaging methods and features
  - ➢Mammography
  - ~~➢Ultrasound~~
  - ➢CT
  - ➢MRI
- T stages
- Nodal drainage and N Stages
- Treated breast cancer

ESTRO School

Signs of breast cancer at ultrasound

- Mass
  - ➢Irregular
  - ➢Blurred borders
  - ➢2 Layers
    - Central echopoor zone: Fibrohyalinosis
    - Peripheral hyperechogenic rim: Proliferative zone
  - ➢Vertical orientation
- Acoustic shadow originating from the tumor center
- Increased blood flow at color Doppler
- Incompressibility / Low elasticity at elastography
- Worm-like echopoor extensions
  - ➞DCIS components
- Skin thickening

ESTRO School

Fibroadenoma

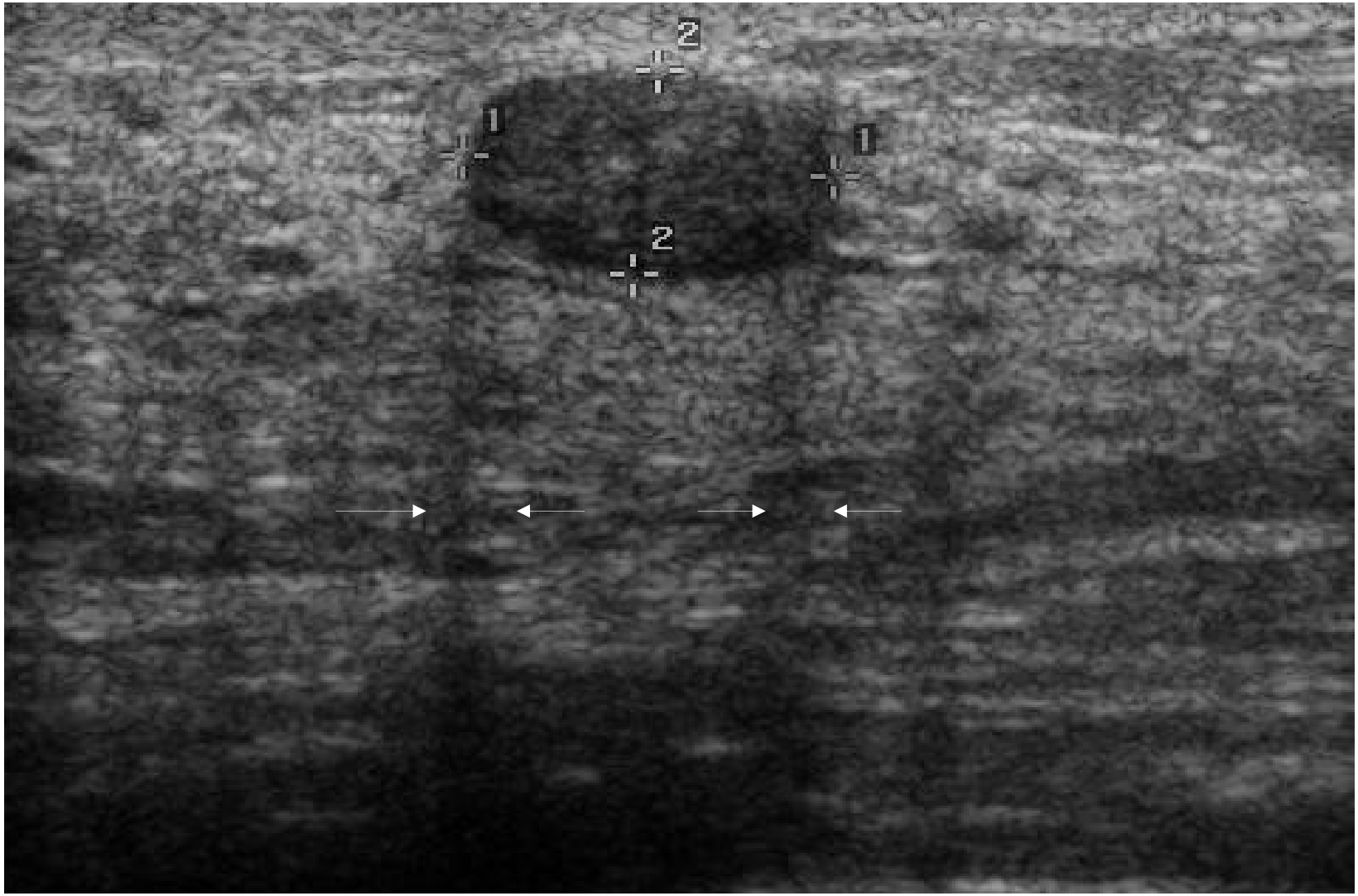

Fibroadenoma

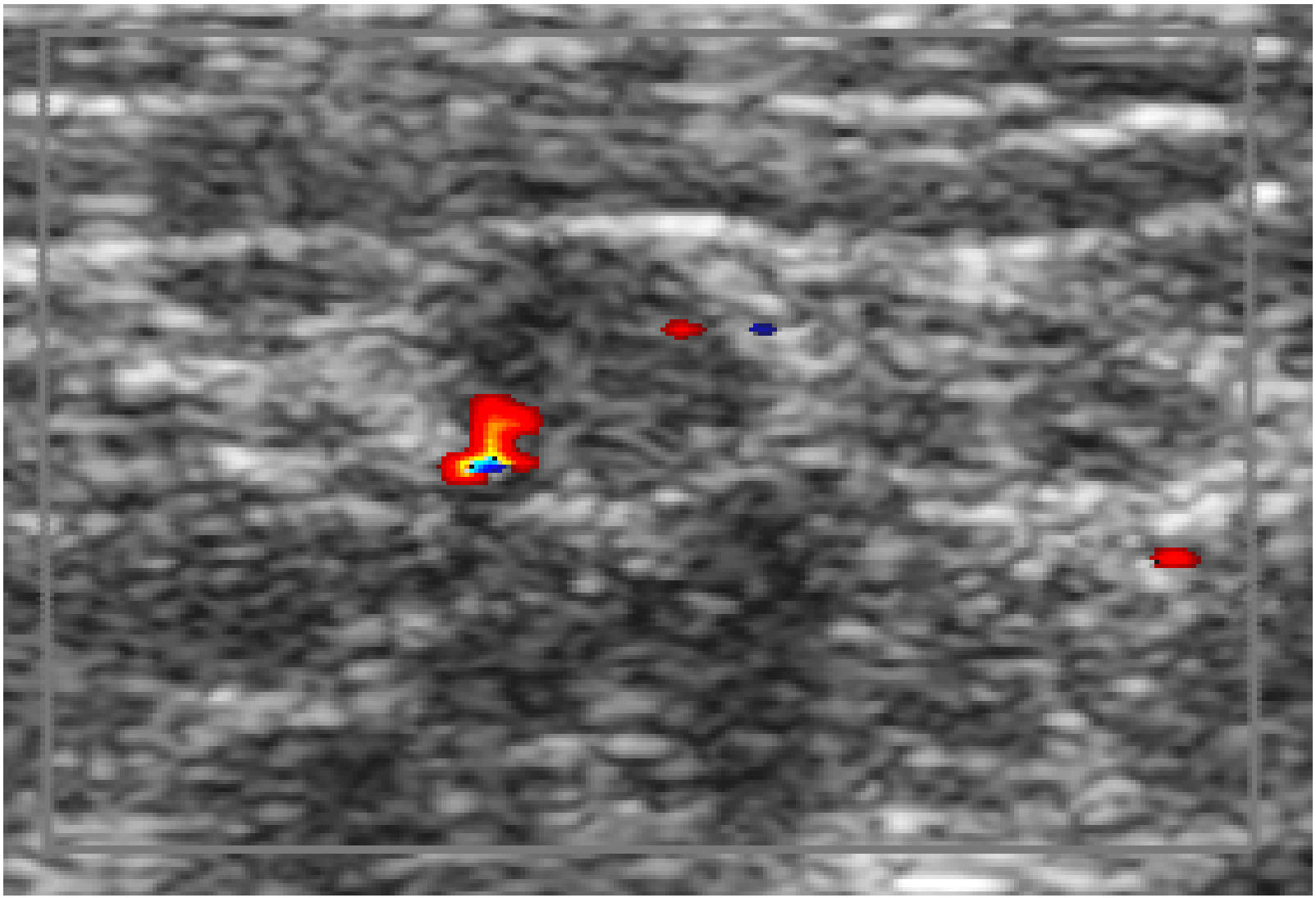

ESTRO School

Invasive breast carcinoma

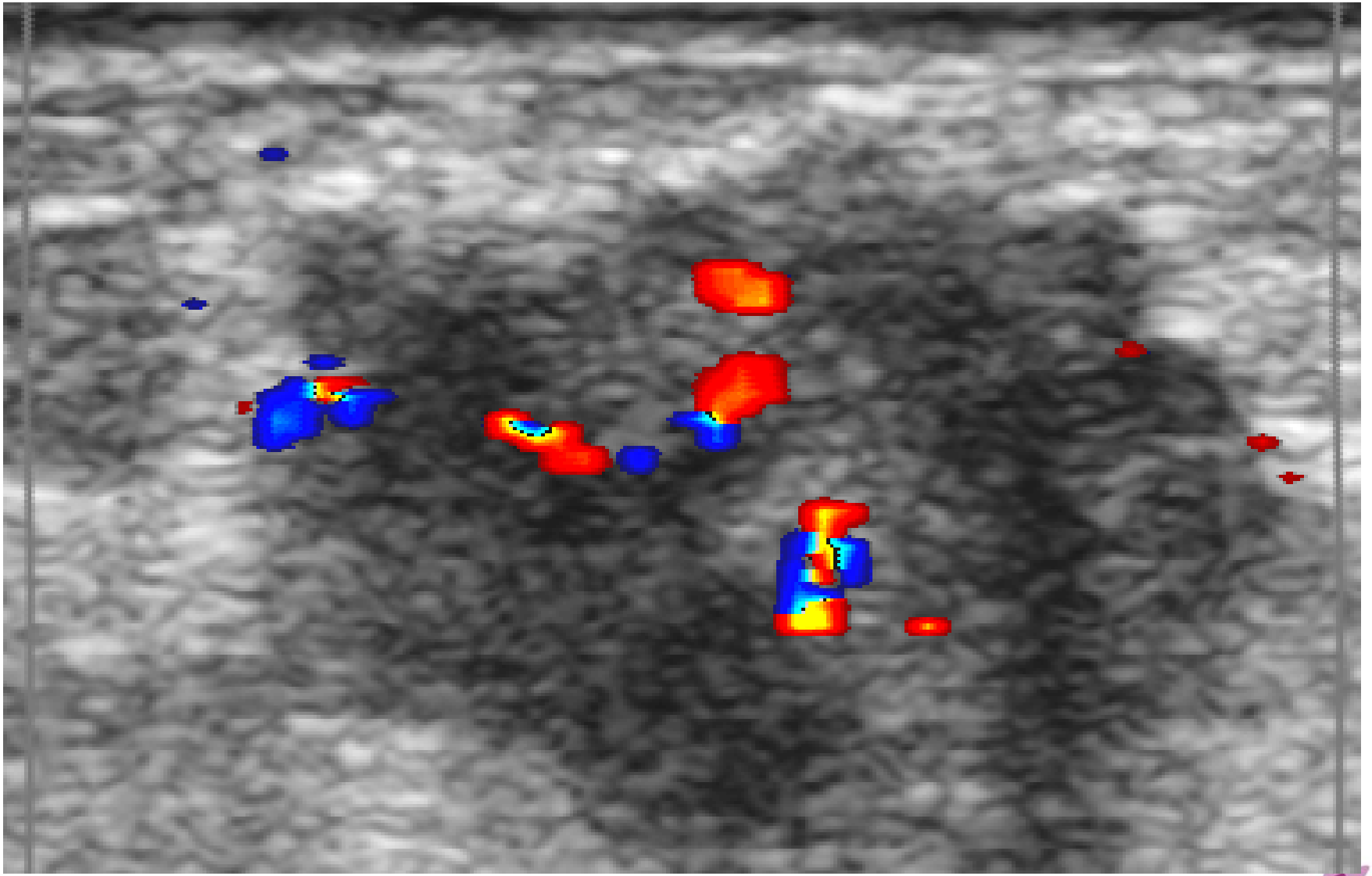

ESTRO School

Invasive breast cancer with DCIS

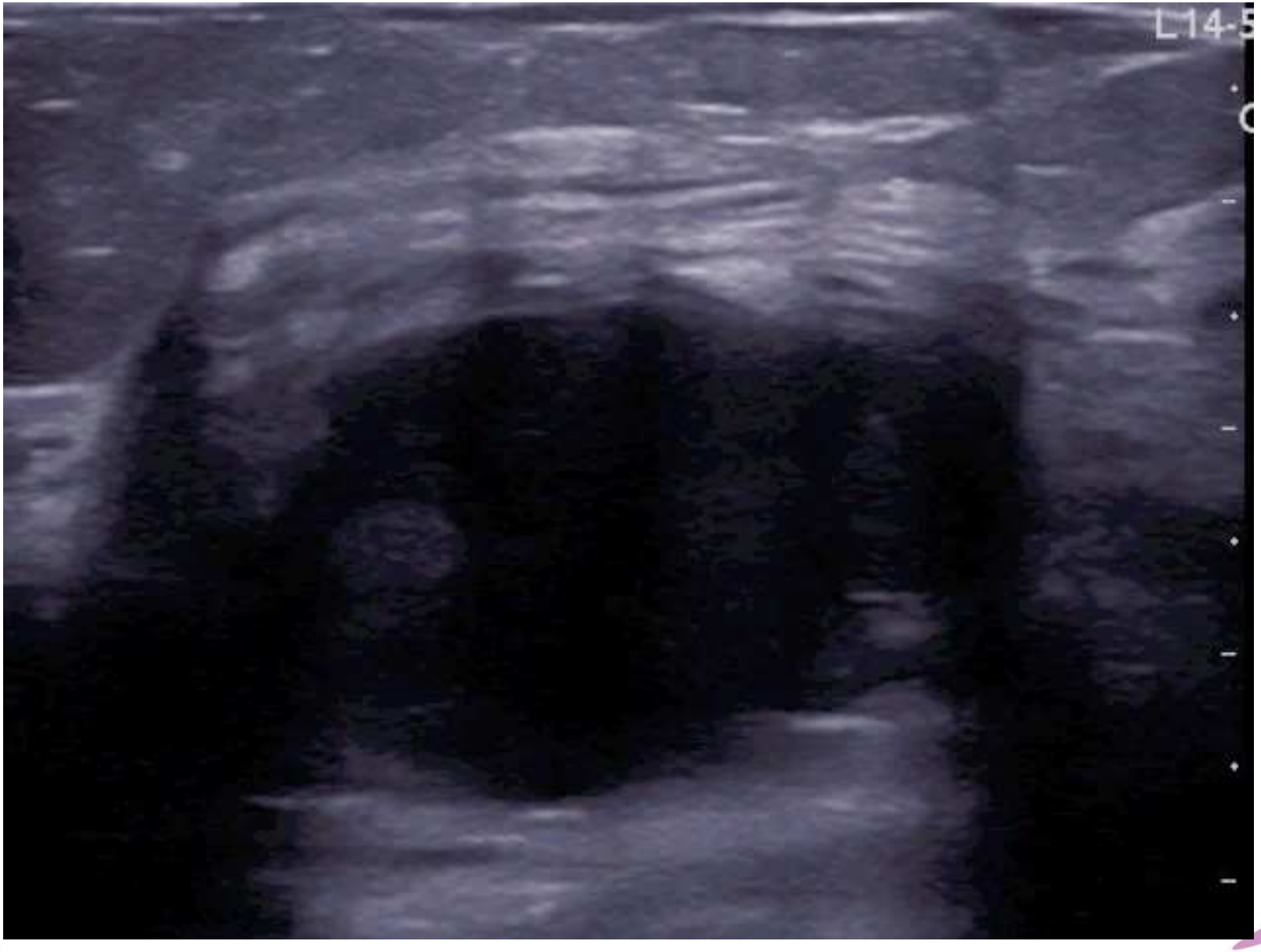

ESTRO School

Outline

- Types of breast cancer
- Imaging methods and features
  - ➢Mammography
  - ~~➢Ultrasound~~
  - ➢CT
  - ➢MRI
- T stages
- Nodal drainage and N Stages
- Treated breast cancer

ESTRO School

CT in breast cancer

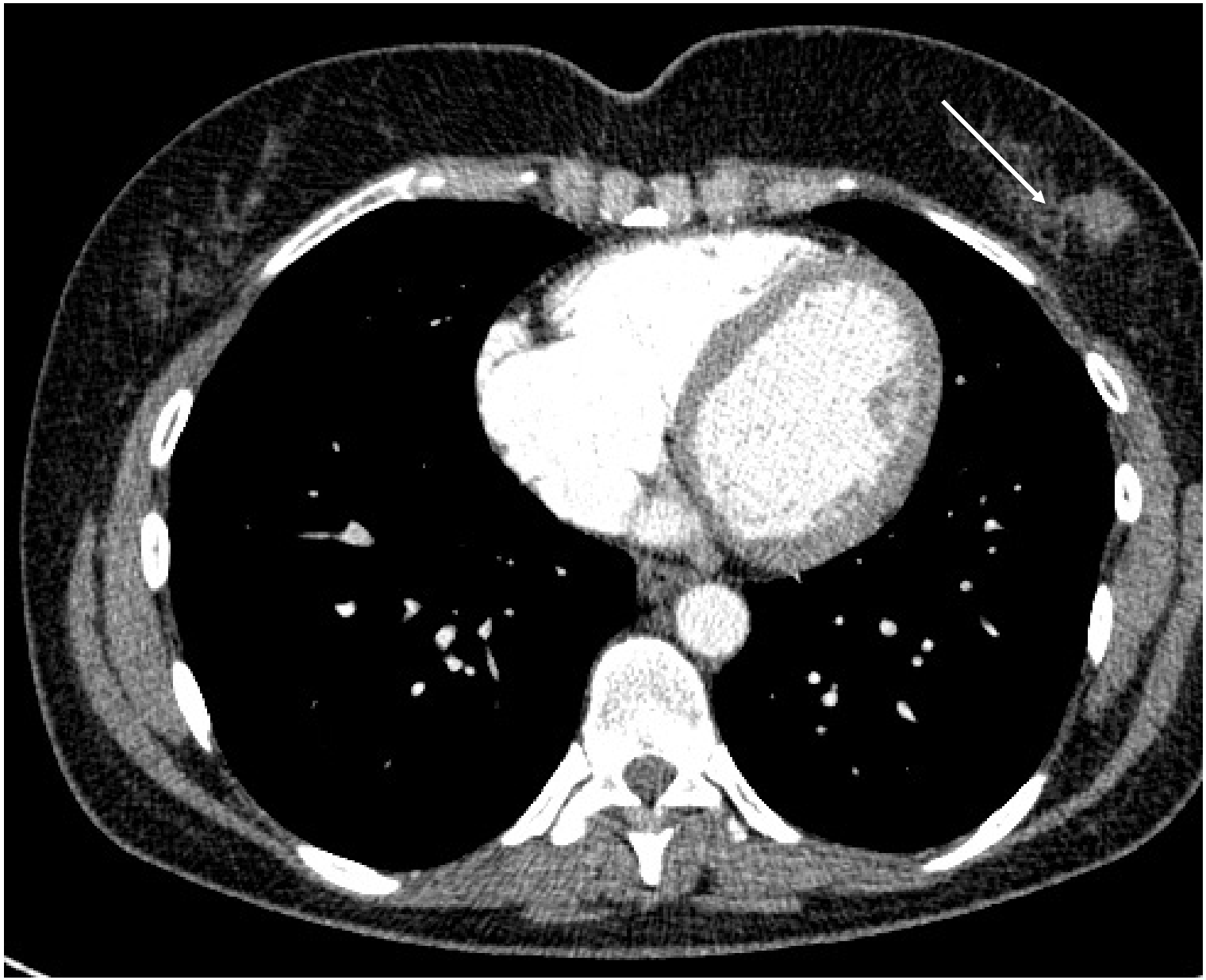

Outline

- Types of breast cancer
- Imaging methods and features
  - ➢Mammography
  - ➢Ultrasound
  - ➢CT
  - ➢MRI
- T stages
- Nodal drainage and N Stages
- Treated breast cancer

ESTRO School

Sequences

- Must:
  - ➢T2w
    - STIR (fat-suppressed T2)
    - T2 TSE
  - ➢T1 dynamic
    - 3D-FLASH (104 slices, 0.8x0.6x1.5 mm, 5x3 min)
    - 0.2 mmol/kg BW Gd-DTPA
    - 1 native and 5 post-contrast series over 3 minutes
    - Subtraction images (post contrast minus native)
- Optional:
  - ➢DWI
  - ➢Silicon-sensitive for Implants
  - ➢Fat-suppressed T1w

ESTRO School

Signs of breast cancer at MR mammography

- Focal contrast enhancement
- Early rise in intensity + plateau or washout
- Contrast enhancement from periphery to center or ring enhancement
- Segmental enhancement -> DCIS
- Irregular shape
- Jagged or unsharp border
- Architectural distortion
- Skin thickening

ESTRO School

Be aware of benign lesions

- Multiple small contrast enhancing spots (starry sky)
  - ➞Benign proliferative changes = normal
- Smooth, enhancing tumors
  - ➞Mostly fibroadenomas
- Bean-shaped, enhancing nodules
  - ➞Intramammary lymph nodes
- Cysts with enhancing wall
  - ➞Inflammatory reaction
- Complex lesions with contrast enhancement post-op
  - ➞Fat necrosis
  - ➞Look for fat or blood degradation products

ESTRO School

Weightings

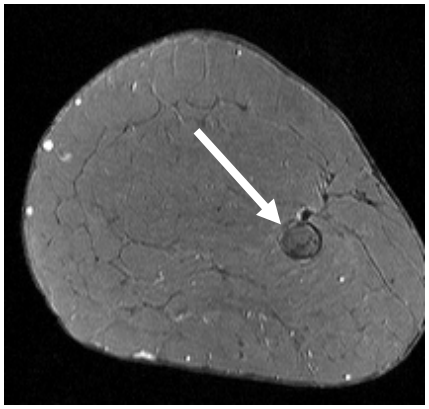

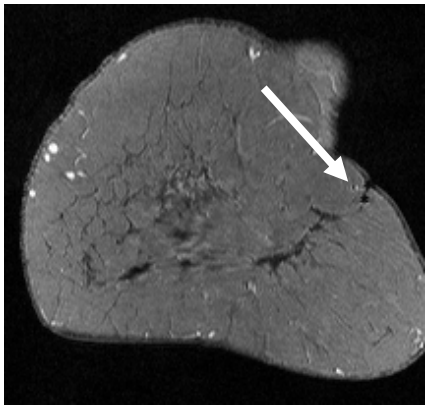

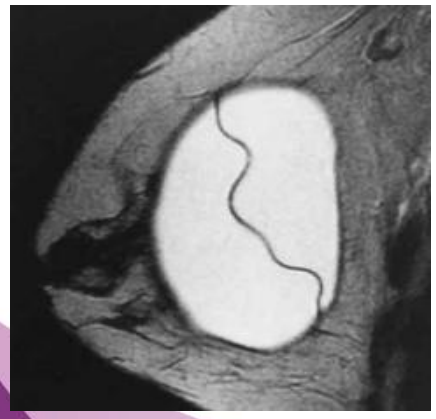

- T1
  - ➢ Sensitive for susceptibility (blood, electro-coagulators, clips, large calcifications)
  - ➢ For post contrast imaging
- T2
  - ➢ Cysts
  - ➢ Edema
  - ➢ Lymph nodes
  - ➢ Fatty secretion
  - ➢ Implants

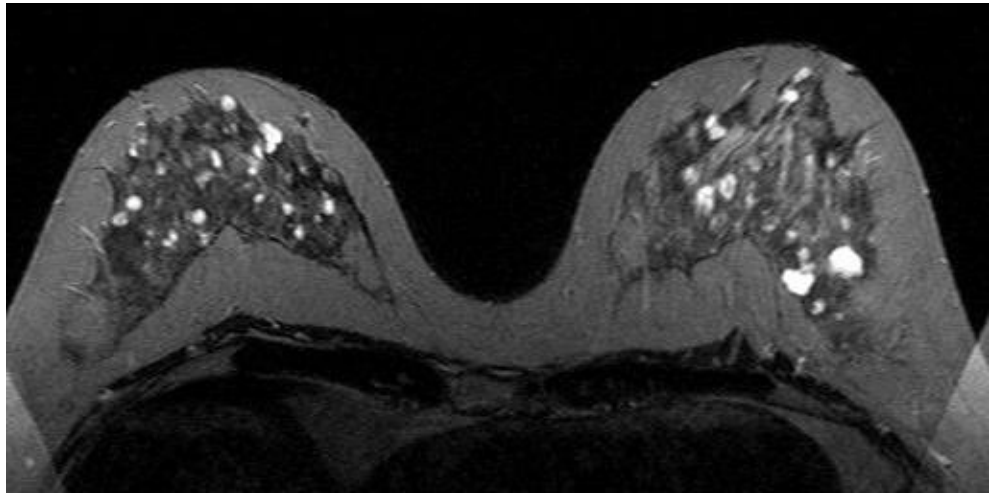

ESTRO School

High versus Low Resolution

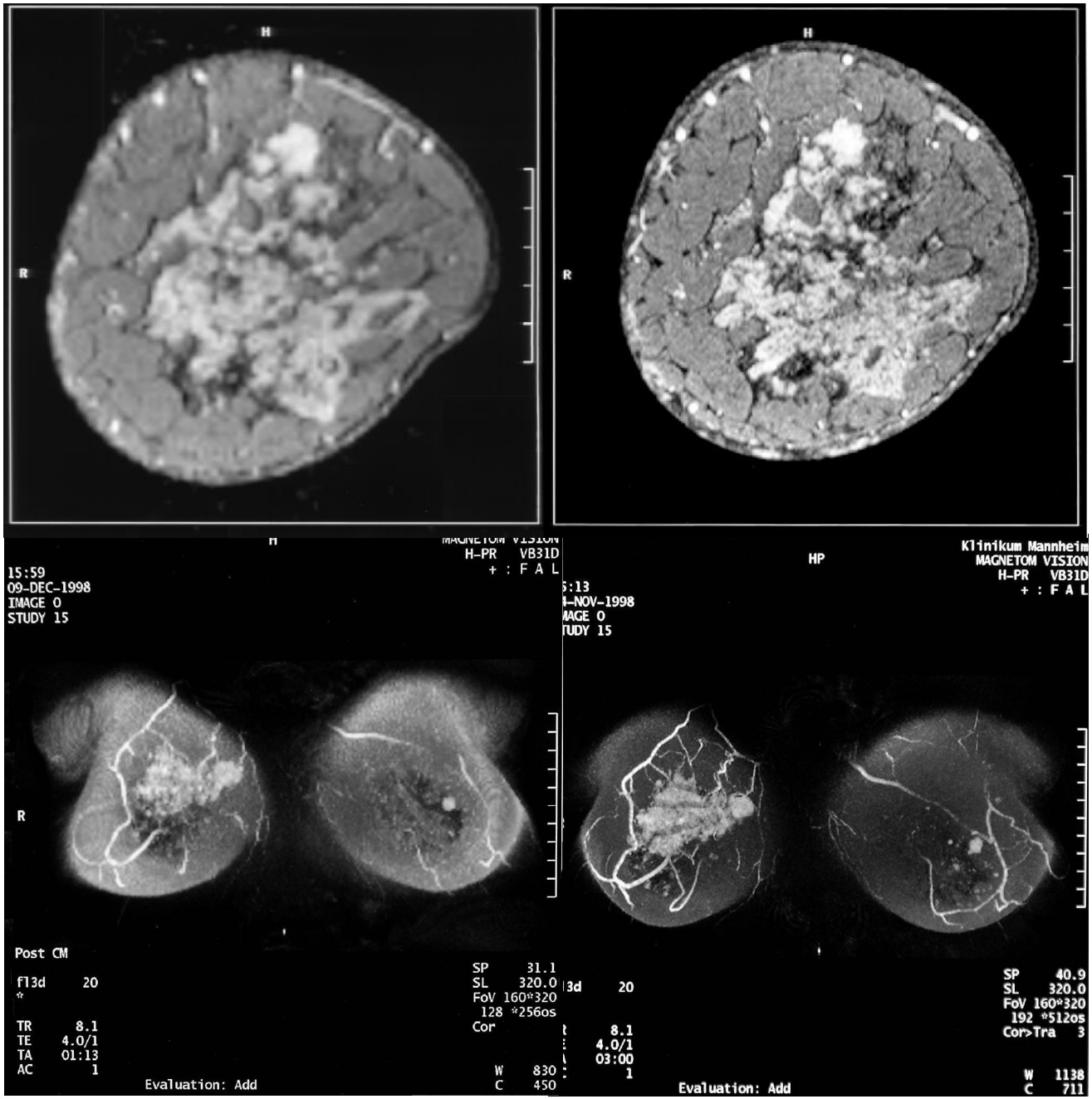

ESTRO School

Dynamic or static

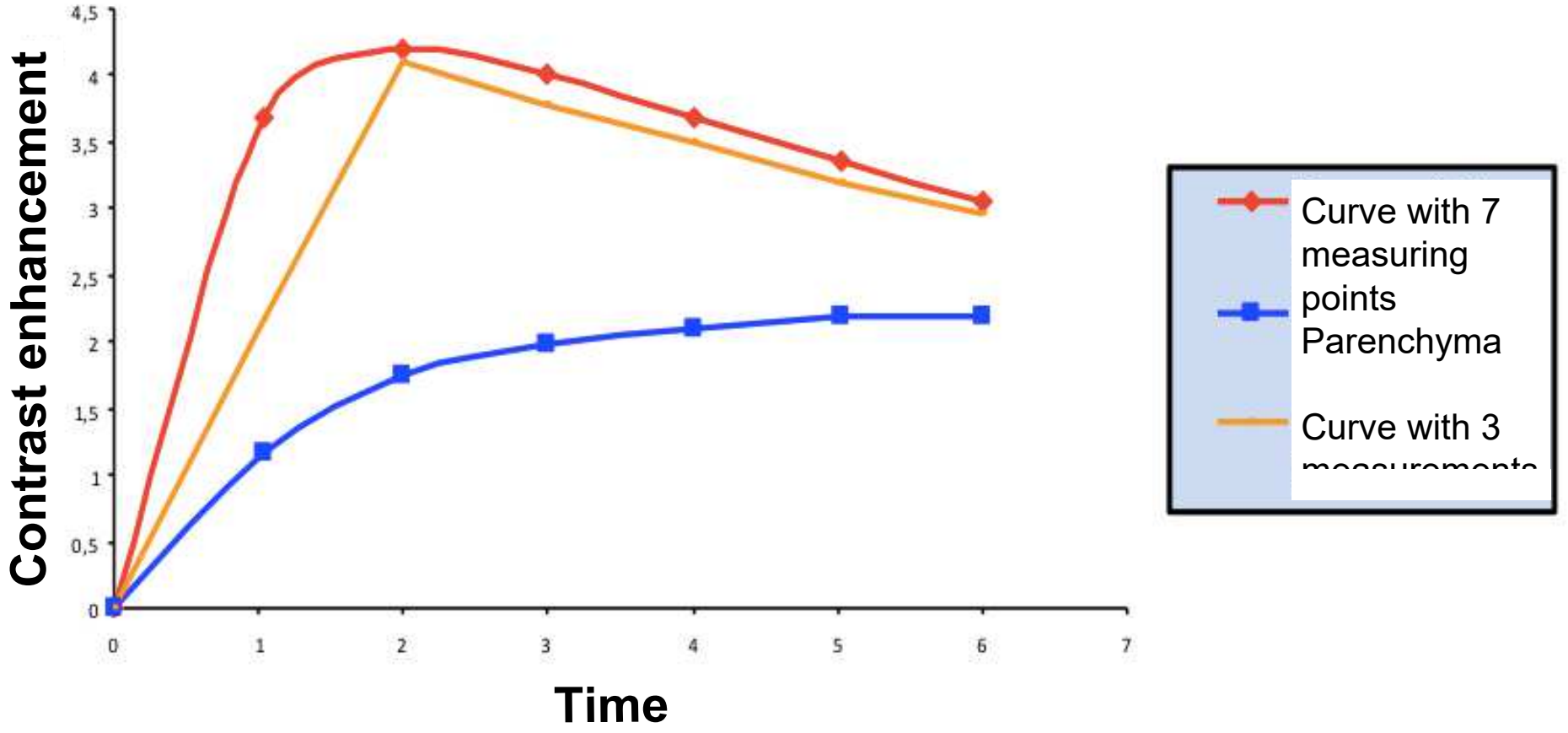

In Anlehnung an Heywang-Köbrunner, IIBM Studie, Eur Radiol 2001

ESTRO School

Subtraction

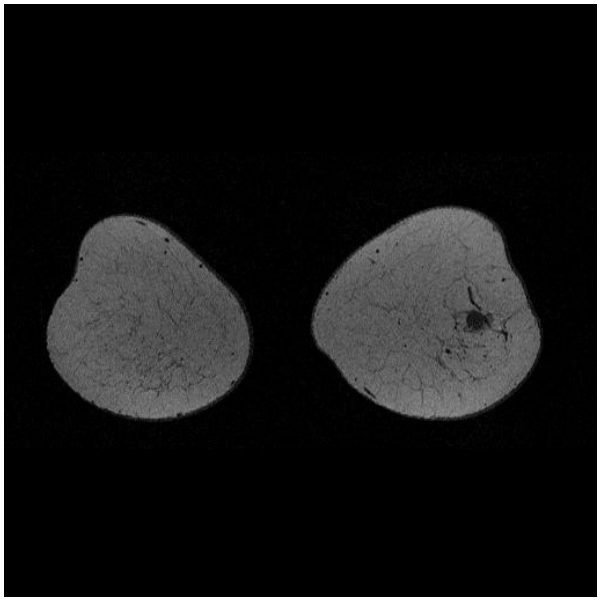

Plain

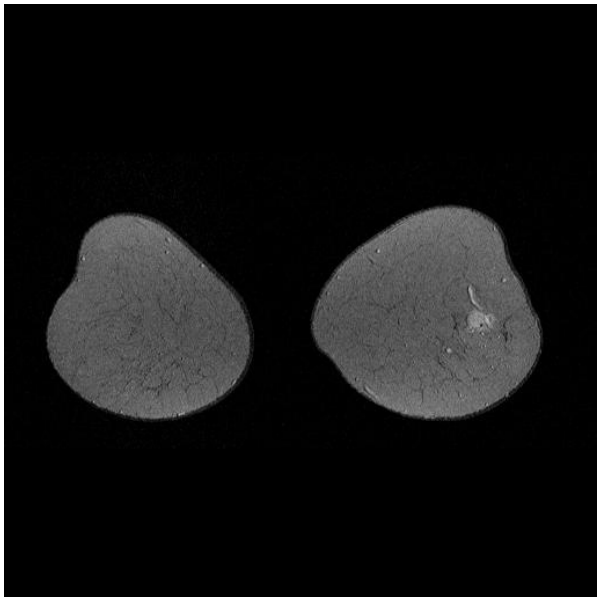

Enhanced

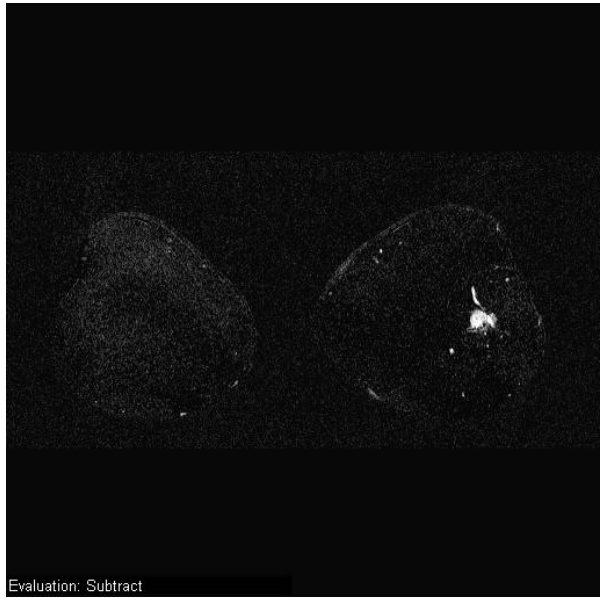

Subtraction

Dynamic enhancement evaluation

- Initial signal rise
  - ➢< 50%
  - ➢50% - 100%
  - ➢> 100%
- Signal evolution over time
  - ➢Continuous increase
  - ➢Plateau
  - ➢Wash-out
- Enhancement pattern
  - ➢Homogeneous
  - ➢Inside -> outside
    - Fibroadenomas, lymph nodes
  - ➢Outside -> inside
    - Carcinomas



Morphology

- Diameter
- Shape
  - ➢Round, oval, polygonal, linear, tubular
  - ➢Dendritic, spiculated, multiple longitudinal (Comedo-like)
- Delineation
  - ➢Smooth
  - ➢Unsharp
- Enhancement pattern
  - ➢Homogeneous, septations
  - ➢Inhomogeneous
  - ➢Ring enhancement
    - Thin, sharp -> Often with cysts or fatty necrosis
    - Thick, unsharp -> Suspicious

ESTRO School

Multicentric breast carcinoma

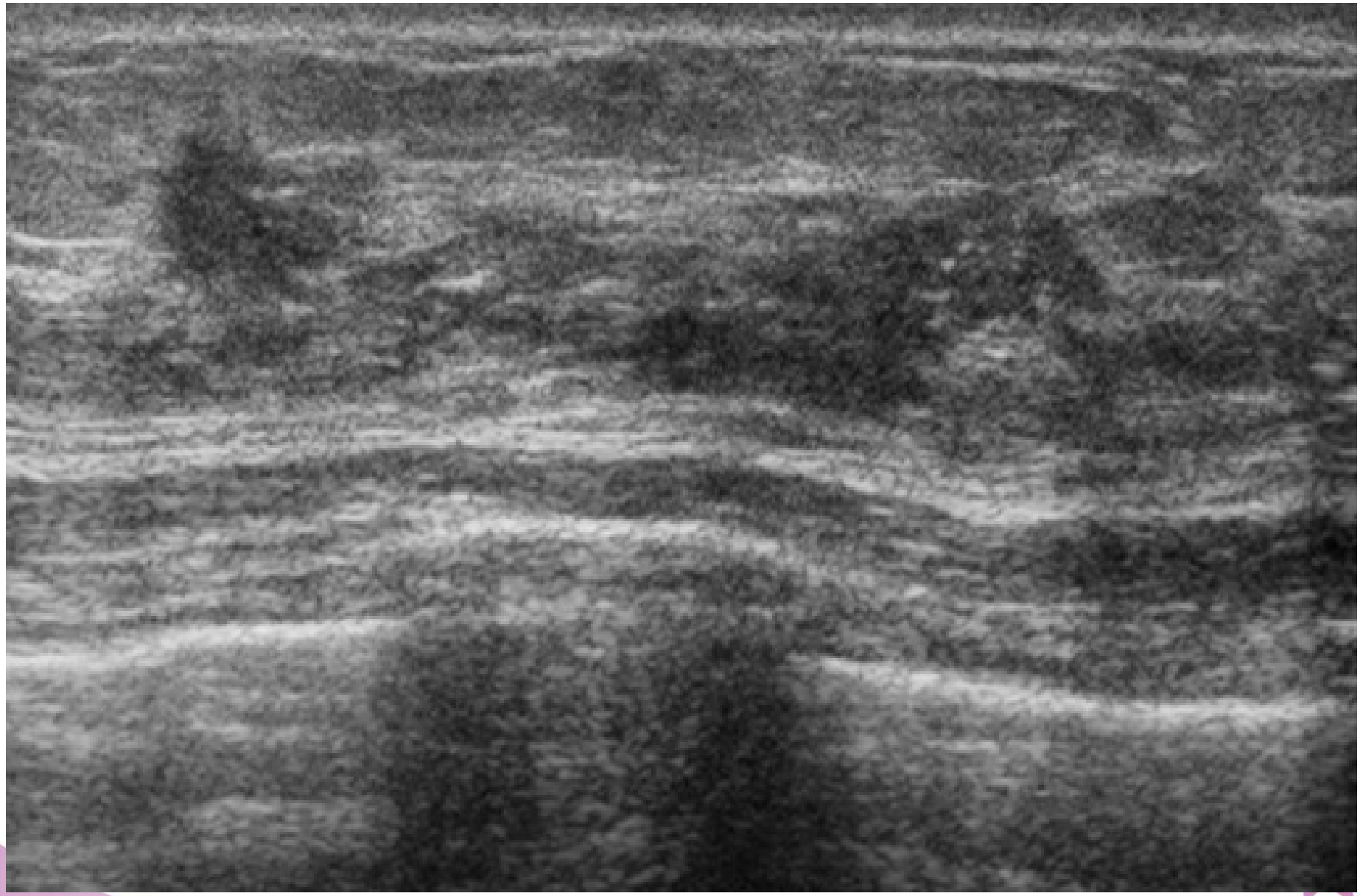

ESTRO School

Multicentric breast carcinoma

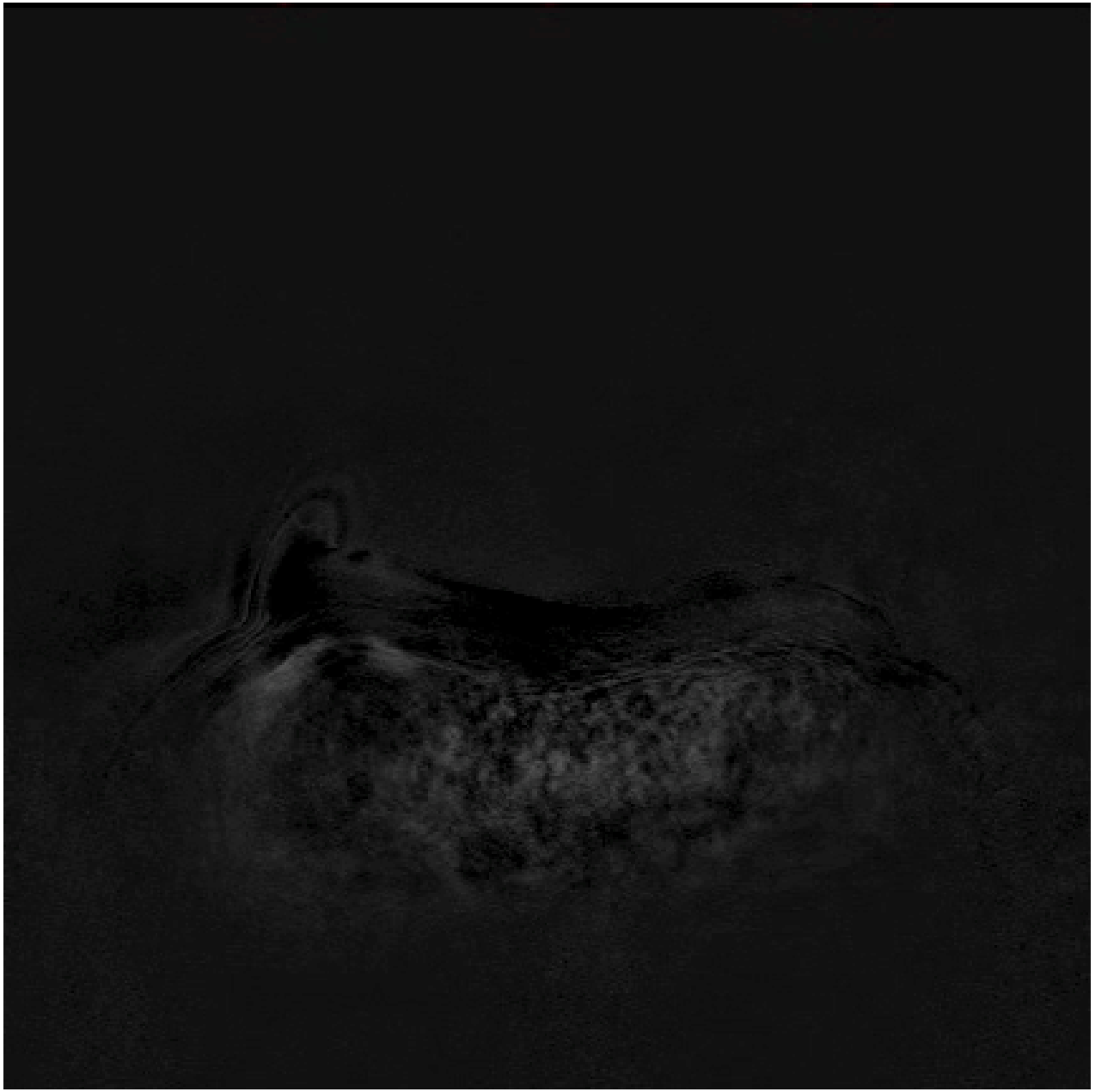

Multicentric breast carcinoma

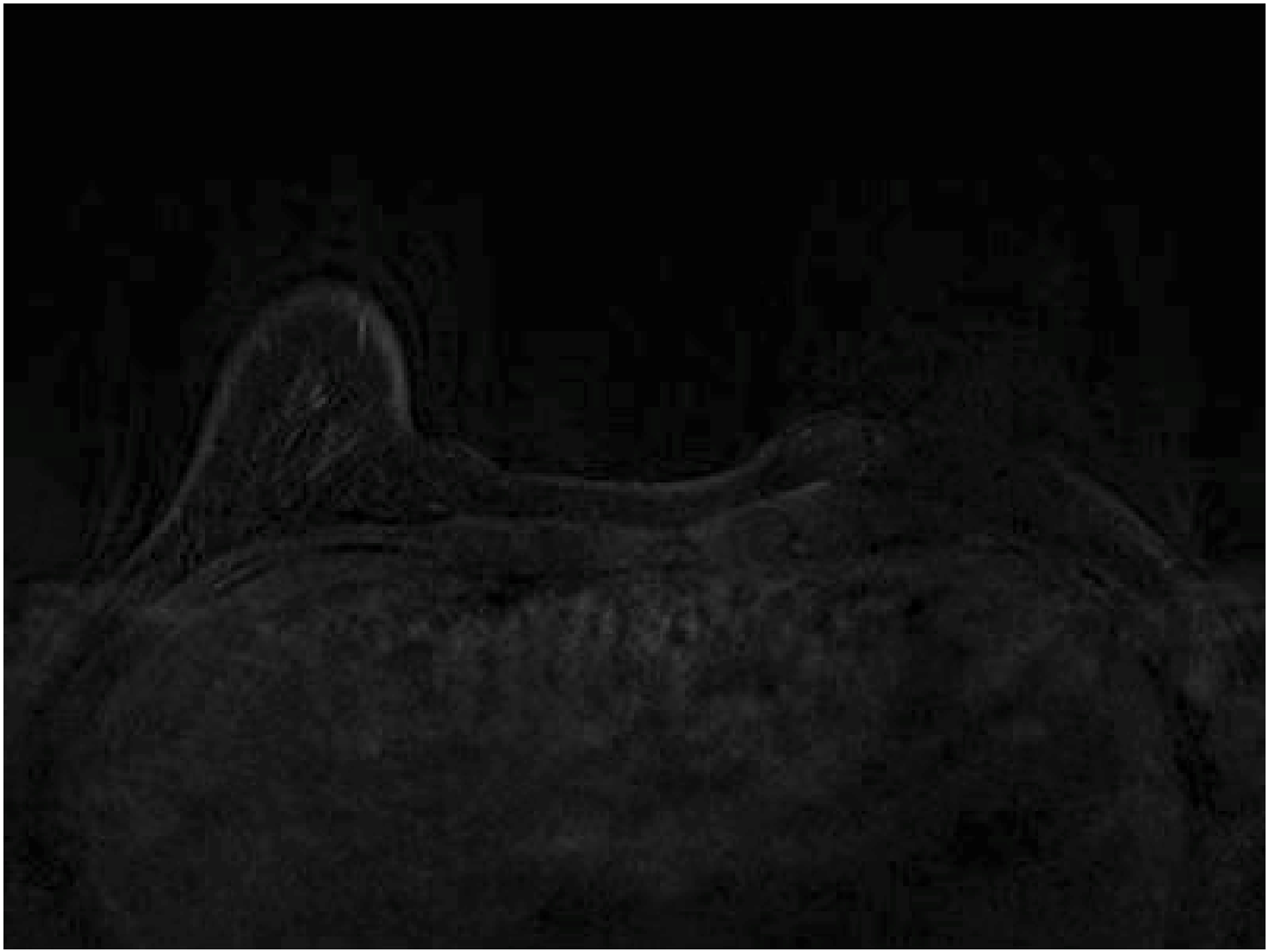

Multifocal breast carcinoma: DWI



Punch biopsy equipment

ESTRO School

Ultrasound verification of successful biopsy

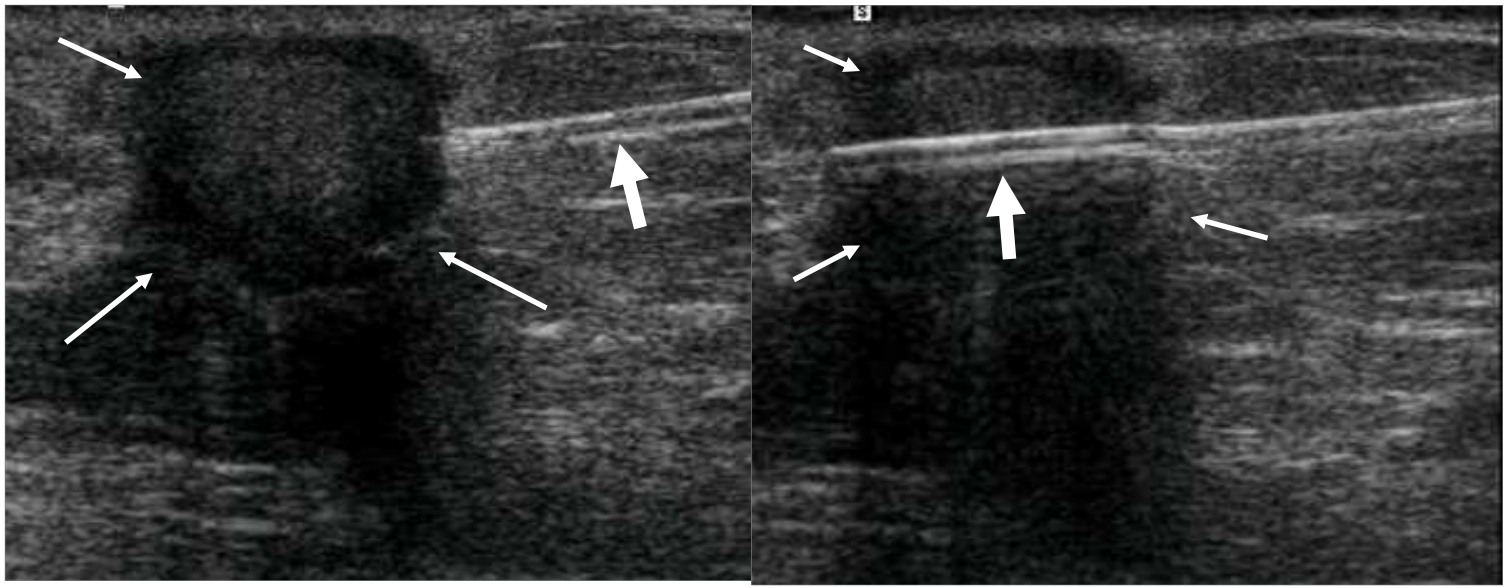

Vacuum aspiration biopsy equipment

Biopsy

Biopsy yield

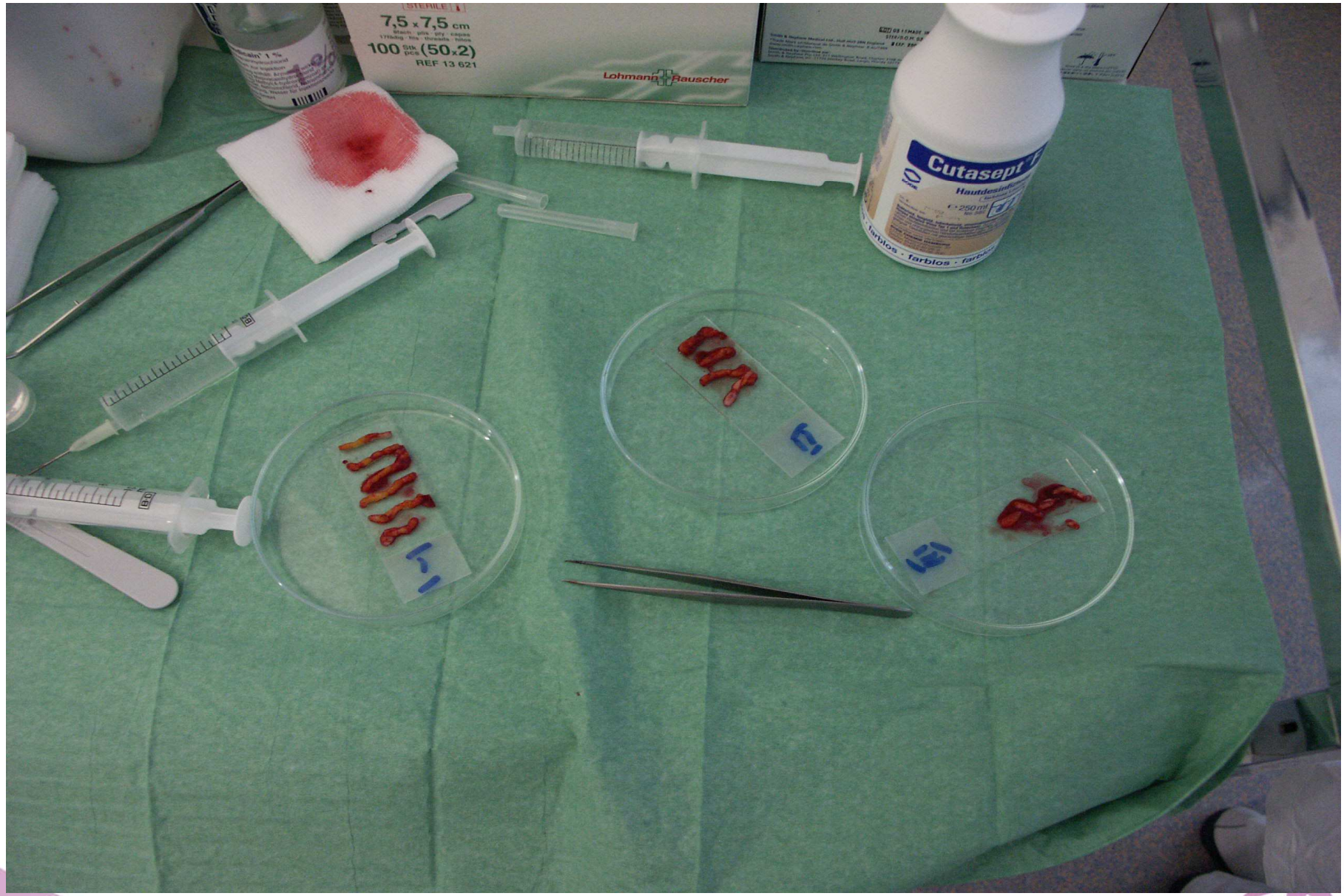

Excision biopsy

Resected specimen

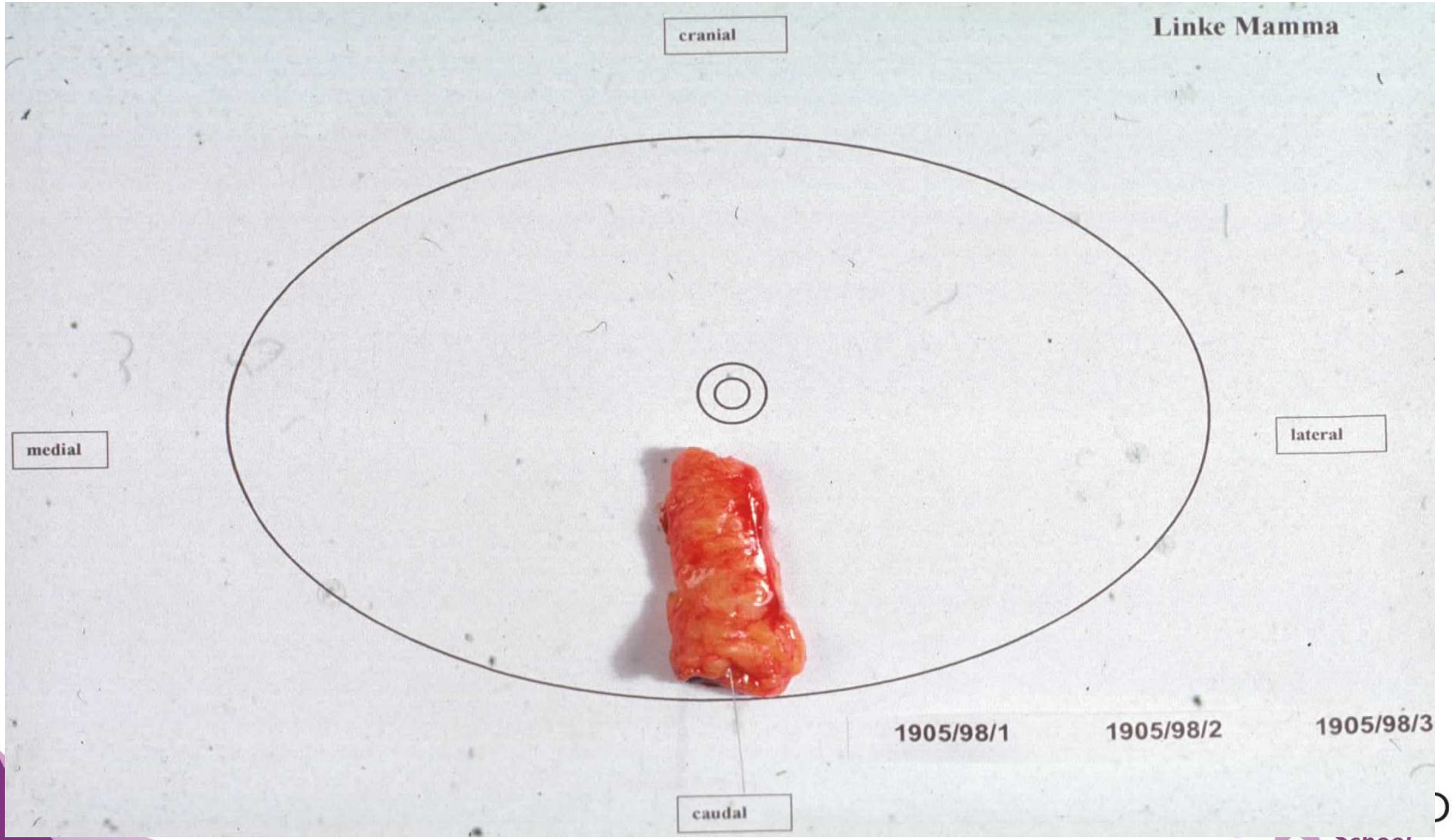

Outline

- Types of breast cancer
- Imaging methods and features
  - ➢Mammography
  - ➢Ultrasound
  - ➢CT
  - ➢MRI
- ~~T stages~~
- Nodal drainage and N Stages
- Treated breast cancer

ESTRO School

Breast cancer T stages

Stage	Criterion
T0	No evidence of PT
Tis - DCIS - LCIS - Paget	In situ carcinoma - Ductal Ca in situ - Lobular Ca in situ - Paget of the nipple, no invasive foci
T1 - T1a - T1b - T1c	Tumor 2 cm or less in diameter - max. 5 mm in diameter - > 5 mm but max. 10 mm in diameter - > 10 mm but max. 20 mm in diameter
T2	> 2 cm but max. 5 cm in diameter
T3	> 5 cm in diameter
T4	Any size with direct invasion of chest wall or skin, including inflammatory carcinoma

ESTRO School

Breast cancer T4

ESTRO School

Outline

- Types of breast cancer
- Imaging methods and features
  - ➢Mammography
  - ➢Ultrasound
  - ➢CT
  - ➢MRI
- T stages
- Nodal drainage ~~and N Stages~~
- Treated breast cancer

ESTRO School

Breast cancer: Lymphatic drainage

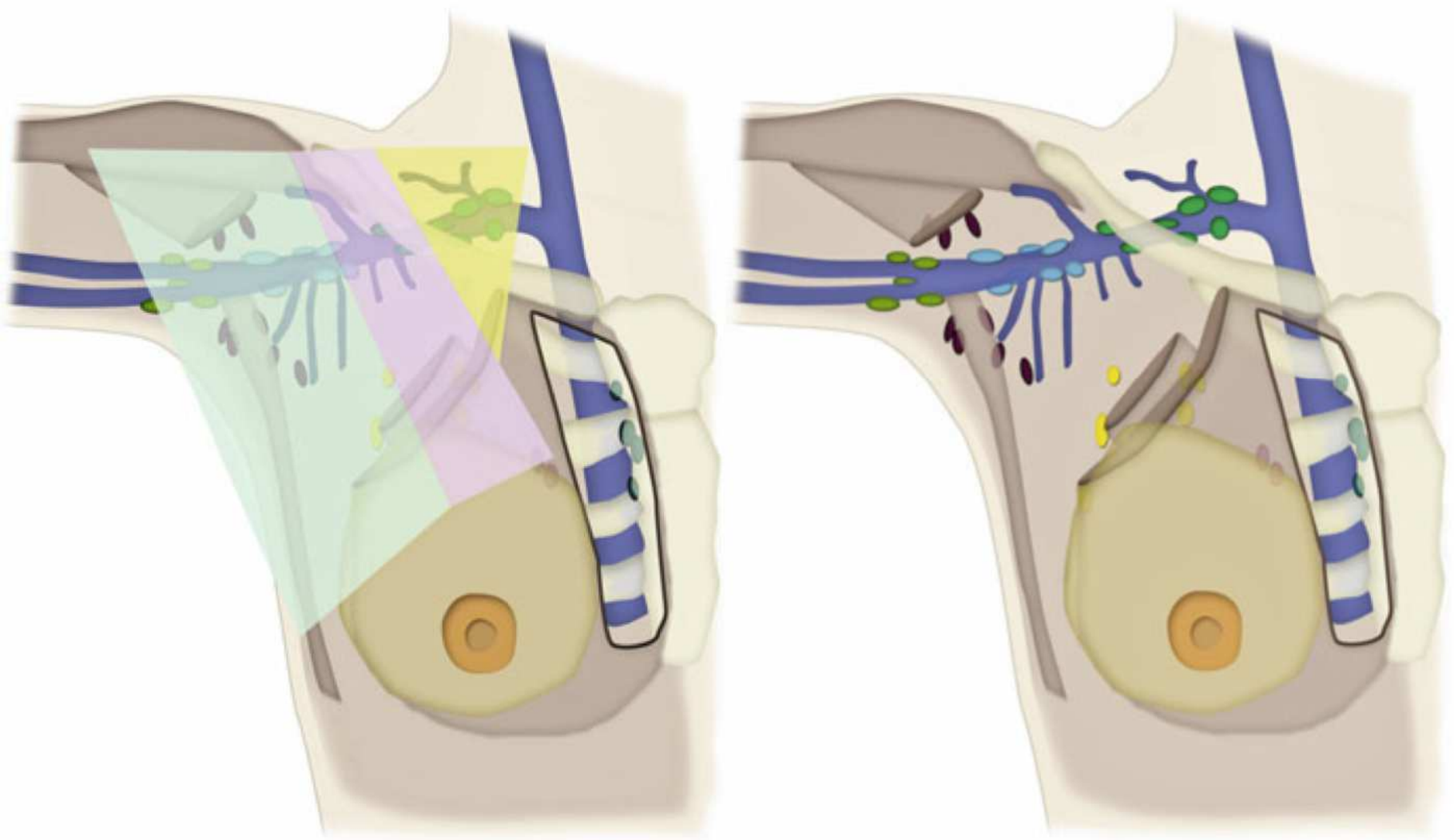

ESTRO School

Breast cancer N stages

Stage	*Criterion*
N0	*No regional lymph node metastases*
N1	*Metastases in movable ipsilateral Level I or II lymph nodes*
N2a *N2b*	- *Clinically fixed ipsilateral Level I or II LN* - *Clinical (incl. imaging) evidence of internal mammary LN in absence of clinically detected axillary lymph nodes*
N3a *N3b* *N3c*	- *Metastases in infraclavicular LN* - *Metastases in internal mammary AND axillary lymph nodes* - *Metastases in supraclavicular LN*

ESTRO School

Axillary lymph nodes Level I

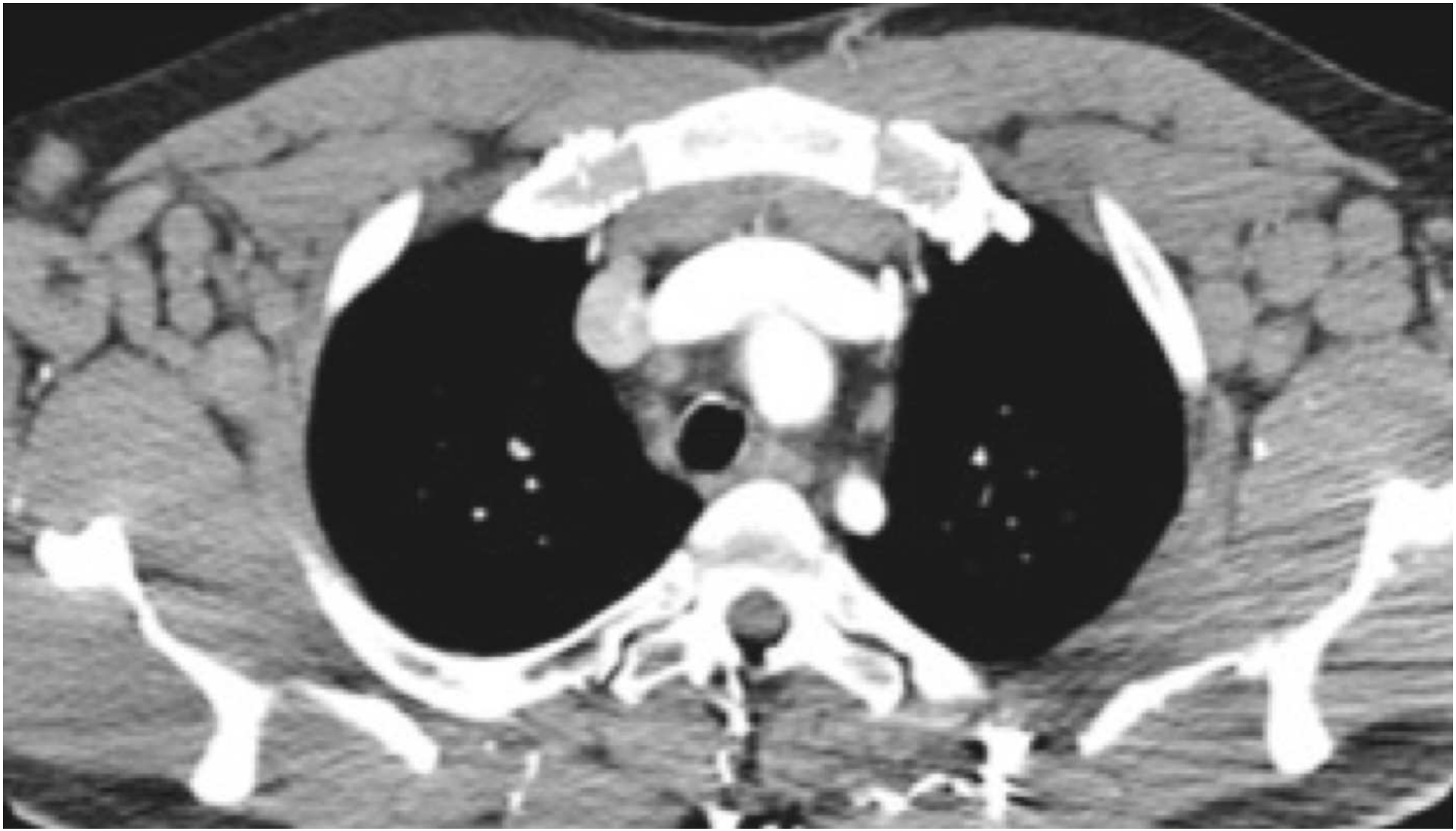

Internal mammary chain

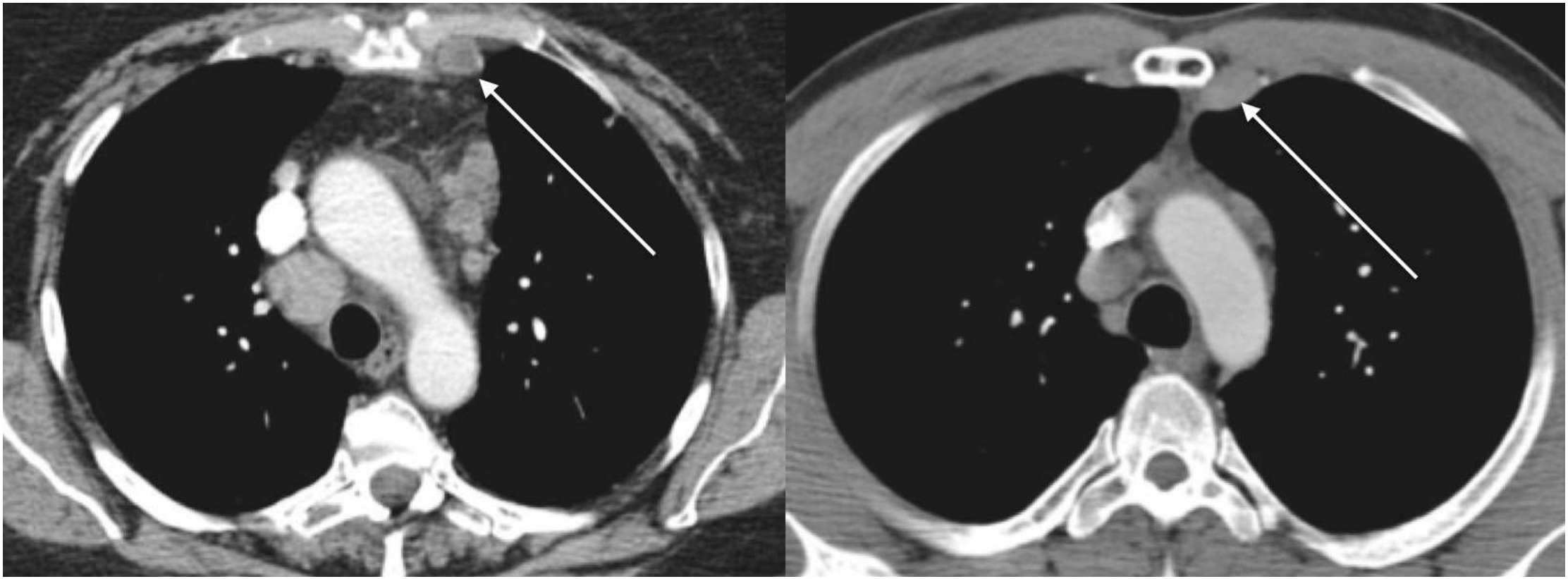

Axillary lymph node metastasis

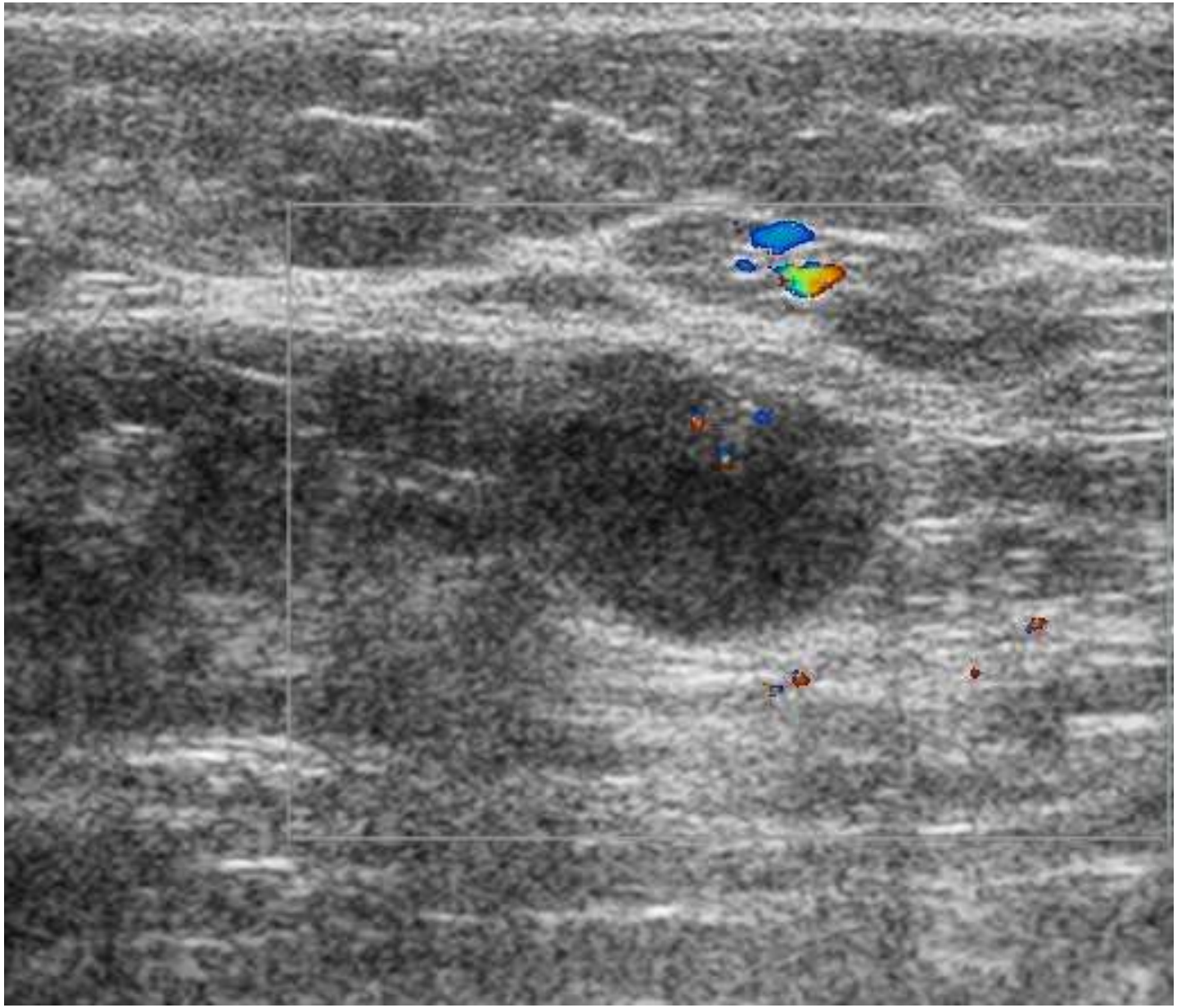

Outline

- Types of breast cancer
- Imaging methods and features
  - ➢Mammography
  - ➢Ultrasound
  - ➢CT
  - ➢MRI
- T stages
- Nodal drainage and N Stages
- Treated breast cancer

ESTRO School

Response: Tumor cells

- Apoptosis
  - Early (hours to days)
  - Single-cell pattern
  - No inflammatory reaction
  - Phagocytosis by neighbor cells
- Necrosis
  - Delayed (next mitosis, possibly after several cycles)
  - Grouped cell pattern
  - Inflammation
  - Phagocytosis by macrophages

ESTRO School

Response: Tumor stroma

- Regression of cellular components
  - Lack of stimulation by tumor cells
  - Very delayed
- Often persistence of fibrous components
- Regression of vasculature
  - Lack of angiogenic stimulation
  - Direct antivascular effects
    - » Radiation
    - » Anti-angiogenic treatment etc.
    - » Chemotherapy

ESTRO School

Optimal treatment result

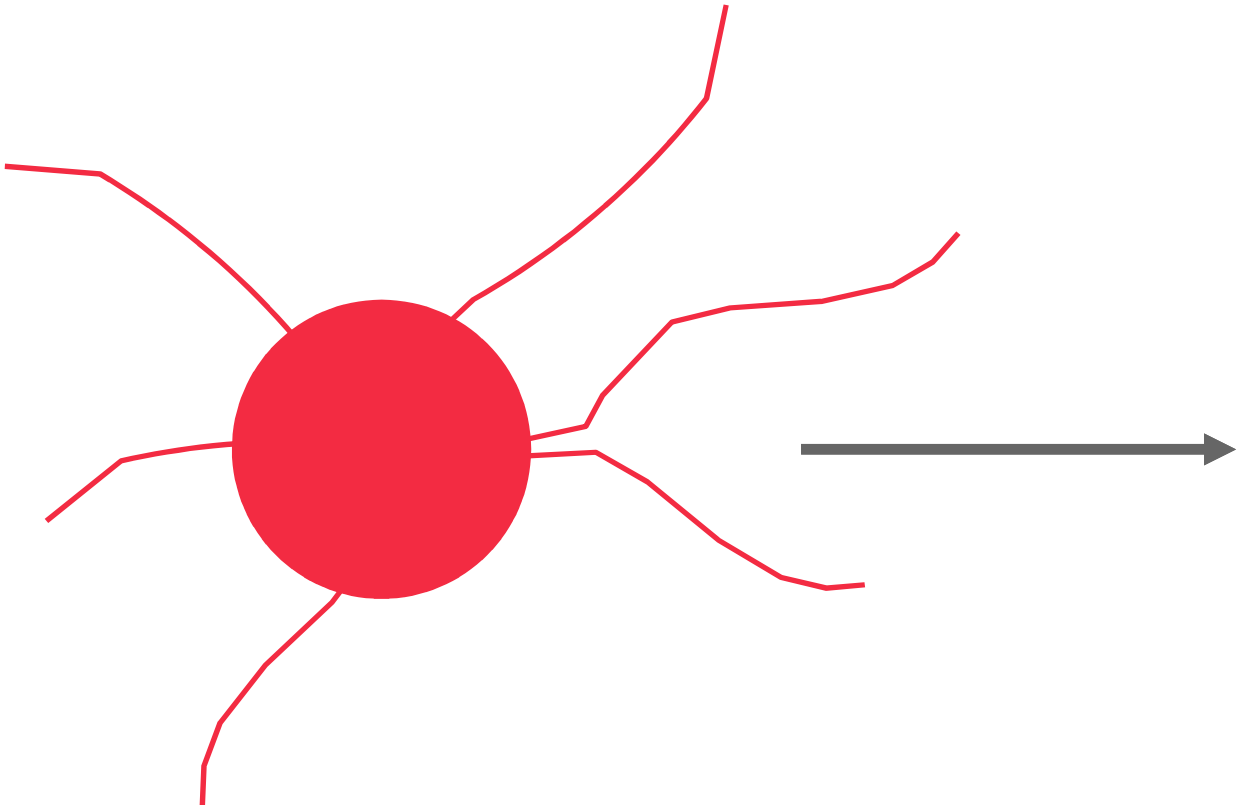

Possible response patterns

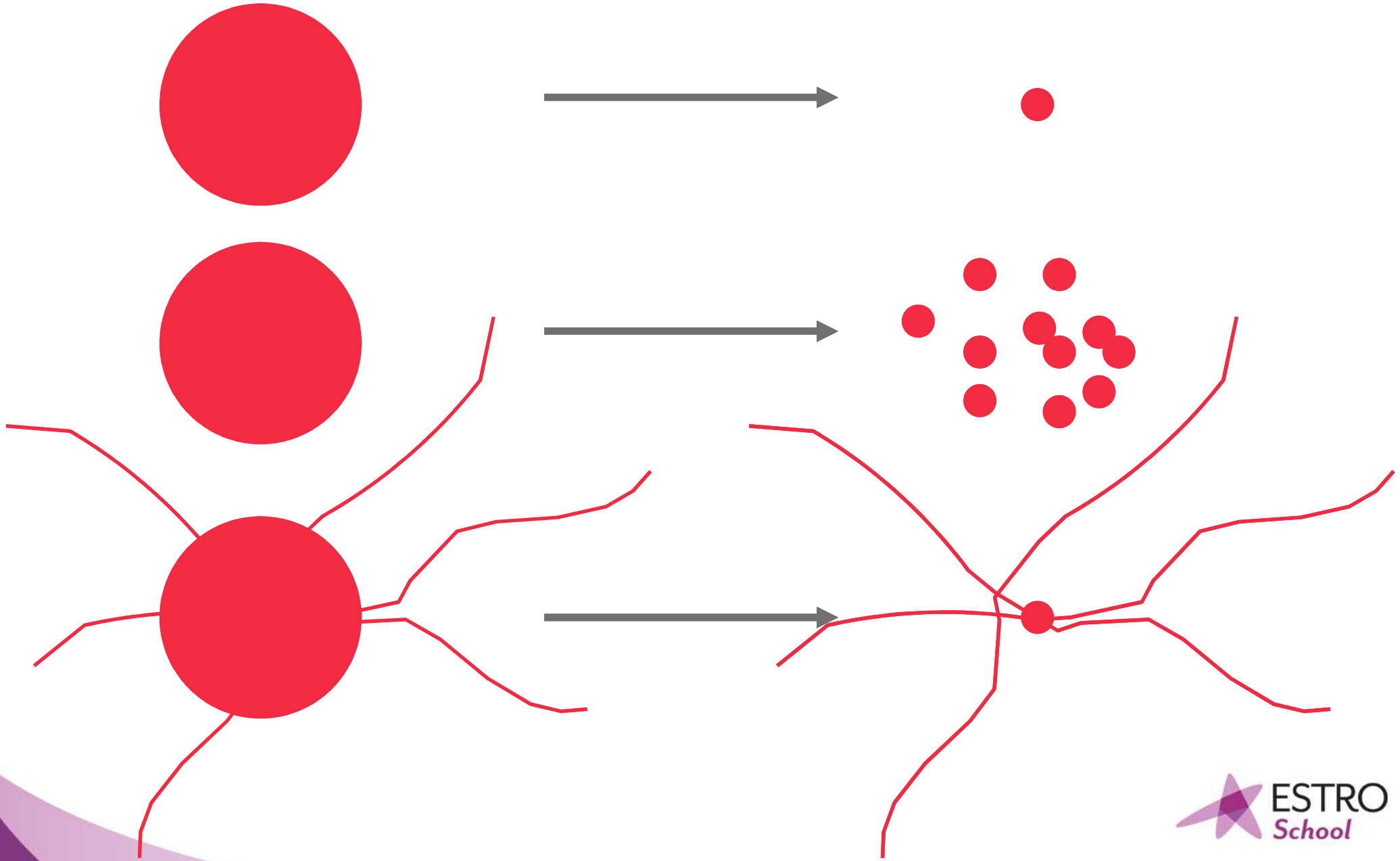

US: Partial response

Mammography: Partial response

Comparison of methods

	Correlation with pathology	
Mammography	***r=0.628***	***p<0.001***
Ultrasound	***r=0.541***	***p<0.001***
Physical examination	***r=0.597***	***p<0.001***

Loehberg CR et al., Anticancer res 25:2519-26(2005)

ESTRO School

REALITY

ESTRO School

Measuring tumor size?

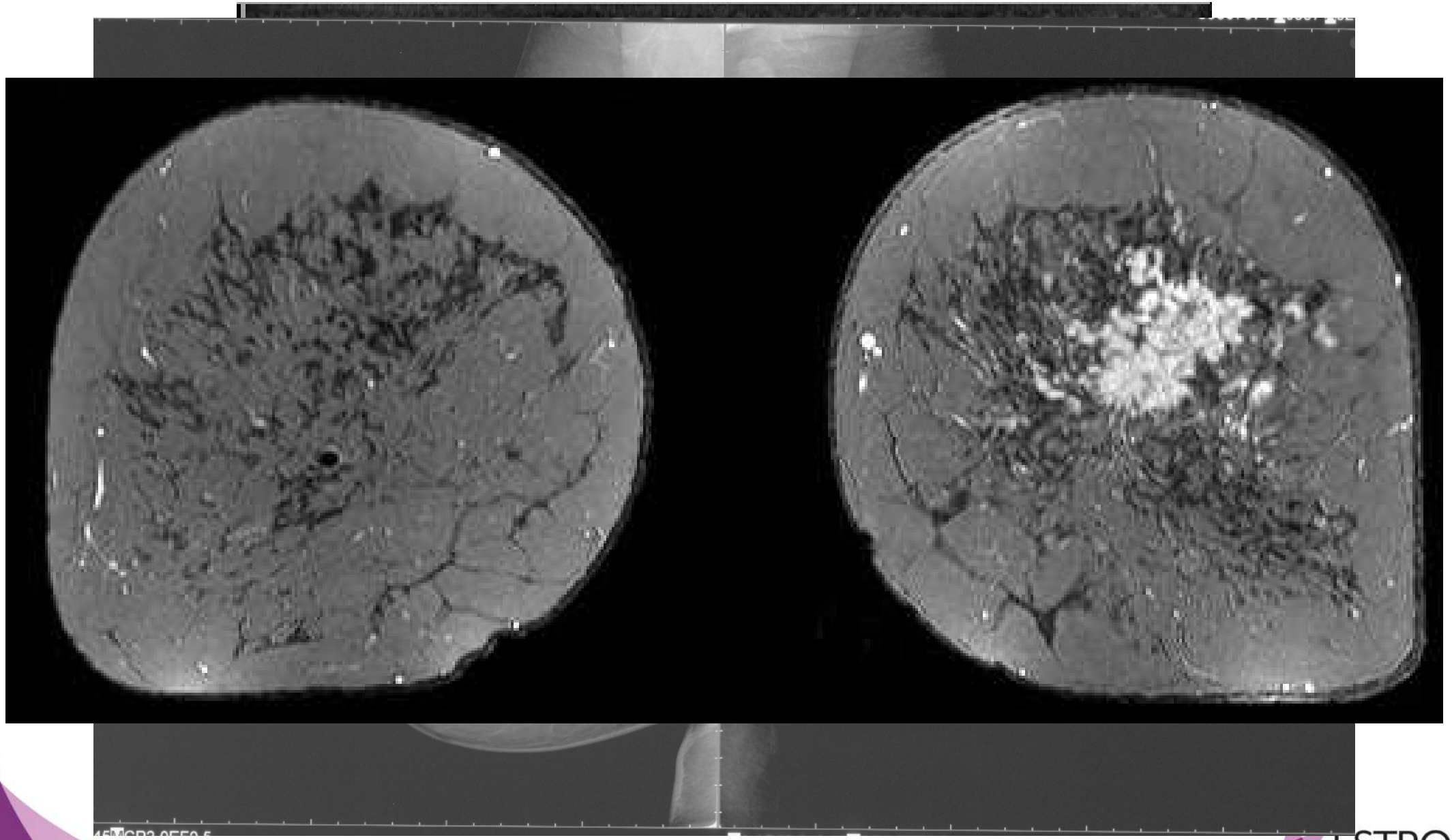

Extent of mircrocalcifications

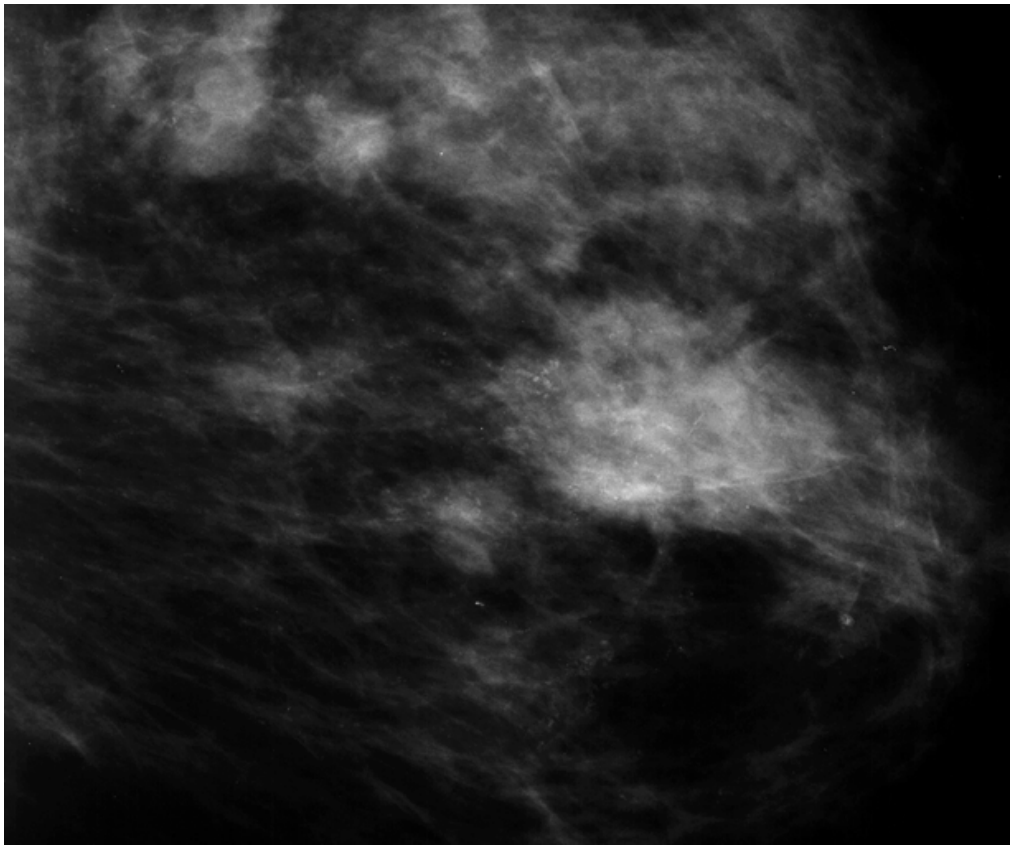

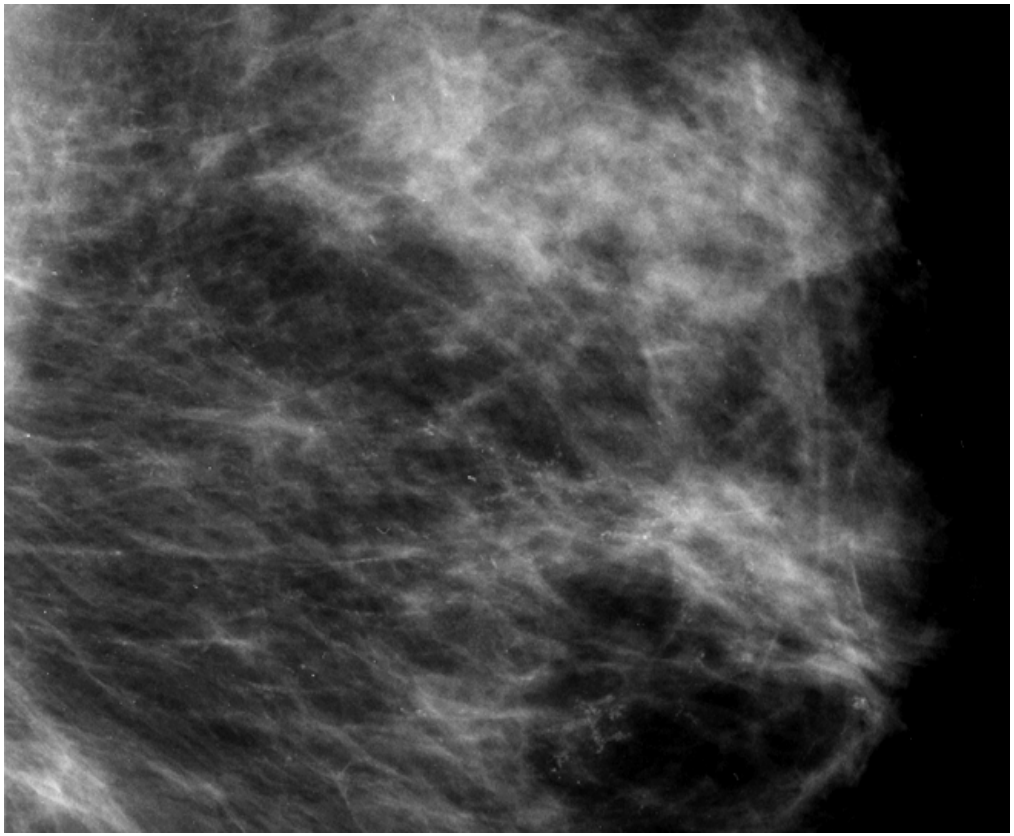

Abb. 16

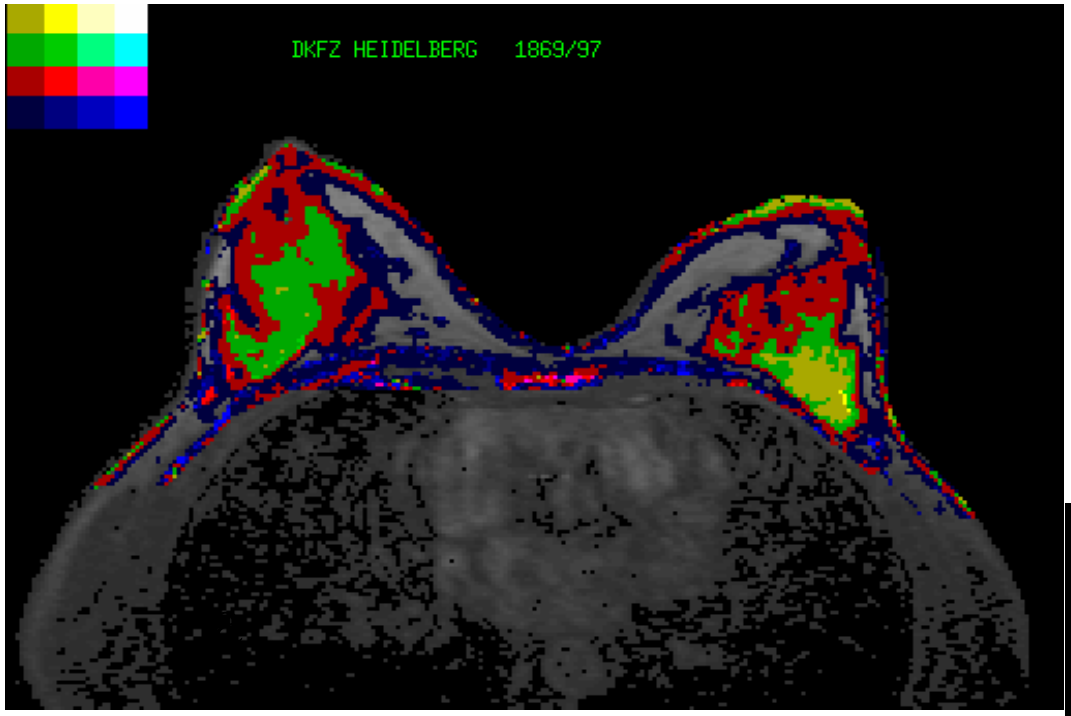
DKFZ HEIDELBERG 1869/97

b

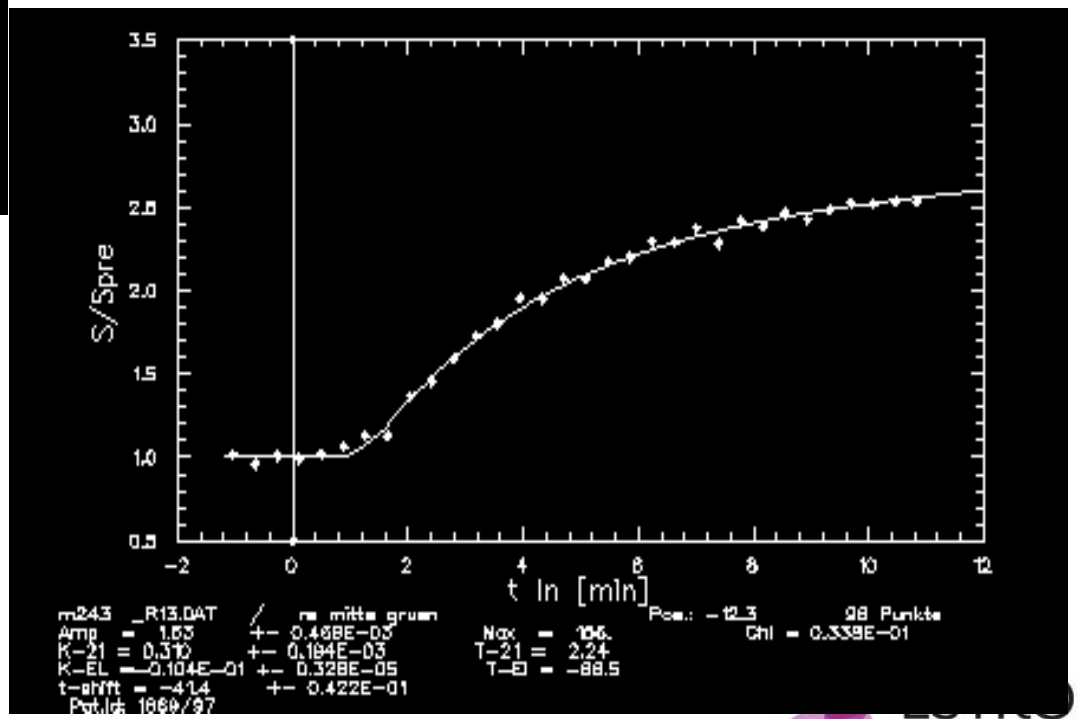
S/Spre
t in [min]
3.5
3.0
2.5
2.0
1.5
1.0
0.5
-2
0
2
4
6
8
10
12
m243 _R13.DAT / m mitte grum
Amp = 1.63 +- 0.468E-03
K-21 = 0.310 +- 0.184E-03
K-EL = -0.104E-01 +- 0.328E-05
t-shift = -4.14 +- 0.422E-01
Patid: 1869/97
Max = 196.
T-21 = 2.24
T-0 = -88.5
Pos.: -12.3
Chi = 0.338E-01
98 Punkte

Before chemotherapy

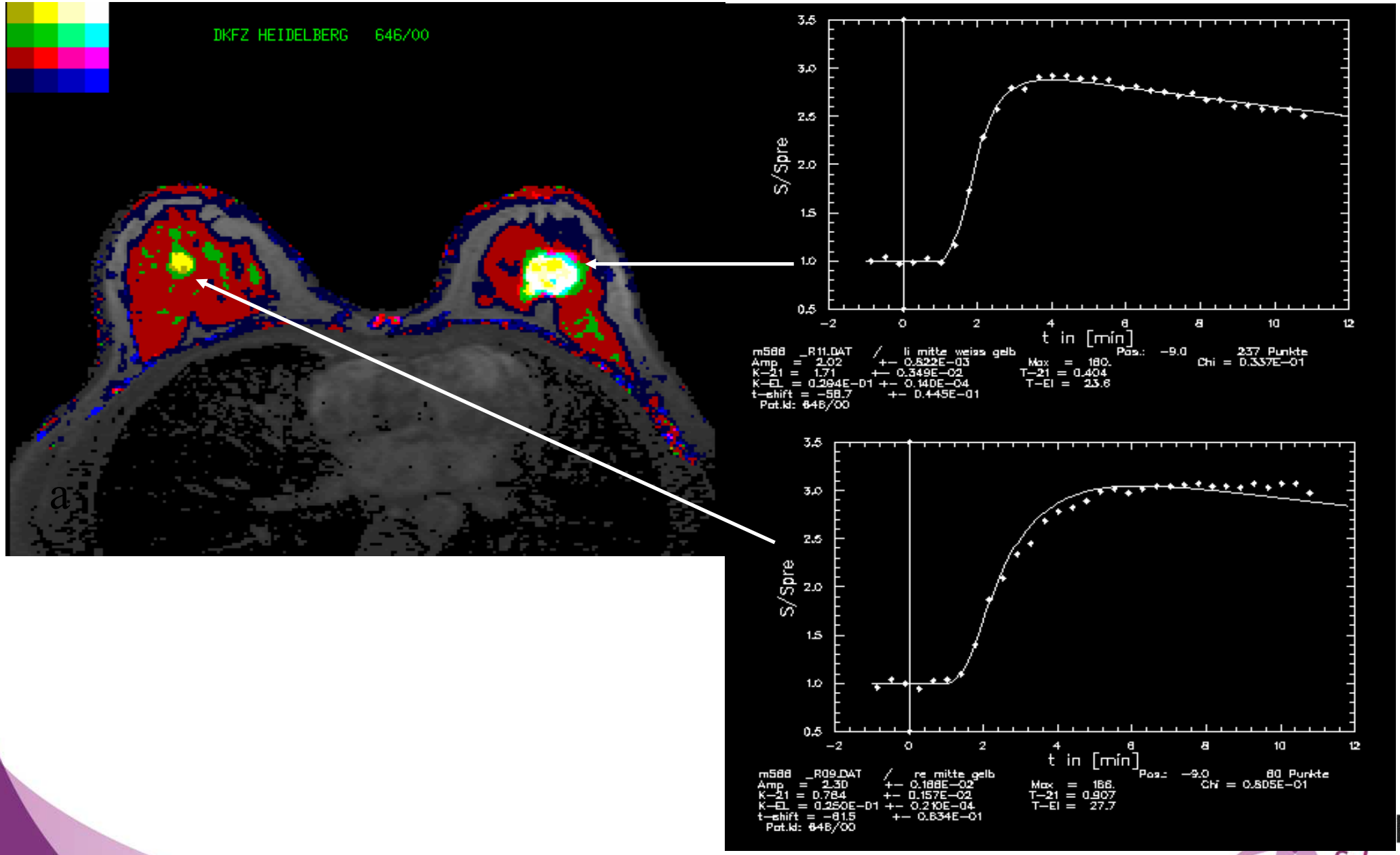

After chemotherapy

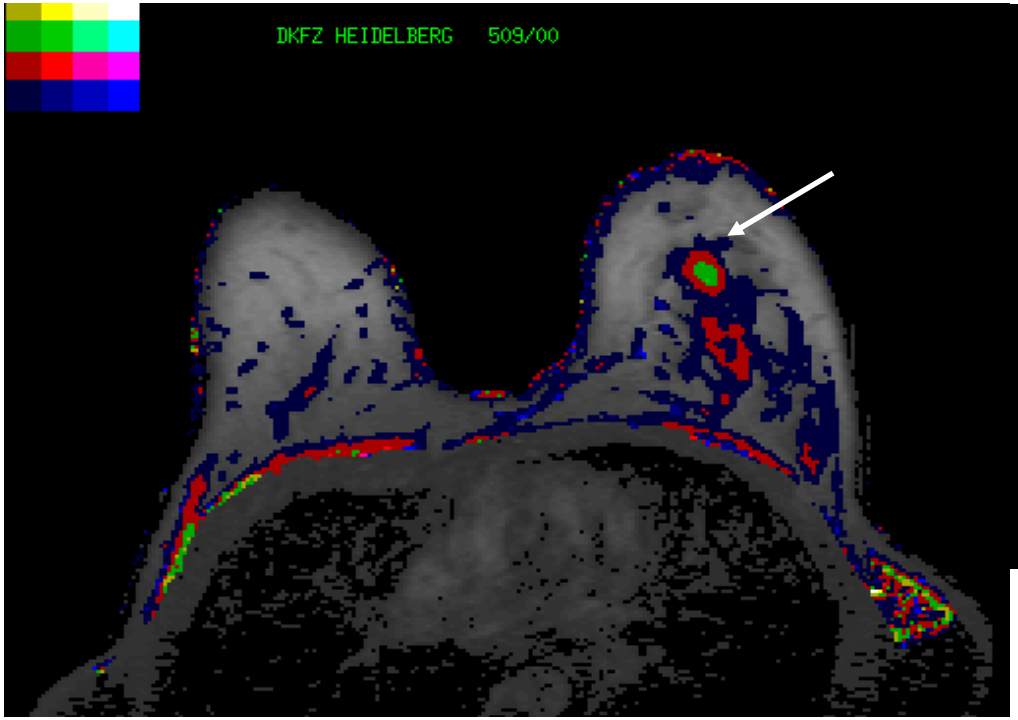

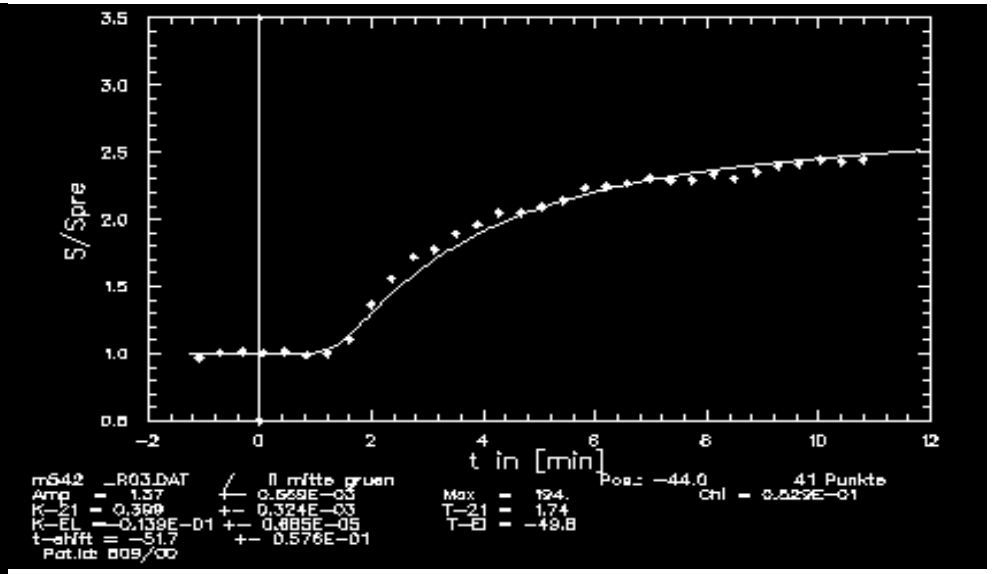

Before chemotherapy

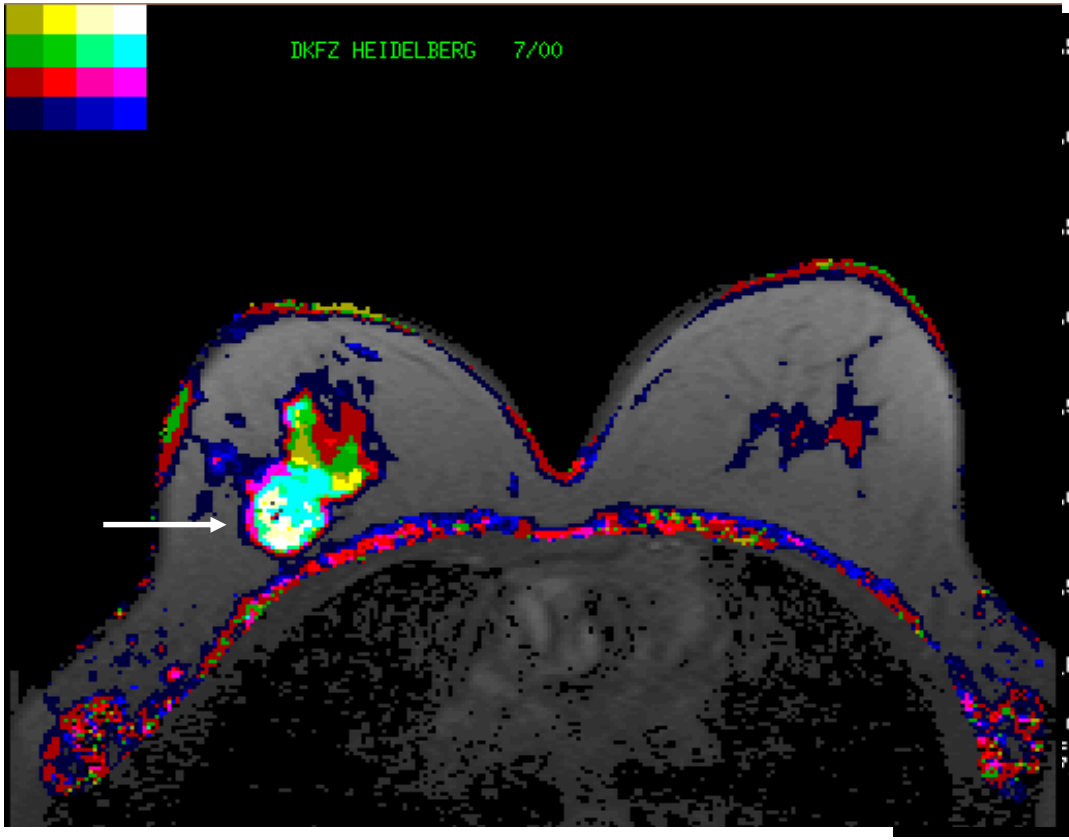

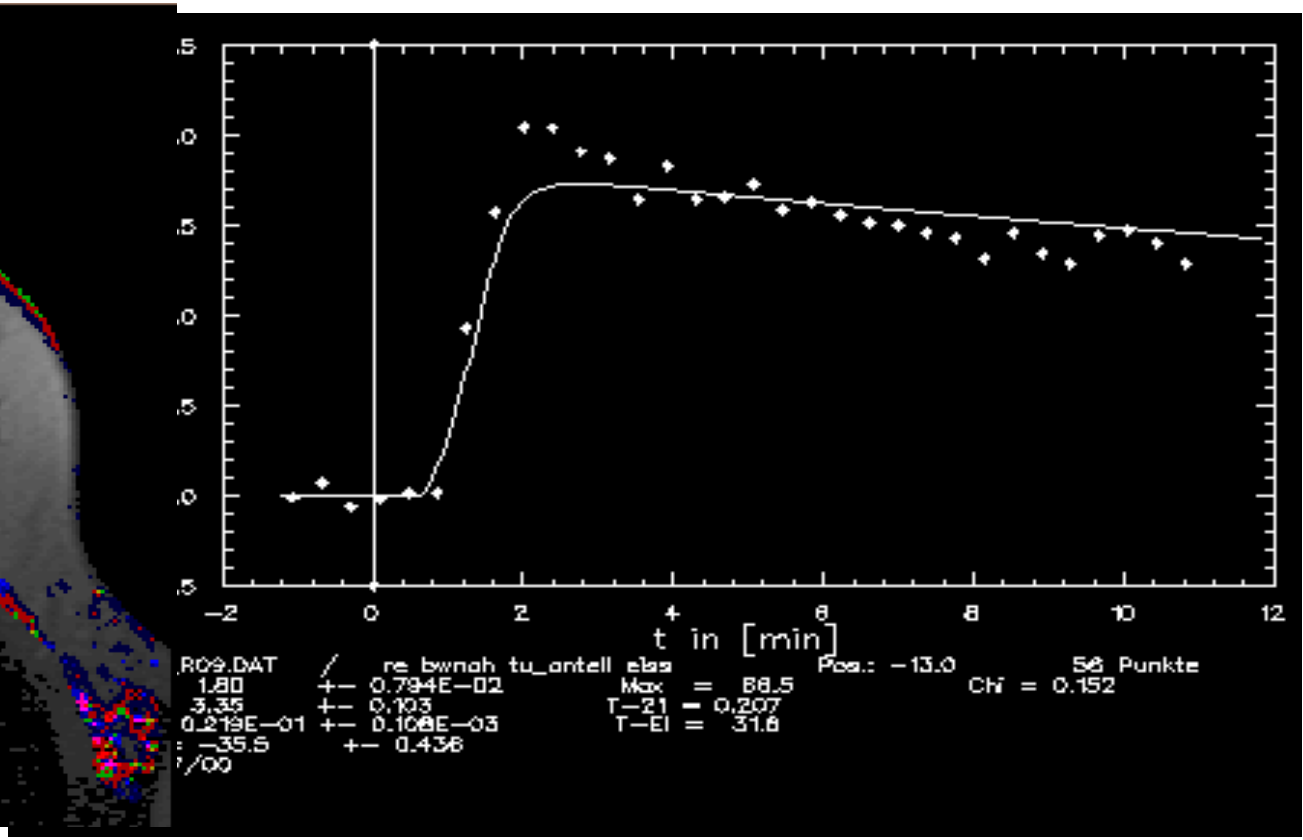

After chemotherapy

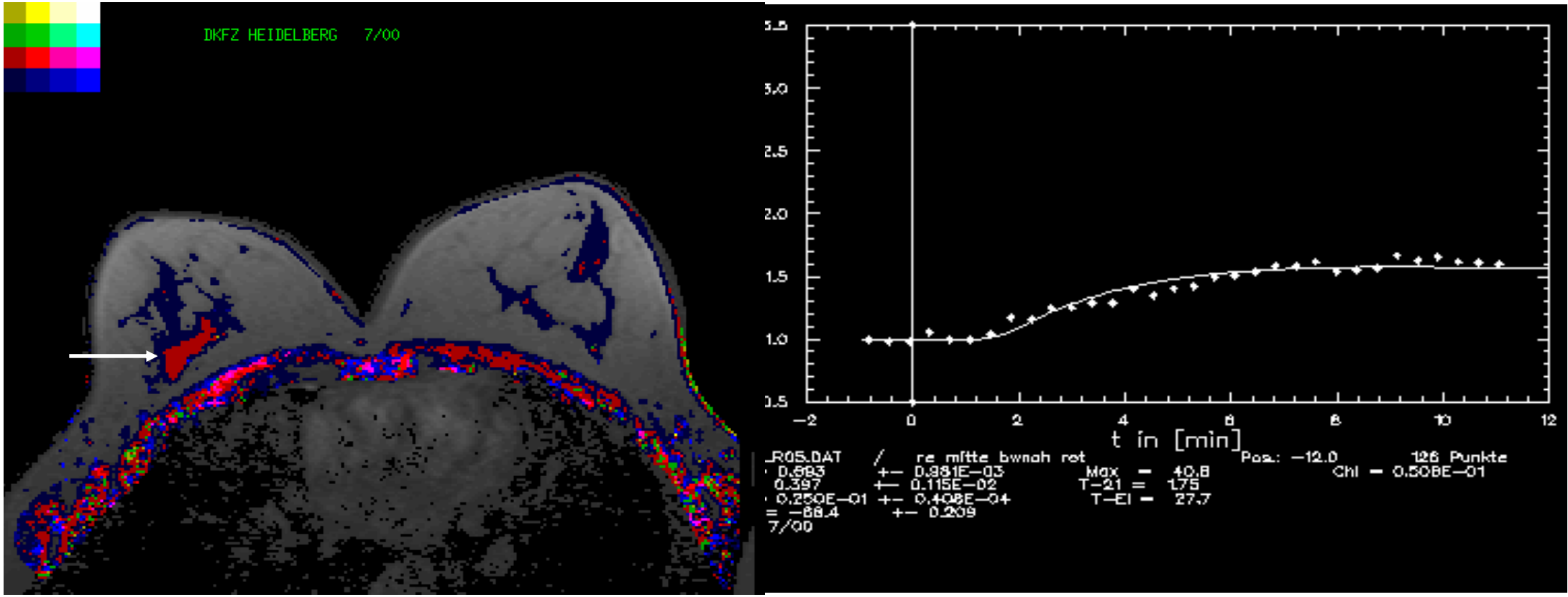

Microcalcifications: Changes during treatment

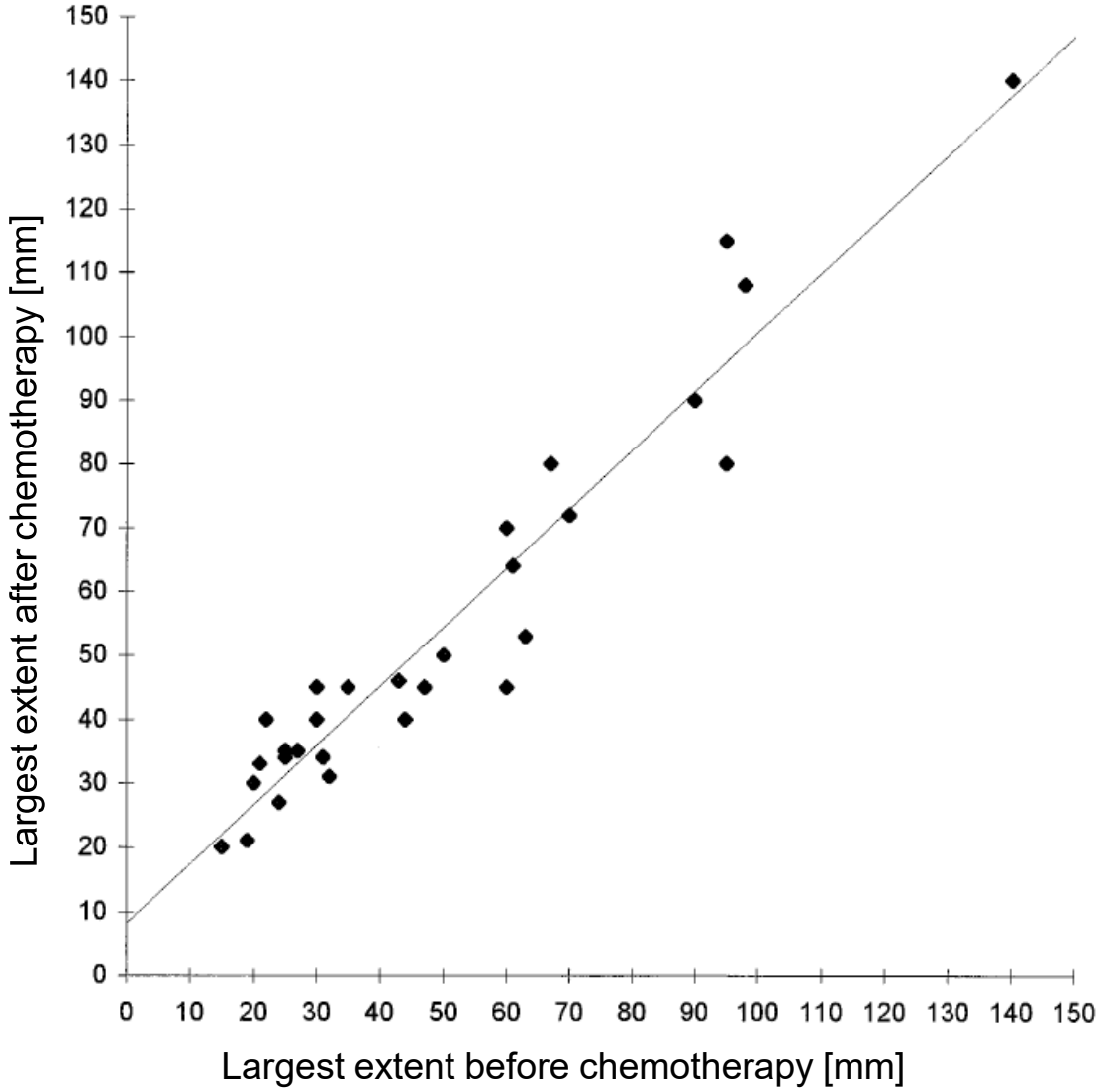

Junkermann 1997

ESTRO School

MRI vs. histology

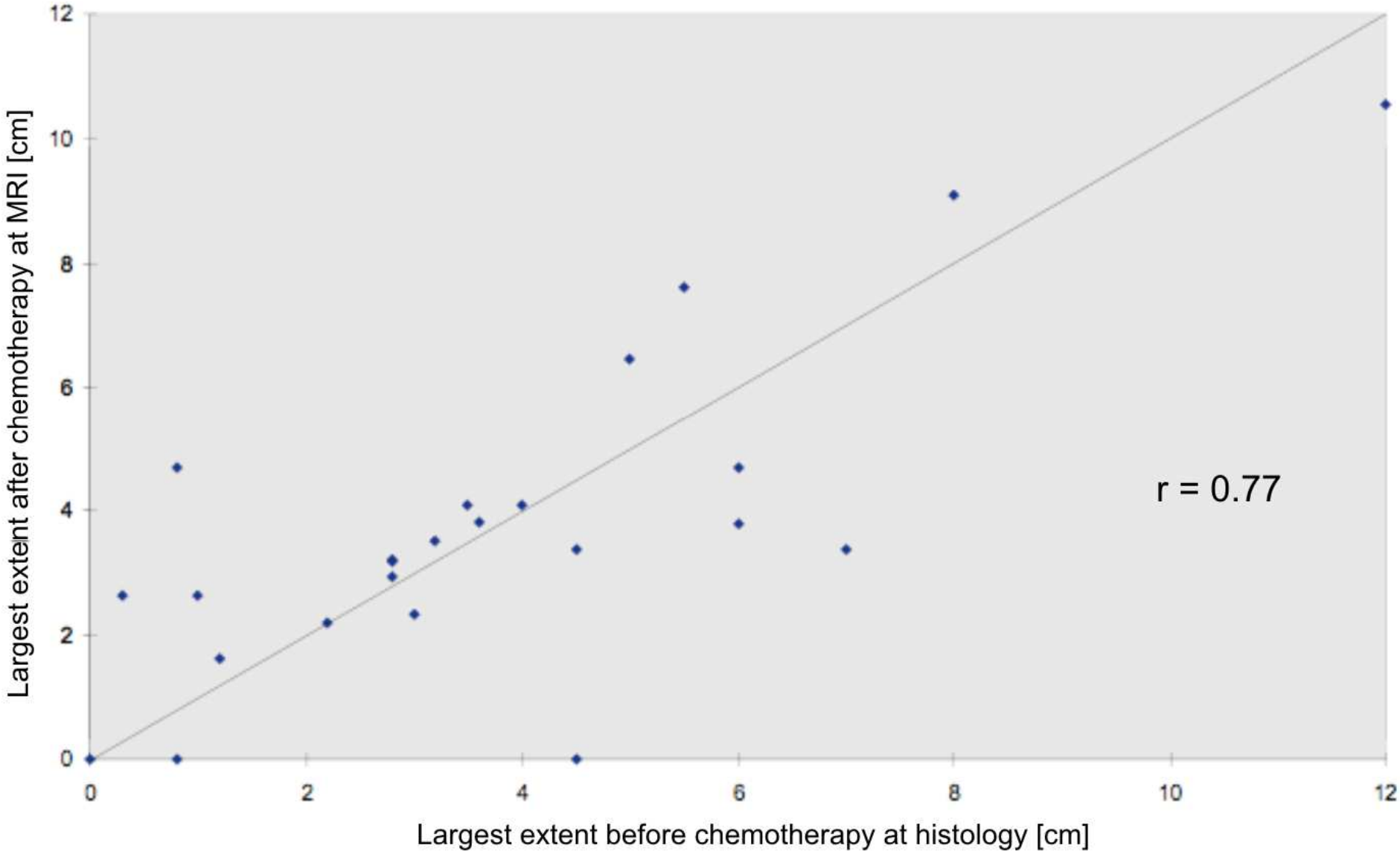

Klein SK medical dissertation 2002

ESTRO School

Pause!

Pause!

Key anatomical structures. Breast - CTV & OARs

Dra Marta Bonet
Radiation Oncology Department,
Hospital Universitari Sant Joan de Reus,
University Rovira i Virgili, Spain

Hospital Universitari Sant Joan REUS

Lisbon, Portugal

24-28 July, 2017

- **Introduction**
- CTV:
  - Post-lumpectomy intact breast
  - Chestwall
  - Boost
  - Nodes
    - L1, L2, L3, L4, IM, Rotter
- Organs at risk
- Margins: CTV to PTV and OAR to PRV
- Conclusions

WHY DO WE USE ADJUVANT RT IN BREAST CANCER PATIENTS? (i)

- After **conservative** surgery:
  - To decrease local recurrences:

	CS	CS + RT	Reduction
NSABP B-06	36%	12%	67%
Uppsala-Orebro	24%	9%	63%
Ontario	35%	11%	69%
Milan	24%	6%	75%
Swedish	14%	4%	71%

  - To decrease mortality:

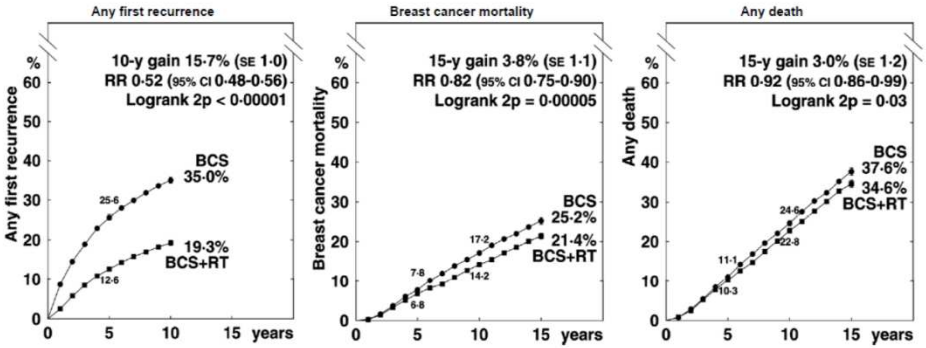

N=10801 in 17 randomized trials

Early Breast Cancer Trialists' Collaborative Group (EBCTCG). Lancet. 2011 Nov 12;378(9804):1707-16

ESTRO School

Conservative treatment is even better nowadays!!!

The Breast Journal

Explore this journal >

Original Article

Survival after Breast-Conserving Surgery with Whole Breast or Partial Breast Irradiation in Women with Early Stage Breast Cancer: A SEER Data-base Analysis

Surbhi Grover MD, MPH, Sommer Nurkic MD, MPH, Marie Diener-West PhD, Shayna L. Showalter MD

First published: 18 December 2016 Full publication history

■ **Abstract:** Randomized clinical trials have demonstrated equivalency in survival outcomes for early stage breast cancer patients treated with either mastectomy or breast-conserving surgery (BCS) with radiation. Recent, state-level data confirm comparable survival outcomes. Using Surveillance Epidemiology and End Research (SEER) data, we sought to evaluate survival outcomes among patients with early stage breast cancer treated with mastectomy, BCS with whole breast irradiation (BCS + WBI), or BCS with accelerated partial breast irradiation (BCS + APBI). Data on women 50 years or older diagnosed with a node negative invasive breast cancer (≤3 cm in size) between 1995 and 2009 were extracted from the SEER data base. Women treated with mastectomy alone or BCS with radiation were eligible for analysis. Kaplan–Meier estimates and Cox proportional hazard models were used to compare overall survival (OS) and cancer-specific survival (CSS) among the treatment groups. 150,171 women fulfilled inclusion criteria. OS was significantly improved among women treated with BCS and WBI or BCS and APBI compared to mastectomy alone. Adjusted hazard ratios for death in BCS with WBI or APBI (versus mastectomy alone) were 0.73 (95% CI: 0.71, 0.76) and 0.68 (95% CI: 0.58, 0.79), respectively. Adjusted CSS was also significantly improved in patients treated with BCS and WBI (HR 0.80, 95% CI: 0.76, 0.85) as compared to mastectomy. BCS with radiation (WBI or APBI) was associated with significantly improved OS and CSS, versus mastectomy alone. These results support the use of BCS with WBI or APBI (in well selected patients) for the treatment of breast cancer. ■

Key Words: accelerated partial breast irradiation, breast-conserving therapy, mastectomy

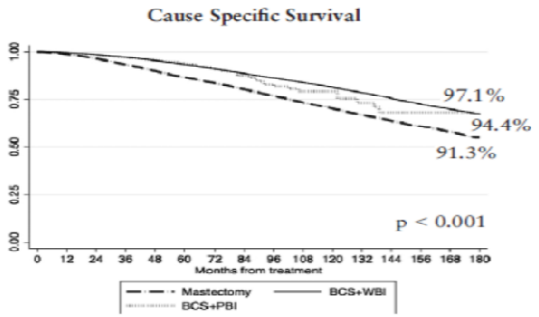

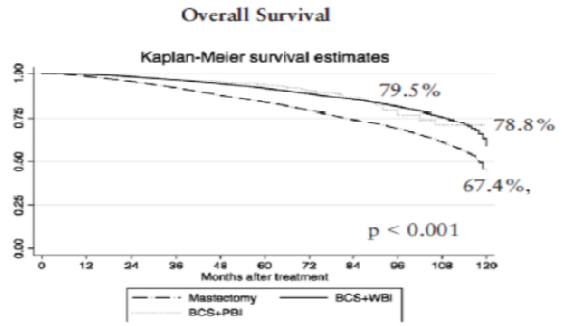

TRO School

Benefits of IMC+Regional irradiation

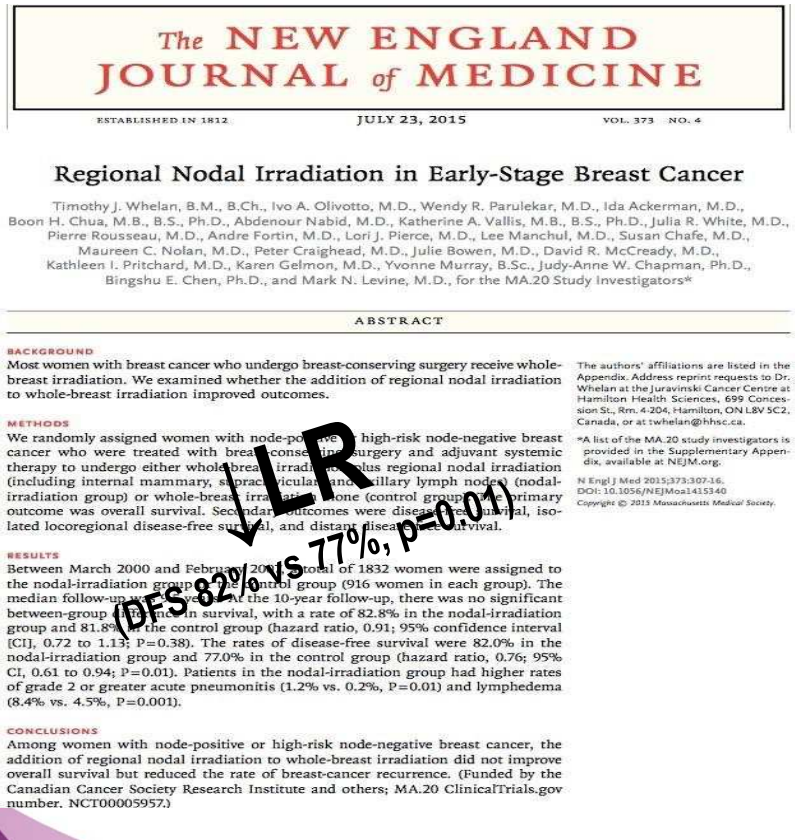

The NEW ENGLAND JOURNAL of MEDICINE

ESTABLISHED IN 1812 JULY 23, 2015 VOL. 373 NO. 4

Regional Nodal Irradiation in Early-Stage Breast Cancer

Timothy J. Whelan, B.M., B.Ch., Ivo A. Olivotto, M.D., Wendy R. Parulekar, M.D., Ida Ackerman, M.D., Boon H. Chua, M.B., B.S., Ph.D., Abdenour Nabid, M.D., Katherine A. Vallis, M.B., B.S., Ph.D., Julia R. White, M.D., Pierre Rousseau, M.D., Andre Fortin, M.D., Lori J. Pierce, M.D., Lee Manchul, M.D., Susan Chafe, M.D., Maureen C. Nolan, M.D., Peter Craighead, M.D., Julie Bowen, M.D., David R. McCready, M.D., Kathleen I. Pritchard, M.D., Karen Gelmon, M.D., Yvonne Murray, B.Sc., Judy-Anne W. Chapman, Ph.D., Bingshu E. Chen, Ph.D., and Mark N. Levine, M.D., for the MA.20 Study Investigators*

ABSTRACT

BACKGROUND

Most women with breast cancer who undergo breast-conserving surgery receive whole-breast irradiation. We examined whether the addition of regional nodal irradiation to whole-breast irradiation improved outcomes.

METHODS

We randomly assigned women with node-positive or high-risk node-negative breast cancer who were treated with breast-conserving surgery and adjuvant systemic therapy to undergo either whole-breast irradiation plus regional nodal irradiation (including internal mammary, supraclavicular, and axillary lymph nodes) (nodal-irradiation group) or whole-breast irradiation alone (control group). The primary outcome was overall survival. Secondary outcomes were disease-free survival, isolated locoregional disease-free survival, and distant disease-free survival.

RESULTS

Between March 2000 and February 2[illegible], a total of 1832 women were assigned to the nodal-irradiation group or the control group (916 women in each group). The median follow-up was 8.2 years. At the 10-year follow-up, there was no significant between-group difference in survival, with a rate of 82.8% in the nodal-irradiation group and 81.8% in the control group (hazard ratio, 0.91; 95% confidence interval [CI], 0.72 to 1.13; P=0.38). The rates of disease-free survival were 82.0% in the nodal-irradiation group and 77.0% in the control group (hazard ratio, 0.76; 95% CI, 0.61 to 0.94; P=0.01). Patients in the nodal-irradiation group had higher rates of grade 2 or greater acute pneumonitis (1.2% vs. 0.2%, P=0.01) and lymphedema (8.4% vs. 4.5%, P=0.001).

CONCLUSIONS

Among women with node-positive or high-risk node-negative breast cancer, the addition of regional nodal irradiation to whole-breast irradiation did not improve overall survival but reduced the rate of breast-cancer recurrence. (Funded by the Canadian Cancer Society Research Institute and others; MA.20 ClinicalTrials.gov number, NCT00005957.)

The authors' affiliations are listed in the Appendix. Address reprint requests to Dr. Whelan at the Juravinski Cancer Centre at Hamilton Health Sciences, 699 Concession St., Rm. 4-204, Hamilton, ON L8V 5C2, Canada, or at twhelan@hhsc.ca.

*A list of the MA.20 study investigators is provided in the Supplementary Appendix, available at NEJM.org.

N Engl J Med 2015;373:307-16.
DOI: 10.1056/NEJMoa1415340
Copyright © 2015 Massachusetts Medical Society.

The NEW ENGLAND JOURNAL of MEDICINE

ORIGINAL ARTICLE

Internal Mammary and Medial Supraclavicular Irradiation in Breast Cancer

P.M. Poortmans, S. Collette, C. Kirkove, E. Van Limbergen, V. Budach, H. Struikmans, L. Collette, A. Fourquet, P. Maingon, M. Valli, K. De Winter, S. Marnitz, I. Barillot, L. Scandolaro, E. Vonk, C. Rodenhuis, H. Marsiglia, N. Weidner, G. van Tienhoven, C. Glanzmann, A. Kuten, R. Arriagada, H. Bartelink, and W. Van den Bogaert, for the EORTC Radiation Oncology and Breast Cancer Groups*

ABSTRACT

BACKGROUND

The effect of internal mammary and medial supraclavicular lymph-node irradiation (regional nodal irradiation) added to whole-breast or thoracic-wall irradiation after surgery on survival among women with early-stage breast cancer is unknown.

METHODS

We randomly assigned women who had a c[illegible] centrally located primary tumor, irrespective of axillary involvement, [illegible] tumor with axillary involvement to undergo either whole-breast or thoracic-wall irradiation in addition to regional nodal irradiation (nodal-irradiation group) or whole-breast or thoracic-wall irradiation alone (control group). The primary end point was overall survival. Secondary end points [illegible] the rates of disease-free survival, survival free from distant disease, and death from breast cancer.

RESULTS

Between 1996 and 2004, a total of 4004 patients underwent randomization. The majority of patients (76.1%) underwent breast-conserving surgery. After mastectomy, 73.4% of the patients in both groups underwent chest-wall irradiation. Nearly all patients with node-positive disease (96.9%) and 66.3% of patients with node-negative disease received adjuvant systemic treatment. At a median follow-up of 10.9 years, 811 patients had died. At 10 years, overall survival was 82.3% in the nodal-irradiation group and 80.7% in the control group (hazard ratio for death with nodal irradiation, 0.87; 95% confidence interval [CI], 0.76 to 0.[illegible]). The rate of disease-free survival was 72.1% in the nodal-irradiation group and 69.1% in the control group (hazard ratio for disease recurrence or death, 0.89; 95% CI, 0.80 to 1.00; P=0.04). The rate of distant disease–free survival was 78.0% versus 75.0% (hazard ratio, 0.8[illegible]; 95% CI, 0.7[illegible] to 0.98; P=0.02), and breast-cancer mortality was 12.5% versus 15.[illegible]% (hazard ratio, 0.82; 95% CI, 0.70 to 0.97; P=0.02). Acute side effects of regional nodal irradiation were modest.

CONCLUSIONS

In patients with early-stage breast cancer, irradiation of the regional nodes had a marginal effect on overall survival. Disease-free survival and distant disease-free survival were improved, and breast-cancer mortality was reduced. (Funded by Fonds Cancer; ClinicalTrials.gov number, NCT00002851.)

The authors' full names, academic degrees, and affiliations are listed in the Appendix. Address reprint requests to Dr. [illegible] at the Department of Radiation Oncology, Radboud University Medical Center, P.O. Box 9101, 6500 HB Nijmegen, the Netherlands, or at philip.poortmans@radboudumc.nl.

*A complete list of investigators in the European Organization for Research and Treatment of Cancer (EORTC) Radiation Oncology and Breast Cancer Groups is provided in the Supplementary Appendix, available at NEJM.org.

N Engl J Med 2015;373:317-27.
DOI: 10.1056/NEJMoa1415369
Copyright © 2015 Massachusetts Medical Society.

LR (DFS 82% vs 77%, p=0.01)

Better DFS (72.1% vs 69.1%, p=0.04) and MFS (78% vs 75%, p=0.02)

ESTRO School

WHY DO WE USE ADJUVANT RT IN BREAST CANCER PATIENTS? (ii)

- **Post-mastectomy**: Meta-análisis EBCTG (Node (-): 700 pts); Node (+): 3131 pts)

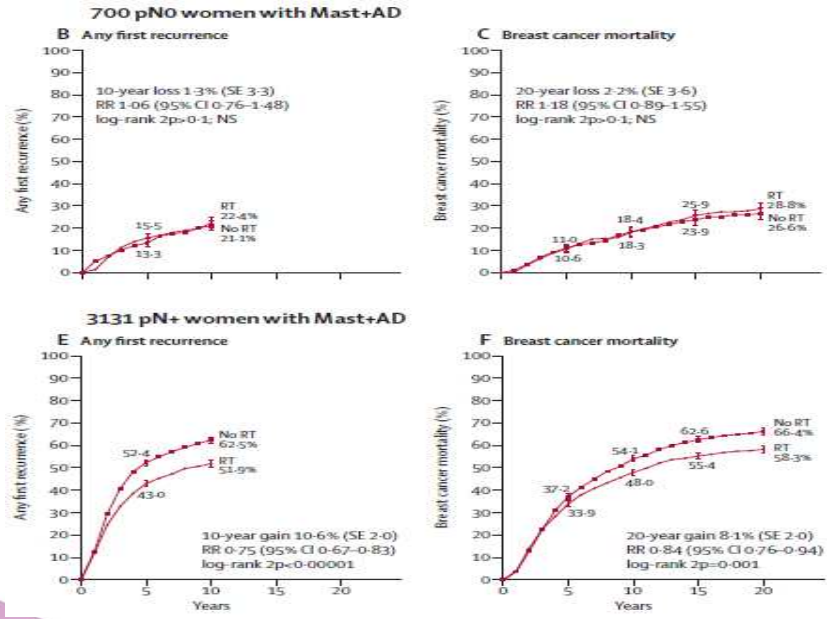

Reduces recurrence
10 year gain 1.3% (N-) and 10.6% (N+)

Reduces breast cancer mortality
20 year gain 2.2% (N-) and 8.1% (N+)

ONE BREAST CANCER DEATH IS AVOIDED FOR EVERY FOUR LOCAL RECURRENCES AVOIDED

The Lancet 2014 , Volume 383 , Issue 9935 , 2127 - 2135

ESTRO School

CTV L4-L3: Even for 1-3 N+

EBCTG META-ANALYSIS (post-mastectomy): POSITIVE RESULTS in SURVIVAL 1-3 N+

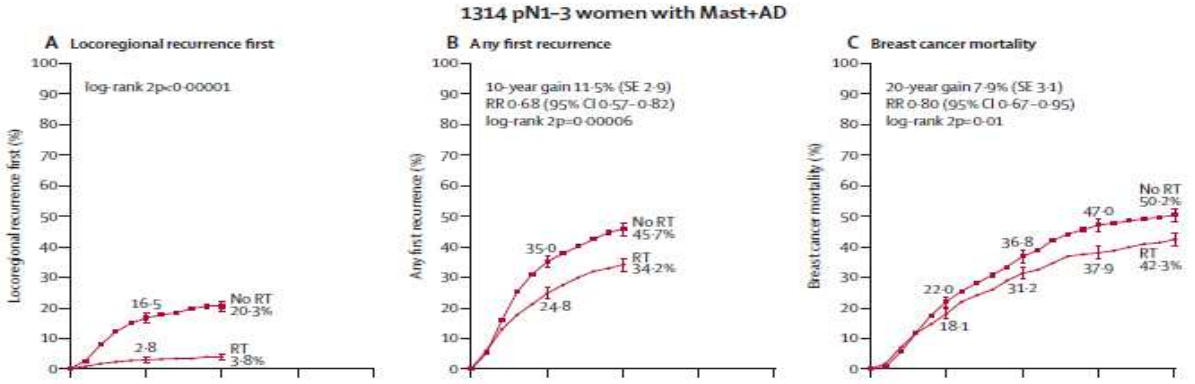

11.5%

7.9%

ESTRO School

Postmastectomy radiation in breast cancer with one to three involved lymph nodes: ending the debate

www.thelancet.com **Vol 383 June 21, 2014**

Philip Poortmans
Department of Radiation Oncology, Institute Verbeeten, Tilburg, LA 5000, Netherlands
poortmans.ph@bvi.nl

The results of this EBCTCG meta-analysis clearly confirm that postmastectomy radiotherapy should be considered equally for patients with one to three involved axillary lymph nodes as it should be for patients with four or more affected axillary lymph nodes. The same considerations concerning regional radiotherapy also seem to be valid for patients treated with breast-conserving therapy.[1,2] Here, the addition of regional radiotherapy to whole breast irradiation adds less to the burden of treatment to the patient, on the condition that long-term toxic effects can be avoided with modern radiotherapy techniques.

ESTRO School

Variability in delineation

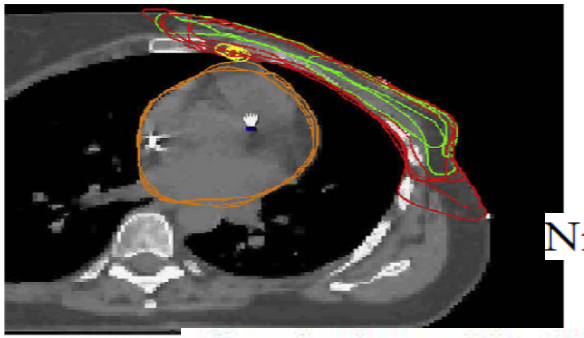

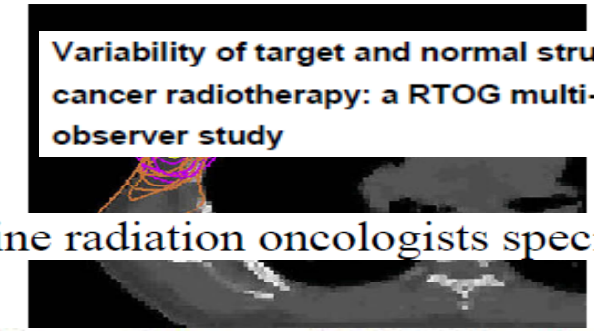

Variability of target and normal structure delineation for breast-cancer radiotherapy: a RTOG multi-institutional and multi-observer study

Nine radiation oncologists specializing in breast RT

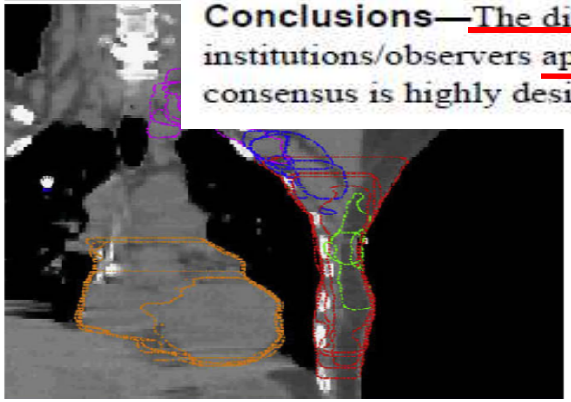

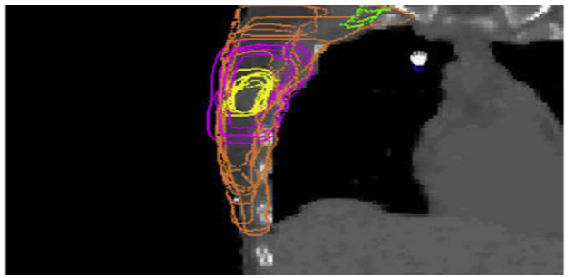

Conclusions—The differences in target and OAR delineation for breast irradiation between institutions/observers appear to be clinically and dosimetrically significant. A systematic consensus is highly desirable, particularly in the era of IMRT/IGRT.

X. Allen Li. Int. J. Radiation Oncology Biol. Phys., Vol. 73, No. 3, pp. 944–951, 2009

ESTRO School

Variability in delineation

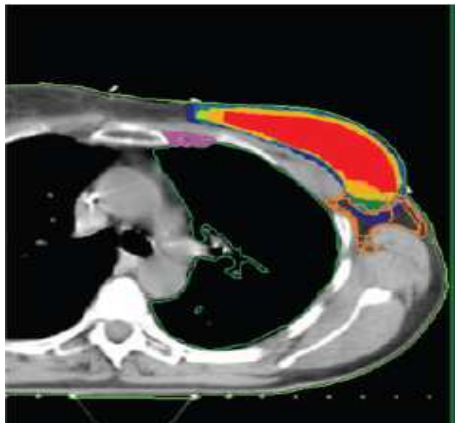

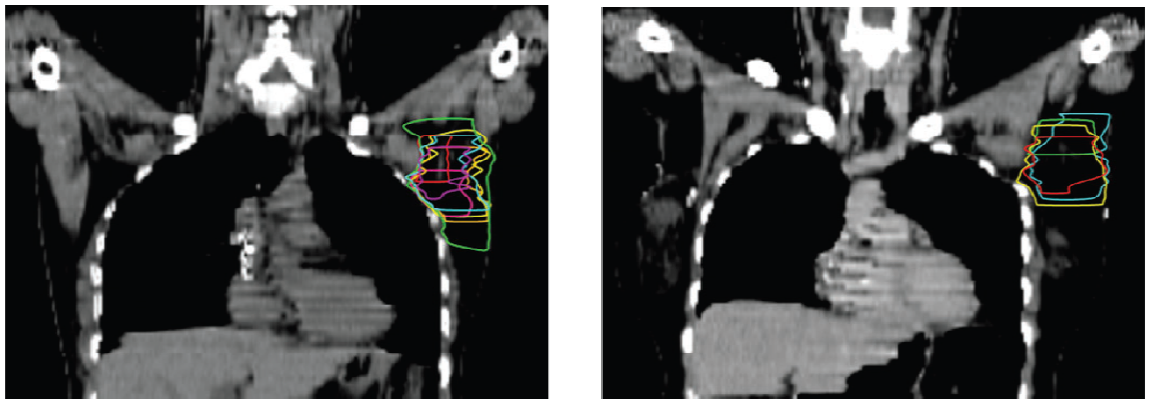

(a) (b)

Figure 3. Practical example of axillary delineation before and after continuing medical education (CME) and using the simplified practical rules: ''how to delineate the lymph node areas?''. (a) Before training; (b) after training.

It's very important to know the local and the individual anatomy of the patients, their position and the large variability in the depth of nodes.

The British Journal of Radiology, 82 (2009), 595–599

Anatomical, clinical and radiological delineation of target volumes in breast cancer radiotherapy planning: individual variability, questions and answers

P CASTRO PENA, MD, Y M KIROVA, MD, F CAMPANA, MD, R DENDALE, MD, M A BOLLET, MD, N FOURNIER-BIDOZ, PhD and A FOURQUET, MD

ESTRO School

Breast CTV delineation

- **Outcomes may be dependent on what is being targeted and/or avoided**
- **Use standardised definitions for target and Organs at risk delineation (Guidelines)**

- **Most frequent situations:**
  - Intact post-lumpectomy breast CTV
  - Post-mastectomy CTV (Chestwall)
  - Lumpectomy CTV (as a boost / for partial breast irradiation)

- Less frequent situations:
  - Intact post-lumpectomy breast CTV with a retropectoral or retroglandular implant
  - Post-mastectomy reconstructed “breast” CTV
  - Preoperative GTV

ESTRO School

Breast anatomy

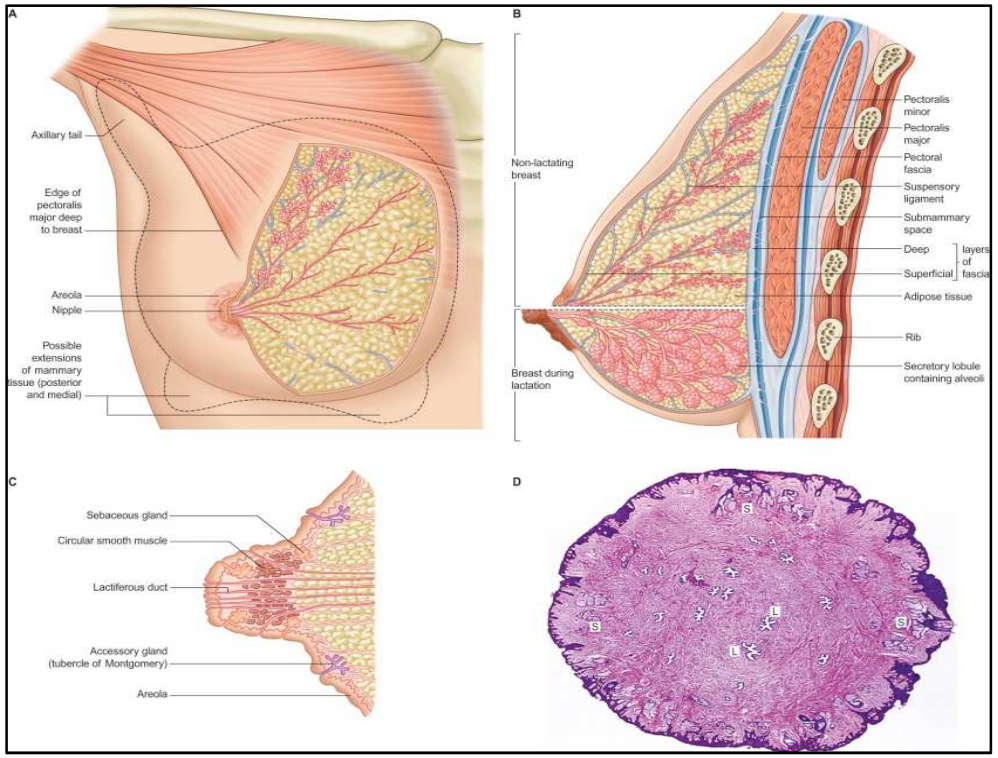

Jorge I. de la Torre y Michael R. DavisAnatomy for plastic surgery of the breast. Plastic SurgeryThird Edition 2013, Elsevier

A–C from Standring S, ed. Gray's anatomy, 40th edn. London: Churchill Livingstone; 2008; D, from Kerr JB. Atlas of functional histology. London: Mosby; 1999

ESTRO School

Tips to quickly recognise the most important boundaries in the breast

KEY ANATOMICAL STRUCTURES

ESTRO School

Muscles and bones

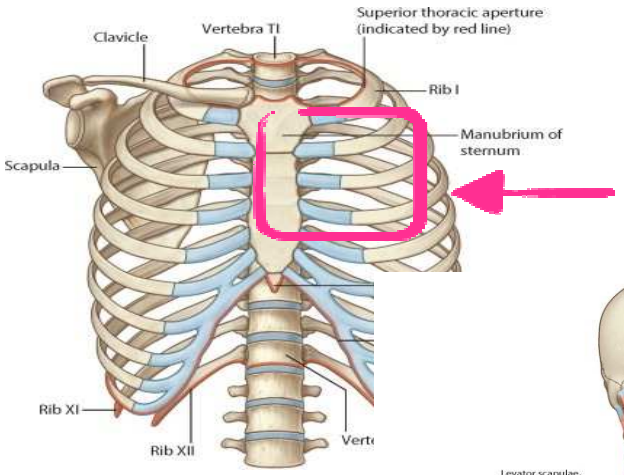

The 3 first intercostal spaces

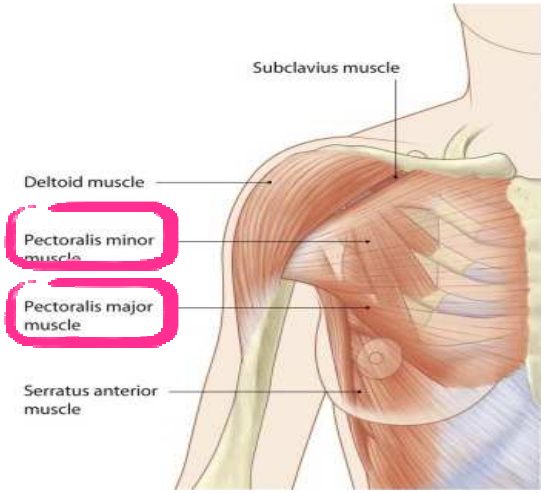

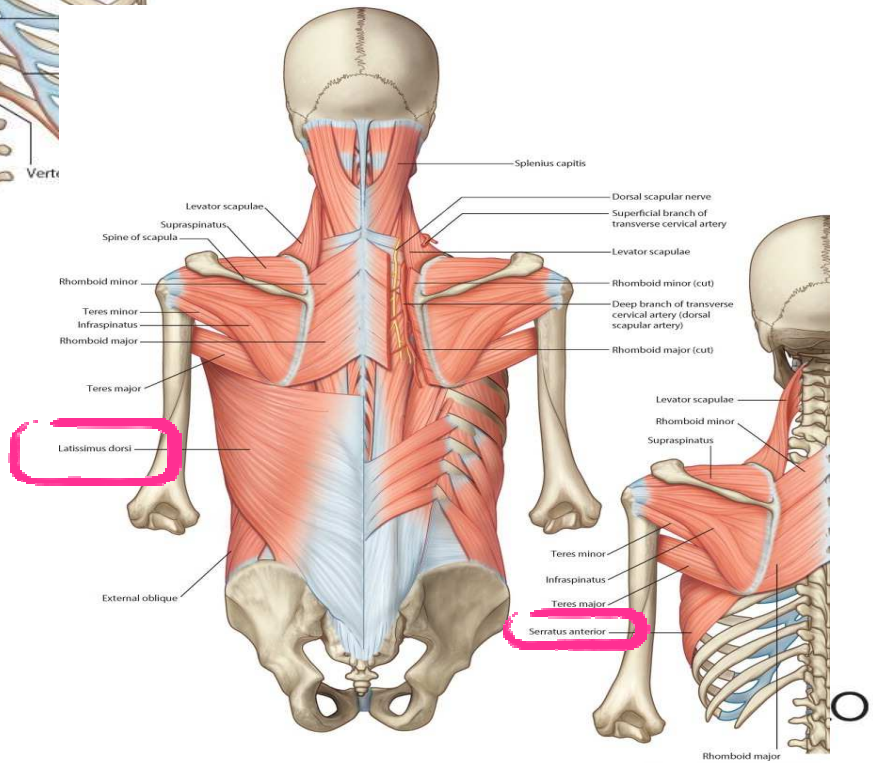

Drake, RL, Vogl, AW, Mitchell, A (eds), Gray's Anatomy for Students, 2nd ed, Elsevier, Churchill Livingstone. Copyright 2010

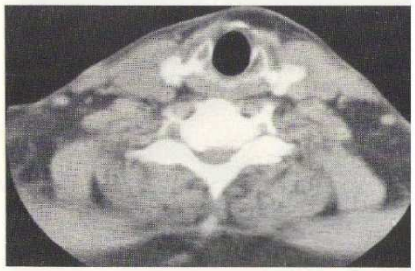

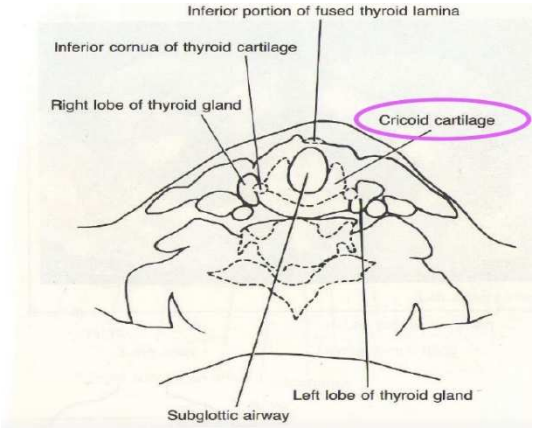

Pocket Atlas of normal CT anatomy. JB Weinstein

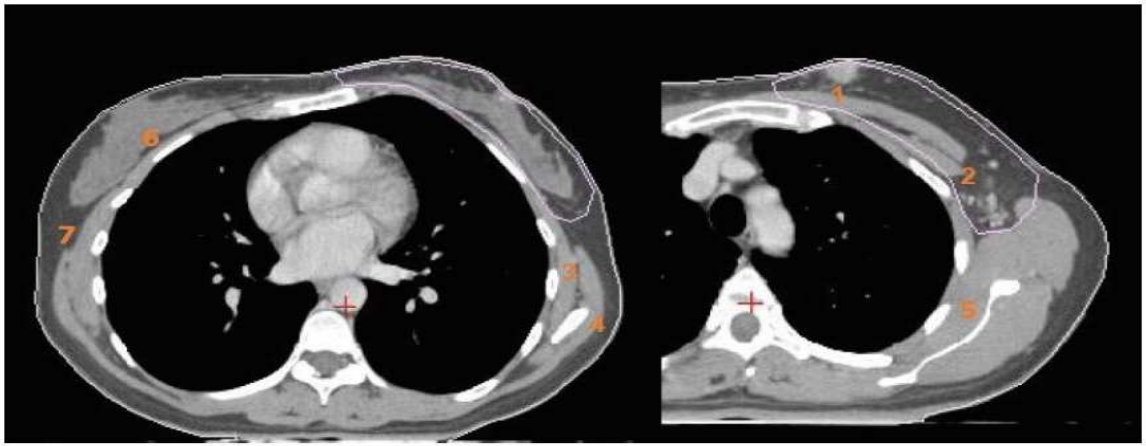

1 pectoralis major. 2 pectoralis minor. 3 serratus anterior.
4 latissimus dorsi. 5 subscapularis. 6 mammary gland. 7 fat

Courtesy of Dra. Arenas

ESTRO School

ESTRO School

Arteries and veins

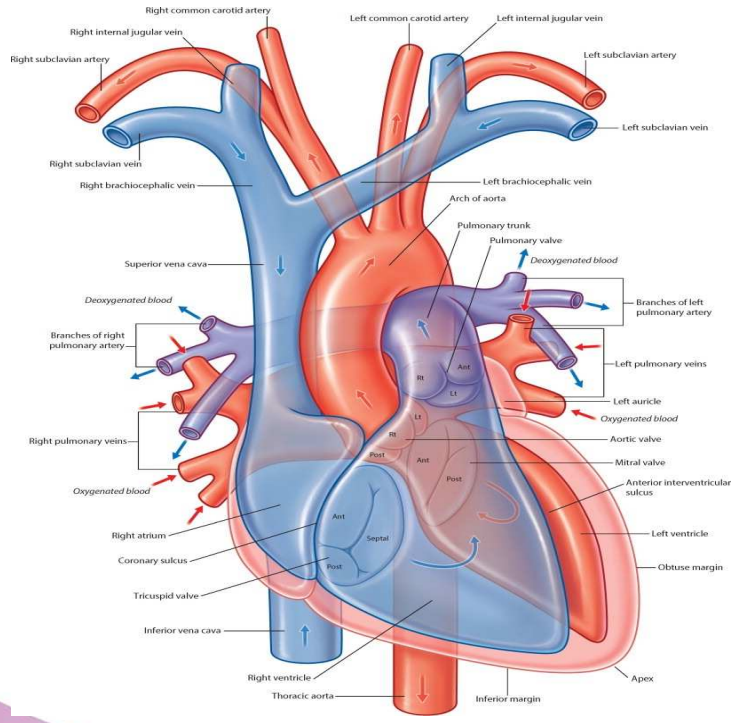

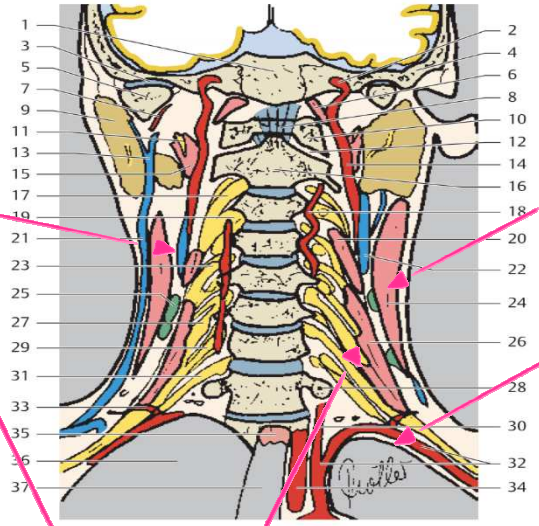

Internal jugular vein

Sternocleidomastoid ms

Subclavian artery

Anterior scalene ms

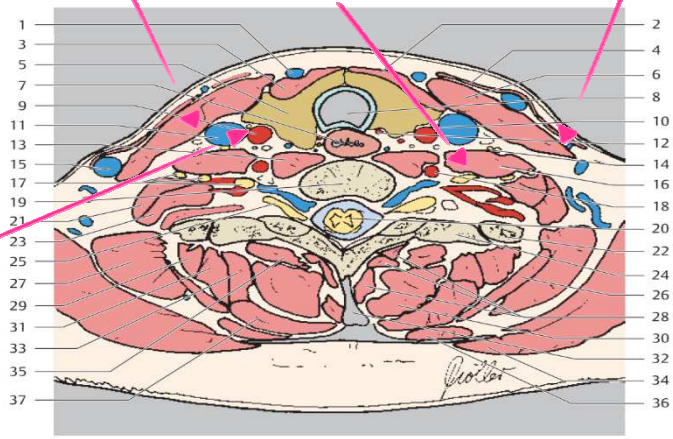

Common carotid artery

ESTRO School

The nodes

- Boundaries of the “surgical” axila (Berg I-II levels):
  - ➢ Medially: serratus anterior muscle
  - ➢ Anteriorly: pectoralis major and minor muscles
  - ➢ Posteriorly: muscles and fascia of the subscapular region
  - ➢ Cranially: lies below the midclavicle, in proximity to the vascular structures

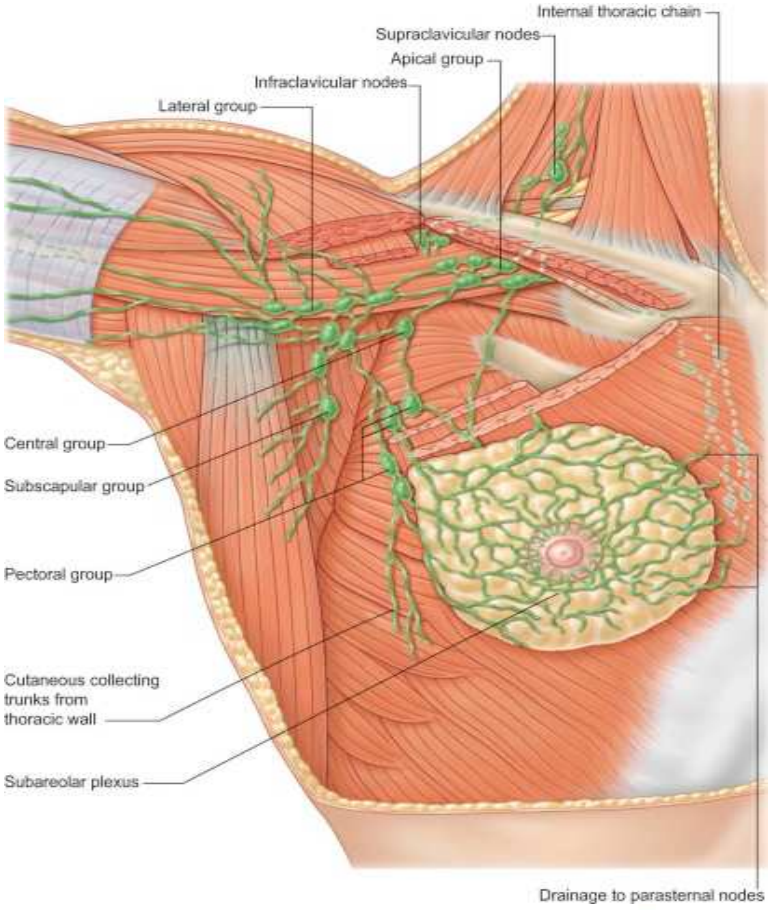

Shares EW (2104) Anatomical variations of the axilla. SpringerPlus 3 (1) 305

ESTRO School

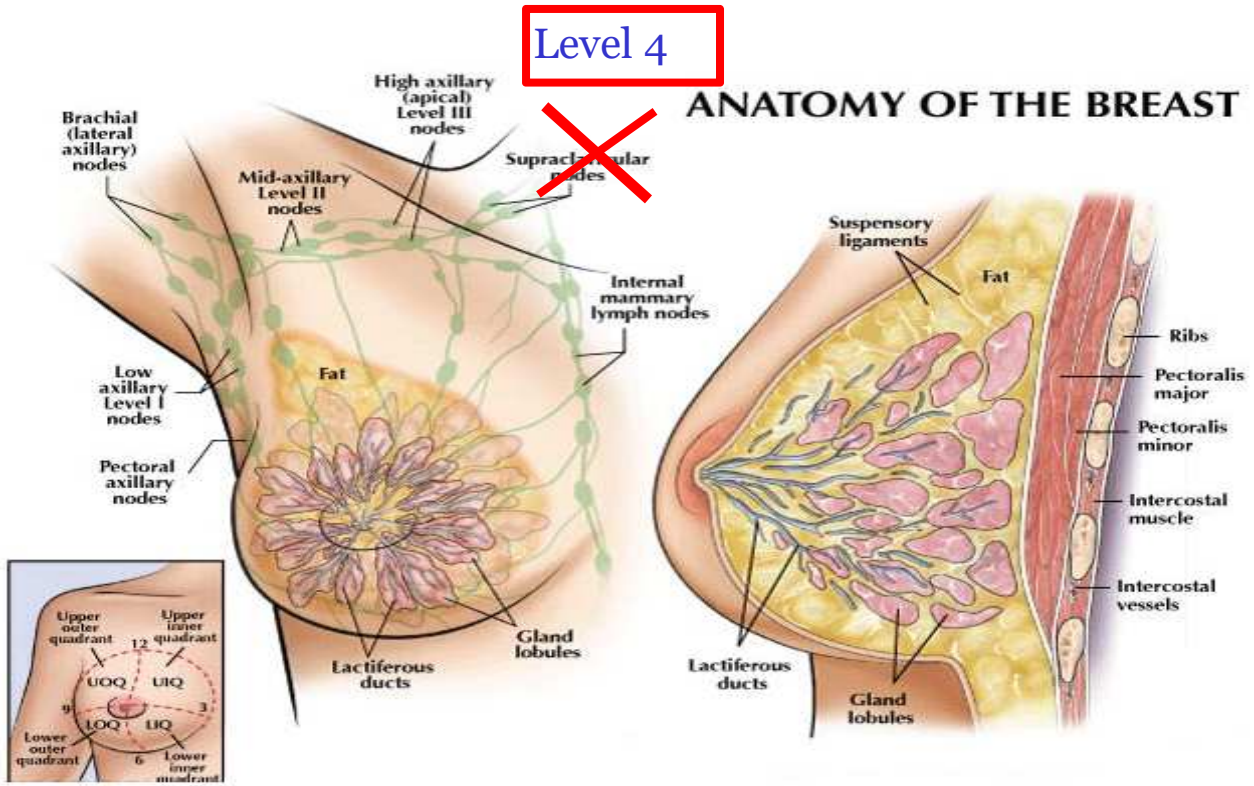

Patients with advanced disease are also at risk for involvement of Rotter's (interpectoral) nodes.

ESTRO School

BREAST ANATOMY

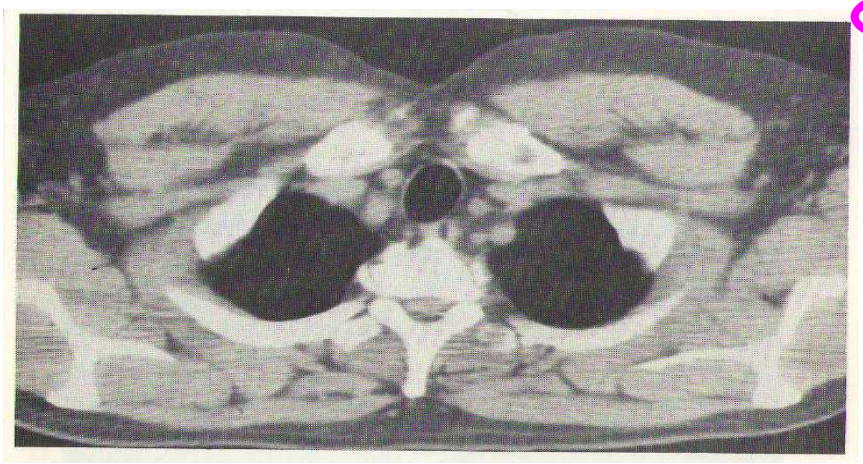

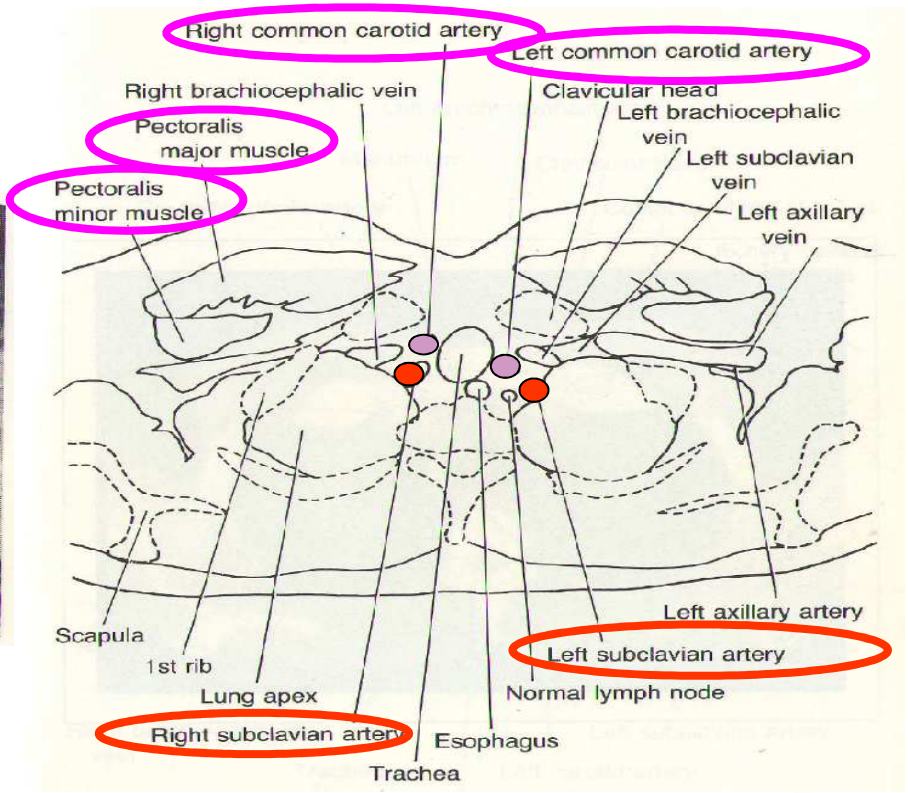

Pocket Atlas of Normal CT Anatomy. JB Weinstein

ESTRO School

BREAST ANATOMY

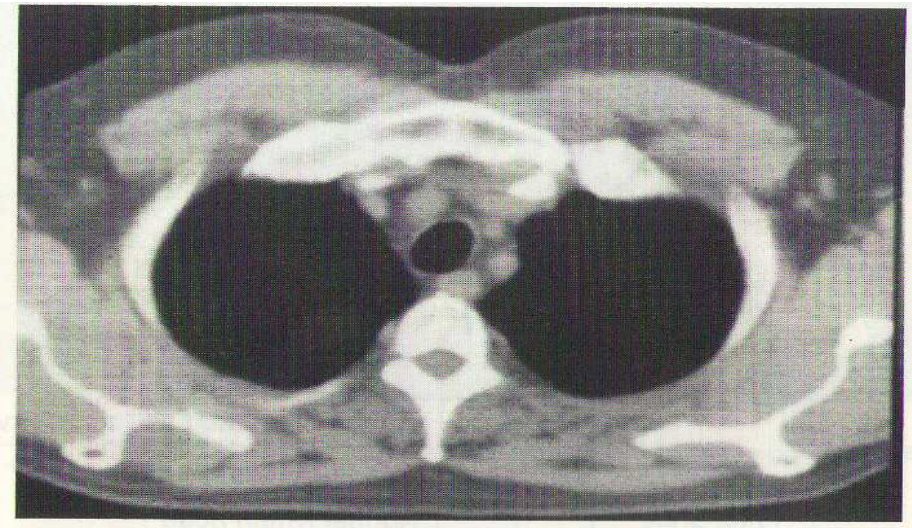

Pocket Atlas of Normal CT Anatomy. JB Weinstein

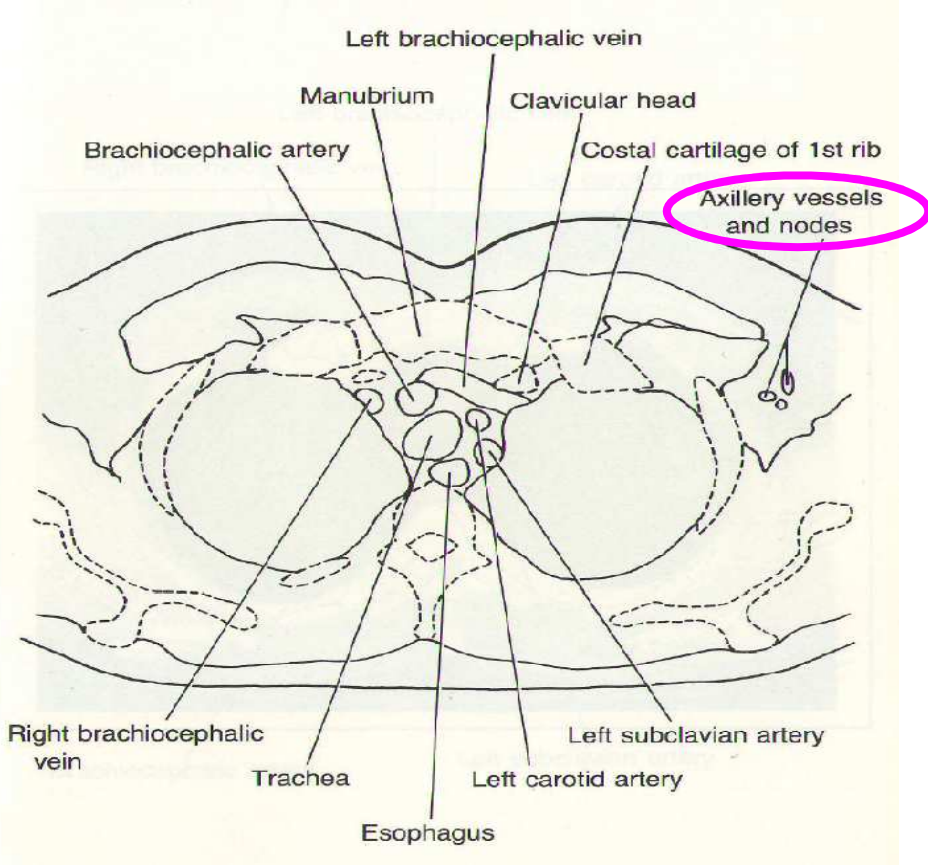

Classical boundaries of breast

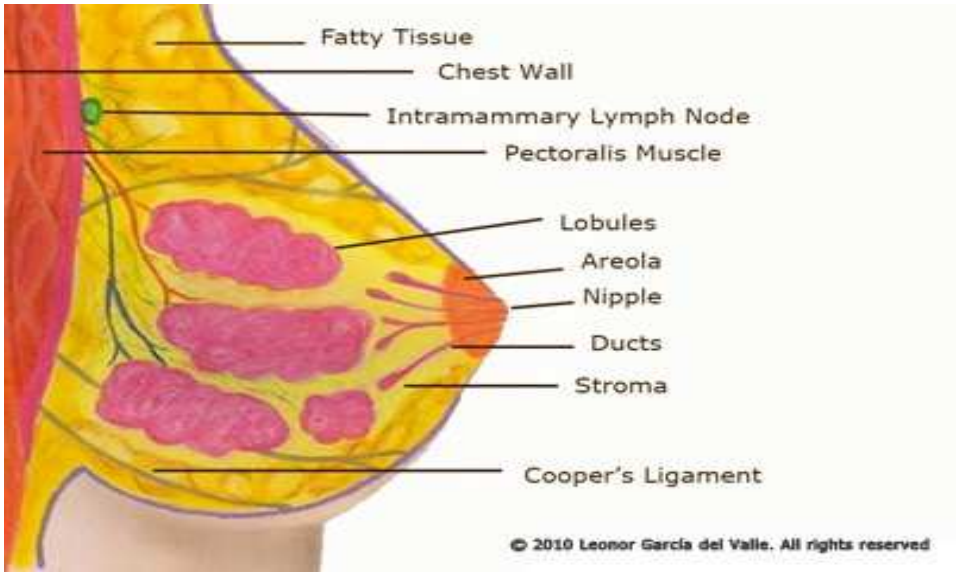

Limits:

2nd costal arch
6th-7th rib cartilage
Anterior axillary line
Mid-line sternal border

ESTRO School

Breast delineation guidelines

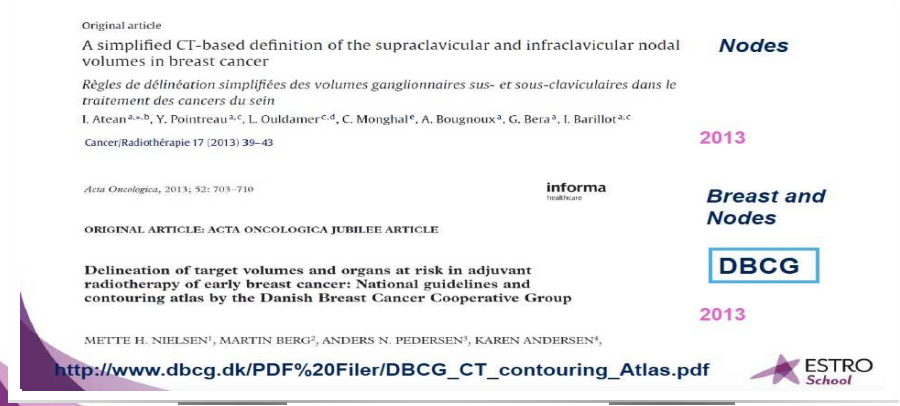

ESTRO School

We’re attending an ESTRO course… isn’t it?

ESTRO

Breast and Nodes

2015

Radiotherapy and Oncology 114 (2015) 3–10

Contents lists available at ScienceDirect

Radiotherapy and Oncology

journal homepage: www.thegreenjournal.com

ESTRO consensus guidelines

ESTRO consensus guideline on target volume delineation for elective radiation therapy of early stage breast cancer

Birgitte V. Offersen [a,*], Liesbeth J. Boersma [b], Carine Kirkove [c], Sandra Hol [d], Marianne C. Aznar [e], Albert Biete Sola [f], Youlia M. Kirova [g], Jean-Philippe Pignol [h], Vincent Remouchamps [i], Karolien Verhoeven [j], Caroline Weltens [j], Meritxell Arenas [k], Dorota Gabrys [l], Neil Kopek [m], Mechthild Krause [n], Dan Lundstedt [o], Tanja Marinko [p], Angel Montero [q], John Yarnold [r], Philip Poortmans [s]

2016

Contents lists available at ScienceDirect

Radiotherapy and Oncology

journal homepage: www.thegreenjournal.com

Letter to the Editor

ESTRO consensus guideline on target volume delineation for elective radiation therapy of early stage breast cancer, version 1.1 ☆

ESTRO School

ESTRO School

ESTRO CONSENSUS


Radiotherapy and Oncology 118 (2016) 205–208

Contents lists available at ScienceDirect

Radiotherapy and Oncology

journal homepage: www.thegreenjournal.com

ESTRO breast cancer consensus guidelines

ESTRO consensus guideline on target volume delineation for elective radiation therapy of early stage breast cancer, version 1.1

To the Editor,

One year ago we presented the ESTRO consensus guideline on target volume delineation for elective radiation therapy of early stage breast cancer [1]. We hereby present an update following the need for modification of the caudal part of CTVn_L4 and the lateral border of CTVn_IMN in the published pdf-files. Also, as a consequence of frequent questions, we provide more information regarding the lateral border of the CTVp_breast and for dose planning in relation to the humeral joint.

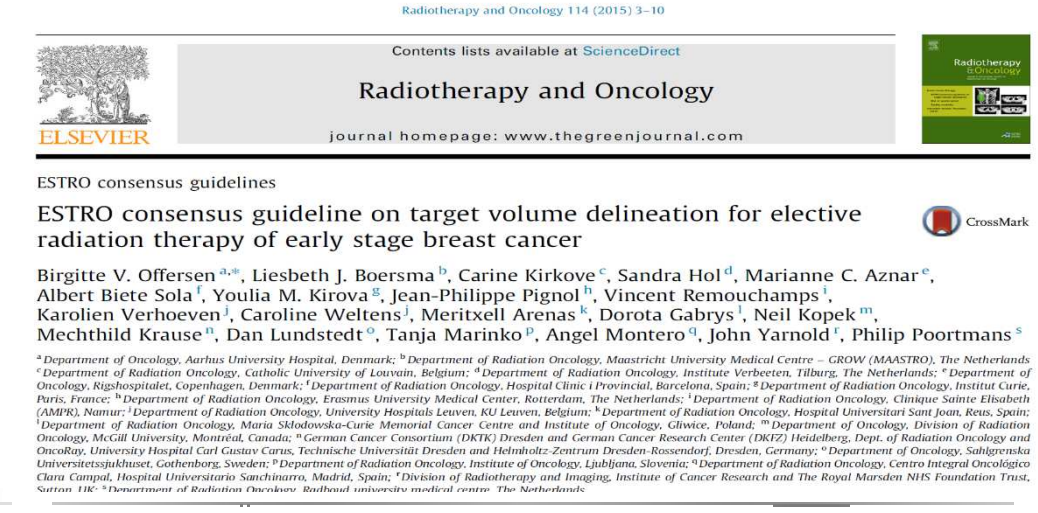
Radiotherapy and Oncology 114 (2015) 3–10

Contents lists available at ScienceDirect

Radiotherapy and Oncology

journal homepage: www.thegreenjournal.com

ESTRO consensus guidelines

ESTRO consensus guideline on target volume delineation for elective radiation therapy of early stage breast cancer

Birgitte V. Offersen [a,*], Liesbeth J. Boersma [b], Carine Kirkove [c], Sandra Hol [d], Marianne C. Aznar [e], Albert Biete Sola [f], Youlia M. Kirova [g], Jean-Philippe Pignol [h], Vincent Remouchamps [i], Karolien Verhoeven [j], Caroline Weltens [j], Meritxell Arenas [k], Dorota Gabrys [l], Neil Kopek [m], Mechthild Krause [n], Dan Lundstedt [o], Tanja Marinko [p], Angel Montero [q], John Yarnold [r], Philip Poortmans [s]

[a] Department of Oncology, Aarhus University Hospital, Denmark; [b] Department of Radiation Oncology, Maastricht University Medical Centre – GROW (MAASTRO), The Netherlands; [c] Department of Radiation Oncology, Catholic University of Louvain, Belgium; [d] Department of Radiation Oncology, Institute Verbeeten, Tilburg, The Netherlands; [e] Department of Oncology, Rigshospitalet, Copenhagen, Denmark; [f] Department of Radiation Oncology, Hospital Clinic i Provincial, Barcelona, Spain; [g] Department of Radiation Oncology, Institut Curie, Paris, France; [h] Department of Radiation Oncology, Erasmus University Medical Center, Rotterdam, The Netherlands; [i] Department of Radiation Oncology, Clinique Sainte Elisabeth (AMPR), Namur; [j] Department of Radiation Oncology, University Hospitals Leuven, KU Leuven, Belgium; [k] Department of Radiation Oncology, Hospital Universitari Sant Joan, Reus, Spain; [l] Department of Radiation Oncology, Maria Sklodowska-Curie Memorial Cancer Centre and Institute of Oncology, Gliwice, Poland; [m] Department of Oncology, Division of Radiation Oncology, McGill University, Montréal, Canada; [n] German Cancer Consortium (DKTK) Dresden and German Cancer Research Center (DKFZ) Heidelberg, Dept. of Radiation Oncology and OncoRay, University Hospital Carl Gustav Carus, Technische Universität Dresden and Helmholtz-Zentrum Dresden-Rossendorf, Dresden, Germany; [o] Department of Oncology, Sahlgrenska Universitetssjukhuset, Gothenborg, Sweden; [p] Department of Radiation Oncology, Institute of Oncology, Ljubljana, Slovenia; [q] Department of Radiation Oncology, Centro Integral Oncológico Clara Campal, Hospital Universitario Sanchinarro, Madrid, Spain; [r] Division of Radiotherapy and Imaging, Institute of Cancer Research and The Royal Marsden NHS Foundation Trust, Sutton, UK; [s] Department of Radiation Oncology, Radboud university medical centre, The Netherlands

- Done by ESTRO teachers in 2015. Updated in 2016 (v1.1)
- Purpose for Santanam nomenclature (CTVp_breast; CTVp_thoracic wall…)
- Patient simulated in the supine position in a breast board, with abducted arms, and straight head
- Free breathing CT at 2.5mm thick
- Radiopaque wires (not necessarily representing the borders of the CTV)

ESTRO School

- Introduction
- **CTV:**
  - **Post-lumpectomy intact breast**
  - Chestwall
  - Boost
  - Nodes
    - L1, L2, L3, L4, IM, Rotter
- Organs at risk
- Margins: CTV to PTV and OAR to PRV
- Conclusions

ESTRO School

“COLOR CODE”

RTOG

ESTRO

DBCG

PROCAB

ESTRO School

CTV: BREAST

After conservative surgery, CTV of the entire breast should be considered unless the patient is a candidate for partial breast irradiation

It may be useful to mark the scar

It may be useful to mark lateral, lower and upper limits

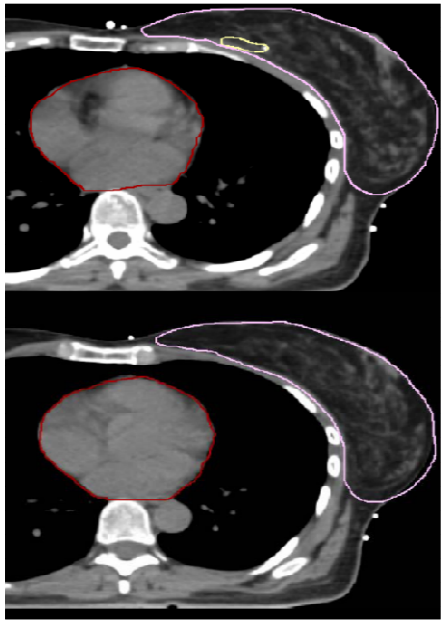

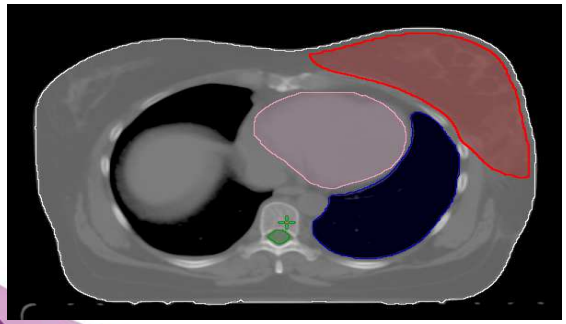

Volume between pectoralis major muscle and 5 mm below the skin

ESTRO School

Cranial	Residual breast CTVp_breast	Maximal to the caudal edge of the sterno-clavicular-junction
Clinical Reference + Second rib insertion[a]	Upper border of palpable/ visible breast tissue; maximally up to the inferior edge of the sterno-clavicular joint	

RTOG ESTRO DBCG

The cranial boundary is highly variable and depends on the size of the breast and its ptosis.

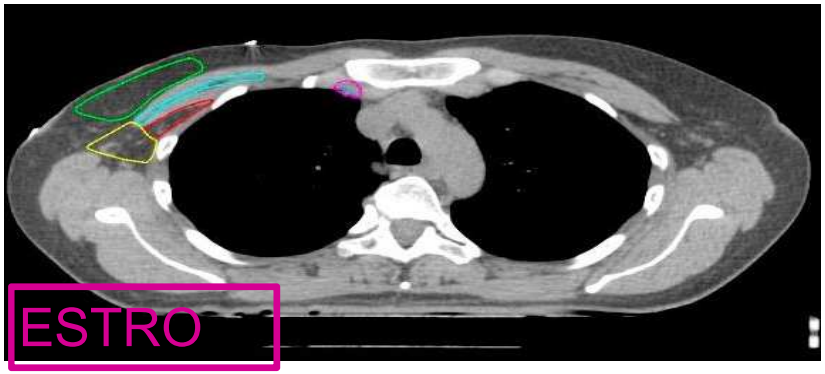

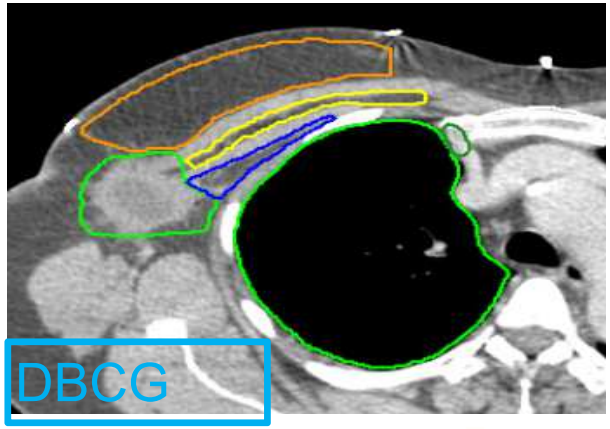

ESTRO School

Caudal

Clinical reference + loss of CT apparent breast

Most caudal CT slice with visible breast

The intermammary sulcus

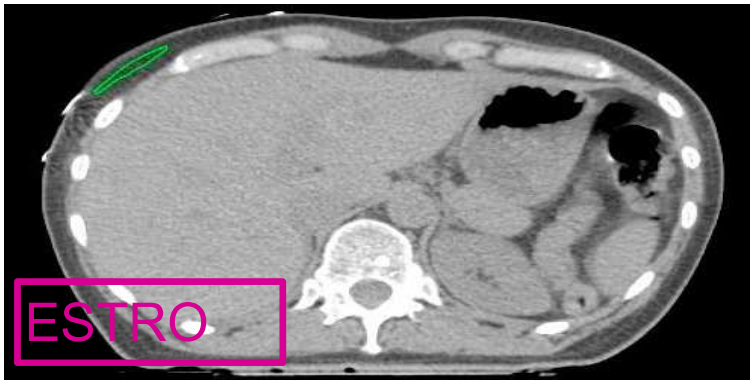

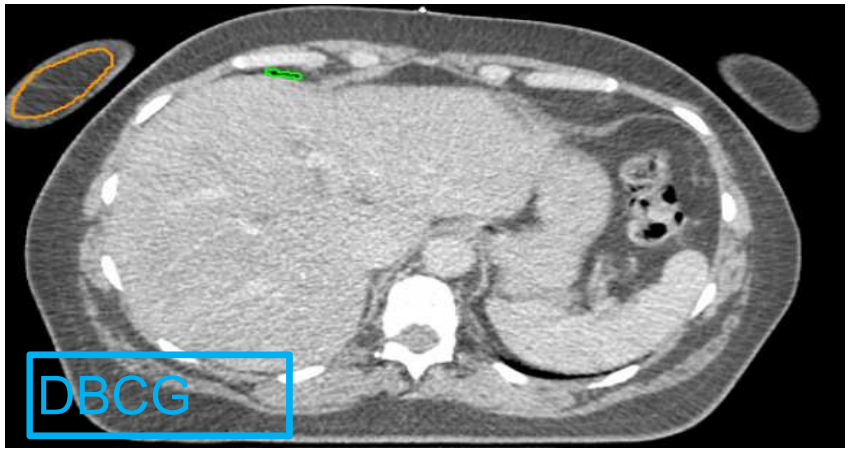

ESTRO School

Anterior

Skin

5 mm under skin surface

5 mm below the skin

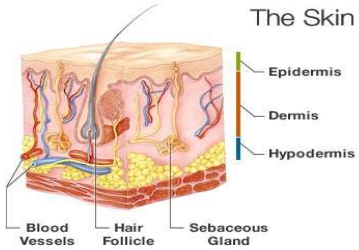

Creating an automatic internal contour can be helpful

RTOG: Skin
ESTRO, DBCG: 5 mm under the skin

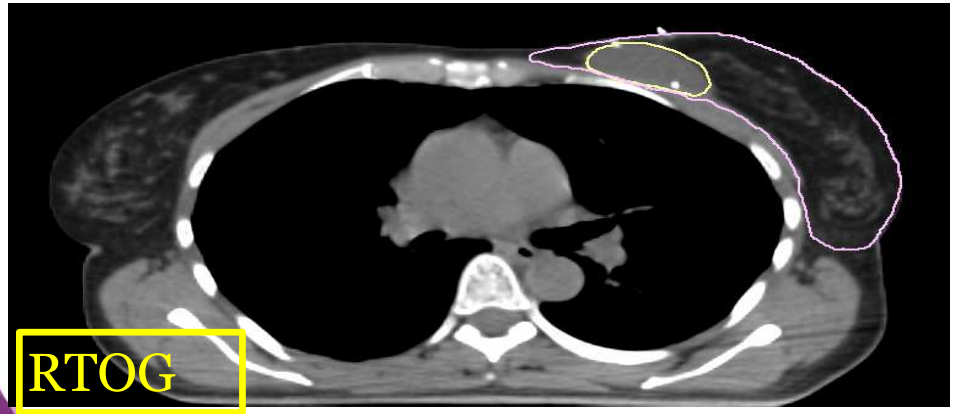

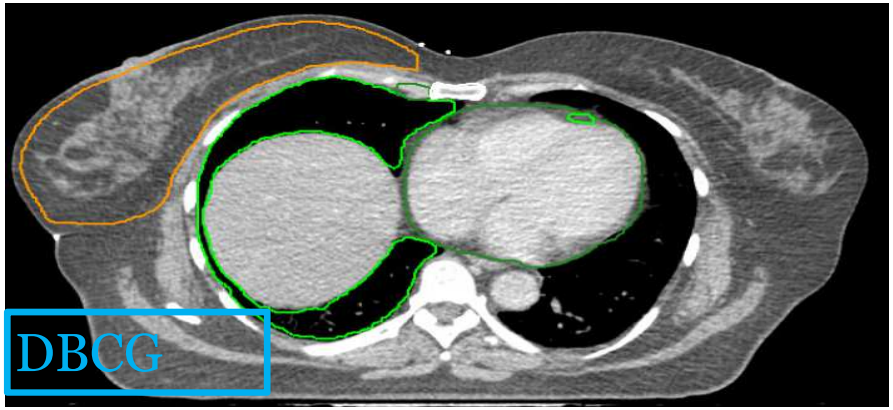

ESTRO School

Posterior	Major pectoral muscle or costae and intercostal muscles where no muscle
Excludes pectoralis muscles, chestwall muscles, ribs	

M. pectoralis major

Some authors recommend including part of the pectoralis major because sometimes there are deep extensions of the breast parenchyma that penetrate the surface portion of it

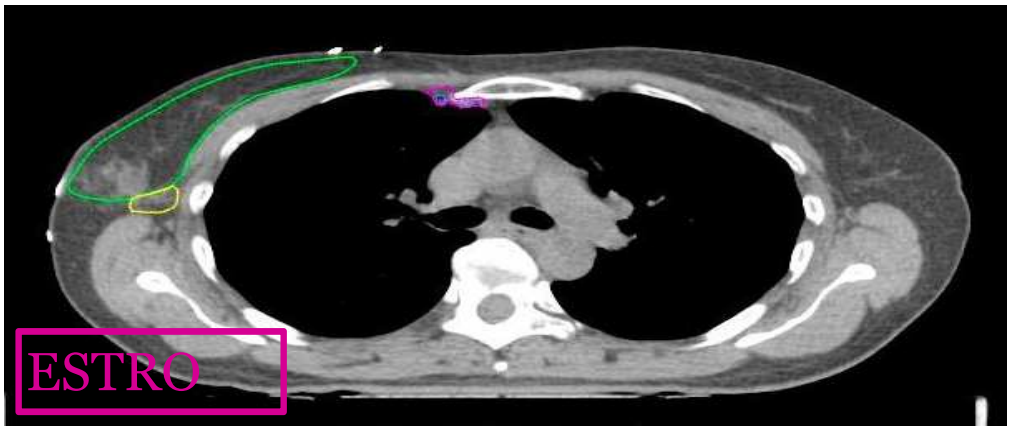

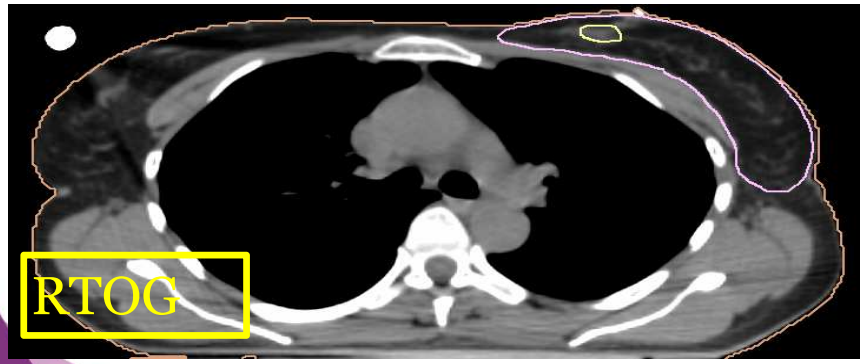

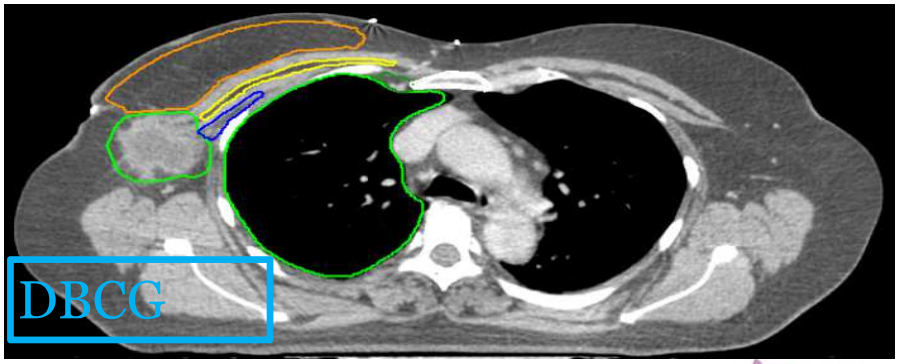

ESTRO School

Lateral
Clinical Reference + mid axillary line typically, excludes latissimus (Lat.) dorsi m. b

Lateral breast fold; anterior to the lateral thoracic artery

The axillary vessels (branches from the lateral thoracic vessel)

The lateral boundary is highly variable and depends on the size of the breast and its ptosis.

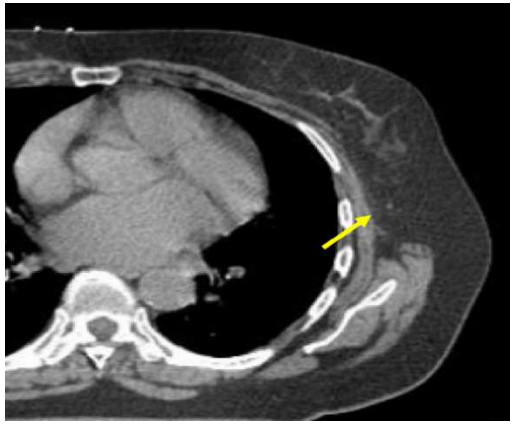

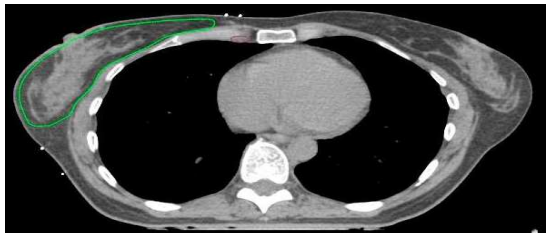

ESTRO

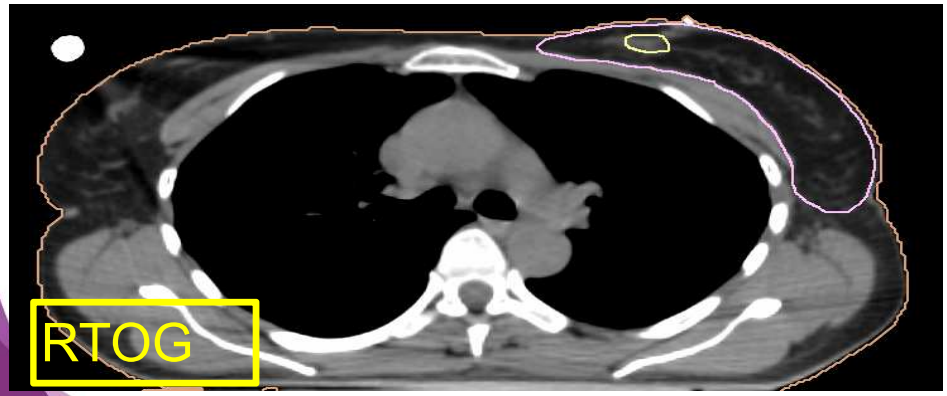

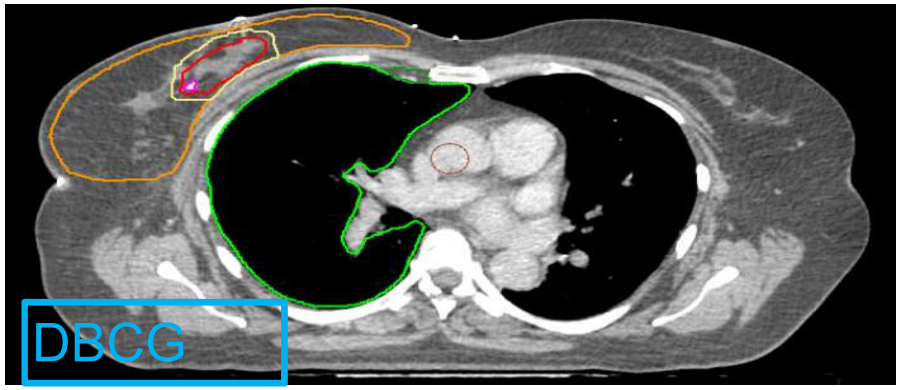

ESTRO School

V1.1 of ESTRO guidelines:

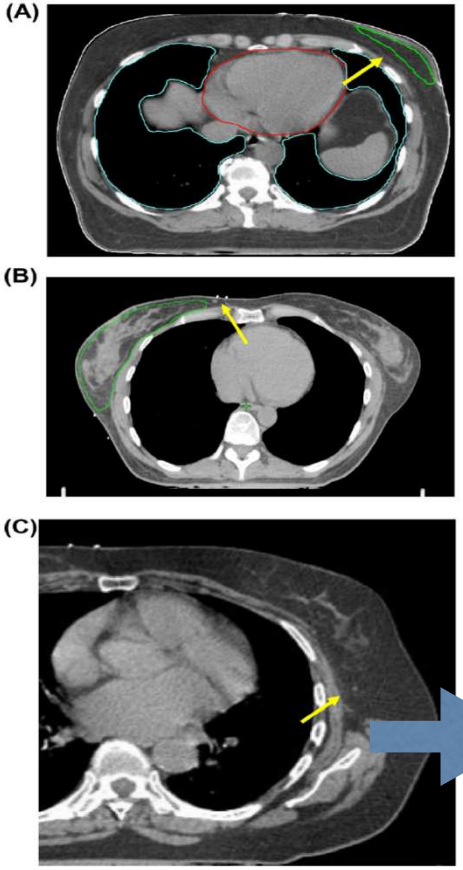

Fig. 3. (A) In relatively obese patients the CTVp_breast is positioned more ventrally in the caudal part of the breast due to fatty tissue. (B) It is often possible to identify medial mammary branches of the internal thoracic artery, and the CTVp_breast is positioned lateral to these vessels. (C) Arrow points at the lateral thoracic artery.

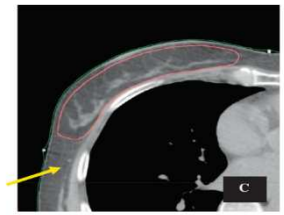

Fig. 1C. Arrow indicates the lateral thoracic vessel at a distance from the delineated CTVp_breast.

- **CRANIAL:** the caudal edge of the sternoclavicular joint as maximum
- **CAUDAL**: breast shape still visible
- **ANTERIOR:** 5mm under skin, except for T4b-d
- **POSTERIOR:** ventral side of the major pectoral muscle or ribs/intercostal muscles. In the caudal part, exclude the subcutaneous fat from the abdominal wall.
- **LATERAL**: visible glandular tissue. **The thoracic vessels can be helpful, but not imperative to include.**
- **MEDIAL**: lateral to medial mamary branches (if visible), maximally to the ipsilateral

ESTRO School

Medial	Lateral to the medial perforating mammarian vessels; maximally to the edge of the sternal bone	Maximal to the ipsilateral edge of sternum
Sternal-rib junction [c]		

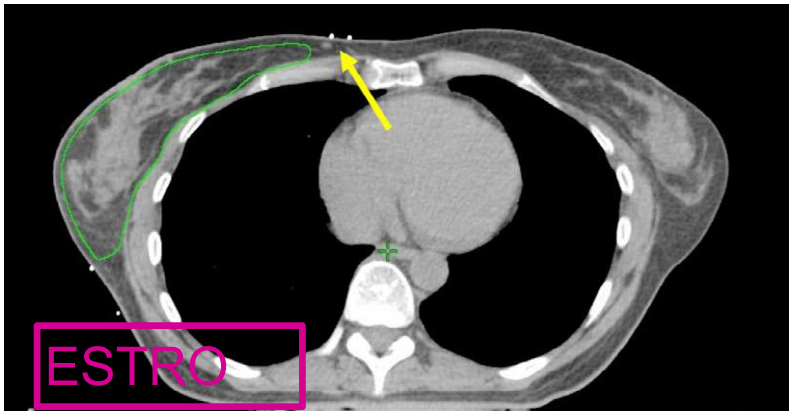

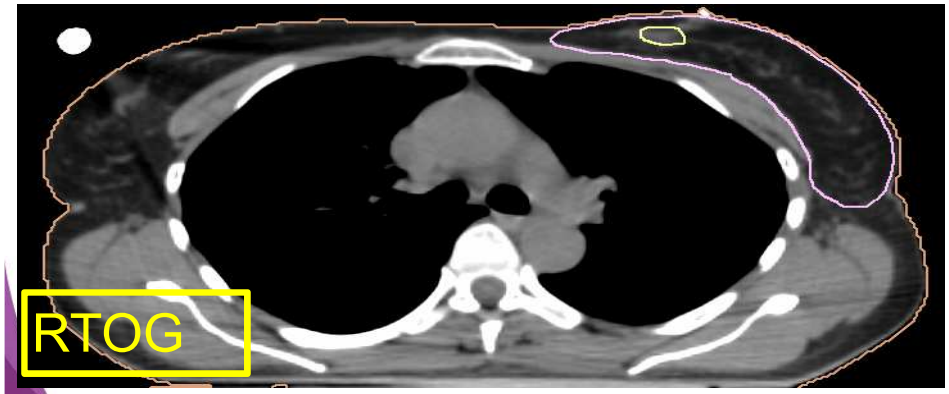

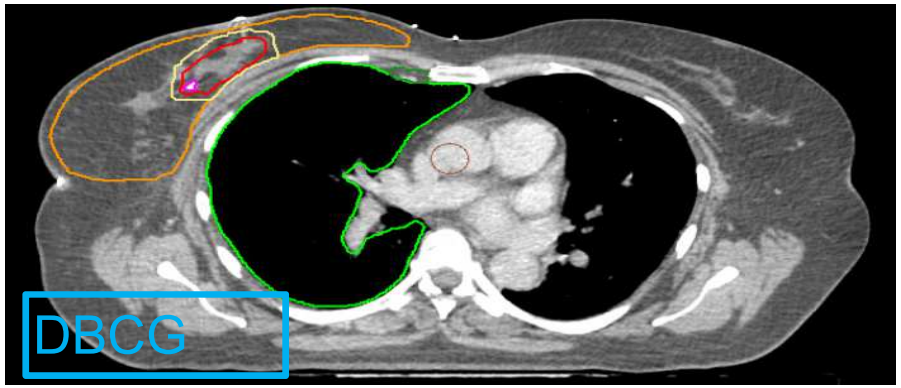

ESTRO School

CTV: CONSERVATIVE SURGERY AFTER PRIMARY SYSTEMIC TRATMENT

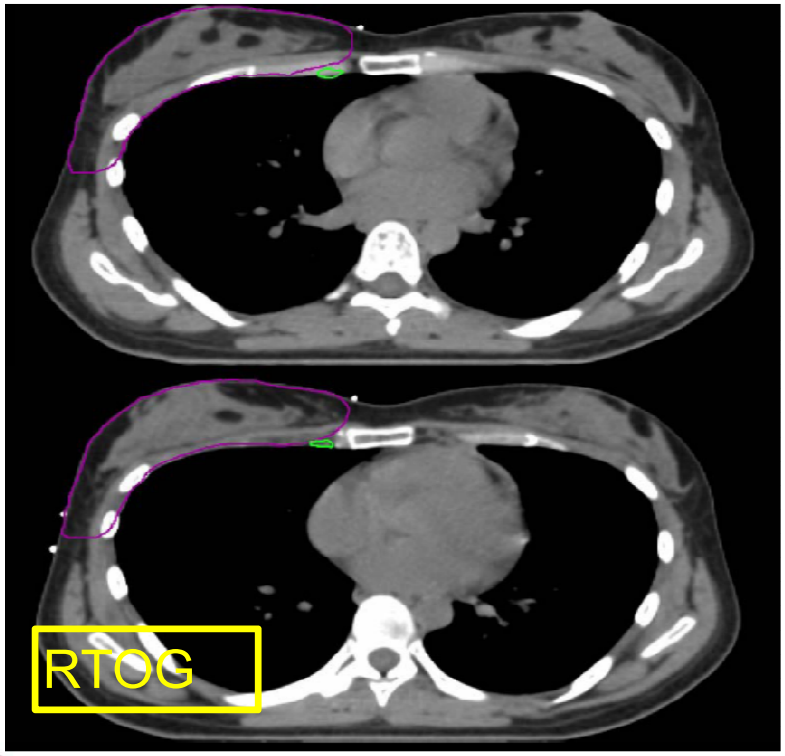

Only one difference

Posterior:

Includes pectoralis muscles, chestwall muscles, ribs

ESTRO School

- Introduction
- **CTV:**
  - Post-lumpectomy intact breast
  - **Chestwall**
  - Boost
  - Nodes
    - L1, L2, L3, L4, IM, Rotter
- Organs at risk
- Margins: CTV to PTV and OAR to PRV
- Conclusions

ESTRO School

CHEST WALL CTV

It might be useful to mark the scar

It might be useful to mark the medial, lateral and inferior limit (reference: contralateral breast)

Include all the scar whenever possible

ESTRO School

Craneal

Caudal border of the clavicle head

Guided by palpable/visible signs; if appropriate guided by the contralateral breast; maximally up to the inferior edge of the sterno-clavicular joint

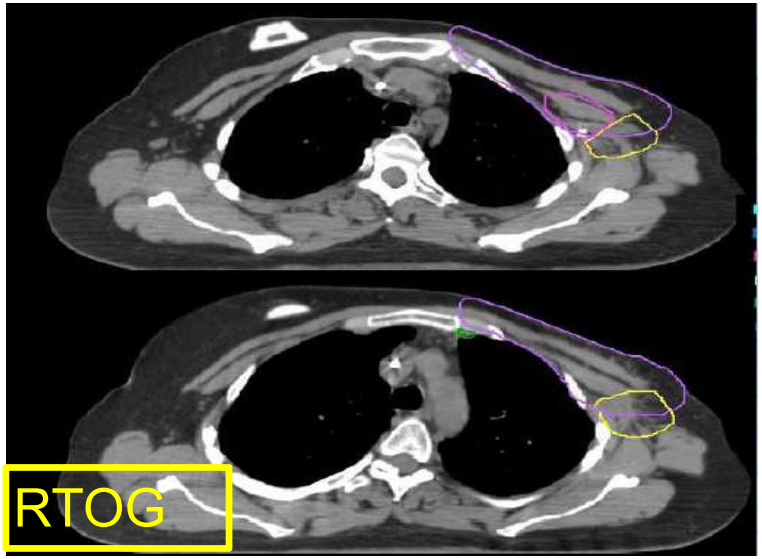

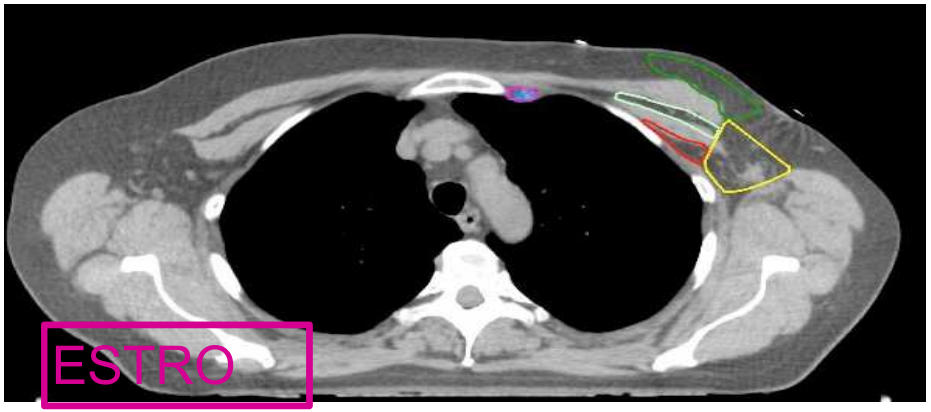

Equal to a CTV-breast guided by the contralateral breast

ESTRO School

Caudal

Clinical reference+ loss of CT apparent contralateral breast

Guided by palpable/visible signs; if appropriate guided by the contralateral breast

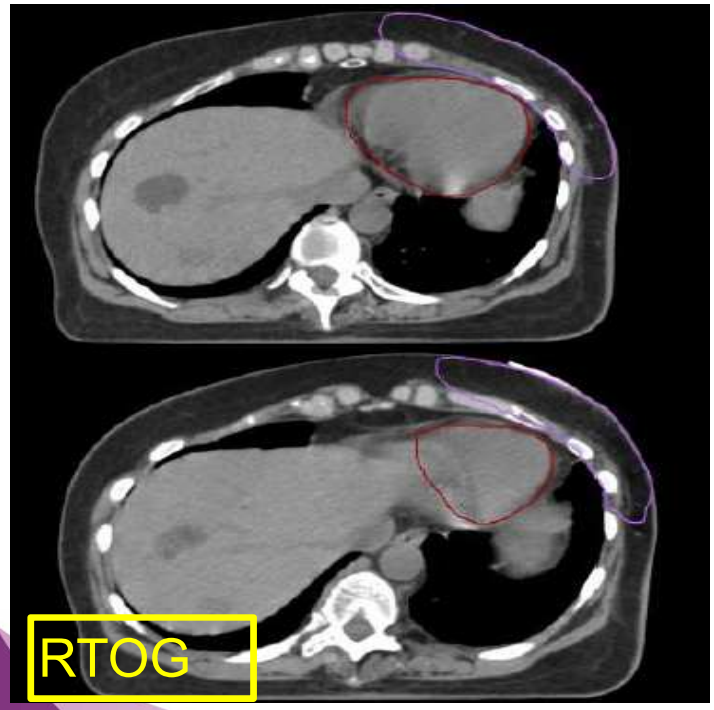

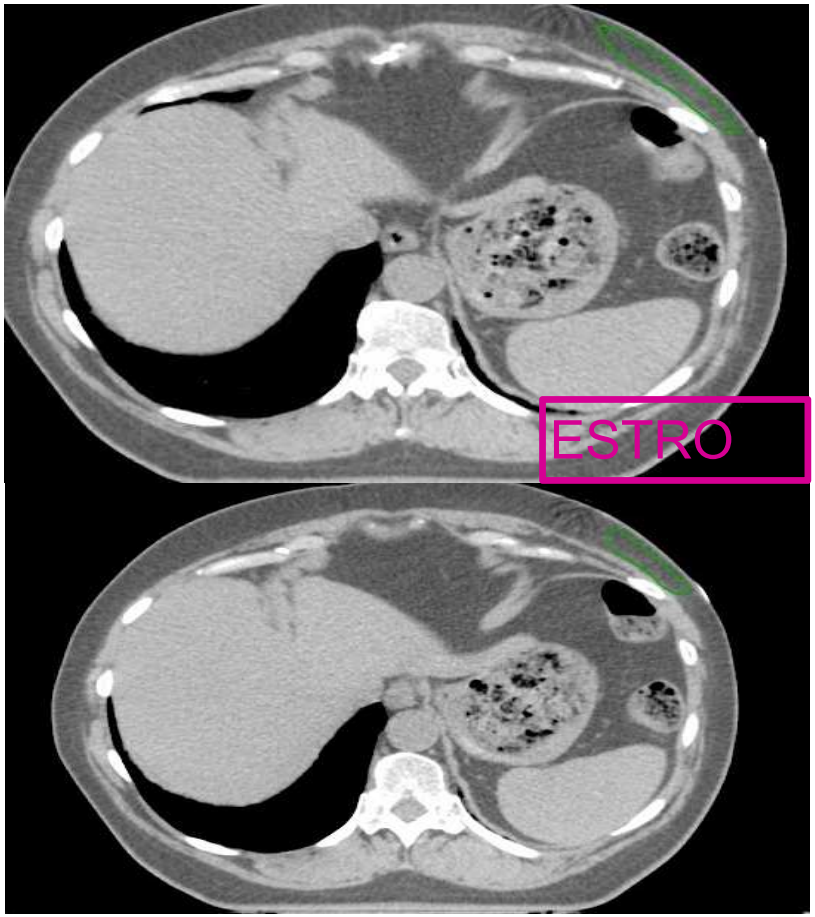

ESTRO School

5 mm under skin surface

In case of a thin thoracic wall, omission of the first 5 mm under the skin may result in no CTV at all. In that case, the CTV should be extended into the skin.

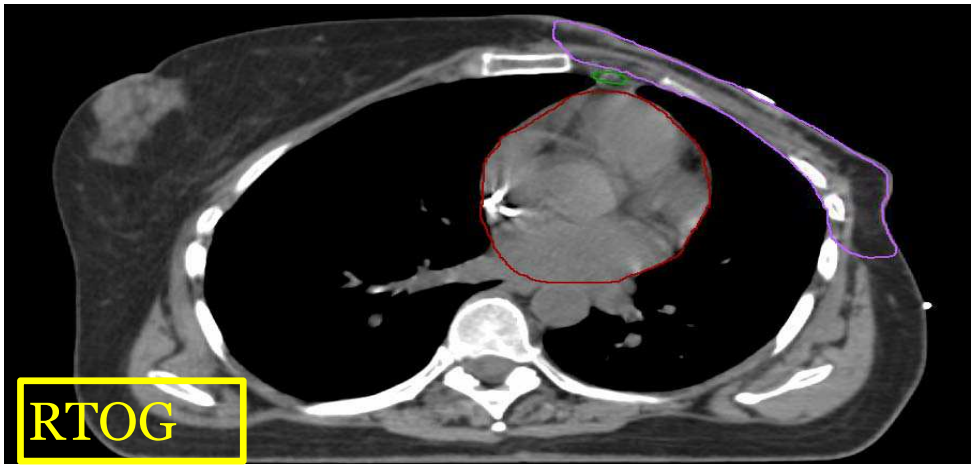

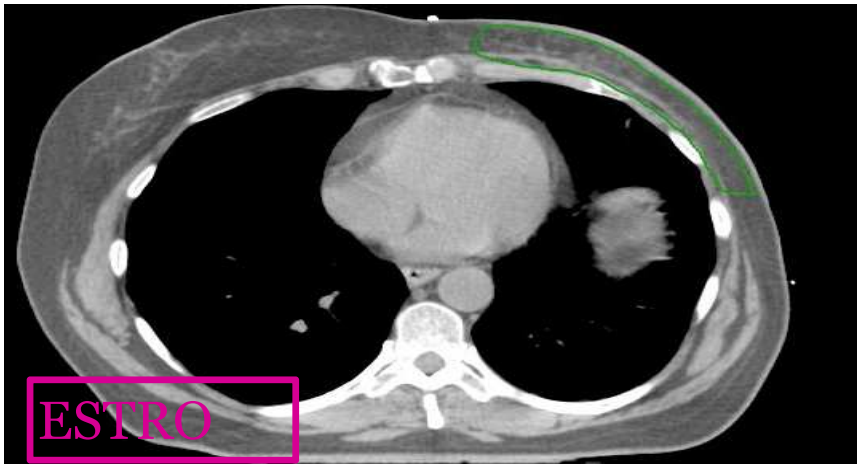

RTOG: Skin
ESTRO: 5 mm under the skin

ESTRO School

Posterior
Rib-pleural interface. (Includes pectoralis muscles, chestwall muscles, ribs)

Major pectoral muscle or costae and intercostal muscles where no muscle

The deep fascia and the pectoralis ms are anatomical barriers.

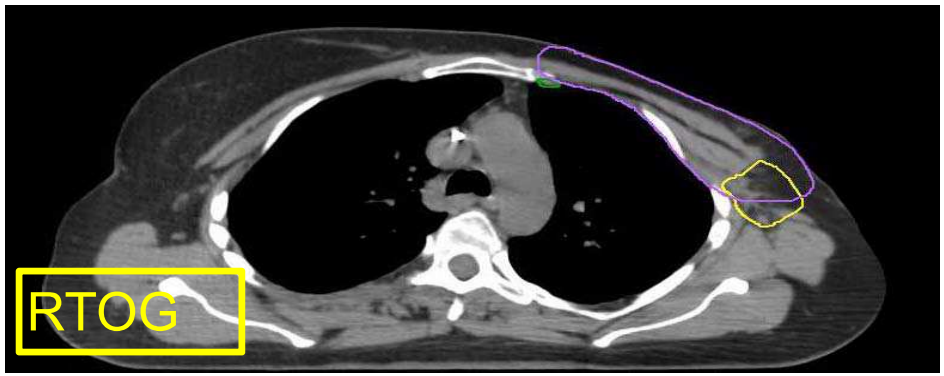

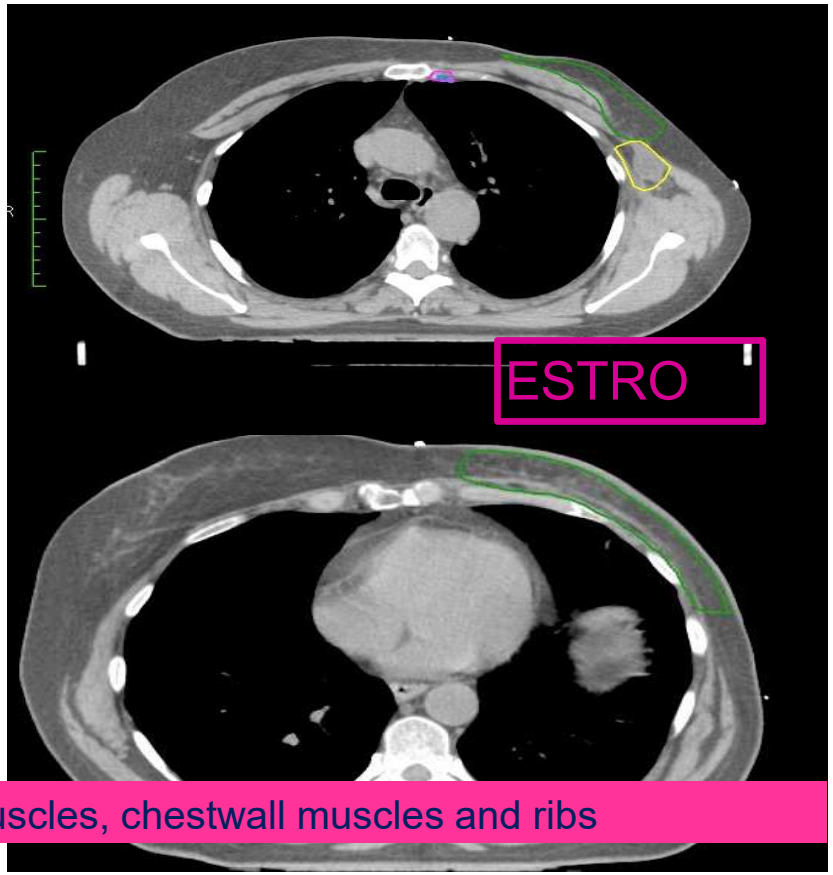

ESTRO recomendations: do not include pectoralis muscles, chestwall muscles and ribs

ESTRO School

RTOG published some studies about RTOG atlas in September 2015 Red Journal

International Journal of Radiation Oncology biology • physics
www.redjournal.org

BRIEF REPORT

RTOG Chest Wall Contouring Guidelines for Post-Mastectomy Radiation Therapy: Is It Evidence-Based?

John A. Vargo, MD, and Sushil Beriwal, MD

Department of Radiation Oncology, University of Pittsburgh Cancer Institute, Pittsburgh, Pennsylvania

Received Aug 12, 2014, and in revised form Feb 2, 2015. Accepted for publication Mar 2, 2015.

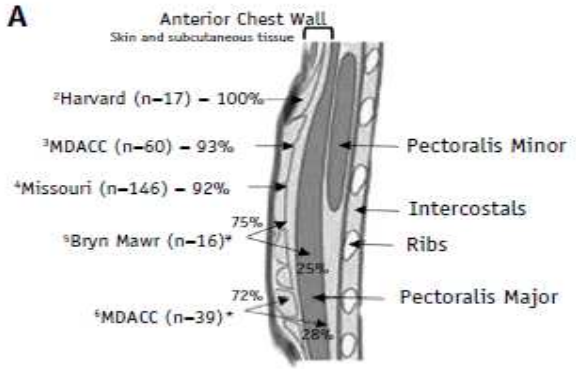

They recomend changing posterior boundary of chest wall CTV: Subcutaneous tissue and pectoralis musculature may be warranted.

But: Not including ribs and intercostal muscles.

Medial	Sternal-rib junction [b]	Guided by palpable/visible signs; if appropriate guided by the contralateral breast
Lateral	Clinical Reference/ mid axillary line typically, excludes lattismus dorsi m [a]	Guided by palpable/visible signs; if appropriate guided by the contralateral breast. Usually anterior to the mid-axillary line

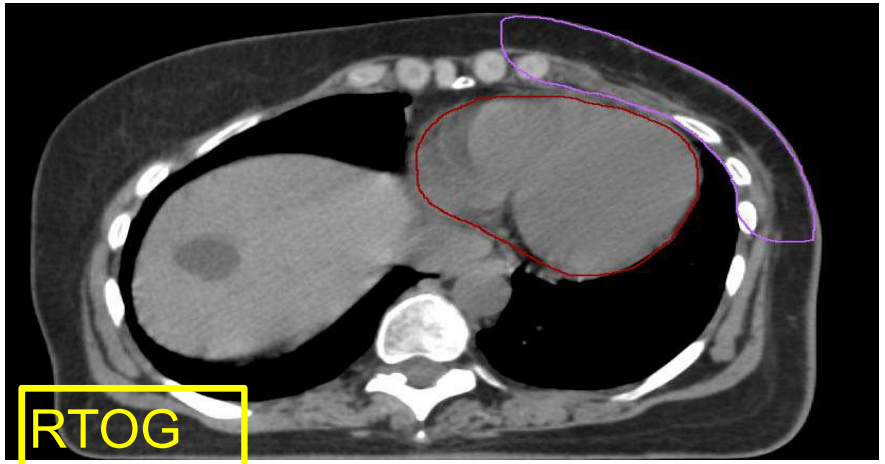

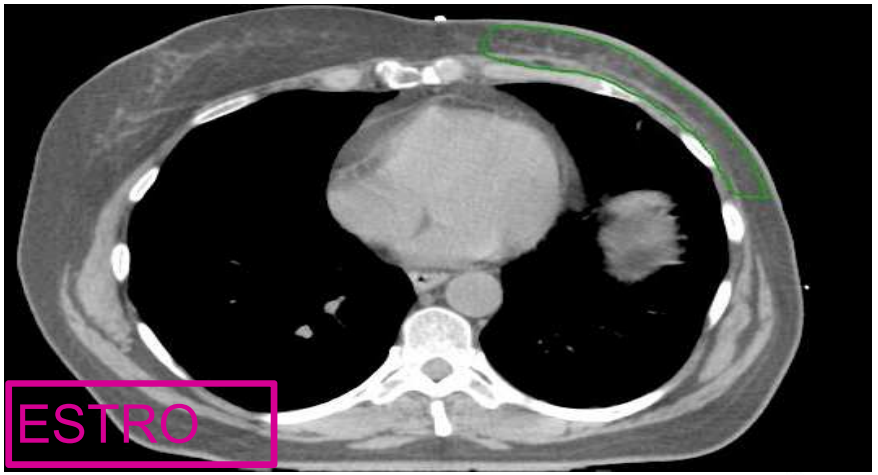

ESTRO School

- Introduction
- **CTV:**
  - Post-lumpectomy intact breast
  - Chestwall
  - **Boost**
  - Nodes
    - L1, L2, L3, L4, IM, Rotter
- Organs at risk and constraints
- Margins: CTV to PTV and OAR to PRV
- Conclusions

ESTRO School

BOOST CTV: INDICATIONS

Boost tumour bed reduces local relapse (benefit in all ages), but has no impact on the DFS.

2 randomized trials confirm it:

Lyon trial
EORTC trial

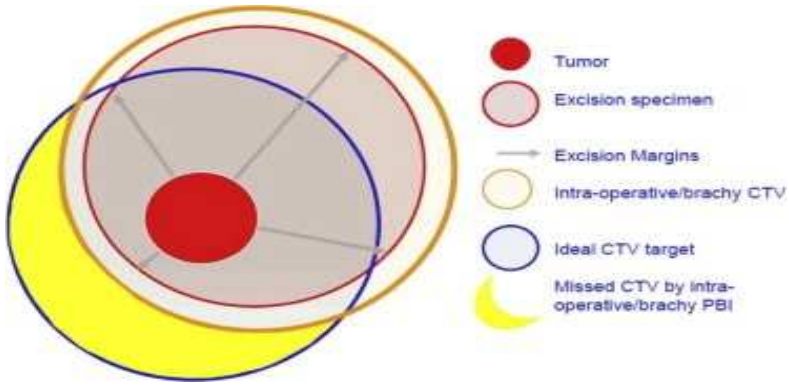

ESTRO School

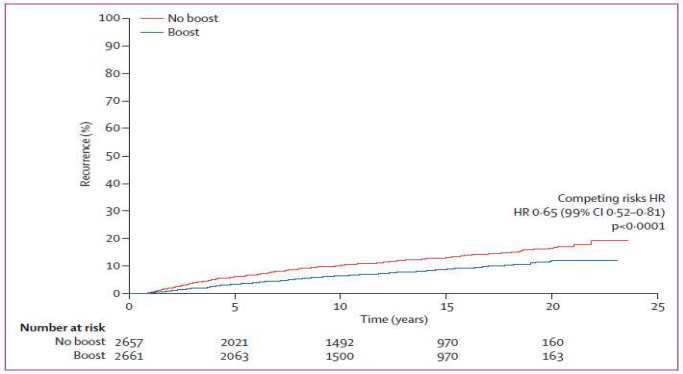

± Boost – EORTC Trial

Bartelink H, Lancet Oncol 2015; 16:47-56

Follow up: 20y

N = 4.318

Age	Gain (LR)
≤40	**11.6%**
41-50	5.9%
51-60	2.9%
>60	3%

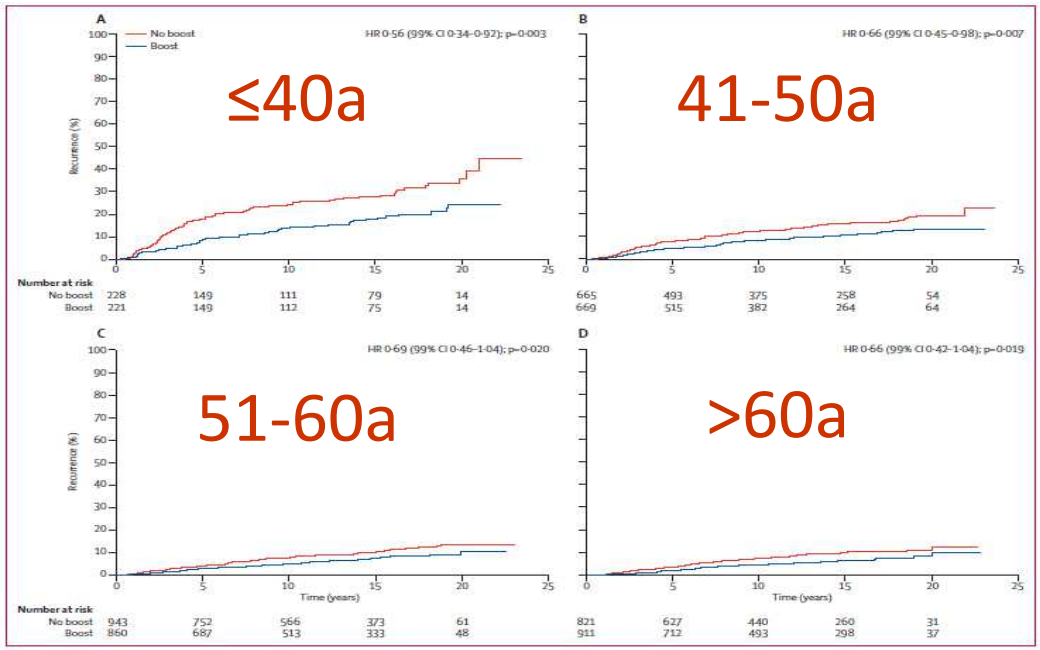

ESTRO School

The tumor bed: very important for PBI !

Radiotherapy and Oncology 108 (2013) 181–189

Contents lists available at SciVerse ScienceDirect

Radiotherapy and Oncology

journal homepage: www.thegreenjournal.com

Systematic review

Tumor bed delineation for external beam accelerated partial breast irradiation: A systematic review

T. Jonathan Yang [a], Randa Tao [b], Paula H.M. Elkhuizen [c], Corine van Vliet-Vroegindeweij [c], Guang Li [d,*], Simon N. Powell [a]

[a] Department of Radiation Oncology, Memorial Sloan-Kettering Cancer Center, New York, United States; [b] Department of Radiation Oncology, The University of Texas MD Anderson Cancer Center, Houston, United States; [c] Department of Radiotherapy, The Netherlands Cancer Institute – Antoni van Leeuwenhoek Hospital, Amsterdam, The Netherlands; [d] Department of Medical Physics, Memorial Sloan-Kettering Cancer Center, New York, United States

ARTICLE INFO

Article history:
Received 5 October 2012
Received in revised form 12 May 2013
Accepted 12 May 2013
Available online 24 June 2013

Keywords:
Accelerated partial breast irradiation
Tumor delineation
External beam radiotherapy

ABSTRACT

In recent years, accelerated partial breast irradiation (APBI) has been considered an alternative to whole breast irradiation for patients undergoing breast-conserving therapy. APBI delivers higher doses of radiation in fewer fractions to the post-lumpectomy tumor bed with a 1–2 cm margin, targeting the area at the highest risk of local recurrence while sparing normal breast tissue. However, there are inherent challenges in defining accurate target volumes for APBI. Studies have shown that significant interobserver variation exists among radiation oncologists defining the lumpectomy cavity, which raises the question of how to improve the accuracy and consistency in the delineation of tumor bed volumes. The combination of standardized guidelines and surgical clips significantly improves an observer's ability in delineation, and it is the standard in multiple ongoing external-beam APBI trials. However, questions about the accuracy of the clips to mark the lumpectomy cavity remain, as clips only define a few points at the margin of the cavity. This paper reviews the techniques that have been developed so far to improve target delineation in APBI delivered by conformal external beam radiation therapy, including the use of standardized guidelines, surgical clips or fiducial markers, pre-operative computed tomography imaging, and additional imaging modalities, including magnetic resonance imaging, ultrasound imaging, and positron emission tomography/computed tomography. Alternatives to post-operative APBI, future directions, and clinical recommendations were also discussed.

© 2013 The Authors. Published by Elsevier Ireland Ltd. Radiotherapy and Oncology 108 (2013) 181–189

Open access under CC BY-NC-ND license.

- Surgical clips guide tumor bed delineation on CT
- Integrate MRI or US in addition to CT/surgical clips.
- The expansion of CTV to PTV varies (0.5– 1.5 cm).
- Tumor is often eccentric in a lumpectomy specimen: optimal margin?
- The seroma could also induce errors!

ESTRO School

BOOST CTV

Multiinstitutional study on target volume delineation variation in breast radiotherapy in the presence of guidelines

Anke M. van Mourik, Paula H.M. Elkhuizen, Danny Minkema, Joop C. Duppen,
On behalf of the Dutch Young Boost Study Group[1], Corine van Vliet-Vroegindeweij *

The Netherlands Cancer Institute, Amsterdam, The Netherlands

Radiotherapy and Oncology 94 (2010) 286–291

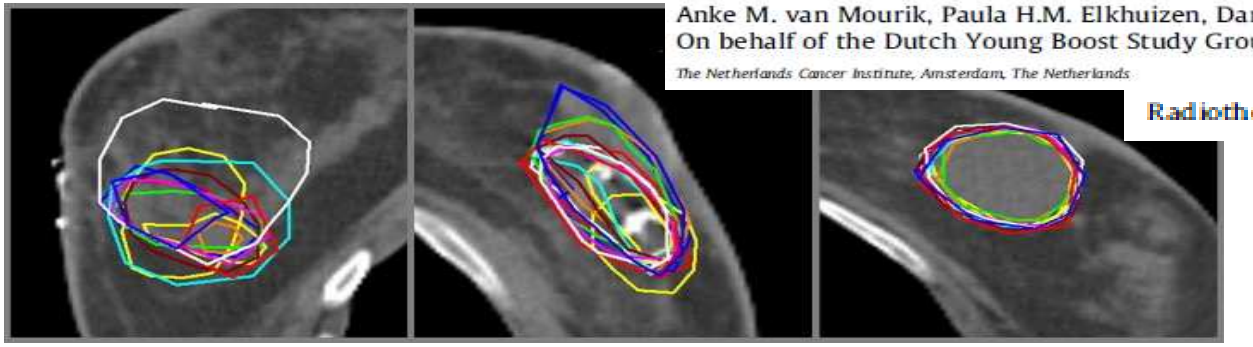

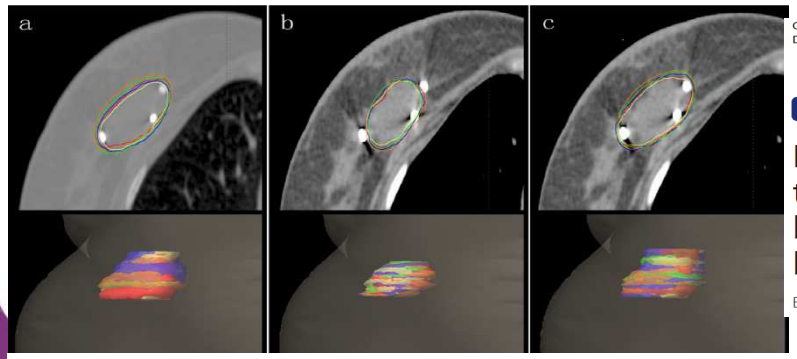

Guo et al. Radiation Oncology (2015) 10:66
DOI 10.1186/s13014-015-0370-3

RADIATION ONCOLOGY

RESEARCH Open Access

Interobserver variability in the delineation of the tumour bed using seroma and surgical clips based on 4DCT scan for external-beam partial breast irradiation

Bing Guo[1,2], Jianbin Li[1*], Wei Wang[1], Min Xu[1], Qian Shao[1], Yingjie Zhang[1], Chaoqian Liang[1] and Yanluan Guo[1,2]

Conclusions: When the SCS was 3 ~ 5 points and the number of surgical clips was ≥5, interobserver variability was minimal for the delineation of the tumour bed based on seroma.

ESTRO School

INDICATIONS FOR APBI

Practical Radiation Oncology (2017) 7, 73-79

pro
www.practicalradonc.org

Special Article

Accelerated Partial Breast Irradiation: Executive summary for the update of an ASTRO Evidence-Based Consensus Statement

Candace Correa MD [a], Eleanor E. Harris MD [b], Maria Cristina Leonardi MD [c], Benjamin D. Smith MD [d], Alphonse G. Taghian MD, PhD [e], Alastair M. Thompson MD [f], Julia White MD [g], Jay R. Harris MD [h,*]

[a]Department of Radiation Oncology, Faxton St. Luke's Healthcare, Utica, New York
[b]Department of Radiation Oncology, East Carolina University, Greenville, North Carolina
[c]Department of Radiation Oncology, European Institute of Oncology, Milan, Italy
[d]Department of Radiation Oncology, The University of Texas MD Anderson Cancer Center, Houston, Texas
[e]Department of Radiation Oncology, Massachusetts General Hospital, Boston, Massachusetts
[f]Department of Breast Surgical Oncology, The University of Texas MD Anderson Cancer Center, Houston, Texas
[g]Department of Radiation Oncology, Ohio State University Cancer Center, Columbus, Ohio
[h]Department of Radiation Oncology, Brigham and Women's Hospital and Dana-Farber Cancer Institute, Boston, Massachusetts

Received 18 August 2016; accepted 12 September 2016

Table 1 Comparison of patient groups in original and updated consensus statements

Patient group	Risk factor	Original	Update
Suitability	Age	≥60 y	≥50 y
	Margins	Negative by at least 2 mm	No change
	T stage	T1	Tis or T1
	DCIS	Not allowed	If all of the below: • Screen-detected • Low to intermediate nuclear grade • Size ≤2.5 cm • Resected with margins negative at ≥3 mm
Cautionary	Age	50-59 y	• 40-49 y if all other criteria for "suitable" are met • ≥50 y if patient has at least 1 of the pathologic factors below and does not have any "unsuitable" factors *Pathologic factors:* • Size 2.1-3.0 cm [a] • T2 • Close margins (<2 mm) • Limited/focal LVSI • ER(-) • Clinically unifocal with total size 2.1-3.0 cm [b] • Invasive lobular histology • Pure DCIS ≤3 cm if criteria for "suitable" not fully met • EIC ≤3 cm
	Margins	Close (<2 mm)	No change
	DCIS	≤3 cm	≤3 cm and does not meet criteria for "suitable"
Unsuitable	Age	<50 years	• <40 y • 40-49 y and do not meet the criteria for cautionary
	Margins	Positive	No change
	DCIS	>3 cm	No change

[a] The size of the invasive tumor component.
[b] Microscopic multifocality allowed, provided the lesion is clinically unifocal (a single discrete lesion by physical examination and ultrasonography/mammography) and the total lesion size (including foci of multifocality and intervening normal breast parenchyma) falls between 2.1 and 3.0 cm.

ESTRO School

INDICATIONS FOR PBI

Partial breast radiotherapy can be considered for patients ≥50 years, Grade 1–2, ≤3 cm, ER+, HER2-, N0 using either (i) external beam radiotherapy with 40 Gy in 15 fractions over three weeks or (ii) multicatheter brachytherapy using fractionation within GEC-ESTRO trial.

Statement + 2 millimetre (mm) minimum margins.	Very strongly supported
Statement + 1 mm minimum margins.	Strongly supported
Statement + classical lobular cancer should be excluded.	Strongly supported
Statement + lymphovascular space invasion.	Strongly supported

ESTRO School

WHAT CAN WE LEARN FORM GEC - ESTRO consensus?

Radiotherapy and Oncology 115 (2015) 342–348

Contents lists available at ScienceDirect

Radiotherapy and Oncology

journal homepage: www.thegreenjournal.com

GEC ESTRO Recommendations

Recommendations from GEC ESTRO Breast Cancer Working Group (I): Target definition and target delineation for accelerated or boost Partial Breast Irradiation using multicatheter interstitial brachytherapy after breast conserving closed cavity surgery

Vratislav Strnad [a,*], Jean-Michel Hannoun-Levi [b], Jose-Luis Guinot [c], Kristina Lössl [d], Daniela Kauer-Dorner [e], Alexandra Resch [e], György Kovács [f], Tibor Major [g], Erik Van Limbergen [h], On behalf of Working Group Breast Cancer of GEC-ESTRO

[a] Department of Radiation Oncology, University Hospital Erlangen, Germany; [b] Department of Radiation Oncology, Centre Antoine Lacassagne, Nice, France; [c] Department of Radiation Oncology, Fundación Instituto Valenciano de Oncología, Valencia, Spain; [d] Department of Radiation Oncology, Inselspital, University of Bern, Switzerland; [e] Department of Radiotherapy and Radiobiology, University Hospital Vienna, Austria; [f] Interdisciplinary Brachytherapy Unit, University of Lübeck, Germany; [g] Department of Radiation Oncology, National Institute of Oncology, Budapest, Hungary; and [h] Department of Radiotherapy, University Hospital Gasthuisberg, Leuven, Belgium

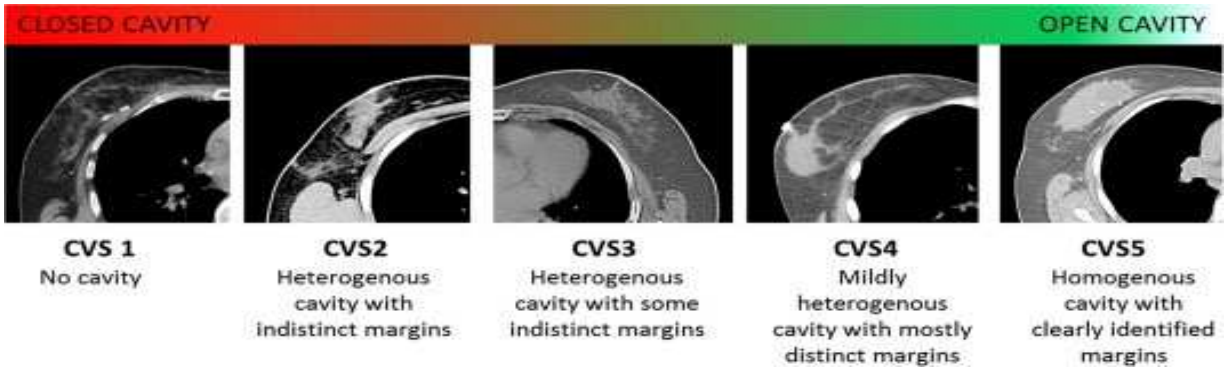

ESTRO School

Information and procedures for appropriate delineation of (boost) CTV:

- DETAILED KNOWLEDGE about primary surgical procedure and details of the pathology report, as well as about preoperative imaging.
- Identification of the TUMOUR LOCALIZATION before breast conserving surgery inside the breast and translation of this information into current CT imaging data set.
- Calculation of the size of the TOTAL SAFETY MARGINS needed to cover the CTV in all 6 directions that should be at least 2 cm from the tumour.
- DEFINITION OF TARGET – CTV/PTV.
- DELINEATION OF THE TARGET– CTV/PTV.

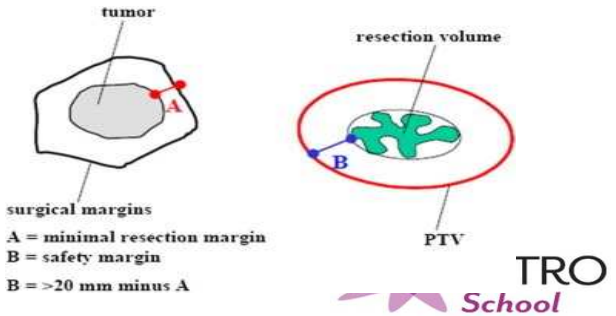

TRO School

Steps for target delineation after closed cavity surgery

1. Perform a CT with marks on the scar.
2. Delineation of clips.
3. Delineation of surgical bed – whole surgical scar (WS) inside breast.
4. Delineation of ImTV (Imaging correlated Target Volume).
5. Delineation of ETB (Estimated Tumour Bed).
6. Delineation of CTV (Clinical Target Volume).

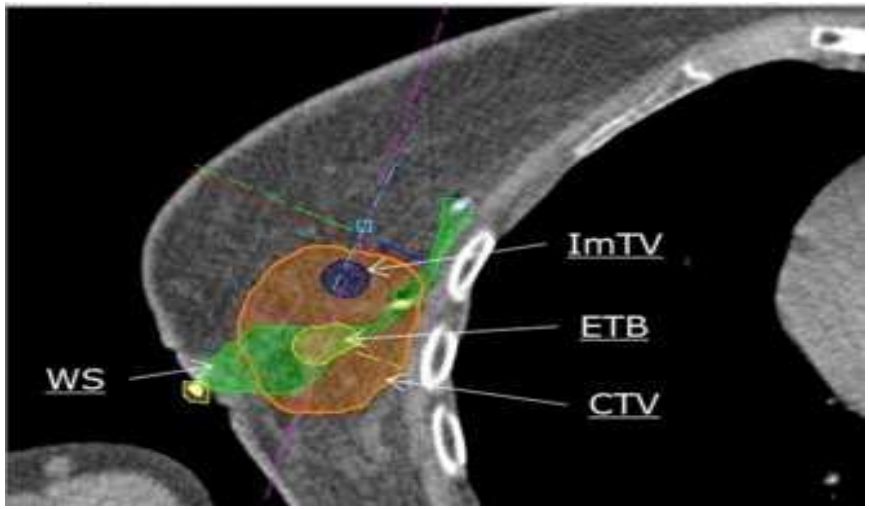

ESTRO School

Steps for target delineation after closed cavity surgery

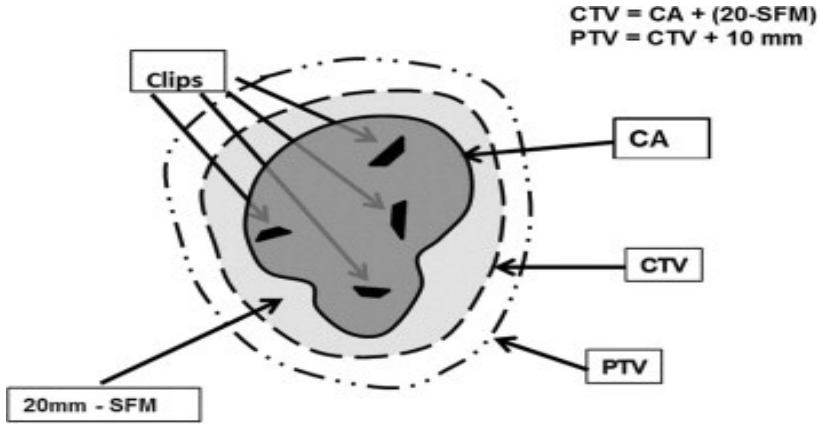

In case of oncoplastic surgery no recommendations can be given.
In selected cases of limited rotational flaps the CTV can be defined as the sum of the clipped area and the distance of 20 mm minus the smallest surgical free margin.

ESTRO School

- Introduction
- **CTV:**
  - Post-lumpectomy intact breast
  - Chestwall
  - Boost
  - **Nodes**
    - **L1, L2, L3, L4, IM, Rotter**
- Organs at risk and constraints
- Margins: CTV to PTV and OAR to PRV
- Conclusions

ESTRO School

REGIONAL NODES

L4: or supraclavicular
L3 or infraclavicular: cranially situated pectoral muscles
L2: posterior to pectoral minor muscle
L1: caudally to pectoral major
IM
Rotter: enter major and minor pectoral muscle

Lymph node is tipically around the veins, 5 mm margin around the veins

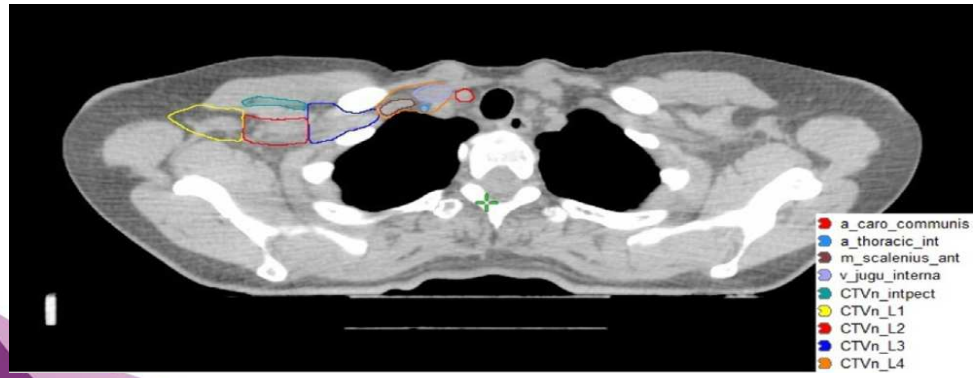

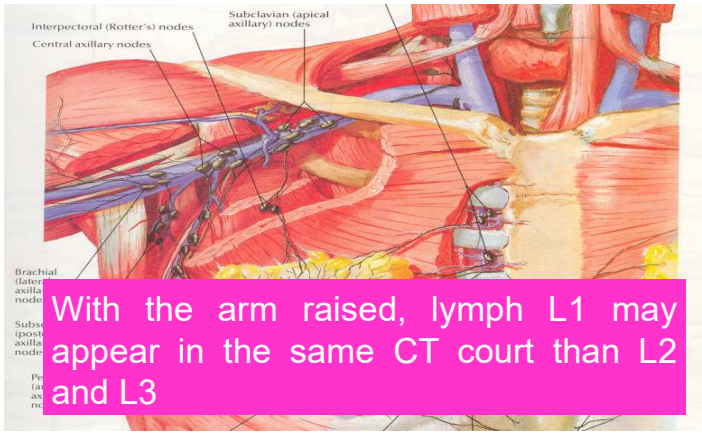

With the arm raised, lymph L1 may appear in the same CT court than L2 and L3

nivel 4 - nivel 3 - nivel 2 – Rotter - nivel 1

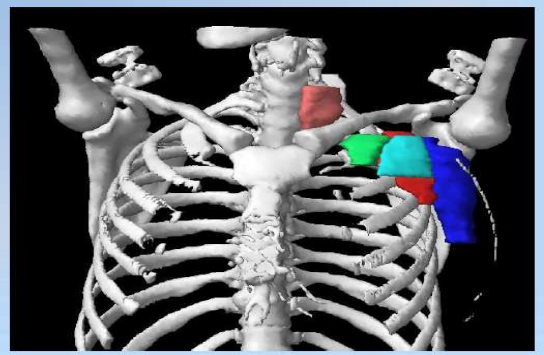

School

BREAST ANATOMY

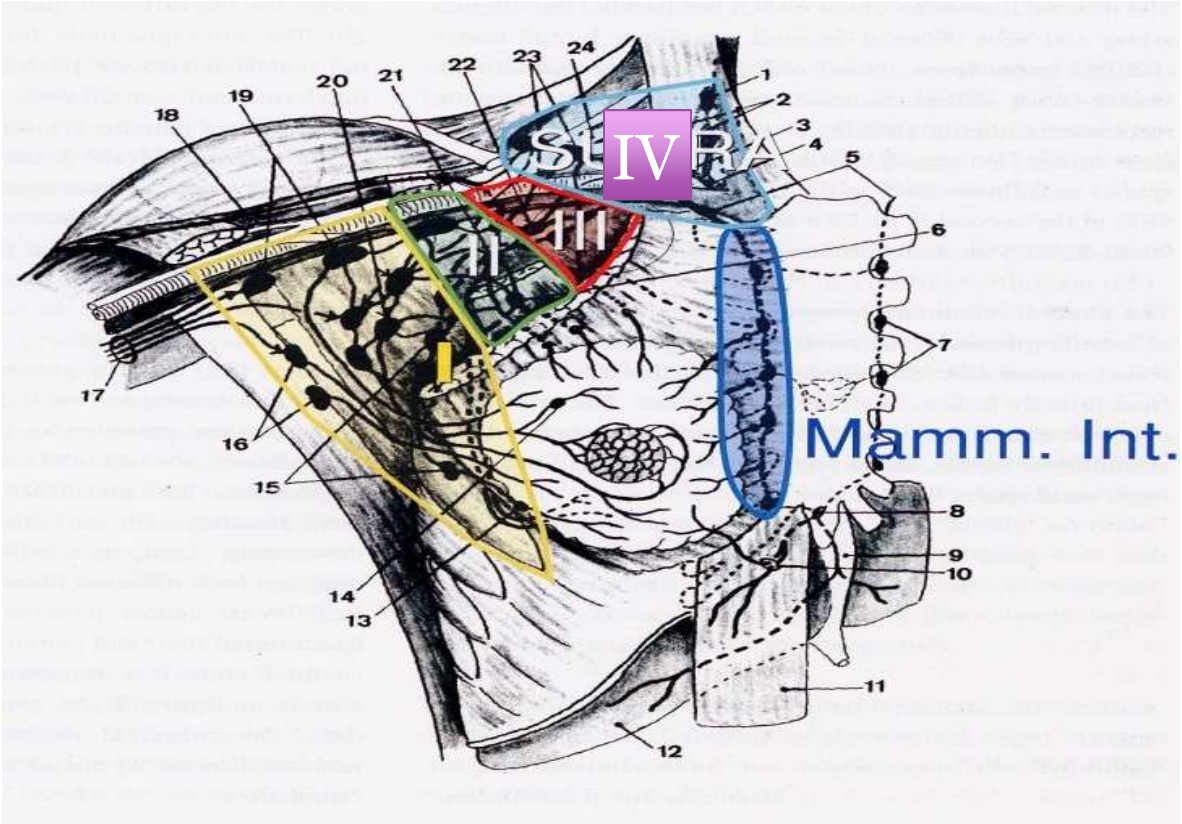

ESTRO School

L1-L2

ESTRO School

CTV L2-L1: INDICATIONS

- No or inadequate lymphadenectomy (L) **RT L4-L3-L2-L1**
- Bulky nodal disease
- SN (+) (Macrometastases) without lymphadenectomy

AMAROS Trial (EORTC) (Adjuvant Management of the Axilla Radiotherapy of Surgery) is comparing L vs axillary RT with SN (+).

RT L4-L3-L2-L1

(Micrometastases: no RT)

AMAROS Donker 2014 Lancet Oncol

Including 4800 patients demonstrated that axillary RT is as effective as axillary surgery with less morbidity at 5 year follow-up.

ESTRO School

L1

ESTRO School

	Cranial	Caudal	Anterior	Posterior	Lateral	Medial
Axilla-Level I	Axillary vessels cross lateral edge of Pec. Minor m.	Pectoralis (Pec.) major muscle insert into ribs [b]	Plane defined by: anterior surface of Pec. Maj. m. and Lat. Dorsi m.	Anterior surface of subscapularis m.	Medial border of lat. dorsi m.	Lateral border of Pec. minor m.
Axilla level 1 CTVn_L1	Medial: 5 mm cranial to the axillary vein Lateral: max up to 1 cm below the edge of the humeral head, 5 mm around the axillary vein	To the level of rib 4 – 5, taking also into account the visible effects of the sentinel lymph node biopsy	Pectoralis major & minor muscles	Cranially up to the thoraco-dorsal vessels, and more caudally up to an imaginary line between the anterior edge of the latissimus dorsi muscle and the intercostal muscles	Cranially up to an imaginary line between the major pectoral and deltoid muscles, and further caudal up to a line between the major pectoral and latissimus dorsi muscles	Level 2, the interpectoral level and the thoracic wall

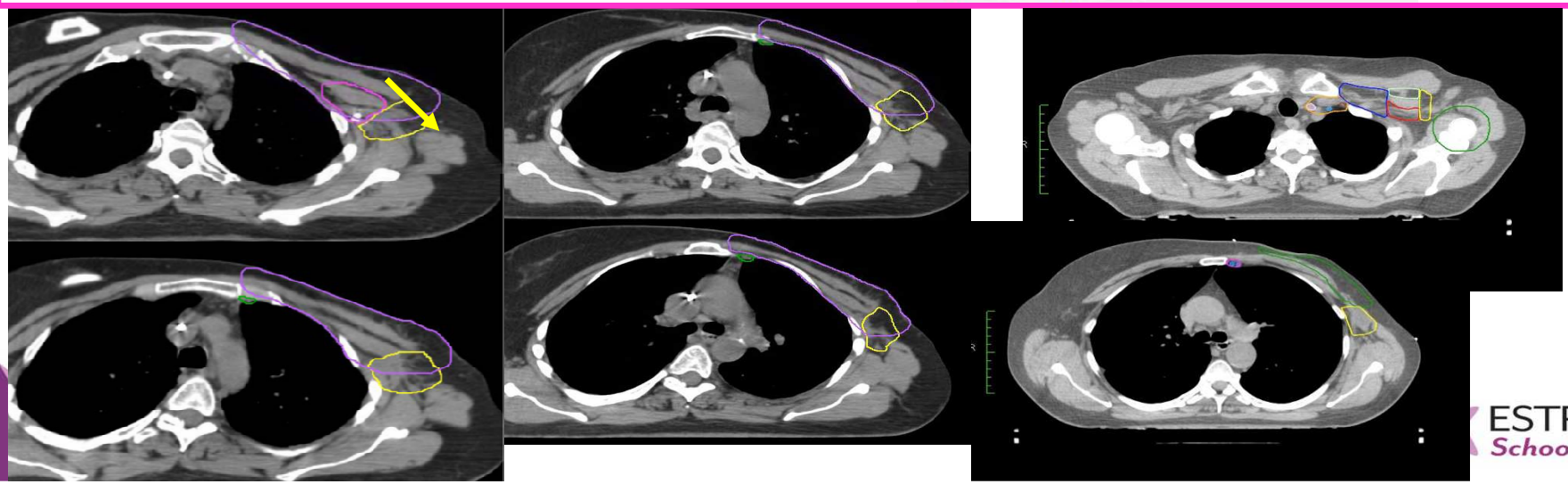

ESTRO School

DCBG guidelines for delineation of CTV of breast and CTVs of the regional lymph node regions

LN region	cranial	caudal	ventral	dorsal	lateral	medial
Level I	1 cm below caput humeri	Free edge of m. pectoralis major including seroma	5 mm below the skin	M. latissimus dorsi, 5 mm dorsal of the axillary vessels	Maximal to 5 mm below the skin	CTV-breast, lateral border of m. pectoralis minor, m. biceps brachii

DBCG guidelines

Level I of the axilla CTVn_L1	The top of the axillary artery where it crosses the lateral edge of the pectoralis minor muscle or 5 mm above the axillary vein, including clips and seroma	Around 4th–5th rib and guided by the clips and/or seroma if present	Not external to the 'imaginary' line between the anterior surface of pectoralis major muscle and latero-anterior border of the deltoid muscle (cranially) and the latissimus dorsi muscle (caudally), but include seroma and/or clips	Lateral border of the pectoralis major and minor muscle and the thoracic wall	Up to the 'imaginary line' connecting the anterior border of the subscapular m and the anterior border of the deltoid or latissimus dorsi muscle, so excluding the subscapular vessels

PROCAB guidelines

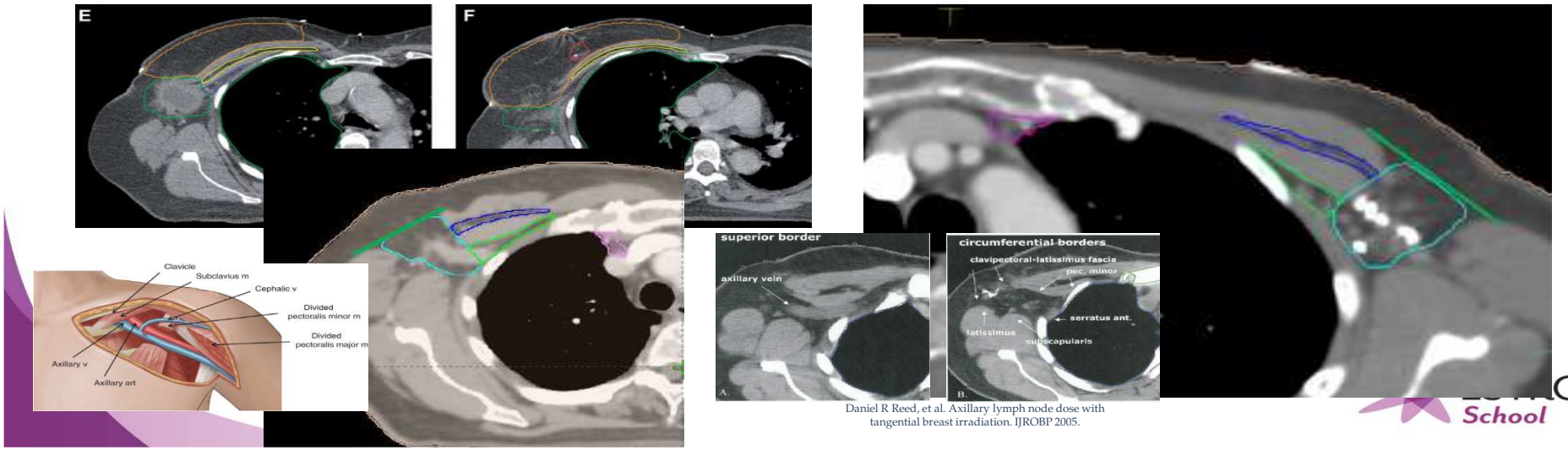

Daniel R Reed, et al. Axillary lymph node dose with tangential breast irradiation. IJROBP 2005.

ESTRO School

Axilla level 1 CTVn_L1	Medial: 5 mm cranial to the axillary vein Lateral: max up to 1 cm below the edge of the humeral head, 5 mm around the axillary vein	To the level of rib 4 – 5, taking also into account the visible effects of the sentinel lymph node biopsy	Pectoralis major & minor muscles	Cranially up to the thoraco-dorsal vessels, and more caudally up to an imaginary line between the anterior edge of the latissimus dorsi muscle and the intercostal muscles	Cranially up to an imaginary line between the major pectoral and deltoid muscles, and further caudal up to a line between the major pectoral and latissimus dorsi muscles	Level 2, the interpectoral level and the thoracic wall

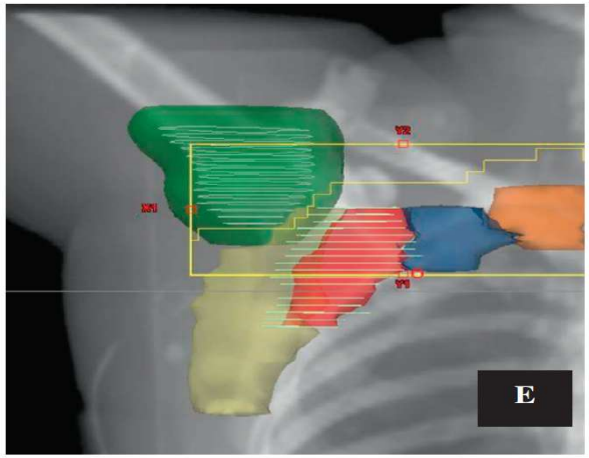

Fig. 1E. Position of field edge in a patient where CTVn_L1 is included in the RT fields with a compromise to shield the humeral head.

ESTRO UPDATE v1.1 suggests a PRV respecting humeral head with the 50% isodose for early stage breast cancer and elective irradiation.

ESTRO School

L2

ESTRO School

	Cranial	*Caudal*	*Anterior*	*Posterior*	*Lateral*	*Medial*
Axilla-level II	Axillary vessels cross medial edge of Pec. Minor m.	Axillary vessels cross lateral edge of Pec. Minor m. [c]	Anterior surface Pec. Minor m.	Ribs and intercostal muscles	Lateral border of Pec. Minor m.	Medial border of Pec. Minor m.
Axilla level 2 CTVn_L2	Includes the cranial extent of the axillary artery (i.e. 5 mm cranial of axillary vein)	The caudal border of the minor pectoral muscle. If appropriate: top of surgical ALND	Minor pectoral muscle	Up to 5 mm dorsal of axillary vein or to costae and intercostal muscles	Lateral edge of minor pectoral muscle	Medial edge of minor pectoral muscle

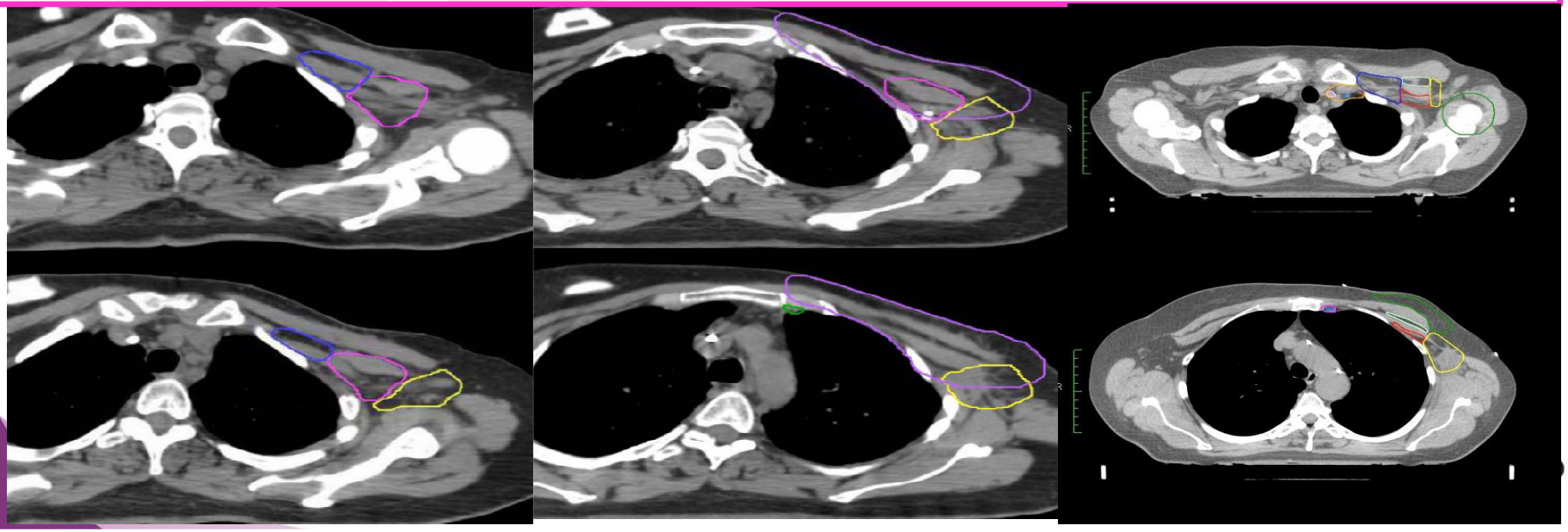

DCBG guidelines for delineation of CTV of breast and CTVs of the regional lymph node regions

LN region	cranial	caudal	ventral	dorsal	lateral	medial
Level II	5 mm cranial to the axillary vessels	Caudal edge of m. pectoralis minor	Dorsal surface of m. pectoralis minor	Chest wall, 5 mm dorsal of the axillary vessels	Lateral border of m. pectoralis minor	Medial border of m. pectoralis minor

DBCG guidelines

Level II of the axilla CTVn_L2	When the axillary A. crosses the medial edge of the pectoralis minor m.	5 mm below the axillary vein when it crosses the lateral border of the pectoralis minor m.	Dorsal surface of the pectoralis minor m.	Visible Ribs and intercostal muscles	Lateral border of the pectoralis minor m.	Medial border of the pectoralis minor m.

PROCAB guidelines

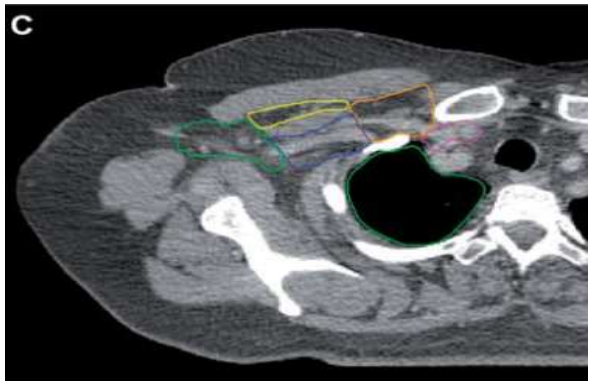

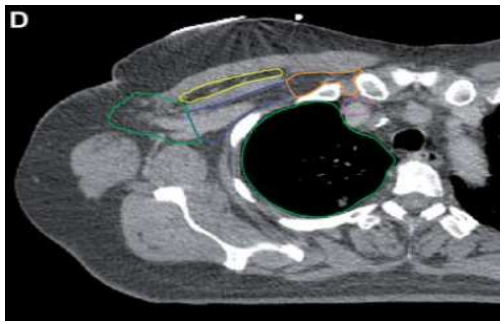

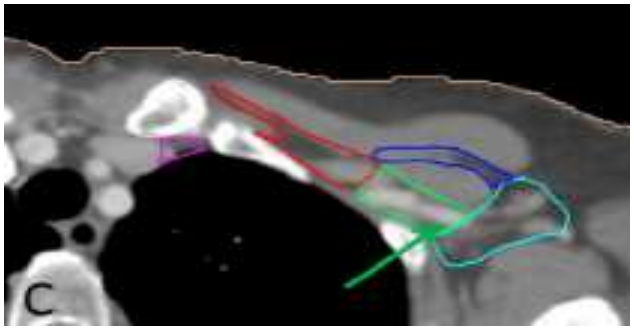

ESTRO School

L1-L2 summary

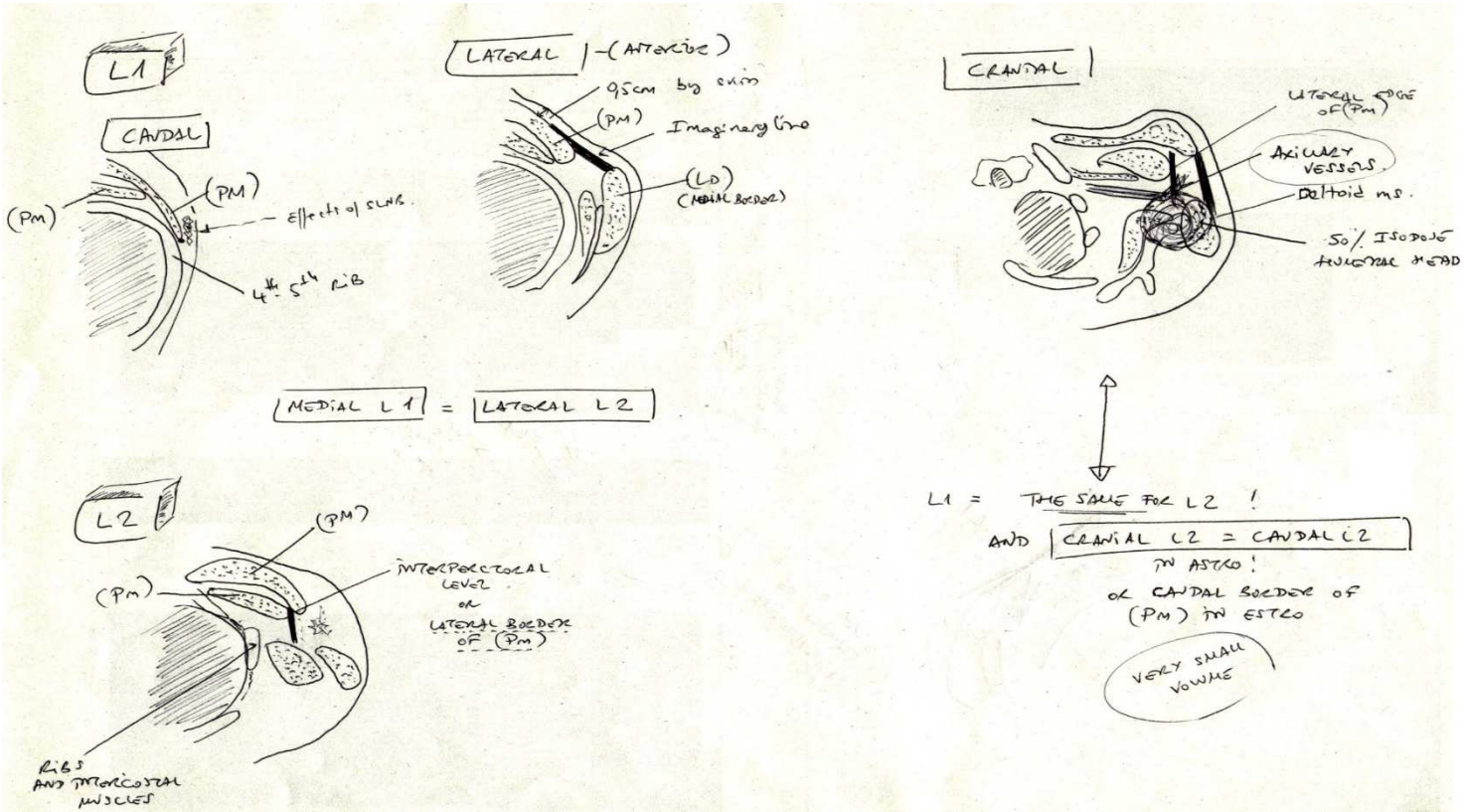

L3-L4

ESTRO School

CTV L4-L3: INDICATIONS

- Tumours > 5 cm (T3)
- Invasion of the skin or chest wall (T4)
- Positive nodes
- No or inadequate lymphadenectomy (< 6-10 nodes)
- SN (+) (Macrometastases) without lymphadenectomy

ESTRO School

L3

ESTRO School

	Cranial	Caudal	Anterior	Posterior	Lateral	Medial
Axilla-level III	Pec. Minor m. insert on coracoid	Axillary vessels cross medial edge of Pec. Minor m. d.	Posterior surface Pec. Major m.	Ribs and intercostal muscles	Medial border of Pec. Minor m.	Thoracic inlet
Axilla level 3 CTVn_L3	Includes the cranial extent of the subclavian artery (i.e. 5 mm cranial of subclavian vein)	5 mm caudal to the subclavian vein. If appropriate: top of surgical ALND	Major pectoral muscle	Up to 5 mm dorsal of subclavian vein or to costae and intercostal muscles	Medial side of the minor pectoral muscle	Junction of subclavian and internal jugular veins – >level 4

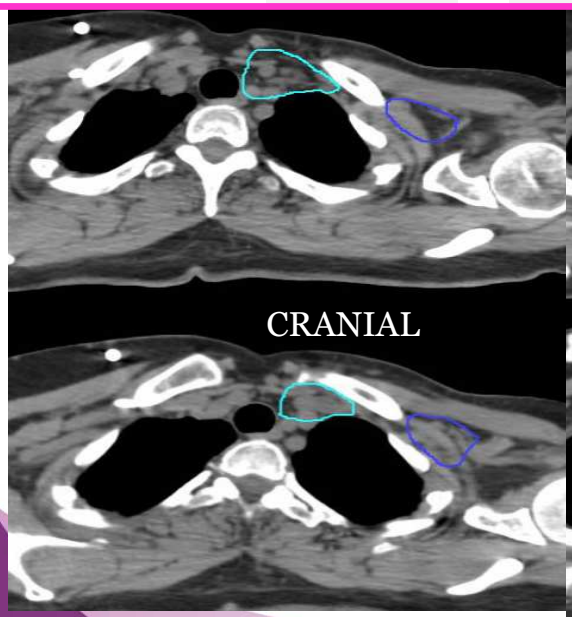

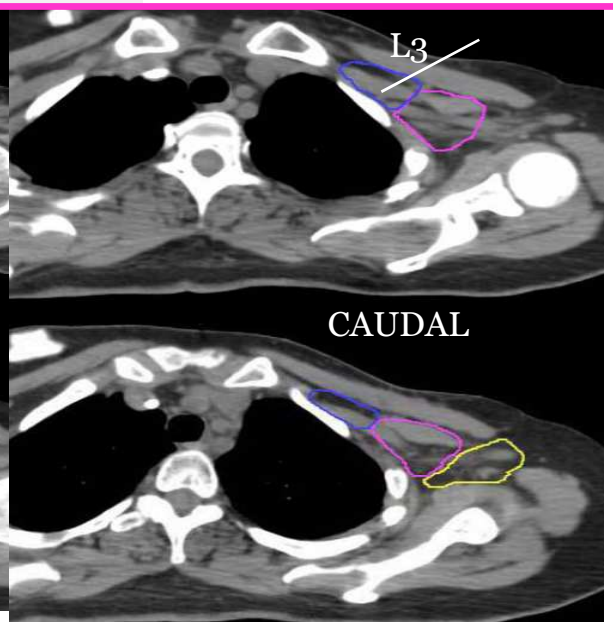

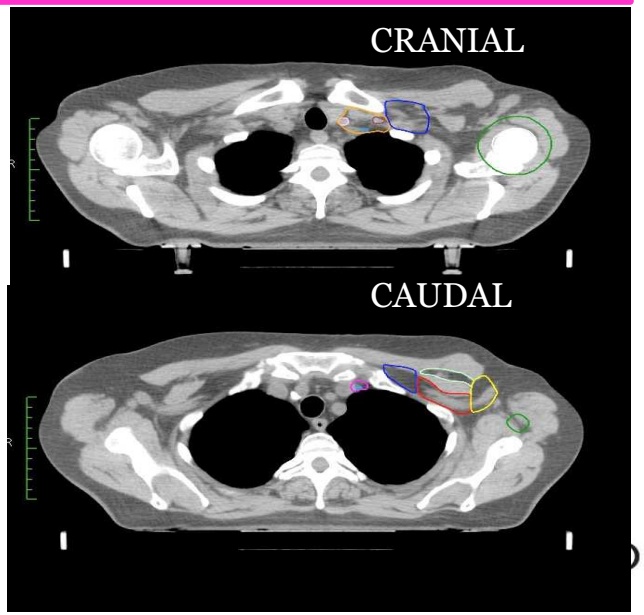

DCBG guidelines for delineation of CTV of breast and CTVs of the regional lymph node regions

LN region	cranial	caudal	ventral	dorsal	lateral	medial
Level III	5 mm cranial to the axillary vessels	1 cm caudal to the axillary vessels	Dorsal surface of m. pectoralis major	Chest wall, 5 mm dorsal of the axillary and subclavian vessels	Medial border of m. pectoralis minor	Clavicle
DBCG guidelines						
Level III of the axilla CTVn_L3	When the subclavian A. exits the thorax (crosses the vertical line between the clavicle and the first rib) and becomes the axillary A.	5 mm below the axillary vein when it crosses the medial border of the pectoralis minor m.	Posterior surface of the pectoralis major m. and the clavicle	Ribs and intercostal muscles. Try to exclude the brachial plexus if visible	Medial border of the pectoralis minor m.	Clavicle and/or lateral border of CTVn_L4
PROCAB guidelines						

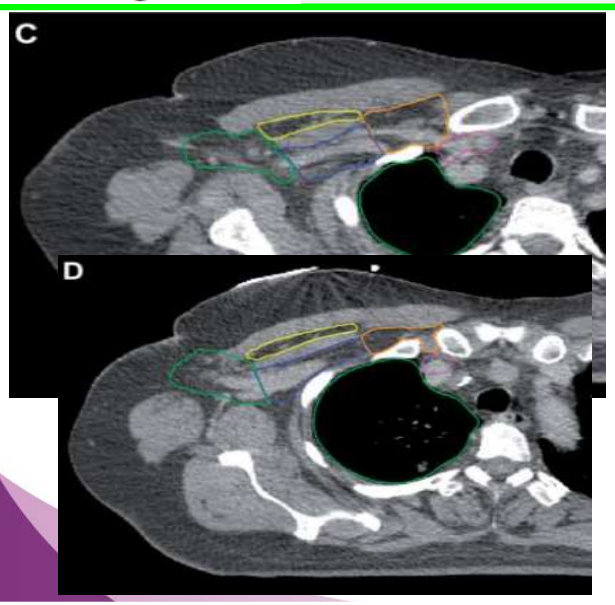

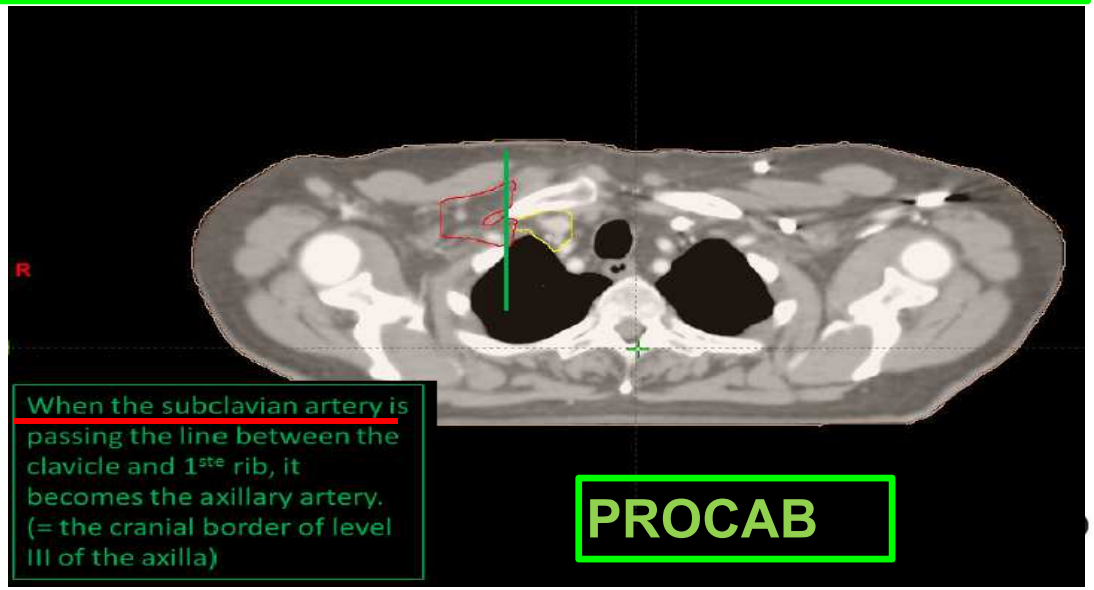

L3 summary

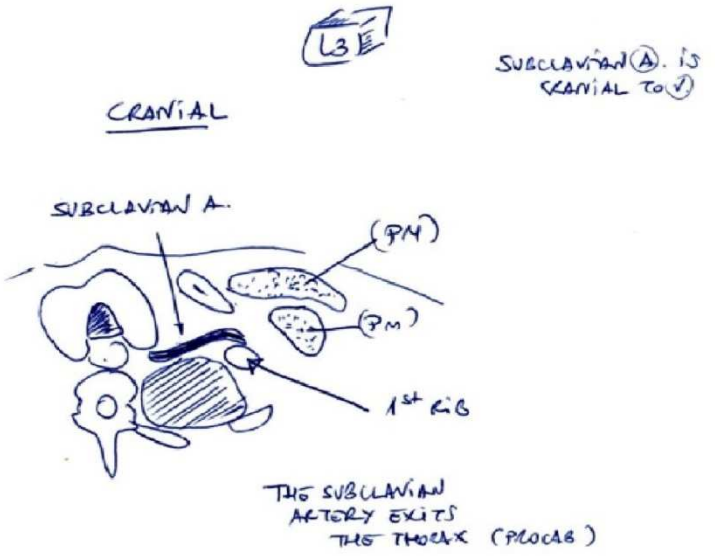
L3
SUBCLAVIAN Ⓐ. IS CRANIAL TO Ⓥ
CRANIAL
SUBCLAVIAN A.
(PM)
(PM)
1st RIB
THE SUBCLAVIAN ARTERY EXITS THE THORAX (PLOCAB)

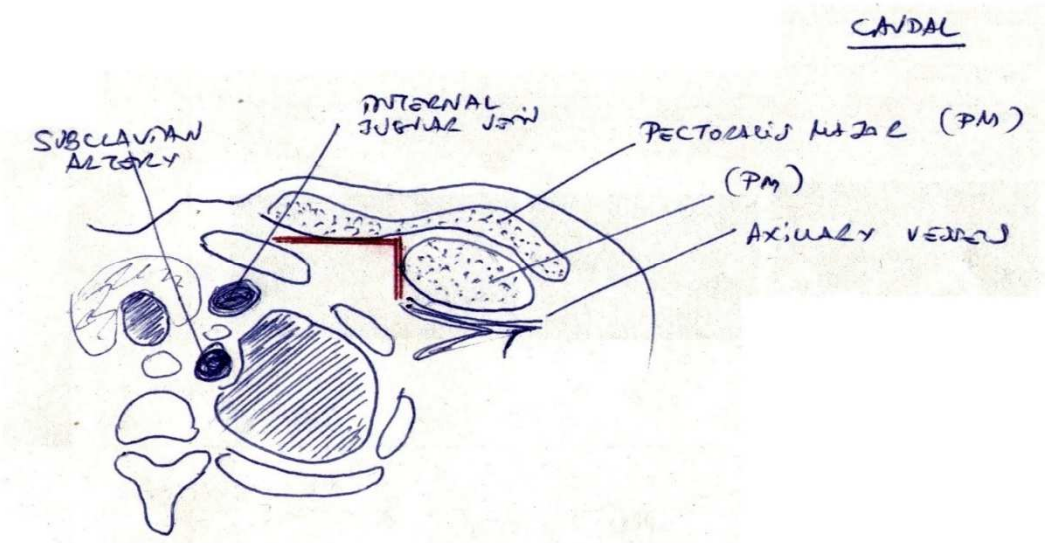
CAUDAL
SUBCLAVIAN ARTERY
INTERNAL JUGULAR VEIN
PECTORALIS MAJOR (PM)
(PM)
AXILLARY VEIN

L4

ESTRO School

	Cranial	Caudal	Anterior	Posterior	Lateral	Medial
Supra-clavicular	Caudal to the cricoid cartilage	Junction of brachioceph.-axillary vns./ caudal edge clavicle head [a]	Sternocleido mastoid (SCM) muscle (m.)	Anterior aspect of the scalene m.	Cranial: lateral edge of SCM m. Caudal: junction 1st rib-clavicle	Excludes thyroid and trachea
Lymph node level 4 CTVn_L4	Includes the cranial extent of the subclavian artery (i.e. 5 mm cranial of subclavian vein)	Includes the subclavian vein with 5 mm margin, thus connecting to the cranial border of CTVn_IMN	Sternocleidomastoid muscle, dorsal edge of the clavicle	Pleura	Includes the anterior scalene muscles and connects to the medial border of CTVn_L3	Including the jugular vein without margin; excluding the thyroid gland and the common carotid artery

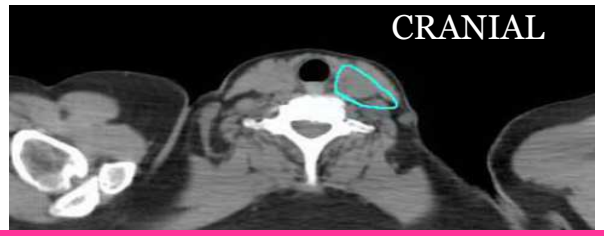

ESTRO recommends lowering the cranial limit (cranial of subclavian vein)

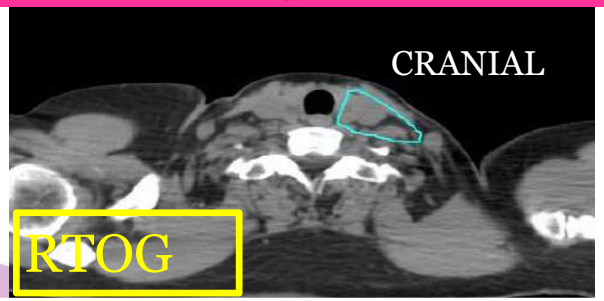

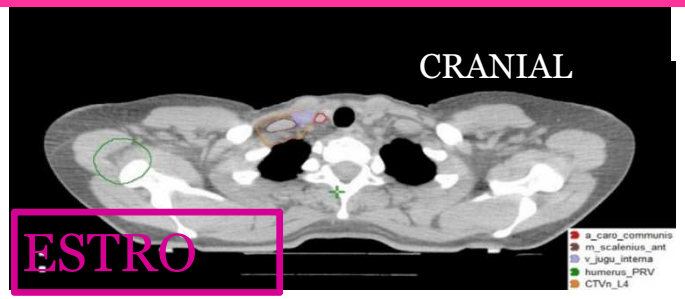

ESTRO School

	Cranial	Caudal	Anterior	Posterior	Lateral	Medial
Level IV CTVn_L4	Cranial edge of the subclavian A. arch	5 mm caudal of the junction of the subclavian and the internal jugular vein	*Cranially: dorsal surface of the SCM *Caudally: the infrahyoid muscle (strap muscles) and clavicle	*Cranially: ventral edge of the subclavian artery *Caudally: lung	*Cranially: lateral border of the anterior scalene m. *Caudally: joining CTVn_L3, excluding the subclavian A.	The medial edge of the internal jugular vein, without any margin medially, excluding the carotid A. and thyroid gland

DBCG guidelines

Lymph node level 4 CTVn_L4	Includes the cranial extent of the subclavian artery (i.e. 5 mm cranial of subclavian vein)	Includes the subclavian vein with 5 mm margin, thus connecting to the cranial border of CTVn_IMN	Sternocleidomastoid muscle, dorsal edge of the clavicle	Pleura	Includes the anterior scalene muscles and connects to the medial border of CTVn_L3	Including the jugular vein without margin; excluding the thyroid gland and the common carotid artery

PROCAB guidelines

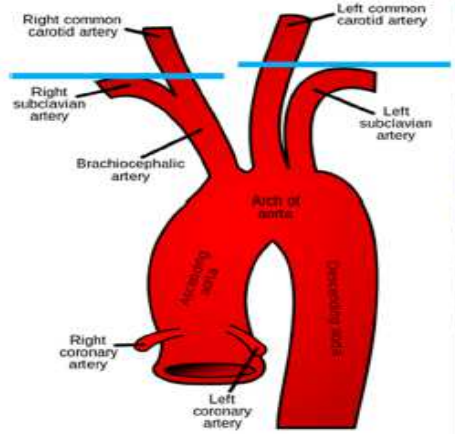

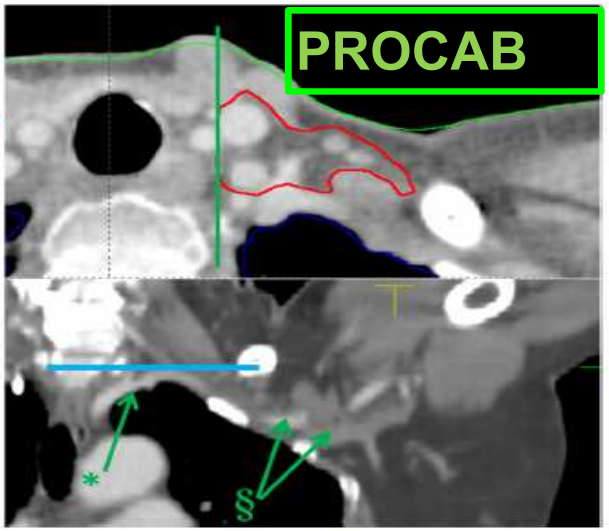

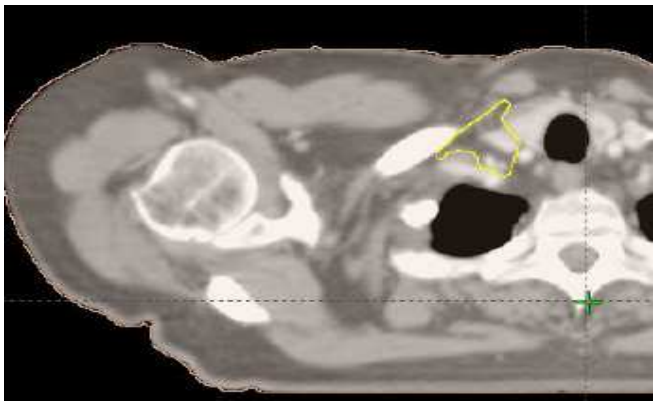

Fig. 2. The cranial border of level 4 or the supraclavicular region. *Subclavian artery arch. §Axillary artery and vein.

ESTRO School

	Cranial	*Caudal*	*Anterior*	*Posterior*	*Lateral*	*Medial*
Supra-clavicular	Caudal to the cricoid cartilage	Junction of brachioceph.-axillary vns./ caudal edge clavicle head [a]	Sternocleido mastoid (SCM) muscle (m.)	Anterior aspect of the scalene m.	Cranial: lateral edge of SCM m. Caudal: junction 1st rib-clavicle	Excludes thyroid and trachea
Lymph node level 4 CTVn_L4	Includes the cranial extent of the subclavian artery (i.e. 5 mm cranial of subclavian vein)	Includes the subclavian vein with 5 mm margin, thus connecting to the cranial border of CTVn_IMN	Sternocleidomastoid muscle, dorsal edge of the clavicle	Pleura	Includes the anterior scalene muscles and connects to the medial border of CTVn_L3	Including the jugular vein without margin; excluding the thyroid gland and the common carotid artery
Periclavicular	Caudal edge of cricoid cartilage	Cranial border of level II and III (lateral). Cranial edge of the sterno-clavicular-junction (medial)	Dorsal surface of m. sternomastoideus, dorsal surface of clavicle, 5 mm below skin	In front of the clavicle, behind a. carotis interna, in front of m. scalenus ant, m. scalenus med, m. omo-hyoideus and m. levator scapulae	Medial edge of m. pectoralis minor, clavicle	Medial edge of a. carotis interna and v. jugularis interna

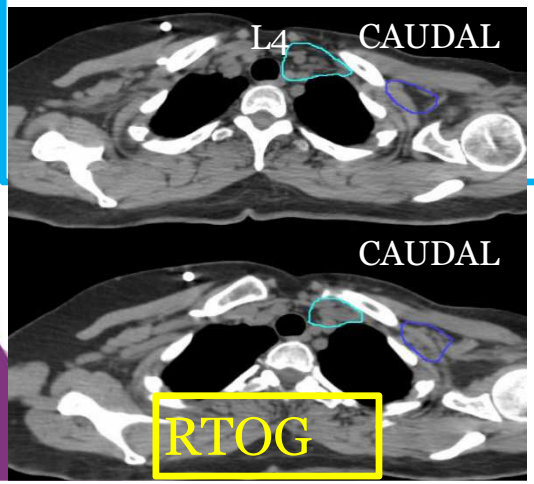

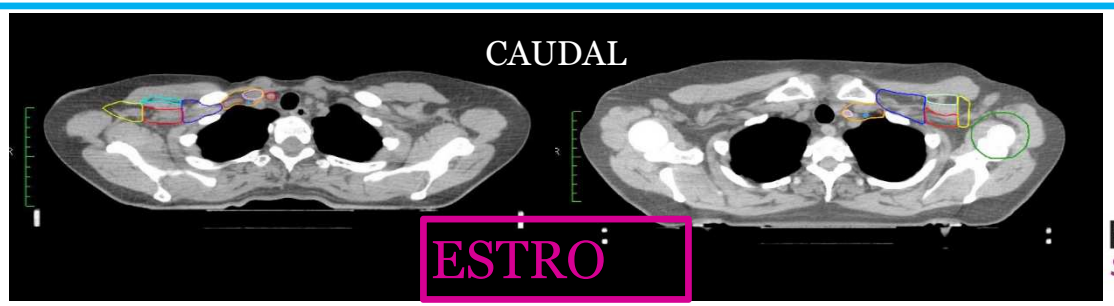

ESTRO School

2016

Letter to the Editor

Radiotherapy and Oncology xxx (2016) xxx–xxx

Contents lists available at ScienceDirect

Radiotherapy and Oncology

journal homepage: www.thegreenjournal.com

ESTRO consensus guideline on target volume delineation for elective radiation therapy of early stage breast cancer, version 1.1 ☆

Caudal part of CTVn_L4

In the consensus guideline a link is given to an atlas with patients treated for left-sided and right-sided breast cancer, respectively. In both cases the caudal border of CTVn_L4 has now been modified a few slices more caudal to fully include the Subclavian vein, which is positioned caudal and ventral to the Subclavian artery (Figs. 1A and 1B). New links are provided to the corrected atlases (links. . .).

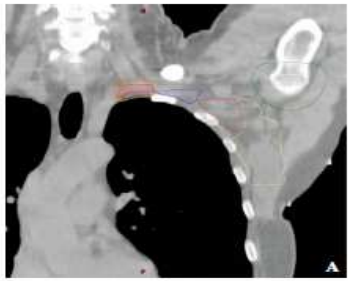

Fig. 1A. CTVn_L4 including the Subclavian artery highlighted in red. (For interpretation of the references to colour in this figure legend, the reader is referred to the web version of this article.)

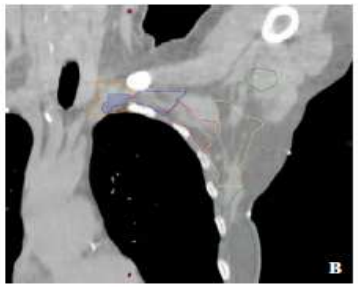

Fig. 1B. CTVn_L4 including the Subclavian vein highlighted in blue (positioned slightly more caudal and ventral to the Subclavian artery). (For interpretation of the references to colour in this figure legend, the reader is referred to the web version of this article.)

ESTRO School

L4 summary

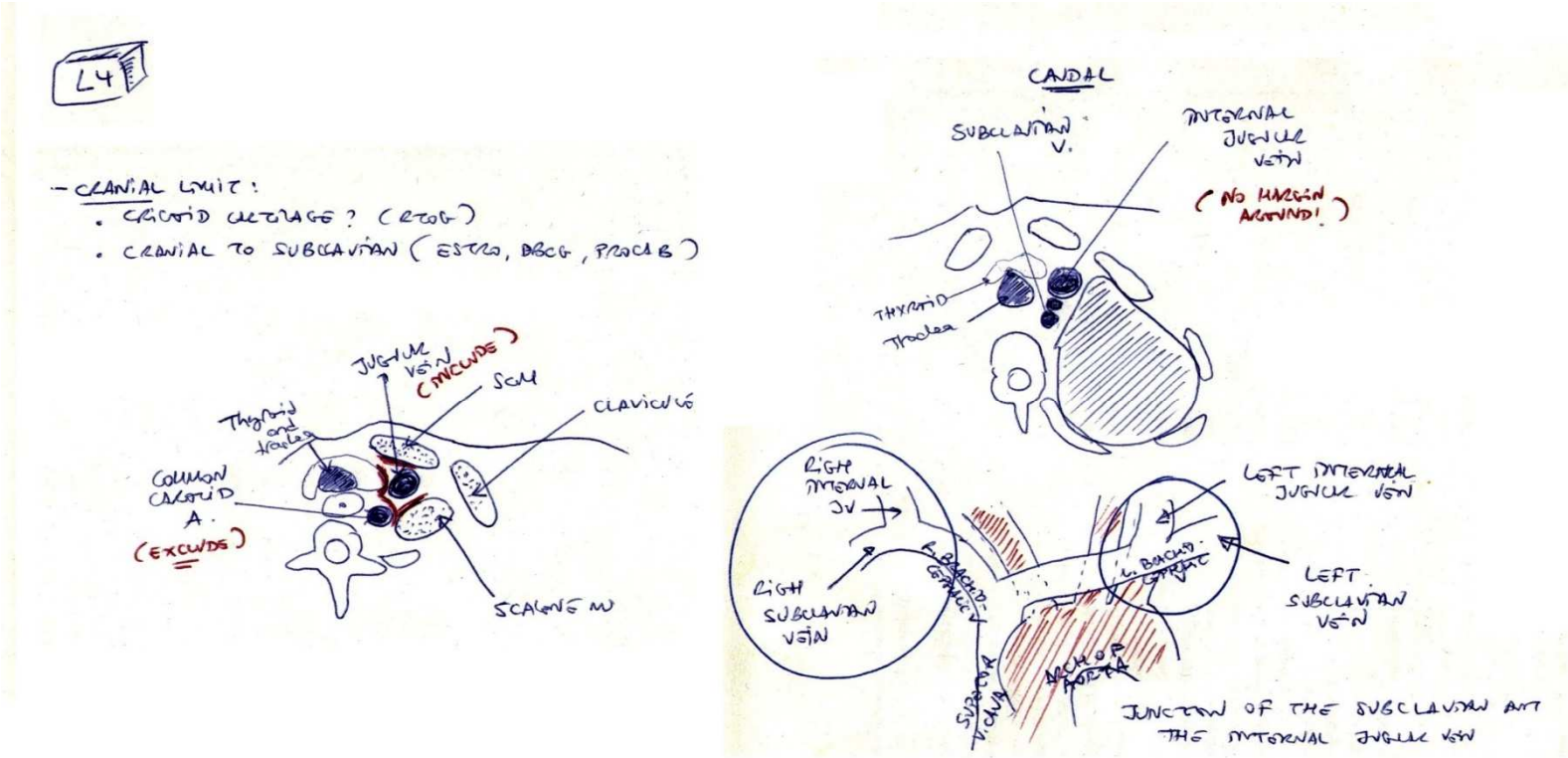
L4
- CRANIAL LIMIT :
• CRICOID CARTILAGE ? (RTOG)
• CRANIAL TO SUBCLAVIAN (ESTRO, BSCG, PROCB)
JUGULAR VEIN (INCLUDE)
SCM
CLAVICULE
Thyroid and Trachea
COMMON CAROTID A. (EXCLUDE)
SCALENE M
CAUDAL
SUBCLAVIAN V.
INTERNAL JUGULAR VEIN
(NO MARGIN AROUND!)
THYROID
Trachea
RIGHT INTERNAL JV
RIGHT SUBCLAVIAN VEIN
R. BRACHIO-CEPHALIC V.
L. BRACHIO-CEPHALIC V.
LEFT INTERNAL JUGULAR VEIN
LEFT SUBCLAVIAN VEIN
SUPERIOR VENA CAVA
ARCH OF AORTA
JUNCTION OF THE SUBCLAVIAN ART THE INTERNAL JUGULAR VEIN

IMC

ESTRO School

CTV IM: INDICATIONS

- Controversy:
- IN FAVOR: decreases LR

  Freedman / Gustave-Roussy / Veronessi / Host
- AGAINST: No decreases LR; fibrosis, cardiotoxicity

  Fowble / Obedian

RT IM if SN (+) (histologically confirmed) in IM

Locally advanced disease, medial tumour with positive axillary nodes

Trials: EORTC 22922 / Canadian **NCIC MA20**

ESTRO School

Benefits of IMC + Regional irradiation

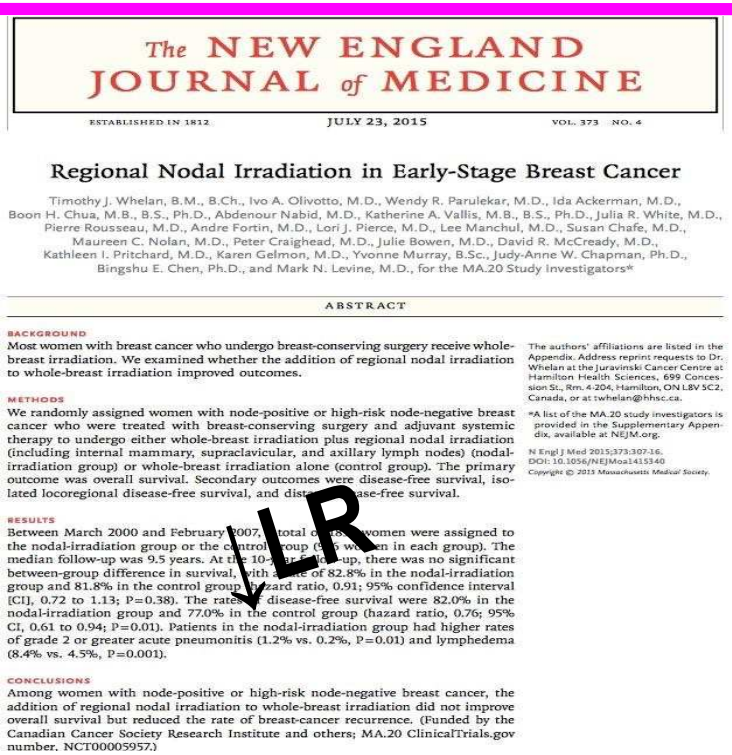

The NEW ENGLAND JOURNAL of MEDICINE

ESTABLISHED IN 1812 JULY 23, 2015 VOL. 373 NO. 4

Regional Nodal Irradiation in Early-Stage Breast Cancer

Timothy J. Whelan, B.M., B.Ch., Ivo A. Olivotto, M.D., Wendy R. Parulekar, M.D., Ida Ackerman, M.D., Boon H. Chua, M.B., B.S., Ph.D., Abdenour Nabid, M.D., Katherine A. Vallis, M.B., B.S., Ph.D., Julia R. White, M.D., Pierre Rousseau, M.D., Andre Fortin, M.D., Lori J. Pierce, M.D., Lee Manchul, M.D., Susan Chafe, M.D., Maureen C. Nolan, M.D., Peter Craighead, M.D., Julie Bowen, M.D., David R. McCready, M.D., Kathleen I. Pritchard, M.D., Karen Gelmon, M.D., Yvonne Murray, B.Sc., Judy-Anne W. Chapman, Ph.D., Bingshu E. Chen, Ph.D., and Mark N. Levine, M.D., for the MA.20 Study Investigators*

ABSTRACT

BACKGROUND
Most women with breast cancer who undergo breast-conserving surgery receive whole-breast irradiation. We examined whether the addition of regional nodal irradiation to whole-breast irradiation improved outcomes.

METHODS
We randomly assigned women with node-positive or high-risk node-negative breast cancer who were treated with breast-conserving surgery and adjuvant systemic therapy to undergo either whole-breast irradiation plus regional nodal irradiation (including internal mammary, supraclavicular, and axillary lymph nodes) (nodal-irradiation group) or whole-breast irradiation alone (control group). The primary outcome was overall survival. Secondary outcomes were disease-free survival, isolated locoregional disease-free survival, and distant disease-free survival.

RESULTS
Between March 2000 and February 2007, a total of 1832 women were assigned to the nodal-irradiation group or the control group (916 women in each group). The median follow-up was 9.5 years. At the 10-year follow-up, there was no significant between-group difference in survival, with a rate of 82.8% in the nodal-irradiation group and 81.8% in the control group (hazard ratio, 0.91; 95% confidence interval [CI], 0.72 to 1.13; P=0.38). The rates of disease-free survival were 82.0% in the nodal-irradiation group and 77.0% in the control group (hazard ratio, 0.76; 95% CI, 0.61 to 0.94; P=0.01). Patients in the nodal-irradiation group had higher rates of grade 2 or greater acute pneumonitis (1.2% vs. 0.2%, P=0.01) and lymphedema (8.4% vs. 4.5%, P=0.001).

CONCLUSIONS
Among women with node-positive or high-risk node-negative breast cancer, the addition of regional nodal irradiation to whole-breast irradiation did not improve overall survival but reduced the rate of breast-cancer recurrence. (Funded by the Canadian Cancer Society Research Institute and others; MA.20 ClinicalTrials.gov number, NCT00005957.)

The authors' affiliations are listed in the Appendix. Address reprint requests to Dr. Whelan at the Juravinski Cancer Centre at Hamilton Health Sciences, 699 Concession St., Rm. 4-204, Hamilton, ON L8V 5C2, Canada, or at twhelan@hhsc.ca.

*A list of the MA.20 study investigators is provided in the Supplementary Appendix, available at NEJM.org.

N Engl J Med 2015;373:307-16.
DOI: 10.1056/NEJMoa1415340
Copyright © 2015 Massachusetts Medical Society.

↓LR

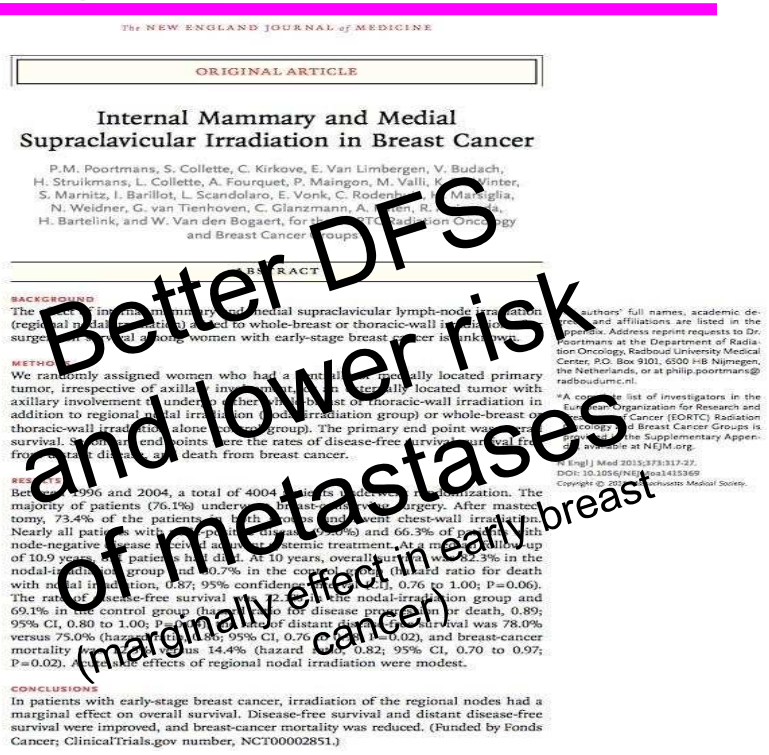

The NEW ENGLAND JOURNAL of MEDICINE

ORIGINAL ARTICLE

Internal Mammary and Medial Supraclavicular Irradiation in Breast Cancer

P.M. Poortmans, S. Collette, C. Kirkove, E. Van Limbergen, V. Budach, H. Struikmans, L. Collette, A. Fourquet, P. Maingon, M. Valli, K. [illegible] Winter, S. Marnitz, I. Barillot, L. Scandolaro, E. Vonk, C. Rodenhuis, [illegible] Marsiglia, N. Weidner, G. van Tienhoven, C. Glanzmann, A. [illegible]en, R. [illegible], H. Bartelink, and W. Van den Bogaert, for [illegible] Radiation Oncology and Breast Cancer Groups

ABSTRACT

BACKGROUND
The [illegible] internal mammary and medial supraclavicular lymph-node irradiation (regional nodal irradiation) added to whole-breast or thoracic-wall irradiation after surgery [illegible] among women with early-stage breast cancer is unknown.

METHODS
We randomly assigned women who had a [illegible] histologically confirmed primary tumor, irrespective of axillary involvement, with a centrally located tumor with axillary involvement [illegible] to undergo either whole-breast or thoracic-wall irradiation in addition to regional nodal irradiation (nodal-irradiation group) or whole-breast or thoracic-wall irradiation alone (control group). The primary end point was overall survival. Secondary end points were the rates of disease-free survival, local [illegible] from [illegible] distant [illegible] and death from breast cancer.

RESULTS
Between 1996 and 2004, a total of 4004 patients [illegible] to [illegible] randomization. The majority of patients (76.1%) underwent breast-conserving surgery. After mastectomy, 73.4% of the patients [illegible] with [illegible] had undergone chest-wall irradiation. Nearly all patients with [illegible] disease (98.6%) and 66.3% of patients with node-negative disease received [illegible] systemic treatment. At a median follow-up of 10.9 years, 1168 patients had died. At 10 years, overall survival was 82.3% in the nodal-irradiation group and 80.7% in the control group (hazard ratio for death with nodal irradiation, 0.87; 95% confidence interval [CI], 0.76 to 1.00; P=0.06). The rate of disease-free survival was 72.2% in the nodal-irradiation group and 69.1% in the control group (hazard ratio for disease progression or death, 0.89; 95% CI, 0.80 to 1.00; P=0.04). The rate of distant disease-free survival was 78.0% versus 75.0% (hazard ratio, 0.85; 95% CI, 0.76 to 0.96; P=0.02), and breast-cancer mortality was [illegible] 14.4% (hazard ratio, 0.82; 95% CI, 0.70 to 0.97; P=0.02). Acute toxic effects of regional nodal irradiation were modest.

CONCLUSIONS
In patients with early-stage breast cancer, irradiation of the regional nodes had a marginal effect on overall survival. Disease-free survival and distant disease-free survival were improved, and breast-cancer mortality was reduced. (Funded by Fonds Cancer; ClinicalTrials.gov number, NCT00002851.)

[illegible] authors' full names, academic de[illegible] and affiliations are listed in the [illegible]ppendix. Address reprint requests to Dr. [illegible]oortmans at the Department of Radiation Oncology, Radboud University Medical Center, P.O. Box 9101, 6500 HB Nijmegen, the Netherlands, or at philip.poortmans@radboudumc.nl.

*A complete list of investigators in the [illegible] European Organization for Research and [illegible] Cancer (EORTC) Radiation [illegible]ology and Breast Cancer Groups is [illegible] the Supplementary Appendix, available at NEJM.org.

N Engl J Med 2015;373:317-27.
DOI: 10.1056/NEJMoa1415369
Copyright © 2015 Massachusetts Medical Society.

Better DFS and lower risk of metastases (marginally effect on cancer) in early breast

HOWEVER, THESE TRIALS DO NOT EVALUATE THE **CONTRIBUTION OF THE IMC SEPARATELY** FROM REGIONAL IRRADIATION

ESTRO School

Potential benefits of CMI irradiation

Danish prospective cohort study

pN+ patients (60% 1-3gg). Left 1587; Right 1486

Patients with right-sided disease were allocated to IMNI, whereas patients with left-sided disease were allocated to no IMNI.

Median FU 9 years

RESULTS:

Effect of IMNI **more pronounced in patients at high risk** of internal mammary node metastasis**.**

Equal numbers in each group **died of ischemic heart disease.**

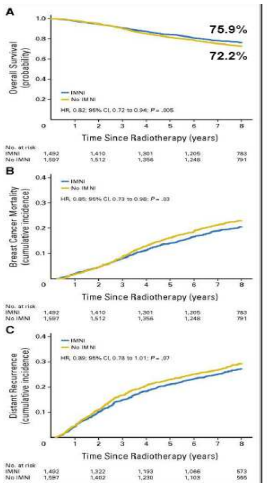

Overall Survival, HR 0.82; p=0.005

Breast Cancer Mortality, HR 0.85; p=0.03

Distant Recurrence, HR 0.89; p=0.07

ESTRO School

Internal mamary lymph nodes

Table 1 Published guidelines for delineation of internal mammary nodal clinical target volume for adjuvant radiation therapy for breast cancer.

Cooperative group	Cranial	Caudal	Anterior	Posterior	Lateral	Medial
DBCG	Cranial edge of first rib	Cranial edge of fifth rib	Posterior surface of pectoralis major muscle, posterior surface of sternum	Pleura	5 mm lateral to IM vessels or 2 cm from edge of sternum	Edge of sternum
Utrecht, The Netherlands	Cranial CT slice of jugulo-subclavian junction	Cranial aspect of fourth rib	Posterior surface of pectoralis major muscle, posterior surface of sternum	Pleura or 5 mm of fat tissue posterior to IMV	5 mm lateral to IMV, lateral border of brachiocephalic vein	5 mm medial to IMV, medial border brachiocephalic vein
ESTRO	Caudal limit of supraclavicular volume 5 mm caudal to subclavian vein	Cranial aspect of fourth rib (in selected cases, fifth rib)	Anterior limit of vascular area	Pleura	5 mm lateral to IMV (artery in cranial part up to and including first intercostal space)	5 mm medial to IMV (artery in cranial part up to and including first intercostal space)
RTOG	Cranial aspect of first rib	Cranial aspect of fourth rib	-	-	Lateral border of IM vessels	Medial border of IM vessels
PROCAB	5 mm caudal to junction of subclavian and internal jugular vein	Cranial edge of fourth rib	Cranially: manubrium of sternum Caudally: posterior surface of intercostal muscles	5-mm fatty space posterior to IM vessels, excluding pleura	5 mm lateral to IM vessels	Cranially: lateral border of brachiocephalic vein Caudally: up to sternal bone

Abbreviations: CT = computed tomography; DBCG = Danish Breast Cancer Cooperative Group; ESTRO = European Society for Therapeutic Radiology and Oncology; IM = internal mammary; IMV = internal mammary vein; PROCAB = Project on Cancer of the Breast; RTOG = Radiation Therapy Oncology Group.

- Recommendations for the optimal extent of the IMN CTV are particularly important for patients being treated with highly conformal radiation therapy techniques.

ESTRO School

International Journal of Radiation Oncology biology • physics
www.redjournal.org

Clinical Investigation

Delineation of Internal Mammary Nodal Target Volumes in Breast Cancer Radiation Therapy

Krishan R. Jethwa, MD,* Mohamed M. Kahila, MBBCh,* Katie N. Hunt, MD,† Lindsay C. Brown, MD,* Kimberly S. Corbin, MD,* Sean S. Park, MD, PhD,* Elizabeth S. Yan, MD,* Judy C. Boughey, MD,‡ and Robert W. Mutter, MD*

*Departments of *Radiation Oncology, †Radiology, and ‡Surgery, Mayo Clinic, Rochester, Minnesota*

Received Apr 21, 2016, and in revised form Oct 5, 2016. Accepted for publication Nov 21, 2016.

- 78% within the first 3 intercostal spaces
- 90% of lymph nodes encompassed with a **4-mm medial and lateral expansion on the IM vessels** or RTOG IMN target volume.

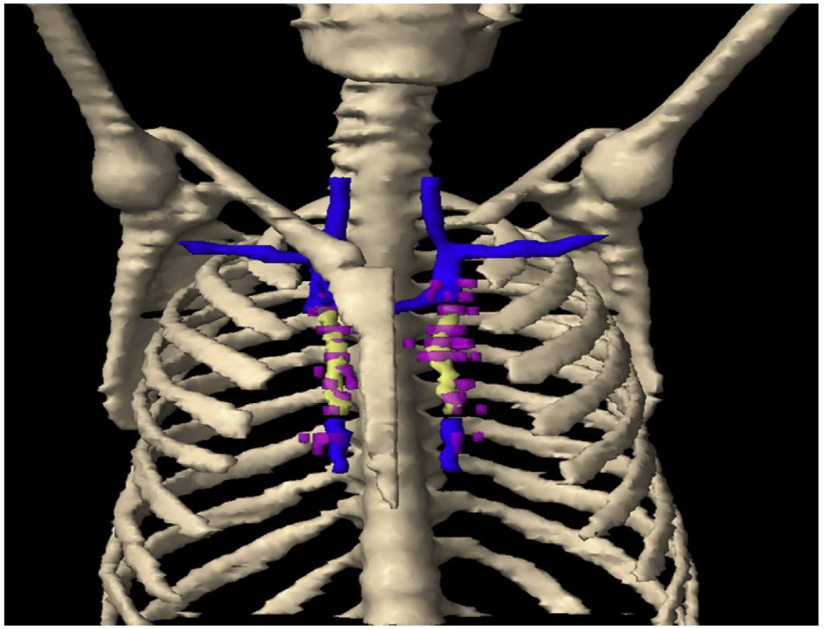

Fig. 2. Internal mammary node metastases (magenta), in relation to the vasculature (internal jugular vein, subclavian vein, brachiocephalic vein, and internal mammary vessels) (blue), and Radiation Therapy Oncology Group consensus internal mammary node clinical target volume (yellow).

ESTRO School

	Cranial	Caudal	Anterior	Posterior	Lateral	Medial
Internal mammary	Superior aspect of the medial 1st rib.	Cranial aspect of the 4th rib	_ e.	_ e.	_ e.	_ e.
Internal mammary chain CTVn_IMN	Caudal limit of CTVn_L4	Cranial side of the 4th rib (in selected cases 5th rib, see text)	Ventral limit of the vascular area	Pleura	5 mm from the internal mammary vein (artery in cranial part up to and including first intercostal space)	5 mm from the internal mammary vein (artery in cranial part up to and including first intercostal space)

Most IMN in first 3-4 intercostal spaces

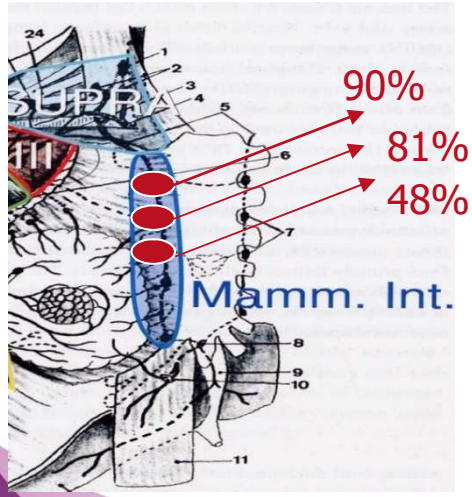

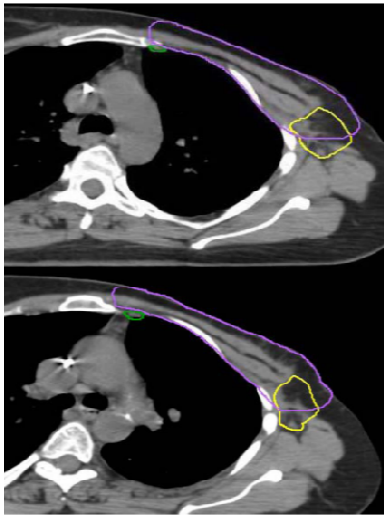

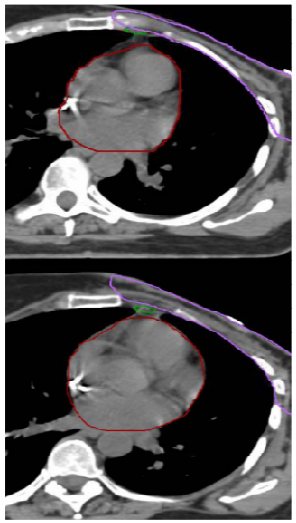

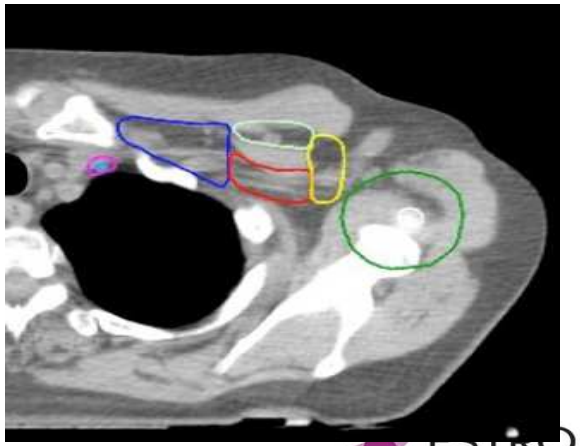

ESTRO School

2016

Letter to the Editor

Radiotherapy and Oncology xxx (2016) xxx–xxx

Contents lists available at ScienceDirect

Radiotherapy and Oncology

journal homepage: www.thegreenjournal.com

ESTRO consensus guideline on target volume delineation for elective radiation therapy of early stage breast cancer, version 1.1 ☆

Lateral border of CTVn_IMN

Since lymph nodes are positioned equally frequent medial and lateral to the internal mammary vessels, the definition of CTVn_IMN is modified to include both the internal mammary vein and artery with 5 mm margin (Table 1) [2,3].

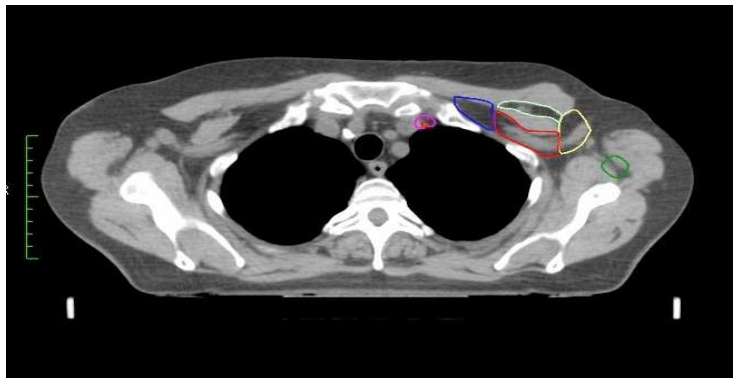

ESTRO School

Interpectoral nodes CTVn_interpectoralis	
Cranial	Includes the cranial extent of the axillary artery (i.e. 5 mm cranial of axillary vein)
Caudal	Level 2's caudal limit
Ventral	Major pectoral muscle
Dorsal	Minor pectoral muscle
Medial	Medial edge of minor pectoral muscle
Lateral	Lateral edge of minor pectoral muscle

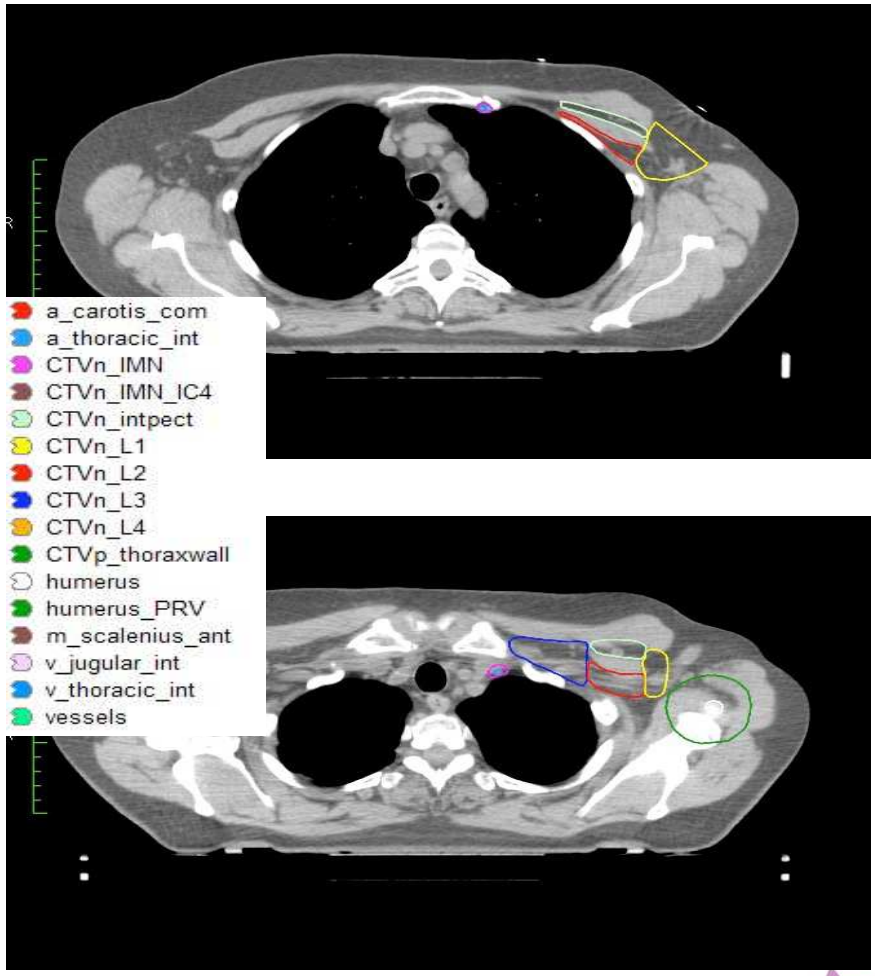

Interpectoral or Rotter lymph nodes: enter pectoral major and minor

ESTRO School

2016 v1.1 ESTRO Guideline

Table 1
ESTRO delineation guidelines for the CTV of lymph node regions, breast and postmastectomy thoracic wall for elective irradiation in breast cancer (see figures).

Borders per region	Axilla level 1 CTVn_L1	Axilla level 2 CTVn_L2	Axilla level 3 CTVn_L3	Lymph node level 4 CTVn_L4	Internal mammary chain CTVn_IMN	Interpectoral nodes CTVn_interpectoralis	Residual breast CTVp_breast	Thoracic wall CTVp_thoracicwall
Cranial	Medial: 5 mm cranial to the axillary vein Lateral: max up to 1 cm below the edge of the humeral head, 5 mm around the axillary vein	Includes the cranial extent of the axillary artery (i.e. 5 mm cranial of axillary vein)	Includes the cranial extent of the subclavian artery (i.e. 5 mm cranial of subclavian vein)	Includes the cranial extent of the subclavian artery (i.e. 5 mm cranial of subclavian vein)	Caudal limit of CTVn_L4	Includes the cranial extent of the axillary artery (i.e. 5 mm cranial of axillary vein)	Upper border of palpable/visible breast tissue; maximally up to the caudal edge of the sterno-clavicular joint	Guided by palpable/visible signs; if appropriate guided by the contralateral breast; maximally up to the caudal edge of the sterno-clavicular joint
Caudal	To the level of rib 4–5, taking also into account the visible effects of the sentinel lymph node biopsy	The caudal border of the minor pectoral muscle If appropriate: top of surgical ALND	5 mm caudal to the subclavian vein If appropriate: top of surgical ALND	Includes the subclavian vein with 5 mm margin, thus connecting to the cranial border of CTVn_IMN	Cranial side of the 4th rib (in selected cases 5th rib, see text)	Level 2's caudal limit	Most caudal CT slice with visible breast	Guided by palpable/visible signs; if appropriate guided by the contralat. breast
Ventral	Pectoralis major & minor muscles	Minor pectoral muscle	Major pectoral muscle	Sternocleidomastoid muscle, dorsal edge of the clavicle	Ventral limit of the vascular area	Major pectoral muscle	5 mm under skin surface	5 mm under skin surface
Dorsal	Cranially up to the thoraco-dorsal vessels, and more caudally up to an imaginary line between the anterior edge of the latissimus dorsi muscle and the intercostal muscles	Up to 5 mm dorsal of axillary vein or to costae and intercostal muscles	Up to 5 mm dorsal of axillary vein or to costae and intercostal muscles	Pleura	Pleura	Minor pectoral muscle	Major pectoral muscle or costae and intercostal muscles where no muscle	Major pectoral muscle or costae and intercostal muscles where no muscle
Medial	Level 2, the interpectoral level and the thoracic wall	Medial edge of minor pectoral muscle	Junction of subclavian and internal jugular veins – level 4	Including the jugular vein without margin; excluding the thyroid gland and the common carotid artery	5 mm from the internal mammary vein (artery in cranial part down to and including first intercostal space)	Medial edge of minor pectoral muscle	Lateral to the medial perforating mammarian vessels; maximally to the edge of the sternal bone	Guided by palpable/visible signs; if appropriate guided by the contralat. breast
Lateral	Cranially up to an imaginary line between the major pectoral and deltoid muscles, and further caudal up to a line between the major pectoral and latissimus dorsi muscles	Lateral edge of minor pectoral muscle	Medial side of the minor pectoral muscle	Includes the anterior scalene muscles and connects to the medial border of CTVn_L3	5 mm from the internal mammary artery	Lateral edge of minor pectoral muscle	Lateral breast fold; anterior to the lateral thoracic artery	Guided by palpable/visible signs; if appropriate guided by the contralat. breast. Usually anterior to the mid-axillary line

Legend: ALND = axillary lymph node dissection.

ESTRO School

2016 PROCAB update

Table 1
Adapted PROCAB/ESTRO delineation guidelines for the clinical target volume (CTV) definition for elective irradiation of lymph node level 2–4, interpectoral and internal mammary node region in breast cancer.

	Cranial	Caudal	Anterior	Posterior	Lateral	Medial
Level IV CTVn_L4	Cranial edge of the subclavian A. Arch	5 mm caudal of the junction of the Subclavian and the Internal Jugular Vein	∗ Cranially: dorsal surface of the SCM ∗ Caudally: the Infrahyoid Muscle (Strap muscles) and Clavicle	∗Cranially: Ventral edge of the Subclavian Artery ∗Caudally: lung	∗ Cranially: lateral border of the Anterior Scalene m. ∗ Caudally: joining CTVn_L3, excluding the Subclavian A	The medial edge of the Internal Jugular Vein, without any margin medially, excluding the Carotid A. and thyroid gland
Level III of the axilla CTVn_L3	When the subclavian A. exist the thorax (crosses the vertical line between the clavicle and the first rib) and becomes the Axillary A	5 mm below the Axillary Vein when it crosses the medial border of the Pectoralis Minor m	Posterior surface of the pectoralis Major m. and the clavicle	Ribs and Intercostal muscles. Try to exclude the brachial plexus if visible	Medial border of the Pectoralis Minor m	Clavicle and/or lateral border of CTVn_L4
Level II of the axilla CTVn_L2	When the axillary A. crosses the medial edge of the Pectoralis Minor m	The caudal border of the Pectoralis Minor m	Dorsal surface of the Pectoralis Minor m	Ribs and Intercostal muscles	Lateral border of the Pectoralis Minor m	Medial border of the Pectoralis Minor m
Rotter or interpectoral space	Idem CTVn_L2	Idem CTVn_L2	Dorsal surface of the Pectoralis Major m	Ventral surface of the Pectoralis Minor m	Lateral border of the Pectoralis Major m	Idem CTVn_L2
Internal mammary node region CTVn_IMN In	In conjunction with the caudal edge of CTVn_L4	Cranial edge of the 4th rib	∗ Cranially: Manubrium Sterni ∗ Caudally: the dorsal surface of the intercostal muscles	5 mm fatty space dorsal of the IM Vessels, excluding the pleura	5 mm lateral of the IM Vessels	∗ Cranially: lateral border of the Brachiocephalic Vein ∗ Caudally: up to the sternal bone

Abbreviations: SCM = sternocleidomastoid muscle; A. = artery; m. = muscle, IM = internal mammary.

ESTRO School

- Introduction
- CTV:
  - Post-lumpectomy intact breast
  - Chestwall
  - Boost
  - Nodes
    - L1, L2, L3, L4, IM, Rotter
- **Organs at risk**
- Margins: CTV to PTV and OAR to PRV
- Conclusions

ESTRO School

ORGANS AT RISK

- Lung
- Heart
- Contralateral breast
- Skin
- Humeral heads
- Spinal Cord
- Thyroid
- Brachial plexus

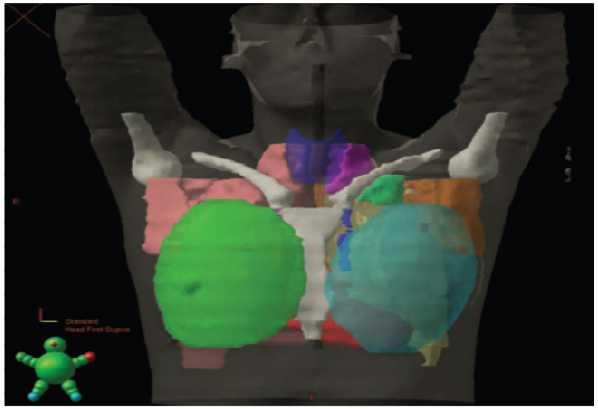

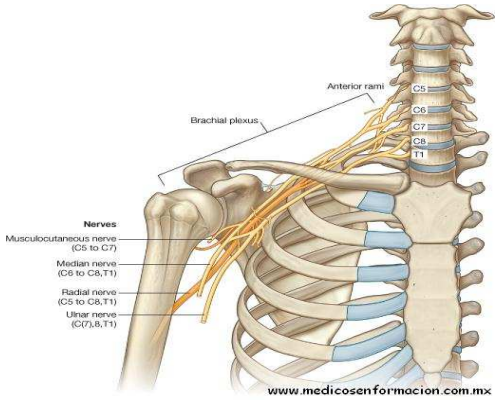

ESTRO School

LUNG

- Automatic delineation
- Both lungs should be evaluated as a single organ
- Pulmonary hila and trachea should be excluded

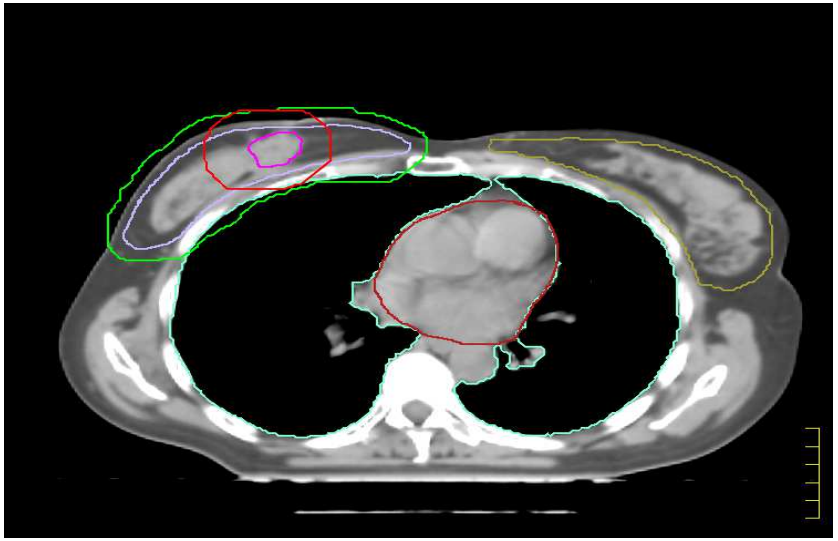

ESTRO School

THE HEART

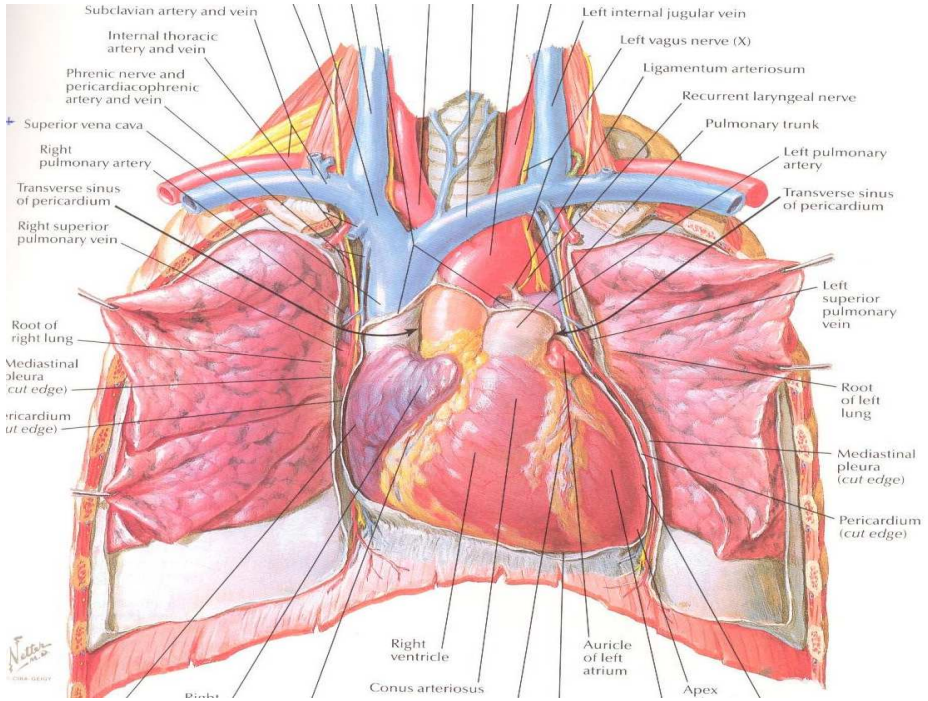
Subclavian artery and vein
Internal thoracic artery and vein
Phrenic nerve and pericardiacophrenic artery and vein
Superior vena cava
Right pulmonary artery
Transverse sinus of pericardium
Right superior pulmonary vein
Root of right lung
Mediastinal pleura (cut edge)
Pericardium (cut edge)
Left internal jugular vein
Left vagus nerve (X)
Ligamentum arteriosum
Recurrent laryngeal nerve
Pulmonary trunk
Left pulmonary artery
Transverse sinus of pericardium
Left superior pulmonary vein
Root of left lung
Mediastinal pleura (cut edge)
Pericardium (cut edge)
Right ventricle
Conus arteriosus
Auricle of left atrium
Apex

CARDIAC TOXICITY

- Seen in patients treated for lymphoma, breast cancer, and lung cancer.

- Cardiac injury:
  - Myocardium
  - Vascular endothelium and capillary vessels

- The relationship between dose to **cardiac substructures** and subsequent toxicity has not been well defined.

ESTRO School

CARDIAC TOXICITY

The NEW ENGLAND JOURNAL of MEDICINE

ESTABLISHED IN 1812 MARCH 14, 2013 VOL. 368 NO. 11

Risk of Ischemic Heart Disease in Women after Radiotherapy for Breast Cancer

Sarah C. Darby, Ph.D., Marianne Ewertz, D.M.Sc., Paul McGale, Ph.D., Anna M. Bennet, Ph.D., Ulla Blom-Goldman, M.D., Dorthe Brønnum, R.N., Candace Correa, M.D., David Cutter, F.R.C.R., Giovanna Gagliardi, Ph.D., Bruna Gigante, Ph.D., Maj-Britt Jensen, M.Sc., Andrew Nisbet, Ph.D., Richard Peto, F.R.S., Kazem Rahimi, D.M., Carolyn Taylor, D.Phil., and Per Hall, Ph.D.

n: 2168
mean dose: 4.9 Gy (range: 0.03 to 27.72)

Increase of major coronary events started within the first 5 years after radiotherapy and continued until the 3d decade

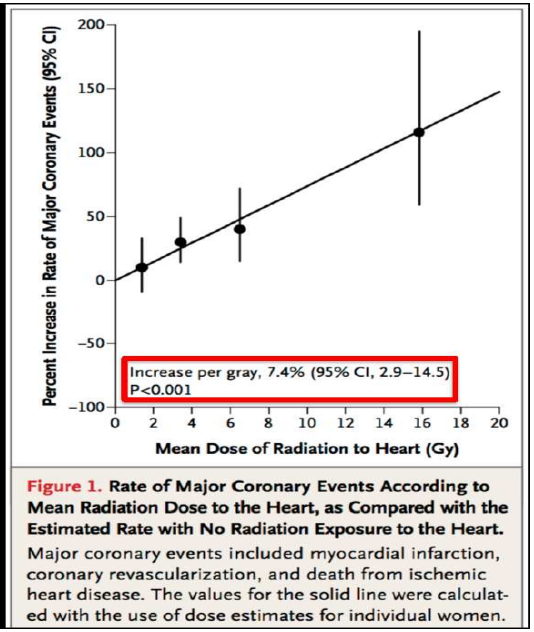

Figure 1. Rate of Major Coronary Events According to Mean Radiation Dose to the Heart, as Compared with the Estimated Rate with No Radiation Exposure to the Heart.
Major coronary events included myocardial infarction, coronary revascularization, and death from ischemic heart disease. The values for the solid line were calculated with the use of dose estimates for individual women.

ELIGIBILITY CRITERIA

A single study protocol was used, but the selection of case patients and controls varied slightly between the two countries. In Sweden, all women living in Stockholm for whom data were recorded in the Swedish National Cancer Register[15] were considered for the study if they received a diagnosis of breast cancer between 1958 and 2001, were younger than 70 years of age at the time of diagnosis, and had received radiotherapy. In Denmark, all women for whom data were recorded in the register held by the Danish Breast Cancer Cooperative Group[16] were considered for the study if they received the diagnosis of breast cancer between 1977 and 2000, were younger than 75 years at the time of diagnosis, and received radiotherapy. The study was

CARDIAC CONTOURING ATLAS (I)

ELSEVIER

Int. J. Radiation Oncology Biol. Phys., Vol. 79, No. 1, pp. 10–18, 2011
Copyright © 2011 Elsevier Inc.
Printed in the USA. All rights reserved
0360-3016/$–see front matter

doi:10.1016/j.ijrobp.2009.10.058

CLINICAL INVESTIGATION **Breast**

DEVELOPMENT AND VALIDATION OF A HEART ATLAS TO STUDY CARDIAC EXPOSURE TO RADIATION FOLLOWING TREATMENT FOR BREAST CANCER

MARY FENG, M.D.,* JEAN M. MORAN, PH.D.,* TODD KOELLING, M.D.,† AAMER CHUGHTAI, M.D.,‡
JUNE L. CHAN, M.D.,* LAURA FREEDMAN, M.D.,* JAMES A. HAYMAN, M.D.,*
RESHMA JAGSI, M.D., D. PHIL.,* SHRUTI JOLLY, M.D.,* JANICE LAROUERE, M.D.,*
JULIE SORIANO, M.D.,* ROBIN MARSH, C.M.D.,* AND LORI J. PIERCE, M.D.*

Department of *Radiation Oncology; Internal Medicine, Division of †Cardiology and; ‡Radiology, University of Michigan Medical Center, Ann Arbor, Michigan

ESTRO School

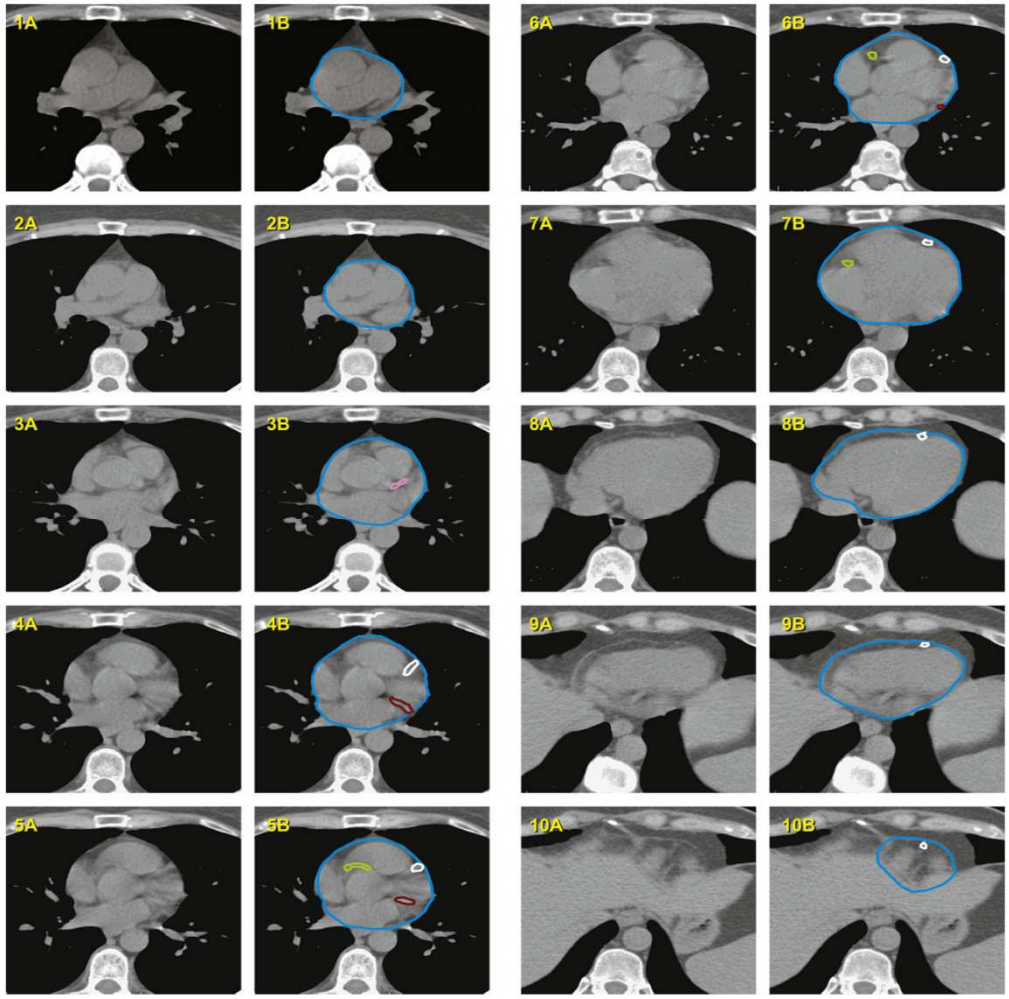

Fig. 1. Cardiac atlas showing scans without IV contrast. Contours are illustrated in the right column, with unmarked images provided in the left column for reference. Colored outlines are explained in the key to Fig. 2.

WHOLE HEART and PERICARDIUM:

- Superiorly: just inferior to the left pulmonary artery.
- Inferiorly: blends with the diaphragm.
- The cardiac vessels should be included in the contours, even if there is no heart muscle visible.

ESTRO School

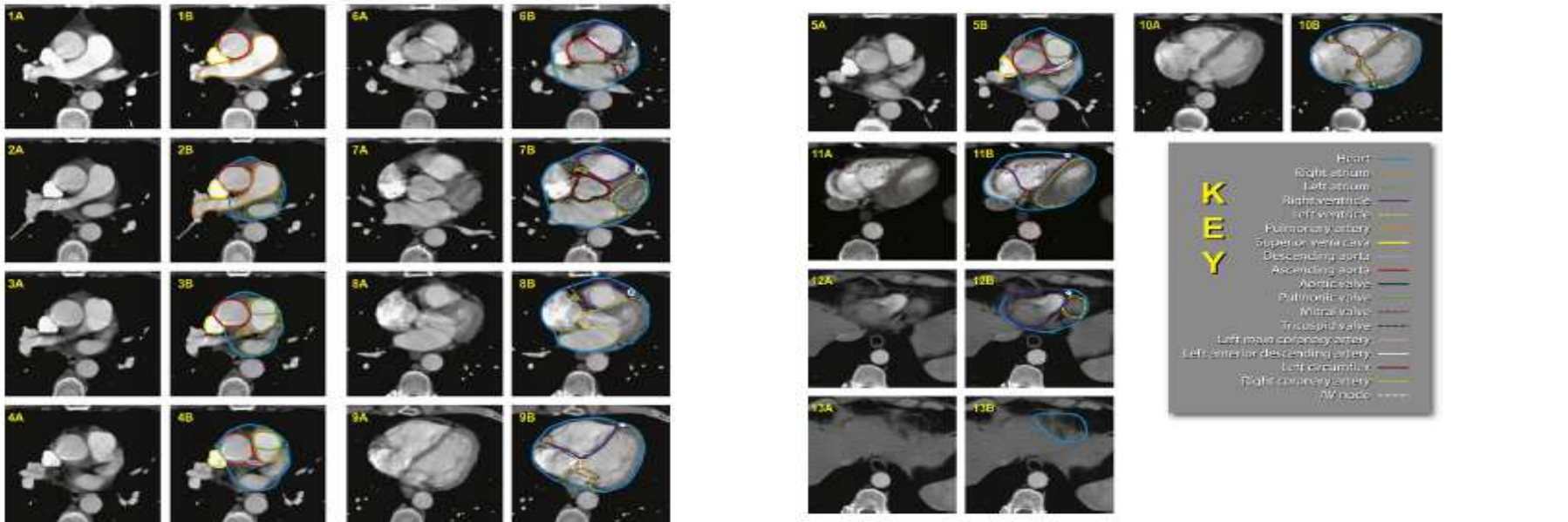

Fig. 2. Cardiac atlas showing scans with IV contrast. Contours are illustrated in the right column, with unmarked images provided in the left column for reference.

CHAMBERS:
- Left atrium: left and posterior to the pulmonary trunk and begins just inferior to the left pulmonary artery.
- Left ventricle: anterior to the left of the left atrium
- Right atrium: starts to the right of the aortic root superiorly.
- Right ventricle: lies directly beneath the sternum and connects to the pulmonary trunk.

VESSELS:
- LM coronary artery: originates from the left side of the ascending aorta, inferior to the right pulmonary artery.
- LAD artery, interventricular branch: originates from the left coronary artery and runs in the interventricular groove between the right and left ventricles.
- Left circumflex artery: originates from the left coronary artery and runs between the left atrium and ventricle.
- RCA: from the right side of the ascending aorta.

ESTRO School

CARDIAC CONTOURING ATLAS (II)

Radiotherapy and Oncology 122 (2017) 416–422

Contents lists available at ScienceDirect

Radiotherapy and Oncology

journal homepage: www.thegreenjournal.com

Cardiac contouring atlas

A cardiac contouring atlas for radiotherapy

Frances Duane [a,b,*], Marianne C. Aznar [a], Freddie Bartlett [c], David J. Cutter [a], Sarah C. Darby [a], Reshma Jagsi [d], Ebbe L. Lorenzen [e], Orla McArdle [f], Paul McGale [a], Saul Myerson [g], Kazem Rahimi [h], Sindu Vivekanandan [i], Samantha Warren [j], Carolyn W. Taylor [a]

[a] *Clinical Trial Service Unit, Nuffield Department of Population Health, University of Oxford;* [b] *Medical Research Council Population Health Research Unit, Nuffield Department of Population Health, University of Oxford;* [c] *Department of Oncology and Haematology, Queen Alexandra Hospital, Portsmouth, UK;* [d] *Department of Radiation Oncology, University of Michigan, Ann Arbor, USA;* [e] *Laboratory of Radiation Physics, Odense University Hospital, Denmark;* [f] *St. Luke's Radiation Oncology Network, Dublin, Ireland;* [g] *Division of Cardiovascular Medicine, Radcliffe Department of Medicine, University of Oxford;* [h] *George Institute for Global Health, University of Oxford;* [i] *CRUK/MRC Oxford Institute for Radiation Oncology, Gray Laboratories, University of Oxford; and* [j] *University of Birmingham NHS Foundation Trust, Birmingham, UK*

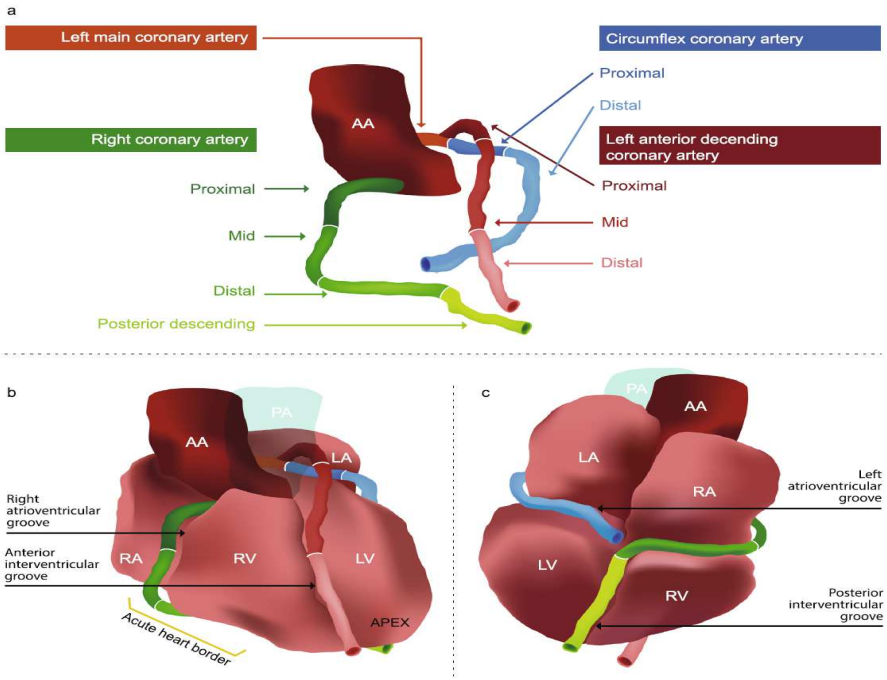

Fig. 3. Coronary artery segmentation. 3D representation of the segments of the three main coronary arteries in relation to the atrial and ventricular chambers, ascending aorta and pulmonary artery. *Abbreviations:* PA: pulmonary artery, AA: ascending aorta, RA: right atrium, LA: left atrium, LV: left ventricle, RV: right ventricle.

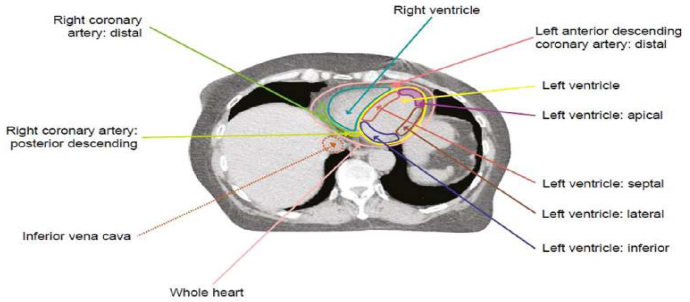

Fig. 2. Axial radiotherapy CT planning image at the level of the left ventricle inferiorly showing contouring of the coronary arterial and left ventricular myocardial segments. See Supplementary Figs. 1–3 for further images.

A reproducible method for contouring left ventricular and coronary arterial segments on radiotherapy CT-planning scans.

(two cardiologists + six radiation oncologists

Definitions identifiable on non-contrast radiotherapy CT-planning scans

ESTRO School

BRACHIAL PLEXUS (I)

Int. J. Radiation Oncology Biol. Phys., Vol. 82, No. 3, pp. 1060–1064, 2012
Copyright © 2012 Elsevier Inc.
Printed in the USA. All rights reserved
0360-3016/$ - see front matter

ELSEVIER

doi:10.1016/j.ijrobp.2010.10.035

CLINICAL INVESTIGATION **Normal Tissue**

VALIDATING THE RTOG-ENDORSED BRACHIAL PLEXUS CONTOURING ATLAS: AN EVALUATION OF REPRODUCIBILITY AMONG PATIENTS TREATED BY INTENSITY-MODULATED RADIOTHERAPY FOR HEAD-AND-NECK CANCER

SUN K. YI, M.D.,* WILLIAM H. HALL, M.D.,* MATHEW MATHAI, C.M.D.,* ARTHUR B. DUBLIN, M.D.,† VISHAL GUPTA, M.D.,* JAMES A. PURDY, PH.D.,* AND ALLEN M. CHEN, PH.D.*

Departments of *Radiation Oncology and †Diagnostic Radiology, University of California Davis School of Medicine, Sacramento, California

Purpose: To evaluate interobserver variability for contouring the brachial plexus as an organ-at-risk (OAR) and to analyze its potential dosimetric consequences in patients treated with intensity-modulated radiotherapy (IMRT) for head-and-neck cancer.

Methods and Materials: Using the Radiation Therapy Oncology Group (RTOG)-endorsed brachial plexus contouring atlas, three radiation oncologists independently delineated the OAR on treatment planning computed-tomography (CT) axial scans from 5 representative patients undergoing IMRT to a prescribed dose of 70 Gy for head-and-neck cancer. Dose-volume histograms for the brachial plexus were calculated, and interobserver differences were quantified by comparing various dosimetric statistics. Qualitative analysis was performed by visually assessing the overlapping contours on a single beam's eye view.

Results: Brachial plexus volumes for the 5 patients across observers were 26 cc (18–35 cc), 25 cc (21–30 cc), 29 cc (28–32 cc), 29 cc (23–38 cc), and 29 cc (23–34 cc). On qualitative analysis, minimal variability existed except at the inferolateral portion of the OAR, where slight discrepancies were noted among the physicians. Maximum doses to the brachial plexus ranged from 71.6 to 72.6 Gy, 75.2 to 75.8 Gy, 69.1 to 71.0 Gy, 76.4 to 76.9 Gy, and 70.6 to 71.4 Gy. Respective volumes receiving doses greater than 60 Gy (V60) were 8.6 to 10.9 cc, 6.2 to 8.1 cc, 8.2 to 11.6 cc, 8.3 to 10.5 cc, and 5.6 to 9.8 cc.

Conclusion: The RTOG-endorsed brachial plexus atlas provides a consistent set of guidelines for contouring this OAR with essentially no learning curve. Adoption of these contouring guidelines in the clinical setting is encouraged. © 2012 Elsevier Inc.

Brachial plexus, Contouring atlas, Reproducibility, IMRT, Head and neck.

ESTRO School

1. Identify and contour C5, T1, and T2.
2. Identify and contour the subclavian and axillary neurovascular bundle.
3. Identify and contour anterior and middle scalene muscles from C5 to insertion onto the first rib.
4. To contour the brachial plexus OAR use a 5-mm diameter paint tool.
5. Start at the neural foramina from C5 to T1; this should extend from the lateral aspect of the spinal canal to the small space between the anterior and middle scalene muscles.
6. For CT slices, where no neural foramen is present, contour only the space between the anterior and middle scalene muscles.
7. Continue to contour the space between the anterior and middle scalene muscles; eventually the middle scalene will end in the region of the subclavian neurovascular bundle.
8. Contour the brachial plexus as the posterior aspect of the neurovascular bundle inferiorly and laterally to one to two CT slices below the clavicular head.
9. The first and second ribs serve as the medial limit of the OAR contour.

Fig. 1. Step-by-step guidelines for contouring the brachial plexus on axial CT images (http://rtog.org/atlases/BrachialAtlas/Brachial%20plexus%20contouring.pdf) (8).

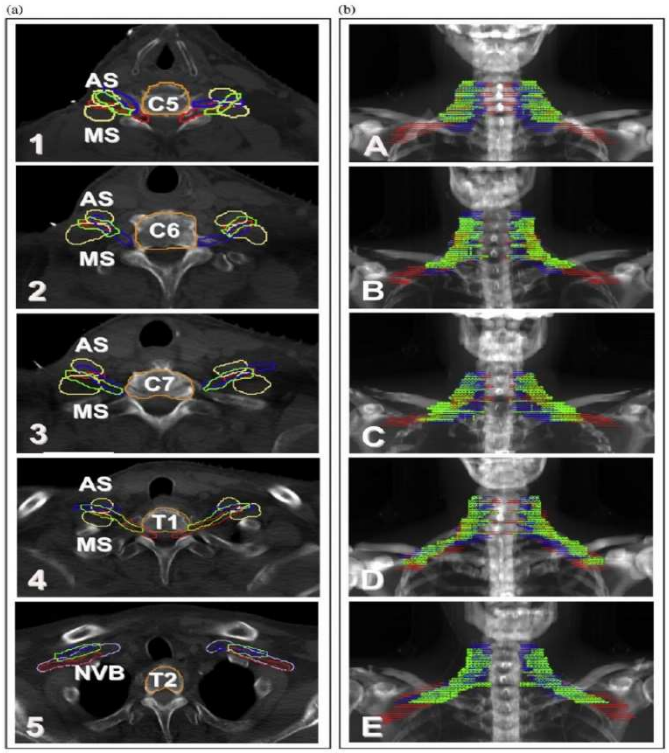

Fig. 2. (a, panels 1–5) Axial sections from vertebral levels C5 to T2 showing brachial plexus contours by three independent radiation oncologists in green, blue, and red. The brachial plexus is contoured from the lateral border of the neural foramina to the lateral portion of the scalene muscles. From levels C5 through T1, the brachial plexus lies between the anterior scalene (AS) and middle scalene (MS) muscles (shown in yellow [panels 1–4]). At the T2 vertebral level and inferolaterally, the brachial plexus is contoured posterior to the subclavian/axillary neurovascular bundle (NVB) as seen in purple. Qualitative variability among observers seemed to occur most at this level and inferolaterally (panel 5). (b, panels A–E). Beam's eye view of overlapping reconstructed brachial plexus contours from 5 representative patients (A–E) as seen in the anteroposterior view. Brachial plexus contours for patient E were reconstructed from axial contours shown to the left in Fig. 2a. Colors (green, blue, and red) represent each radiation oncologist's brachial plexus contours across all 5 patients and correlate to those observed in the axial images in Fig. 2a.

ESTRO School

BRACHIAL PLEXUS (II)

International Journal of
Radiation Oncology
biology • physics

www.redjournal.org

Physics Contribution

An Anatomically Validated Brachial Plexus Contouring Method for Intensity Modulated Radiation Therapy Planning

Joris Van de Velde, MSc,*,† Emmanuel Audenaert, MD, PhD,§ Bruno Speleers, MSc,† Tom Vercauteren, MSc,† Thomas Mulliez, MD,† Pieter Vandemaele, Ir ‡ Eric Achten, MD, PhD,‡ Ingrid Kerckaert, MD, PhD,* Katharina D'Herde, MD, PhD,* Wilfried De Neve, MD, PhD,† and Tom Van Hoof, MSc, PhD*

*Department of Anatomy; †Department of Radiotherapy; ‡Department of Radiology; and §Department of Physical Medicine and Orthopedic Surgery, Ghent University, Ghent, Belgium

Received Feb 13, 2013, and in revised form Jul 17, 2013. Accepted for publication Aug 2, 2013

ESTRO School

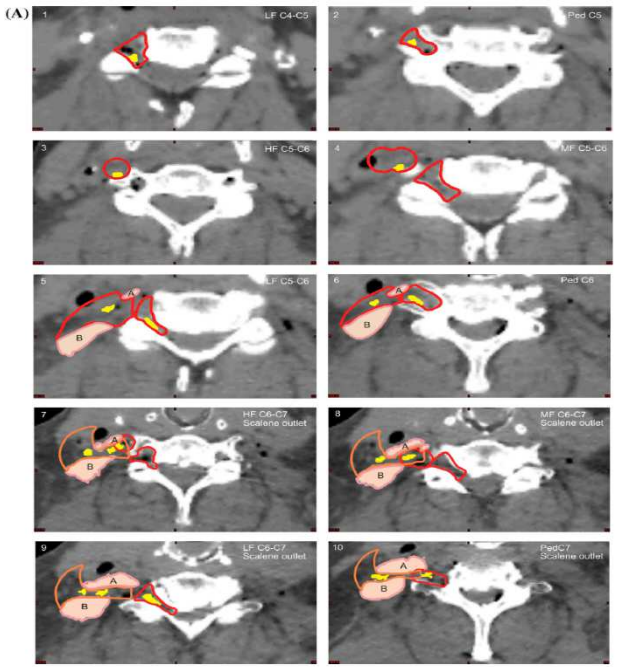

Fig. 4. Axial computed tomographic sections for every delineation level for 1 cadaver. (A) Delineation levels from low facet C4-C5 up to pedicular C7 are shown and labeled sequentially, 1-10. (B) Delineation levels from mid facet C7-T1 up to the muscular triangle (most lateral) are shown and labeled sequentially, 11-18. The brachial plexus contouring area is shown for each independent region: red (vertebral region), yellow (brachial plexus), pink (muscles), orange (scalene outlet), blue (subclavius-serratus outlet), green (additional first rib delineation), and purple (muscular triangle). The total delineation area at each level represents a summation of the delineations for each region: HF = high facet level; MF = mid facet level; LF = low facet level; ped = pedicular level. A = anterior scalene; B = middle scalene; C = serratus anterior; D = subclavian muscle; E = minor pectoral; F = coracobrachial muscle; G = subscapular muscle.

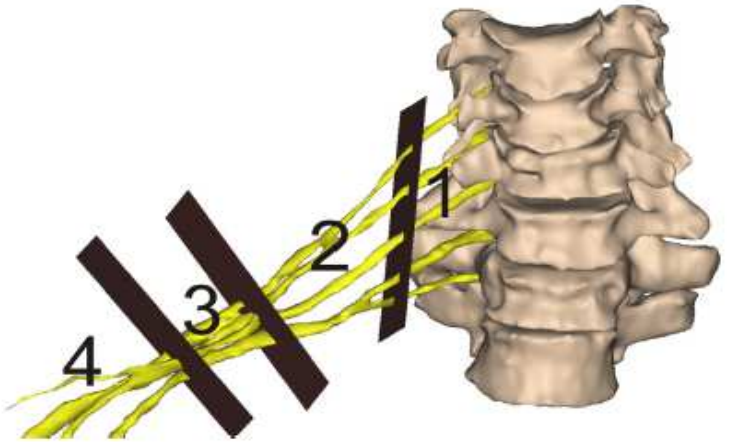

Fig. 1. Division of the course of the brachial plexus into 4 anatomic regions to independently superimpose these regions relative to proximal reference structures. 1, vertebral region; 2, scalene outlet; 3, subclavius-serratus outlet; 4, muscle triangle.

Using MRI and cadaveric models

ESTRO School

- Introduction
- Indications and CTV:
  - Breast
  - Boost. Partial Breast Irradiation
  - Chestwall
  - Regional nodal
    - L4, L3, L2, L1, IM, Rotter
- Organs at risk
- **Margins: CTV to PTV and OAR to PRV**
- Conclusions

ESTRO School

CTV to PTV (Planning Target Volume)
OAR to PRV (Planning Organs at Risk Volume)

ICRU (International Comission on Radiation Units and Mesuraments) 50 and 62

CTV margin for creating PTV:
- geometrical errors
- internal motion of CTV
- treatment technique (beam orientation)
- intra and interfractional errors (patient fixation, daily setup errors)

OAR margin for creating PRV: movements of the OAR due to the change in size and setup uncertainities

ESTRO School

CTV to PTV (Planning Target Volume)
OAR to PRV (Planning Organs at Risk Volume)

The recommended CTV margin to create PTV is at least 5 mm.

But, PTV outside skin can't be used for dosimetric calculations (air, outside the body ...).

Typical solutions in free breath treatments:

- To crop PTV by 3 mm (without reaching the skin) but treatment planning carried out with 2-3 cm
- To create PTV outside the body (margin for breathing) without croping. An additional "cropped" PTV volume will then be needed for normalization purposes and DVH analysis

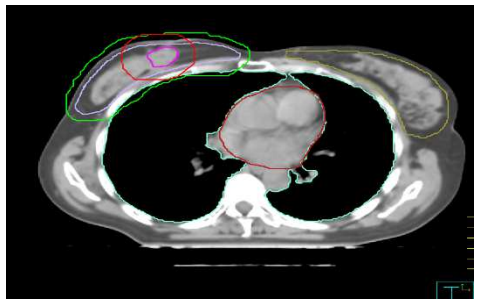

ESTRO School

- Introduction
- Indications and CTV:
  - Whole Breast
  - Boost
  - Chest wall
  - Regional nodes
    - L4, L3, L2, L1, IM, Rotter
- Organs at risk
- Margins CTV to PTV and OAR to PRV
- **Conclusions**

ESTRO School

CONCLUSIONS

- Irradiation of breast cancer involves a variety of clinical situations and individualized treatment for each patient should be designed
- We need clear criteria for CTV and OAR delineation. There are several guidelines (RTOG, DBCG, PROCAB, ESTRO) to follow.
- We need adequate positioning, immobilization and verification systems

A proper volume delineation is CRUCIAL

ESTRO School

QUICK GUIDE

Breast or chest wall:

CRANIAL: Clinical reference, maximally up to inferior edge sterno-clavicular joint
CAUDAL: Breast end (chest wall: guided by contralateral breast)
ANT: 5 mm skin (if possible) or skin (RTOG)
POST: Pectoral M
LAT: Clinical reference, anterior to the lateral thoracic artery
MEDIAL: Sternal-rib junction; perforating mammary vessels

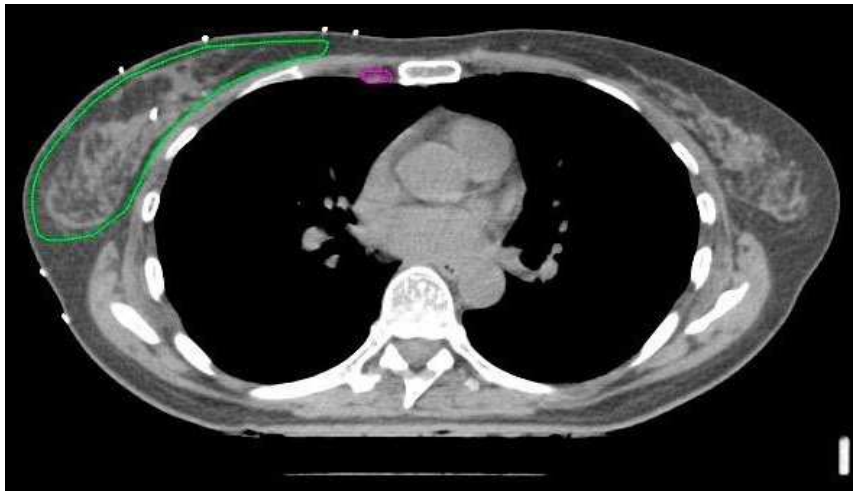

ESTRO School

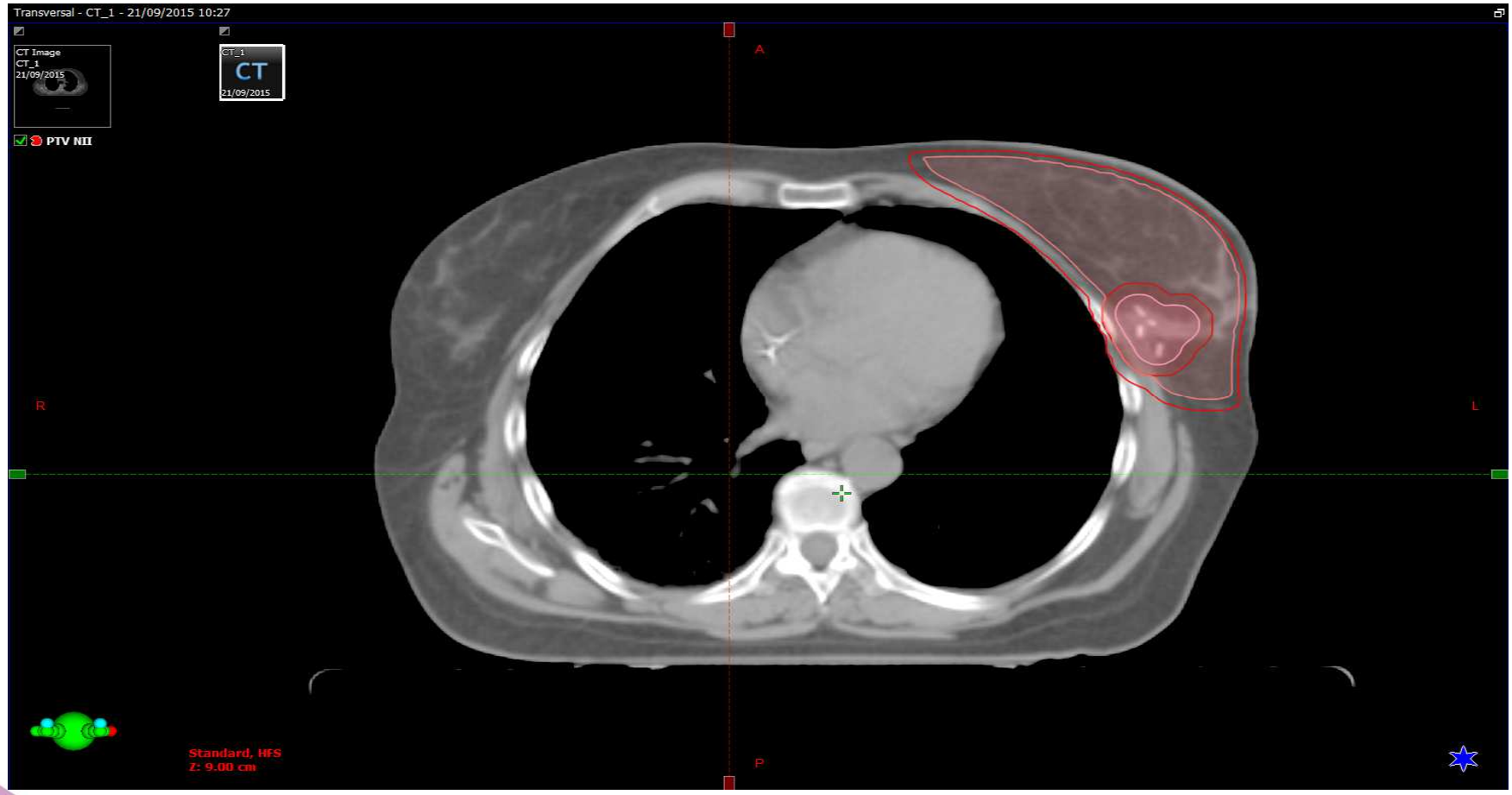

ESTRO School

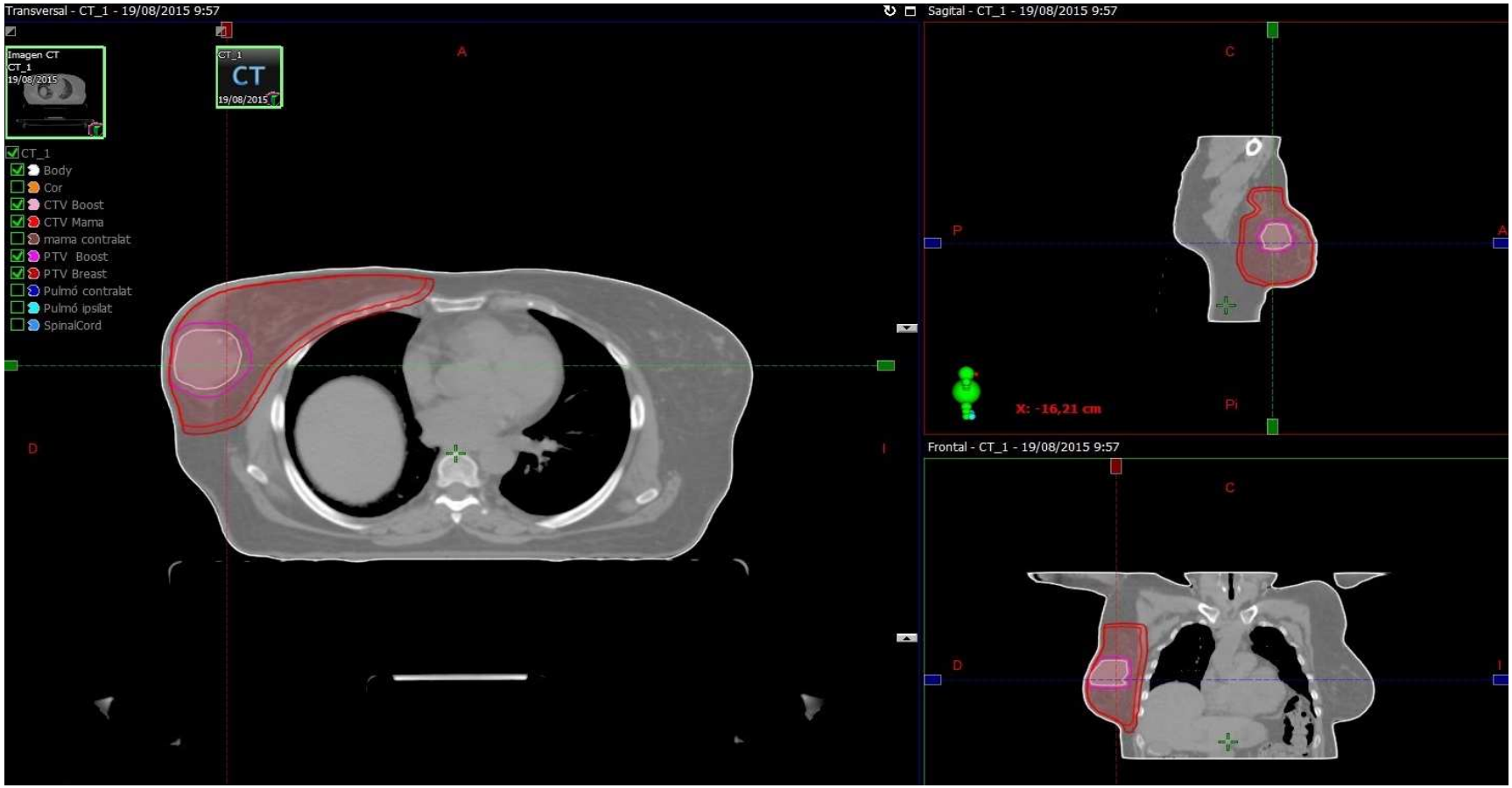
Transversal - CT_1 - 19/08/2015 9:57
Imagen CT
CT_1
19/08/2015
CT_1
CT
19/08/2015
CT_1
Body
Cor
CTV Boost
CTV Mama
mama contralat
PTV Boost
PTV Breast
Pulmó contralat
Pulmó ipsilat
SpinalCord
A
D
I
Sagital - CT_1 - 19/08/2015 9:57
C
P
A
X: -16,21 cm
Pi
Frontal - CT_1 - 19/08/2015 9:57
C
D
I

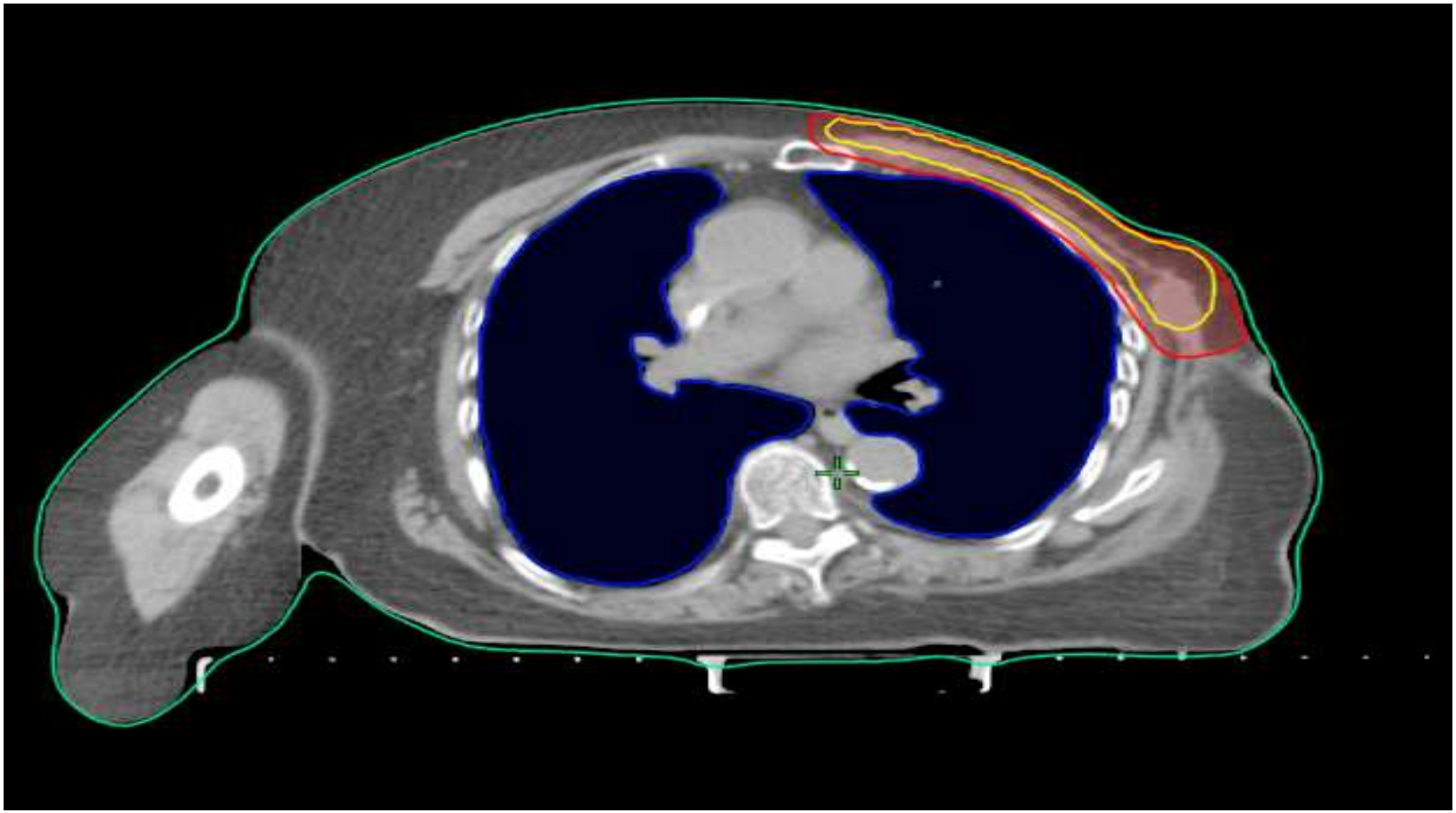

ESTRO School

QUICK GUIDE

L1: caudally to pectoralis major

CRANIAL: Where the axillary vessels cross lateral edge of pectoral minor
CAUDAL: Pectoral major insert into ribs
ANT: Pectoralis major and minor
POST: Subscapularis muscle
LAT: Imaginary line between pectoral major and deltoid / latissiumus dorsi
MEDIAL: Lateral border pectoral minor

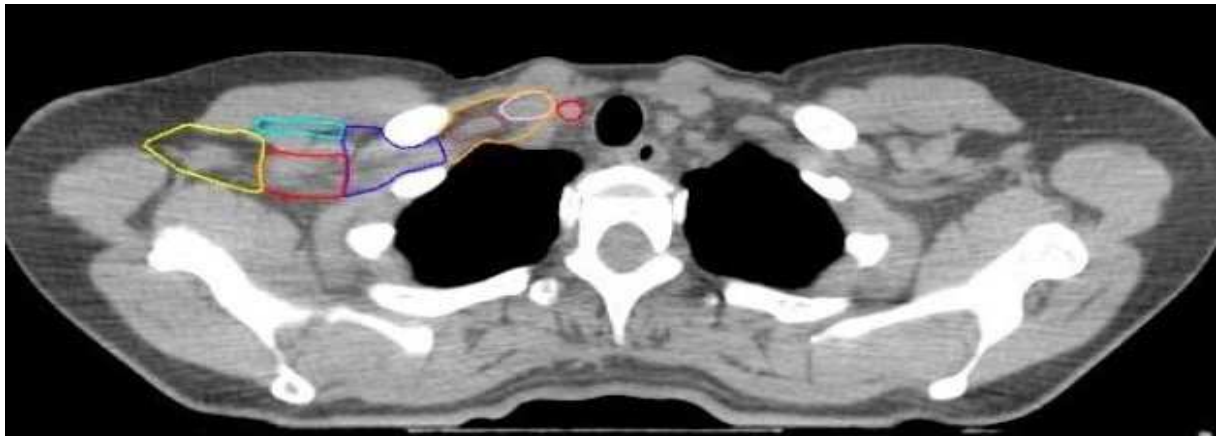

ESTRO School

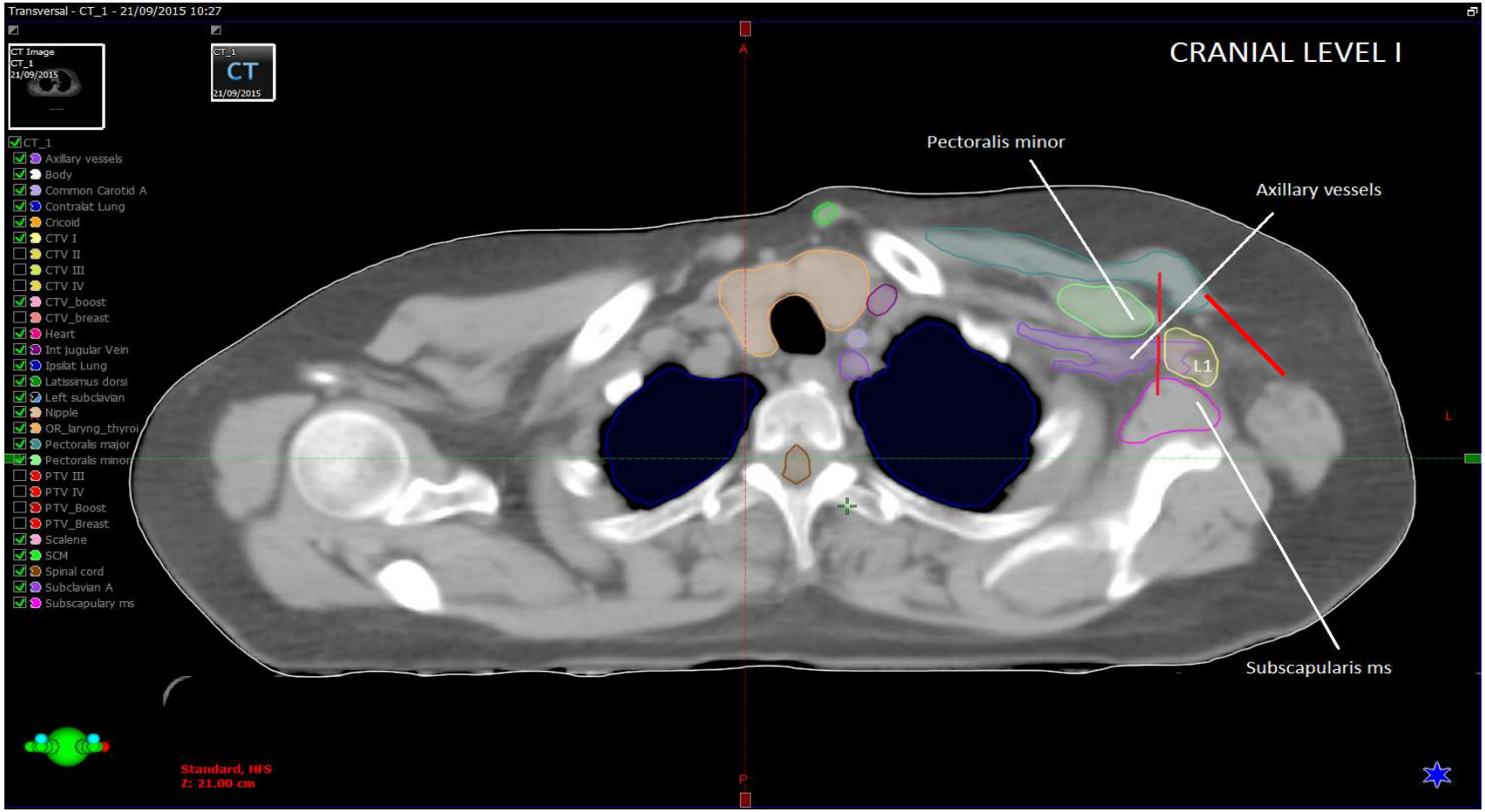
Transversal - CT_1 - 21/09/2015 10:27
CT Image
CT_1
21/09/2015
CT_1
CT
21/09/2015
CRANIAL LEVEL I
Pectoralis minor
Axillary vessels
L1
Subscapularis ms
CT_1
Axillary vessels
Body
Common Carotid A
Contralat Lung
Cricoid
CTV I
CTV II
CTV III
CTV IV
CTV_boost
CTV_breast
Heart
Int jugular Vein
Ipsilat Lung
Latissimus dorsi
Left subclavian
Nipple
OR_laryng_thyroi
Pectoralis major
Pectoralis minor
PTV III
PTV IV
PTV_Boost
PTV_Breast
Scalene
SCM
Spinal cord
Subclavian A
Subscapulary ms
Standard, HFS
Z: 21.00 cm
A
P
L

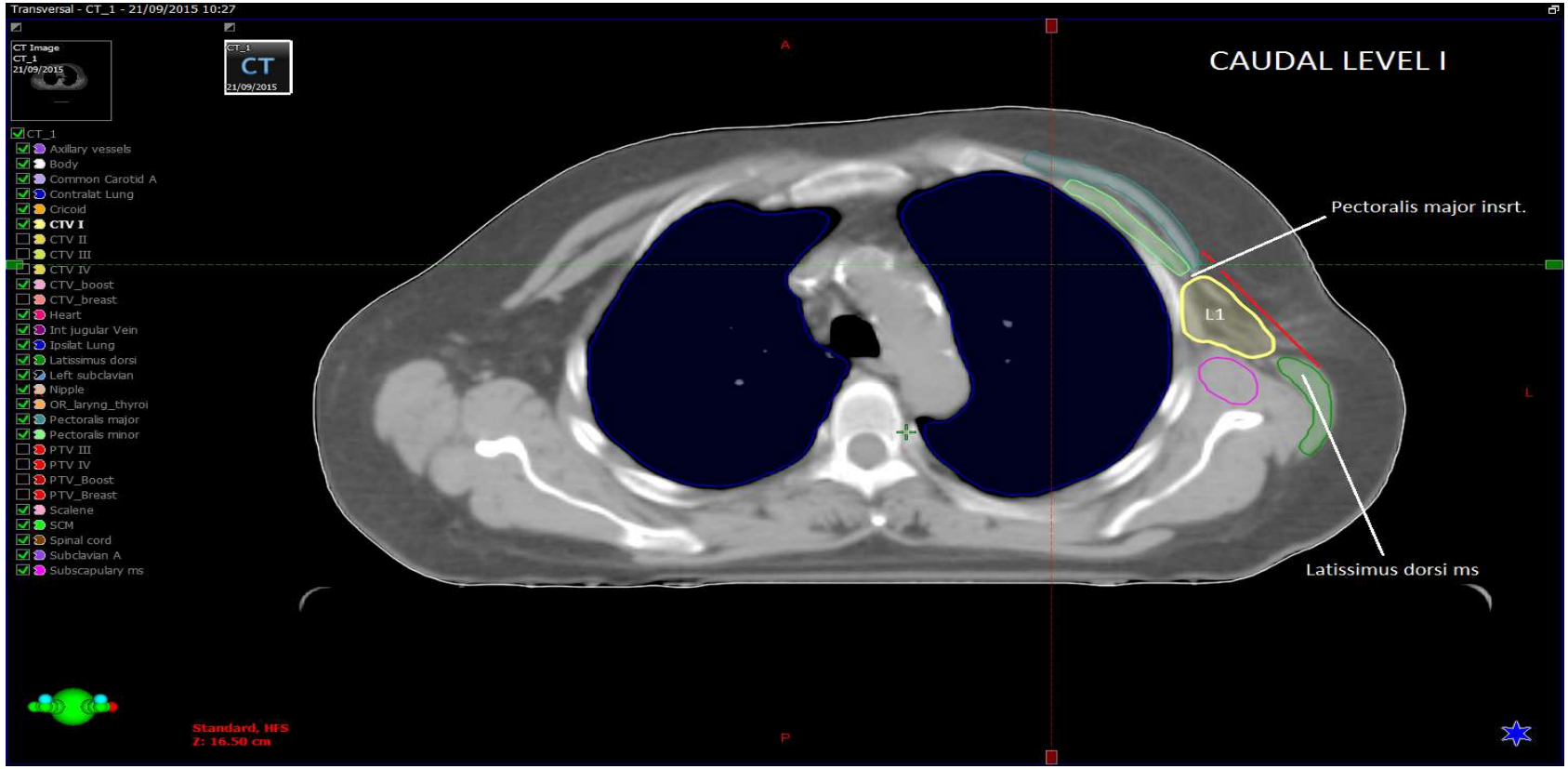
Transversal - CT_1 - 21/09/2015 10:27
CT Image
CT_1
21/09/2015
CT_1
CT
21/09/2015
CT_1
Axillary vessels
Body
Common Carotid A
Contralat Lung
Cricoid
CTV I
CTV II
CTV III
CTV IV
CTV_boost
CTV_breast
Heart
Int jugular Vein
Ipsilat Lung
Latissimus dorsi
Left subclavian
Nipple
OR_laryng_thyroi
Pectoralis major
Pectoralis minor
PTV III
PTV IV
PTV_Boost
PTV_Breast
Scalene
SCM
Spinal cord
Subclavian A
Subscapulary ms
CAUDAL LEVEL I
Pectoralis major insrt.
L1
Latissimus dorsi ms
A
P
L
Standard, HFS
Z: 16.50 cm

QUICK GUIDE

L2: **posterior to pectoral minor muscle**

CRANIAL: Where the axillary vessels cross the medial edge of pectoral minor
CAUDAL: Caudal border pectoral minor
ANT: Pectoralis minor
POST: Ribs and intercostal muscles
LAT: Lateral border pectoral m
MEDIAL: Medial border pectoral m

ESTRO School

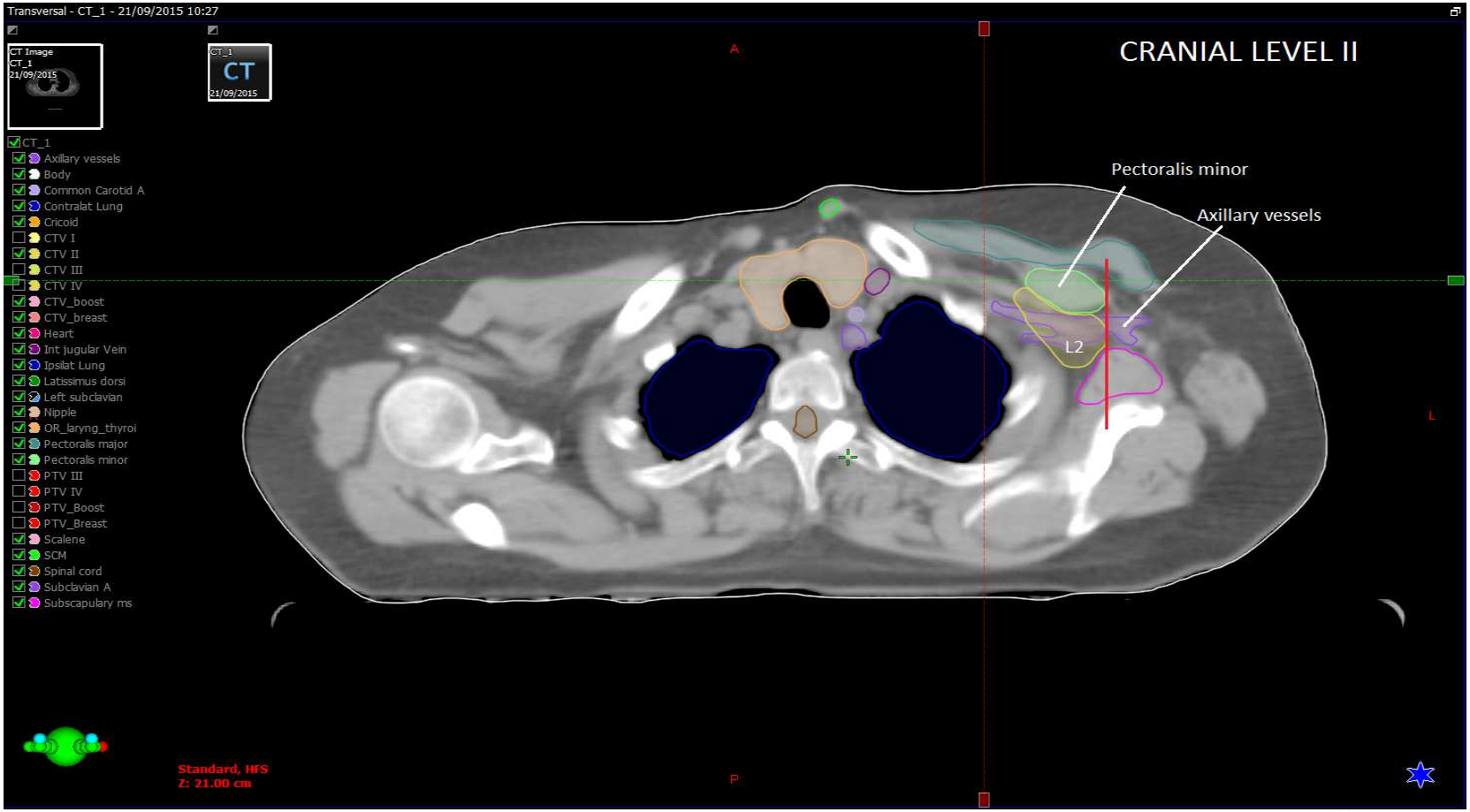
Transversal - CT_1 - 21/09/2015 10:27
CRANIAL LEVEL II
Pectoralis minor
Axillary vessels
L2
CT_1
Axillary vessels
Body
Common Carotid A
Contralat Lung
Cricoid
CTV I
CTV II
CTV III
CTV IV
CTV_boost
CTV_breast
Heart
Int jugular Vein
Ipsilat Lung
Latissimus dorsi
Left subclavian
Nipple
OR_laryng_thyroi
Pectoralis major
Pectoralis minor
PTV III
PTV IV
PTV_Boost
PTV_Breast
Scalene
SCM
Spinal cord
Subclavian A
Subscapulary ms
Standard, HFS
Z: 21.00 cm
A
P
L

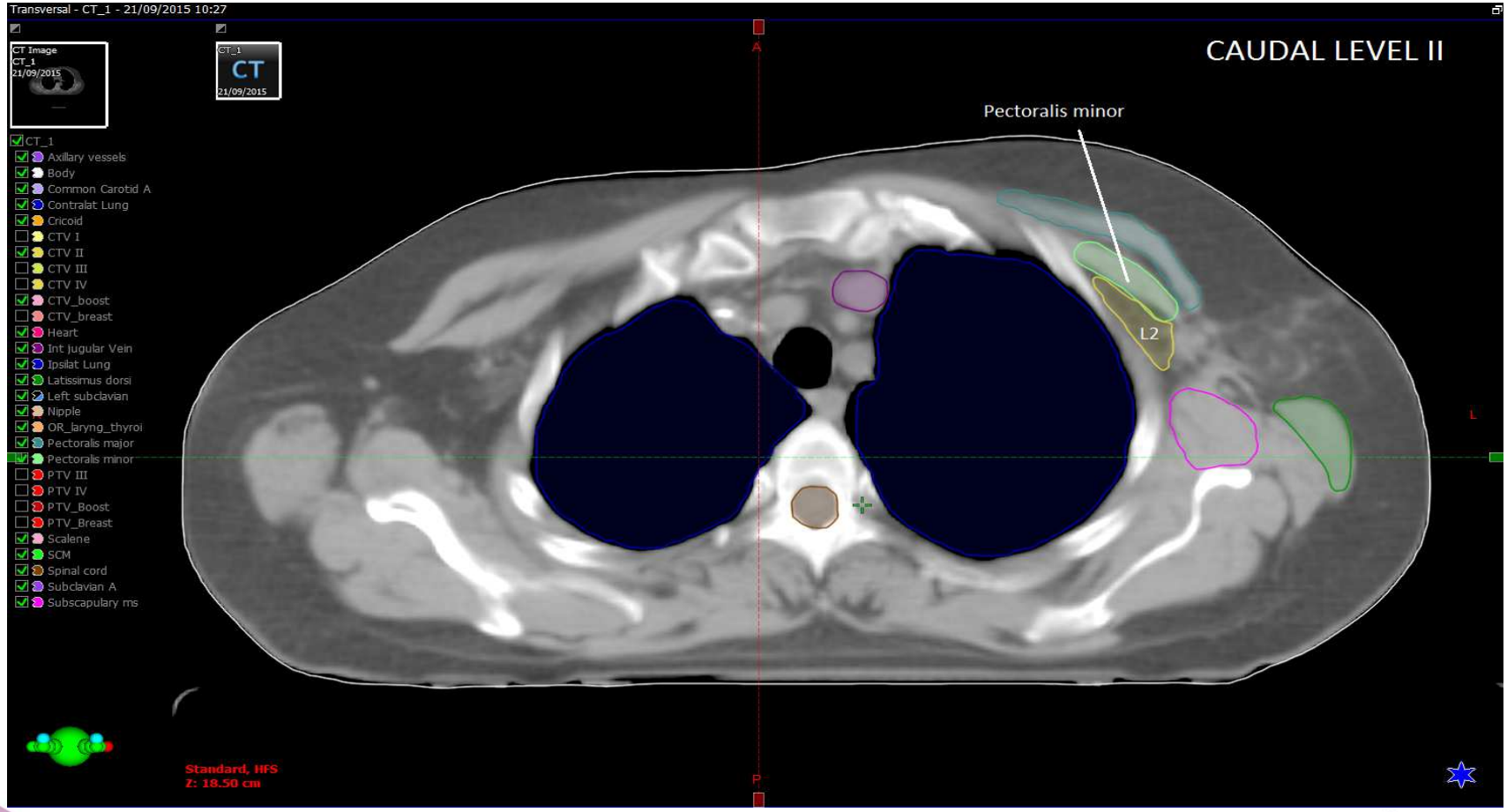
Transversal - CT_1 - 21/09/2015 10:27
CT Image
CT_1
21/09/2015
CT_1
CT
21/09/2015
CAUDAL LEVEL II
Pectoralis minor
L2
CT_1
Axillary vessels
Body
Common Carotid A
Contralat Lung
Cricoid
CTV I
CTV II
CTV III
CTV IV
CTV_boost
CTV_breast
Heart
Int jugular Vein
Ipsilat Lung
Latissimus dorsi
Left subclavian
Nipple
OR_laryng_thyroi
Pectoralis major
Pectoralis minor
PTV III
PTV IV
PTV_Boost
PTV_Breast
Scalene
SCM
Spinal cord
Subclavian A
Subscapulary ms
A
P
L
Standard, HFS
Z: 18.50 cm

QUICK GUIDE

L3: **between the pectoralis muscles and thoracic inlet**

CRANIAL: Cranial subclavian artery or pectoral minor insert on coracoid (RTOG). Where the subclavian artery passes the line between clavicle-1st rib (PROCAB)

CAUDAL: Where the axillary vessels cross the medial edge of pectoral minor

ANT: Pectoralis major

POST: Ribs and intercostal muscles

LAT: Medial border pectoral minor

MEDIAL: The junction of subclavian and internal jugular veins

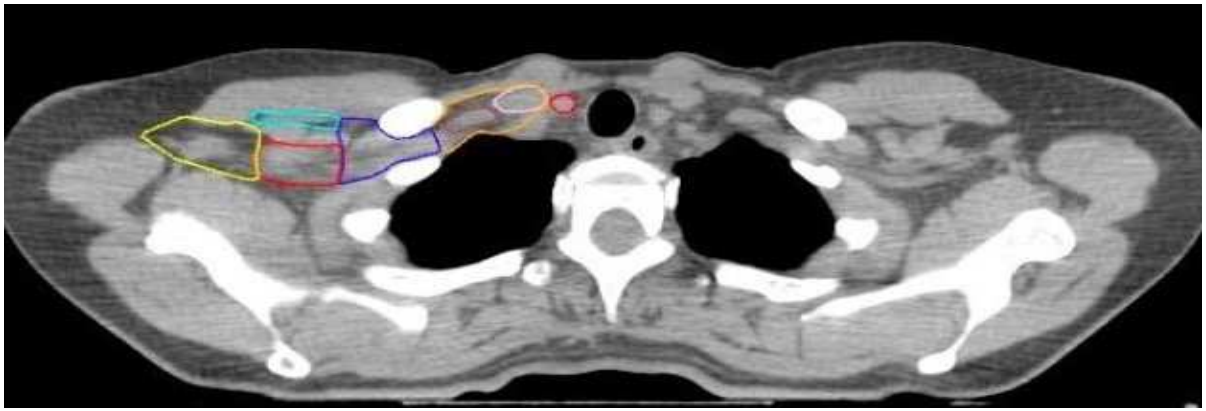

ESTRO School

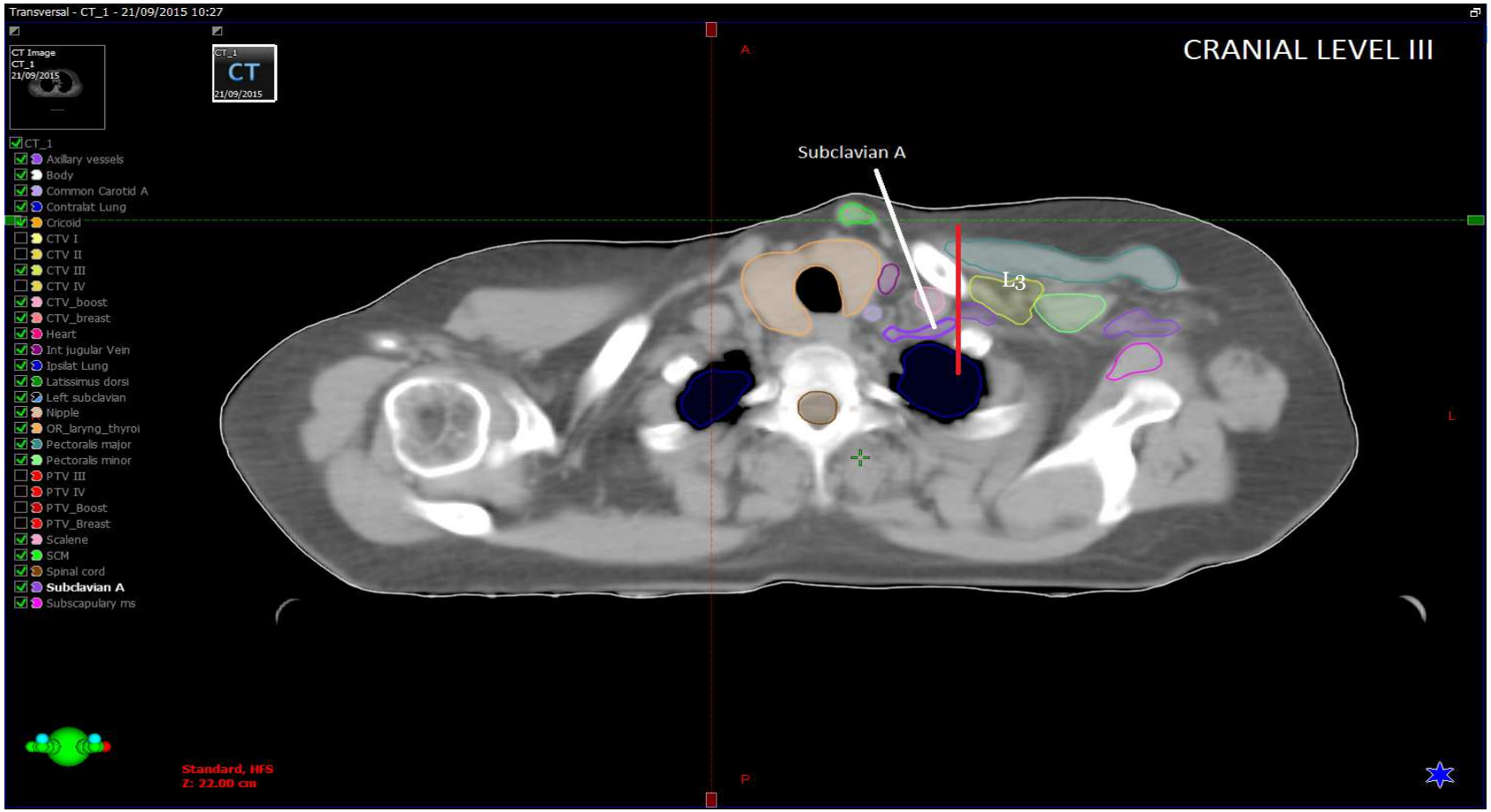
Transversal - CT_1 - 21/09/2015 10:27
CRANIAL LEVEL III
Subclavian A
L3
CT_1
Axillary vessels
Body
Common Carotid A
Contralat Lung
Cricoid
CTV I
CTV II
CTV III
CTV IV
CTV_boost
CTV_breast
Heart
Int jugular Vein
Ipsilat Lung
Latissimus dorsi
Left subclavian
Nipple
OR_laryng_thyroi
Pectoralis major
Pectoralis minor
PTV III
PTV IV
PTV_Boost
PTV_Breast
Scalene
SCM
Spinal cord
Subclavian A
Subscapulary ms
Standard, HFS
Z: 22.00 cm
A
P
L

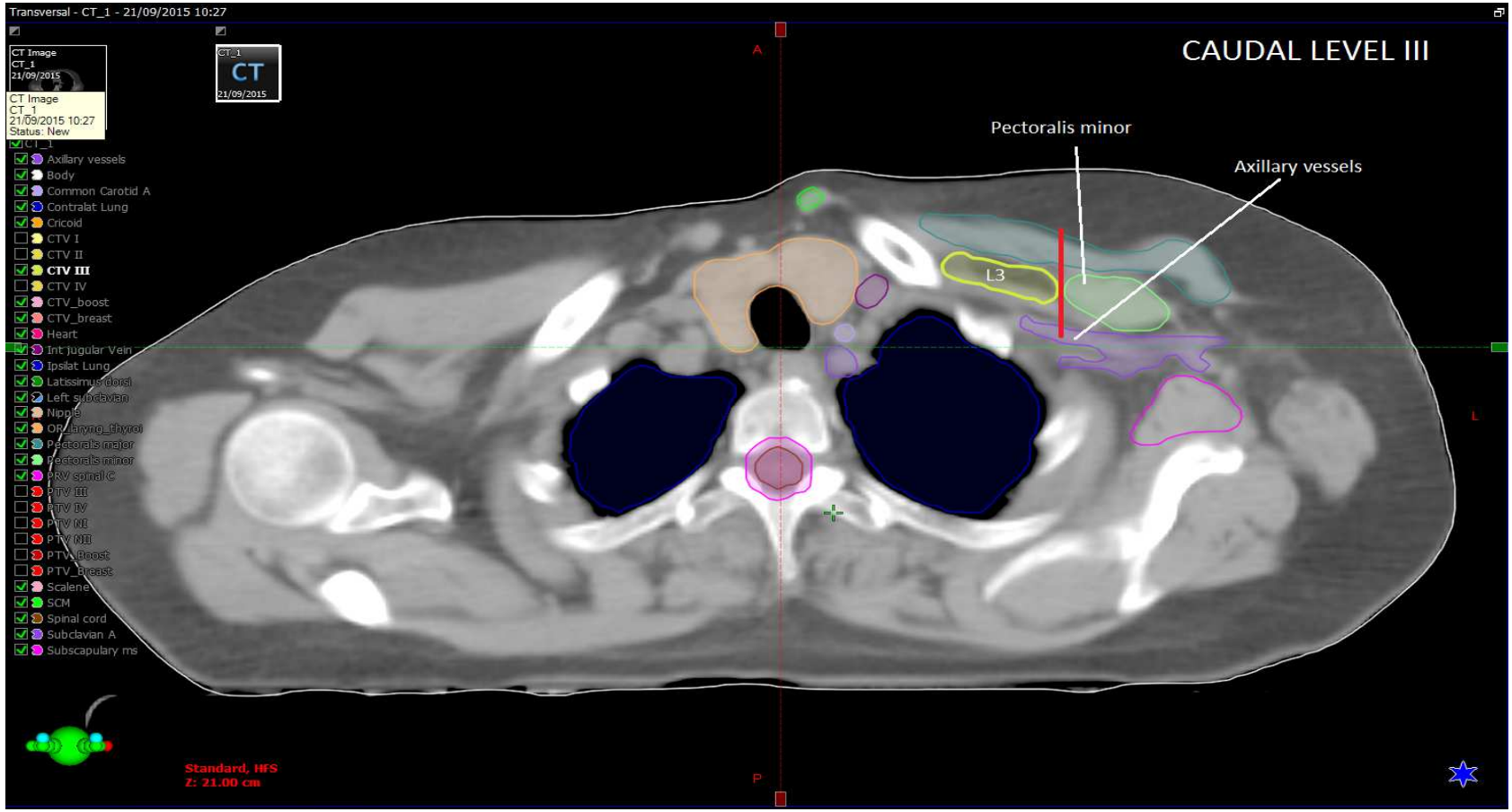
Transversal - CT_1 - 21/09/2015 10:27
CAUDAL LEVEL III
Pectoralis minor
Axillary vessels
L3
CT Image
CT_1
21/09/2015 10:27
Status: New
Axillary vessels
Body
Common Carotid A
Contralat Lung
Cricoid
CTV I
CTV II
CTV III
CTV IV
CTV_boost
CTV_breast
Heart
Int jugular Vein
Ipsilat Lung
Latissimus dorsi
Left subclavian
Nipple
OR_laryng_thyroi
Pectoralis major
Pectoralis minor
PRV spinal C
PTV III
PTV IV
PTV NII
PTV NIII
PTV_Boost
PTV_Breast
Scalene
SCM
Spinal cord
Subclavian A
Subscapulary ms
Standard, HFS
Z: 21.00 cm
A
P
L

QUICK GUIDE

L4:

CRANIAL: Cranial subclavian artery or caudal cricoid (RTOG)
CAUDAL: 5 mm subclavian vein or caudal edge clavicle head (RTOG)
ANT: SCM muscle
POST: Scalene muscle
LAT: Lateral edge of SCM or junction 1st rib-clavicle
MEDIAL: Include: jugular vein. Exclude: common cartotid artery, thyroid

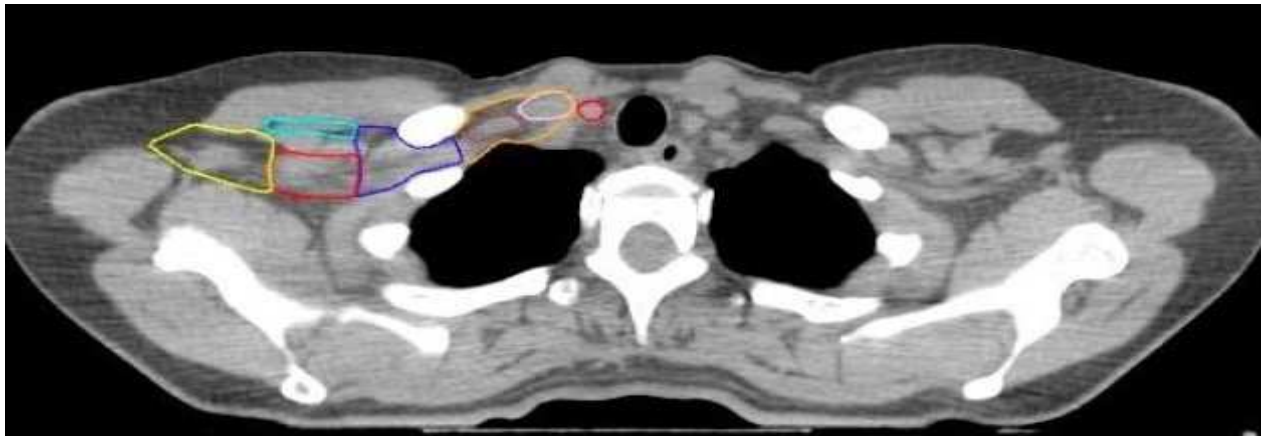

ESTRO School

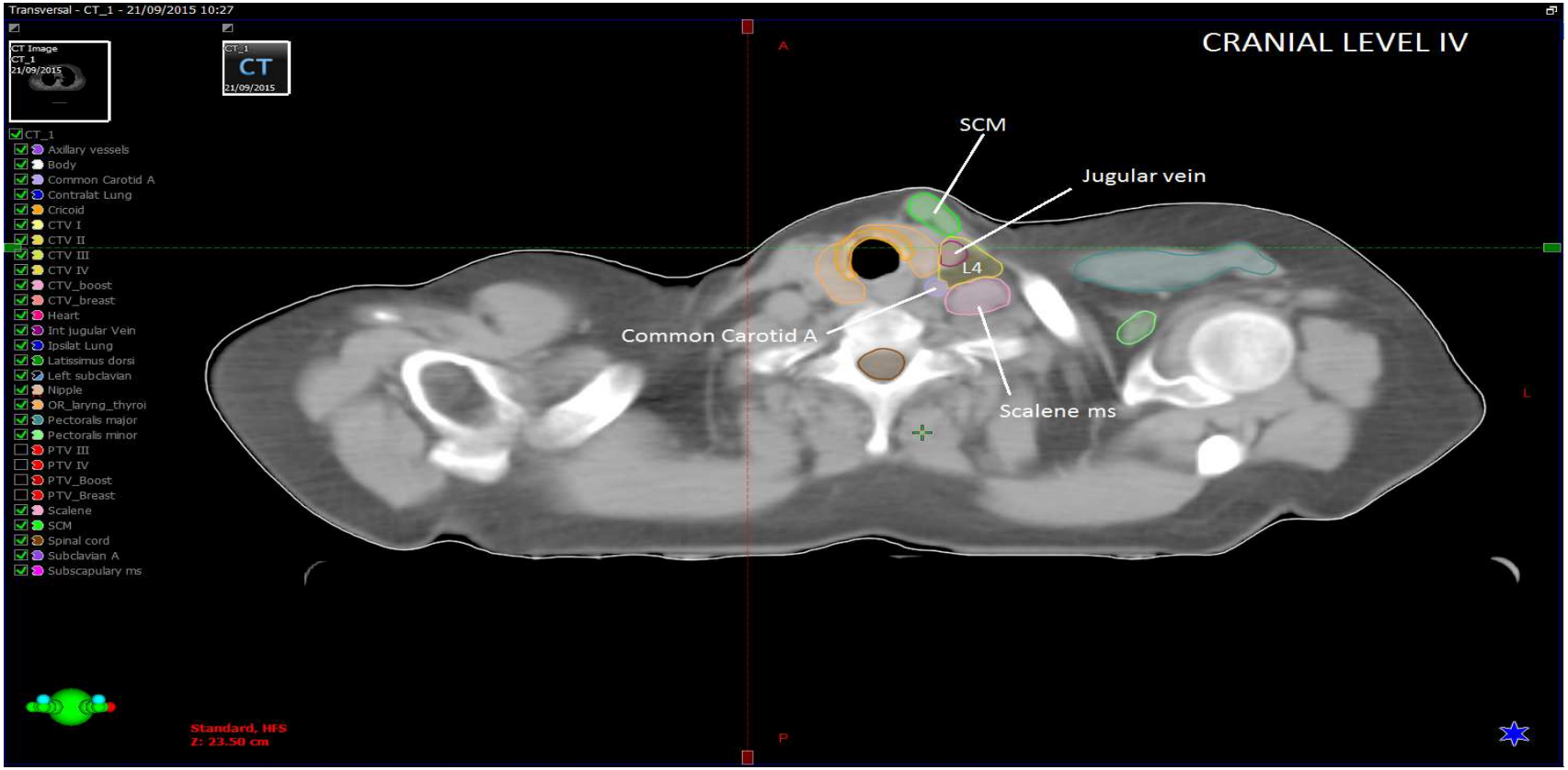
Transversal - CT_1 - 21/09/2015 10:27
CRANIAL LEVEL IV
SCM
Jugular vein
L4
Common Carotid A
Scalene ms
CT_1
Axillary vessels
Body
Common Carotid A
Contralat Lung
Cricoid
CTV I
CTV II
CTV III
CTV IV
CTV_boost
CTV_breast
Heart
Int jugular Vein
Ipsilat Lung
Latissimus dorsi
Left subclavian
Nipple
OR_laryng_thyroi
Pectoralis major
Pectoralis minor
PTV III
PTV IV
PTV_Boost
PTV_Breast
Scalene
SCM
Spinal cord
Subclavian A
Subscapulary ms
Standard, HFS
Z: 23.50 cm

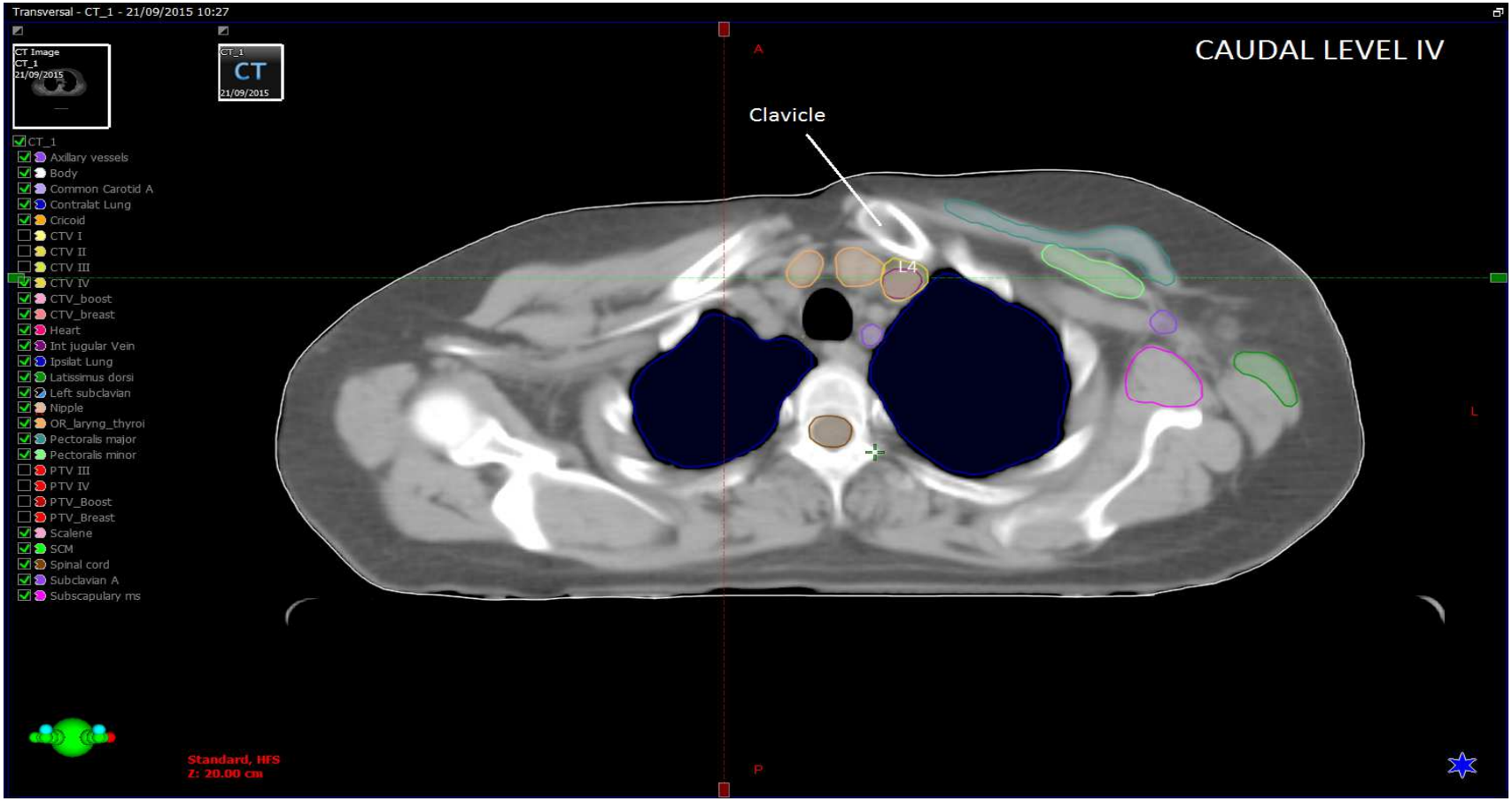
Transversal - CT_1 - 21/09/2015 10:27
CT Image
CT_1
21/09/2015
CT_1
CT
21/09/2015
CT_1
Axillary vessels
Body
Common Carotid A
Contralat Lung
Cricoid
CTV I
CTV II
CTV III
CTV IV
CTV_boost
CTV_breast
Heart
Int jugular Vein
Ipsilat Lung
Latissimus dorsi
Left subclavian
Nipple
OR_laryng_thyroi
Pectoralis major
Pectoralis minor
PTV III
PTV IV
PTV_Boost
PTV_Breast
Scalene
SCM
Spinal cord
Subclavian A
Subscapulary ms
A
CAUDAL LEVEL IV
Clavicle
L4
L
P
Standard, HFS
Z: 20.00 cm

QUICK GUIDE

IMN: First 3-4 intercostal spaces

Rotter Nodes: Between pectoralis M and m

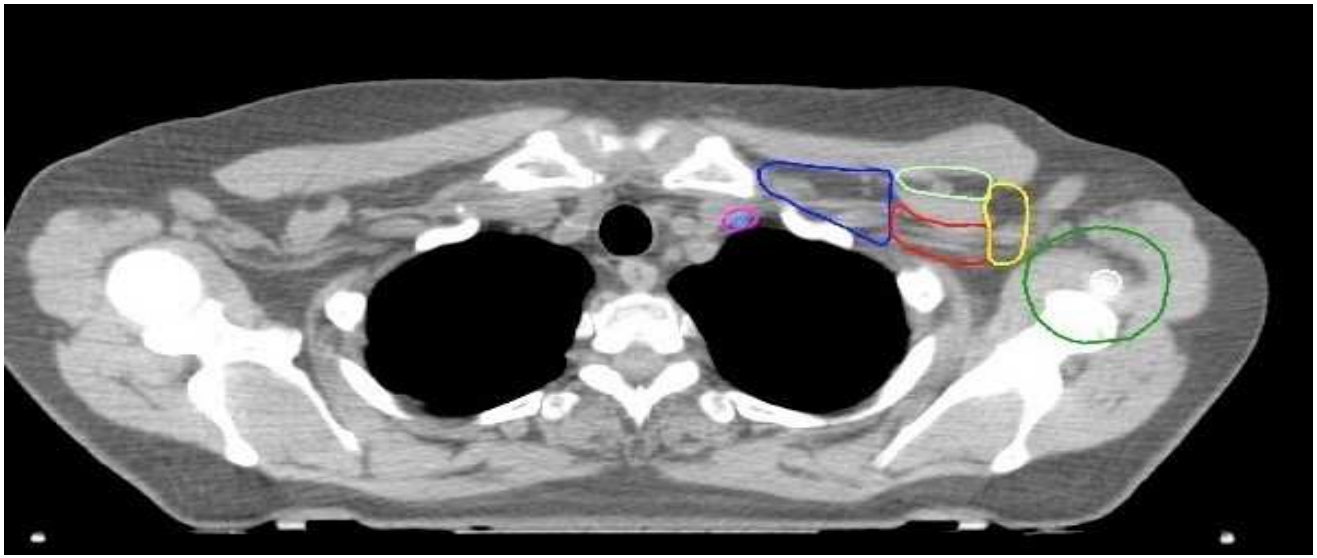

ESTRO School

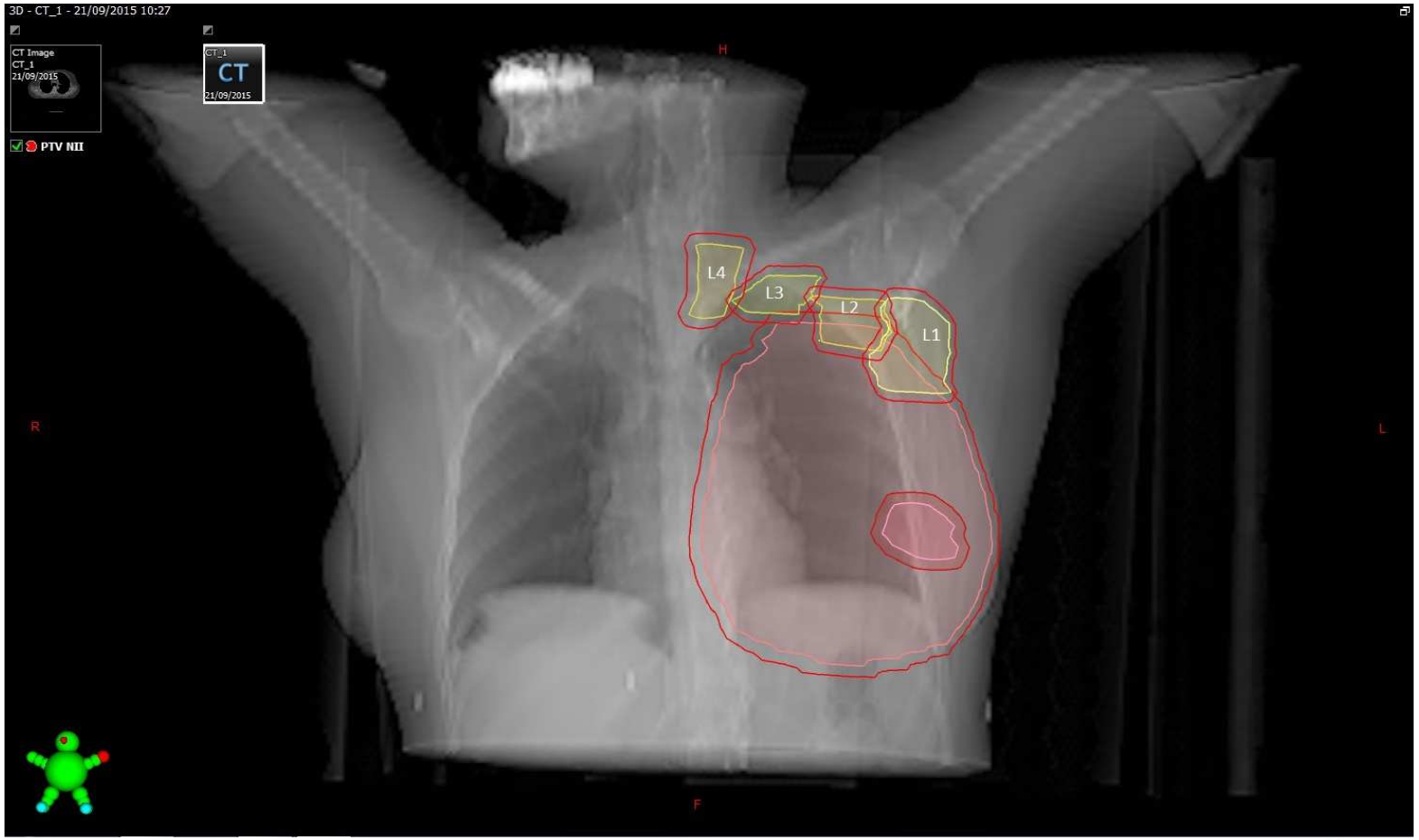
3D - CT_1 - 21/09/2015 10:27
CT Image
CT_1
21/09/2015
CT_1
CT
21/09/2015
PTV NII
H
R
L
F
L4
L3
L2
L1

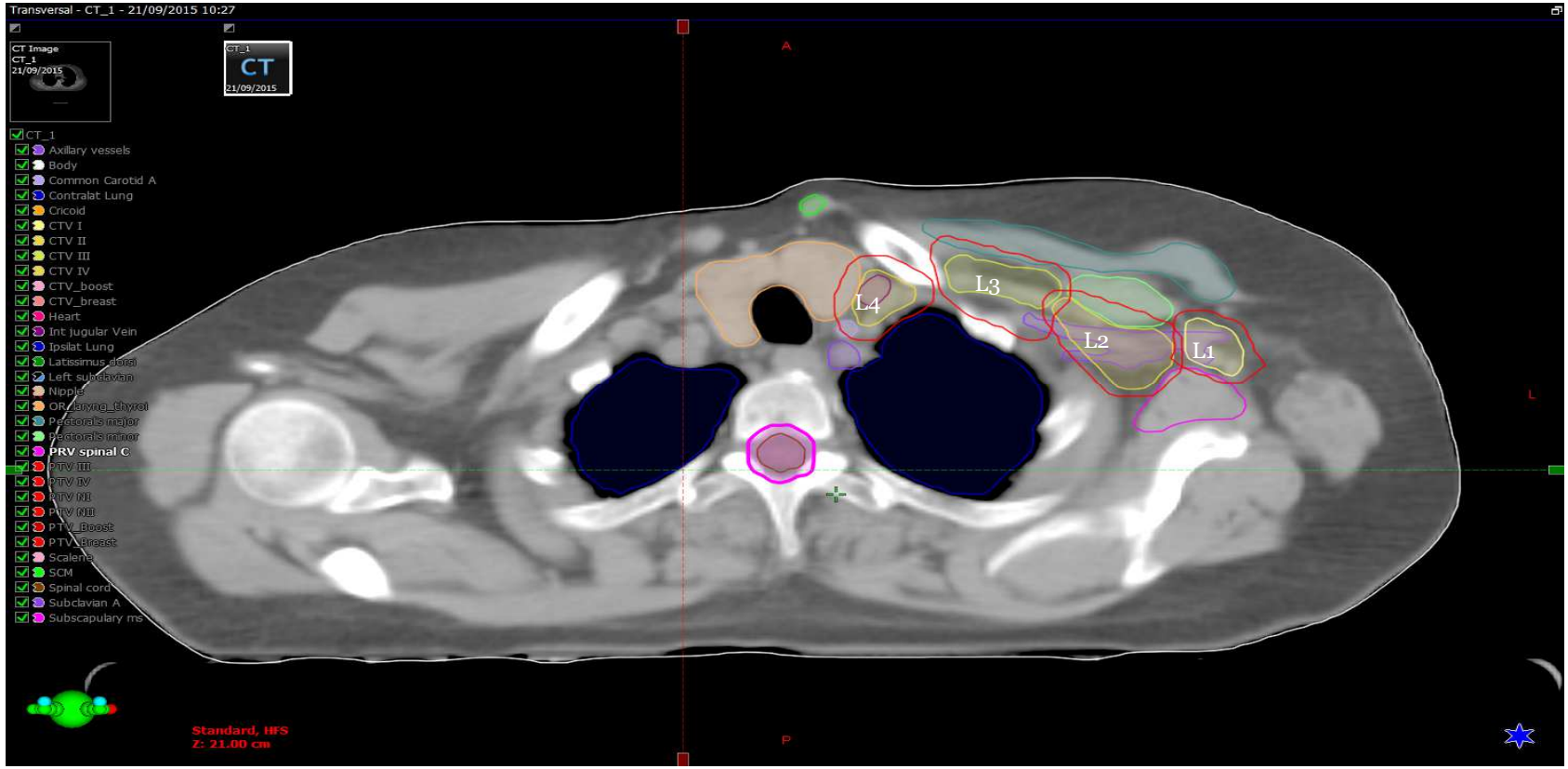
Transversal - CT_1 - 21/09/2015 10:27
CT Image
CT_1
21/09/2015
CT_1
CT
21/09/2015
CT_1
Axillary vessels
Body
Common Carotid A
Contralat Lung
Cricoid
CTV I
CTV II
CTV III
CTV IV
CTV_boost
CTV_breast
Heart
Int jugular Vein
Ipsilat Lung
Latissimus dorsi
Left subclavian
Nipple
OR_Larynq_thyroi
Pectoralis major
Pectoralis minor
PRV spinal C
PTV III
PTV IV
PTV NI
PTV NII
PTV_Boost
PTV_Breast
Scalene
SCM
Spinal cord
Subclavian A
Subscapulary ms
A
P
L
L4
L3
L2
L1
Standard, HFS
Z: 21.00 cm

CRANIAL

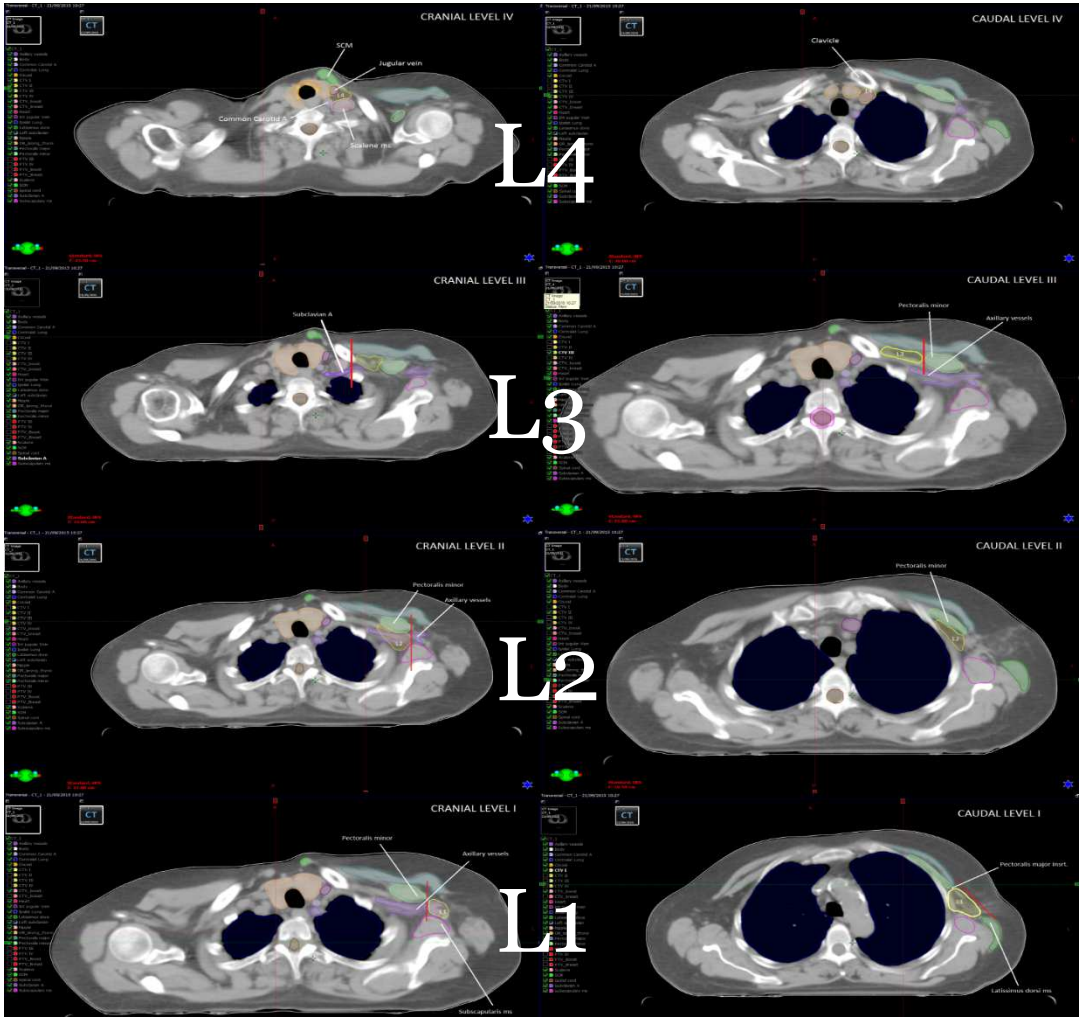

CAUDAL

ESTRO School

Acknowledgements:

Merixell Arenas
Magda Font
Víctor Hernández
Glòria Baldó
Xavi Fillat
.....

Kilian Jornet: climbed in may 2017 the north face of Mount Everest (8.848m) in a single push, twice in a week, without oxygen nor fixed ropes.

Gràcies!

bonet.marta@gmail.com
mbonet@grupsagessa.cat

ESTRO School