ESTRO School

ESTRO Course Book

Target Volume Determination

From Imaging to Margins

4 - 7 October, 2015
Budapest, Hungary

NOTE TO THE PARTICIPANTS

The present slides are provided to you as a basis for taking notes during the course. In as many instances as practically possible, we have tried to indicate from which author these slides have been borrowed to illustrate this course.

It should be realised that the present texts can only be considered as notes for a teaching course and should not in any way be copied or circulated. They are only for personal use. Please be very strict in this, as it is the only condition under which such services can be provided to the participants of the course.

Faculty

Gert De Meerleer

Disclaimer

EUROPEAN ACCREDITATION COUNCIL
FOR CONTINUING MEDICAL EDUCATION
Institution of the UEMS

The faculty of the teachers for this event has disclosed any potential conflict of interest that the teachers may have.

Programme

Day 1 - Sunday, 4 October		
09:00-09:15	Welcome to the Course & Housekeeping	G. De Meerleer
	Imaging Techniques in Oncology	**Chair: G. De Meerleer**
09:15-09:45	Morphological Imaging Techniques (PET CT included)	S. Delorme
	Discussion	
09:45-10:30	Functional & Biological Imaging Techniques (PET CT included)	S. Delorme
	Discussion	
10:30-11:00	***COFFEE***	
	Radiotherapy Planning	**Chair: E. Troost**
11:00-11:45	ICRU 50, ICRU 62 and beyond	
	Discussion	
11:45-12:15	Image handling	M. Kunze-Busch
	Discussion	
12:15-13:15	***LUNCH***	
13:15-13:45	Workshop Instructions & Organisation	**Faculty**
	Instructions in Computer Setup & Use	
	Clinical Workshop (All delegates)	
13:45-15:15	CNS case	
	H&N case	
15:15-15:45	***COFFEE***	
15:45-16:30	Lung case	
16:30-17:15	Prostate case	

Day 2 - Monday, 5 October		
	Imaging & Margins	**Chair: I. Madani**
08:30-09:00	Inter-Observer Variation in Radiotherapy Delineation	P. Remeijer
	Discussion	
09:00-09:30	From uncertainties to margins	P. Remeijer
	Discussion	
09:30-10:15	Image Registration	M. Kunze-Busch P. Remeijer
	Discussion	
10:15-10:45	***COFFEE***	
	Imaging & Anatomy – Partim Thorax	**Chair: M. Kunze- Busch**
10:45-11:15	Anatomy and Lymph Node Drainage in the Mediastinum	E. Troost
	Breast Cancer	
11:15-11:45	Anatomy and Lymph Node Drainage for Breast Cancer	S. Delorme
11:45-12:45	GTV and CTV for Breast – Delineation of OAR in Breast cancer	M. Arenas
	Discussion	
12:45-13:30	***LUNCH***	
	Lung Cancer	**Chair: B. Carrey**
13:30-14:00	Anatomy & Lymph Node Drainage for Lung Cancer	S. Delorme
	Discussion	
14:00-15:00	GTV and CTV for Lung Cancer - Delineation of OAR in Lung cancer	E. Troost
	Discussion	
15:00-15:30	***COFFEE***	
15:30-16:15	Solution of Lung Case	E. Troost, S. Delorme, P. Remeijer, G. De Meerleer
16:15-17:00	Solution of Prostate Case - Discussion	

Day 3 - Tuesday, 6 October		
	Head & Neck Cancer Cancer	**Chair: I. Madani**
08:30-09:00	Anatomy & Lymph Node Drainage for H&N Cancer	B. Carey
09:00-09:30	CTV of the Elective Neck	I. Madani
09:30-10:00	GTV/CTV of the primary tumor/metastatic lymph node(s) – Delineation of OAR in H&N cancer - Discussion	
10:00-10:30	Solution of H&N Case	I. Madani, P. Remeijer
	Discussion	
10:30-11:00	***COFFEE***	
	CNS Cancer	**Chair: E. Troost**
11:00-11:30	Anatomy for CNS tumors	S. Delorme
11:30-12:30	GTV and CTV for CNS tumours - Delineation of OAR in CNS cancer	S. Jefferies
	Discussion	
12:30-13.00	Solution of CNS Case	N. Burnet, S. Delorme, M. Kunze-Busch
	Discussion	
13:00-14:00	***LUNCH***	
	Upper GI Cancer	**Chair: M. Kunze-Busch**
14:00-14:45	Anatomy and Lymph Node Drainage for Upper GI Cancer.	B. Carey
14:45-15:15	GTV & CTV for Oesophageal Cancer - Delineation of OAR in Oesophagal cancer	N. Gambacorta
	Discussion	
15:15-15:45	***COFFEE***	
15:45-16:30	GTV & CTV for gastric Cancer - Delineation of OAR in Gastric cancer	N. Gambacorta
	Discussion	

Day 4 – Wednesday, 7 October		
	Imaging & Anatomy – Lower GI Cancer	Chair: S. Delorme
08:30-09:00	Anatomy & Lymph Node Drainage for Rectal and anal Cancer	B. Carey
09:00-09:45	GTV and CTV for Rectal Cancer	N. Gambacorta
	Discussion	
09:45-10:30	GTV and CTV for Anal Cancer - Delineation of OAR in Ano-rectal cancer	N. Gambacorta
	Discussion	
10:30-11:00	***COFFEE***	
	Gynaecological Cancer	**Chair: P. Remeijer**
11:00-11:30	Anatomy & Lymph Node Drainage for Gynaecological Cancer	B. Carey
11:30-12:15	GTV and CTV for Cervical Cancer - Delineation of OAR in Cervical cancer	G. De Meerleer
	Discussion	
12:15-12:45	GTV and CTV in the postoperative Gynaecological setting	G. De Meerleer
	Discussion	
12:45-13:45	***LUNCH***	
	Prostate Cancer	**Chair: N. Gambacorta**
13:45-14:15	Anatomy & Lymph Node Drainage for Prostate Cancer	S. Delorme
14:15-15:00	GTV and CTV for Prostate Cancer - Primary Setting	G. De Meerleer
	Discussion	
15:00-15:20	GTV and CTV for Prostate Cancer - Salvage Setting	G. De Meerleer
	Discussion	
15:20-15:40	Delineation of OAR in Prostate cancer	G. De Meerleer
15:40-16:10	***COFFEE***	
	All you ever wanted to know, but always were afraid to ask	
16:10-16:55	The Audience	The Faculty
16:55-17:15	Presentation Ceremony of Course Certificates (in exchange of Course Evaluation Forms)	The Faculty

Faculty

Gert De Meerleer	University Hospital Gent Gent, Belgium Gert.DeMeerleer@uzgent.be
Meritxell Arenas	Hospital University Sant Joan de Reus Barcelona, Spain marenas@grupsagessa.com
Brendan Carey	St. James Institute of Oncology Leeds, United Kingdom brendan.carey@nhs.net
Stefan Delorme	German Cancer Research Center Heidelberg, Germany s.delorme@dkfz-heidelberg.de
Netta Gambacorta	University Clinics A. Gemelli Roma, Italy nettagambacorta@gmail.com
Sarah Jefferies	Addenbrooke's Hospital Cambridge, United Kingdom sarah.jefferies@addenbrookes.nhs.uk
Martina Kunze-Busch	Radboud University Nijmegen Medical Centre Nijmegen, the Netherlands Martina.Kunze-Busch@radboudumc.nl
Indira Madani	University Hospital of zurich Zurich, Switzerland Indira.Madani@usz.ch
Peter Remeijer	Netherlands Cancer Insititute Amsterdam, the Netherlands p.remeijer@nki.nl
Esther Troost	Maastro Clinic Maastricht, the Netherlands esther.troost@maastro.nl

Morphologic imaging techniques

Stefan Delorme

dkfz. GERMAN CANCER RESEARCH CENTER IN THE HELMHOLTZ ASSOCIATION
50 Years – Research for A Life Without Cancer

Acknowledgements

- Marc Kachelrieß, Heidelberg
- Michael Bock, Freiburg

Outline

- Computed tomography
  - How it works
  - Strengths
  - Weaknesses
- Magnetic resonance imaging
  - How it works
  - Strengths
  - Weaknesses
- Ultrasound
  - How it works
  - Strengths
  - Weaknesses

Outline

- Computed tomography
  - How it works
  - Strengths
  - Weaknesses
- Magnetic resonance imaging
  - How it works
  - Strengths
  - Weaknesses
- Ultrasound
  - How it works
  - Strengths
  - Weaknesses

Sir Godfrey Hounsfield

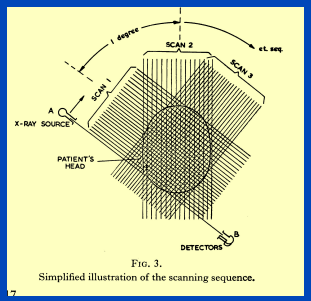

FIG. 3.
Simplified illustration of the scanning sequence.

Generation 3

GE
Philips
Siemens
Toshiba
and others



Generation 3

GE
Philips
Siemens
Toshiba
and others



Generation 4

Elscint
Picker
Marconi
Philips



Generation 4

Elscint
Picker
Marconi
Philips

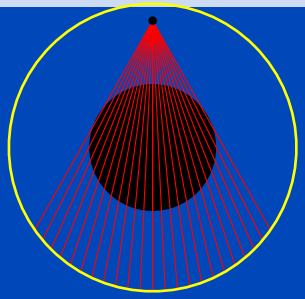

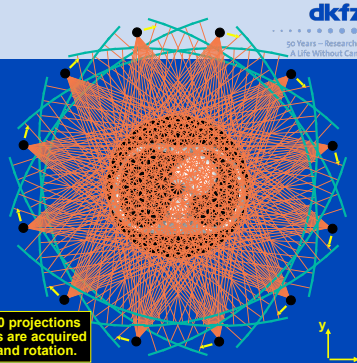

In the order of 1000 projections with 1000 channels are acquired per detector slice and rotation.

Axial Geometry (z-Direction)

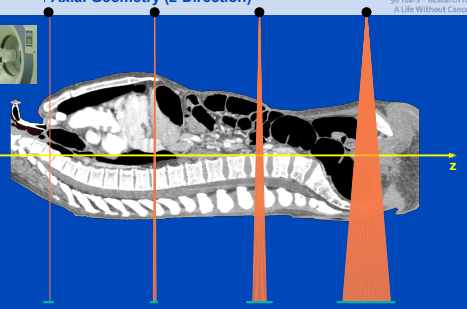

<1998: *M*=1 1998: *M*=4 2002: *M*=16 2006: *M*=64

Dual-source CT

Stefan Delorme
Division of Radiology
21.05.14 |

Siemens 2·2·96=384-slice
dual source cone-beam spiral CT(2013)

525 views (1050 readings) per rotation in 0.25 s
2·96×(920+640) two-byte channels per view
1,200 MB/s data transfer rate
up to 4 GB rawdata, 2 GB volume size typical

EMI parallel beam scanner (1972)

180 views per rotation in 300 s
2×160 positions per view
384 B/s data transfer rate
113 kB data size

Stefan Delorme
Division of Radiology
21.05.14 |

Siemens 2·2·96=384-slice
dual source cone-beam spiral CT(2013)

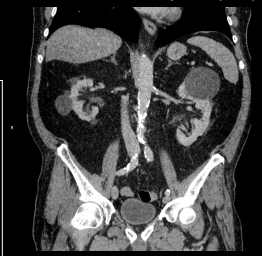

525 views (1050 readings) per rotation in 0.25 s
2·96×(920+640) two-byte channels per view
1,200 MB/s data transfer rate
up to 4 GB rawdata, 2 GB volume size typical

EMI parallel beam scanner (1972)

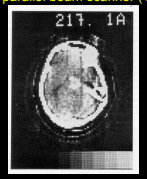

180 views per rotation in 300 s
2×160 positions per view
384 B/s data transfer rate
113 kB data size

Stefan Delorme
Division of Radiology
21.05.14 |

Siemens 2·2·96=384-slice
dual source cone-beam spiral CT(2013)

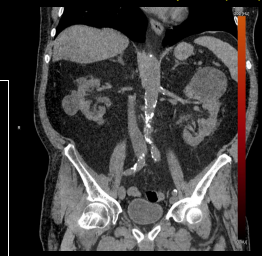

525 views (1050 readings) per rotation in 0.25 s
2·96×(920+640) two-byte channels per view
1,200 MB/s data transfer rate
up to 4 GB rawdata, 2 GB volume size typical

EMI parallel beam scanner (1972)

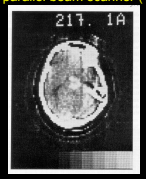

180 views per rotation in 300 s
2×160 positions per view
384 B/s data transfer rate
113 kB data size

Stefan Delorme
Division of Radiology
21.05.14 |

Siemens 2·2·96=384-slice
dual source cone-beam spiral CT(2013)

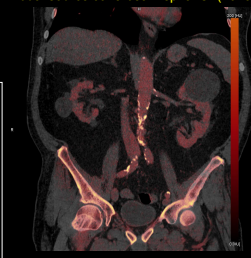

525 views (1050 readings) per rotation in 0.25 s
2·96×(920+640) two-byte channels per view
1,200 MB/s data transfer rate
up to 4 GB rawdata, 2 GB volume size typical

EMI parallel beam scanner (1972)

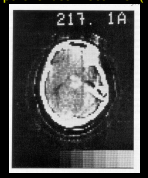

180 views per rotation in 300 s
2×160 positions per view
384 B/s data transfer rate
113 kB data size

What is Displayed?

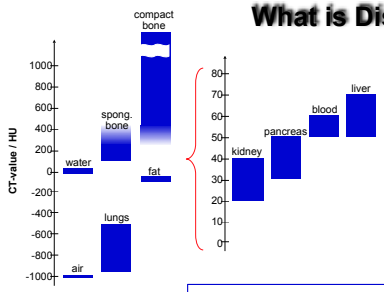

$$CT(\boldsymbol{r}) = \frac{\mu(\boldsymbol{r}) - \mu_{\mathrm{Water}}}{\mu_{\mathrm{Water}}} \cdot 1000\ \mathrm{HU}$$

dkfz.

Stefan Delorme
Division of Radiology
21.05.14 |

dkfz.
50 Years – Research for A Life Without Cancer

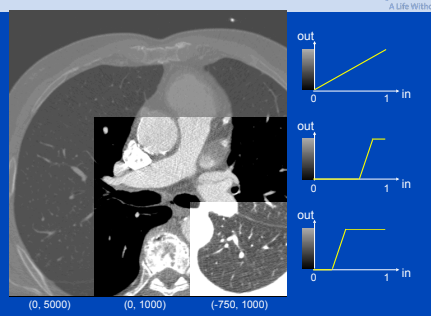

Outline

dkfz.
50 Years – Research for A Life Without Cancer

- Computed tomography
  - How it works
  - Strengths
  - Weaknesses
- Magnetic resonance imaging
  - How it works
  - Strengths
  - Weaknesses
- Ultrasound
  - How it works
  - Strengths
  - Weaknesses

CT: Strengths

dkfz.
50 Years – Research for A Life Without Cancer

- Reliable
- Geometrically correct
- Fast
  - Patient ease and comfort
  - Minimal motion artifacts
  - 4D imaging possible
- Density values
  - Electron density with dual-energy CT
- High spatial resolution

CT: Weaknesses

dkfz.
50 Years – Research for A Life Without Cancer

- Relatively low tissue contrast
- Artifacts in neighbourhood to metal
- Limited potential for functional imaging
- Ionising radiation

Outline

dkfz.
50 Years – Research for A Life Without Cancer

- Computed tomography
  - How it works
  - Strengths
  - Weaknesses
- Magnetic resonance imaging
  - How it works
  - Strengths
  - Weaknesses
- Ultrasound
  - How it works
  - Strengths
  - Weaknesses

What do we need for an MR image?

dkfz.
50 Years – Research for A Life Without Cancer

We need…

- Atomic nuclei
  - Protons
- Magnetic fields
  - Static fields
  - Gradient fields
- RF fields
  ➡= rotating magnetic fields

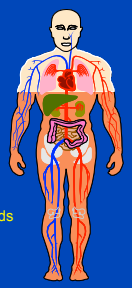

Atomic nucleus

dkfz.
50 Years – Research for A Life Without Cancer

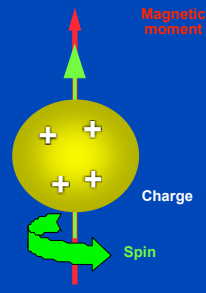

Suitable nuclei for in-vivo MR

Nucleus	Spin	
^{1}H	1/2	Water
^{31}P	1/2	ADP / ATP
^{23}Na	3/2	Na-K-Pump
^{14}N	1	
^{13}C	1/2	
^{19}F	1/2	Dental enamel
^{3}He	-1/2	
^{129}Xe	-1/2	

Precession

Magnetic moment

Precession with ω

Protons

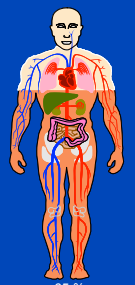

65 % water

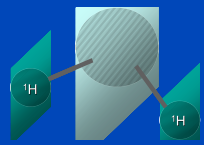

1g (H_2O) = $3.67 \cdot 10^{22}$ molecules

Makroskopic magnetization

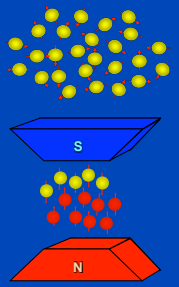

$B = 0$

$B = B_0$

Σ =

Precession

$$\omega = \gamma B_0$$

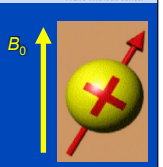

Resonant high-frequency excitation

- Larmor frequency
  - ω Precession frequency
  - External magnetic field, rotating with ω (B_1 field)
  - Spins feel a quasi-static field

➡Deflection by the flip angle α

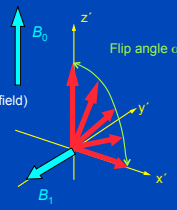

How to receive a signal

Bicycle dynamo

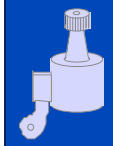

Coil and rotating magnet

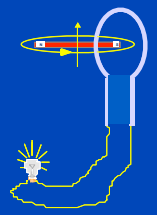

Rotating magnetic moment

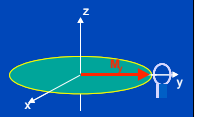

HF coils: Volume resonators

T1-weighting

- Multi-pulse experiment
  - 90° HF pulse
  - Repetition time TR

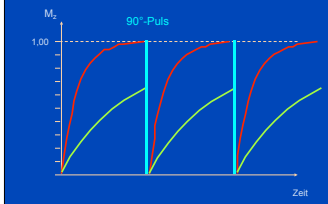

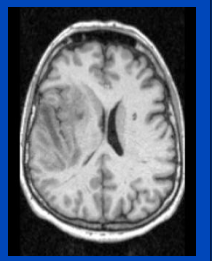

T2-weighting

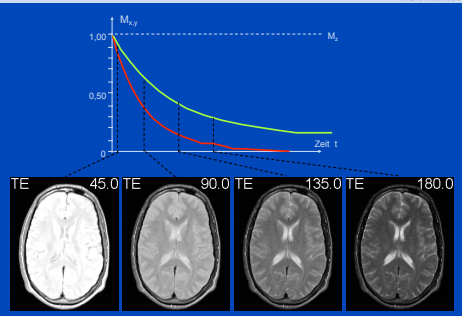

Gradients

- Gradient
  - Used to localize an MR signal
  - Coils under electric current
  - Linearly increasing, superimposed fields

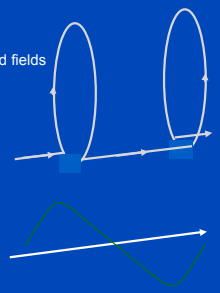

Gradient tube

Slice selection

dkfz.
50 Years – Research for A Life Without Cancer

- Concept
  - z gradient and HF puls simultaneous
  - Only spins in one slice will be excited

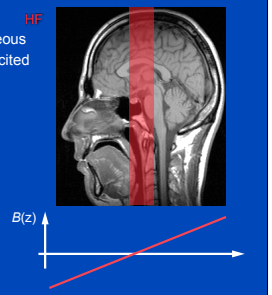

k-space

dkfz.
50 Years – Research for A Life Without Cancer



Image k-space

T2-weighted images

dkfz.
50 Years – Research for A Life Without Cancer

Bright:

Long T2:
- Fat (moderately)
- Blood
- Fluid
- **Many pathologies**

Dark:

Short T2:
- After Gd-DTPA (slightly)
- Bone, calcium
- Blood (Hämosiderine)

Flow: Signal void

Lack of protons: Air

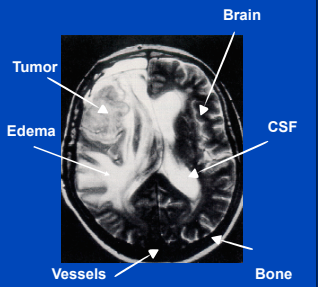

Contrast medium: Gd-DTPA

dkfz.
50 Years – Research for A Life Without Cancer

- GD3+ is paramagnetic
  - Reduces relaxation times in tissue
  - Affects mainly T1
- Toxic if liberated, inert as a DTPA chelate
  - Other chelates: DOTA, DTPA-BMA, etc.
- Excreted in urine
- Administration i.v., oral possible

T1-weighting

dkfz.
50 Years – Research for A Life Without Cancer

Bright:

Short T1:
- **Fat**
- **Blood (age !)**
- **After Gd-DTPA: disturbed BBB**
- **Fluid with high protein content**

Dark:

Long T1:
- **Free water**
- **Bone, calcium**

Flow: signal void

Lack of protons: air

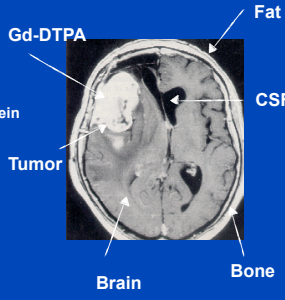

Outline

dkfz.
50 Years – Research for A Life Without Cancer

- Computed tomography
  - How it works
  - Strengths
  - Weaknesses
- Magnetic resonance imaging
  - How it works
  - Strengths
  - Weaknesses
- Ultrasound
  - How it works
  - Strengths
  - Weaknesses

MRI: Strengths

- Excellent tissue contrast
- Flexible assessment of tissue properties
- Functional imaging
- No ionizing radiation

MRI: Weaknesses

- Slow
- Not always geometrically correct
- Artifacts
  - Motion
  - Metal
  - Air
- Exclusions
  - Electronic devices
    - Pacemakers
    - Insulin pumps etc.
    - Cochlea implants
  - Metal
    - Implants, clips not fixed to bone
    - Large tatoos
  - Claustrophobia

Outline

- Computed tomography
  - How it works
  - Strengths
  - Weaknesses
- Magnetic resonance imaging
  - How it works
  - Strengths
  - Weaknesses
- Ultrasound
  - How it works
  - Strengths
  - Weaknesses

Pre-ultrasound era…

Pulse-echo techniques



Delorme, Debus: Duale Reihe Sonographie, Thieme

Interaction between sound and tissue

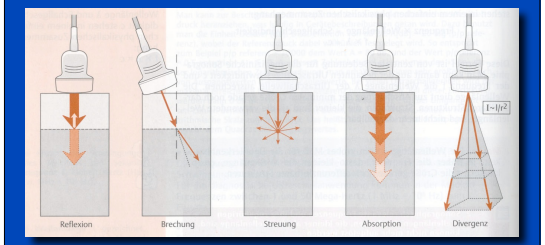

Reflection Refraction Scattering Absorption Divergence

Delorme, Debus: Duale Reihe Sonographie, Thieme

Influence of object size

$d \ll \lambda$ $d \approx \lambda$ $d \gg \lambda$

No interaction — Scattering — Reflection

Pulse-echo experiment



Compound ultrasound imaging

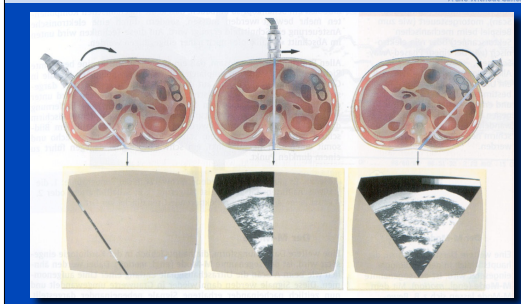

Delorme, Debus: Duale Reihe Sonographie, Thieme

Ultrasound probes

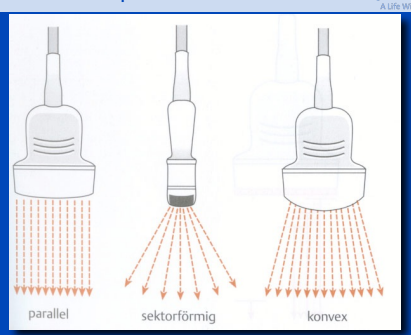

Delorme, Debus: Duale Reihe Sonographie, Thieme

Acoustic shadowing

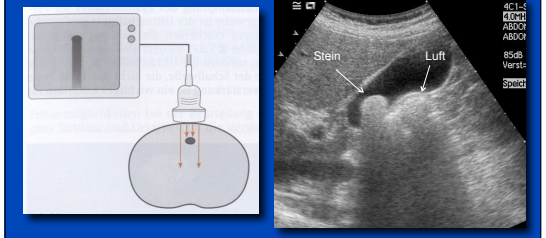

Delorme, Debus: Duale Reihe Sonographie, Thieme

Tangential deflection

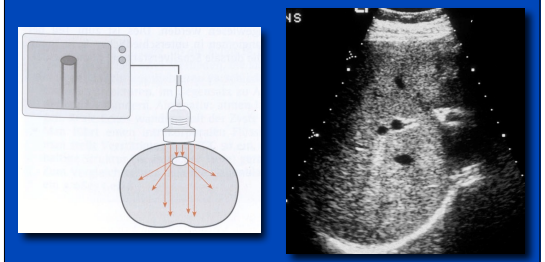

Delorme, Debus: Duale Reihe Sonographie, Thieme

Stefan Delorme
Division of Radiology
21.05.14 |

dkfz.
50 Years – Research for A Life Without Cancer

Normal thyroid

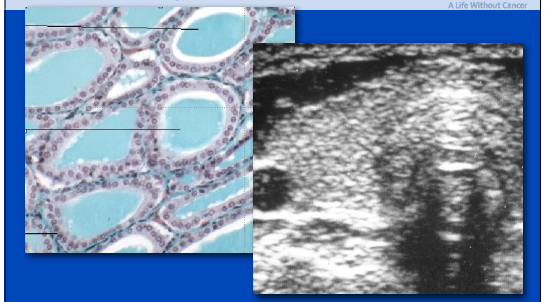

Stefan Delorme
Division of Radiology
21.05.14 |

dkfz.
50 Years – Research for A Life Without Cancer

Graves disease

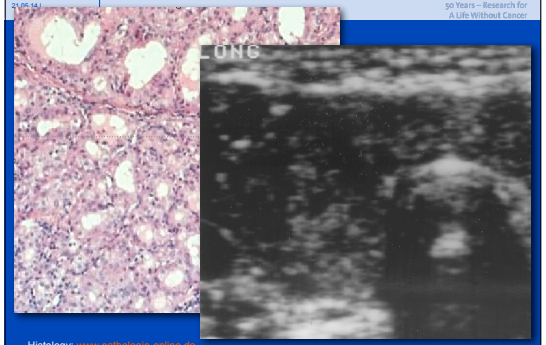

Histology: www.pathologie-online.de

Stefan Delorme
Division of Radiology
21.05.14 |

dkfz.
50 Years – Research for A Life Without Cancer

Metastasis

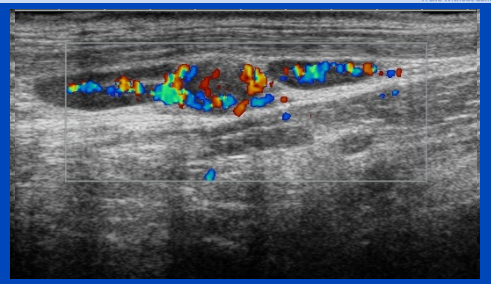

Malignant melanoma

Stefan Delorme
Division of Radiology
21.05.14 |

dkfz.
50 Years – Research for A Life Without Cancer

Metastasis

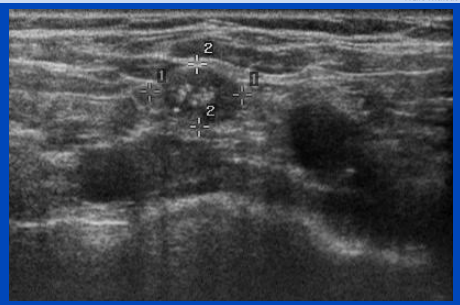

Medullary thyroid carcinoma

Stefan Delorme
Division of Radiology
21.05.14 |

dkfz.
50 Years – Research for A Life Without Cancer

Contrast-enhanced ultrasound: Arterial phase

Metastatic rectal carcinoma

Stefan Delorme
Division of Radiology
21.05.14 |

dkfz.
50 Years – Research for A Life Without Cancer

Contrast-enhanced ultrasound: Portal phase

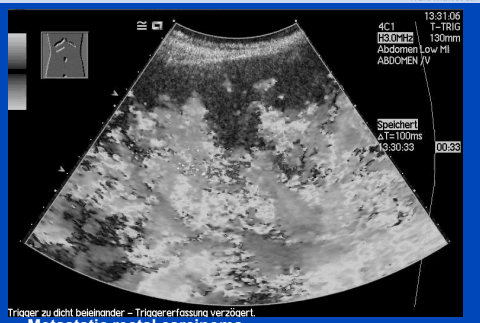

Metastatic rectal carcinoma

Outline

- Computed tomography
  - How it works
  - Strengths
  - Weaknesses
- Magnetic resonance imaging
  - How it works
  - Strengths
  - Weaknesses
- Ultrasound
  - How it works
  - Strengths
  - Weaknesses

Ultrasound: Strengths

- Fast
- Flexible
- Highest resolution of all
- Real-time
- No ionising radiation
- Functional information
  - Motion
  - Blood flow
    - Color Doppler
    - Contrast agents

Ultrasound: Weaknesses

- Difficult
  - Requires skill and dexterity
- No volume-covering documentation
- Access limited
  - Bone
  - Air

ESTRO Course: Target Volume Definition

Functional imaging

Stefan Delorme

dkfz. DEUTSCHES KREBSFORSCHUNGSZENTRUM IN DER HELMHOLTZ-GEMEINSCHAFT

Functional imaging

- Motion
- Perfusion
- Diffusion
- Metabolism

dkfz.

Functional imaging

- Motion: Adaptation of the PTV
- Perfusion: Viability, Aggressiveness
- Diffusion: Cellularity
- Metabolism: Delineation, Differentiation

dkfz.

Functional imaging methods

- Ultrasound:
  - Motion tracking
  - Contrast-enhanced ultrasound
  - Elastography, ARFI
  - Optoacoustic imaging
- CT:
  - 4D CT
  - Dual engergy CT
- MRI
  - 4D MRI
  - Dynamic contrast-enhanced MRI
  - Dynamic susceptibility contrast MRI
  - Diffusion imaging
  - Spectrospopy
- PET

dkfz.

Dual Energy CT

- Scanning with two energies simultaneously
  - Dual source technique
  - Energy switching
- Tissue differentiation
  - Water
  - Fat
  - Calcium
  - Iodine
- Basis for calculation of electron density

dkfz.

Motion

- CT
  - In- and expiratory images
  - Gated imaging (4D CT)
- MRI
  - Fast MRI techniques

dkfz.

4D MRI – Breathing

- Chest wall infiltration

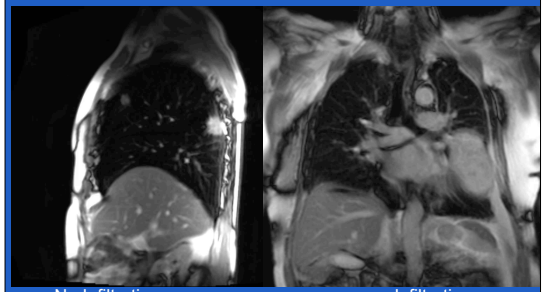

No Infiltration Infiltration

dkfz.

4D MRI – Breathing

- Tumor and atelectasis

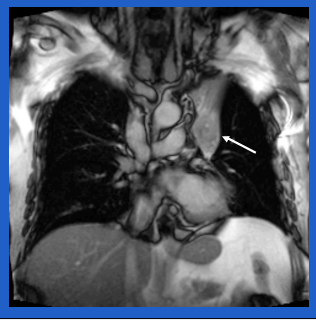

dkfz.

Dynamic contrast-enhanced MRI

dkfz.

How it works: DCE MRI

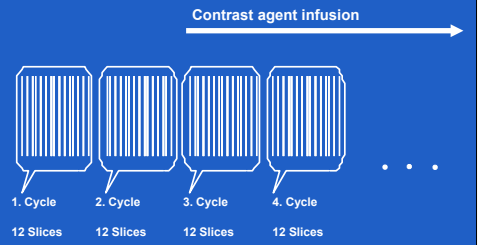

dkfz.

Time-intensity curves

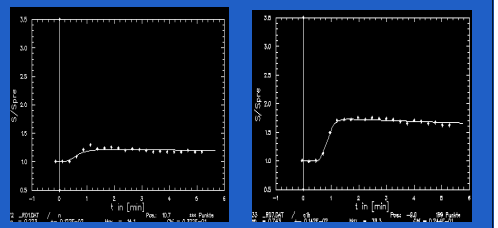

Normal Myeloma

dkfz.

Pharmakokinetic model

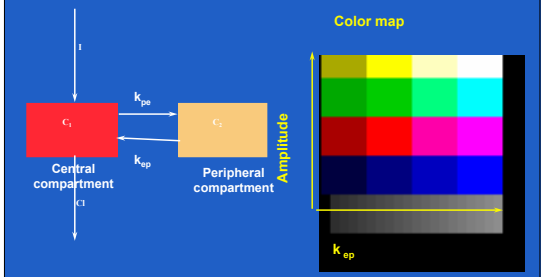

dkfz.

Physiological correlates

Amplitude	Relative blood volume Interstitial space	
k_{ep}	Perf > Diff Diff > Perf	Diffusion Perfusion

Diffusion = Transcapillary exchange
Depends on:
Permeability, capillary exchange surface

dkfz.

Normal spine

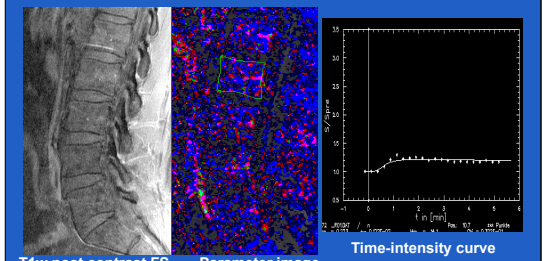

T1w post contrast FS Parameter image Time-intensity curve

dkfz.

Diffuse infiltration by multiple myeloma

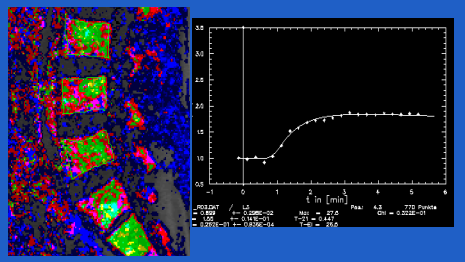

dkfz.

Amplitude vs. infiltration degree

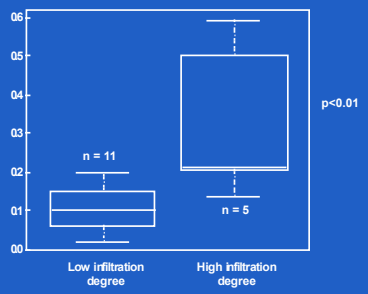

Nosas-Garcia et al., 2005

dkfz.

Amplitude vs. vessel density

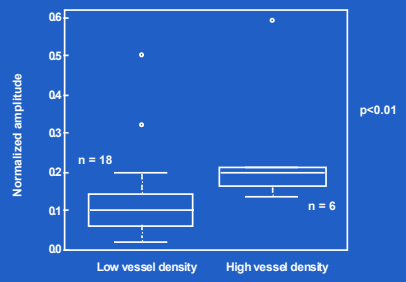

Nosas-Garcia et al., 2005

dkfz.

Prognostic information of DCE-MRI

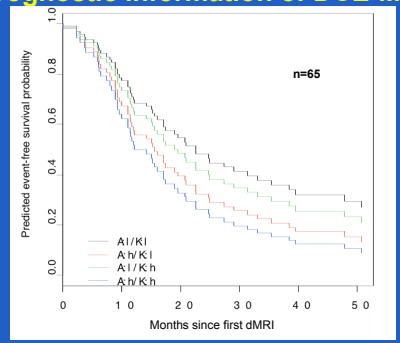

Hillengass et al., Clin Cancer Res 2007

dkfz.

Perfusion MRI
= Dynamic contrast susceptibility imaging

dkfz.

T2*w Perfusion MRT

Transient signal loss by intravascular CM

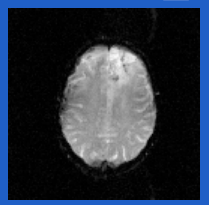

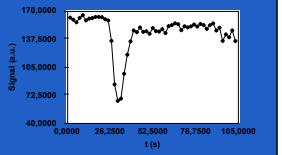

T2*-weighted MRI

dkfz.

Diffusion

dkfz.

Diffusion MRI: How it works

- First gradient field induces dephasing
  - » Signal loss
- Inverted gradient field induces rephasing
  - » Restoration of signal
- Effect:
  - – Stationary protons:
    - » Return into phase and regain signal
  - – Moving protons
    - » Incomplete restoration of signal
    - » Persistant signal loss

dkfz.

First Gradient: Dephasing

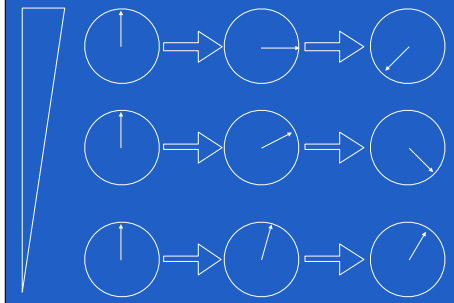

dkfz.

Second gradient: Rephasing Stationary protons

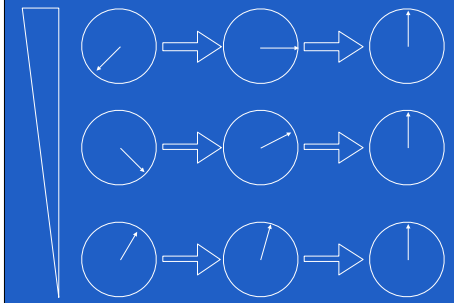

dkfz.

Second gradient: Rephasing Moving protons

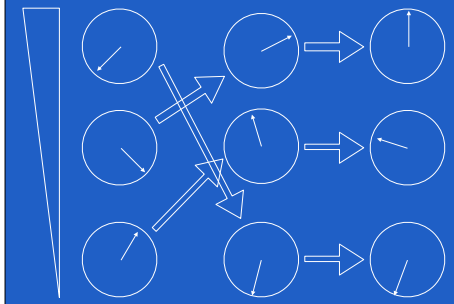

dkfz.

Stejskal-Tanner sequence

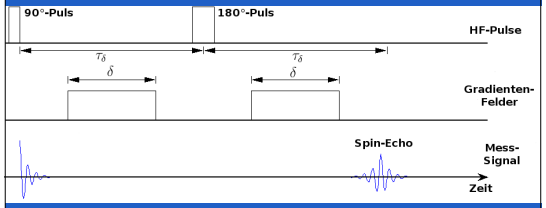

www.wikipedia.de

dkfz.

Three principal axes

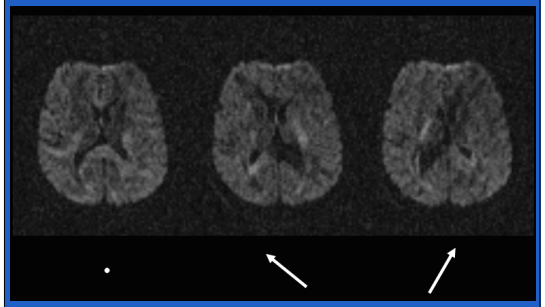

dkfz.

The B-value

- Expresses strength and duration of gradient field
- Low B-values:
  - B = 0: T2-weighted image
  - B = 50 - 400
    - Signal loss in fast moving protons (perfusion)
- High B-values
  - B > 400
    - Signal loss in slowly moving protons (diffusion)

dkfz.

The ADC

- ADC = apparent diffusion coefficient
- Slope of straight line connecting two values obtained with different B-values

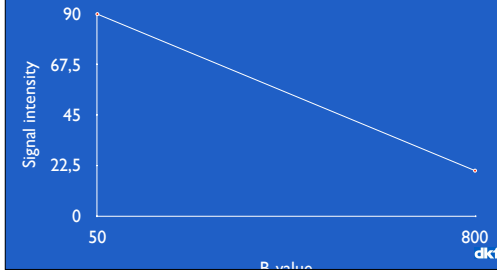

dkfz.

Calculation of the ADC

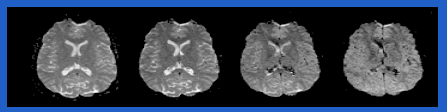

Low b-value ⟷ High b-value

Calculation of signal loss/pixel →

$$ADC = \frac{(\lambda_1 + \lambda_2 + \lambda_3)}{3}$$

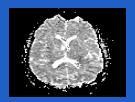

ADC image

dkfz.

ADC and cellularity

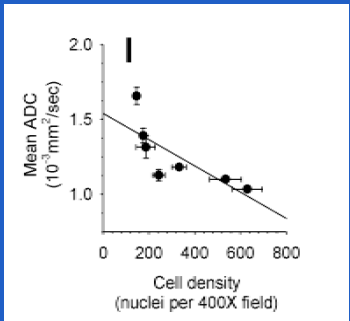

Chenevert et al., J Natl Cancer Inst 2000; 92:2029–36

dkfz.

Three principal axes: A second look

DWI assesses also preferential direction of movement of water molecules

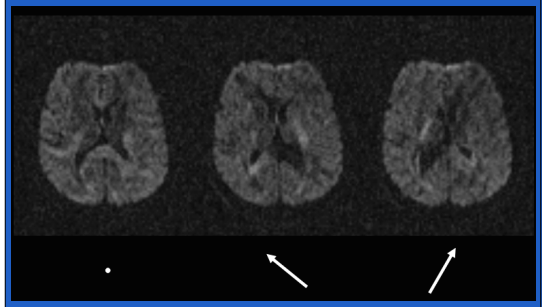

dkfz.

Fiber tracking with Diffusion Tensor Imaging

- Diffusion: tractography and fractional anisotropy

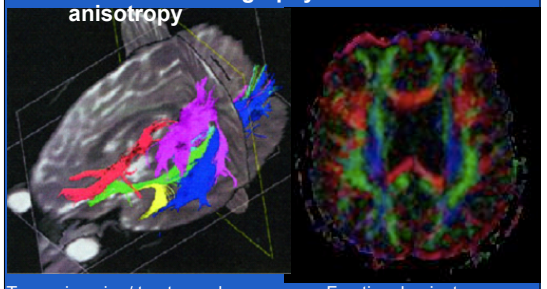

Tensor imaging/ tractography

Fractional anisotropy

dkfz.

Fiber tracking

- Diffusion: tractography

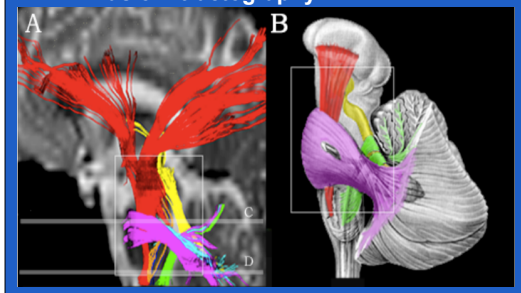

Stieltjes et al. 2002

dkfz.

Fractional anisotropy

- Degree of preferential movement along one axis
  - FI = 0: Equal movement in all directions
  - FI = 1: Movement in one direction only
- Measures the degree of architectural disturbance in organized tissues
  - Tumor infiltration in white matter

dkfz.

Quantifying disorder in fiber arrangement

- Diffusion: fractional anisotropy

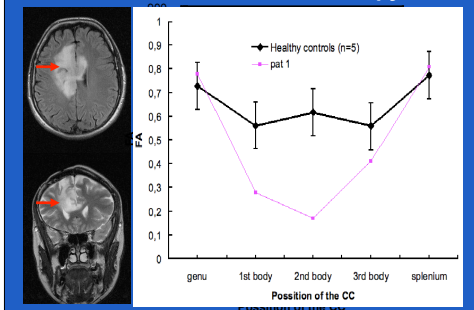

dkfz.

Disturbance in fiber architecture by tumors

- Diffusion: fractional anisotropy

Control

Patient

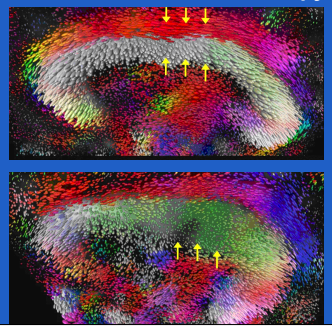

Stieltjes et al. Neuroimage 2006

dkfz.

Glioma: Inapparent CC infiltration

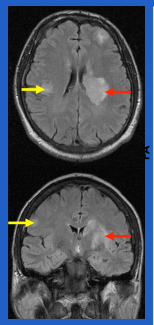

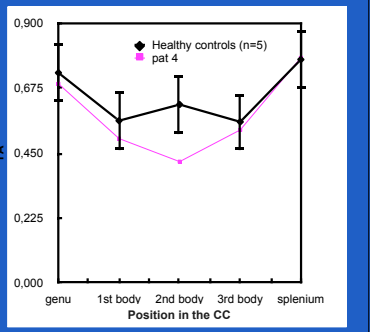

dkfz.

Why spectroscopy?

dkfz.

Grade III glioma

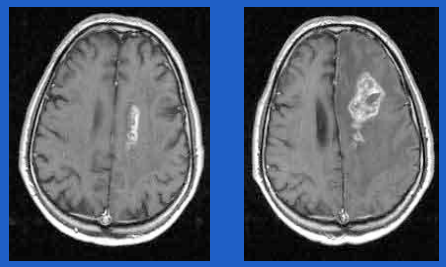

3.5.1997 9.1.1998

dkfz.

?

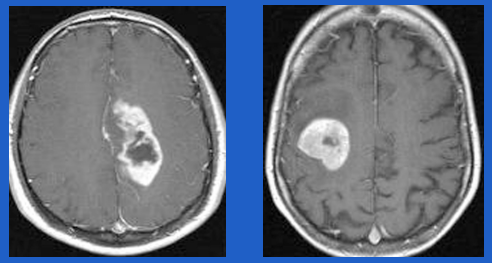

dkfz.

Grade II glioma

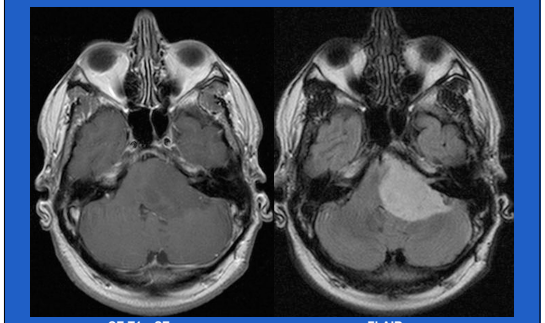

CE T1w SE FLAIR

dkfz.

Brain: Physiologic metabolites

- NAA: Neuronal marker
  - N-acetyl-L-aspartate
  - δ = 2.01 ppm
- Cr: Energy store
  - (Phospho-) Creatine
  - δ = 3.03 ppm and 4 ppm
- Cho: Membrane turnover
  - Phosphocholin, Glycerophosphorylcholin
  - δ = 3.22 ppm

dkfz.

Brain: Pathologic metabolites

- Lactate: Anaerobic glycolysis
  - Hypoxic areas
  - Macrophages
  - δ = 1.33 ppm doublet (inverted at 135 ms)
- Lipids (fatty acids): Necrosis
  - δ = 1.2 - 1.4 ppm

dkfz.

Typical spectra

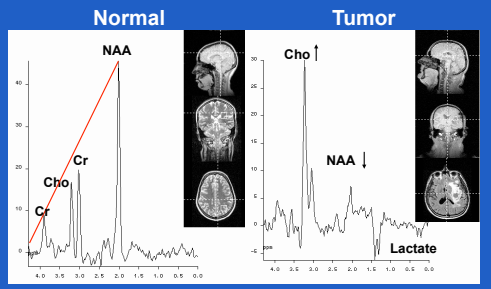

Bachert et al., Radiologe 2004

dkfz.

Tumor characterization

dkfz.

Metastasis

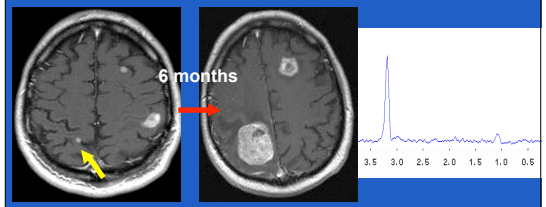

Schlemmer et al., AJNR 2001; Weber et al., Radiologe 2003

dkfz.

Grade II glioma

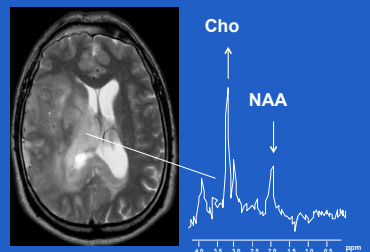

dkfz.

Diagnosis please...

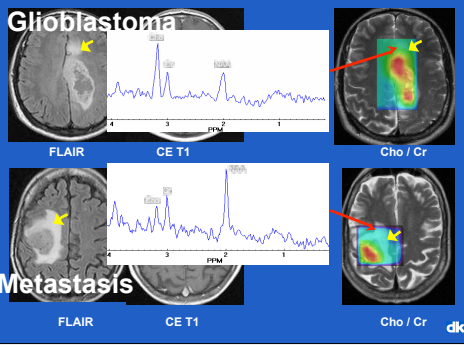

dkfz.

Grading

dkfz.

Grading in gliomas

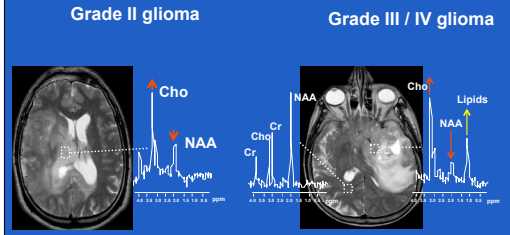

c/o H.-P. Schlemmer,Heidelberg / Tübingen

dkfz.

Gold standard?

- Grade determined by highest malignant component
- Any biopsy subject to sampling error

dkfz.

Tumor hetereogeneity

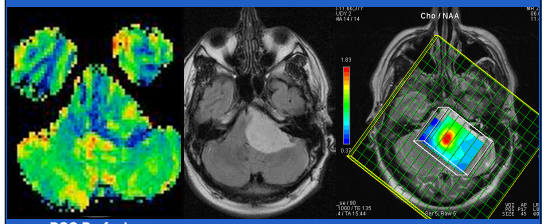

dkfz.

Radiation injury

dkfz.

Enhancing lesion post radiotherapy

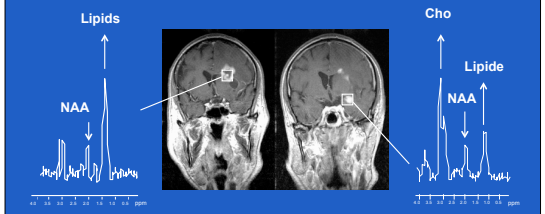

Radiation damage Tumor progression

dkfz.

MRSI in brain lesions: Summary

Pathology	Cho/Cr	Cho/Cho(n)	NAA/Cr	Cho peritumoral
High grade glioma	⇑⇑	⇑⇑	⇓⇓	⇑
Low grade glioma	⇑	⇑	⇓	~
Radiation necrosis	⇓	⇓	⇓	⇓
Metastasis	⇑	⇑	⇓⇓	⇓
Lymphoma	⇑	⇑	⇓⇓	⇓

Law 2004

dkfz.

Visions

dkfz.

^{23}Na Imaging

Courtesy of M.A. Weber and M. Bock, Heidelberg

dkfz.

Sodium imaging

- Possible applications:
  - Viability
  - Therapy monitoring

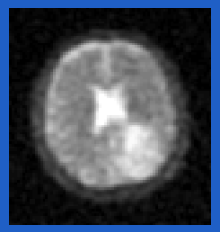

dkfz.

Positron emission tomography

dkfz.

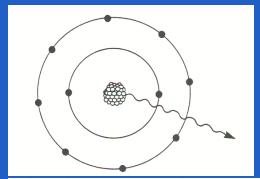

Gamma decay

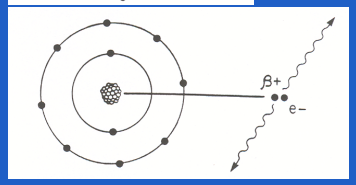

Positron decay

dkfz.

PET isotopes

Isotope	$T_{1/2}$(min)	E_{max}(MeV)
^{11}C	20,4	0,97
^{13}N	9,9	1,19
^{15}O	2,05	1,72
^{18}F	109	0,64
^{68}Ga	68	1,9

dkfz.

PET tracers - oncology

- Metabolism
  - ^{18}FDG
- Amino acids
  - ^{11}C-methionine
  - ^{18}F-tyrosine
  - ^{11}C-AIB
  - ^{18}FET
- Peptides
  - ^{68}Ga-DOTATOC
  - ^{68}Ga-PSMA
- Perfusion
  - $H_2{}^{15}O$
- Proliferation
  - ^{11}C-thymidine
  - ^{18}FLT
  - ^{18}F-Ethyl Choline
  - ^{11}C-Choline
- Hypoxia
  - ^{18}F-MISO
- Drugs
  - ^{18}FU

dkfz.

68Ga-DKFZ-PSMA-11

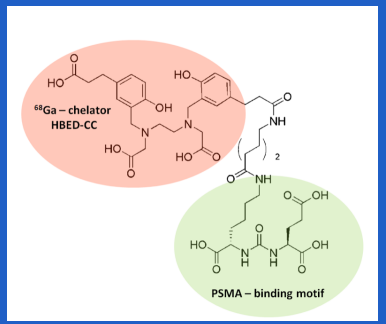

Eder M et al. Bioconjugate Chem 2012; 23: 688-697.
Afshar-Oromieh A et al. Eur J Nucl Med Mol Imaging 2013; 40: 486-495.

dkfz.

FDG metabolism

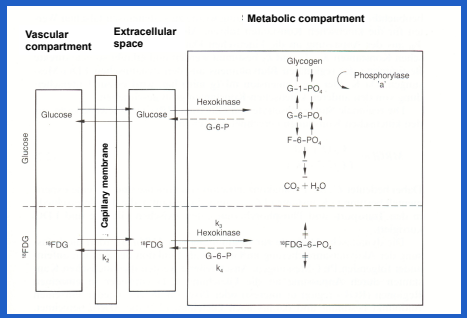

dkfz.

CT/PET hybrid system

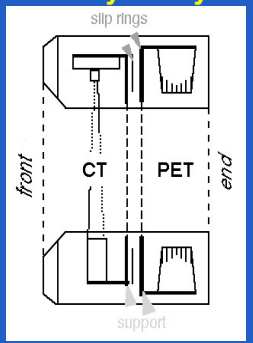

dkfz.

CT/PET hybrid system

dkfz.

PET: Glucose Metabolism

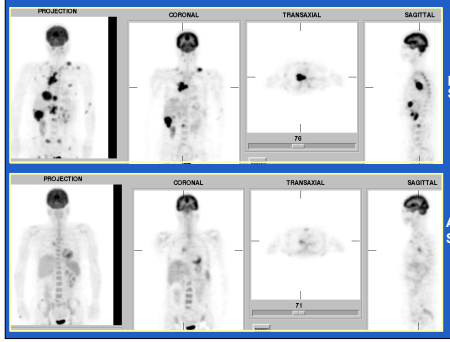

pre therapy
SUV 10,2

After 2nd cycle
SUV 5,7

dkfz.

DWI with background suppression: Multiple myeloma

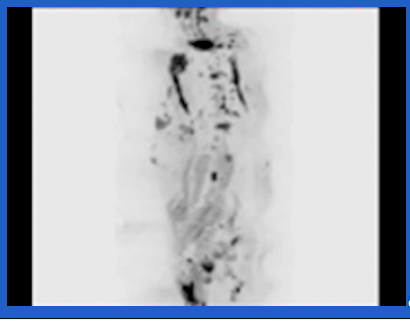

dkfz.

Multiple myeloma post chemotherapy

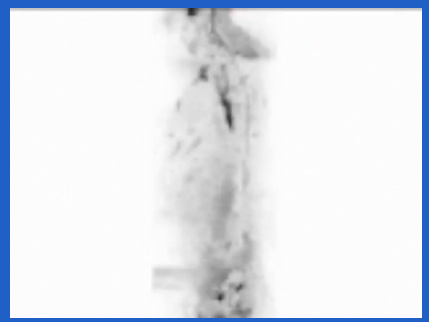

dkfz.

Take home: Functional imaging

- Information beyond anatomy
  - Movement
  - Microstructure
  - Biology
- Ready to use:
  - Movement analysis
- Needs evidence basis in RTX planning:
  - Spectroscopy
  - PET
  - Dynamic MRI and DWI
  - Diffusion-weighted imaging
- Music of the future:
  - Diffusion tensor imaging for RTX planning

s.delorme@dkfz.de, Radiologie – E010, Innovative Krebsdiagnostik und -therapie

dkfz.

GTV, CTV and PTV
(ICRU 62 + 83 and beyond)

Neil Burnet

University of Cambridge Department of Oncology,

Oncology Centre, Addenbrooke's Hospital, Cambridge, UK

ora dos lugares
marcados
xcepto cargas e
descargas
Atenção
Entrada
e
saída
de
camiões
30

GTV, CTV and PTV

- Introduction
- GTV/CTV/PTV
- Organs at Risk (OARs)
- Planning organ at Risk Volume (PRV)
- Palliative target volumes

- Questions

Learning Objectives

- To understand the concept of different planning volumes
- To understand definitions of
  - GTV
  - CTV
  - PTV
- To understand the relevance of Organs At Risk
- To understand the relevance of dose adaptation

The history of radiotherapy

- 1895 - Röntgen discovered X-rays
- 1896 - first treatment of cancer with X-rays
- 100+ years later the technology has changed!

- ICRU reports are here to help us
- Series began with Report 50 and Supplement 62 (1993 + 1999)
- BIR report (2003) addressed uncertainties
- ICRU 71 (2004) added a few details
- ICRU 83 (2010) is designed for IMRT

TomoTherapy
HI·ART

Imaging - technology advance

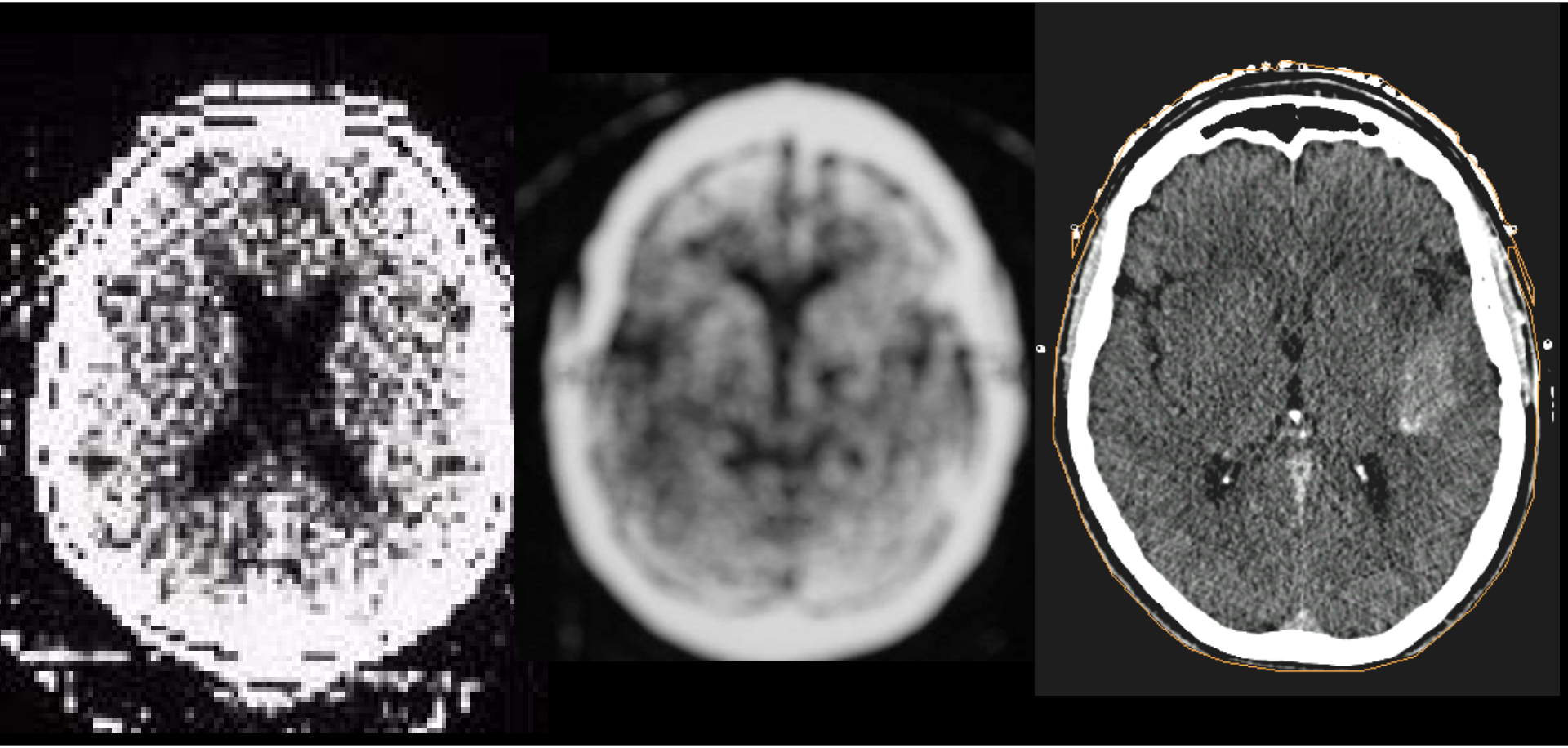

Late 1970s 1980s 2003

ESTRO School

Target volumes

We need to consider, and define, how we describe target volumes

This is a prerequisite for integrating any diagnostic imaging

Think of an onion …

Target volumes



Target volumes are like the concentric rings of an onion

Target volumes

ICRU 50 target volumes

The PTV can be eccentric

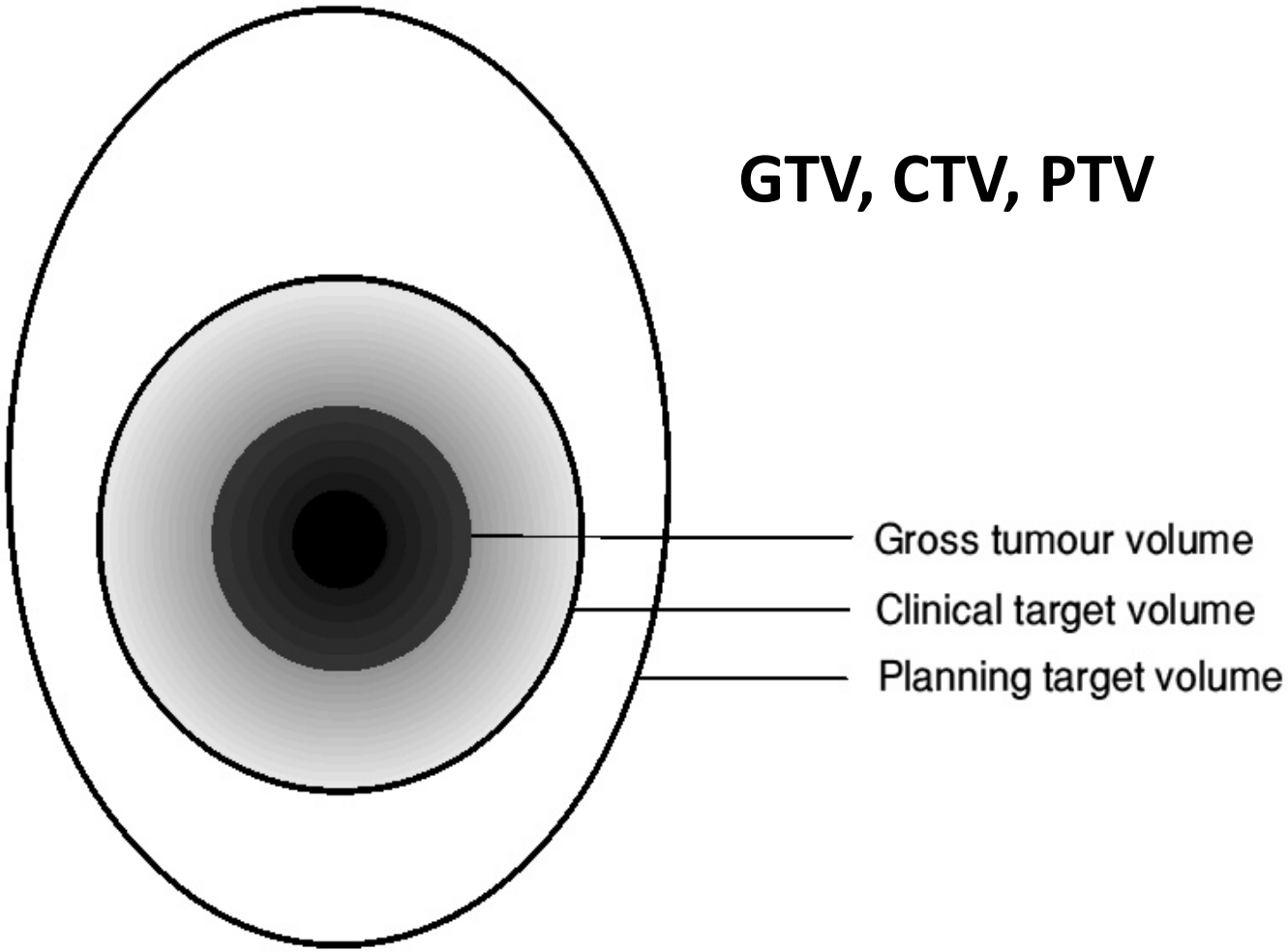

Target volumes

- ICRU report 50 and supplement 62 (1993 + 1999) specified definitions of different target volumes

- ICRU 62 was an update triggered by:
  i) increasing availability of conformal therapy where margins are more critical
  ii) need to describe normal tissues better

- ICRU 62 introduced the Planning organ at Risk Volume (PRV)

- ICRU 83 (2010) developed concepts for IMRT

Target volumes

- ICRU 50 + 62 set out an underlying philosophy for prescribing, recording and reporting radiotherapy

- They included careful attention to planning

- They did ***not*** attempt to specify the magnitude of errors in the planning process, nor how to combine them – ie how to define the size of the PTV

Target volumes

- The British Institute of Radiology (BIR) published a report from an international working party attempting to do just this

  … so we should discuss it too

- The BIR report (2003) is entitled:

  ‘Geometric Uncertainties in Radiotherapy – Defining the Planning Target Volume’

- ICRU 71 (2004) introduced this, but had less detail
- ICRU 83 (2010) has additional advice

Target volumes - GTV

Target volumes - GTV

- GTV - Gross Tumour Volume is the gross demonstrable extent and location of the tumour

- So, GTV is tumour you can:
  - **See, Feel, Image**

- Use different imaging modalities for different situations
  - Especially useful is … MRI
  - PET becoming more important
- GTV can include lymph nodes or soft tissue spread as well as the primary tumour itself

Target volumes - GTV

GTV – where tumour cell density is highest

(from ICRU 62)

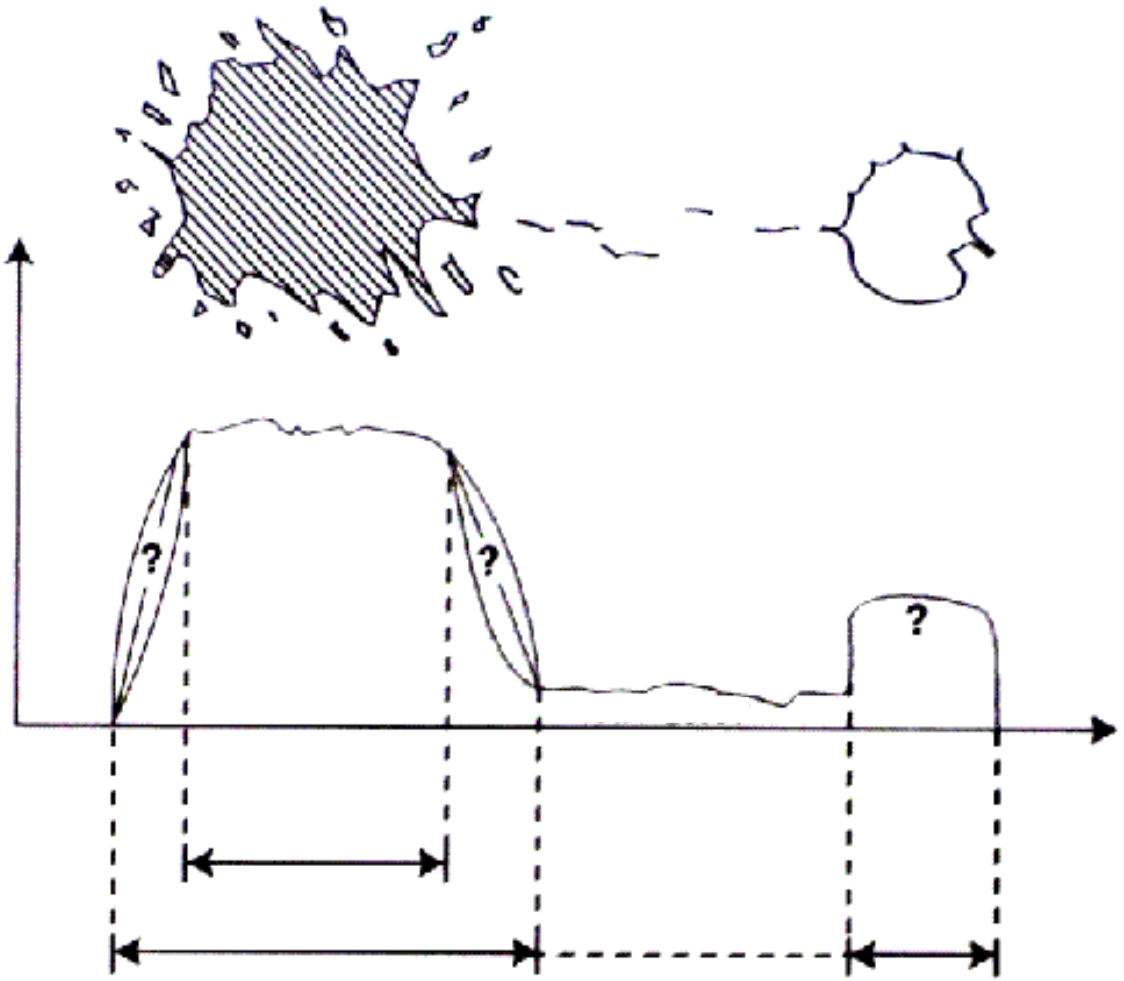

ESTRO School

Target volumes - GTV

- GTV - seems to be the easiest volume to define
- GTV is not always completely obvious
- Better methods to delineate gross tumour could still be helpful
- Use ***different*** imaging modalities for ***different*** situations

- GTV - completely obvious in this case
- (though not an easy clinical problem)

- GTV - reasonably obvious in this case
- (MRI would be better)

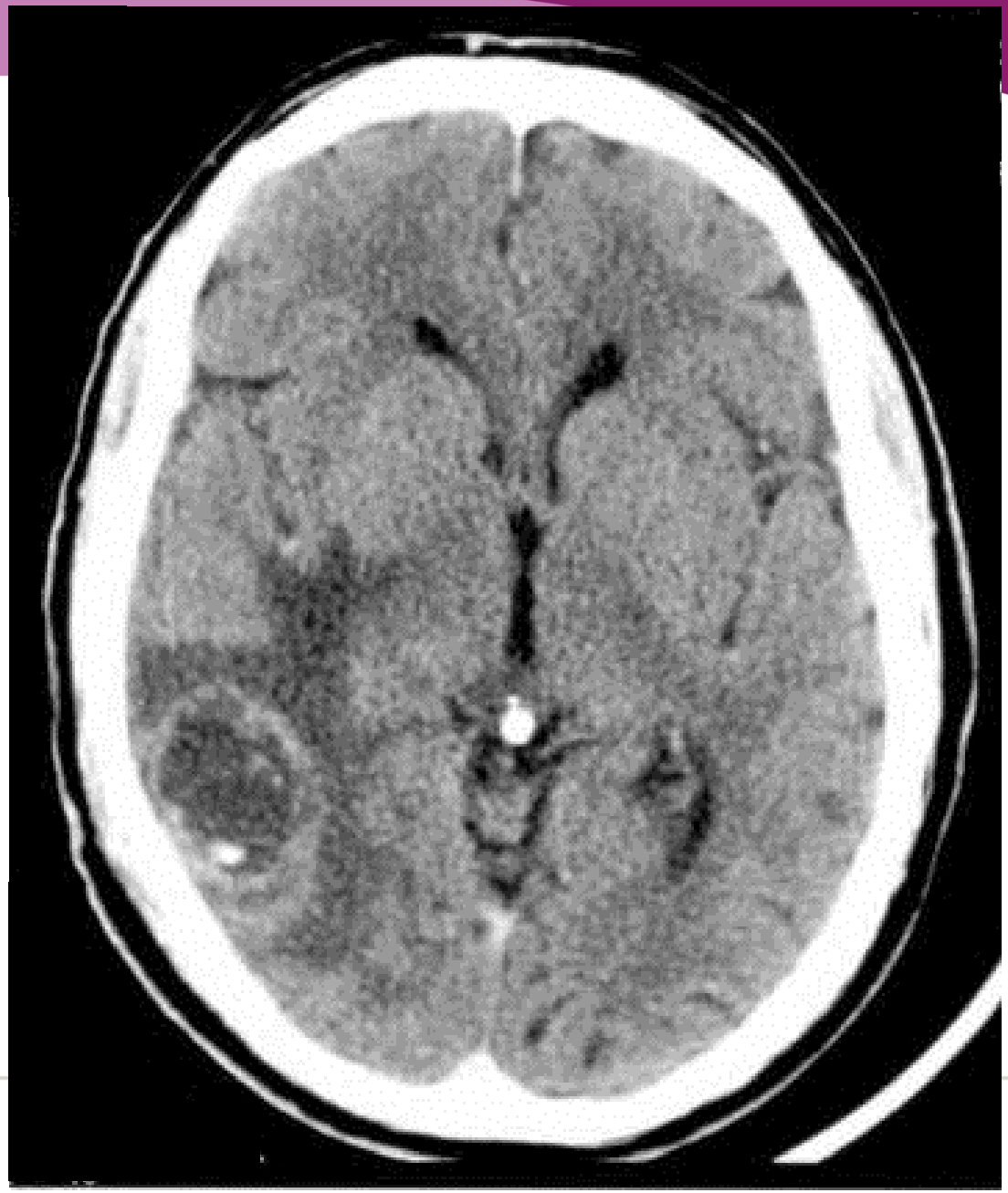

- GTV is hard to see on both CT and MRI
- The two modalities show different parts of the tumour

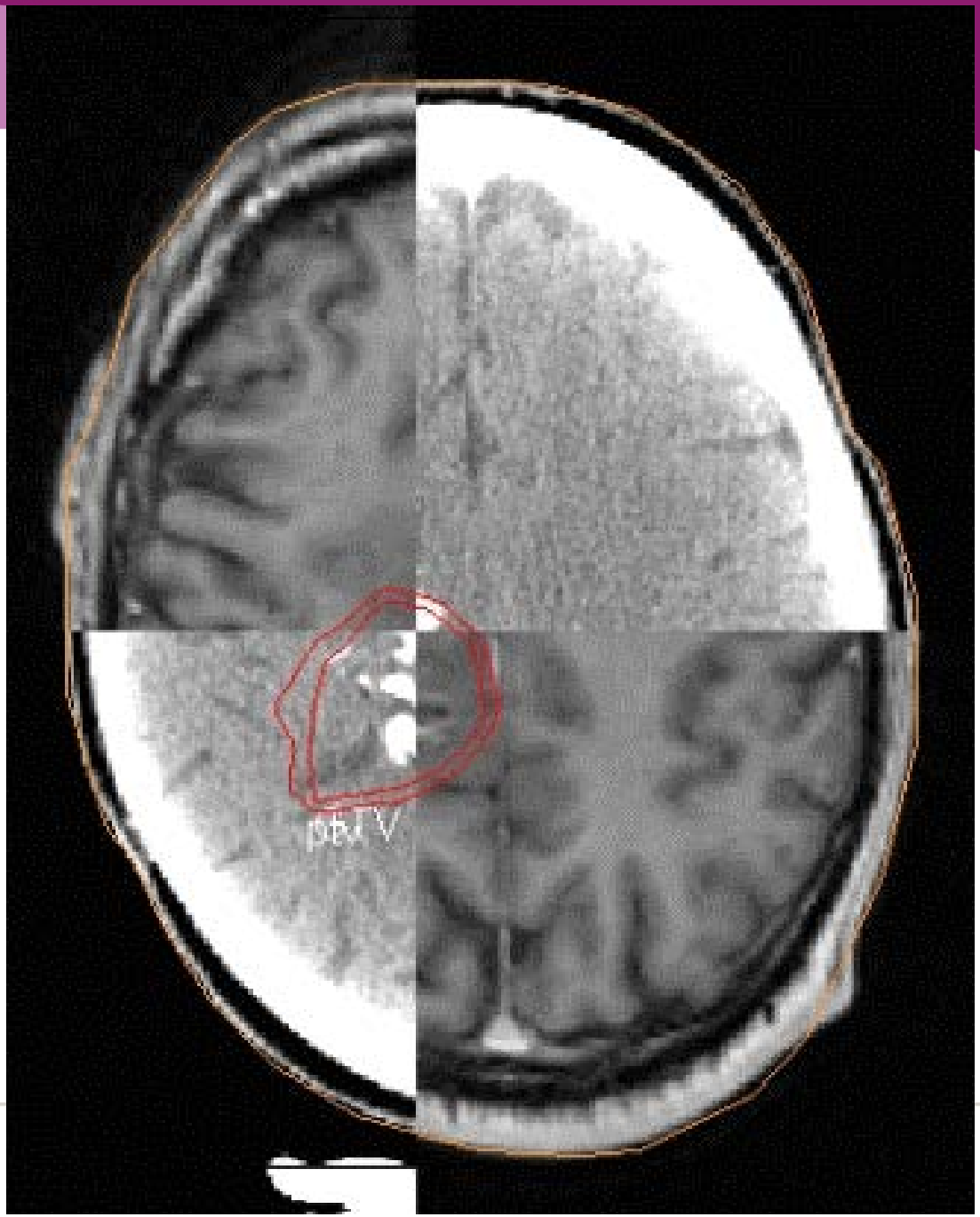

MRI **FDG PET**

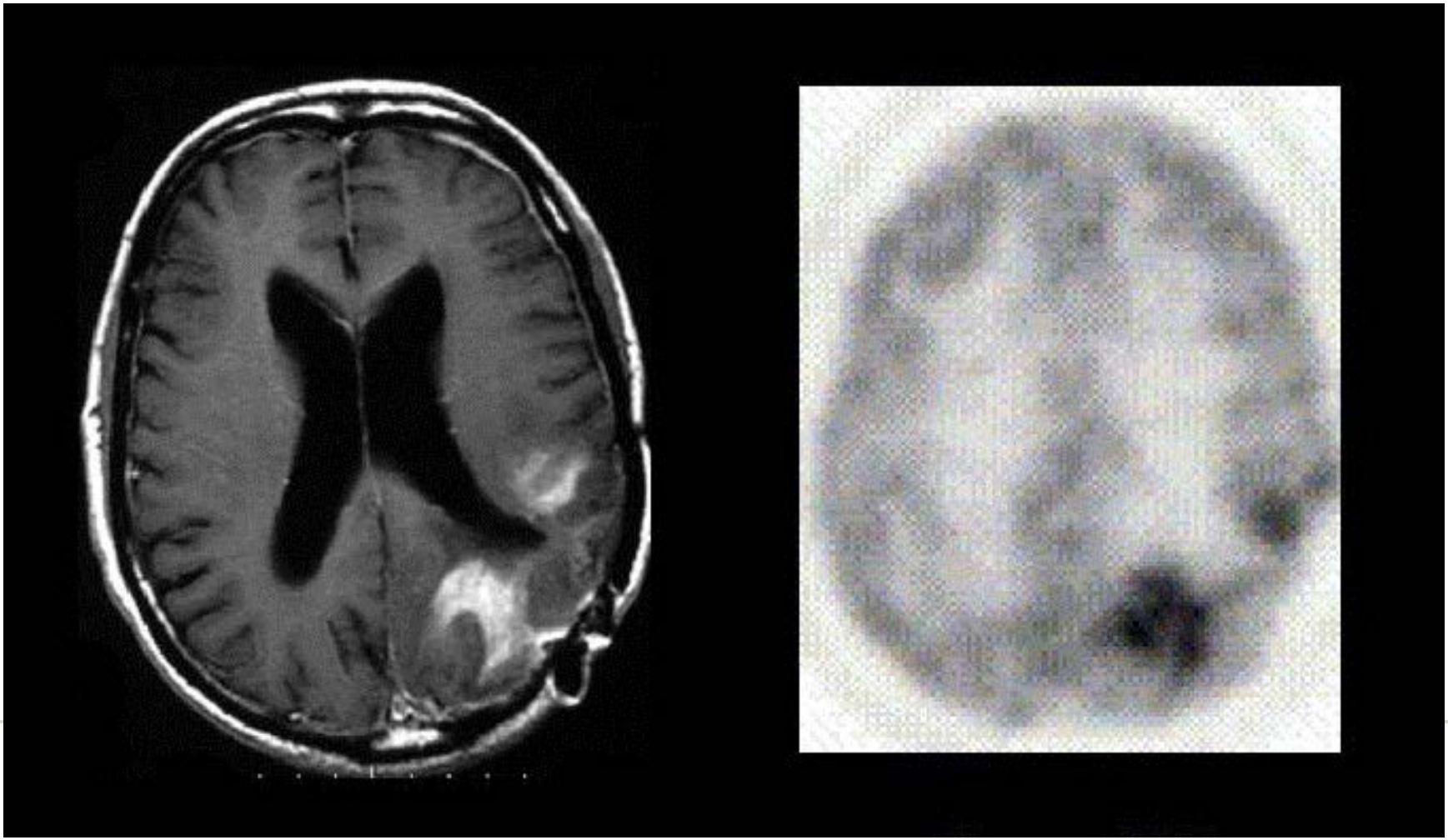

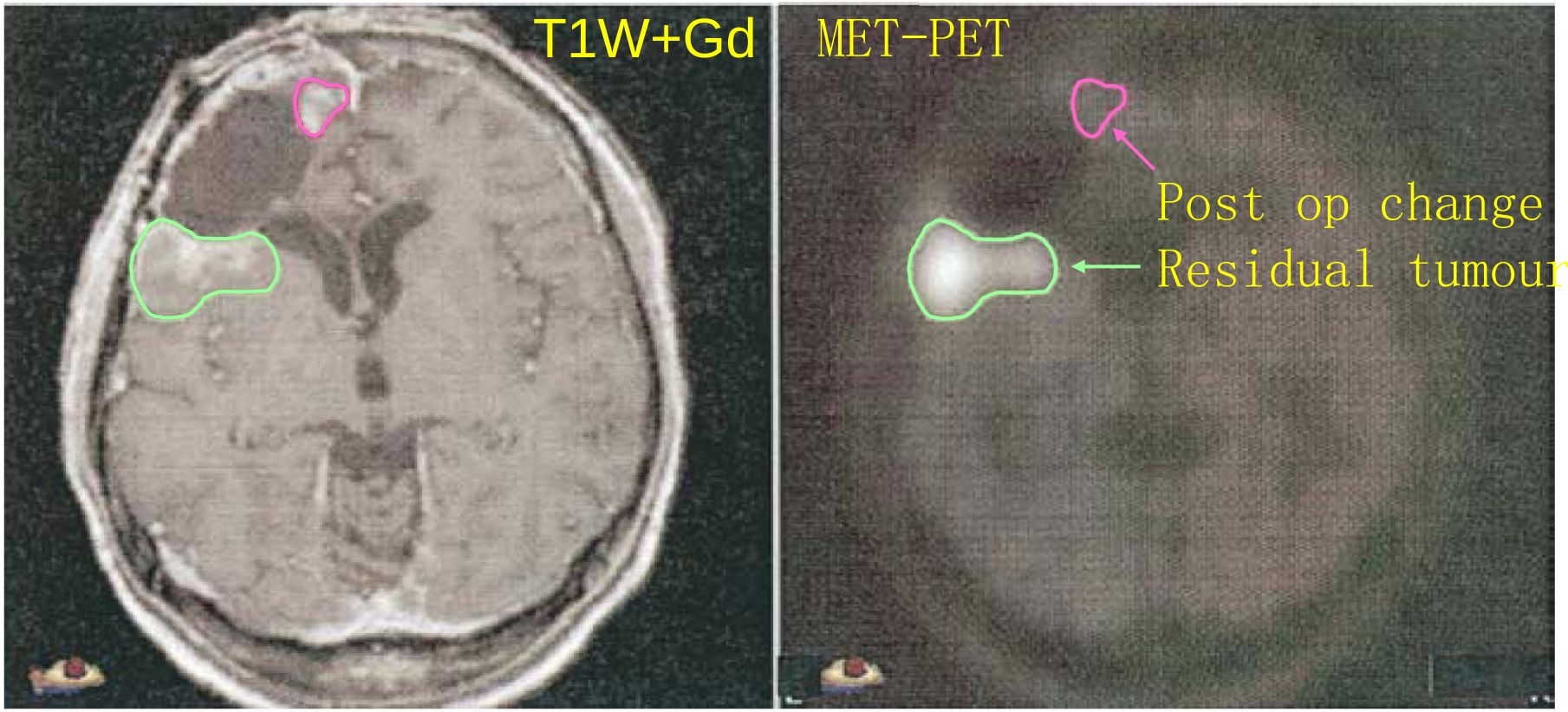

- PET may aid discrimination between tumour and post-op change
- Thus may refine target volume (GTV)
  Grosu AL et al IJROBP 2005; 63(1): 64-74

ESTRO School

Target volumes - GTV

- Imaging does ***not*** always correlate perfectly with
  - Other imaging
  - Pathology

- Specimen to imaging: 10% mismatch

Daisne JF et al Radiology 2004; 233(1):93-100

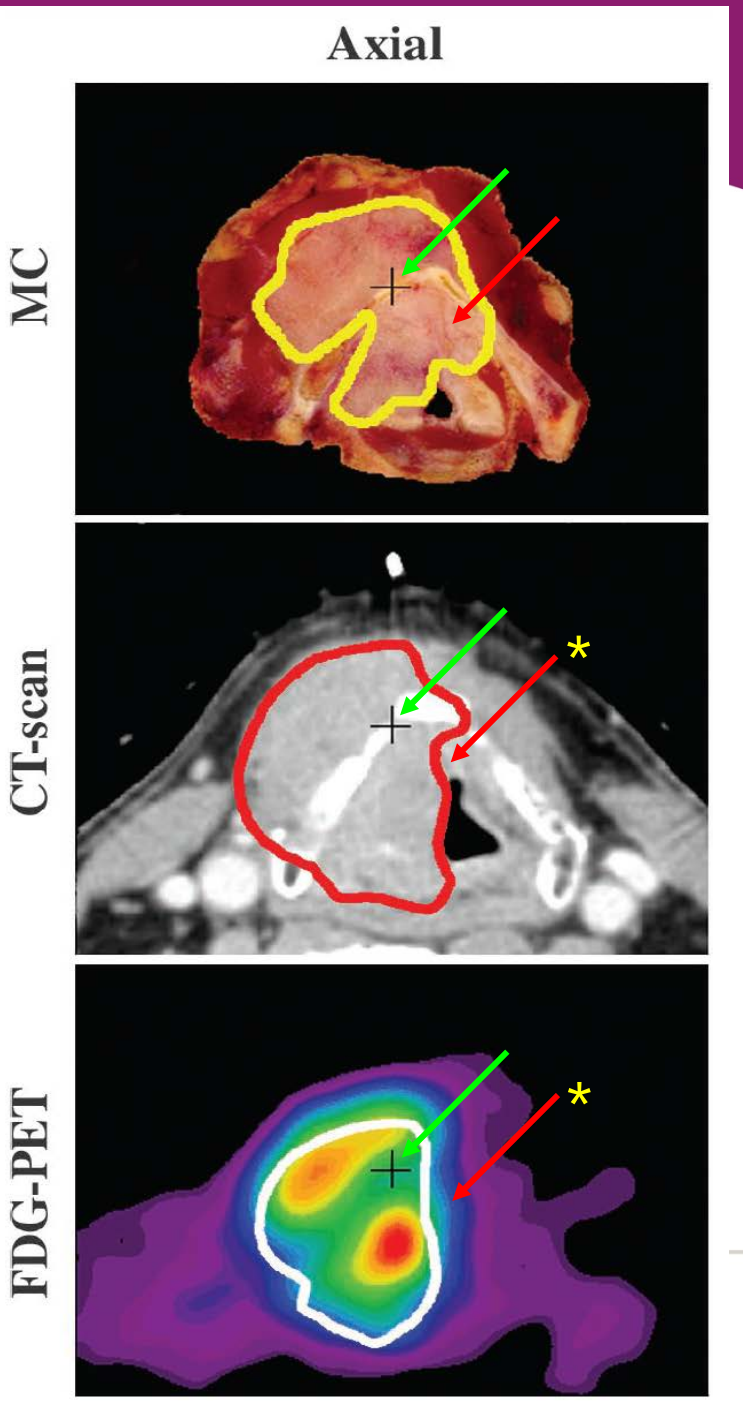

Target volumes - GTV

- ICRU 83 suggests specifying the modality used to delineate the GTV
- Primary rectal tumour (prone)
  - 1. GTV-T (CT)
  - 2. GTV-T (MRI T1 fat sat)
  - 3. GTV-T (FDG-PET)
  - 4. GTV-T (F-miso-PET)

  - Pre-RT so GTV-T (CT, 0 Gy)

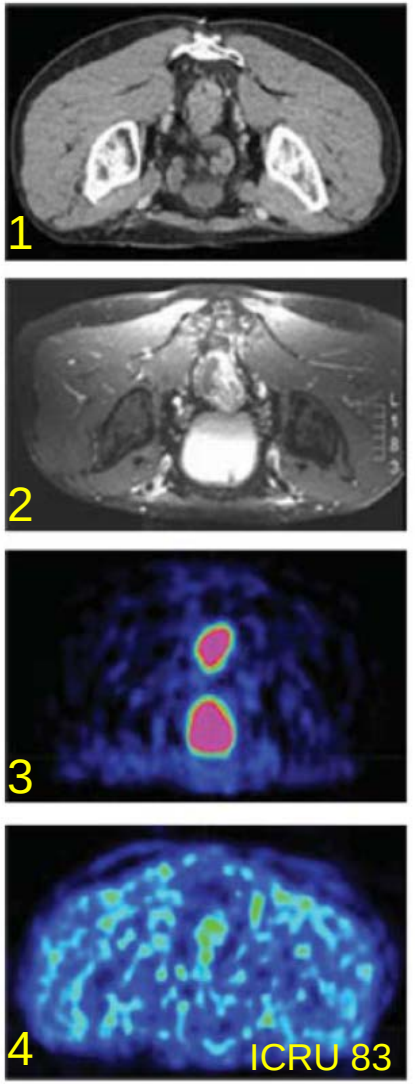

Target volumes - GTV

- Talk to your radiologists!

- They know ***lots*** about
  - Choosing the best imaging
  - The correct imaging sequences
  - Interpreting the imaging



Target volumes - GTV

- Need clear definitions for target volume delineation (TVD) protocol
  - What imaging to use
  - How to interpret imaging
  - How to deal with uncertainties on the imaging

Improving concordance

Rasch *et al. Radiation Oncology* 2010, **5**:21
http://www.ro-journal.com/content/5/1/21

RESEARCH Open Access

Decreased 3D observer variation with matched CT-MRI, for target delineation in Nasopharynx cancer

Coen RN Rasch[1*], Roel JHM Steenbakkers[2], Isabelle Fitton[3], Joop C Duppen[1], Peter JCM Nowak[4], Frank A Pameijer[5], Avraham Eisbruch[6], Johannes HAM Kaanders[7], Frank Paulsen[8], Marcel van Herk[1]

ESTRO School

Improving concordance

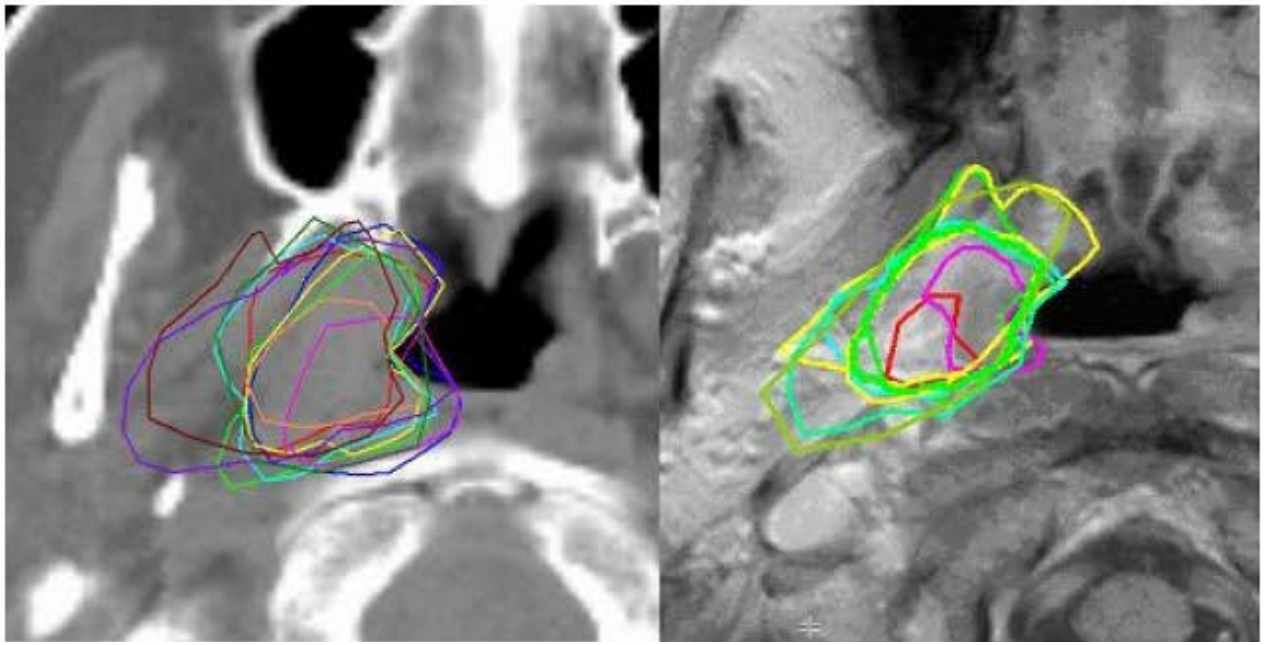

Better imaging improves consistency

Improving concordance

- The largest impact was by improved target volume definitions = protocol

- Biggest differences seen at the top and bottom

  A problem of imaging

- Better concordance using sagittal image display

Improving concordance

- Careful protocols required
  - Carefully written
  - Carefully followed

- The blue group ... ?

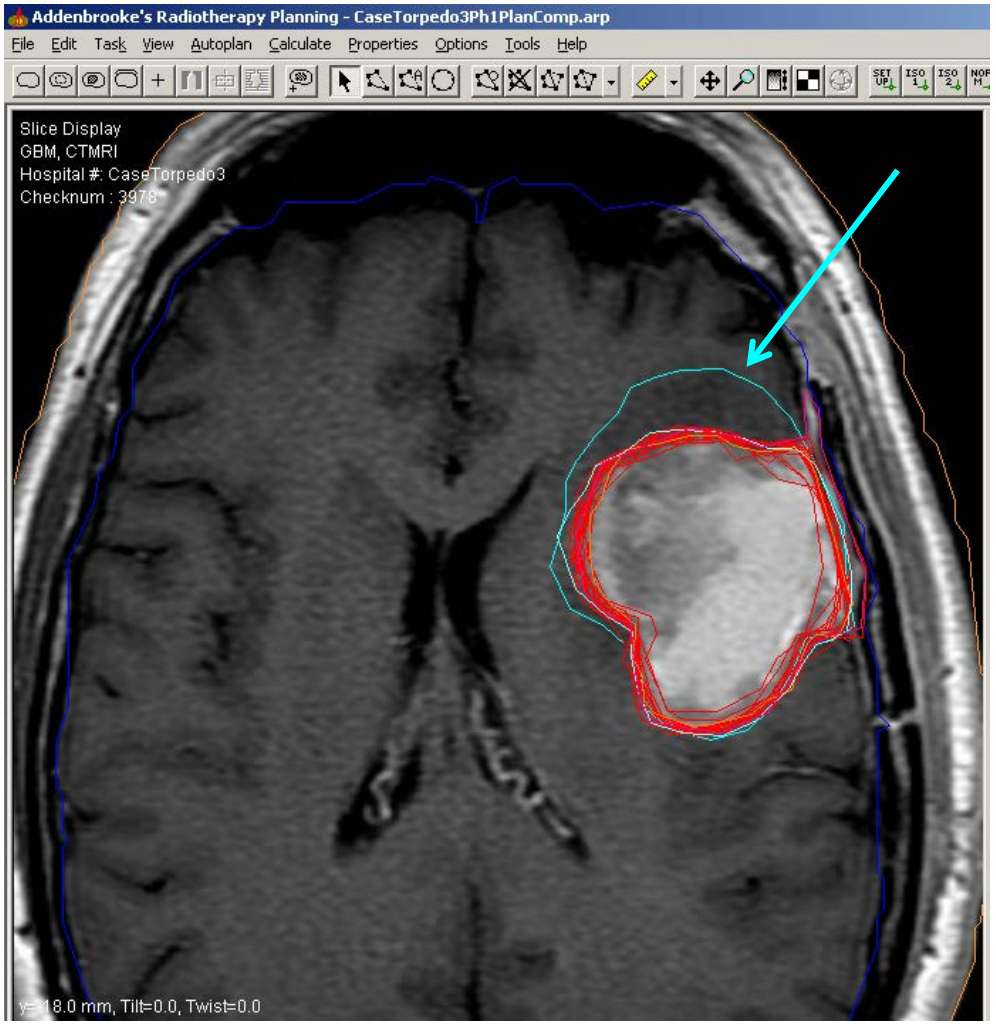

ESTRO School

Quality of RT affects outcome

VOLUME 28 · NUMBER 18 · JUNE 20 2010

JOURNAL OF CLINICAL ONCOLOGY

ORIGINAL REPORT

(2010; 28(18): 2996-3001)

Critical Impact of Radiotherapy Protocol Compliance and Quality in the Treatment of Advanced Head and Neck Cancer: Results From TROG 02.02

Lester J. Peters, Brian O'Sullivan, Jordi Giralt, Thomas J. Fitzgerald, Andy Trotti, Jacques Bernier, Jean Bourhis, Kally Yuen, Richard Fisher, and Danny Rischin

Very scary results

Poor radiotherapy

↓ 20% in OS

↓ 24% in DFS



In 3% contouring responsible for poor outcome

ESTRO School

Quality of RT affects outcome

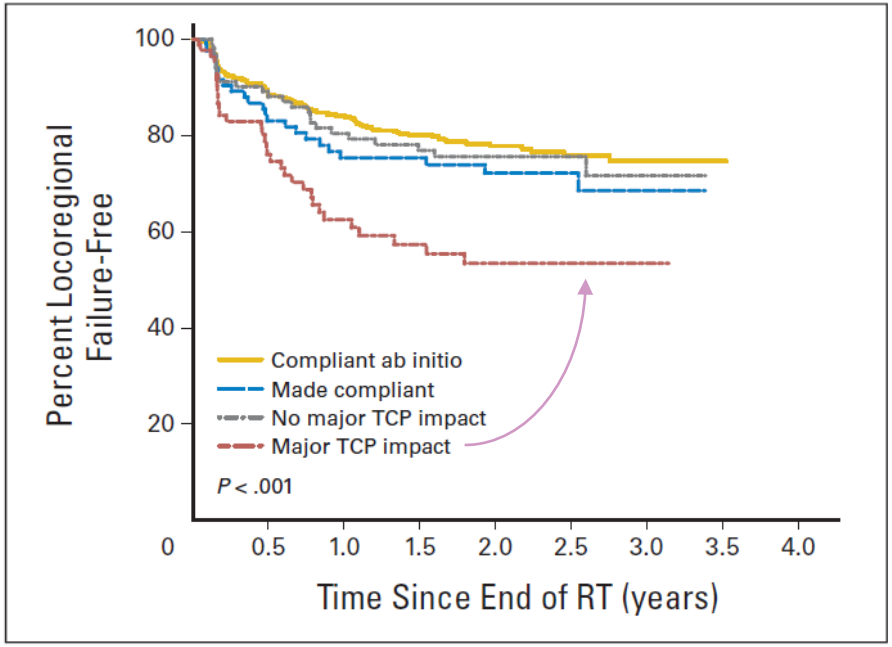

Fig 3. Time to locoregional failure by deviation status

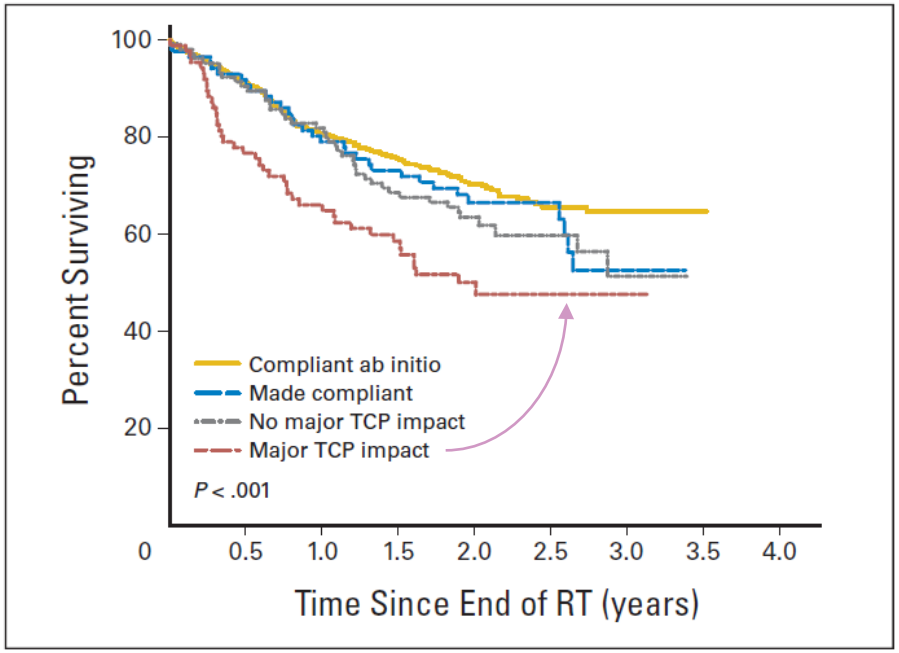

Fig 2. Overall survival by deviation status:

In 3% contouring responsible for poor outcome

TVD an important factor

ESTRO School

Target volumes - CTV

Target volumes - CTV

- CTV - contains demonstrable GTV and/or sub-clinical disease,
- Typically tumour ***cannot*** be seen or imaged in the CTV
- This volume must be treated adequately for cure

Target volumes - CTV

- Now includes the concept that the CTV contains sub-clinical disease ***with a certain probability***

- No consensus as to what probability actually requires treatment

- Probability of ~ 5-10% may be reasonable ***(i.e. cover in 90-95%)***
  Should it be lower or higher?

- Concept of probability introduced in ICRU 83 (2010)

Target volumes - CTV

- CTV is based on historical data
  - Derived from population data
  - Margin not individualised

- Some individualisation according to anatomical boundaries is possible
  - This implies that isotropic growing is often ***not*** appropriate to derive the CTV

Target volumes - CTV

- It is allowable to have more than one CTV if necessary
- It is assumed that tumour cell density is lower in the CTV than in the GTV
- Therefore lower dose may be appropriate

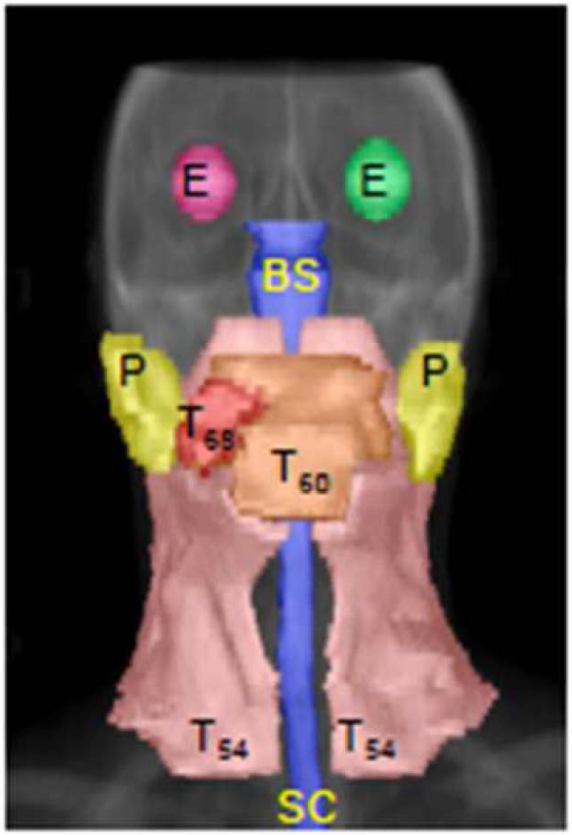

- CTV - ***not*** obvious from the imaging
- CTV ***cannot*** be imaged
- Based on knowledge of population pathology

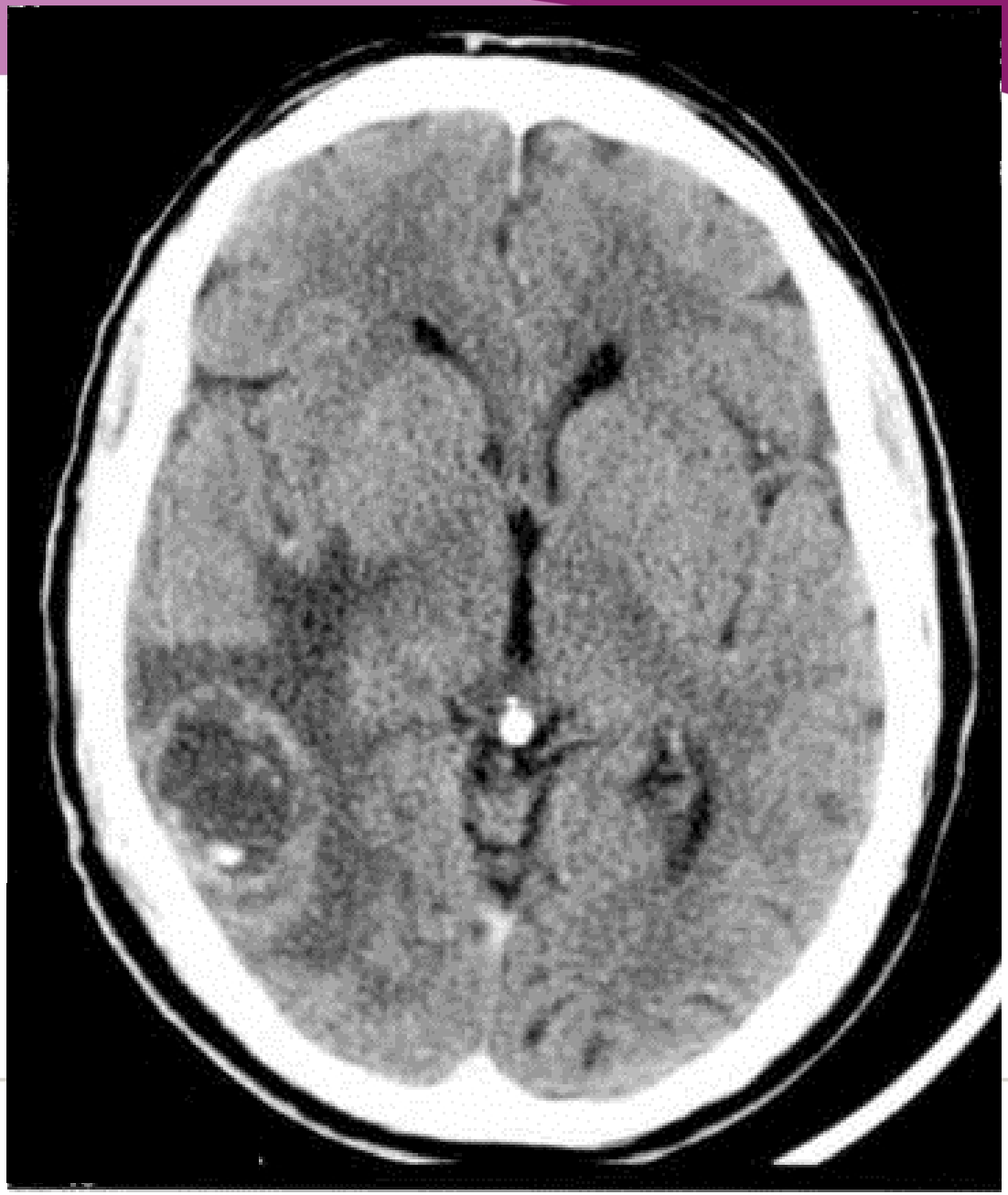

- CTV is an‘average’ volume
- CTV is enclosed by the skull
- Anatomical considerations useful

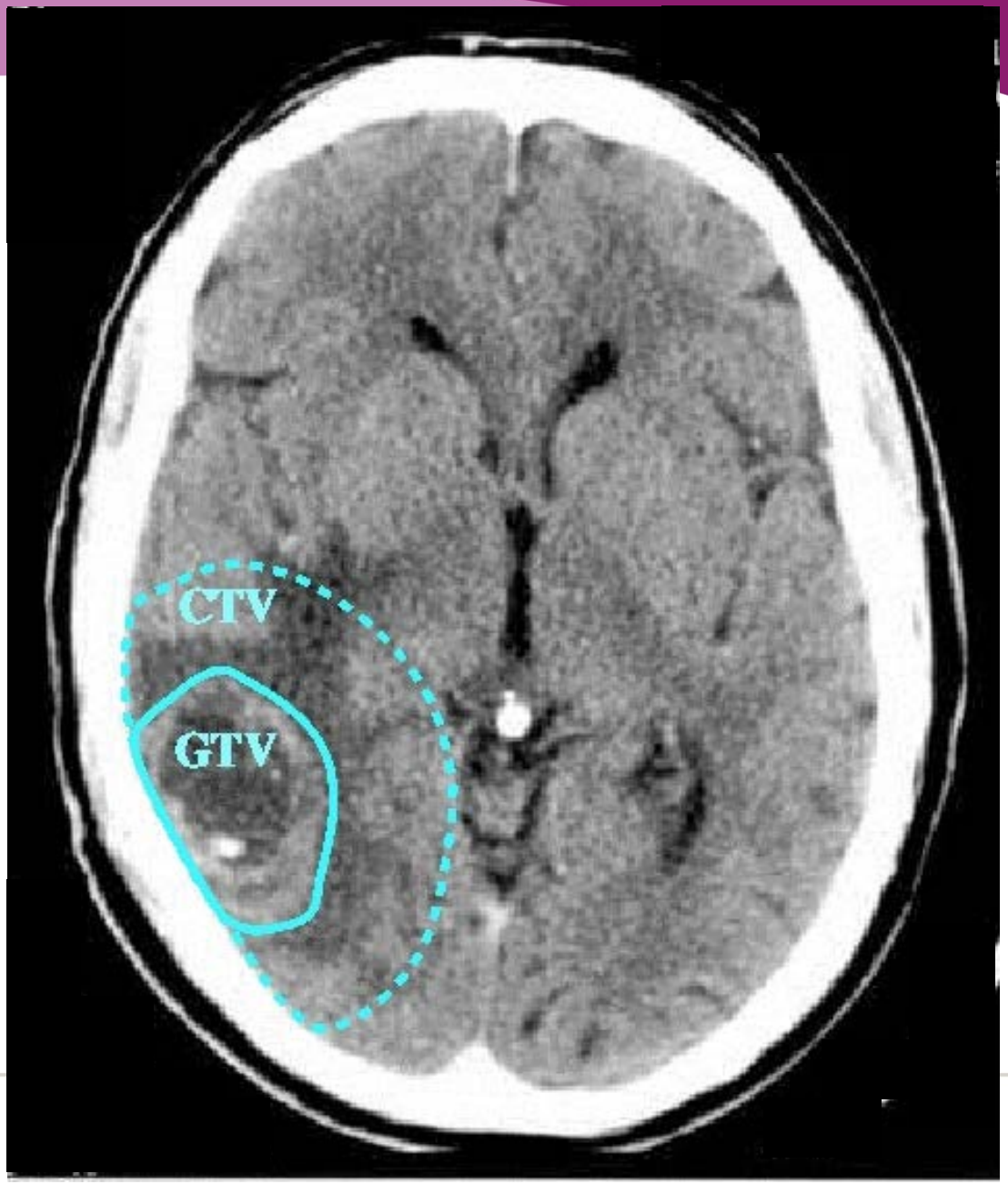

Target volumes - CTV

- The extent of the CTV margin depends upon imaging techniques

- Better imaging may increase the GTV, while reducing the CTV margin- to give the same final volume

- Imaging techniques will change over time

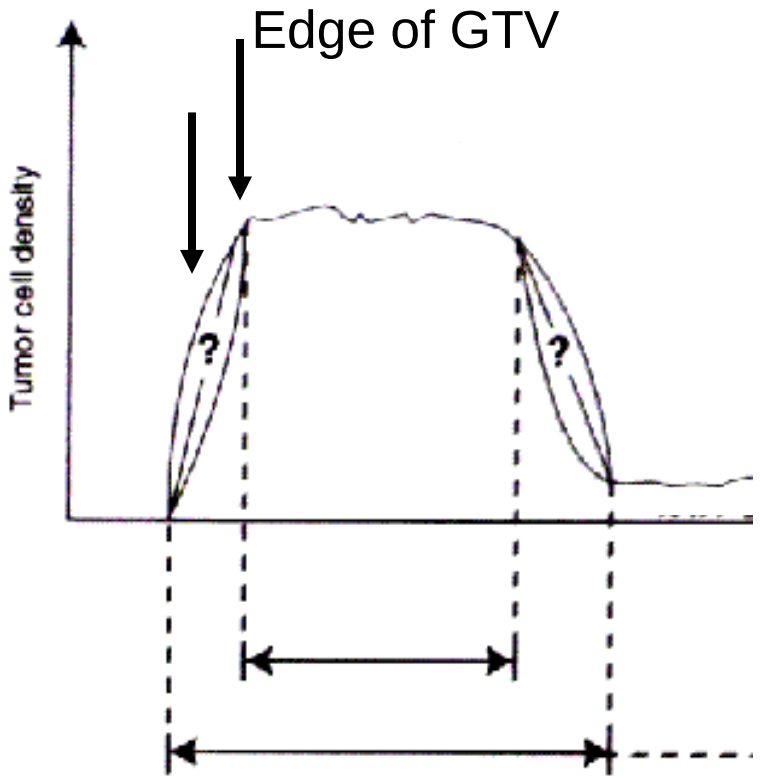

Target volumes - PTV

Target volumes - PTV

PTV is a geometric concept designed to ensure that the prescription dose is actually delivered to the CTV

In a sense, it is a volume in space, rather than one directly related to the anatomy of the patient

PTV may extend beyond bony margins, and even outside

Target volumes - PTV

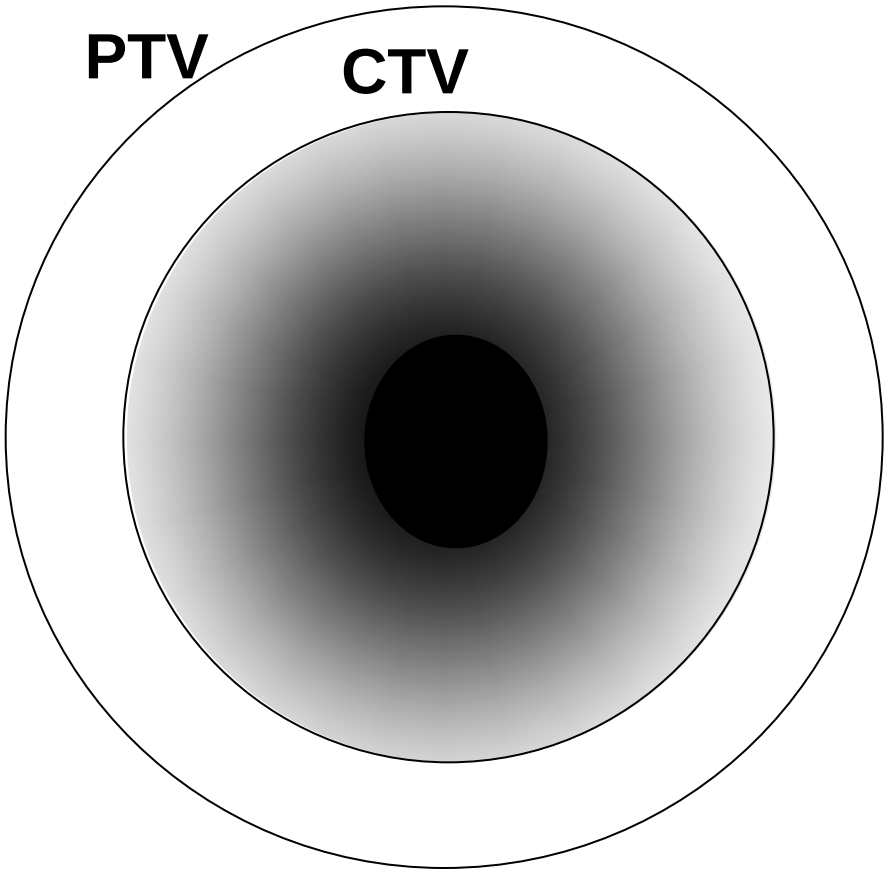

CTV safely enclosed within PTV

Target volumes - PTV

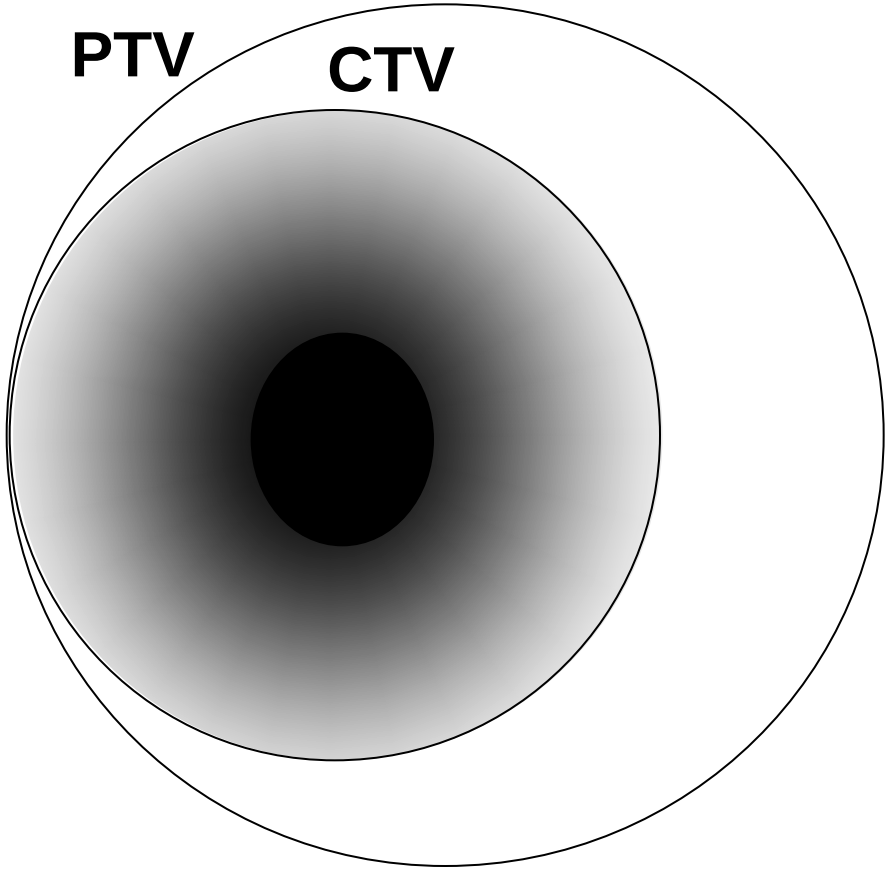

CTV safely enclosed within PTV

Target volumes - PTV

PTV outside the patient

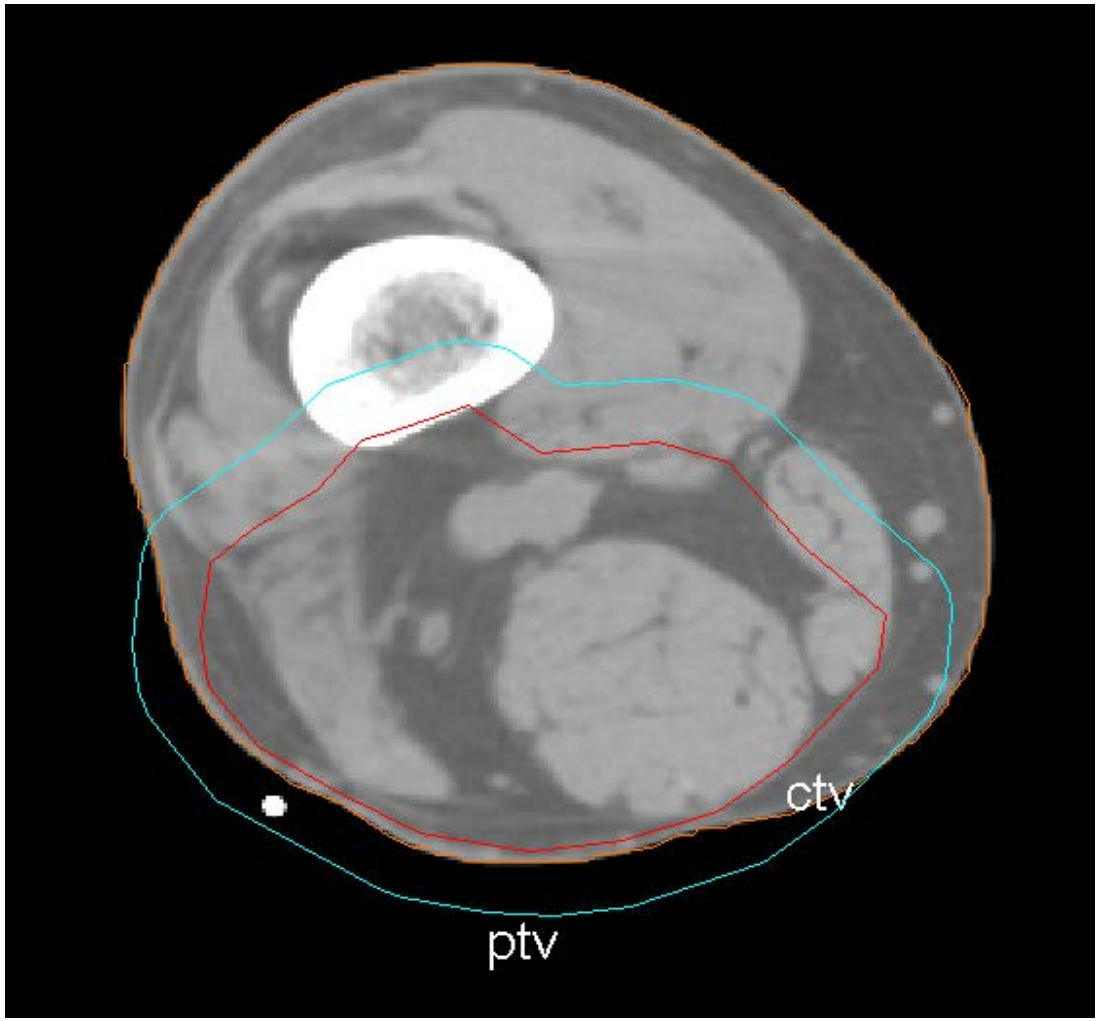

Target volumes - PTV

- The CTV must be treated adequately for cure
- The PTV is used to ensure that the CTV ***is*** properly treated
- PTV designed to allow for uncertainties in the process of planning and delivery
  - These uncertainties are many …

Target volumes - PTV

- The PTV concept has been evolving:
  - ICRU 50 introduced the PTV
  - ICRU 62 discussed the PTV concept more fully, but without specifics

- BIR 2003 describes how to calculate the PTV margin, in detail

- ICRU 83 has some important additional advice

Target volumes – PTV

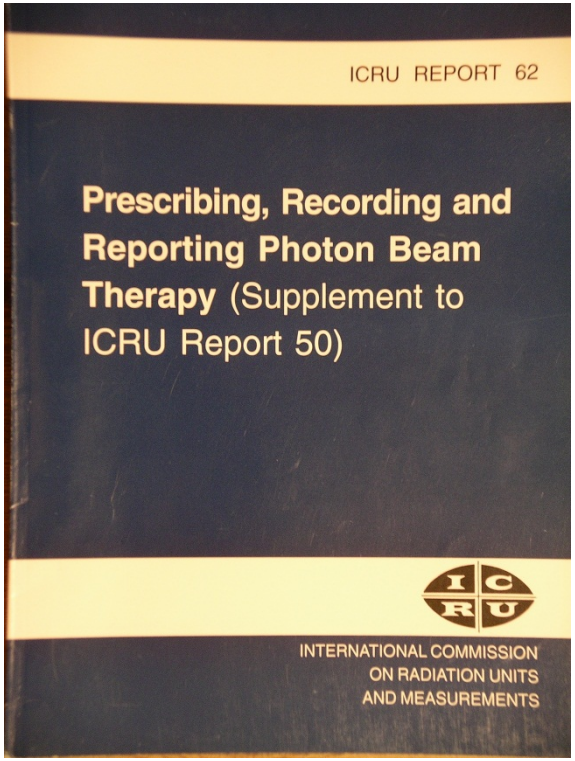

ICRU 62
(1999)



BIR
(2003)

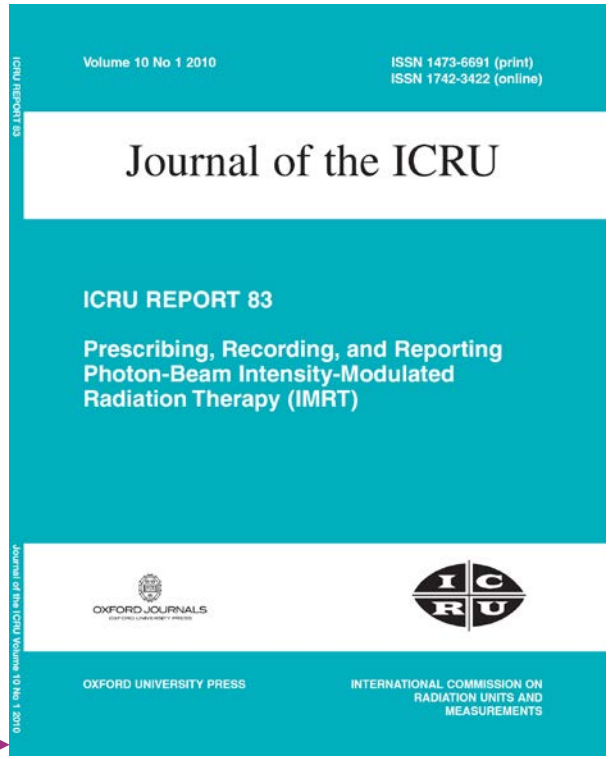

ICRU 83
(2010)

Target volumes – PTV

- ICRU 62 suggested 2 components to the PTV:
  Internal Margin IM – for eg organ movement
  Setup Margin SM – for set-up inaccuracies

  CTV + "Internal Margin" (IM) = ITV *
  ITV + "Set-up Margin" (SM) = PTV

- These are useful to remind about the basis of errors

  * ITV= Internal Target Volume

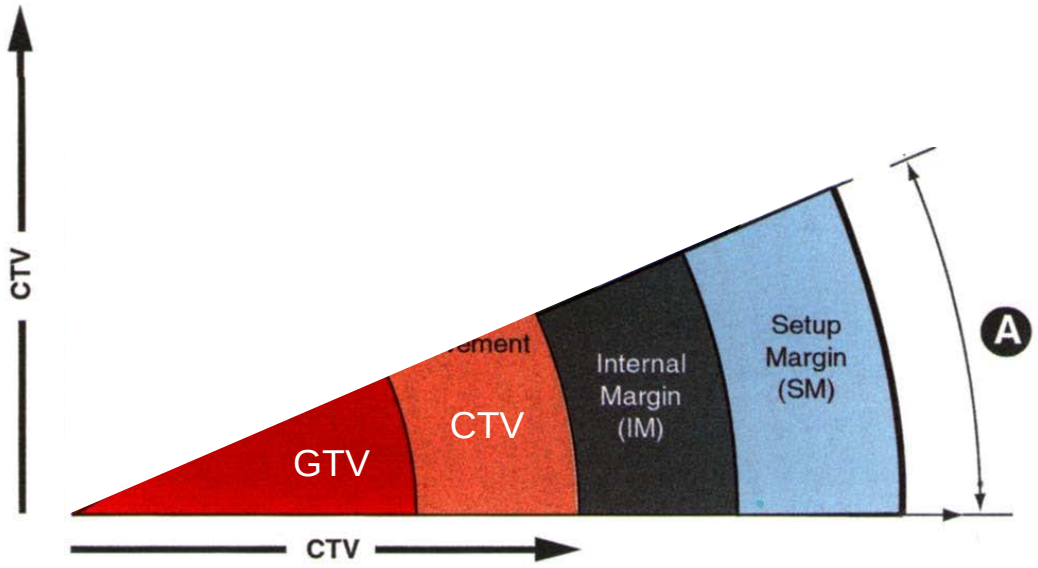

- Fig from ICRU 62 (also in ICRU 71)
- Adding IM + SM to reach the PTV

Gross Tumor Volume (GTV)
Subclinical Involvement
Internal Margin (IM)
Set Up Margin (SM)

ESTRO School

Target volumes – PTV

- ICRU 62 also acknowledged that simple addition may not be :
  - realistic – because the margin becomes very large
  - correct – because not every error occurs in the same direction on the same occasion

- Components to be added in quadrature rather than arithmetically

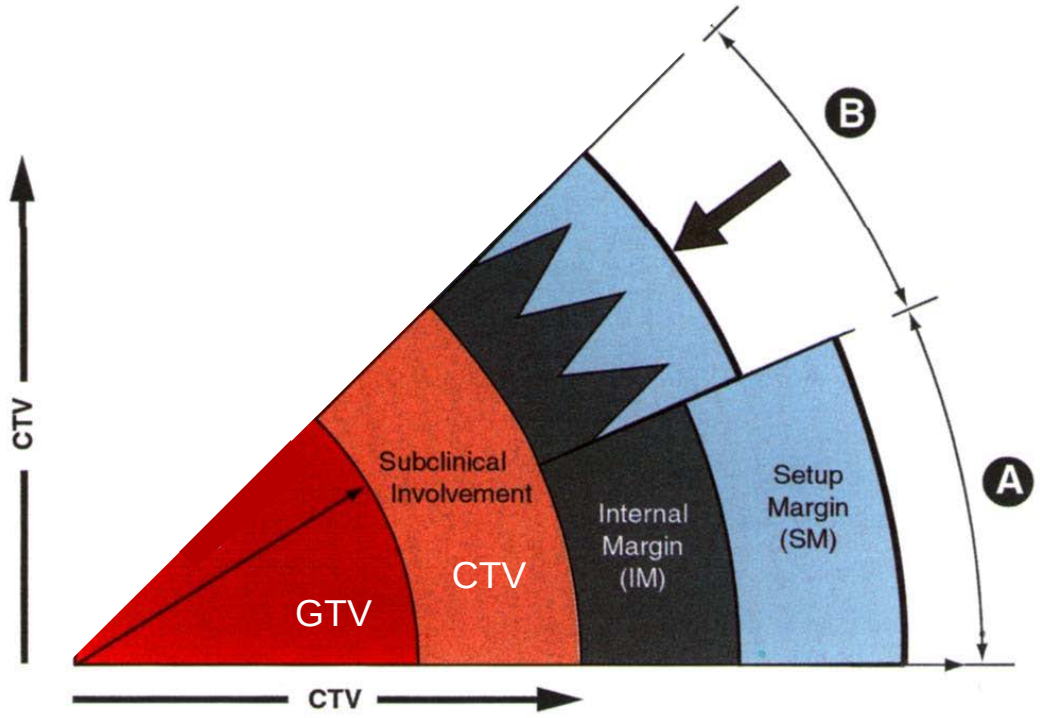

- Scenario B
- Adding IM + SM in quadrature
- Specific margins must still be addressed

Gross Tumor Volume (GTV)
Subclinical Involvement
Internal Margin (IM)
Set Up Margin (SM)

ESTRO School

Target volumes – PTV

- ICRU 62 had 2 components to the PTV:
  Internal Margin IM
  Set-up Margin SM

- BIR 2003 suggests 2 different components:
  Systematic error margin STV *
  Random error margin (STV to PTV margin)

- The ***concept*** of the PTV remains the same

* STV= Systematic Target Volume

Target volumes – PTV

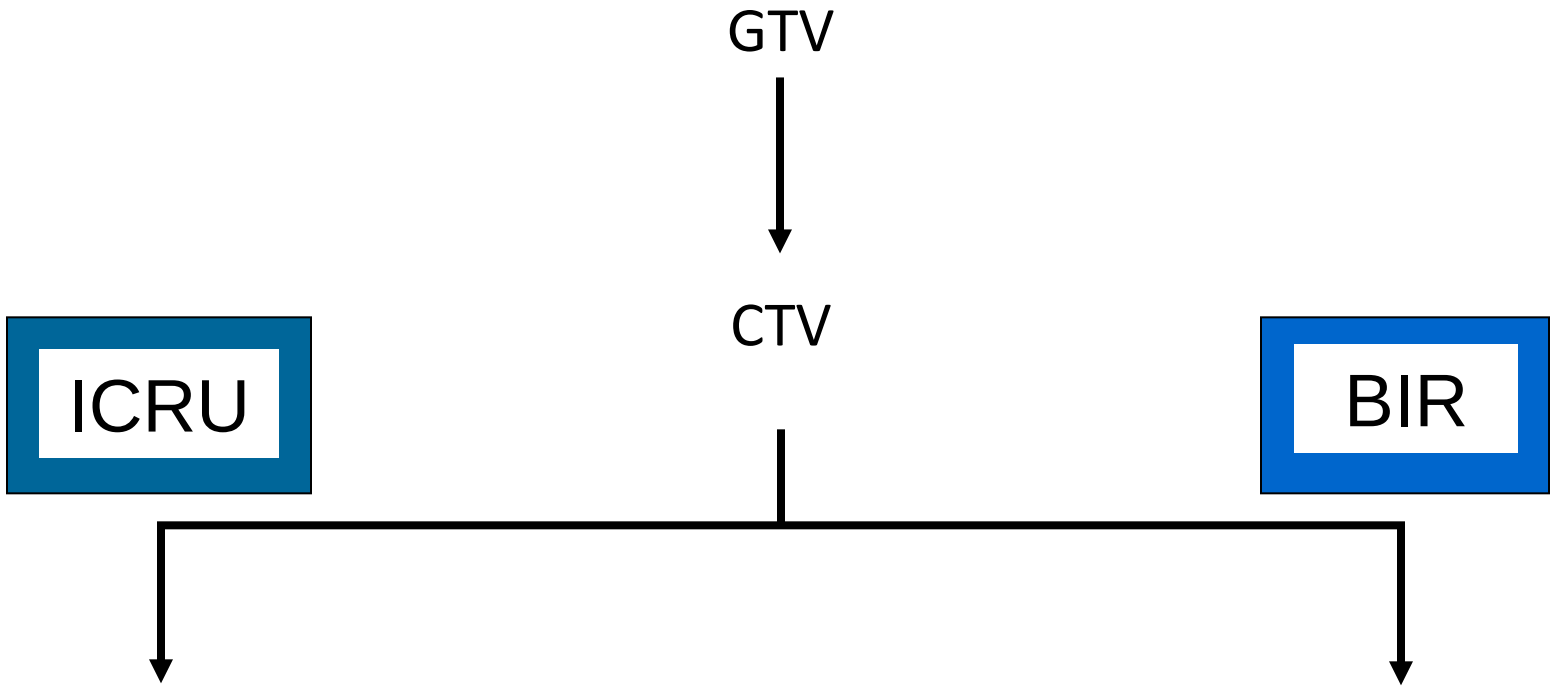

PTV = IM + SM

(**conceptual**)

PTV = systematic + random

(**quantitative**)

Target volumes – PTV - Adaptation

To date PTV margins have been based on population data

Imaging during treatment – allows the concept of individualised PTV margins

Eg. Plan of the day for bladder cancer treatments

This could be a whole separate talk ……

Target volumes – OARs + PRVs (and RVR)

OAR - Organ at Risk

PRV - Planning organ at Risk Volume

Other volume - RVR

- **Remaining Volume at Risk – RVR**

- Volume of the patient excluding the CTV and OARs

- Relevant because unexpected high dose can occur within it
- Can be useful for IMRT optimisation

- Might be useful for estimating risks of late carcinogenesis

Target volumes – OARs

- Organs at Risk are normal tissues whose radiation tolerance influences treatment planning, and /or prescribed dose
- Now know as OARs
- Uncertainties apply to an OAR as well as to the CTV…

OARs

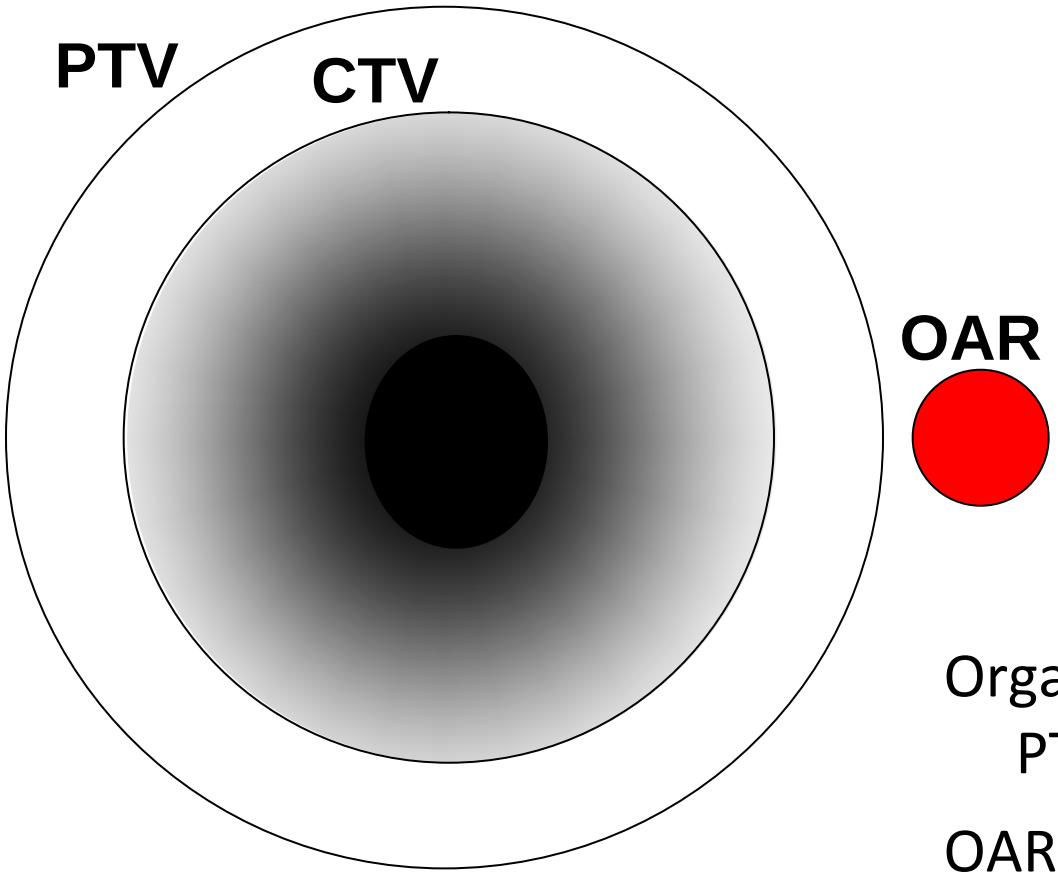

Organ at Risk clear of PTV

OAR safe …

OARs

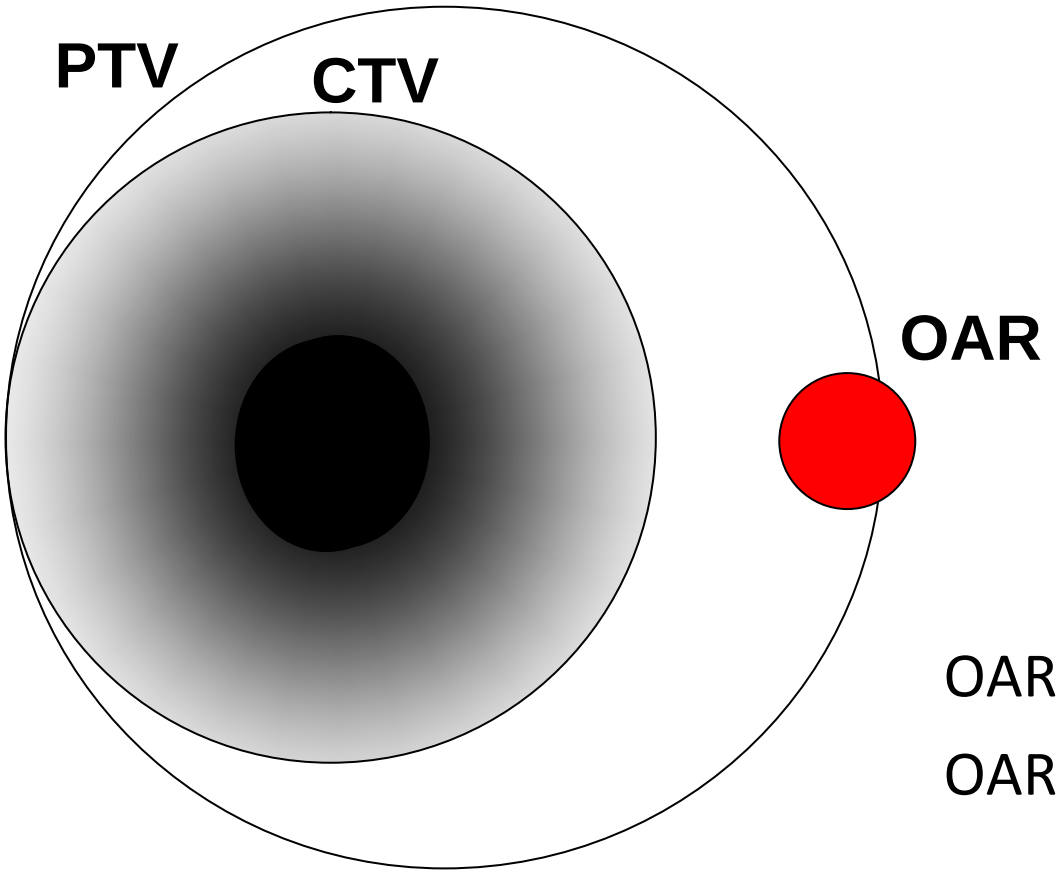

OAR moves with CTV

OAR not so safe…

Target volumes - OARs

- Imaging must also show critical normal structures (Organs At Risk - OARs)

- Essential to achieve a therapeutic gain

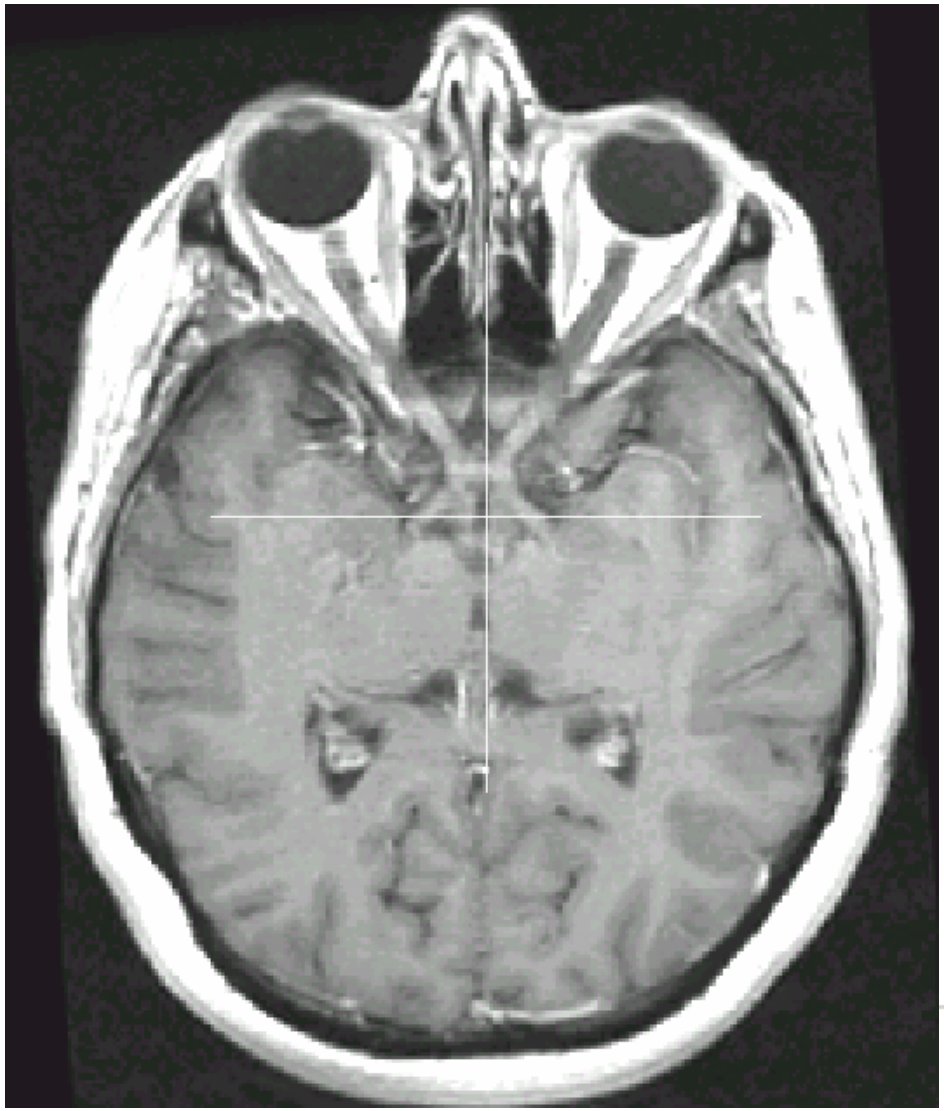

Target volumes – OARs

For parallel organs, comparison between plans, patients or centres requires the ***whole*** organ to be delineated, according to an agreed ***protocol***

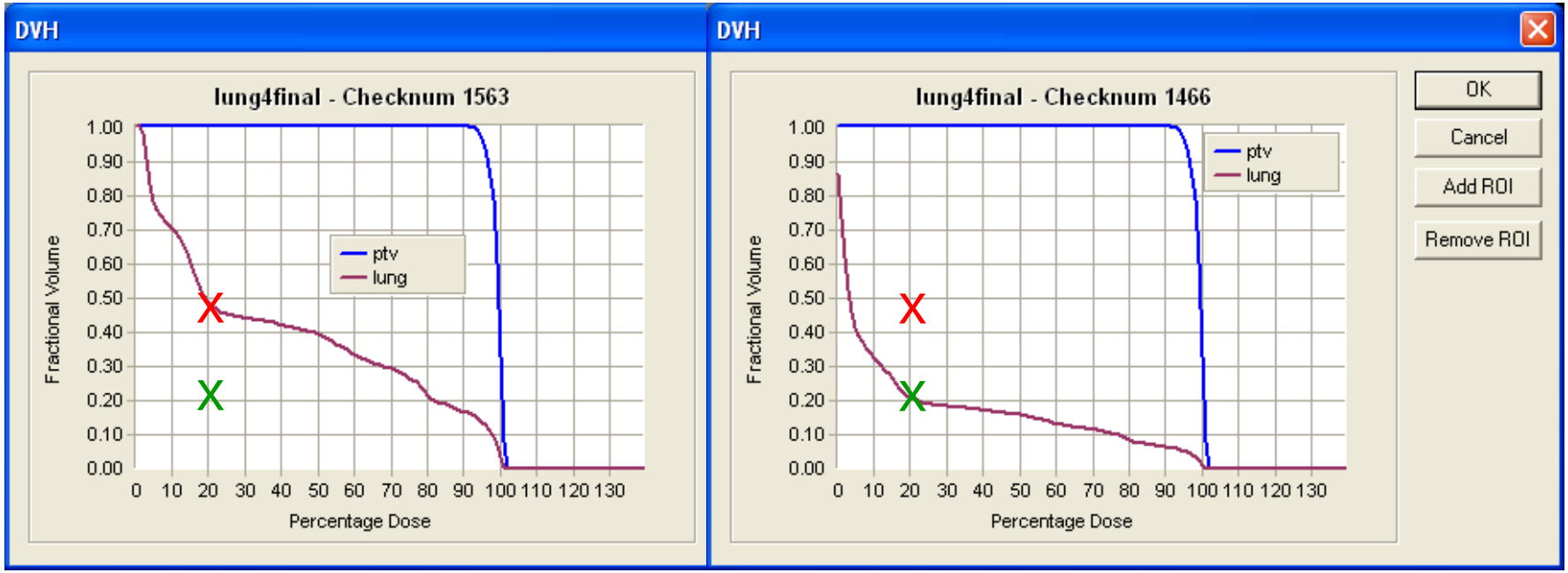

- Whole lung not outlined
- Now with *whole* lung
- Better DVH!

ESTRO School

Target volumes – OARs

For other parallel organs, over-contouring may lead to DVHs which ***appear better*** but are ***incorrect***

Rectum– needs clear delineated, according to an agreed ***protocol***

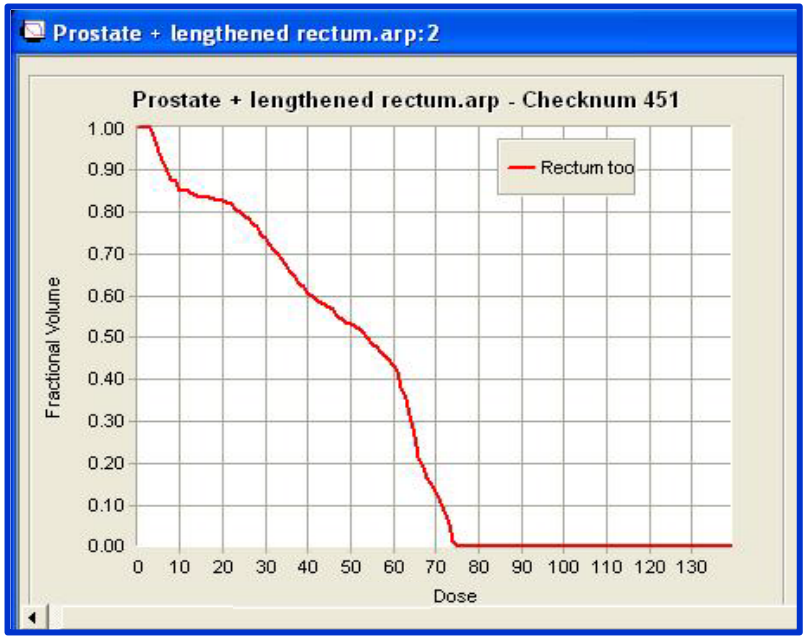

- Rectum 'over-contoured'

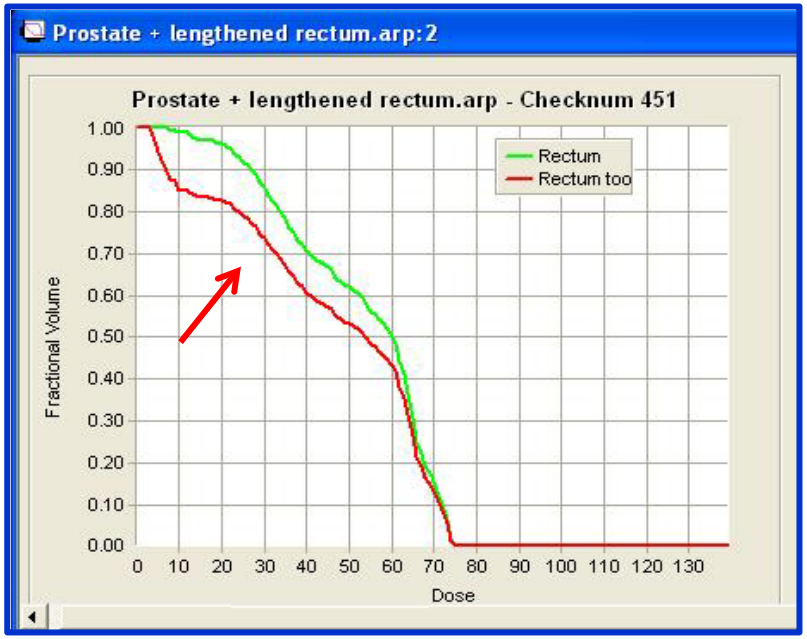

- 'Better' DVH is incorrect

ESTRO School

Target volumes – OARs + PRVs

- Uncertainties apply to the OAR … so a ‘PTV margin’ can be added around it - to give the Planning organ at Risk Volume (PRV)

- But … the use of this technique will substantially increase the volume of normal structures

- May be smaller than PTV margin

  Component for systematic error can often be smaller

Target volumes – PRV

- The use of a PRV around an Organ at Risk is relevant for OARs whose damage is especially dangerous

- This applies to organs where loss of a ***small*** amount of tissue would produce a ***severe*** clinical manifestation

- A PRV is more critical around an OAR with serial organisation

Tissue architecture

Serial organ

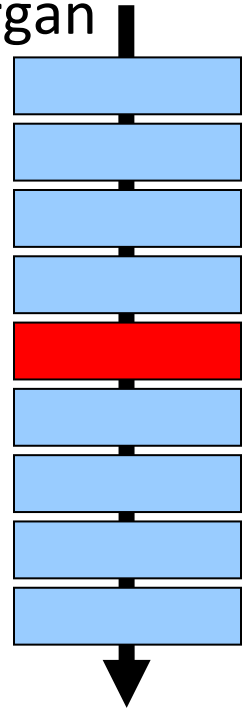

Damage to 1 part causes failure – eg spinal cord

Severe clinical consequence

- Parallel organ

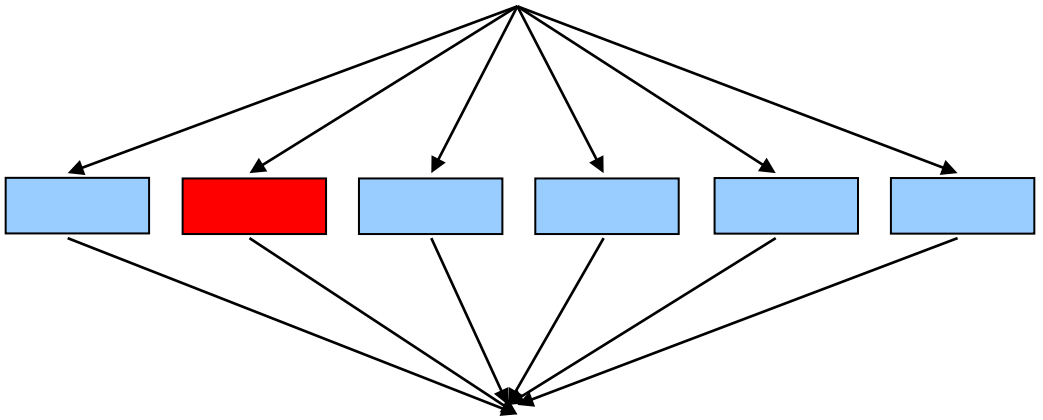

- Damage to 1 part (only) does not compromise function
- Examples …

ESTRO School

Target volumes – PRV

- Spinal cord & optic nerves/chiasm perfect examples where a PRV may be helpful
  - serial tissue organisation
  - damage is clinically catastrophic

- Add a PRV, especially if high doses are planned
- Almost no other OARs where a PRV is needed (or useful)
- PRV may be misleading for parallel organs

(This advice is more definitive than ICRU 83)

Target volumes – PRV

PRV around optic nerves and chiasm

Allows dose escalation

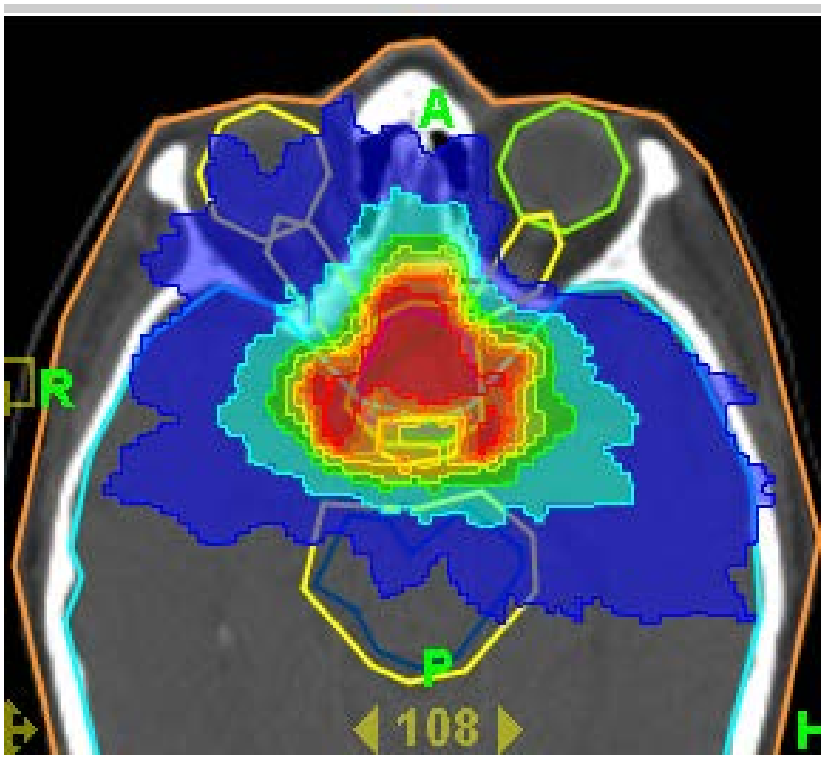

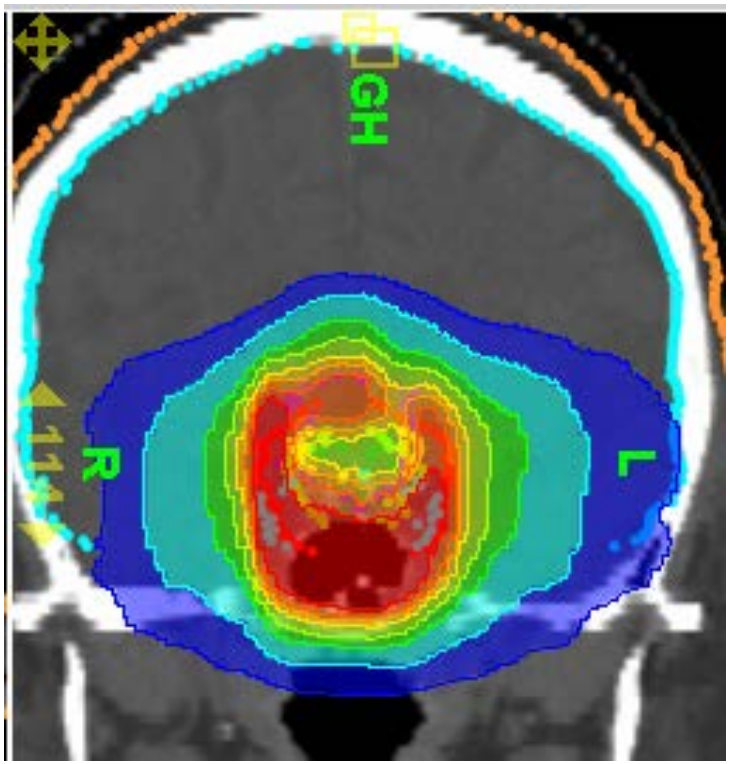

Target volumes – PRV

- Kidney PRV 10mm
- DVH for PTVs ≈ PRVs
- PRV often not of particular value

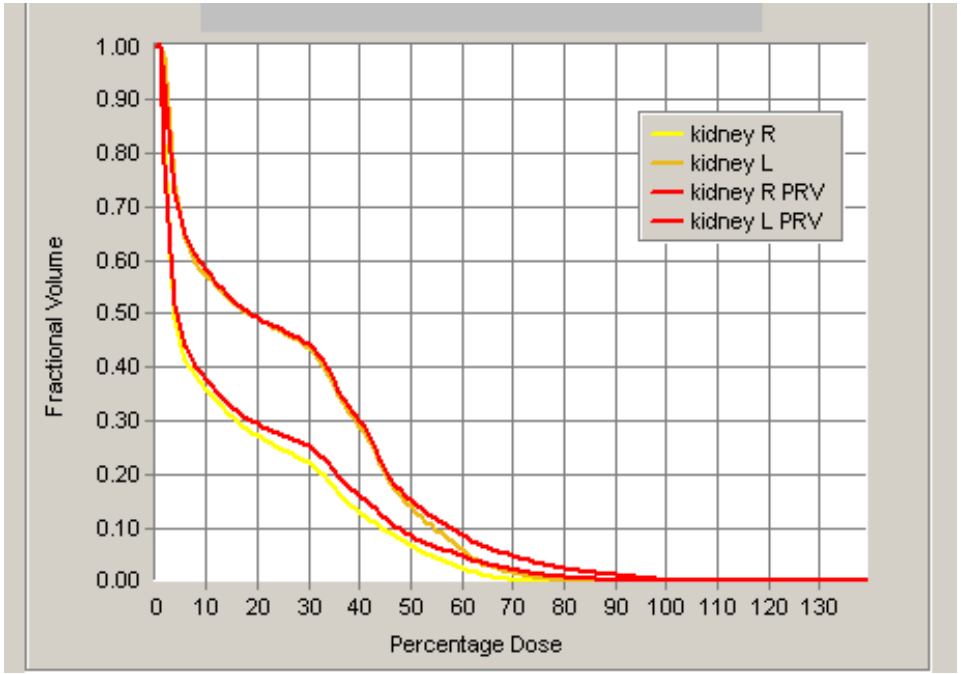

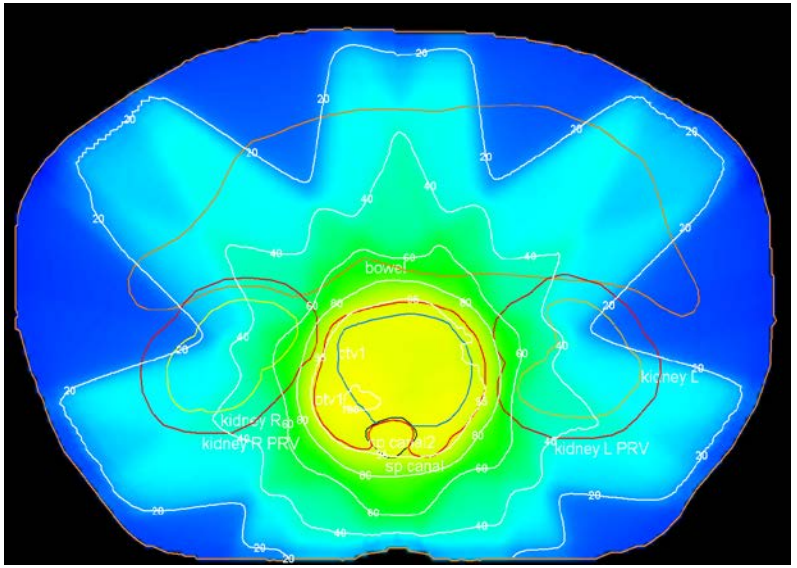

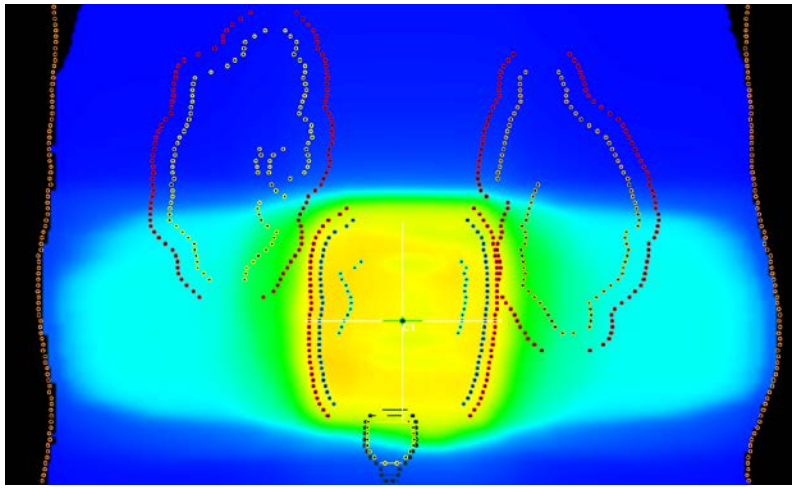

PRV

Example

Ca tonsil

Spinal cord close

Aim for 70 Gy

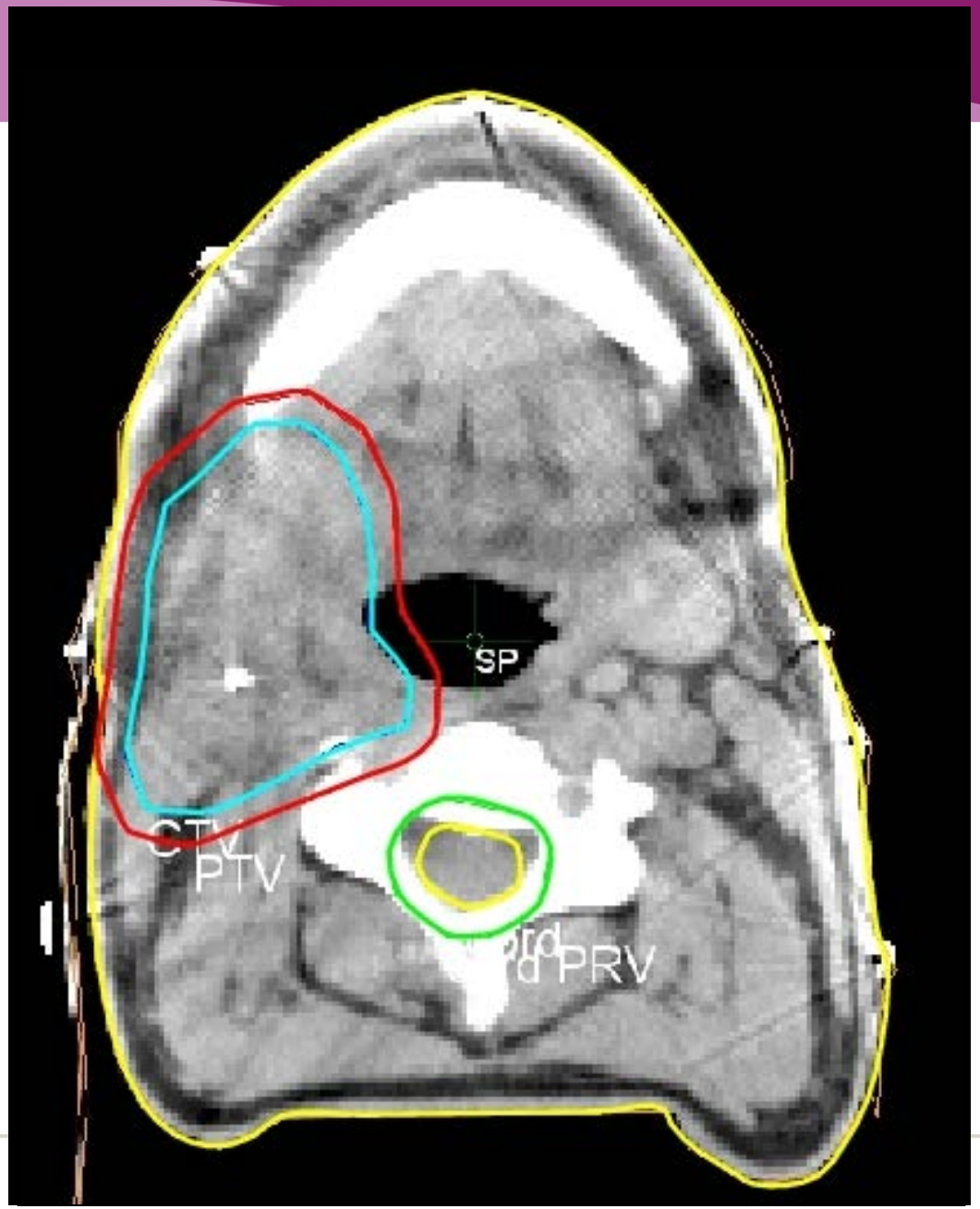

Simple outlines

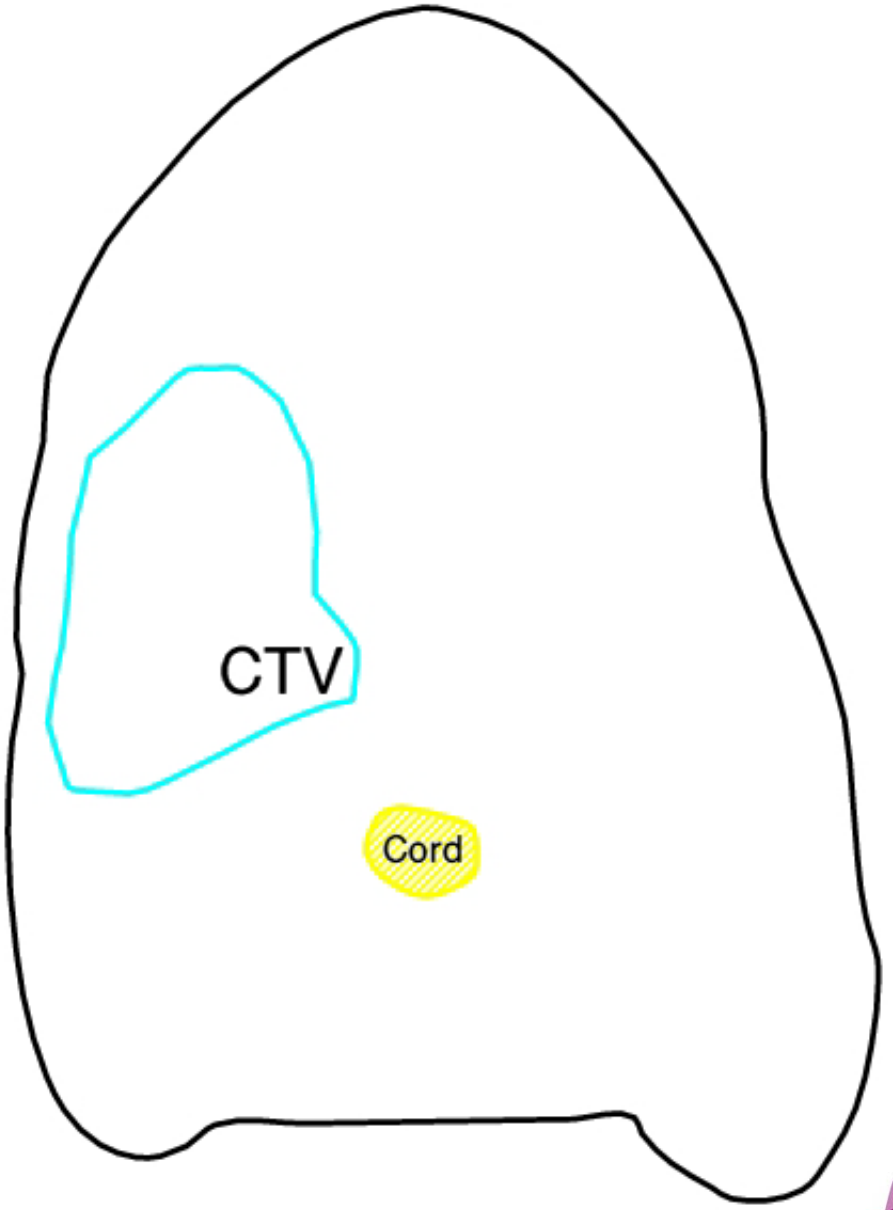

ESTRO School

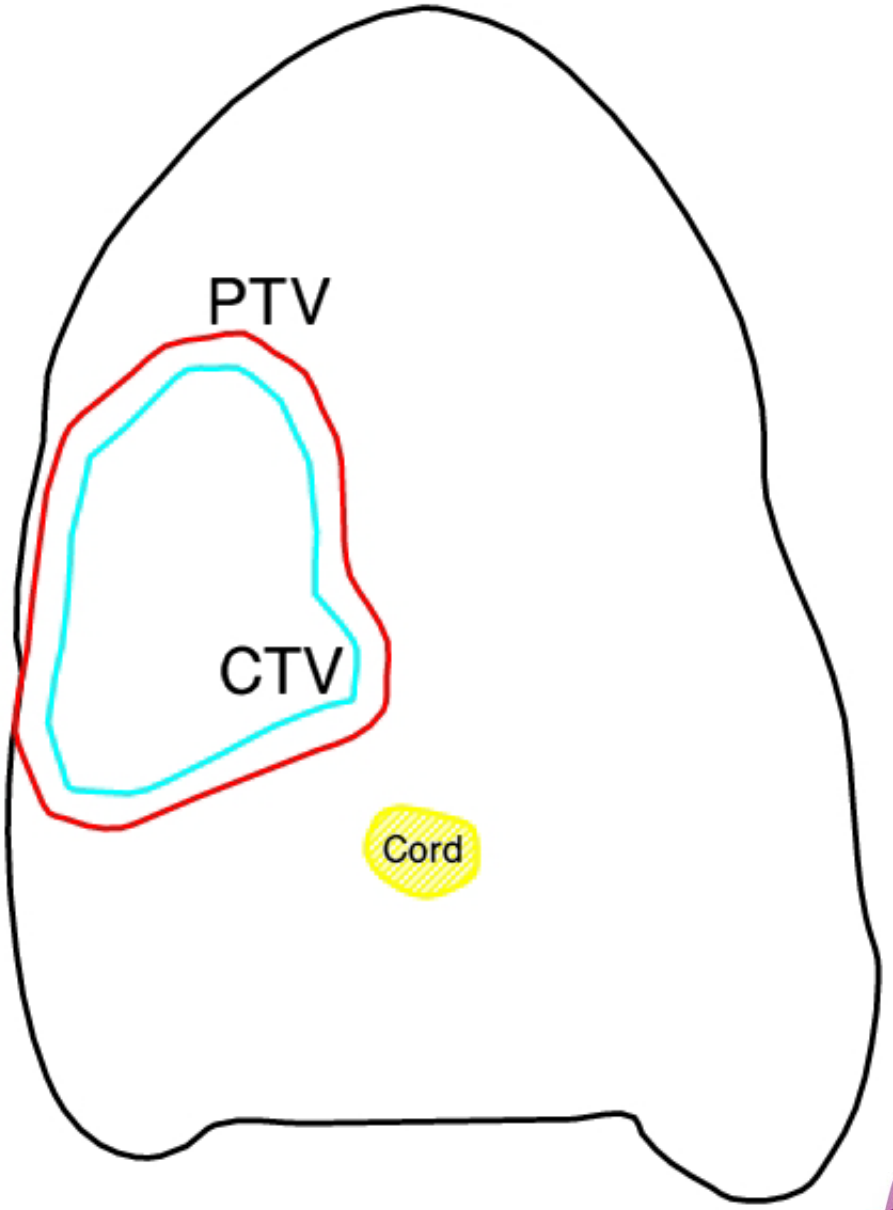

ESTRO School

Cord should be safe

PRV is away from PTV

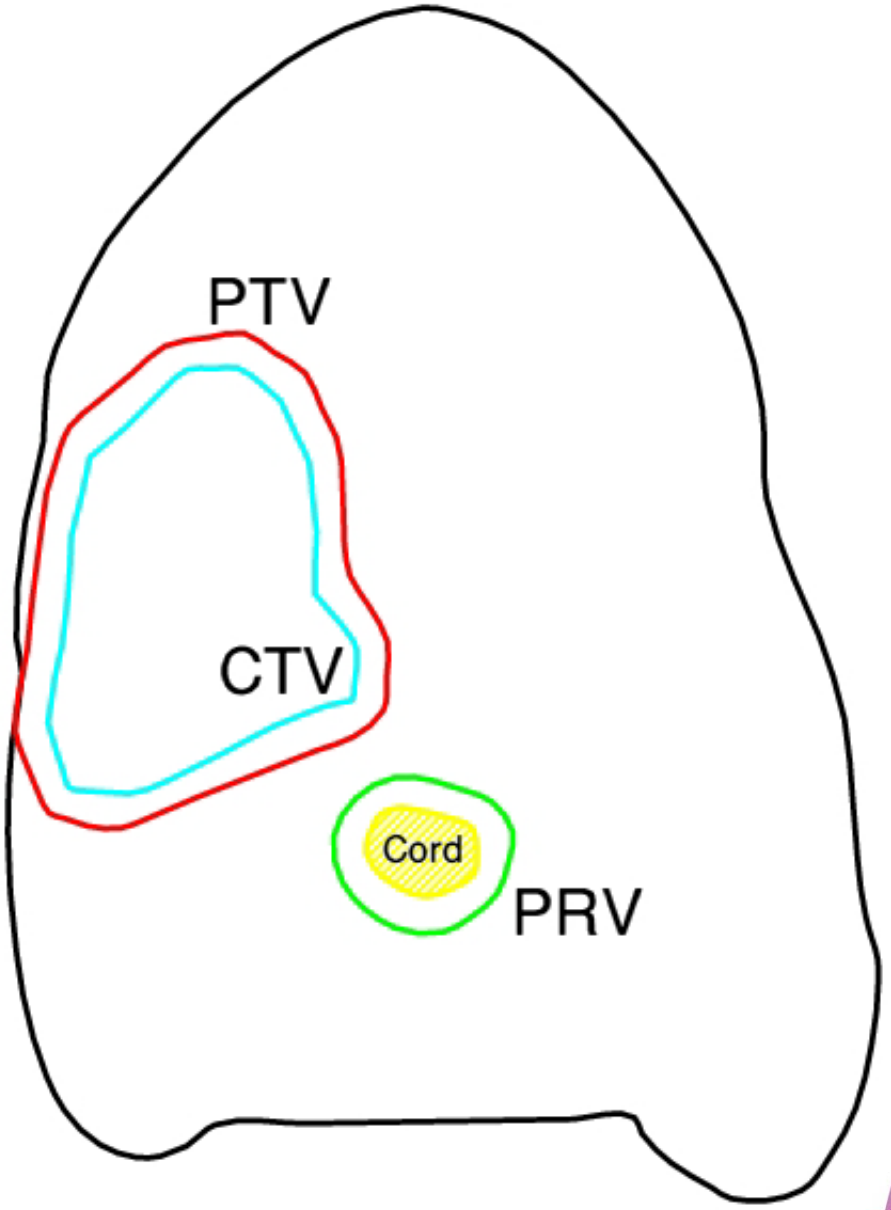

ESTRO School

- Cord still safe even if set up is imperfect
- Note: patient, CTV and cord have moved
- PTV and PRV have not moved

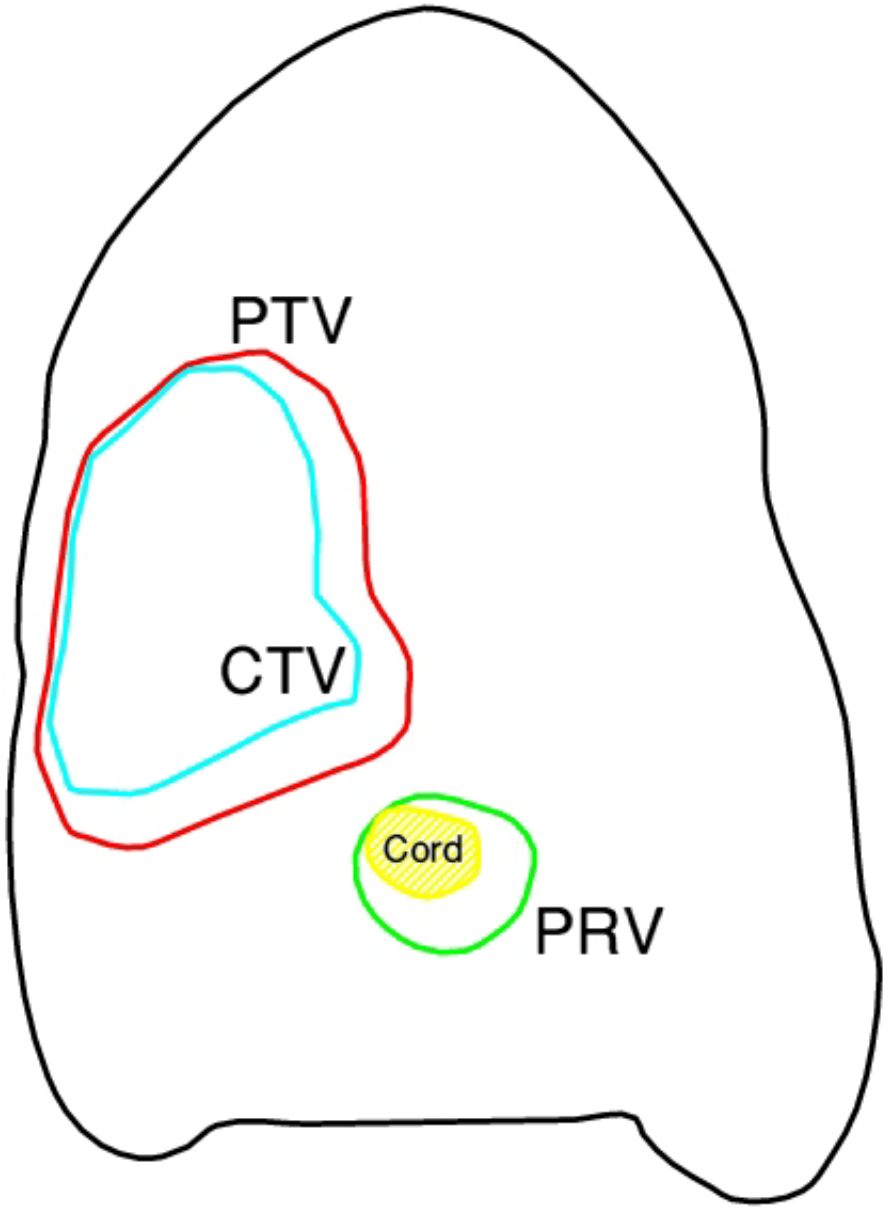

- PTV & PRV closer
- PRV shows area to avoid with high dose to ensure the cord is safe
- No conflict

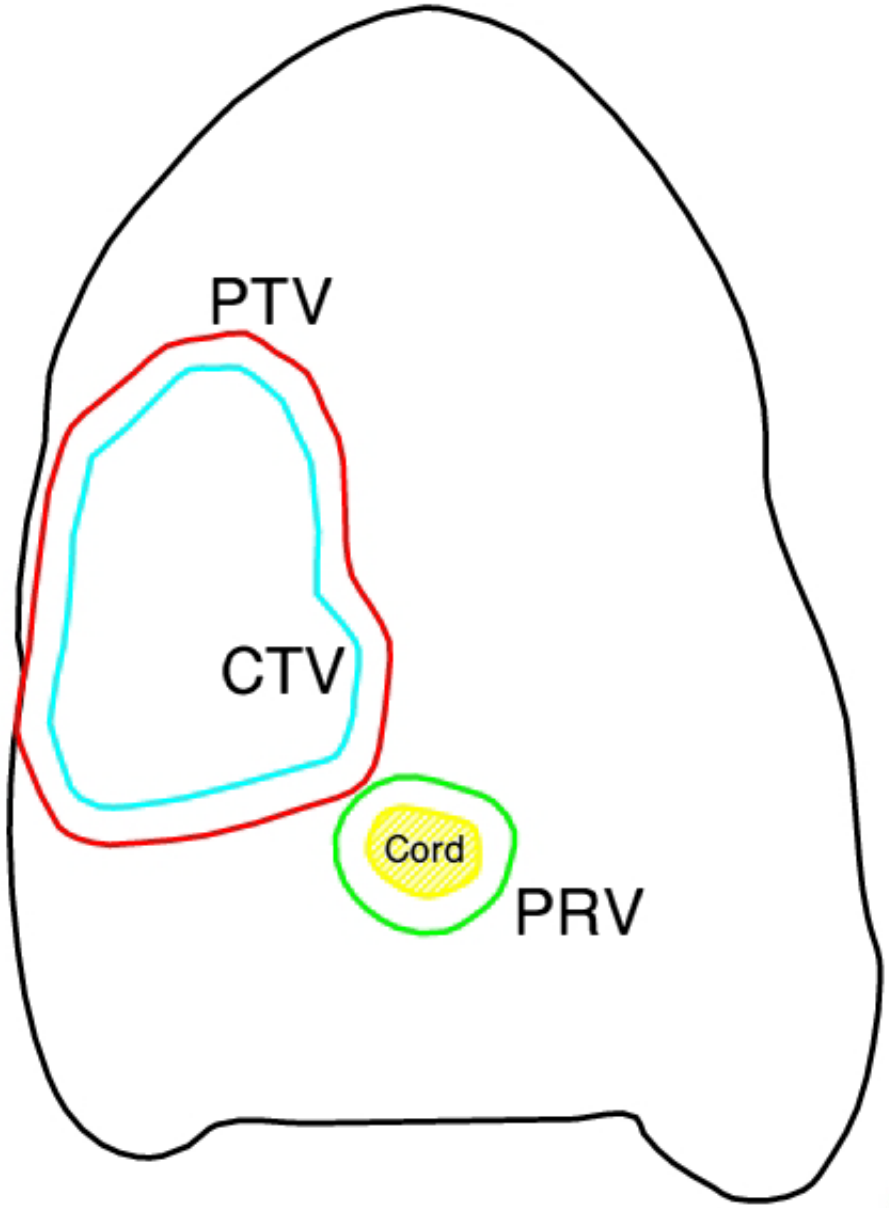

ESTRO School

Target volumes – PTV + PRV

PRV margin can be ***smaller*** than the PTV margin

This is a helpful step for high dose treatments close to an OAR

This is because OAR movement is usually a 1D problem
(occasionally 2D, rarely 3D)

Target volumes – overlaps

Target volumes – overlaps

There are always occasions when PTV and OARs/PRVs overlap

What is the best strategy? ...

... **Use IMRT!**

The planning concept has changed between ICRU 62 and 83 …..

In fact changed ***completely*** in ICRU 83

ICRU 62 – edit PTV (even CTV) – fine for CRT

ICRU 83 – ***do not*** edit – better for IMRT

- PTV and PRV now overlap
- A problem for planning
- We need a solution to the dilemma

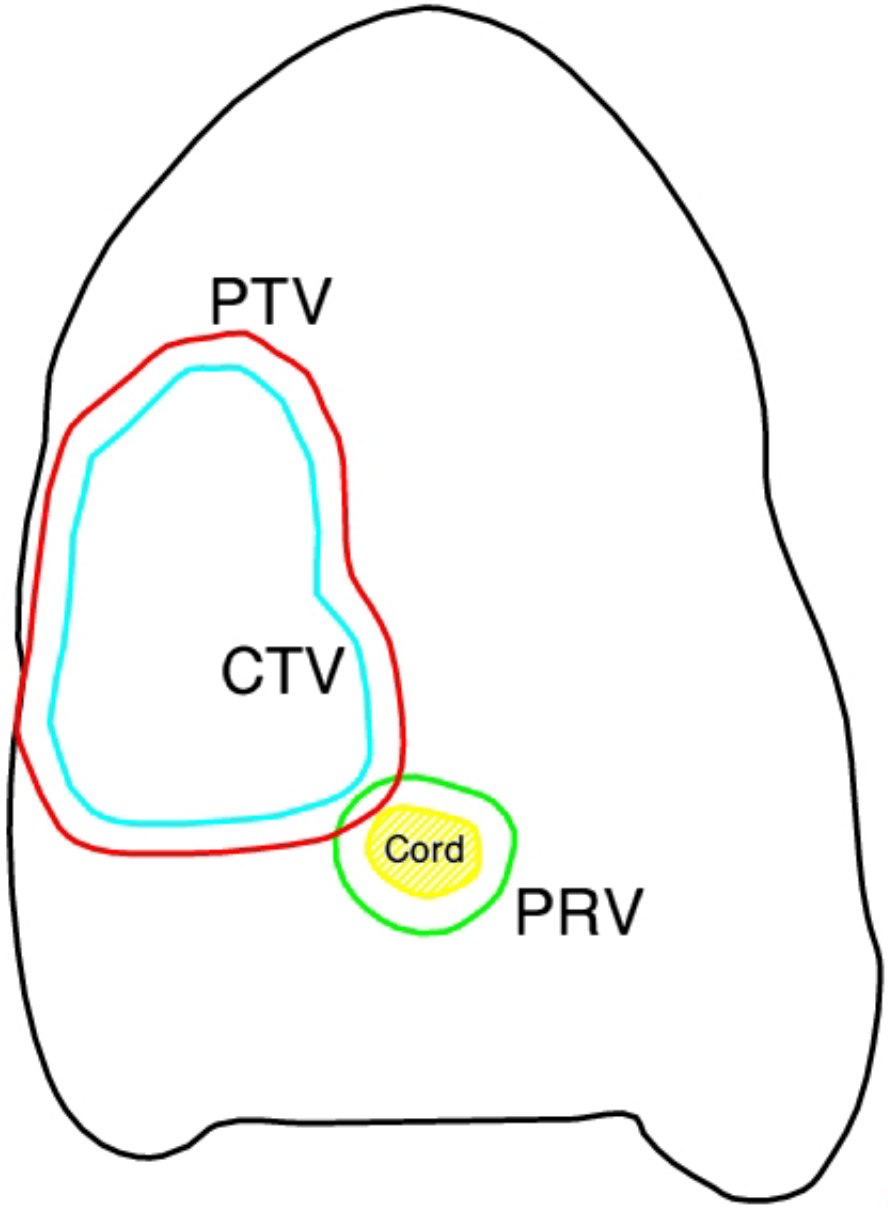

- ICRU 62 recommendation
- OAR would be safe
- Obscures target dose objective

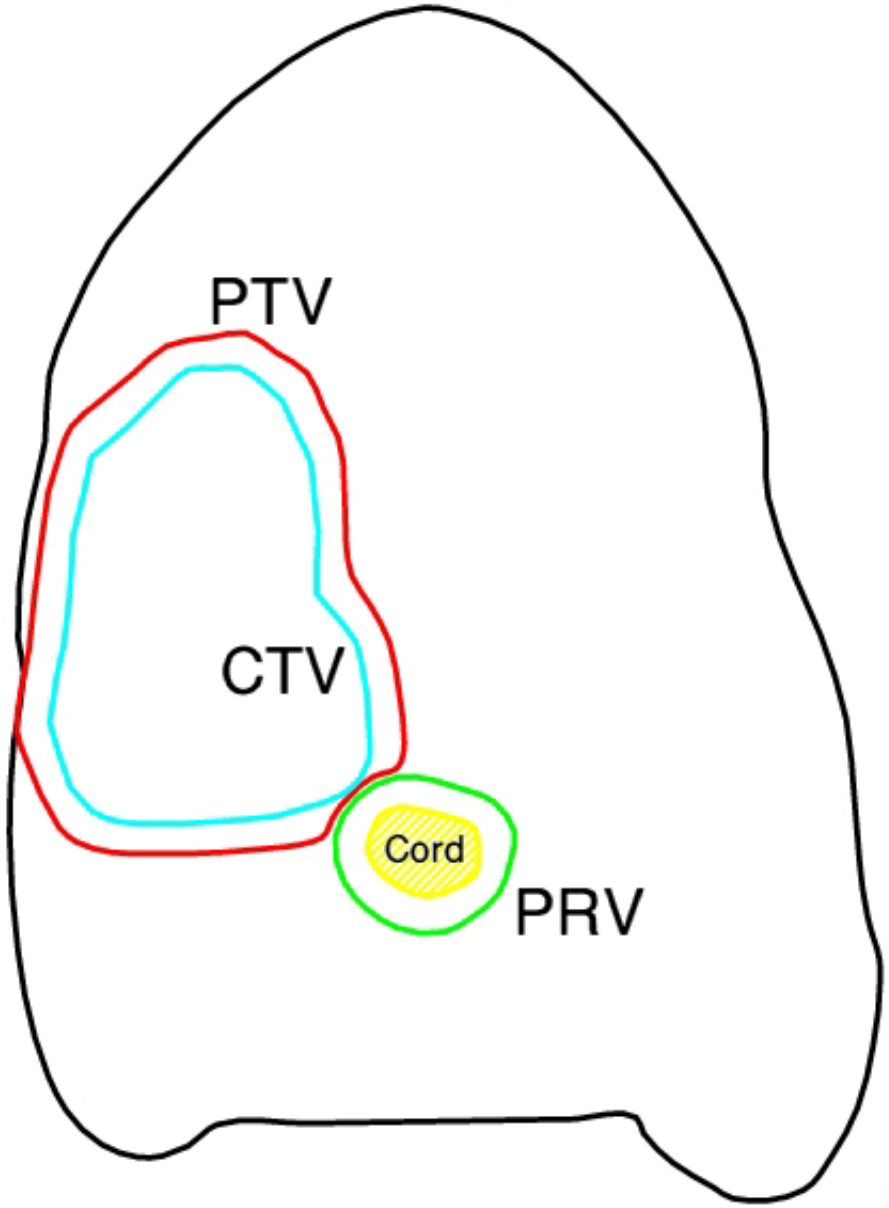

ESTRO School

- ICRU 62 recommendation
- OAR would be safe
- Obscures target dose objective
- Please don’t ...

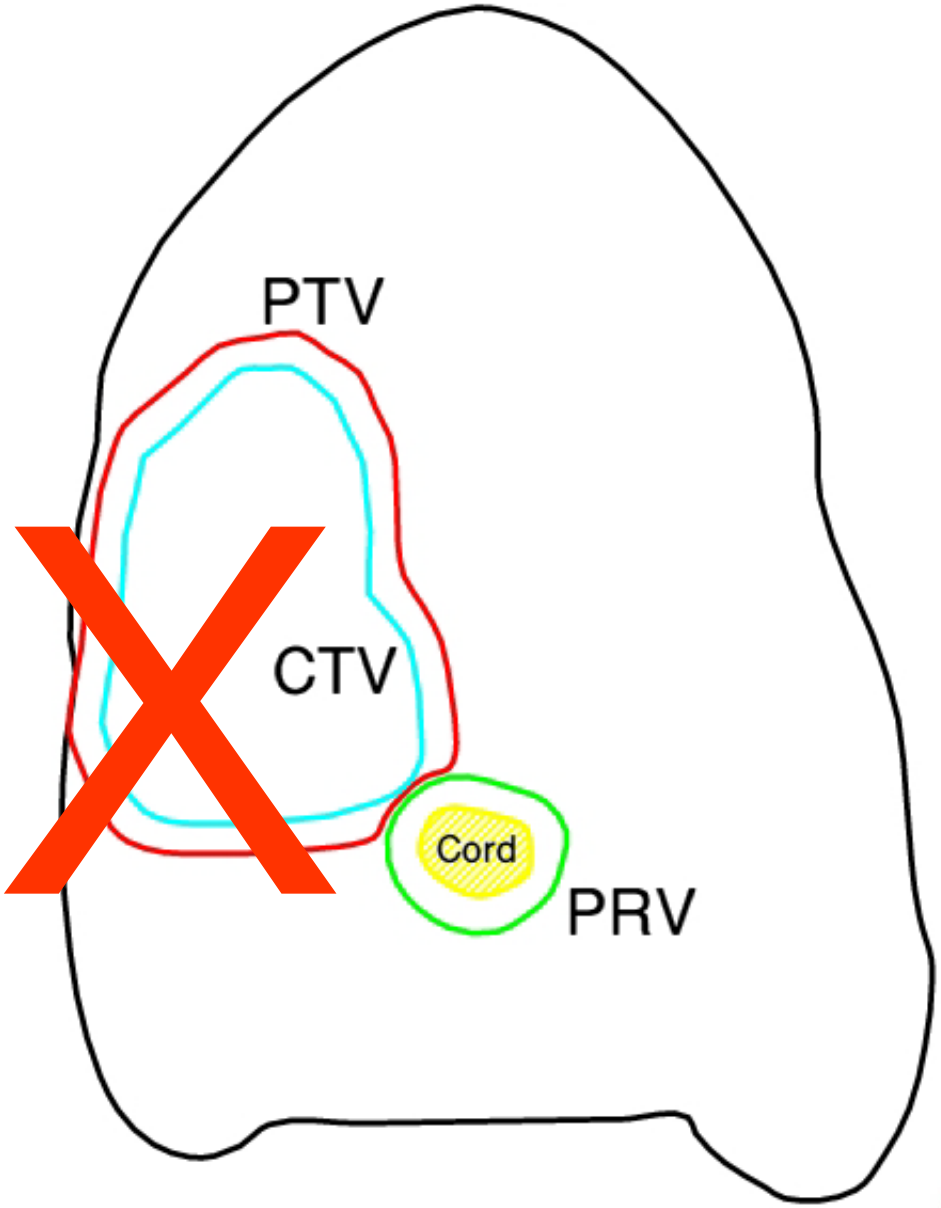

ESTRO School

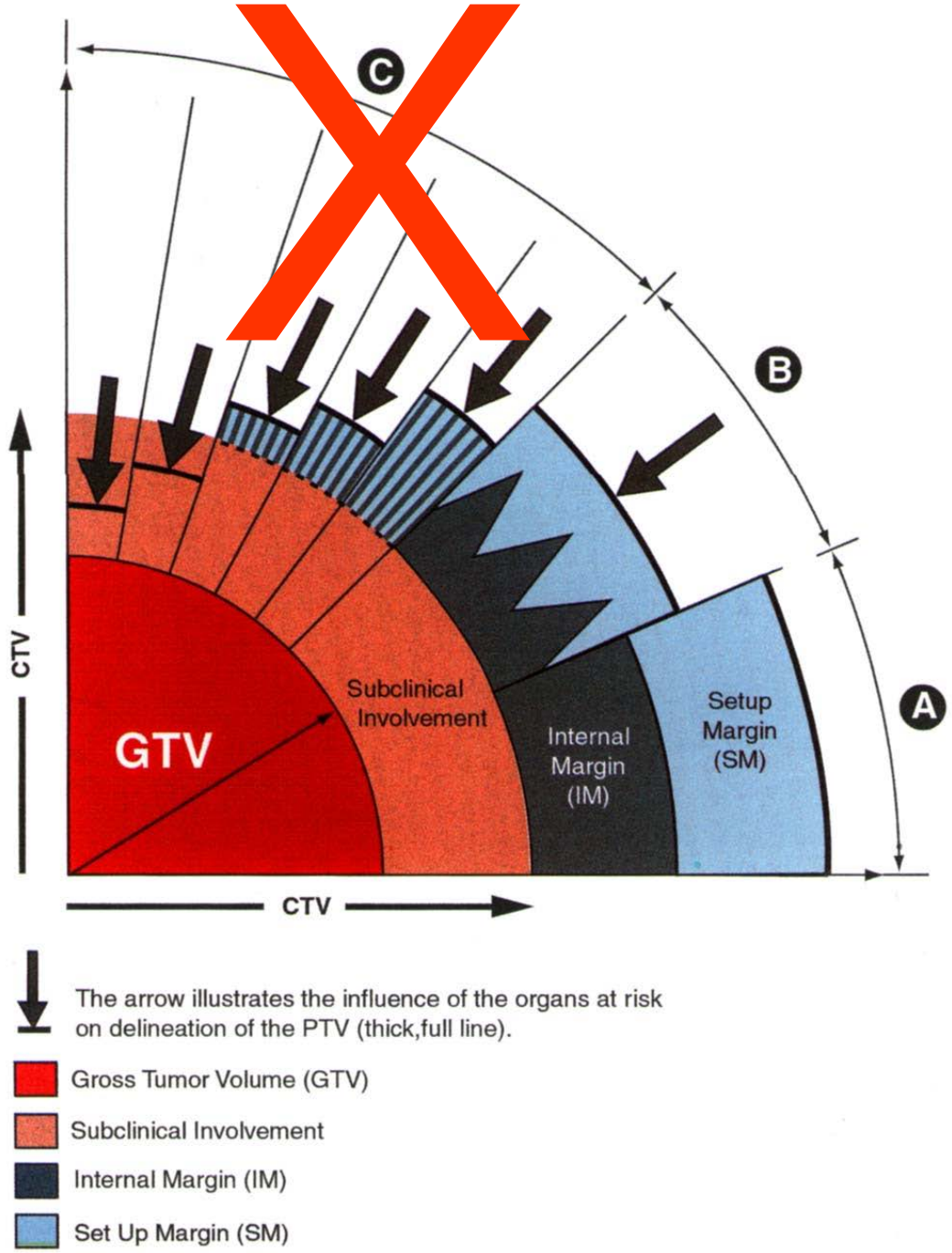

- Fig from ICRU 62 (also in ICRU 71)
- Scenario C not recommended now, in the era of IMRT

ESTRO School

- PTV and PRV now overlap
- IMRT allows variable dose
- Therefore draw what you want
- ***Do not*** modify PTV

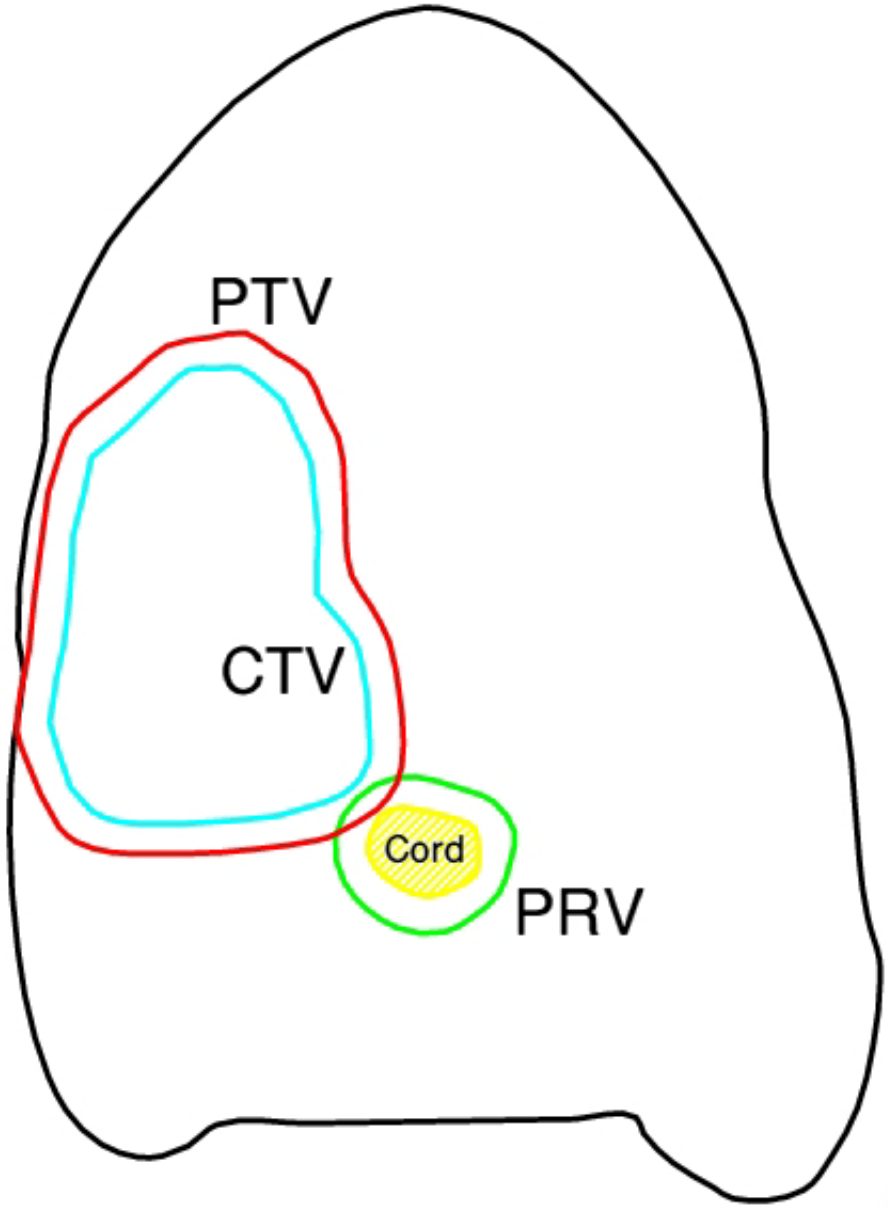

ESTRO School

- ICRU 83 approach for IMRT
- Add 2nd volume avoiding overlap
- Specify priorities and doses

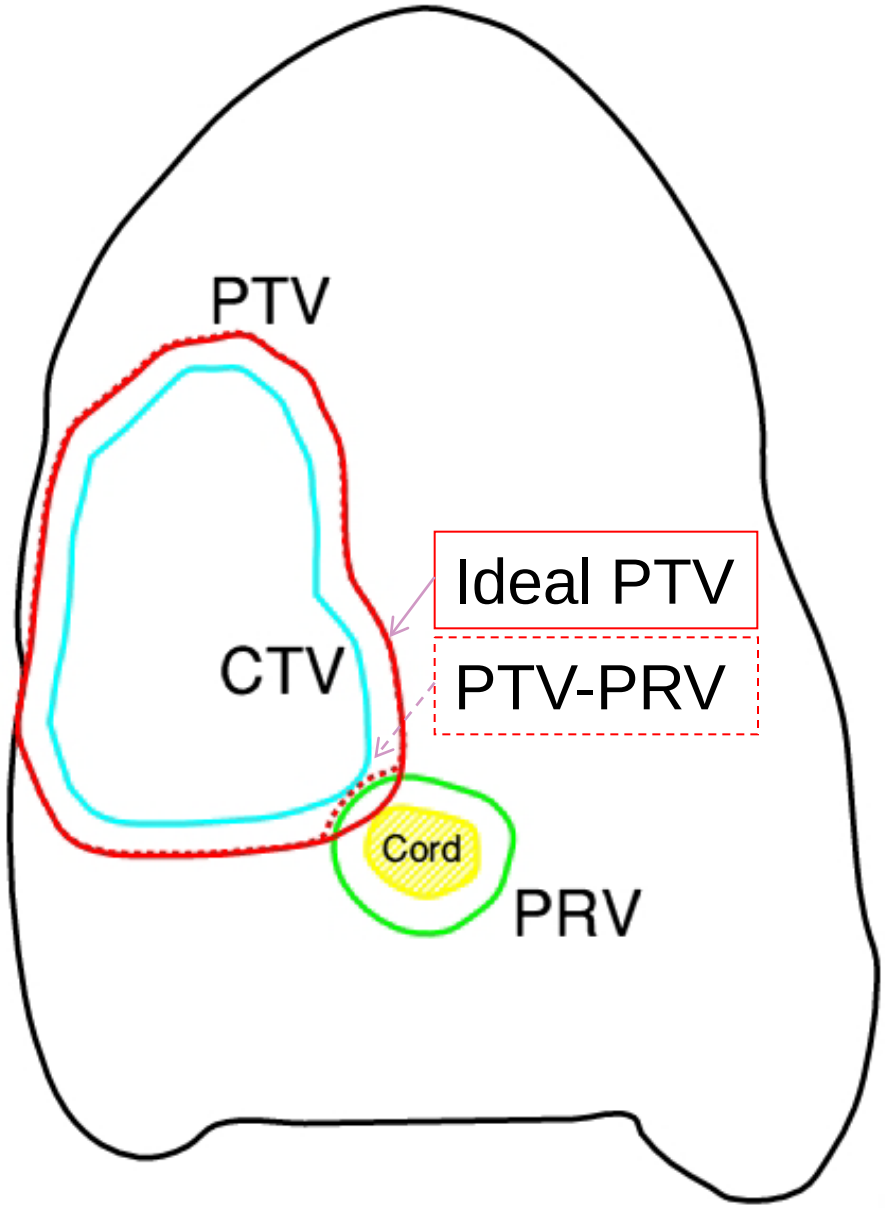

ESTRO School

Target volumes – PTV / PRV

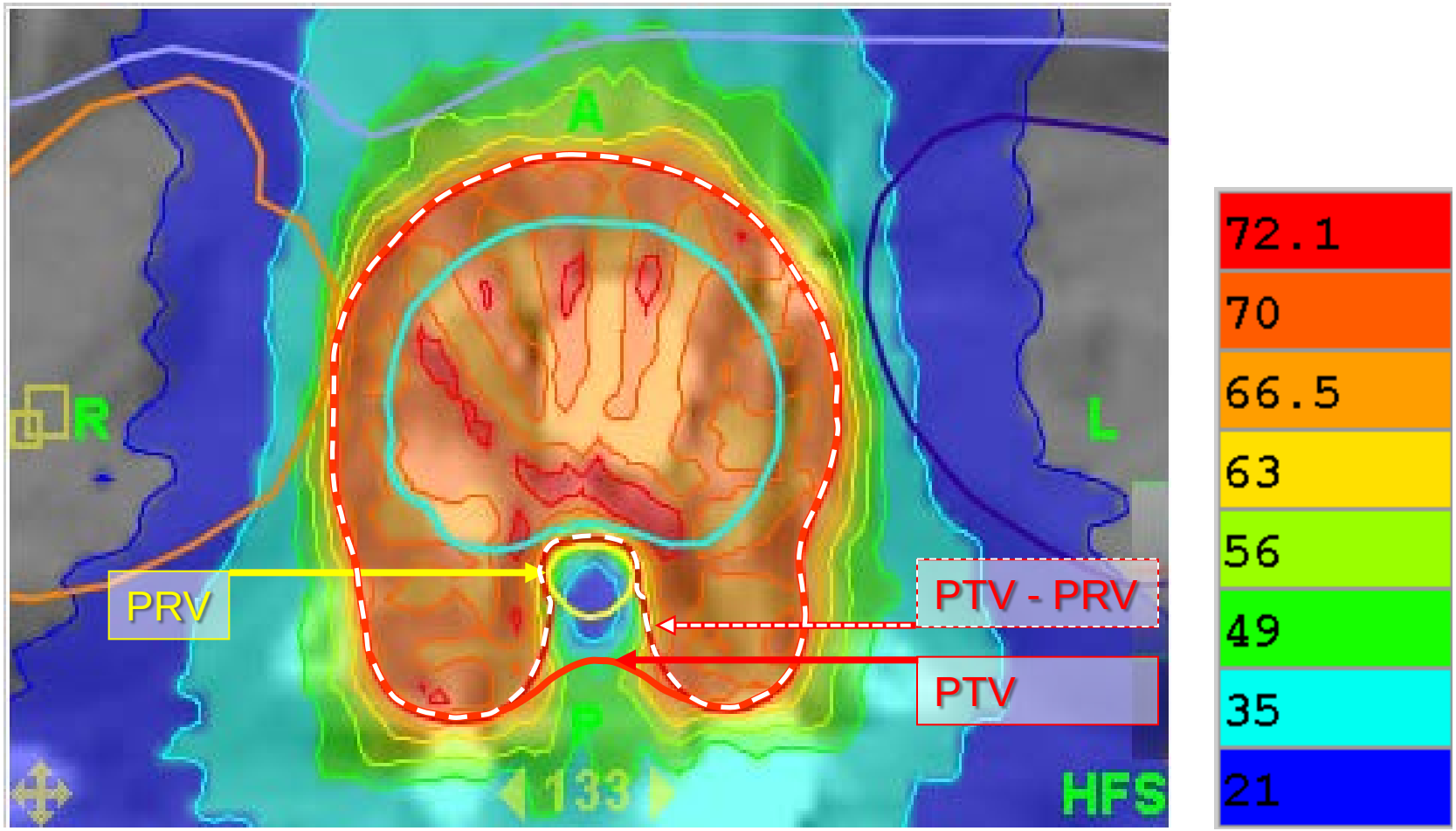

PRV essential here to protect cord (so is IGRT)

Priority PRV > PTV

ESTRO School

Target volumes – overlaps

Overlapping volumes requires:

- Very clear objective setting
- Good communication between clinician & planner
  - Dialogue (i.e. 2 way communication) is recommended !
- Use optimiser to deliver different doses to different parts of the target
- Makes plan evaluation using DVH more difficult

Target volumes – overlaps

From ICRU 83

Review DVHs carefully

Overall, more robust method

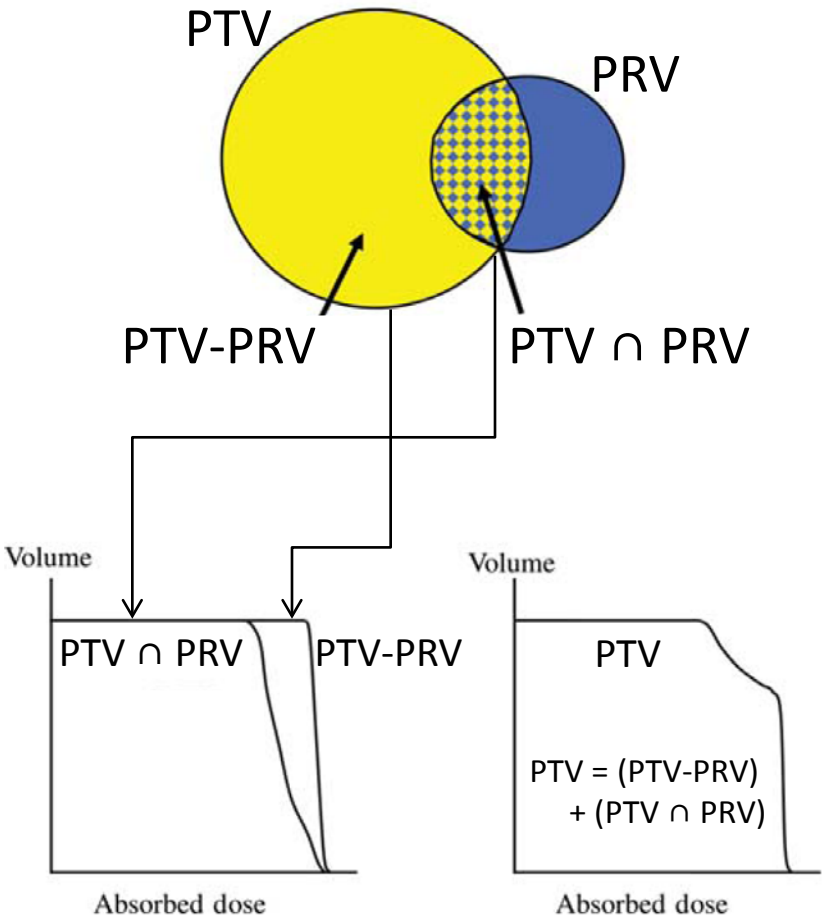

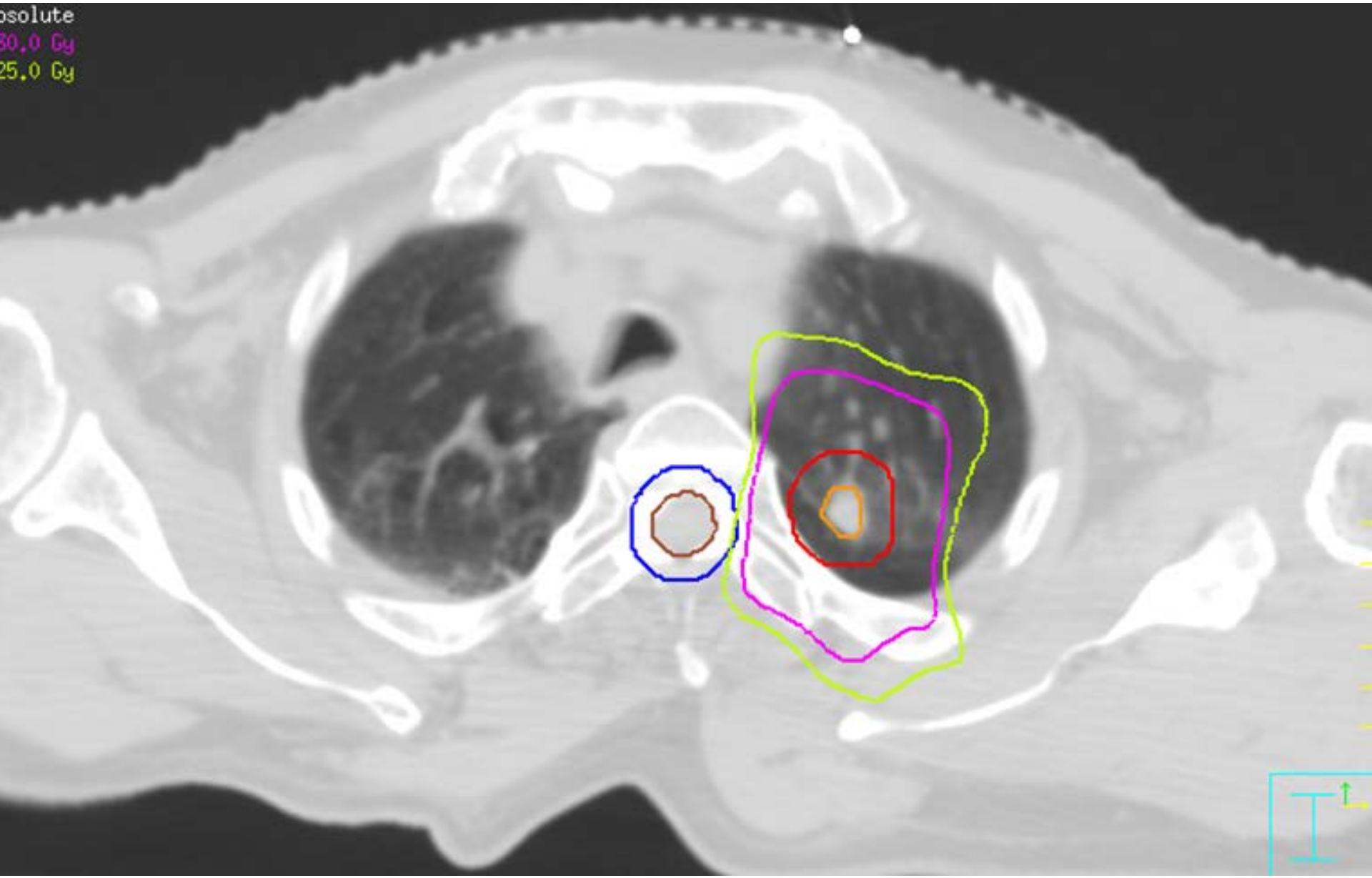

Radboudumc

Take home messages

- GTV is tumour you can ***See - Feel – Image***
  - Outline what you see!

- CTV - contains GTV and/or sub-clinical disease
  - Tumour ***cannot*** be seen or imaged
  - Can be individualised to anatomy

- PTV is a geometric volume
  - Ensures prescription dose is delivered to the CTV
  - Includes systematic + random error components

Take home messages

- Add PRV around CNS structures if giving high doses
- Overlaps can occur between PTV and OAR (or PRV)
  - Do ***not*** edit
- Use clear protocols & follow them
- Assess the treatment to see if adaptation required

Radiation oncology - a team effort

ESTRO School

ESTRO School

WWW.ESTRO.ORG/SCHOOL

Image Handling

Role of images in Radiation Therapy

Martina Kunze-Busch
Radboud University Medical Center Nijmegen
The Netherlands

Radboudumc

ESTRO School

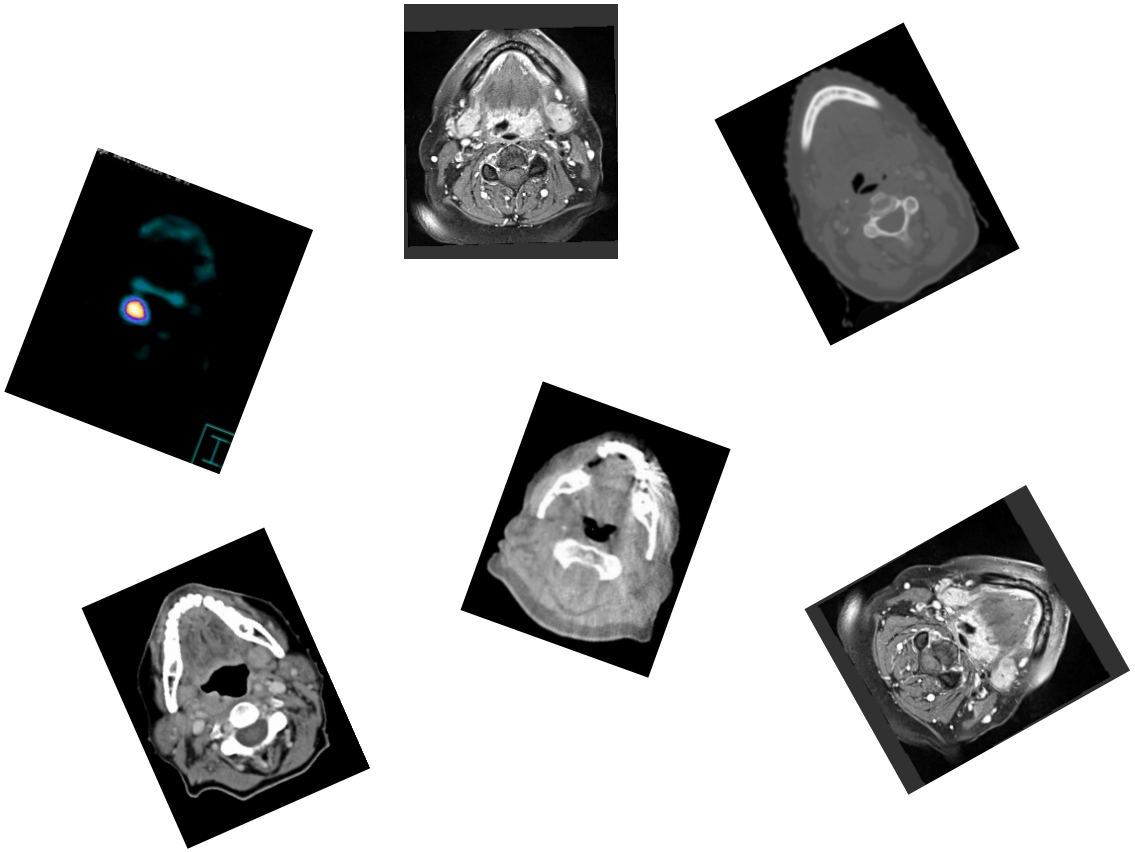

Overview

Image data in RT chain

- Treatment preparation (diagnostic scan, planning CT, registration, delineation, display)
  purpose, potential errors, challenges
- Treatment delivery (ImageGuidedRT)
  examples
- Adaptive RT

Image data in RT chain

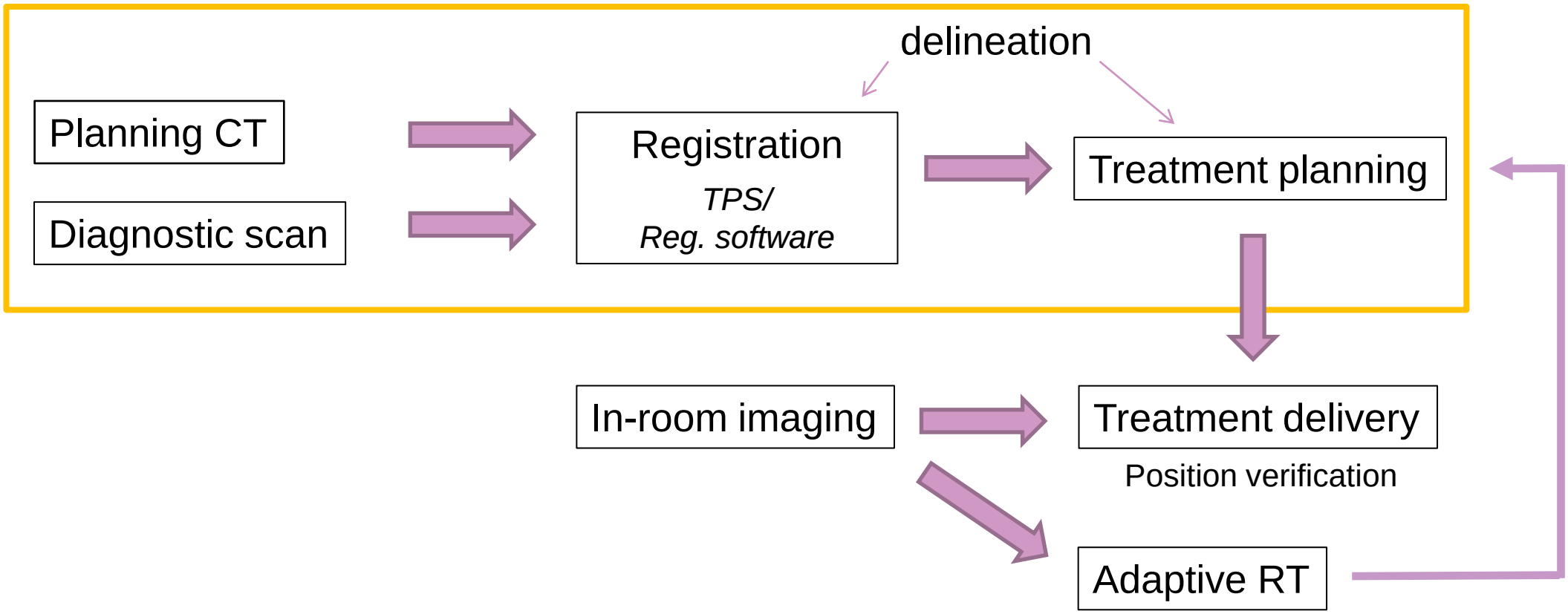

Treatment preparation – diagnostic scan

Purpose: tumor identification + staging

- different modalities CT – MRI – PET …

Challenges:

- imaging artefacts
- different modalities (registration)

Treatment preparation – diagnostic scan

Example: MRI imaging artefacts

Wrap around

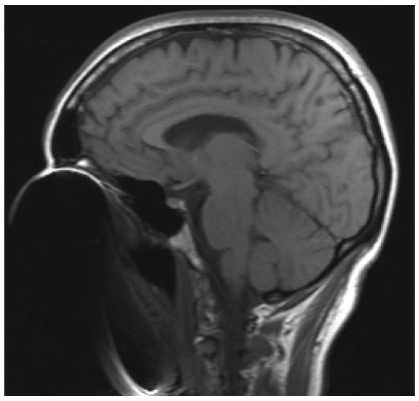

Susceptibility

RadioGraphics 2006

Example: false positive in breast MRI
(pseudo-enhancement)

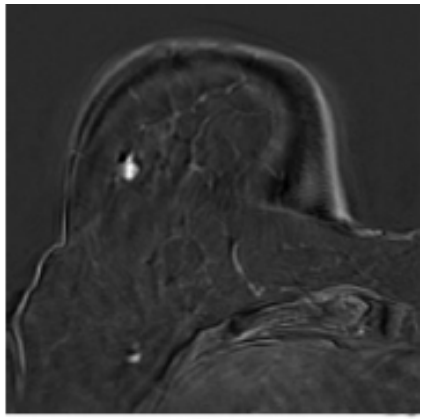

Millet et al., Br J Radiol 85 (2012)

Radboudumc

ESTRO School

Treatment preparation – planning CT

Purpose: delineation of tumor (→ PTV) and calculation of dose

Goal: reproducible positioning of patient at simulation & treatment and during treatment

→ knee support
→ markers (skin)
→ fixation masks
→ …

Potential errors/challenges:

- set up error on scanner
- movement during scan (patient or tumor)
- metal
- ….

Treatment preparation – planning CT

Example: metal

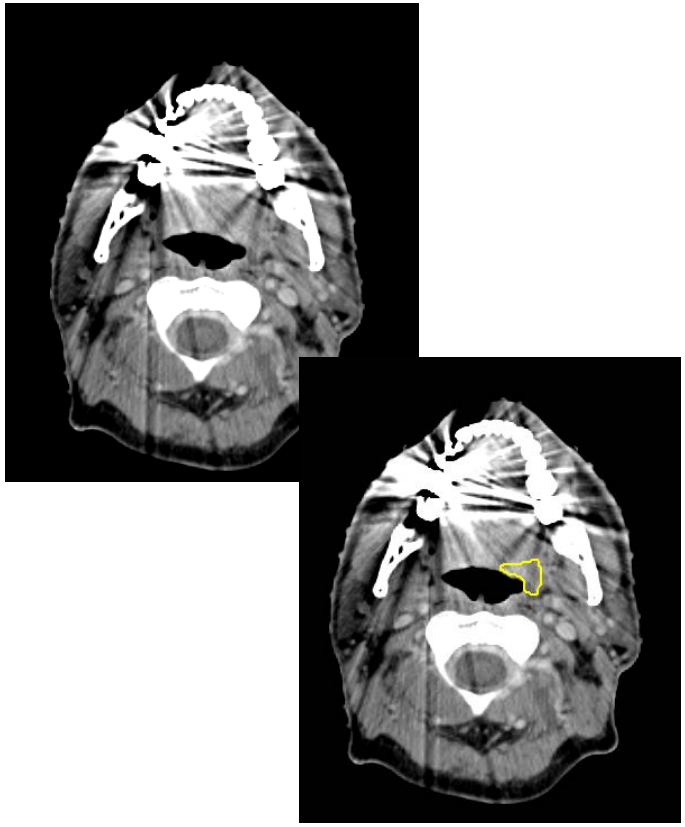

Metal Artefact Reduction software

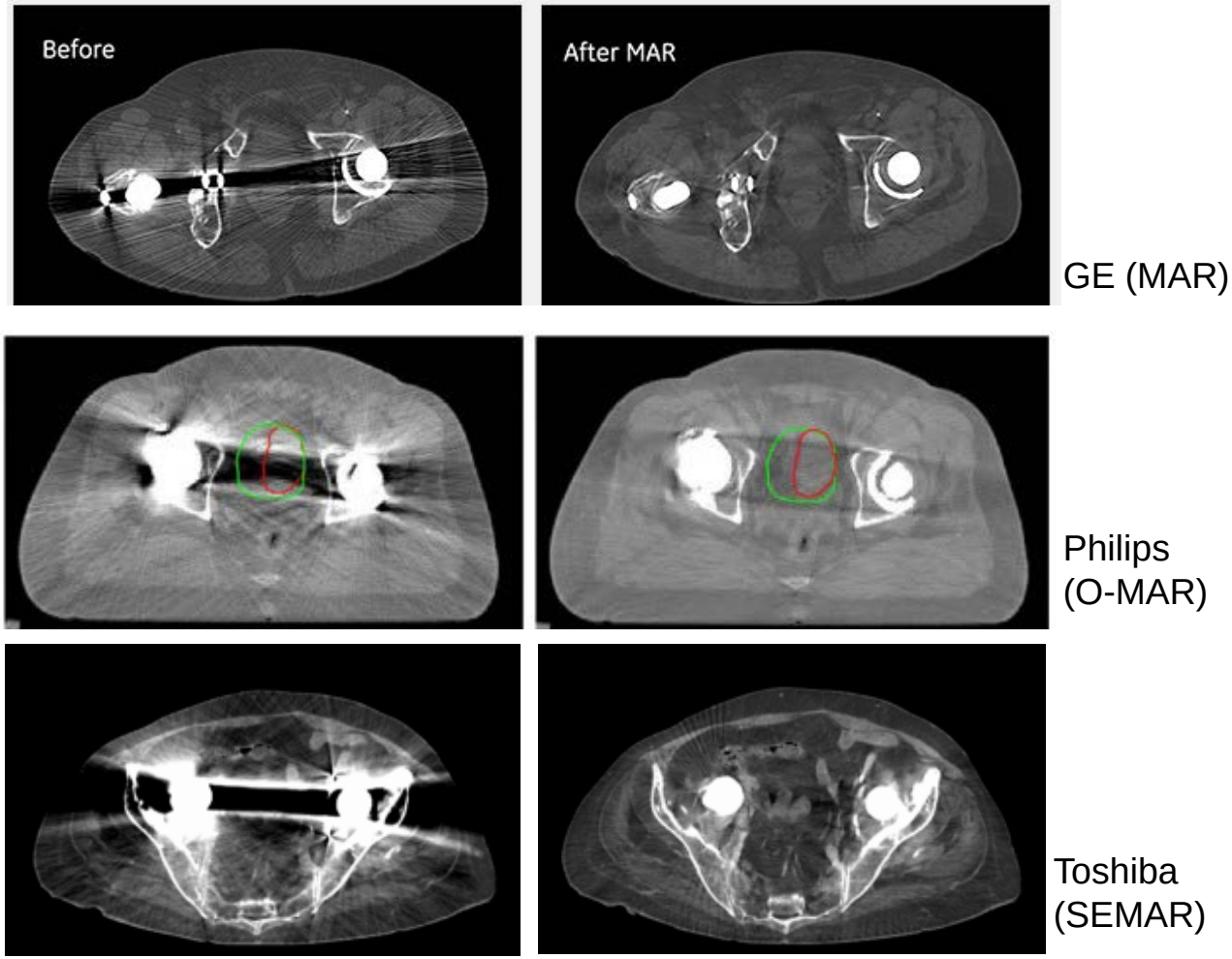

Radboudumc

ESTRO School

Treatment preparation – planning (PET/)CT

Example: movement

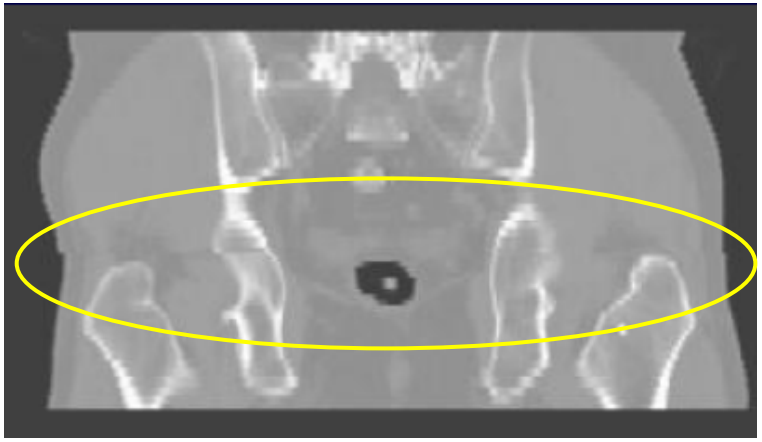

NKI-AVL

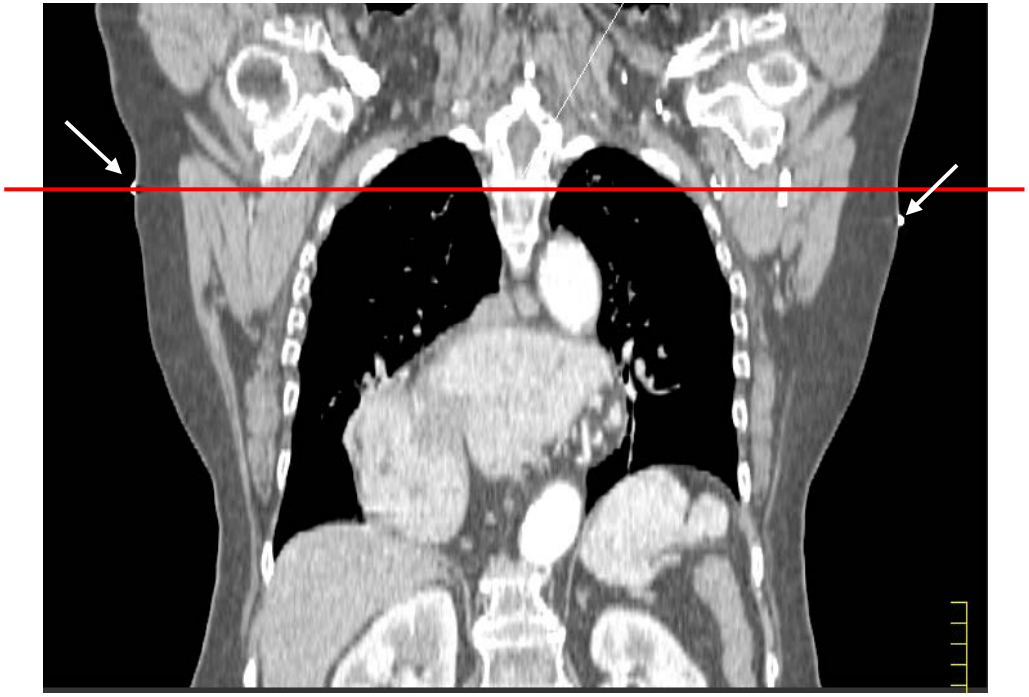

Radboudumc

ESTRO School

Treatment preparation – delineation

Example: motion

fast

slow

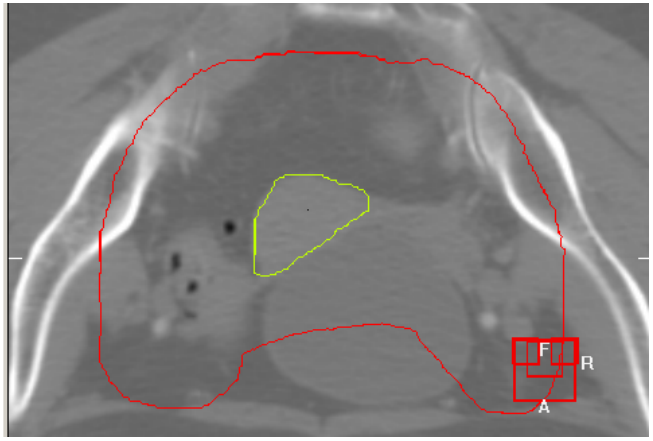

CT

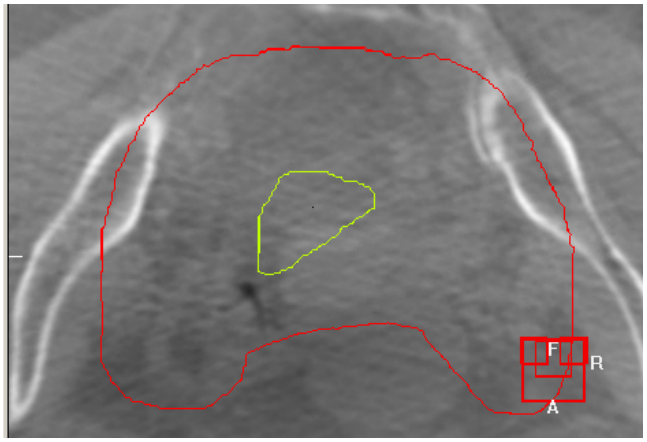

CBCT

Radboudumc

ESTRO School

Dealing with tumor motion

Fast motion

- breath-hold CT scan
- gated CT scan
- 4D CT scan
  = 3D scans at multiple phases

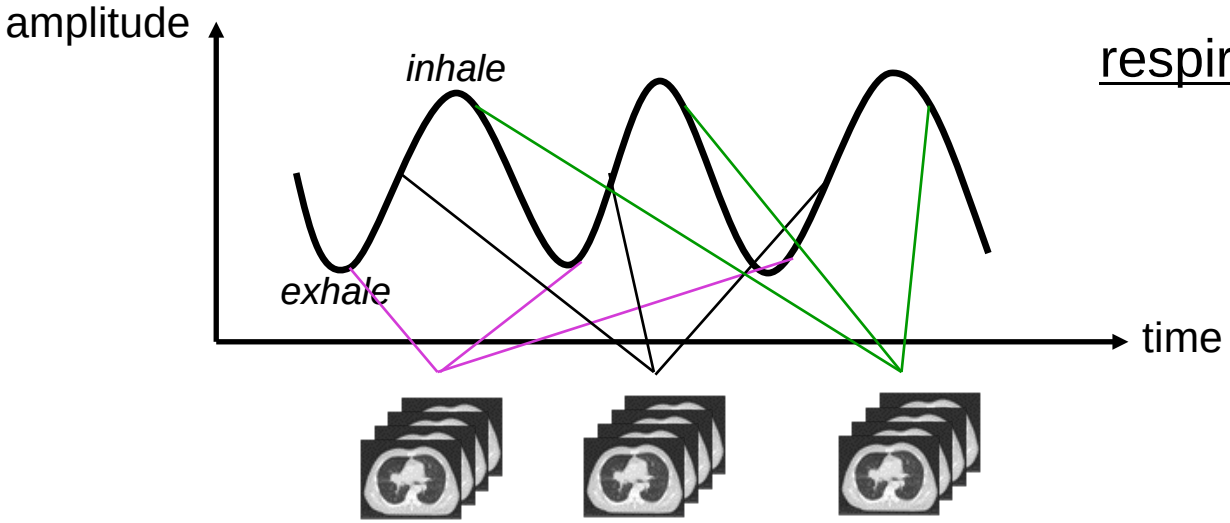

respiration correlated CT

Dealing with tumor motion

4D CT – mid-ventilation

time-weighted average position

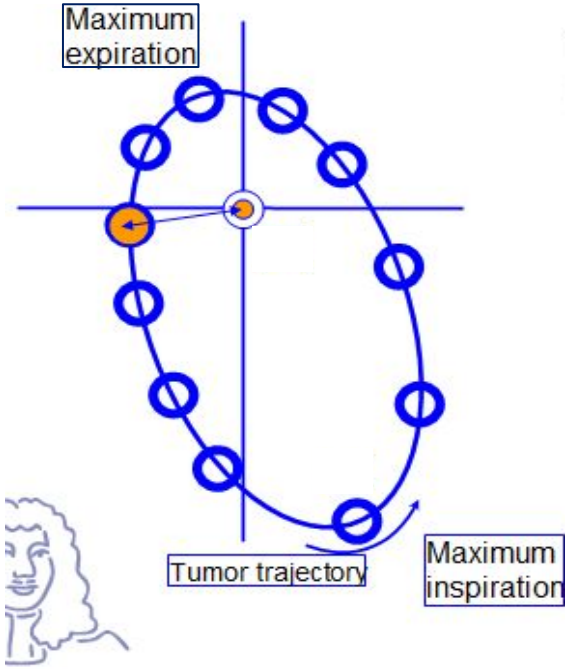

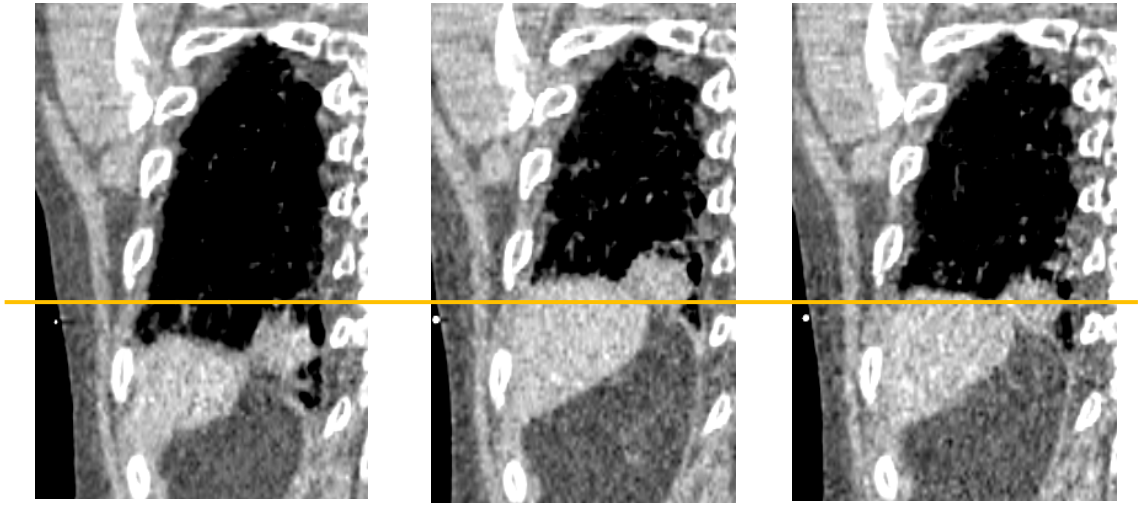

inhale exhale mid-vent

Dealing with tumor motion

Interfraction changes

“plan of the day”

- >1 CT scan (e.g. with full and empty bladder)
- in-room imaging before treatment
- selection of daily plan from library

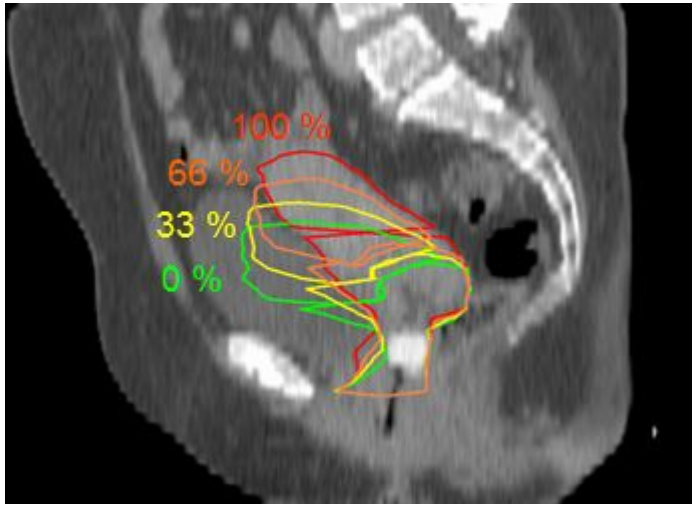

Adaptive RT

NKI-AVL
The Netherlands Cancer Institute
Antoni van Leeuwenhoek Hospital

Radboudumc

ESTRO School

Treatment preparation – display

Example CT: Window/Level (W/L)

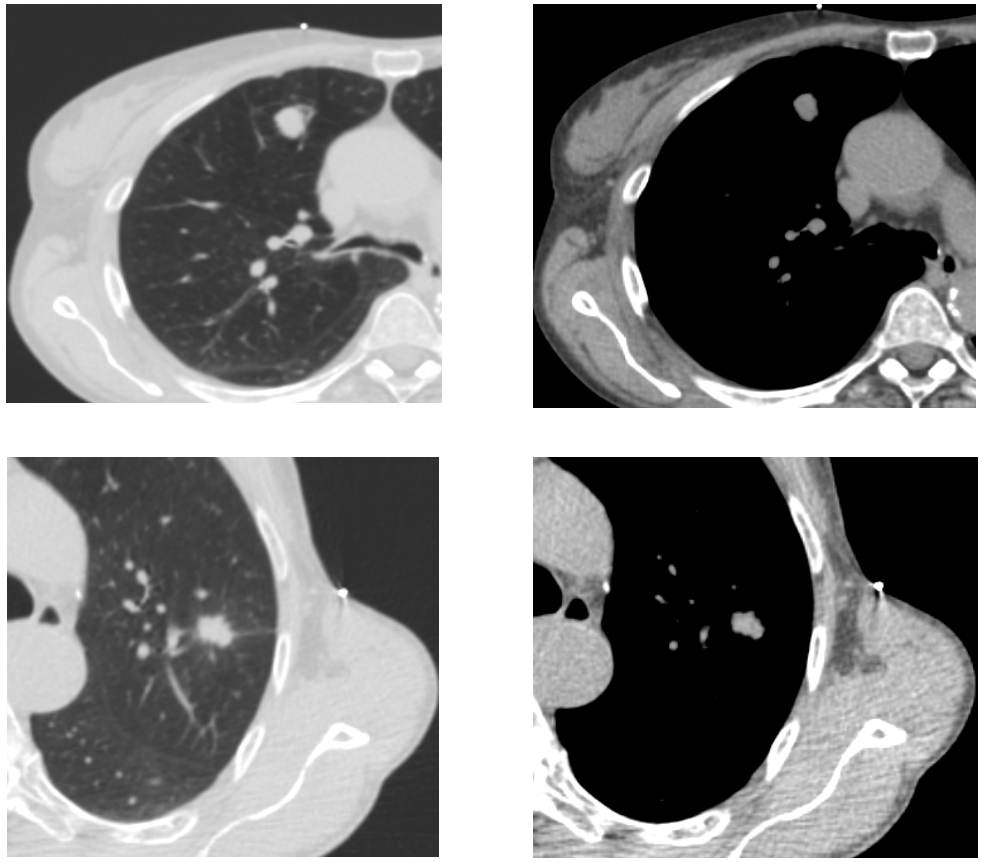

Radboudumc

ESTRO School

Treatment preparation – registration

Purpose: accurate delineation of tumor and organs at risk

Challenges/potential errors:

→ Talk on image registration

Image data in RT chain

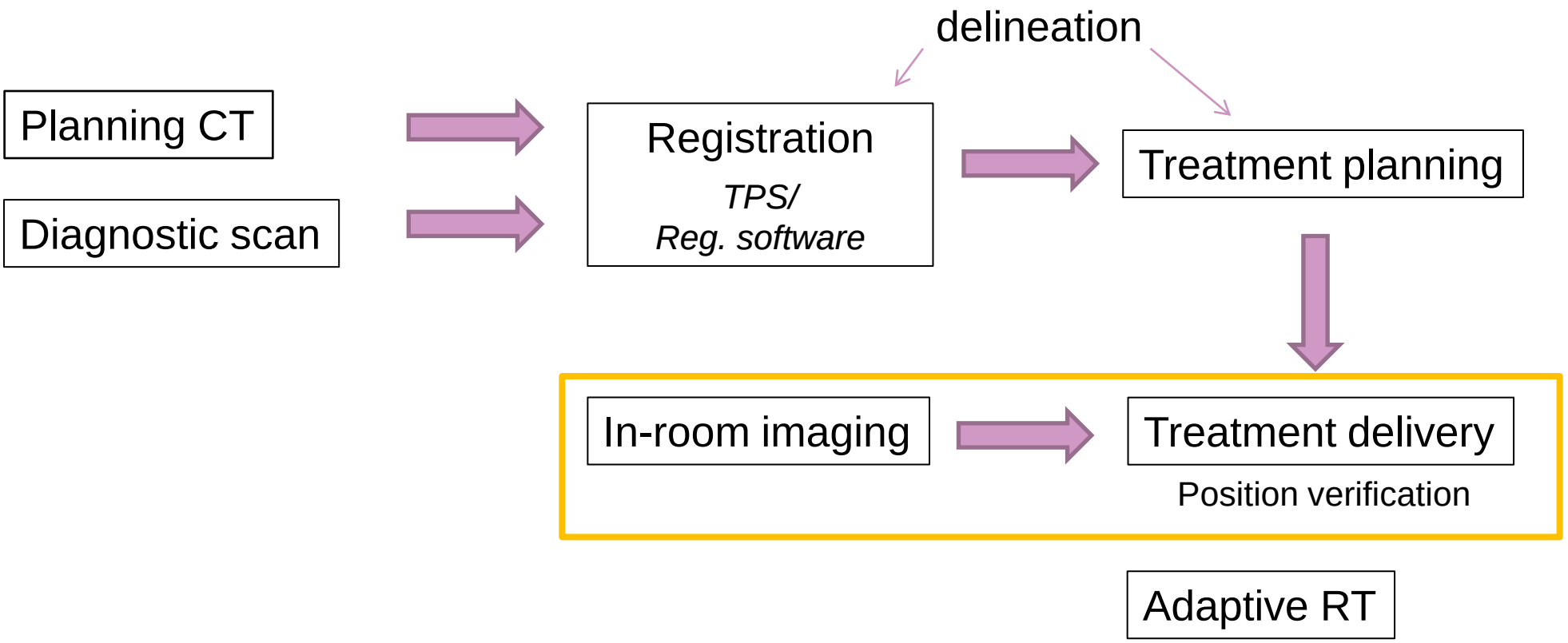

Treatment delivery – ImageGuidedRT

In-room imaging with

- Portal Imaging (2D)
- Cone Beam CT (e.g. Elekta, Varian)
- MV CT (e.g. Tomotherapy)
- MRI (Viewray, Elekta/Philips)

Treatment delivery – IGRT

Example CBCT

tumor regression

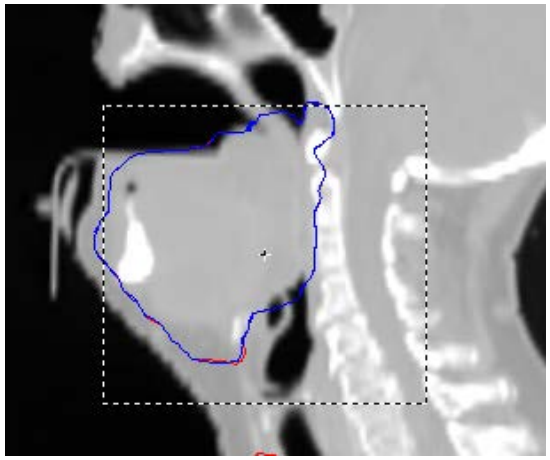

planning CT

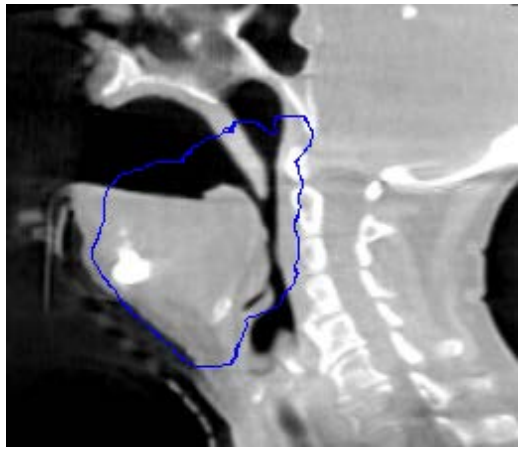

CBCT

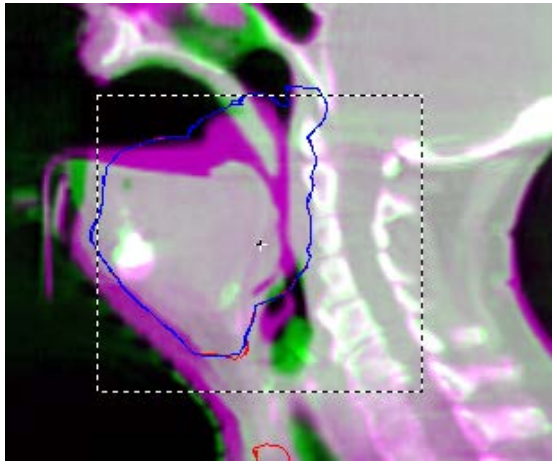

planning CT

CBCT

→ back to the CT scanner

Radboudumc

ESTRO School

Treatment delivery – IGRT

Example CBCT

tumor displacement

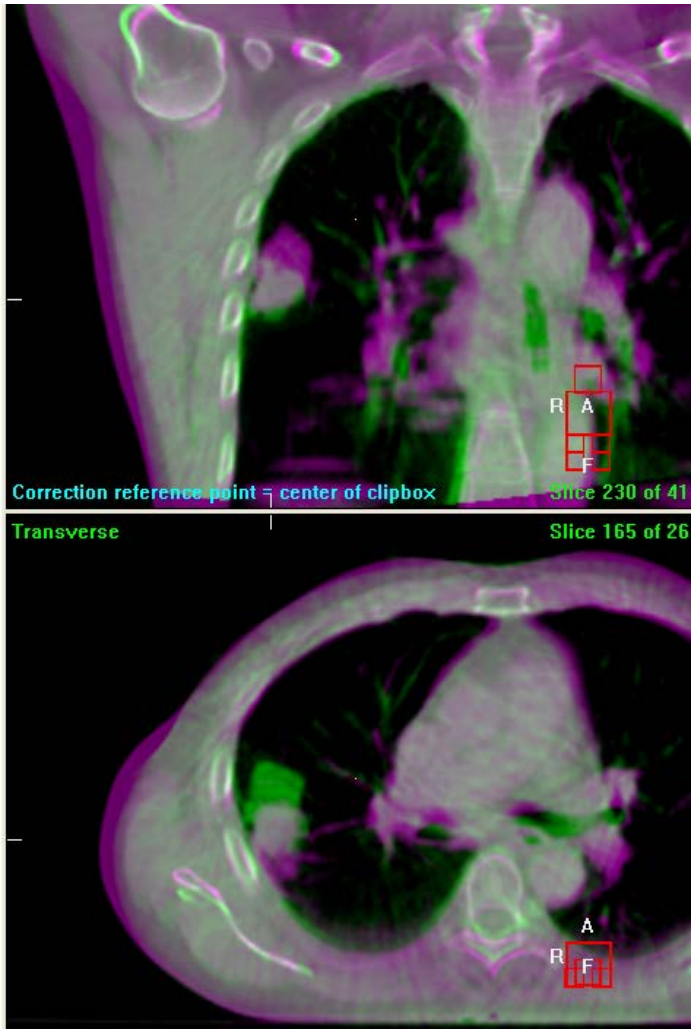

planning CT

CBCT

→ back to the CT scanner

Radboudumc

ESTRO School

Treatment delivery – IGRT

Example CBCT

weight loss

1st week

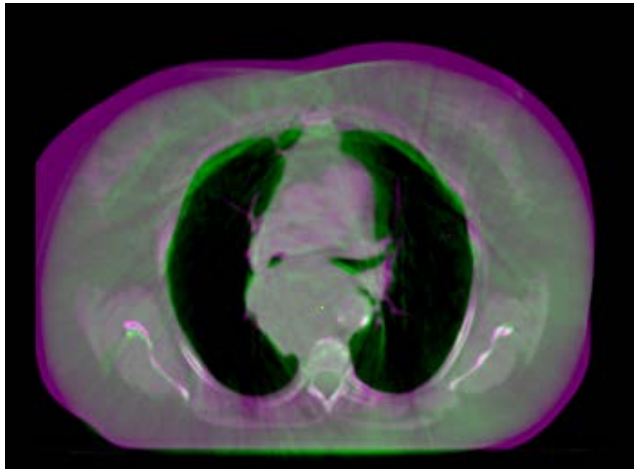

last week of treatment

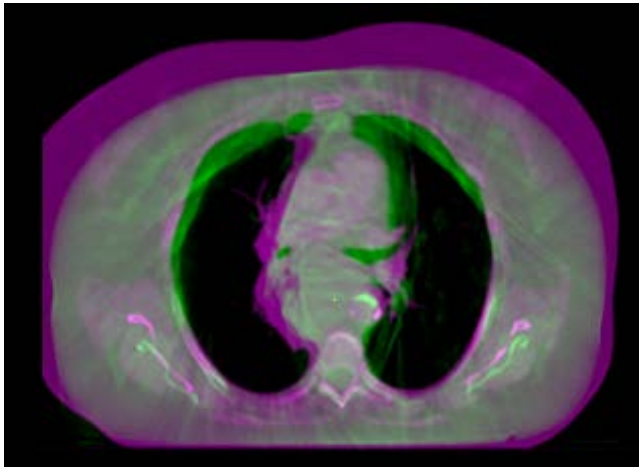

planning CT

CBCT

Radboudumc

ESTRO School

Next IGRT generation: MR-guided RT

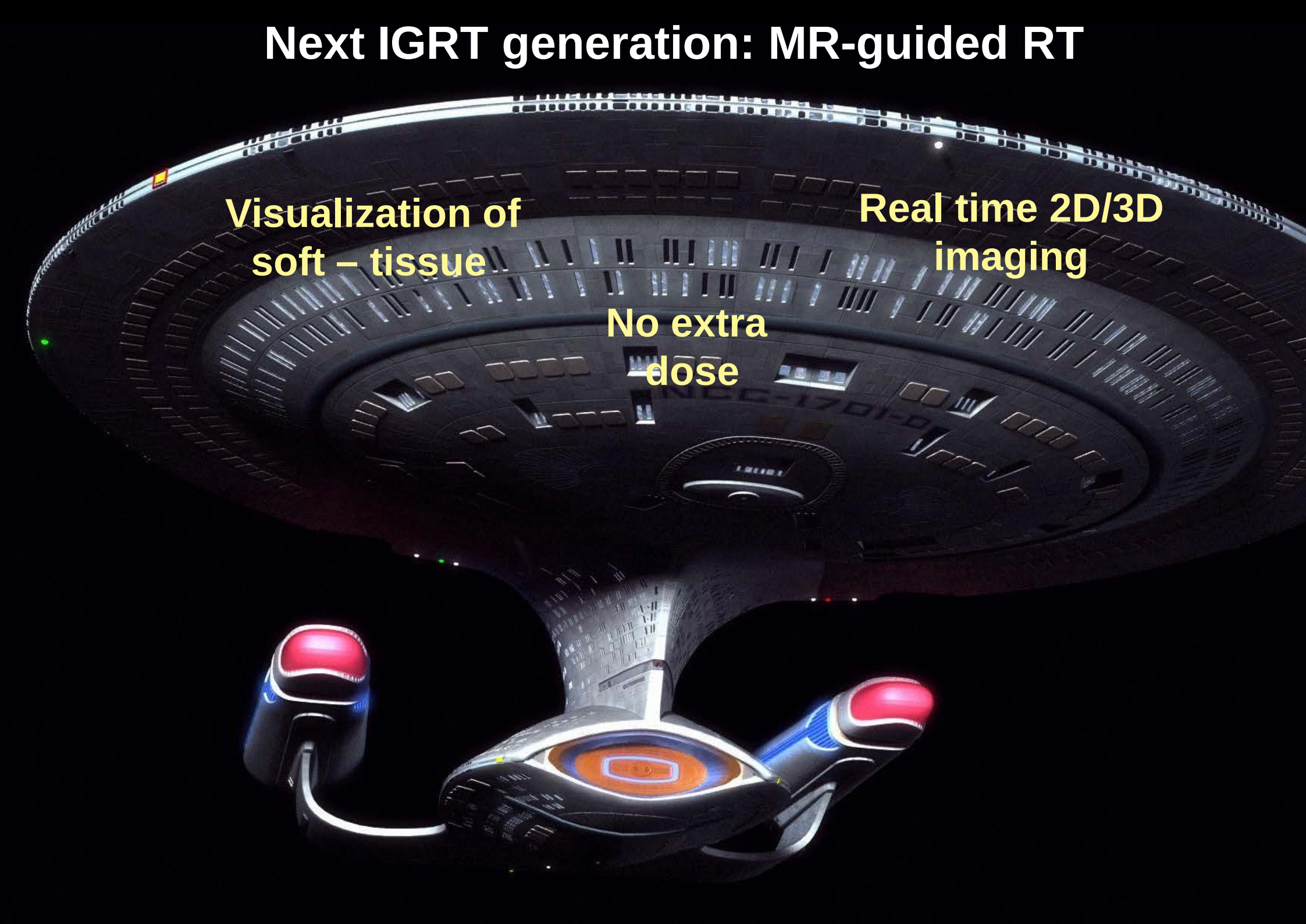

Treatment delivery

MR-guided RT

MRIdian **Viewray**

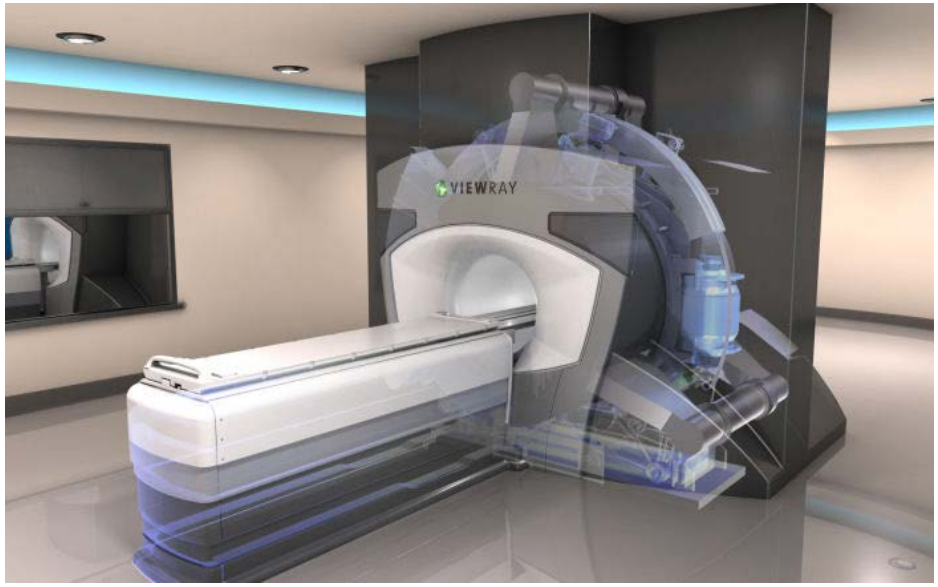

http://medicalphysicsweb.org/cws/article/research/5617916

0.35 T split magnet MRI
3 Cobalt-60 teletherapy heads

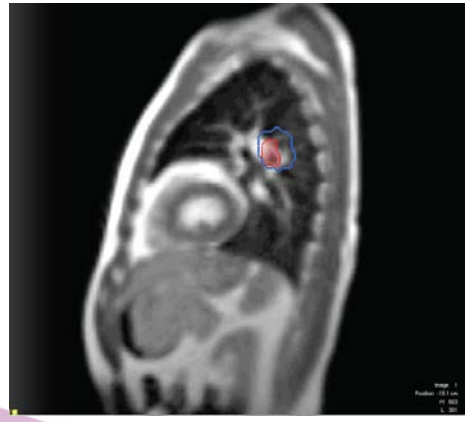

Atlantic **Philips/Elekta**

CE marking expected 2017
cylindrical 1.5 T closed-bore MRI

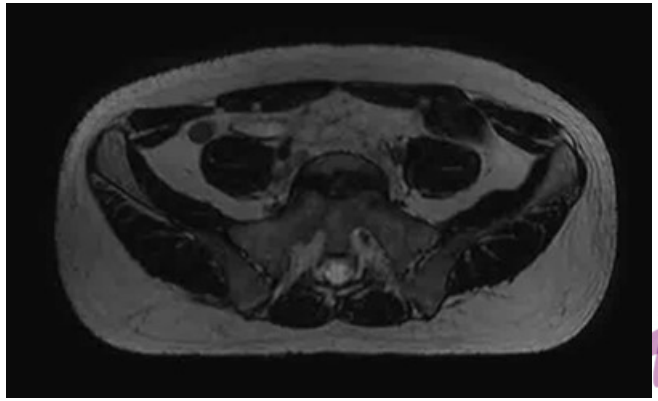

ESTRO School

Image data in RT chain

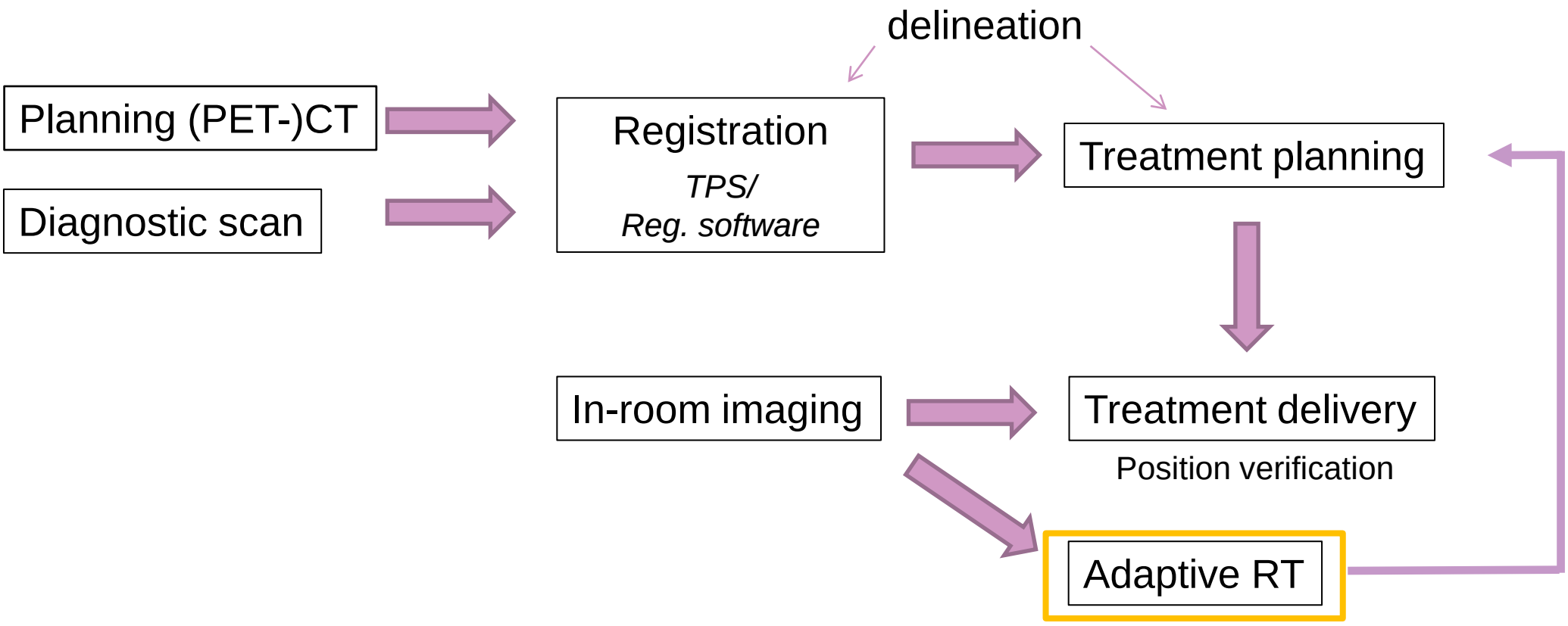

Image guided Adaptive RT

= modify treatment plan due to anatomical (or physiological) changes

(IGRT: acquire image → (rigid) registration → move isocenter/table)

Offline ART ↔ **Online ART**

adapt treatment plan (re-contour & -plan) between fractions

- choose plan from “library” → plan of the day
- adapt plan “online” (while patient on treatment table)

Radboudumc ESTRO School

Martina

Radboudumc

ESTRO School

Take home messages

- Understand imaging and its limitations
- Additional imaging gives additional information -
  additional knowledge increases responsibility
- Use extra information with care (e.g. be careful with reducing margins)

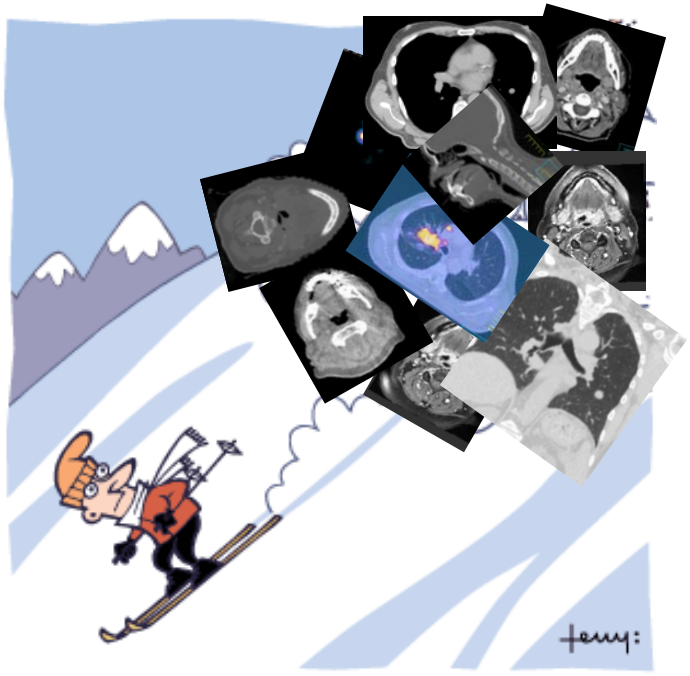

Radboudumc

ESTRO School

USE

IMAGE WISELY®

Radboudumc

ESTRO School

ESTRO School

WWW.ESTRO.ORG/SCHOOL

Inter-observer variation in target volume delineation

Peter Remeijer
Department of Radiation Oncology
The Netherlands Cancer Institute

NETHERLANDS CANCER INSTITUTE
ANTONI VAN LEEUWENHOEK

ESTRO School

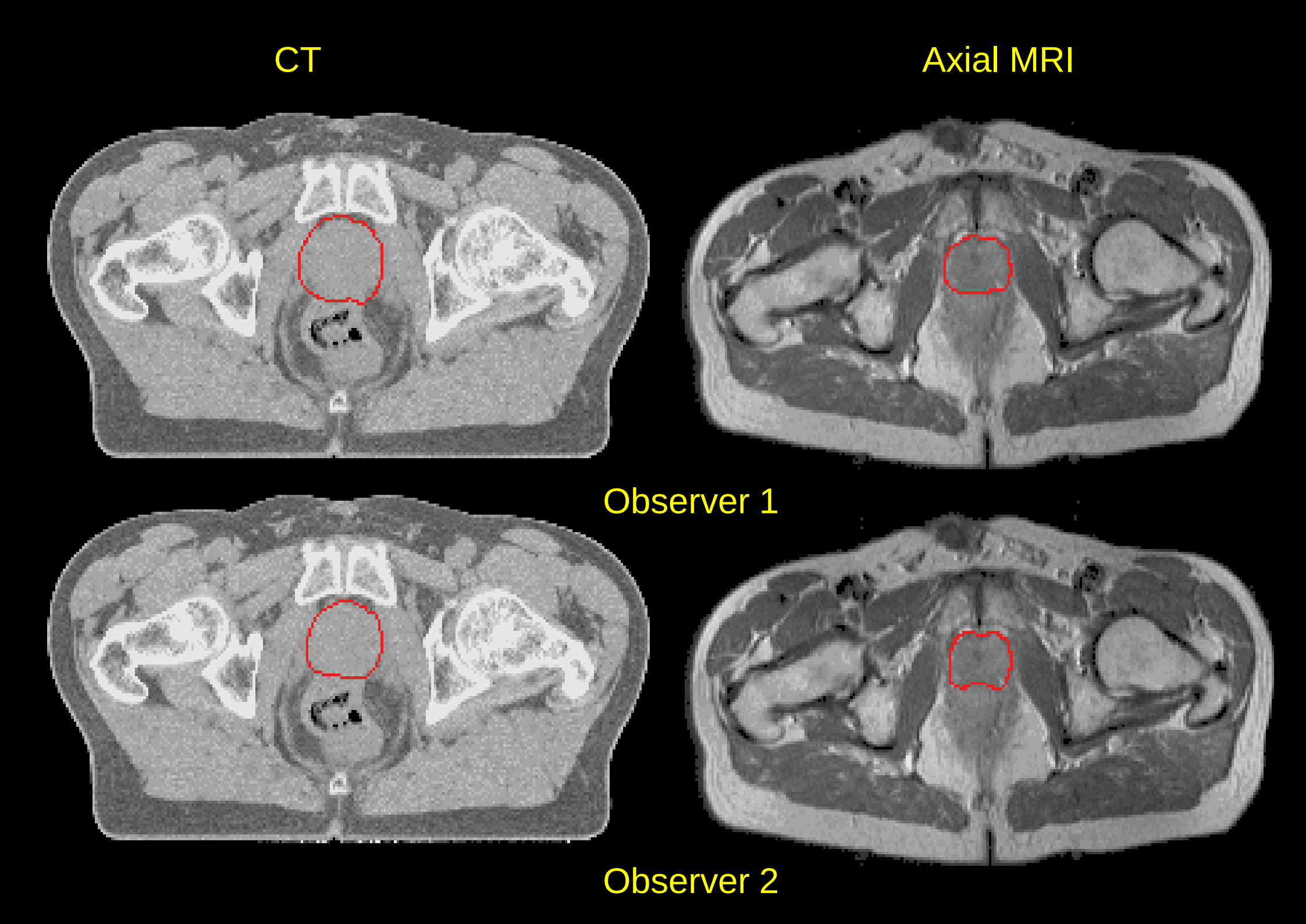
CT
Axial MRI
Observer 1
Observer 2

What influences delineation uncertainty?

Lack of coffee…..

ESTRO School

… or too much coffee

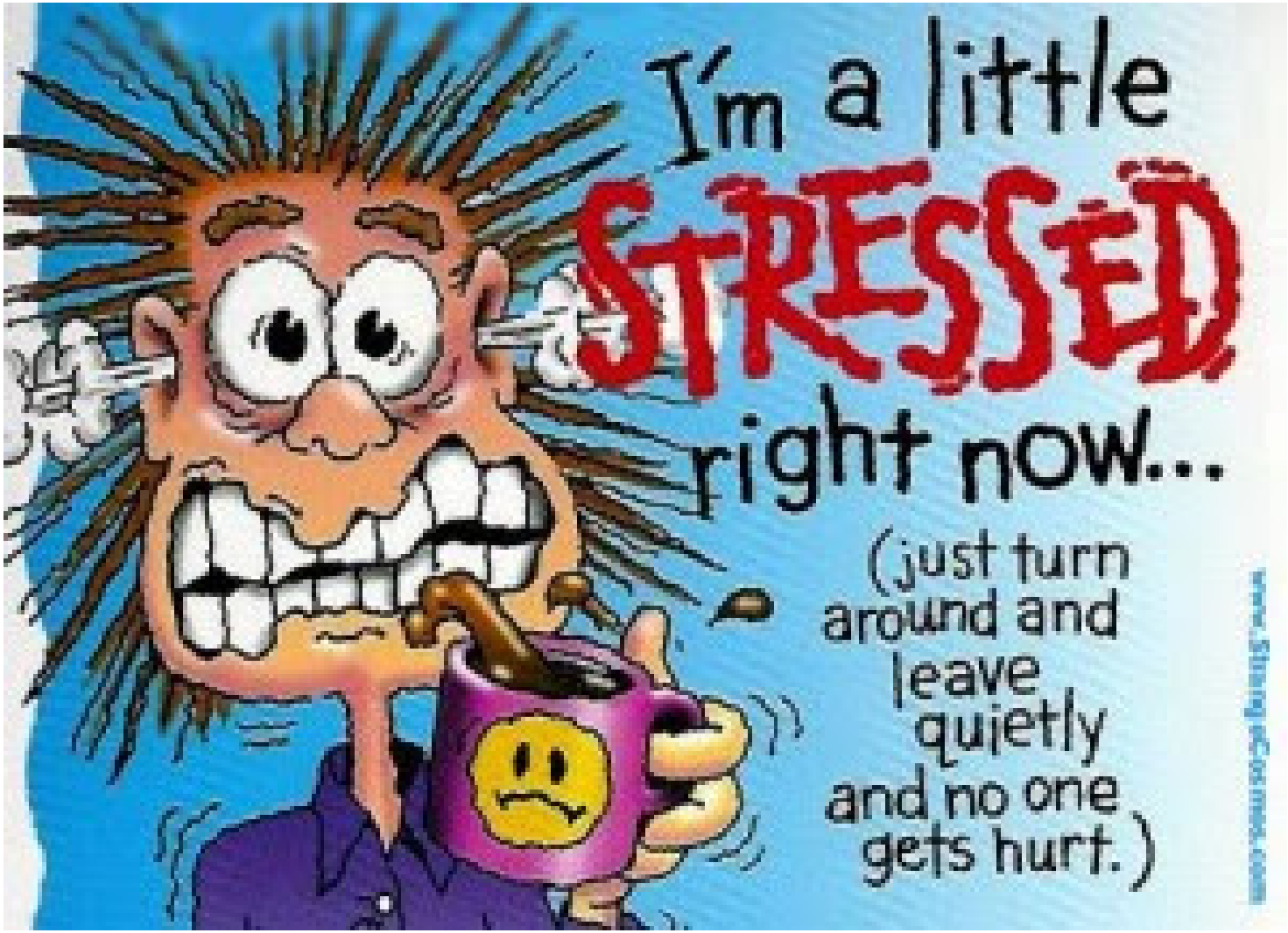

Level/window

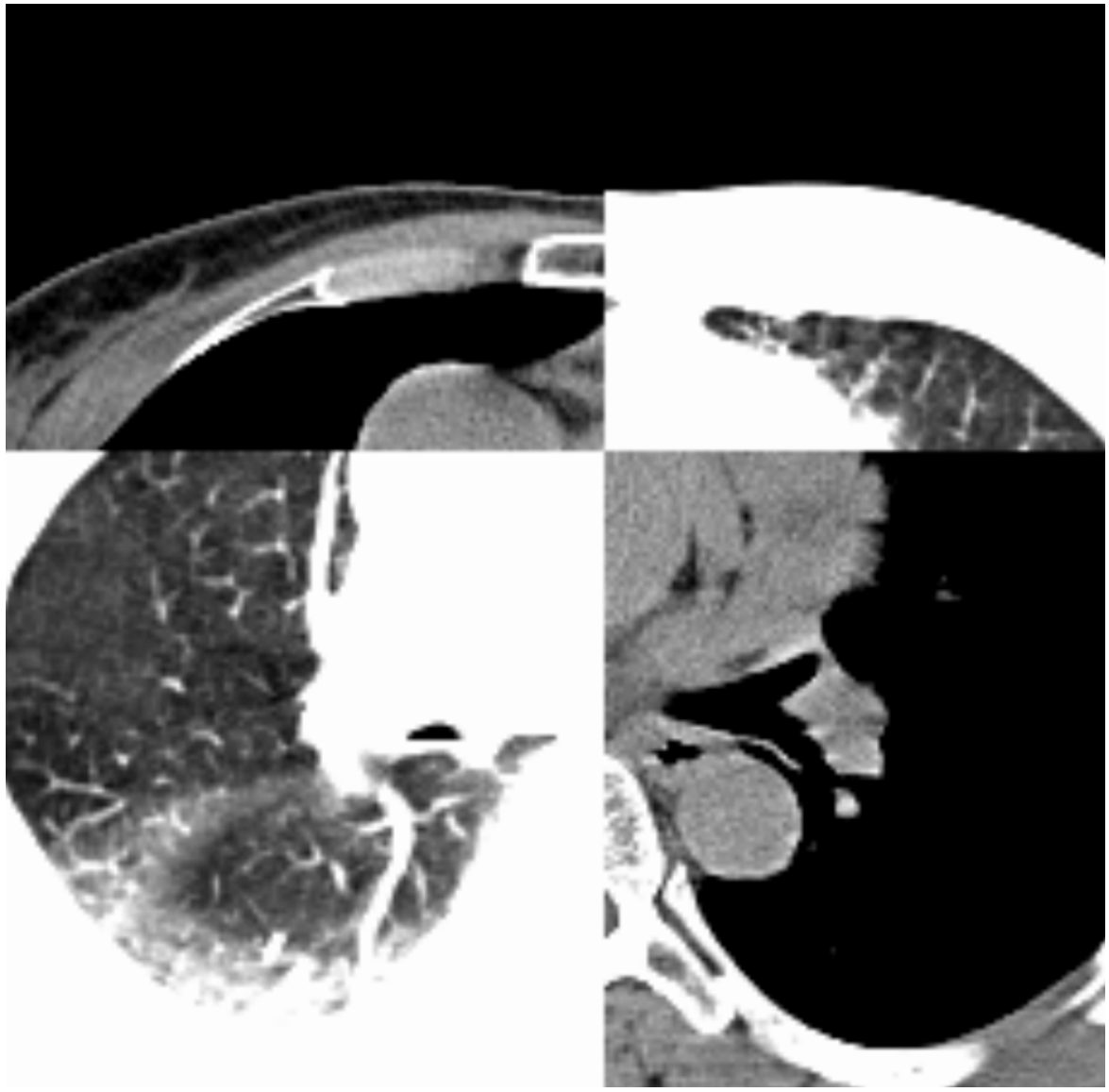

Modalities

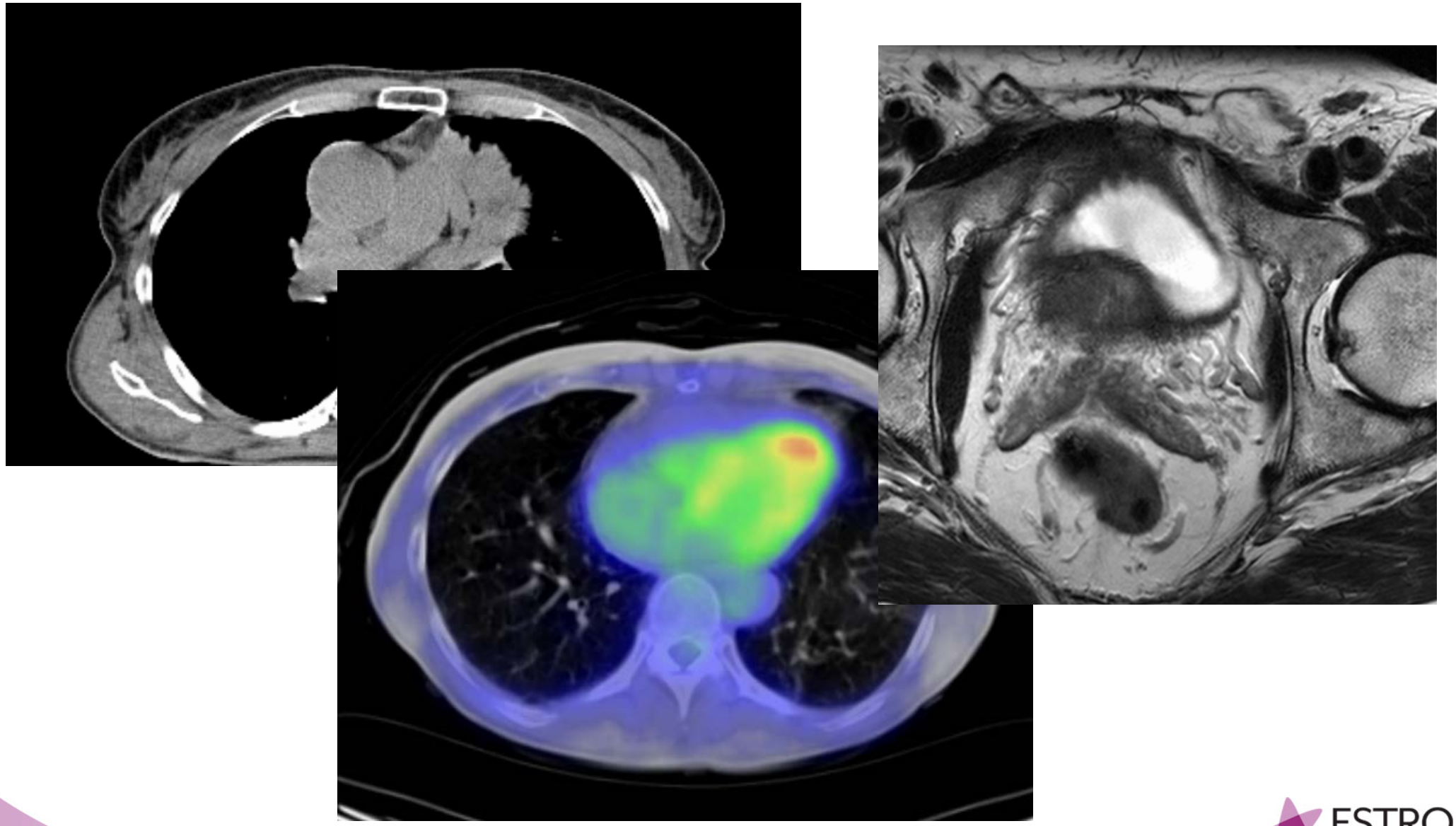

Resolution

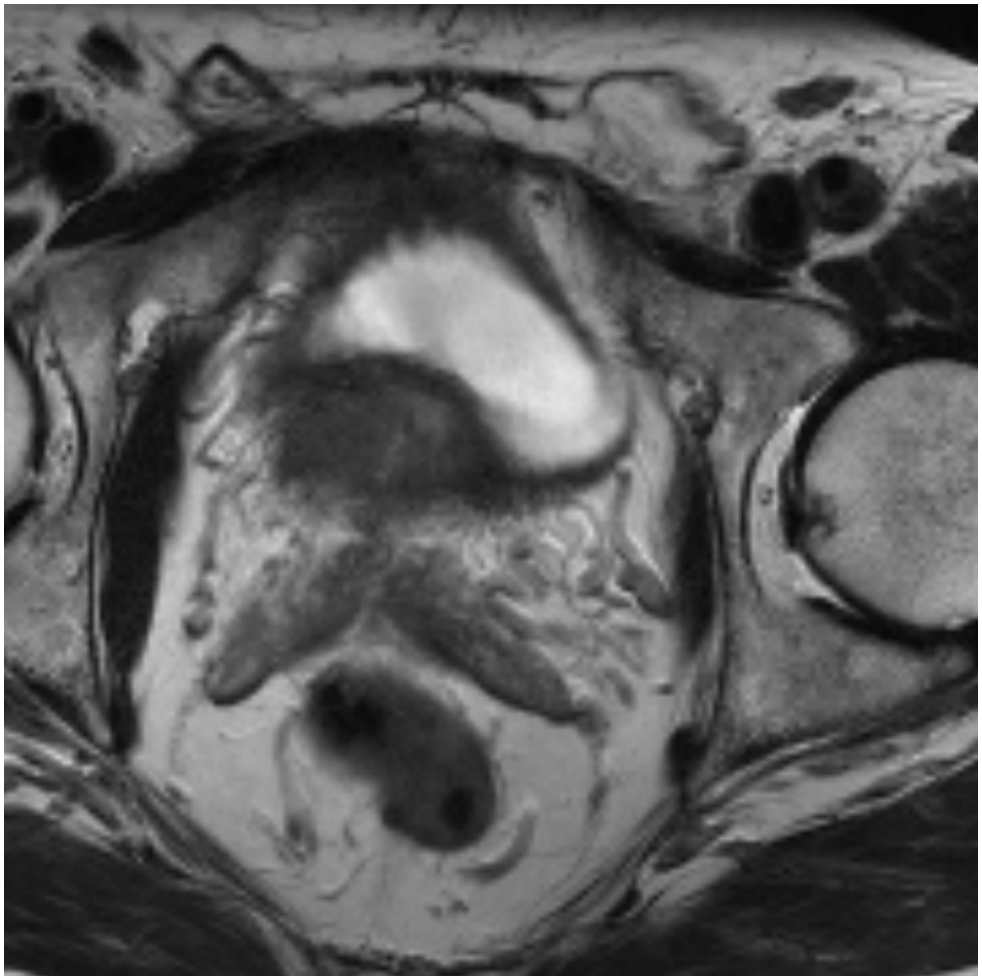

1 mm pixel size

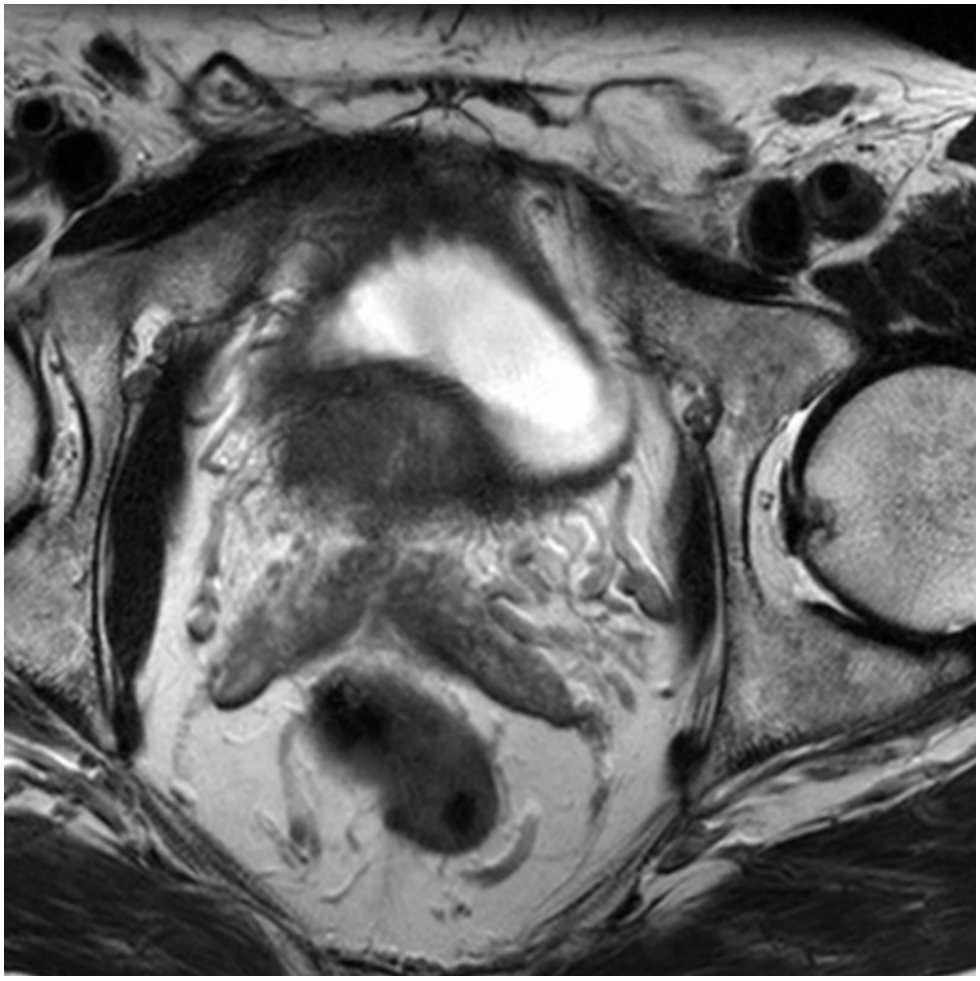

0.4 mm pixel size

ESTRO School

MRI artifacts can cause invisible geometrical errors!

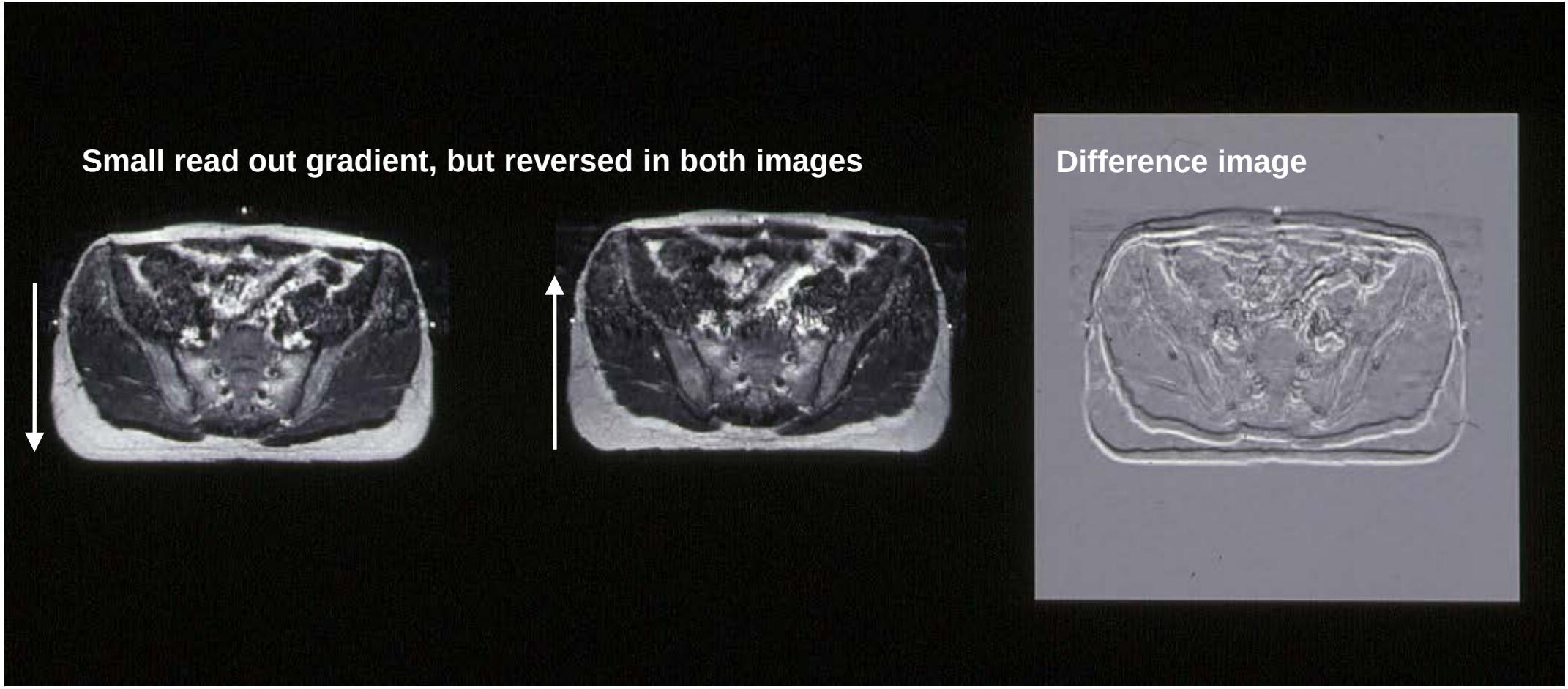

What you see is not always what you get

Courtesy U. van der Heide

ESTRO School

Registration

- Planning and image guidance is CT and CBCT based
- Delineation often based on MRI or PET

→ Registration error = Delineation error!

- Be careful with registrations – especially deformable

Anything can be deformed in anything else...
But is it true?



Why is this so important?

- Purely systematic error source
- Effectively shifts the dose distribution for ALL fractions
- Margin = 2.5 x SD of the errors
- E.g. 4 mm SD → 1 cm margin!
- More on this later

ESTRO School

How to analyze?

- Volumes?

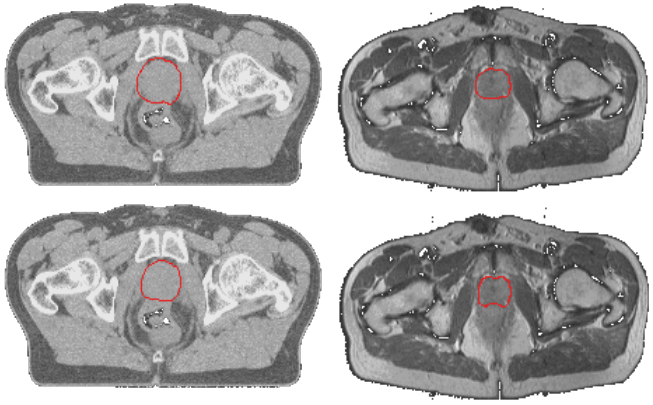



ESTRO School

How to analyze: Volumes?

- Volumes?
- Often used: DICE index

- DICE Index = $\frac{2 * \text{common volume}}{\text{Volume 1} + \text{Volume 2}}$

- No common volume: Index = 0
- Volumes identical: Index = 1

ESTRO School

How to analyze: Volumes?

- Problem: Left and right have the same volume difference!
- DICE index the same for both situations
- Clinically this may have a different impact

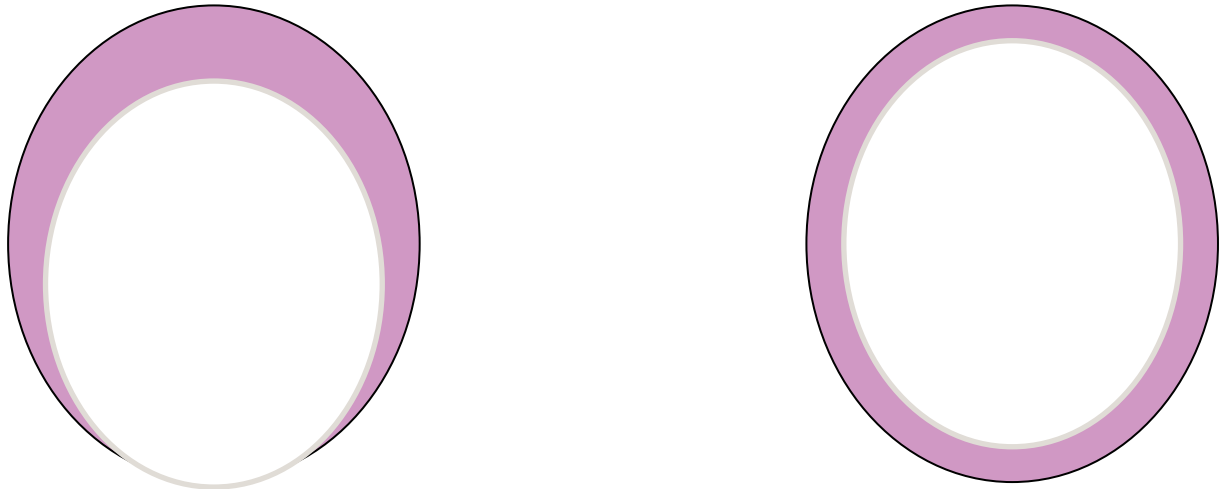

→ DICE is mainly a qualitative comparison tool

ESTRO School

How to analyze?

- Dose?
- E.g. evaluate DVHs of different structures
- Better, because spatial information is taken into account

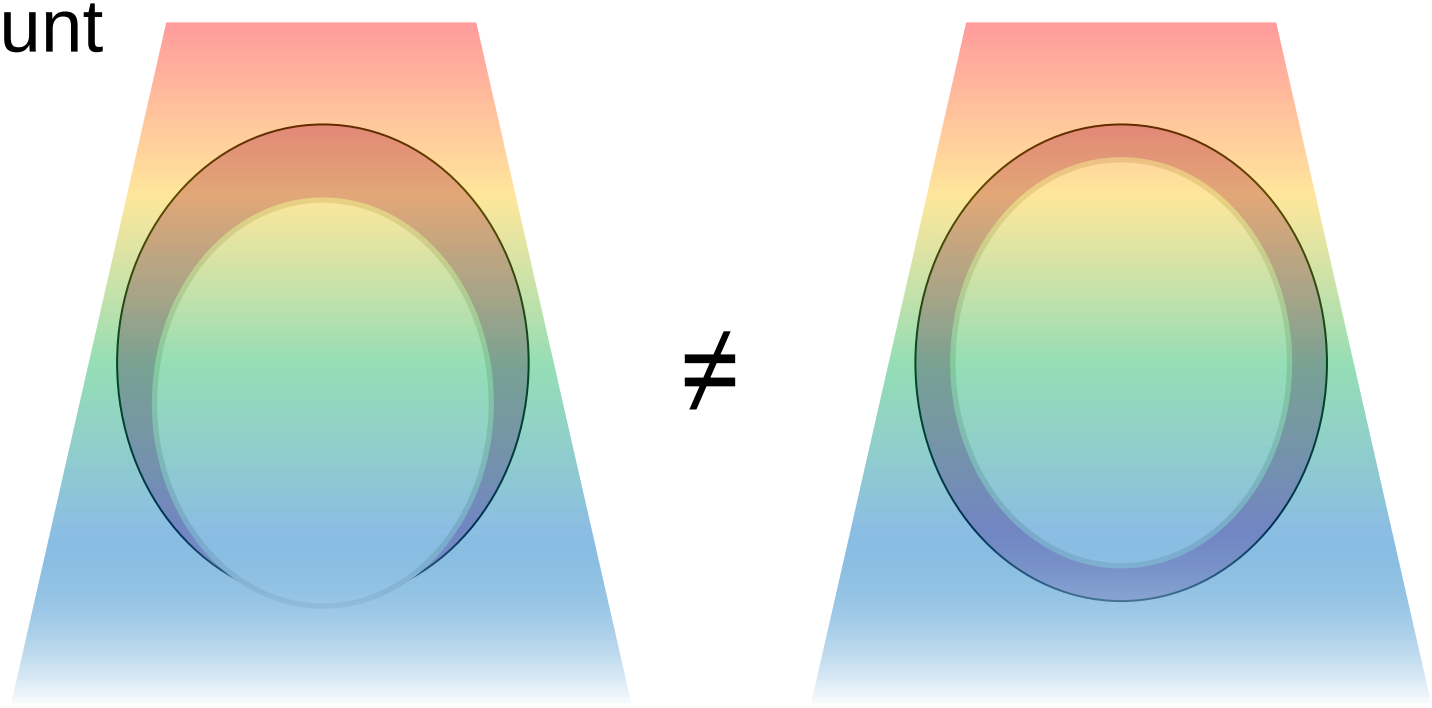

- Still no information on <u>where</u> the difference is

ESTRO School

How to analyze?

- Volumes?
- Dose?
- Distances!

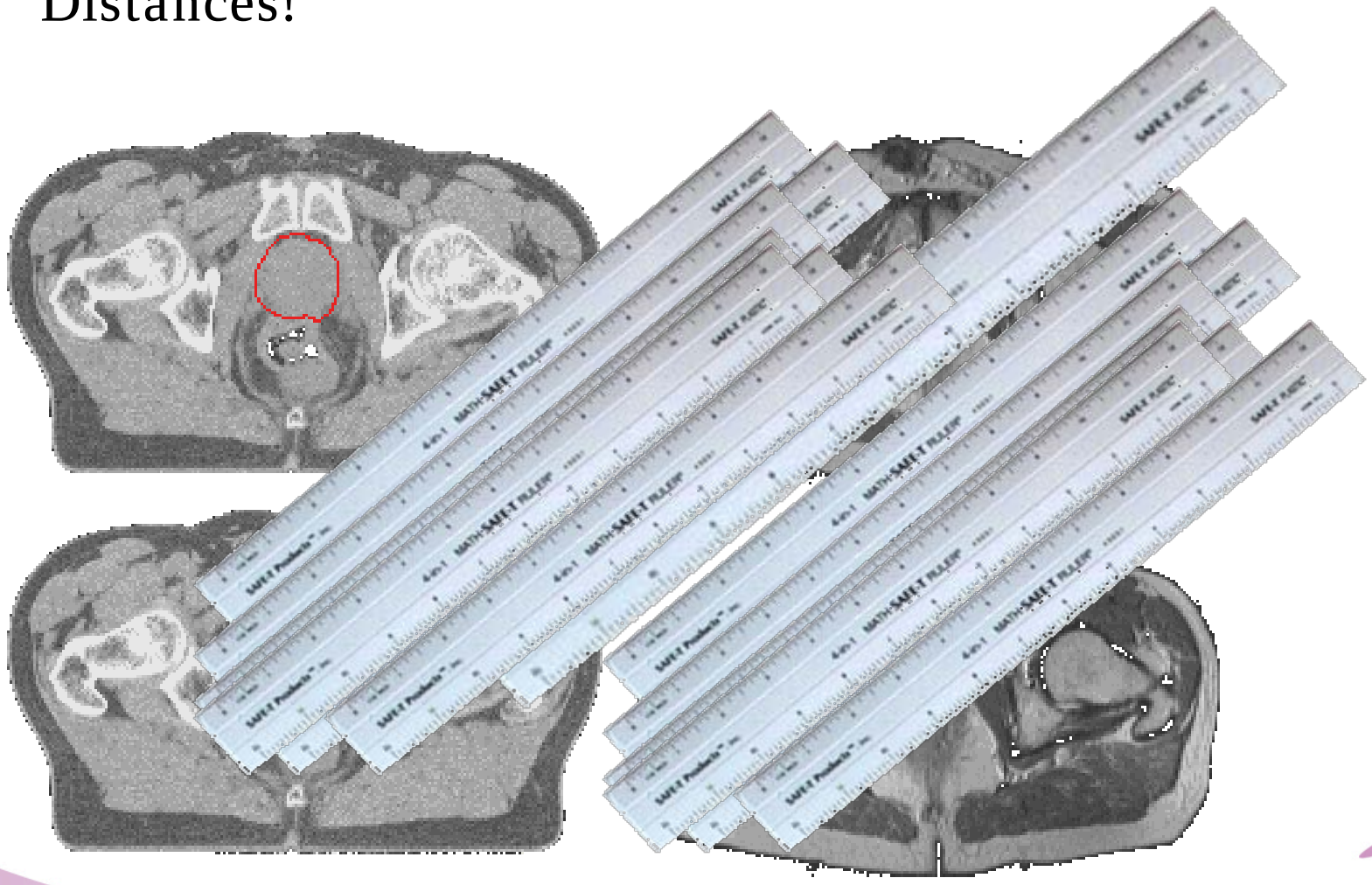

Distance maps

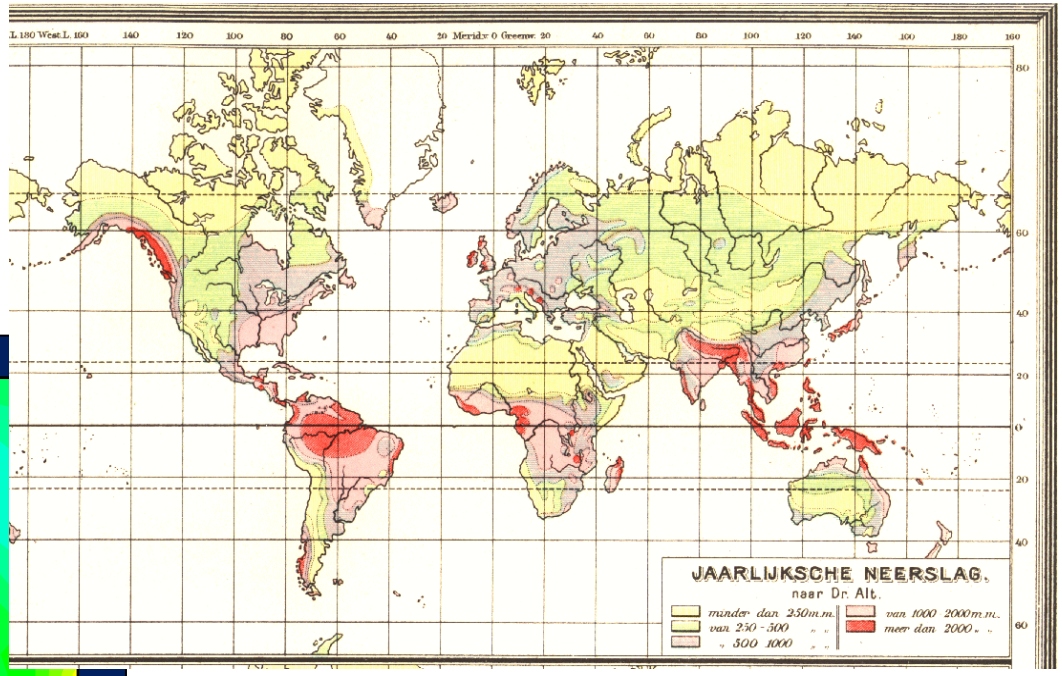

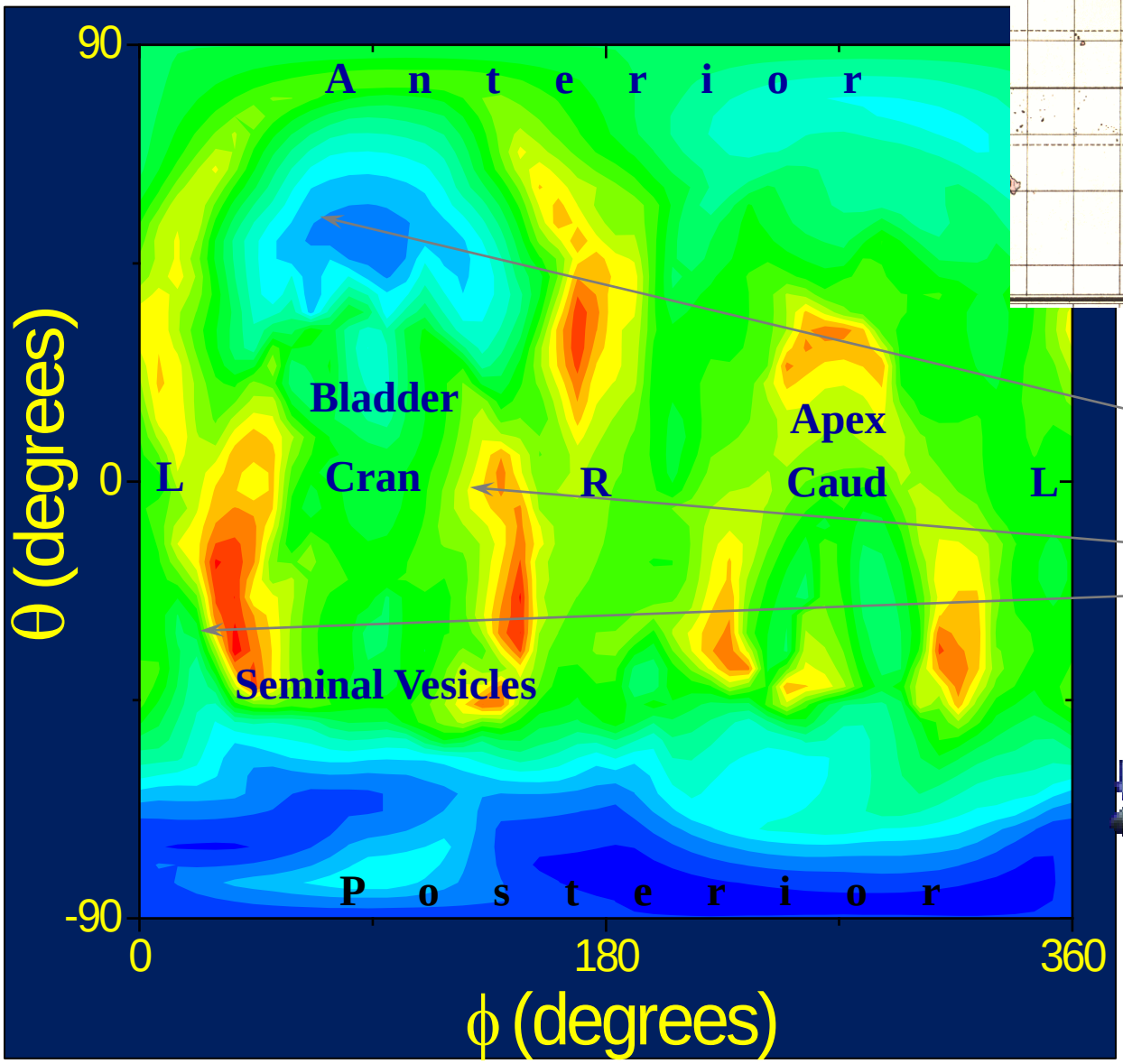

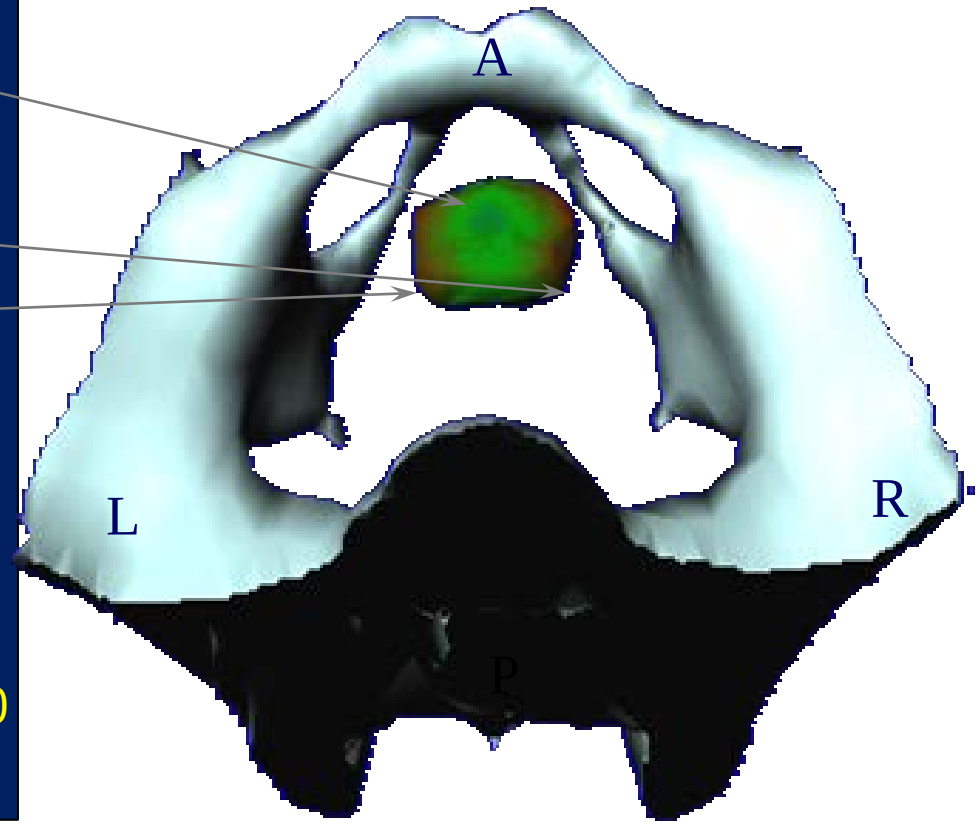

Systematic modality difference (axial MRI - CT)

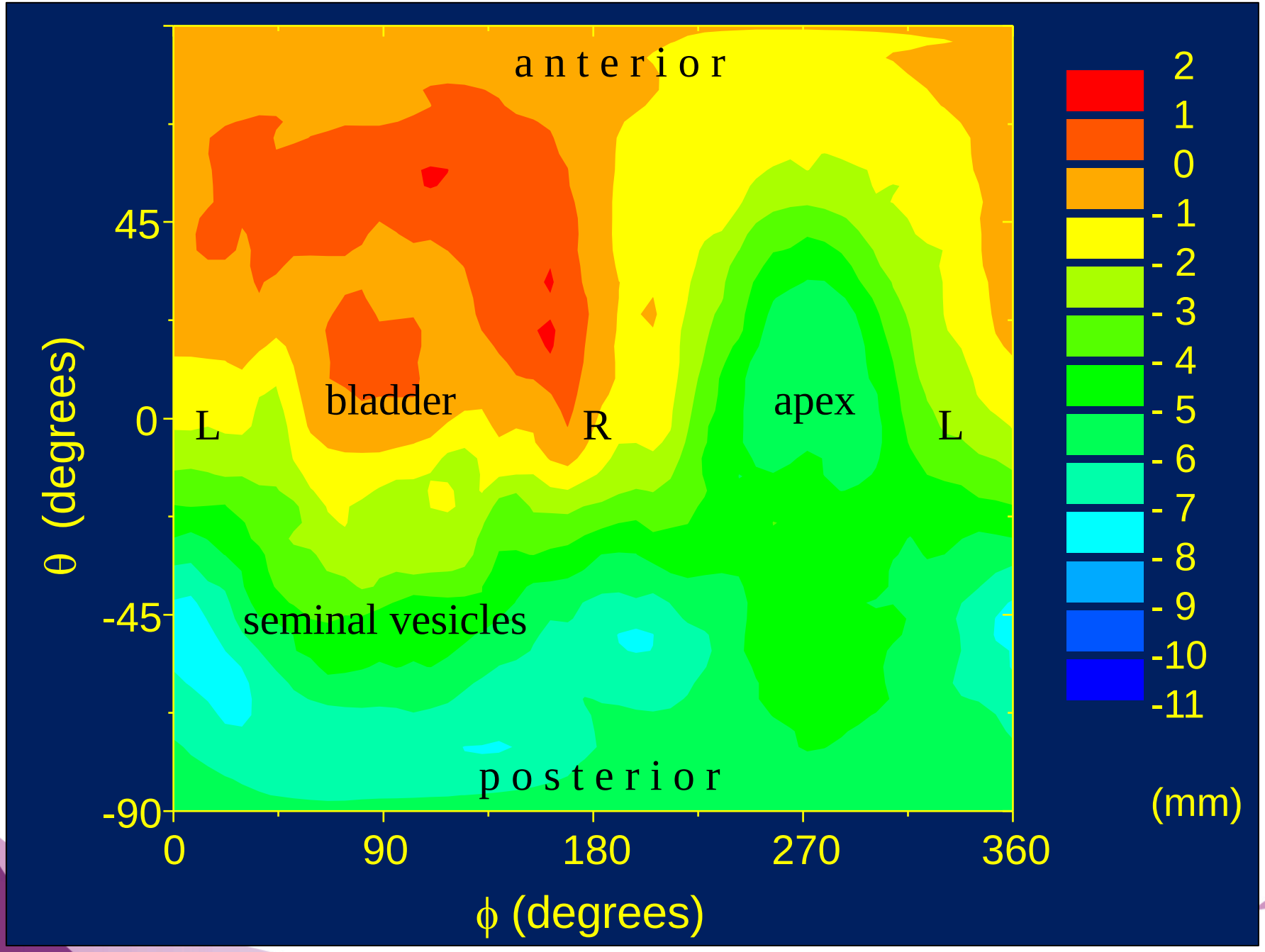

ESTRO School

Overall observer variation in CT (SD)

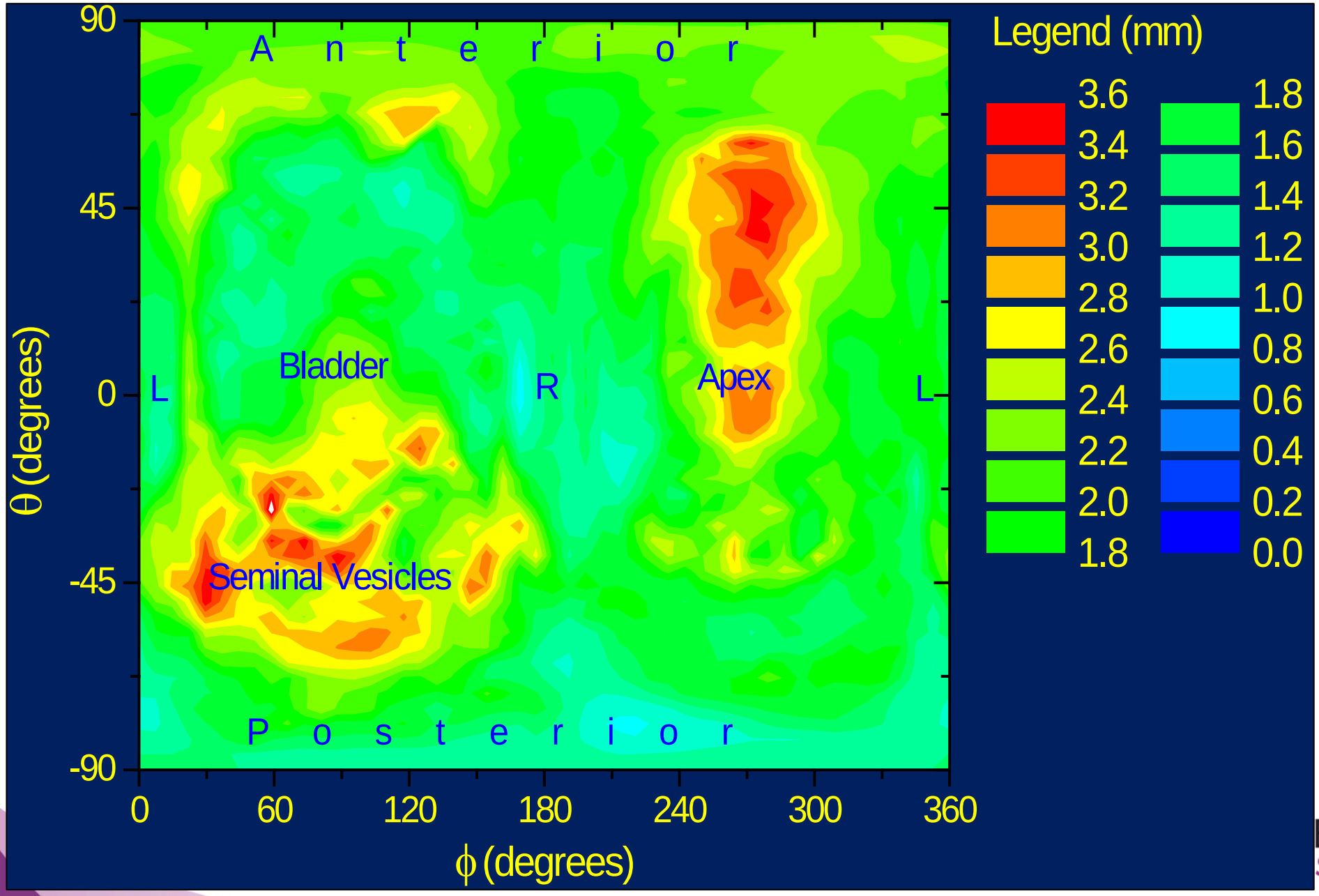

ESTRO School

What next?

- Measure complicated structures
- Improve delineation uncertainty by
  - Inclusion of more modalities
  - Clear protocols
- To determine protocols → See how the doctors are delineating

Geometrical analysis in 3-D

Median Surface

Distance measure

Local SD

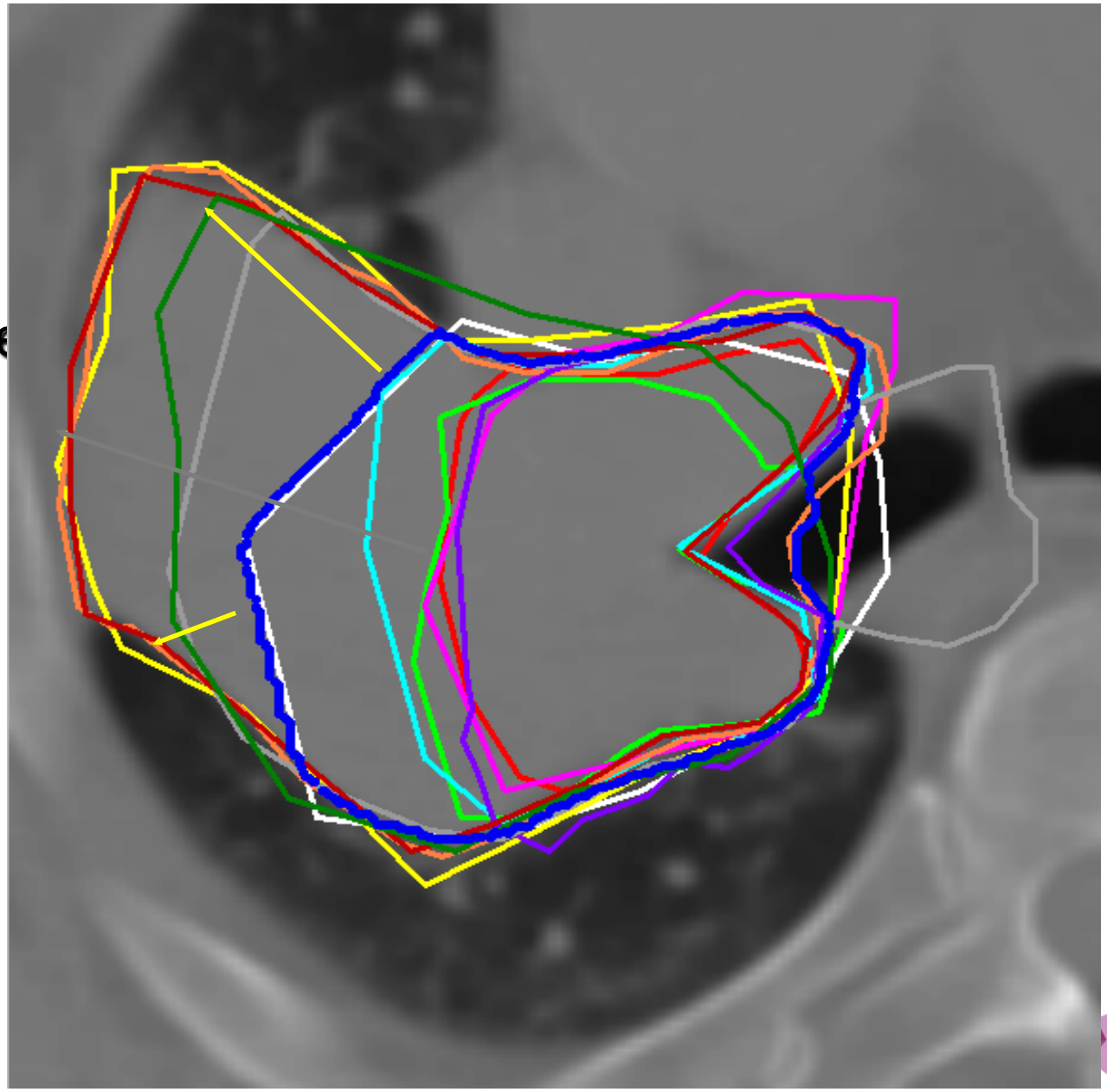

ESTRO School

Geometrical analysis in 3-D

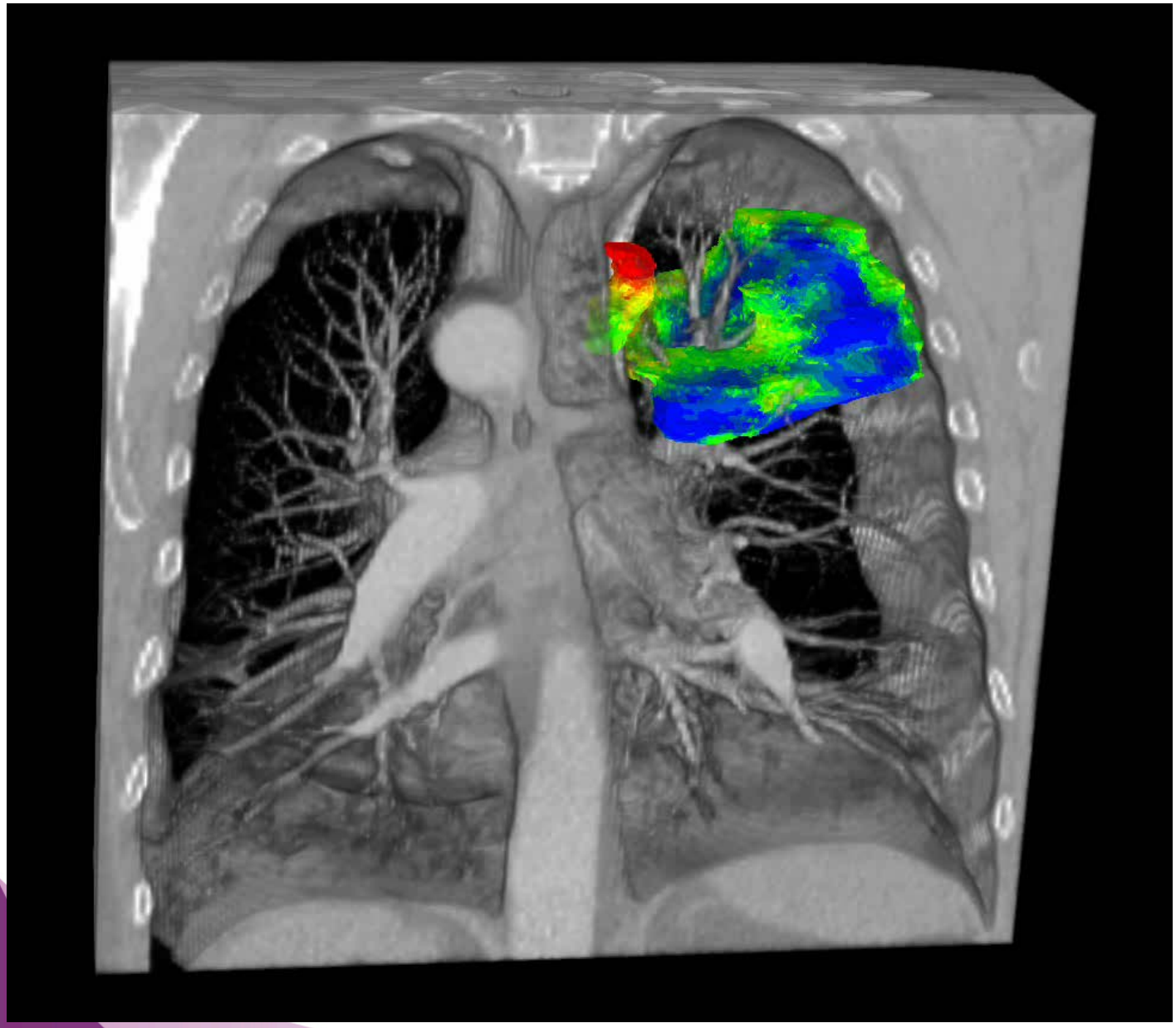

LOCAL SD (mm)

- 0 – 1
- 1 – 2
- 2 – 3
- 3 – 4
- 4 – 5
- 5 – 6
- 6 – 7
- 7 – 8
- 8 – 9
- 9 – 10
- 10 – 11
- 11 – 12
- 12 – 13
- 13 – 14
- 14 – 15
- > 15

ESTRO School

What are the doctors doing?

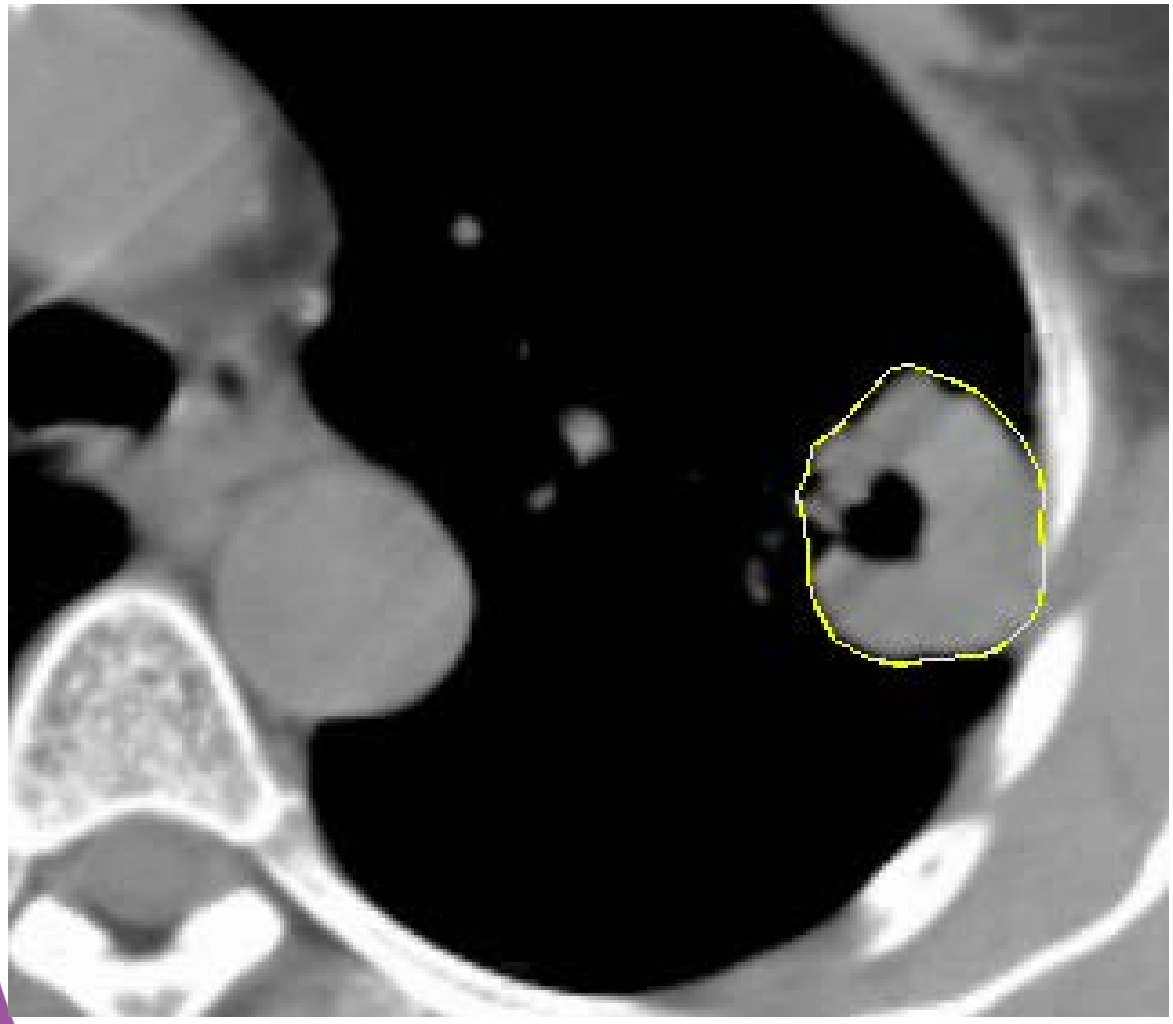

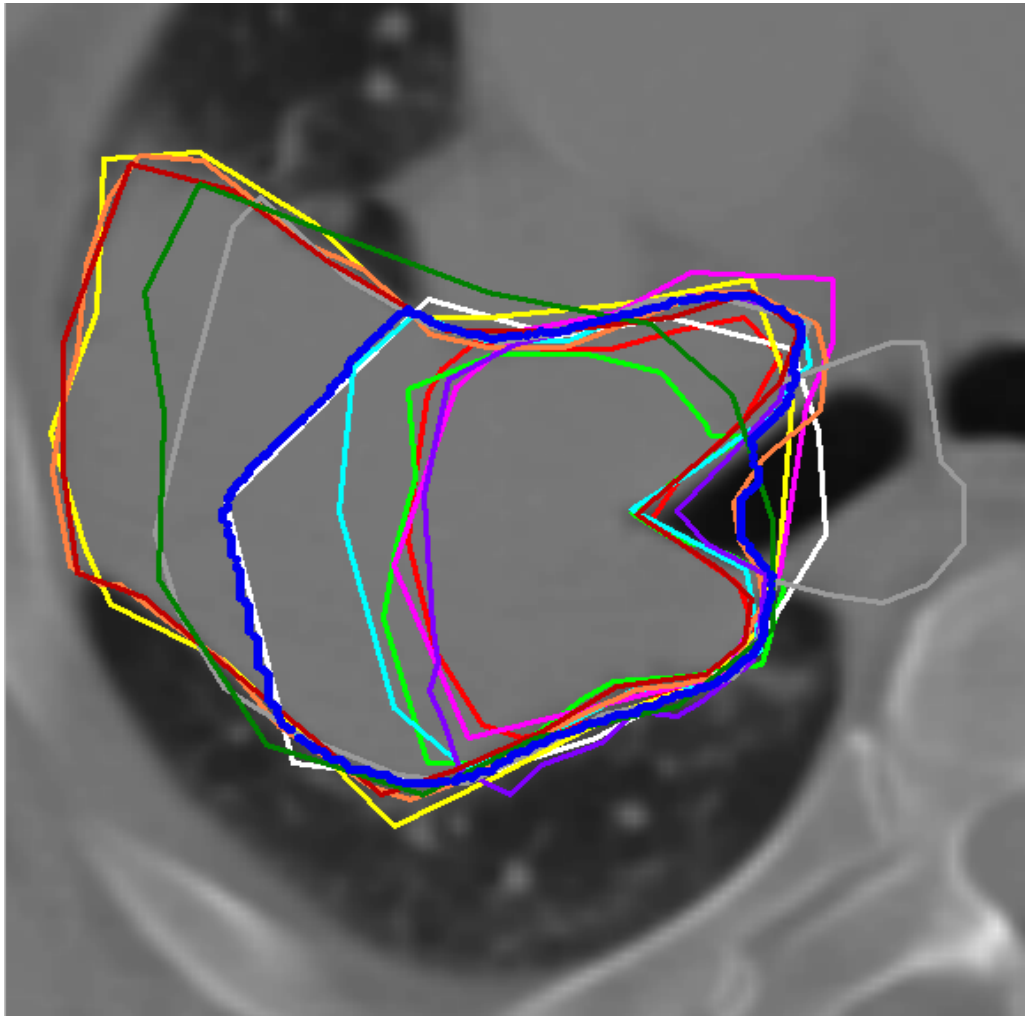

Big brother… ☺

ESTRO School

Target volume delineation

More sites were investigated

- Lung

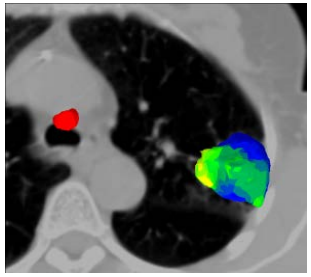

11 radiation oncologists

- H&N

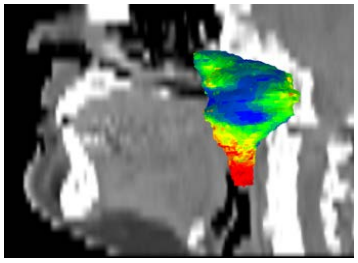

10 radiation oncologists

- Prostate

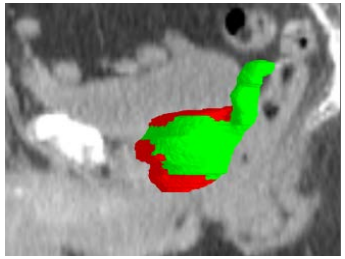

13 radiation oncologists

ESTRO School

Some examples……

Lung

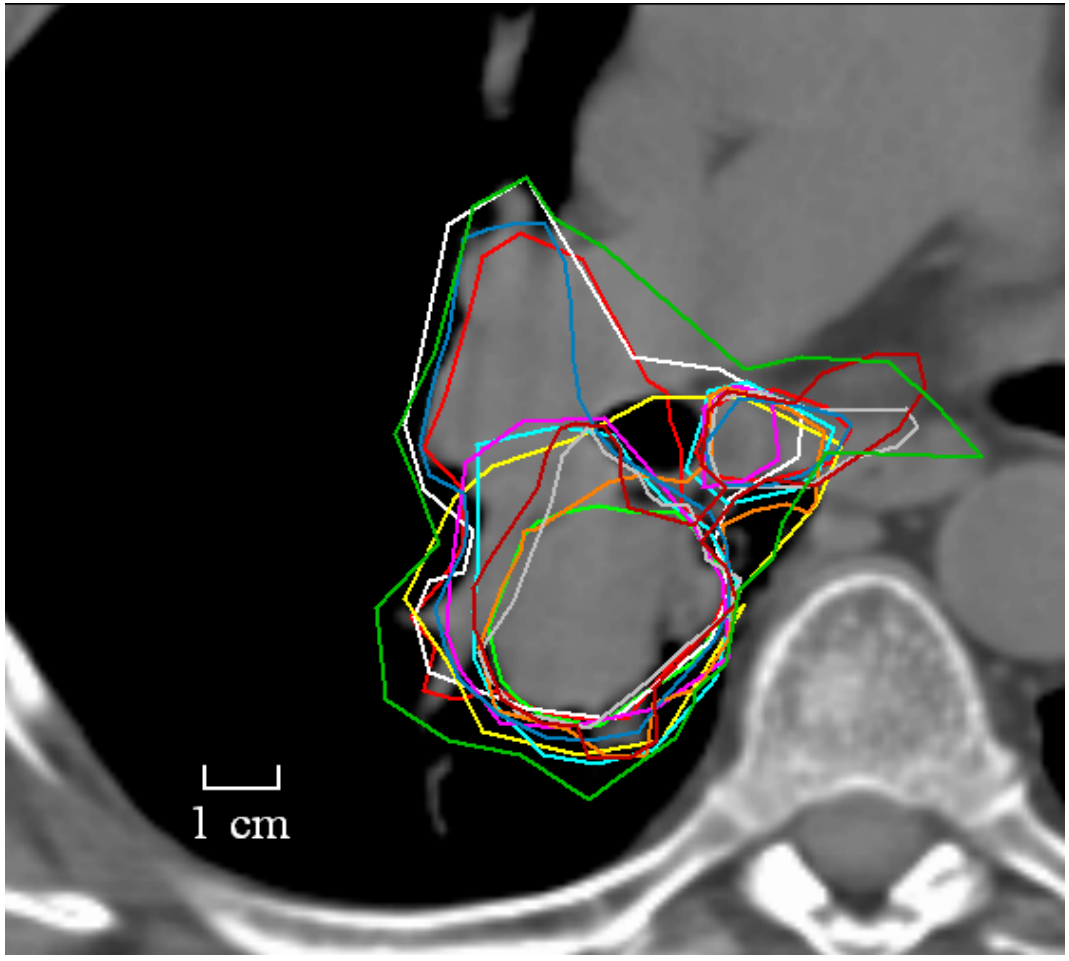

CT

SD 10.2 mm

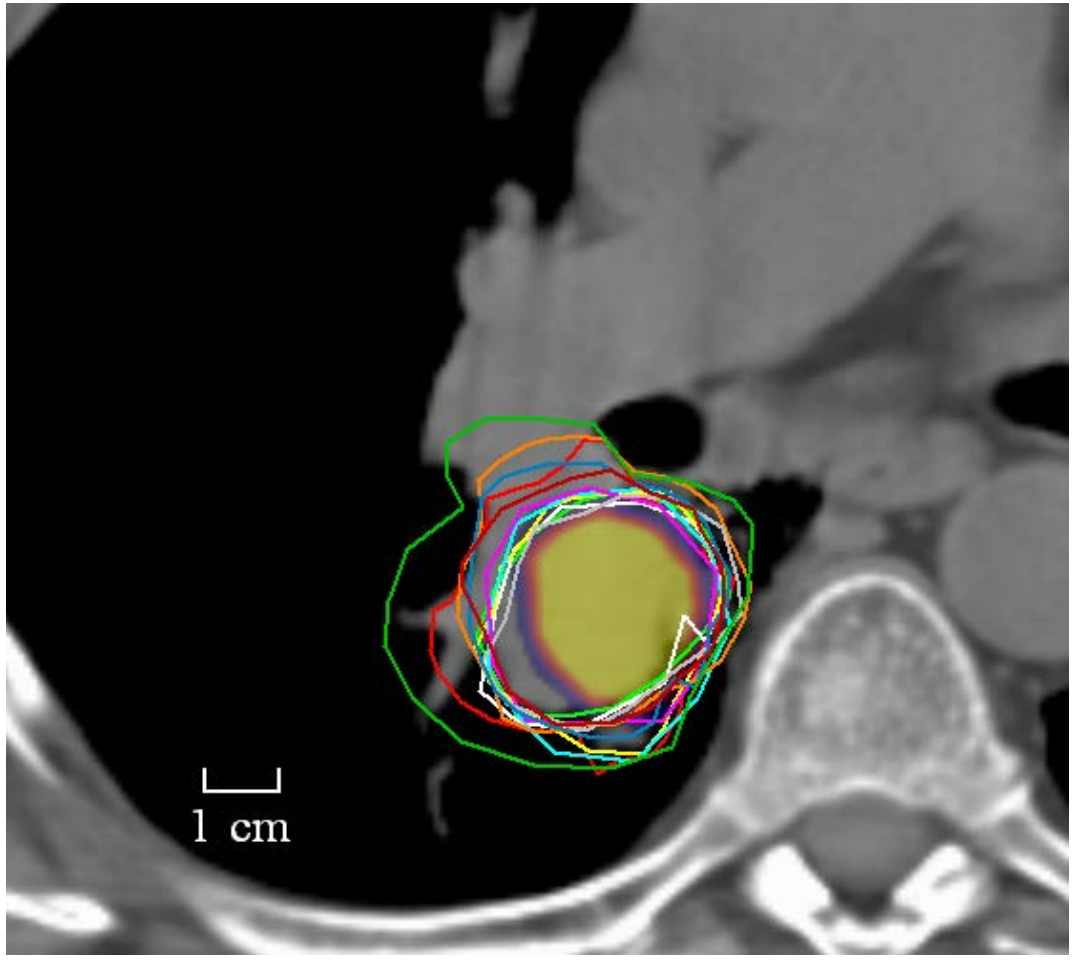

CT + PET

SD 4.2 mm

ESTRO School

Lung

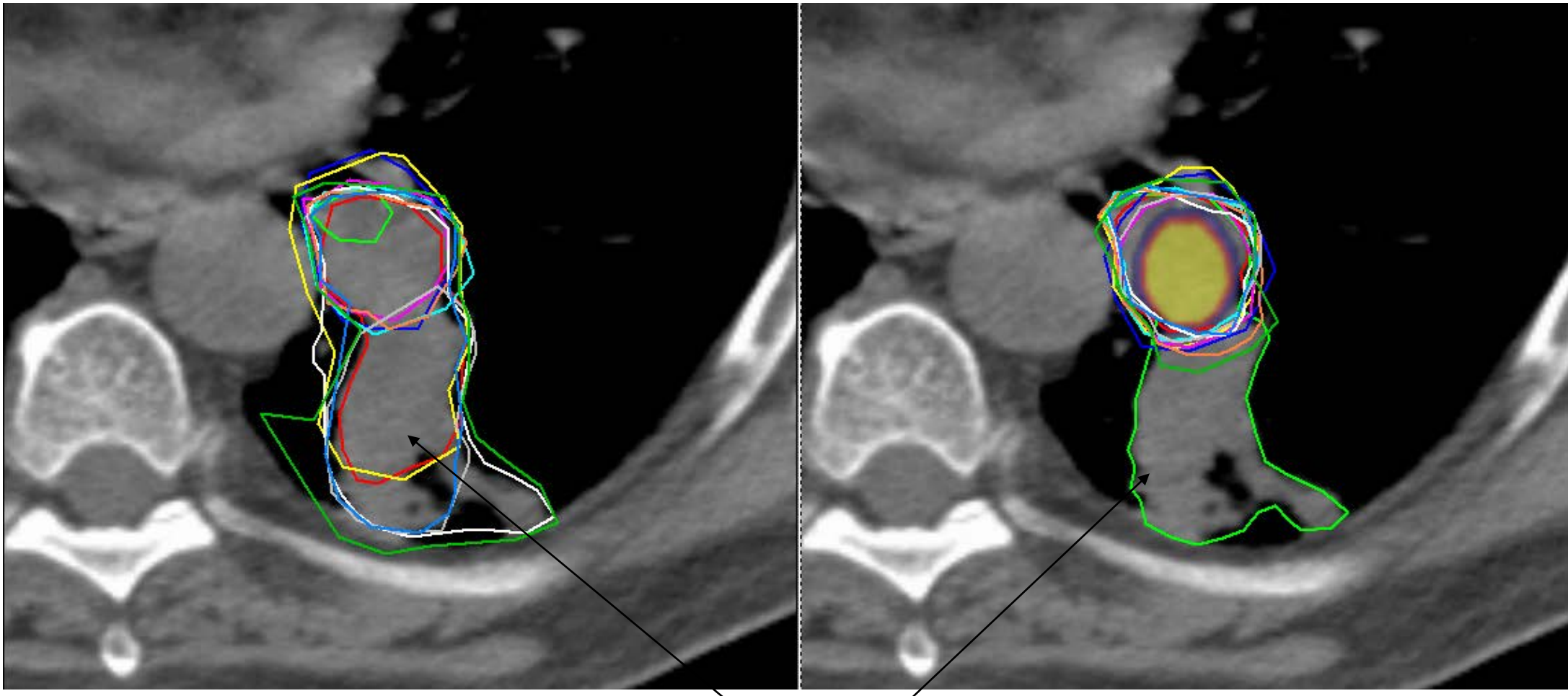

CT

SD 10.9 mm

Atelectasis?

CT+PET

SD 3.5 mm

ESTRO School

Lung

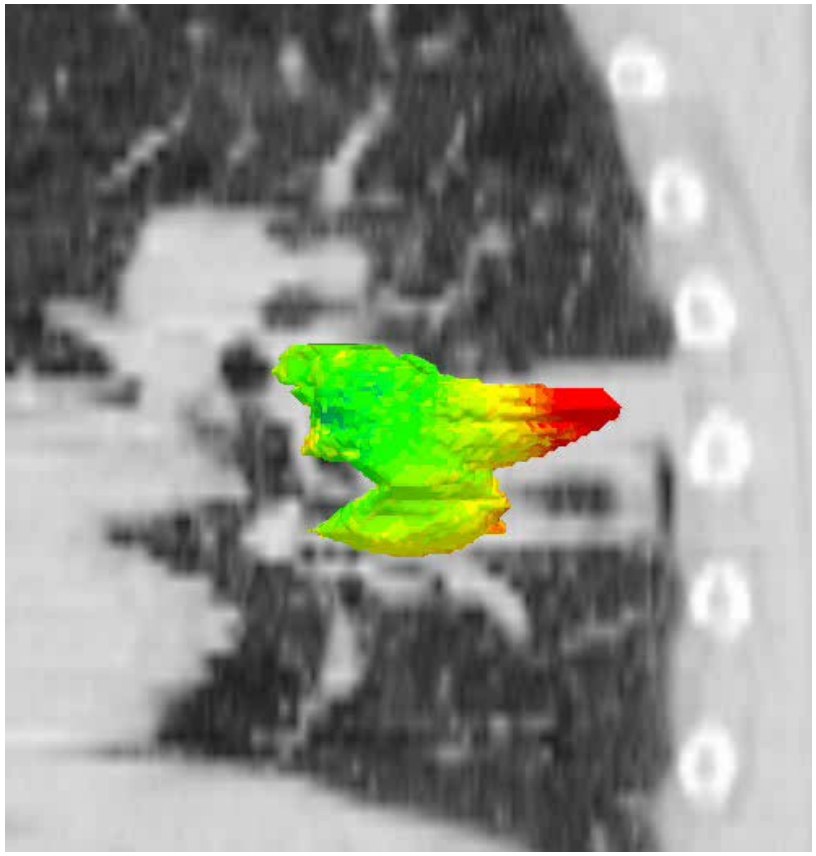

CT

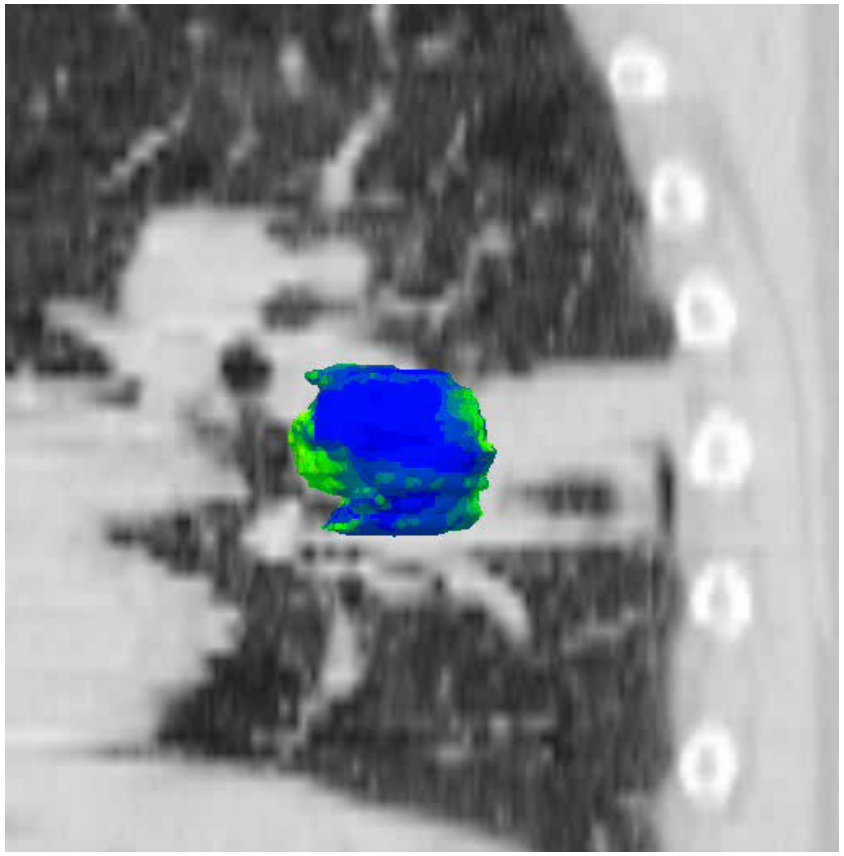

CT + PET

LOCAL SD (mm)

0 – 1	4 – 5	8 – 9	12 – 13
1 – 2	5 – 6	9 – 10	13 – 14
2 – 3	6 – 7	10 – 11	14 – 15
3 – 4	7 – 8	11 – 12	> 15

“Big Brother”

How did the doctors do the segmentation?

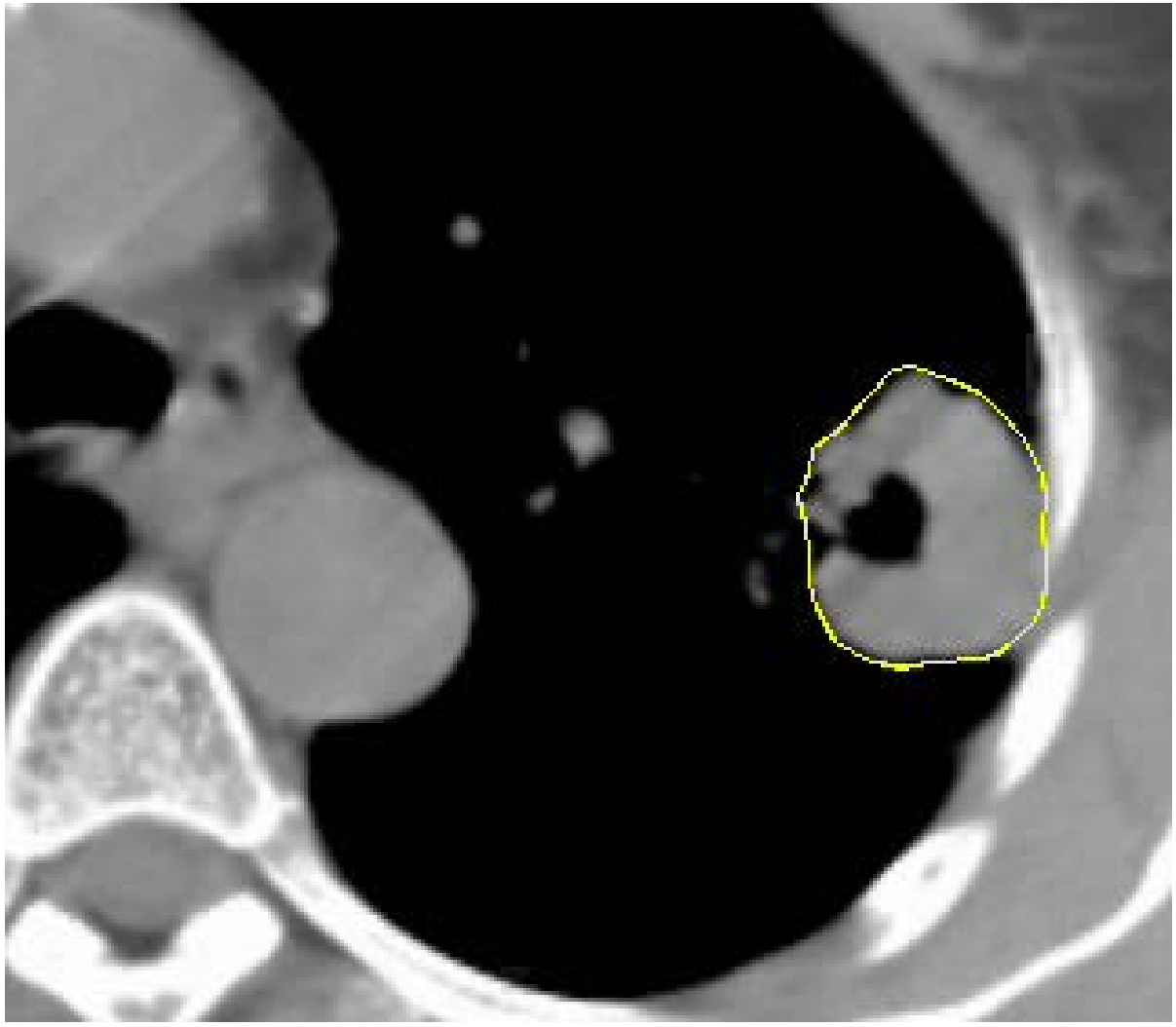

“Big Brother”

- Mean del. time: CT 16 min
  CT-PET 12 min
  } $p < 0.001$ paired students T-test

- Corrections

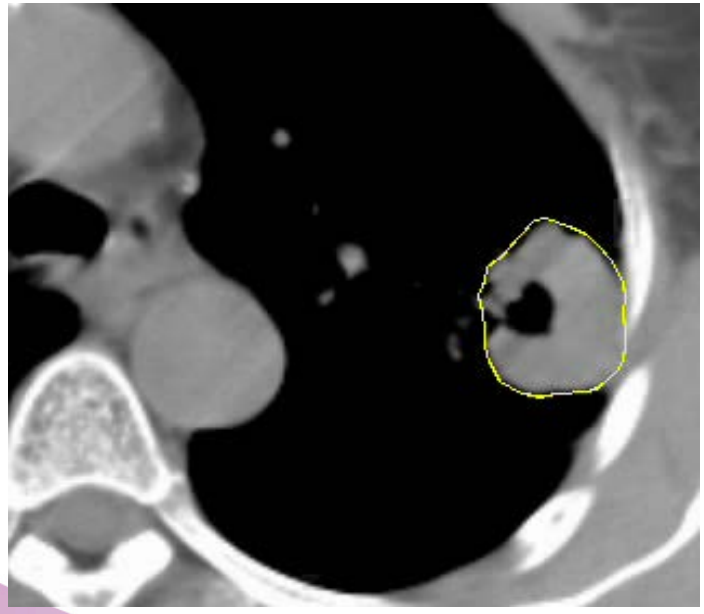

Region	CT (corr / cm²)	CT-PET (corr / cm²)
Tumor – lung	4.2	3.1
Tumor – chest wall	5.0	3.8
Tumor – mediastinum	4.1	3.4
Lymph nodes	4.9	**5.4**
Tumor – atelectasis	2.4	1.9
Total	**4.0**	**3.2**
Total # corrections	**9416**	**6144**

Prostate case

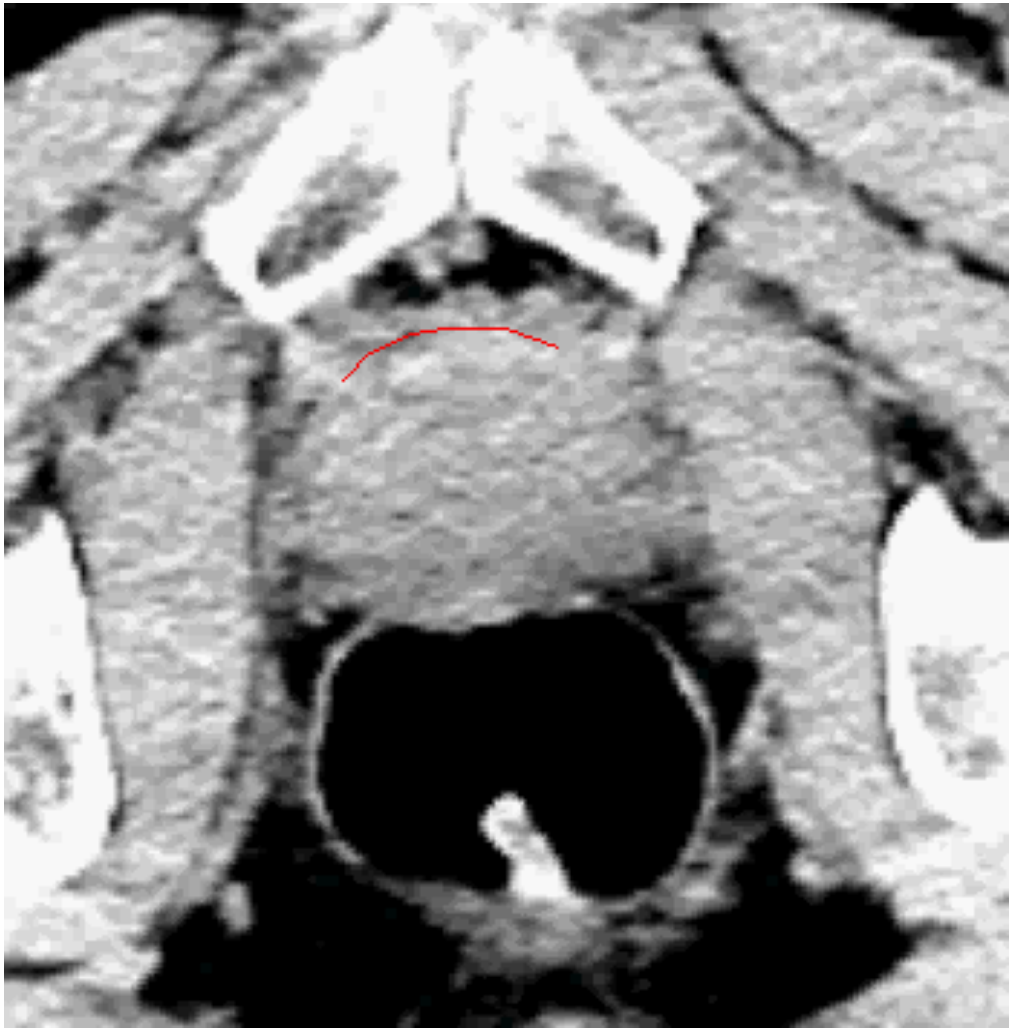

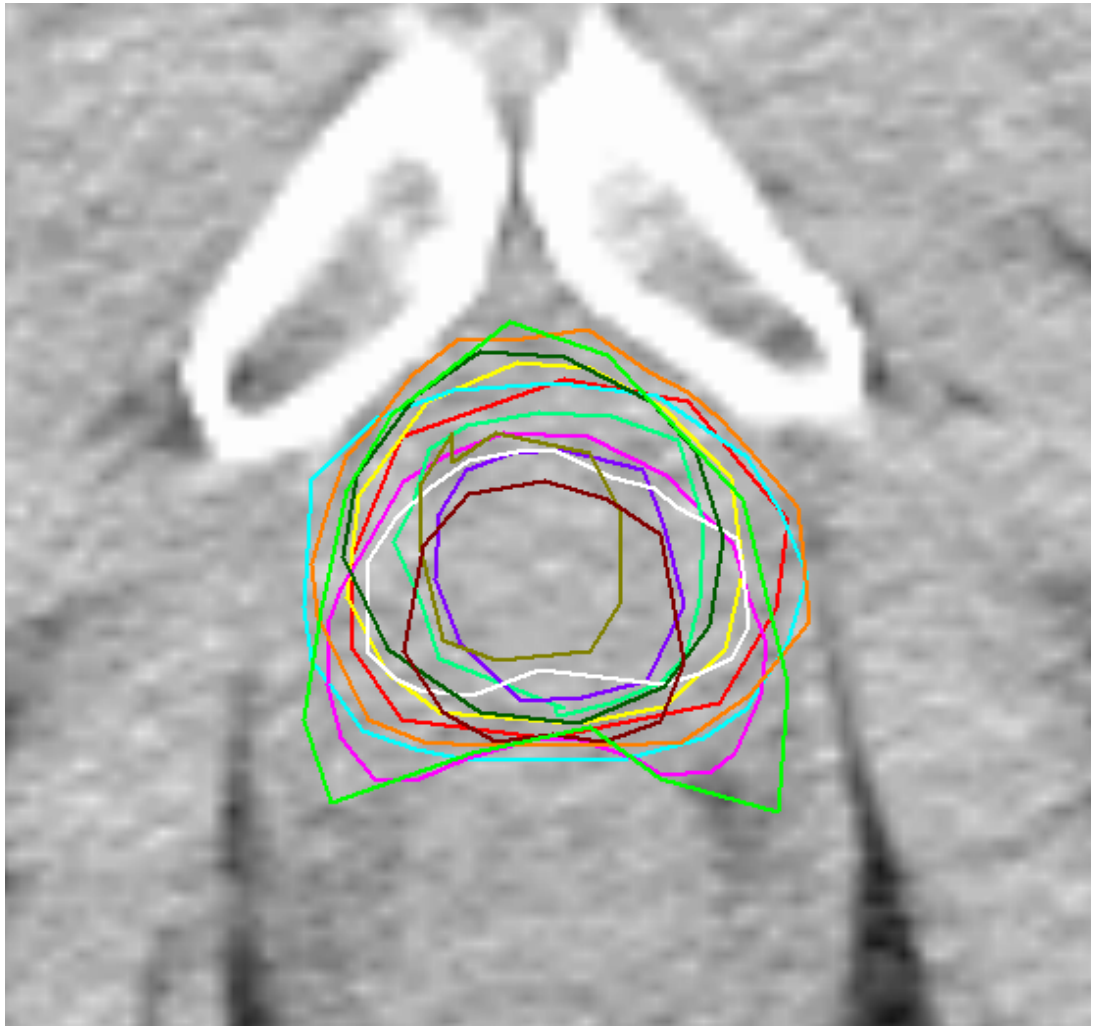

ESTRO School

3-D median surface with local SD

Median Surface

Distance measured

Local SD

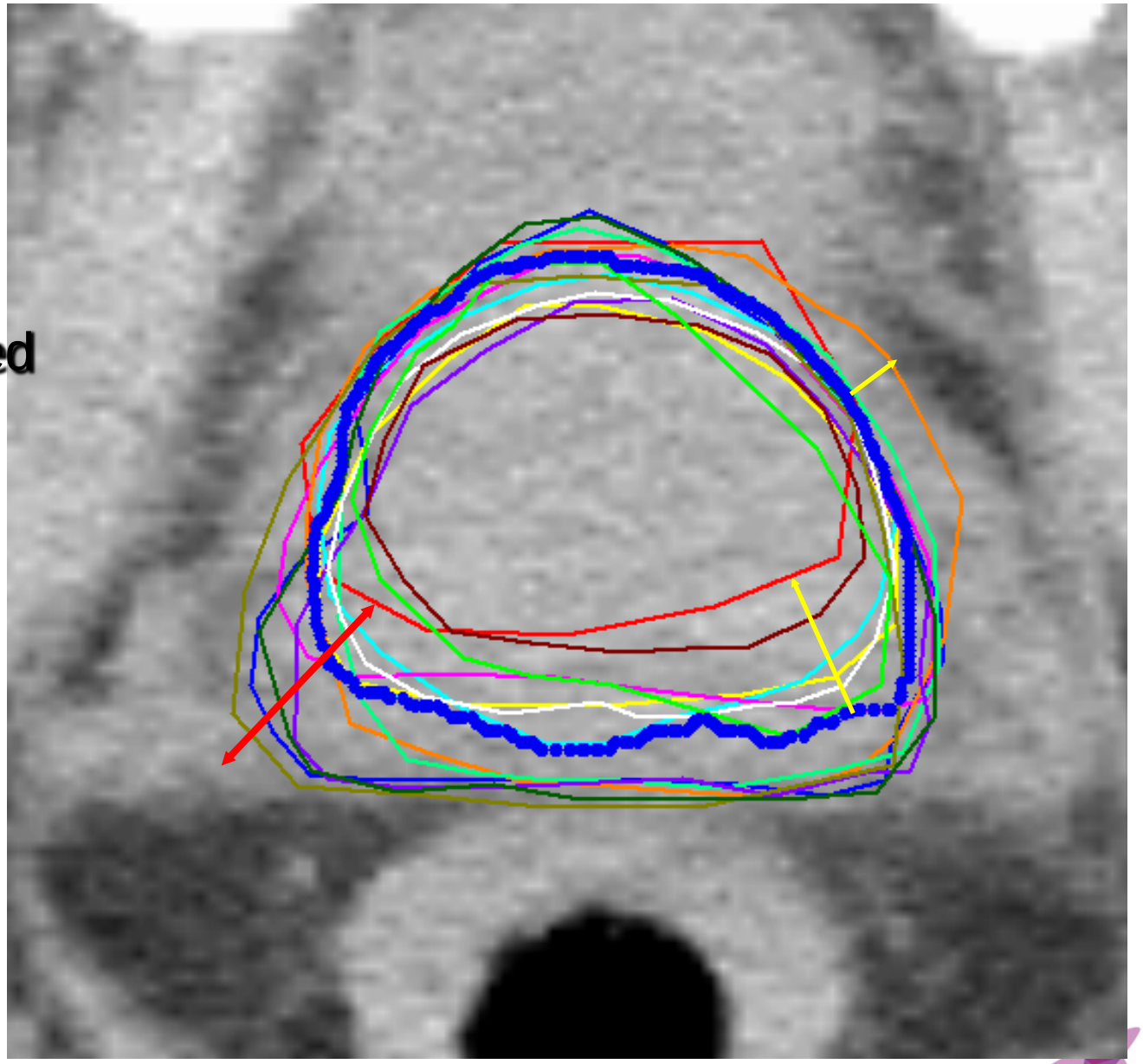

ESTRO School

3-D median surface with local SD

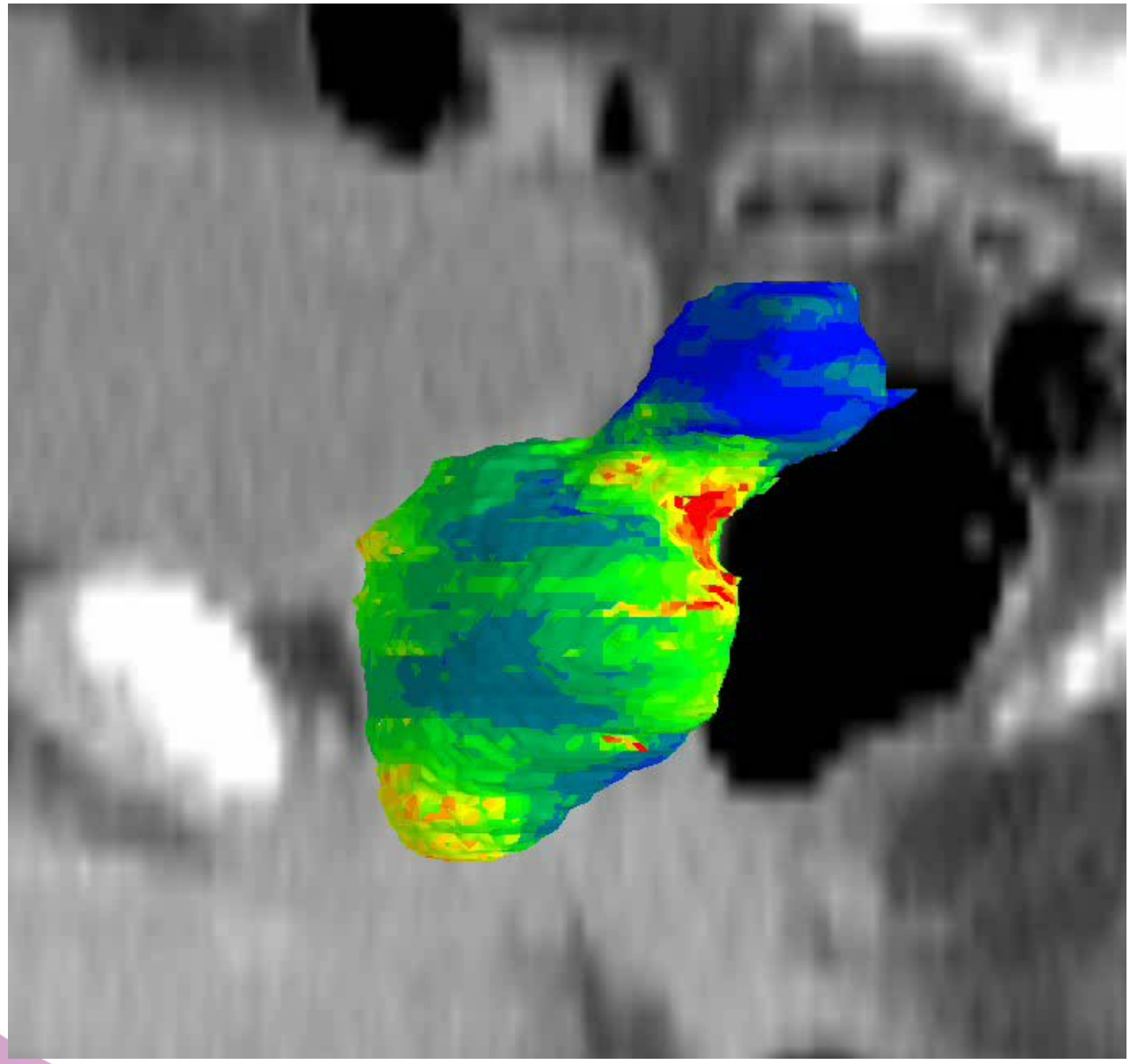



Use diffferent imaging modalities

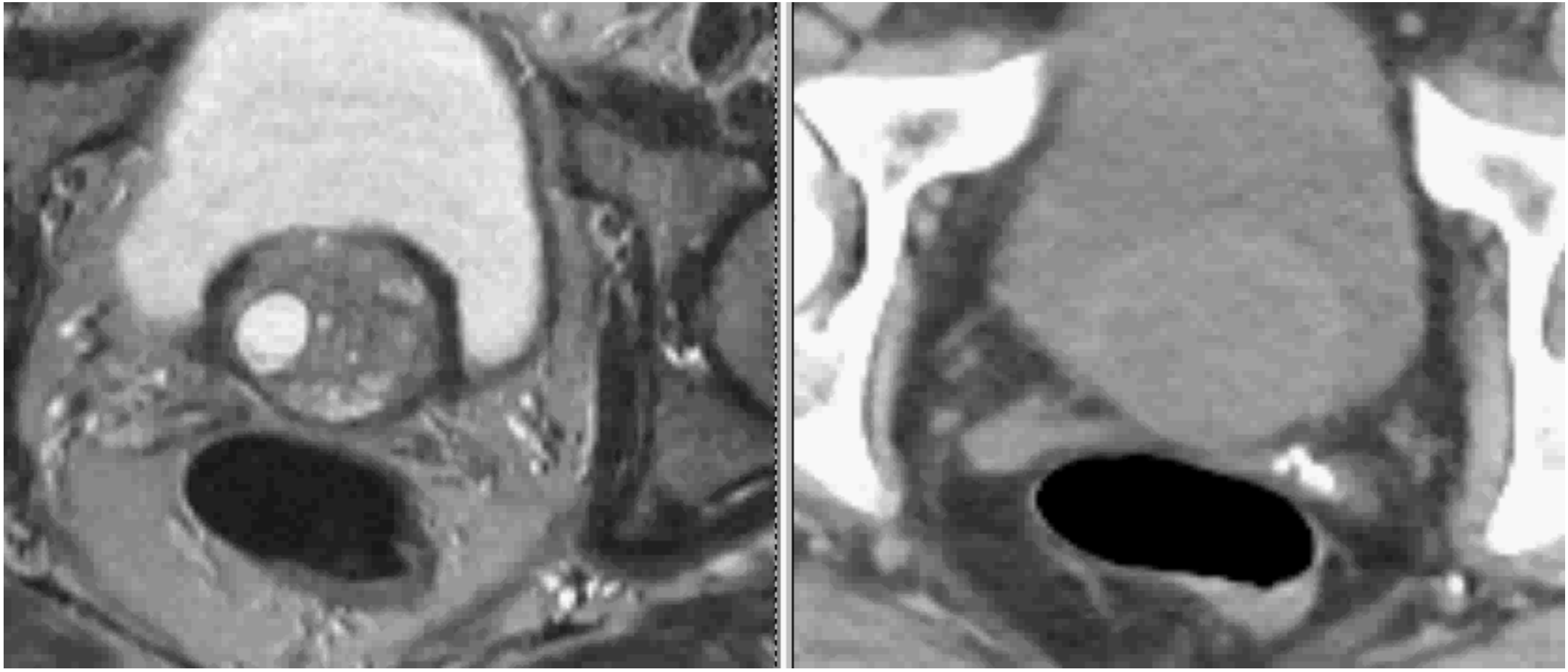

Matched MRI – CT

ESTRO School

Prostate

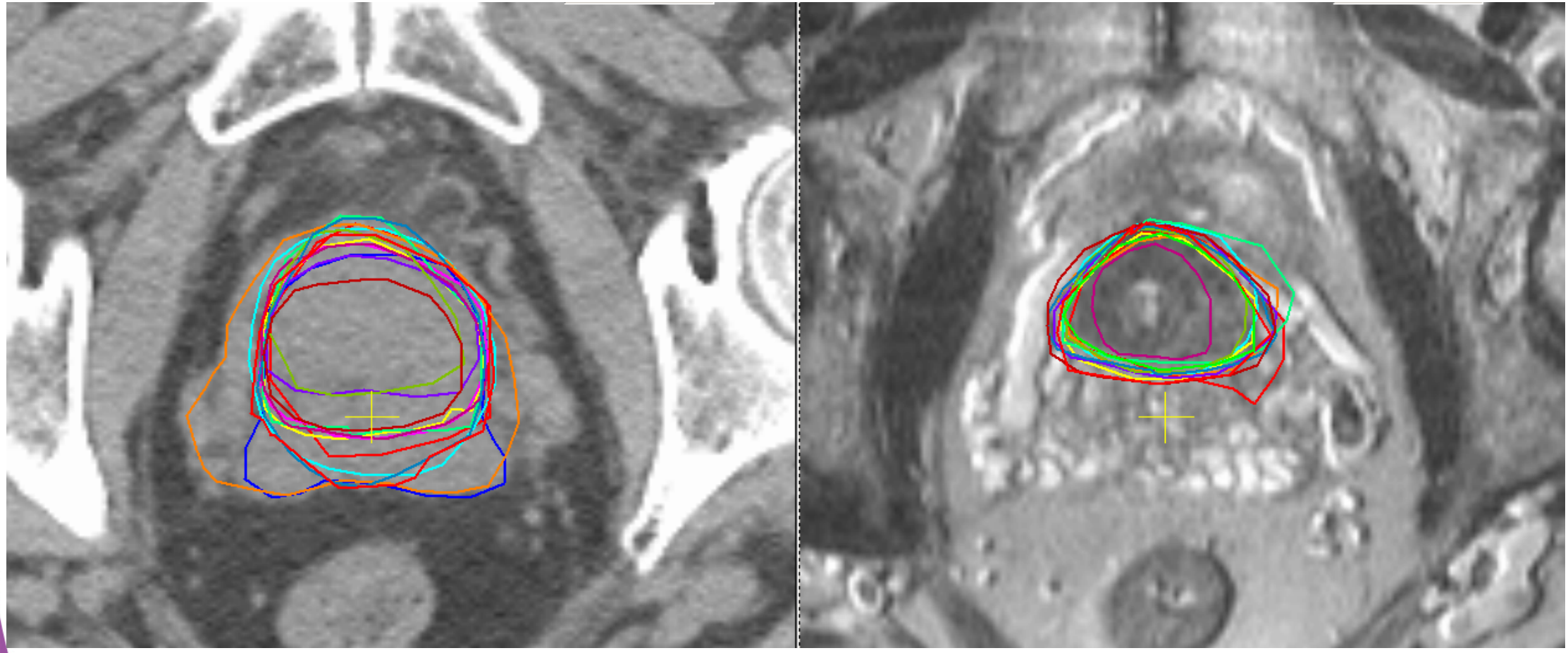

CT

SD 3.0 mm

CT + MRI

SD 2.8 mm

ESTRO School

Conclusions

- Many factors influence the delineation accuracy
- To quantify, a full 3-D analysis (in cms) is needed
- Benefits of different modalities, protocols can then be validated
- Because it's a systematic deviation, the effect on the treatment is large

ESTRO School

Dubouillon
Dubouillon

From uncertainties to margins

Peter Remeijer

Introduction

- Geometrical uncertainties are unavoidable
- Many are patient related
- What types of errors do we get?
- How large a margin do we need?

ANTONI VAN LEEUWENHOEK

Some examples

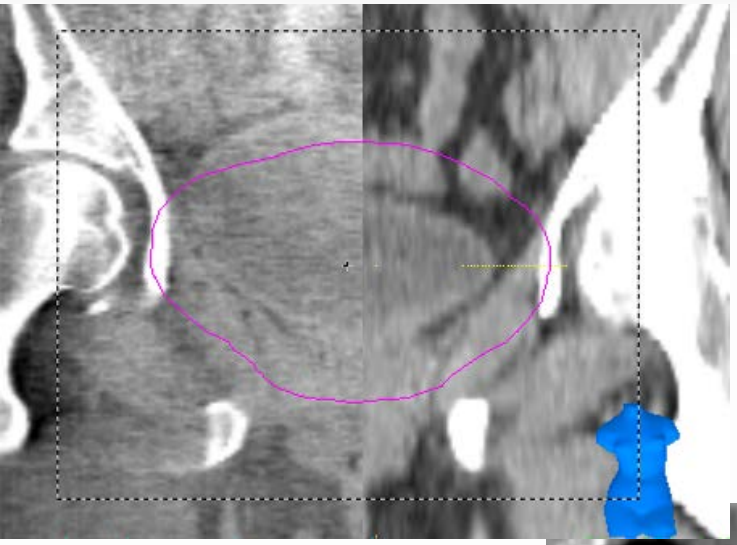

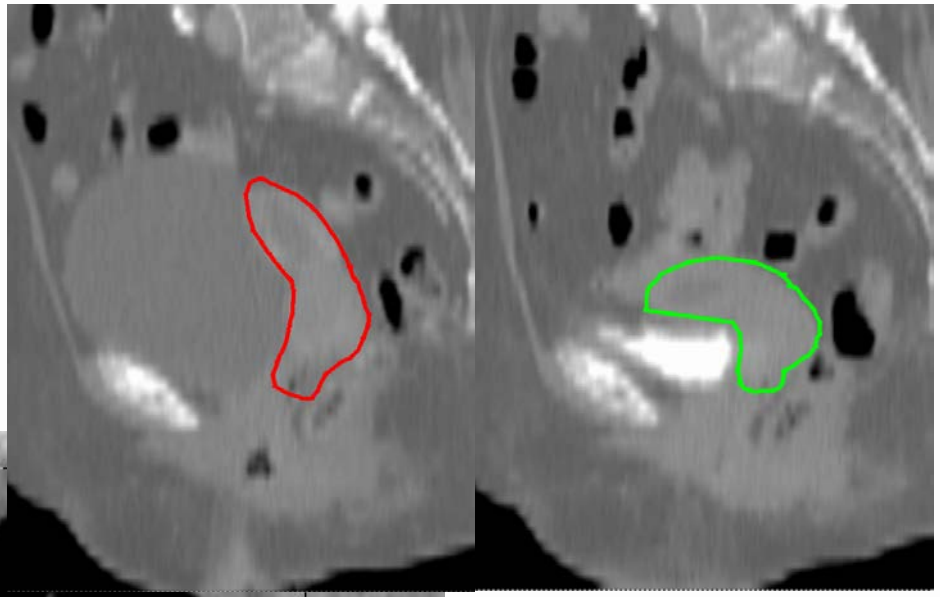

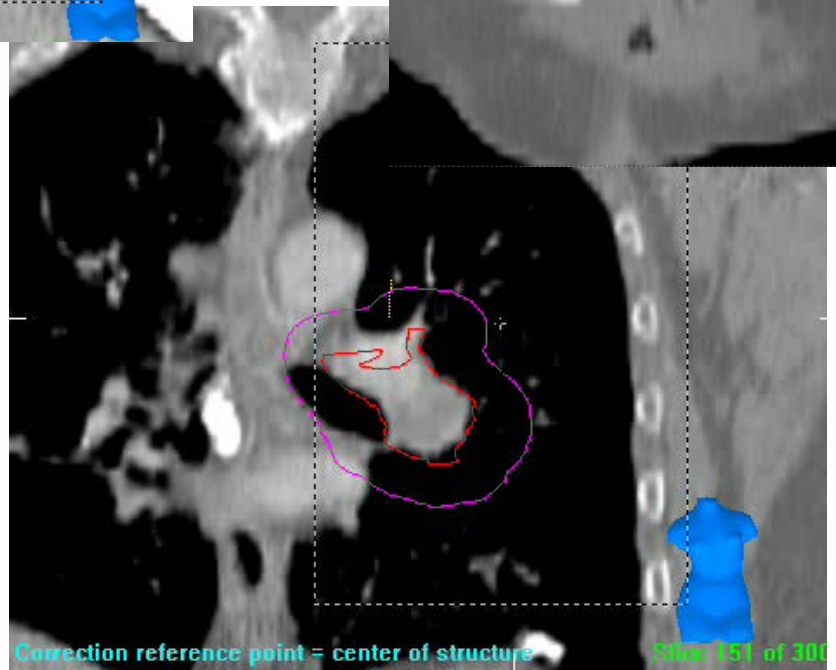

NETHERLANDS CANCER INSTITUTE
ANTONI VAN LEEUWENHOEK

The basics

The radiotherapy chain

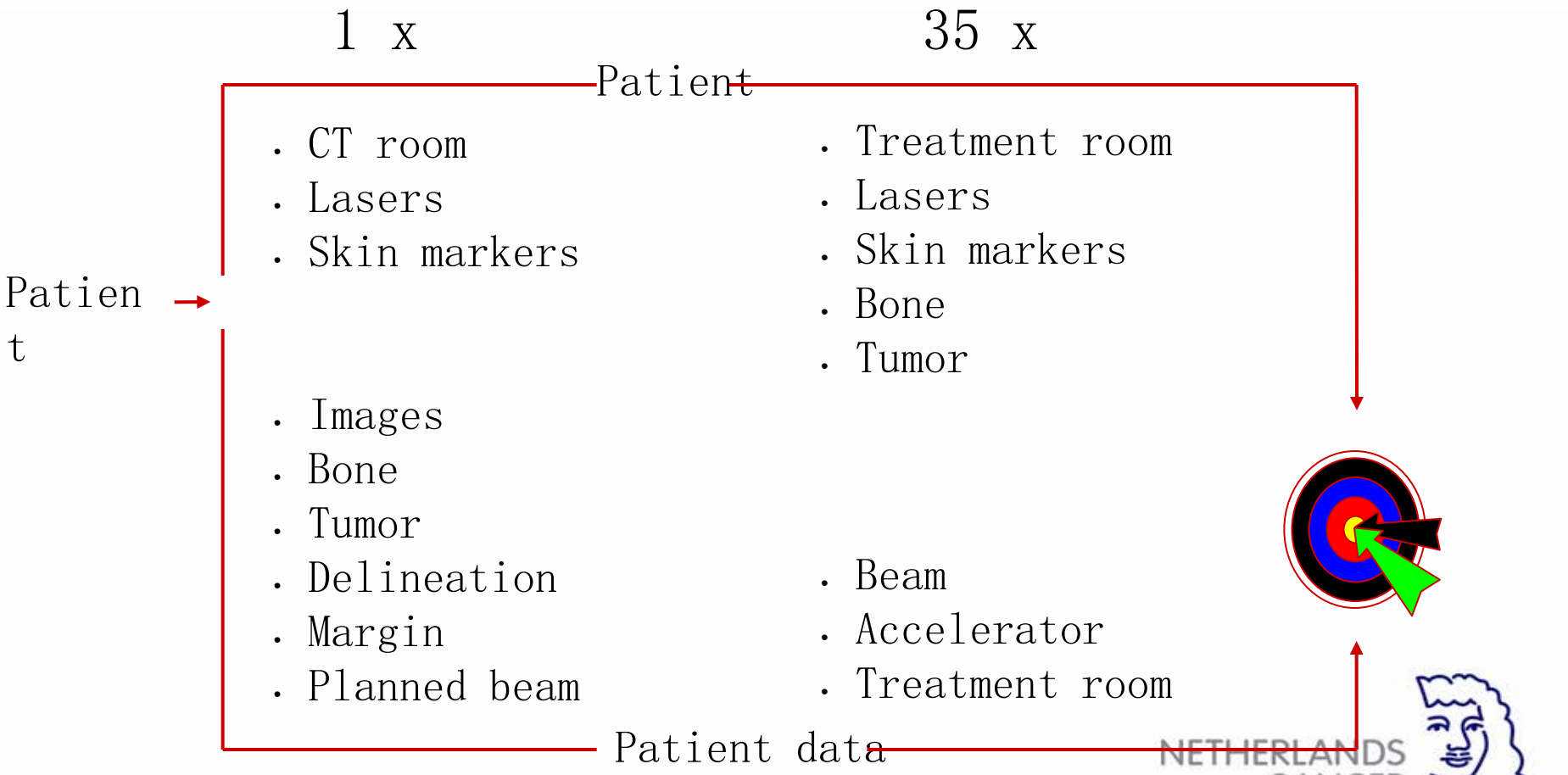

17 steps with a lot of room for errors

NETHERLANDS CANCER INSTITUTE
ANTONI VAN LEEUWENHOEK

Geometrical uncertainties

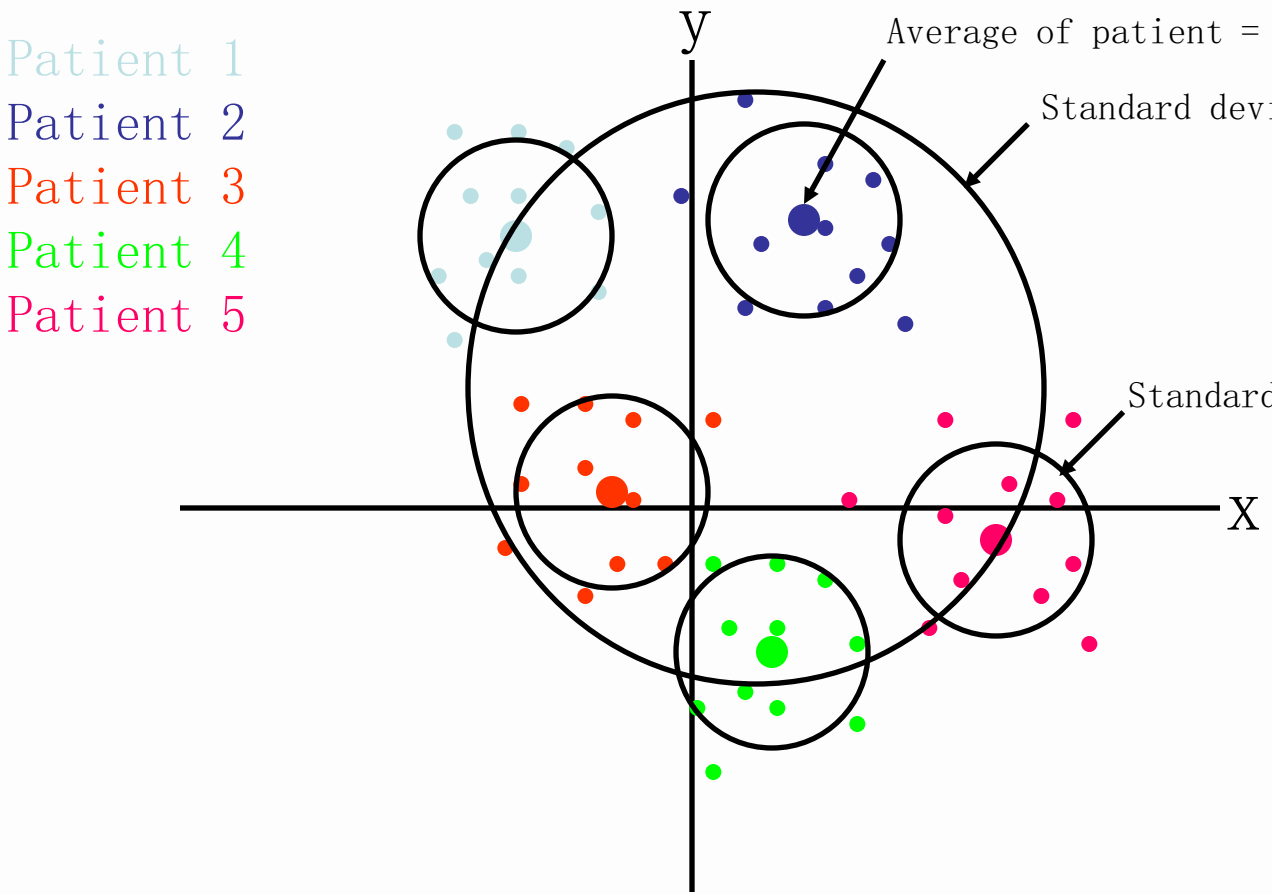

NETHERLANDS CANCER INSTITUTE
ANTONI VAN LEEUWENHOEK

Geometrical uncertainties

Patient 1
Patient 2
Patient 3
Patient 4
Patient 5

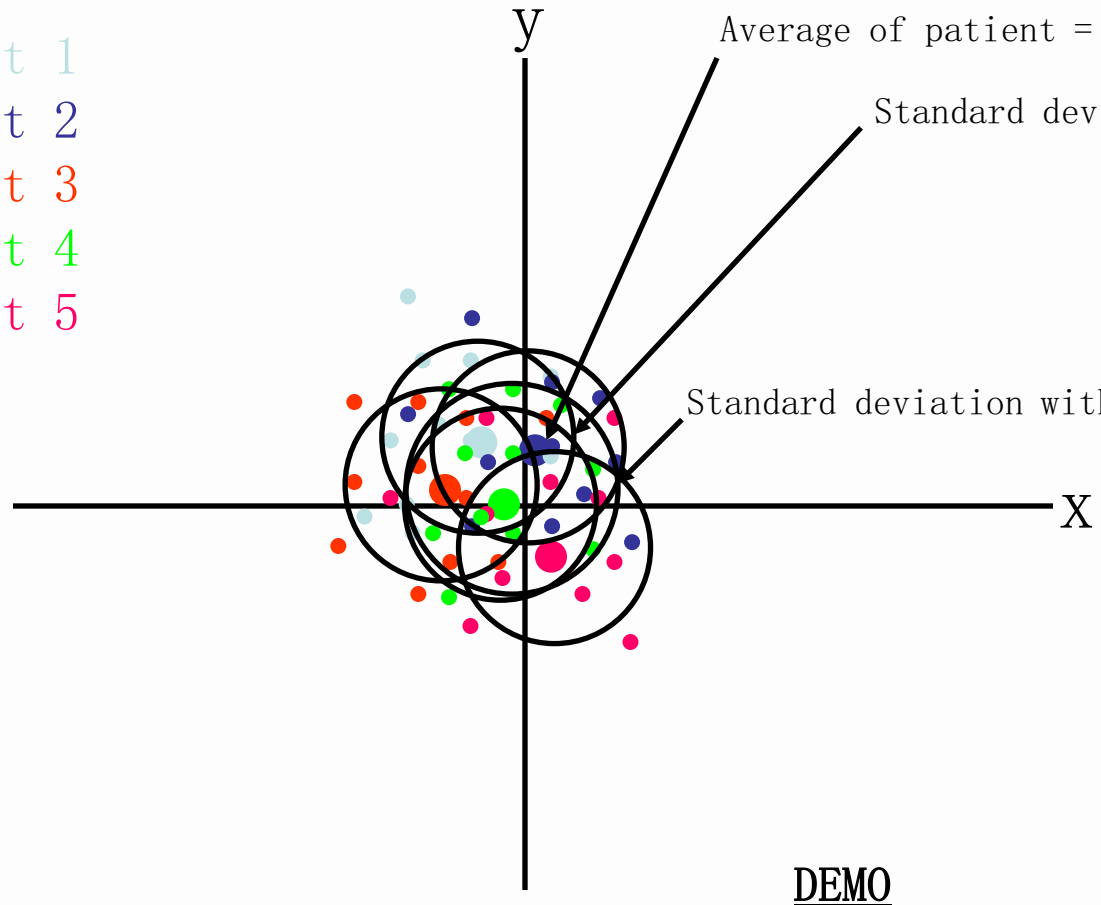

Average of patient = systematic error for that pat

Standard deviation of all averages = Σ

Standard deviation within a patient = σ_p

Average of all σ_p = σ

DEMO

NETHERLANDS CANCER INSTITUTE
ANTONI VAN LEEUWENHOEK

Effect of geometrical errors

Random errors (σ) **blur** the cumulative dose distribution

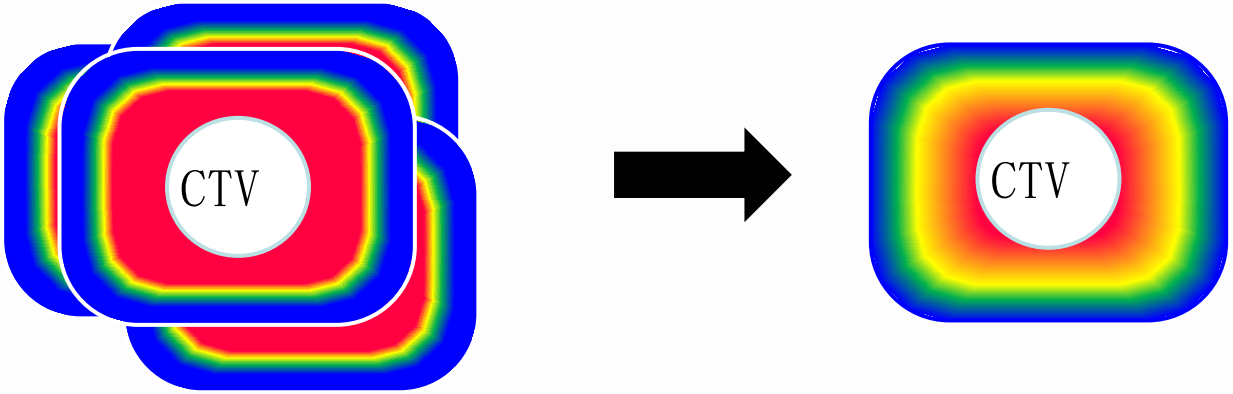

Single fraction doses with random shifts

All fraction doses added

Systematic errors (Σ) **shift** the cumulative dose distribution

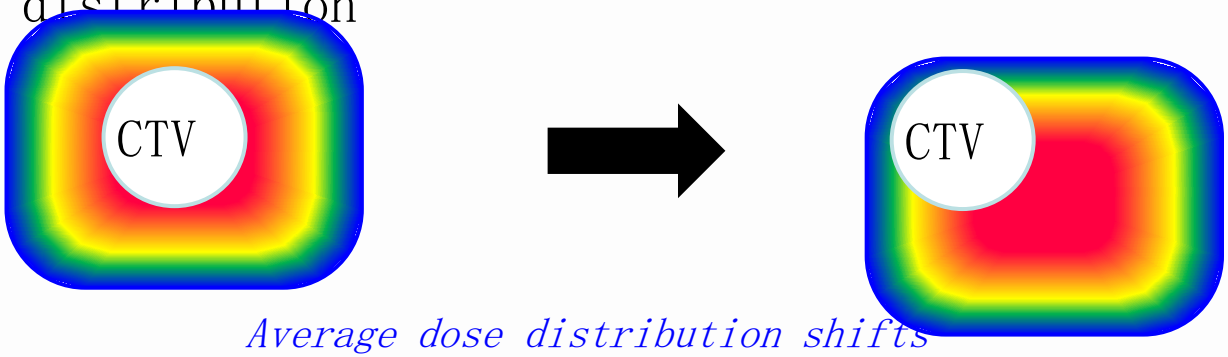

Average dose distribution shifts

NETHERLANDS CANCER INSTITUTE
ANTONI VAN LEEUWENHOEK

Geometrical uncertainties

- Systematic
  - Same for whole treatment
  - Shifts the dose distribution
  - May be different for each patient but the same for one patient
  - Quantified with standard deviation Σ
- Random
  - Different every day
  - Some patients may have larger variations from day to day than others
  - Blurs the dose distribution
  - Quantified with standard deviation σ

NETHERLANDS CANCER INSTITUTE
ANTONI VAN LEEUWENHOEK

Many varieties

- Translational errors
- Rotational errors
- Shape changes



But also different sources!

Source	Systematic	Random	Solution
Delineation example	1-?? mm	-	Multiple modalities
Setup	1-5 mm	1-5 mm	Portal imaging
Organ motion	<1-50 mm	<1-50mm	Markers Repeat CT

And all come as translations / rotations / deformations!

NETHERLANDS CANCER INSTITUTE
ANTONI VAN LEEUWENHOEK

Examples of geometrical uncertainties

Prostate

- Large amount of air in rectum during planning scan
- Not present during treatment

Bladder

- Bladder volume is larger in the CBCT scan than in the planning scan

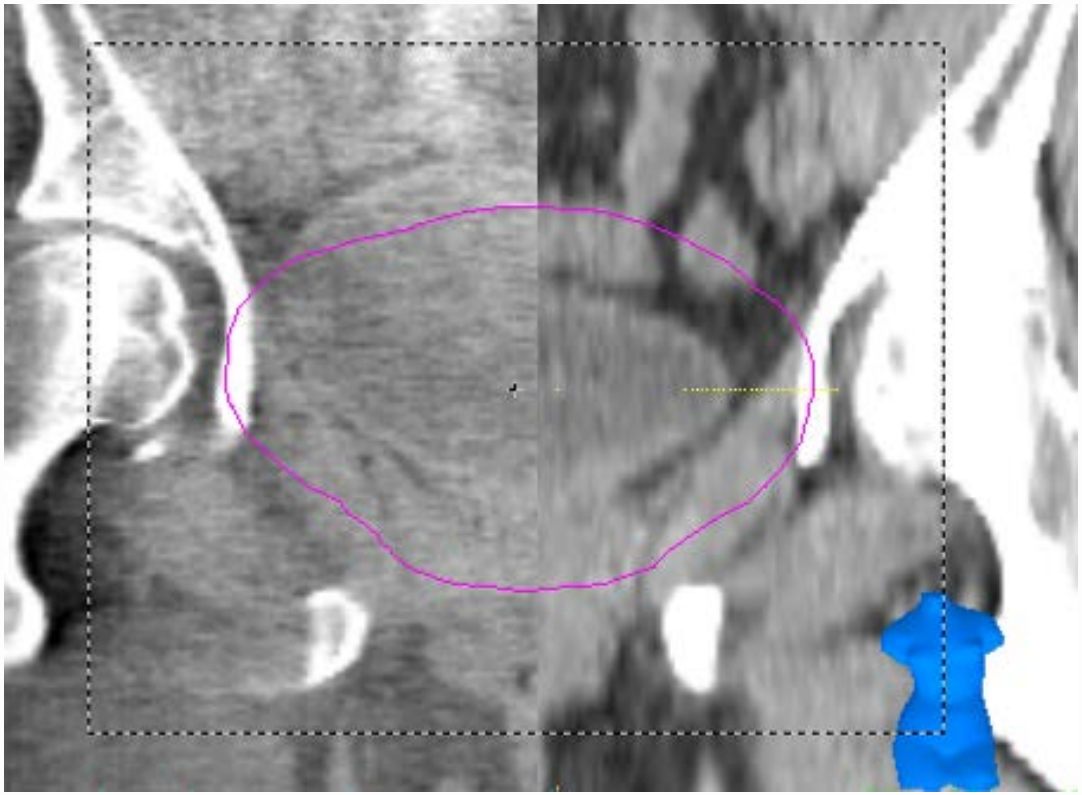

NETHERLANDS CANCER INSTITUTE
ANTONI VAN LEEUWENHOEK

So how do we determine these errors?

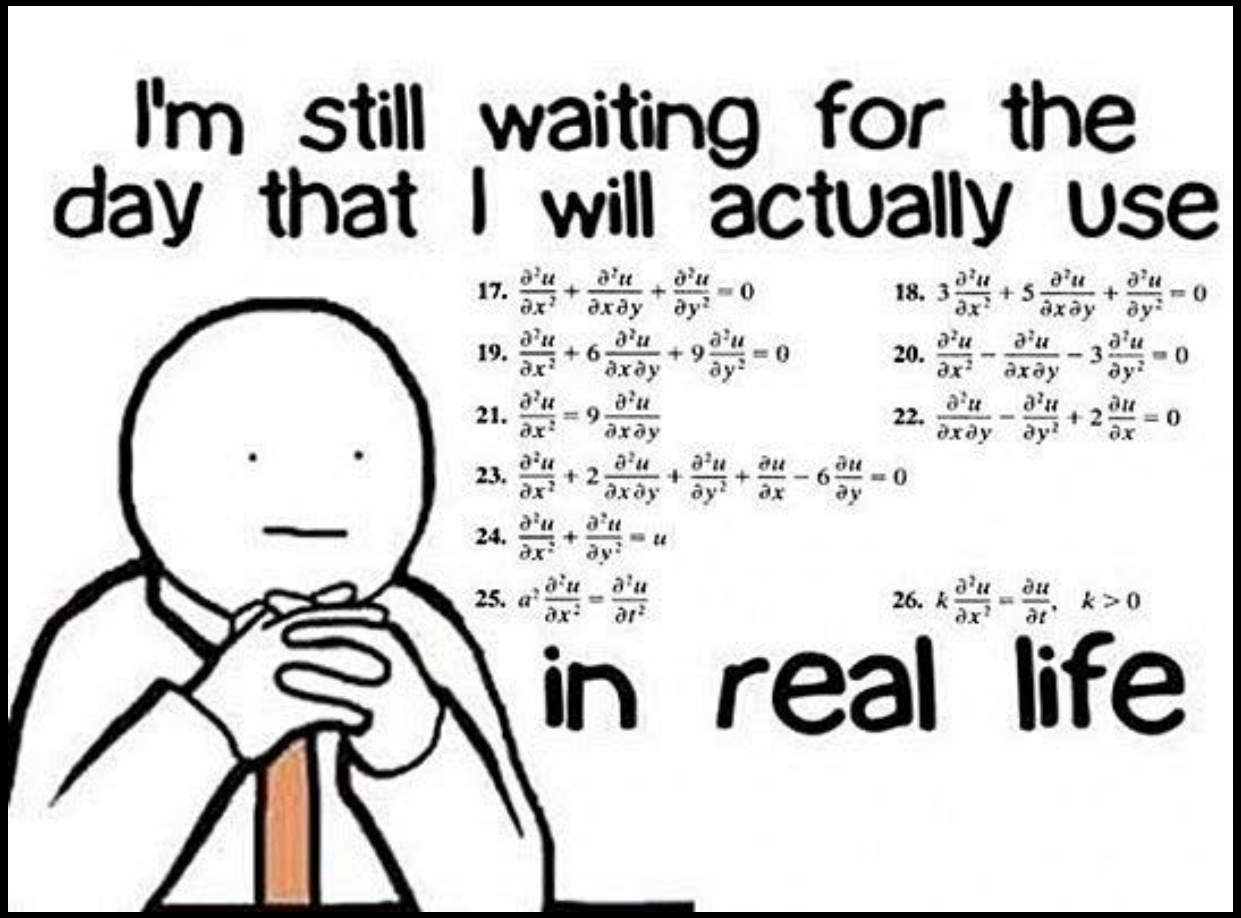

Determining the uncertainties

- Imaging!

HERLANDS
CANCER
INSTITUTE
ANTONI VAN LEEUWENHOEK

Determining the uncertainties

- We can image the patient from fraction to fraction and analyze the geometrical changes

- Image tumor

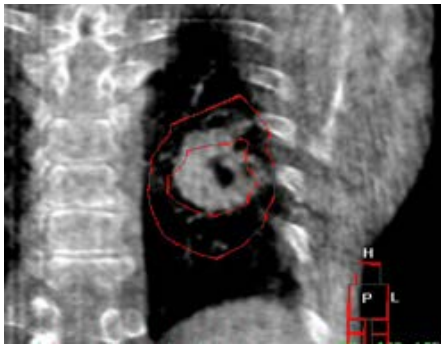

- Use surrogates
  - Fiducials

  - Bony anatomy (margin for organ motion!)



Determining the uncertainties

- Register bony anatomy → Setup error
- Register tumor position → Organ motion
- Analyse re-delineation → Delineation variability

NETHERLANDS CANCER INSTITUTE
ANTONI VAN LEEUWENHOEK

Margins

How do we determine the margin?

- Effect of random and systematic errors on the dose distribution is different

→ We need a separate approach!

NETHERLANDS CANCER INSTITUTE
ANTONI VAN LEEUWENHOEK

Effect of geometrical errors

Random errors (σ) **blur** the cumulative dose distribution

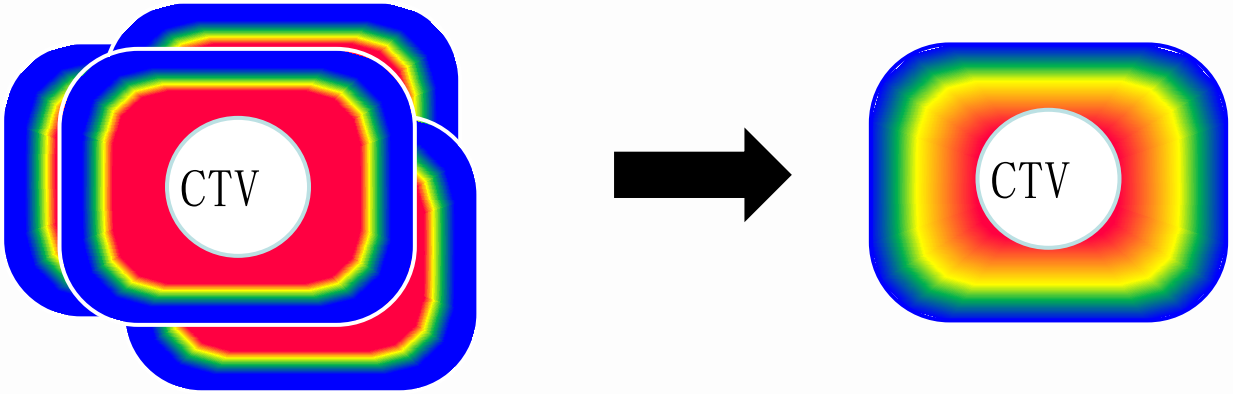

Single fraction doses with random shifts

All fraction doses added

Systematic errors (Σ) **shift** the cumulative dose distribution

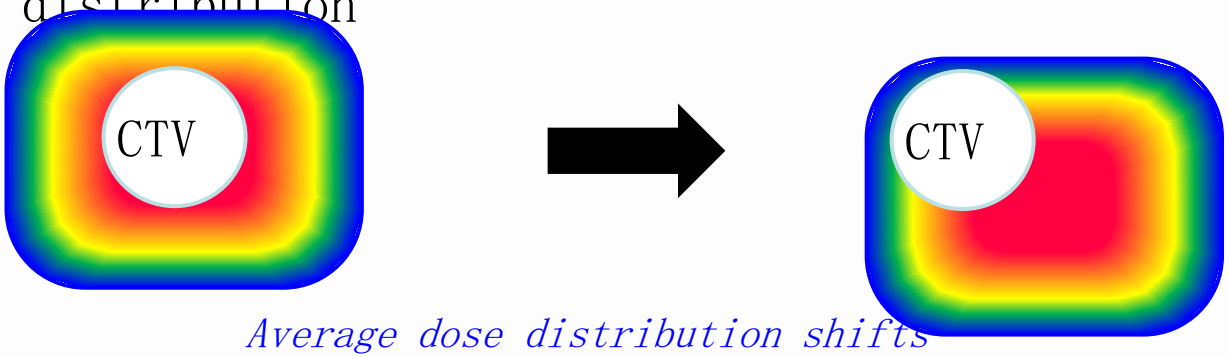

Average dose distribution shifts

NETHERLANDS CANCER INSTITUTE
ANTONI VAN LEEUWENHOEK

Margins for random errors

- Random errors blur the dose distribution
  - Translations : Convolution dose with error distribution
  - Rotations : Convolution dose with error distribution (Bel)

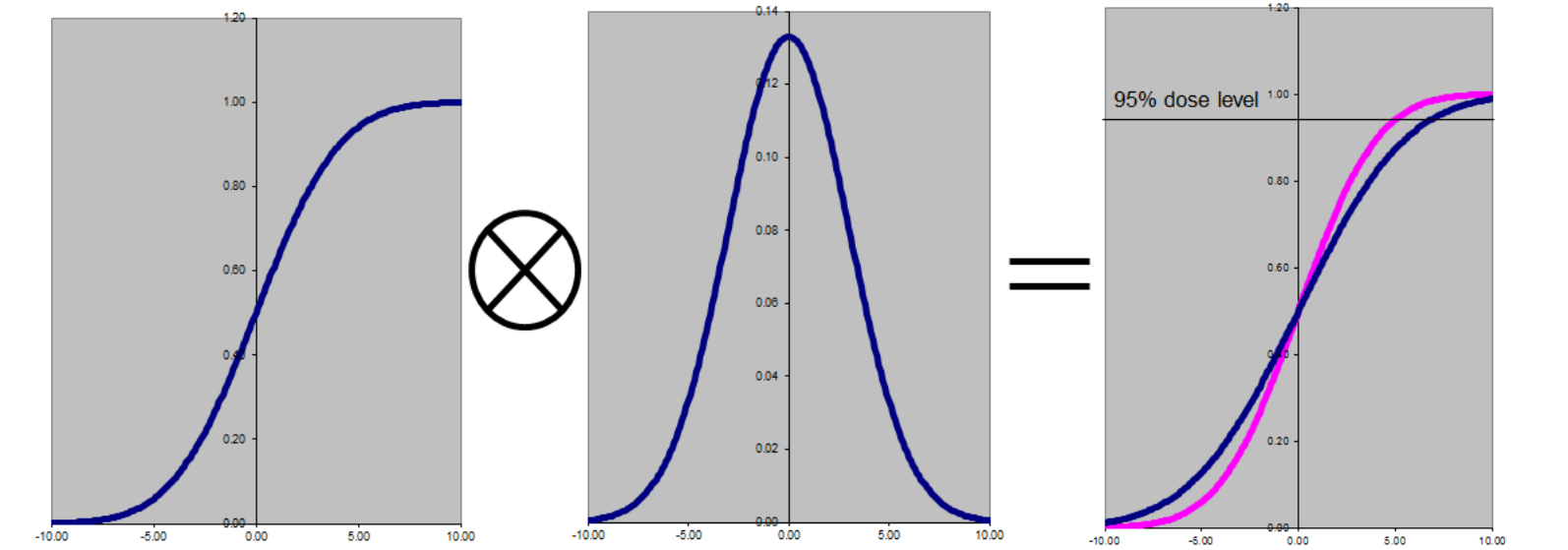

Margins for random errors

- Margin for random errors:

→Difference at 95 % dose level (i.e. the dose level of interest) before/after convolution

- Example

NETHERLANDS CANCER INSTITUTE
ANTONI VAN LEEUWENHOEK

Margins for random errors

Dose level	PTV margin	PTV margin* (ψ = 3.2 mm)
80%	$0.84\sqrt{(\sigma^2+\psi^2)} - 0.84\,\psi$	$0.4\,\sigma$
85%	$1.03\sqrt{(\sigma^2+\psi^2)} - 1.03\,\psi$	$0.5\,\sigma$
90%	$1.28\sqrt{(\sigma^2+\psi^2)} - 1.28\,\psi$	$0.6\,\sigma$
95%	$1.64\sqrt{(\sigma^2+\psi^2)} - 1.64\,\psi$	$0.7\,\sigma$

σ = SD of random errors,

ψ = σ of Gaussian penumbra

NETHERLANDS CANCER INSTITUTE
ANTONI VAN LEEUWENHOEK

*linear approximation

Margins for systematic errors

- Systematic errors shift the dose distribution
  - But we don't know in advance in which direction!

NETHERLANDS CANCER INSTITUTE
ANTONI VAN LEEUWENHOEK

Margins for systematic errors

- Systematic errors shift the dose distribution
  - But we can say something about the “target area’ if we know the distribution of the errors, i.e. the standard deviation

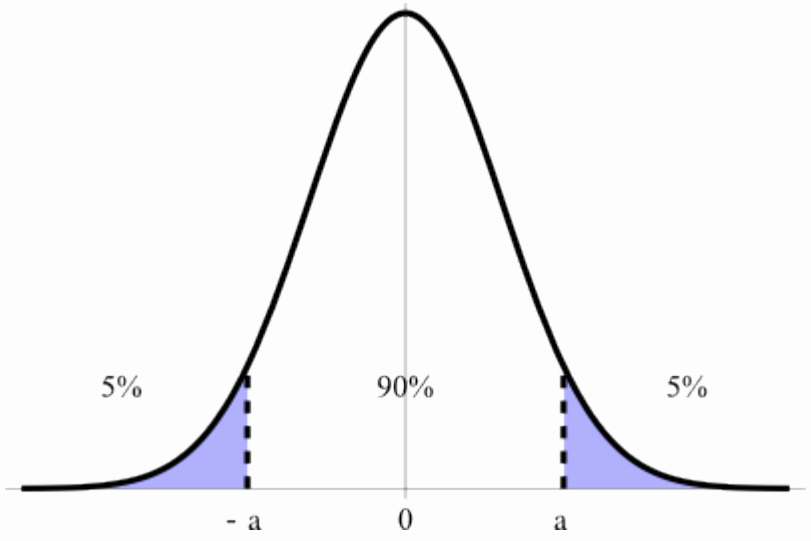

NETHERLANDS CANCER INSTITUTE
ANTONI VAN LEEUWENHOEK

PTV for systematic translations

- 90 % Confidence interval
  - 1-D : ±1.64 Σ
  - 2-D : Ellipse with radii 2.15 $\Sigma_{x,y}$
  - 3-D : Ellipsoid with radii 2.50 $\Sigma_{x,y,z}$

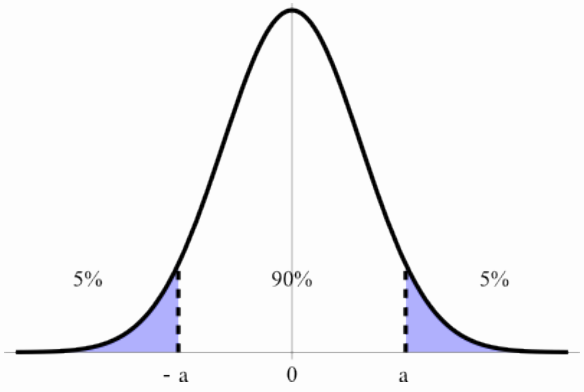

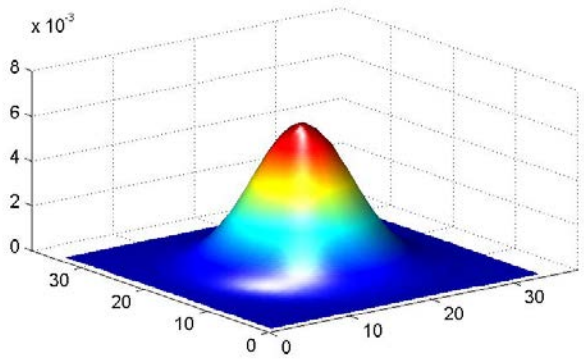

Margins for systematic translations

- Select point in (square shaped) CTV
- Determine CI = Ellipse with radii $\alpha\Sigma_{x,y}$ mm *
- Determine envelope of all CTVs in CI

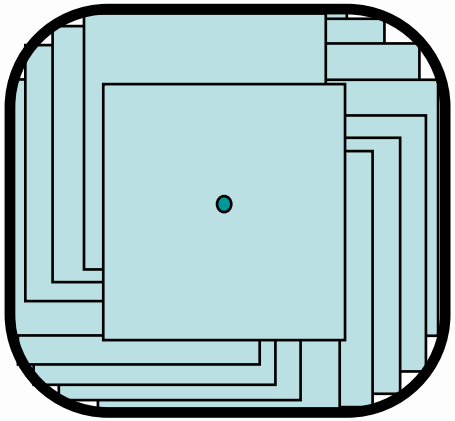

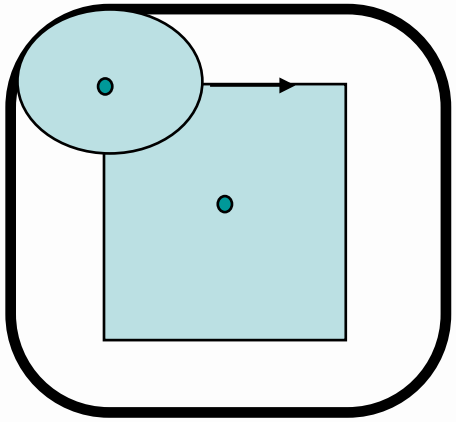

NETHERLANDS CANCER INSTITUTE
ANTONI VAN LEEUWENHOEK

*90% 2D CI: α=2.15

Margin for systematic errors

Confidence level	1-D errors	2-D errors	3-D errors
80%	1.28 Σ	1.79 Σ	2.16 Σ
85%	1.44 Σ	1.95 Σ	2.31 Σ
90%	1.64 Σ	2.15 Σ	2.50 Σ
95%	1.96 Σ	2.45 Σ	2.79 Σ

Σ = SD of preparation/systematic errors

NETHERLANDS CANCER INSTITUTE
ANTONI VAN LEEUWENHOEK

Margin recipe

- To cover 90% of the patients with the 95% isodose level:

Margin = 2.5 * Σ + 0.7 * σ

Where

$$\Sigma = \sqrt{\Sigma_{organmotion}^2 + \Sigma_{setup}^2 + \Sigma_{delineation}^2}$$

$$\sigma = \sqrt{\sigma_{organmotion}^2 + \sigma_{setup}^2}$$

NETHERLANDS CANCER INSTITUTE
ANTONI VAN LEEUWENHOEK

Keeping things in perspective

- Margin recipe assumptions
  - Perfectly conformal dose distribution
  - Large and smooth (compared to penumbra size) CTV
  - Translational errors only
  - Homogeneous dose distribution
  - Large number of fractions (for the 0.7 part)



- Real life
  - Not conformal, i.e. margin will depend on shape of dose distribution
  - Not smooth
  - Lots of changes → translations, rotations, shape changes…
  - Inhomogeneous dose distributions
  - Any number of fractions (or very few!)

NETHERLANDS CANCER INSTITUTE
ANTONI VAN LEEUWENHOEK

GTV versus CTV underdosage

GTV: Whole volume tumor

CTV: Probability of tumor

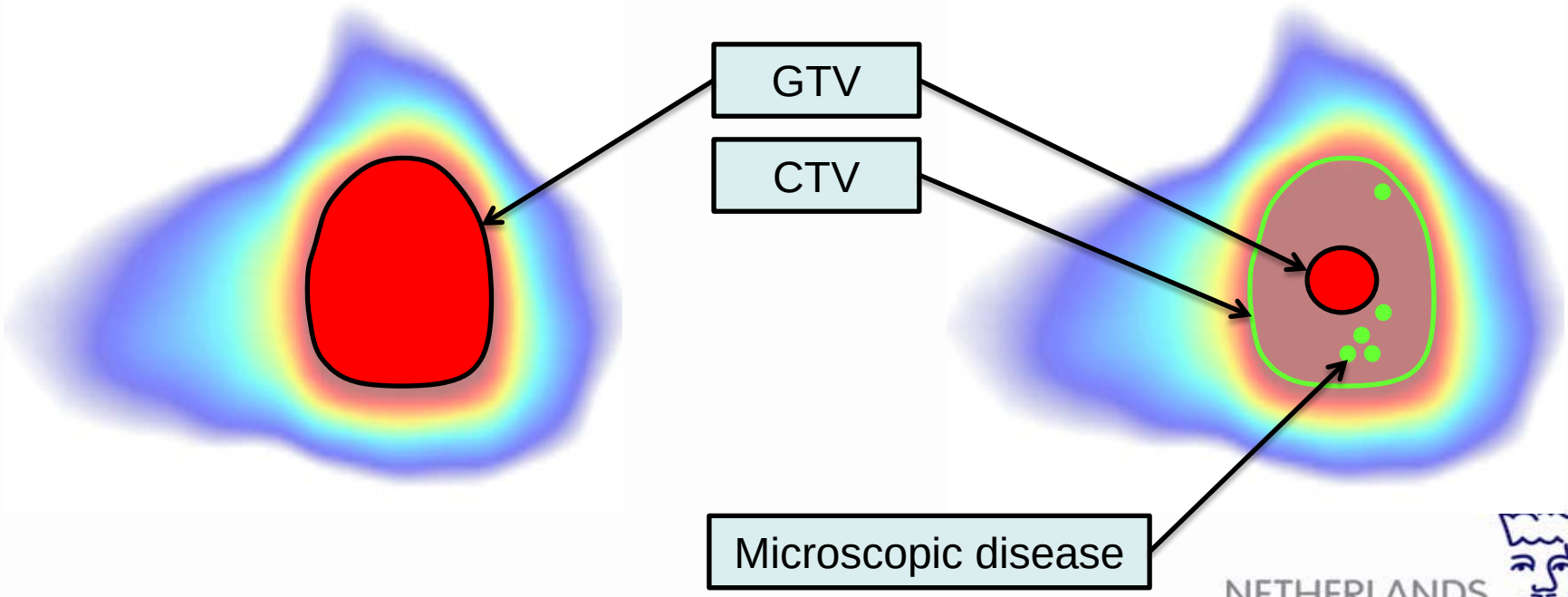

NETHERLANDS CANCER INSTITUTE
ANTONI VAN LEEUWENHOEK

GTV versus CTV underdosage

Underdosage of GTV will always lead to underdosage of tumor cells

Underdosage of CTV will **not** always lead to underdosage of tumor cells

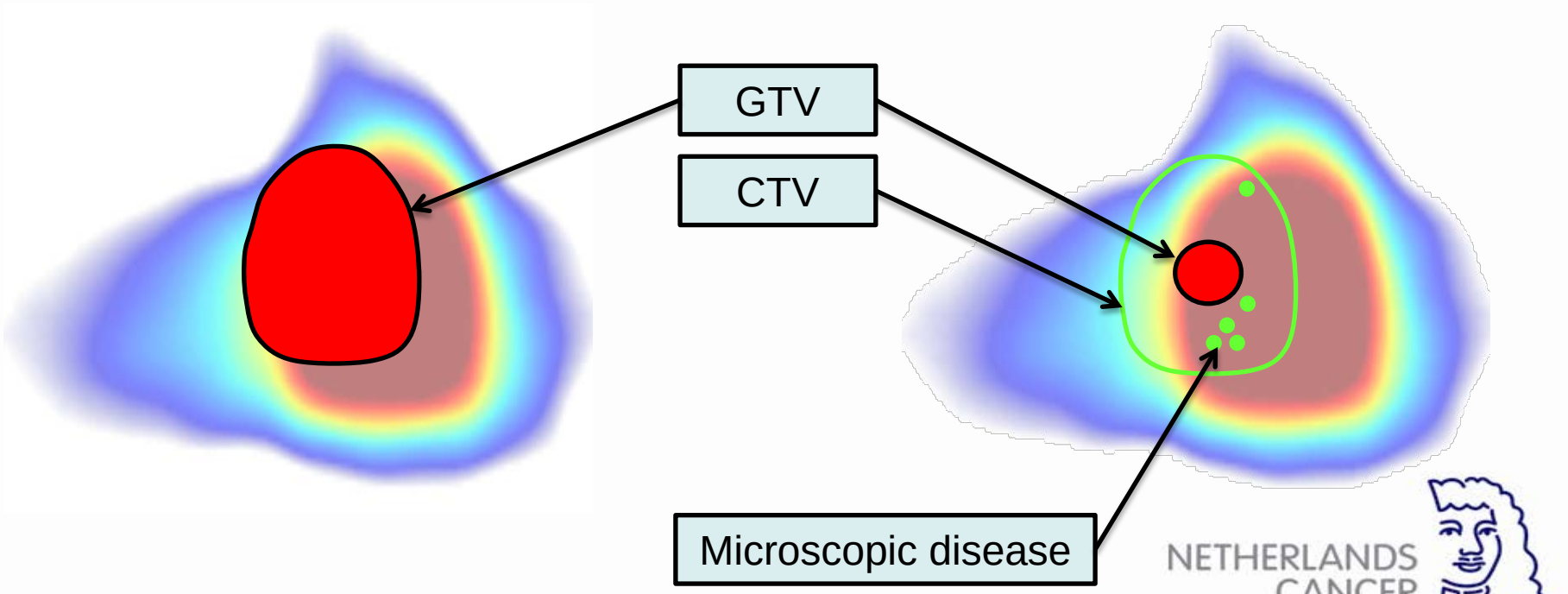

NETHERLANDS CANCER INSTITUTE
ANTONI VAN LEEUWENHOEK

Keeping things in perspective

- GTV → PTV margin
  - All cells in the GTV are considered to be tumor
  - $P_{underdosage} = P_{geometrical\ miss}$
  - Use margin prescription

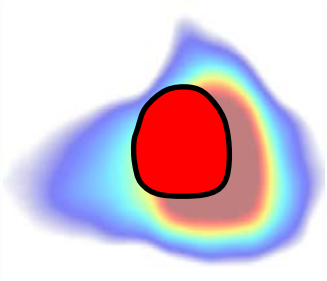

- CTV → PTV margin
  - In the CTV there is a probability of tumor cells
  - $P_{underdosage} = P_{geometrical\ miss} \times P_{presence\ of\ tumor\ cells}$
  - Margin can probably be smaller

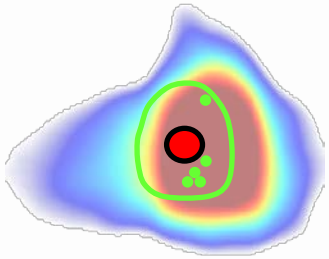

- Caveat: Tumor cell probability is needed

NETHERLANDS CANCER INSTITUTE
ANTONI VAN LEEUWENHOEK

Conclusions

- Systematic errors have different dose effects than random errors
- A margin is always necessary. Without the proper margin underdosage will occur
- To determine margins it is important to now the statistics of the geometrical errors
- Since delineation uncertainties are systematic, they will have a large effect on the required margin

NETHERLANDS CANCER INSTITUTE
ANTONI VAN LEEUWENHOEK

Delineation variation

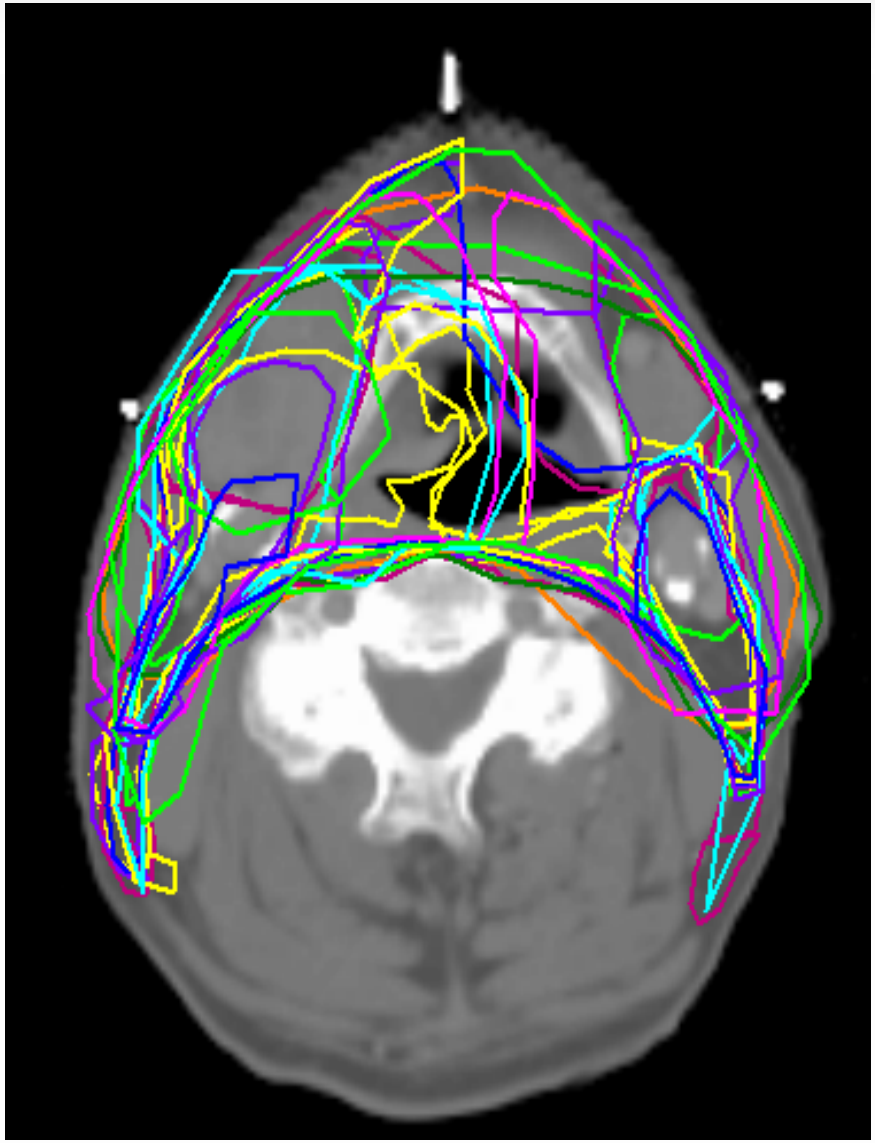

NETHERLANDS CANCER INSTITUTE
ANTONI VAN LEEUWENHOEK

back

ESTRO School

WWW.ESTRO.ORG/SCHOOL

Image registration

in Radiation Oncoloy

Martina Kunze-Busch
Radboud University Medical Center Nijmegen
The Netherlands

Radboudumc

ESTRO School

Overview

Image registration

- Definition
- A closer look at the different components/steps
  - geometrical transformation
  - similarity measure
  - optimization algorithm
- Image registration in the RT chain
  - treatment preparation
  - treatment delivery

problems/challenges

- Quantification of organ motion
- Registration accuracy

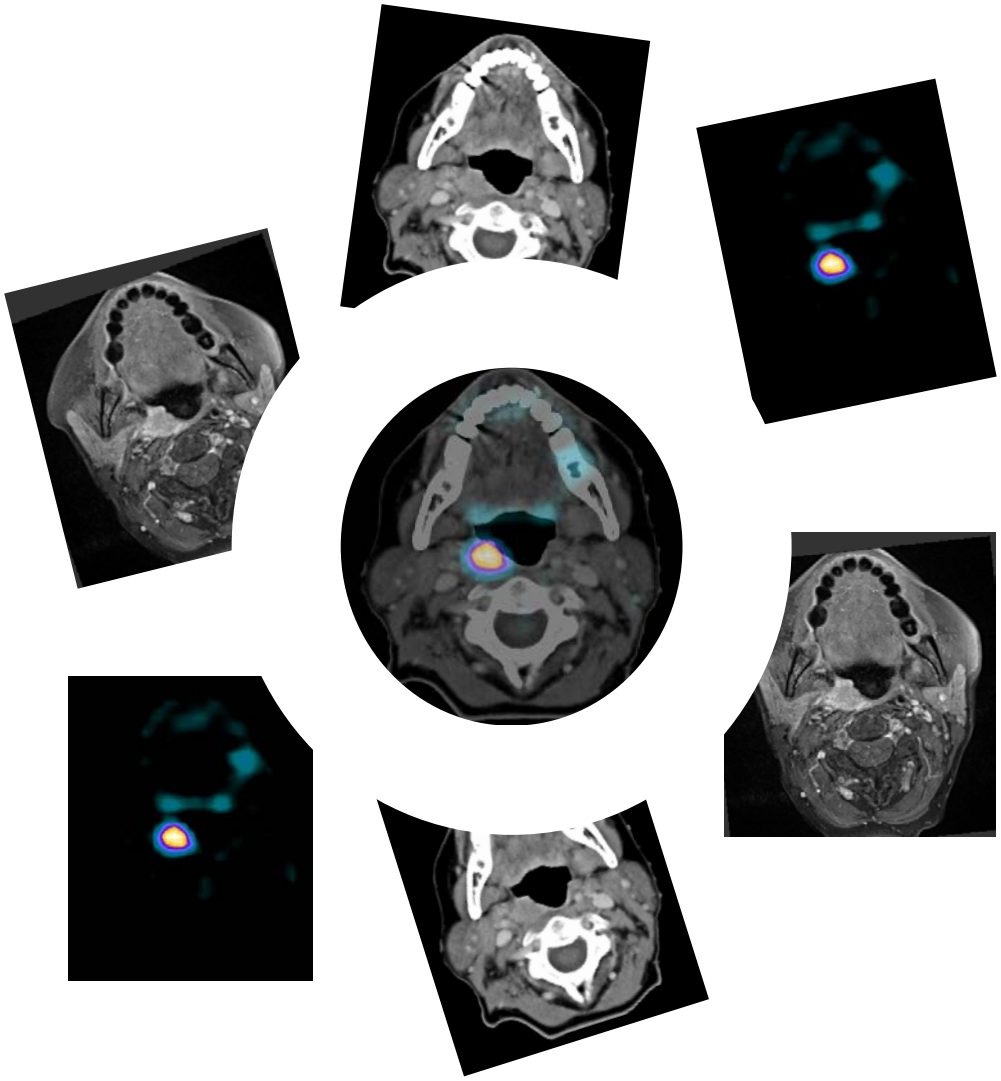

Image fusion?
Just click here

Radboudumc

ESTRO School

Image registration ↔ image fusion

Image registration

spatial alignment/
geometrical transformation T of image

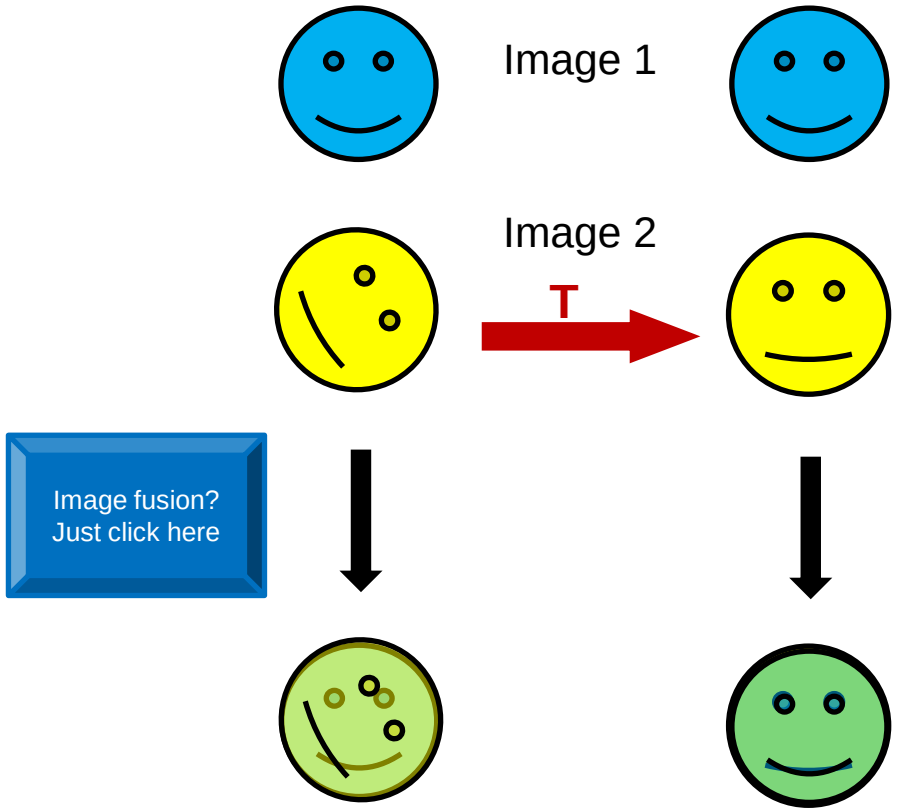

Image fusion

integrated display of data

goal of image registration = find geometric **transformation** that **best** aligns two images

Image registration

The three core components of image registration:

1. Spatial/geometrical transformation T
2. Similarity measure/cost function
3. Optimization algorithm

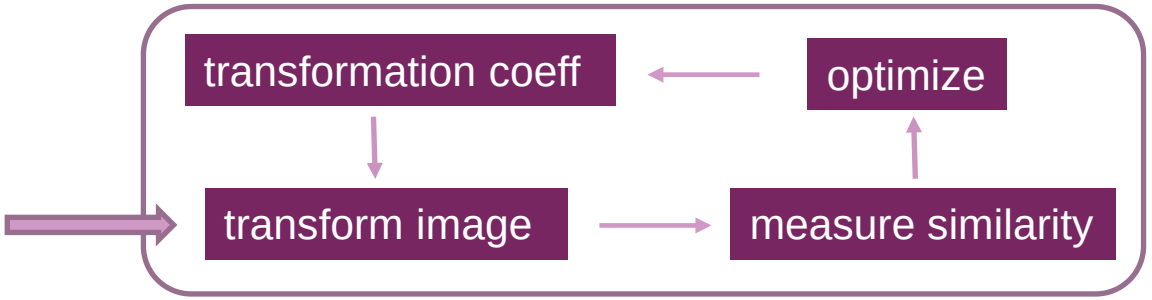

1. Geometrical transformation T

Image 1

- **Rigid**
  - no deformation
  - only translations and rotations are allowed

  (3 rotations, 3 translations → (max) 6 independent parameters)



- **Affine**
  - shearing, stretching

  (3 rotations, 3 translations, 3 stretches, 3 shears → (max) 12 parameters)

1. Geometrical transformation T

- **Deformable /non-rigid**
  - e.g. elastic
    (milions of parameters!)

Image 1

1. Geometrical transformation T

Example: deformable registration of diagnostic PET and CT

deformable

rigid

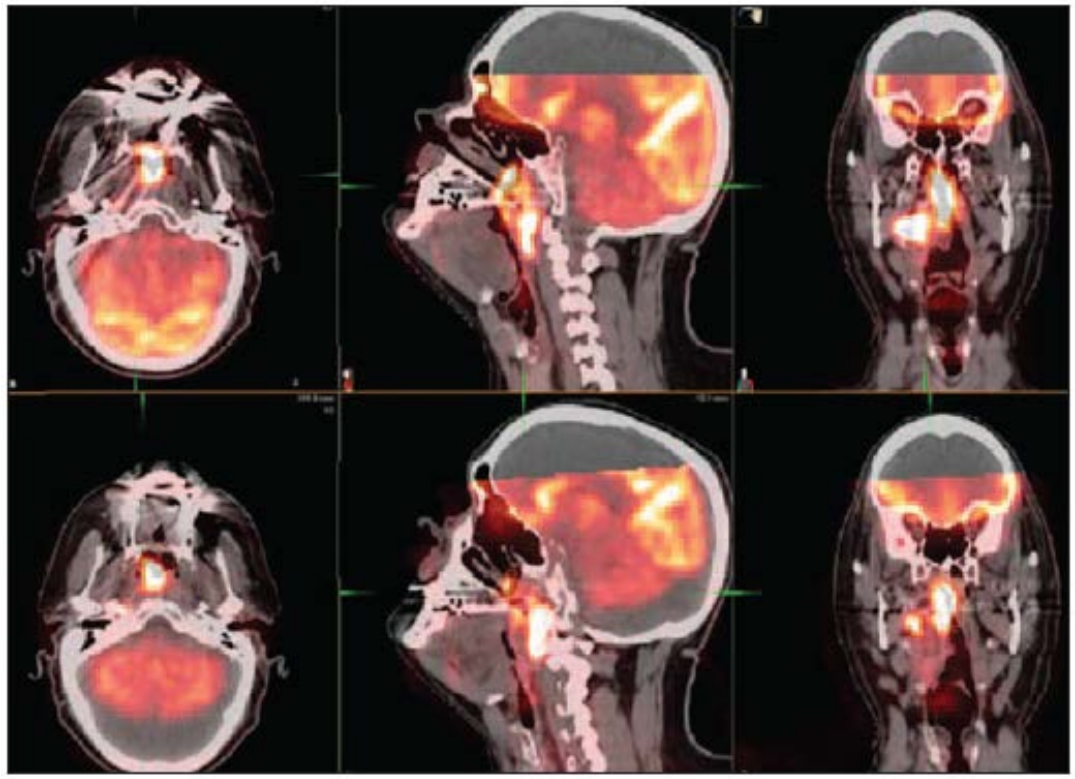

Schoenfeld et al, AJR 2012

1. Geometrical transformation T

- **Deformable /non-rigid**
  - e.g. elastic
    (**milions** of parameters!)

average errors can be in the range of 1 – 5 mm

Validation !

2. Similarity measure

Similarity measure quantifies degree of similarity between 2 images

Different methods exist:

- FEATURE – based
- INTENSITY – based (grey values)
- MODEL – based

2. Similarity measure

Feature-based method

- extract feature from images & evaluate distance between features
- employed when local accuracy is important
- dependent on accuracy of feature extraction

2 types:

Landmark-based method



Segmentation-based method



2. Similarity measure

Intensity-based method (grey values)



- all pixels in overlapping regions are utilized
- does not require detection of geometric features
- time consuming

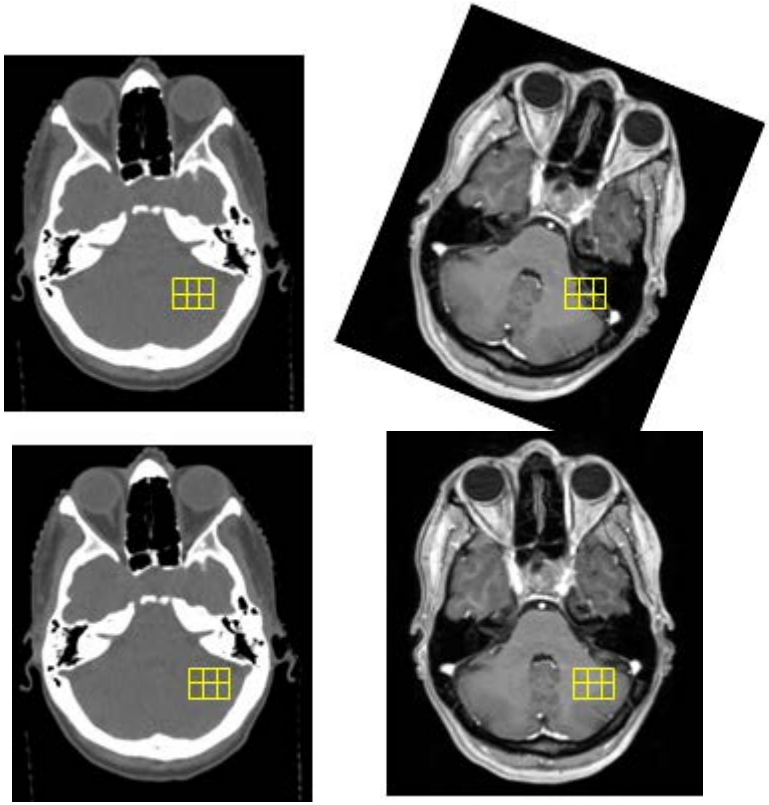

e.g. *mutual information*

Radboudumc

ESTRO School

2. Similarity measure

Model-based method

e.g. deformable transformation model for contours

similarity measure + regularization/penalty term (tissue characteristics)



2. Similarity measure/COST FUNTION

description of problem in **mathematical terms**

value of cost function reflects quality of registration: smallest value = best solution

Example:

find <u>shortest</u> way to Rome → cost function = Σ path lengths

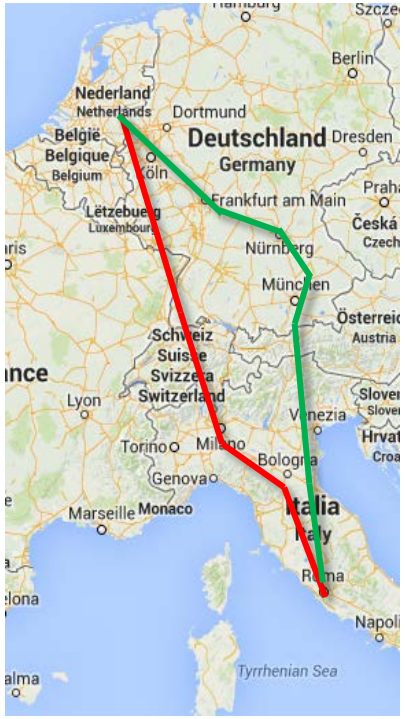

answer: red

find <u>fastest</u> way to Rome → extra parameter: speed limit

answer: green

Radboudumc

ESTRO School

3. Optimizer/optimization algorithm

optimizer finds smallest value of cost function (= “optimal” transformation)

example: gradient descent

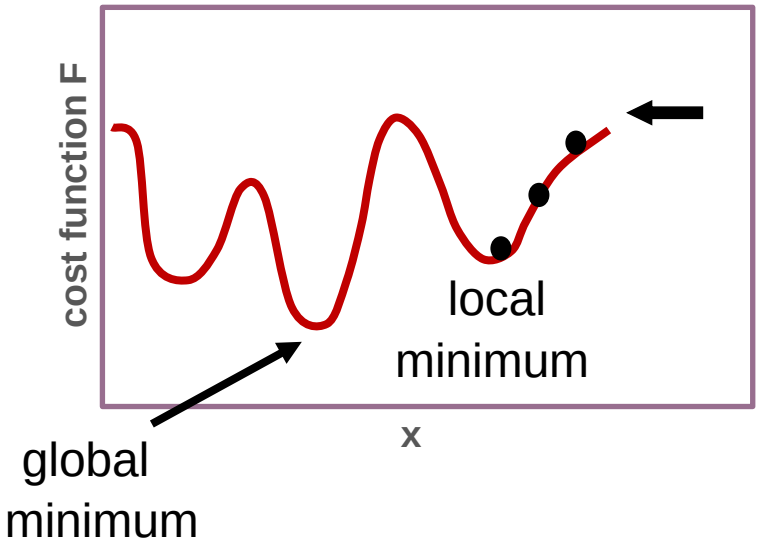

simplified

Image registration in the RT chain

Initial diagnosis and staging	Preparation/planning (delineation)	Delivery (position verification)	Adaptive RT

Quantification of organ motion/ organ motion analysis

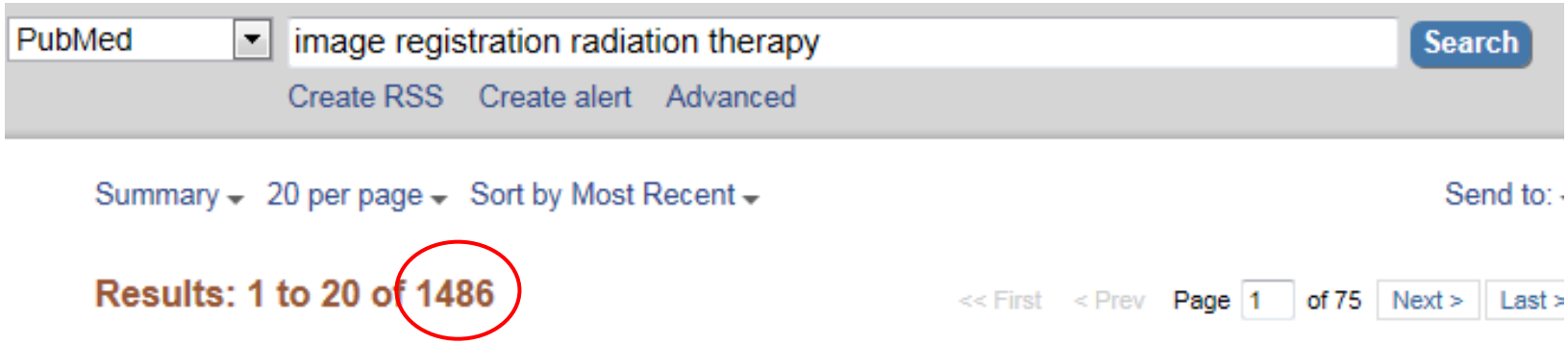

Radboudumc

ESTRO School

Image registration in the RT chain

Initial diagnosis and staging	Preparation/planning (delineation)	Delivery (position verification)	Adaptive RT

Quantification of organ motion/ organ motion analysis

Treatment preparation

planning CT – diagnostic MRI

MIRADA medical

registration

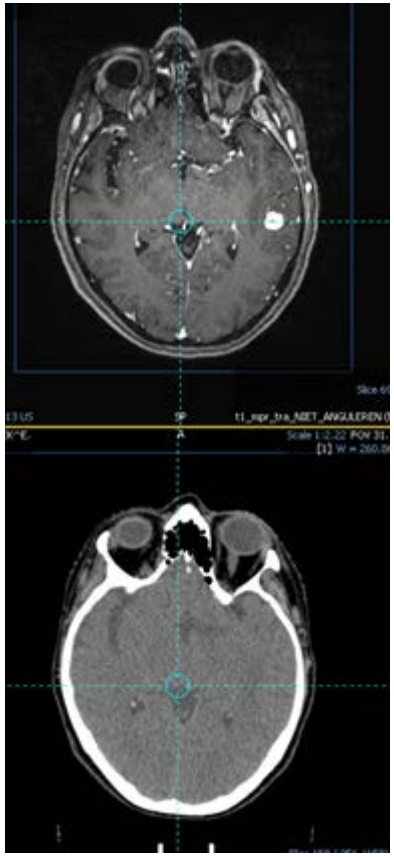

visual check

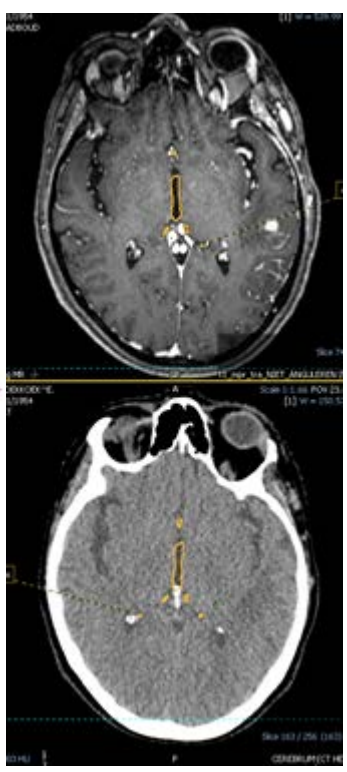

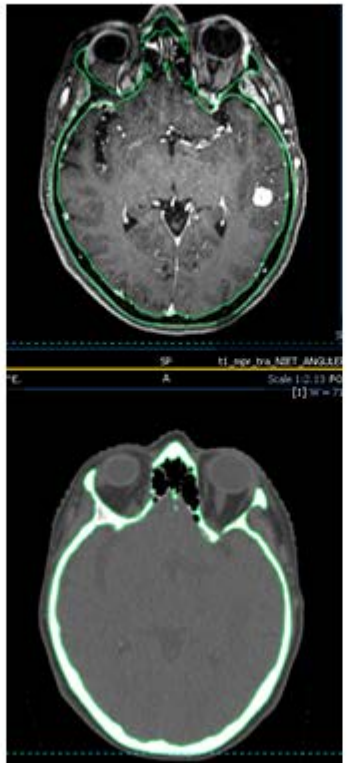

delineation

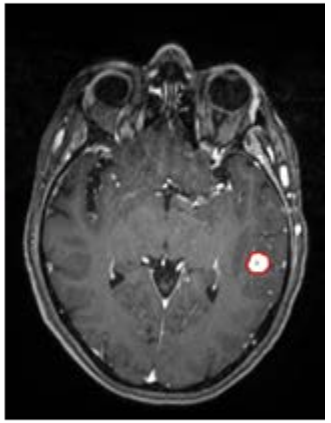

Radboudumc

ESTRO School

Treatment preparation

problems/challenges

- scan artefacts (MRI: geometrical distortions....)
- patient movement / organ motion during scan
  (also possible in hybrid systems)
- different scanning positions in different imaging modalities
- no use of fixation mask in MRI / PET
- different table tops
- .....

Treatment preparation

different scanning position

no fixation mask on MRI $\rightarrow$ different flexion of neck

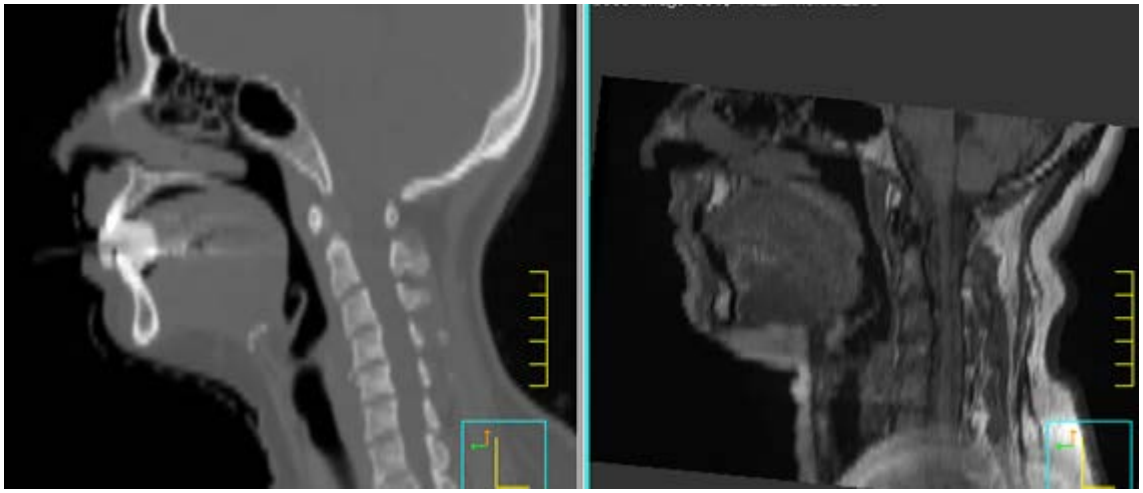

Treatment preparation

motion

Hybrid PET/CT

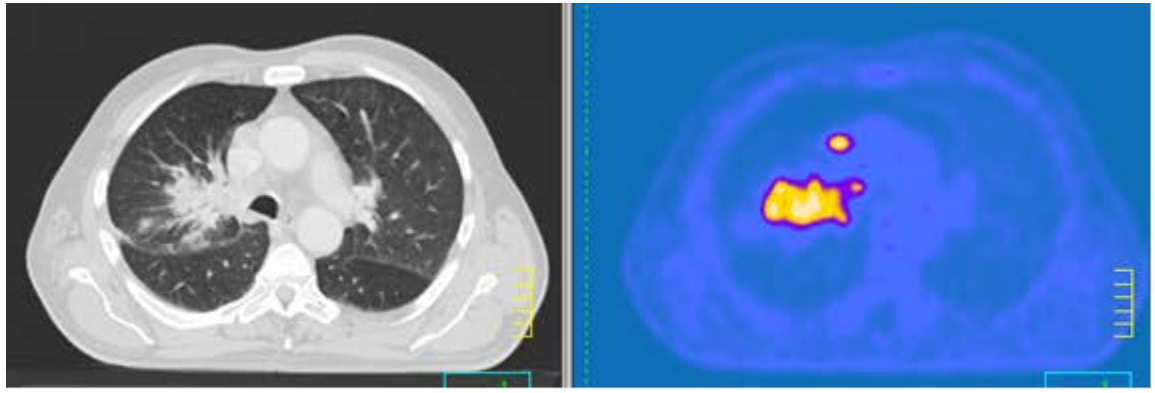

fusion

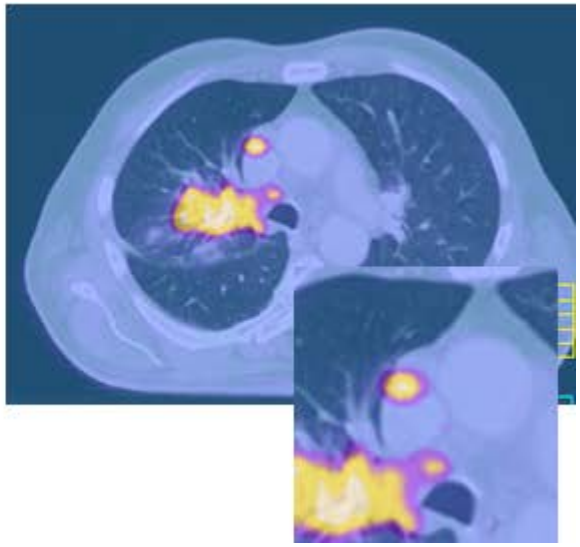

Treatment preparation

scans at different points in time

planning CT

pre-operative diagnostic CT

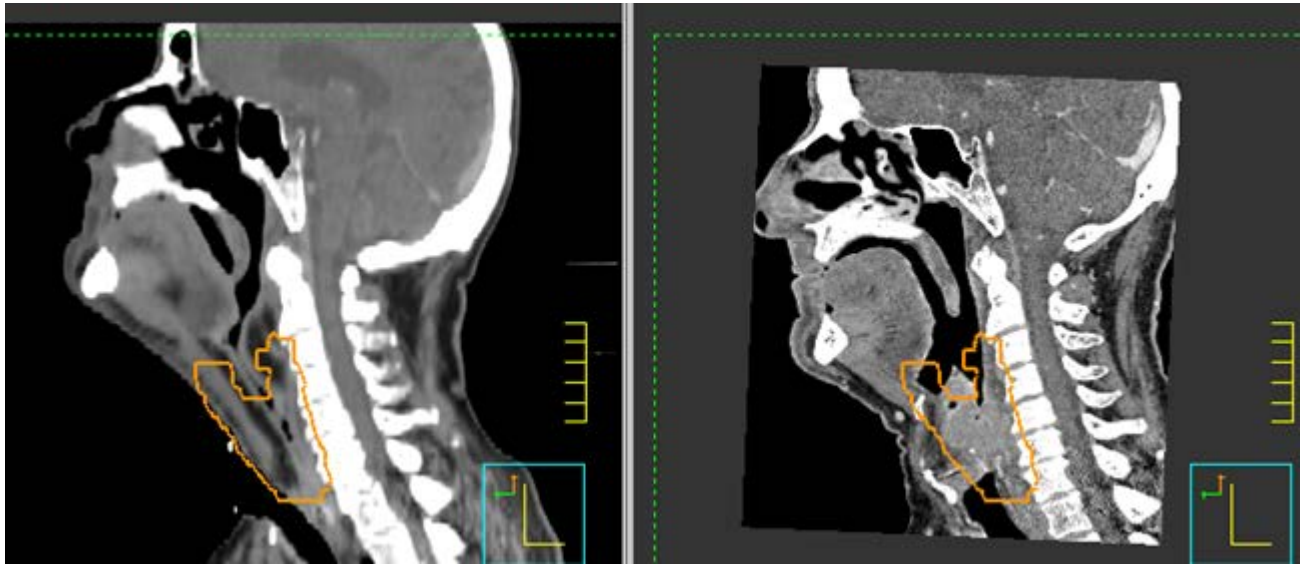

Radboudumc

ESTRO School

Image registration in the RT chain

Initial diagnosis and staging	Preparation/Planning (delineation)	Delivery (position verification)	Adaptive RT

Quantification of organ motion/ organ motion analysis

Treatment delivery

Image guided RT with Cone Beam CT

alignment of in-room CBCT images
with planning CT images

→ position verification of patient (online/offline protocols)
→ localization of tumor at time of treatment
→ assessment of change in anatomy (tumor size/weight loss or gain)

Image guided Adaptive Radiotherapy (ART)

Treatment delivery

CT – CBCT: Bone registration

Planning CT

CBCT

unregistered

Radboudumc

ESTRO School

Treatment delivery

CT – CBCT: Bone registration

Radboudumc

ESTRO School

Treatment delivery

CT – CBCT

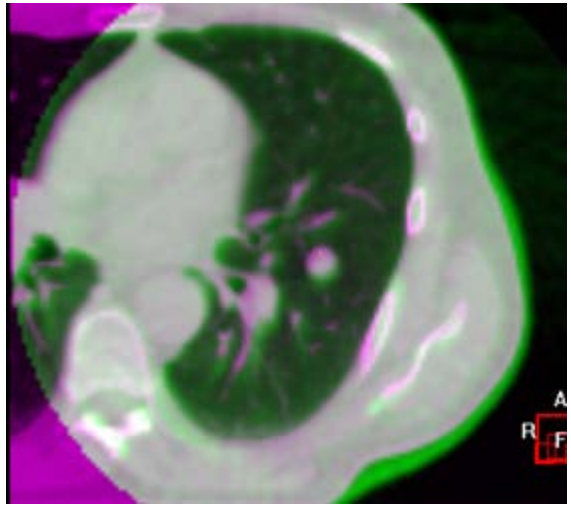

unregistered

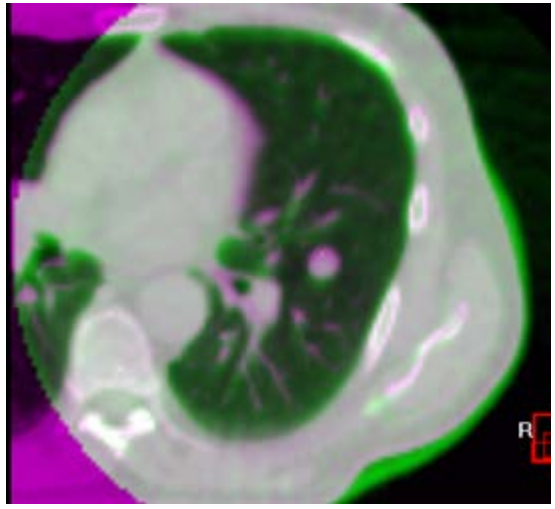

bone registration

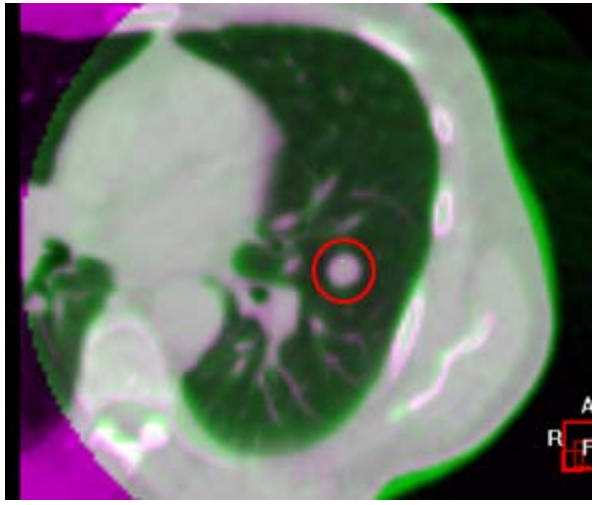

grey value registration

Radboudumc

ESTRO School

Treatment delivery

HI-ART Tomotherapy

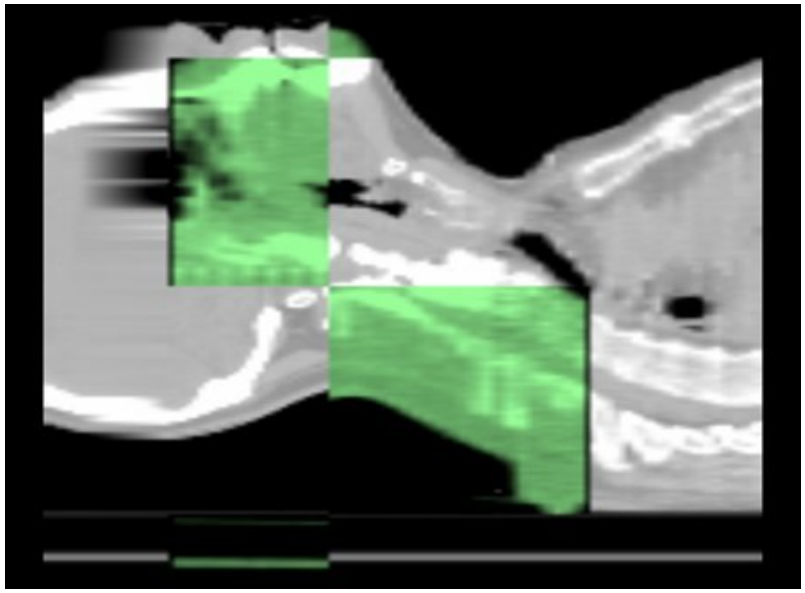

Example of sagittal view of MVCT (green) and kVCT (grey) registration

Yartsev et al. (2007)

Treatment delivery

Outlook - MR

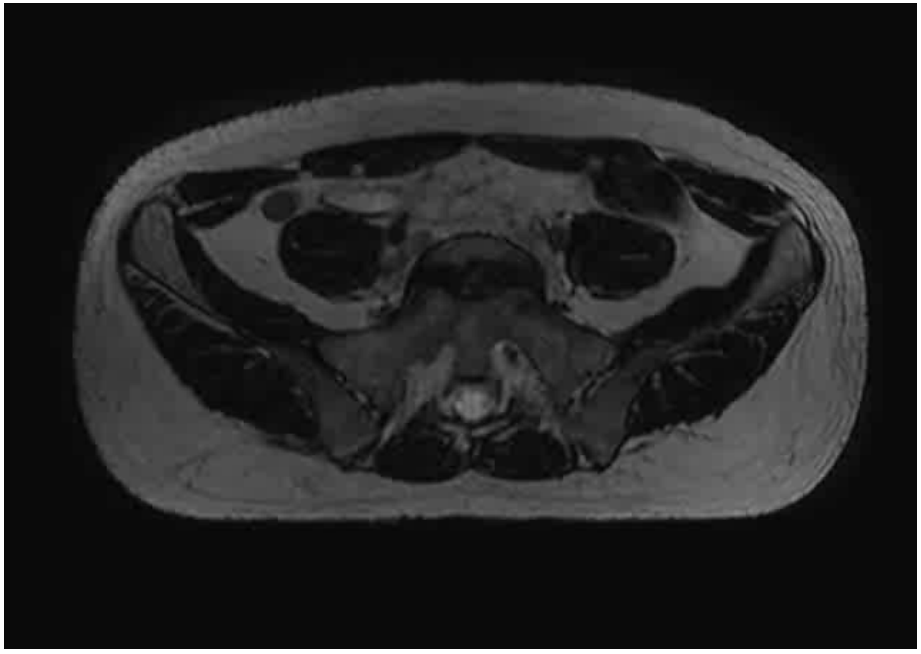

Atlantic **Philips/Elekta**

ESTRO School

Image registration in the RT chain

Initial diagnosis and staging	Preparation/planning (delineation)	Delivery (position verification)	Adaptive RT

Quantification of organ motion/ organ motion analysis

Quantification of organ motion

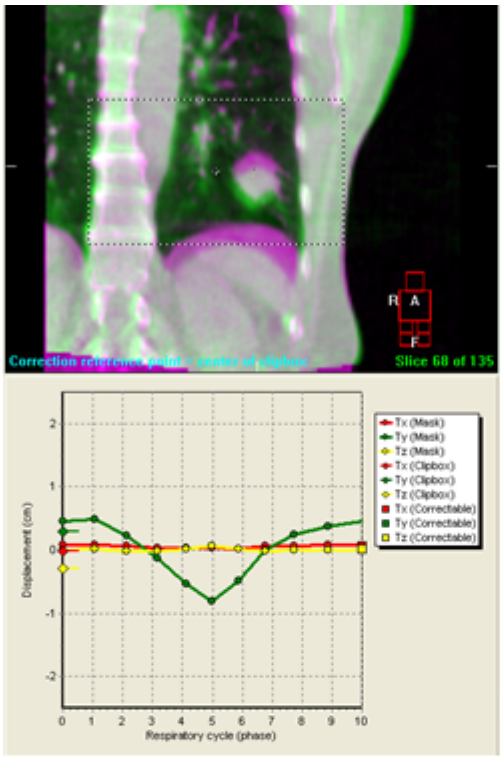

breathing motion:
lung tumor 4D (CB)CT displacement curve

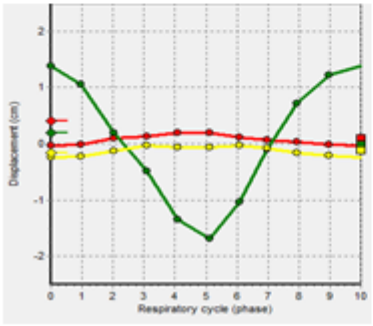

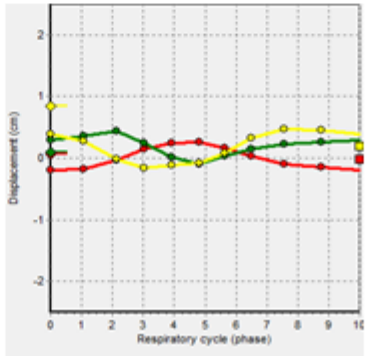

repeat CT

4D CT

4D CBCT

4D MRI

Organ motion analysis

Analysis of prostate motion and deformation
(Deurloo et al IJROBP 2004)

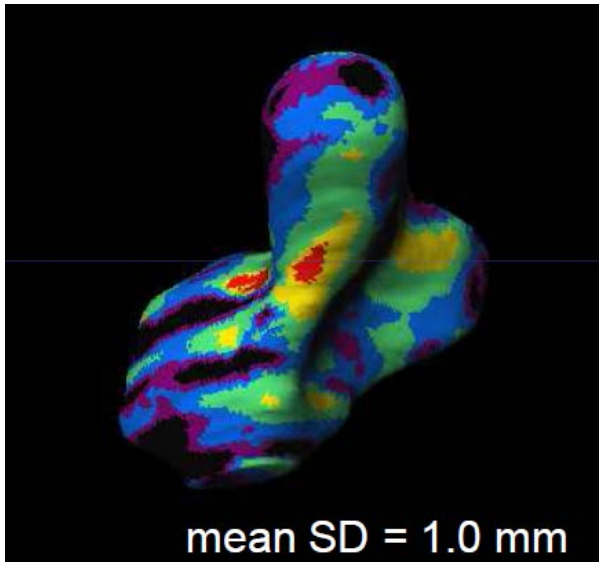

SD (mm)

local shape variation displayed in color wash on average GTV

Radboudumc

ESTRO School

Registration accuracy

Impact on margins?

Examples for registration uncertainties:

~ 0.5 mm for cranial **CT-CBCT** reg

(Sykes et al.,PMB 2009)

≤ 2 mm for cranial C

(Ulin et al.. I

Dependent on registration method and anatomical site!

rectal cancer

~ 2 MR registration for prostate

(Ny et al., Radiat. Onc. 2009)

~ 5-7 mm for DIR

(Yeo et al., Med. Phys 2013)

Some reading material



- Brock (editor) *Image Processing in Radiation Therapy,* CRC Press 2013
- Kessler et al., BJR 2006 *Image registration and data fusion in radiation therapy*
- Brock et al., IJROBP 2010 *Results of a multi-institution deformable registration accuracy study (MIDRAS)*

Look out for…

- AAPM TG 132 *Use of image registration and data fusion algorithms and techniques in radiotherapy treatment planning*

Start: 3/9/2006
End: 12/31/2014

Radboudumc ESTRO School

Take home message

- Image fusion -
  not as simple as “pushing a button”!

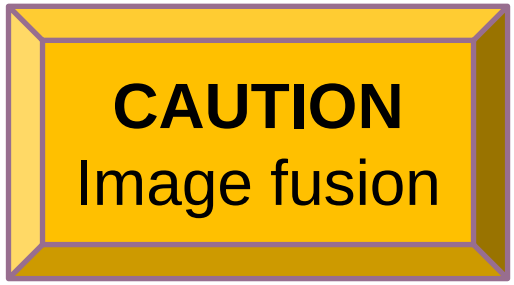

- ALWAYS check fusion result to avoid geometric misses

part 2

DIR

© Randy Glasbergen
Glasbergen.com

"Martina's presentation wasn't so bad. After the third hour, my spirit left my body and went to the beach!"

ESTRO School



Deformable Image Registration

Martina Kunze-Busch
Radboud University Medical Center Nijmegen
The Netherlands

Peter Remeijer
Netherlands Cancer Institute
The Netherlands

Radboudumc NKI-AVL The Netherlands Cancer Institute Antoni van Leeuwenhoek Hospital ESTRO School

Overview

- Introduction (M.Kunze-Busch)

- Clinical practice at the AvL (P.Remeijer)

Radboudumc NKI-AVL The Netherlands Cancer Institute Antoni van Leeuwenhoek Hospital ESTRO School

Available software programs

Features include (among others)

- atlas based auto contouring
- deformable image registration
- dose accumulation

....

and some treatment planning systems

Radboudumc NKI-AVL The Netherlands Cancer Institute Antoni van Leeuwenhoek Hospital ESTRO School

Radboudumc NKI-AVL The Netherlands Cancer Institute Antoni van Leeuwenhoek Hospital ESTRO School

CAUTION

deformable image registration

deformable image registration

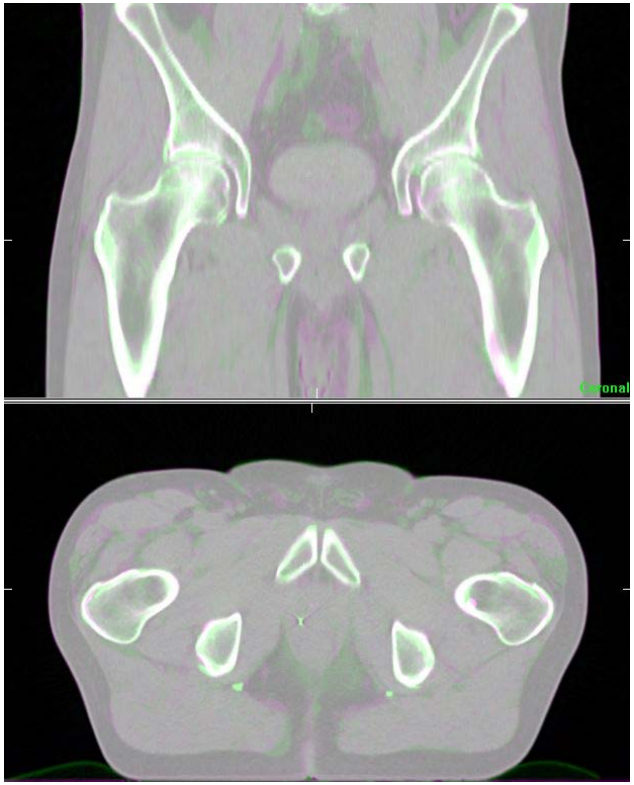

reality

without deformable image registration

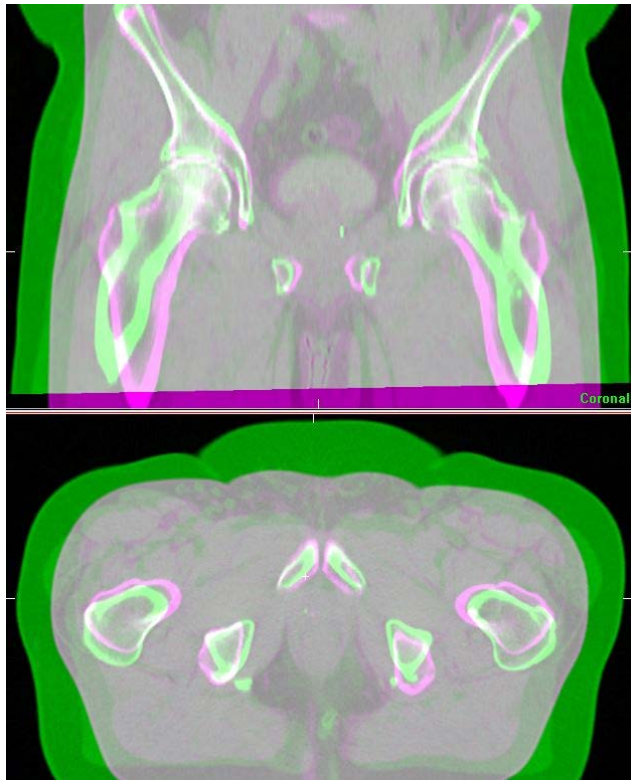

Radboudumc NKI-AVL The Netherlands Cancer Institute Antoni van Leeuwenhoek Hospital ESTRO School

Atlas based segmentation

Would you tell me, please, which way I ought to go from here?
That depends a good deal on where you want to get to.

Alice and the Cat, "Alice in Wonderland"(1951)

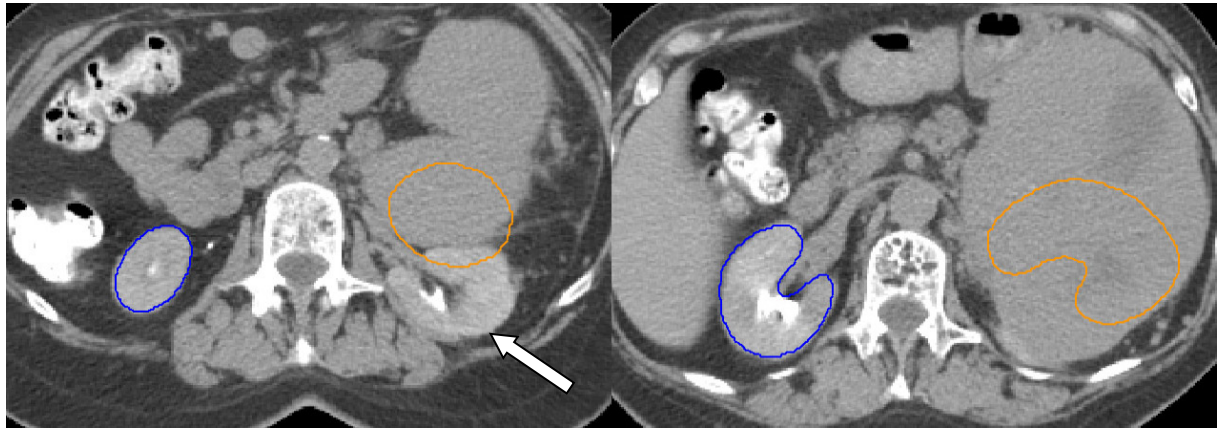

Radboudumc NKI-AVL The Netherlands Cancer Institute Antoni van Leeuwenhoek Hospital ESTRO School

Evaluation of registration

Visual inspection of deformation field

warped grid

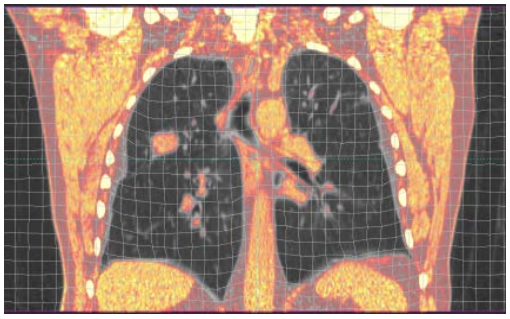

vector field

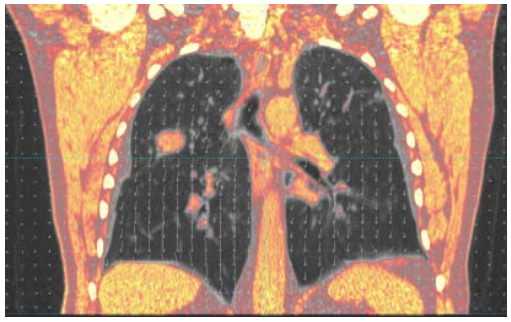

heat maps

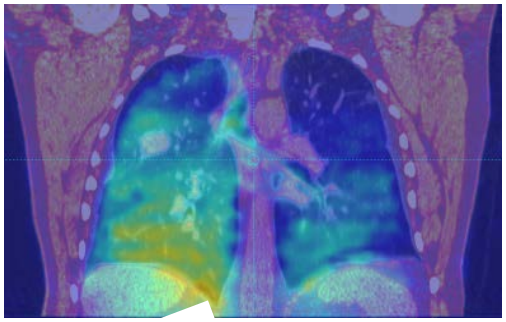

Clinical implementation

Thorough QA of software required !

Understand how software works

Be aware of the limitations of the algorithms

Ask yourself: which accuracy where?

Radboudumc NKI-AVL The Netherlands Cancer Institute Antoni van Leeuwenhoek Hospital ESTRO School

Physical or digital QA

Mechanical phantom

- physical deformable
- in vivo-dosimetry

e.g lung phantom Univ. of Michigan

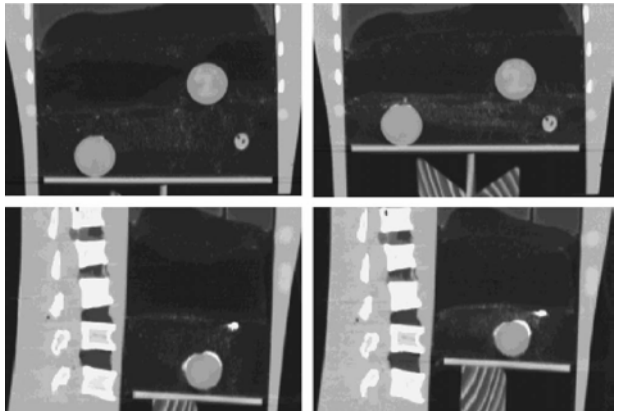

Kashani et al., Med Phys 35 (2008)

e.g deformable H&N phantom Univ. of Calif.

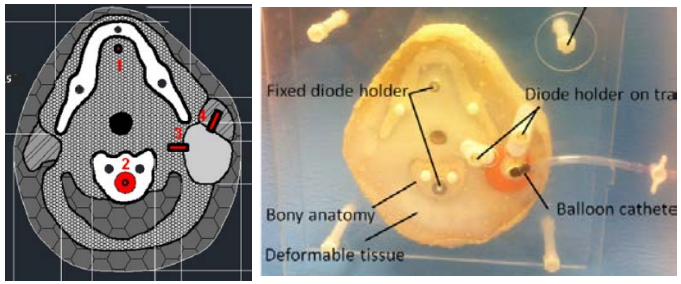

Graves et al., Med Phys 42 (2015)

Simulation

- artificially deformed real patient images or virtual phantoms

e.g. ImSimQA (commercial software)

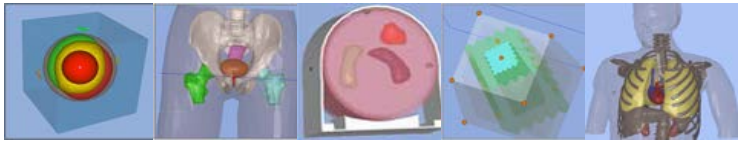

Clinical images

- real patient image data

e.g. - data set from dir-lab/popi…

- replanning CTs or CBCTs

Radboudumc NKI-AVL The Netherlands Cancer Institute Antoni van Leeuwenhoek Hospital ESTRO School

CAUTION

Dose warping/mapping

warped dose uncertainty
=
spatial error (due to registration) x dose gradient

Prof. Jean Pouliot
AAPM 2014

active area of research and discussion

) Mencarelli et al.
plying DIR for tumor
procedures"

AAPM 2014 Moriya et al.
Study on lung SBRT patients
"commissioning test is essential
understand pitfalls of

Validation of dose warping not yet solved !

form" dose along with
gistration in adaptive RT

Me et al.
"Sub nces can be seen between … different
algor dicating that DIR performance should be
scrutinized before application to dose-warping."

Radboudumc NKI-AVL The Netherlands Cancer Institute Antoni van Leeuwenhoek Hospital ESTRO School

Task group 132

Task Group No. 132 Use of Image Registration and Data Fusion Algorithms and Techniques in Radiotherapy Treatment Planning

AAPM Members, Affiliates and Non-Member Affiliates - Login for access to additional information

Charge We propose a task group to: 1) Review the existing techniques and algorithms for image registration and fusion. 2) Discuss issues related to effective clinical implementation of these techniques and algorithms in a variety of treatment planning and delivery situations. 3) Discuss the methods to assess the accuracy of image registration and fusion. 4) Discuss issues related to acceptance testing and quality assurance for image registration and fusion.

Bylaws: Not Referenced. **Rules:** Not Referenced.

Approved Date(s) Start: 3/9/2006
End: 12/31/2014

Chair

Kristy Brock
Task Group Chair

Radboudumc NKI-AVL The Netherlands Cancer Institute Antoni van Leeuwenhoek Hospital ESTRO School

Clinical practice at the AvL

Anatomy and lymph node drainage in the mediastinum

Prof. Dr. med. Dr. Esther Troost
Klinik und Poliklinik für Strahlentherapie und Radioonkologie
Universitäts KrebsCentrum (UCC)
esther.troost@uniklinikum-dresden.de

ESTRO course Target Volume Delineation
Budapest, October, 2015

Content

- Lymphatic drainage of the lungs
- N-stage and regional lymph node stations (maps)
  - Naruke
  - Mountain-Dresler map
  - IASLC
- Evaluation of the mediastinal lymph nodes

Lymphatic drainage of the lungs

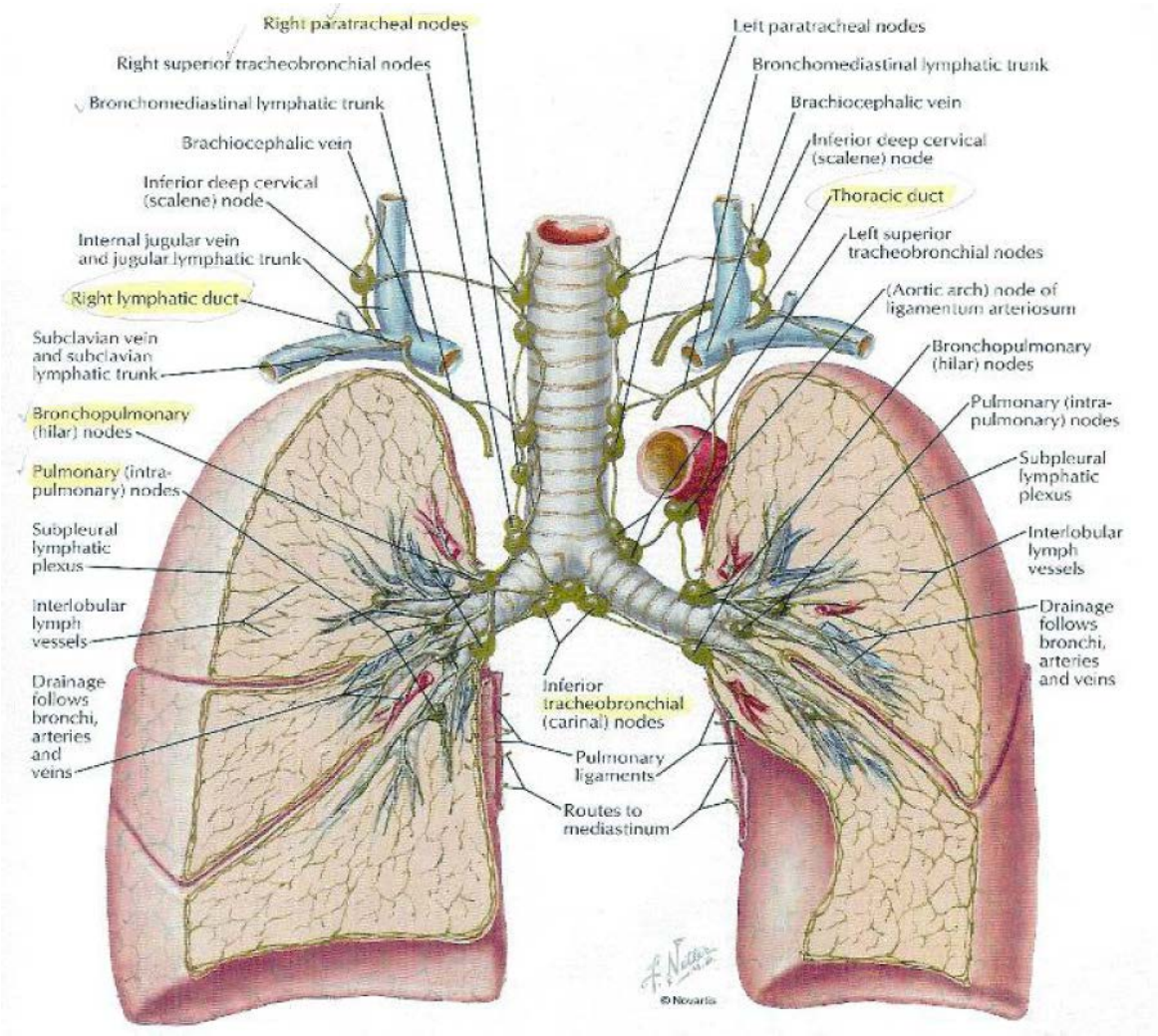

Pattern of mediastinal LN metastases

Nodes	Right upper (N = 113)	Right lower (N = 108)	Left upper (N = 113)	Left lower (N = 68)
Tracheobronchial	16	14.3		11.8
Pretracheal	13.8		6.7	14.3
Paratracheal	15.9	11.1		
Subcarinal	6.3	22.2	2.4	18.5
Para-aortic			16.7	
Subaortic			15.1	19.1

Numbers are expressed in %

Adapted from Ogata and Naruke 1986

Nodal stage

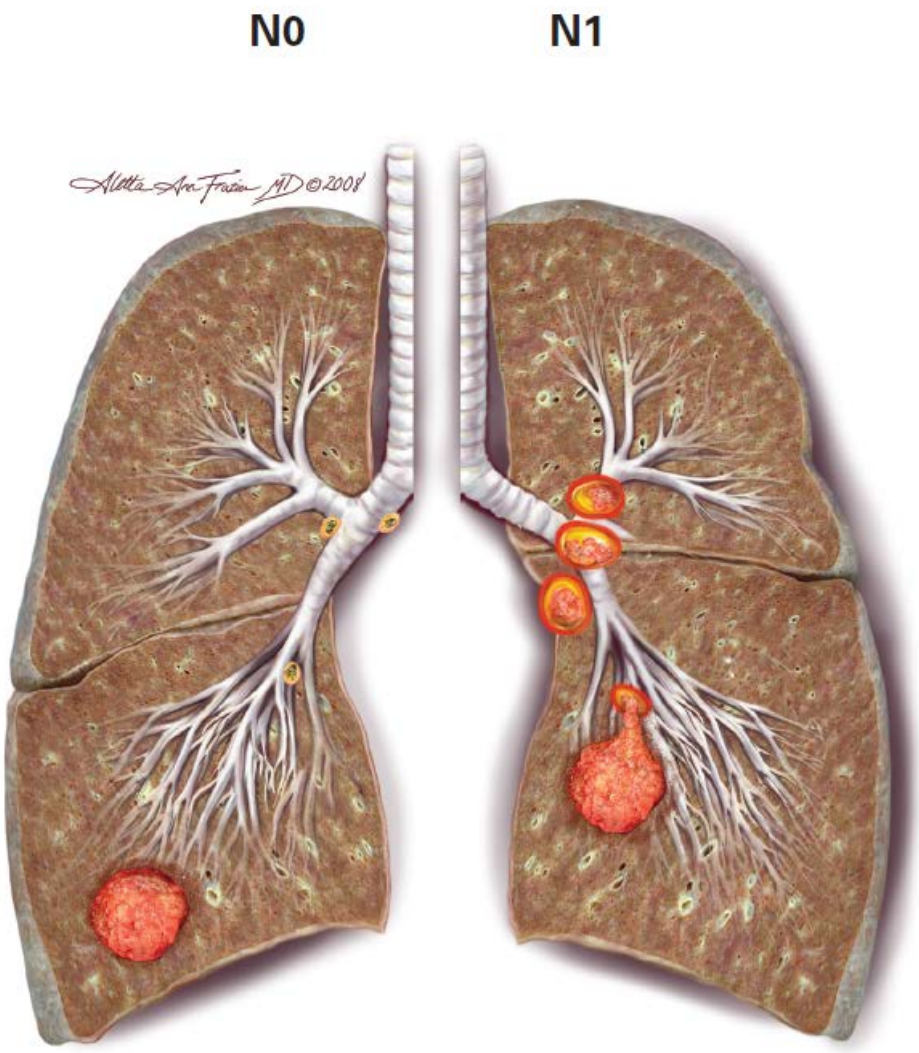

NX Regional lymph nodes cannot be assessed

N0 No regional lymph node metastasis

N1 Metastasis in ipsilateral peribronchial and/or ipsilateral hilar lymph nodes, and intra-pulmonary nodes, including nodal involvement by direct extension

Nodal stage

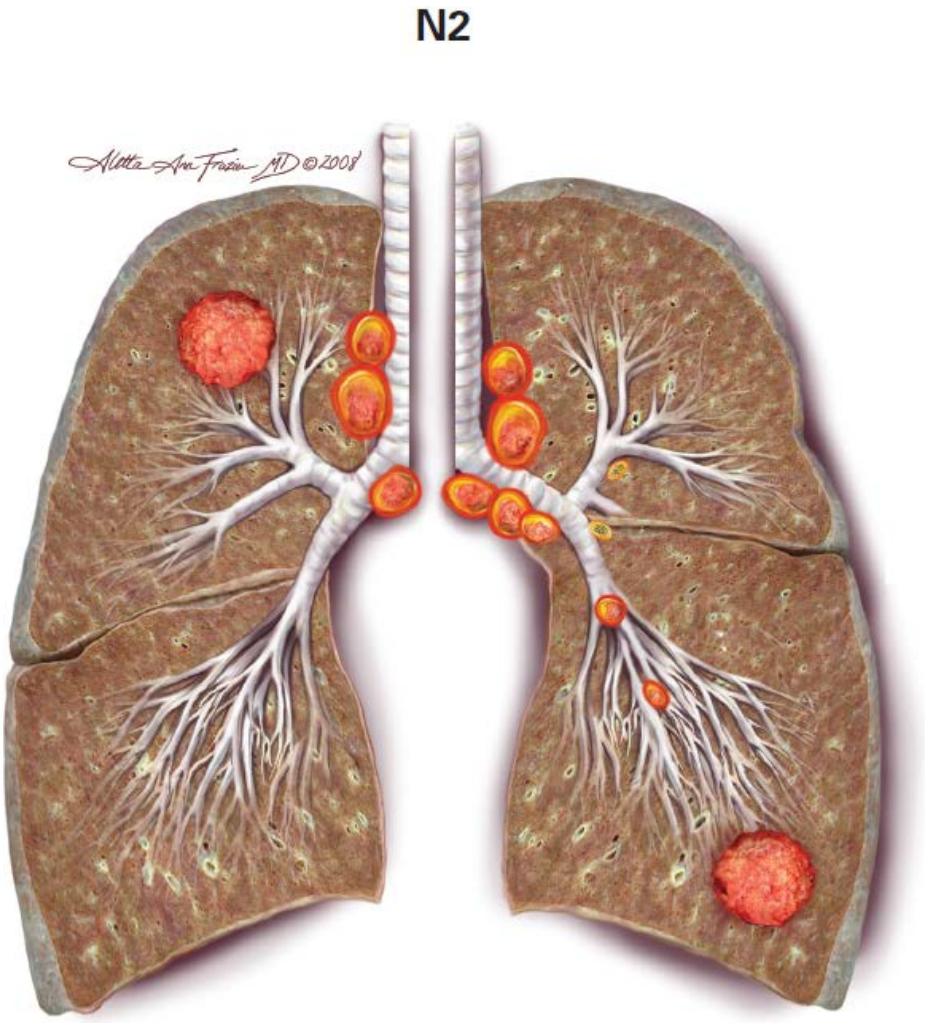

N2 Metastasis in ipsilateral mediastinal and/or subcarinal lymph node(s)

- including skip metastasis without N1 involvement
- or associated with N1 disease

Nodal stage

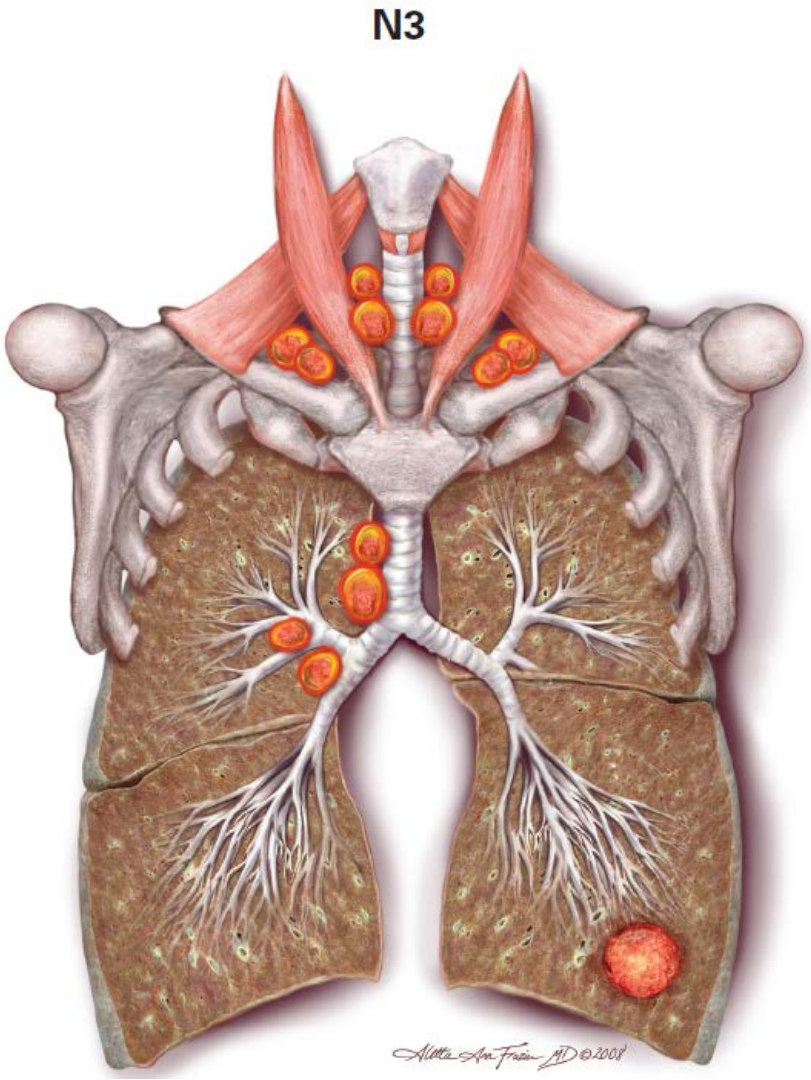

N3 Metastasis to

- contralateral mediastinal, contralateral hilar, contralateral scalene or supraclavicular lymph node(s)

- ipsilateral scalene or supraclavicular lymph node(s)

Regional LN stations: Naruke map

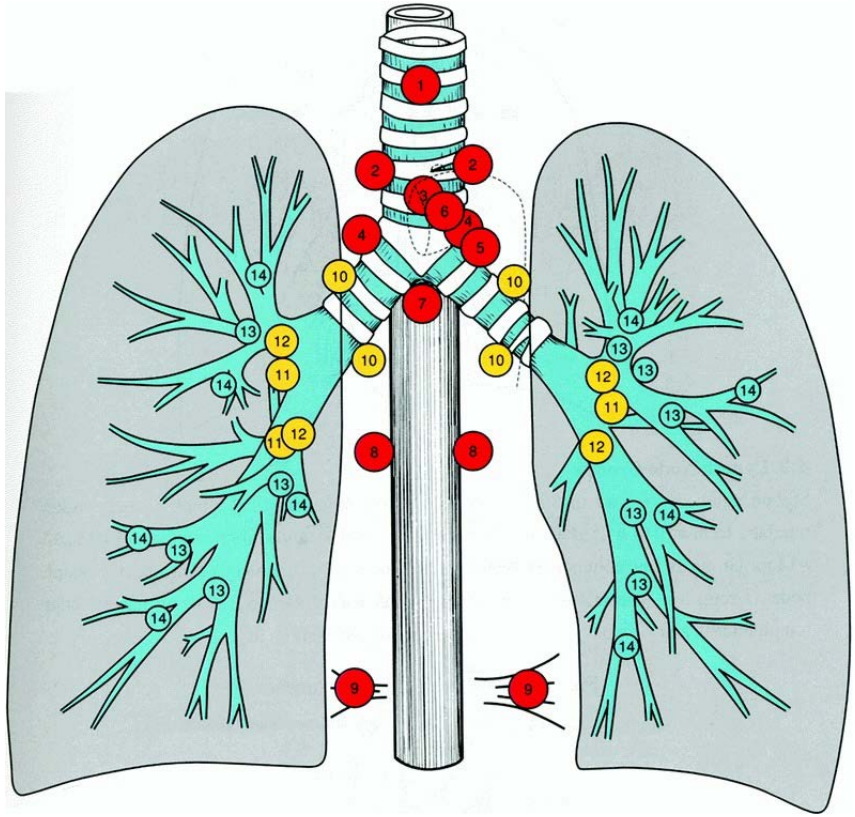

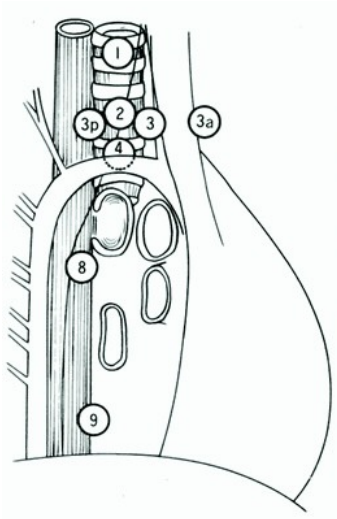

#1 Superior mediastinal or highest mediastinal
#2 Paratracheal
#3 Pretracheal
#3a Anterior mediastinal
#3p Retrotracheal mediastinal or posterior mediastinal
#4 Tracheobronchial
#5 Subaortic or Botallo's
#6 Paraaortic (ascending aorta)
#7 Subcarinal
#8 Paraesophageal (below carina)
#9 Pulmonary ligament
#10 Hilar (main bronchus)
#11 Interlobar
#12 Lobar···upper lobar, middle lobar, and lower lobar
#13 Segmental
#14 Subsegmental

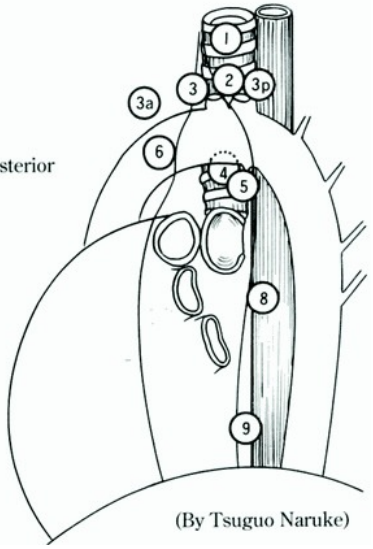

(By Tsuguo Naruke)

The Japan Lung Cancer Society. Classification of Lung Cancer, 1st English Ed. Tokyo: Kanehara & Co., 2000

Regional LN stations: Mountain-Dresler map

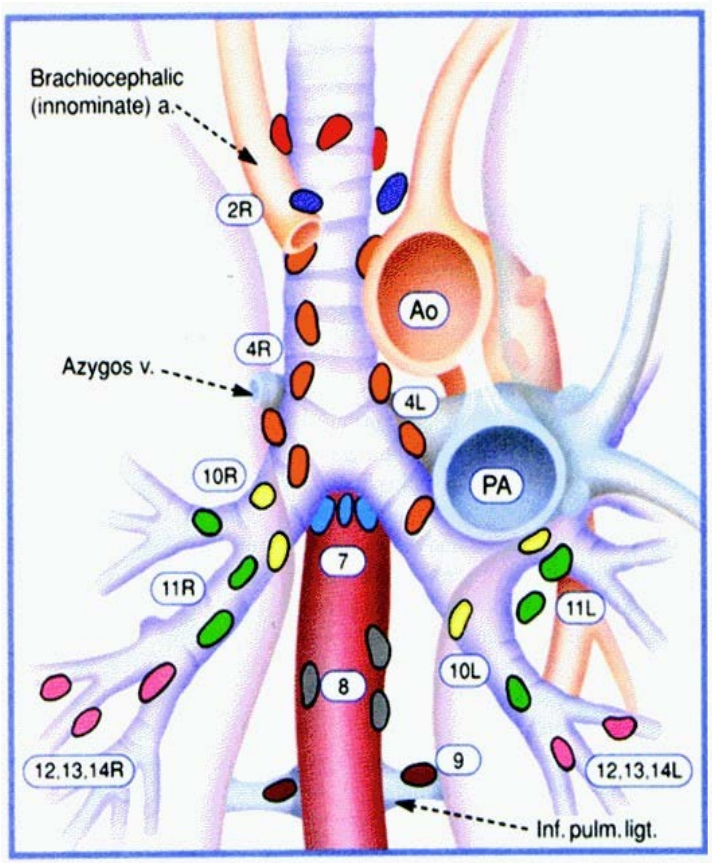

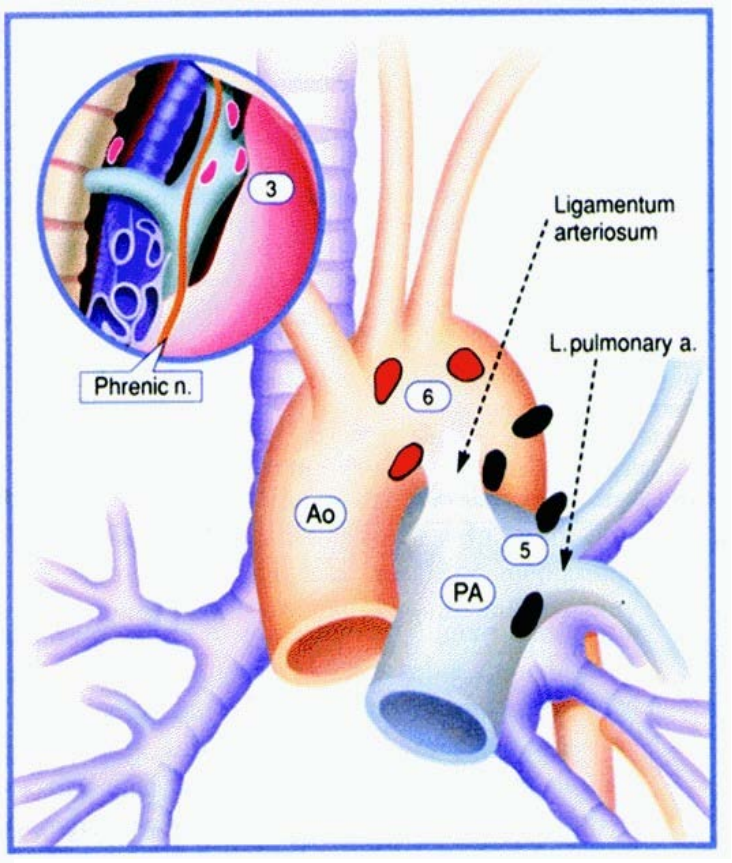

Superior Mediastinal Nodes

- 1 Highest Mediastinal
- 2 Upper Paratracheal
- 3 Pre-vascular and Retrotracheal
- 4 Lower Paratracheal (including Azygos Nodes)

N_2 = single digit, ipsilateral
N_3 = single digit, contralateral or supraclavicular

Aortic Nodes

- 5 Subaortic (A-P window)
- 6 Para-aortic (ascending aorta or phrenic)

Inferior Mediastinal Nodes

- 7 Subcarinal
- 8 Paraesophageal (below carina)
- 9 Pulmonary Ligament

N_1 Nodes

- 10 Hilar
- 11 Interlobar
- 12 Lobar
- 13 Segmental
- 14 Subsegmental

Adapted from Mountain, Dresler Chest 1974

UICC 7 classification (2010)

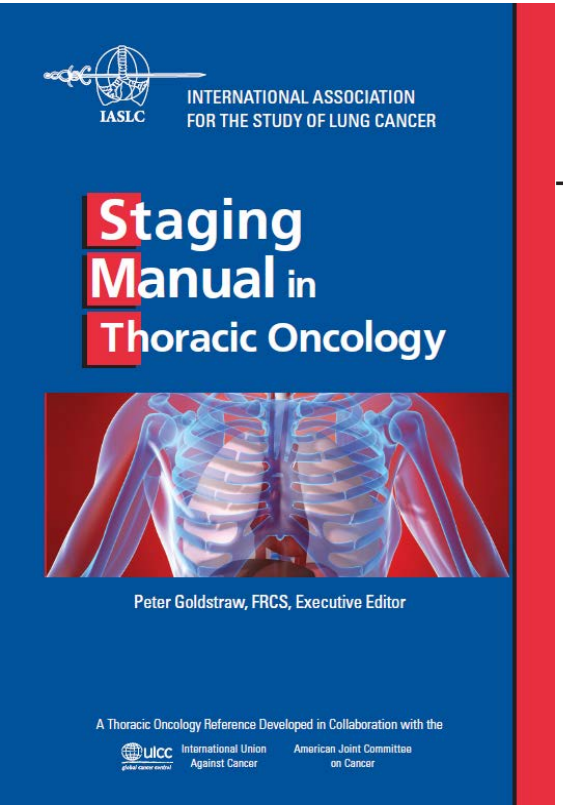

IASLC Staging Committee Article

The IASLC Lung Cancer Staging Project

A Proposal for a New International Lymph Node Map in the Forthcoming Seventh Edition of the TNM Classification for Lung Cancer

Valerie W. Rusch, MD, Hisao Asamura, MD,† Hirokazu Watanabe, MD,‡ Dorothy J. Giroux, MS,§ Ramon Rami-Porta, MD,‖ and Peter Goldstraw, MD,¶ on Behalf of the Members of the IASLC Staging Committee*

Rusch et al J Thorac Oncol 2009
IASLC - staging manual in thoracic oncology 2009

UICC 6 *versus* 7 classification

6th edition T/M descriptor	Revised T/M descriptor	N0	N1	N2	N3
T1 (≤2cm)	**T1a**	IA	IIA	IIIA	IIIB
T1 (>2-3cm)	**T1b**	IA	IIA	IIIA	IIIB
T2 (>3-5 cm)	**T2a**	IB	**IIA**	IIIA	IIIB
T2 (>5-7cm)	**T2b**	**IIA**	IIB	IIIA	IIIB
T2 (>7cm)	**T3**	**IIB**	**IIIA**	IIIA	IIIB
T3 invasion	**T3**	IIB	IIIA	IIIA	IIIB
T4 (same lobe nodules)	**T3**	**IIB**	**IIIA**	**IIIA**	IIIB
T4 (extension)	**T4**	**IIIA**	**IIIA**	IIIB	IIIB
M1 (ipsilateral lung)	**T4**	**IIIA**	**IIIA**	**IIIB**	**IIIB**
T4 (pleural effusion)	**M1a**	**IV**	**IV**	**IV**	**IV**
M1 (contralateral lung)	**M1a**	IV	IV	IV	IV
M1 (distant)	**M1b**	IV	IV	IV	IV

IASLC - staging manual in thoracic oncology 2009

UICC 7 classification (2010)

- Detailed nomenclature for the surgical anatomical boundaries of lymph nodes stations

- Most important changes from Mountain-Dresler map
  - Shift of midline to the left of the trachea:
    4R includes pretracheal LN
  - Shift of cranial and caudal boundaries of # 2, 7, 10R, 10 L
  - Might result in some recoding of N1 -> N2

- No of involved zones (single vs multiple)

Rusch et al J Thorac Oncol 2009

UICC 7 classification (2010)

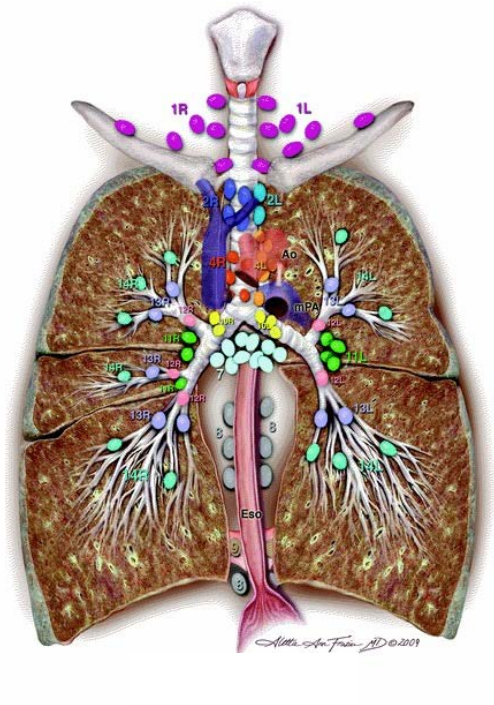

Supraclavicular zone

1 Low cervical, supraclavicular, and sternal notch nodes

SUPERIOR MEDIASTINAL NODES

Upper zone

- 2R Upper Paratracheal (right)
- 2L Upper Paratracheal (left)
- 3a Prevascular
- 3p Retrotracheal
- 4R Lower Paratracheal (right)
- 4L Lower Paratracheal (left)

AORTIC NODES

AP zone

- 5 Subaortic
- 6 Para-aortic (ascending aorta or phrenic)

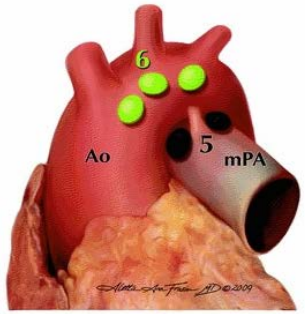

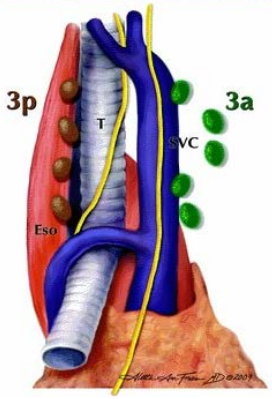

INFERIOR MEDIASTINAL NODES

Subcarinal zone

- 7 Subcarinal

Lower zone

- 8 Paraesophageal (below carina)
- 9 Pulmonary ligament

N1 NODES

Hilar/Interlobar zone

- 10 Hilar
- 11 Interlobar

Peripheral zone

- 12 Lobar
- 13 Segmental
- 14 Subsegmental

Rusch et al J Thorac Oncol 2009

IASLC Map

1

Upper border: lower margin of cricoid cartilage
Lower border: clavicles bilaterally and, in the midline, the upper border of the manubrium, 1R designates right-sided nodes, 1L, left-sided nodes in this region
For lymph node station 1, the midline of the trachea serves as the border between 1R and 1L

2

2R: Upper border: apex of the right lung and pleural space, and in the midline, the upper border of the manubrium
Lower border: intersection of caudal margin of innominate vein with the trachea
As for lymph node station 4R, 2R includes nodes extending to the left lateral border of the trachea
2L: Upper border: apex of the left lung and pleural space, and in the midline, the upper border of the manubrium
Lower border: superior border of the aortic arch

3

3a: Prevascular
On the right
Upper border: apex of chest
Lower border: level of carina
Anterior border: posterior aspect of sternum
Posterior border: anterior border of superior vena cava
On the left:
Upper border: apex of chest
Lower border: level of carina
Anterior border: posterior aspect of sternum
Posterior border: left carotid artery
3p: Retrotracheal
Upper border: apex of chest
Lower border: carina

4

4R: includes right paratracheal nodes, and pretracheal nodes extending to the left lateral border of trachea
Upper border: intersection of caudal margin of innominate vein with the trachea
Lower border: lower border of azygos vein
4L: includes nodes to the left of the left lateral border of the trachea, medial to the ligamentum arteriosum
Upper border: upper margin of the aortic arch
Lower border: upper rim of the left main pulmonary artery

5

Subaortic lymph nodes lateral to the ligamentum arteriosum
Upper border: the lower border of the aortic arch
Lower border: upper rim of the left main pulmonary artery

6

Lymph nodes anterior and lateral to the ascending aorta and aortic arch
Upper border: a line tangential to the upper border of the aortic arch
Lower border: the lower border of the aortic arch

7

Upper border: the carina of the trachea
Lower border: the upper border of the lower lobe bronchus on the left; the lower border of the bronchus intermedius on the right

8

Nodes lying adjacent to the wall of the esophagus and to the right or left of the midline, excluding subcarinal nodes
Upper border: the upper border of the lower lobe bronchus on the left; the lower border of the bronchus intermedius on the right
Lower border: the diaphragm

9

Nodes lying within the pulmonary ligament
Upper border: the inferior pulmonary vein
Lower border: the diaphragm

10

Includes nodes immediately adjacent to the mainstem bronchus and hilar vessels including the proximal portions of the pulmonary veins and main pulmonary artery
Upper border: the lower rim of the azygos vein on the right; upper rim of the pulmonary artery on the left
Lower border: interlobar region bilaterally

11

Between the origin of the lobar bronchi
[a]#11s: between the upper lobe bronchus and bronchus intermedius on the right
[a]#11i: between the middle and lower lobe bronchi on the right

Rusch et al J Thorac Oncol 2009

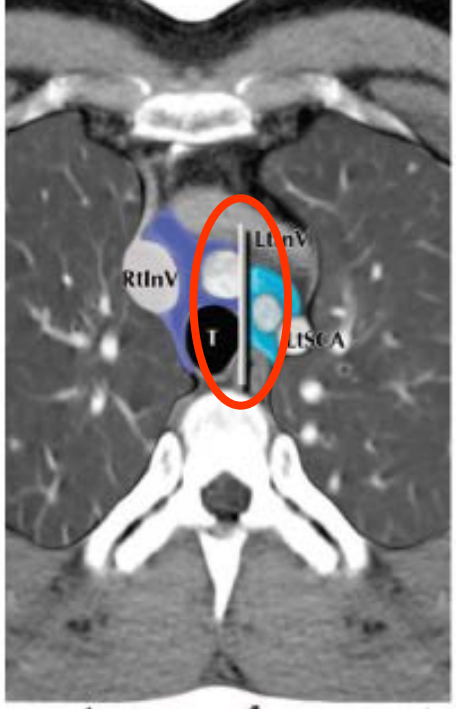

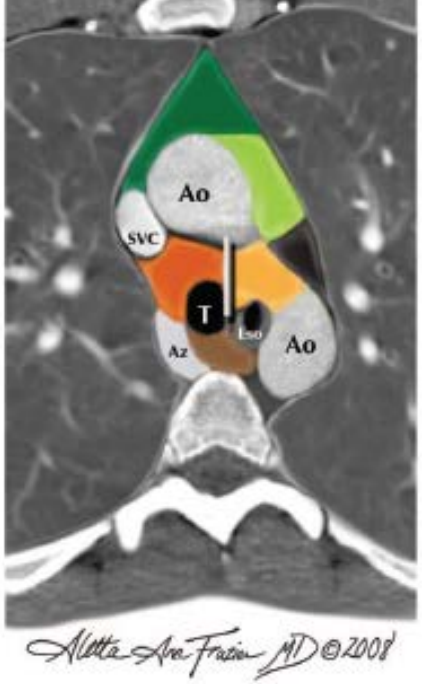

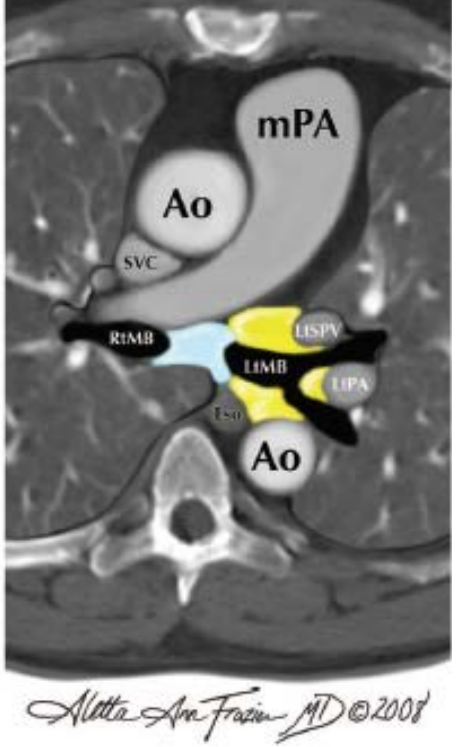

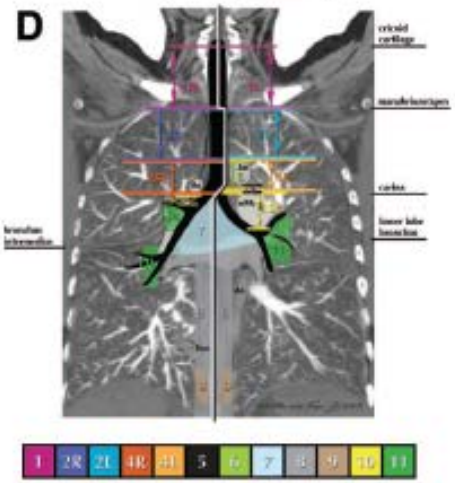

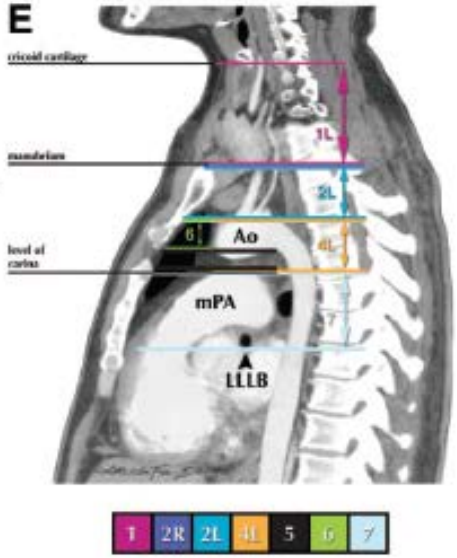

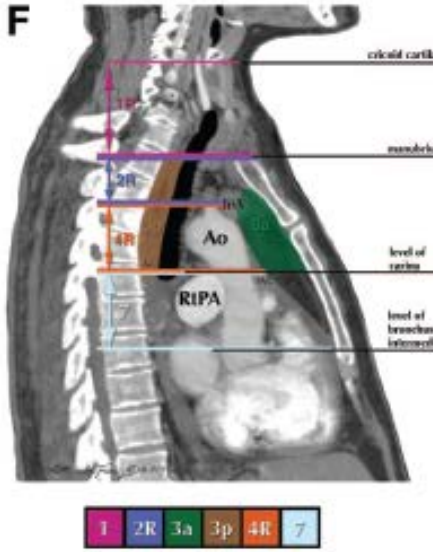

Rusch et al J Thorac Oncol 2009

www.uniklinikum-dresden.de

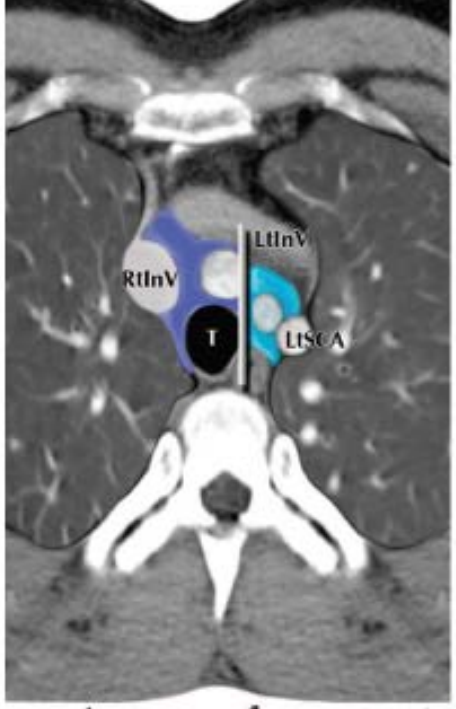

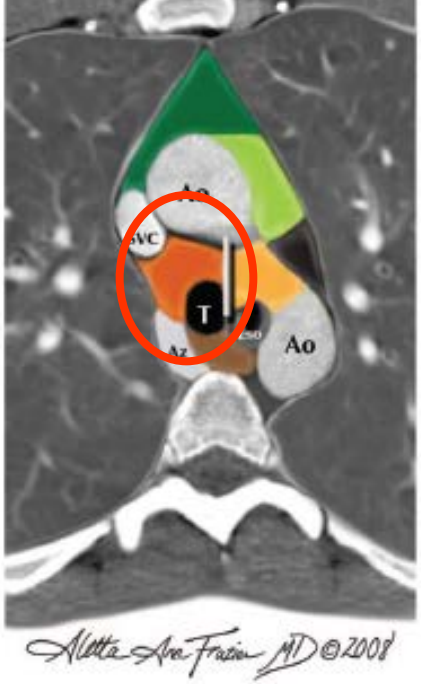

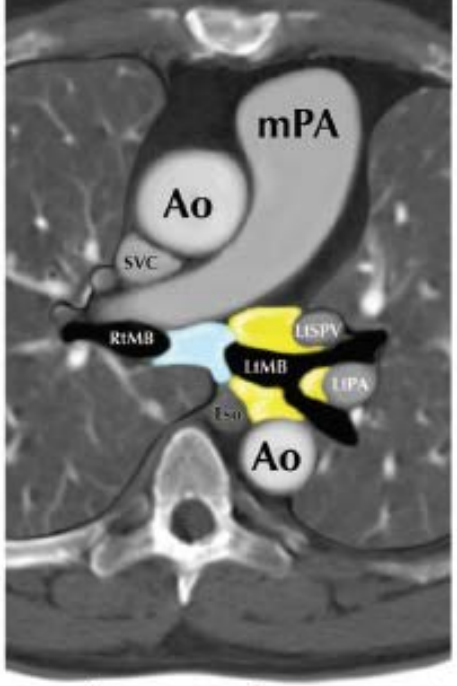

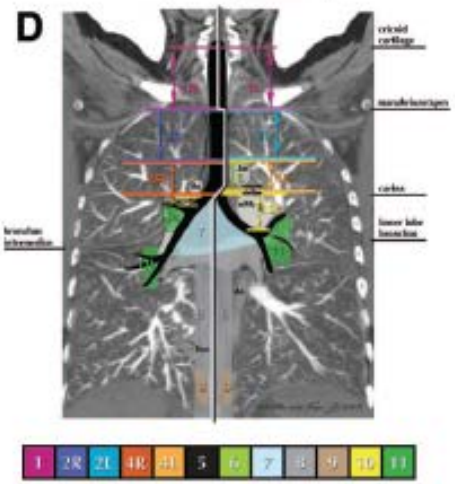

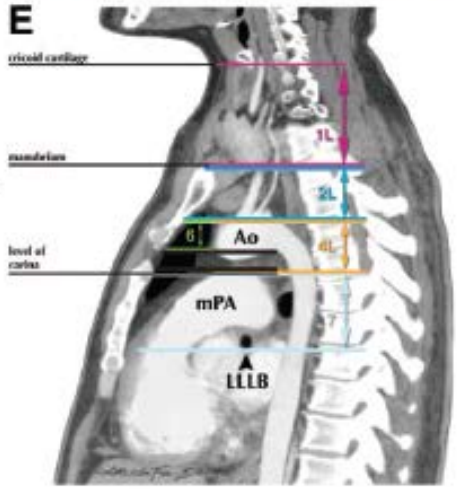

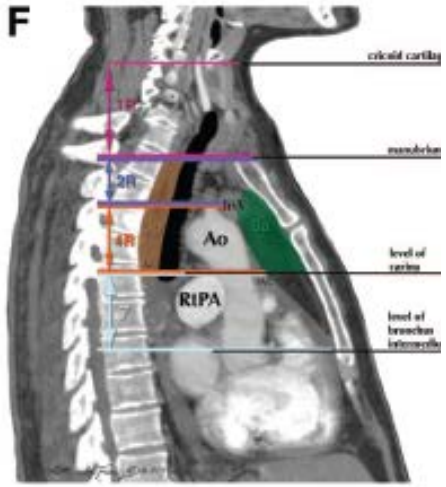

Rusch et al J Thorac Oncol 2009

www.uniklinikum-dresden.de

Content

- Lymphatic drainage of the lungs
- N-stage and regional lymph node stations (maps)
  - Naruke
  - Mountain-Dresler map
  - IASLC
- Evaluation of the mediastinal lymph nodes

Evaluation of mediastinum

- Mediastinoscopy
- EBUS – TBNA
- EUS – FNA
- PET
- CT

Invasive

↓

Non - invasive

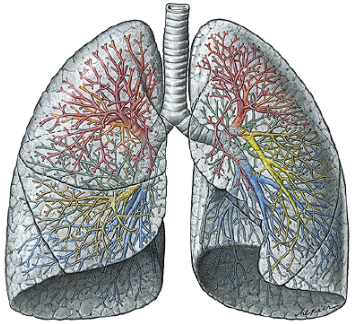

EBUS-TBNA: Endo Bronchial Ultrasound Guided – Trans Bronchial Needle Aspiration

EUS-FNA: Esophageal Ultrasound Guided – Fine Needle Aspiration

Herth et al, Eur Respir J 2006

Mediastinoscopy

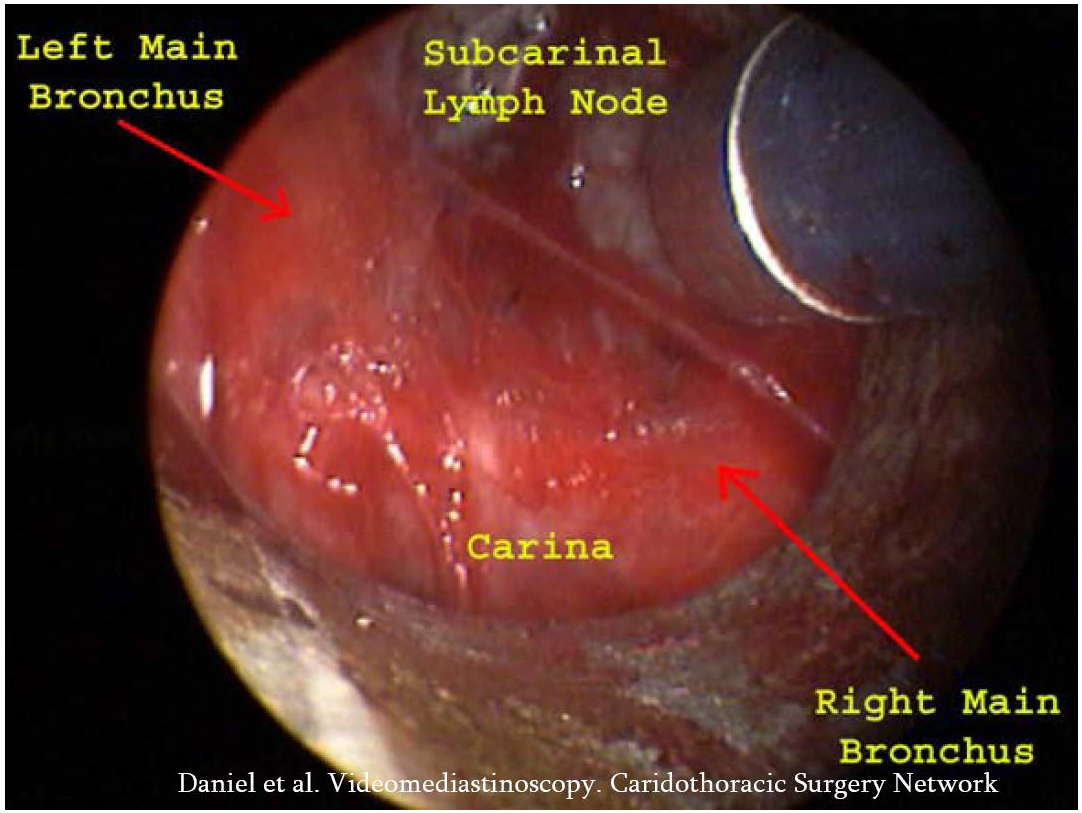

Daniel et al. Videomediastinoscopy. Caridothoracic Surgery Network

- Sensitivity 76-85%
- Negative PV 82-92%
- Complication rate 5%
  - Pneumothorax
  - Hemorrhage
  - Laryngeal nerve palsy

Transesophageal ultrasound

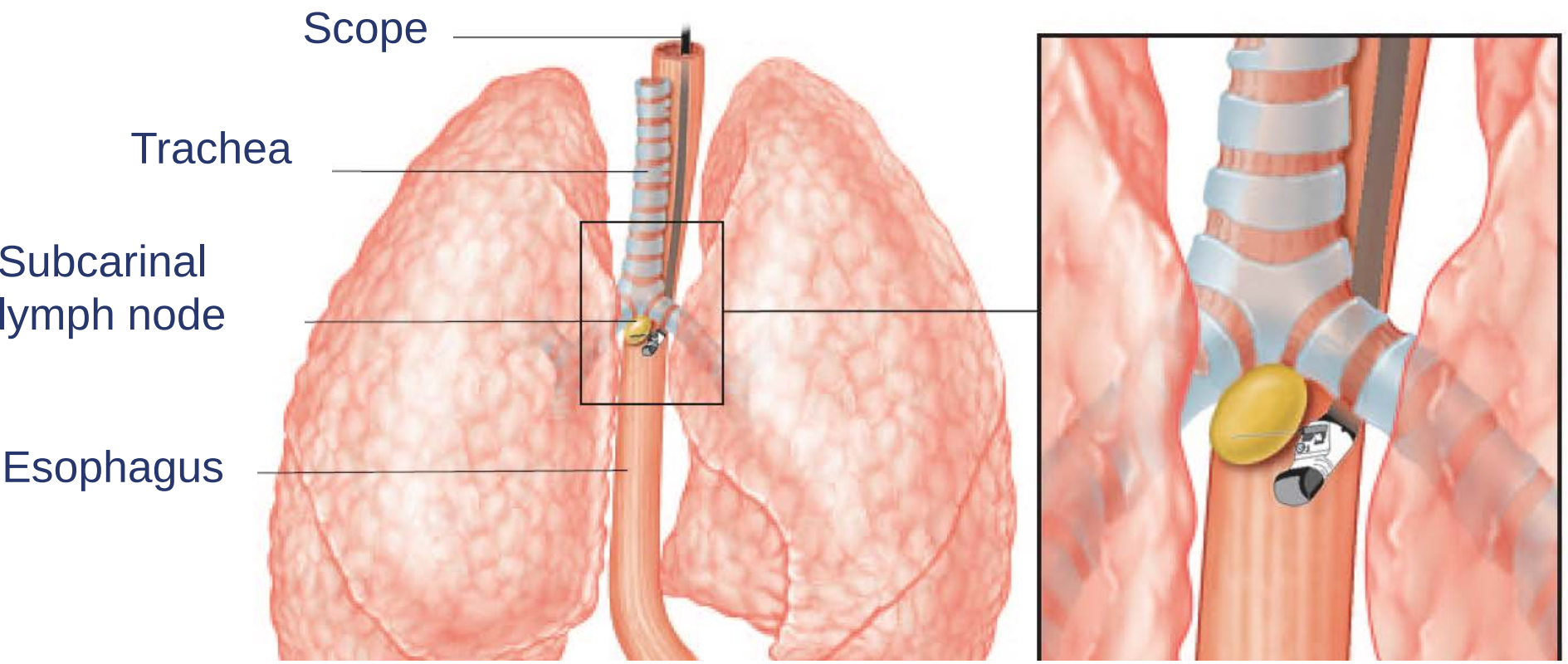

Transesophageal ultrasound-guided fine needle aspiration of a subcarinal lymph node. Sensitivity of 78% and specificity of 71%

Toloza et al, Chest 2003
Herth et al, Eur Respir J 2006

Transesophageal US-guided FNA

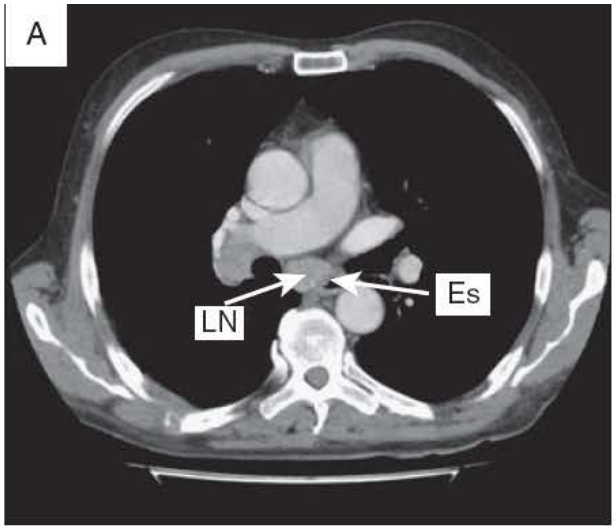

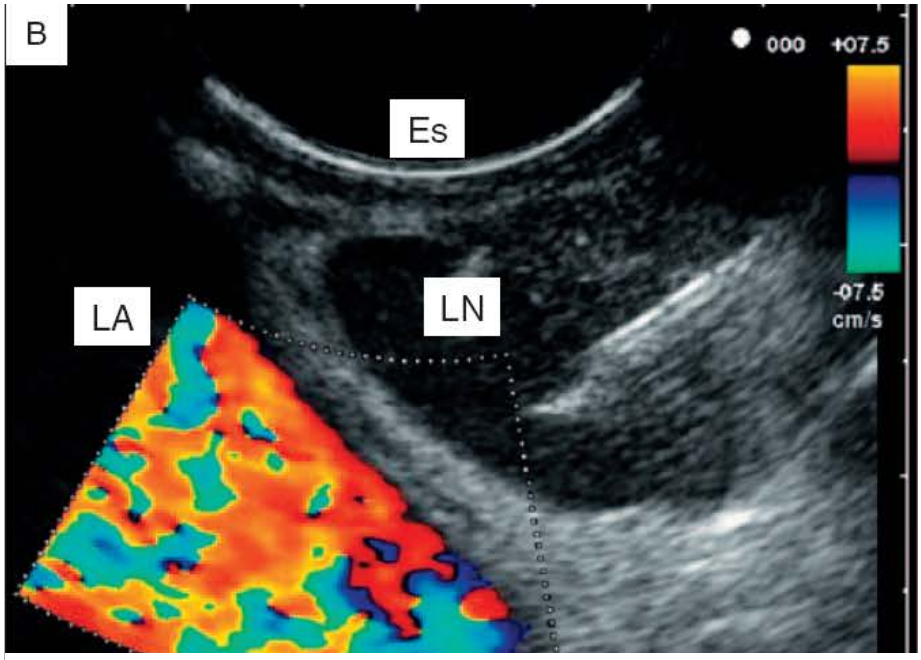

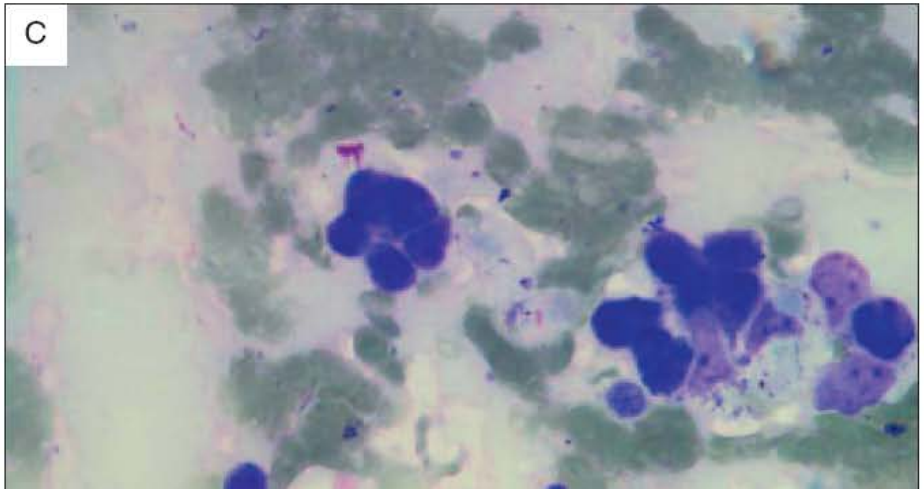

LN: Lymph node
Es: Esophagus
LA: Left Atrium

Toloza et al, Chest 2003
Herth et al, Eur Respir J 2006

Reach of staging techniques

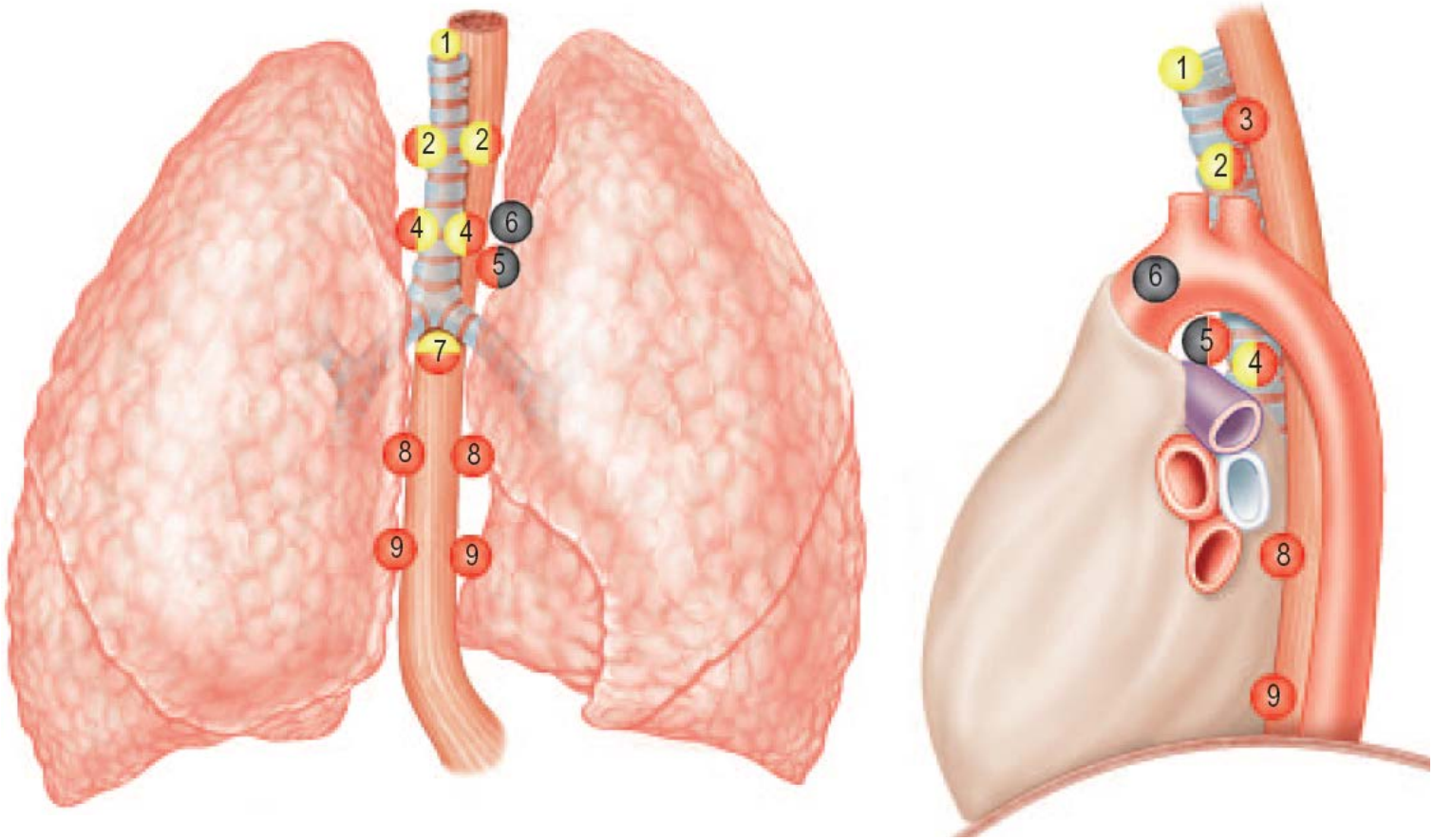

EUS - FNA Mediastinoscopy – EBUS / TBNA Mediastinotomy (VATS)

adapted from Annema et al, JAMA 2005

Non-invasive staging: PET-CT

Review:

- At least 17 well-documented prospective studies, 3 meta-analyses
- PET more accurate than CT (90% vs 75%)
- Correlation with CT scan improves interpretation

	CT	PET
Sensitivity	60%	79%
Specificity	77%	91%

Dwamena 1999, Fischer 2001, Toloza 2003

Non-invasive staging: MRI

- Meta-analysis on value of MRI for staging and RT planning
- N=12 studies eligible

	PET/CT per-patient basis		PET/CT per-nodal basis	
Meta-analyses	Sensitivity (%)	Specificity (%)	Sensitivity (%)	Specificity (%)
Lv YL 2011	76 [65-84]	88 [82-92]	65 [62-68]	95 [94-95]
Zhao L 2012	72 [68-75]	90 [88-91]	61 [58-64]	93 [92-93]
Wu Y 2013	72 [65-78]*	91 [86-94]*	78 [64-87]	90 [84-94]
Wu LM 2012	75 [68-81]	89 [85-91]	-	-

Peerlings et al, accepted for publication in Radiology

Take home messages

The optimal nodal target volume determination remains challenging……

- Extensive lymphatic drainage
- Knowledge! of the incidence of lymph node involvement in different lymph node stations in relation to location of primary tumor
- Knowledge! of the anatomy of lymph node stations and boundaries
- Knowledge! of the TNM classification (use the same language as your colleagues!)
- Knowledge! of the reliability of staging procedures

Thank you for
your attention!
OncoRay – National Center for Radiation
Research in Oncology, Dresden

ESTRO Course From Imaging to Margins

Anatomy and lymph node drainage for breast cancer

Stefan Delorme

DEUTSCHES KREBSFORSCHUNGSZENTRUM IN DER HELMHOLTZ-GEMEINSCHAFT

Outline

- Types of breast cancer
- Imaging methods and features
  - Mammography
  - Ultrasound
  - CT
  - MRI
- T stages
- Nodal drainage and N Stages
- Treated breast cancer

Outline

- Types of breast cancer
- Imaging methods and features
  - Mammography
  - Ultrasound
  - CT
  - MRI
- T stages
- Nodal drainage and N Stages
- Treated breast cancer

Breast cancer: Classification

Criterion	*Types*
According to origin	*- Ductal* *- Lobular*
According to invasiveness	*- In situ* *- Invasive*
According to differentiation	*- G1 Low-grade* *- G2 Intermediate grade* *- G3 High-grade*
According to receptor status	*- Estrogen receptor + / -* *- Progesteron receptor + / -*
According to mutation status	*- Her-2-neu positive* *- Her-2-neu negative*

Breast cancer: Growth patterns

- Ductal carcinoma
  - Intraductal carcinoma in situ
    - Thin extensions
    - Microcalcifications
  - Invasive foci
    - Solitary
    - Multifocal
- Lobular carcinoma
  - LCIS
  - Lobular invasive carcinoma
    - Single-cell invasion pattern
- Medullary carcinoma
  - Smooth lump
- Inflammatory carcinoma
  - Extensive lymphangitic and skin infiltration

Growth patterns

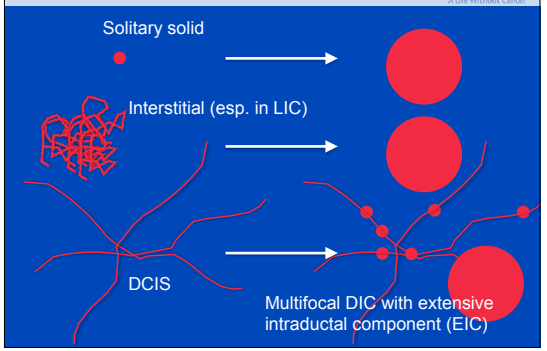

Outline

- Types of breast cancer
- Imaging methods and features
  - Mammography
  - Ultrasound
  - CT
  - MRI
- T stages
- Nodal drainage and N Stages
- Treated breast cancer

Signs of breast cancer on mammography

- Mass
  - Dense
  - Unsharp
  - Irregular or speculated
  - Smooth (rare)
- Architectural distortion
  - Concentric
  - Retraction of surface of glandular body
- Ductal microcalcifications
- Skin thickening

Calcifications

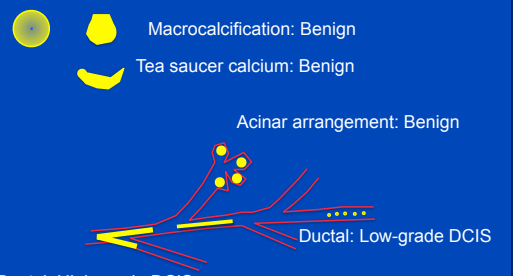

Invasive breast cancer with DCIS

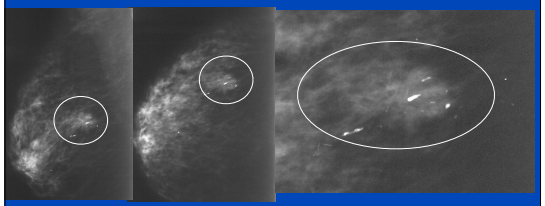

Invasive breast cancer

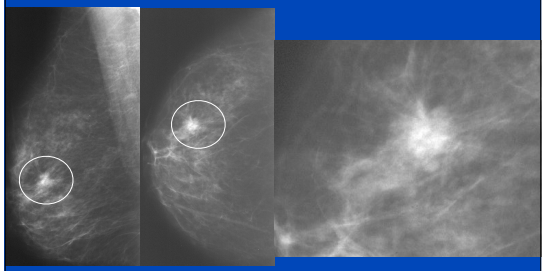

Breast cancer

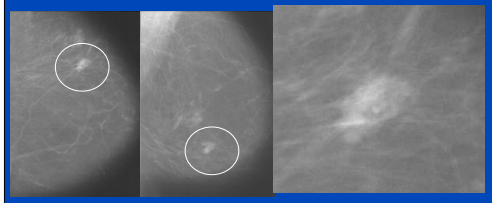

DCIS

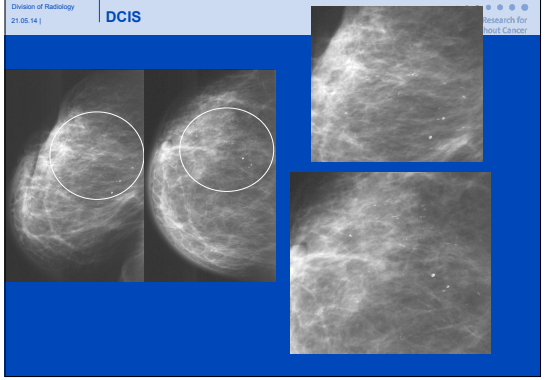

DCIS

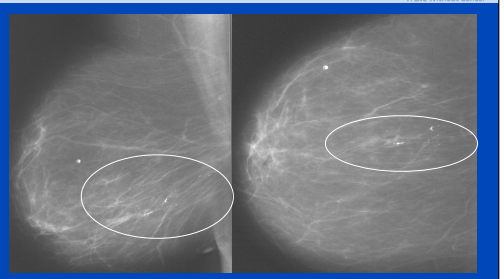

High-grade DCIS

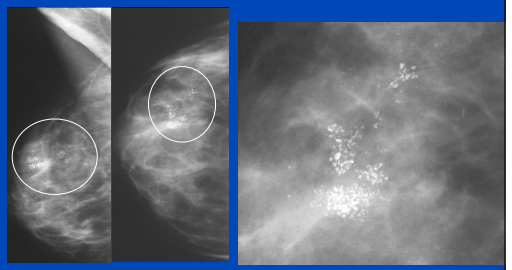

Benign proliferative changes

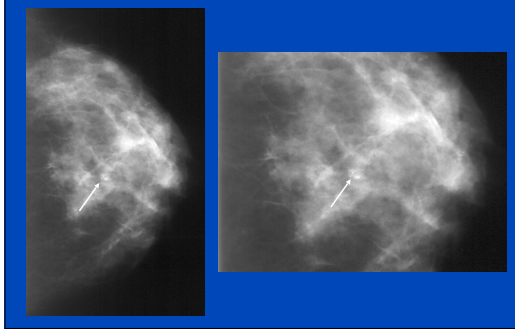

Outline

- Types of breast cancer
- Imaging methods and features
  - Mammography
  - Ultrasound
  - CT
  - MRI
- T stages
- Nodal drainage and N Stages
- Treated breast cancer

Signs of breast cancer at ultrasound

- Mass
  - Irregular
  - Blurred borders
  - 2 Layers
    - Central echopoor zone: Fibrohyalinosis
    - Peripheral hyperechogenic rim: Proliferative zone
  - Vertical orientation
- Acoustic shadow originating from the tumor center
- Increased blood flow at color Doppler
- Incompressibility / Low elasticity at elastography
- Worm-like echopoor extensions
  ➡DCIS components
- Skin thickening

Fibroadenoma

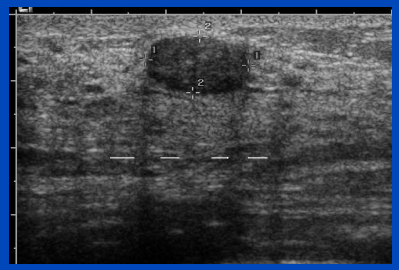

Fibroadenoma

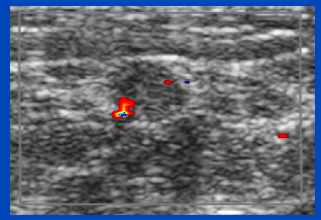

Invasive breast carcinoma

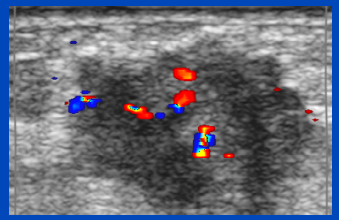

Invasive breast cancer with DCIS

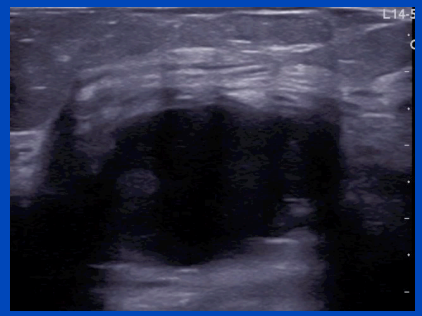

Outline

- Types of breast cancer
- Imaging methods and features
  - Mammography
  - Ultrasound
  - CT
  - MRI
- T stages
- Nodal drainage and N Stages
- Treated breast cancer

CT in breast cancer

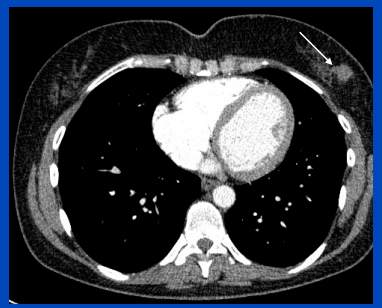

Outline

- Types of breast cancer
- Imaging methods and features
  - Mammography
  - Ultrasound
  - CT
  - MRI
- T stages
- Nodal drainage and N Stages
- Treated breast cancer

Sequences

- Must:
  - T2w
    - STIR (fat-suppressed T2)
    - T2 TSE
  - T1 dynamic
    - 3D-FLASH (104 slices, 0.8x0.6x1.5 mm, 5x3 min)
    - 0.2 mmol/kg BW Gd-DTPA
- Optional:
  - DWI
  - Silicon-sensitive for Implants
  - Fat-suppressed T1w

Signs of breast cancer at MR mammography

- Focal contrast enhancement
- Early rise in intensity + plateau or washout
- Contrast enhancement from periphery to center
- Shape and architecture like in mammography or US

Be aware of benign lesions

- Multiple small contrast enhancing spots (starry sky)
  ➡Benign proliferative changes = normal
- Smooth, enhancing tumors
  ➡Mostly fibroadenomas
- Bean-shaped, enhancing lymph nodes
  ➡Intramammary lymph nodes
- Cysts with enhancing wall
  ➡Inflammatory reaction
- Complex lesions with contrast enhancement post-op
  ➡Fat necrosis
  ➡Look for fat or hemoglobin degradation products

Weightings

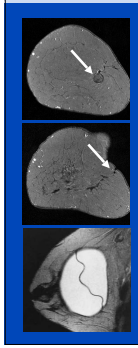

- T1
  - Sensitive for susceptibility (blood, electro-coagulators, clips, large calcifications)
  - For post contrast imaging
- T2
  - Cysts
  - Edema
  - Lymph nodes
  - Fatty secretion
  - Implants

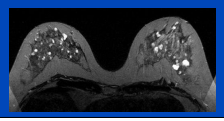

High versus Low Resolution

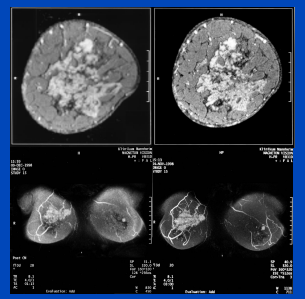

Dynamic or static

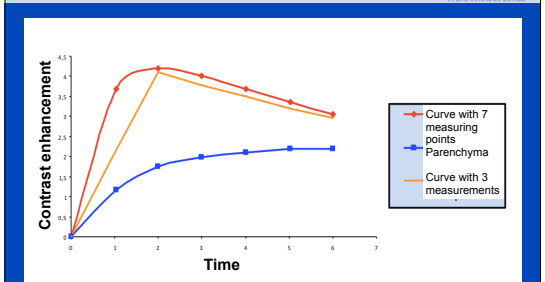

In Anlehnung an Heywang-Köbrunner, IIBM Studie, Eur Radiol 2001

Subtraction

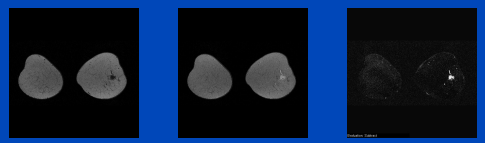

Plain Enhanced Subtraction

Dynamic enhancement evaluation

- Initial signal rise
  - < 50%
  - 50% - 100%
  - > 100%
- Gross signal evolution
  - Continuous increase
  - Plateau
  - Wash-out
- Enhancement pattern
  - Homogeneous
  - From center to periphery
    - Fibroadenomas, lymph nodes
  - From periphery to center
    - Carcinomas

Morphology

- Diameter
- Shape
  - Round, oval, polygonal, linear, tubular
  - Dendritic, spiculated, multiple longitudinal (Comedo-like)
- Delineation
  - Smooth
  - Unsharp
- Enhancement pattern
  - Homogeneous, septations
  - Inhomogeneous
  - Ring enhancement
    - Thin, sharp -> Often with cysts or fatty necrosis
    - Thick, unsharp -> Suspicious

Multicentric breast carcinoma

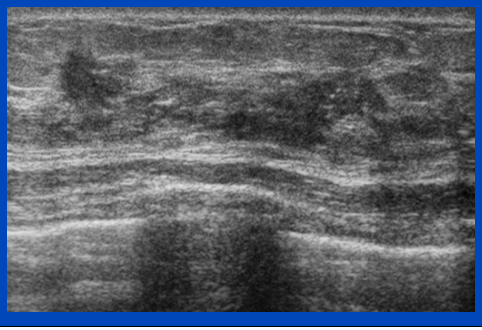

Multicentric breast carcinoma

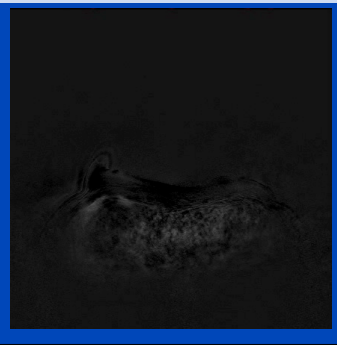

Multicentric breast carcinoma

Multifocal breast carcinoma: DWI

Punch biopsy equipment

Ultrasound verification of successful biopsy

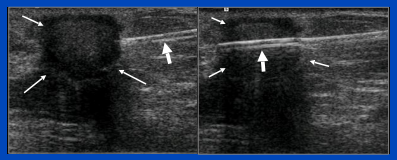

Vacuum aspiration biopsy equipment

Biopsy

Biopsy yield

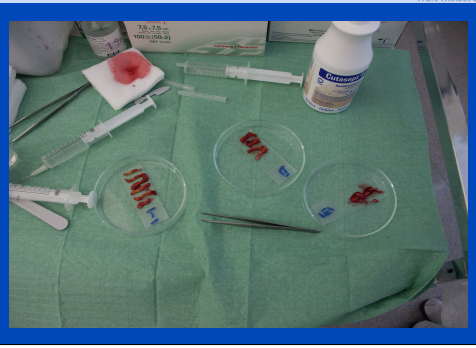

Excision biopsy

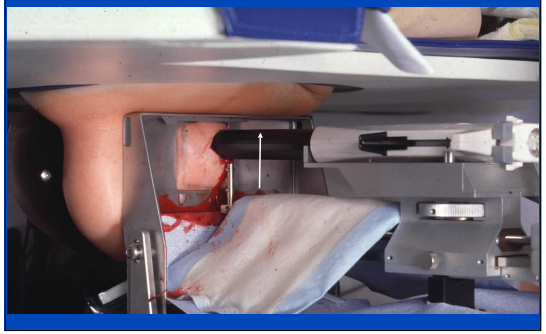

Resected specimen

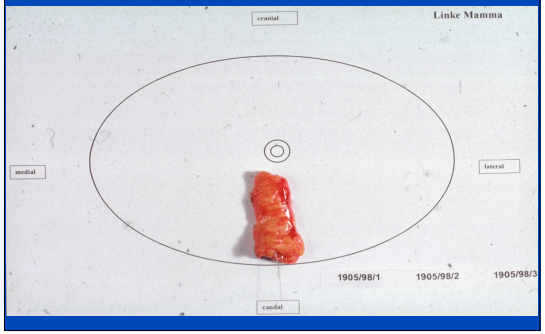

Outline

- Types of breast cancer
- Imaging methods and features
  - Mammography
  - Ultrasound
  - CT
  - MRI
- T stages
- Nodal drainage and N Stages
- Treated breast cancer

Breast cancer T stages

Stage	Criterion
T0	*No evidence of PT*
Tis *DCIS* *LCIS* *Paget*	*In situ carcinoma* *- Ductal Ca in situ* *- Lobular Ca in situ* *- Paget of the nipple, no invasive foci*
T1 *T1a* *T1b* *T1c*	*Tumor 2 cm or less in diameter* *- max. 5 mm in diameter* *- > 5 mm but max. 10 mm in diameter* *- > 10 mm but max. 20 mm in diameter*
T2	*> 2 cm but max. 5 cm in diameter*
T3	*> 5 cm in diameter*
T4	*Any size with direct invasion of chest wall or skin, including inflammatory carcinoma*

Breast cancer T4

Outline

- Types of breast cancer
- Imaging methods and features
  - Mammography
  - Ultrasound
  - CT
  - MRI
- T stages
- Nodal drainage and N Stages
- Treated breast cancer

Breast cancer: Lymphatic drainage

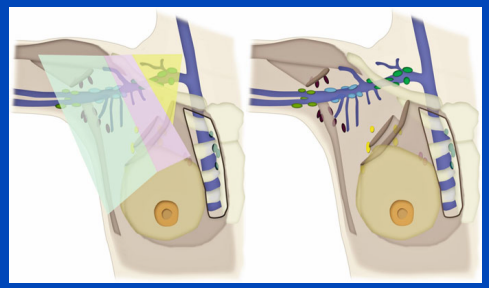

Breast cancer N stages

Stage	*Criterion*
N0	*No regional lymph node metastases*
N1	*Metastases in movable ipsilateral Level I or II lymph nodes*
N2a *N2b*	*- Clinically fixed ipsilateral Level I or II LN* *- Clinical (incl. imaging) evidence of internal mammary LN in absence of clinically detected axillary lymph nodes*
N3a *N3b* *N3c*	*- Metastases in infraclavicular LN* *- Metastases in internal mammary AND axillary lymph nodes* *- Metastases in supraclavicular LN*

Axillary lymph nodes Level I

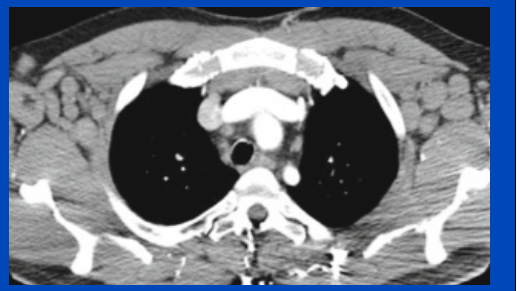

Internal mammary chain

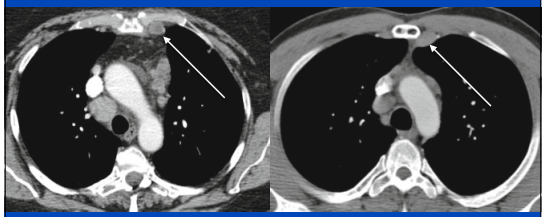

Axillary lymph node metastasis

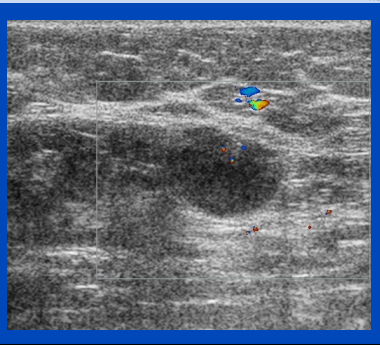

Outline

- Types of breast cancer
- Imaging methods and features
  - Mammography
  - Ultrasound
  - CT
  - MRI
- T stages
- Nodal drainage and N Stages
- Treated breast cancer

Response: Tumor cells

- Apoptosis
  - Early (hours to days)
  - Single-cell pattern
  - No inflammatory reaction
  - Phagocytosis by neighbor cells
- Necrosis
  - Delayed (next mitosis, possibly after several cycles)
  - Grouped cell pattern
  - Inflammation
  - Phagocytosis by macrophages

Response: Tumor stroma

- Regression of cellular components
  - Lack of stimulation by tumor cells
  - Very delayed
- Often persistence of fibrous components
- Regression of vasculature
  - Lack of angiogenic stimulation
  - Direct treatment effects on vessels
    - Radiation
    - Anti-angiogenic treatment etc.
    - Chemotherapy

Breast cancer: Possible response patterns

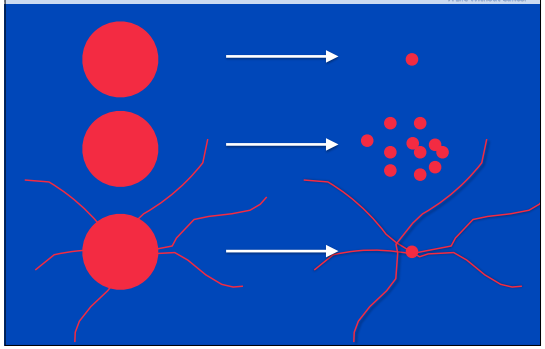

Microcalcifications

Before chemotherapy

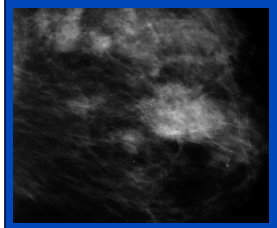

After chemotherapy

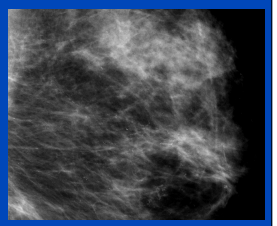

US: Partial response

Mammography: Partial response

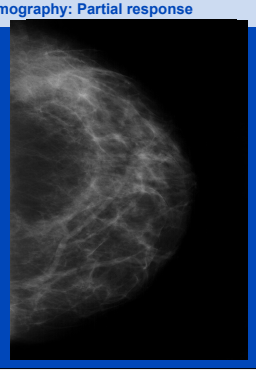

Comparison of methods

	Correlation with pathology	
Mammography	*r=0.628*	*p<0.001*
Ultrasound	*r=0.541*	*p<0.001*
Physical examination	*r=0.597*	*p<0.001*

Loehberg CR et al., Anticancer res 25:2519-26(2005)

Reality

Measuring tumor size

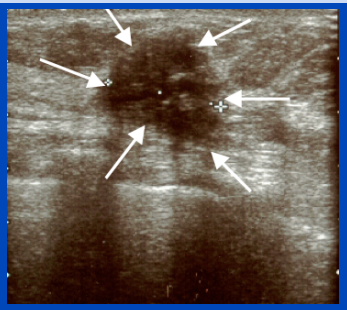

Klein SK, medical dissertation 2002

Measurinng tumor size?

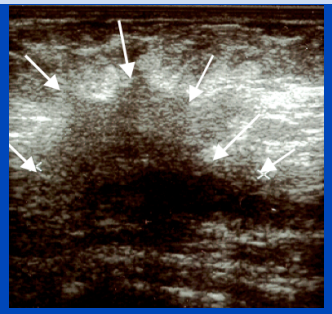

Klein SK, medical dissertation 2002

Measuring tumor size?

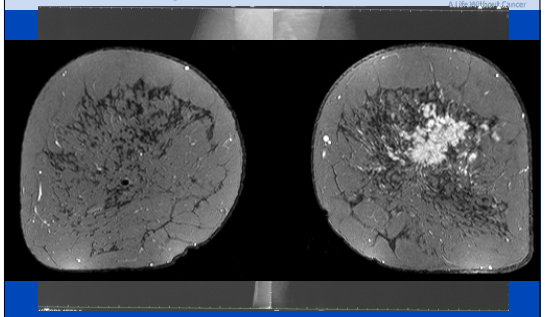

Extent of mircrocalcifications

dkfz.
50 Years – Research for A Life Without Cancer

Before chemotherapy

After final cycle

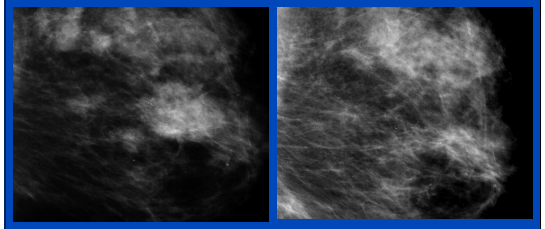

Courtesy K. Wasser, Mannheim

Before chemotherapy

dkfz.
50 Years – Research for A Life Without Cancer

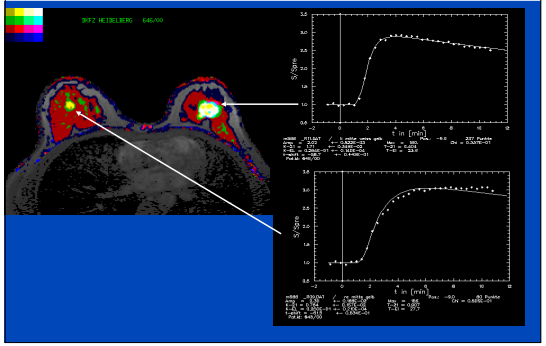

After chemotherapy

dkfz.
50 Years – Research for A Life Without Cancer

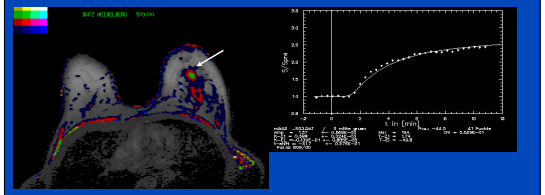

Before chemotherapy

dkfz.
50 Years – Research for A Life Without Cancer

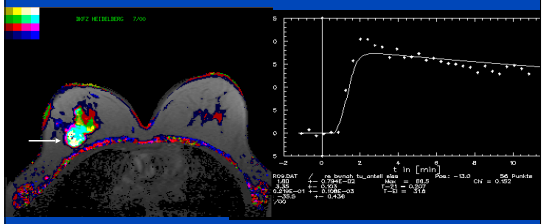

After chemotherapy

dkfz.
50 Years – Research for A Life Without Cancer

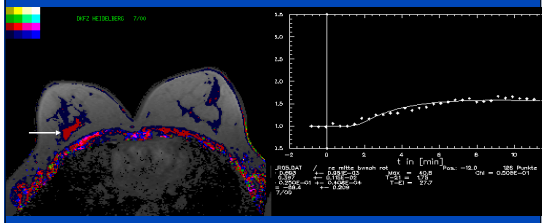

Microcalcifications: Changes during treatment

dkfz.
50 Years – Research for A Life Without Cancer

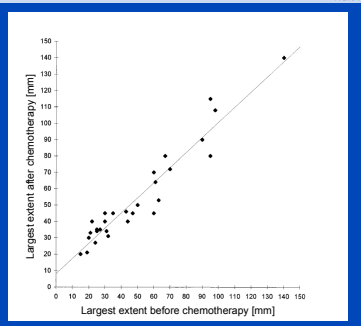

Junkermann 1997

Ultrasound vs. histology

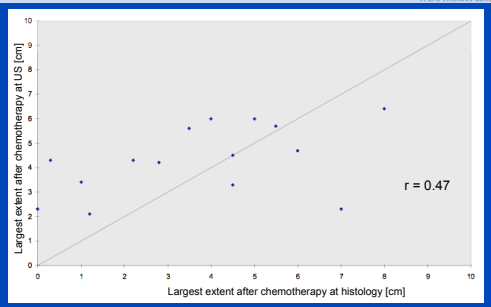

Klein SK medical dissertation 2002

MRI vs. histology

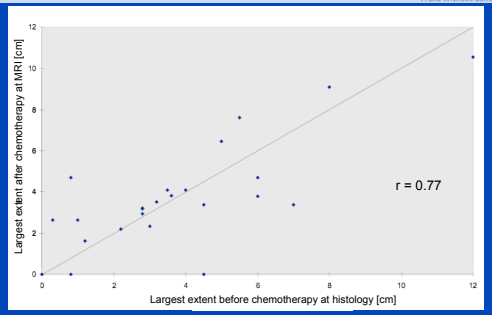

Klein SK medical dissertation 2002



ESTRO School

GTV and CTV for Breast. Delineation of OAR in breast cancer

Dra Meritxell Arenas Prat, MD, PhD
Radiotherapy Oncology Department,
Hospital Universitari Sant Joan de Reus,
University Rovira i Virgili, Spain

Hospital Universitari Sant Joan REUS

TVD Budapest

4-7 October, 2015

ESTRO School

- **Introduction**

- Indications and CTV:
  - Whole Breast
  - Boost
  - Chest wall
  - Regional nodes
    - L4, L3, L2, L1, IM, Rotter

- Organs at risk and constraints

- Margins CTV → PTV OAR → PRV

- Conclusions

ESTRO School

WHEN WE CHOOSE RT TREATMENT ....

- Correct delineation of volumes
- An homogeneous coverage of PTV
- Avoiding organs at risk to reduce acute and late complications

ESTRO School

VOLUME DELINEATION: VARIABILITY!!!

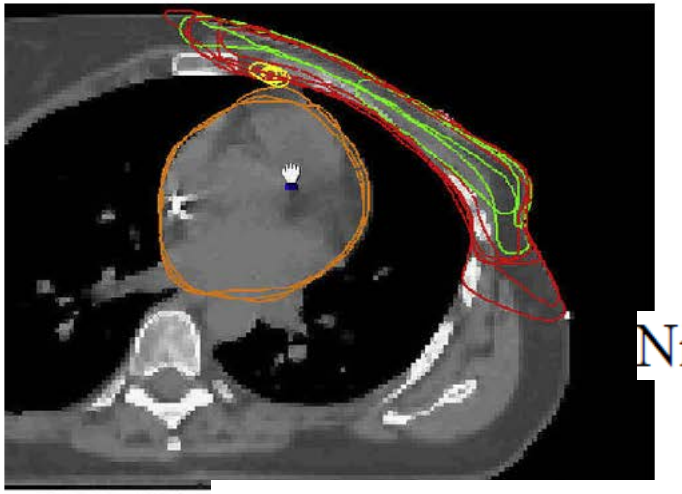

Variability of target and normal structure delineation for breast-cancer radiotherapy: a RTOG multi-institutional and multi-observer study

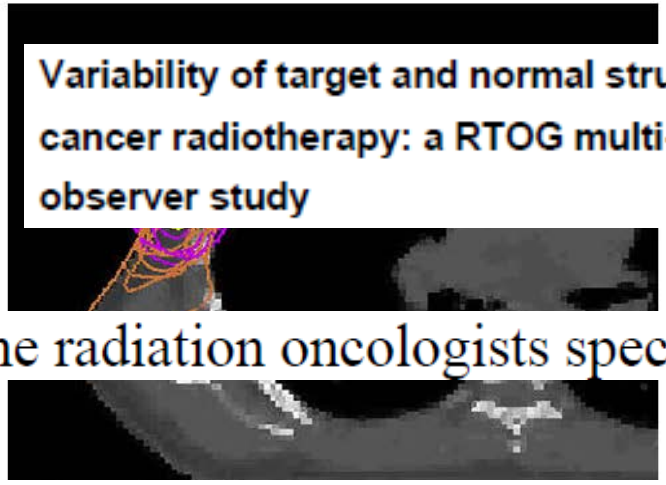

Nine radiation oncologists specializing in breast RT

Conclusions—The differences in target and OAR delineation for breast irradiation between institutions/observers appear to be clinically and dosimetrically significant. A systematic consensus is highly desirable, particularly in the era of IMRT/IGRT.

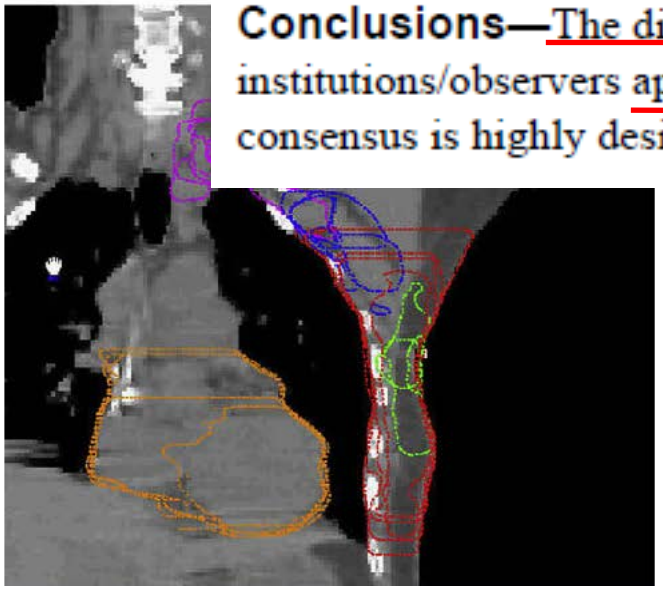

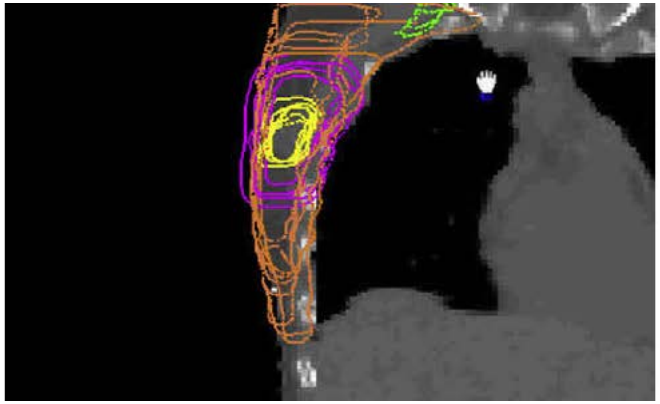

X. Allen Li. Int. J. Radiation Oncology Biol. Phys., Vol. 73, No. 3, pp. 944–951, 2009

ESTRO School

VOLUME DELINEATION: VARIABILITY!!!

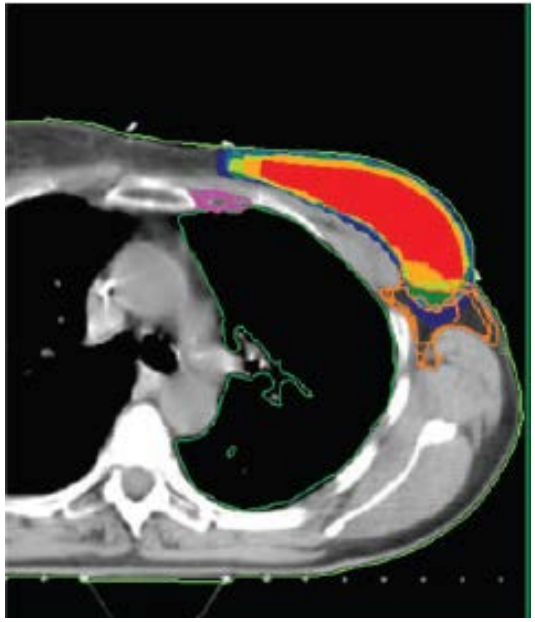

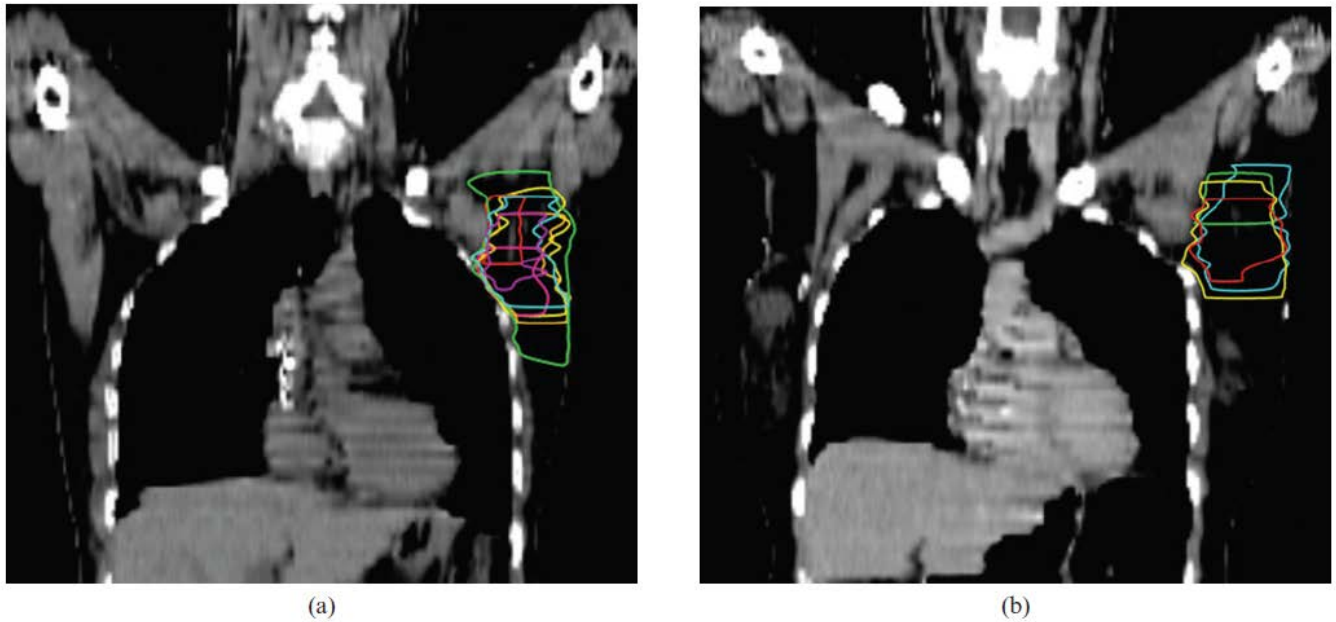

(a) (b)

Figure 3. Practical example of axillary delineation before and after continuing medical education (CME) and using the simplified practical rules: ''how to delineate the lymph node areas?''. (a) Before training; (b) after training.

It's very important to know the individual anatomy of the patients, their position and the large variability in the depth of nodes

The British Journal of Radiology, 82 (2009), 595–599

Anatomical, clinical and radiological delineation of target volumes in breast cancer radiotherapy planning: individual variability, questions and answers

P CASTRO PENA, MD, Y M KIROVA, MD, F CAMPANA, MD, R DENDALE, MD, M A BOLLET, MD, N FOURNIER-BIDOZ, PhD and A FOURQUET, MD

ESTRO School

BREAST ANATOMY

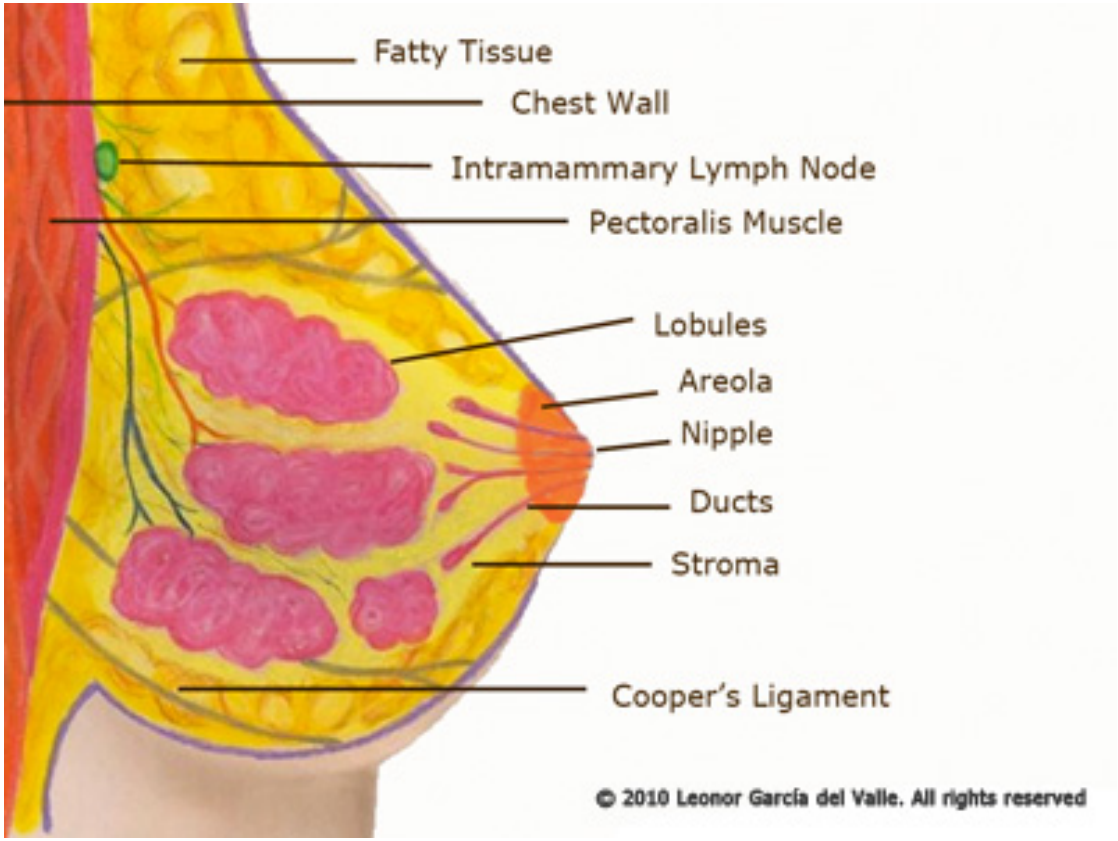

Limits:

2nd costal arch
6th-7th rib cartilage
Anterior axillary line
Sternal border

ESTRO School

BREAST ANATOMY

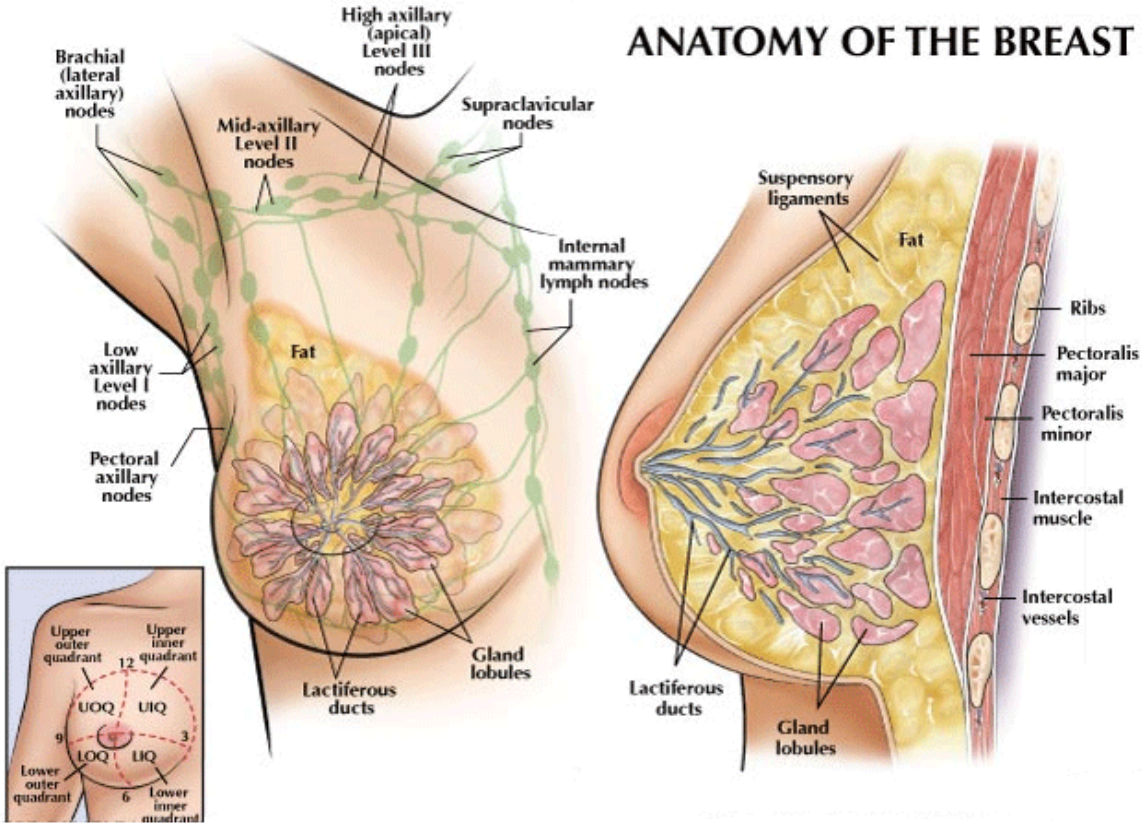

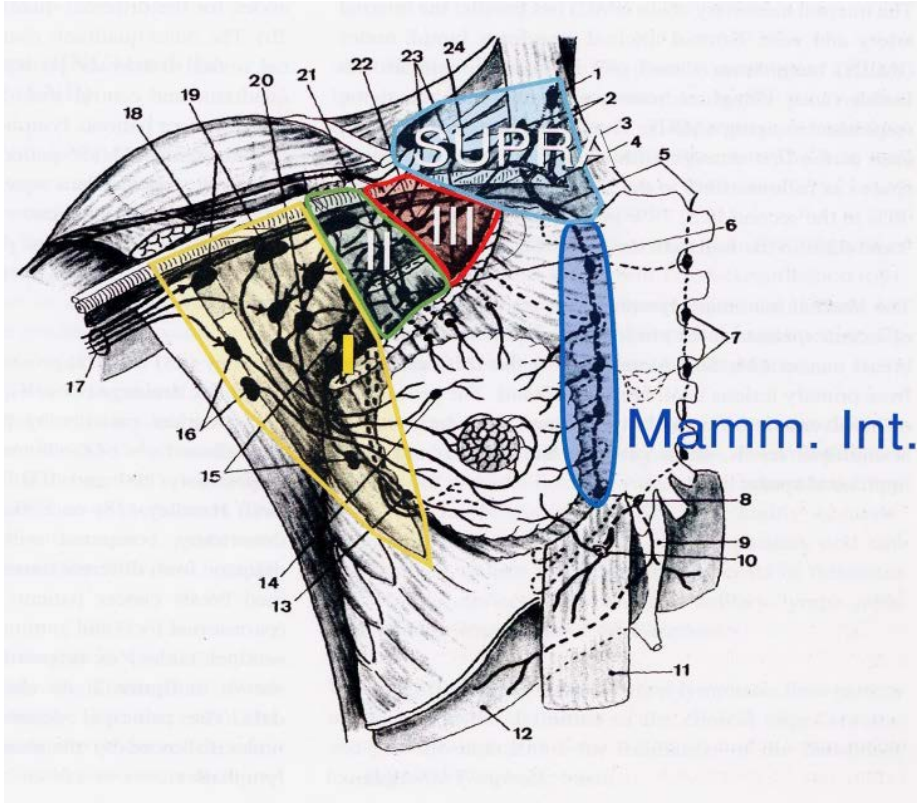

ESTRO School

BREAST ANATOMY

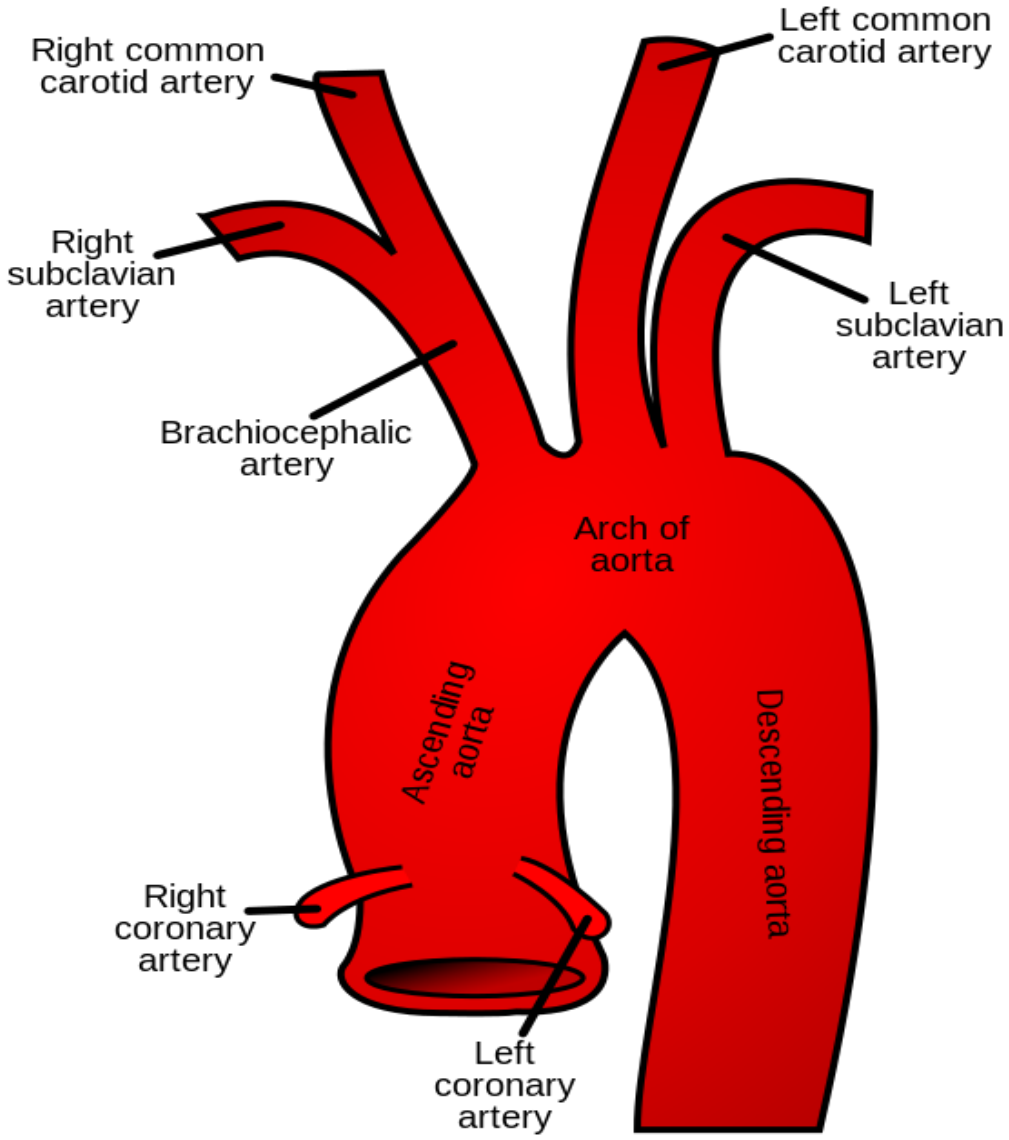

ESTRO School

BREAST ANATOMY

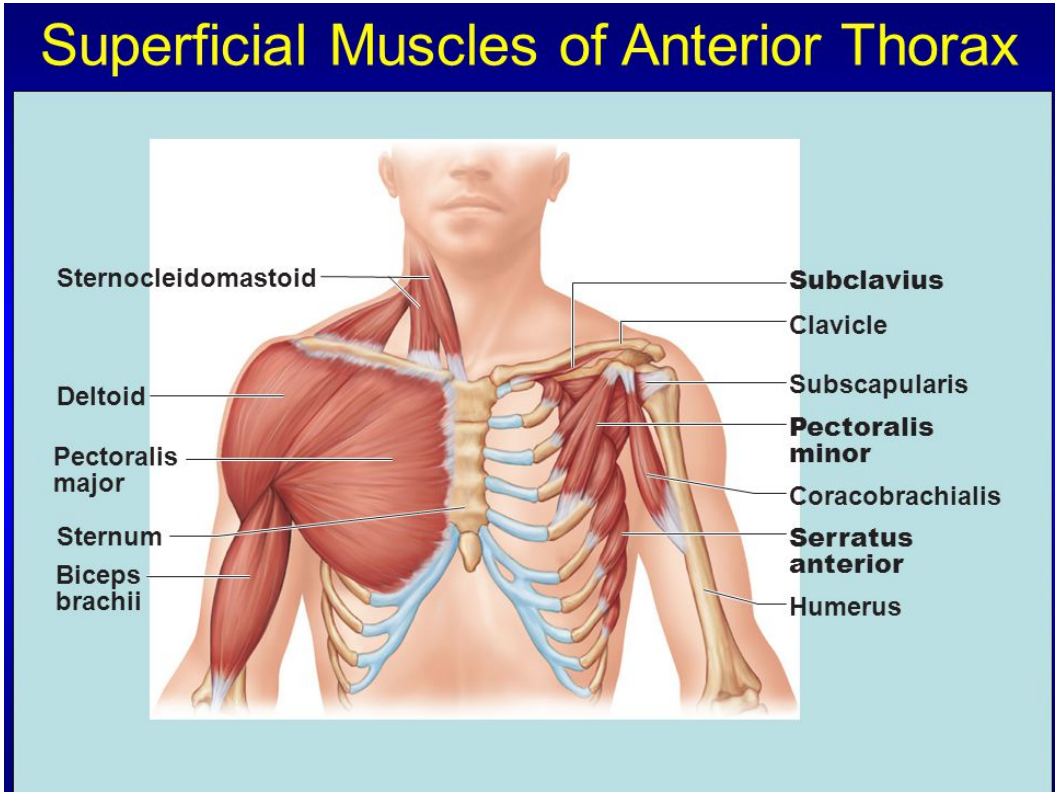

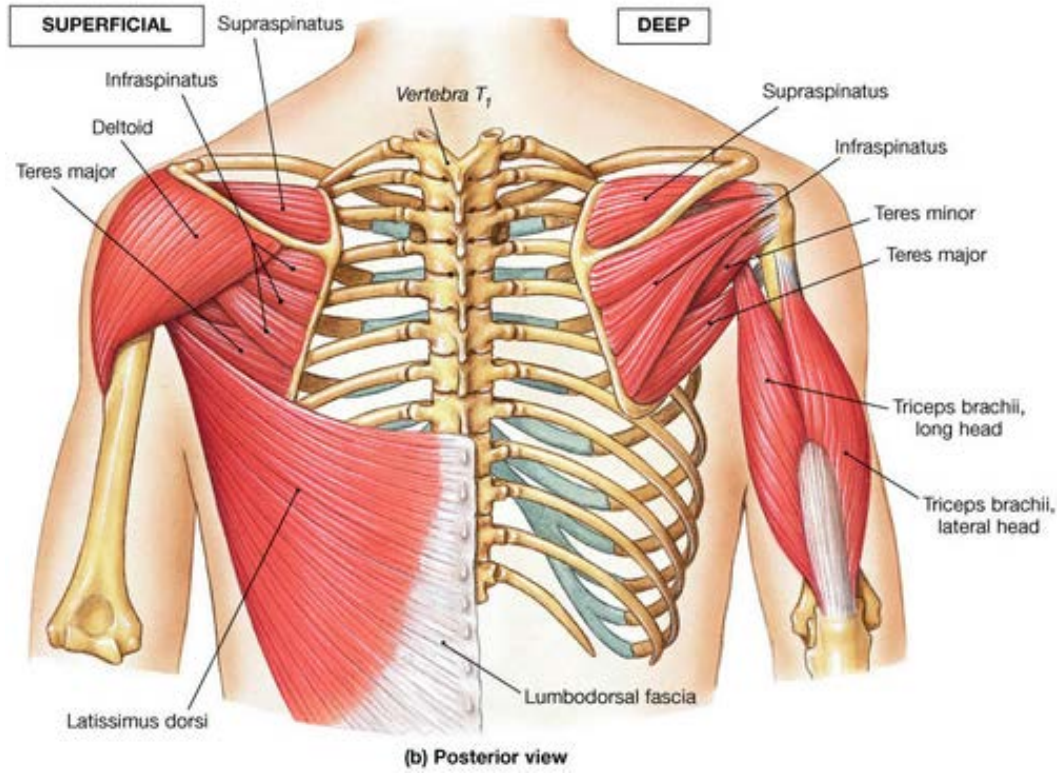

BREAST ANATOMY

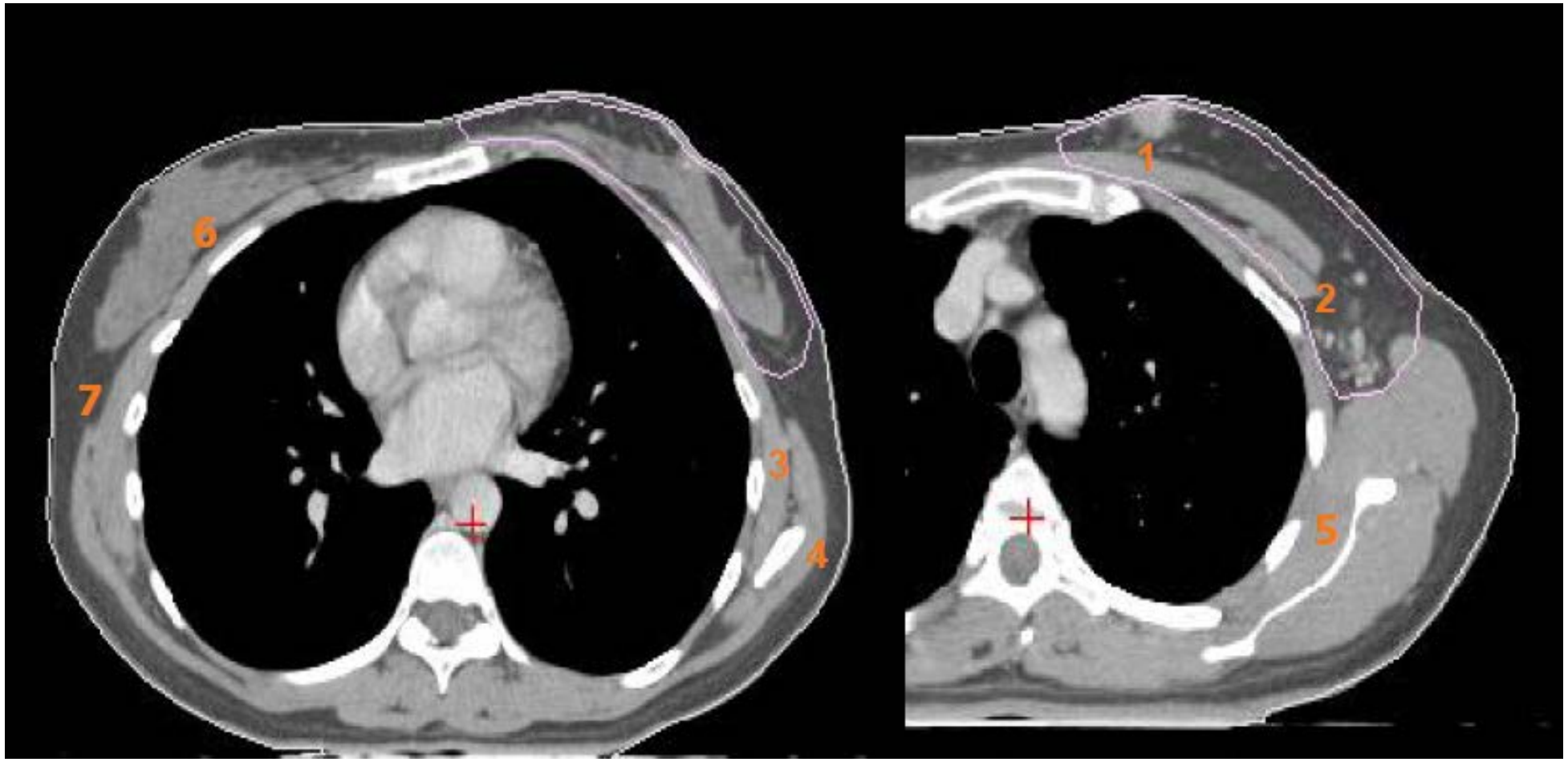

1 pectoralis major. 2 pectoralis minor. 3 serratus anterior.

4 latissimus dorsi. 5 subscapularis. 6 mammary gland. 7 fat

ESTRO School

BREAST ATLAS CAN HELP US!!!

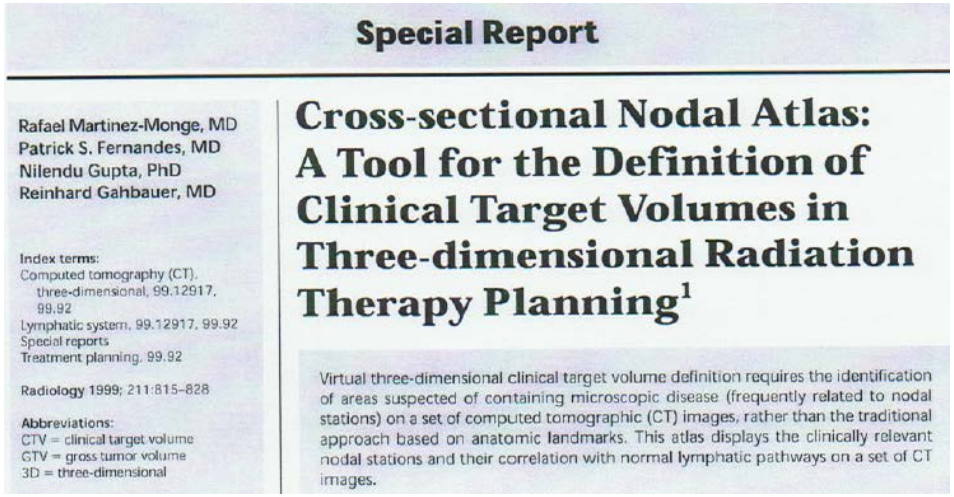

Special Report

Rafael Martinez-Monge, MD
Patrick S. Fernandes, MD
Nilendu Gupta, PhD
Reinhard Gahbauer, MD

Index terms:
Computed tomography (CT), three-dimensional, 99.12917, 99.92
Lymphatic system, 99.12917, 99.92
Special reports
Treatment planning, 99.92

Radiology 1999; 211:815–828

Abbreviations:
CTV = clinical target volume
GTV = gross tumor volume
3D = three-dimensional

Cross-sectional Nodal Atlas: A Tool for the Definition of Clinical Target Volumes in Three-dimensional Radiation Therapy Planning[1]

Virtual three-dimensional clinical target volume definition requires the identification of areas suspected of containing microscopic disease (frequently related to nodal stations) on a set of computed tomographic (CT) images, rather than the traditional approach based on anatomic landmarks. This atlas displays the clinically relevant nodal stations and their correlation with normal lymphatic pathways on a set of CT images.

1999

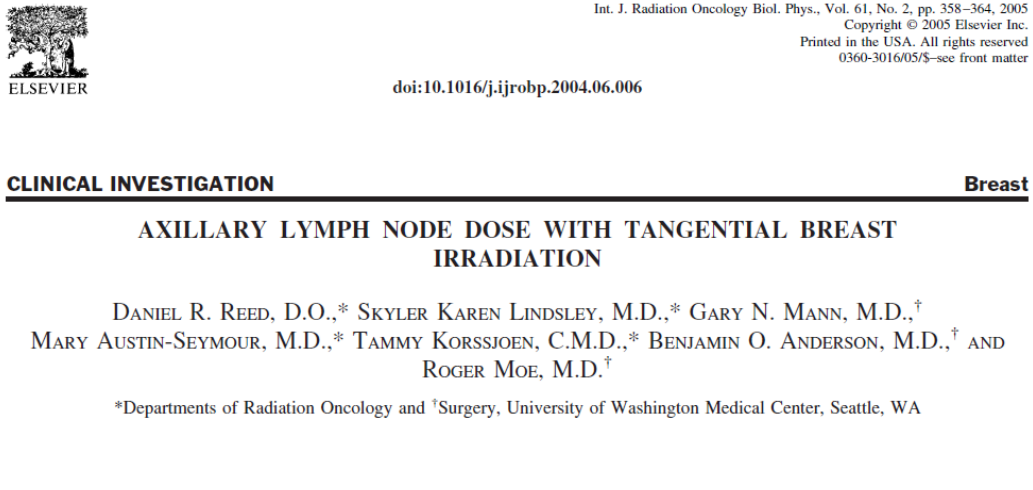

ELSEVIER

Int. J. Radiation Oncology Biol. Phys., Vol. 61, No. 2, pp. 358–364, 2005
Copyright © 2005 Elsevier Inc.
Printed in the USA. All rights reserved
0360-3016/05/$–see front matter

doi:10.1016/j.ijrobp.2004.06.006

CLINICAL INVESTIGATION — Breast

AXILLARY LYMPH NODE DOSE WITH TANGENTIAL BREAST IRRADIATION

DANIEL R. REED, D.O.,* SKYLER KAREN LINDSLEY, M.D.,* GARY N. MANN, M.D.,† MARY AUSTIN-SEYMOUR, M.D.,* TAMMY KORSSJOEN, C.M.D.,* BENJAMIN O. ANDERSON, M.D.,† AND ROGER MOE, M.D.†

*Departments of Radiation Oncology and †Surgery, University of Washington Medical Center, Seattle, WA

2000

Target Volume Definition and Target Conformal Irradiation Technique for Breast Cancer Patients

Ion Christian Kiricuta, Uwe Götz, Franz Schwab, Martin Fehn and Heinz Helmut Neumann

Acta Oncologica Vol. 39, No. 3, pp. 429–436, 2000

2000

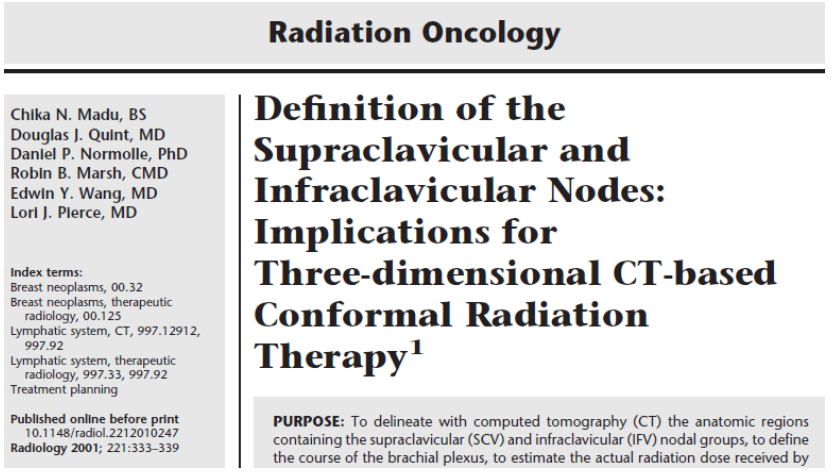

Radiation Oncology

Chika N. Madu, BS
Douglas J. Quint, MD
Daniel P. Normolle, PhD
Robin B. Marsh, CMD
Edwin Y. Wang, MD
Lori J. Pierce, MD

Index terms:
Breast neoplasms, 00.32
Breast neoplasms, therapeutic radiology, 00.125
Lymphatic system, CT, 997.12912, 997.92
Lymphatic system, therapeutic radiology, 997.33, 997.92
Treatment planning

Published online before print 10.1148/radiol.2212010247
Radiology 2001; 221:333–339

Definition of the Supraclavicular and Infraclavicular Nodes: Implications for Three-dimensional CT-based Conformal Radiation Therapy[1]

PURPOSE: To delineate with computed tomography (CT) the anatomic regions containing the supraclavicular (SCV) and infraclavicular (IFV) nodal groups, to define the course of the brachial plexus, to estimate the actual radiation dose received by

2001

ESTRO School

BREAST ATLAS CAN HELP US!!!

ELSEVIER

Radiotherapy and Oncology 71 (2004) 287–295

RADIOTHERAPY & ONCOLOGY
JOURNAL OF THE EUROPEAN SOCIETY FOR THERAPEUTIC RADIOLOGY AND ONCOLOGY

www.elsevier.com/locate/radonline

Loco-regional conformal radiotherapy of the breast: delineation of the regional lymph node clinical target volumes in treatment position

Ivessa M. Dijkema[a,*], Pieter Hofman[a], Cornelis P.J. Raaijmakers[a], Jan J. Lagendijk[a], Jan J. Battermann[a], Berend Hillen[b]

[a]*Department of Radiotherapy, University Medical Centre Utrecht, Heidelberglaan 100, 3584 CX Utrecht, The Netherlands*
[b]*Department of Functional Anatomy, University Medical Centre Utrecht, Heidelberglaan 100, 3584 CX Utrecht, The Netherlands*

Received 22 January 2003; received in revised form 14 February 2004; accepted 26 February 2004

2004

SIMULACIÓN VIRTUAL Y RADIOTERAPIA CONFORMADA 3D

Guía práctica para la delimitación de volúmenes

Hospital Ramón y Cajal

CAPITULO 10

TUMORES DE MAMA

Sonsoles Sancho, Ángel Montero, Sofía Córdoba

The British Journal of Radiology, 83 (2010), 683–686

Simplified rules for everyday delineation of lymph node areas for breast cancer radiotherapy

[1]Y M KIROVA, MD, [1]P CASTRO PENA, MD, [1]R DENDALE, MD, [2]V SERVOIS, MD, [1]M A BOLLET, MD, [1]N FOURNIER-BIDOZ, PhD, [1]F CAMPANA, MD and [1]A FOURQUET, MD

2010

ESTRO School

BREAST ATLAS CAN HELP US!!!

Original article

A simplified CT-based definition of the supraclavicular and infraclavicular nodal volumes in breast cancer

Règles de délinéation simplifiées des volumes ganglionnaires sus- et sous-claviculaires dans le traitement des cancers du sein

I. Atean[a,*,b], Y. Pointreau[a,c], L. Ouldamer[c,d], C. Monghal[e], A. Bougnoux[a], G. Bera[a], I. Barillot[a,c]

Cancer/Radiothérapie 17 (2013) 39–43

Nodes

2013

Acta Oncologica, 2013; 52: 703–710

informa
healthcare

Breast and Nodes

ORIGINAL ARTICLE: ACTA ONCOLOGICA JUBILEE ARTICLE

Delineation of target volumes and organs at risk in adjuvant radiotherapy of early breast cancer: National guidelines and contouring atlas by the Danish Breast Cancer Cooperative Group

DBCG

2013

METTE H. NIELSEN[1], MARTIN BERG[2], ANDERS N. PEDERSEN[3], KAREN ANDERSEN[4],

http://www.dbcg.dk/PDF%20Filer/DBCG_CT_contouring_Atlas.pdf

ESTRO School

BREAST ATLAS CAN HELP US!!!

https://www.abro-bvro.be/index.php?option=com_attachments&task=download&id=105

Radiotherapy and Oncology 114 (2015) 11–16

Contents lists available at ScienceDirect

Radiotherapy and Oncology

journal homepage: www.thegreenjournal.com

Nodes

PROCAB

Guidelines

Vessel based delineation guidelines for the elective lymph node regions in breast cancer radiation therapy – PROCAB guidelines

Karolien Verhoeven [a,*], Caroline Weltens [a], Vincent Remouchamps [b], Khalil Mahjoubi [b], Liv Veldeman [c], Benoit Lengele [d], Eszter Hortobagyi [a], Carine Kirkove [d]

[a] University Hospitals Leuven/KU Leuven; [b] Clinique Sainte Elisabeth (AMPR), Namur; [c] Ghent University Hospital; and [d] Catholic University of Louvain, Brussels, Belgium

2015

Nodes

2015

International Journal of Radiation Oncology biology • physics

www.redjournal.org

Clinical Investigation

Delineation of Supraclavicular Target Volumes in Breast Cancer Radiation Therapy

Lindsay C. Brown, MD,* Felix E. Diehn, MD,†
Judy C. Boughey, MD,‡ Stephanie K. Childs, MD,*
Sean S. Park, MD, PhD,* Elizabeth S. Yan, MD,*
Ivy A. Petersen, MD,* and Robert W. Mutter, MD*

*Departments of *Radiation Oncology, †Radiology, and ‡Surgery, Mayo Clinic, Rochester, Minnesota*

Received Sep 8, 2014, and in revised form Jan 6, 2015. Accepted for publication Feb 12, 2015.

Supraclavicular and infraclavicular lymph node delineation in breast cancer patients: a proposal deriving from a comparative study

Francesca Cucciarelli[1], Youlia M. Kirova[2], Isabella Palumbo[3], Cynthia Aristei[3]

Tumori 2015; 00(00): 000-000
DOI: 10.5301/tj.5000330

ORIGINAL RESEARCH ARTICLE

2015

ESTRO School

BREAST ATLAS CAN HELP US!!!

ESTRO

Radiotherapy and Oncology 114 (2015) 3–10

Contents lists available at ScienceDirect

Radiotherapy and Oncology

journal homepage: www.thegreenjournal.com

ESTRO consensus guidelines

ESTRO consensus guideline on target volume delineation for elective radiation therapy of early stage breast cancer

Birgitte V. Offersen [a,*], Liesbeth J. Boersma [b], Carine Kirkove [c], Sandra Hol [d], Marianne C. Aznar [e], Albert Biete Sola [f], Youlia M. Kirova [g], Jean-Philippe Pignol [h], Vincent Remouchamps [i], Karolien Verhoeven [j], Caroline Weltens [j], Meritxell Arenas [k], Dorota Gabrys [l], Neil Kopek [m], Mechthild Krause [n], Dan Lundstedt [o], Tanja Marinko [p], Angel Montero [q], John Yarnold [r], Philip Poortmans [s]

2015

Breast and Nodes

RTOG



Breast and Nodes

ESTRO School

Volumes can be treated with RT

- Whole breast. Boost to lumpectomy. Partial Breast irradiation
- Chest wall
- Regional Nodes:
  - L4 (SC), L3, L2, L1
  - Internal Mammary (IM)
  - Rotter Nodes

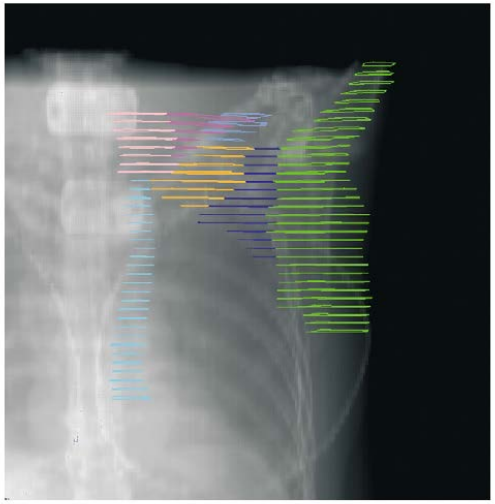

Fig. 3. Digitally reconstructed radiograph (DRR) of CT-images with regional LN CTVs (except for the interpectoral LN CTV) (CT-images from same patient as in Fig. 2).

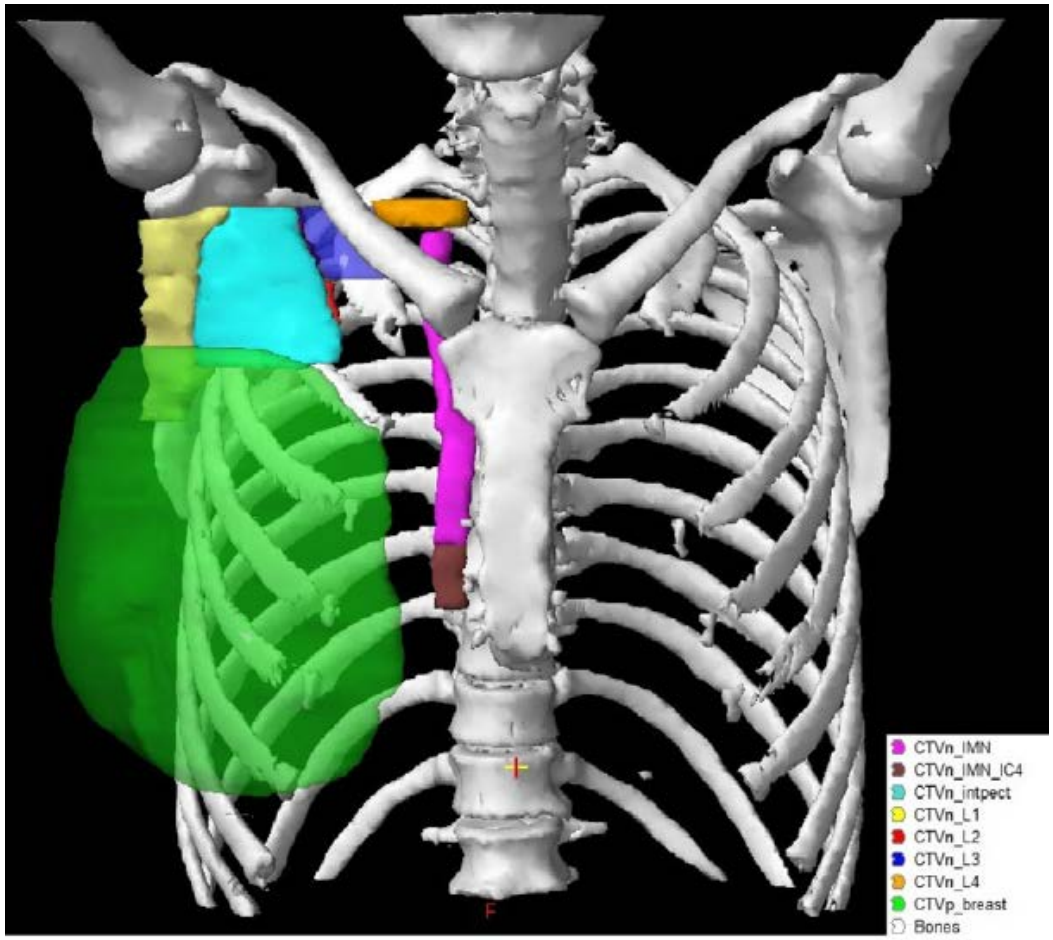

ESTRO School

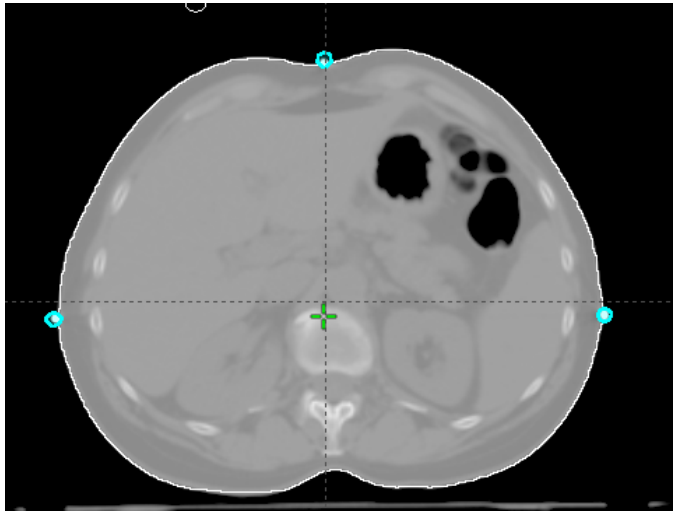

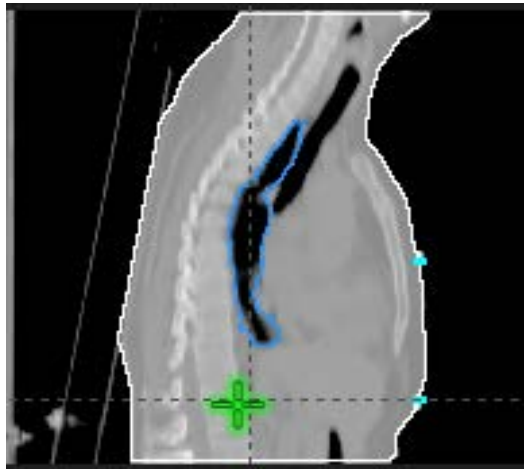

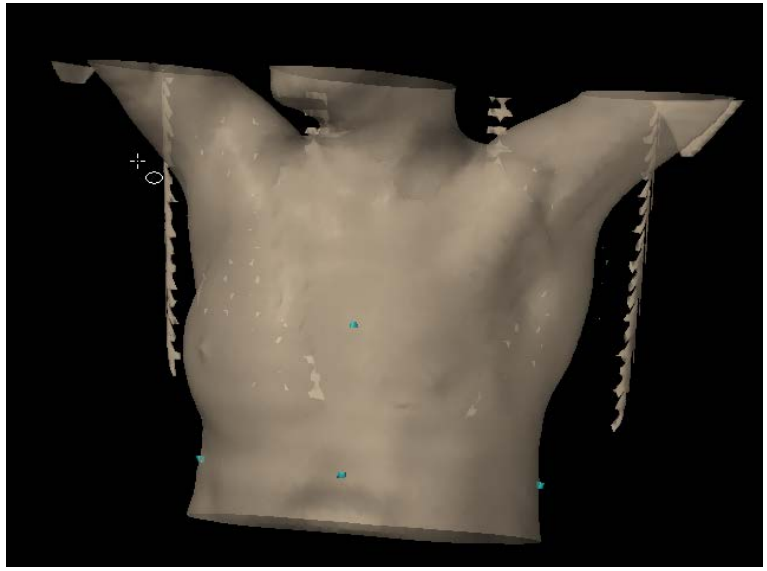

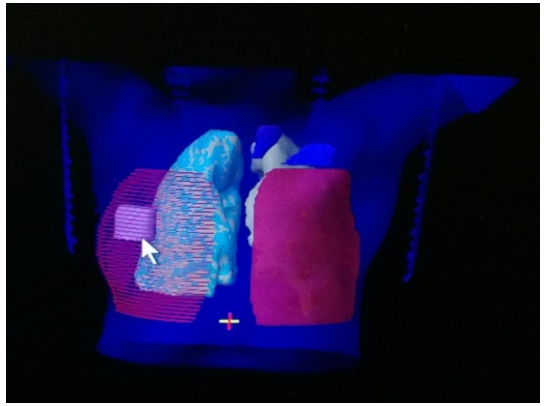

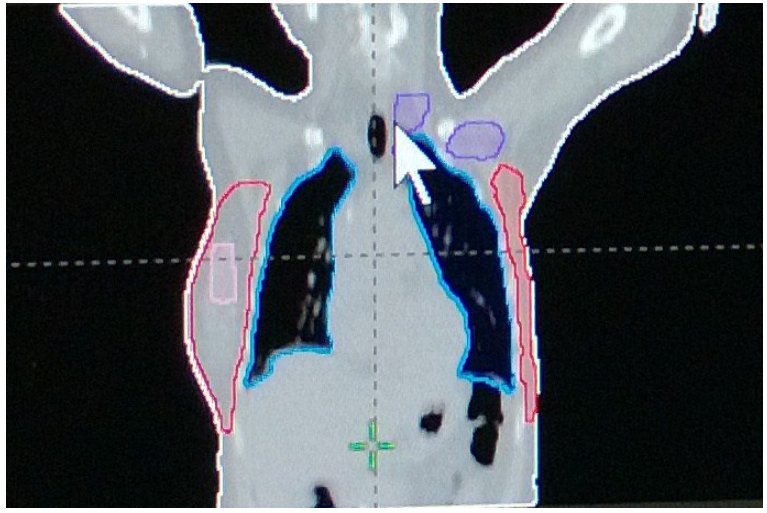

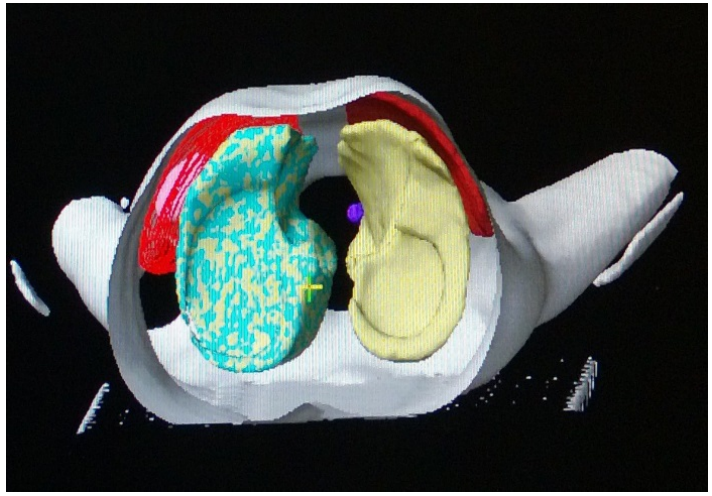

ESTRO School

- Introduction
- **Indications and CTV:**
  - **Whole Breast**
  - Boost
  - Chest wall
  - Regional nodes
    - L4, L3, L2, L1, IM, Rotter
- Organs at risk and constraints
- Margins CTV → PTV OAR → PRV
- Conclusions

ESTRO School

BREAST CTV: INDICATIONS

- RT after breast conservative surgery is indicated for "all" cases
- Conservative surgery and RT is equivalent to a mastectomy in terms of DFS in stages I-II
- The aim is:
  - ↓ local relapse
  - ↑ DFS
  - Minimum side effects (lung, heart, skin)
  - Good cosmetic results

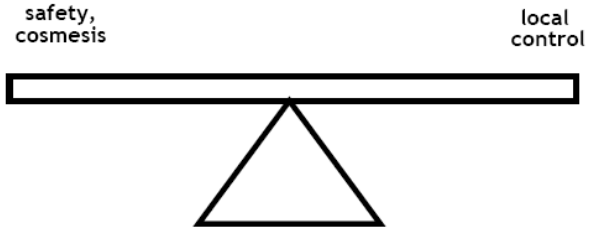

ESTRO School

Effect of radiotherapy after breast-conserving surgery on 10-year recurrence and 15-year breast cancer death: meta-analysis of individual patient data for 10 801 women in 17 randomised trials

Lancet 2011; 378: 1707–16

*Early Breast Cancer Trialists' Collaborative Group (EBCTCG)**

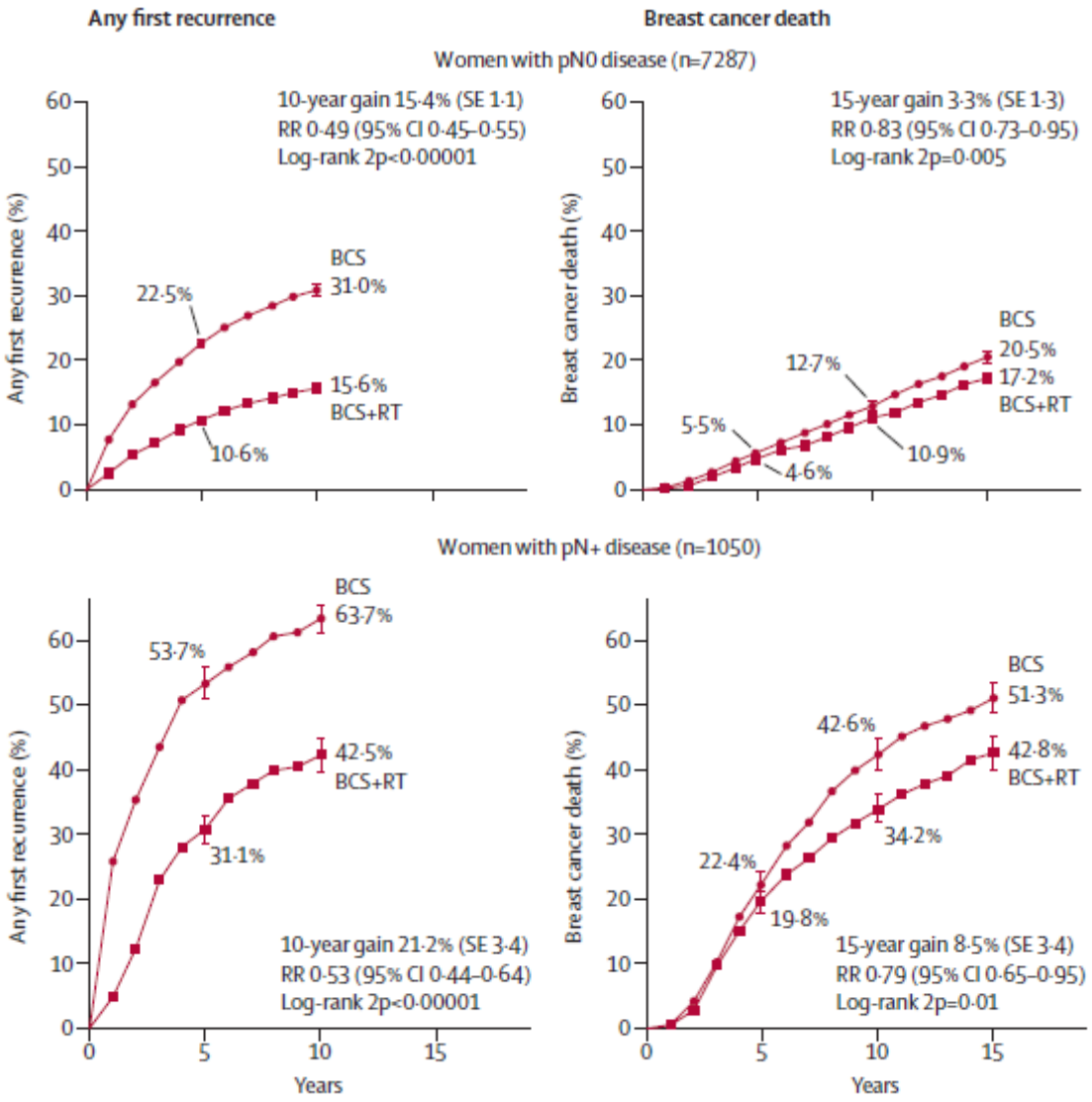

Reduces **recurrence** 31% to 15.4% (N- (7287 pts)) and 63.7% to 42.5% (N+ (1050 pts))

- 10 year gain **15,7% (N-) and 21,2% (N+)**

Reduces breast cancer **mortality** of 20.5% to 17.2% (N-) and 51.3% to 42.8% (N+)

- 15 year gain **3.3% (N-) and 8.5% (N+)**

ESTRO School

BREAST CTV

After conservative surgery, CTV of the entire breast should be considered (unless the patient is a candidate for partial breast irradiation)

It may be useful to mark the scar

It may be useful to mark lateral, lower and upper limits

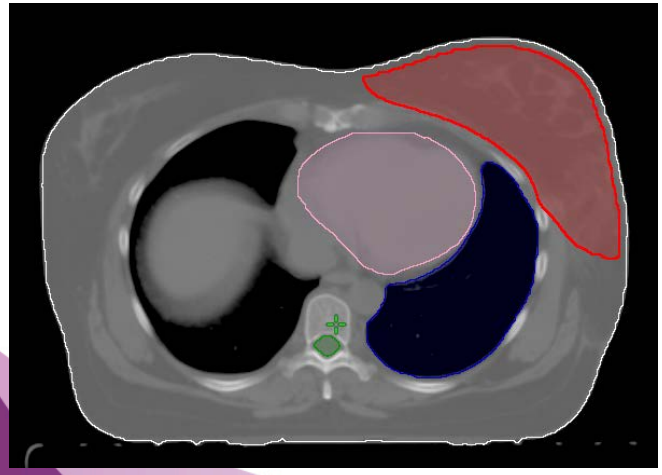

Volume between pectoralis major and 5 mm below the skin

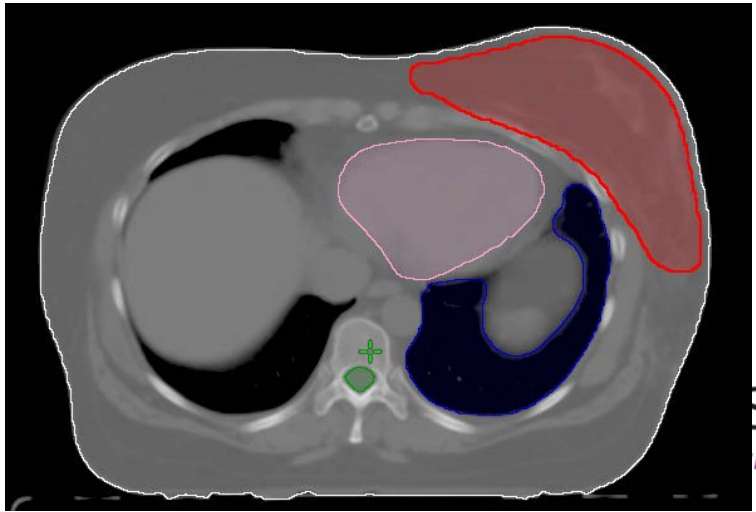

Cranial	Residual breast CTVp_breast	Maximal to the caudal edge of the sterno-clavicular-junction
Clinical Reference + Second rib insertion[a]	Upper border of palpable/ visible breast tissue; maximally up to the inferior edge of the sterno-clavicular joint	
RTOG	ESTRO	DBCG

The cranial boundary is highly variable and it depends on the size of the breast and its ptosis.

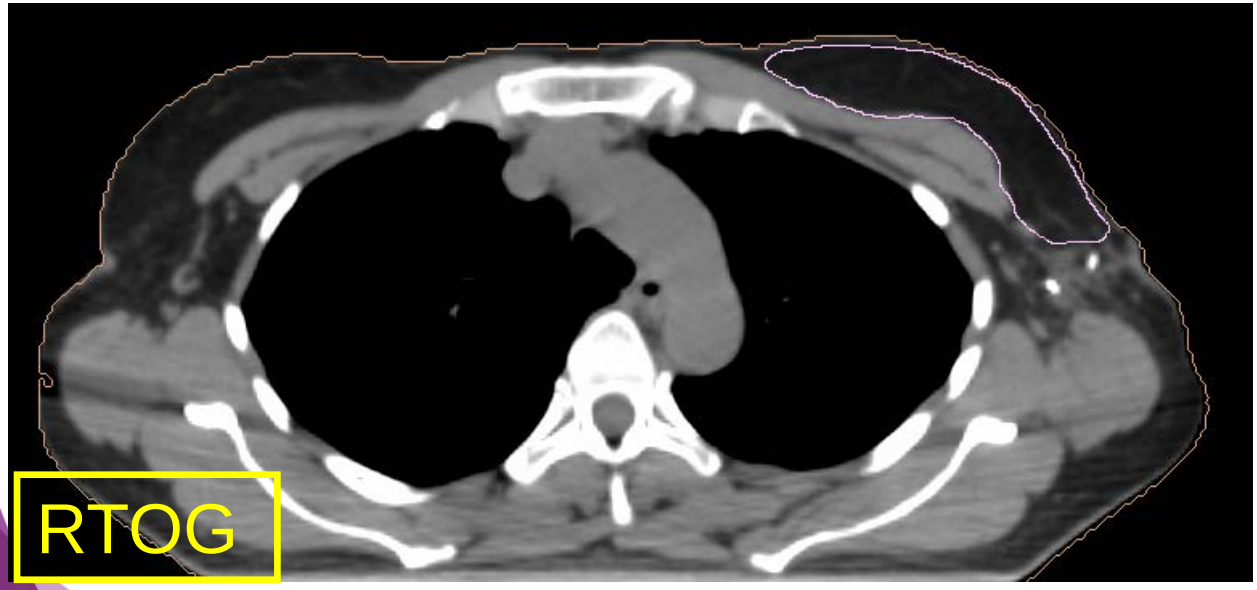

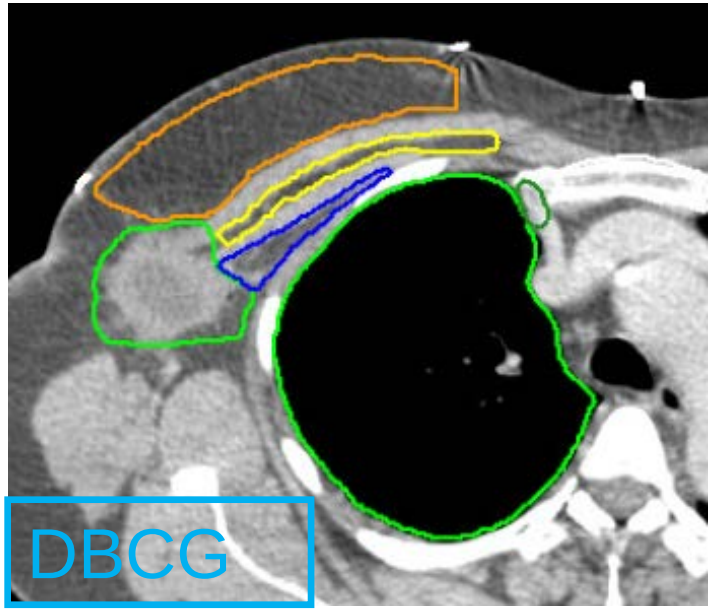

ESTRO School

Caudal

Clinical reference + loss of CT apparent breast

Most caudal CT slice with visible breast

The intermammary sulcus

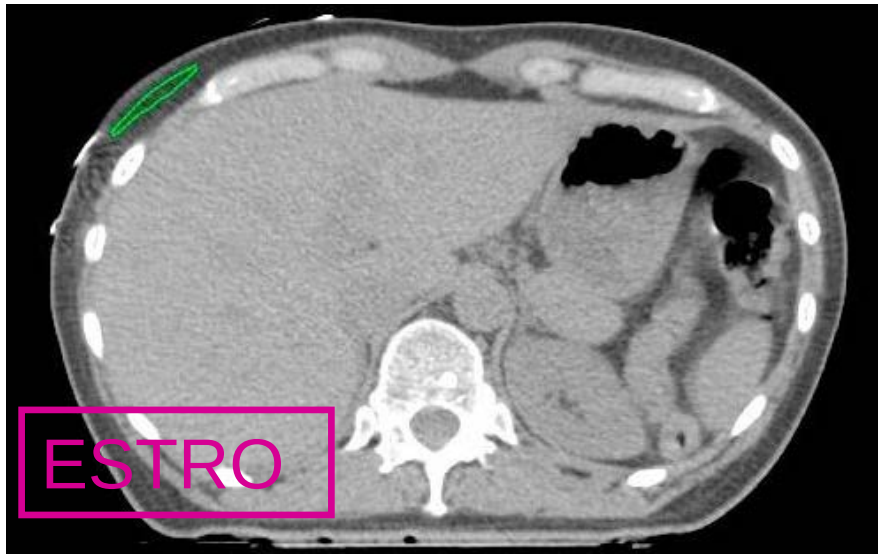

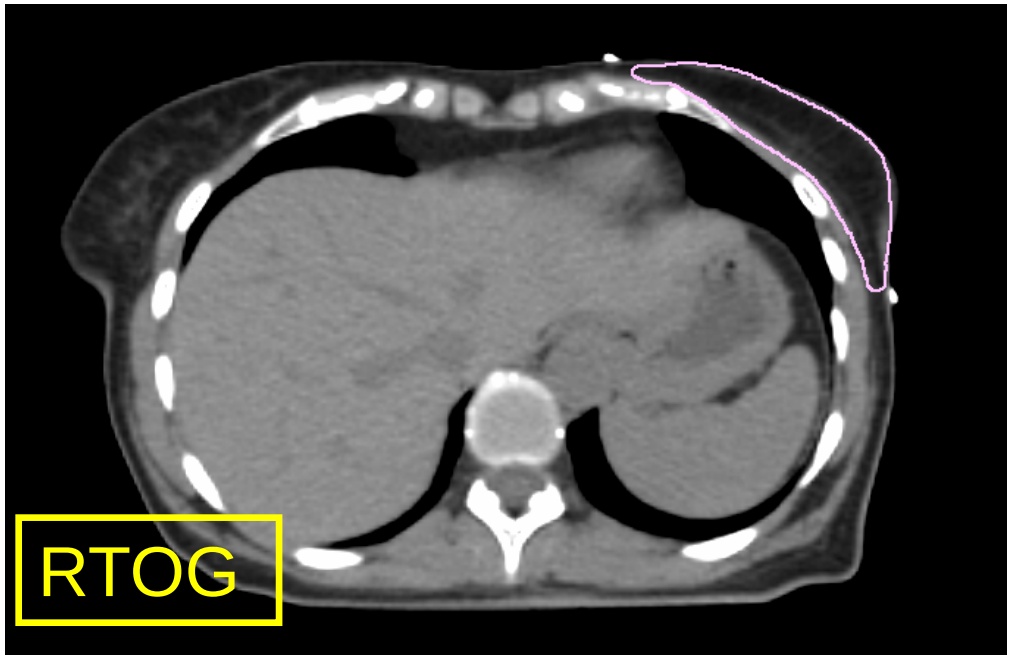

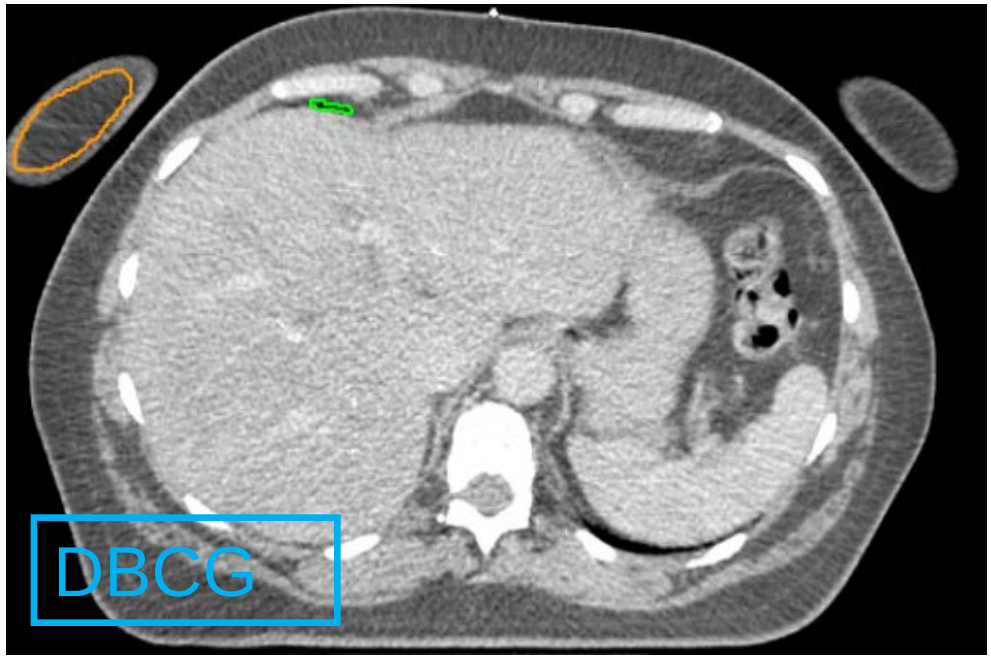

5 mm under skin surface

5 mm below the skin

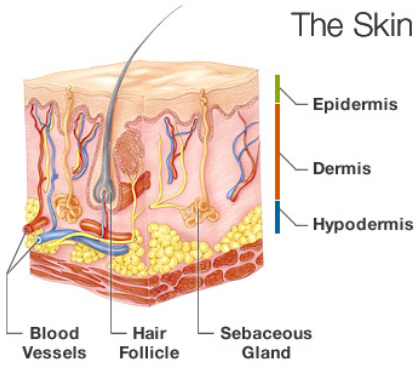

Creating an automatic internal contour can be helpful

RTOG: Skin
ESTRO, DBCG: 5 mm under the skin

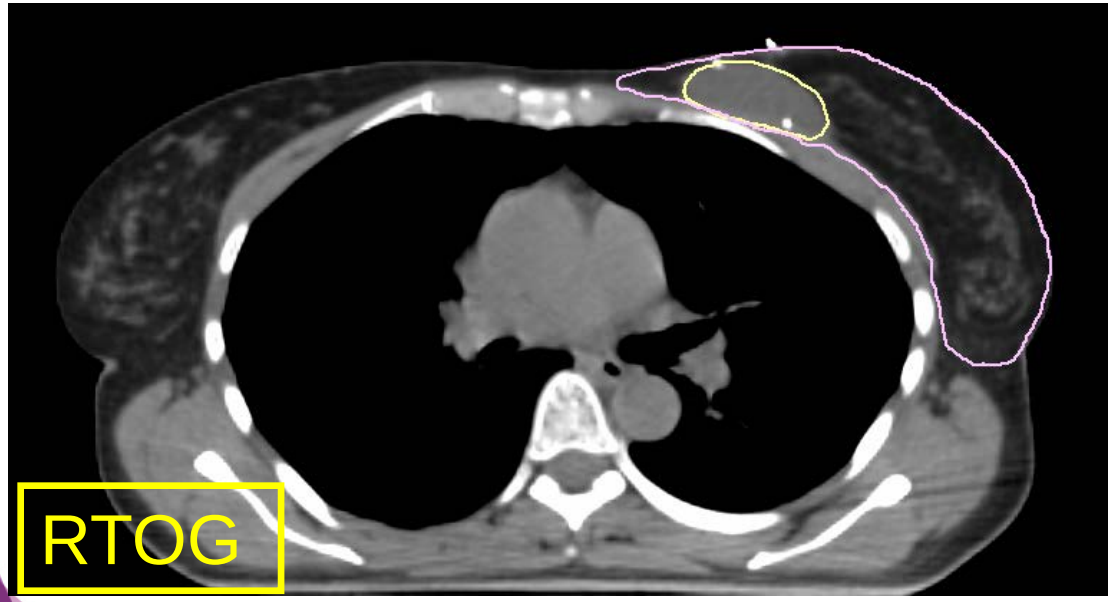

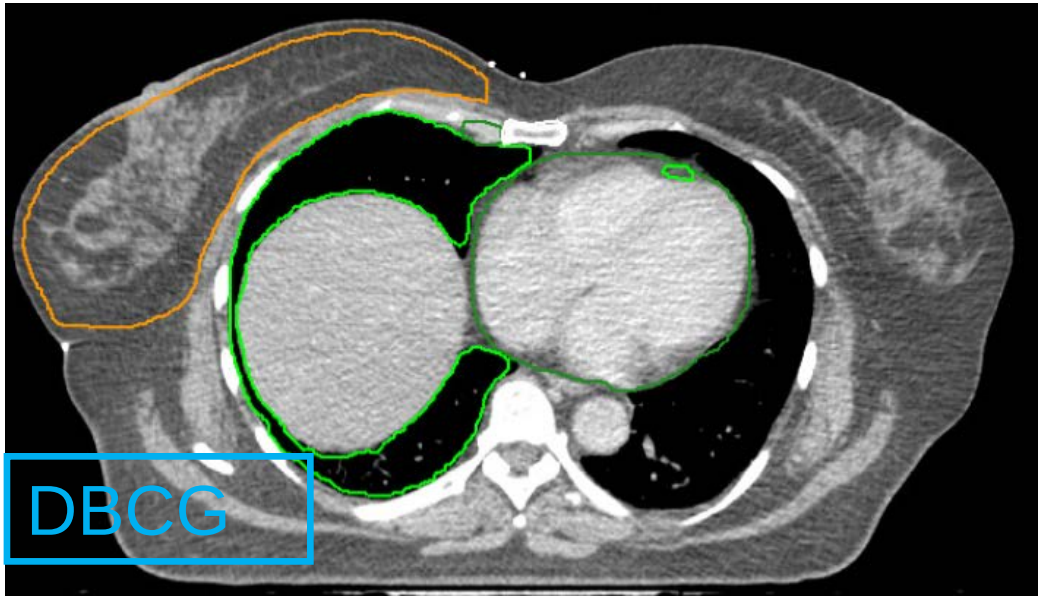

ESTRO School

Posterior	Major pectoral muscle or costae and intercostal muscles where no muscle
Excludes pectoralis muscles, chestwall muscles, ribs	

M. pectoralis major

Some authors recommend including part of the pectoralis major because sometimes there are deep extensions of the breast parenchyma that penetrate the surface portion of it

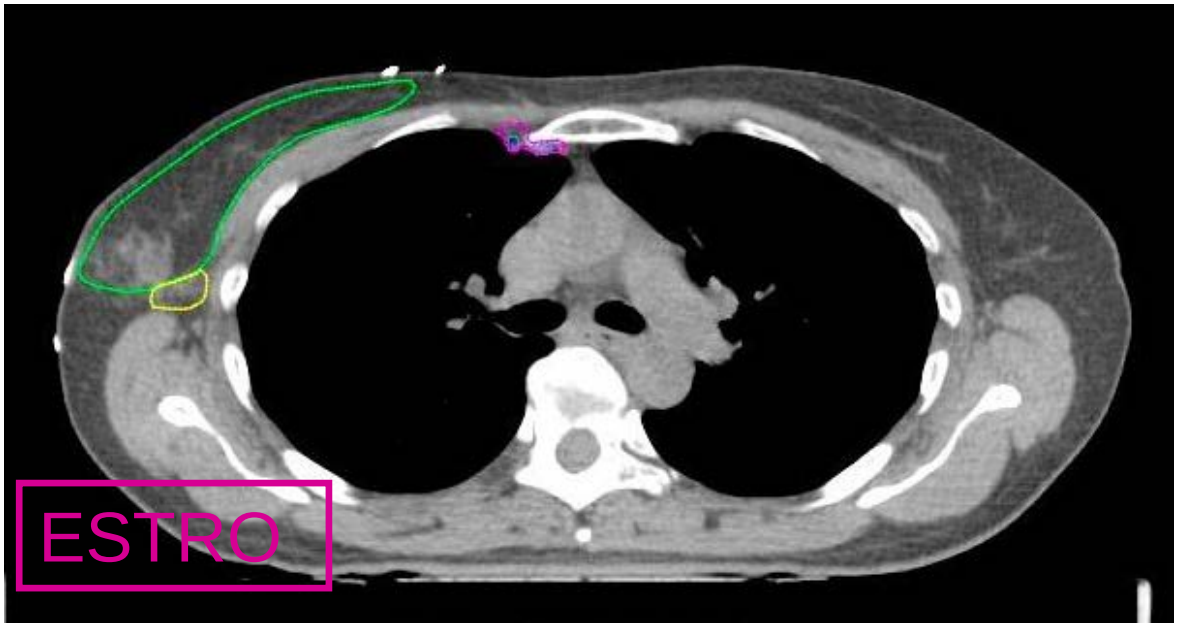

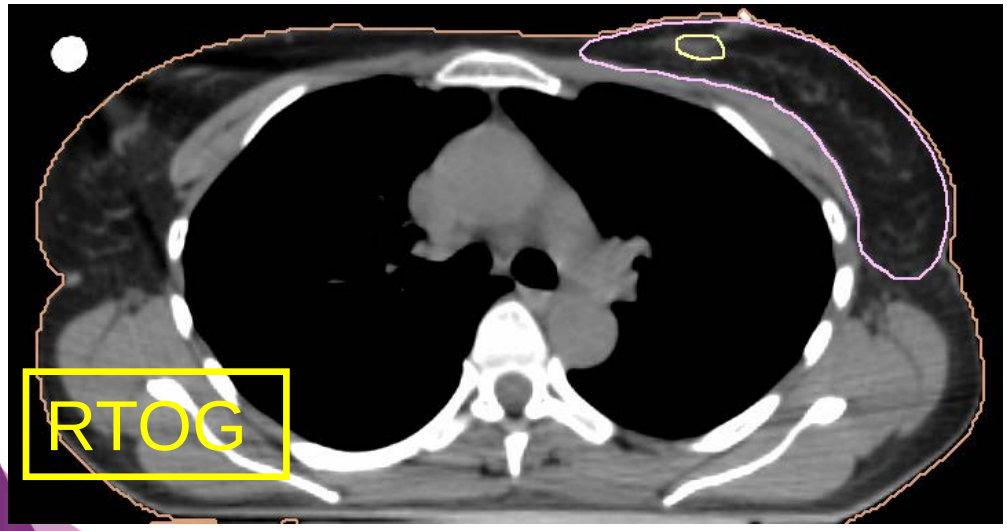

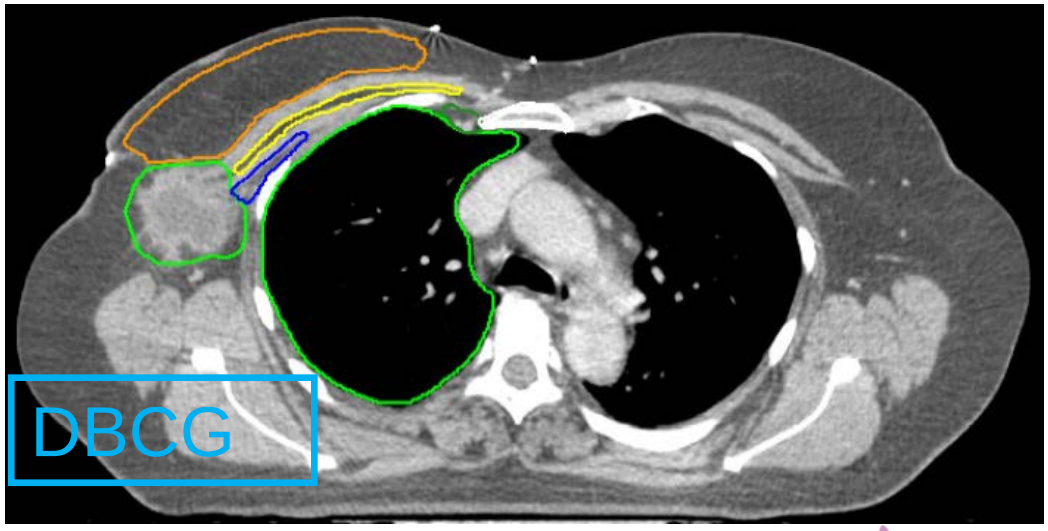

ESTRO School

Lateral
Clinical Reference + mid axillary line typically, excludes latissimus (Lat.) dorsi m. **b**

Lateral breast fold; anterior to the lateral thoracic artery

The axillary vessels (branches from the lateral thoracic vessel)

The lateral boundary is highly variable and it depends on the size of the breast and its ptosis.

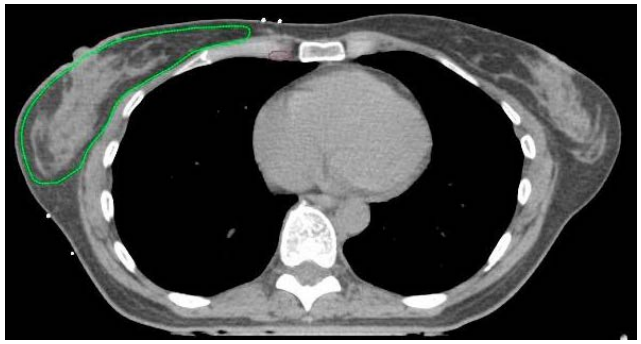

ESTRO

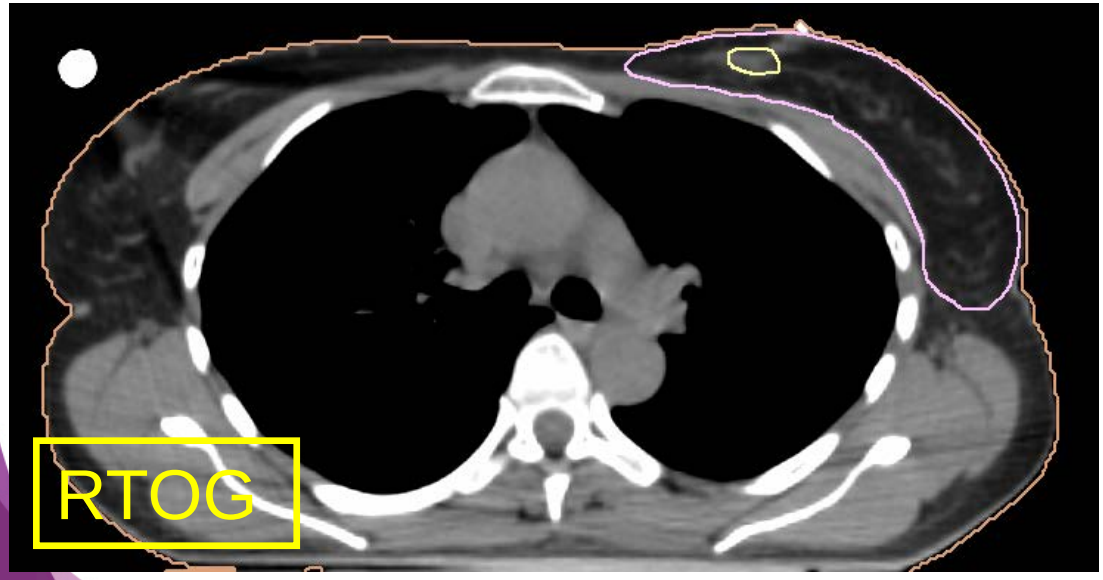

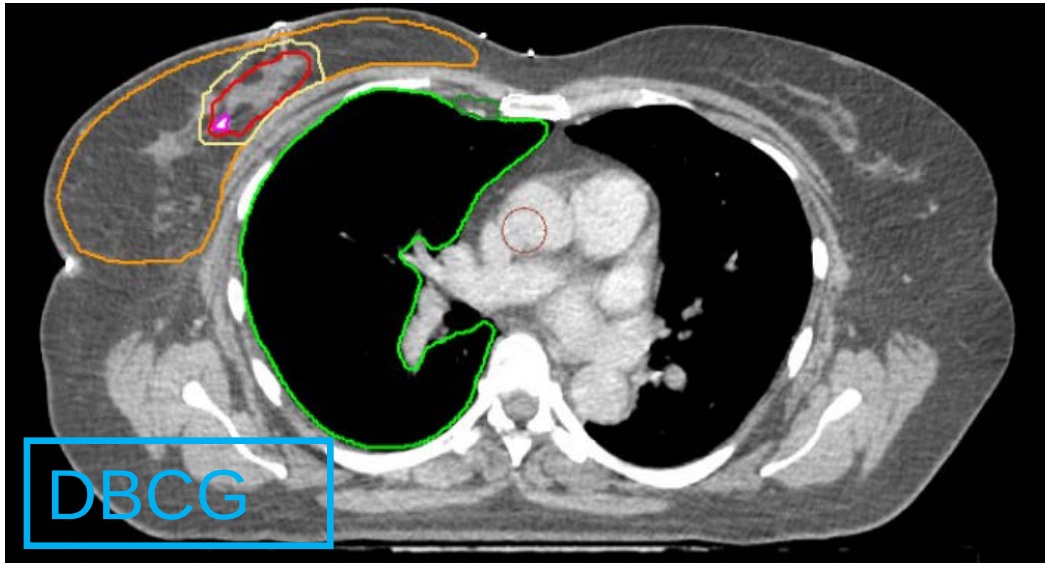

ESTRO School

Medial	Lateral to the medial perforating mammarian vessels; maximally to the edge of the sternal bone	Maximal to the ipsilateral edge of sternum
Sternal-rib junction [c]		

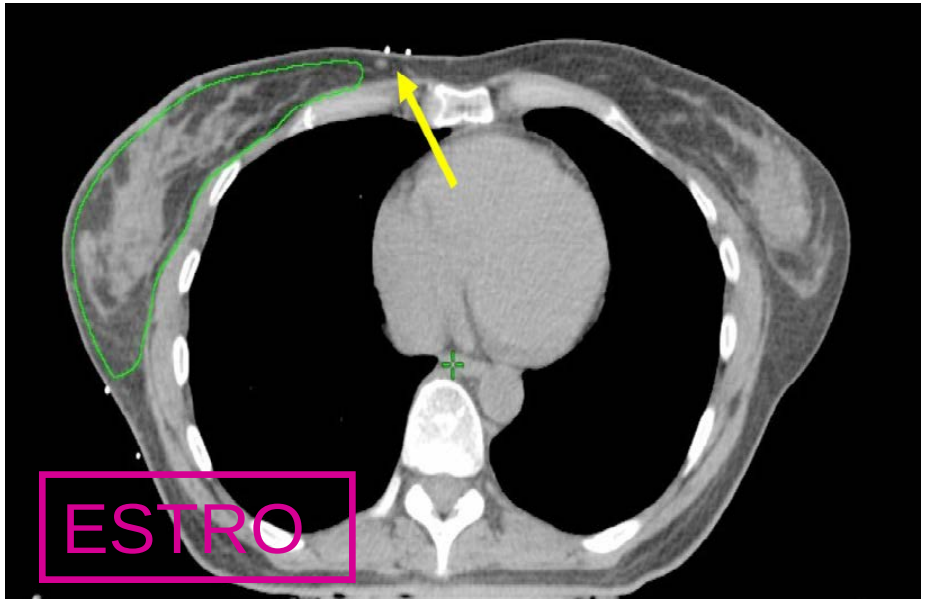

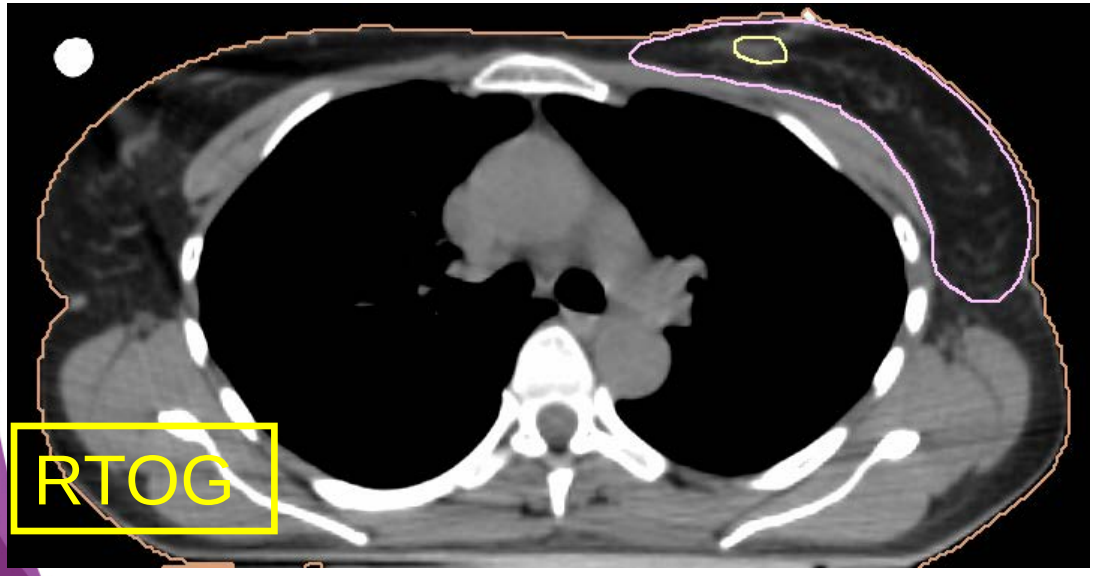

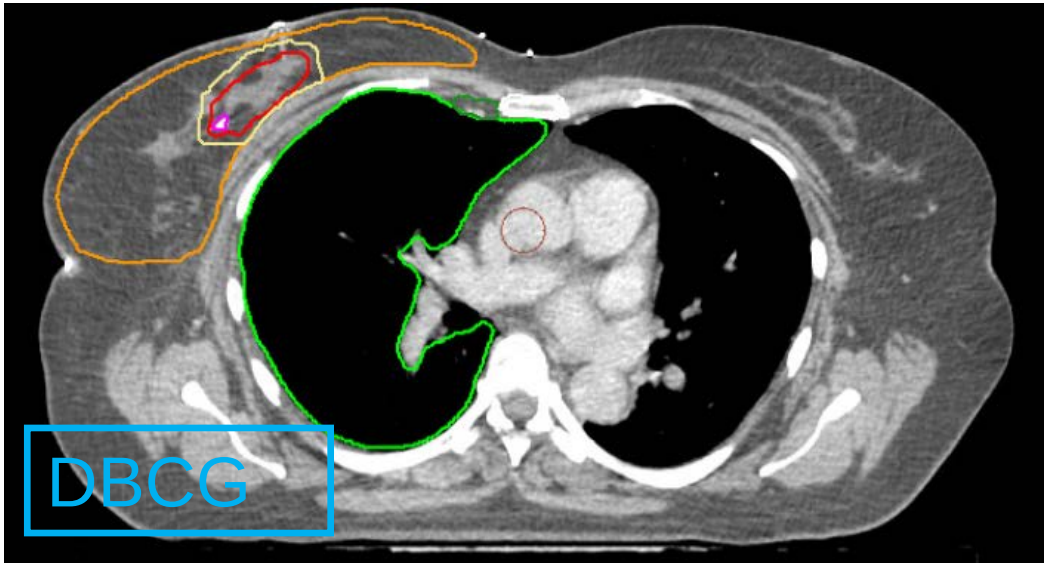

ESTRO School

- Introduction
- **Indications and CTV:**
  - Whole Breast
  - **Boost**
  - Chest wall
  - Regional nodes
    - L4, L3, L2, L1, IM, Rotter
- Organs at risk and constraints
- Margins CTV → PTV OAR → PRV
- Conclusions

ESTRO School

BOOST CTV: INDICATIONS

Boost treatment to the tumour bed reduces local relapse at all ages, but it has no impact on the OS

2 randomized trials confirm this:

Lyon trial
EORTC trial

ESTRO School

± Boost – EORTC Trial

Bartelink H, Lancet Oncol 2015; 16:47-56

Follow up: 20y

N = 4.318

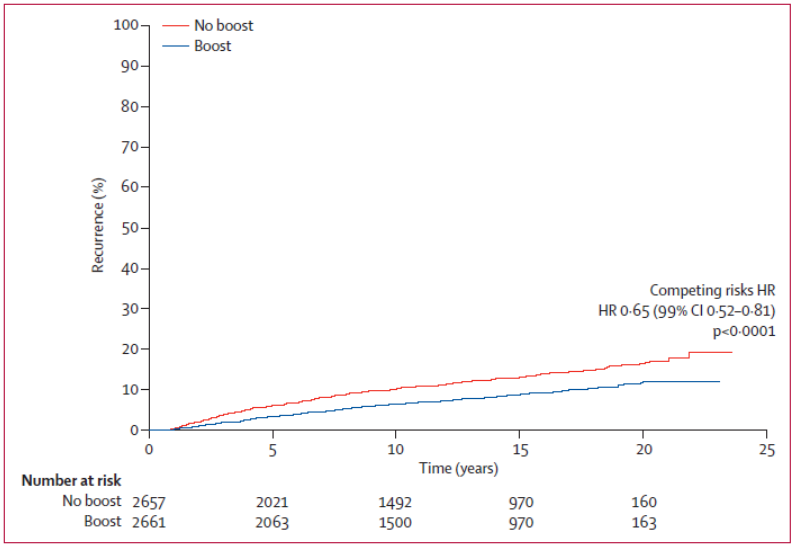

Age	Gain (LR)
≤40	**11.6 %**
41-50	5.9%
51-60	2.9%
>60	3%

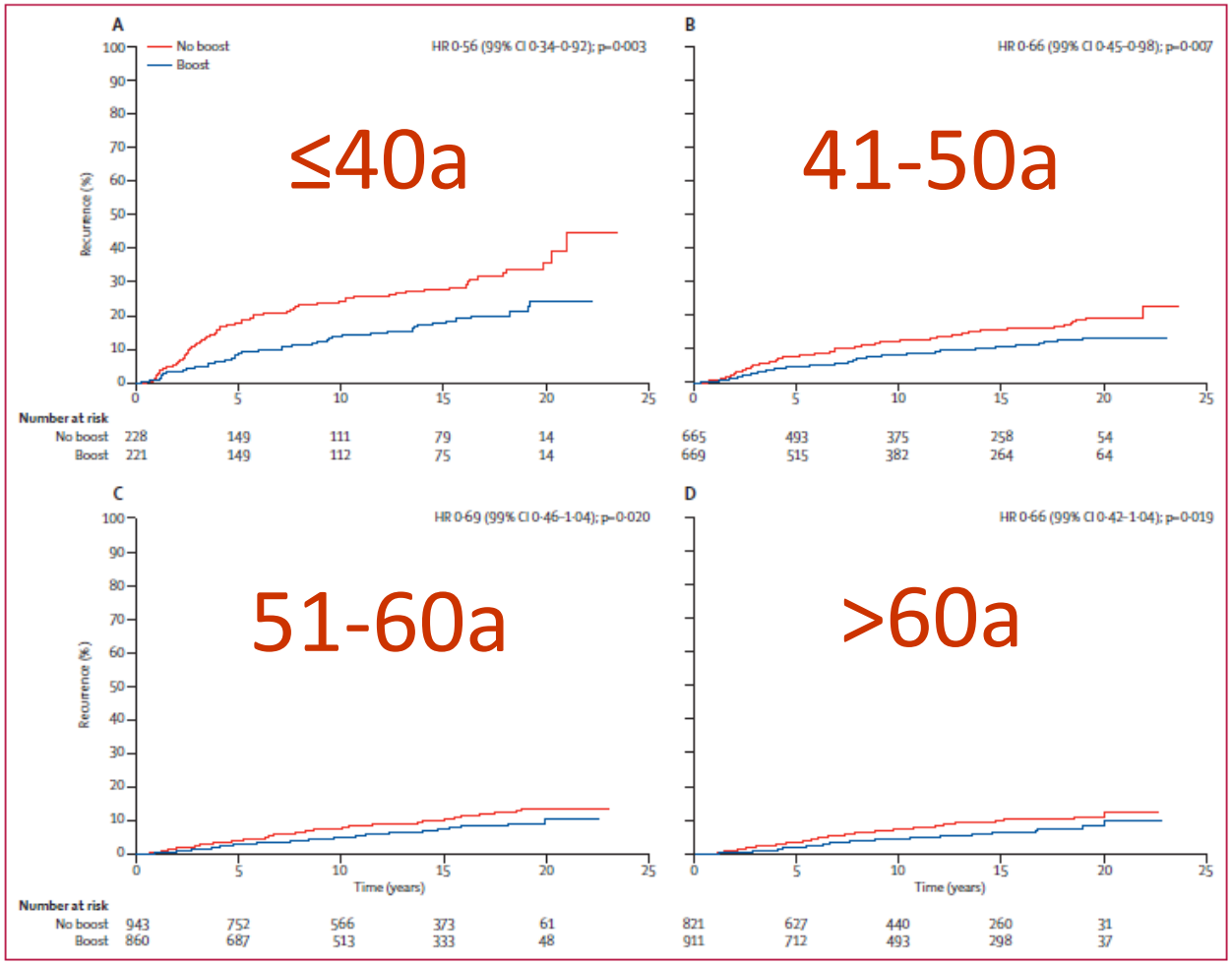

ESTRO School

BOOST CTV

- It might be useful to mark the scar
- Surgical clips
- Imaging studies before surgery (Mx, MRI ..)

- Seroma or surgical clips should be included when present
- Oncoplastic surgery??? (Surgical clips!)

ESTRO School

BOOST CTV

USE OF PRE-OPERATIVE CT IN COMBINATION WITH SURGICAL CLIPS IMPROVES LOCALIZATION OF THE TUMOUR BED

Good communication is ESSENTIAL between radiation oncologists, surgeons, pathologists and radiologists and could help to reduce interobserver differences

ESTRO School

BOOST CTV

Multiinstitutional study on target volume delineation variation in breast radiotherapy in the presence of guidelines

Anke M. van Mourik, Paula H.M. Elkhuizen, Danny Minkema, Joop C. Duppen,
On behalf of the Dutch Young Boost Study Group[1], Corine van Vliet-Vroegindeweij *

The Netherlands Cancer Institute, Amsterdam, The Netherlands

Radiotherapy and Oncology 94 (2010) 286–291

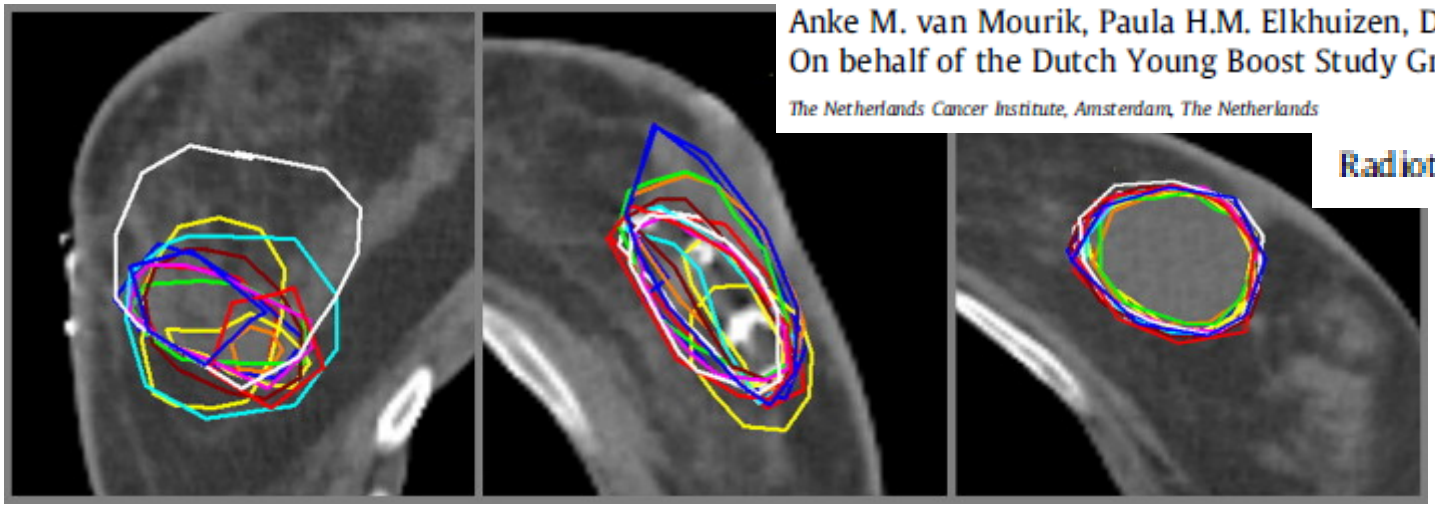

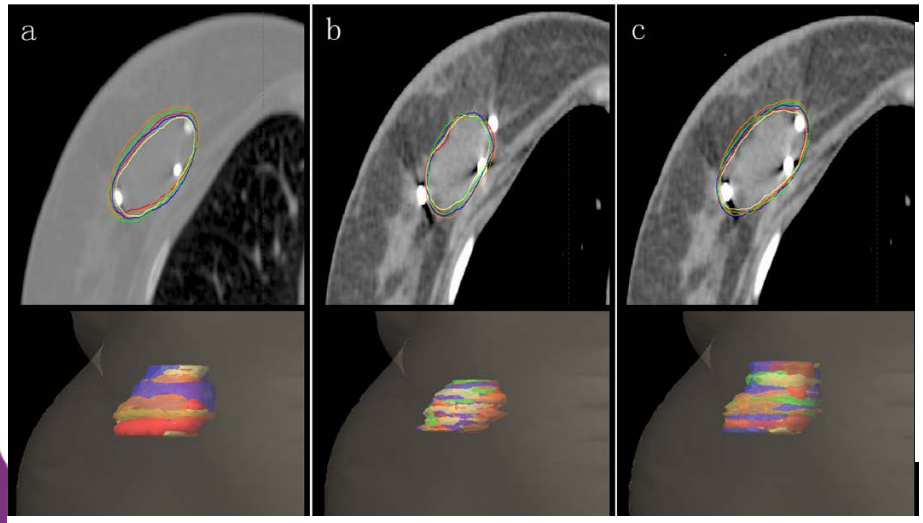

Guo *et al. Radiation Oncology* (2015) 10:66
DOI 10.1186/s13014-015-0370-3

RADIATION ONCOLOGY

RESEARCH **Open Access**

Interobserver variability in the delineation of the tumour bed using seroma and surgical clips based on 4DCT scan for external-beam partial breast irradiation

Bing Guo[1,2], Jianbin Li[1*], Wei Wang[1], Min Xu[1], Qian Shao[1], Yingjie Zhang[1], Chaoqian Liang[1] and Yanluan Guo[1,2]

Conclusions: When the SCS was 3 ~ 5 points and the number of surgical clips was ≥5, interobserver variability was minimal for the delineation of the tumour bed based on seroma.

Figure 1 Single CT slice and volumetric image of one patient with delineated TB_C (a), TB_S (b) and TB_{C+S} (c) of all 5 observers. TB_C, the TB delineated based on clips; TB_S, the TB delineated based on the seroma; TB_{C+S}, the TB delineated based on both seroma and clips.

ESTRO School

BOOST CTV

Radiotherapy and Oncology 106 (2013) 231–235

Contents lists available at SciVerse ScienceDirect

Radiotherapy and Oncology

journal homepage: www.thegreenjournal.com

10) 286–291

Tumor localization and dose planning

Tumour bed delineation for partial breast/breast boost radiotherapy: What is the optimal number of implanted markers?

Anna M. Kirby [a,*], Rajesh Jena [b], Emma J. Harris [c], Phil M. Evans [c], Clare Crowley [a], Deborah L. Gregory [b], Charlotte E. Coles [b]

[a] Royal Marsden NHS Foundation Trust, Sutton; [b] Cambridge University Hospitals NHS Foundation Trust; [c] Institute of Cancer Research, Sutton, UK

- They compare tumor bed volumes delineated using 6, 5, 1 and 0 clips.
- 5 implanted markers (one deep and four radial) are likely to be adequate assuming the addition of a standard 10-15 mm boost CTV margin.

ESTRO School

BOOST CTV

Radiotherapy and Oncology 103 (2012) 178–182

Reducing interobserver variation of boost-CTV delineation in breast conserving radiation therapy using a pre-operative CT and delineation guidelines ☆

Liesbeth J. Boersma [a,*,1], Tomas Janssen [b,1], Paula H.M. Elkhuizen [b], Philip Poortmans [d], Maurice van der Sangen [c], Astrid N. Scholten [e], Bianca Hanbeukers [a], Joop C. Duppen [b], Coen Hurkmans [c], Corine van Vliet [b]

Conclusion: Use of a Preop-CT in BCT results in a modest but statistically significant reduction in interobserver variation of the boost-CTV delineations and in a significant reduction in the boost-CTV volume.

den Hartogh *et al. Radiation Oncology* 2014, **9**:63
http://www.ro-journal.com/content/9/1/63

RADIATION ONCOLOGY

RESEARCH Open Access

MRI and CT imaging for preoperative target volume delineation in breast-conserving therapy

Mariska D den Hartogh[1*], Marielle EP Philippens[1], Iris E van Dam[1], Catharina E Kleynen[1], Robbert JHA Tersteeg[1], Ruud M Pijnappel[2], Alexis NTJ Kotte[1], Helena M Verkooijen[1,2], Maurice AAJ van den Bosch[2], Marco van Vulpen[1], Bram van Asselen[1] and HJG Desirée van den Bongard[1]

Figure 1 MRI patient setup in radiotherapy supine position.

ESTRO School

- Introduction
- **Indications and CTV:**
  - Whole Breast
  - Boost
  - **Chest wall**
  - Regional nodes
    - L4, L3, L2, L1, IM, Rotter
- Organs at risk and constraints
- Margins CTV → PTV OAR → PRV
- Conclusions

ESTRO School

CHEST WALL AND LYMPH NODES RT. INDICATIONS

- Tumours > 5cm (T3) *RT chest wall + L4-L3*
- Invasion of the skin or chest wall (T4) *RT chest wall + L4-L3*
- Positive margins *RT chest wall +/- L4-L3*
- Chest wall recurrence *RT chest wall + L4-L3*
- ≥ 4 positive nodes *RT chest wall + L4-L3*
- 1-3 (+) nodes (individualize, possible future indication) *RT chest wall + L4-L3*
- No or inadequate lymphadenectomy (≤ 6-10 nodes) *RT chest wall + L4-L3*
- SN (+) (Macrometastases) without lymphadenectomy *RT chest wall + L4-L3*

ESTRO School

Effect of radiotherapy after mastectomy and axillary surgery on 10-year recurrence and 20-year breast cancer mortality: meta-analysis of individual patient data for 8135 women in 22 randomised trials

Lancet 2014; 383: 2127–35

EBCTCG (Early Breast Cancer Trialists' Collaborative Group)*

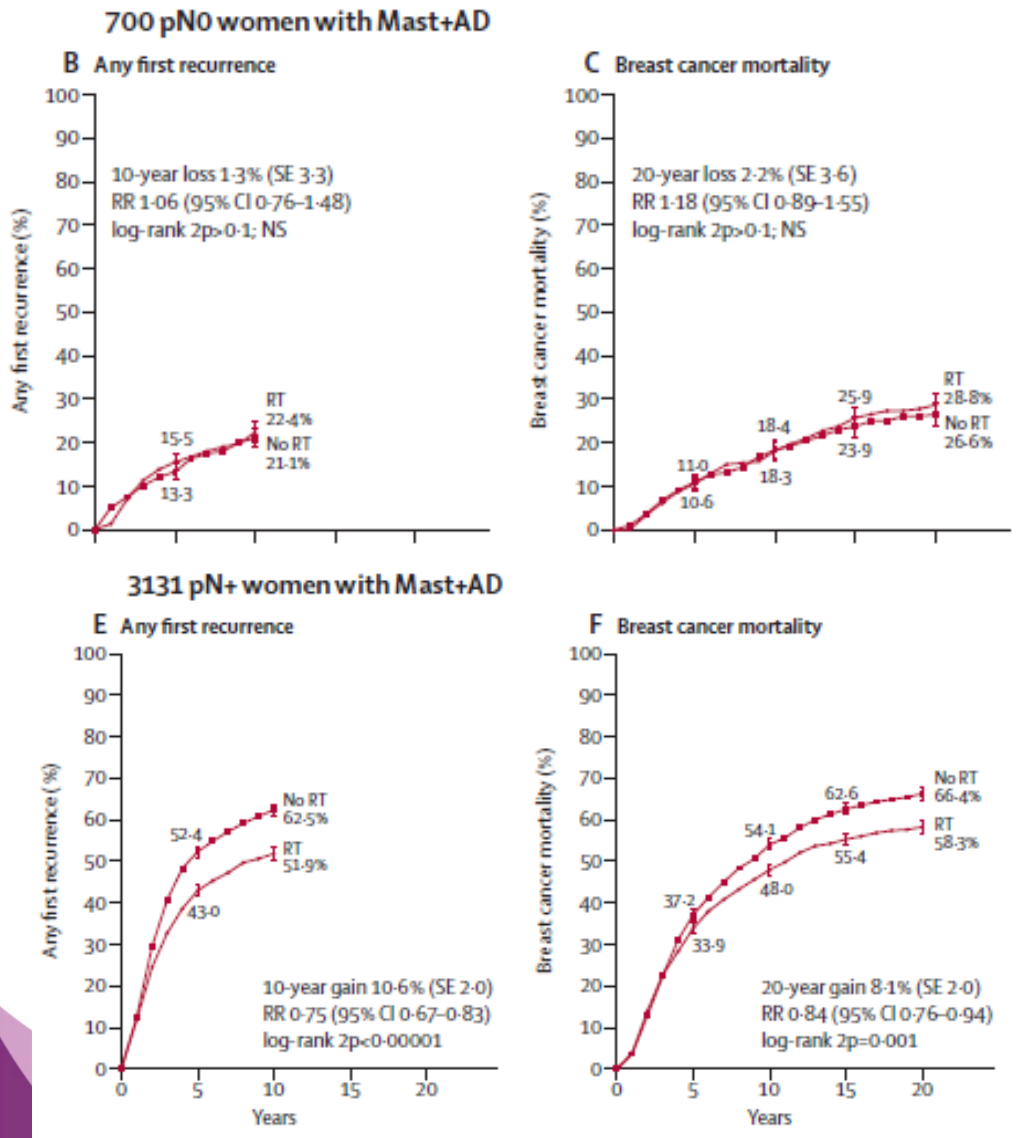

Reduces **recurrence**

(Node (-) (700 pts)

(Node (+) (3131 pts)

- 10 year gain **1.3% (N-) and 10.6% (N+)**

Reduces breast cancer **mortality**

- 20 year gain **2.2% (N-) and 8.1% (N+)**

ONE BREAST CANCER DEATH IS AVOIDED FOR EVERY FOUR LOCAL RECURRENCES AVOIDED

ESTRO School

CHEST WALL CTV

It might be useful to mark the scar

It might be useful to mark the medial, lateral and inferior limit (reference: contralateral breast)

Include all the scar whenever possible

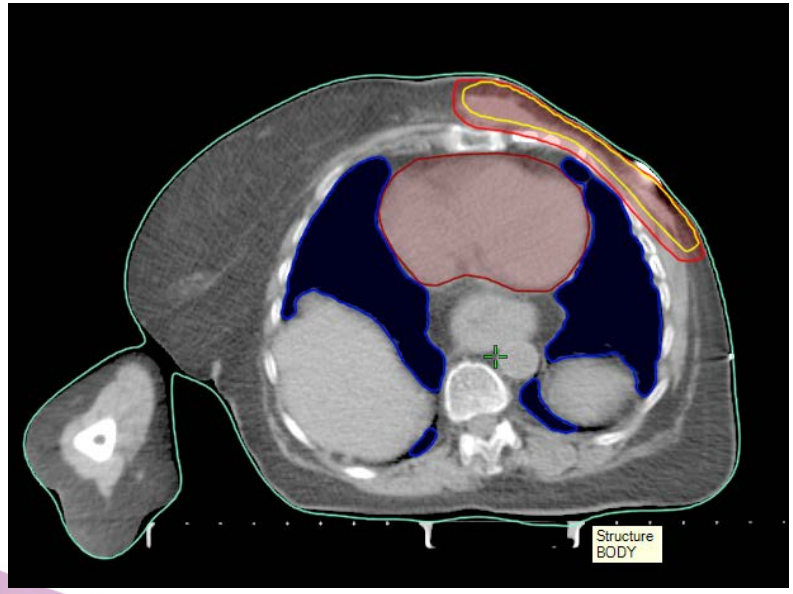

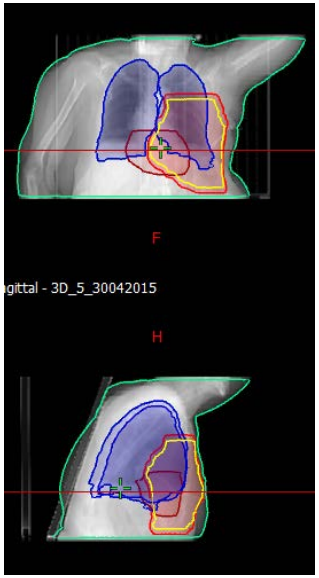

ESTRO School

Craneal

Caudal

border of the clavicle head

Guided by palpable/visible signs; if appropriate guided by the contralateral breast; maximally up to the inferior edge of the sterno-clavicular joint

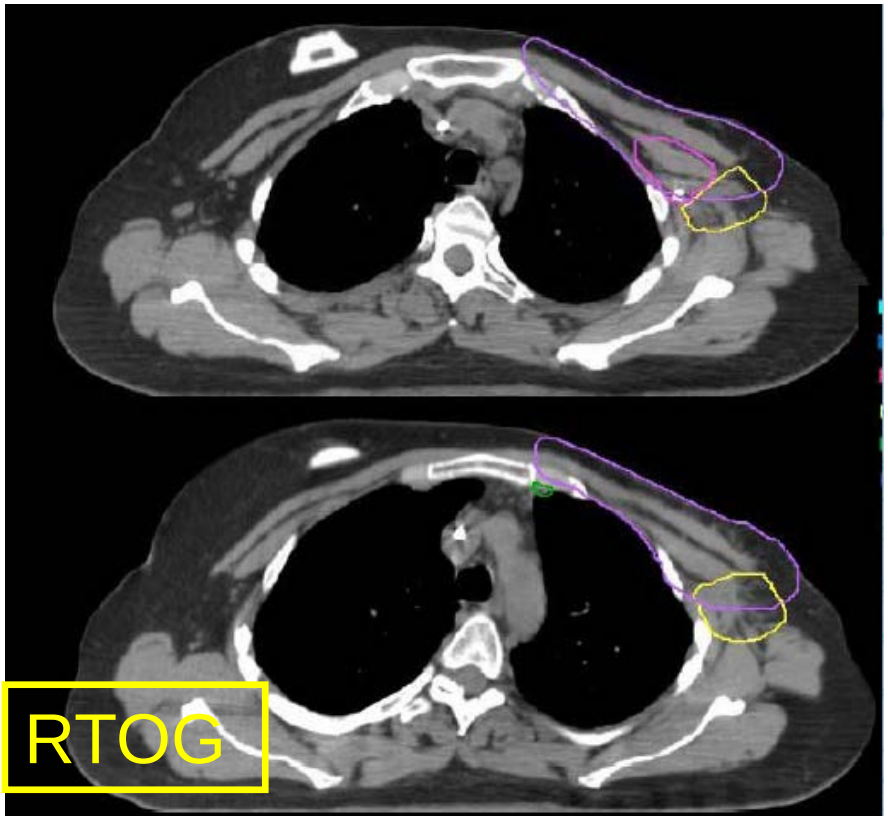

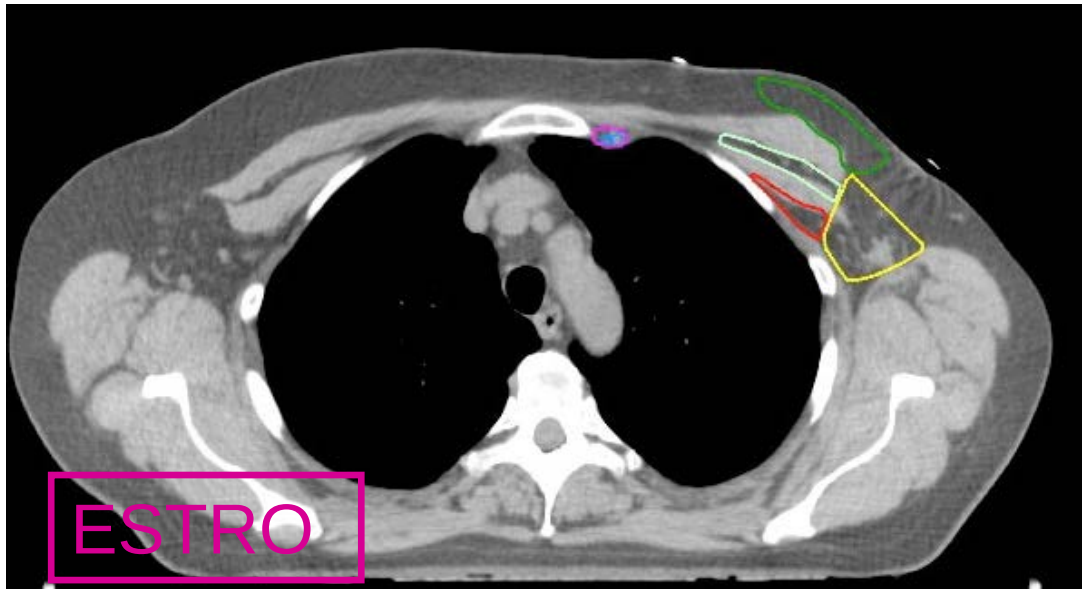

Equal to a CTV-breast guided by the contralateral breast

ESTRO School

Caudal

Clinical reference+ loss of CT apparent contralateral breast

Guided by palpable/visible signs; if appropriate guided by the contralateral breast

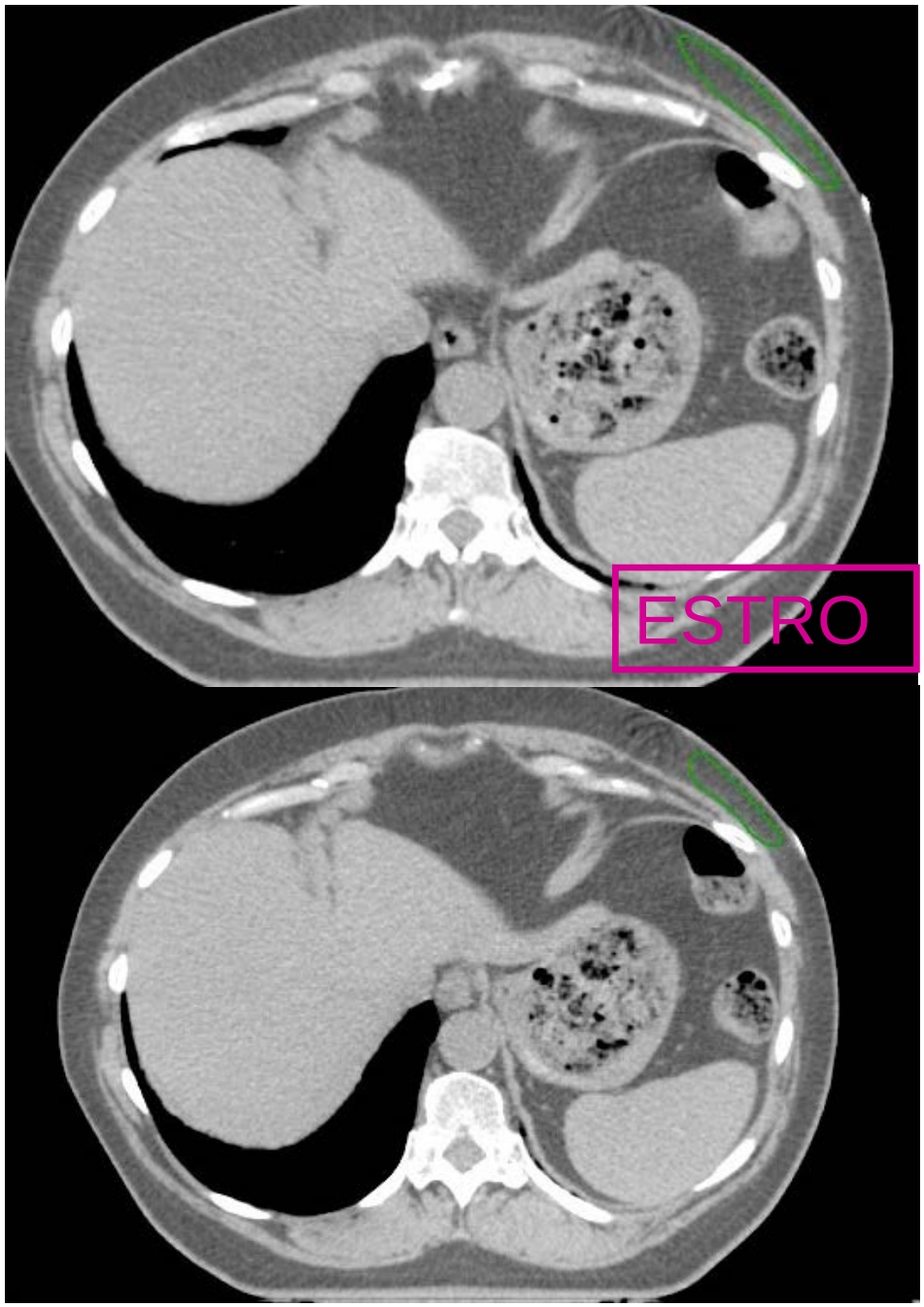

ESTRO School

Anterior

Skin

5 mm under skin surface

In case of a thin thoracic wall, omission of the first 5 mm under the skin may result in no CTV. In that case, extend the CTV into the skin and use bolus

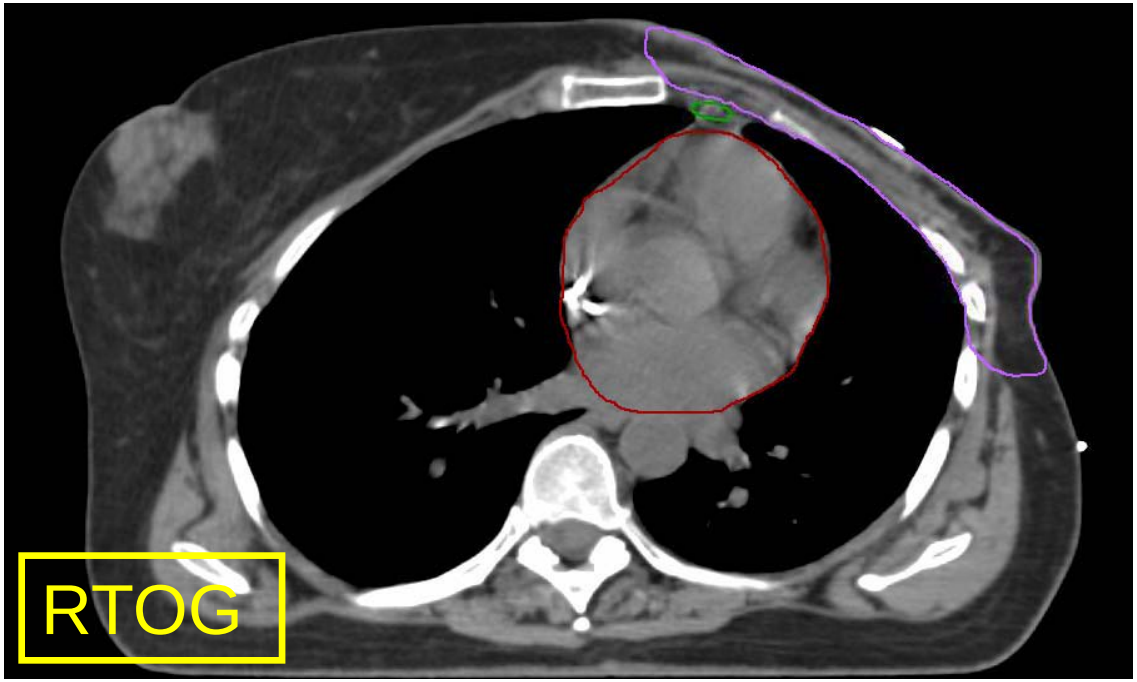

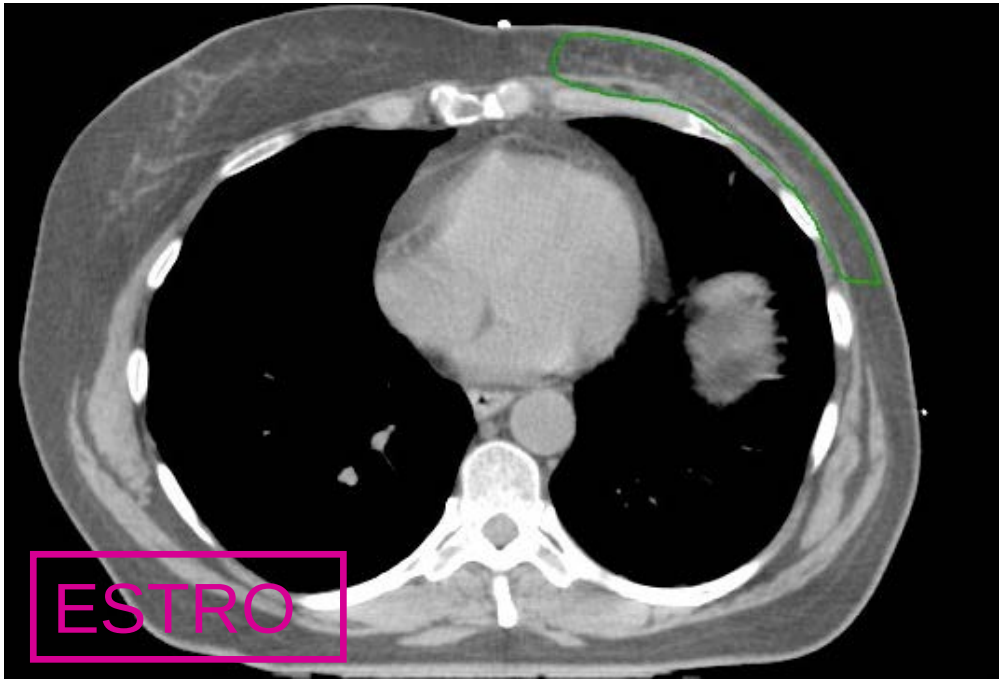

RTOG: Skin
ESTRO: 5 mm under the skin

ESTRO School

Posterior

Rib-pleural interface. (Includes pectoralis muscles, chestwall muscles, ribs)

Major pectoral muscle or costae and intercostal muscles where no muscle

The deep fascia and the pectoralis are anatomical barriers.

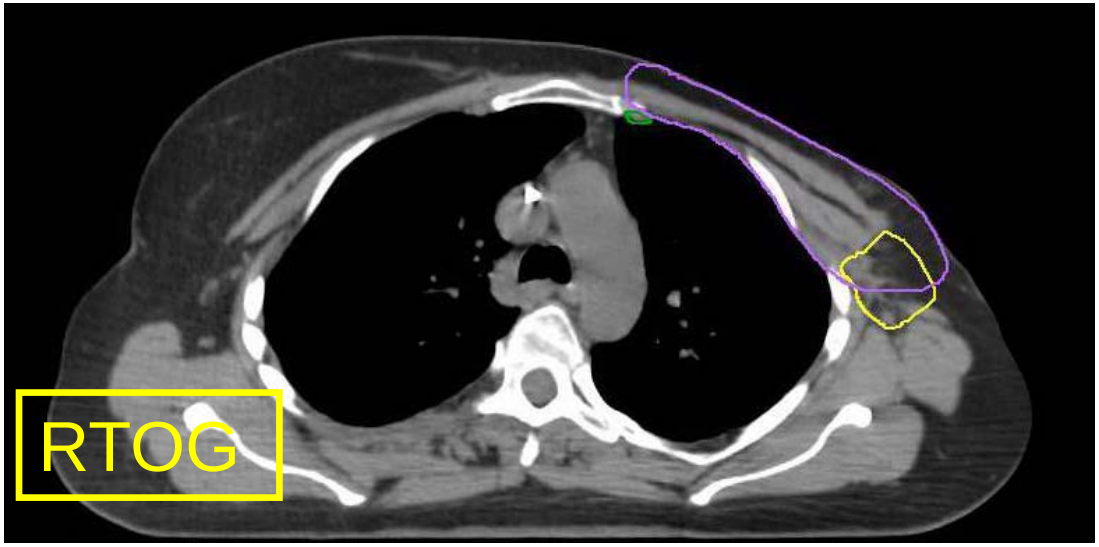

ESTRO recomendations do not include pectoralis muscles, chestwall muscles and ribs

ESTRO School

Medial Sternal-rib junction [b]	Guided by palpable/visible signs; if appropriate guided by the contralateral breast
Clinical Reference/ mid axillary line typically, excludes lattismus dorsi m [a]	Guided by palpable/visible signs; if appropriate guided by the contralateral breast. Usually anterior to the mid-axillary line

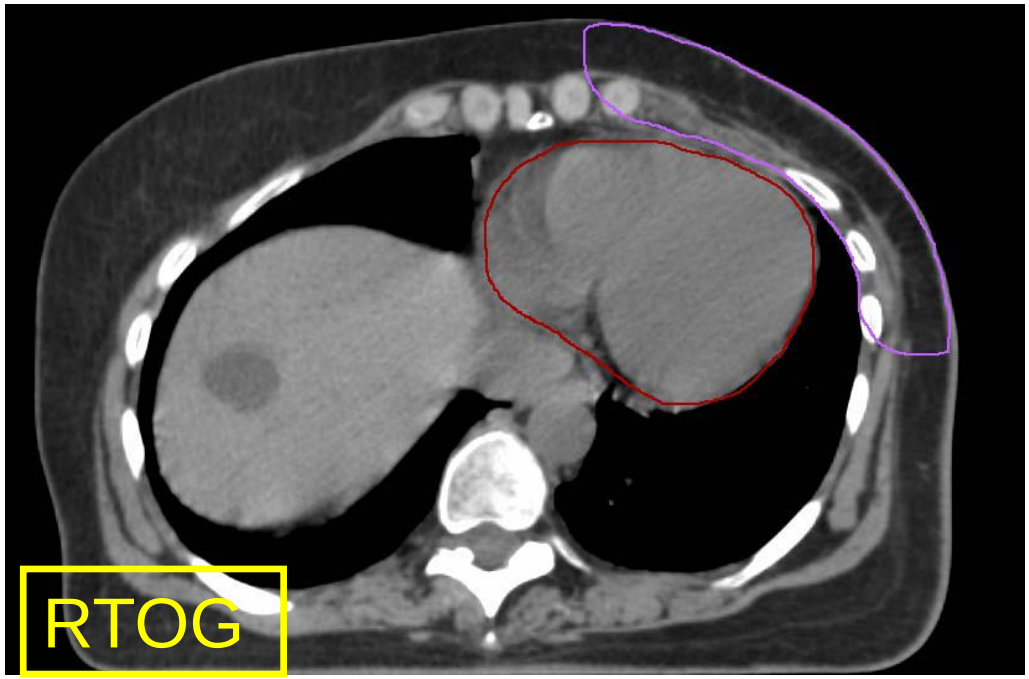

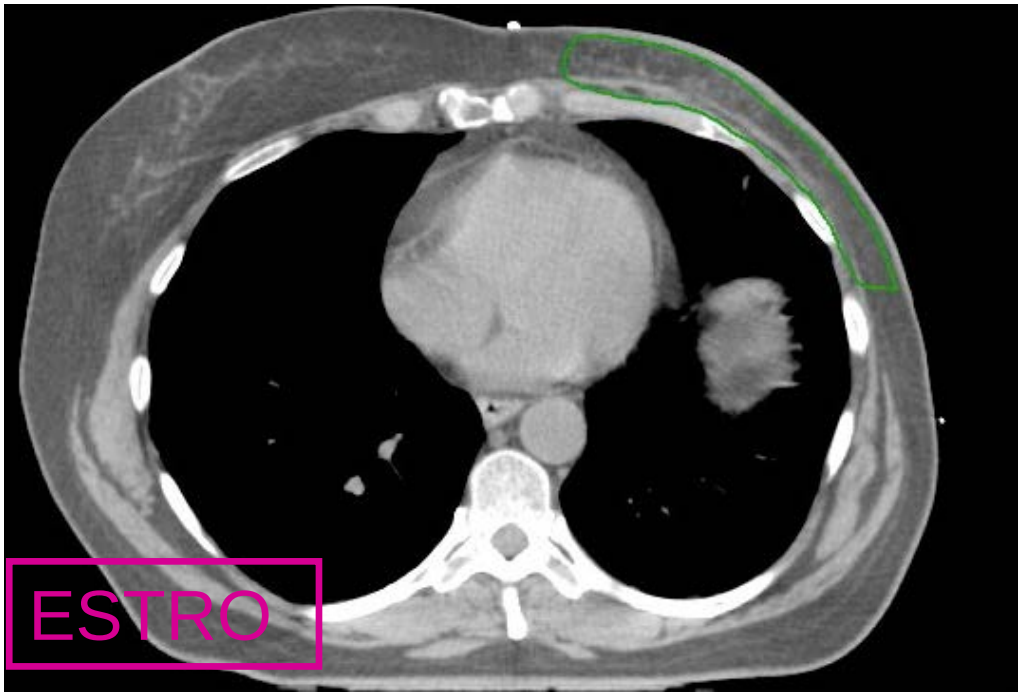

ESTRO School

CTV: CONSERVATIVE SURGERY AFTER PRIMARY SYSTEMIC TREATMENT

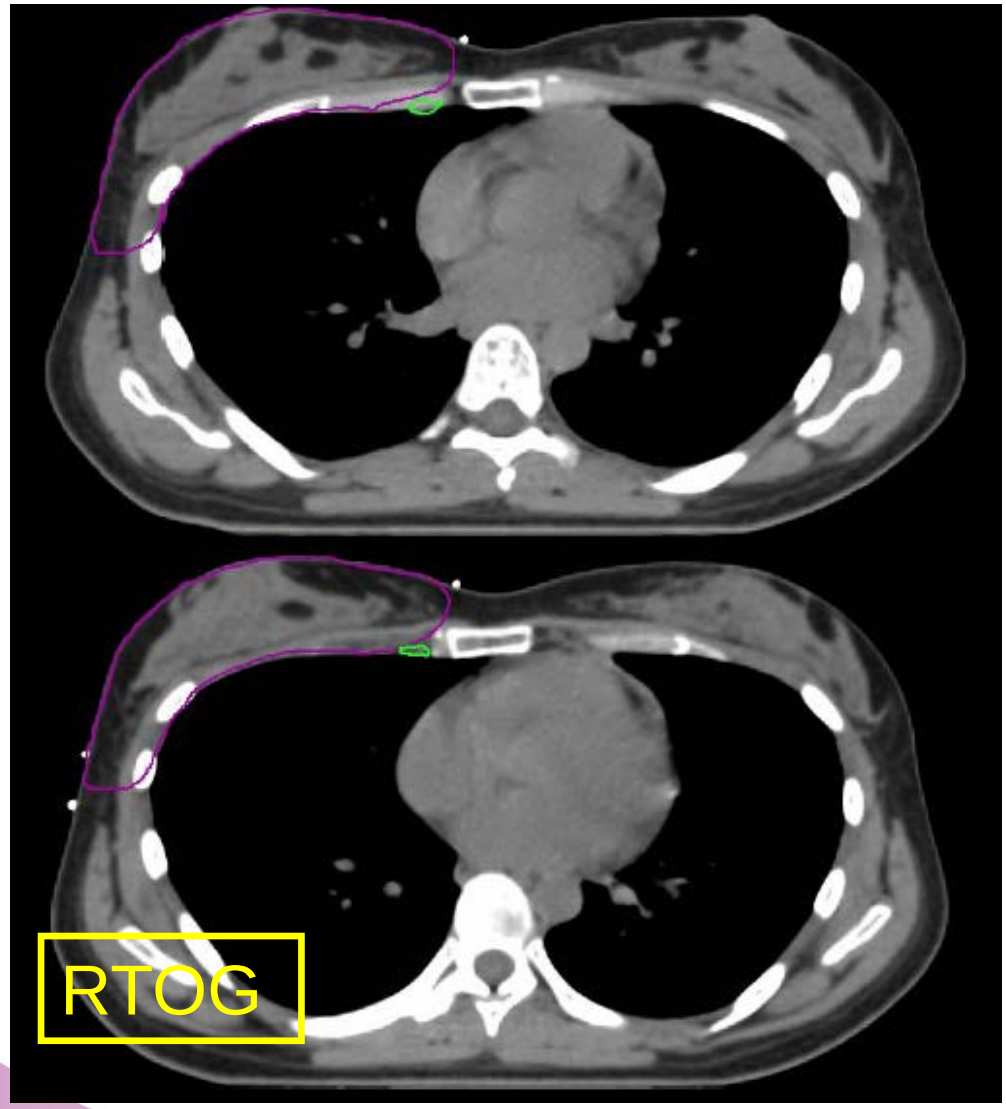

Only one difference

Posterior
Excludes pectoralis muscles, chestwall muscles, ribs
Includes pectoralis muscles, chestwall muscles, ribs

ESTRO School

- Introduction
- **Indications and CTV:**
  - Whole Breast
  - Boost
  - Chest wall
  - **Regional nodes**
    - **L4, L3, L2, L1, IM, Rotter**
- Organs at risk and constraints
- Margins CTV → PTV OAR → PRV
- Conclusions

ESTRO School

REGIONAL NODES

L4: or supraclavicular
L3 or infraclavicular: above pectoral muscles
L2: posterior to pectoralis minor
L1: caudally to pectoralis major
IM
Rotter: between pectoralis major and minor

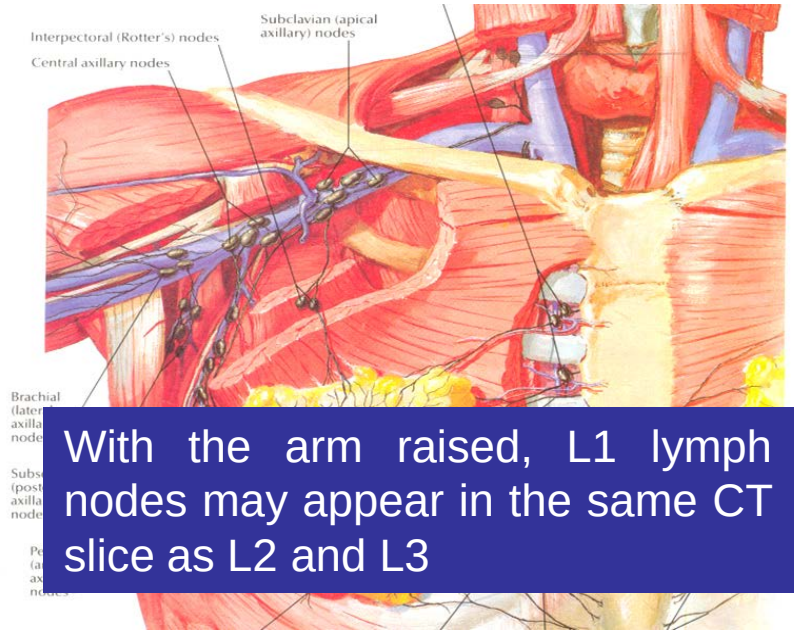

With the arm raised, L1 lymph nodes may appear in the same CT slice as L2 and L3

A lymph node is typically a 5 mm margin around the veins

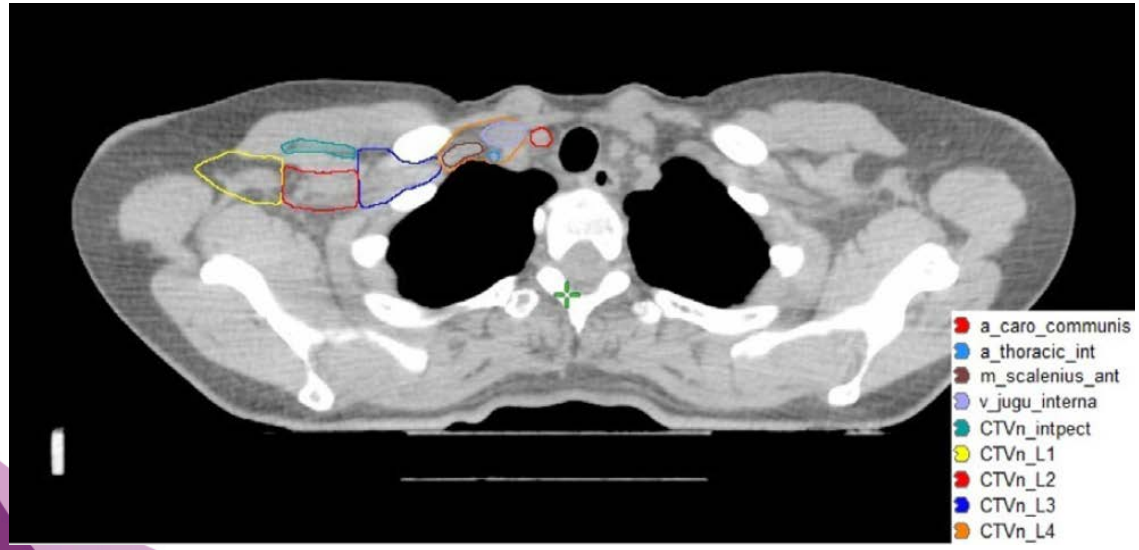

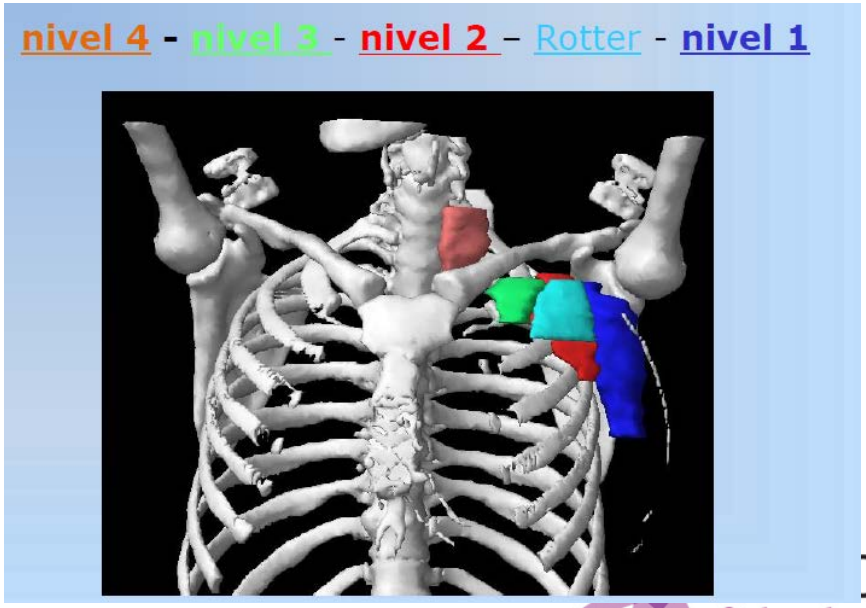

School

CTV L4-L3: INDICATIONS

- Tumours > 5cm (T3)
- Invasion of the skin or chest wall (T4)
- ≥ 4 positive nodes
- 1-3 (+) nodes (individualize, possible future indication)
- No or inadequate lymphadenectomy (≤ 6-10 nodes)
- SN (+) (Macrometastases) without lymphadenectomy

ESTRO School

CTV L4–L3: 1–3 N+: INDICATIONS

Randomized trials are PENDING:

- RTOG 9915 (SWOG)
- EORTC (SUPREMO – Selective Use of Postoperative Radiotherapy After Mastectomy): In this trial, apart from randomize 1-3 N(+) patients, pT2 pN0 with grade 3 and/or vasculo-lymphatic invasion are also randomized.
- NCI CTG
- French study

EBCTG META-ANALYSIS: POSITIVE RESULTS OF SURVIVAL 1-3 N+

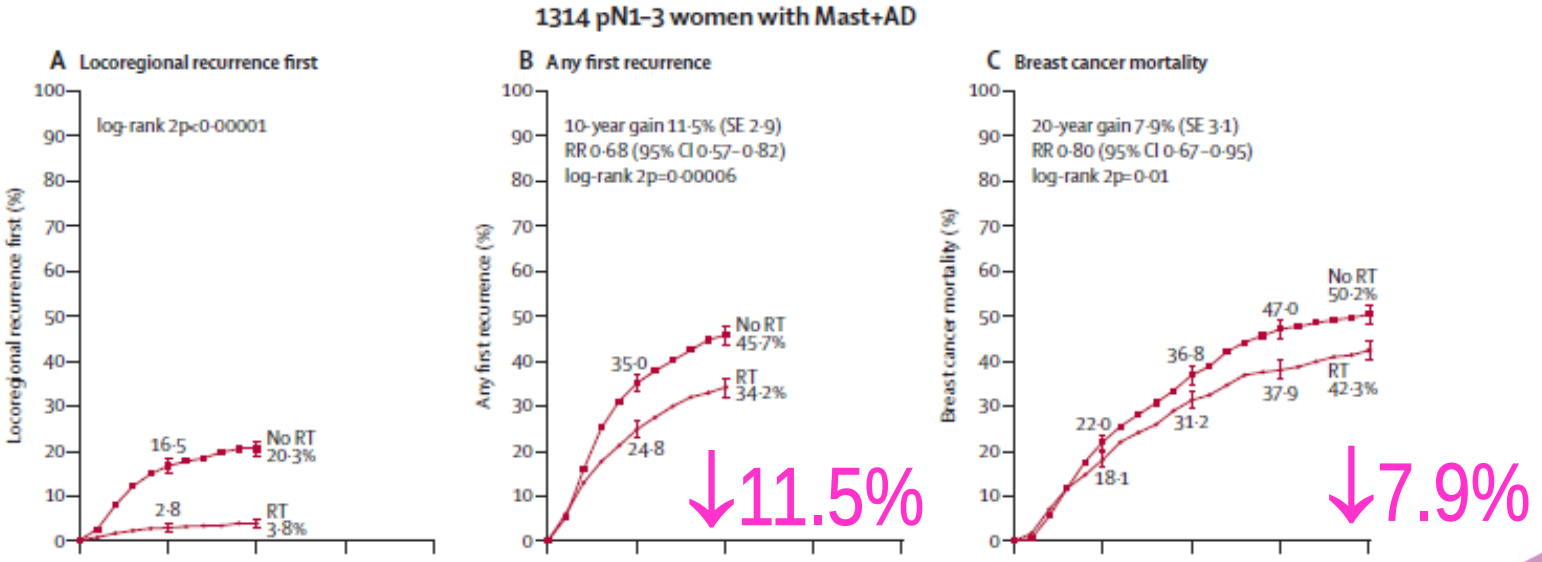

ESTRO School

	Cranial	Caudal	Anterior	Posterior	Lateral	Medial
Supra-clavicular	Caudal to the cricoid cartilage	Junction of brachioceph.-axillary vns./ caudal edge clavicle head [a]	Sternocleido mastoid (SCM) muscle (m.)	Anterior aspect of the scalene m.	Cranial: lateral edge of SCM m. Caudal: junction 1st rib-clavicle	Excludes thyroid and trachea
Lymph node level 4 CTVn_L4	Includes the cranial extent of the subclavian artery (i.e. 5 mm cranial of subclavian vein)	Includes the subclavian vein with 5 mm margin, thus connecting to the cranial border of CTVn_IMN	Sternocleidomastoid muscle, dorsal edge of the clavicle	Pleura	Includes the anterior scalene muscles and connects to the medial border of CTVn_L3	Including the jugular vein without margin; excluding the thyroid gland and the common carotid artery

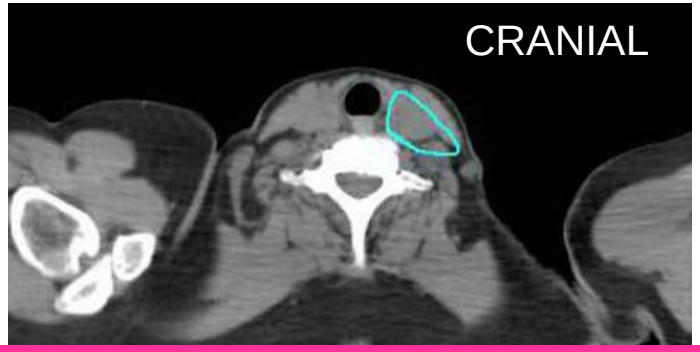

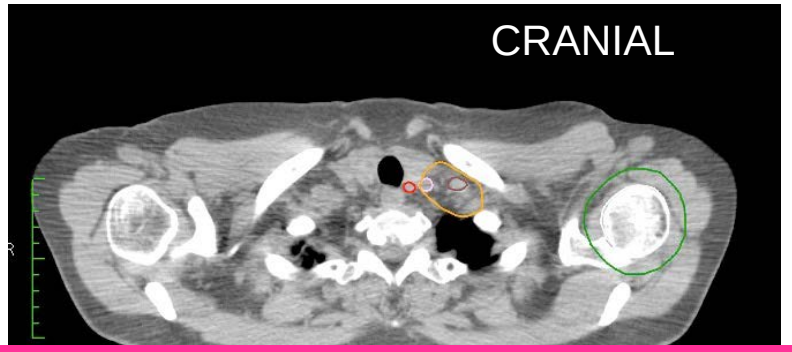

ESTRO recomends lowering cranial limit (cranial of subclavian vein)

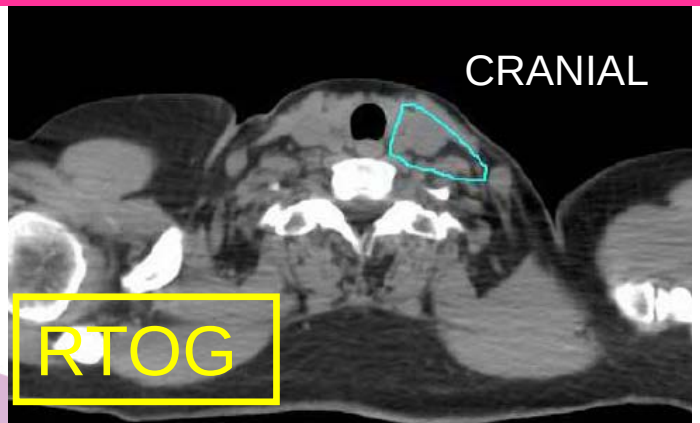

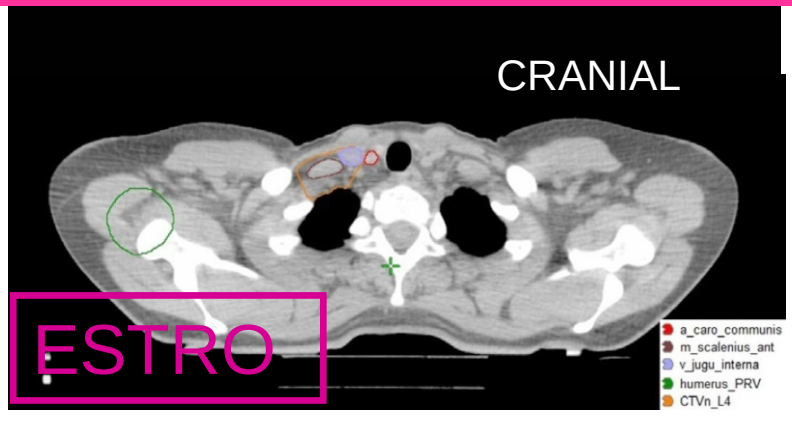

ESTRO School

	Cranial	Caudal	Anterior	Posterior	Lateral	Medial
Level IV CTVn_L4	Cranial edge of the subclavian A. arch	5 mm caudal of the junction of the subclavian and the internal jugular vein	*Cranially: dorsal surface of the SCM *Caudally: the infrahyoid muscle (strap muscles) and clavicle	*Cranially: ventral edge of the subclavian artery *Caudally: lung	*Cranially: lateral border of the anterior scalene m. *Caudally: joining CTVn_L3, excluding the subclavian A.	The medial edge of the internal jugular vein, without any margin medially, excluding the carotid A. and thyroid gland

DBCG guidelines

Lymph node level 4 CTVn_L4	Includes the cranial extent of the subclavian artery (i.e. 5 mm cranial of subclavian vein)	Includes the subclavian vein with 5 mm margin, thus connecting to the cranial border of CTVn_IMN	Sternocleidomastoid muscle, dorsal edge of the clavicle	Pleura	Includes the anterior scalene muscles and connects to the medial border of CTVn_L3	Including the jugular vein without margin; excluding the thyroid gland and the common carotid artery

PROCAB guidelines

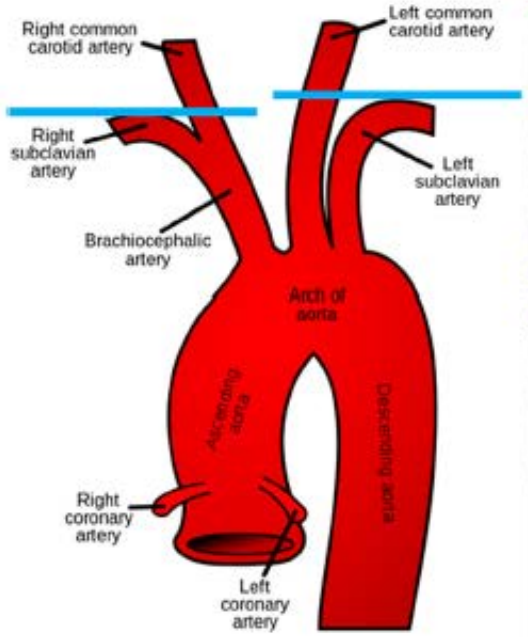

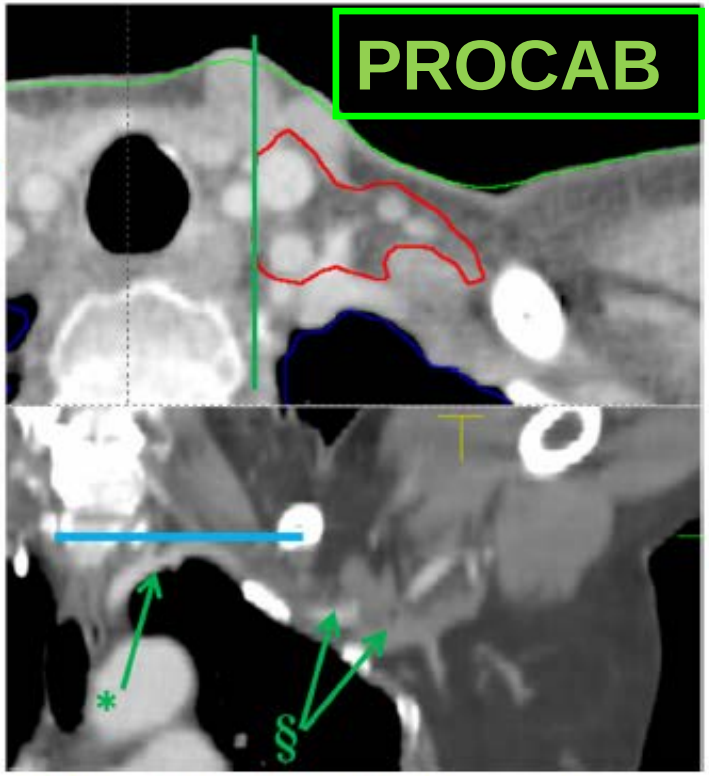

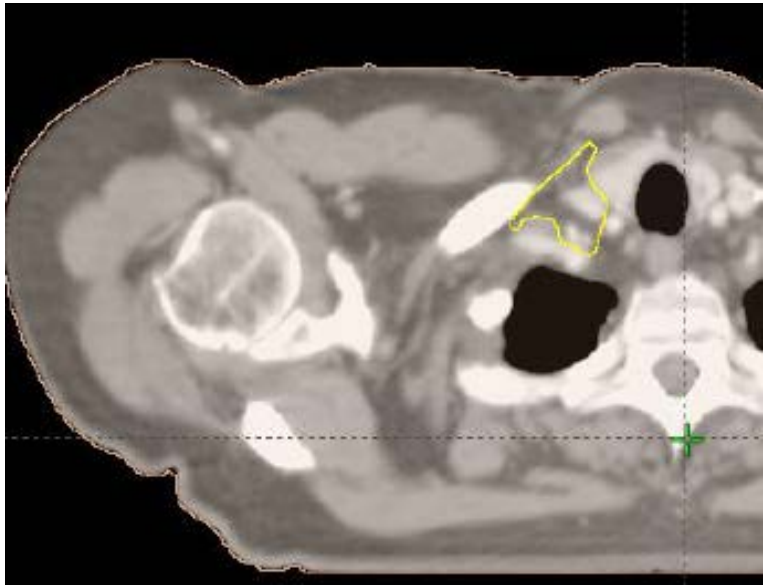

Fig. 2. The cranial border of level 4 or the supraclavicular region. *Subclavian artery arch. §Axillary artery and vein.

ESTRO School

Cranial	Caudal	Anterior	Posterior	Lateral	Medial
Supra-clavicular	Caudal to the cricoid cartilage	Junction of brachioceph.-axillary vns./ caudal edge clavicle head [a]	Sternocleido mastoid (SCM) muscle (m.)	Anterior aspect of the scalene m.	Cranial: lateral edge of SCM m. Caudal: junction 1st rib-clavicle	Excludes thyroid and trachea
Lymph node level 4 CTVn_L4	Includes the cranial extent of the subclavian artery (i.e. 5 mm cranial of subclavian vein)	Includes the subclavian vein with 5 mm margin, thus connecting to the cranial border of CTVn_IMN	Sternocleidomastoid muscle, dorsal edge of the clavicle	Pleura	Includes the anterior scalene muscles and connects to the medial border of CTVn_L3	Including the jugular vein without margin; excluding the thyroid gland and the common carotid artery
Periclavicular	Caudal edge of cricoid cartilage	Cranial border of level II and III (lateral). Cranial edge of the sterno-clavicular-junction (medial)	Dorsal surface of m. sternomastoideus, dorsal surface of clavicle, 5 mm below skin	In front of the clavicle, behind a. carotis interna, in front of m. scalenus ant, m. scalenus med, m. omo-hyoideus and m. levator scapulae	Medial edge of m. pectoralis minor, clavicle	Medial edge of a. carotis interna and v. jugularis interna

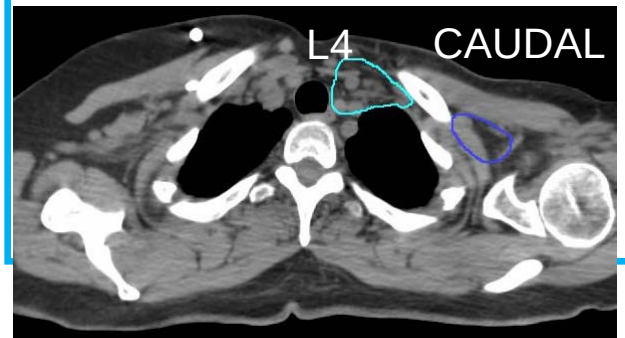

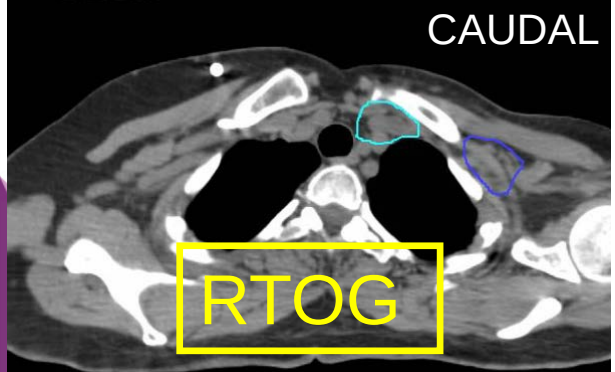

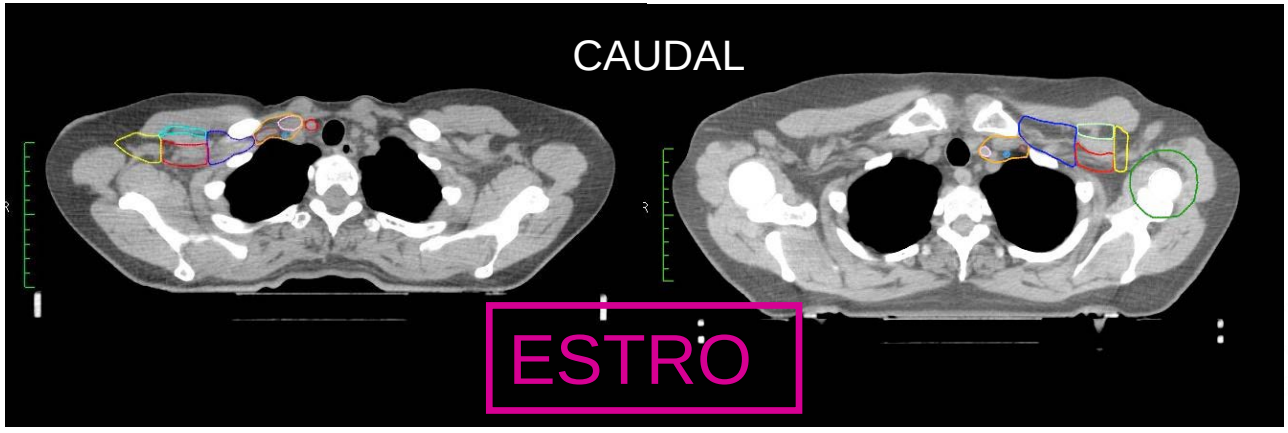

ESTRO School

Delineation of CTVn_L4 – supraclavicular lymph node area

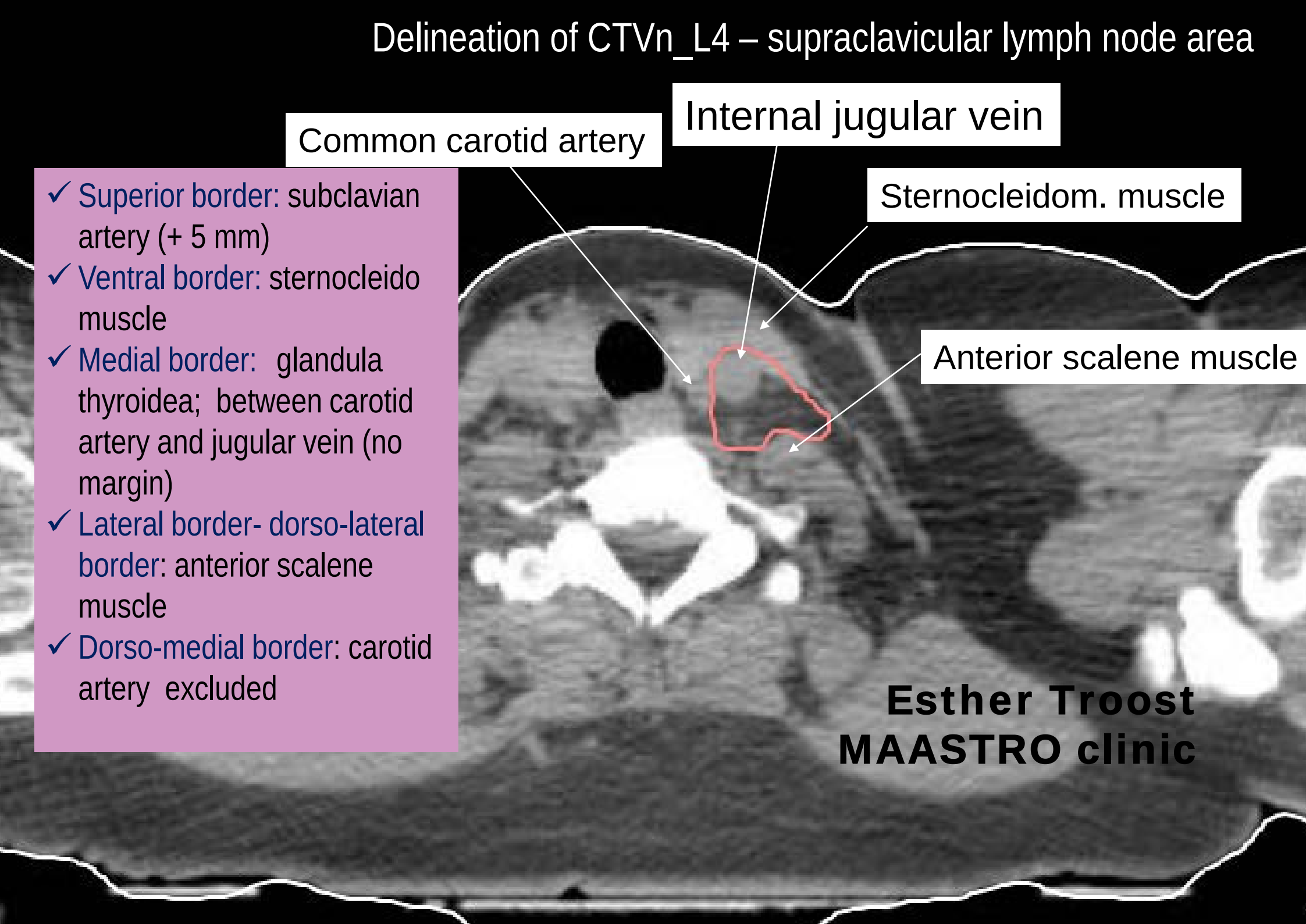

- ✓ Superior border: subclavian artery (+ 5 mm)
- ✓ Ventral border: sternocleido muscle
- ✓ Medial border: glandula thyroidea; between carotid artery and jugular vein (no margin)
- ✓ Lateral border- dorso-lateral border: anterior scalene muscle
- ✓ Dorso-medial border: carotid artery excluded

	Cranial	Caudal	Anterior	Posterior	Lateral	Medial
Axilla-level III	Pec. Minor m. insert on ~~cricoid~~ CORACOID	Axillary vessels cross medial edge of Pec. Minor m. d.	Posterior surface Pec. Major m.	Ribs and intercostal muscles	Medial border of Pec. Minor m.	Thoracic inlet
Axilla level 3 CTVn_L3	Includes the cranial extent of the subclavian artery (i.e. 5 mm cranial of subclavian vein)	5 mm caudal to the subclavian vein. If appropriate: top of surgical ALND	Major pectoral muscle	Up to 5 mm dorsal of subclavian vein or to costae and intercostal muscles	Medial side of the minor pectoral muscle	Junction of subclavian and internal jugular veins – >level 4

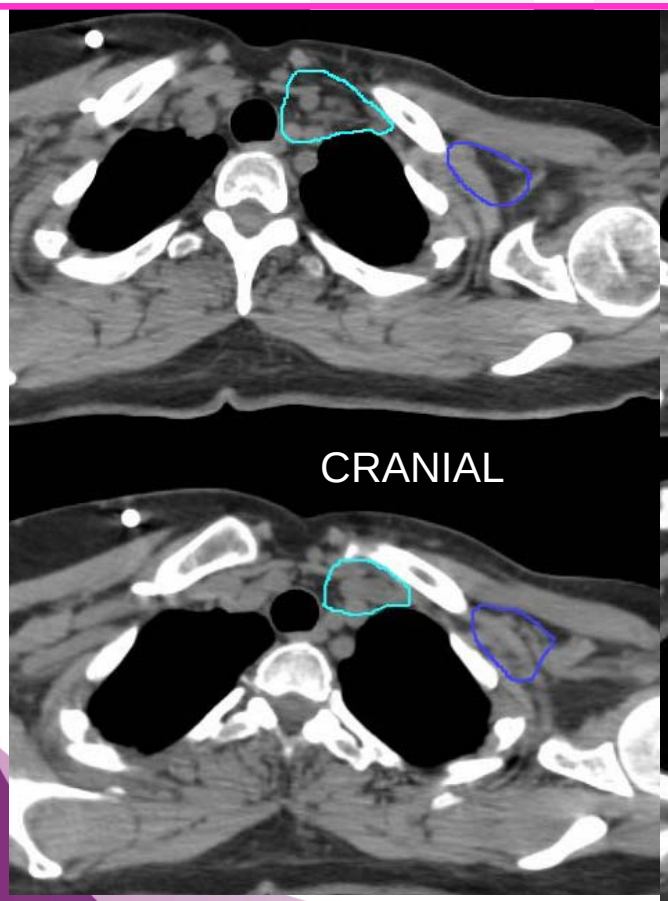

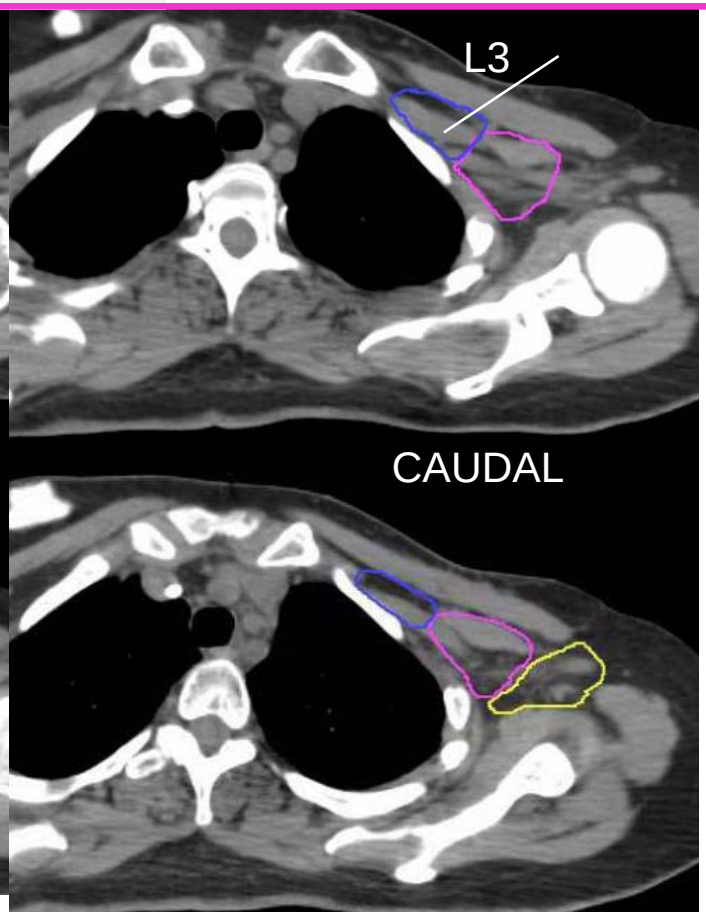

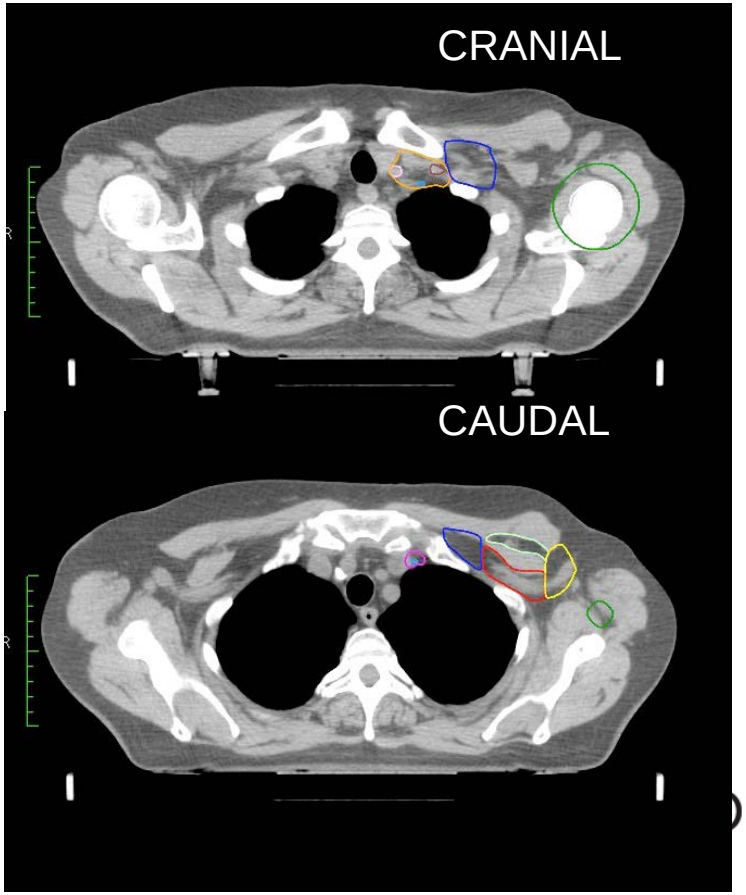

DCBG guidelines for delineation of CTV of breast and CTVs of the regional lymph node regions

LN region	cranial	caudal	ventral	dorsal	lateral	medial
Level III	5 mm cranial to the axillary vessels	1 cm caudal to the axillary vessels	Dorsal surface of m. pectoralis major	Chest wall, 5 mm dorsal of the axillary and subclavian vessels	Medial border of m. pectoralis minor	Clavicle

DBCG guidelines

Level III of the axilla CTVn_L3	When the subclavian A. exits the thorax (crosses the vertical line between the clavicle and the first rib) and becomes the axillary A.	5 mm below the axillary vein when it crosses the medial border of the pectoralis minor m.	Posterior surface of the pectoralis major m. and the clavicle	Ribs and intercostal muscles. Try to exclude the brachial plexus if visible	Medial border of the pectoralis minor m.	Clavicle and/or lateral border of CTVn_L4

PROCAB guidelines

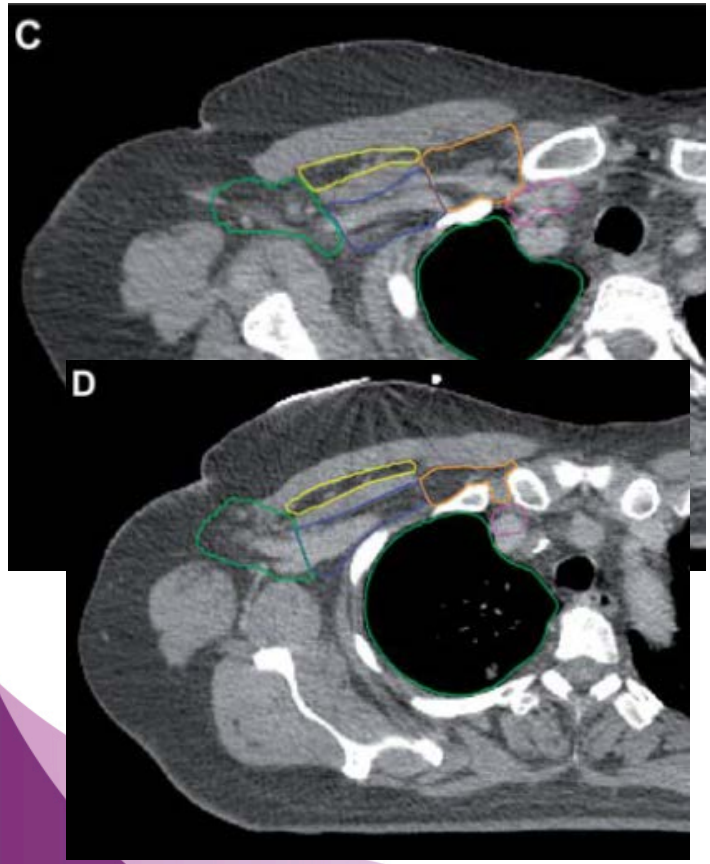

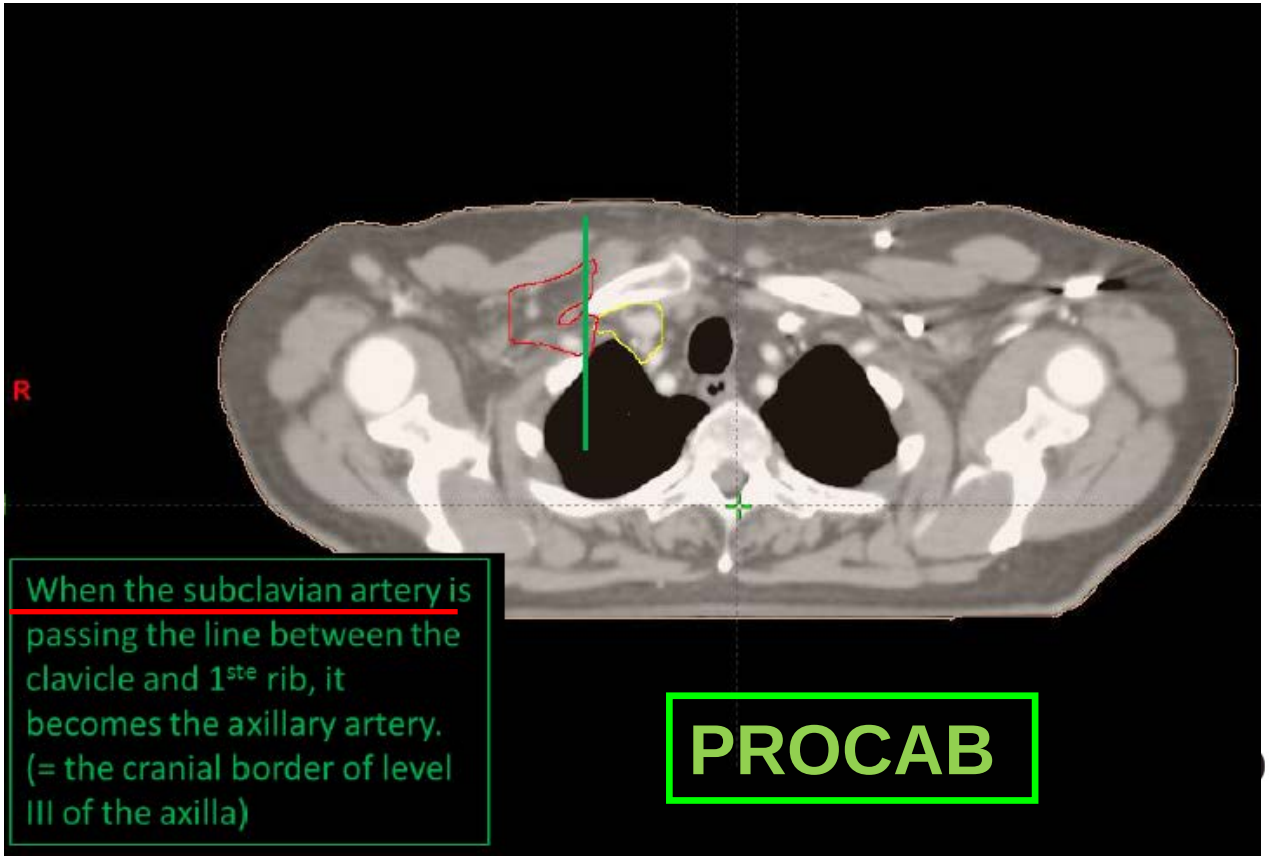

	Cranial	Caudal	Anterior	Posterior	Lateral	Medial
Axilla-level III	Pec. Minor m. insert on ~~cricoid~~ CORACOID	Axillary vessels cross medial edge of Pec. Minor m. d.	Posterior surface Pec. Major m.	Ribs and intercostal muscles	Medial border of Pec. Minor m.	Thoracic inlet
Axilla level 3 CTVn_L3	Includes the cranial extent of the subclavian artery (i.e. 5 mm cranial of subclavian vein)	5 mm caudal to the subclavian vein. If appropriate: top of surgical ALND	Major pectoral muscle	Up to 5 mm dorsal of subclavian vein or to costae and intercostal muscles	Medial side of the minor pectoral muscle	Junction of subclavian and internal jugular veins – >level 4

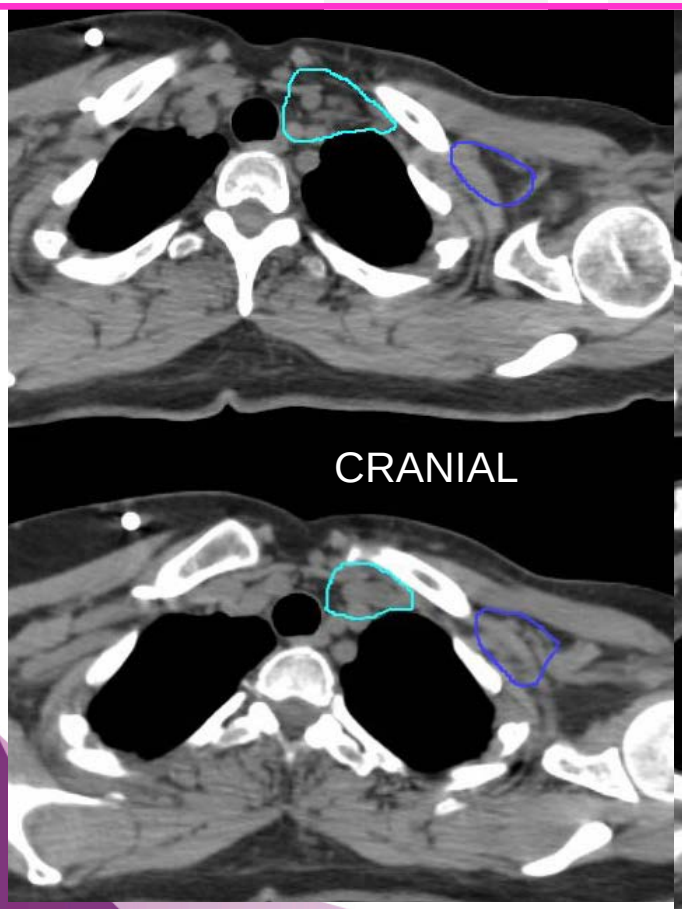

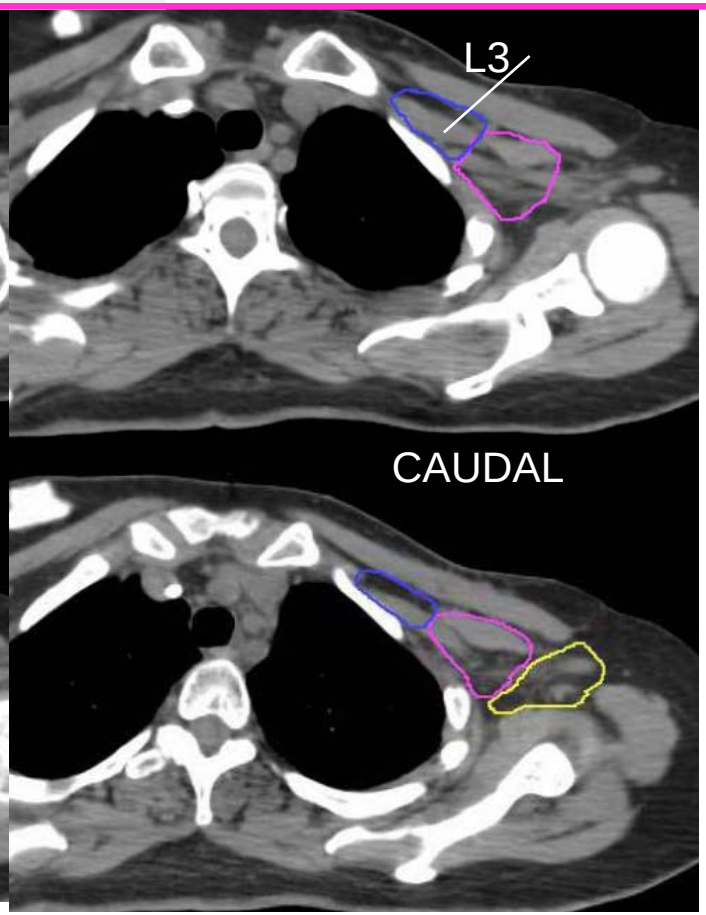

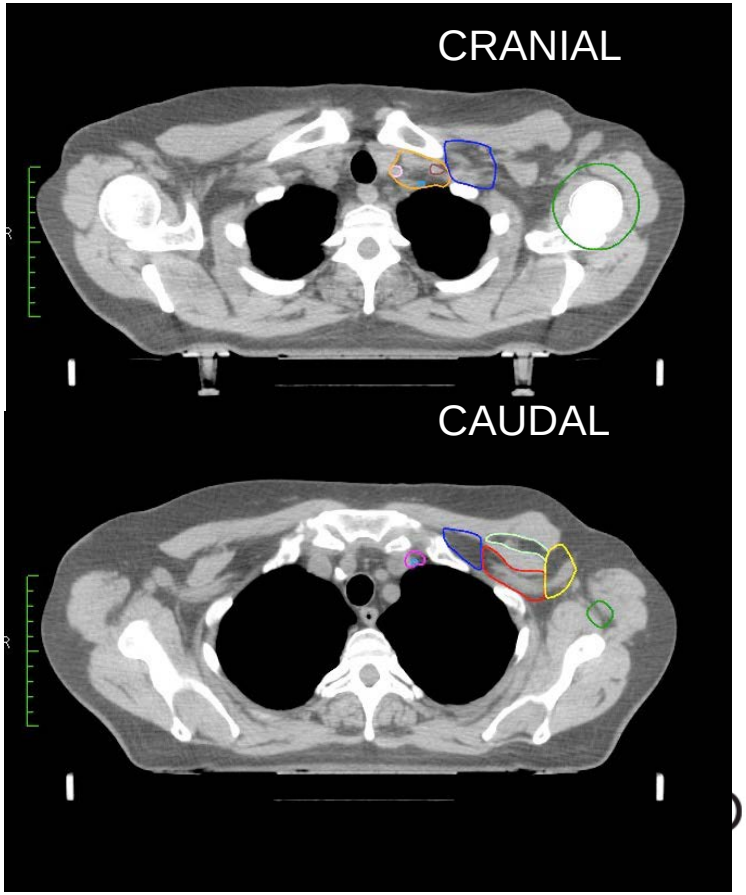

CTV L2-L1: INDICATIONS

- No or inadequate lymphadenectomy (L) **RT L4-L3-L2-L1**
- Bulky nodal disease
- SN (+) (Macrometastases) without lymphadenectomy. **AMAROS Trial (EORTC)** (Adjuvant Management of the Axilla Radiotherapy of Surgery) is comparing L vs axillary RT with SN (+).

  RT L4-L3-L2-L1

  (Micrometastases: no RT)

AMAROS Donker 2014 Lancet Oncol

Including 4800 patients demonstrated that axillary RT is as effective as axillary surgery with less morbidity at 5 year follow-up.

ESTRO School

	Cranial	Caudal	Anterior	Posterior	Lateral	Medial
Axilla-level II	Axillary vessels cross medial edge of Pec. Minor m.	Axillary vessels cross lateral edge of Pec. Minor m. [c]	Anterior surface Pec. Minor m.	Ribs and intercostal muscles	Lateral border of Pec. Minor m.	Medial border of Pec. Minor m.
Axilla level 2 CTVn_L2	Includes the cranial extent of the axillary artery (i.e. 5 mm cranial of axillary vein)	The caudal border of the minor pectoral muscle. If appropriate: top of surgical ALND	Minor pectoral muscle	Up to 5 mm dorsal of axillary vein or to costae and intercostal muscles	Lateral edge of minor pectoral muscle	Medial edge of minor pectoral muscle

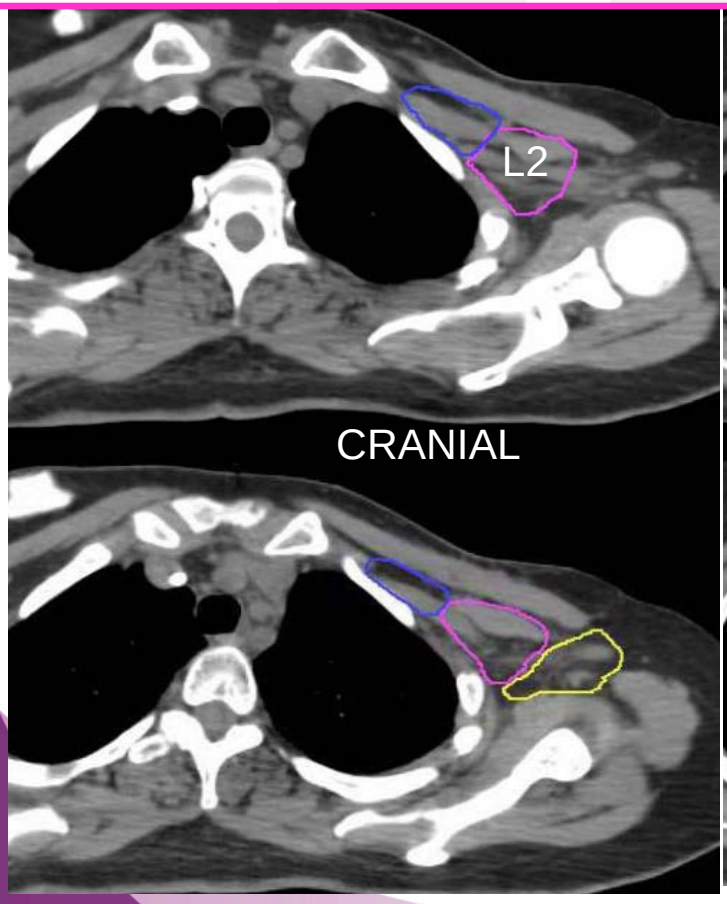

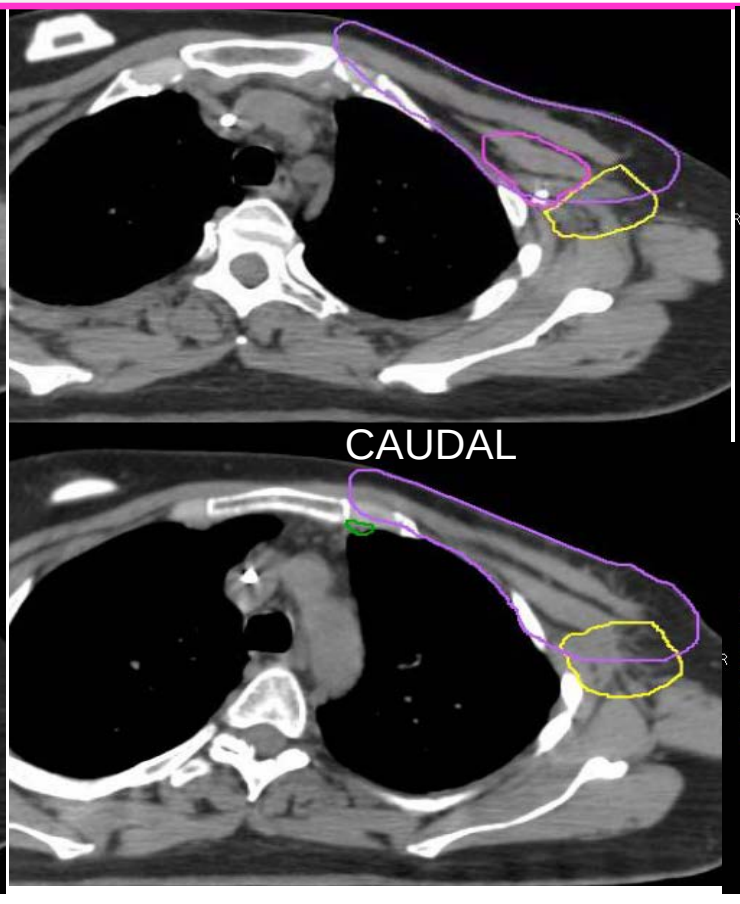

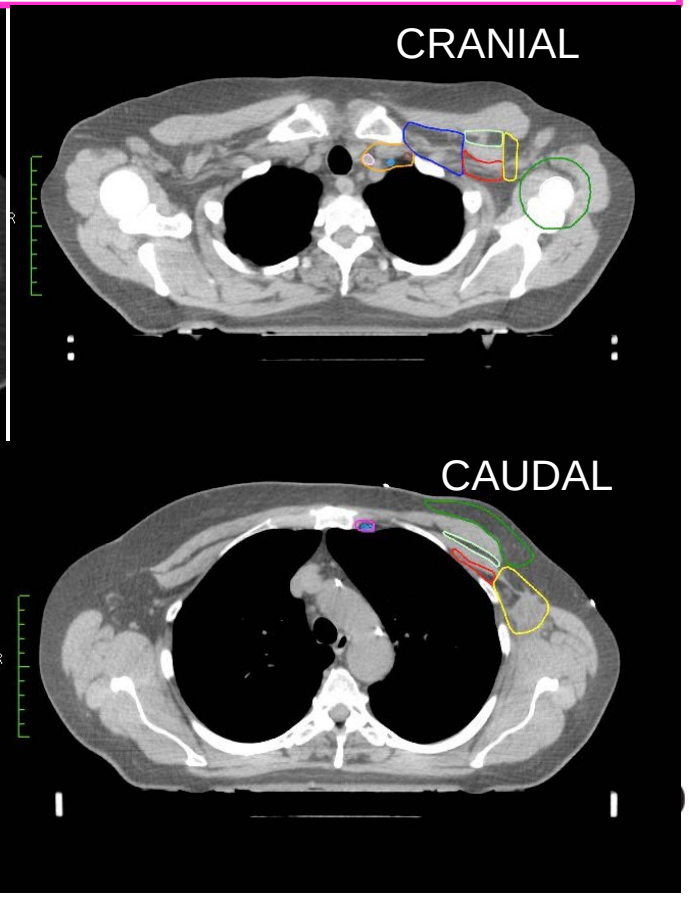

DCBG guidelines for delineation of CTV of breast and CTVs of the regional lymph node regions

LN region	cranial	caudal	ventral	dorsal	lateral	medial
Level II	5 mm cranial to the axillary vessels	Caudal edge of m. pectoralis minor	Dorsal surface of m. pectoralis minor	Chest wall, 5 mm dorsal of the axillary vessels	Lateral border of m. pectoralis minor	Medial border of m. pectoralis minor

DBCG guidelines

Level II of the axilla CTVn_L2	When the axillary A. crosses the medial edge of the pectoralis minor m.	5 mm below the axillary vein when it crosses the lateral border of the pectoralis minor m.	Dorsal surface of the pectoralis minor m.	Visible Ribs and intercostal muscles	Lateral border of the pectoralis minor m.	Medial border of the pectoralis minor m.

PROCAB guidelines

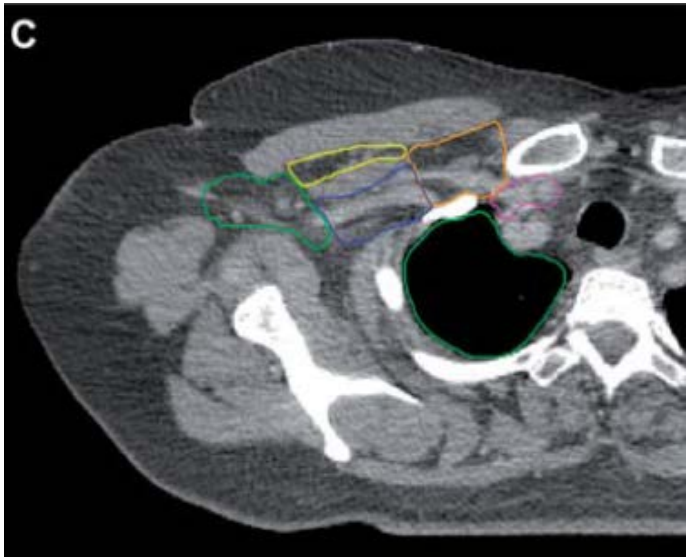

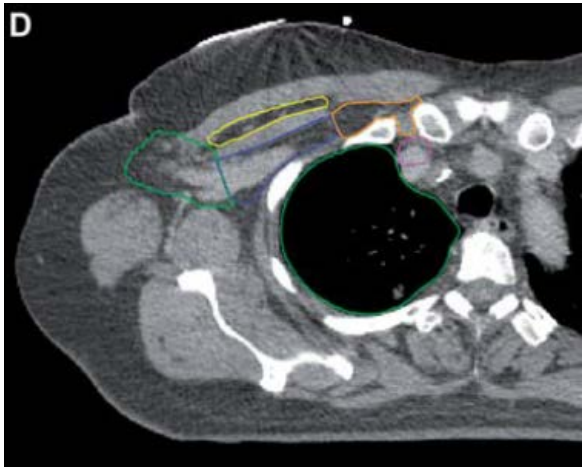

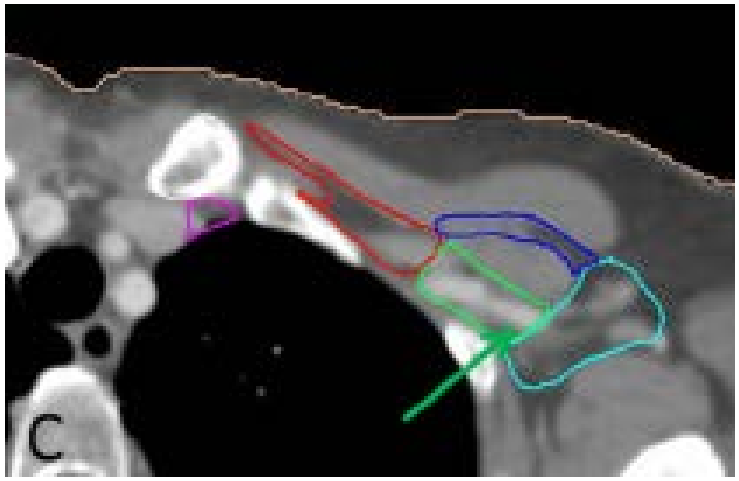

	Cranial	Caudal	Anterior	Posterior	Lateral	Medial
Axilla-Level I	Axillary vessels cross lateral edge of Pec. Minor m.	Pectoralis (Pec.) major muscle insert into ribs [b]	Plane defined by: anterior surface of Pec. Maj. m. and Lat. Dorsi m.	Anterior surface of subscapularis m.	Medial border of lat. dorsi m.	Lateral border of Pec. minor m.
Axilla level 1 CTVn_L1	Medial: 5 mm cranial to the axillary vein Lateral: max up to 1 cm below the edge of the humeral head, 5 mm around the axillary vein	To the level of rib 4 – 5, taking also into account the visible effects of the sentinel lymph node biopsy	Pectoralis major & minor muscles	Cranially up to the thoraco-dorsal vessels, and more caudally up to an imaginary line between the anterior edge of the latissimus dorsi muscle and the intercostal muscles	Cranially up to an imaginary line between the major pectoral and deltoid muscles, and further caudal up to a line between the major pectoral and latissimus dorsi muscles	Level 2, the interpectoral level and the thoracic wall

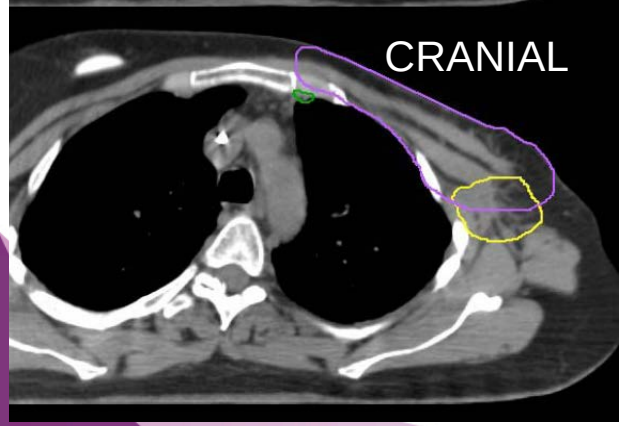

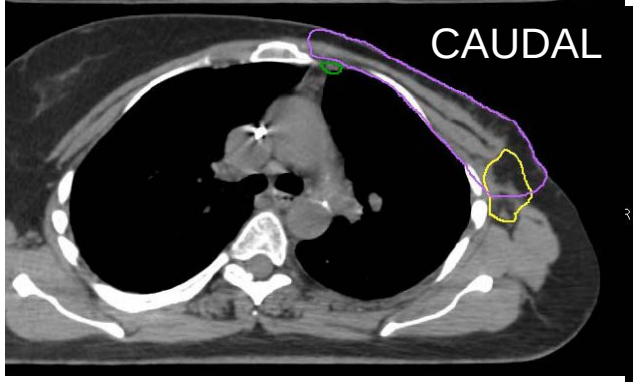

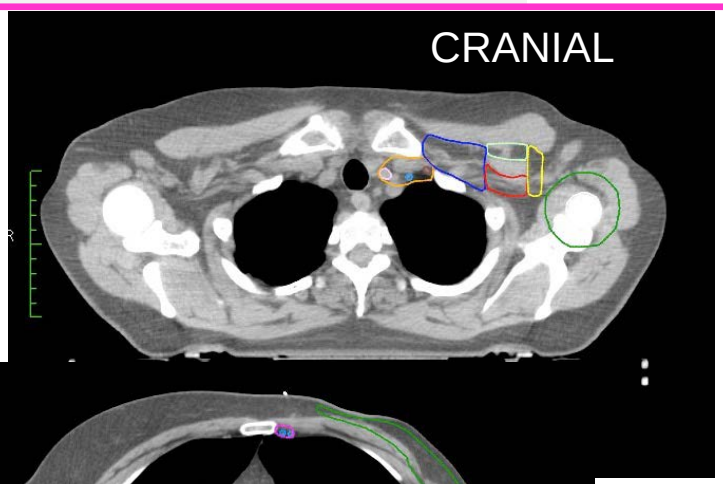

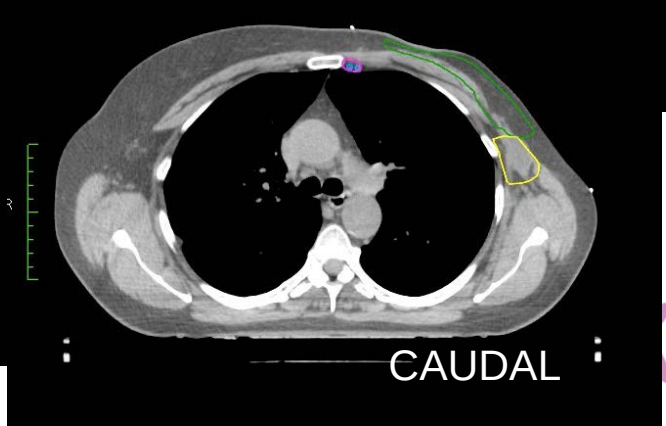

ESTRO School

DCBG guidelines for delineation of CTV of breast and CTVs of the regional lymph node regions

LN region	cranial	caudal	ventral	dorsal	lateral	medial
Level I	1 cm below caput humeri	Free edge of m. pectoralis major including seroma	5 mm below the skin	M. latissimus dorsi, 5 mm dorsal of the axillary vessels	Maximal to 5 mm below the skin	CTV-breast, lateral border of m. pectoralis minor, m. biceps brachii

DBCG guidelines

Level I of the axilla CTVn_L1	The top of the axillary artery where it crosses the lateral edge of the pectoralis minor muscle or 5 mm above the axillary vein, including clips and seroma	Around 4th–5th rib and guided by the clips and/or seroma if present	Not external to the 'imaginary' line between the anterior surface of pectoralis major muscle and latero-anterior border of the deltoid muscle (cranially) and the latissimus dorsi muscle (caudally), but include seroma and/or clips	Lateral border of the pectoralis major and minor muscle and the thoracic wall	Up to the 'imaginary line' connecting the anterior border of the subscapular m and the anterior border of the deltoid or latissimus dorsi muscle, so excluding the subscapular vessels

PROCAB guidelines

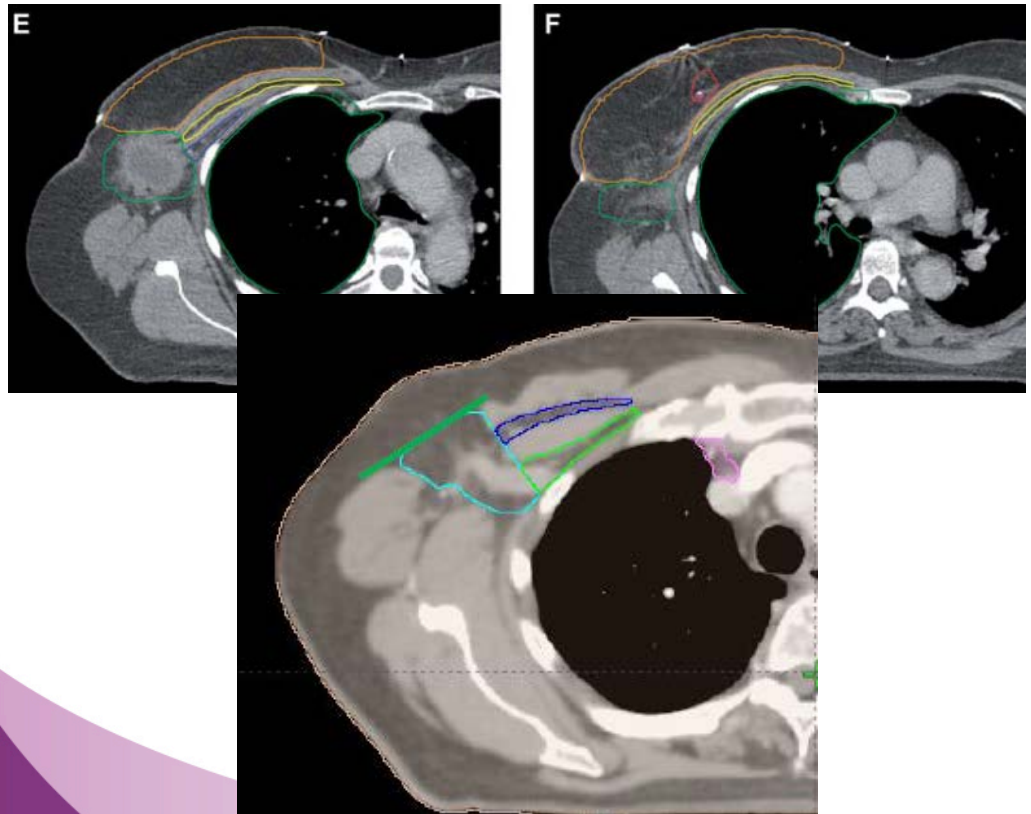

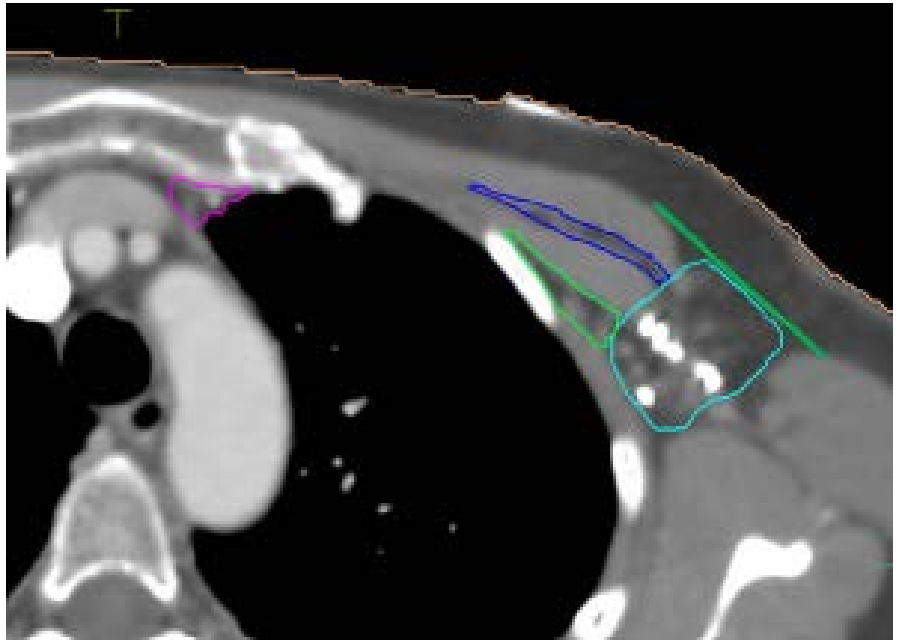

ESTRO School

CTV IM: INDICATIONS

- Controversy
- IN FAVOR: ↓ LR

  Freedman / Gustave-Roussy / Veronessi / Host
- AGAINST: No ↓ LR, fibrosis, cardiotoxicity
  Fowble / Obedian

RT IM if SN (+) (histologically confirmed) in IM

Locally advanced disease, medial tumour with positive axillary nodes

Trials: EORTC 22922 / Canadian **NCIC MA20**

ESTRO School

Budach *et al. Radiation Oncology* 2013, **8**:267
http://www.ro-journal.com/content/8/1/267

RADIATION ONCOLOGY

RESEARCH Open Access

Adjuvant radiotherapy of regional lymph nodes in breast cancer - a meta-analysis of randomized trials

Wilfried Budach[1*], Kai Kammers[2], Edwin Boelke[1] and Christiane Matuschek[1]

EORTC, MA.20, French

Meta-analysis concludes that RT to IM and SC statistically improve DFS and OS in I-III stages of BC.

Overall, it has to recommend including IM in locally advanced tumours.

The NEW ENGLAND JOURNAL of MEDICINE

N Engl J Med 2015;373:317-27.
DOI: 10.1056/NEJMoa1415369

ORIGINAL ARTICLE

Internal Mammary and Medial Supraclavicular Irradiation in Breast Cancer

P.M. Poortmans, S. Collette, C. Kirkove, E. Van Limbergen, V. Budach, H. Struikmans, L. Collette, A. Fourquet, P. Maingon, M. Valli, K. De Winter, S. Marnitz, I. Barillot, L. Scandolaro, E. Vonk, C. Rodenhuis, H. Marsiglia, N. Weidner, G. van Tienhoven, C. Glanzmann, A. Kuten, R. Arriagada, H. Bartelink, and W. Van den Bogaert, for the EORTC Radiation Oncology and Breast Cancer Groups*

4004 patients

Randomized between RT IMC and Medial SC nodes or no RT.

PATIENTS

From July 1996 through January 2004, a total of 4004 patients were enrolled at 46 institutions in 13 countries. Eligibility criteria included unilateral histologically confirmed breast adenocarcinoma of stage I, II, or III with a centrally or medially located primary tumor, irrespective of axillary involvement, or an externally located tumor with axillary involvement. Eligible patients had undergone mastectomy or breast-conserving surgery and axillary dissection. During the last years of the trial, patients were eligible if they had undergone a sentinel-node biopsy followed by an axillary dissection in the case of a positive node.

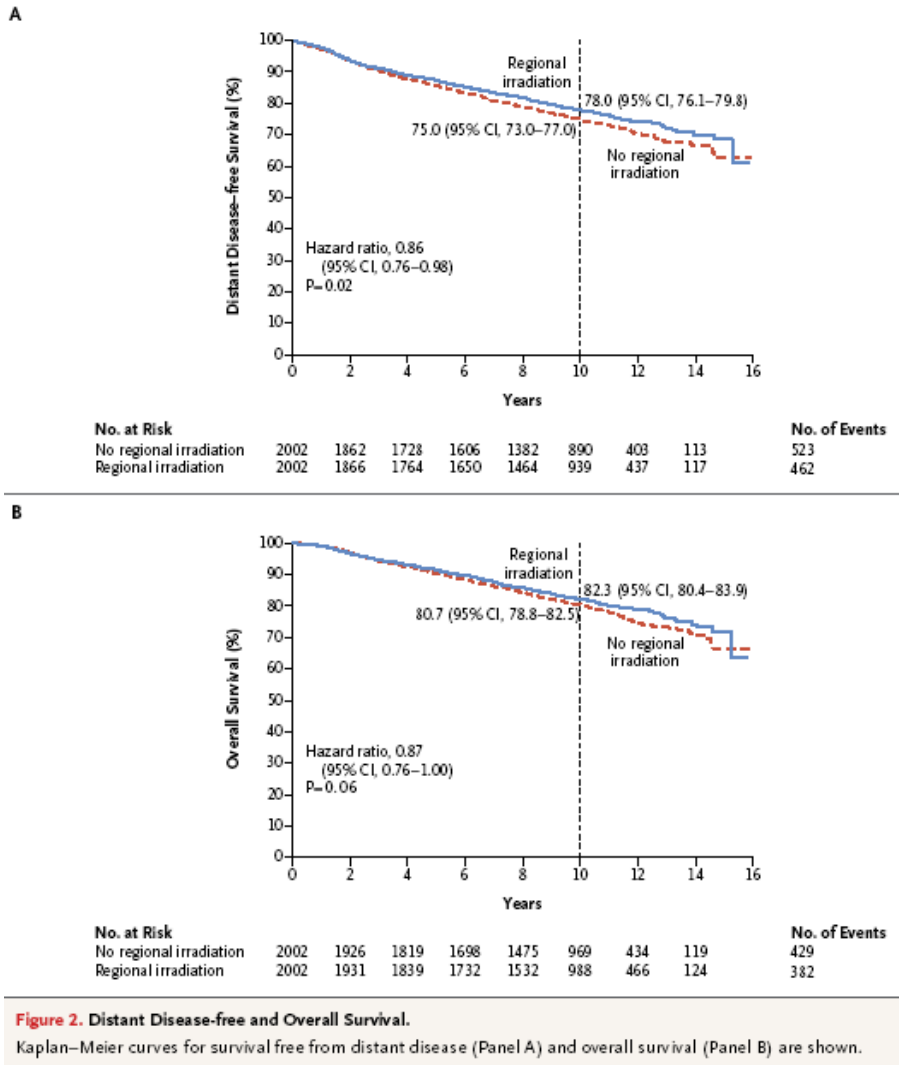

Figure 2. Distant Disease-free and Overall Survival.
Kaplan–Meier curves for survival free from distant disease (Panel A) and overall survival (Panel B) are shown.

CONCLUSIONS

In patients with early-stage breast cancer, irradiation of the regional nodes had a marginal effect on overall survival. Disease-free survival and distant disease-free survival were improved, and breast-cancer mortality was reduced. (Funded by Fonds

	Cranial	Caudal	Anterior	Posterior	Lateral	Medial
Internal mammary	Superior aspect of the medial 1st rib.	Cranial aspect of the 4th rib	_ e.	_ e.	_ e.	_ e.
Internal mammary chain CTVn_IMN	Caudal limit of CTVn_L4	Cranial side of the 4th rib (in selected cases 5th rib, see text)	Ventral limit of the vascular area	Pleura	5 mm from the internal mammary vein (artery in cranial part up to and including first intercostal space)	5 mm from the internal mammary vein (artery in cranial part up to and including first intercostal space)

Most IMN in first 3-4 intercostal spaces

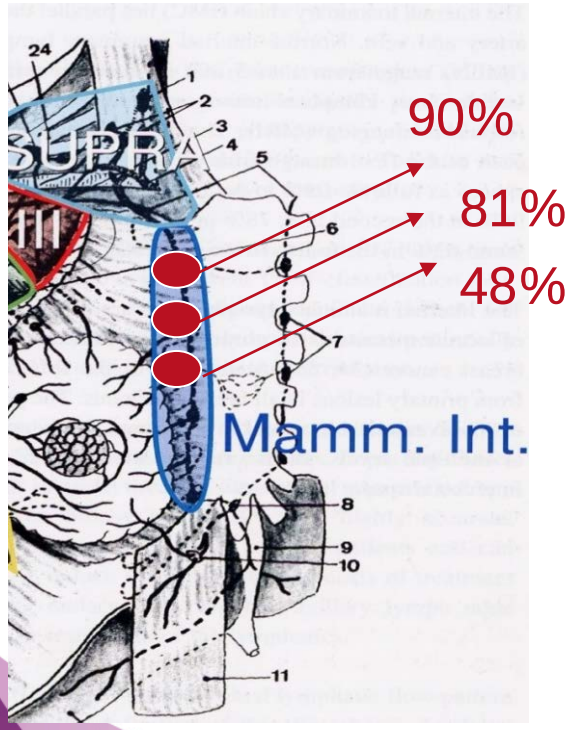

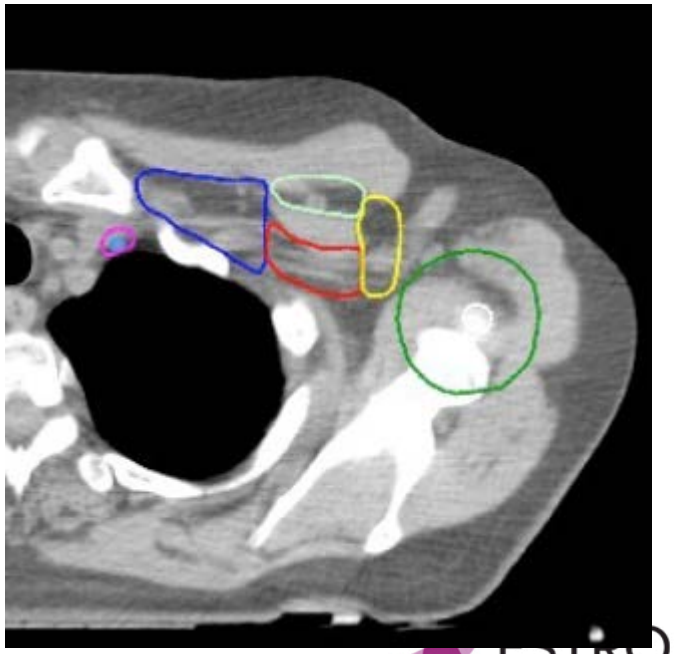

ESTRO School

Interpectoral nodes CTVn_interpectoralis	
Cranial	Includes the cranial extent of the axillary artery (i.e. 5 mm cranial of axillary vein)
Caudal	Level 2's caudal limit
Ventral	Major pectoral muscle
Dorsal	Minor pectoral muscle
Medial	Medial edge of minor pectoral muscle
Lateral	Lateral edge of minor pectoral muscle

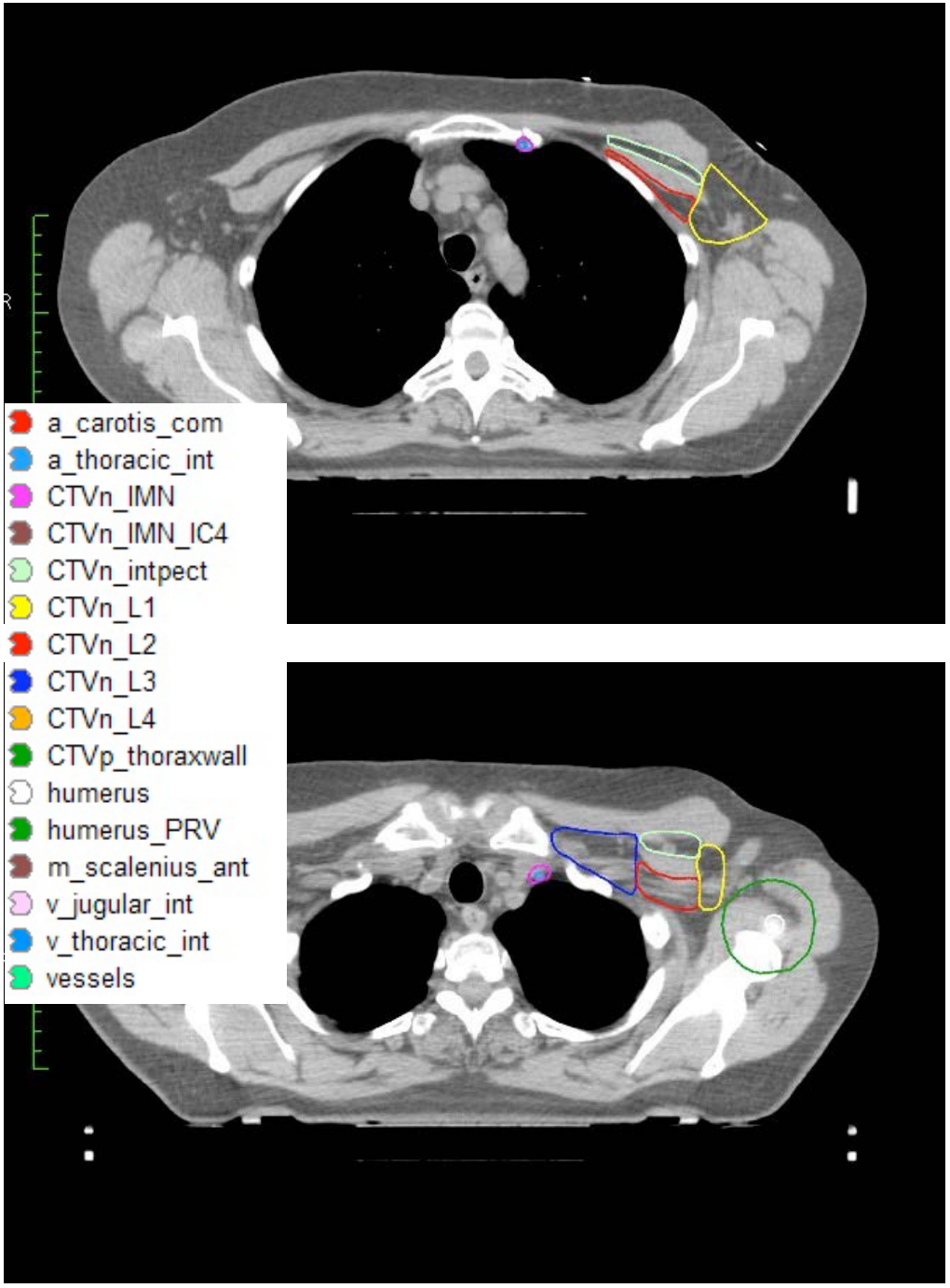

Interpectoral or Rotter lymph nodes: between pectoral major and minor

ESTRO School

- Introduction
- Indications and CTV:
  - Whole Breast
  - Boost
  - Chest wall
  - Regional nodal
    - L4, L3, L2, L1, IM, Rotter
- **Organs at risk and constraints**
- Margins CTV → PTV OAR → PRV
- Conclusions

ESTRO School

ORGANS AT RISK

- Lung
- Heart
- Contralateral breast
- Skin
- Humeral heads
- Spinal Cord
- Thyroid
- Brachial plexus

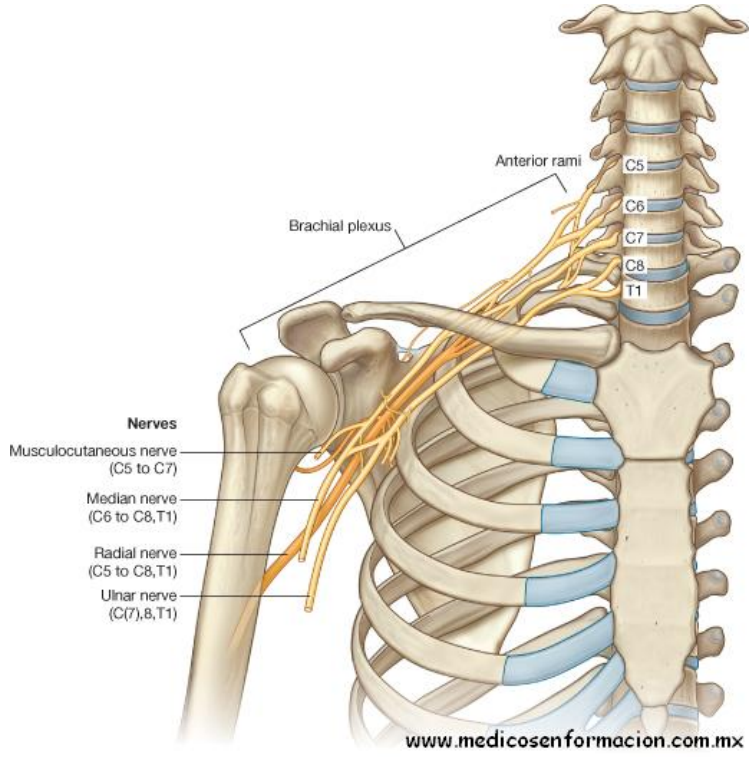

ESTRO School

LUNG

- Automatic delineation
- Both lungs should be evaluated as a single organ
- Pulmonary hila and trachea should be excluded

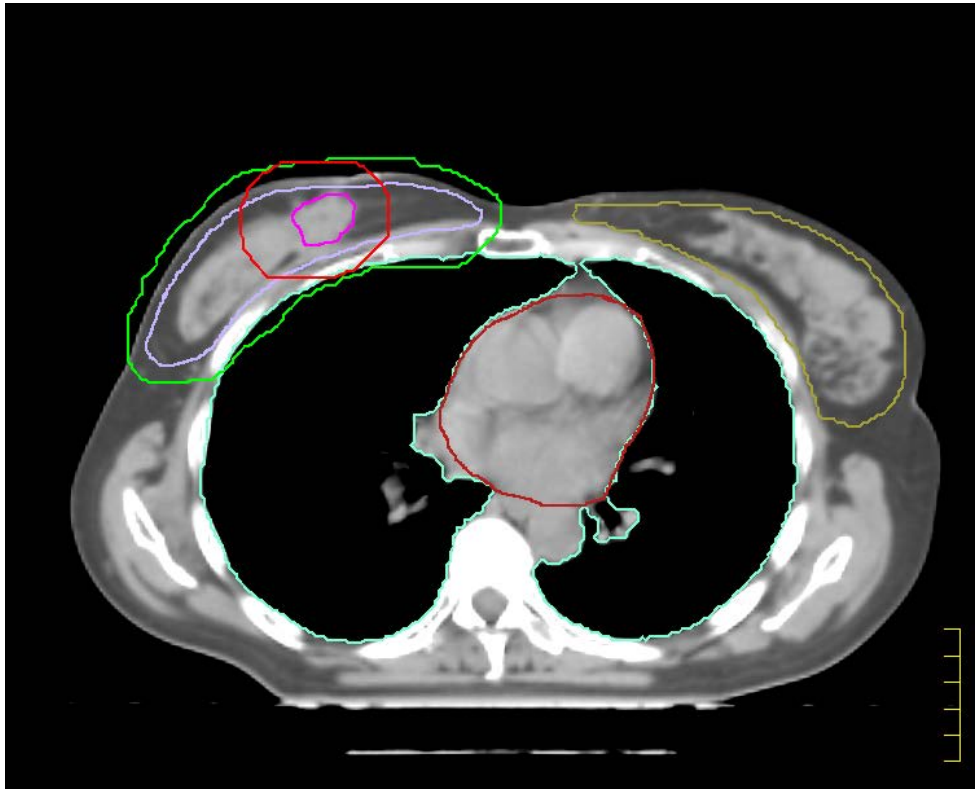

HEART

- It begins below the left pulmonary artery
- The first cavity that appears usually is the left atrium
- Lower limit: peak myocardial
- The whole heart should be contoured apart from the pericardium
- The left anterior descending coronary artery should be outlined, if it's possible
- Pulmonary artery trunk, ascending aorta and superior vena cava should be excluded

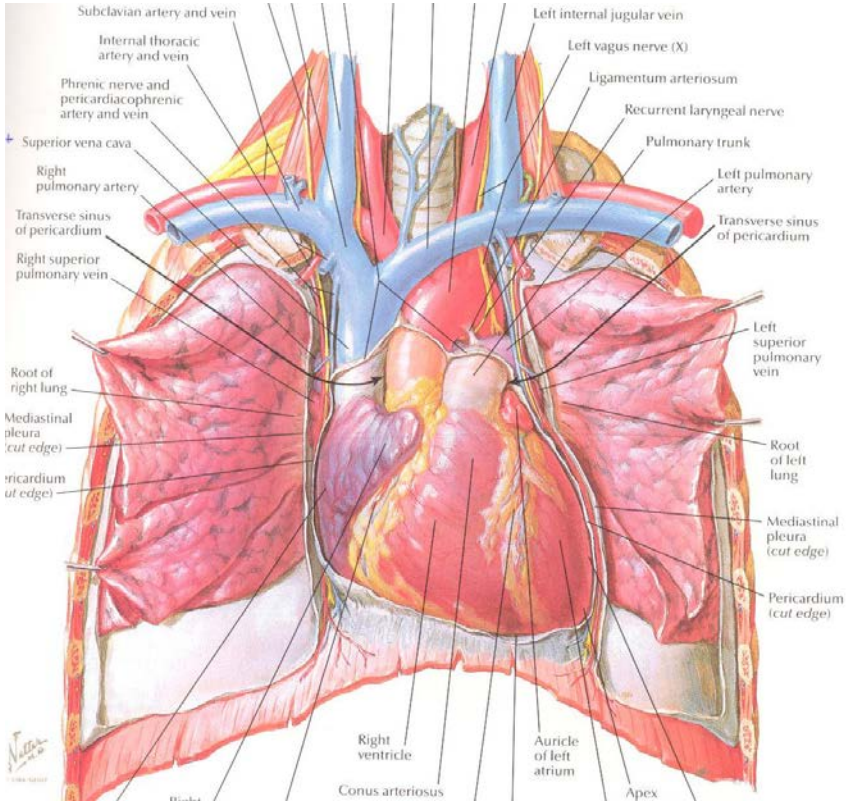

University of Michigan Medical Center

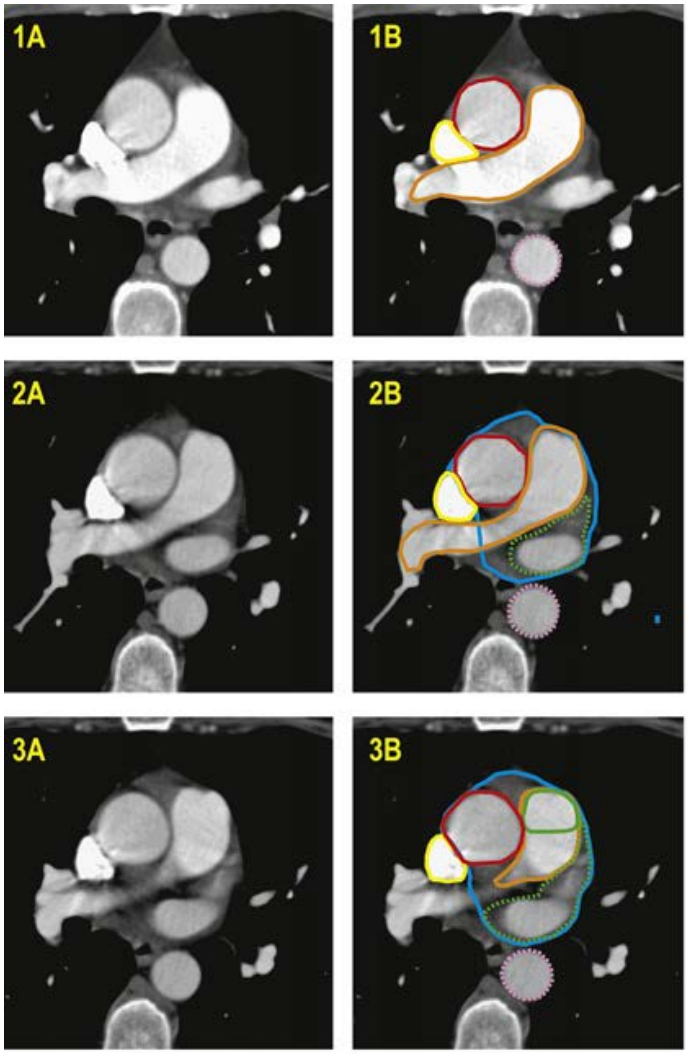

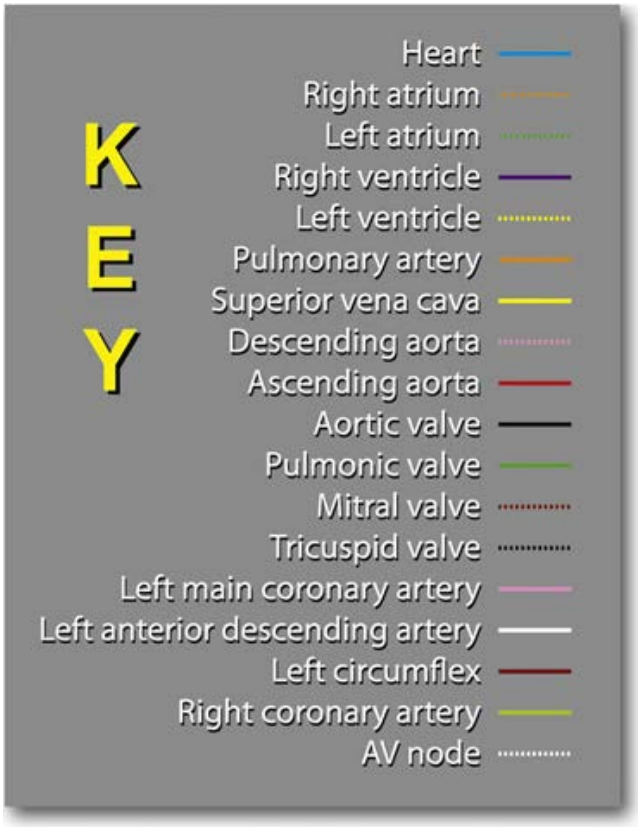

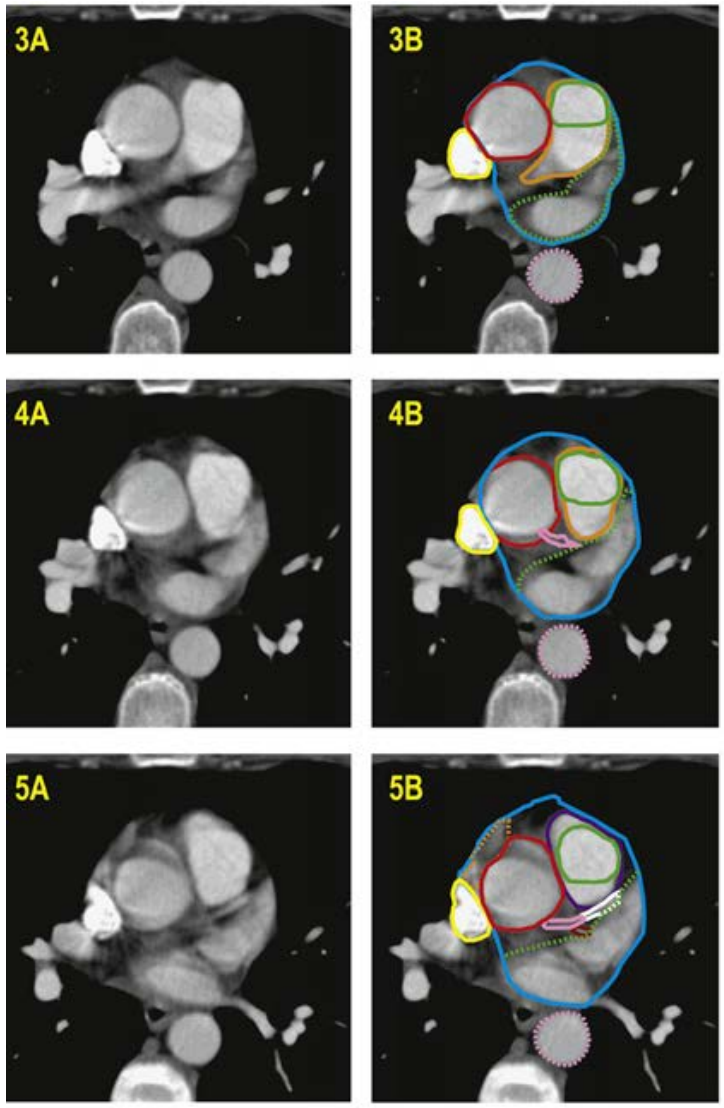

Int J Radiat Oncol Biol Phys. 2011 January 1; 79(1): 10–18. doi:10.1016/j.ijrobp.2009.10.058.

Development and validation of a heart atlas to study cardiac exposure to radiation following treatment for breast cancer

Mary Feng, M.D.[1], **Jean M. Moran, Ph.D.**[1], **Todd Koelling, M.D.**[2], **Aamer Chughtai, M.D.**[3], **June L. Chan, M.D.**[1], **Laura Freedman, M.D.**[1], **James A. Hayman, M.D.**[1], **Reshma Jagsi, M.D., D. Phil.**[1], **Shruti Jolly, M.D.**[1], **Janice Larouere, M.D.**[1], **Julie Soriano, M.D.**[1], **Robin Marsh, C.M.D.**[1], and **Lori J. Pierce, M.D.**[1]

[1] Department of Radiation Oncology, University of Michigan Medical Center

First LEFT ATRIUM

LEFT ANTERIOR DESCENDING ARTERY

ESTRO School

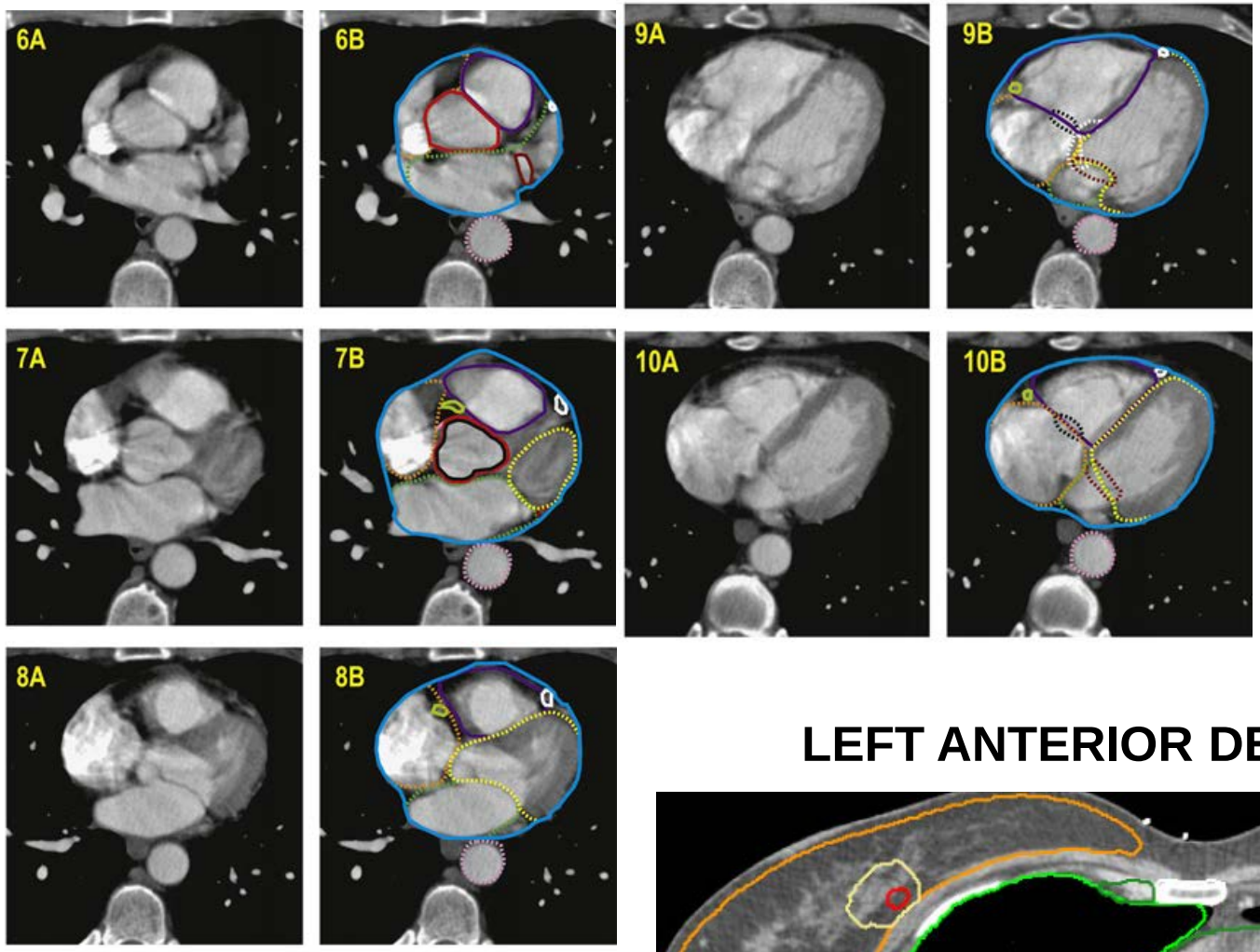

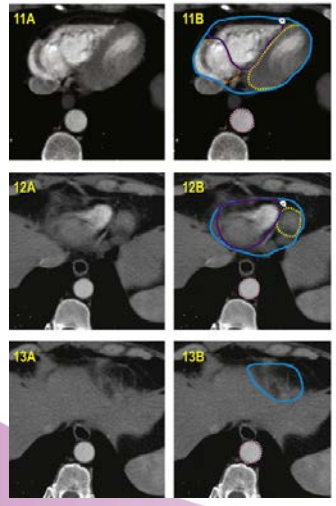

KEY

- Heart
- Right atrium
- Left atrium
- Right ventricle
- Left ventricle
- Pulmonary artery
- Superior vena cava
- Descending aorta
- Ascending aorta
- Aortic valve
- Pulmonic valve
- Mitral valve
- Tricuspid valve
- Left main coronary artery
- Left anterior descending artery
- Left circumflex
- Right coronary artery
- AV node

LEFT ANTERIOR DESCENDING ARTERY

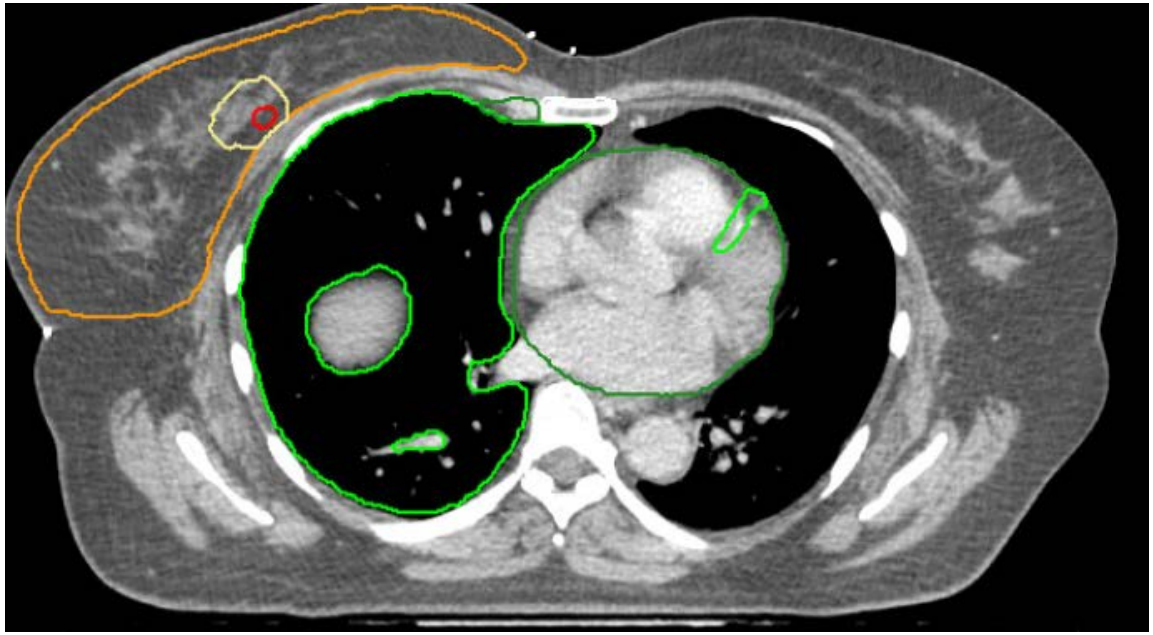

ESTRO School

CONSTRAINTS (Our Department)

Total volume of both *lungs* taken together V20<30%
Ipsilateral lung V20<20-25%, mean dose <15Gy
Contralateral lung V10<10% mean dose <5Gy

Heart V20<10%, V25<10%, V45<30%, V50<20%

Contralateral breast V10<10% mean dose <5Gy

Humerus and ribcage maximum dose 50Gy

Brachyal plexus maximum dose 60Gy

Thyroid maximum dose 45Gy

Spinal cord maximum dose 46Gy

Other: QUANTEC

ESTRO School

- Introduction
- Indications and CTV:
  - Whole Breast
  - Boost. Partial Breast Irradiation
  - Chestwall
  - Regional nodal
    - L4, L3, L2, L1, IM, Rotter
- Organs at risk and constraints
- **Margins CTV → PTV OAR → PRV**
- Conclusions

ESTRO School

5 mm

CTV → PTV (Planning Target Volume)
OAR → PRV (Planning Organs at Risk Volume)

ICRU (International Comission on Radiation Units and Mesuraments) 50 and 62

CTV margin to create PTV:
- geometrical errors
- internal motion of CTV
- treatment technique (beam orientation)
- intra and interfractional errors (patient fixation, daily setup errors)

OAR margin to create PRV: movements of the OAR due to the change in size and setup uncertainities

ESTRO School

5 mm

CTV → PTV (Planning Target Volume)
OAR → PRV (Planning Organs at Risk Volume)

The recommended CTV margin to create PTV is at least 5 mm.

But, PTV outside skin can't be used for dosimetric calculations (air, outside the body ...). Typical solutions:

1. To crop PTV by 3 mm (without reaching the skin) but treatment planning carried out with 2-3 cm
2. To create PTV outside the body (margin for breathing) without croping → An additional "cropped" PTV volume will then be needed for normalization purposes and DVH analysis

ESTRO School

5 mm

CTV → PTV (Planning Target Volume)
OAR → PRV (Planning Organs at Risk Volume)

PTV Breast 5 mm, skin 3-5 mm
PTV Boost 5 - 10 mm, skin 3-5 mm
PTV Chest wall 5 mm, skin 0-5 mm
PTV Nodes 5 mm
PRV 5 mm

Avoid the lungs

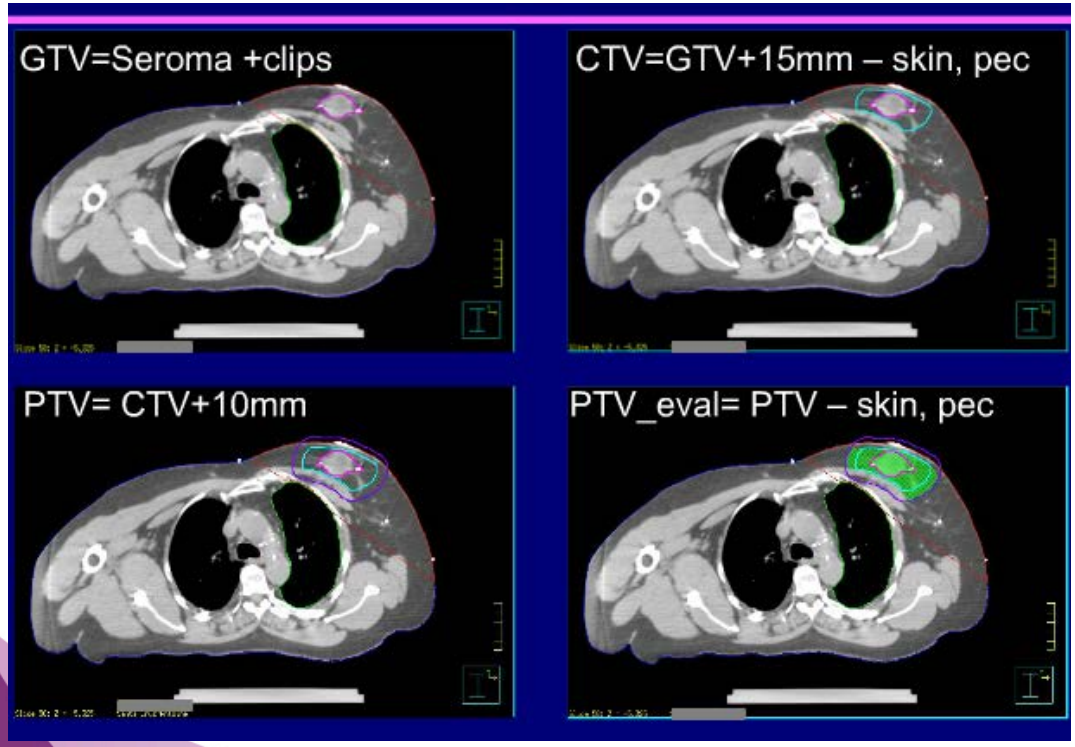

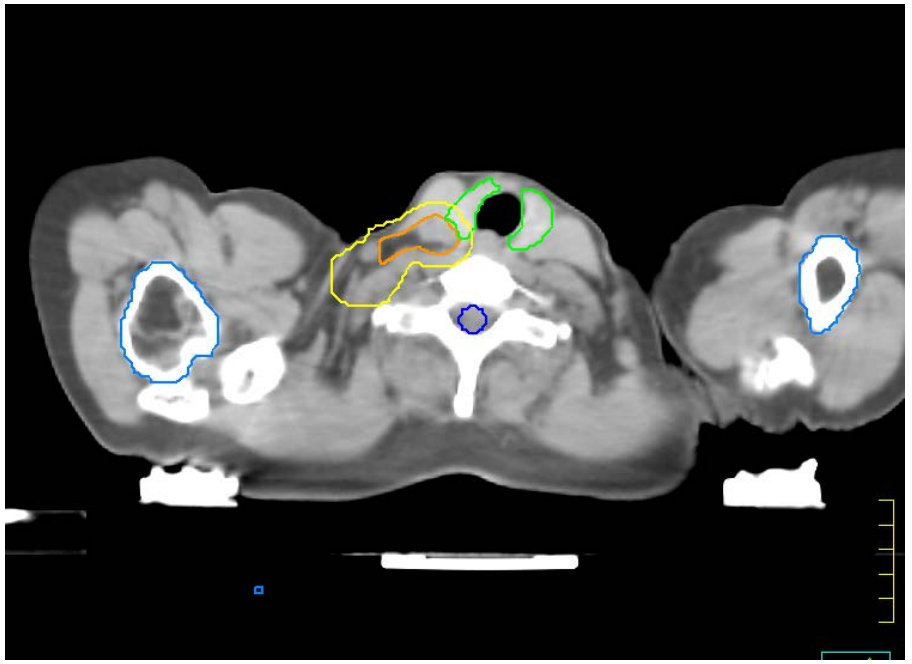

ESTRO School

- Introduction
- Indications and CTV:
  - Whole Breast
  - Boost
  - Chest wall
  - Regional nodes
    - L4, L3, L2, L1, IM, Rotter
- Organs at risk and constraints
- Margins CTV → PTV OAR → PRV
- **Conclusions**

ESTRO School

CONCLUSIONS

- Irradiation of breast cancer involves a variety of clinical situations and individualized treatment for each patient can be designed
- Clear criteria are needed for PTV and OAR delineation. Several guidelines (RTOG, DCBCG, PROCAB, ESTRO) are helpful for delineating CTV in breast cancer
- Adequate positioning, immobilization and verification systems are needed

Proper volumes delineation is CRUCIAL

ESTRO School

QUICK GUIDE

Breast or chest wall:

CRANIAL: Clinical reference, maximally up to inferior edge sterno-clavicular joint
CAUDAL: Breast end (chest wall: guided by contralateral breast)
ANT: 5 mm skin or skin (RTOG)
POST: Pectoral M, intercostal muscle or ribs, or include both (Chest Wall) (RTOG)
LAT: Clinical reference, anterior to the lateral thoracic artery
MEDIAL: Sternal-rib junction

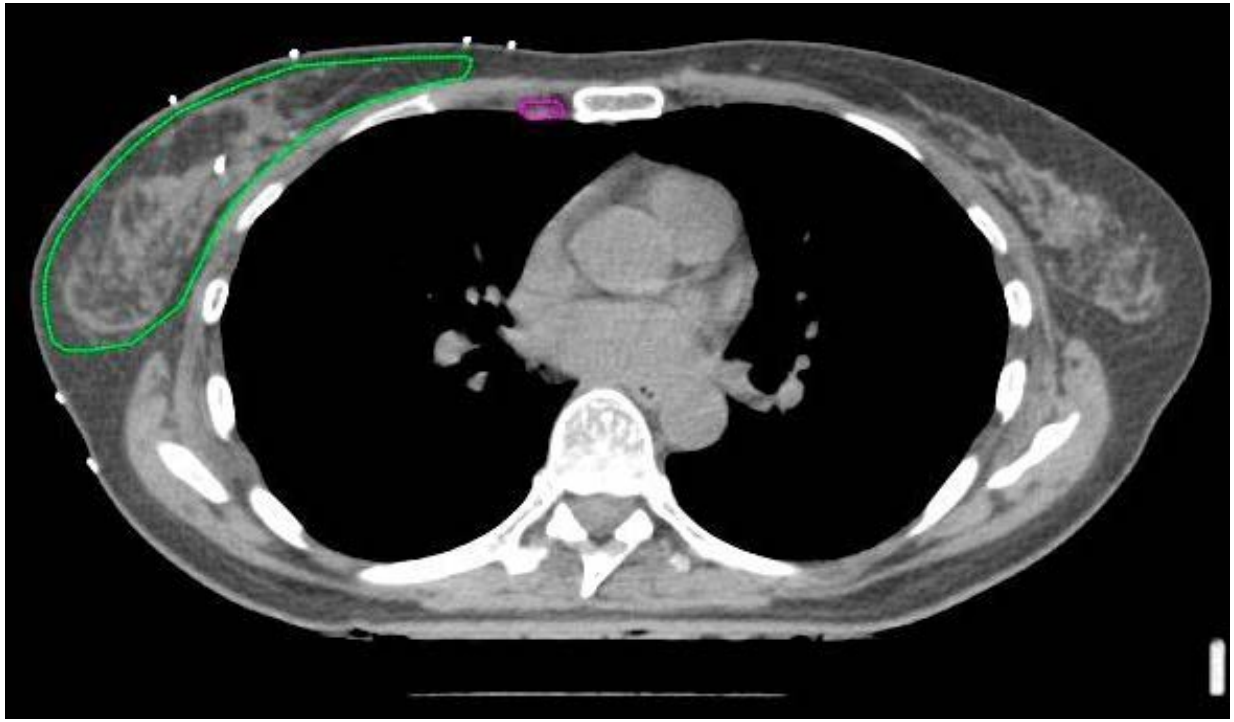

ESTRO School

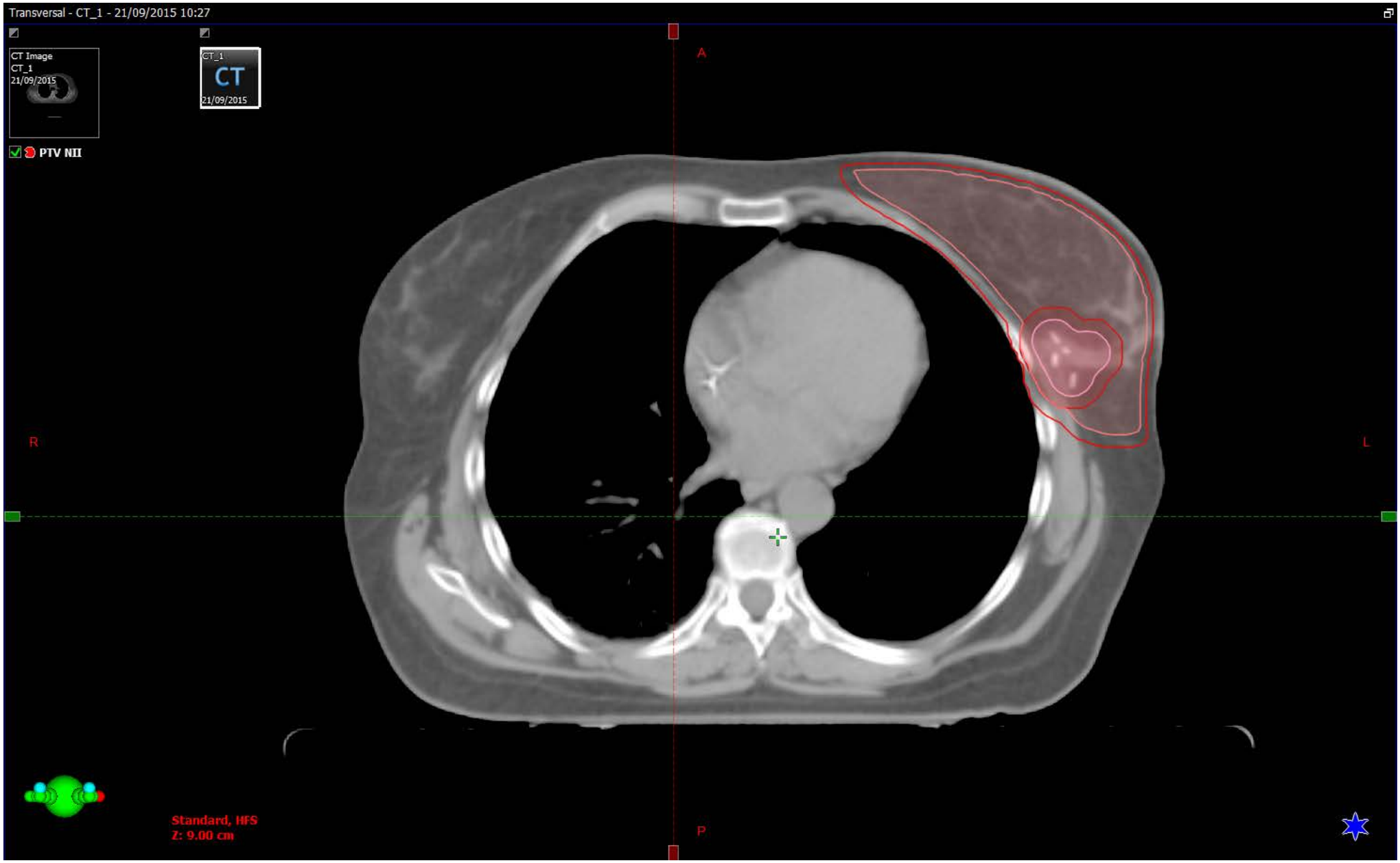

ESTRO School

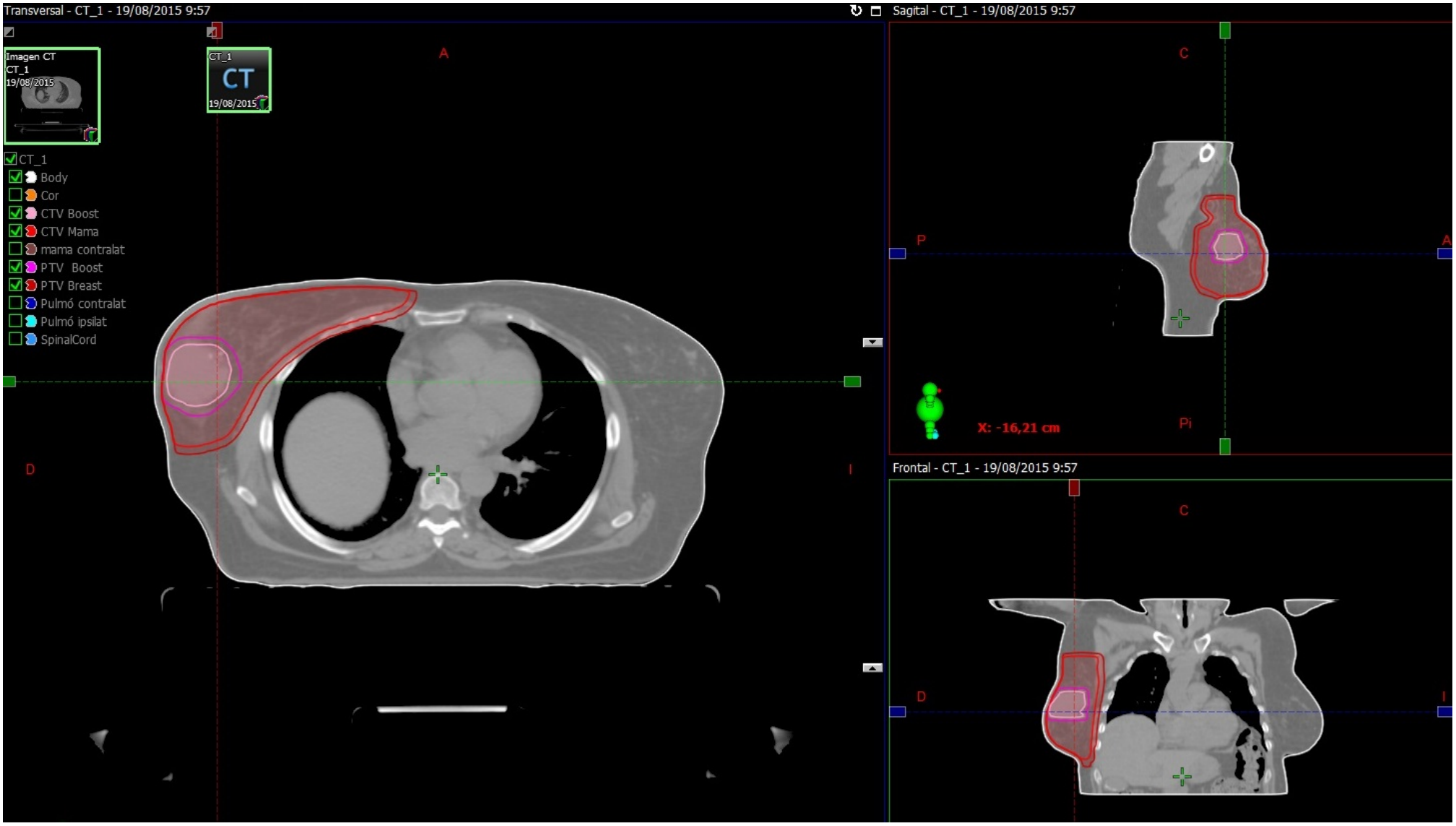
Transversal - CT_1 - 19/08/2015 9:57
Imagen CT
CT_1
19/08/2015
CT_1
CT
19/08/2015
A
CT_1
Body
Cor
CTV Boost
CTV Mama
mama contralat
PTV Boost
PTV Breast
Pulmó contralat
Pulmó ipsilat
SpinalCord
D
I
Sagital - CT_1 - 19/08/2015 9:57
C
P
A
X: -16,21 cm
Pi
Frontal - CT_1 - 19/08/2015 9:57
C
D
I

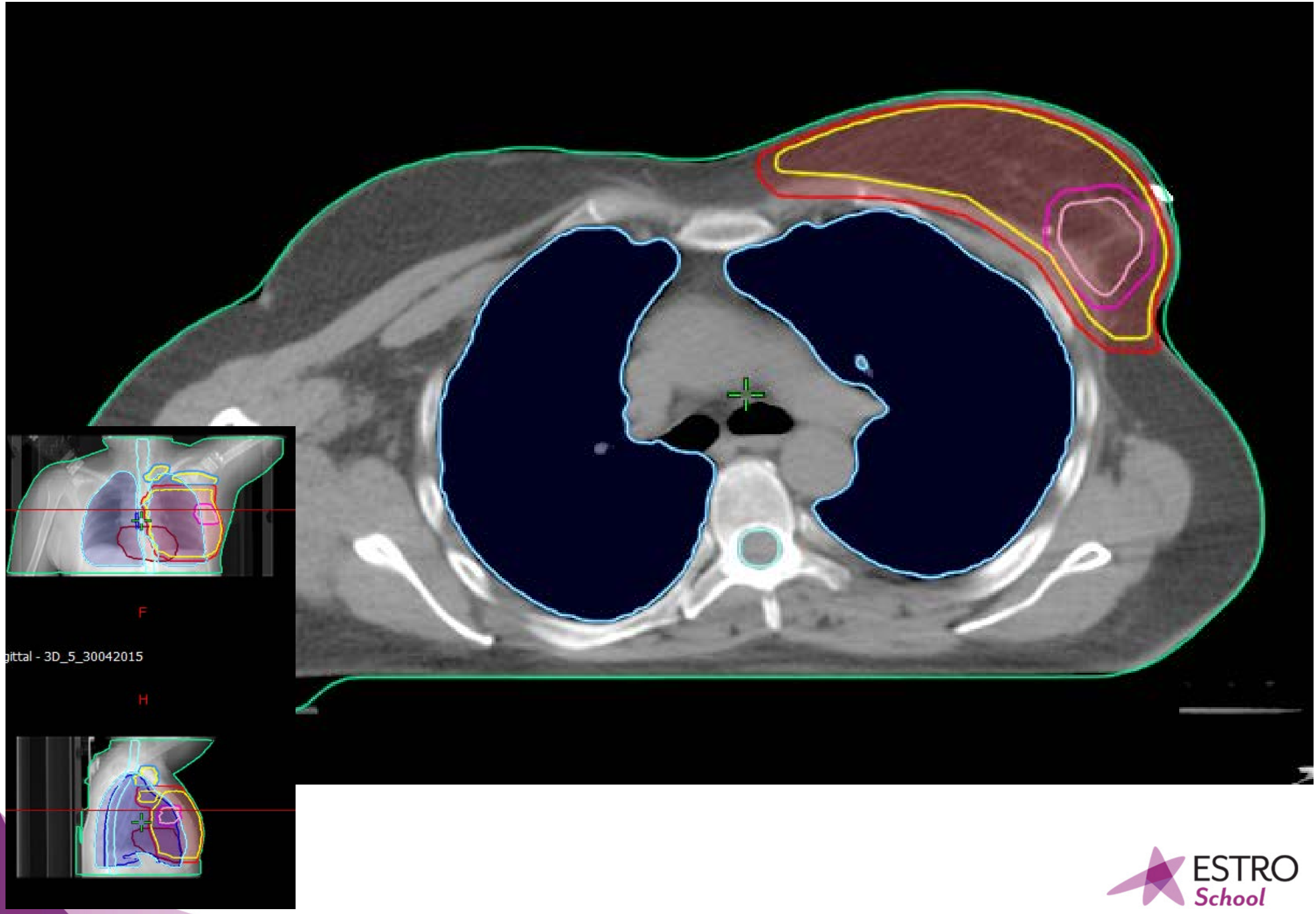

ESTRO School

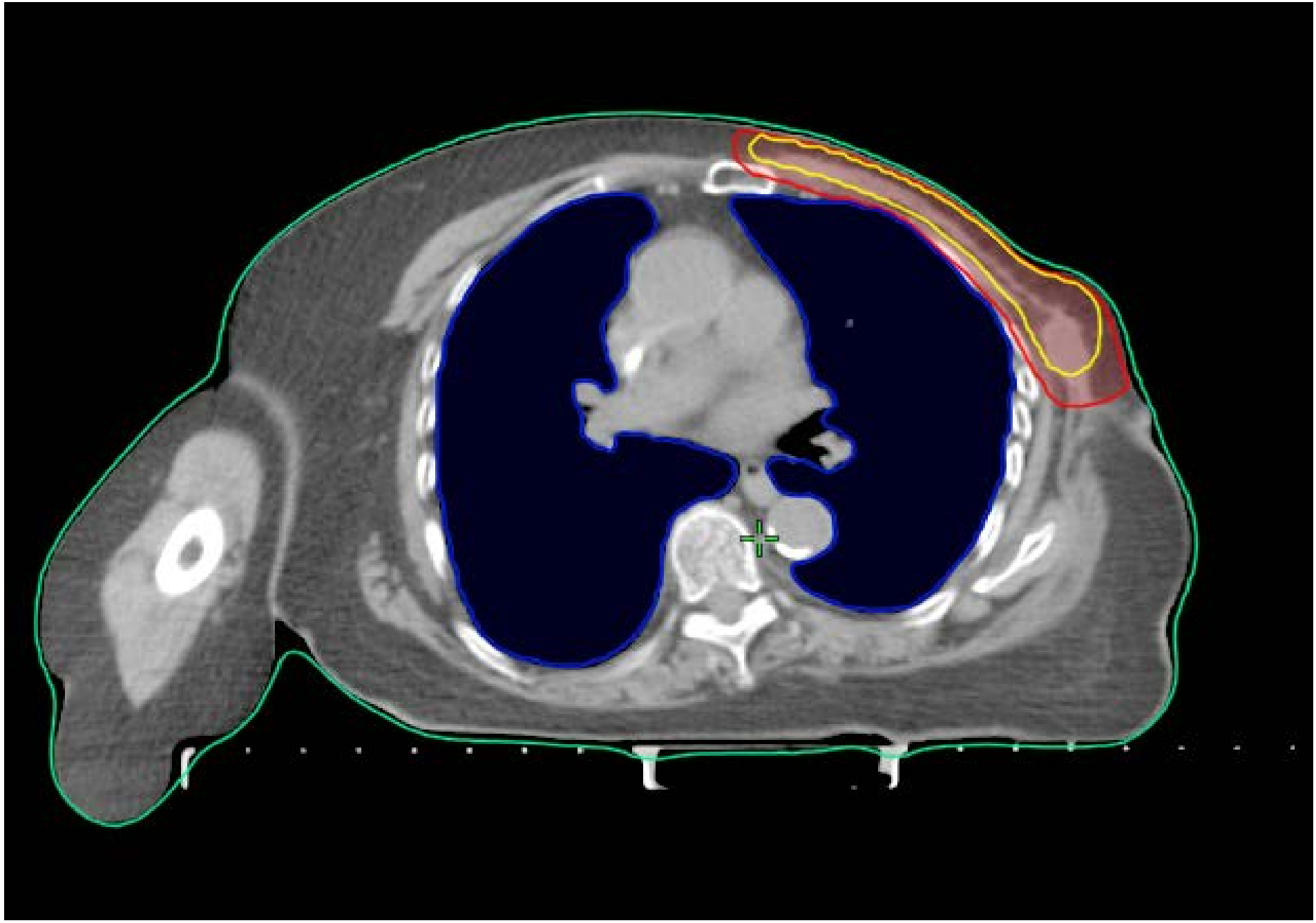

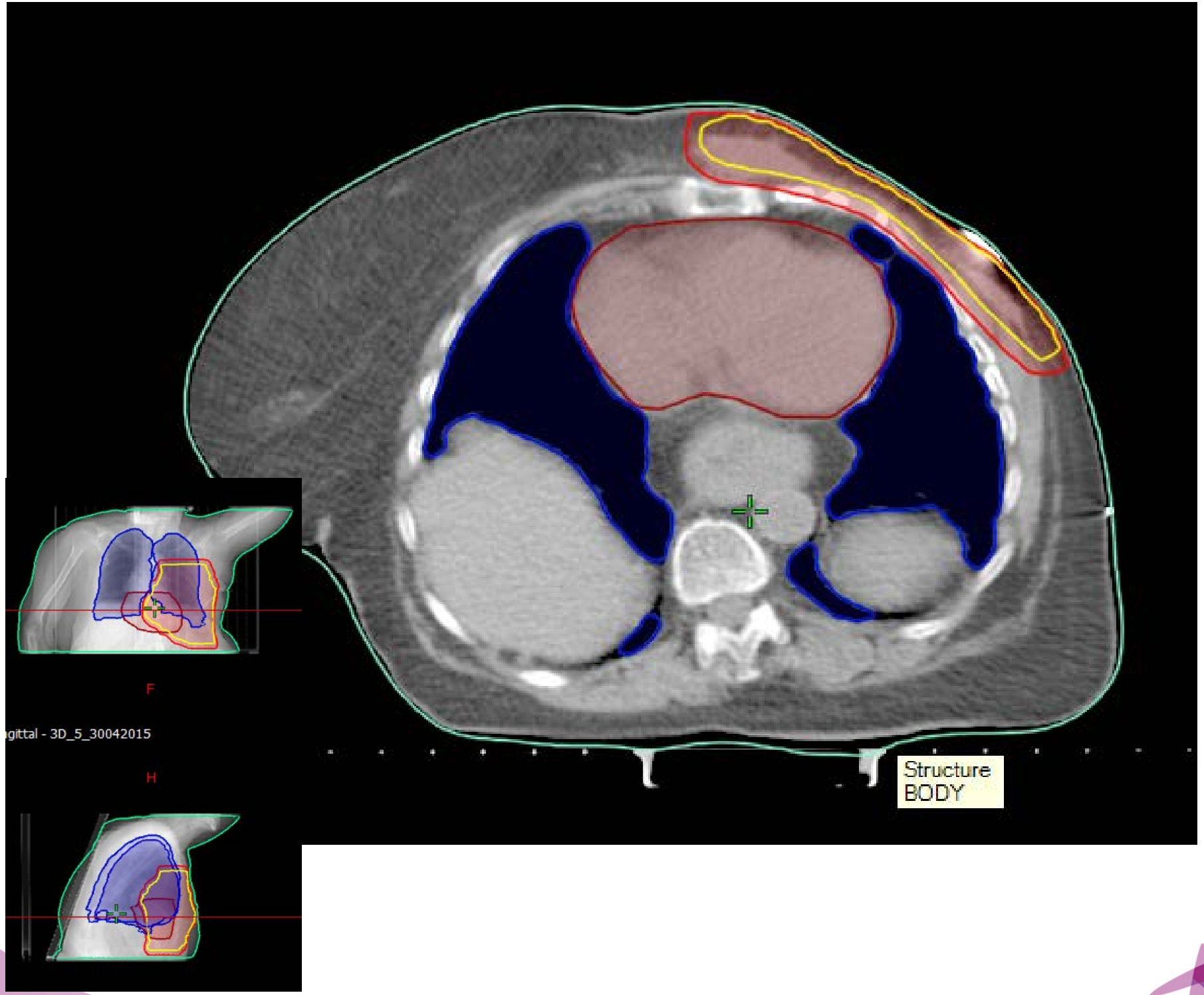
F
gittal - 3D_5_30042015
H
Structure
BODY

QUICK GUIDE

L4:

CRANIAL: Cranial subclavian artery or caudal cricoid (RTOG)
CAUDAL: 5 mm subclavian vein or caudal edge clavicle head (RTOG)
ANT: SCM muscle
POST: Scalene muscle
LAT: Lateral edge of SCM or junction 1st rib-clavicle
MEDIAL: Include: jugular vein. Exclude: common cartotid artery, thyroid

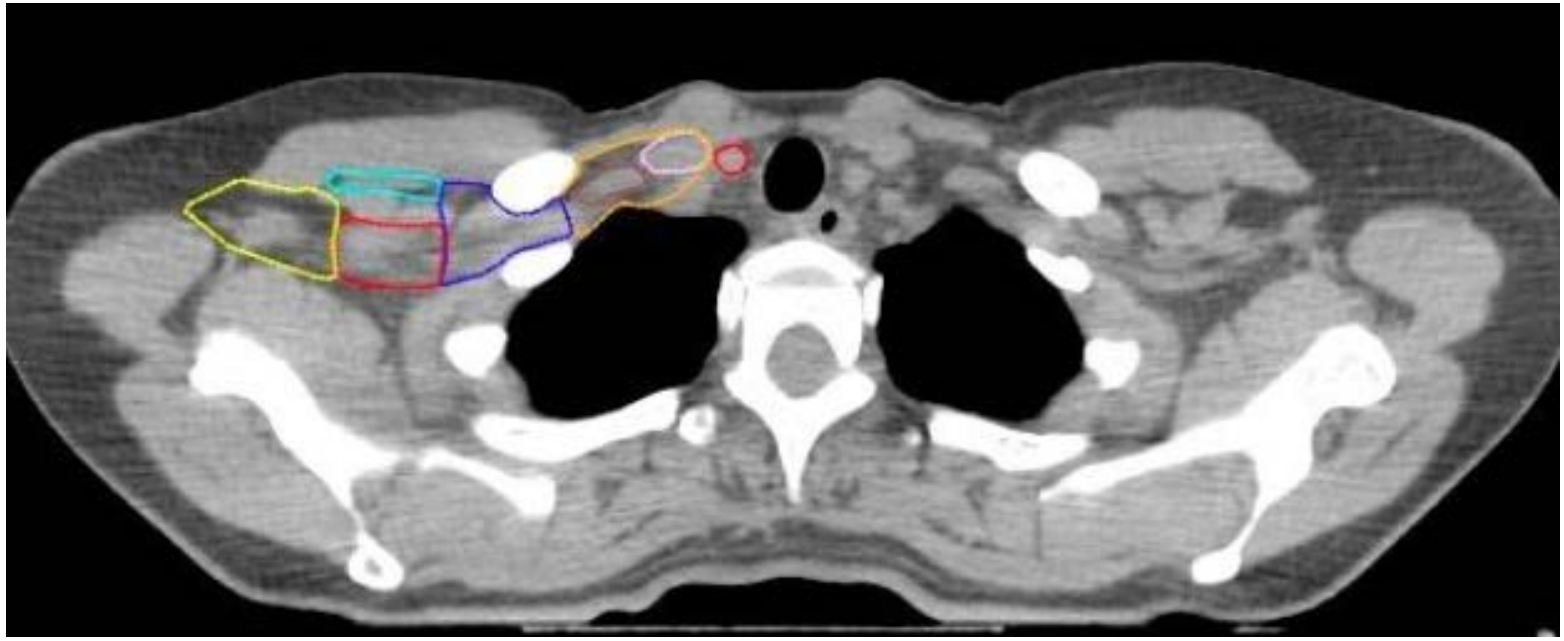

ESTRO School

Transversal - CT_1 - 21/09/2015 10:27
CRANIAL LEVEL IV
SCM
Jugular vein
L4
Common Carotid A
Scalene ms
CT_1
Axillary vessels
Body
Common Carotid A
Contralat Lung
Cricoid
CTV I
CTV II
CTV III
CTV IV
CTV_boost
CTV_breast
Heart
Int jugular Vein
Ipsilat Lung
Latissimus dorsi
Left subclavian
Nipple
OR_laryng_thyroi
Pectoralis major
Pectoralis minor
PTV III
PTV IV
PTV_Boost
PTV_Breast
Scalene
SCM
Spinal cord
Subclavian A
Subscapulary ms
Standard, HFS
Z: 23.50 cm

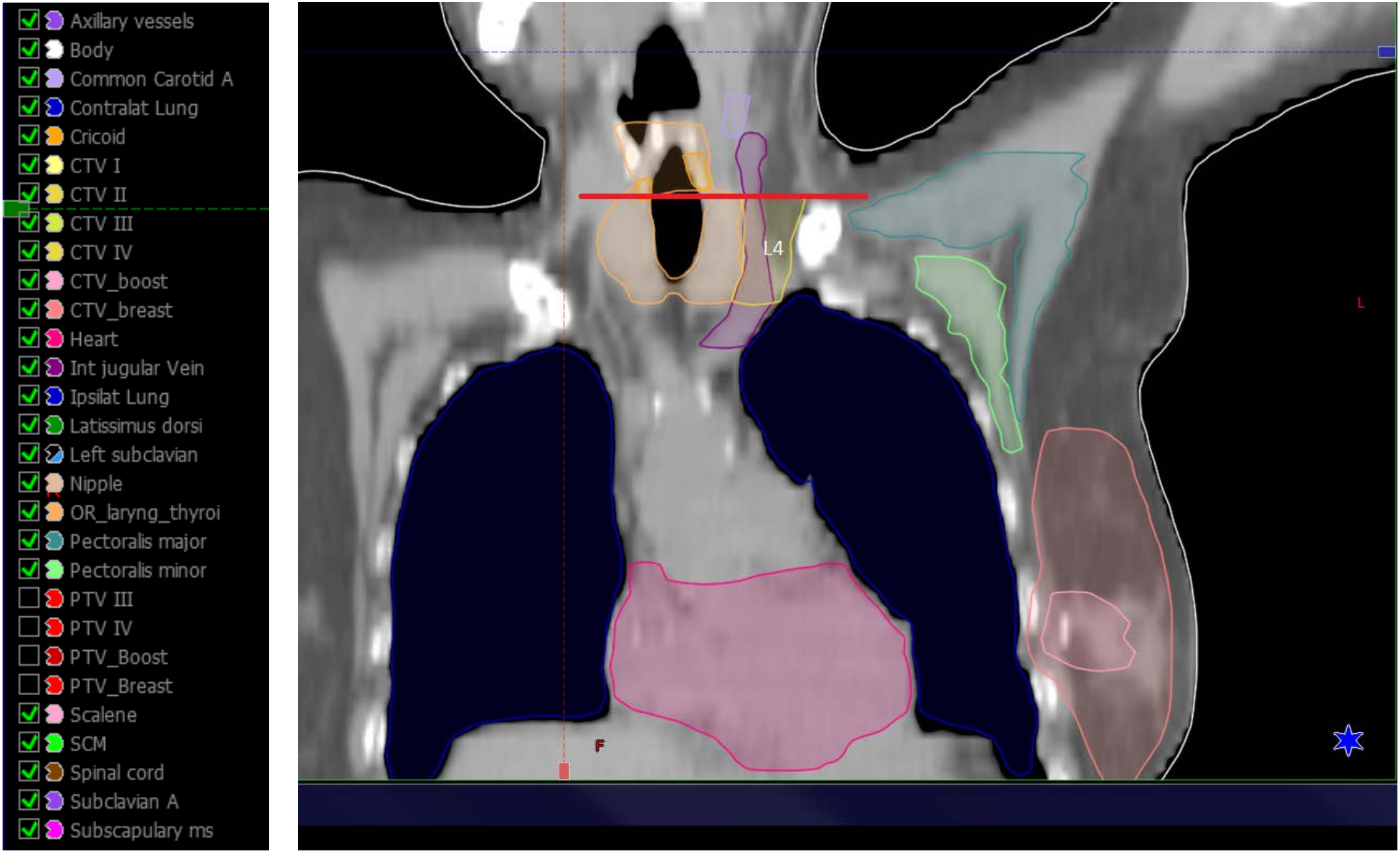

ESTRO School

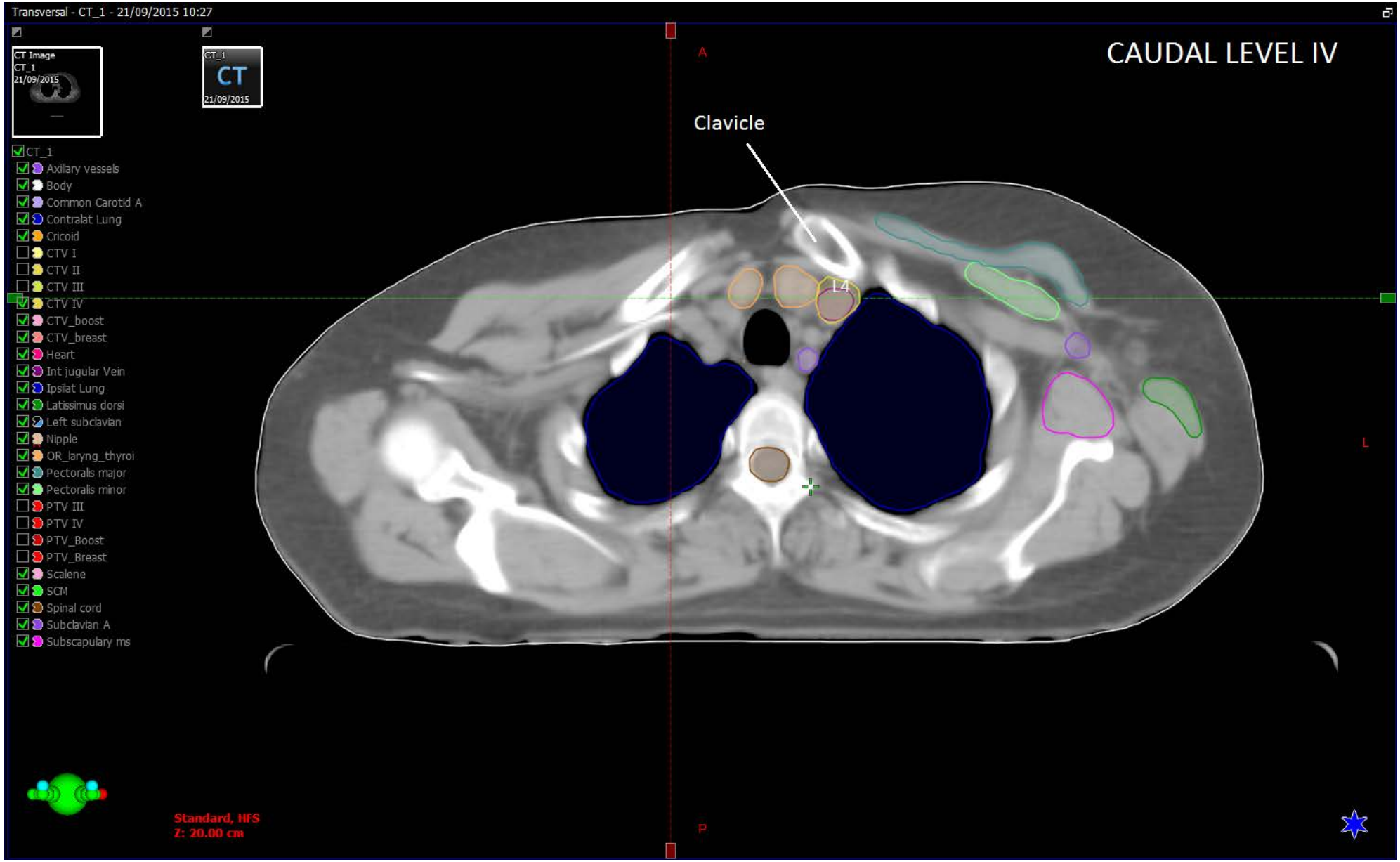

ESTRO School

QUICK GUIDE

L3:

CRANIAL: Cranial subclavian artery or pectoral minor insert on coracoid (RTOG).
Where the subclavian artery passes the line between clavicle-1st rib (PROCAB)

CAUDAL: Where the axillary vessels cross the medial edge of pectoral minor

ANT: Pectoralis major

POST: Ribs and intercostal muscles

LAT: Medial border pectoral minor

MEDIAL: The junction of subclavian and internal jugular veins

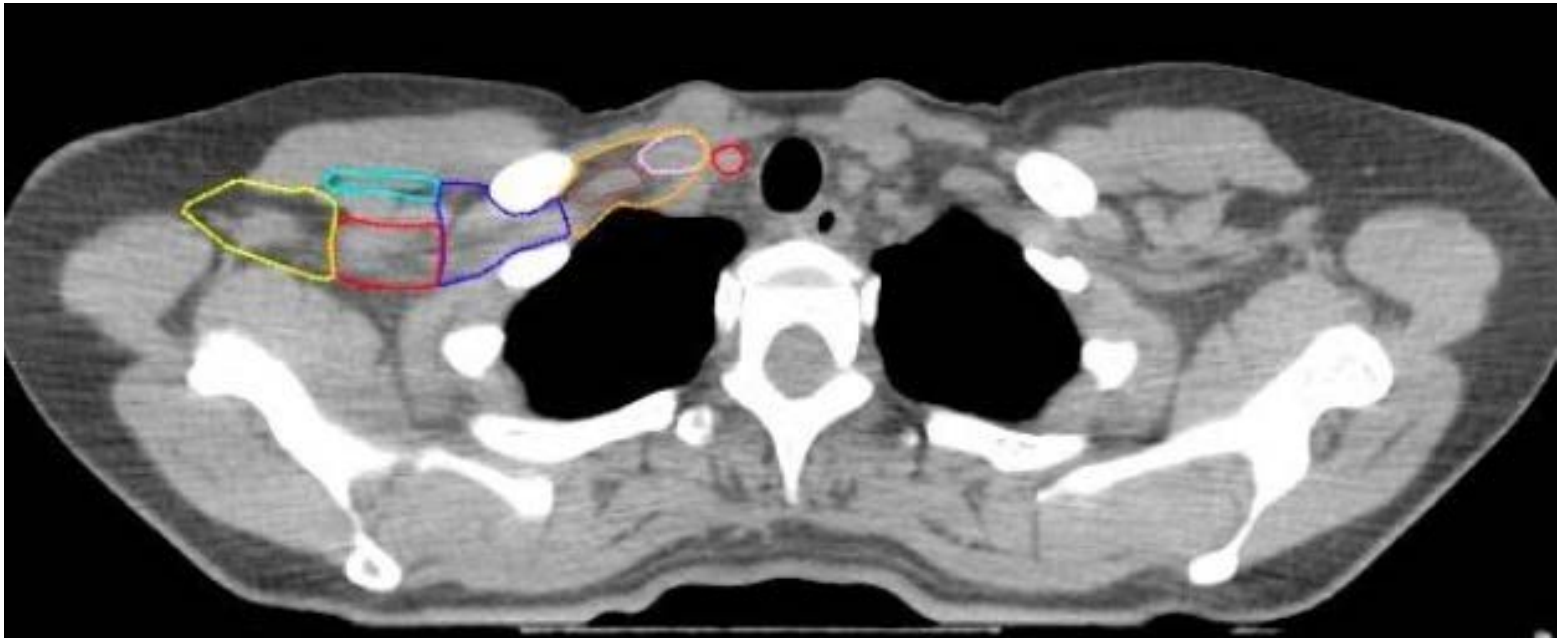

ESTRO School

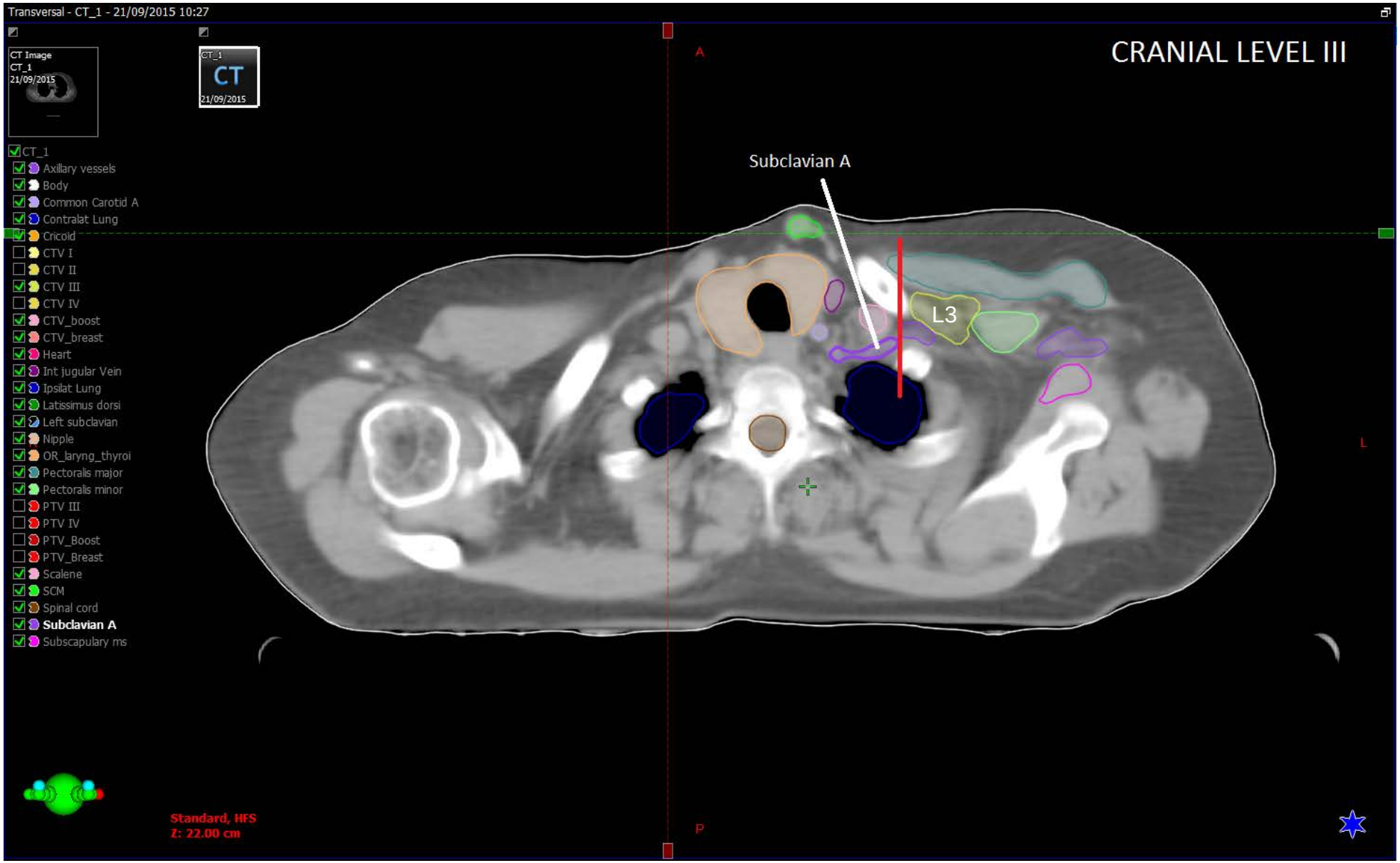
Transversal - CT_1 - 21/09/2015 10:27
CT Image
CT_1
21/09/2015
CT_1
CT
21/09/2015
CRANIAL LEVEL III
A
Subclavian A
L3
L
P
CT_1
Axillary vessels
Body
Common Carotid A
Contralat Lung
Cricoid
CTV I
CTV II
CTV III
CTV IV
CTV_boost
CTV_breast
Heart
Int jugular Vein
Ipsilat Lung
Latissimus dorsi
Left subclavian
Nipple
OR_laryng_thyroi
Pectoralis major
Pectoralis minor
PTV III
PTV IV
PTV_Boost
PTV_Breast
Scalene
SCM
Spinal cord
Subclavian A
Subscapulary ms
Standard, HFS
Z: 22.00 cm

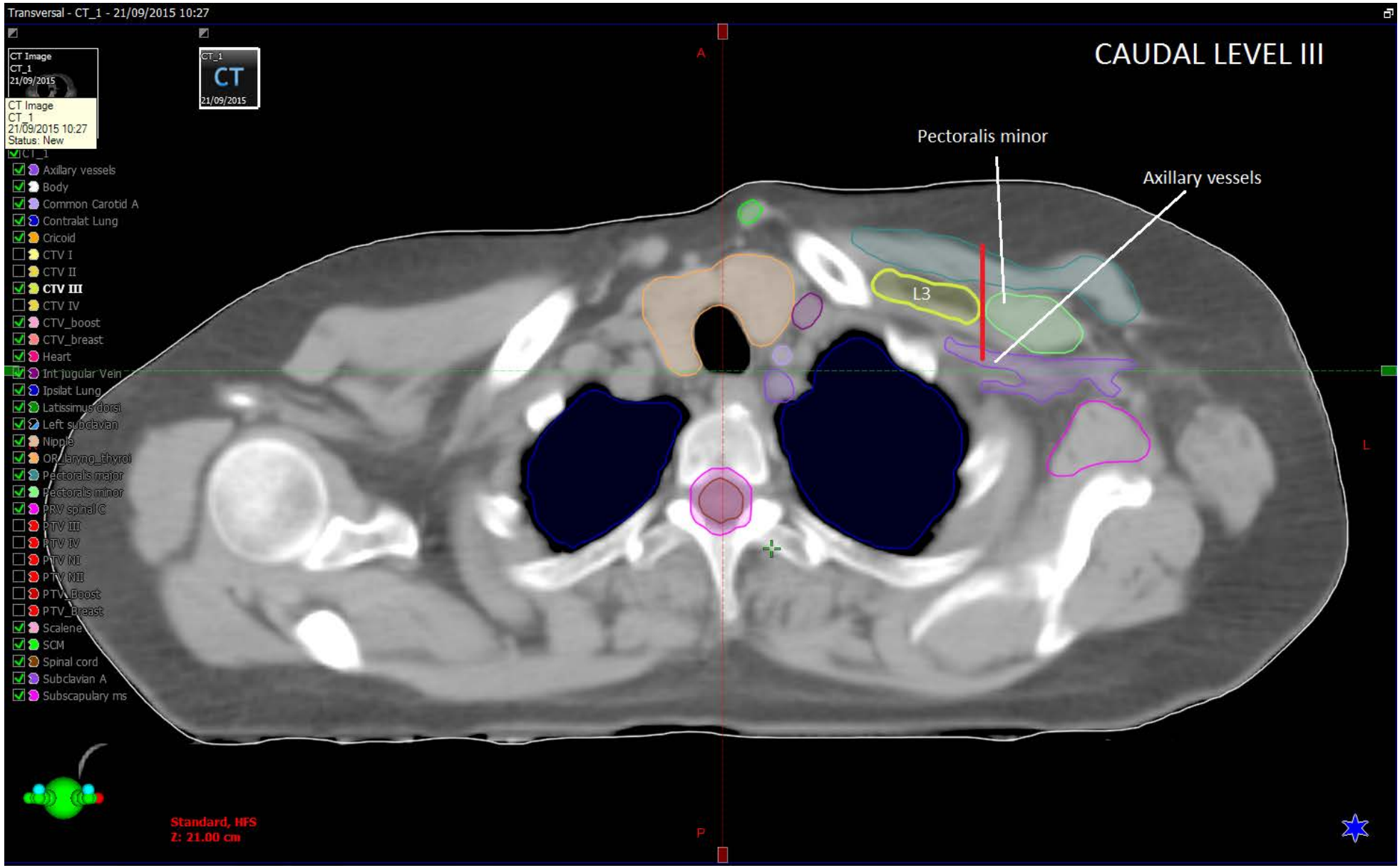
Transversal - CT_1 - 21/09/2015 10:27
CAUDAL LEVEL III
Pectoralis minor
Axillary vessels
L3
CT Image
CT_1
21/09/2015
CT Image
CT_1
21/09/2015 10:27
Status: New
CT_1
CT
21/09/2015
CT_1
Axillary vessels
Body
Common Carotid A
Contralat Lung
Cricoid
CTV I
CTV II
CTV III
CTV IV
CTV_boost
CTV_breast
Heart
Int jugular Vein
Ipsilat Lung
Latissimus dorsi
Left subclavian
Nipple
OR_laryng_thyroi
Pectoralis major
Pectoralis minor
PRV spinal C
PTV III
PTV IV
PTV NI
PTV NII
PTV_Boost
PTV_Breast
Scalene
SCM
Spinal cord
Subclavian A
Subscapulary ms
A
P
L
Standard, HFS
Z: 21.00 cm

ESTRO School

QUICK GUIDE

L2: posterior to pectoral minor muscle

CRANIAL: Where the axillary vessels cross the medial edge of pectoral minor
CAUDAL: Caudal border pectoral minor
ANT: Pectoralis minor
POST: Ribs and intercostal muscles
LAT: Lateral border pectoral m
MEDIAL: Medial border pectoral m

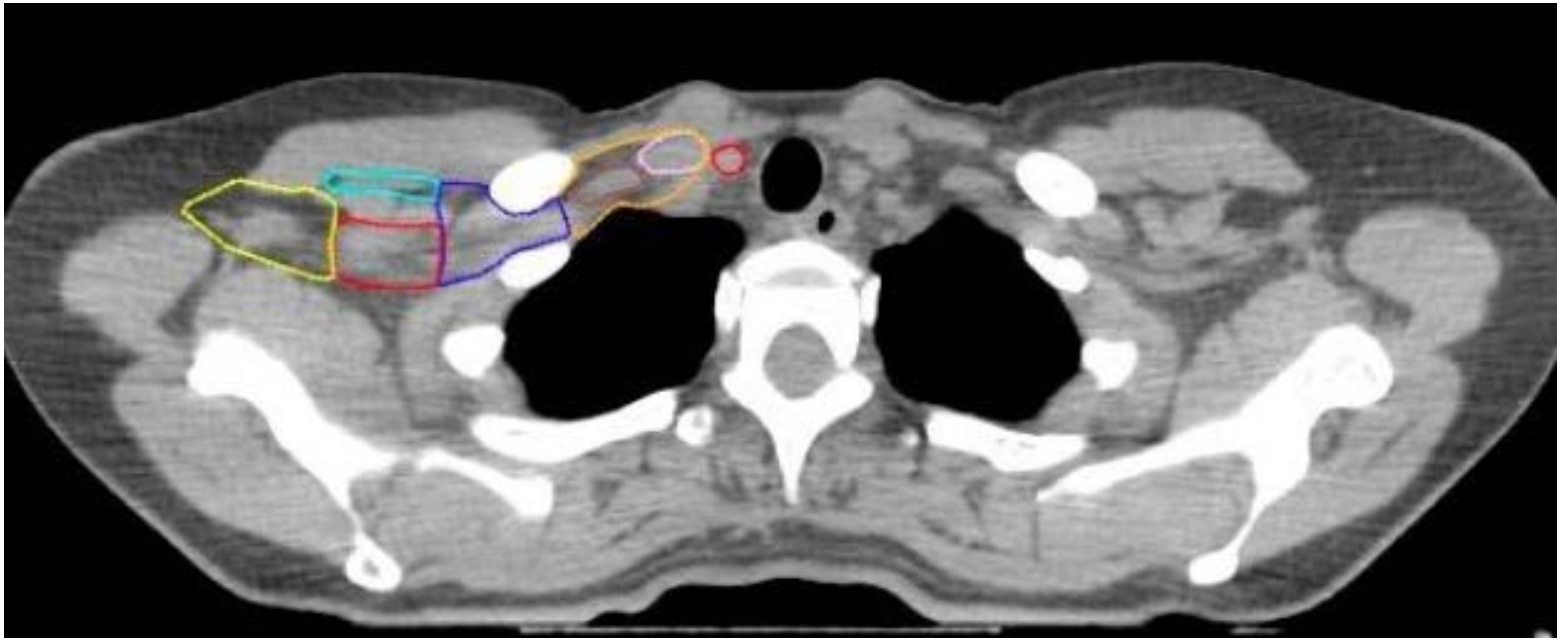

ESTRO School

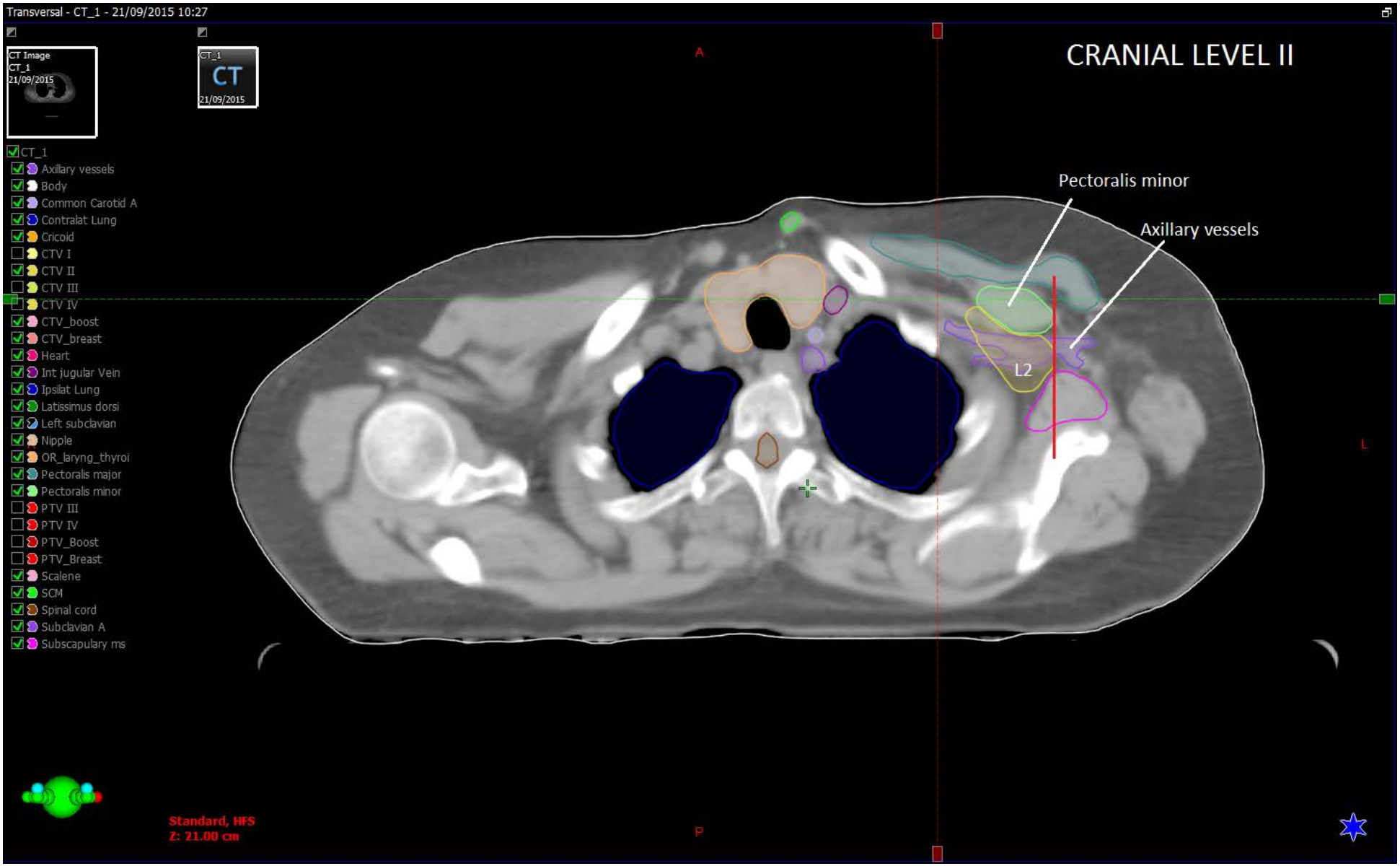
Transversal - CT_1 - 21/09/2015 10:27
CT Image
CT_1
21/09/2015
CT_1
CT
21/09/2015
CRANIAL LEVEL II
A
P
L
Pectoralis minor
Axillary vessels
L2
CT_1
Axillary vessels
Body
Common Carotid A
Contralat Lung
Cricoid
CTV I
CTV II
CTV III
CTV IV
CTV_boost
CTV_breast
Heart
Int jugular Vein
Ipsilat Lung
Latissimus dorsi
Left subclavian
Nipple
OR_laryng_thyroi
Pectoralis major
Pectoralis minor
PTV III
PTV IV
PTV_Boost
PTV_Breast
Scalene
SCM
Spinal cord
Subclavian A
Subscapulary ms
Standard, HFS
Z: 21.00 cm

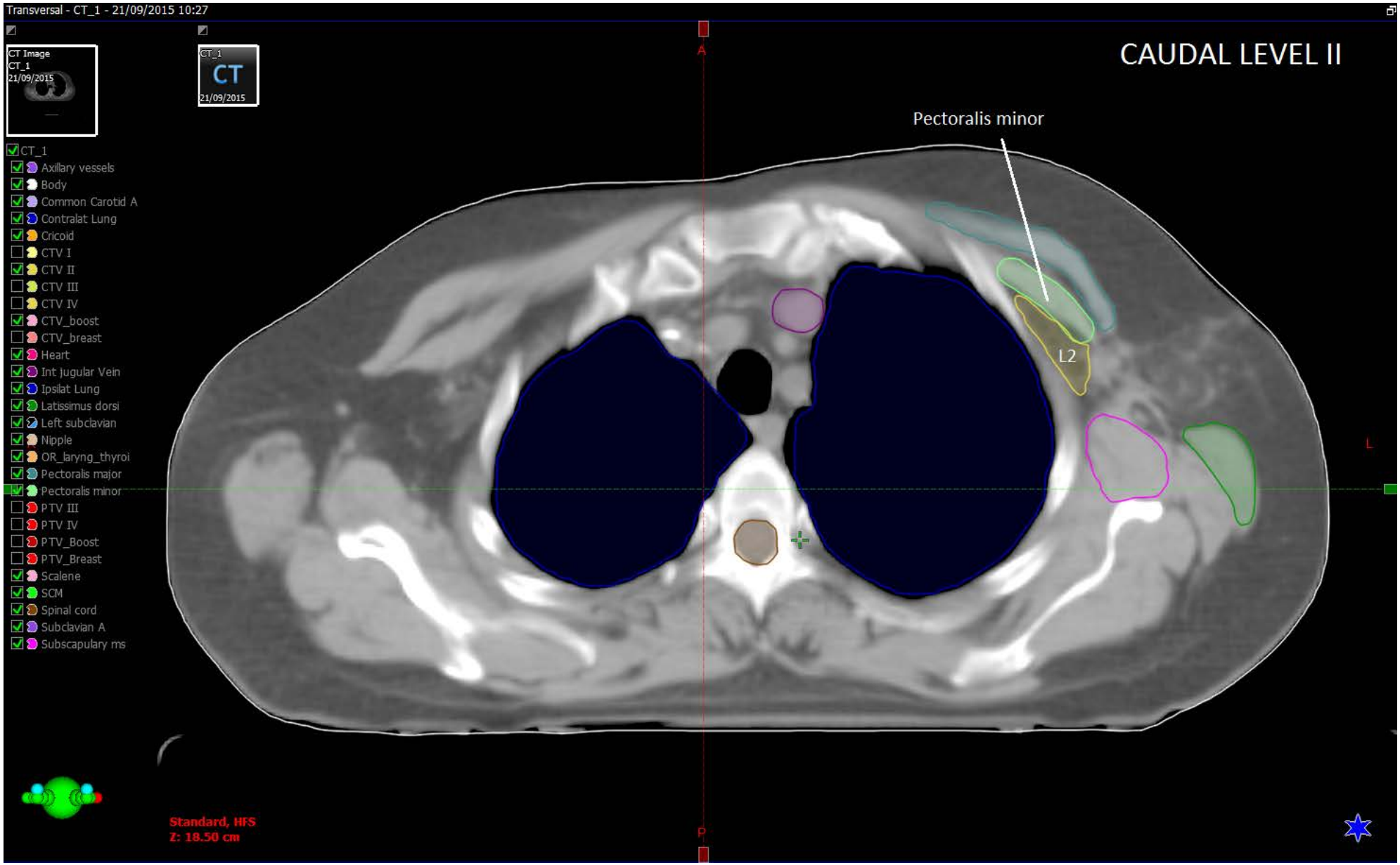
Transversal - CT_1 - 21/09/2015 10:27
CT Image
CT_1
21/09/2015
CT_1
CT
21/09/2015
CAUDAL LEVEL II
Pectoralis minor
L2
CT_1
Axillary vessels
Body
Common Carotid A
Contralat Lung
Cricoid
CTV I
CTV II
CTV III
CTV IV
CTV_boost
CTV_breast
Heart
Int jugular Vein
Ipsilat Lung
Latissimus dorsi
Left subclavian
Nipple
OR_laryng_thyroi
Pectoralis major
Pectoralis minor
PTV III
PTV IV
PTV_Boost
PTV_Breast
Scalene
SCM
Spinal cord
Subclavian A
Subscapulary ms
A
P
L
Standard, HFS
Z: 18.50 cm

QUICK GUIDE

L1:

CRANIAL: Where the axillary vessels cross lateral edge of pectoral minor
CAUDAL: Pectoral major insert into ribs
ANT: Pectoralis major and minor
POST: Subscapularis muscle
LAT: Imaginary line between pectoral major and deltoid / latissiumus dorsi
MEDIAL: Lateral border pectoral minor

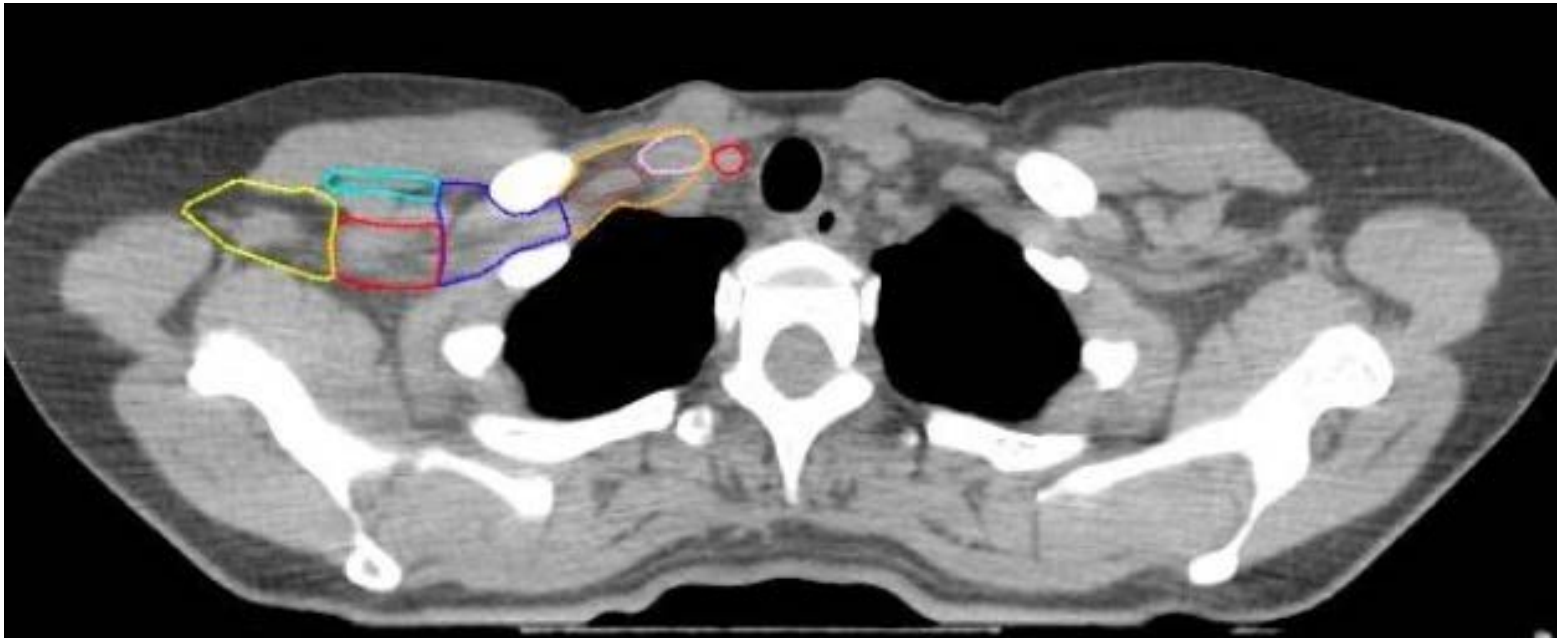

ESTRO School

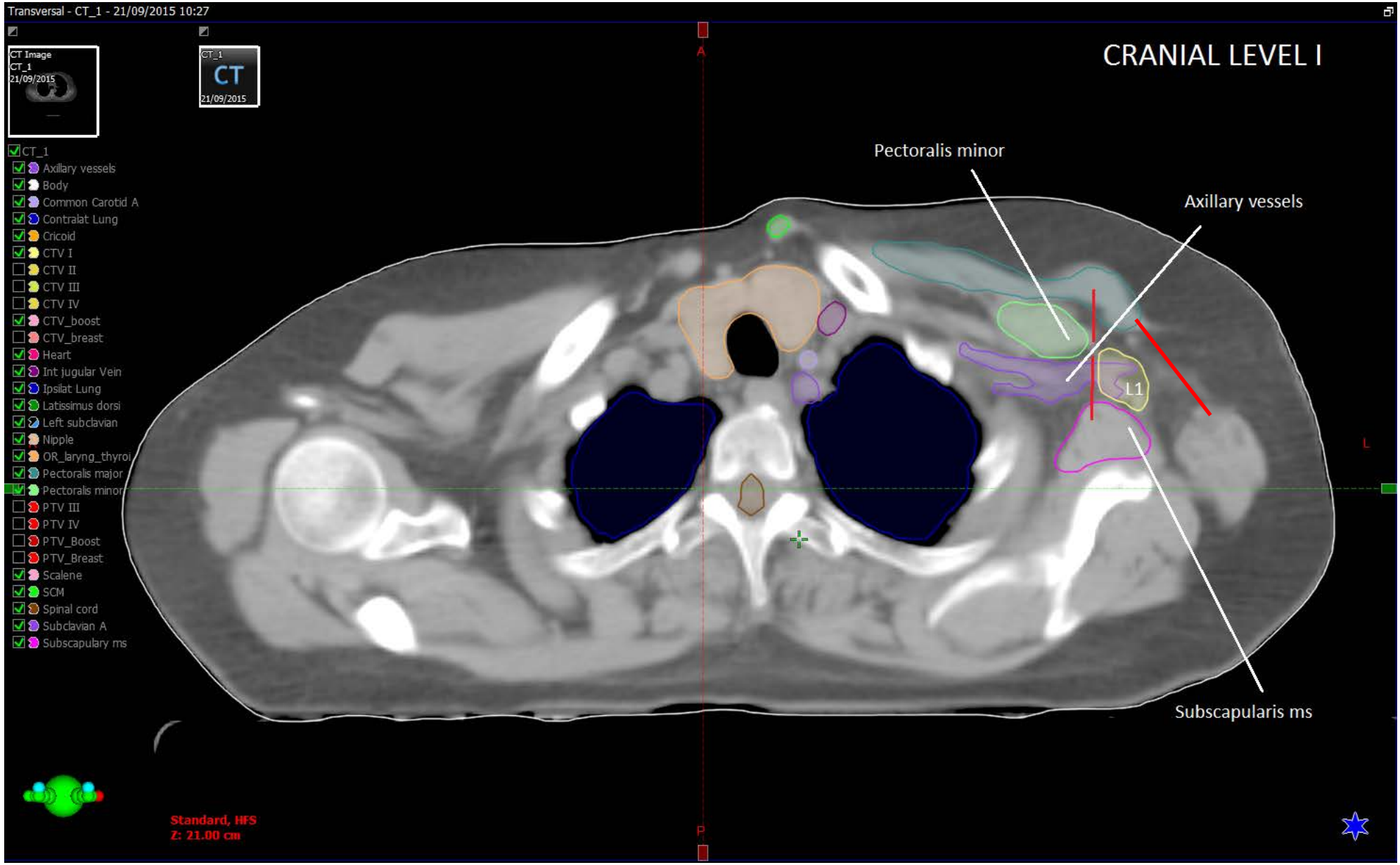
Transversal - CT_1 - 21/09/2015 10:27
CT Image
CT_1
21/09/2015
CT_1
CT
21/09/2015
CRANIAL LEVEL I
CT_1
Axillary vessels
Body
Common Carotid A
Contralat Lung
Cricoid
CTV I
CTV II
CTV III
CTV IV
CTV_boost
CTV_breast
Heart
Int jugular Vein
Ipsilat Lung
Latissimus dorsi
Left subclavian
Nipple
OR_laryng_thyroi
Pectoralis major
Pectoralis minor
PTV III
PTV IV
PTV_Boost
PTV_Breast
Scalene
SCM
Spinal cord
Subclavian A
Subscapulary ms
Pectoralis minor
Axillary vessels
L1
Subscapularis ms
A
P
L
Standard, HFS
Z: 21.00 cm

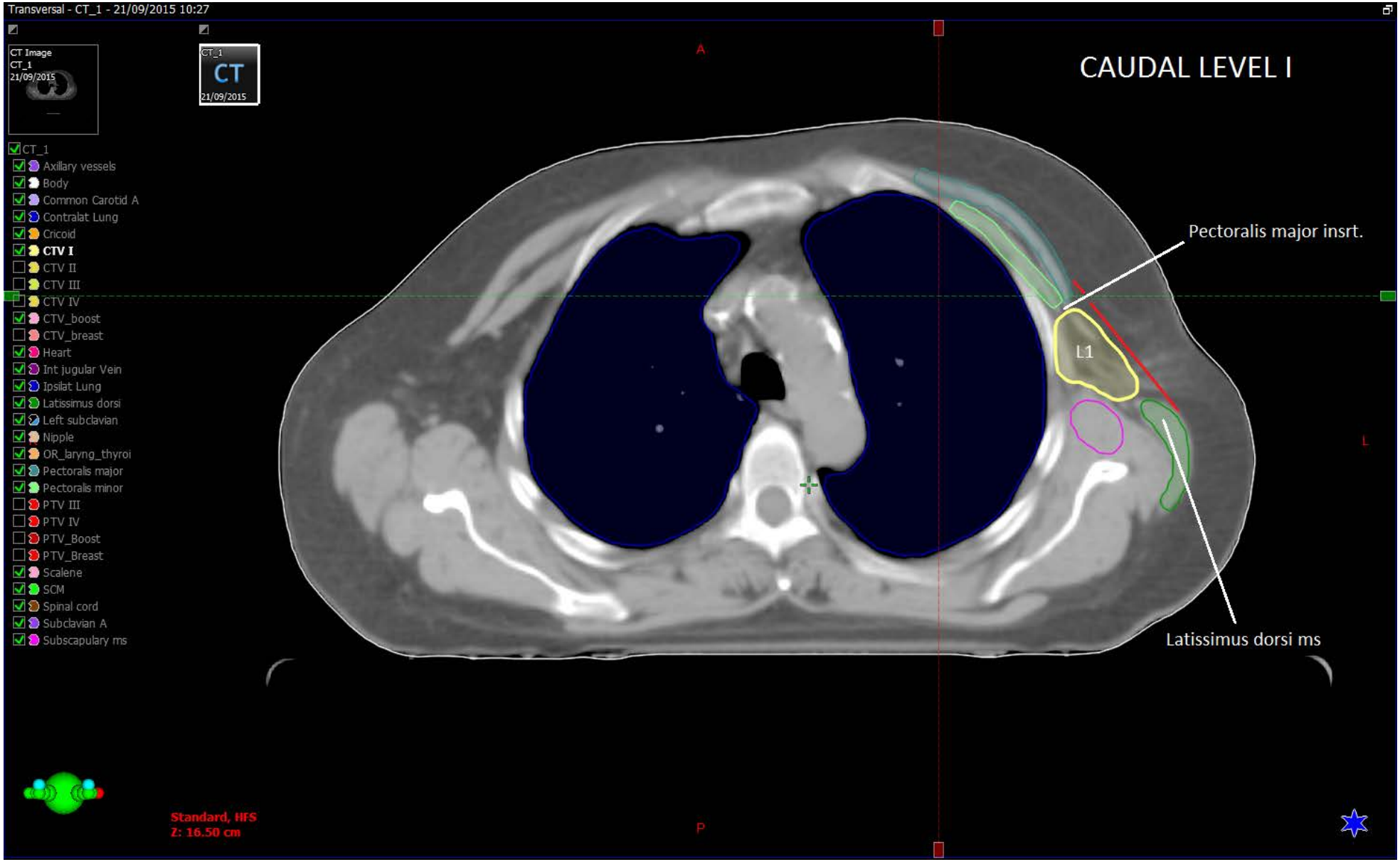
Transversal - CT_1 - 21/09/2015 10:27
CT Image
CT_1
21/09/2015
CT_1
CT
21/09/2015
CT_1
Axillary vessels
Body
Common Carotid A
Contralat Lung
Cricoid
CTV I
CTV II
CTV III
CTV IV
CTV_boost
CTV_breast
Heart
Int jugular Vein
Ipsilat Lung
Latissimus dorsi
Left subclavian
Nipple
OR_laryng_thyroi
Pectoralis major
Pectoralis minor
PTV III
PTV IV
PTV_Boost
PTV_Breast
Scalene
SCM
Spinal cord
Subclavian A
Subscapulary ms
A
P
L
CAUDAL LEVEL I
Pectoralis major insrt.
L1
Latissimus dorsi ms
Standard, HFS
Z: 16.50 cm

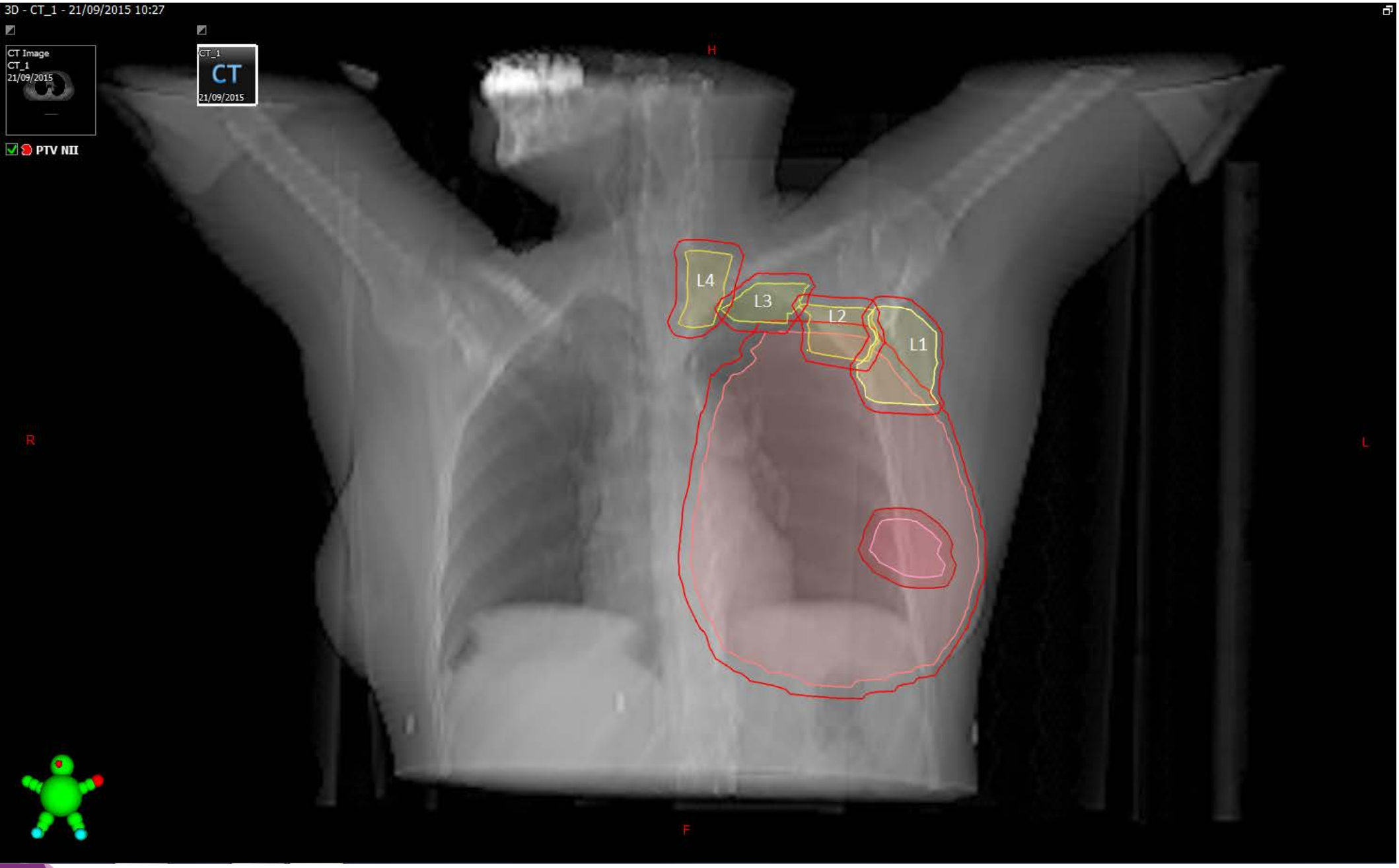
3D - CT_1 - 21/09/2015 10:27
CT Image
CT_1
21/09/2015
CT_1
CT
21/09/2015
PTV NII
H
R
L
F
L4
L3
L2
L1

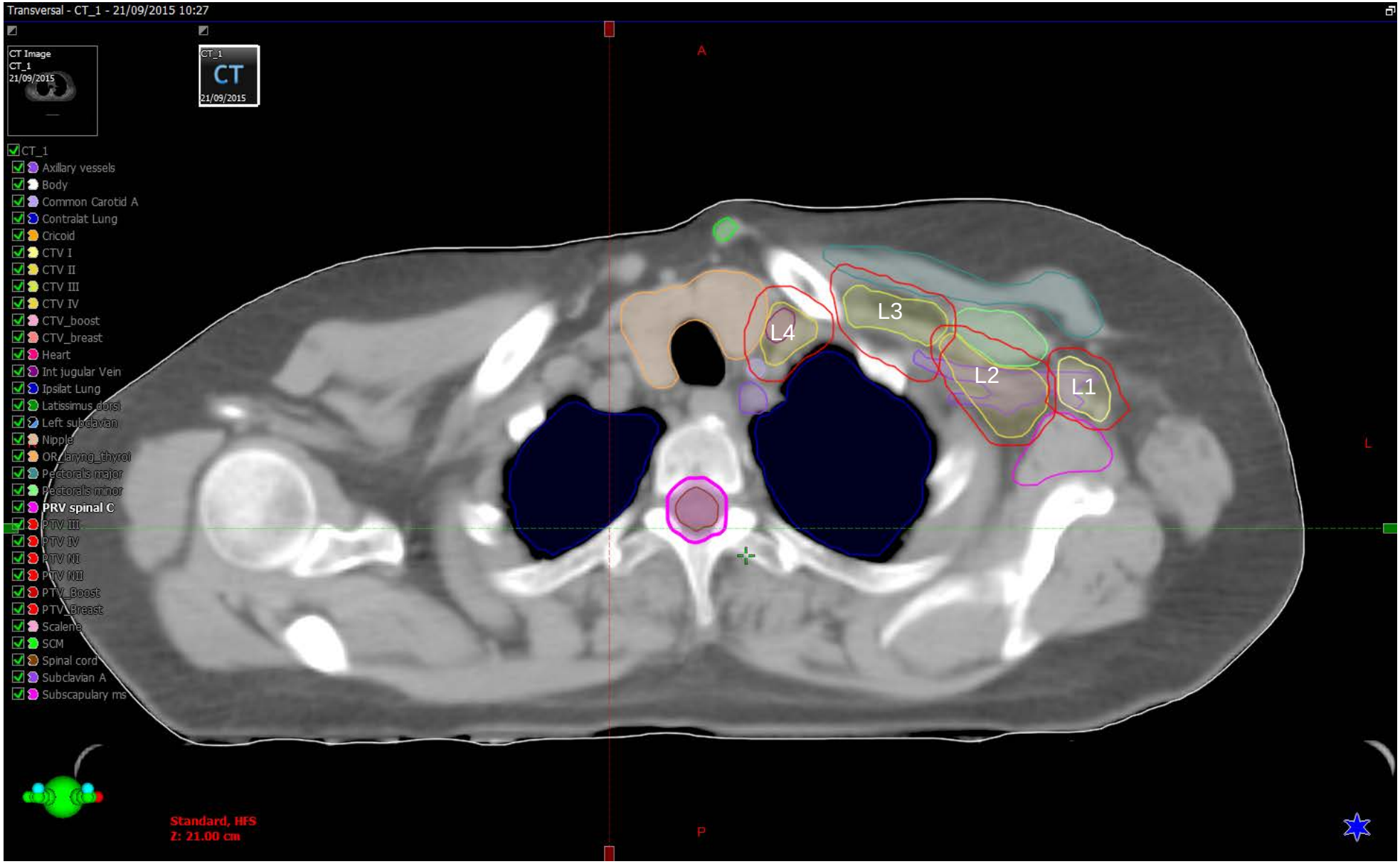
Transversal - CT_1 - 21/09/2015 10:27
CT Image
CT_1
21/09/2015
CT_1
CT
21/09/2015
CT_1
Axillary vessels
Body
Common Carotid A
Contralat Lung
Cricoid
CTV I
CTV II
CTV III
CTV IV
CTV_boost
CTV_breast
Heart
Int jugular Vein
Ipsilat Lung
Latissimus dorsi
Left subclavian
Nipple
OR_laryng_thyroi
Pectoralis major
Pectoralis minor
PRV spinal C
PTV III
PTV IV
PTV NI
PTV NII
PTV_Boost
PTV_Breast
Scalene
SCM
Spinal cord
Subclavian A
Subscapulary ms
L4
L3
L2
L1
A
P
L
Standard, HFS
Z: 21.00 cm

CRANIAL

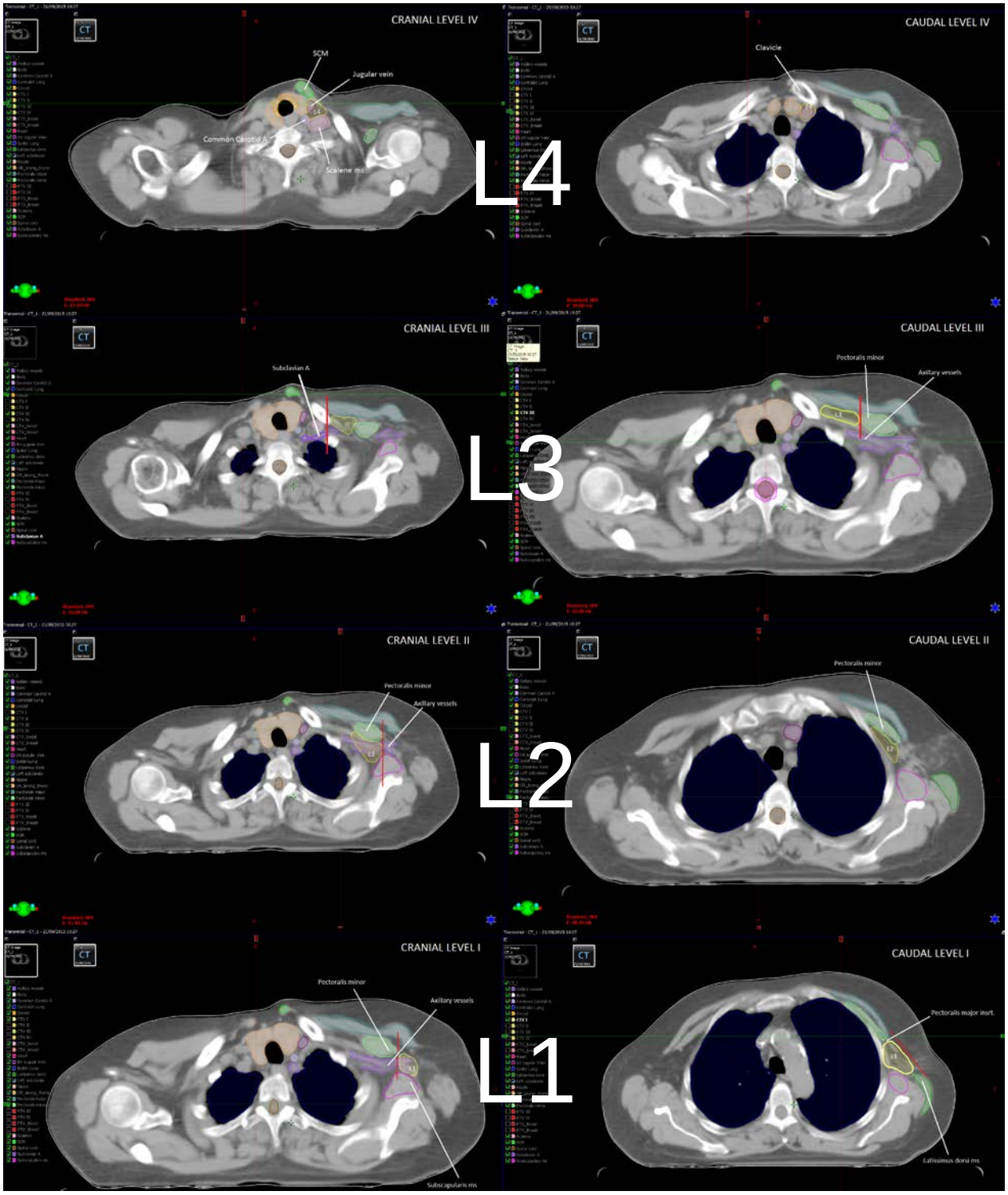

CAUDAL

ESTRO School

QUICK GUIDE

IMN: First 3-4 intercostal spaces

Rotter Nodes: Between pectoral M and m

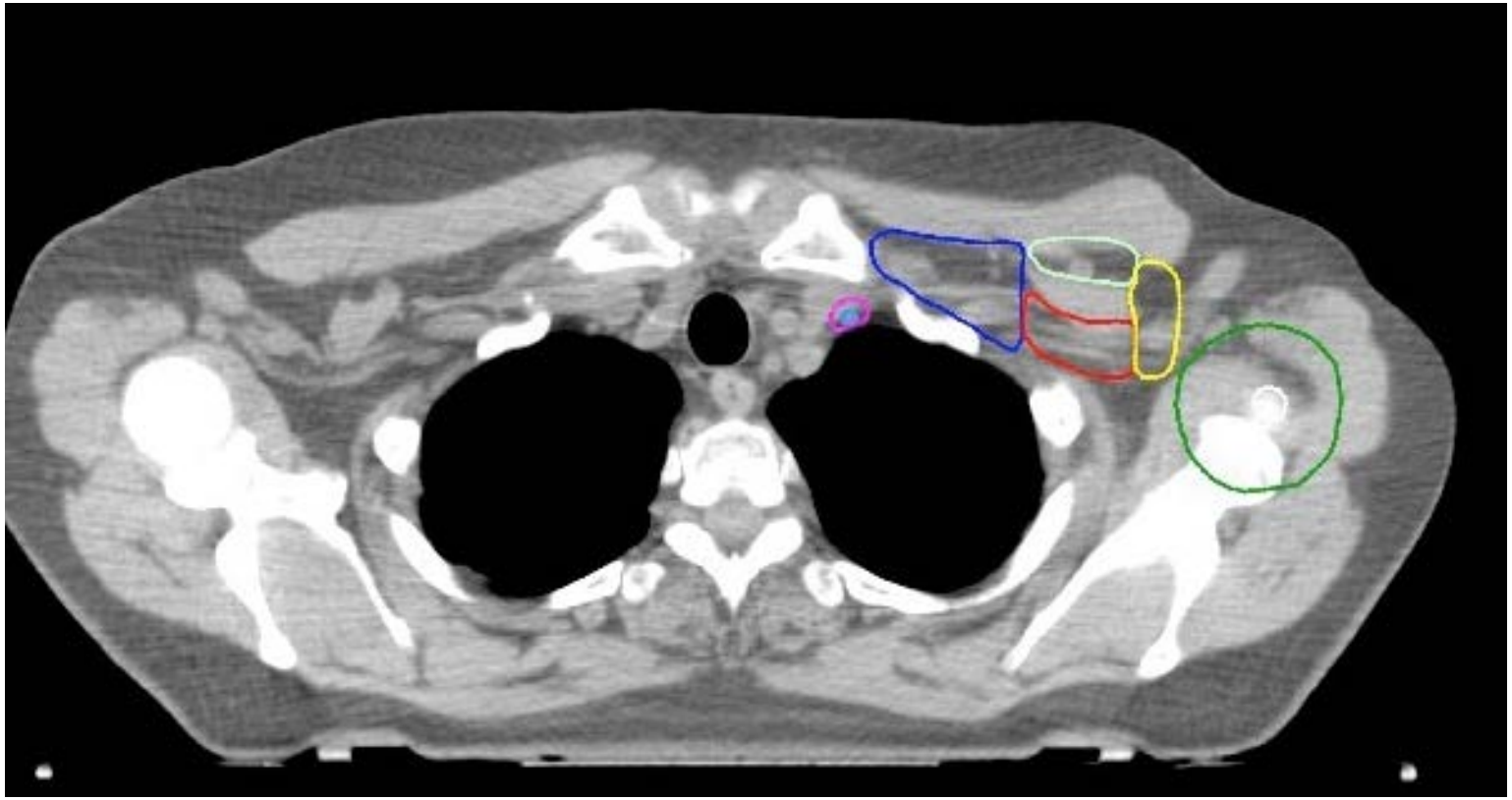

ESTRO School

DBCG Counturing atlas pdf
PROCAB Counturing atlas pdf
ESTRO Counturing atlas pdf
RTOG Counturing atlas pdf

EXAMPLES OF CTV AND PTV BREAST CANCER (Our Department)

ESTRO School

Acknowledgements:

MARTA BONET
Sebastià Sabater
Lorena Díez
Marina Gascón
Eloisa Bayo
Blanca Farrús
Ángel Montero
Katrin Müller
Víctor Hernández
Philip Poortmans
.....

meritxell.arenas@gmail.com
marenas@grupsagessa.com

Köszönöm, Gracias, Gràcies, Thanks, Merci, Danke, Grazie…

ESTRO School

ESTRO Course: Target Volume Definition

Imaging for Determining the Gross Tumor Volume (GTV): Lung Cancer

Stefan Delorme

dkfz. DEUTSCHES KREBSFORSCHUNGSZENTRUM IN DER HELMHOLTZ-GEMEINSCHAFT

Learning Objectives: Lung Cancer

- To understand chest anatomy
- To comprehend the staging system used for lung cancer
- To appreciate the imaging features of lung cancer
  - CT
  - MRI and PET (/CT)
- To appreciate the limitations of current imaging techniques

dkfz.

Windowing

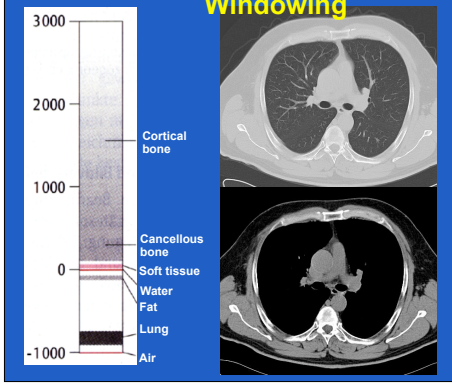

dkfz.

Supraaortic level I

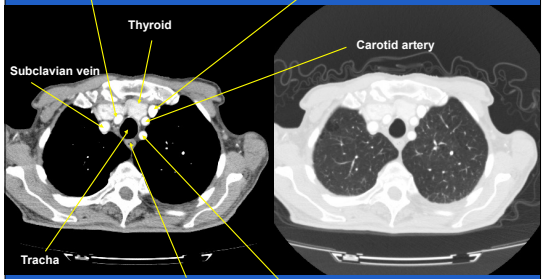

dkfz.

Supraaortic level II

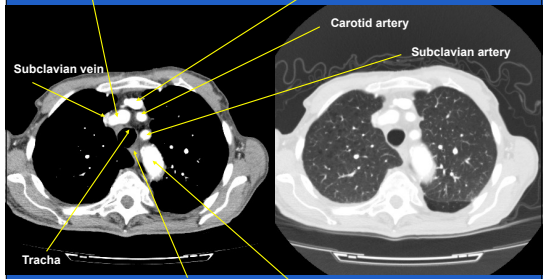

dkfz.

Aortic arch

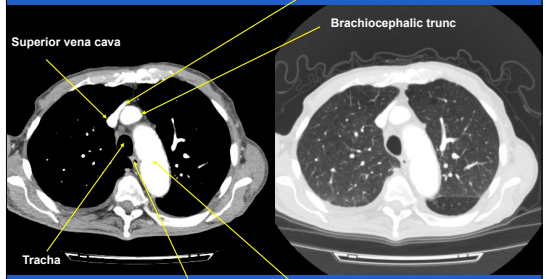

dkfz.

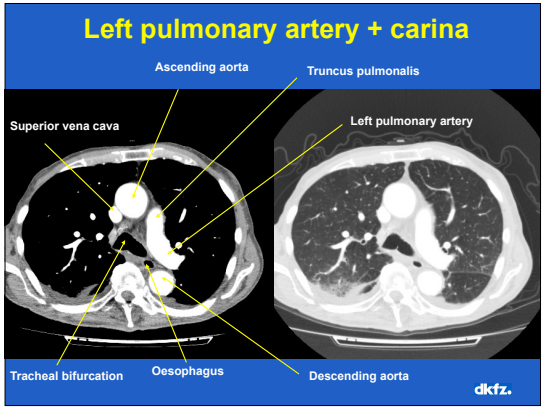
Left pulmonary artery + carina
Ascending aorta
Truncus pulmonalis
Superior vena cava
Left pulmonary artery
Tracheal bifurcation
Oesophagus
Descending aorta
dkfz.

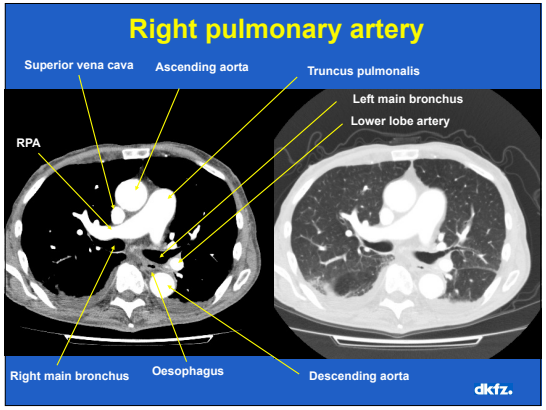
Right pulmonary artery
Superior vena cava
Ascending aorta
Truncus pulmonalis
Left main bronchus
Lower lobe artery
RPA
Right main bronchus
Oesophagus
Descending aorta
dkfz.

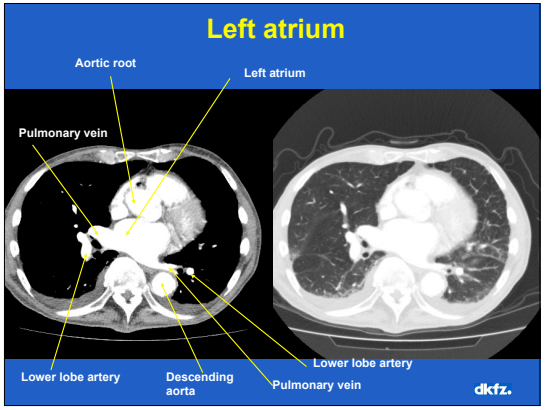
Left atrium
Aortic root
Left atrium
Pulmonary vein
Lower lobe artery
Descending aorta
Lower lobe artery
Pulmonary vein
dkfz.

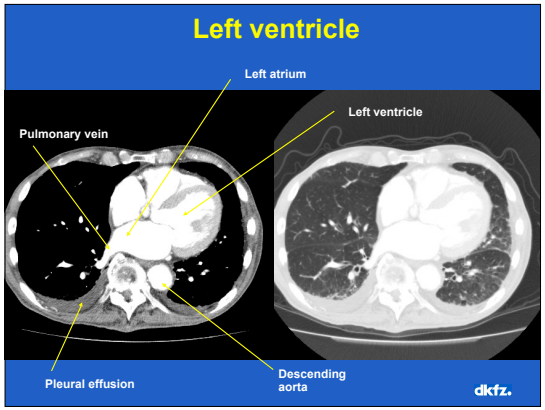
Left ventricle
Left atrium
Pulmonary vein
Left ventricle
Pleural effusion
Descending aorta
dkfz.

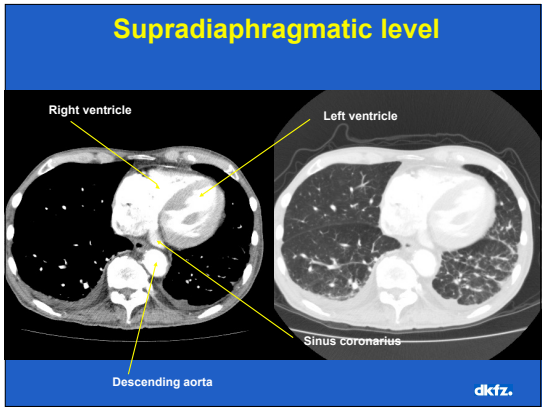
Supradiaphragmatic level
Right ventricle
Left ventricle
Sinus coronarius
Descending aorta
dkfz.

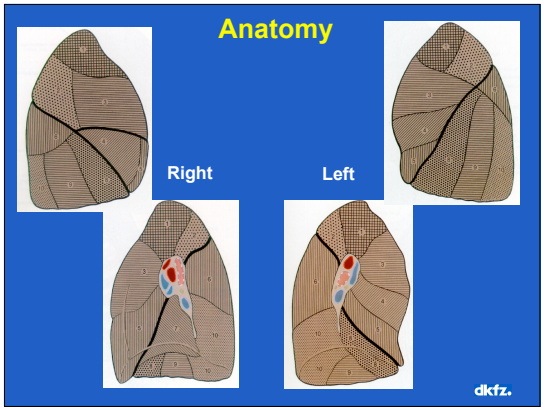
Anatomy
Right
Left
dkfz.

Lung lobes

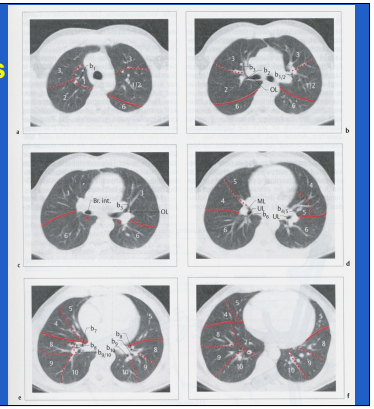

Bronchial tree

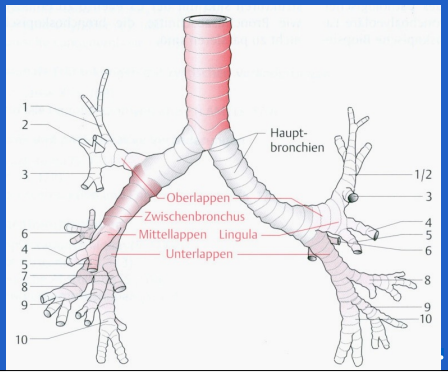

Morphology of chest neoplasms

dkfz.

Peripheral lung carcinoma

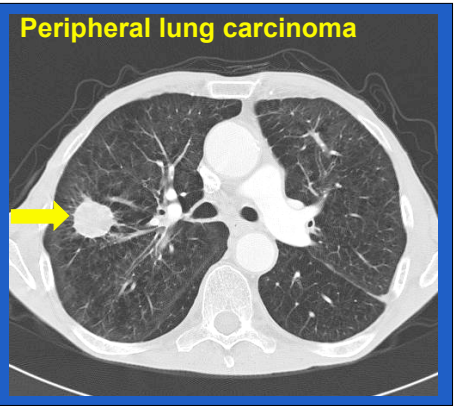

Central lung carcinoma

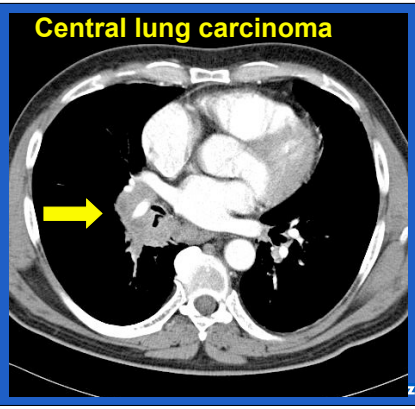

dkfz.

Ground-glass lung lesions

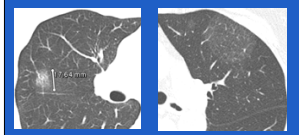

Focal interstitial pneumonia

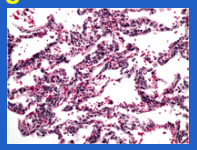

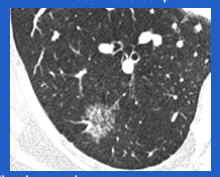

Lepidic adenocarcinoma

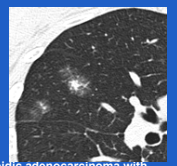

Lepidic adenocarcinoma with focal invasion

Godoy MCB Radiology 2009

dkfz.

Metastases (Breast cancer)

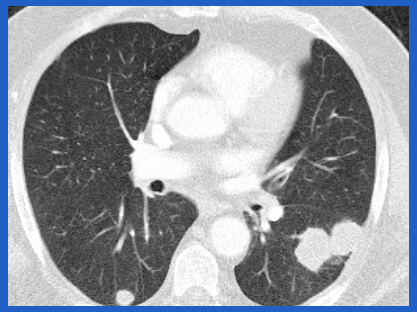

dkfz.

Pleural effusion

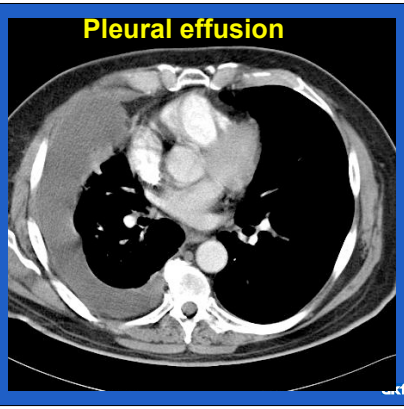

dkfz.

Pleural mesothelioma

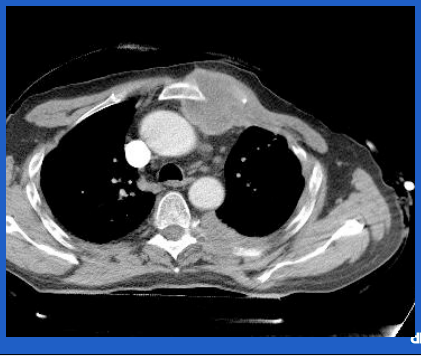

dkfz.

TNM staging

- 7th edition 2009
- Based on outcomes in
  - 70,000 NSCLC
  - 30,000 SCLC
- Now including SCLS and carcinoid
- Subclassification of T1 and T2 stages
- More appropriate regarding treatment options and prognosis than 6th ed.

dkfz.

CT

- T1: Malignant solitary nodules < 3 cm

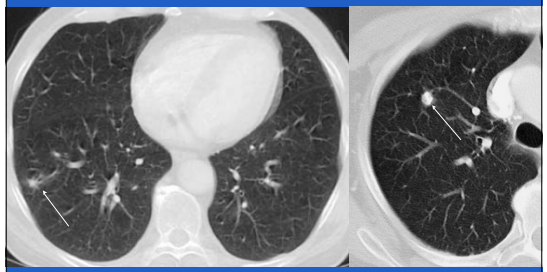

dkfz.

CT

- T2:
  - > 3 cm, < 7 cm
  - Infiltration of visceral pleura
  - ≥ 2cm from carina

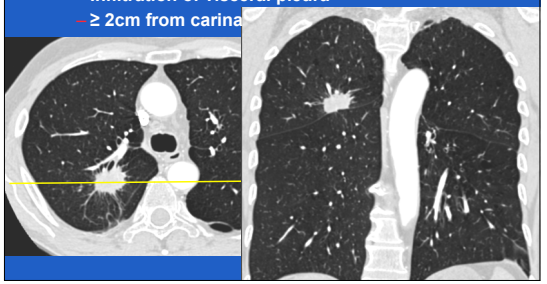

CT

- **T3:**
  - > 7 cm
  - Infiltration of chest wall, diaphragm, mediastinum, pleura, pericardium
  - < 2cm from carina
  - Total atelectasis
  - Satellite nodules, same lobe

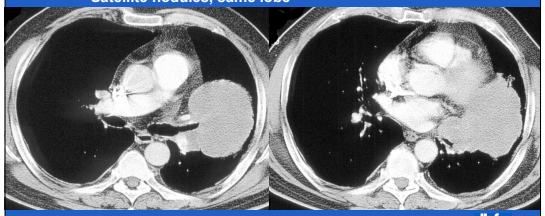

dkfz.

CT

- **T3:**
  - > 7 cm
  - Infiltration of chest wall, diaphragm, mediastinum, pleura, pericardium
  - < 2cm from carina
  - Total atelectasis
  - Satellite nodules, same lobe

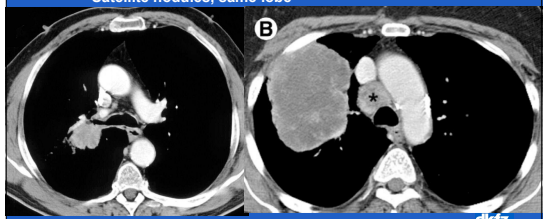

dkfz.

CT

- **T3:**
  - > 7 cm
  - Infiltration of chest wall, diaphragm, mediastinum, pleura, pericardium
  - < 2cm from carina
  - Total atelectasis
  - Satellite nodules, same lobe

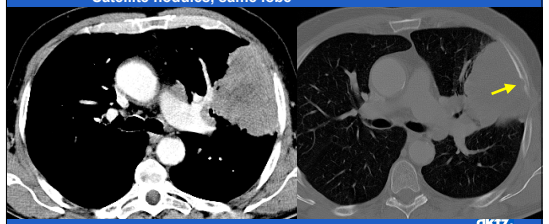

dkfz.

CT

- **T3:**
  - > 7 cm
  - Infiltration of chest wall, diaphragm, mediastinum, pleura, pericardium
  - < 2cm from carina
  - Total atelectasis
  - Satellite nodules, same lobe

dkfz.

CT

- **T4:**
  - Infiltration of heart, large vessels, trachea, carina esophagus, or spine
  - Metastasis same lung but other lobe

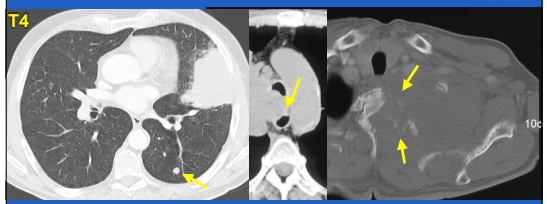

dkfz.

Lymphatic drainage

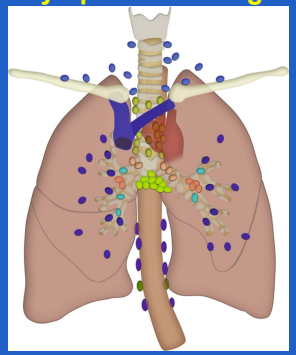

Harisinghani MG (ed.)
Atlas of lymph node anatomy
Springer 2013

dkfz.

Lymph node levels I

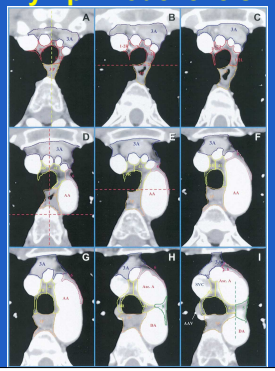

Chapet O et al., IJROBP 2005

dkfz.

Lymph node levels II

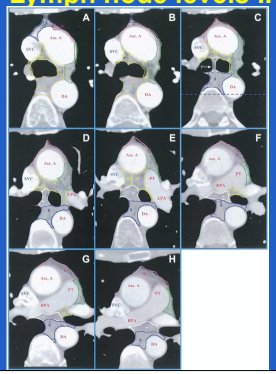

Chapet O et al., IJROBP 2005

dkfz.

Lymphatic drainage

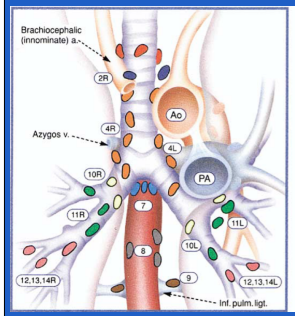

Superior Mediastinal Nodes

- **1** Highest Mediastinal
- **2** Upper Paratracheal
- **3** Pre-vascular and Retrotracheal
- **4** Lower Paratracheal (including Azygos Nodes)

N_2 = single digit, ipsilateral
N_3 = single digit, contralateral or supraclavicular

Aortic Nodes

- **5** Subaortic (A-P window)
- **6** Para-aortic (ascending aorta or phrenic)

dkfz.

Lymphatic drainage

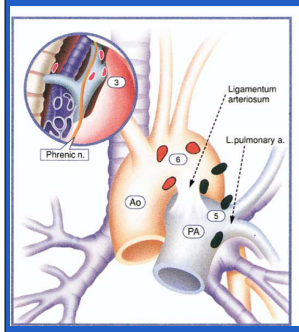

Inferior Mediastinal Nodes

- **7** Subcarinal
- **8** Paraesophageal (below carina)
- **9** Pulmonary Ligament

N_1 Nodes

- **10** Hilar
- **11** Interlobar
- **12** Lobar
- **13** Segmental
- **14** Subsegmental

dkfz.

Lymphatic drainage

Level 3R

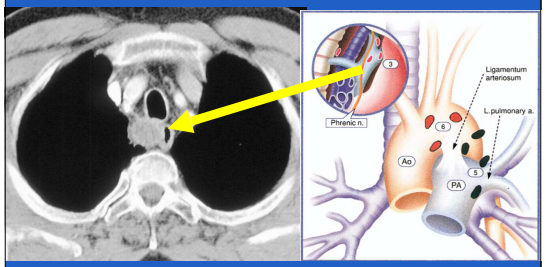

dkfz.

Lymphatic drainage

Level 4R

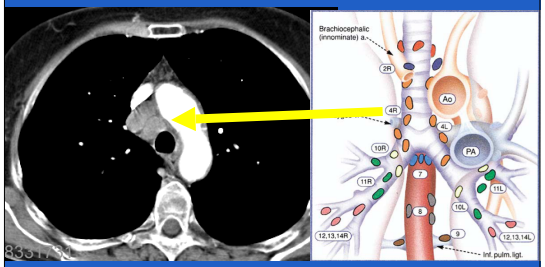

dkfz.

Lymphatic drainage

Levels 4L and 5

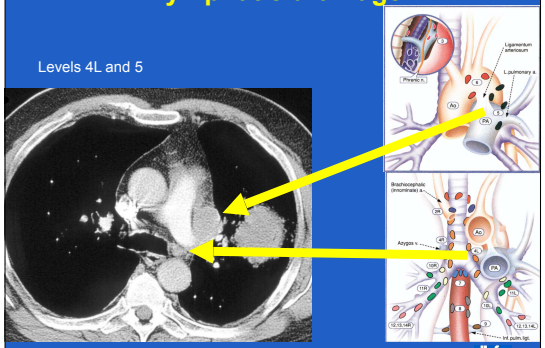

dkfz.

Lymphatic drainage

Level 6

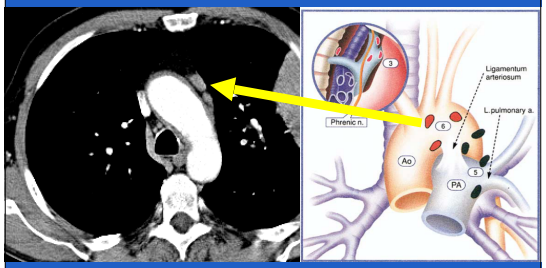

dkfz.

Lymphatic drainage

Levels 7 and 10R

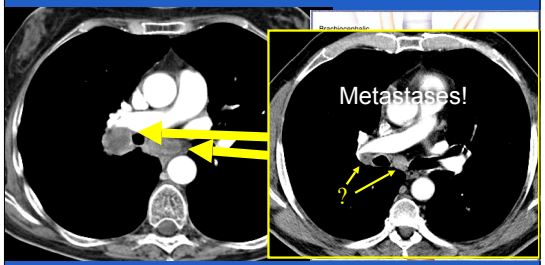

dkfz.

Lymphatic drainage

Levels 8 and 11R

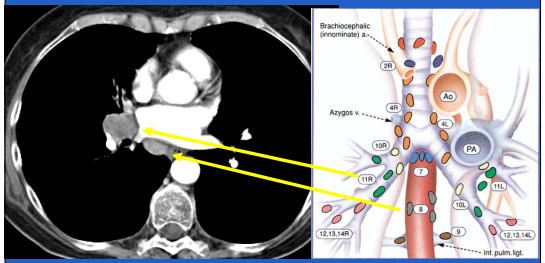

dkfz.

N Staging: Pitfalls

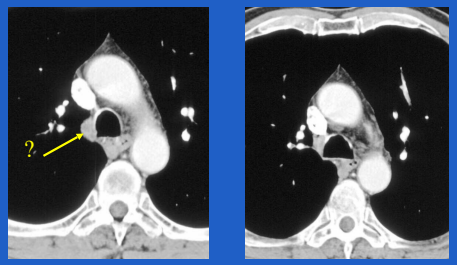

Azygos vein

dkfz.

N Staging: Pitfalls

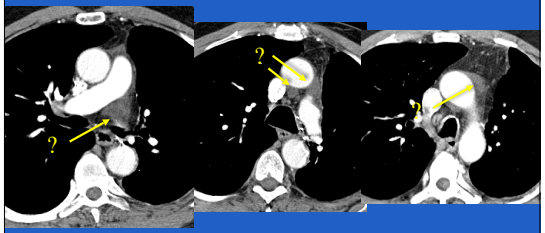

Pericardium

dkfz.

N stages

- N1
  - Ipsilateral hilum or interlobar lymph nodes
- N2
  - Ipsilateral mediastinal lymph nodes
  - Subcarinal lymph nodes
  - Aortopulmonary lymph nodes
- N3
  - Contralateral lymph nodes
  - Supraclavicular lymph nodes

dkfz.

M stages

- M1a
  - Contralateral lung metastases
  - Malignant pleural or pericardial effusion
- M1b
  - Any metastases outside the chest cavity
  - Abdominal or cervical lymph nodes

dkfz.

CT and MRI

- T Staging: Mediastinal infiltration

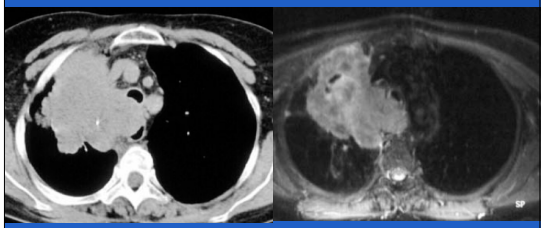

dkfz.

CT and MRI

- T Staging: Pancoast

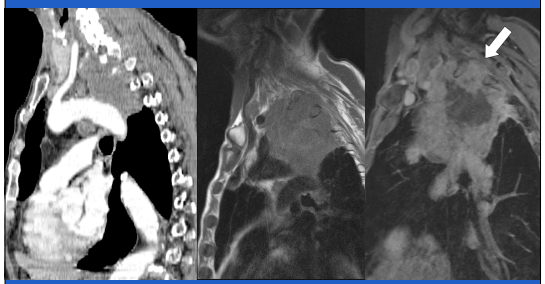

Hintze et al. Radiologe 2006

dkfz.

MRI

- T Staging: Chest wall infiltration

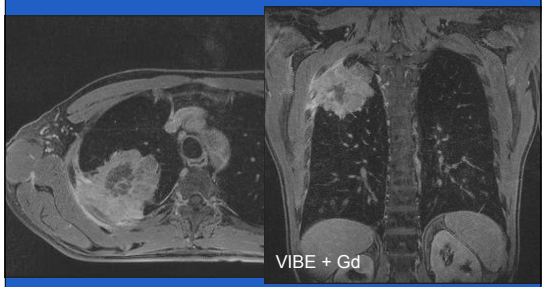

dkfz.

MRI

- Tumor, effusion, atelectasis

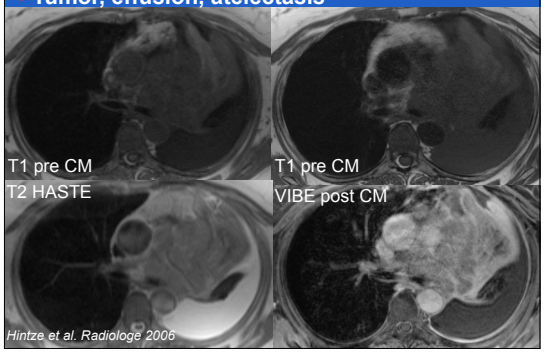

Hintze et al. Radiologe 2006

CT and MRI

- T Staging

	Sensitivity	Specificity	Accuracy
CT	43-63%	84-97%	68-78%
MRI	52-81%	80-96%	73-88%

Musset et al 2003; Laurent et al, 1988; Grenier et al 1989; Webb et al 1991

dkfz.

CT and MRI

- N Staging

	Sensitivity	Specificity	Accuracy
CT	46-91%	69-82%	65-84%
MRI	48-93%	64-85%	61-84%

Musset et al 2003; Laurent et al, 1988; Grenier et al 1989; Webb et al 1991

dkfz.

PET

- T- and N-Staging

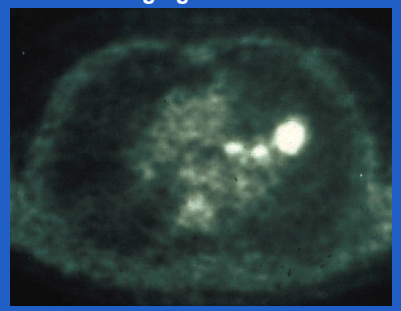

dkfz.

PET/CT

- N Staging

	Sensitivity	Specificity	Accuracy
CT	58-73%	65-76%	68-78%
PET/CT	81-89%	83-91%	73-88%

- PET/CT correctly modified stage in 17% of patients
- 2% were incorrect

Grosu et al Strahlenther Onkol 2005

dkfz.

Determining GTV

- Soft Tissue Delineation: Use Soft Tissue Window

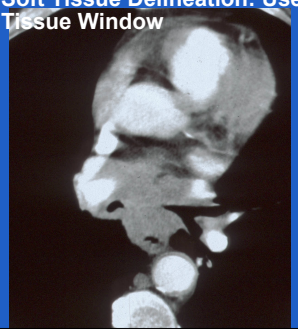

dkfz.

Determining GTV

- Delineation inside Lung: Use Lung Window

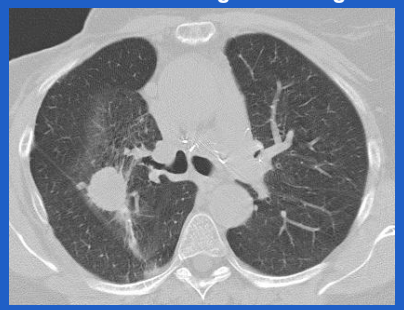

dkfz.

Determining GTV: CT

- Challenges for radiotherapy planning:
  - Atelectasis
  - Effusion
  - Lymph node involvement
- Use of lung and soft tissue window side-by-side
  - Lung window for lung interfaces
  - Soft tissue window for mediastinal and hilar interfaces
  - Bone window if infiltration suspected
- Use of MPR display
- Lymph nodes remain difficult

Steenbakkers et al Radiother Oncol 2005

dkfz.

Determining GTV: PET/CT

- Change of GTV from CT alone in 52%
- Increase of concordance among observers from 37% to 84%

Black: CT, Purple: PET/CT

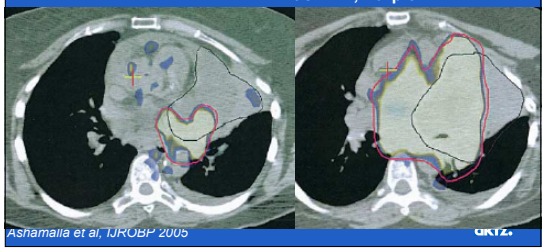

Ashamalla et al, TJROBP 2005

dkfz.

Determining GTV: PET/CT

- PET adds essential information to CT
  - Significant consequences on GTV, CTV and PTV
    - Range 21 -100 % of patients
    - Lymph node involvement
    - Differentiation tumor vs. atelectasis
  - Shortcoming: Inflammatory disease
- Generally recommended for all dose escalation studies

Grosu et al Strahlenther Onkol 2005

dkfz.

Lung motion

dkfz.

Lung Tumor Mobility

CC	AP	ML
4.3 ± 2.4	2.8 ± 1.3	3.4 ± 1.6
7.2 ± 1.8	4.3 ± 2.2	4.3 ± 2.4
9.5 ± 4.9	6.1 ± 3.3	6.0 ± 2.8

Tumor mobility during shallow breathing [mm]

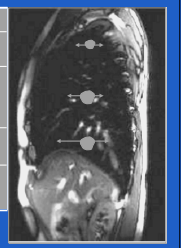

dkfz.

Lung Tumor Mobility after Radiotherapy

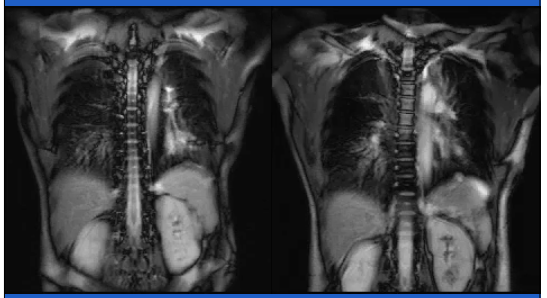

Plathow et al. 2005

dkfz.

Response and treatment-induced changes

dkfz.

Metastasis Renal Cell Carcinoma

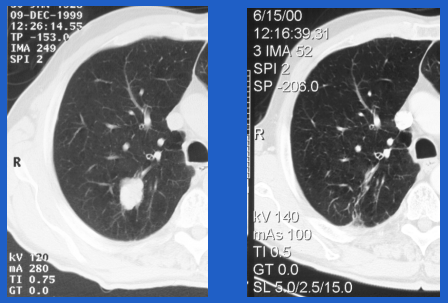

dkfz.

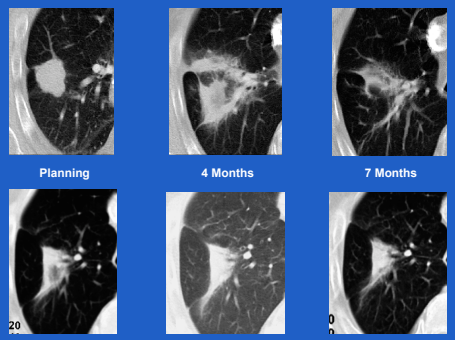

dkfz.

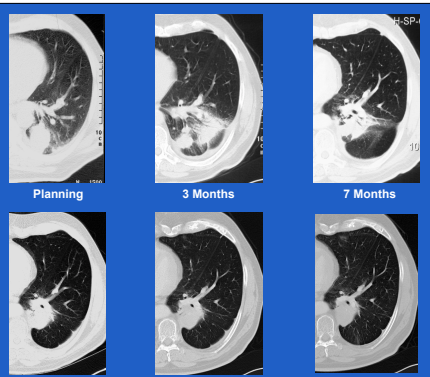

dkfz.

Take home

- CT as basis for morphology,
  - Good for T-stage
  - Well-known limitations, esp. N-stage
  - New: 4D-CT
- MRI
  - Similar for morphology
  - Superior for heterogeneity, differentiation, function: Perfusion and motion
- PET / CT
  - Best for N-stage
  - Well-known limitations
  - Reimbursement issues

dkfz.

My tastes are simple: I like the best*

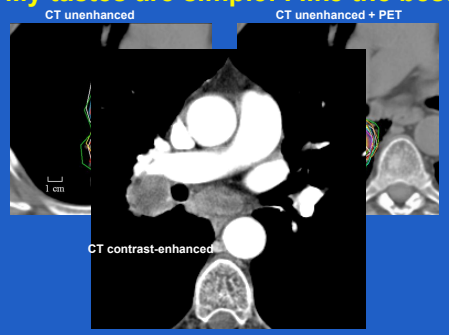

s.delorme@dkfz.de, Radiology – E010, Imaging and Radiooncology

dkfz.

Universitätsklinikum Carl Gustav Carus
DIE DRESDNER.

GTV and CTV for lung cancer – Delineation of Organs at Risk

Prof. Dr. med. Dr. Esther Troost

Klinik und Poliklinik für Strahlentherapie und Radioonkologie

Universitäts KrebsCentrum (UCC)

esther.troost@uniklinikum-dresden.de

ESTRO course Target Volume Delineation

Budapest, October, 2015

Content

- Elective nodal irradiation *versus* selective nodal irradiation in NSCLC and SCLC
- Proposal for nodal target volume
- Primary tumor
- SABR
- Postoperative irradiation
- Organs at risk

Content

- Elective nodal irradiation *versus* selective nodal irradiation in NSCLC and SCLC
- Proposal for nodal target volume
- Primary tumor
- SABR
- Postoperative irradiation
- Organs at risk

Nodal stage

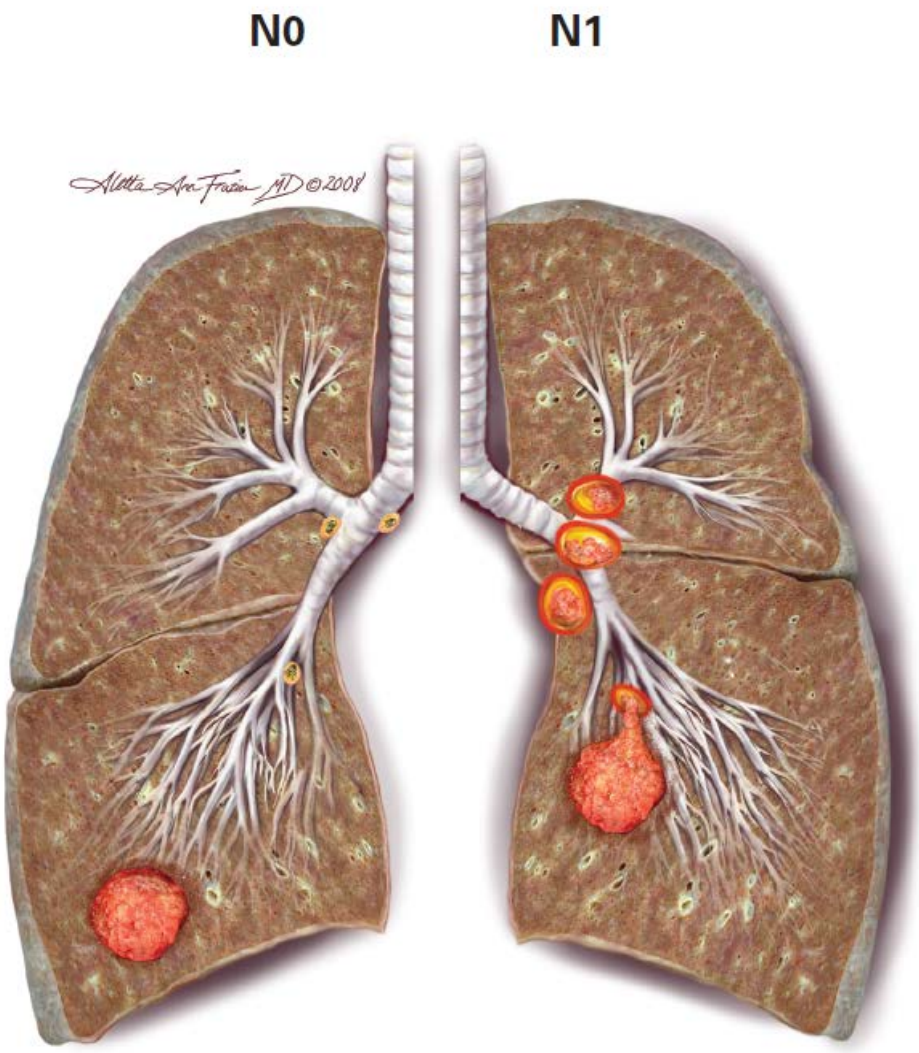

NX Regional lymph nodes cannot be assessed

N0 No regional lymph node metastasis

N1 Metastasis in ipsilateral peribronchial and/or ipsilateral hilar lymph nodes, and intra-pulmonary nodes, including nodal involvement by direct extension

Nodal stage

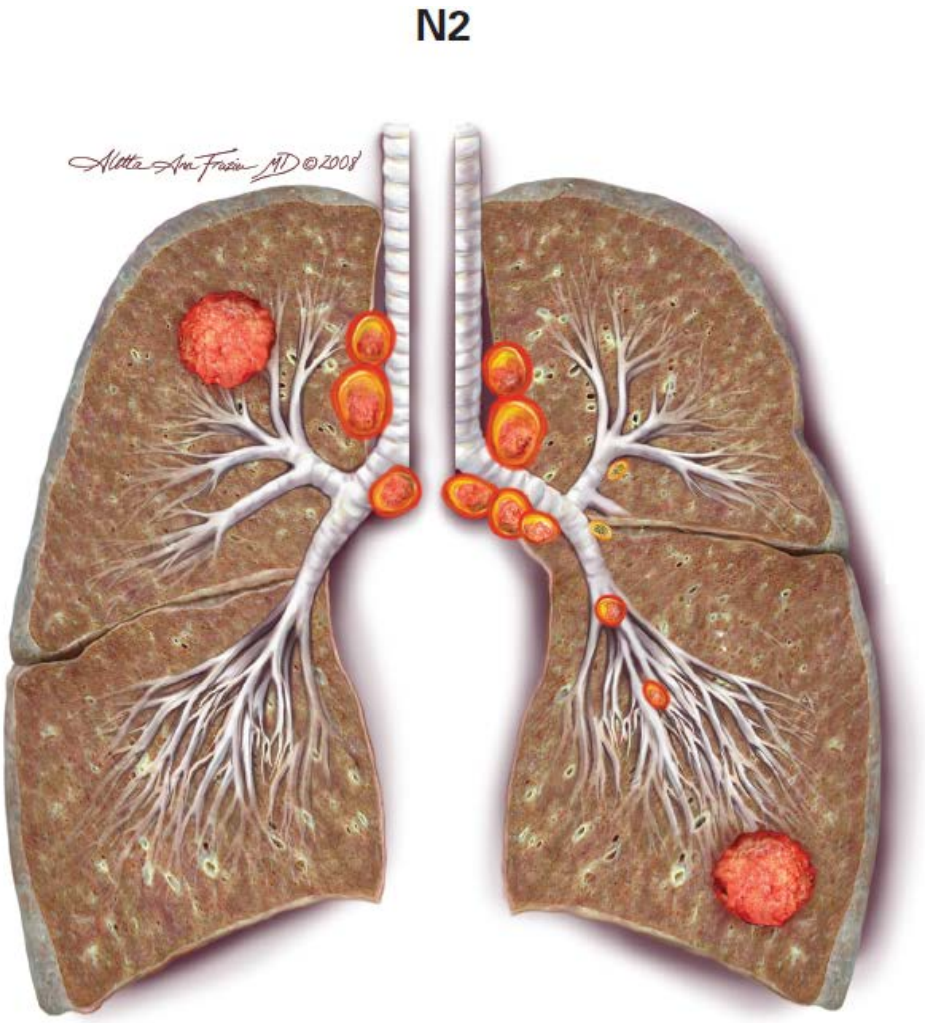

N2 Metastasis in ipsilateral mediastinal and/or subcarinal lymph node(s)

- including skip metastasis without N1 involvement
- or associated with N1 disease

Nodal stage

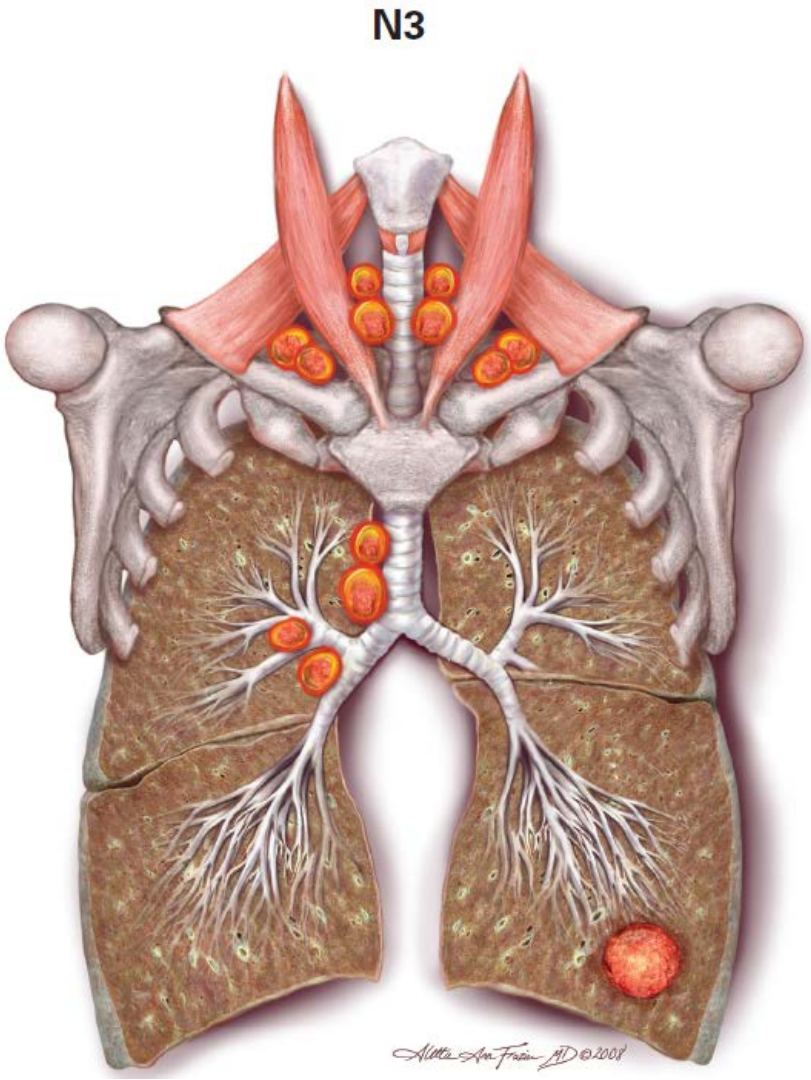

N3 Metastasis to

- contralateral mediastinal, contralateral hilar, contralateral scalene or supraclavicular lymph node(s)

- ipsilateral scalene or supraclavicular lymph node(s)

Elective versus selective nodal irradiation in NSCLC

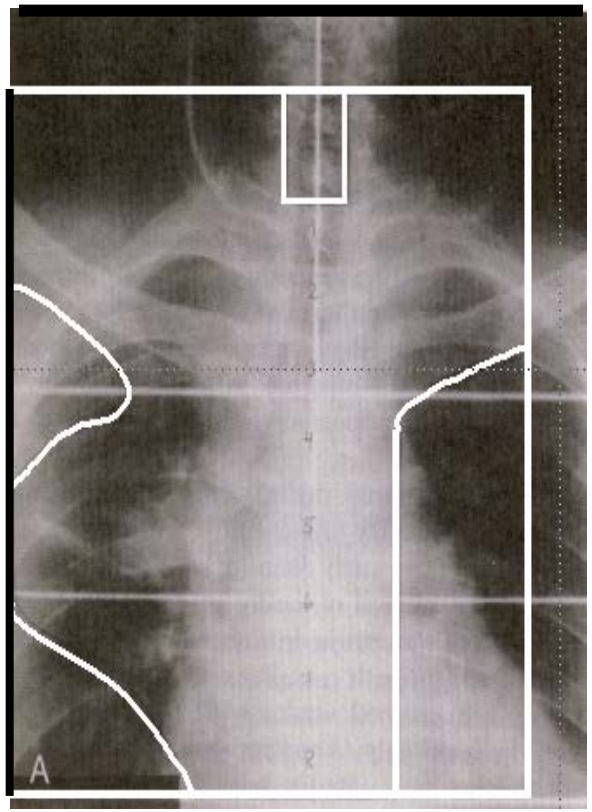

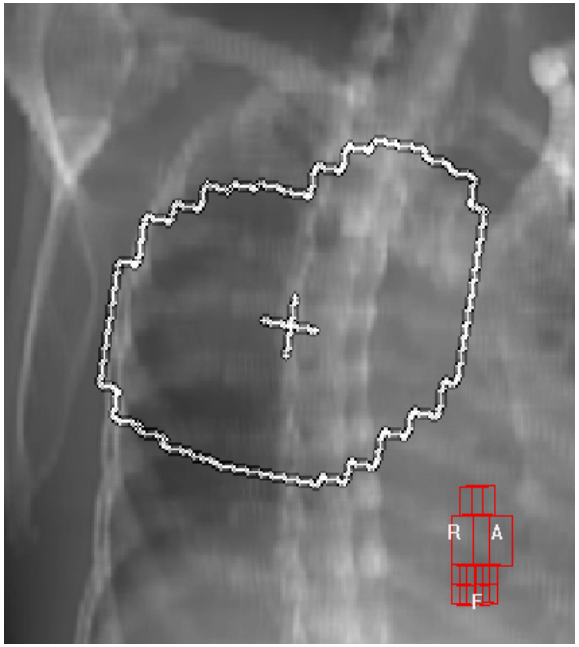

Importance of staging

CT 1 cm size criterion (short axis)

PET positive lymph nodes

Elective versus selective nodal irradiation in NSCLC

+ elective

- Conventional
- False negative rate on CT scan
- Occult micrometastases

+ selective

- Toxicity
- Relapses mainly local and distant
- Isolated nodal relapse 0-6%
- Incidental dose in regional lymph nodes

Selective nodal irradiation in NSCLC: CT or PET?

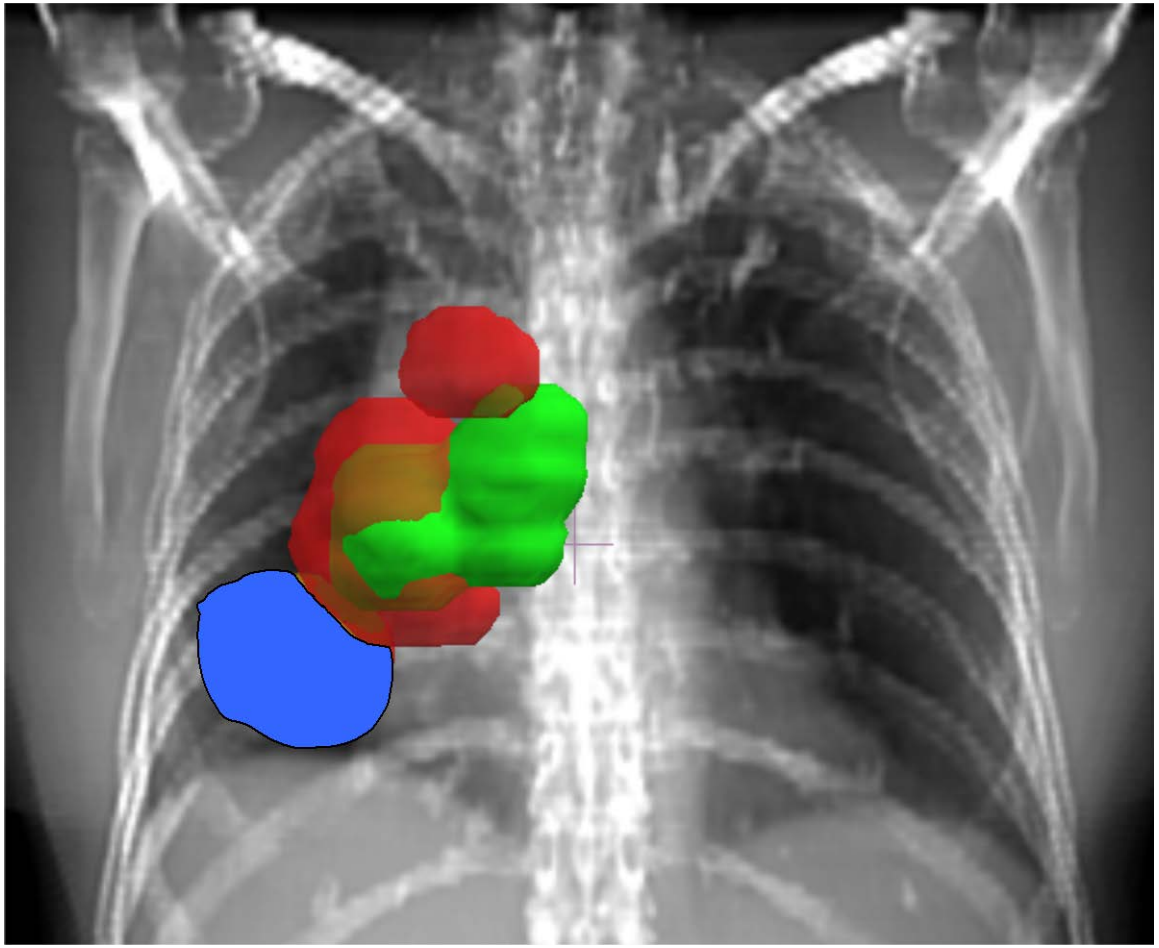

Primary tumour right lower lobe (blue)

Pathological lymph nodes
CT based: red
FDG-PET scan based: green

Selective nodal irradiation in NSCLC: CT or PET?

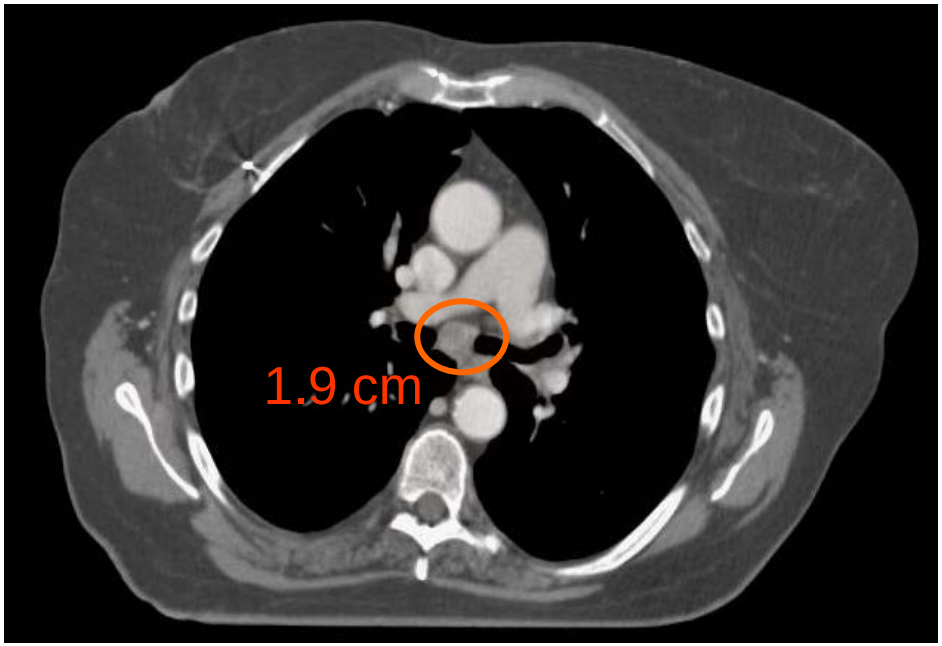

CT: lnn station 7 enlarged
cT4**N2**M0

PET: lnn station 7 negative
cT4**N0**M0

Selective nodal irradiation in NSCLC: FDG-PET-CT based!

- 44 patients NSCLC
- 61.2-64.8 Gy (1.8 Gy BID)
- median FU: 16 months
- Isolated nodal recurrence: 1 patient (2.3%)

- 88 patients NSCLC
- dose-escalation study
- median FU: 16 months
- Isolated nodal recurrence: 2 patients (2.3%)

Selective nodal irradiation based on **PET-CT** is safe in NSCLC

De Ruysscher *et al*., IJROBP 2005
Belderbos *et al*., IJROBP 2006

Elective versus selective nodal irradiation in NSCLC

Reference	Number of patients	LN target volume using CT and/or ^{18}FDG PET	ENI yes/no	ENI dose (Gy)	% isolated LN failure
Graham M., *et al.*, 1995†	179	LN ≥1 cm	No		8%
Kong FM., *et al.*, 2005*	106	LN ≥1 cm (pre-chemotherapy)	No		6%
Rosenzweig K., *et al.*, 2001*	171	LN ≥1.5 cm	No	-	6.4%
Senan S., *et al.*, 2002*	50	LN ≥1 cm N2 and T4N0 tumors: ipsilateral hilus included	Yes	50	0
De Ruysscher D., *et al.*, 2005†	44	PET + LN only	No	-	2 %
Belderbos J., *et al.*, 2006†	67	PET + LN only	No	-	3 %
Rosenzweig K., *et al.*, 2007*	524	LN ≥1.5 cm and in 314 patients PET + LN also	No		6.1%

- No proven benefit of ENI in NSCLC
- Selective nodal RT is recommended

Belderbos *et al.*, IJROBP 2008

Selective nodal irradiation in NSCLC: FDG-PET-CT based in IMRT!

- Validation of concept in IMRT era
- Retrospective study in N=183 NSCLC patients

- Isolated nodal recurrence in 1.6% of the patients
- Out of field regional recurrence 29.2%, 85.7% of these in non-adjacent lymph node station

- Combined locoregional recurrence: 2.2%
- Combined nodal and distant recurrence: 15.3%

- SNI remains safe in the era of highly conformal RT

Martinussen *et al.*, submitted

Proposal definition of nodal target volume in NSCLC

Table 1 Scheme for Defining the Mediastinal GTV for NSCLC

Nodal Diameter* and PET†	Action
<1 cm PET +ve	Include in GTV
<1 cm PET −ve	Exclude from GTV
>1 cm PET +ve	Include in GTV unless repeated cytology of the node is negative
>1 cm PET −ve and where no cytology is available	Include in GTV if primary tumor is PET negative If primary tumor shows PET uptake, exclude node from GTV unless cytologically positive

*Diameter in short-axis.
†Using a dedicated PET scanner.

Senan *et al.*, Radiother Oncol 2004

Elective versus selective nodal irradiation in SCLC

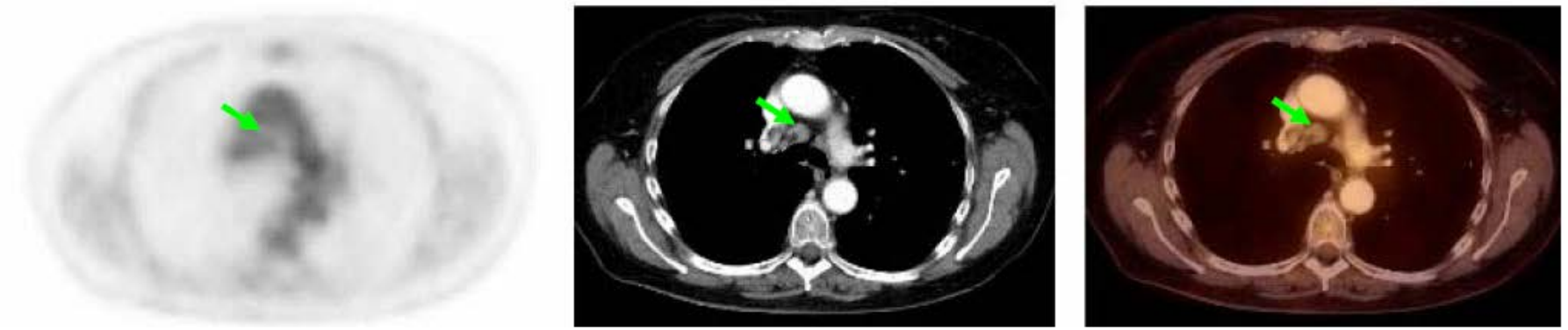

- Is selective nodal irradiation save in SCLC?
- If so, CT or PET based?

Selective nodal irradiation in SCLC: CT based

- 27 patients with SCLC – Limited Disease
- Concurrent chemo-radiotherapy (30 x 1.5 Gy BID)
- Selective nodal irradiation to CT-positive nodes
- Median follow-up 18 months
- 3 patients (11%) developed isolated nodal recurrence in the ipsilateral supraclavicular fossa

Selective nodal irradiation based on **CT** is possibly not safe in SCLC

De Ruysscher *et al.*, Radiother Oncol 2006

Selective nodal irradiation in SCLC: FDG-PET based

- 60 patients with SCLC – Limited Disease
- Concurrent chemo-radiotherapy (30 x 1.5 Gy BID)
- Selective nodal irradiation to PET-positive nodes
- Median follow-up 29 months
- 2 patients (3%) developed isolated regional recurrence

Selective nodal irradiation based on **FDG-PET** seems safe in SCLC

Van Loon *et al.*, Int J Radiat Oncol Biol Phys 2010

Interobserver variation in nodal delineation

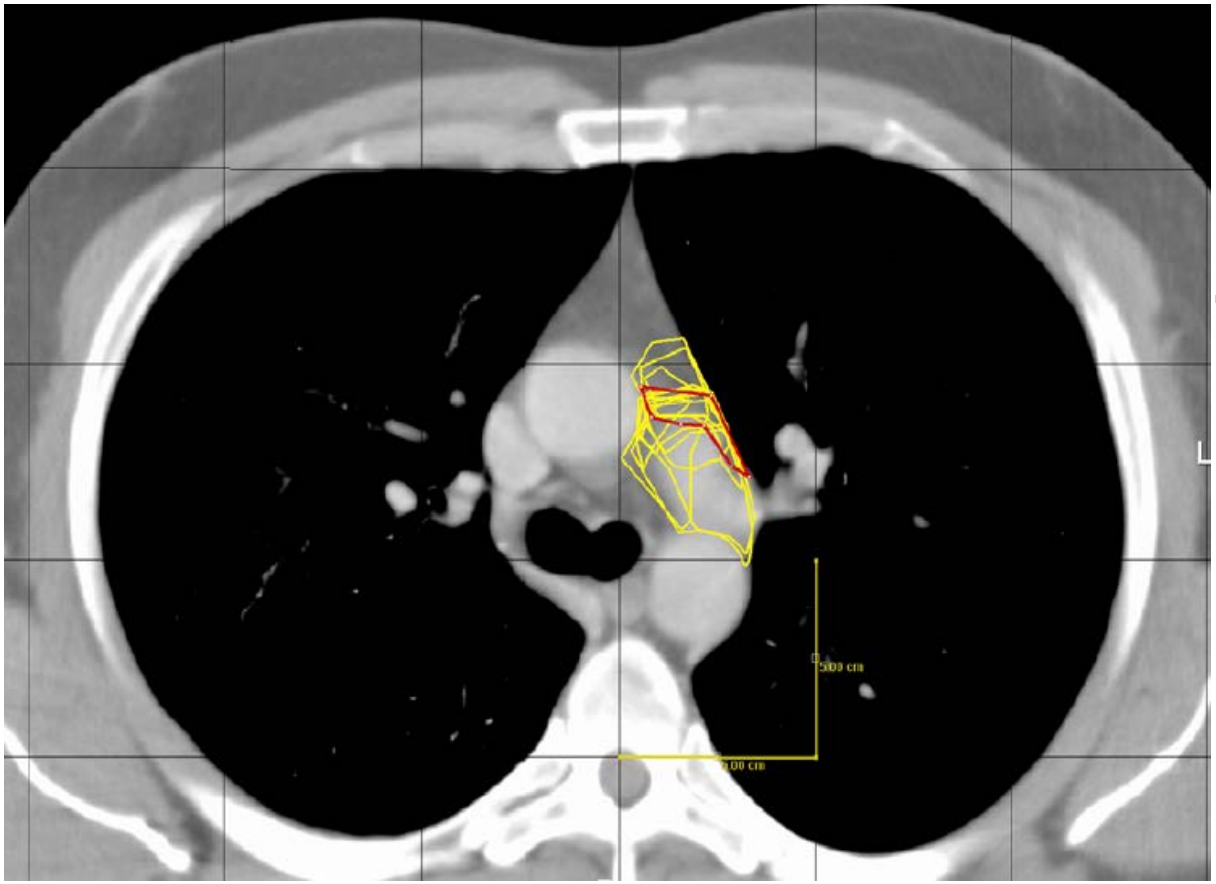

Consensus
Different observers

Kepka *et al.*, Radiother Oncol 2007

IASCL Nodal Definitions

Nodal station	Description	Definition
#1 (Left/Right)	Low cervical, supraclavicular and sternal notch nodes	Upper border: lower margin of cricoid cartilage Lower border: clavicles bilaterally and, in the midline, the upper border of the manubrium #L1 and #R1 limited by the midline of the trachea.
#2 (Left/Right)	Upper paratracheal nodes	2R: Upper border: apex of lung and pleural space and, in the midline, the upper border of the manubrium Lower border: intersection of caudal margin of innominate vein with the trachea 2L: Upper border: apex of the lung and pleural space and, in the midline, the upper border of the manubrium Lower border: superior border of the aortic arch As for #4, in #2 the oncologic midline is along the left lateral border of the trachea.

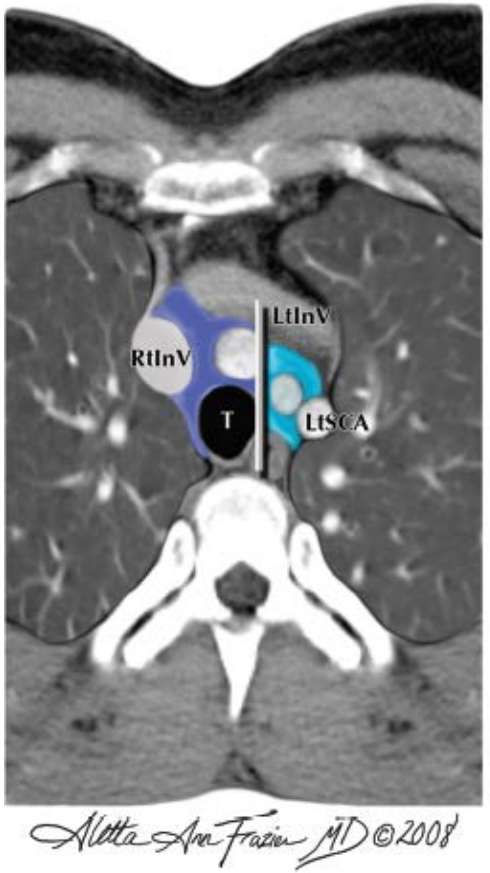

IASCL Nodal Definitions

#3	Pre-vascular and retrotracheal nodes	3a: Prevascular On the right upper border: apex of chest lower border: level of carina anterior border: posterior aspect of sternum posterior border: anterior border of superior vena cava On the left upper border: apex of chest lower border: level of carina anterior border: posterior aspect of sternum posterior border: left carotid artery 3p: Retrotracheal upper border: apex of chest lower border: carina
#4 (Left/Right)	Lower paratracheal nodes	4R: includes right paratracheal nodes, and pretracheal nodes extending to the left lateral border of trachea upper border: intersection of caudal margin of innominate vein with the trachea lower border: lower border of azygos vein 4L: includes nodes to the left of the left lateral border of the trachea, medial to the ligamentum arteriosum upper border: upper margin of the aortic arch lower border: upper rim of the left main pulmonary artery

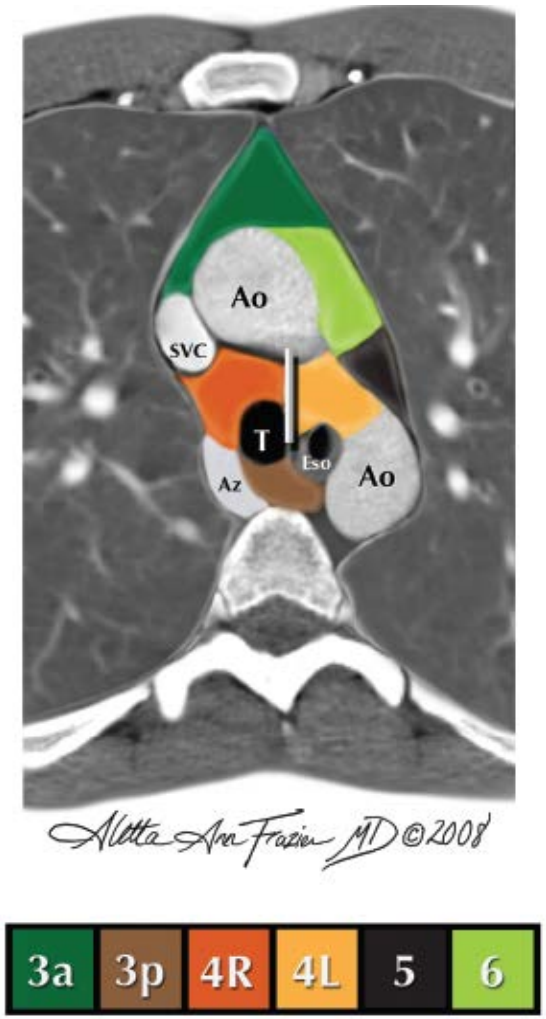

IASCL – staging manual in thoracic oncology 2009

IASCL Nodal Definitions

#5	Subaortic (aorto-pulmonary window)	Subaortic lymph nodes lateral to the ligamentum arteriosum upper border: the lower border of the aortic arch lower border: upper rim of the left main pulmonary artery
#6	Para-aortic nodes (ascending aorta or phrenic)	Lymph nodes anterior and lateral to the ascending aorta and aortic arch upper border: a line tangential to the upper border of the aortic arch lower border: the lower border of the aortic arch
#7	Subcarinal nodes	upper border: the carina of the trachea lower border: the upper border of the lower lobe bronchus on the left; the lower border of the bronchus intermedius on the right
#8 (Left/Right)	Para-esophageal nodes (below carina)	Nodes lying adjacent to the wall of the esophagus and to the right or left of the midline, excluding subcarinal nodes upper border: the upper border of the lower lobe bronchus on the left; the lower border of the bronchus intermedius on the right lower border: the diaphragm

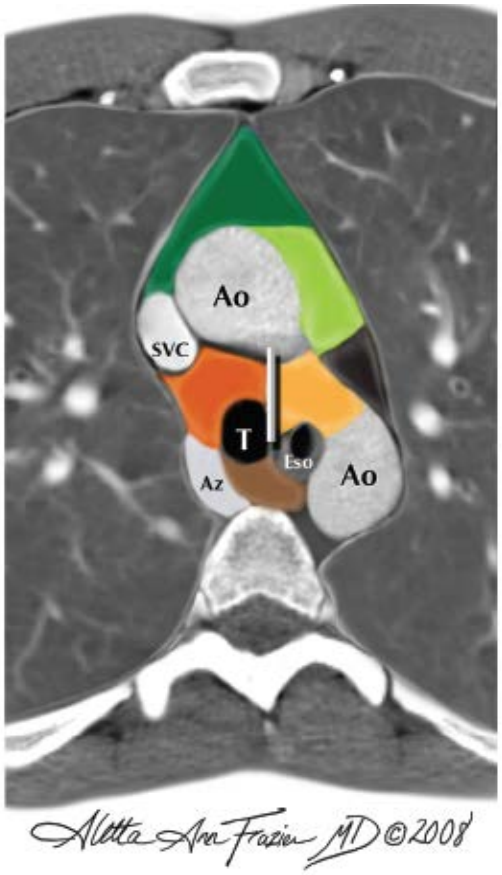

IASCL – staging manual in thoracic oncology 2009

IASCL Nodal Definitions

#9 (Left/Right)	Pulmonary ligament nodes	Nodes lying within the pulmonary ligament upper border: the inferior pulmonary vein lower border: the diaphragm
#10 (Left/Right)	Hilar nodes	Includes nodes immediately adjacent to the mainstem bronchus and hilar vessels including the proximal portions of the pulmonary veins and main pulmonary artery upper border: the lower rim of the azygos vein on the right; upper rim of the pulmonary artery on the left lower border: interlobar region bilaterally
#11	Interlobar nodes	Between the origin of the lobar bronchi *#11s: between the upper lobe bronchus and bronchus intermedius on the right *#11i: between the middle and lower lobe bronchi on the right *optional sub-categories

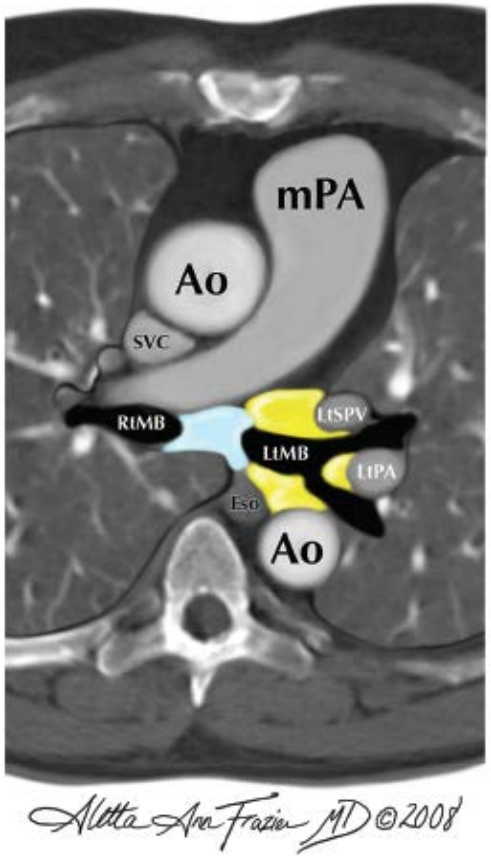

Content

- Elective nodal irradiation *versus* selective nodal irradiation in NSCLC and SCLC
- Proposal for nodal target volume
- Primary tumor
- SABR
- Postoperative irradiation
- Organs at risk

- Window-level setting:
  - lung window for lung interfaces
  - soft tissue window for mediastinal and hilar interfaces

soft tissue window

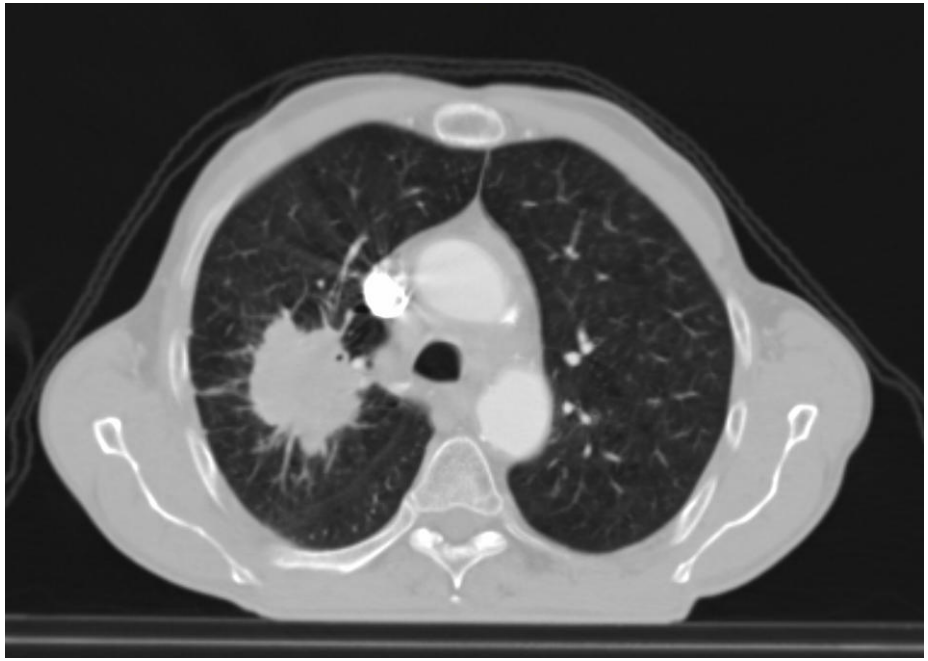

lung window

PET

- Window-level setting:
  - fixed setting necessary

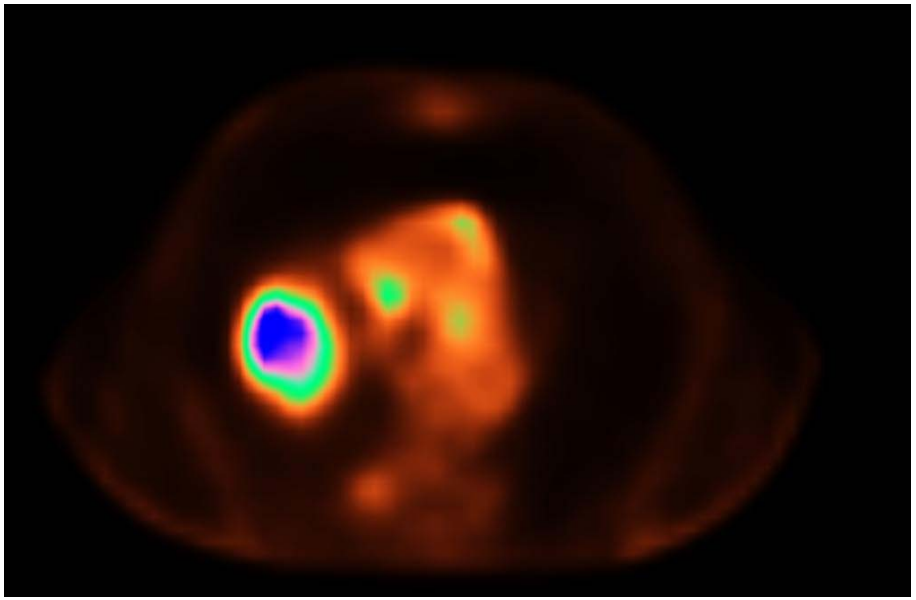

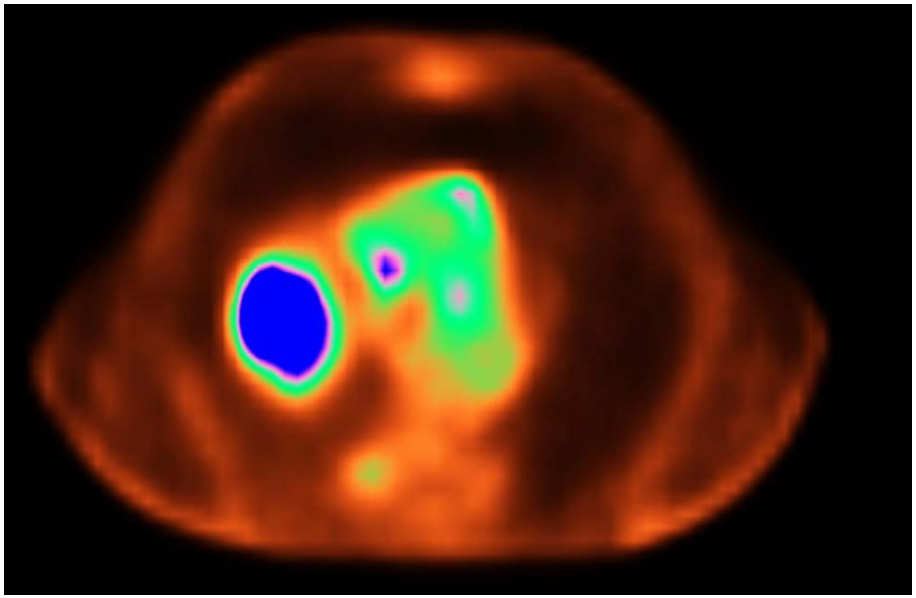

Same tumor, different settings

Boellaard *et al.*, Eur J Nucl Med Mol Imaging 2010

CT and PET for GTV

CT

- Window-level setting:
  - lung window for lung
  - soft tissue window for mediastinum
- Challenges for RT planning:
  - atelectasis
  - effusion
  - nodal involvement
  - movements

PET

- Window-level setting:
  - fixed setting necessary
- Challenges for RT planning:
  - inflammation
  - border (low resolution)
  - movements

Boellaard *et al.*, Eur J Nucl Med Mol Imaging 2010

Interobserver variability in delineation

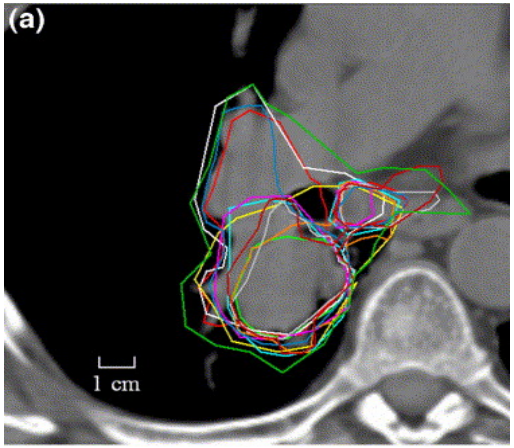

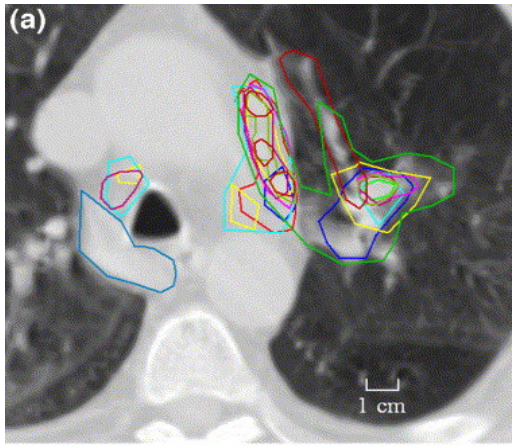

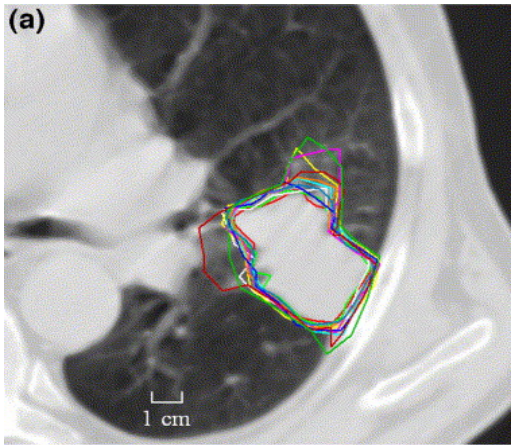

CT: large interobserver variation

Steenbakkers *et al.*, Int J Radiat Biol Oncol Phys 2006

Interobserver variability in delineation

SD 10.2 mm

SD 5.2 mm

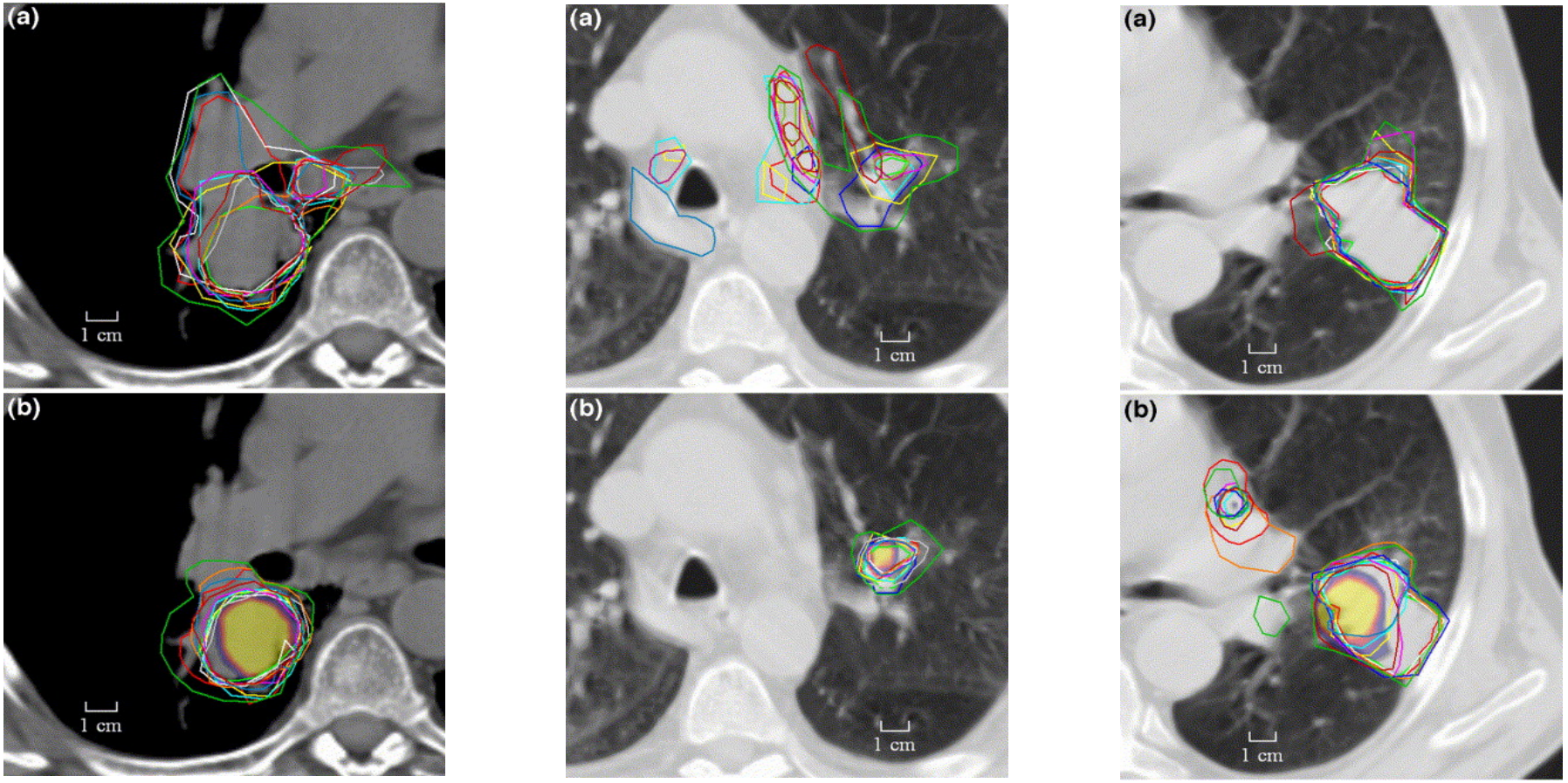

PET: reduced interobserver variation

Steenbakkers *et al.*, Int J Radiat Biol Oncol Phys 2006

CTV: Imaging vs pathology

- n=70 surgical resection specimens
- quantification of microscopic extension

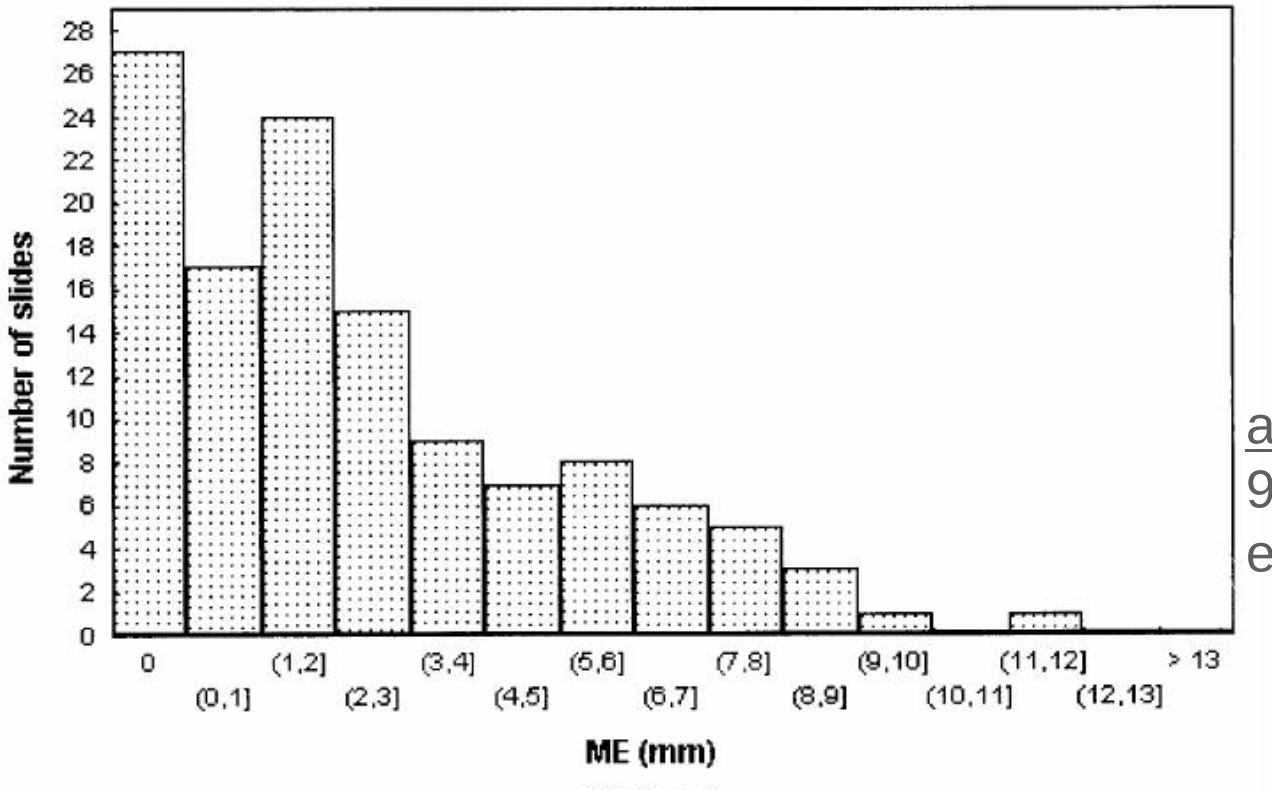

adenocarcinoma
95% of microscopic extension < 8 mm

Giraud *et al.*, Int J Radiat Biol Oncol Phys 2000

CTV: Imaging vs pathology

- n=70 surgical resection specimens
- quantification of microscopic extension

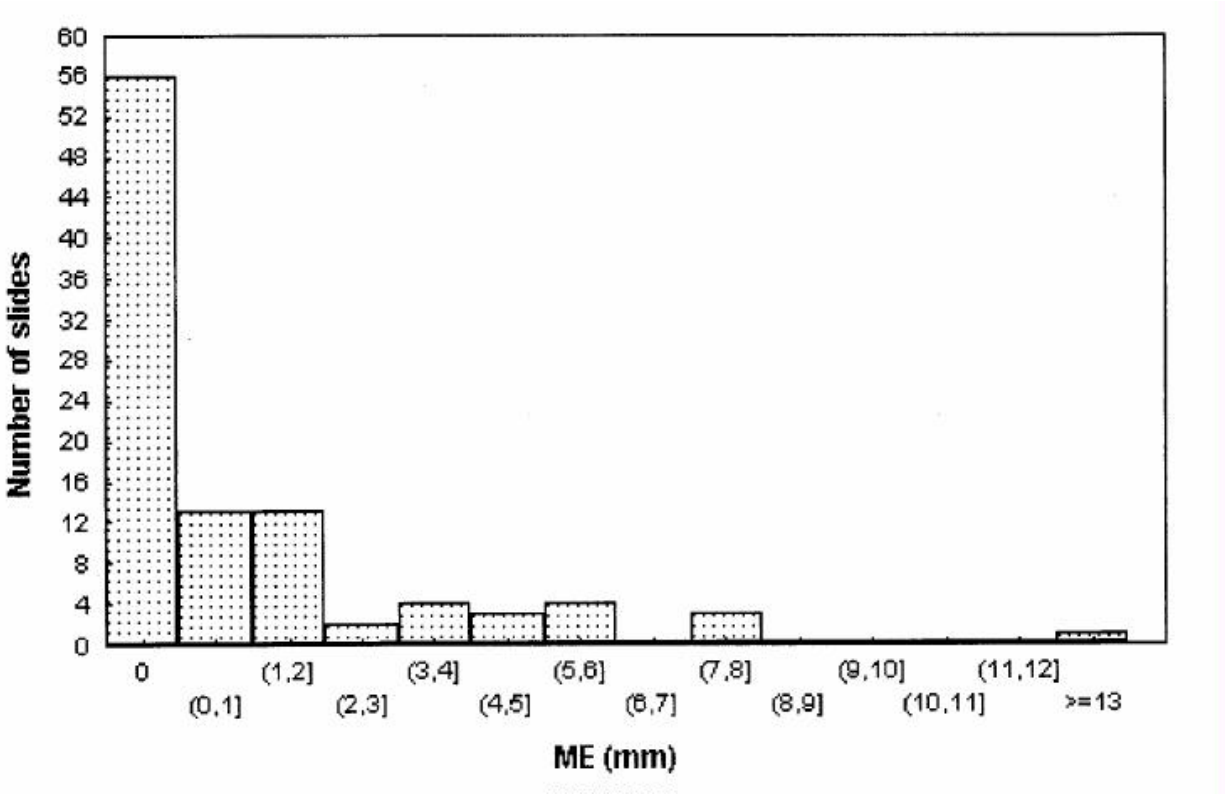

Squamous cell ca
95% of microscopic extension < 6 mm

Giraud *et al.*, Int J Radiat Biol Oncol Phys 2000

CTV: Imaging vs pathology

Imaging vs pathology

- patients undergoing lobectomy
- Pre-operative imaging
  - High resolution RC-CT
  - (RC-)FDG-PET
- Post-operative imaging
  - Macroscopy
  - Microscopy

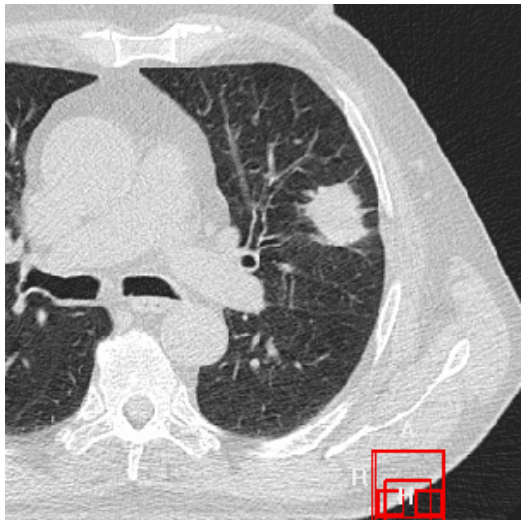

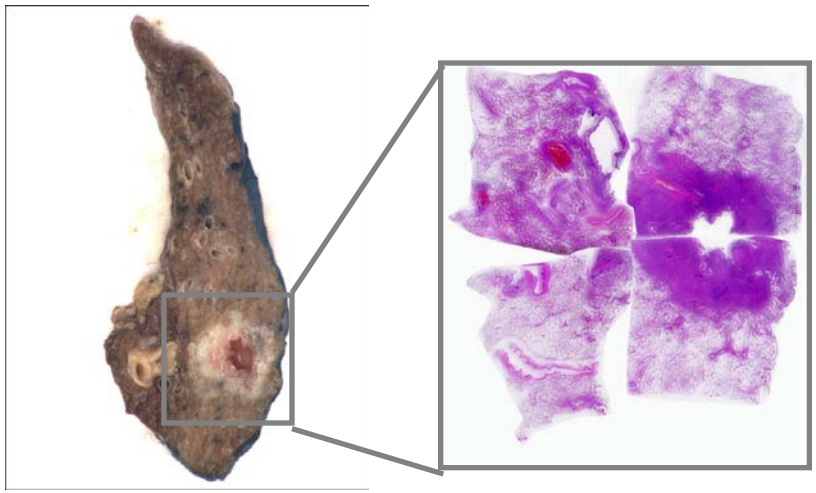

Stroom *et al.*, Int J Radiat Biol Oncol Phys 2007

CTV: Imaging vs pathology

GTV: volume comparison CT – PET - pathology

	GTVs (cm^3)			
Pt. No.	CT	PET	Pathology	ME_{max} (mm)
1	15	13	6	6
2	12	-	12	5
3	9	7	4	9
4	10	7	8	0
5	23	24	39	3

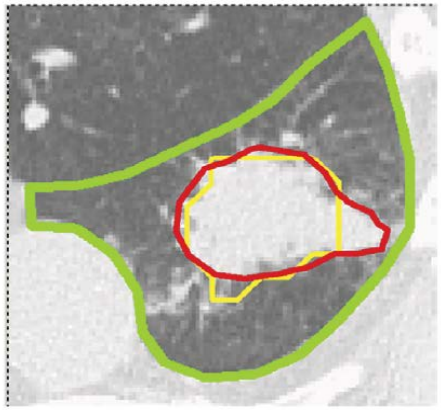

pt # 5

Stroom *et al.*, Int J Radiat Biol Oncol Phys 2007

Content

- Elective nodal irradiation *versus* selective nodal irradiation in NSCLC and SCLC
- Proposal for nodal target volume
- Primary tumor
- SABR
- Postoperative irradiation
- Organs at risk

Respiration-induced imaging artifacts

- One CT scan is not sufficient to delineate the GTV
- Motion should be taken into account:
  - fluoroscopy
  - slow CT
  - 4D CT / midventilation CT

Respiration-induced imaging artifacts – FDG-PET

Why respiration correlated PET-CT?

- Motion blurring → Contrast reduction!
- Different acquisition times: PET 2-5 min CT 20-50 sec

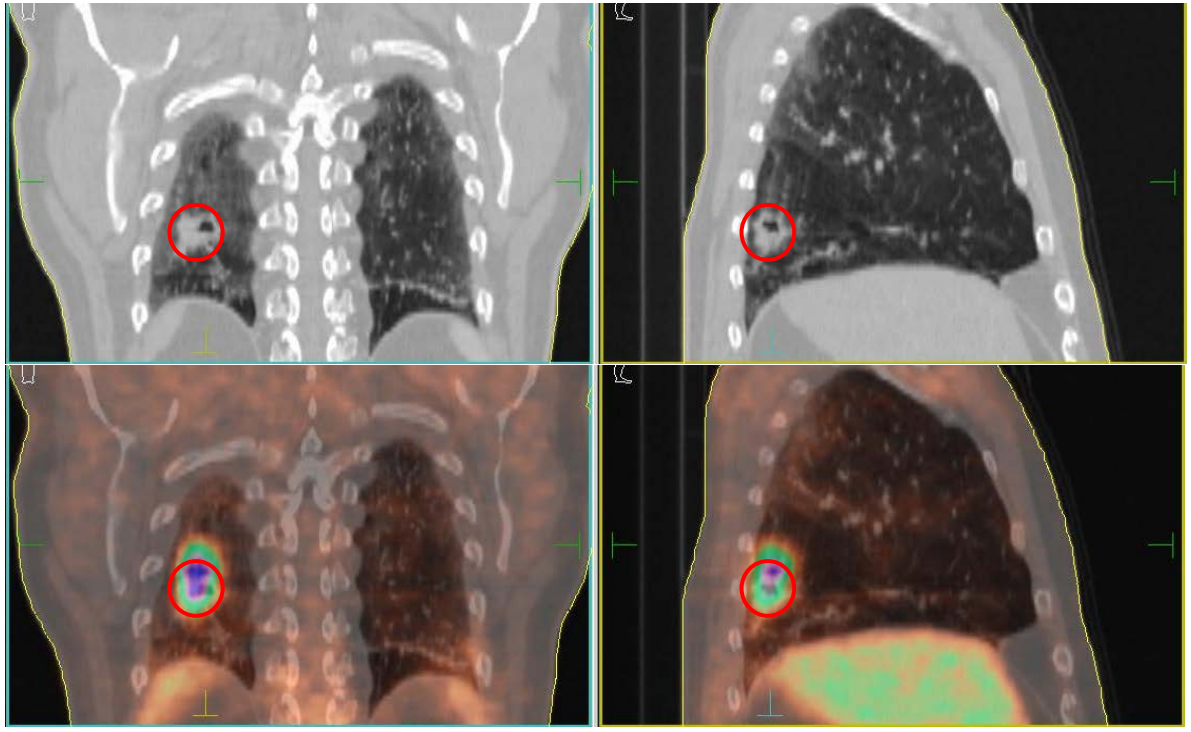

Respiration correlated FDG-PET/CT

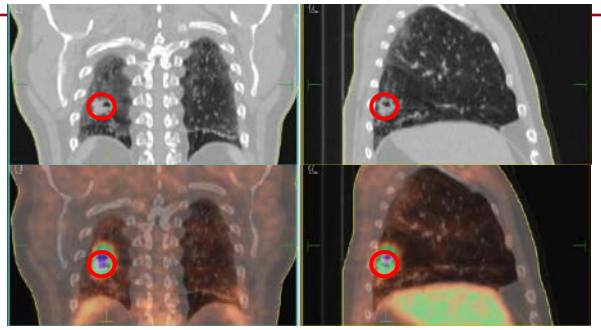

Consequences for GTV delineation:

- Stage I / SABR:
  - Delineation on CT of all (8) phases of the respiratory cycle
  - ITV generated on 3D-FDG-PET is NO surrogate!!
  - Automatically segmented 4D-FDG-PET may provide additional information

- Advanced stage:
  - Delineation of target volume on CT of 3 respiratory phases – i.e., 0%/50%/100% exspiration
  - FDG-PET provides additional information, e.g. Atelectasis.

Troost *et al.*, in preparation

Different SABR concepts

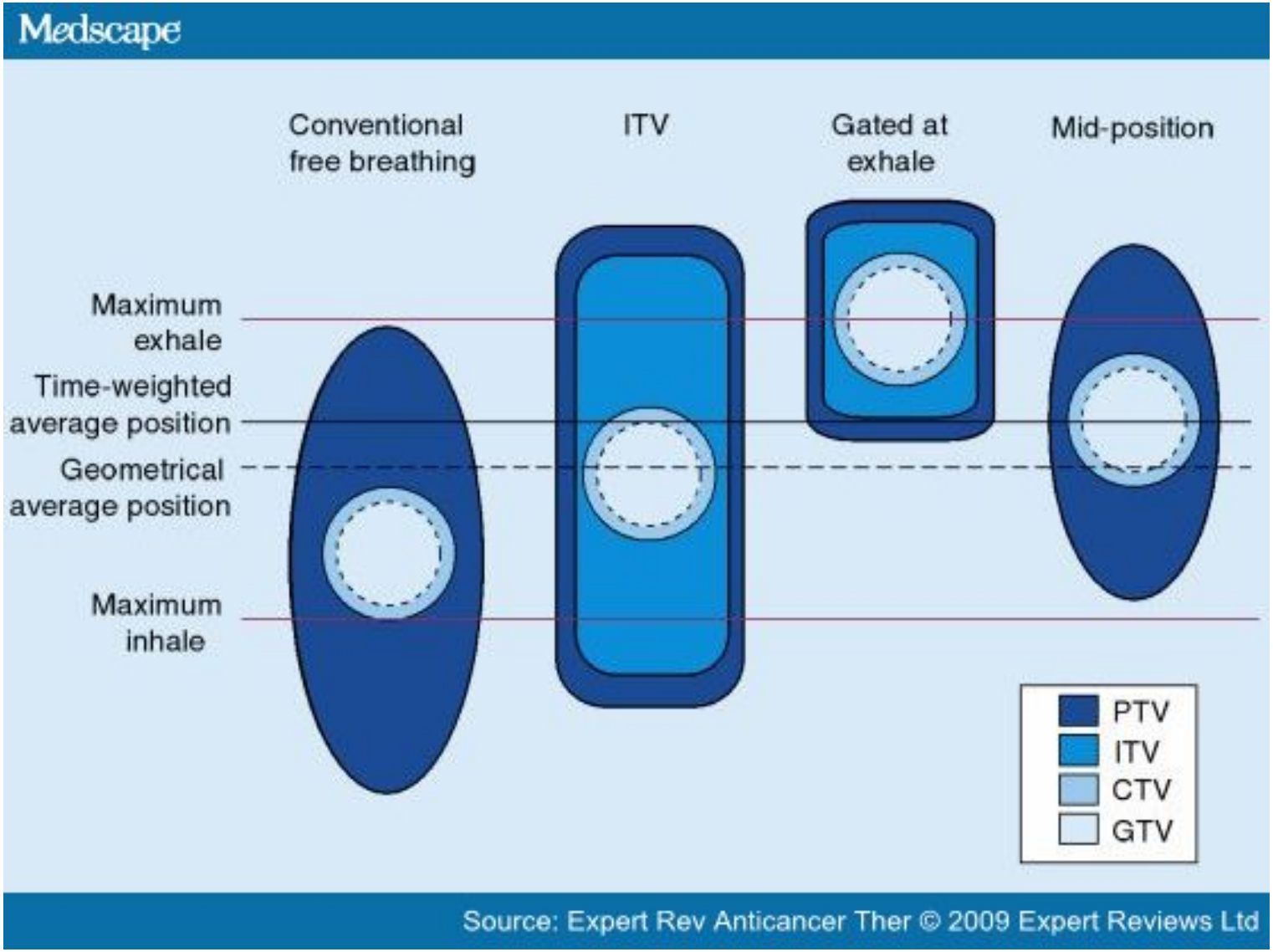

Content

- Elective nodal irradiation *versus* selective nodal irradiation in NSCLC and SCLC
- Proposal for nodal target volume
- Primary tumor
- SABR
- Postoperative irradiation
- Organs at risk

Postoperative irradiation

- Possibly perform a FDG-PET-CT scan for postoperative staging and treatment planning, especially after adjuvant chemotherapy
- Use surgical report and clips as guidance
- Include the entire surgical bed
- No uniform recommendation on lymph node levels:
  - Only include the involved level?
  - Or 1 adjacent levels (cranially and caudally) in the presence of extranodal spread?
  - Take lymphatic drainage into account!

Content

- Elective nodal irradiation *versus* selective nodal irradiation in NSCLC and SCLC
- Proposal for nodal target volume
- Primary tumor
- SABR
- Postoperative irradiation
- Organs at risk

Organs at risk

- Joint recommendation by RTOG, EORTC, SWOG
- 3D-delination of OARs described
- Lungs, bronchial tree, brachial plexus, spinal cord, oesophagus, ribs

Kong *et al.*, Int J Radiat Oncol Biol Phys 2011

Importance

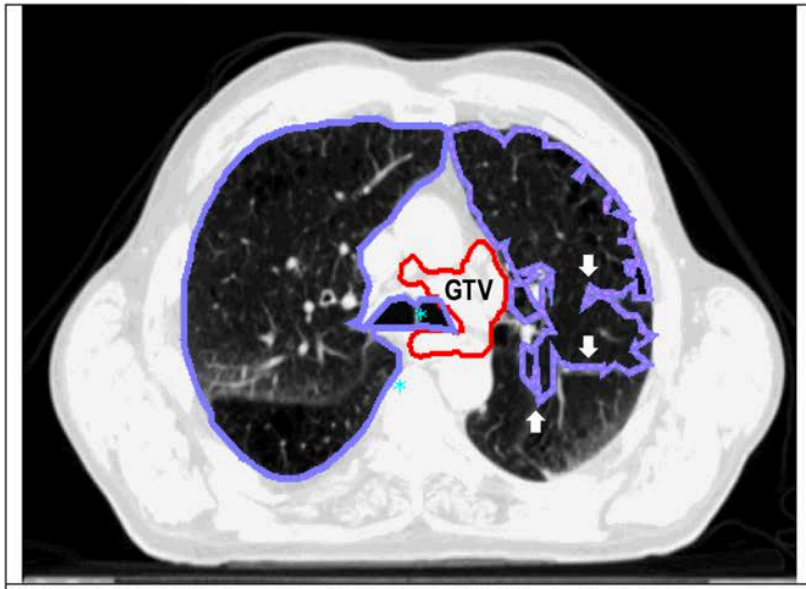

A: Lung Contour - Autotrack Failure (white arrows)

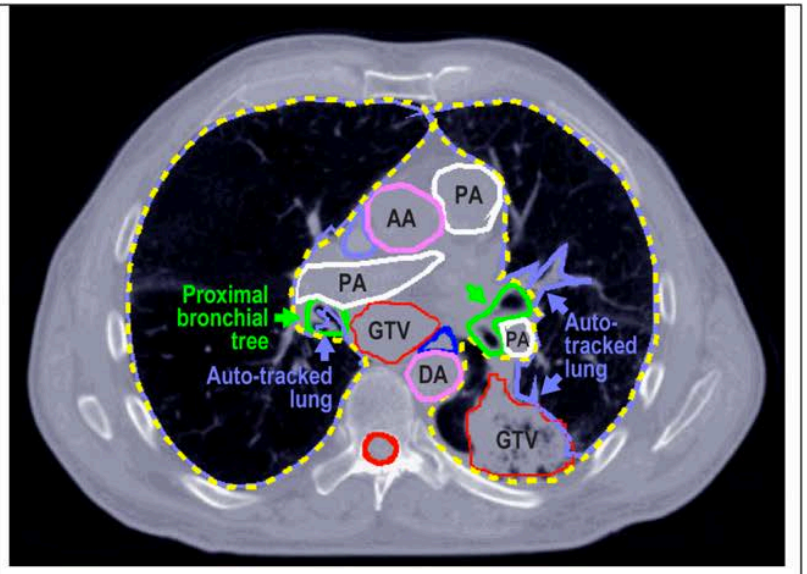

B: Lung Contour Variants (dashed and solid)

Kong *et al.*, Int J Radiat Oncol Biol Phys 2011

Importance

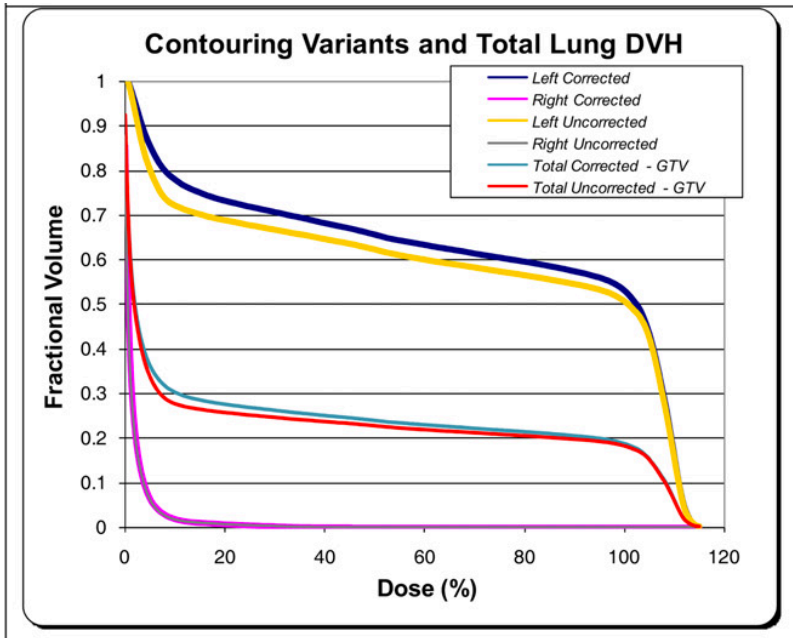

C: Lung DVH differences of contouring variants

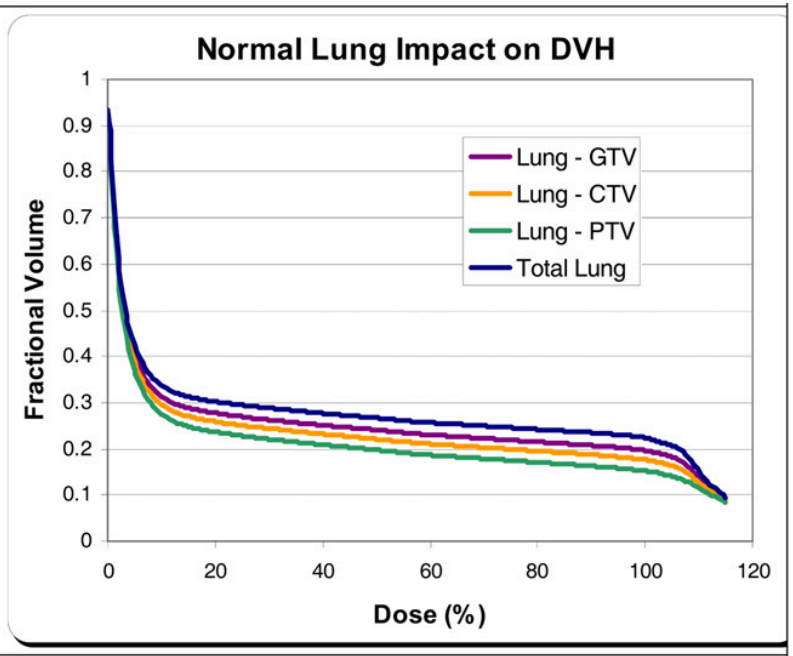

D: Lung DVH differences on target consideration

Kong *et al.*, Int J Radiat Oncol Biol Phys 2011

Variation and motion of OARs

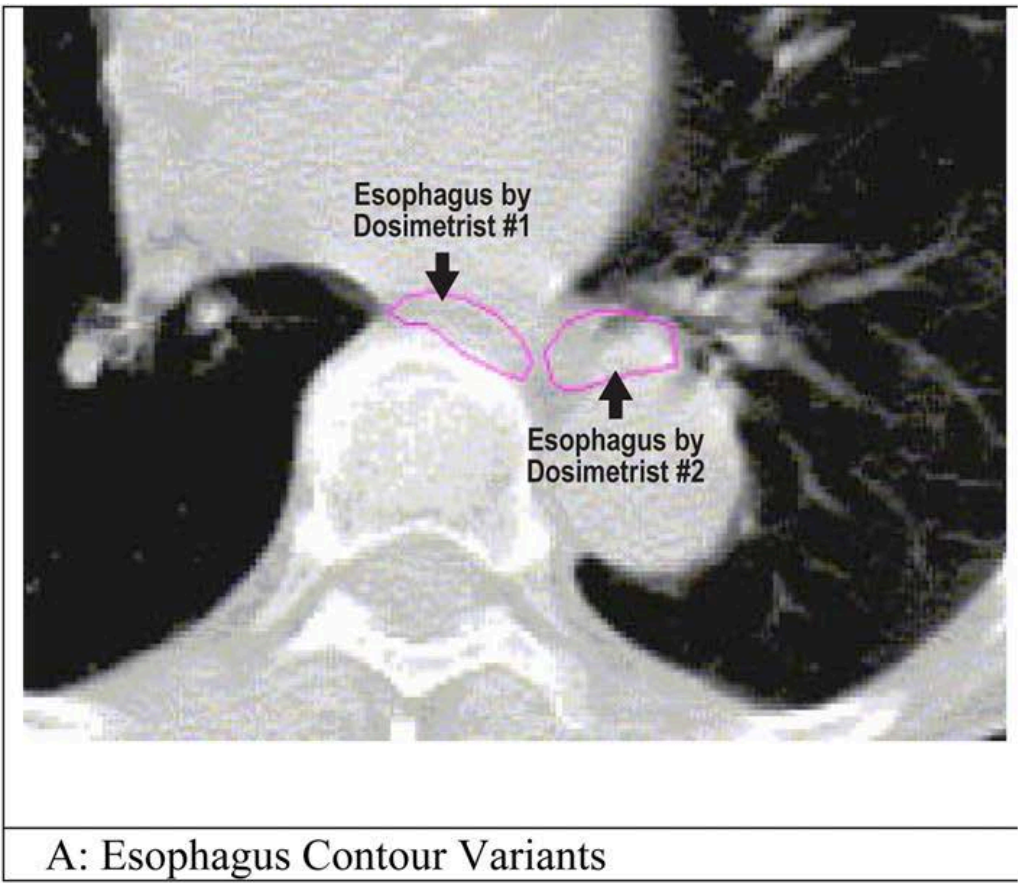

A: Esophagus Contour Variants

Kong *et al.*, Int J Radiat Oncol Biol Phys 2011

Thorax

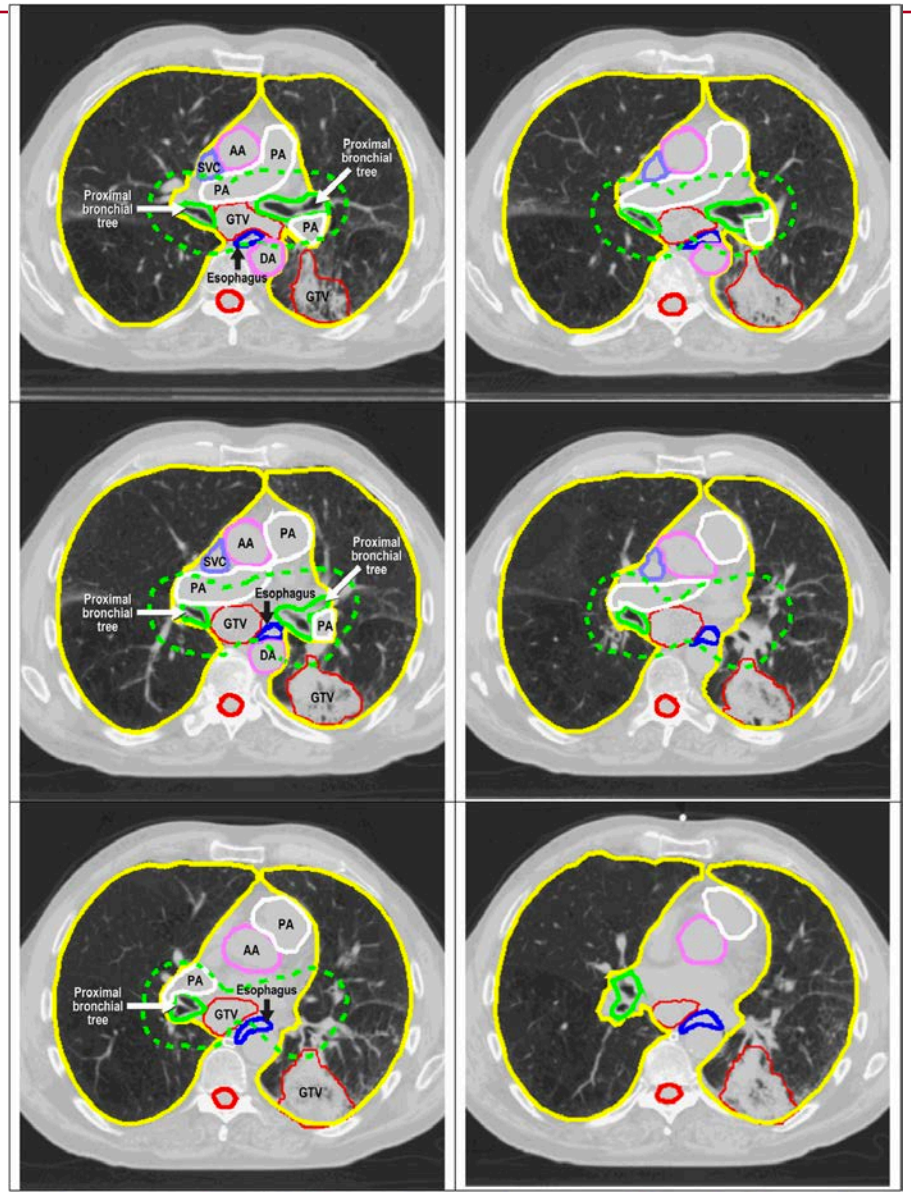

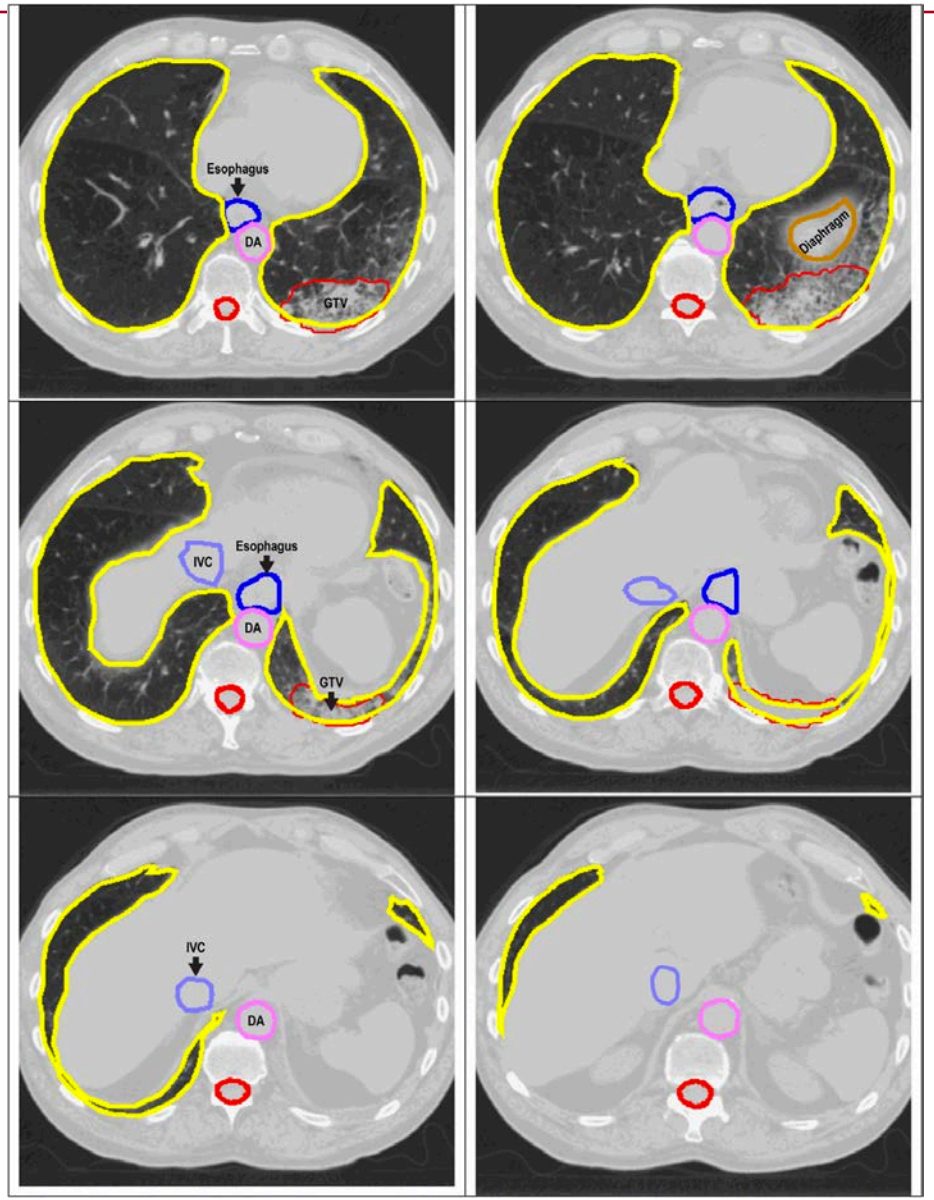

Kong *et al.*, Int J Radiat Oncol Biol Phys 2011

Brachial plexus

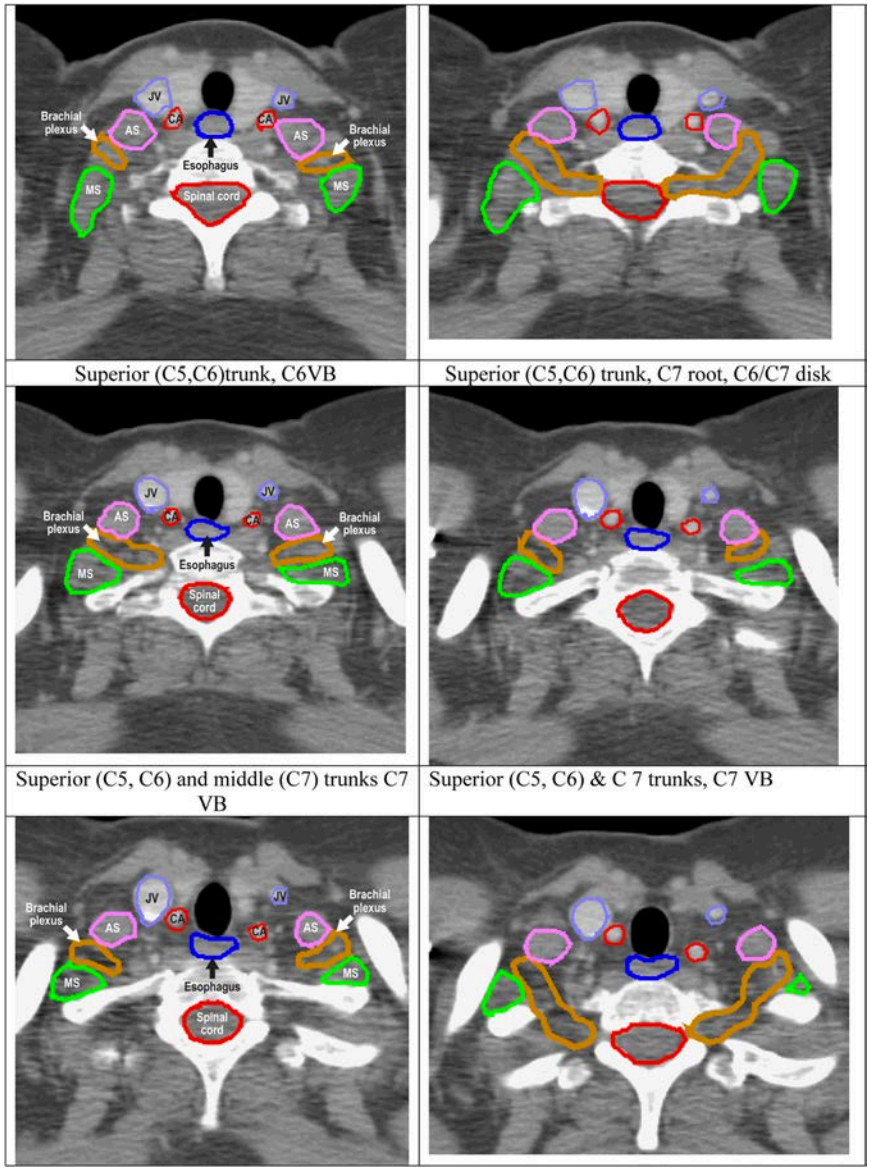

Kong *et al.*, Int J Radiat Oncol Biol Phys 2011

Take home messages

The optimal nodal target volume determination remains challenging……

- Selective nodal irradiation based on non-invasive techniques (CT/PET/EUS) standard of care in many centers → seems safe also in era of highly conformal RT techniques

- Use of IASCL nodal mapping

Take home messages

- Reduction of interobserver variation in GTV delineation when using combined CT and FDG-PET
- Delineation of EBRT *versus* SABR requires different strategies
- No consensus guidelines on postoperative target volume
- Organs at risk are gaining importance for dose-escalation or re-irradiation

Thank you for
your attention!
OncoRay – National Center for Radiation
Research in Oncology, Dresden

ANATOMY & LYMPH NODE DRAINAGE FOR HEAD & NECK CANCER

Dr Brendan Carey

St James's University Hospital

Leeds

UK



7
6
O
d
K
S
M

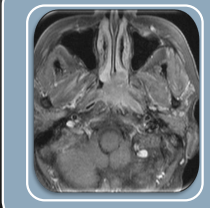

NASOPHARYNX

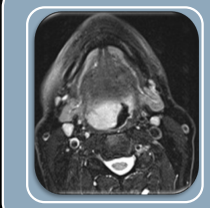

ORAL CAVITY

LARYNX

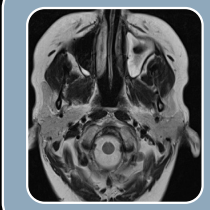

Salivary Glands

NECK NODES

Relevant Anatomy for defining GTV

What do tumours look like ?

What nodes are likely to be involved ?

CT

-Bone / Cartilage

MRI

Soft Tissue

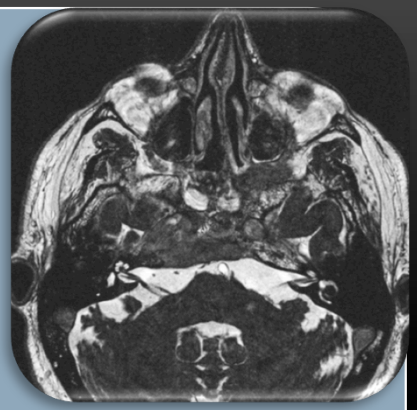

Imaging

For

Anatomy (GTV)

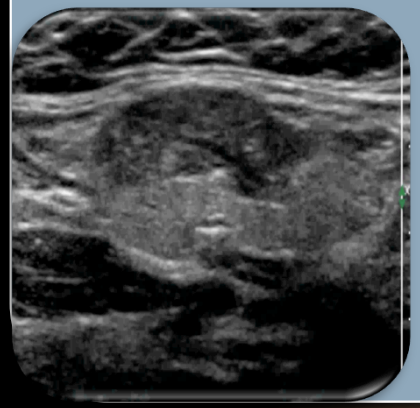

US

-nodes

PET

- Staging

- Response

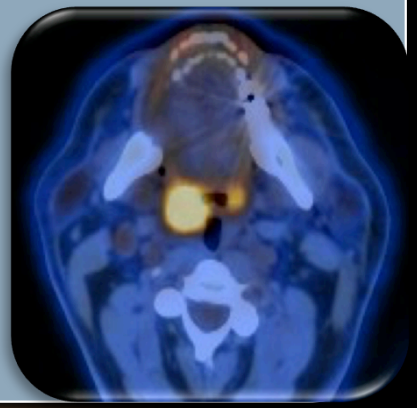

CT better for Bone and Cartilage Anatomy

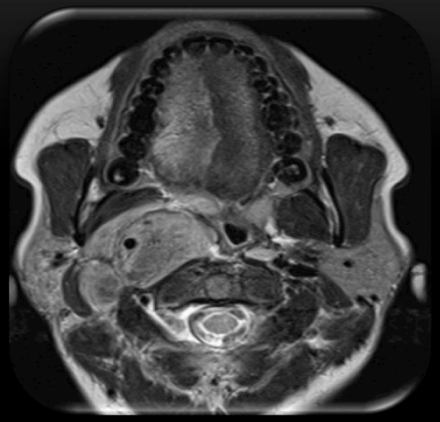

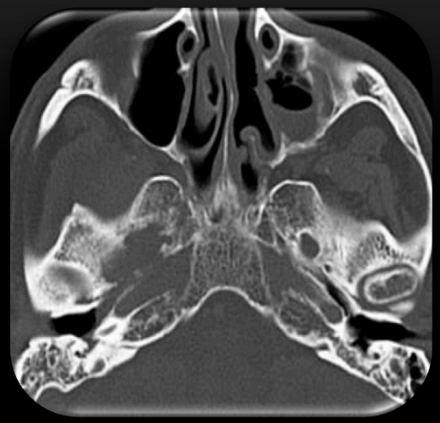

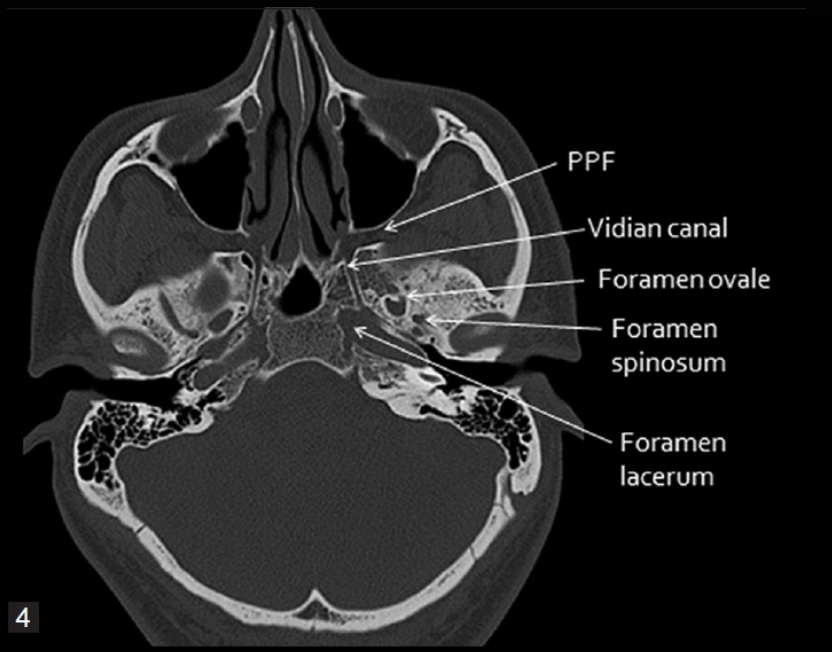

Extent of bony involvement can be underestimated on MRI alone

No MRI signal from Cortical Bone (only marrow)

MRI BEST FOR SOFT TISSUE ANATOMY

Best Imaging Technique for Soft Tissue detail

- imaging of choice for Oropharynx

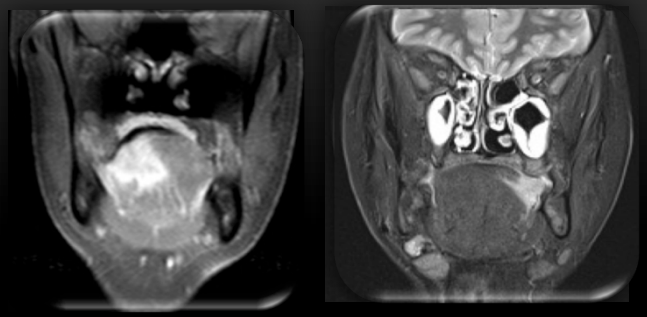

Best technique for demonstrating perineural spread

- particularly for Nasopharynx

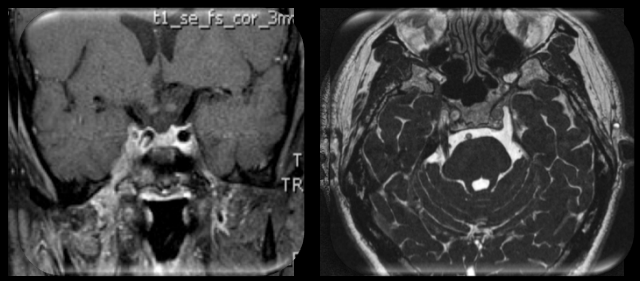

Generally better for delineation of recurrences

- especially post-surgery

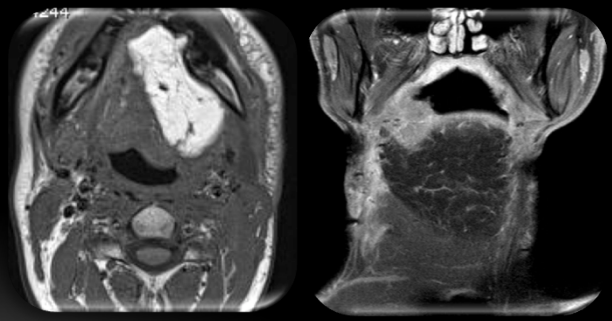

The image cannot be displayed. Your computer may not have enough memory to open the image, or the image may have been corrupted. Restart your computer, and then open the file again. If the red x still appears, you may have to delete the image and then insert it again.

US BEST FOR EVALUATING / BIOPSY NECK NODES

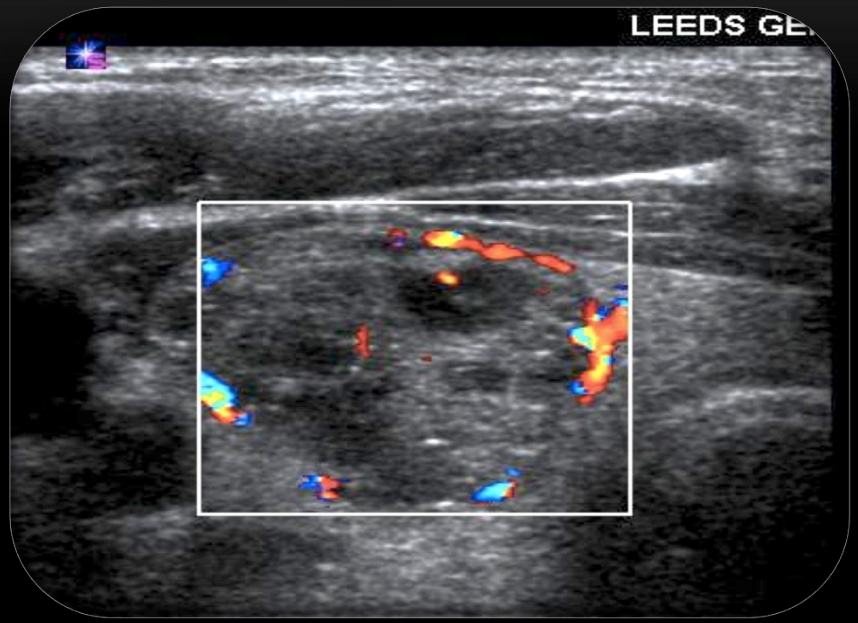

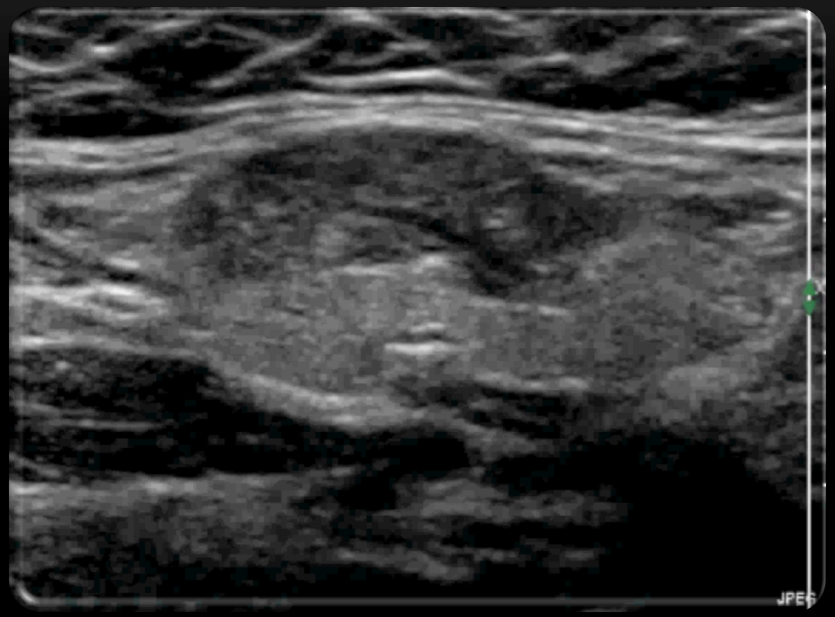

ANATOMY - NASOPHARYNX

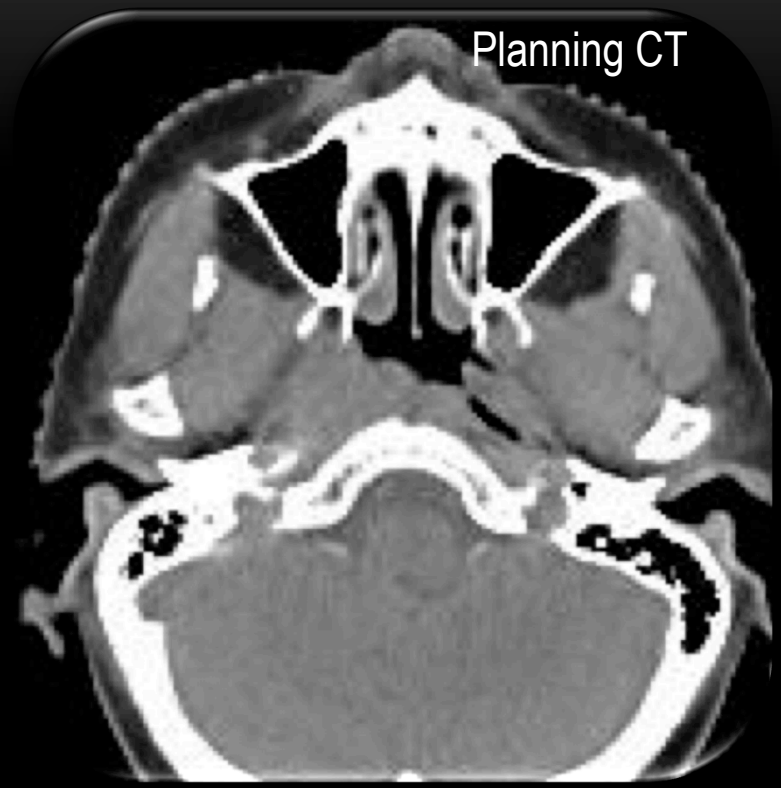

Fossa of Rosenmuller

ANATOMY - CA NASOPHARYNX

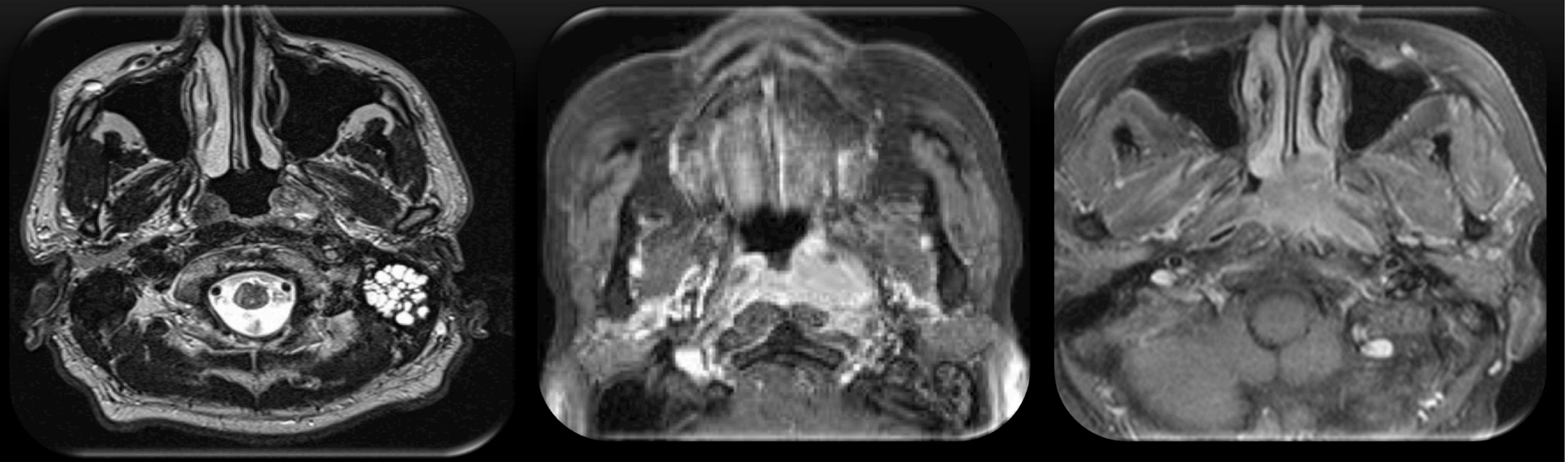

Arise on mucosal surface of Fossa of Rosenmuller
Lymph node involvement is bilateral in 30%
Skull base involvement is common (30%)

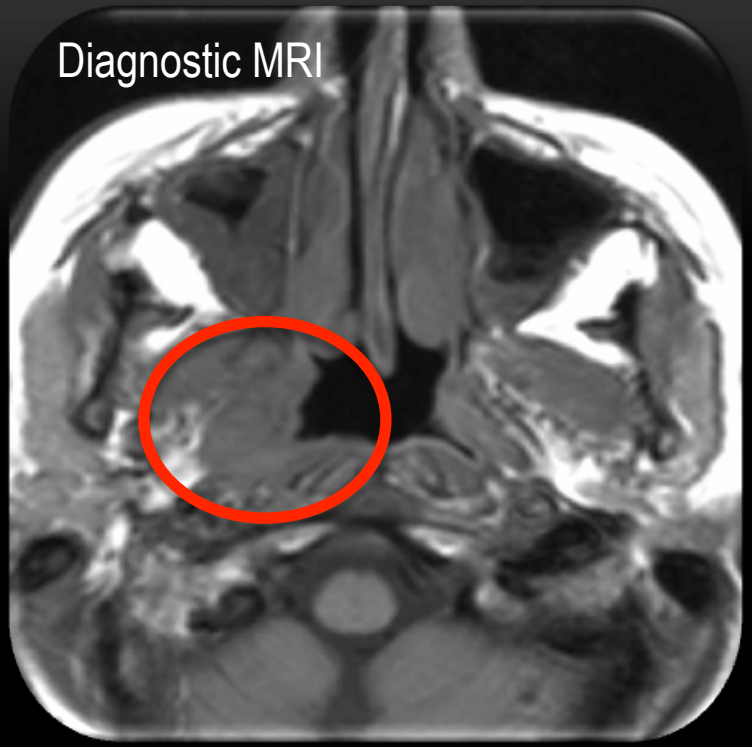

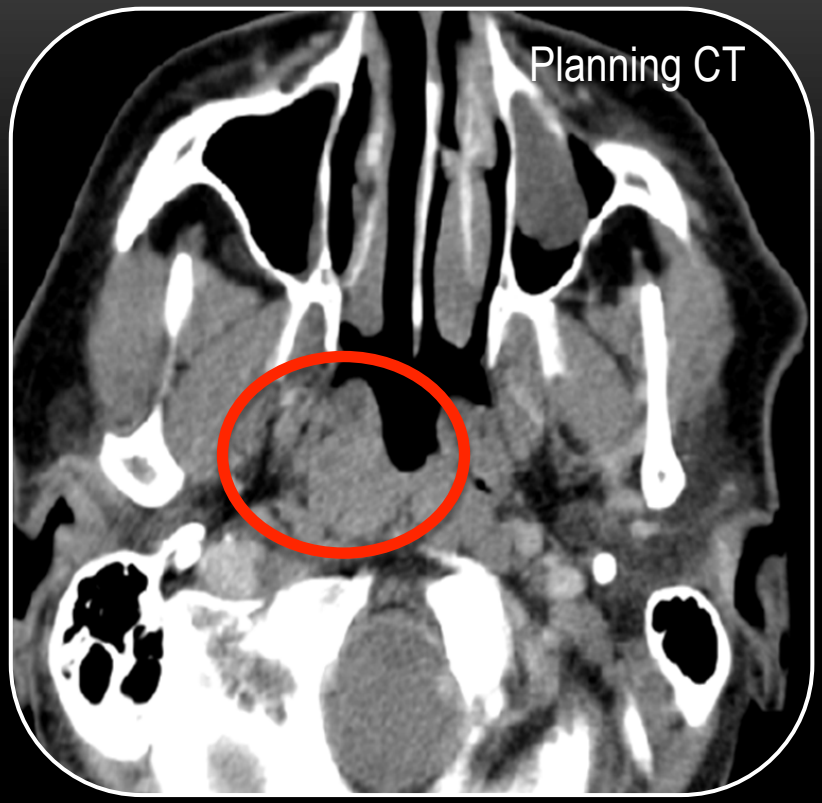

Early Ca Right Nasopharynx

MRI to define Soft Tissue GTV

Perineural Spread

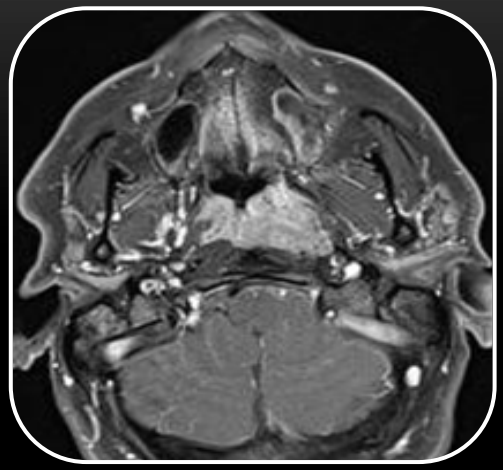

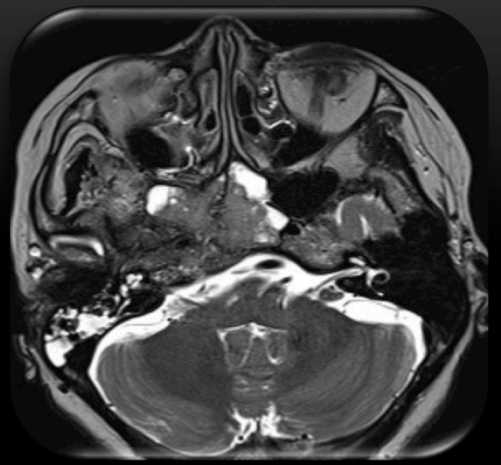

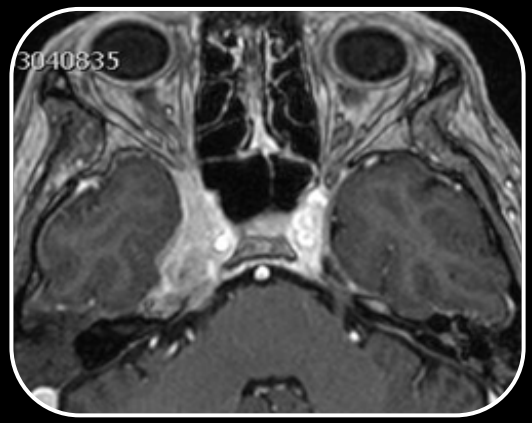

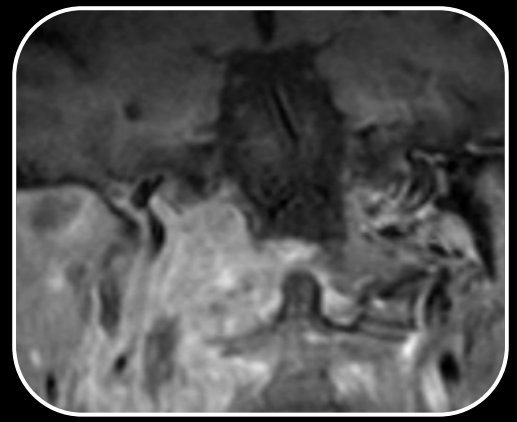

Bony Spread better seen with CT

NASOPHARYNGEAL TUMOURS : IMPORTANT ANATOMY

Confluent involvement with retropharyngeal nodes

Inferior submucosal spread to oropharynx

Know where the parapharyngeal space is !

Know where the pterygopalatine fossa is !

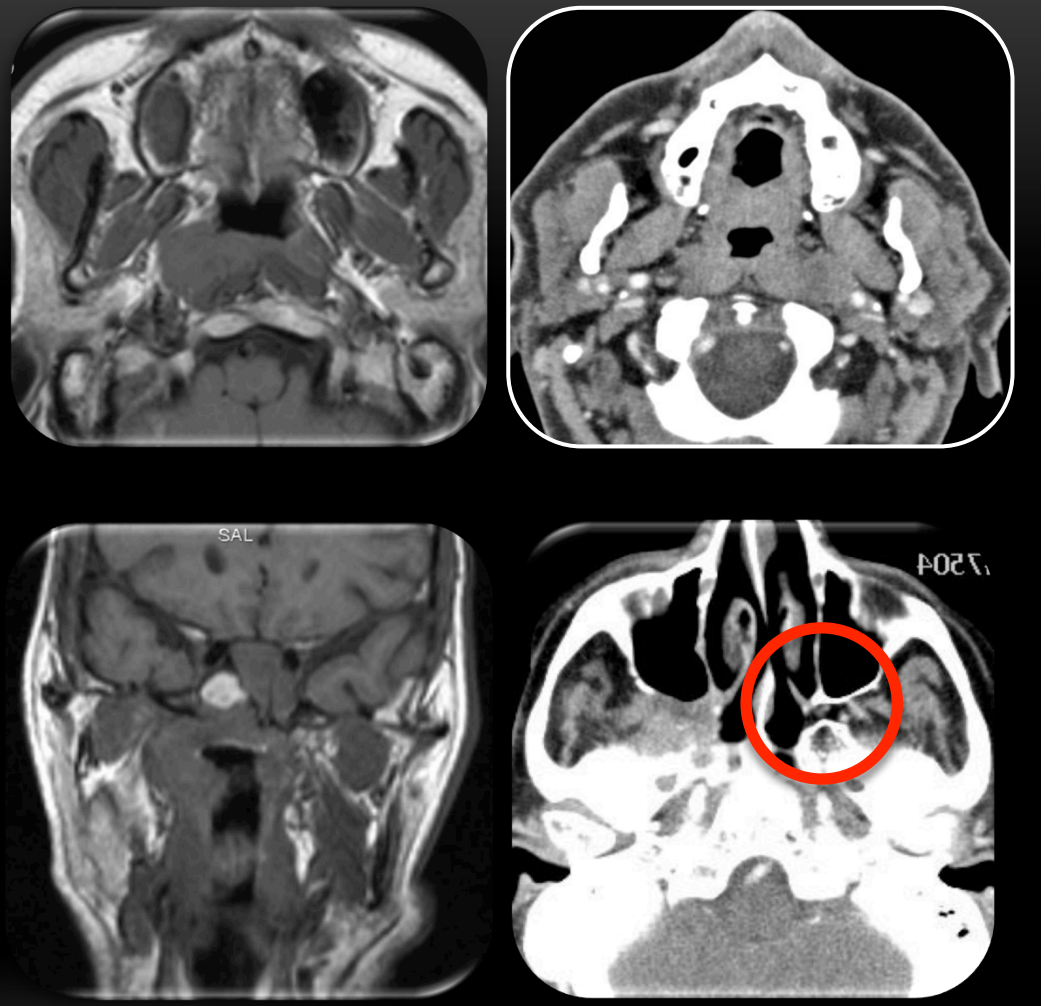

Anatomy - ORAL CAVITY

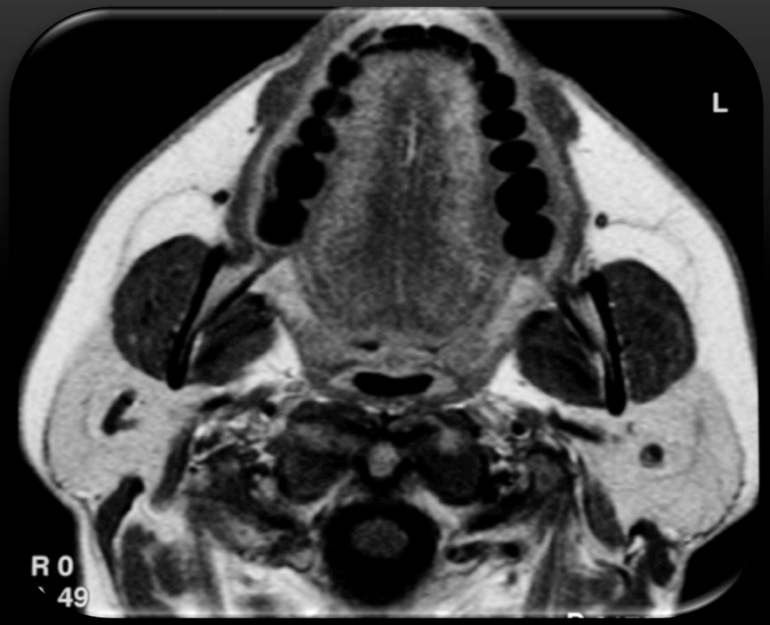

MRI IS THE BEST IMAGING FOR EVALUATION OF ORAL CAVITY TUMOURS

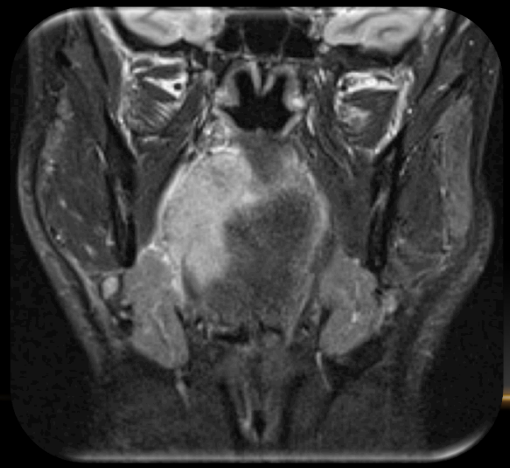

TONGUE CA

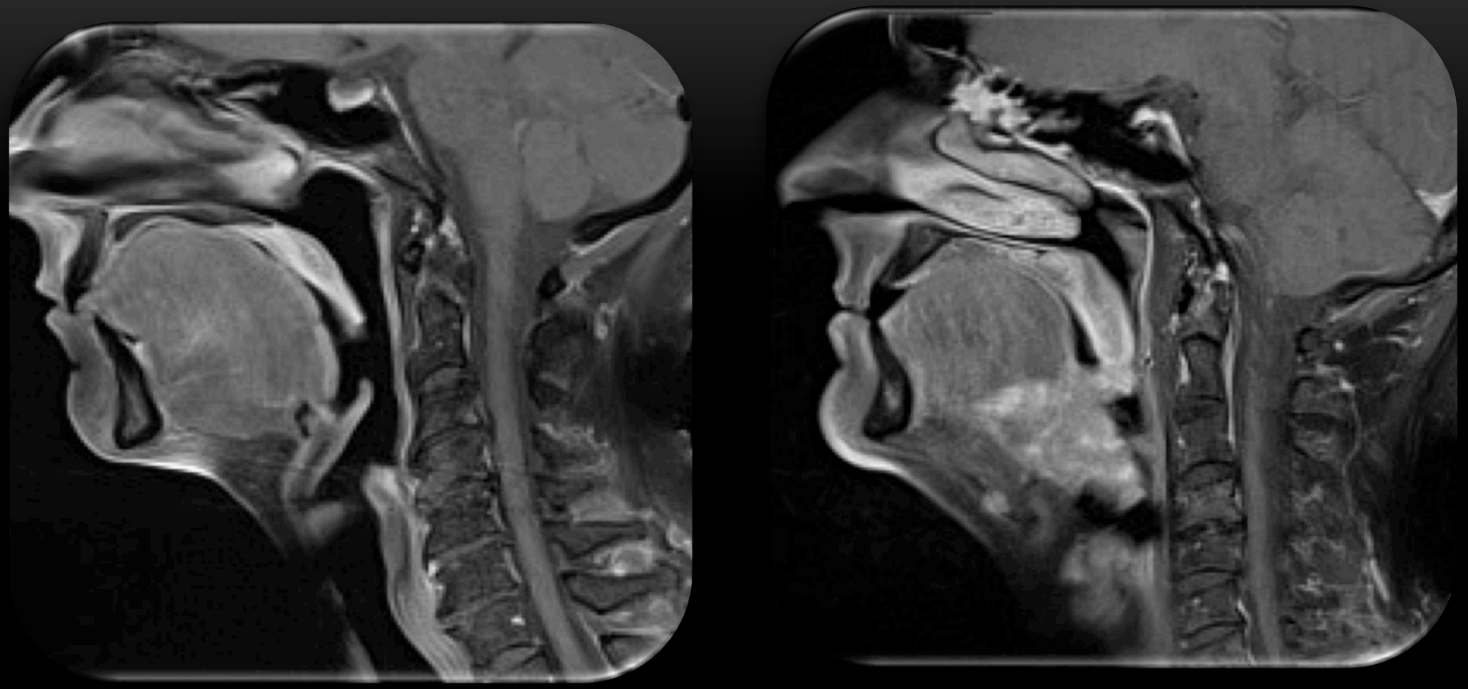

MRI best imaging for assessing midline spread

Tongue base tumours often clinically silent and spread with deep infiltration.

TONGUE CA

FLOOR OF MOUTH CA

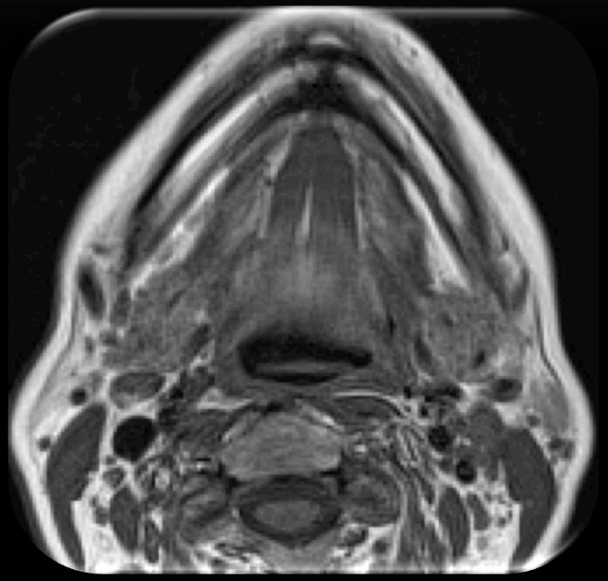

NORMAL

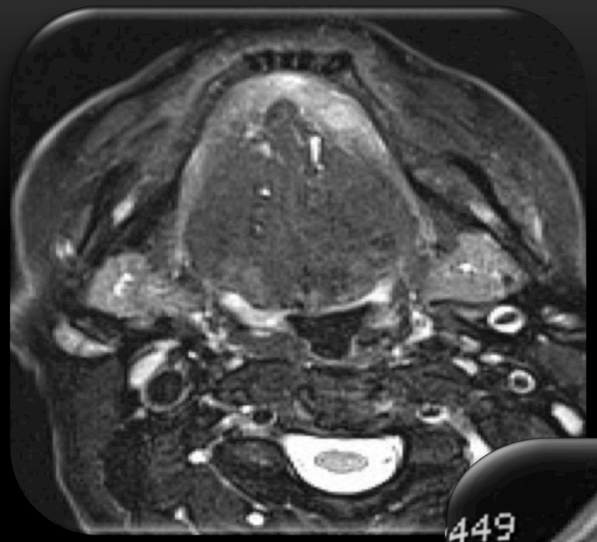

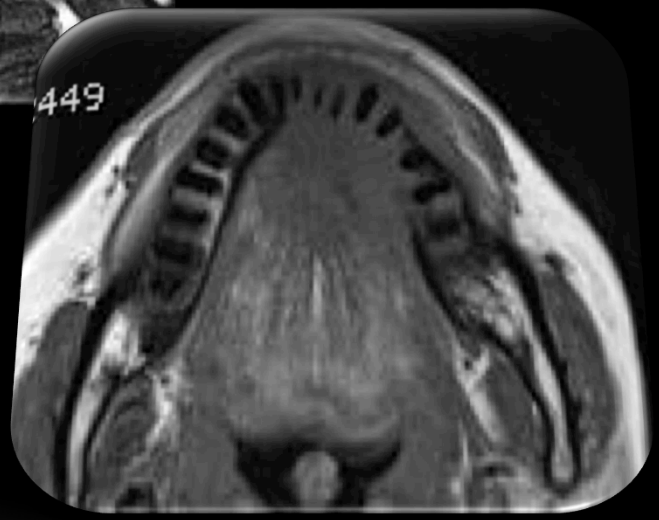

LARYNX

The larynx extends from the tip of epiglottis to the inferior margin of the cricoid cartilage.

3 anatomical compartments

- ***Supraglottis***
- ***Glottis***
- ***Subglottis***

ANATOMY – LARYNX CANCER

The imaging appearance of these cartilages depends on whether or not they are ossified. The epiglottis and the vocal process of arytenoids are fibrocartilages that do not ossify.

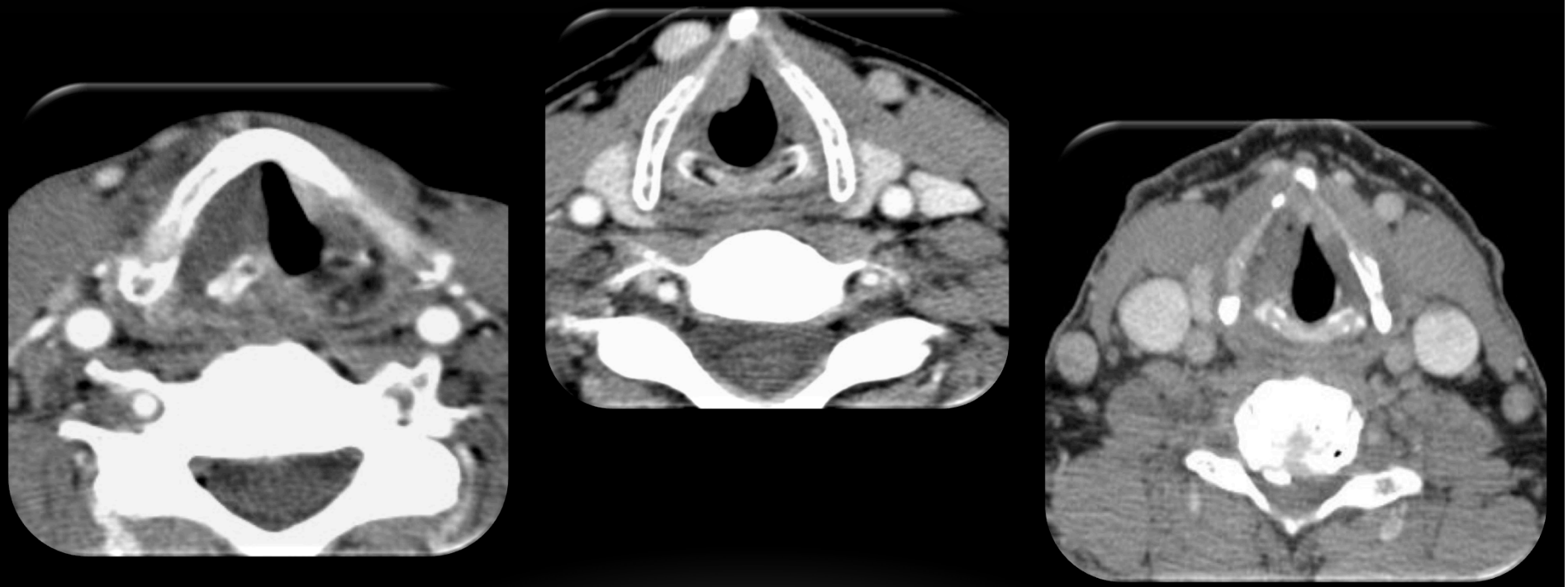

SUPRAGLOTTIC CANCER

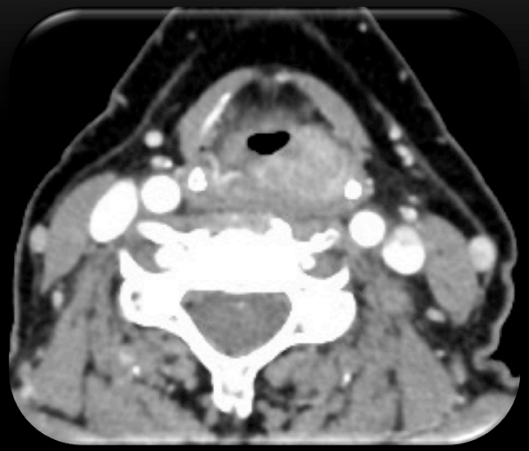
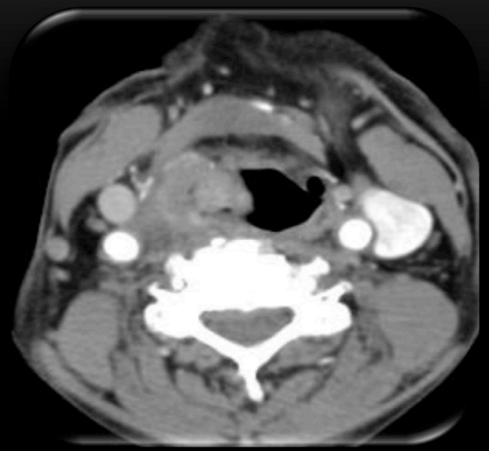
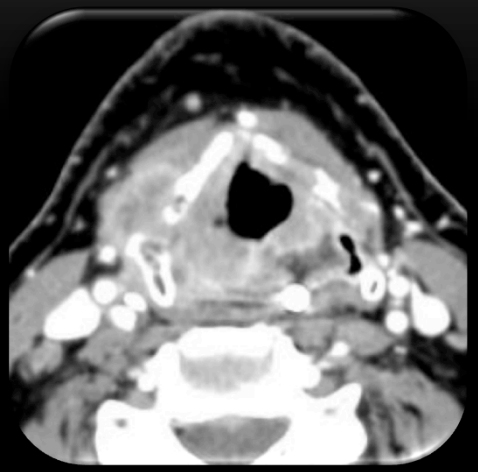
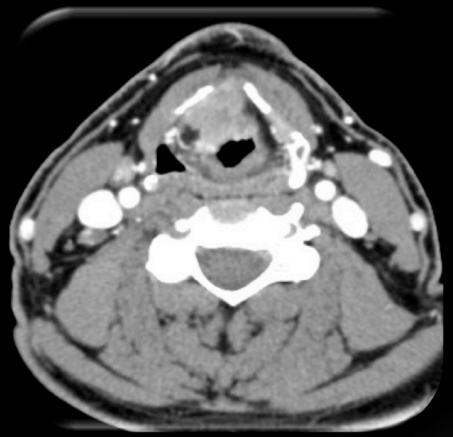

- Approximately 30% of all laryngeal cancers arise in the supraglottis.
- They often present in advanced stages.
- Due to the rich lymphatic network of the supraglottis, nodal disease (levels II and III) is a frequent finding in these patients.

LARYNGEAL TUMOURS – SUPRAGLOTTIC EXTENSION

MRI superior to CT for assessment of base of tongue

SALIVARY GLAND ANATOMY

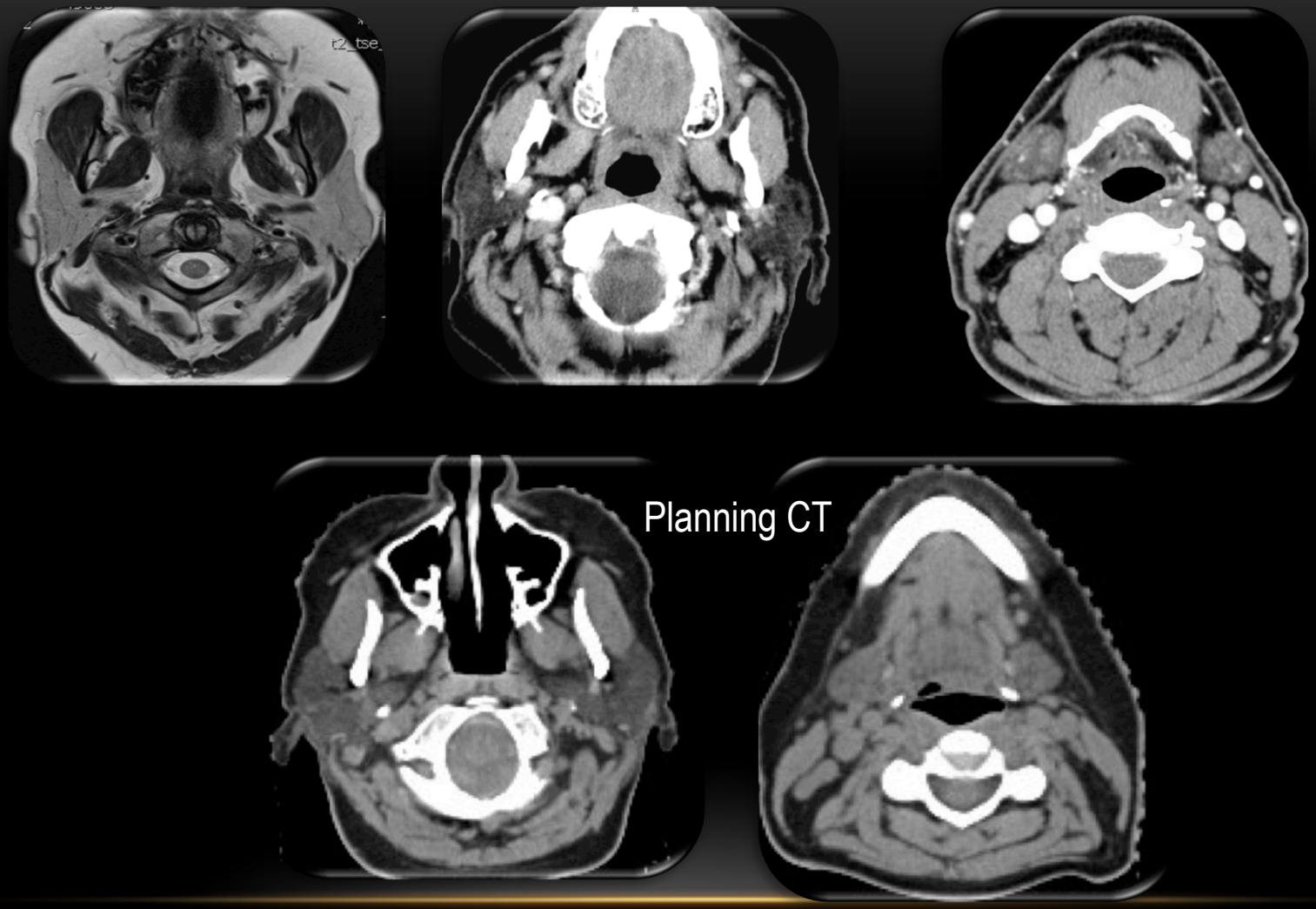

ANATOMY LOCATION IN PAROTID GLAND

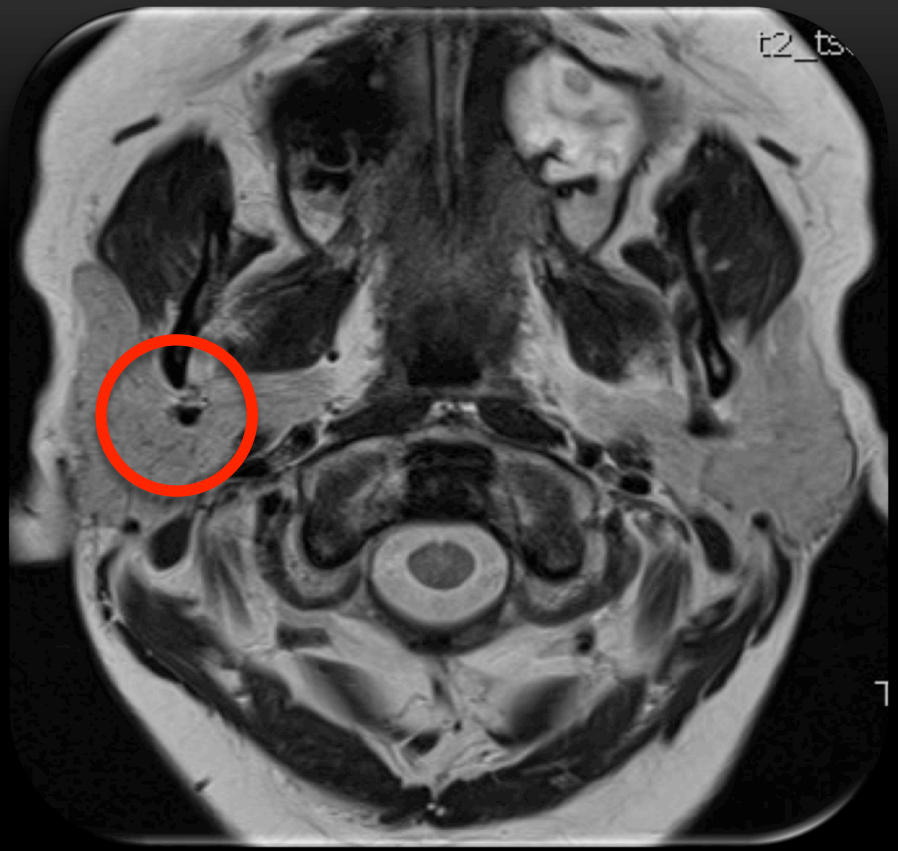

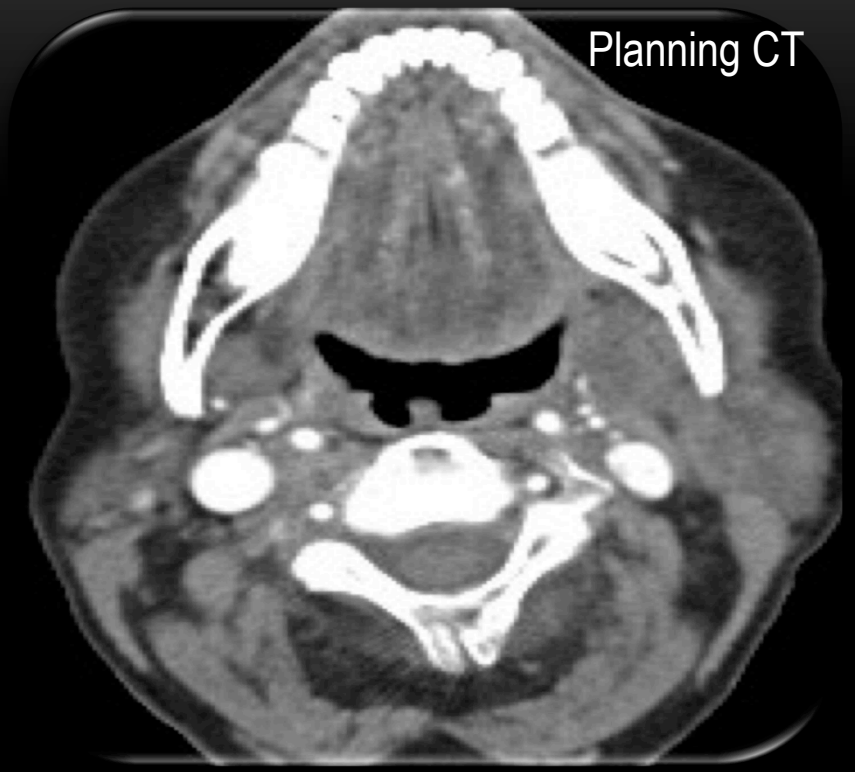

Use Retromandibular vein as Reference landmark

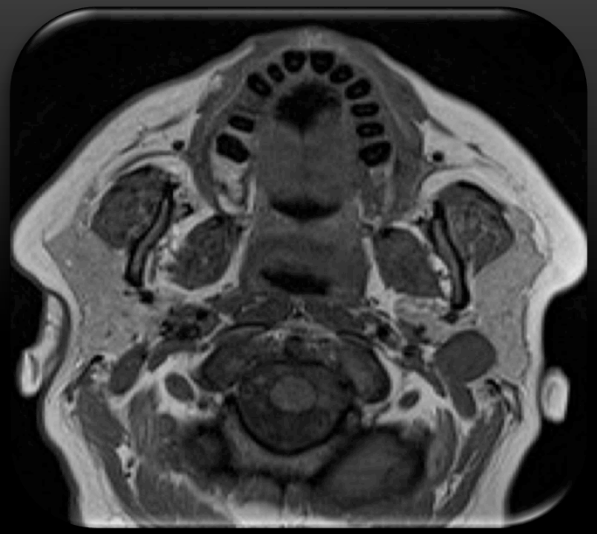

Superficial Lobe PSA
(left)

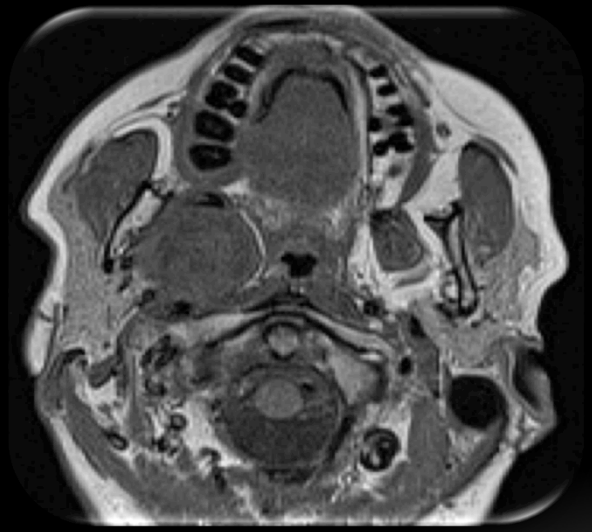

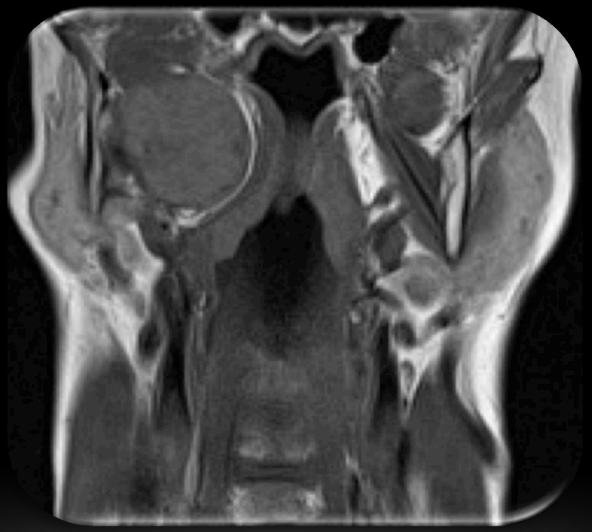

Deepl Lobe PSA
(right)

ACCESSORY PAROTID LOBE

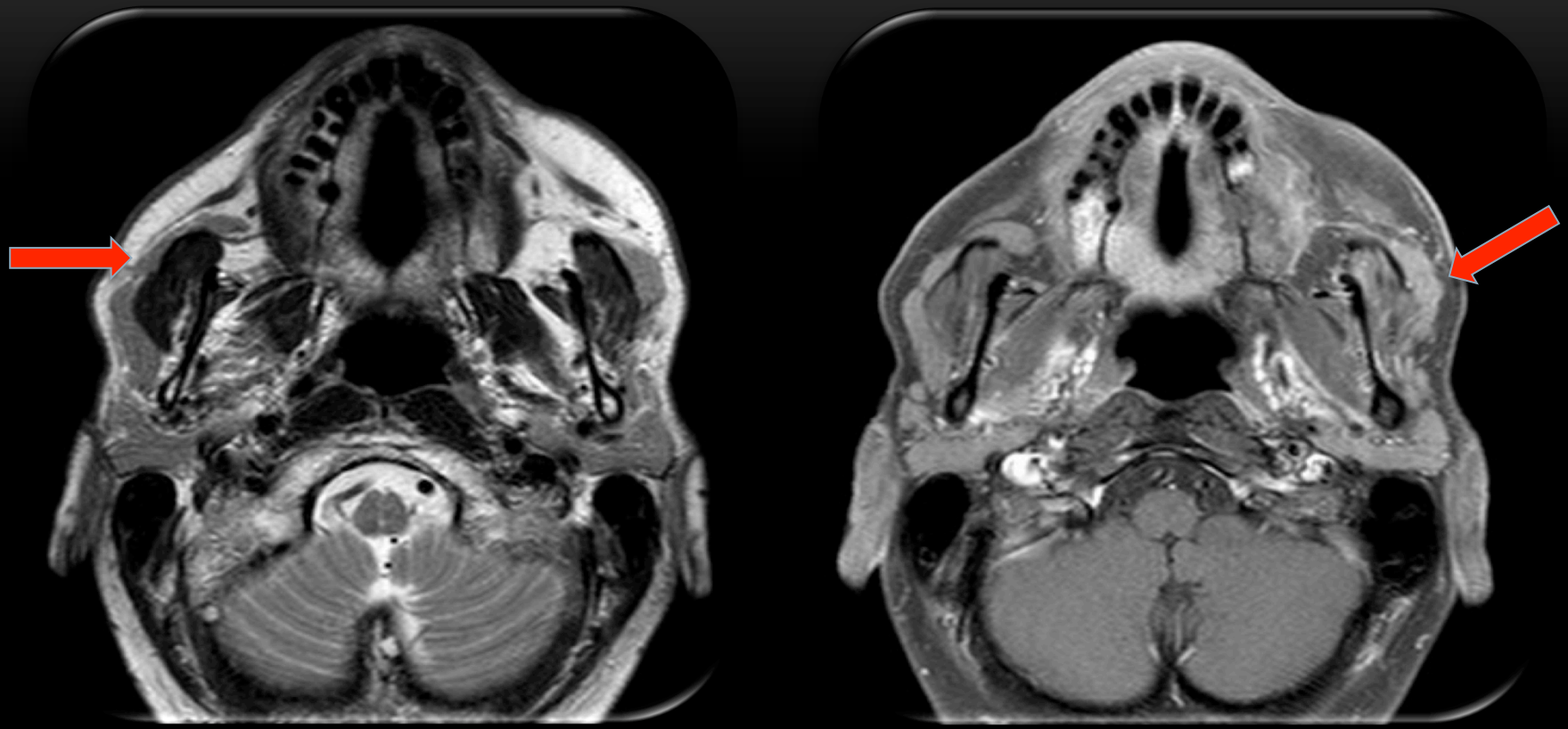

THE (FEARED..) PARAPHARYNGEAL SPACE !

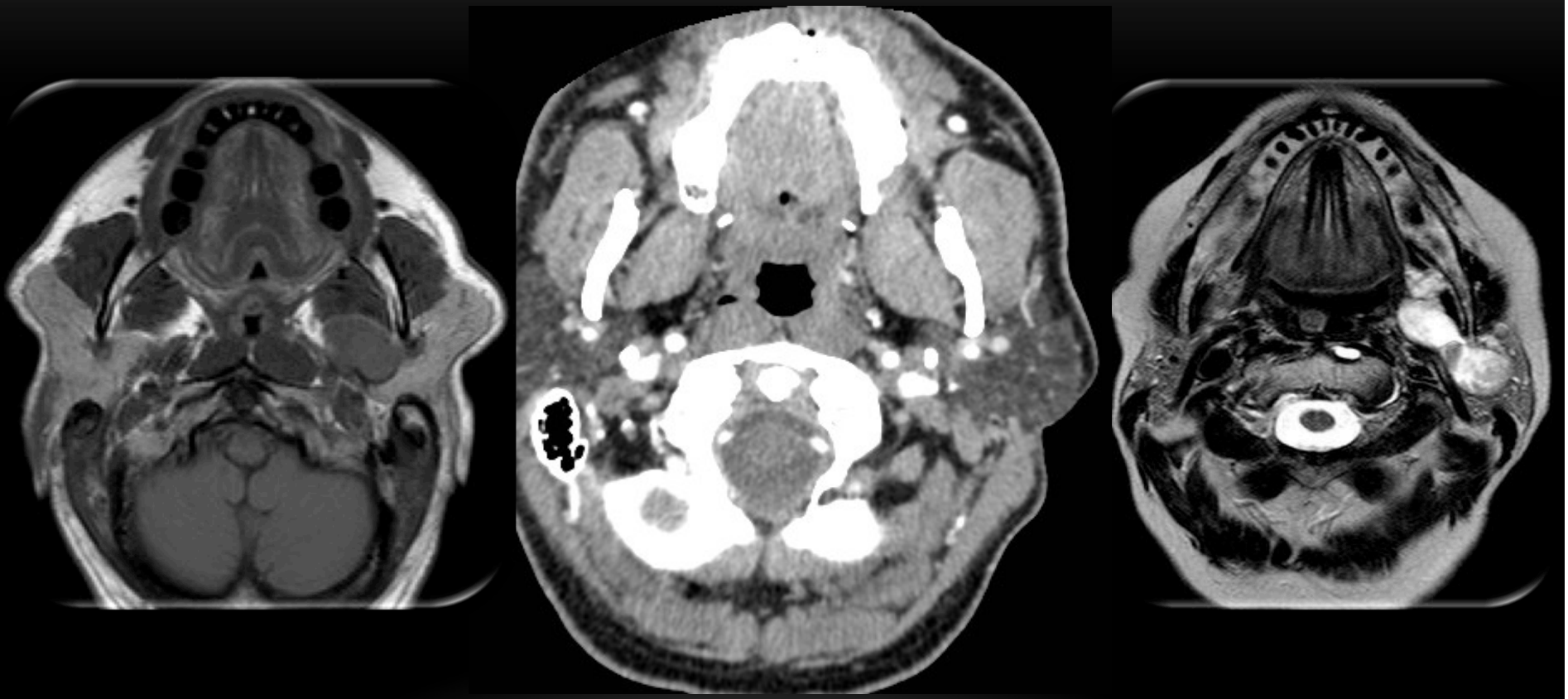

ANATOMY - NECK LYMPH NODES

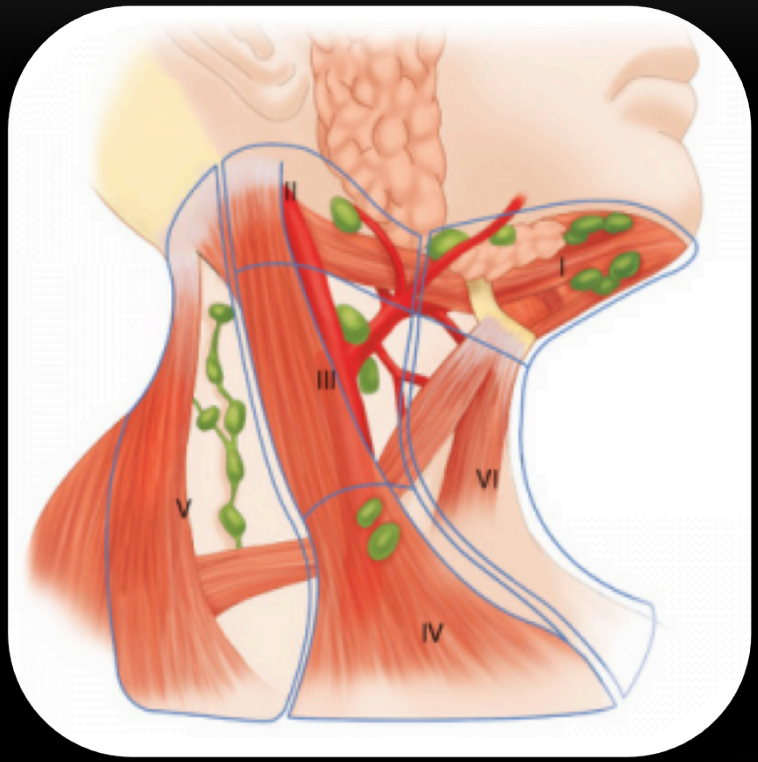

NODES – LOOK IN THE RIGHT PLACE!

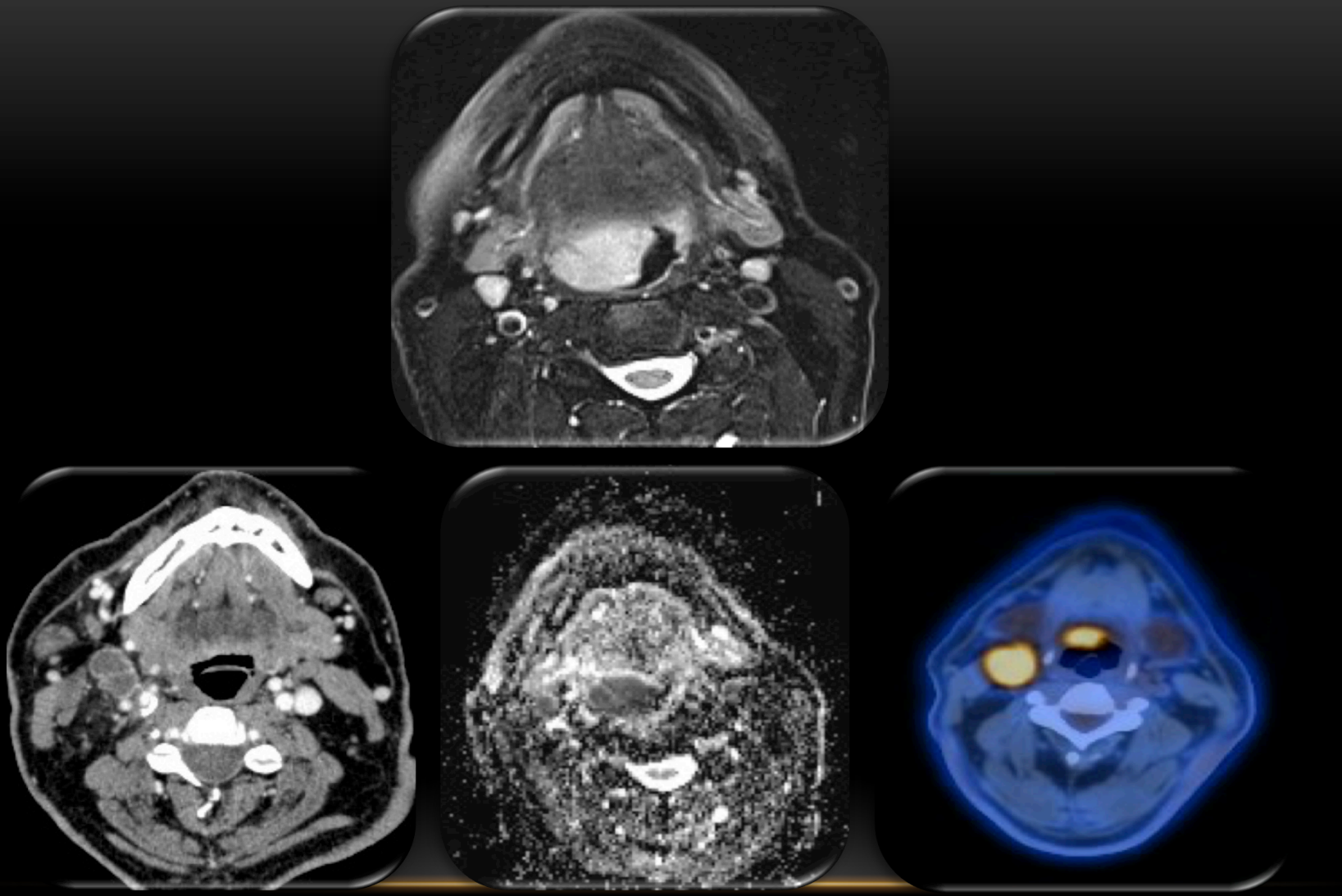

..e g Base Tongue Ca = Level 2 nodes

ANATOMY- NECK NODES

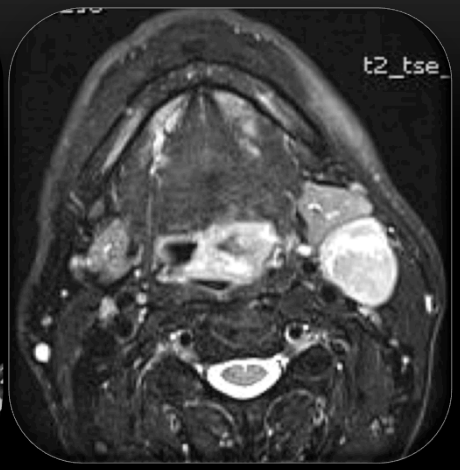

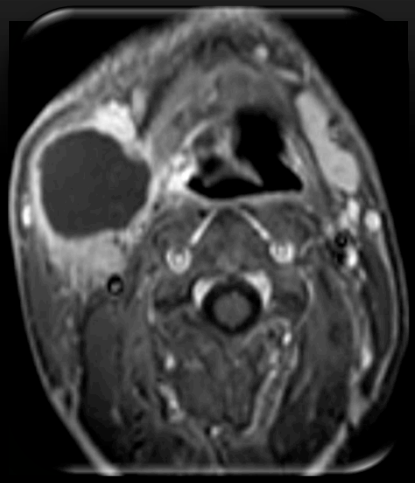

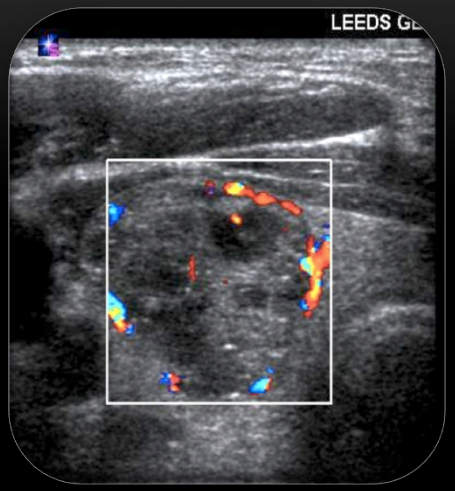

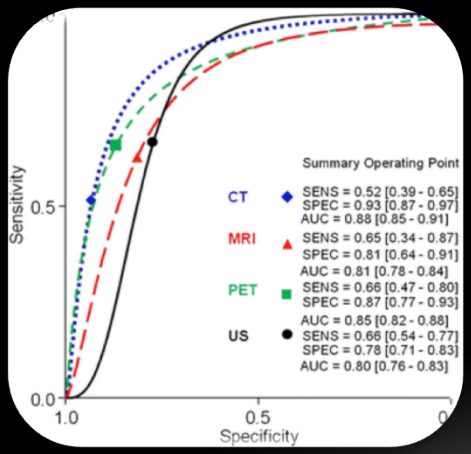

The performance of different imaging modalities shown with summary receiver operating characteristic curves. Liao *BMC Cancer* 2012

No particular advantages to CT v MRI for neck node evaluation
Use whatever imaging you are using for Primary tumour

CT AND MR SIGNS OF NODAL MALIGNANCY

- Larger than 9mm(approx)
- Rounded
- Central necrosis
- Irregular outline

RETRO-PHARYNGEAL NODES

Lie within retropharyngeal space from skull base to upper border of hyoid

- Situated between the Carotid Artery and Prevertebral muscle

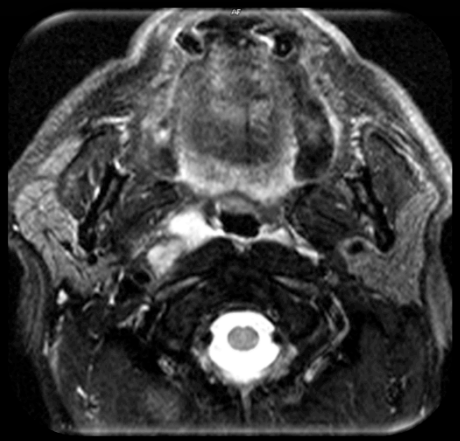

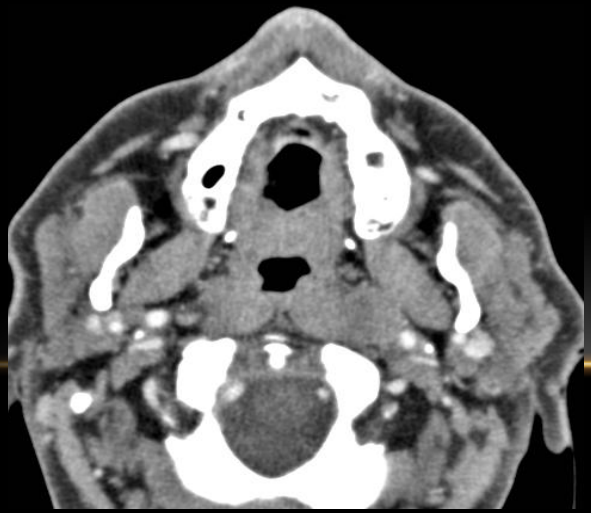

Planning CT

Multi-modality Imaging for Head & Neck
Different imaging may show different aspects of the same anatomy

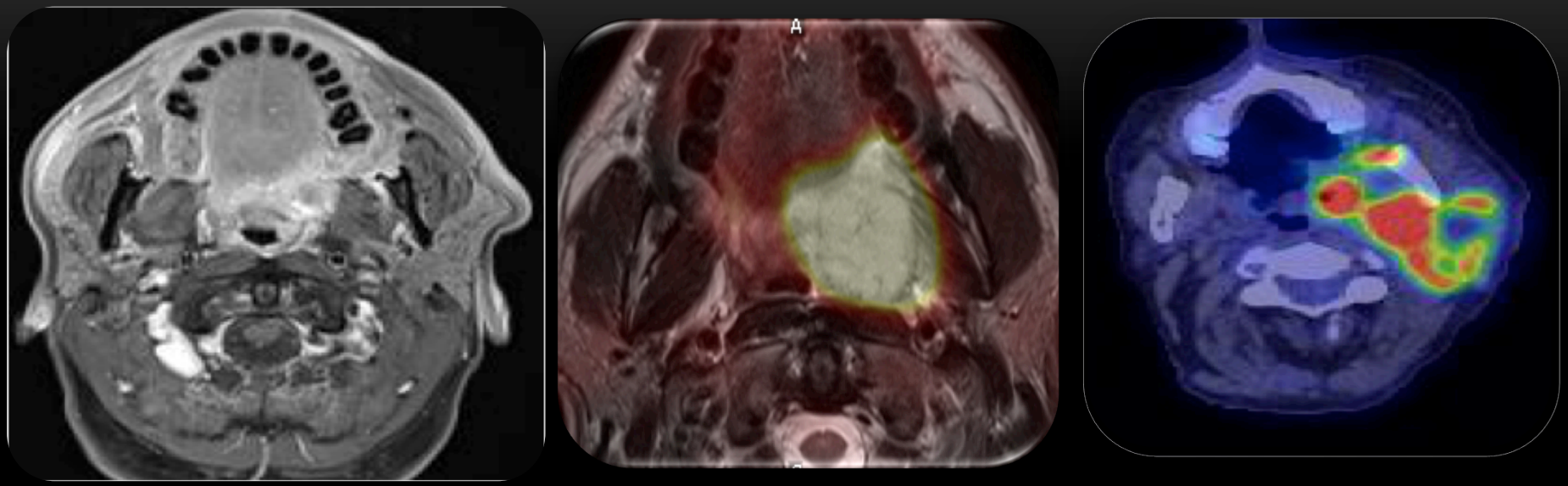

It is possible that the abnormal areas do not co-localise anatomically on the different imaging techniques

Tumour not a biologically homogenous mass of abnormal tissue

Different molecular and biological processes expressing different functional footprints

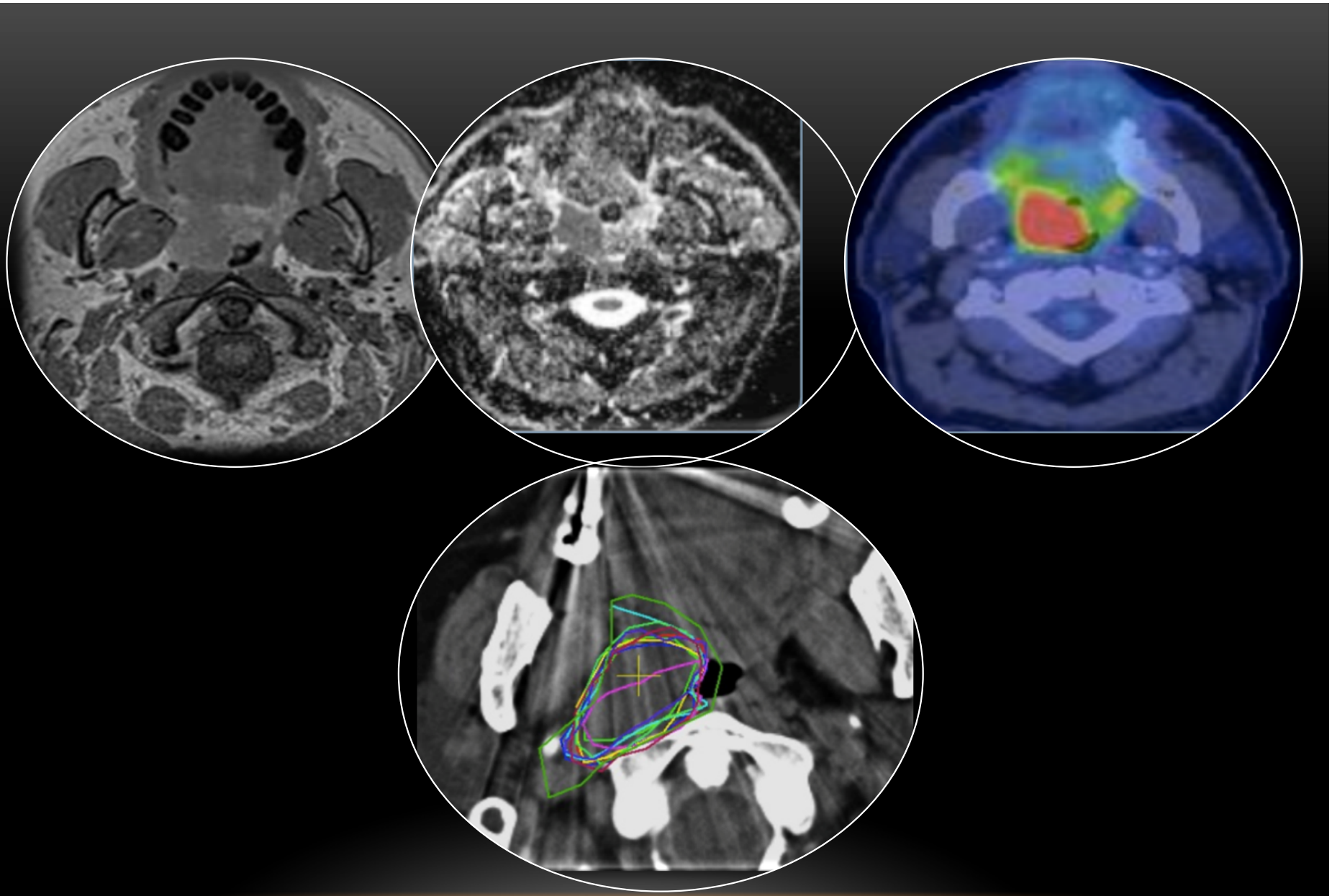

Same tumour – different imaging – “different GTV”

May be no visible residual GTV
-interpolate the original tumour anatomy

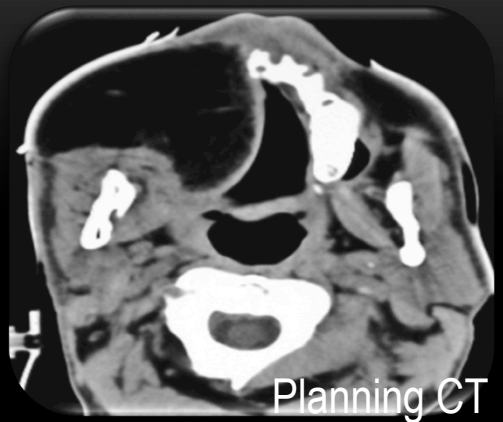

surgery + flap reconstruction

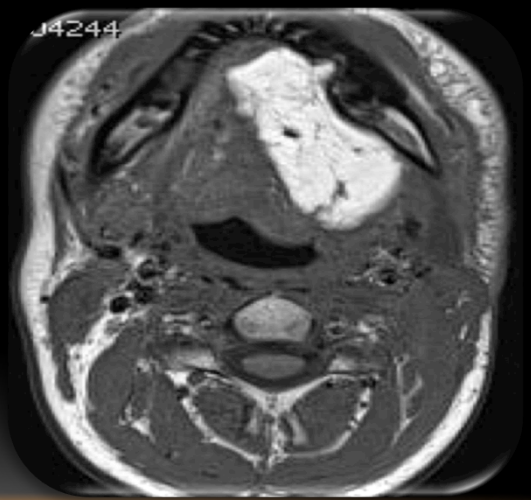

OAR – KNOW ANATOMY!

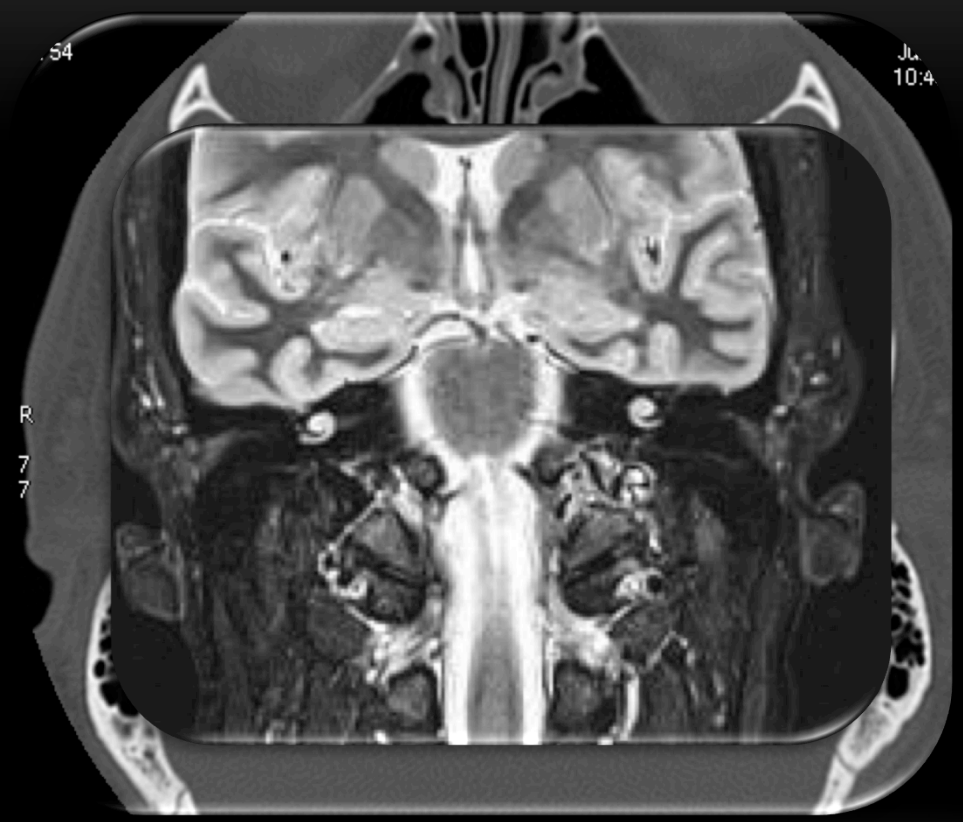

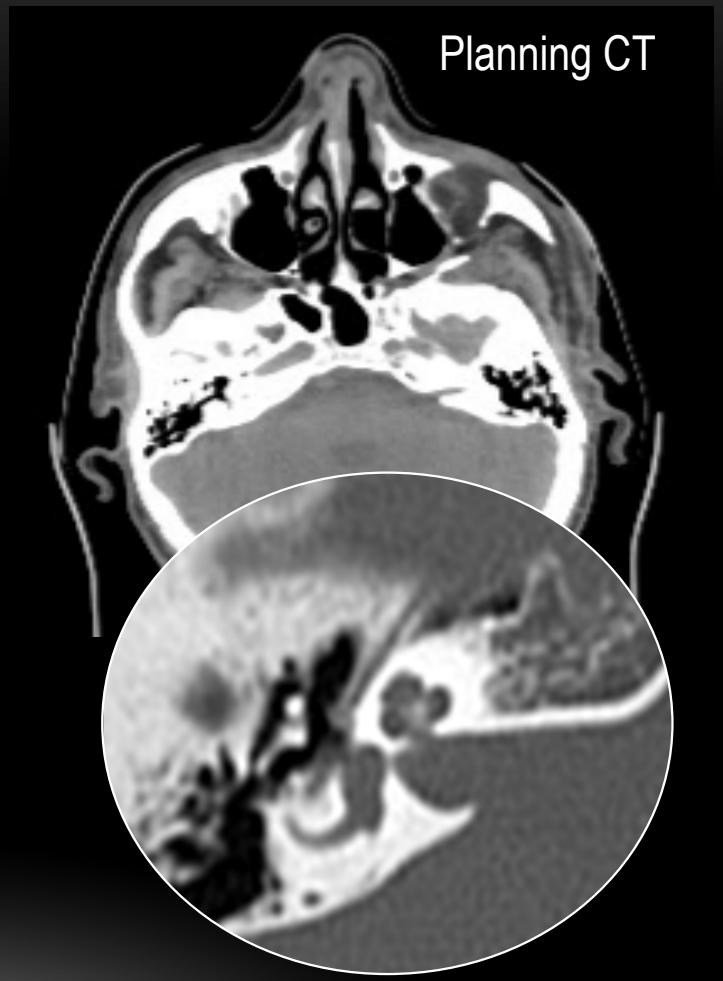



The Clinical Target Volume of elective neck in head-and-neck cancer

ESTRO Teaching Course
"Target Volume Determination: from Imaging to Margins"

Budapest, Hungary, October 6th, 2015

Indira Madani, M.D., Ph.D.

Nothing to disclose

Questions

1. What is elective neck in head-and-neck cancer?
2. Do we need to treat the neck electively?
3. How do we define the CTV of elective neck?
4. How do we delineate the CTV of elective neck?
5. What are results of elective neck irradation?
6. Can we improve the results of elective neck irradiation?

What is correct?

a. **ELECTIVE NECK** irradiation

b. Elective **NECK IRRADIATION**

c. **ELECTIVE** neck **IRRADIATION**

Definition of “elective”

http://dictionary.cambridge.org/dictionary/british/elective

e·lec·tive /ɪˈlek.tɪv/

- Voted for or chosen:

  elective surgery
  elective irradiation

Correct answer: **ELECTIVE** neck/nodal **IRRADIATION**

Elective neck in head-and-neck cancer

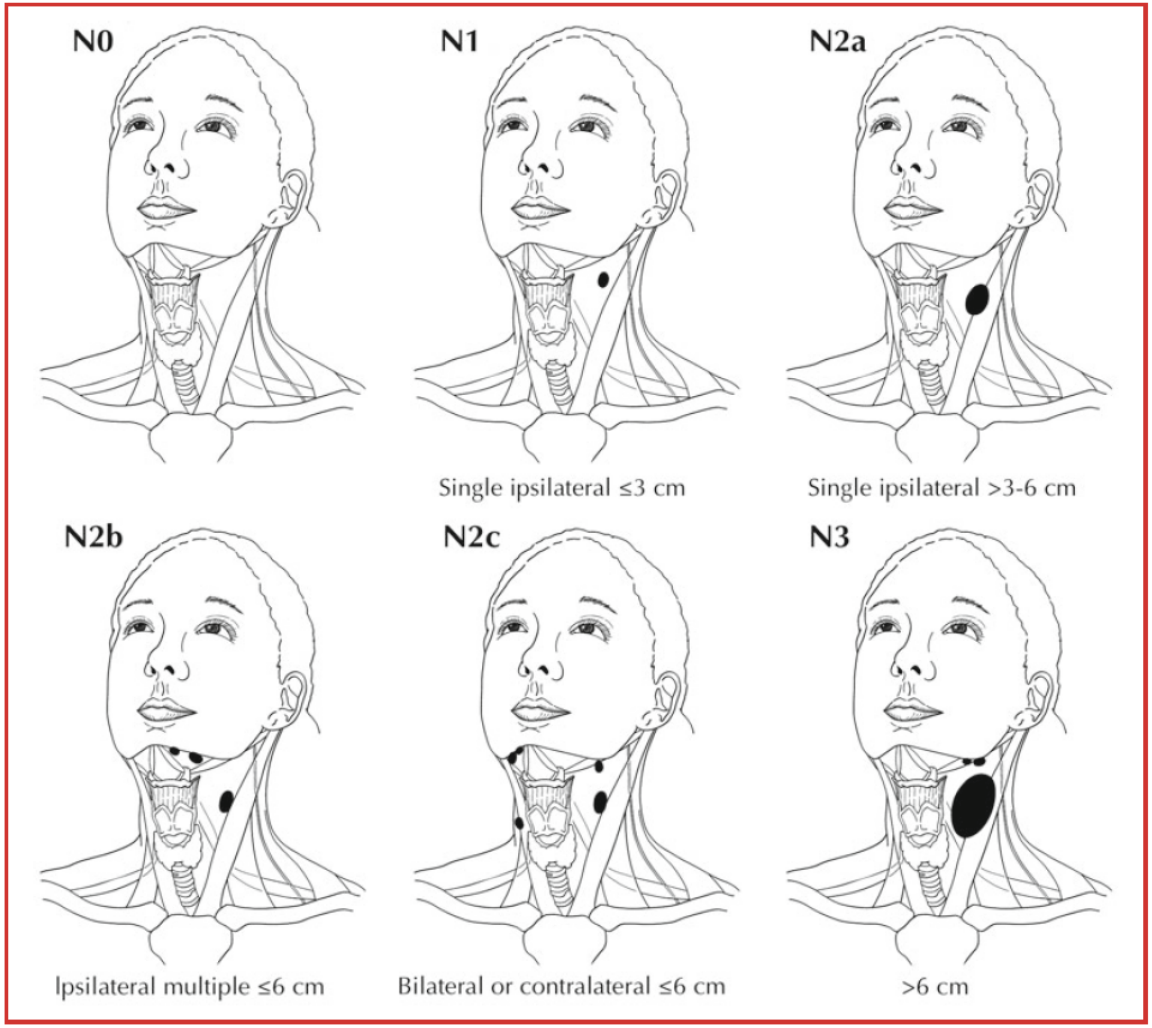

AJCC Cancer Staging Atlas: A Companion to the Seventh Editions of the AJCC Cancer Staging Manual and Handbook. 2012.

Incidence of cN0 disease in head-and-neck cancer

Tumor site	cN0	cN0 but pN+	N0 > N+ with no neck treatment
Oral cavity	35-70%	19-54%	17-52%
Oropharynx	17-63%	22%	16-25%
Hypopharynx	28-48%	38%	No data
Larynx: supraglottis	46-69%	16-26%	33%
Nasopharynx	10-14%	No data	19-50%

Larynx: T1-T2 glottis > 90%
Sinonasal > 90%

Mendenhall et al. *Head Neck Surg* 1980; 3:15-20.

Risks of cN0 disease

Tumor site	cN0	cN0, pN+	N0 > N+ with no neck treatment
Oral cavity	35-70%	19-54%	17-52%
Oropharynx	17-63%	22%	16-25%
Hypopharynx	28-48%	38%	No data
Larynx: supraglottis	46-69%	16-26%	33%
Nasopharynx	10-14%	No data	19-50%

ELECTIVE NECK IRRADIATION

#1: risk of occult metastases

#2: risk of regional failure

Mendenhall et al. *Head Neck Surg* 1980; 3:15-20.

Threshold for elective neck treatment of cN0 neck

A patient with primary squamous cell carcinoma of the head and neck and stage N0 neck status should be observed if the probability of occult cervical metastasis is less than 20%. If the probability is greater than 20%, treatment of the neck is warranted.

It has been proposed from decision analysis trees that a treatment of the N0 neck is warranted if the probability of occult cervical metastasis is higher than 20% [63]. This is a very high figure that is likely not to be adopted in the majority of the European centers, which would probably treat the neck when the probability of occult metastasis is higher than 5–10%.

Weiss, Harrison, Isaacs. *Arch Otolaryngol Head Neck Surg* 1994;120:699–702.
Gregoire et al. Radiat Oncol 2000;56;135-50.

Nomenclature of cervical lymph nodes

- Anatomical (nodal groups):

  Rouviere H. Lymphatic System of the Head and Neck. In: Rouvier H, editor. Anatomy of the human lymphatic system. 1st edn. Ann Arbor, MI: Edwards Brothers, 1938.

- Surgical (node levels):

  Shah et al. *Clin Bull* 1981;11:25-33.

- Radiological (imaging):

  Som et al. *Arch Otolaryngol Head Neck Surg* 1999;125:388-96.

Nodal groups of the extracranial head and neck

important for head-and-neck cancer (Appendix 1)

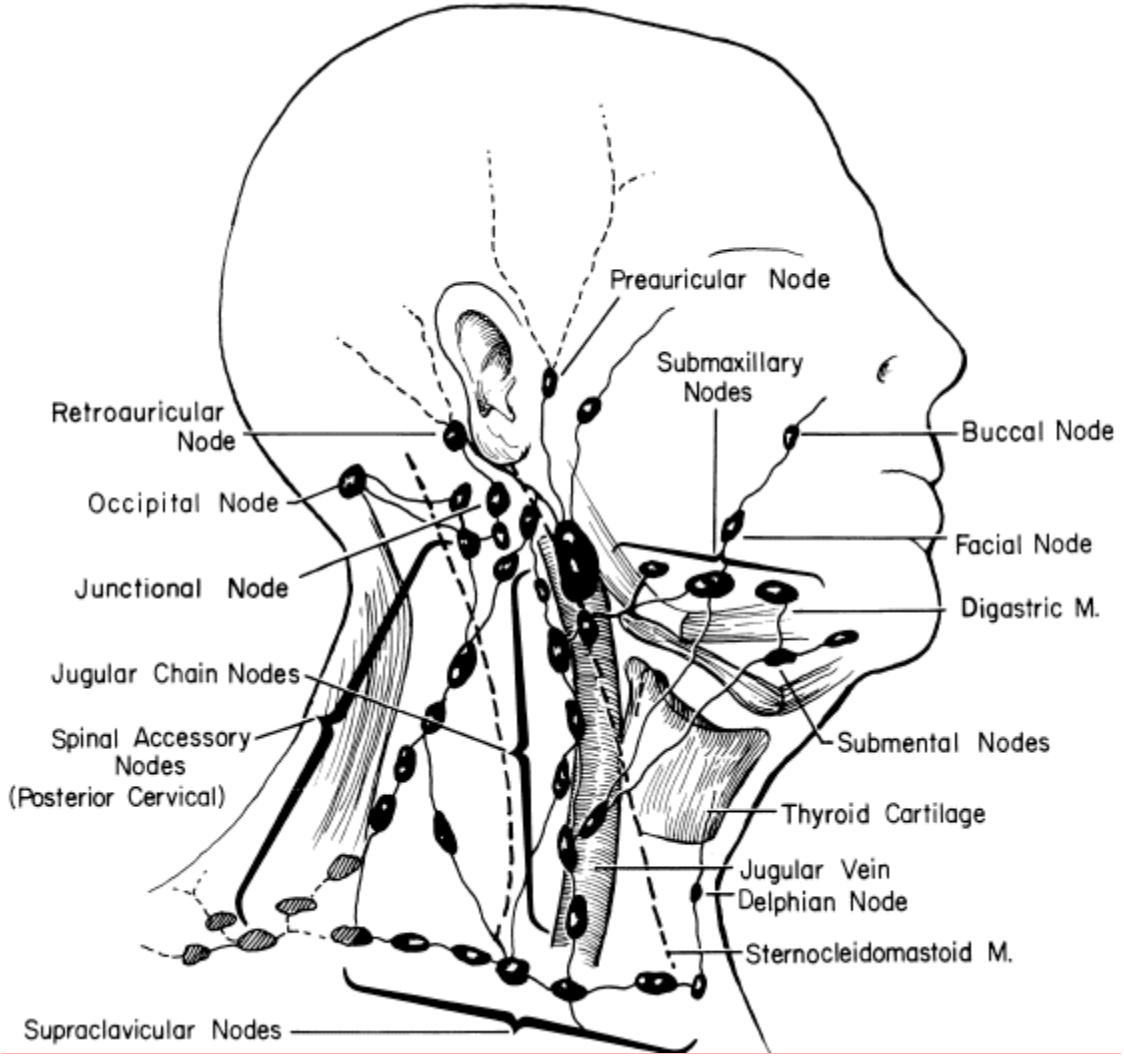

Nodal groups of the extracranial head-and-neck

1. Deep lateral cervical group
2. Anterior cervical group
3. Submental-submandibular group
4. Parotid group
5. Retropharyngeal group

Sublingual, mastoid, occipital, facial groups

Nodal groups of the extracranial head-and-neck

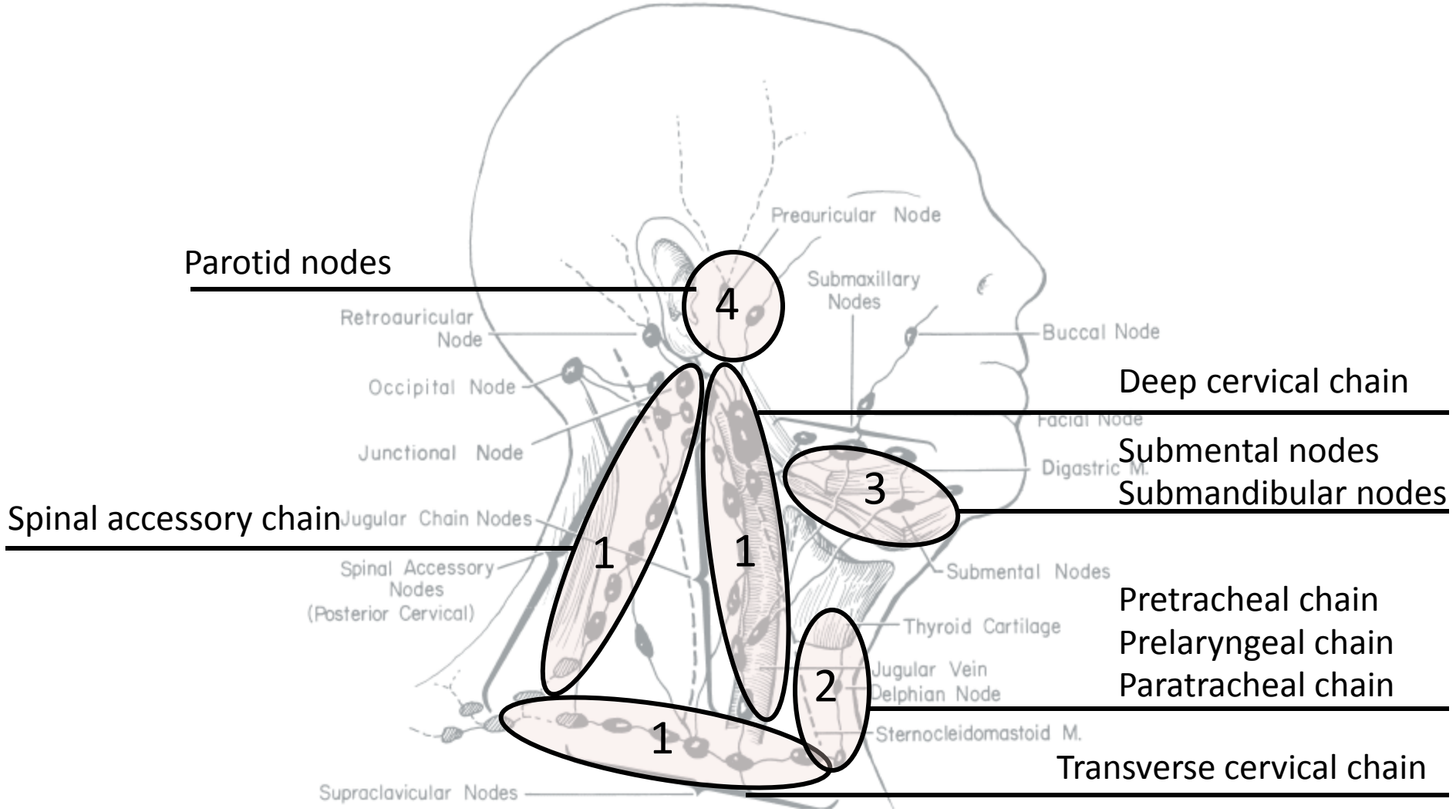

Cervical lymph nodes by level

used for neck dissection (Appendix 2)

Level	Lymph nodes	Nodal group
Level Ia	Submental nodes	Submental-submandibular
Level Ib	Submandibular nodes	
Level II	High deep cervical chain nodes	Deep lateral cervical
Level III	Middle deep cervical chain nodes	
Level IV	Low deep cervical chain nodes	
Level V	Spinal accessory chain nodes	
	Transverse cervical chain nodes	
Level VI	Pretracheal nodes	Anterior cervical
	Prelaryngeal nodes	
	Paratracheal nodes	

Parotid and retropharyngeal nodal groups are not incorporated.

Shah et al. *Clin Bull* 1981;11:25-33.

Imaging of cervical lymph nodes: year 1981

SCC of the larynx (supraglottis)

SCC of the hypopharynx (piriform sinus)

Mancuso et al. *Am J Roentgenol* 1981;136:381-5.

Imaging cervical lymph nodes: radiological classification

- 7 node levels (I-VII) and retropharyngeal nodes.
- CT-based node level boundaries.
- Diagnosis.
- Surgery.
- Not for radiotherapy.

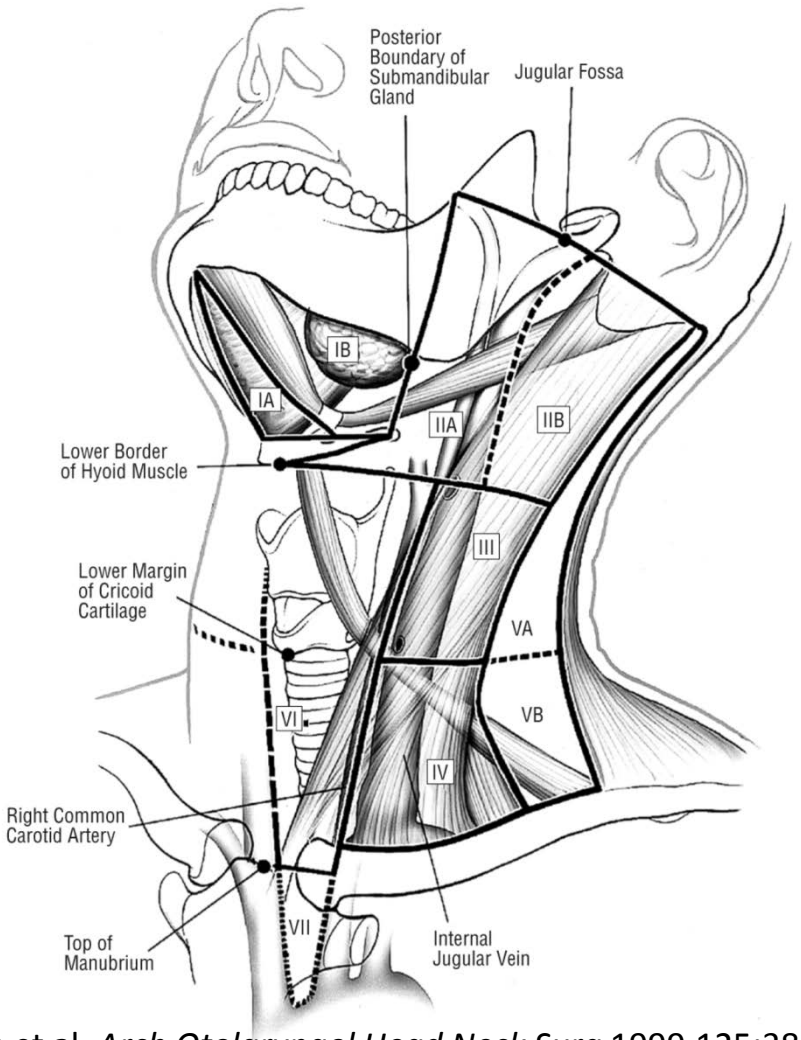

Som et al. *Arch Otolaryngol Head Neck Surg* 1999;125:388-96.

ELSEVIER

Radiotherapy and Oncology 69 (2003) 227–236

RADIOTHERAPY & ONCOLOGY
JOURNAL OF THE EUROPEAN SOCIETY FOR THERAPEUTIC RADIOLOGY AND ONCOLOGY

www.elsevier.com/locate/radonline

The CTV of the N0 neck

CT-based delineation of lymph node levels and related CTVs in the node-negative neck: DAHANCA, EORTC, GORTEC, NCIC, RTOG consensus guidelines

Vincent Grégoire[a,*,1], Peter Levendag[b,1], Kian K. Ang[c], Jacques Bernier[d], Marijel Braaksma[b], Volker Budach[e], Cliff Chao[c], Emmanuel Coche[f], Jay S. Cooper[c], Guy Cosnard[f], Avraham Eisbruch[c], Samy El-Sayed[g], Bahman Emami[c], Cai Grau[h], Marc Hamoir[i], Nancy Lee[c], Philippe Maingon[j], Karin Muller[b], Hervé Reychler[k]

[a]*Radiation Oncology Dept. and Laboratory of Radiobiology, Université Catholique de Louvain, St-Luc University Hospital, B-1200 Brussels, Belgium*
[b]*Radiation Oncology Dept., Erasmus Medical Center Daniel den Hoed Cancer Center, Rotterdam, The Netherlands*
[c]*Head and Neck group, RTOG, 1101 Market Street, 14th Floor, Philadelphia, PA 19107, USA*
[d]*Head and Neck group, EORTC, Avenue E. Mounier, 83/11, B-1200 Brussels, Belgium*
[e]*Radiotherapy group, EORTC, Avenue E. Mounier, 83/11, B-1200 Brussels, Belgium*
[f]*Radiology Dept., Université Catholique de Louvain, St-Luc University Hospital, B-1200 Brussels, Belgium*
[g]*Head and Neck DSG, NCIC-CTG, 10 Alcorn Avenue, Suite 200, Toronto, Ont., Canada, M4V 3B1*
[h]*DAHANCA, Norrebrogade 44, 8000 Aarhus C, Denmark*
[i]*Head and Neck Surgery Dept., Université Catholique de Louvain, St-Luc University Hospital, B-1200 Brussels, Belgium*
[j]*GORTEC, Rue C. Desmoulins, 39, 94805, Villejuif, France*
[h]*Maxillo-Facial Surgery Dept., Université Catholique de Louvain, St-Luc University Hospital, B-1200 Brussels, Belgium*

Received 4 July 2003; received in revised form 18 August 2003; accepted 12 September 2003

The CTV of N0 neck: 2003 guidelines (Appendix 3)

- 6 node levels (Ia, Ib, IIa, IIb, III-VI) and retropharyngeal nodes.
- CT-based boundaries of each node level as a part of the CTV.
- For conformal (3DCRT and/or IMRT) radiotherapy
- Not for diagnosis, surgery or prediction of nodal involvement.

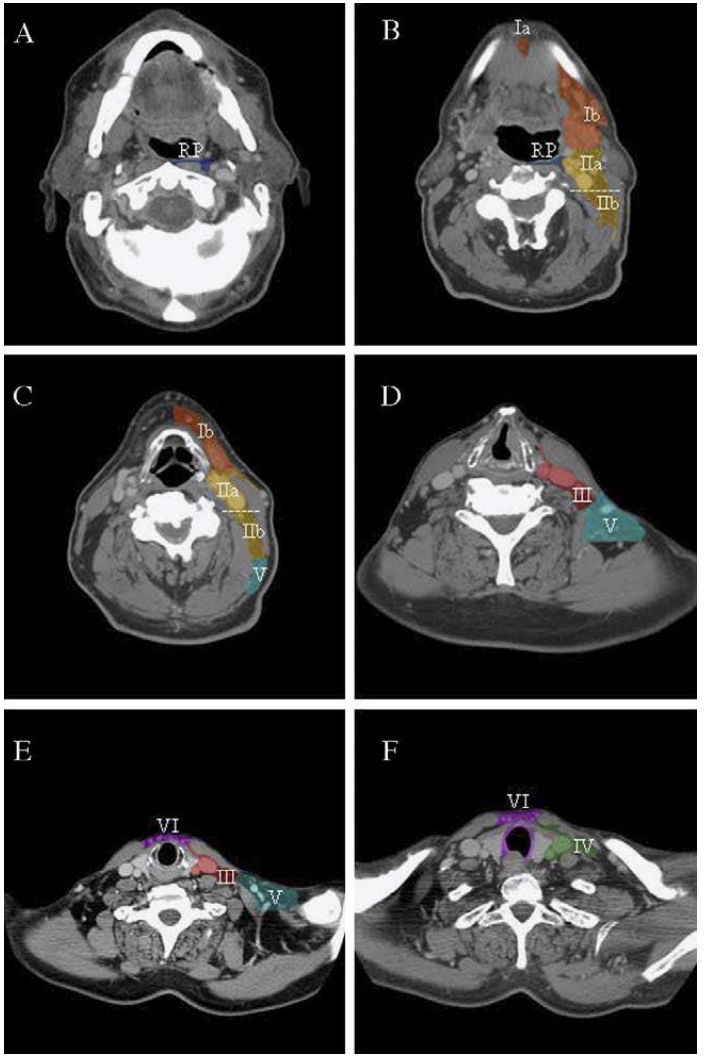

cN0 neck in head-and-neck cancer per node level [%]

Tumor site	Level I	Level II	Level III	Level IV	Level V	Others
Oral cavity	58/96.5*	21/92	82/97	95/99	99/0	98.6/99.7
Oropharynx	87/98	19/76	77/95	91/97.5	87/97	98/99
Hypopharynx	98/100	20/87	49/96	80/97	76/98	97/99
Larynx: Supraglottis	98/100	29/79	52/90	82/93	85/96	98/100
Nasopharynx	91/95	29/44	64/68	78/85	68/74	85/90

*ipsilateral/contralateral cervical lymph nodes

Gregoire et al. *Radiother Oncol* 2000; 56:135-50.

Selecting the lymph node level for the CTV of N0 neck:

on the example of cancer of the supraglottic larynx

These guidelines do not intend to give recommendations on the optimal strategy (observation vs. prophylactic treatment) for patients with a clinically N0 neck. Such a decision remains at the discretion of the multidisciplinary head and neck tumor board.

	Level I	Level II	Level III	Level IV	Level V	Retropharyngeal
Incidence of cN0	98/100	29/79	52/90	82/93	85/96	98/0
Probability of occult nodal metastases	<5%	**>5%**	**>5%**	**>5%**	>5% ipsi	<5%
To be included in the CTV	-	+	+	+	±	-

Gregoire et al. *Radiother Oncol* 2000; 56:135-50.
Eisbruch et al. *Semin Radiat Oncol* 2002;12:2380-49.

Selecting the lymph node level for the CTV of N0-1 neck

Tumor site	Level I	Level II	Level III	Level IV	Level V	Retropharyngeal
Oral cavity	+	+	+	+[a]	-	-
Oropharynx	-	+	+	+	-	+[b]
Hypopharynx[c]	-	+	+	+	-	-
Larynx[d]	-	+	+	+	-	-
Nasopharynx	-	+	+	+	+	+

[a]For tumors of the anterior tongue.
[b]For tumors of the posterior pharyngeal wall.
[c]Level VI for for esophageal extension.
[d]Level VI for transglottic and subglottic tumors.

Gregoire et al. *Radiother Oncol* 2000; 56:135-50.

Selecting the lymph node level for the CTV of elective neck in N2b neck

Tumor site	Level I	Level II	Level III	Level IV	Level V	Retropharyngeal
Oral cavity	+	+	+	+	+[a]	-
Oropharynx	+	+	+	+	+	+
Hypopharynx[b]	+	+	+	+	+	+
Larynx[c]	±	+	+	+	+	-
Nasopharynx	+	+	+	+	+	+

[a]May be omitted if only levels I-III are involved.
[b]Level VI for for esophageal extension.
[c]Level VI for transglottic and subglottic tumors.

Gregoire et al. *Radiother Oncol* 2000; 56:135-50.

The CTV of elective neck in N+ and post-op neck: 2006 guidelines

Radiotherapy and Oncology 79 (2006) 15–20
www.thegreenjournal.com

Target volume delineation

Proposal for the delineation of the nodal CTV in the node-positive and the post-operative neck

Vincent Grégoire[a,*], Avraham Eisbruch[b], Marc Hamoir[c], Peter Levendag[d]

[a]*Department of Radiation Oncology, Head and Neck Oncology Program and Center for Molecular Imaging and Experimental Radiation Oncology, Université Catholique de Louvain, Brussels, Belgium,* [b]*Department of Radiation Oncology, University of Michigan, Ann Arbor, MI, USA,* [c]*Department of Head and Neck Surgery and Head and Neck Oncology Program, Université Catholique de Louvain, Brussels, Belgium,* [d]*Department of Radiation Oncology, Rotterdam, The Netherlands*

The CTV of elective neck: the retrostyloid space

- If N+ at (upper) node level II.

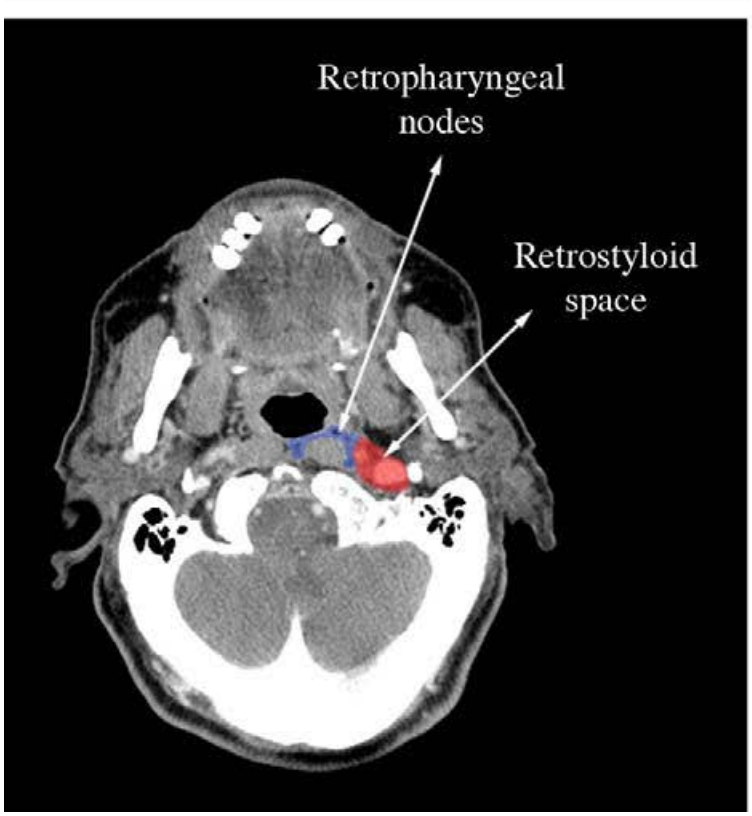

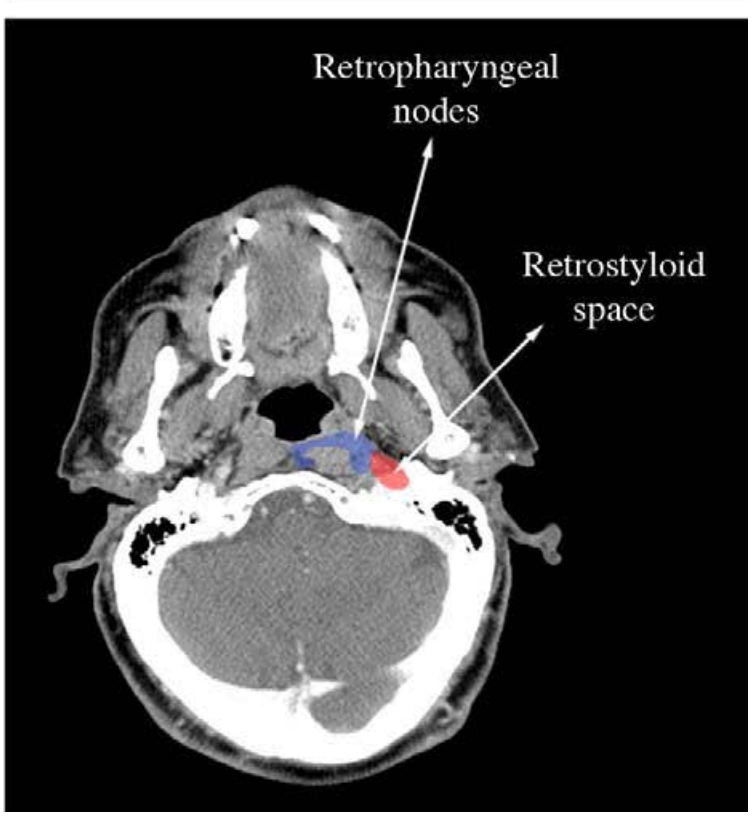

Gregoire et al. *Radiother Oncol* 2006; 79:15-20.

The CTV of elective neck: the supraclavicular fossa

- If N+ at node level IV-V.

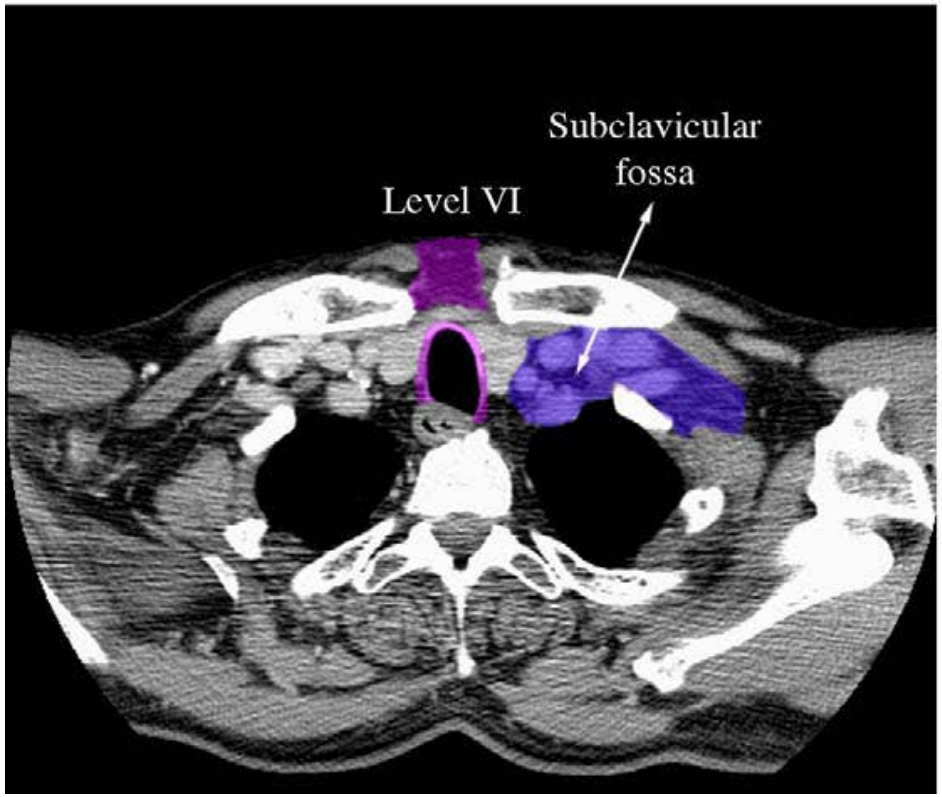

Gregoire et al. *Radiother Oncol* 2006; 79:15-20.

The CTV of elective neck: two node levels

- If N+ at the boundary with another level.

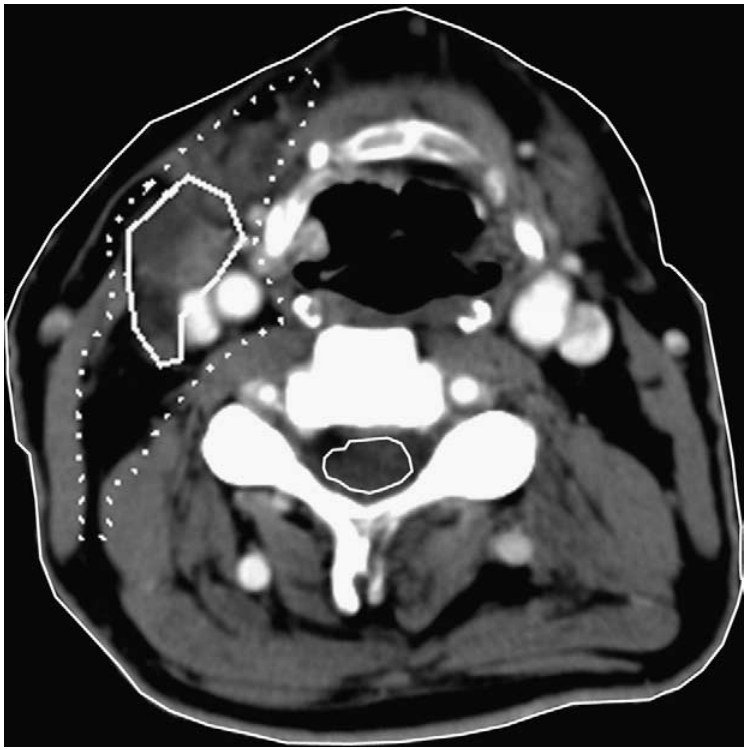

Gregoire et al. *Radiother Oncol* 2006; 79:15-20.

The CTV of elective neck: 2013 update

Contents lists available at ScienceDirect

Radiotherapy and Oncology

journal homepage: www.thegreenjournal.com

Guidelines

Delineation of the neck node levels for head and neck tumors: A 2013 update. DAHANCA, EORTC, HKNPCSG, NCIC CTG, NCRI, RTOG, TROG consensus guidelines ☆

Vincent Grégoire [a,*], Kian Ang [b], Wilfried Budach [c], Cai Grau [d], Marc Hamoir [e], Johannes A. Langendijk [f], Anne Lee [g], Quynh-Thu Le [h,i], Philippe Maingon [j], Chris Nutting [k], Brian O'Sullivan [l], Sandro V. Porceddu [m], Benoit Lengele [n]

[a] Cancer Center and Department of Radiation Oncology, Clinical and Experimental Research Institute, Université Catholique de Louvain, Cliniques Universitaires St-Luc, Brussels, Belgium; [b] Department of Radiation Oncology, The University of Texas MD Anderson Cancer Center, Houston, USA; [c] Department of Radiation Oncology, University Hospital Düsseldorf, Germany; [d] Department of Oncology, Aarhus University Hospital, Denmark; [e] Cancer Center and Department of Otorhinolaryngology, Head and Neck Surgery, Institut de Recherche Experimentale et Clinique, Université Catholique de Louvain, Cliniques Universitaires St-Luc, Brussels, Belgium; [f] Department of Radiation Oncology, University Medical Center Groningen, University of Groningen, The Netherlands; [g] Department of Clinical Oncology, The University of Hong Kong (Shenzhen) Hospital, China; [h] Department of Radiation Oncology, Stanford University School of Medicine, Stanford Cancer Center, Stanford; [i] Radiation Therapy Oncology Group (RTOG), USA; [j] Department of Radiation Oncology, Centre Georges-François Leclerc, Dijon, France; [k] Department of Radiation Oncology, Royal Marsden Hospital and Institute of Cancer Research, London, UK; [l] Department of Radiation Oncology, Princess Margaret Hospital, University of Toronto, Canada; [m] Cancer Services, Princess Alexandra Hospital, Brisbane, Australia; [n] Cancer Center and Department of Human Anatomy and Plastic & Reconstructive Surgery, Institut de Recherche Experimentale et Clinique, Université Catholique de Louvain, Cliniques Universitaires St-Luc, Brussels, Belgium

The CTV of elective neck: 2013 update

- New node levels: VIIa (lateral retropharyngeal), VIIb (retro-styloid), VIII (parotid), IX (bucco-facial), Xa (mastoid) & Xb (occipital).
- New node sublevels: IVa-b, Va-c, VIa-b.
- No medial retropharyngeal lymph nodes.

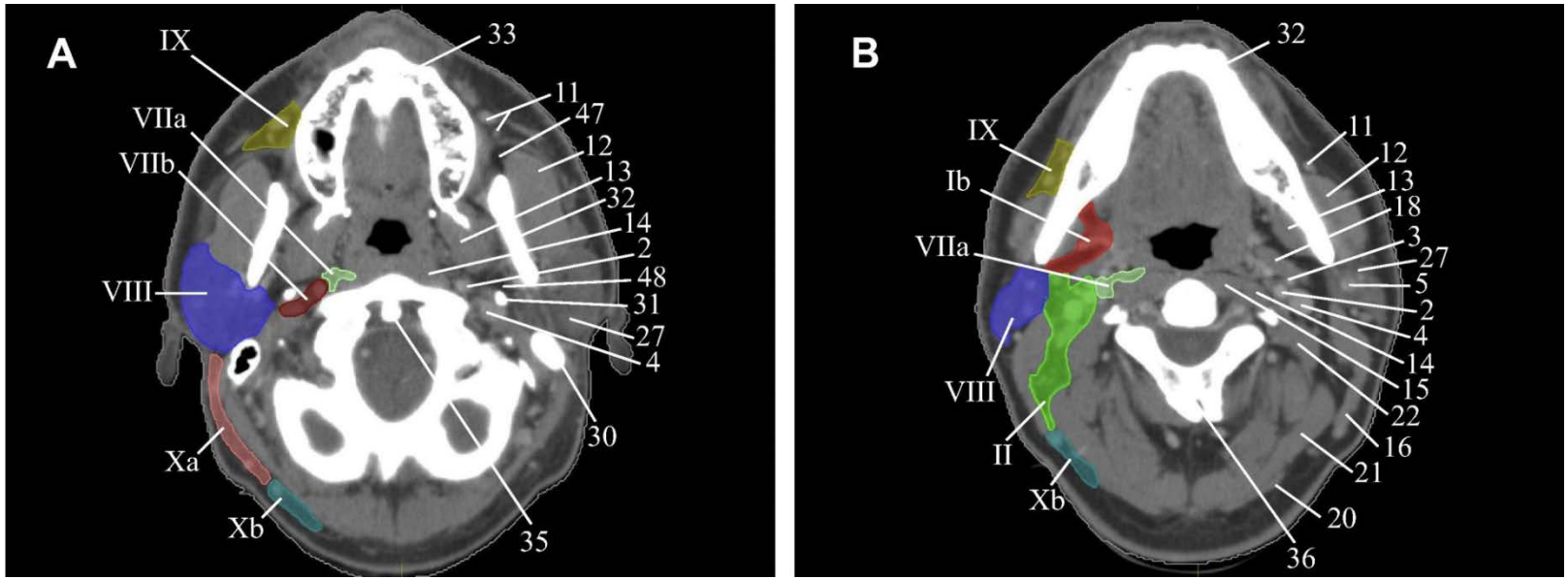

Gregoire et al. *Radiother Oncol* 2014;110:172-81.

The CTV of elective neck: a muscle abutting N+

Including the muscle for the entire node level

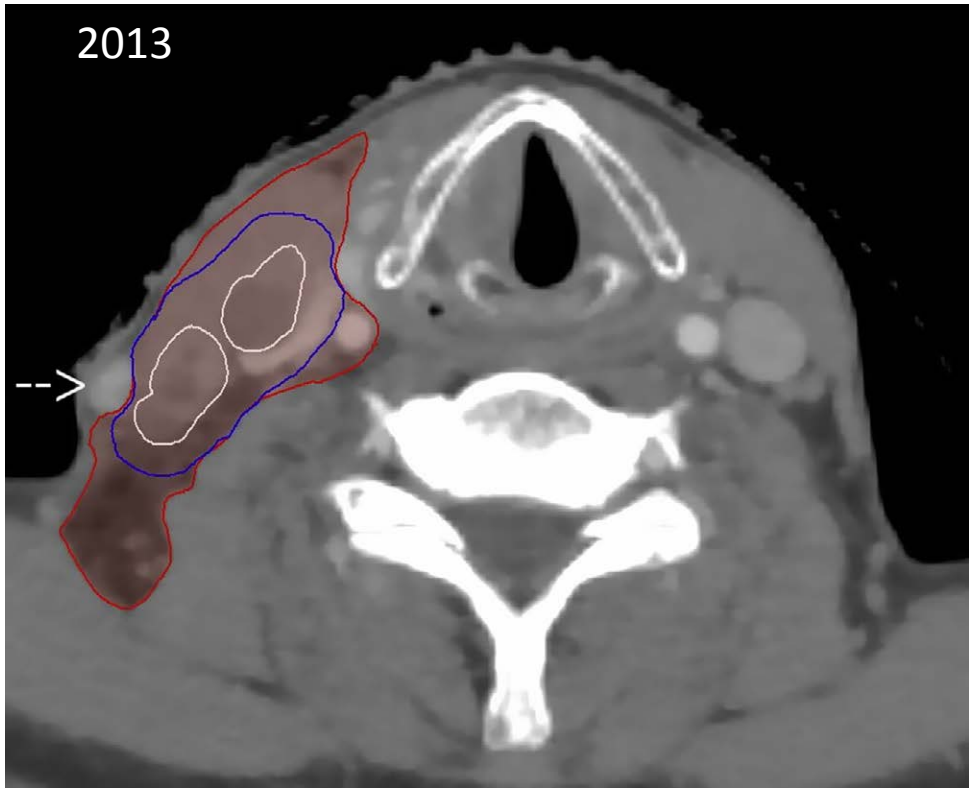

A 1-2 cm 3D-expansion into the muscle

Gregoire et al. *Radiother Oncol* 2006; 79:15-20.
Gregoire et al. *Radiother Oncol* 2014;110:172-81.

How do we define the CTV of elective neck?

International Journal of
Radiation Oncology
biology • physics

www.redjournal.org

Oncology Scan—Nodal Regions, Nodal Regression, and Molecular Biomarkers: New Thinking in Head and Neck Radiation Therapy

By Juliette Thariat, MD, PhD, *Associate Editor*, Sue S. Yom, MD, PhD, *Senior Editor*, Giuseppe Sanguineti, MD, *Associate Editor*, June Corry, MD, *Associate Editor*

Grégoire et al. Delineation of the neck node levels for head and neck tumors: A 2013 update. DAHANCA, EORTC, HKNPCSG, NCIC CTG, NCRI, RTOG, TROG consensus guidelines. *Radiother Oncol 2014*. (1)

Comment: Practically, level-by-level delineation is time consuming. Automatic segmentation of the head and neck structures has been challenging for anatomic and technical reasons, and most atlases have not truly reached the level of entering routine practice. The introduction of more segmented areas with low contrast boundaries constitutes an additional challenge in the field of automatic segmentation. Such guidelines may thus only be applicable for routine practice in university hospitals.

Delineation methods

1. Manual:
   - **RTOG** atlas: https://www.rtog.org/CoreLab/ContouringAtlases/HNAtlases.aspx
   - **Gregoire** *et al*. *Radiother Oncol* 2014;110:172-81.
2. Autosegmentation
   - Advantages:
     - Improving efficacy:
       - reducing intra- & interobserver viriability.
     - Improving efficiency:
       - Time saving.
       - Personnel saving.
       - Streamline workflow.
     - Enabling adaptive radiotherapy.
   - Limitations:
     - Unavoidable visual expection & manual editing by an experienced MD.

ELECTIVE IRRADIATION OF SUBCLINICAL DISEASE IN CANCERS OF THE HEAD AND NECK

GILBERT H. FLETCHER, MD*

Forty-five hundred to 5,000 rads in 5 weeks, 5 days a week, is adequate to eradicate more than 90 per cent of subclinical aggregates of epithelial cancer cells. The elective irradiation of neck nodes in squamous cell carcinoma of the upper respiratory and digestive tract is based on the probability of infestation of specific node areas. This policy applies to the high-grade malignant tumors of minor salivary gland origin. The ipsilateral neck should be irradiated in patients with malignant tumors of the major salivary glands.

Fletcher GH. *Cancer* 1972; 29:1450-4.

Dose prescription to the CTV of elective neck

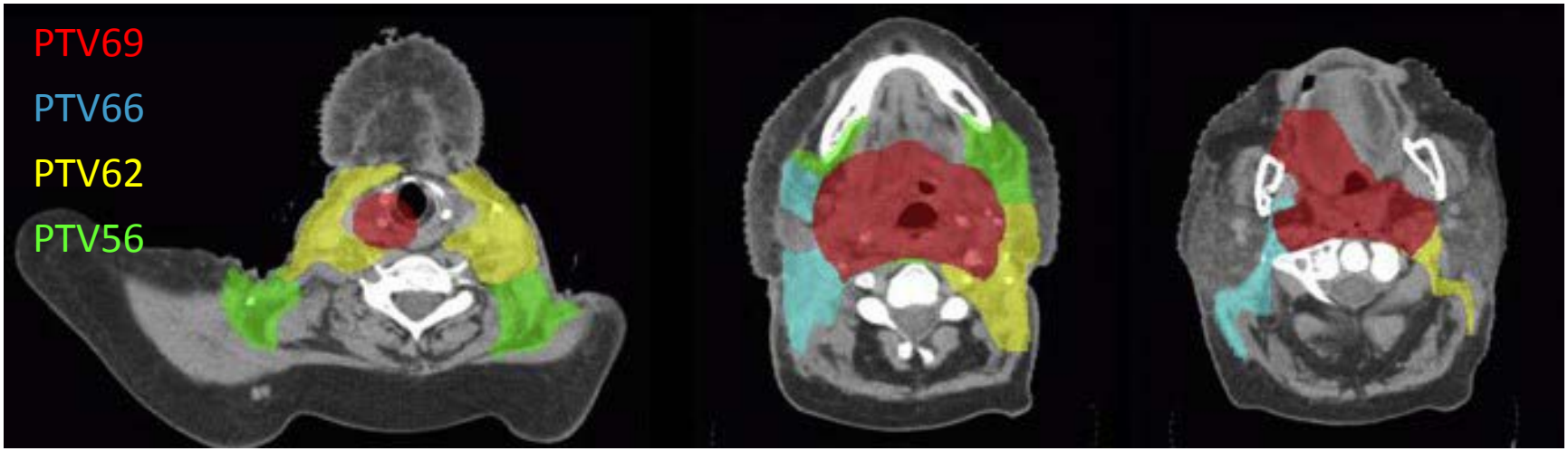

PTV	Description	Dose [Gy]	NID_{2Gy} [Gy]
PTV66	Node level with resected cervical lymph node metastasis with capsule rupture	66	~67
PTV62	Node level with resected cervical lymph node metastasis without capsule rupture	62	~61
PTV56	Nodal level at risk of occult metastasis	56	~51

Duprez et al. *IJROBP* 2011; 79:450-8.

Isolated regional failure after IMRT

Isolated regional failure – lymph node relapse in cN0/pN+ after elective neck irradiation.

Study	*n*	Median follow-up (year)	Chemo, *n* (%)	Elective neck D (Gy)	Isolated regional relapse
Yao 2005	150	1.5	68 (45)	50-60	2%
Schoenfeld 2008	100	2.7	54 (54)	50-54	2% at 3 years
Duprez 2011	285	2.3	92 (32)	56-66	3% at 2 years
Yossi 2015	167	2.9	130 (77)	50	4.2%
				≥50 Gy	<5%

Swallowing disturbances

De-intensification of elective neck irradiation

Yao et al. *IJROBP* 2005;6:101-8.
Shoenfeld et al. *IJROBP* 2008;71;377-85.
Duprez et al. *IJROBP* 2011; 79:450-8.
Yossi et al. *Cancer Radiother* 2015; 19:73-81.

De-intensification of elective neck irradiation

- Decrease in target volume:
  - Disphagia-sparing IMRT:

    Feng et al. *JCO* 2010;28:2731-8.
- Decrease in dose:
  - Dose de-escalation:

    Phase II RCT NCT01812486;

    Phase III RTC RTOG 1016.
- Decrease in target volume & dose:
  - Omitting elective neck at lower risk of occult metastases from irradiation to NID2Gy 40 Gy:

    Phase II RCT NCT01287390.
  - Irradiation of sentinel lymph nodes in T1-2N0 cancer of oral cavity?

Dysphagia-sparing IMRT

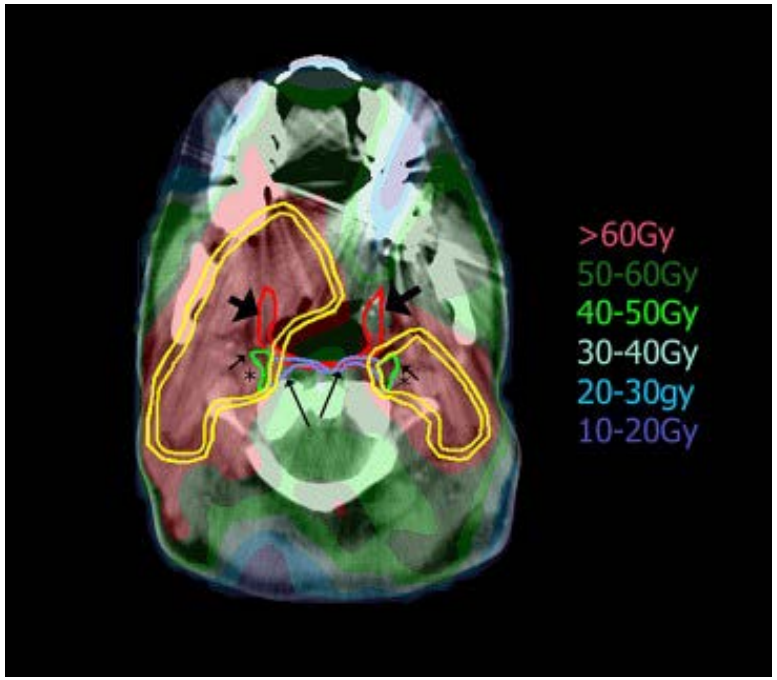

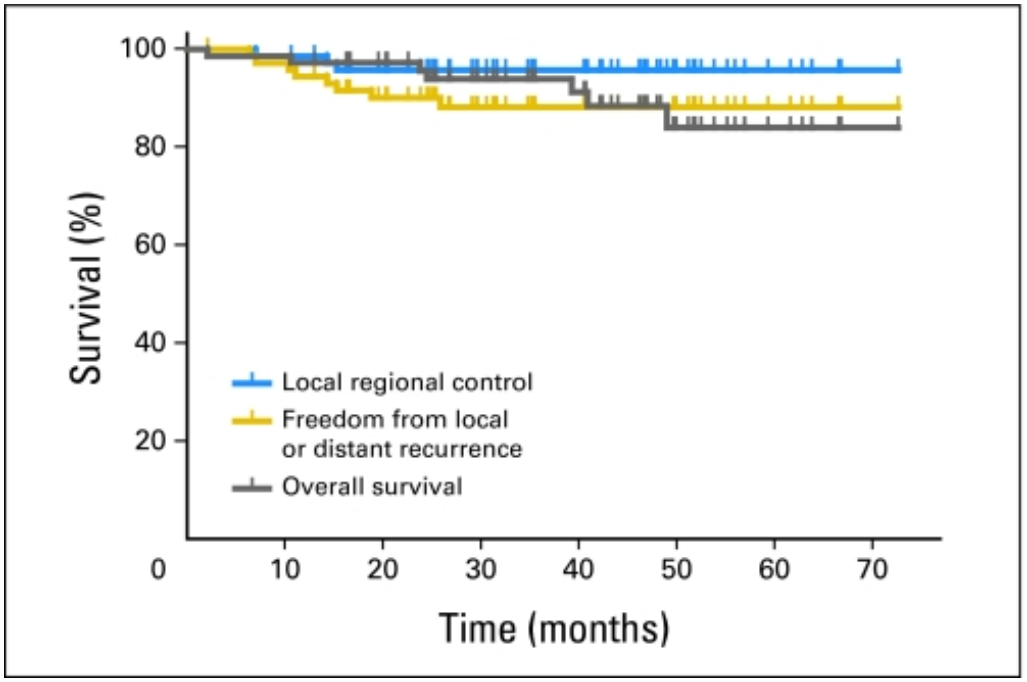

- Omitting medial retropharyngeal lymph nodes from the CTV of elective neck.
- The PTV1 of elective neck: 35 x 1.8 Gy/63 Gy.
- The PTV2 of elective neck: 35 x 1.7 Gy/59.5 Gy.

Feng et al. *IJROBP* 2007;28:2732-8.
Feng et al. *JClin Oncol* 2010;28:2732-8.

Dose de-escalation in elective neck

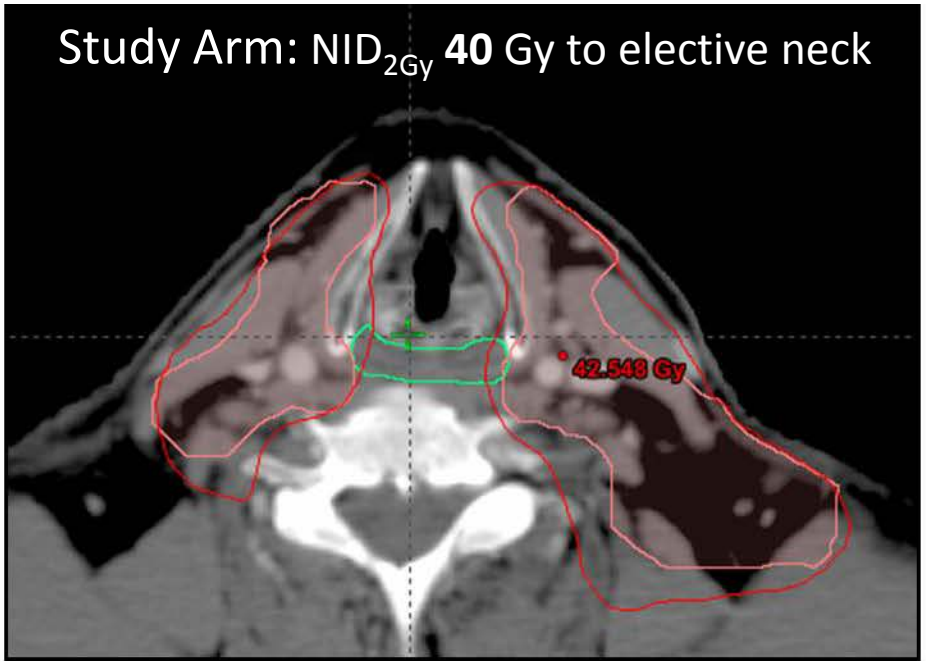

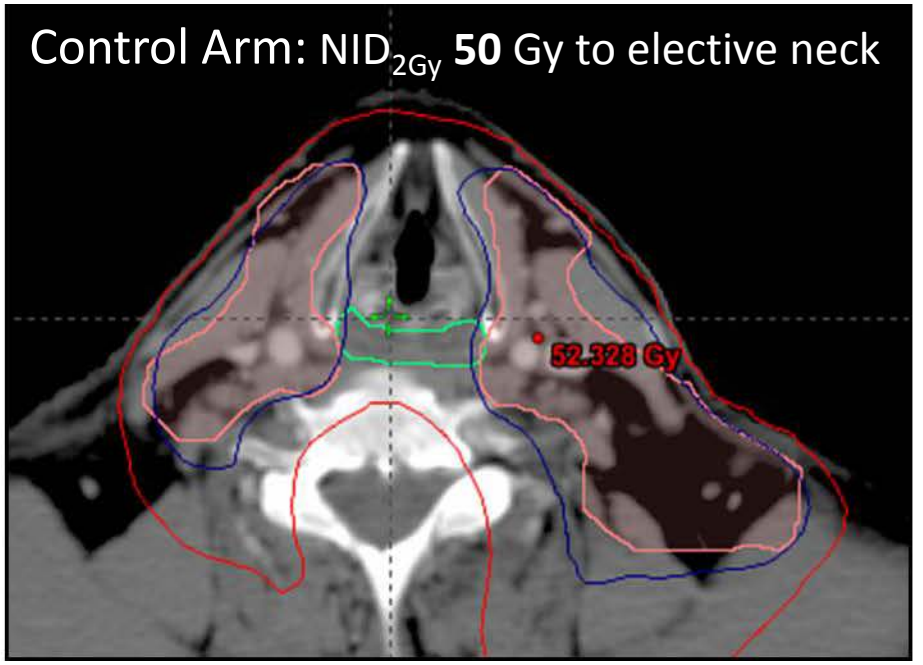

Rates of death or recurrence at 2 years (p = 0.53):

42% [95% CI 32.8-52.9%]

35% [95% CI 25.9-45.4%]

Nuyts et al. *Radiother Oncol* 2013;109:323-9.
Nevens et al. Radiother Oncol 2014: 11, Suppl.1:S21-S22.

Sentinel lymph node biopsy vs. elective neck dissection:

T1-2N0 cancer of the oral cavity

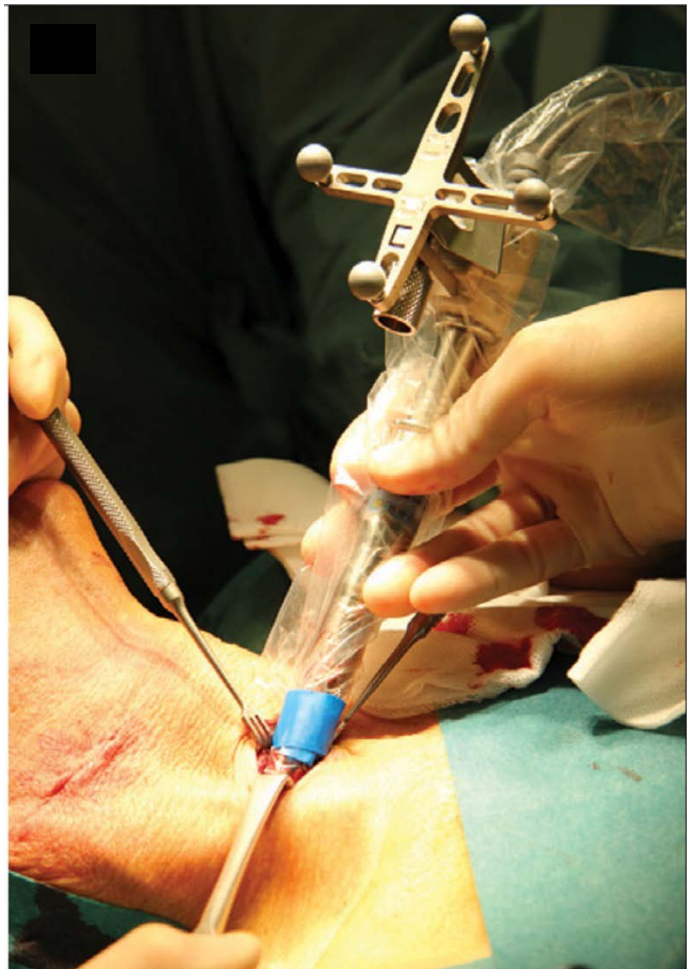

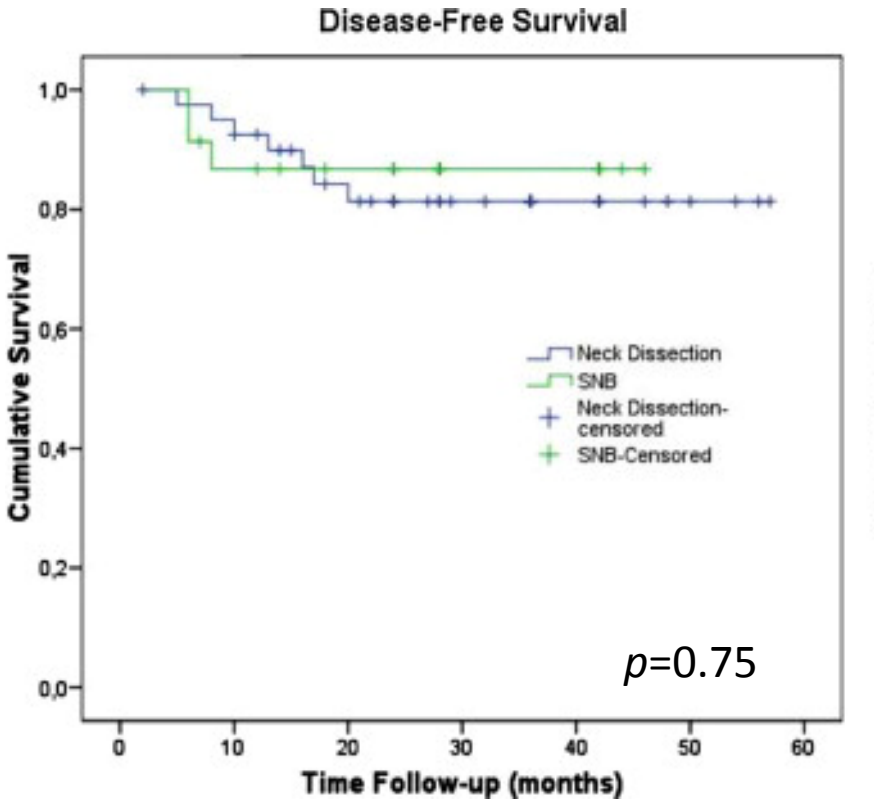

Leusink et al. *Lancet Oncol* 2012;13:e554-61
Hernando et al. *Int J Maxillofac Surg* 2014;11:1307-12.

Sentinel lymph nodes: irradiation instead of biopsy?

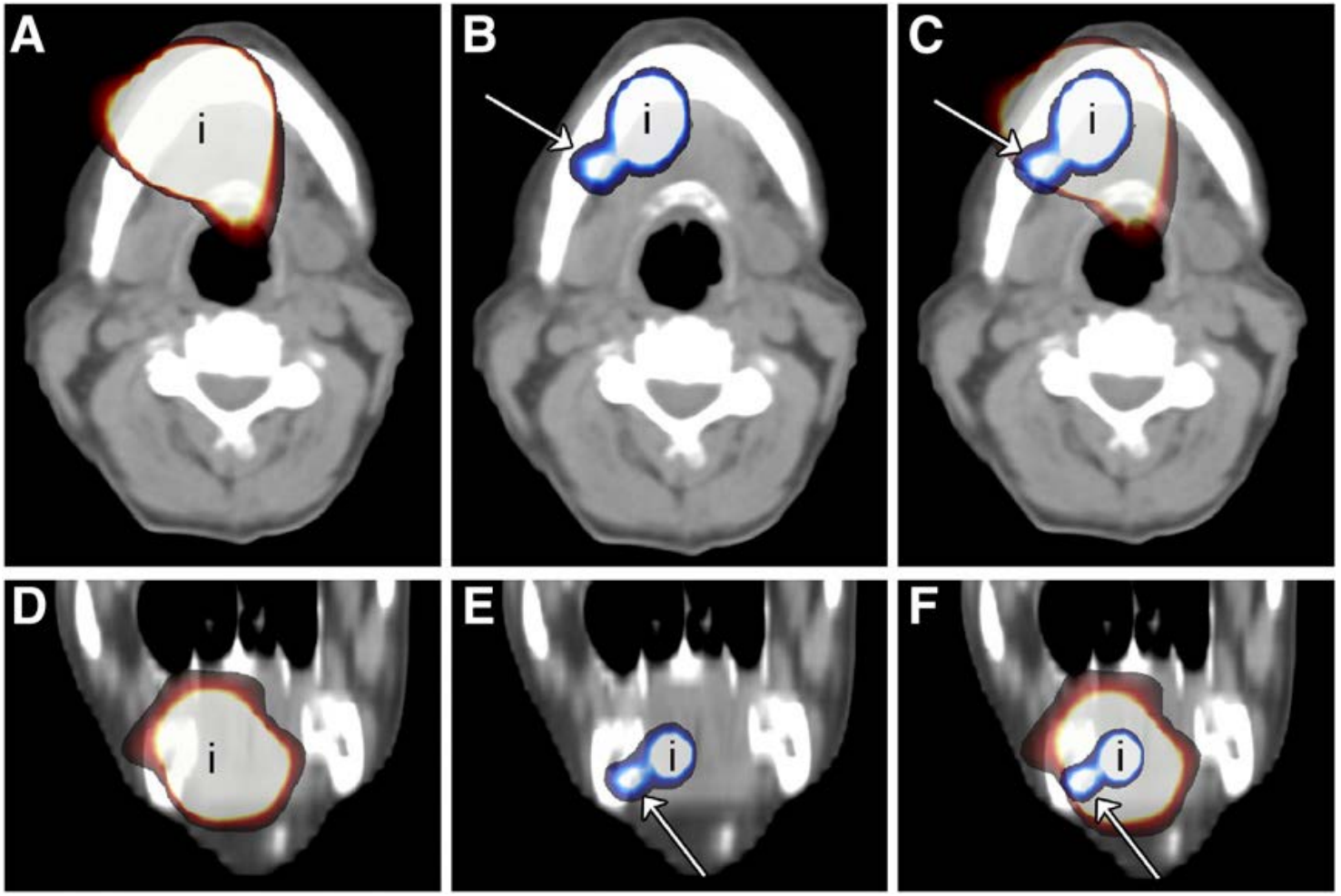

Heuveling et al. *J Nucl Med* 2013;54:585-9.

Take home messages

- N0 head-and-neck cancer requires elective neck treatment.
- The threshold for elective neck irradiation is ≥5-10% probability of occult lymph node metastases.
- The 2013 guidelines specify neck node levels.
- Tumor site, histology & N-stage are the principle factors in selection node levels in the CTV of elective neck.
- De-intensification is a new paradigm in elective neck irradiation.

Post Scriptum

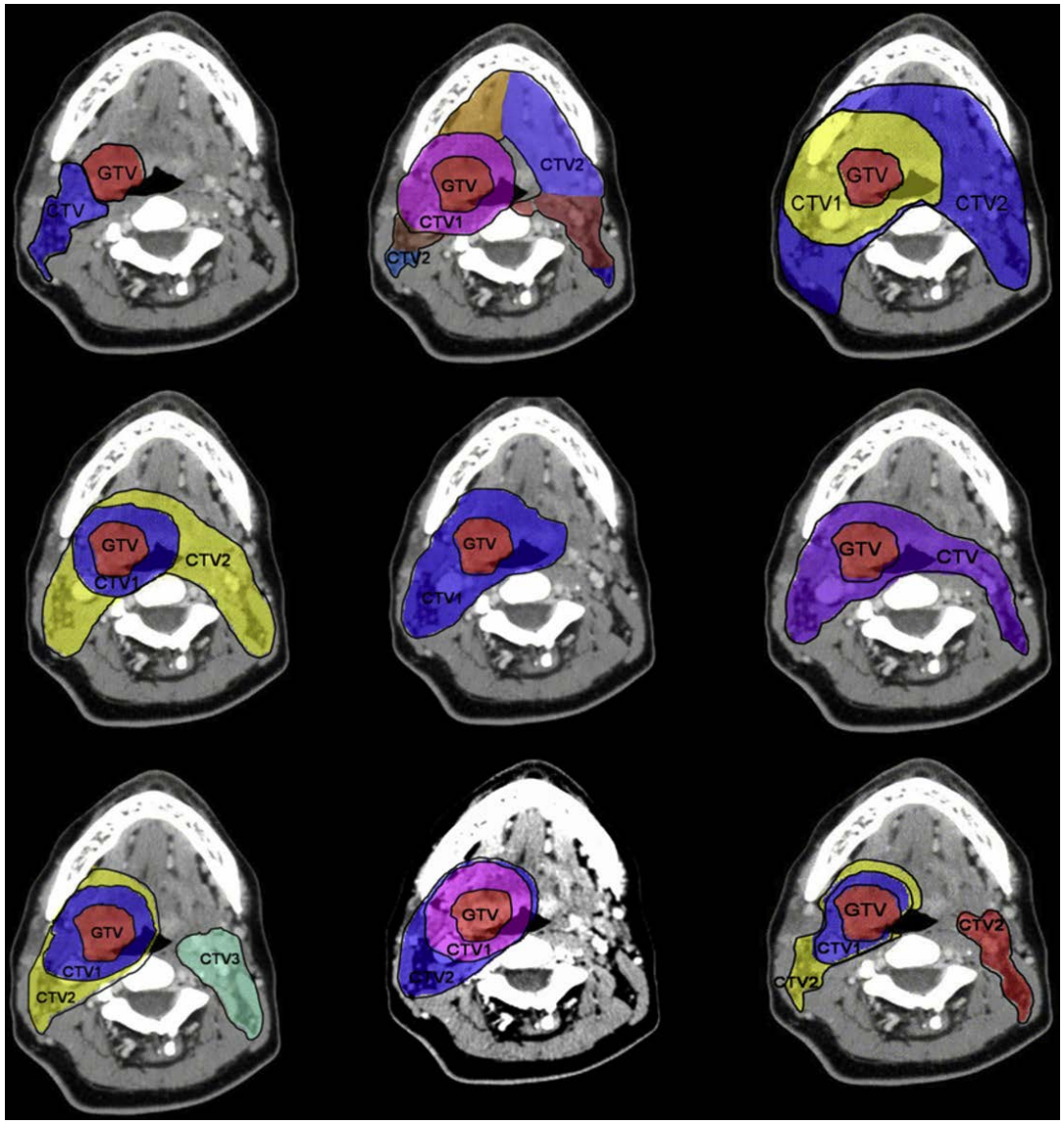

Hong, Tome, Harari. *Radiat Oncol* 2012;103:92-8.

Appendix 1
Cervical lymph nodes of extracranial head-and-neck

Deep lateral cervical group

- Deep cervical chain:
  along the internal jugular vein, often within the facial layers of the carotid sheath.
  - Jugulodigastric node = “sentinel”
  - Virchow’s node =“signal”
- High, middle and low deep cervical chain:
  above, between and below the hyoid bone and cricoid cartilage
- Drainage:
  parotid, retropharyngeal and submental-submandibular groups > the deep cervical chain > the **subclavian** or **internal jugular vein**

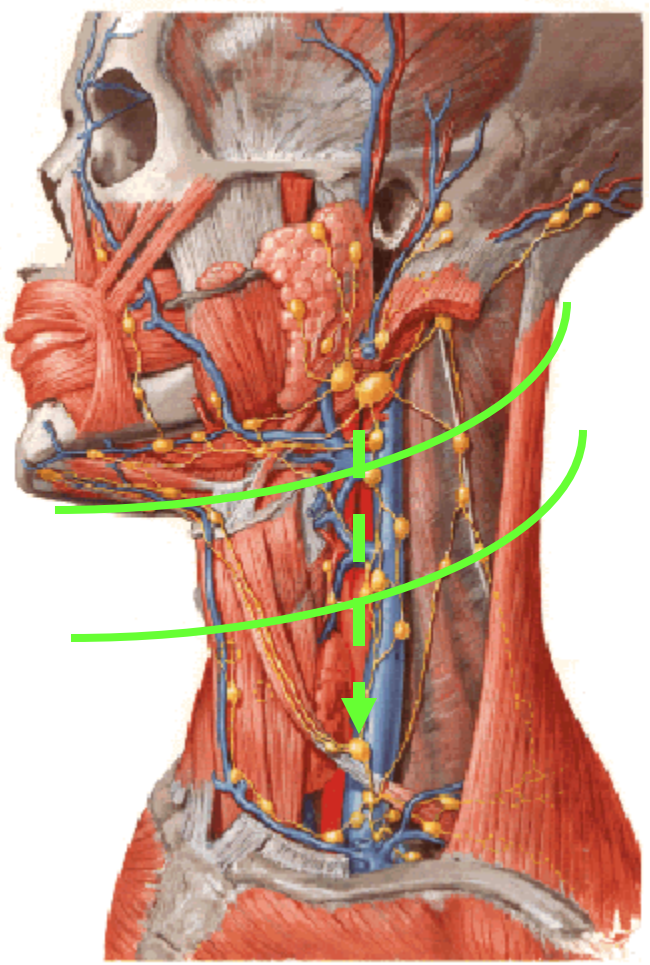

Deep lateral cervical group

- Spinal accessory chain:

  following the course of the spinal accessory nerve (cranial nerve XI) in the posterior cervical space of the neck (posterior trianlge)

- Drainage:

  occipital, mastoid groups, parietal scalp, lateral neck, shoulders > spinal accessory chain > **transverse cervical chain**

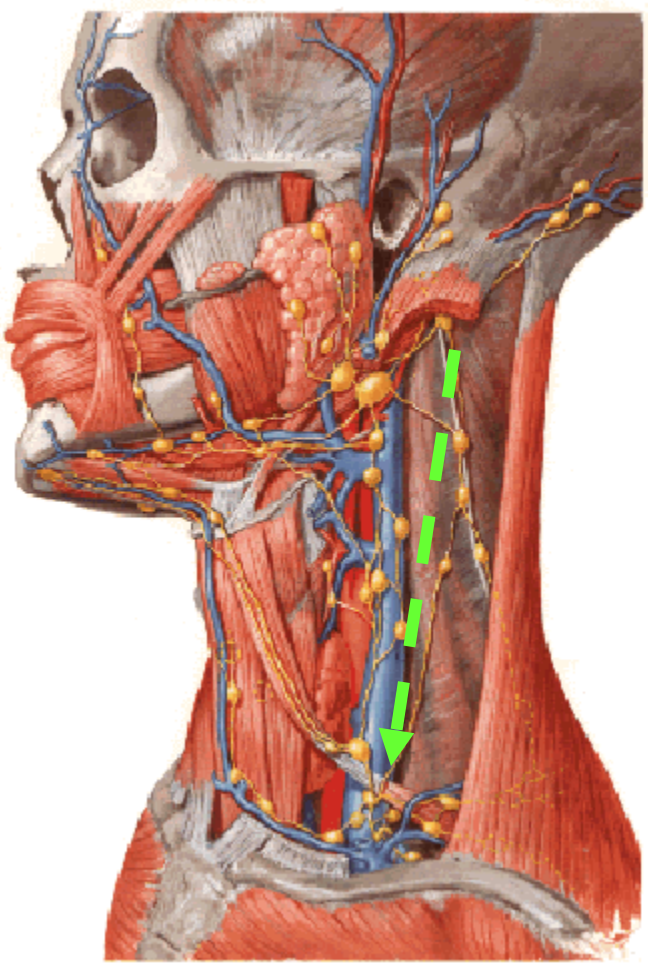

Deep lateral cervical group

- Transverse cervical chain:

  transverse, parallel the clavicles

- Drainage:

  spinal accessory chain, deep cervical chain, subclavicular nodes, upper anterior chest wall, skin of the anterolateral neck > transverse cervical chain > ... > the **subclavian** or **internal jugular vein**

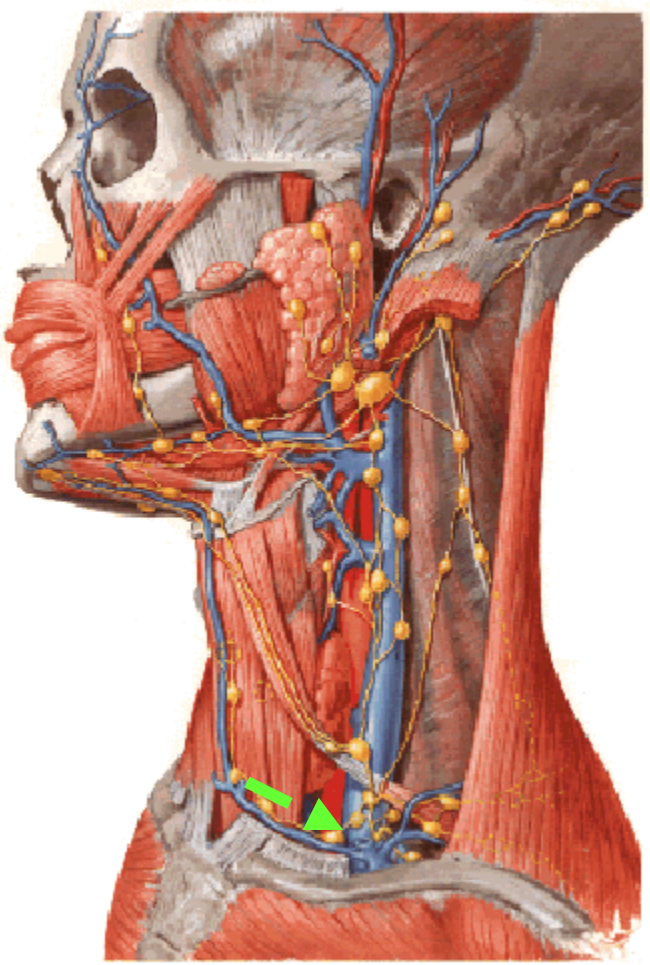

Anterior cervical group

- Pretracheal nodal chain:

  along the length of the external jugular vein external to the strap muscles.

- Drainage:

  The skin and muscles of the anterior neck > the **thoracic duct** or the **anterior mediastinal nodes** (left) and the **low deep cervical chain** or **highest intrathoracic node** (right)

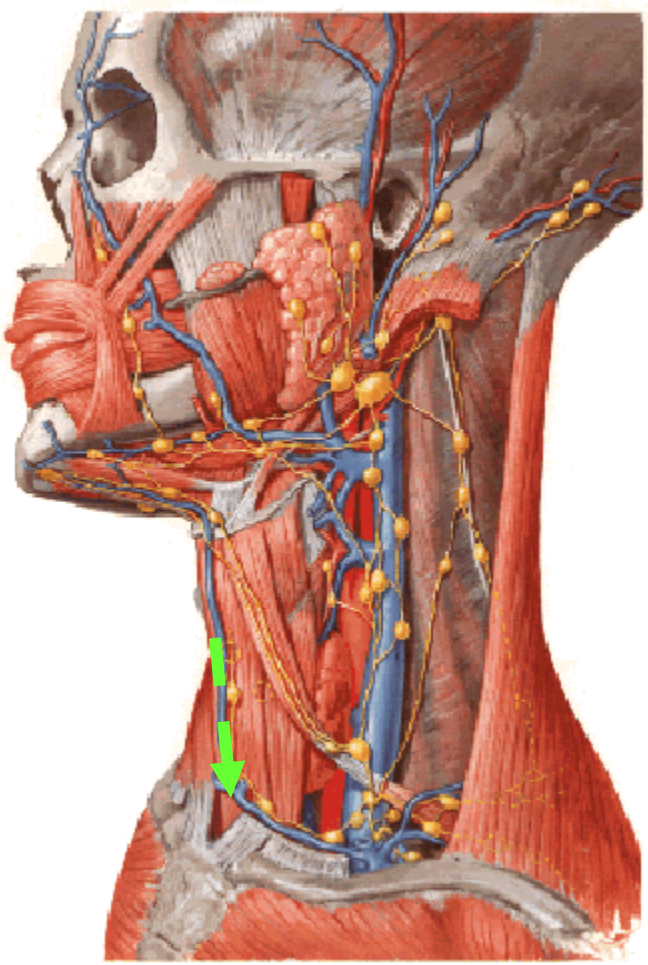

Anterior cervical group

- Prelaryngeal nodal chain:

  - Delphian node

- Paratracheal nodal chain:

  within the viceral space of the infrahyoid neck

- Drainage:

  supra- and subglottic larynx, pyriform sinus, thyroid gland, trachea, esophagus > the **thoracic duct** or the **anteroir mediastinal nodes** (left) and the **low deep cervical chain** or **highest intrathoracic node** (right)

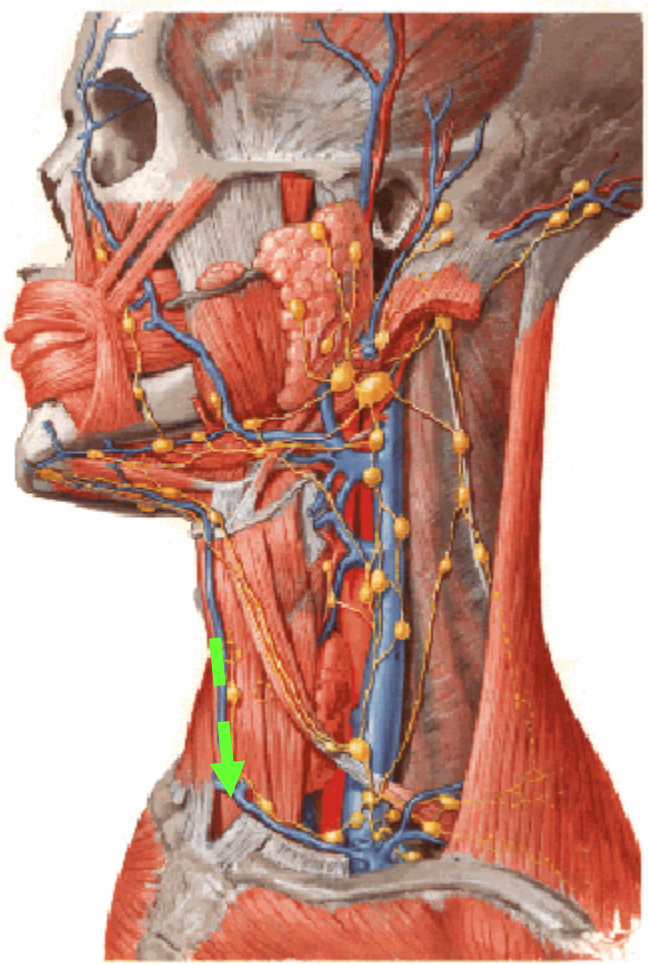

Submental-submandibular group

- Submental nodes:
  between the anterior belly of the two digastric muscles.
- Submandibular nodes:
  in the vicinity of the submandibular gland.
- Drainage:
  the anterior facial structures and skin, anterior floor of the mouth, anterior oral cavity > the **submandibular group** > the **deep cervical chain**

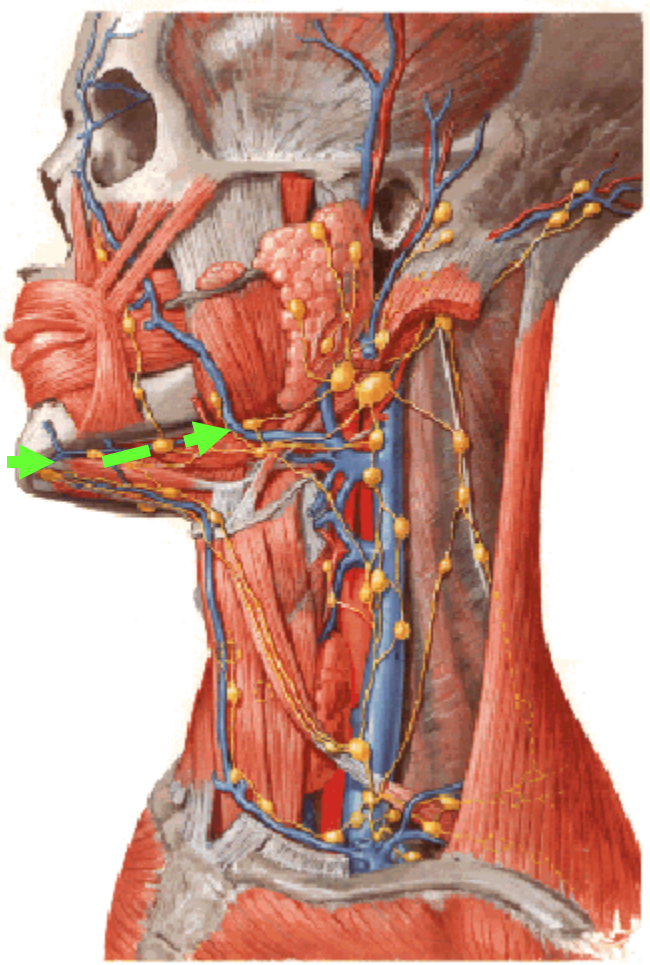

Parotid group

- Parotid nodes:
  - extraglandular
  - intraglandular
- Drainage:

the external auditory canal, eustachian tube, skin of the forehead and temporal region, posterior cheek, gums, buccal mucosal membrains > the **high deep cervical chain**

Retropharyngeal group

- Retropharyngeal nodes:

in the retropharyngeal space at the naso- and oropharyngeal levels

- medial near the midline

- lateral (Rouviere's nodes) lateral to the longus colli and capitus muscles and medial to the internal carotid artery

- Drainage:

the nasopharynx and oropharynx > the **high deep cervical chain**

Appendix 2
Classification of lymph node dissection

American Head Neck Society Neck Dissection Classification (2008)

	Type	*Description*
Comprehensive	Radical	Removal of lymph nodes from levels I-V, the sternocleidomastoid muscle, the spinal accessory nerve, and the internal jugular vein
	Modified radical	As radical with preservation of at least 1 non-lymphatic structure
	Extended	Removal of additional lymph node levels and/or non-lymphatic structures (e.g., muscle, blood vessel, nerves)
	Selective	Preservation of 1 or more lymph node levels

Robbins et al. *Arch Otolaryngol Head Neck Surg* 2008;134: 536–538.

Appendix 3

http://www.rtog.org/CoreLab/ContouringAtlases/HNAtlases.aspx

CT-based definition of nodal target volumes

ANATOMICAL BOUNDARIES						
LEVEL	**CRANIAL**	**CAUDAL**	**ANTERIOR**	**POSTERIOR**	**LATERAL**	**MEDIAL**
Ia	Geniohyoid m., plane tangent to basilar edge of mandible	Plane tangent to body of hyoid bone	Symphysis menti, platysma m.	Body of hyoid bone	Medial edge of ant. Belly of digastric m.	n.a.[a]
Ib	Mylohyoid m., cranial edge of submandibular gland	Plane through central part of hyoid bone	Symphysis menti, platysma m.	Posterior edge of submandibular gland	Basilar edge/innerside of mandible, platysma m., skin	Lateral edge of ant. Belly of digastric m.
IIa	Caudal edge of lateral process of C1	Caudal edge of the body of hyoid bone	Post. Edge of submandibular gland; ant. Edge of int. carotid artery; post edge of post. belly of digastric m.	Post. border of int. jugular vein	Medial edge of sternocleidomastoid	Medial edge of int. carotid artery, paraspinal (levator scapulae) m.
IIb	Caudal edge of lateral process of C1	Caudal edge of the body of hyoid bone	Post. border of int. jugular vein	Post. border of sternocleidomastoid	Medial edge of sternocleidomastoid	Medial edge of int. carotid artery, paraspinal (levator scapulae) m.

CT-based definition of nodal target volumes

ANATOMICAL BOUNDARIES						
LEVEL	**CRANIAL**	**CAUDAL**	**ANTERIOR**	**POSTERIOR**	**LATERAL**	**MEDIAL**
III	Caudal edge of the bosy of hyoid bone	Caudal edge of cricoid cartilage	Posterior-lateral edge of the sternohyoid m.; ant. edge of sternocleidomastoid m.	Post. edge of sternocleidomastoid m.	Medial edge of sternocleidomastoid	Medial edge of int. carotid artery, paraspinal (scalenius) m.
IV	Caudal edge of cricoid cartilage	2 cm cranial to sternoclavicular joint	Anteromedial edge of sternocleidomastoid m.	Post. edge of sternocleidomastoid m.	Medial edge of sternocleidomastoid	Medial edge of int. carotid artery, paraspinal (scalenius) m.
V	Cranial edge of body of hyoid bone	CT slice encompassing the transverse cervical vessels[b]	Post. edge of sternocleidomastoid m.	Ant. Border of the trapezius m.	Platysma m., skin	Paraspinal (levator scapulae, scalenius) m.
VI	Caudal edge of body of thyroid cartilage[c]	Sternal manubrium	skin; platysma m.	Separation between trachea and esophagus[d]	Medial edges of thyroid gland, skin and ant.-medial edge of sternocleidomastoid m.	NA

CT-based definition of nodal target volumes

ANATOMICAL BOUNDARIES						
LEVEL	**CRANIAL**	**CAUDAL**	**ANTERIOR**	**POSTERIOR**	**LATERAL**	**MEDIAL**
VI	Caudal edge of body of thyroid cartilage[c]	Sternal manubrium	skin; platysma m.	Separation between trachea and esophagus[d]	Medial edges of thyroid gland, skin and ant.-medial edge of sternocleidomastoid m.	NA
R.	base of skull	Cranial edge of the body of hyoid bone	Fascia under the pharyngeal mucosa	Prevertebral m. (longus colli, longus capitis)	Median edge of the int. carotid artery	Midline

R.: retropharyngeal.

NA: not available.

[a] midline structure lying between the medial borders of the anterior bellies of the digastric muscles.

[b] fatty planes below and around the clavicle down to the trapezius muscle.

[c] for paratracheal and recurrent nodes, the cranial border is the caudal edge of the cricoid cartilage.

[d] for pretracheal nodes, trachea and anterior edge of cricoid cartilage.

The GTV/CTV of the primary tumor & metastatic lymph node
Organs-at-risk in head-and-neck cancer

ESTRO Teaching Course

"Target Volume Determination: from Imaging to Margins"

Budapest, Hungary, October 6th, 2015

Indira Madani, M.D., Ph.D.

Nothing to disclose

Questions

1. How do we define the GTV of the primary head-and-neck tumor & metastatic lymph node?
2. How do we define the CTV of the primary head-and-neck tumor & metastatic lymph node?
3. What are organs-at-risk?
4. Do targets and OARs change during radiation therapy?
5. Do we need adaptive radiation therapy?

The gross tumor volume (GTV)

"There are currently no absolute standards of how to delineate the GTV."

Schmidt-Ulrich *et al*, 2006

Defining the GTV:

- Independent of the irradiation techniques.
- Influenced by the oncological considerations.
- Using 3D imaging.
- Done on a CT scan acquired at treatment conditions.
- Represents a snapshot of the anatomy at a given time.

ICRU report 83. 2010;10:41-46.
Schmidt-Ulrich et al. In: Image-Guided IMRT. *Springer*;2006:304.

The GTV-T: CT, MR or FDG-PET?

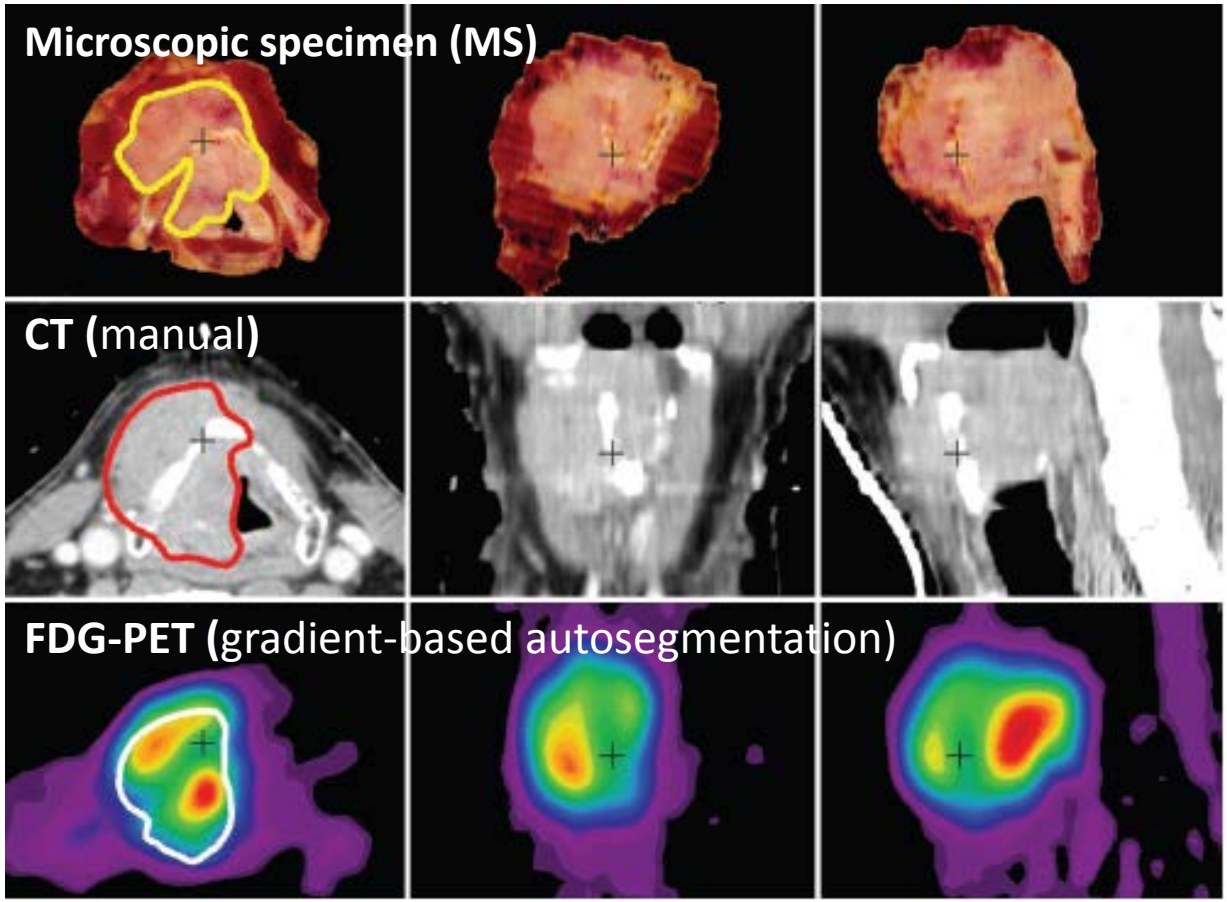

	GTV (cm^3)	*Δ (%)*
MS	12.6	-
CT	20.8	+65
MRI	23.8	+89
FDG-PET	16.3	+29

Daisne et al. *Radiology* 2004;233:93-100.

Defining the GTV-T (FDG-PET)

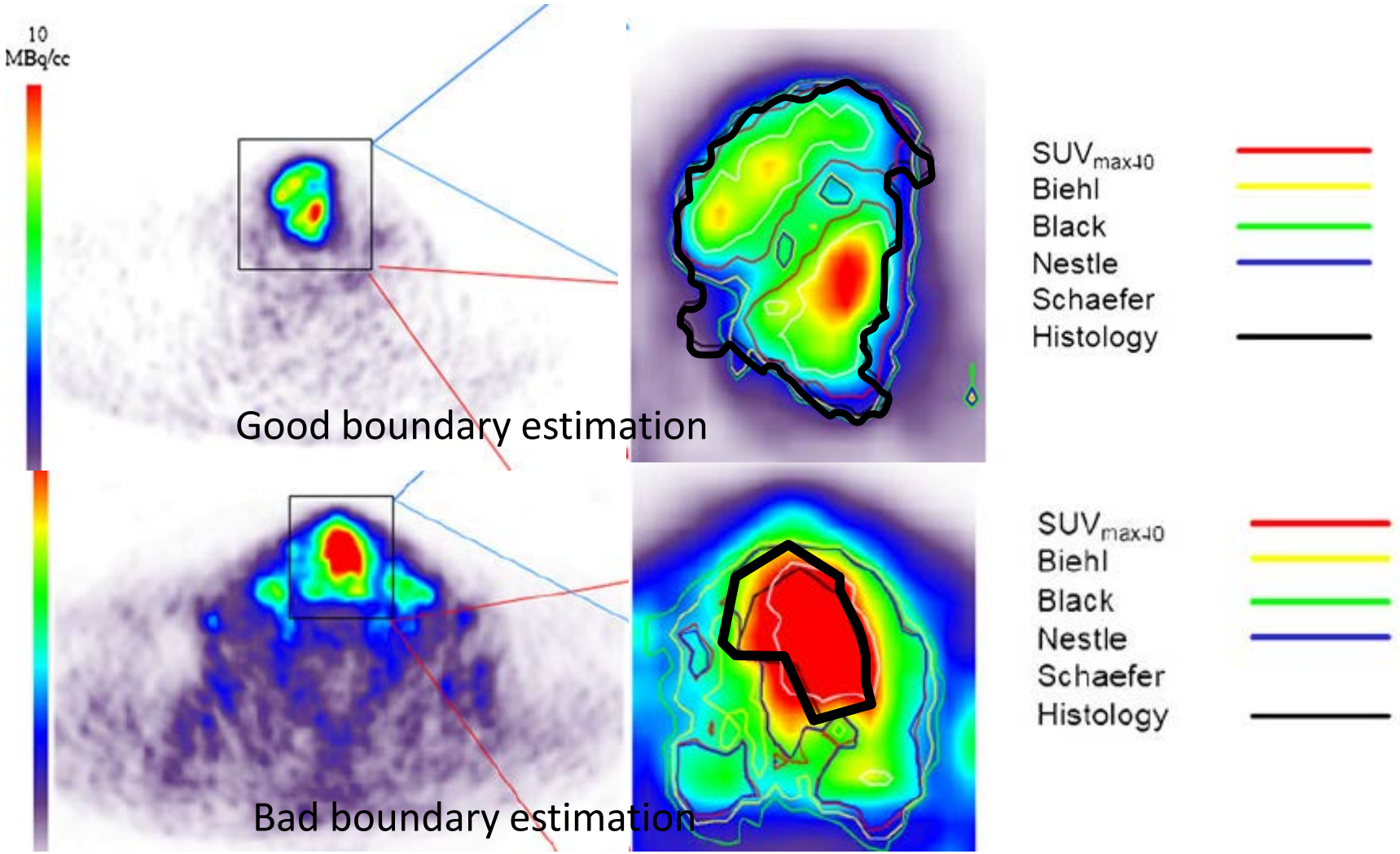

Zaidi et al. *Eur J Nucl Med Mol Imaging* 2012;39:881-91.

The GTV: CTV, MR or FDG-PET?

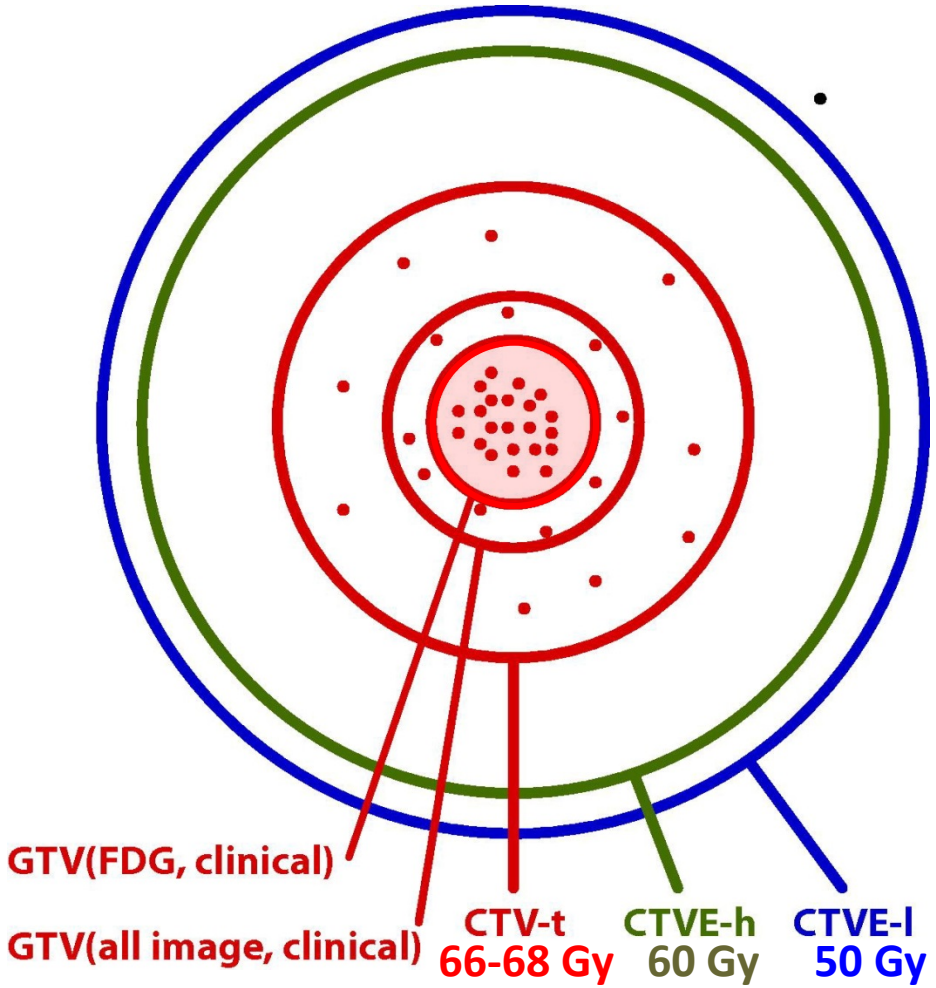

Tumor recurrence:

- 54% inside the GTV (FDG-PET)
- 96% inside the ≥66 Gy region.

Due et al. *Radiat Oncol* 2014;111:365-5.

The GTV: CTV, MR or FDG-PET?

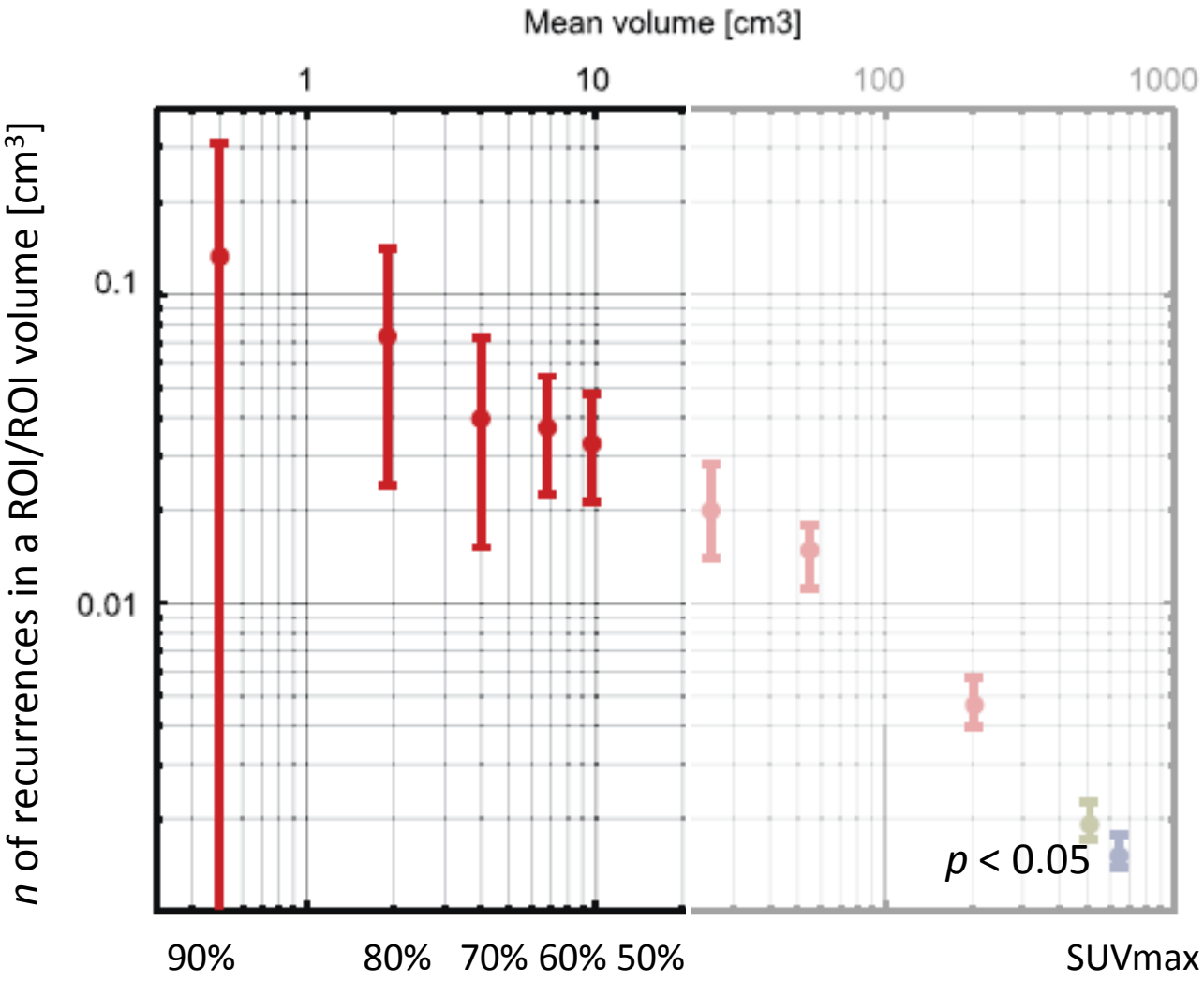

Due et al. *Radiat Oncol* 2014;111:365-5.

The GTV-T: CT, MR, FDG-PET & physical examination!

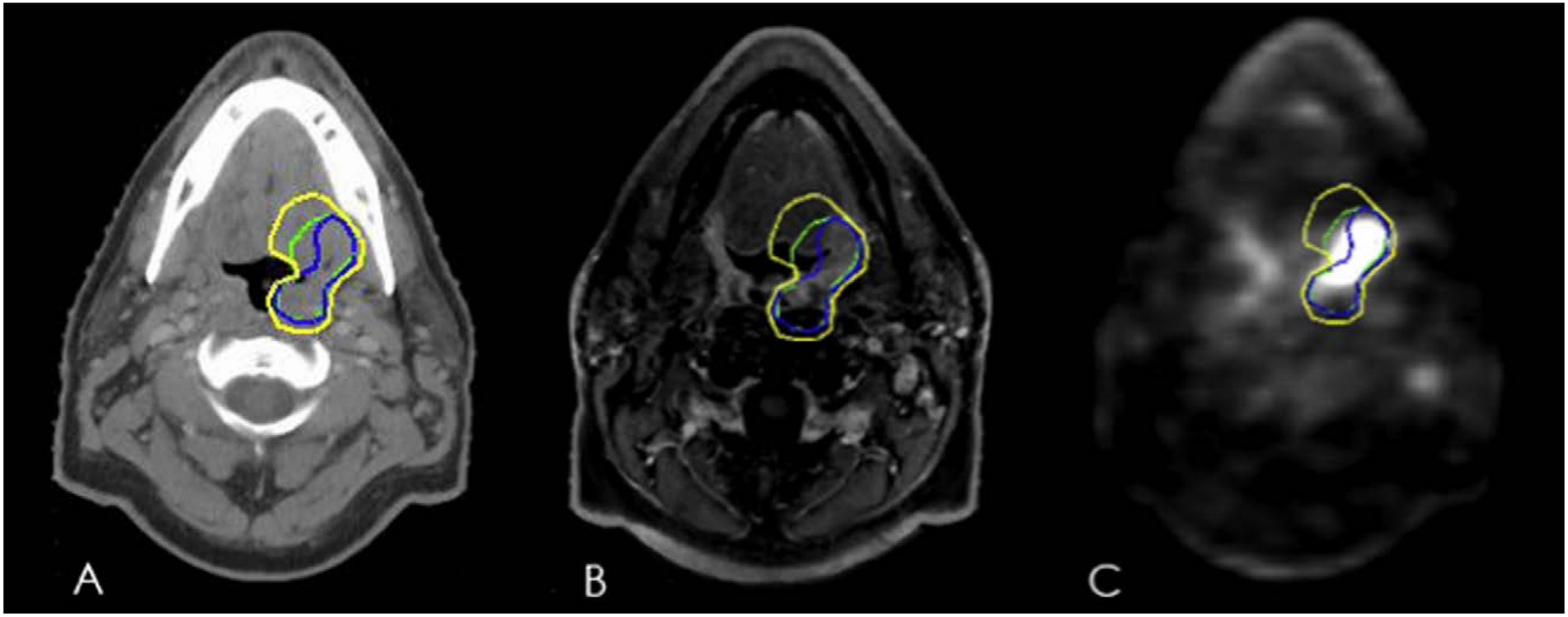

Thiagarajan et al. *IJROBP* 2012;83:220-7.

The GTV-N: CT or FDG-PET?

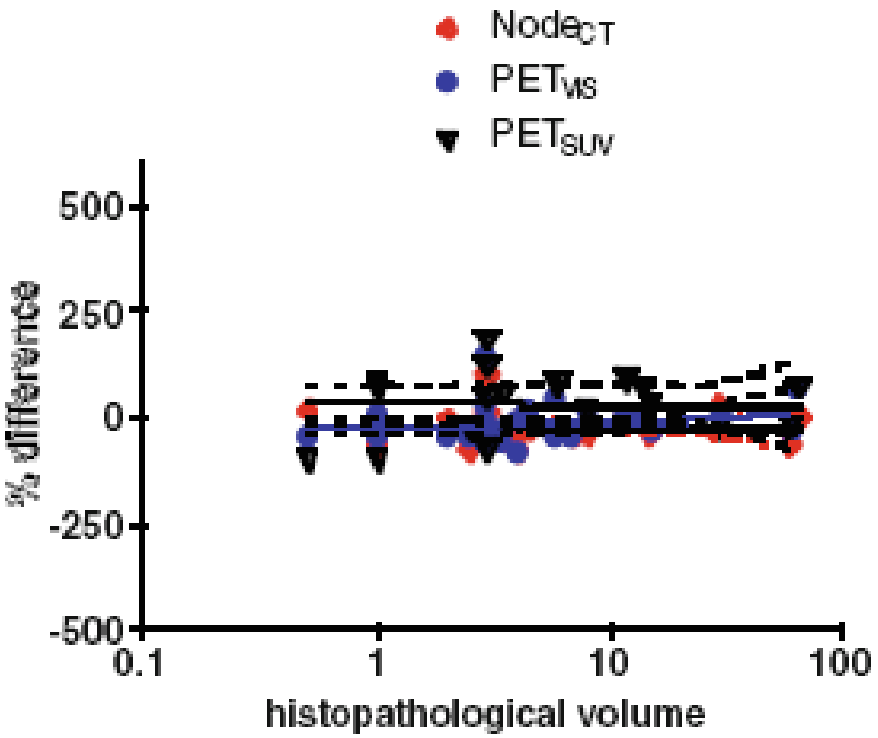

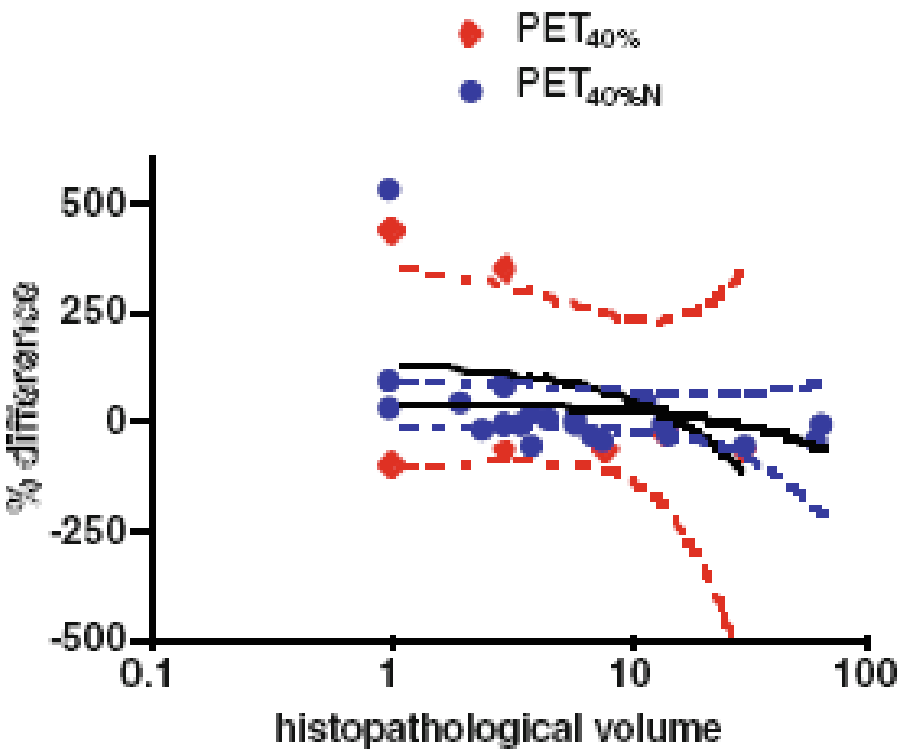

Schinagl et al. *Eur J Nucl Med Mol Imaging* 2013;40:1828-35.

The GTV-N: CT, MR or DW-MR?

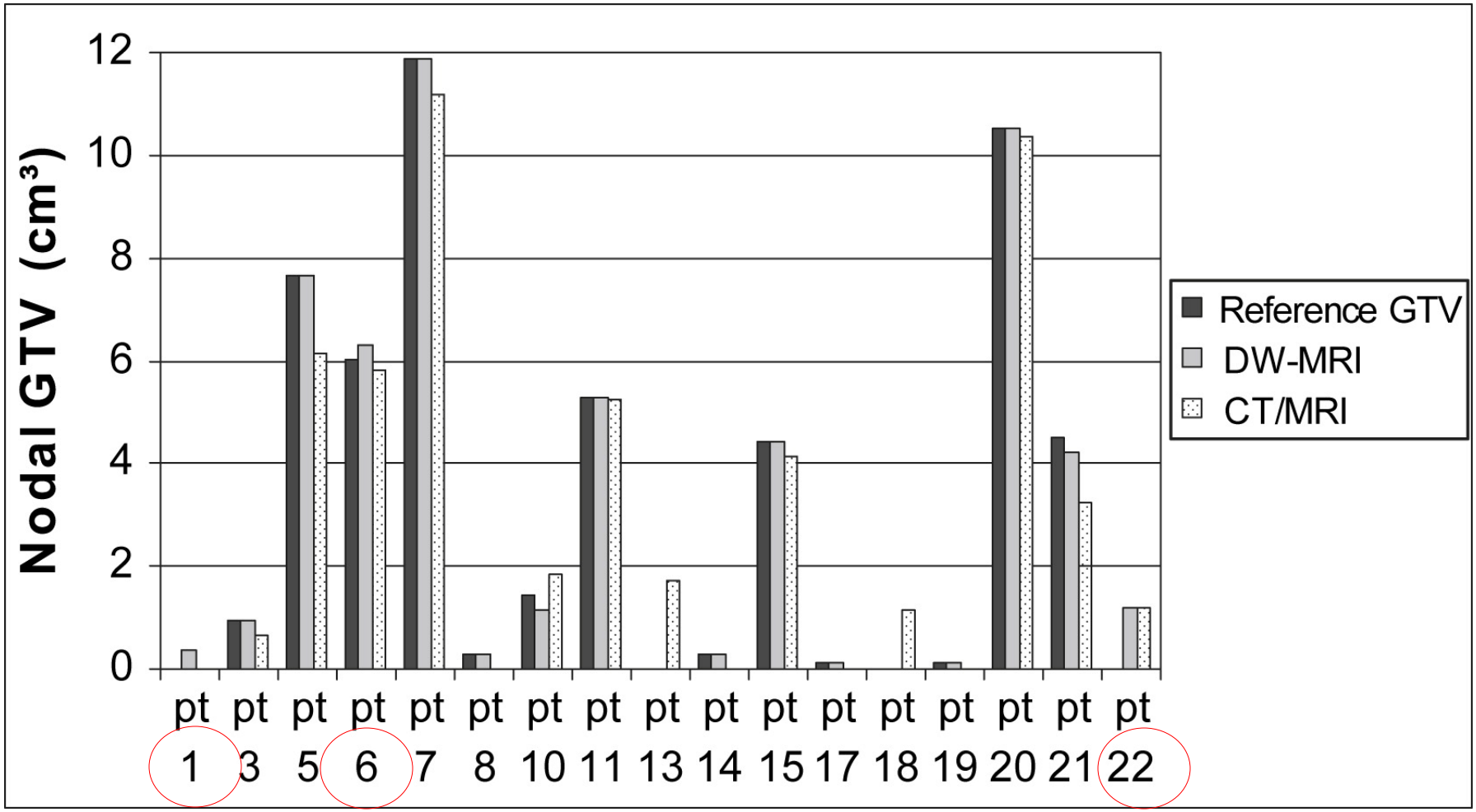

Dirix et al. *Radiat Oncol* 2010;76:761-6.

The clinical target volume (CTV)

"Delineating the CTV is more an art than a science because current imaging techniques are not capable of detecting subclinical tumor involvement directly".

Perez & Brady, 2008

Defining the CTV:

1. Probability of microscopic tumor extension: 5-10%.
2. Methods:
   - Volumetric (isotropic) expansion using margins.
   - Anatomic/compartmental: including anatomic compartments bounded by anatomic barriers.

Perez & Brady. In: Principles and practice of radiation oncology. *Lippincott Williams & Wilkins.* 2008:228.
ICRU report 83. 2010;10:44-45.

The CTV-T

Merlotti *et al. Radiation Oncology* (2014) 9:264
DOI 10.1186/s13014-014-0264-9

REVIEW Open Access

Technical guidelines for head and neck cancer IMRT on behalf of the Italian association of radiation oncology - head and neck working group

Anna Merlotti[1†], Daniela Alterio[2†], Riccardo Vigna-Taglianti[3†], Alessandro Muraglia[4†], Luciana Lastrucci[5†], Roberto Manzo[6†], Giuseppina Gambaro[7†], Orietta Caspiani[8†], Francesco Miccichè[9†], Francesco Deodato[10†], Stefano Pergolizzi[11†], Pierfrancesco Franco[12†], Renzo Corvò[13†], Elvio G Russi[3*†] and Giuseppe Sanguineti[14†]

The margin between each GTV and its CTV should be typically 10–20 mm, with a minimum of 5 mm except in those areas where the GTV is immediately adjacent to structures known to be uninvolved (i.e. anatomic barriers).

The CTV-T

RTOG 0129 (2002-2005; closed)

A PHASE III TRIAL OF CONCURRENT RADIATION AND CHEMOTHERAPY (FOLLOWED BY SURGERY FOR RESIDUAL PRIMARY/N2-3 NODAL DISEASE) FOR ADVANCED HEAD AND NECK CARCINOMAS

RT technique: 2 opposed lateral fields + matching anterior field
A 20-30 mm margin to the GTV

RTOG 1016 (2011-2014; closed for accrual):

PHASE III TRIAL OF RADIOTHERAPY PLUS CETUXIMAB VERSUS CHEMORADIOTHERAPY IN HPV-ASSOCIATED OROPHARYNX CANCER

RT technique: IMRT
A margin 5-15 mm to the GTV

The CTV-T/N

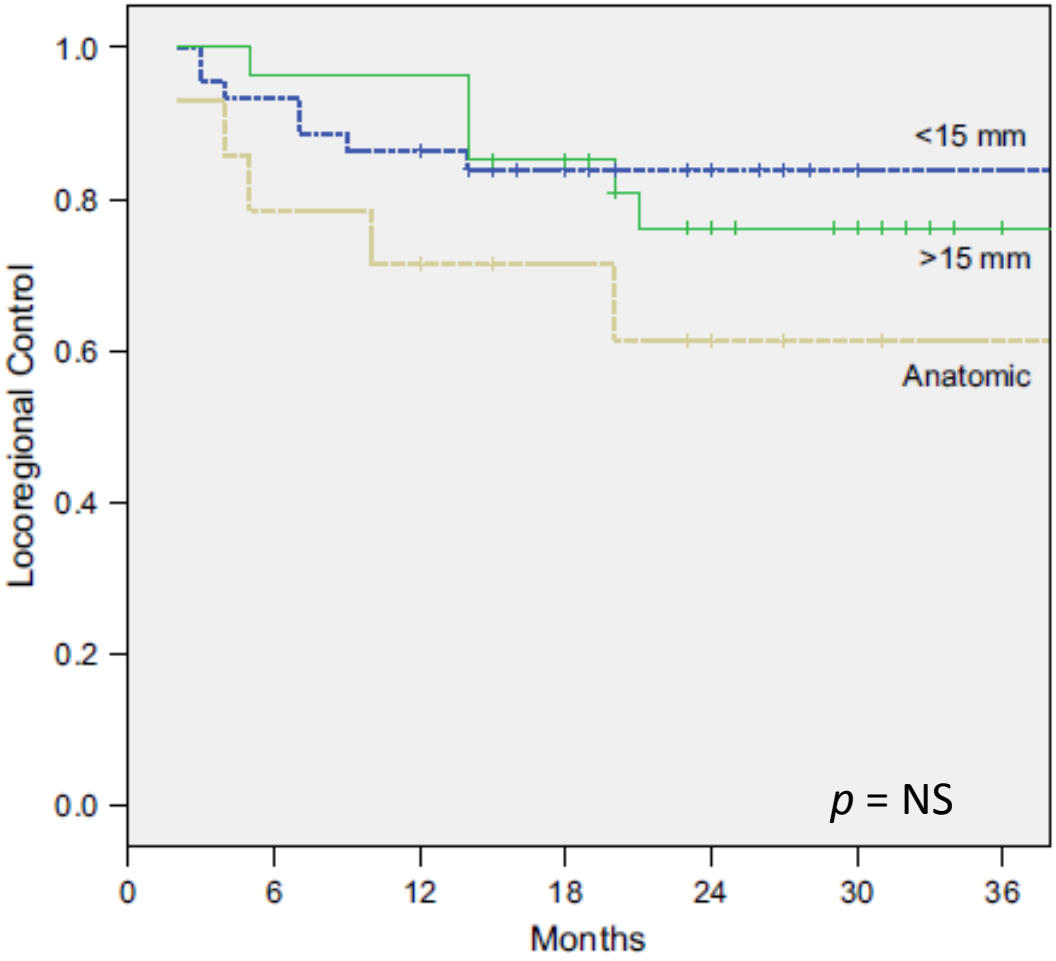

Volumetric 3D expansion:
0-20 mm (GTV → CTV)
3-6 mm (CTV → PTV)

Anatomic

Caudell et al. *IJROBP* 2010;76:164-8.

The CTV-N

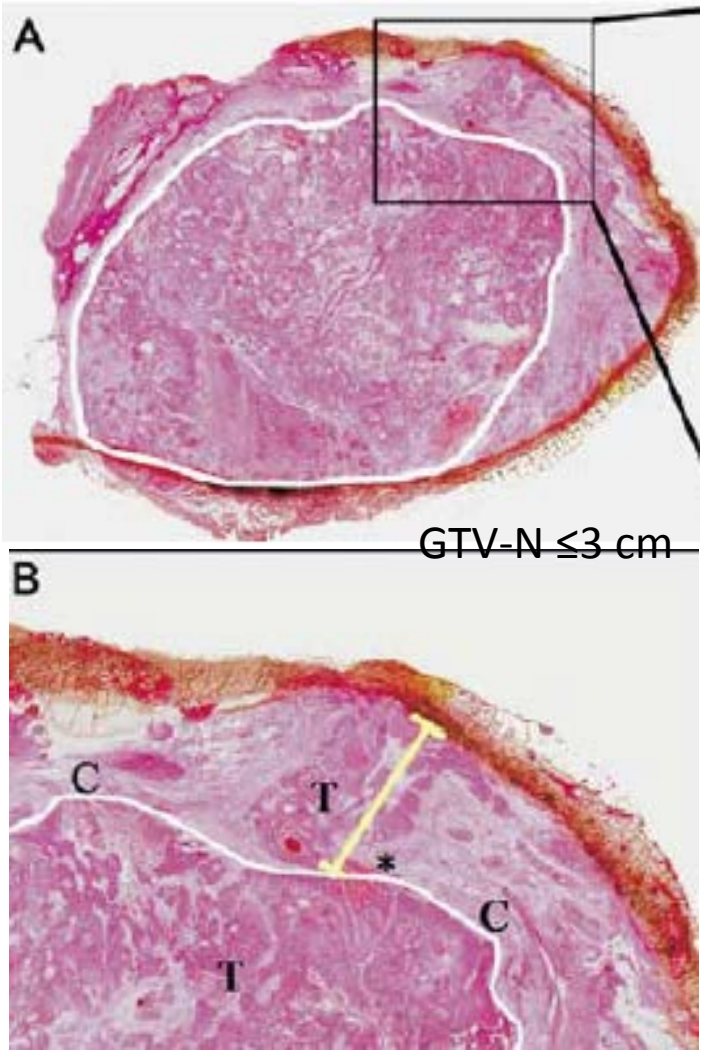

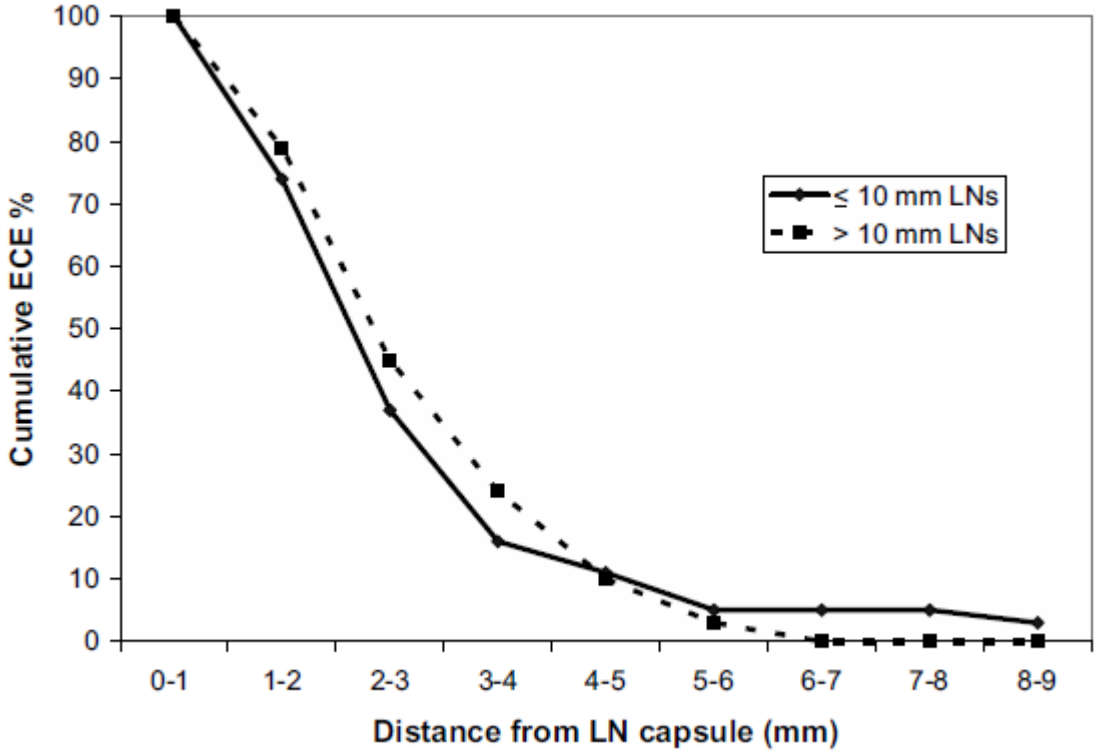

IMRT: a 10 mm margin to the GTV-N.
3D-CRT: a 13-15 mm margin to the GTV-N.

Apisarnthanarax et al. *IJROBP* 2006;64:678-83.

Organs-at-risk (OARs): 2015 guidelines

Radiotherapy and Oncology xxx (2015) xxx–xxx

Contents lists available at ScienceDirect

Radiotherapy and Oncology

journal homepage: www.thegreenjournal.com

Original article

CT-based delineation of organs at risk in the head and neck region: DAHANCA, EORTC, GORTEC, HKNPCSG, NCIC CTG, NCRI, NRG Oncology and TROG consensus guidelines

Charlotte L. Brouwer [a,*,1], Roel J.H.M. Steenbakkers [a,1], Jean Bourhis [b], Wilfried Budach [c], Cai Grau [d], Vincent Grégoire [e], Marcel van Herk [f], Anne Lee [g], Philippe Maingon [h], Chris Nutting [i], Brian O'Sullivan [j], Sandro V. Porceddu [k], David I. Rosenthal [l], Nanna M. Sijtsema [a], Johannes A. Langendijk [a]

What are OARs?

OAR	PRV	Imaging	Delineation method
Spinal cord itself	Yes	CT	Manual/autosegmentation
Brainstem itself	Yes	CT/MR	Manual/autosegmentation
Parotid/submandibular glands	No	CT/MR	Manual/autosegmentation
Mandible	No	CT	Manual/autosegmentation
Retina, optic nerve, optic chiasm	Yes	CT/MR	Manual
Lacrimal glands	No	CT/MR	Manual
Brain/brain structures	No	CT/MR	Manual/autosegmentation
Swallowing structures	No	CT	Manual
Thyroid gland	No	CT	Manual
Oral cavity	No	CT/MR	Manual
Middle/inner ear	No	CT	Manual
Temporomandibular joint, masseter & pterygoid muscles	No	CT	Manual
Brachial plexus	Yes?	CT/MR	Manual
Cranial nerves	Yes?	CT/MR	Manual
Lungs & trachea	No	CT	Manual/autosegmentation
Carotid arteries	No	CT	Manual/autosegmentation

PRV = Planning organ-at-Risk Volume

OARs: manual or automatic segmentation?

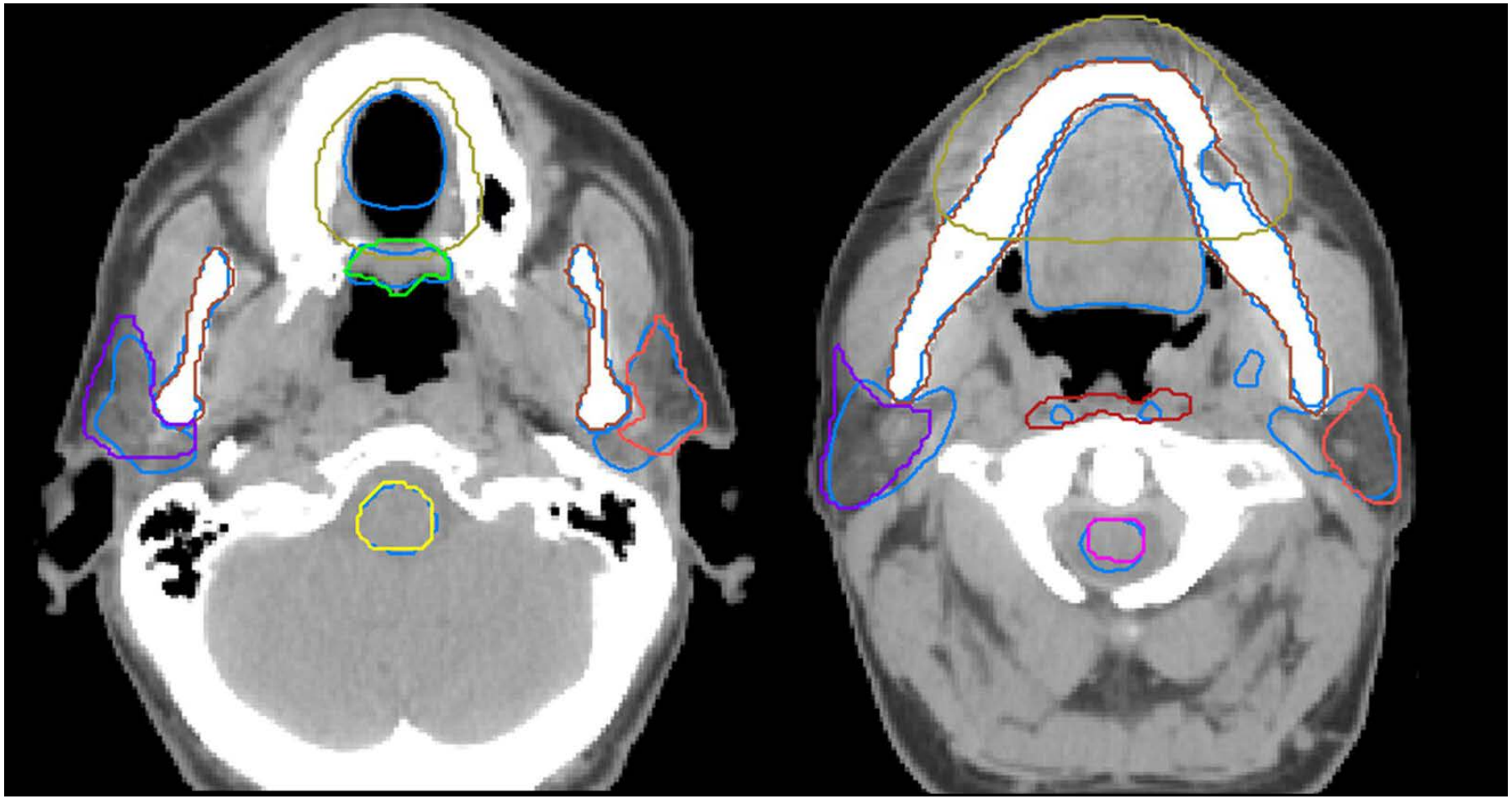

Walker et al. *Radiother Oncol* 2014;112:321-5.

OARs: manual or automatic segmentation?

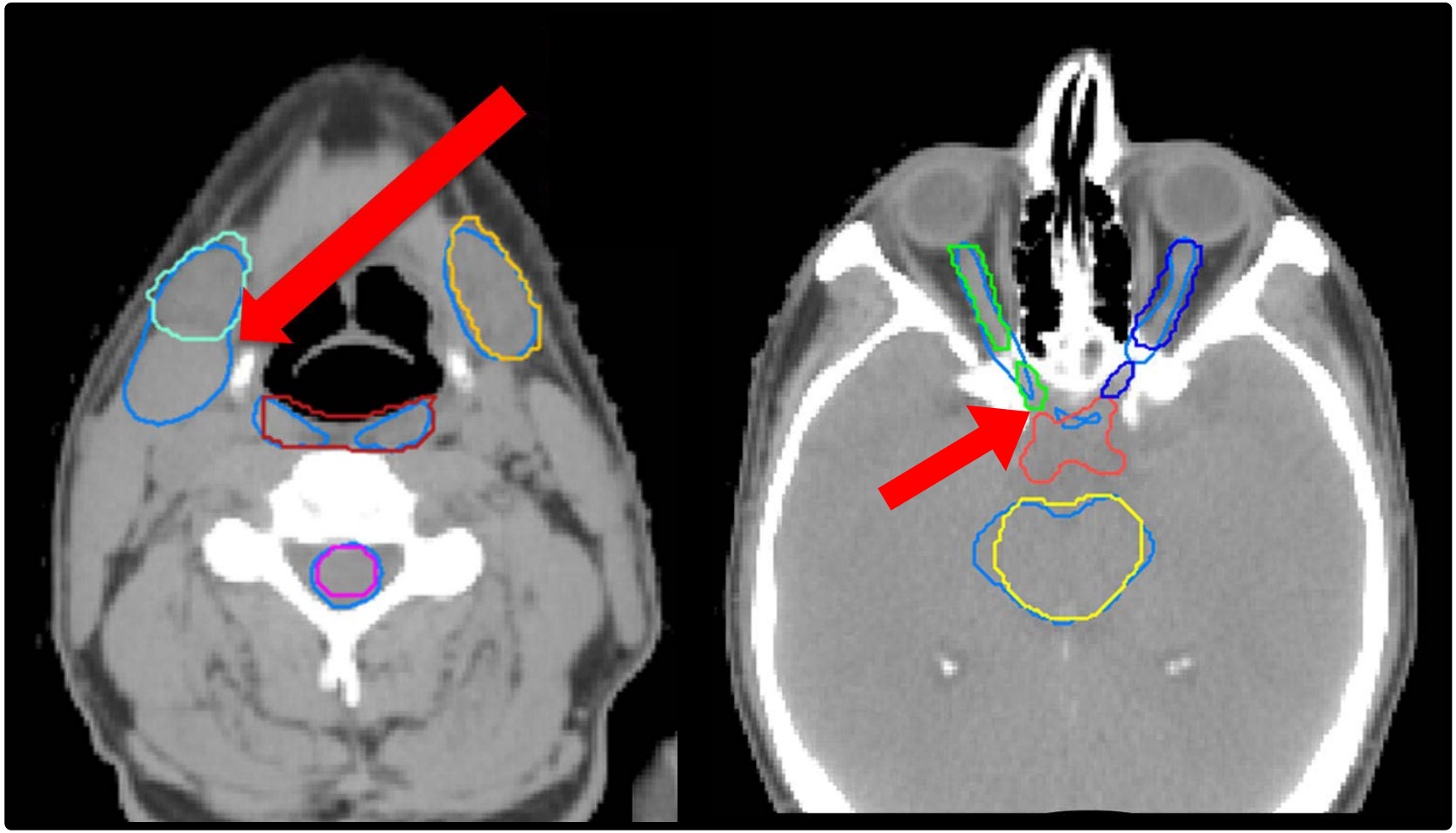

Walker et al. *Radiother Oncol* 2014;112:321-5.

Delineation of optic structures

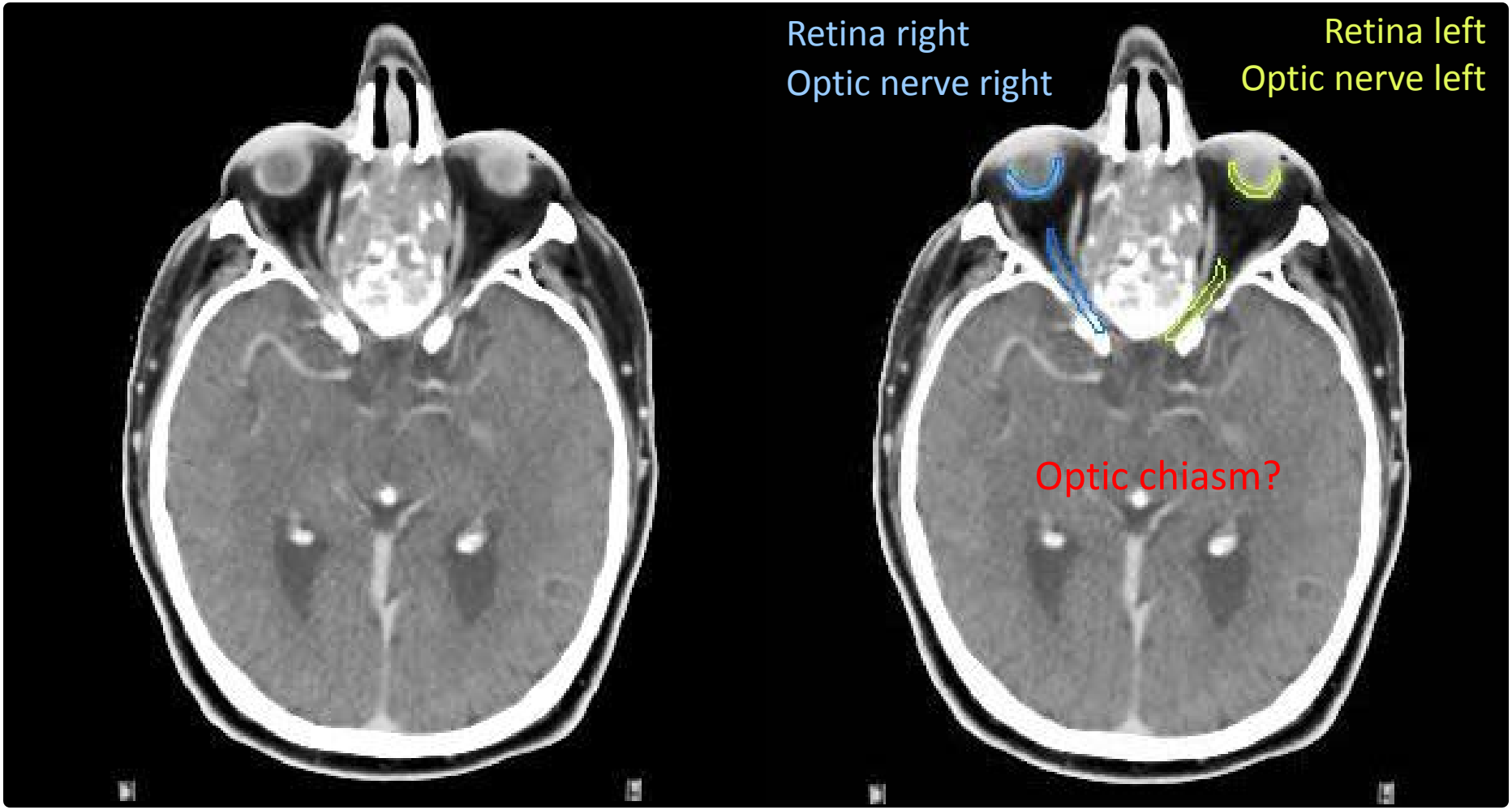

Delineation of optic structures

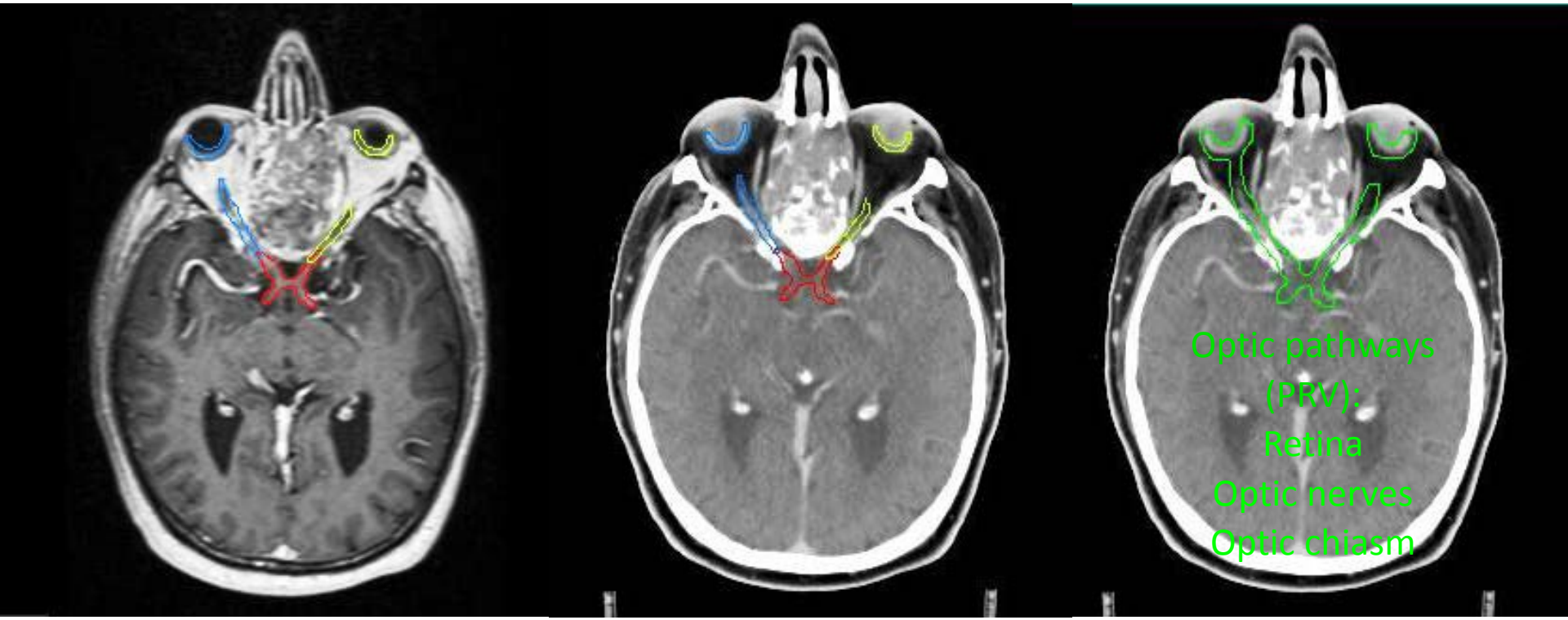

Uncommon toxicity: new OARs or the remaining volume at-risk (RVR)?

Rosenthal et al. *IJROBP* 2008;72:747-55.

Uncommon toxicity: new OARs or the RVR?

Toxicity	Toxicity rates	IMRT + chemo	Structure	Dose
Occipital scalp epilation	40%	25%	Occipital scalp	D_{max} > 30 Gy
Anterior oral mucositis	9%	22%	Anterior mandible	D_{max} > 34 Gy
Nausea	76%	98%	Brainstem	D_{mean} > 36 Gy
Emesis	38%	68%		
Hypothyroidism	65%	82%	Thyroid gland	~D_{min}
Acute fatigue G≥2 (PARSPORT)	74%	-	Posterior fossa Cerebellum Brainstem	~D_{mean} ~D_{max}

Rosenthal et al. *IJROBP* 2008;72:747-55.
Murthy et al. *Head Neck* 2014;
Gulliford et al. *Radiat Oncol* 2012;104:205-12.

Is the skin an OAR?

Med Phys. 2015 Jun;42(6):3742. doi: 10.1118/1.4926298.

TH-EF-BRD-11: Clinical Skin Toxicity Comparison and Phantom Dose Measurements for Head and Neck Patients Treated with IMRT Vs. VMAT.

Bredfeldt JS[1], Sapir E[1], Masi KJ[1], Schipper MJ[1], Eisbruch A[1], Matuszak MM[1].

Author information

Abstract

PURPOSE: Observations in our clinic have suggested a trend towards increased skin-toxicity for head and neck (HN) patients treated with Volumetric Modulated Arc Therapy (VMAT) compared with Intensity Modulated Radiation Therapy (IMRT). Here, we report on these observations and quantify surface dose differences between VMAT and IMRT treatment plans for HN cancer patients.

METHODS: We retrospectively compared skin-toxicity scores gathered by the treating physician according to the Common Terminology Criteria for Adverse Events (CTCAE v4.0) for head and neck squamous cell carcinoma (HNSCC) patients treated with IMRT (102) and VMAT (88) . A Cochran-Armitage test evaluated the relationship between treatment modality, chemotherapy and toxicity. Six patients with grade 3 skin-toxicities were selected from this cohort and the target/organ at risk volumes were transferred onto an anthropomorphic phantom using a deformable image registration based atlas (SmartSegmentation, Varian Medical). Two-arc VMAT and 9-field IMRT plans were optimized and delivered to the anthropomorphic phantom to produce similar, clinically-acceptable, dose distributions. Surface dose was measured using optically-stimulated luminescent dosimeters placed at 2 positions on the phantom's neck which were identical between VMAT and IMRT deliveries. N-factor ANOVA was performed to identify statistically significant differences in surface dose.

RESULTS: Our retrospective study showed a marginally significant higher skin-toxicity (Grade≥ 2) for VMAT compared with IMRT (35% vs.20%, p=0.06) for patients treated with radiation alone. Phantom measurements showed a significant effect of treatment modality on surface dose ($F=42.5, p<0.001$) with VMAT delivering 8% higher surface doses on average. No interaction was found between use of a thermoplastic mask and treatment with VMAT ($F=0.02, p=0.884$).

Per-treatment GTV (CT) volume changes

(observational studies)

Reference	Radiotherapy technique	Per-treatment imaging time	Δ per-treatment volume/ pretreatment volume
Fang 2001	2DRT/3DCRT	Week 5	GTV-T: -62% GTV-N: -76%
Barker 2004	2DRT/3DCRT/IMRT	3/week	GTV-T: -1.7%/day GTV-N: -1.7%/day
Yang 2010	IMRT	Week 4-5	GTVsum:-36-47%
Height 2010	IMRT	Week 5	GTV-T: -50% GTV-N: -74%

Fang et al. *IJROBP* 2001;50:961-9.
Barker et al. *IJROBP* 2004;59:960-70.
Yang et al. *IJROBP* 2011;79:1096-103.
Height et al. *J Med Imaging Radiat Oncol* 2010;54:497-504.

Per-treatment GTV (PET) volume changes

(observational studies)

Reference	Radiotherapy technique	Per-treatment imaging/autosegmentation method	Δ per-treatment volume/ pretreatment volume
Castadot 2010	IMRT	FDG-PET/ gradient-based	GTV-T Week 2,3,4,5: -3.9%/day
Troost 2010	IMRT	FLT-PET/ signal-to-background ratio	GTV-T Week 2: -4% Week 4: +19%
Hentschel 2009	3D-CRT	FDG-PET/ signal-to-background ratio	GTVsum Week 1/2: +33% Week 3/4: +51% Week 5/6: +92%

Castadot et al. *Radiother Oncol* 2010;95:209-17.
Troost et al. *J Nucl Med* 2010;51:866-74.
Hentschel et al. *Int J Radiat Biol* 2009;85:796-804.

Per-treatment GTV-T (FDG-PET/CT) volume changes

(interventional study on 3-phase adaptive IMRT)

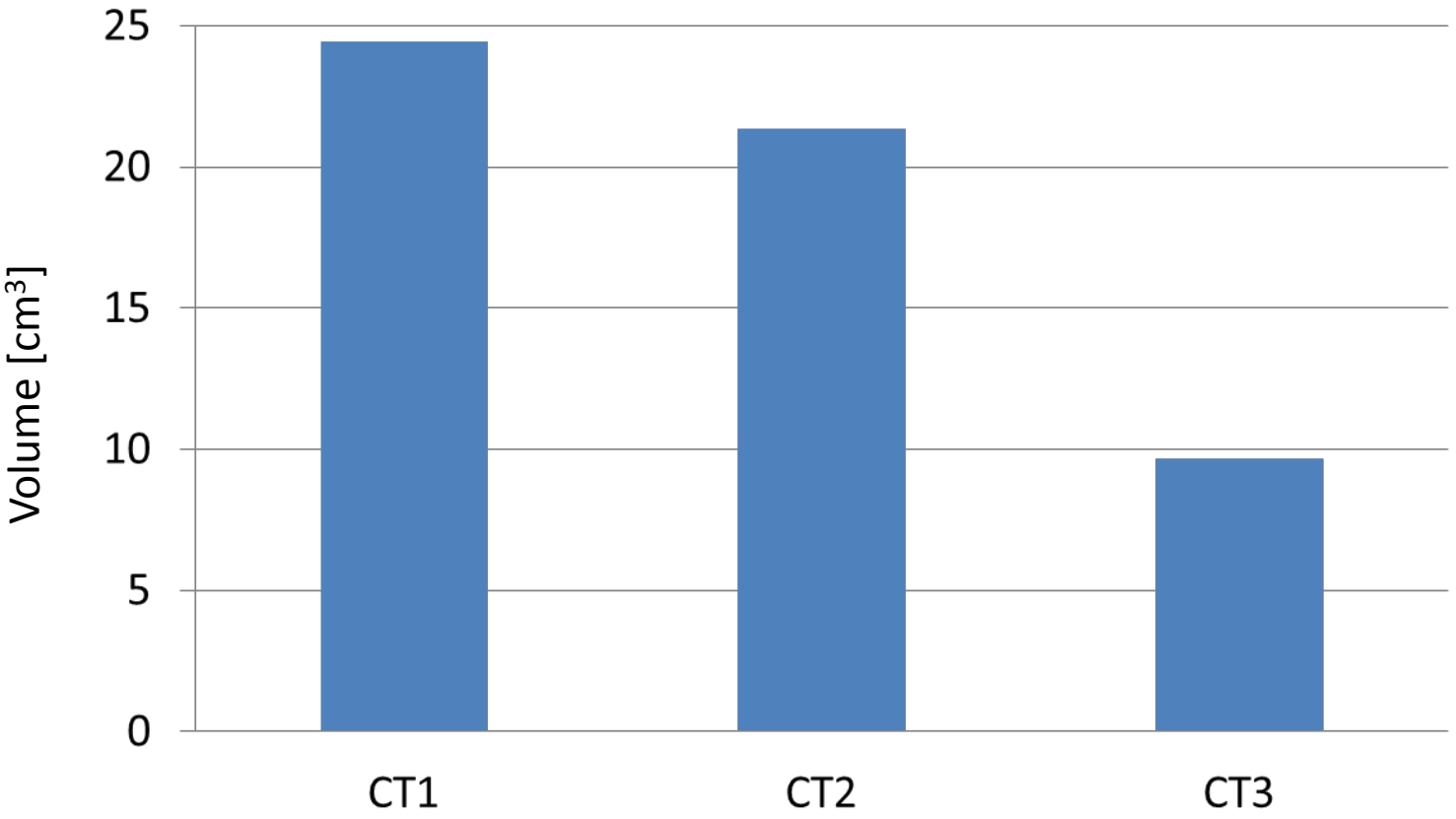

Berwouts et al. *Radiat Oncol* 2013;107:310-6.

Per-treatment GTV-T (FDG-PET/CT) volume changes

(interventional study on 3-phase adaptive IMRT)

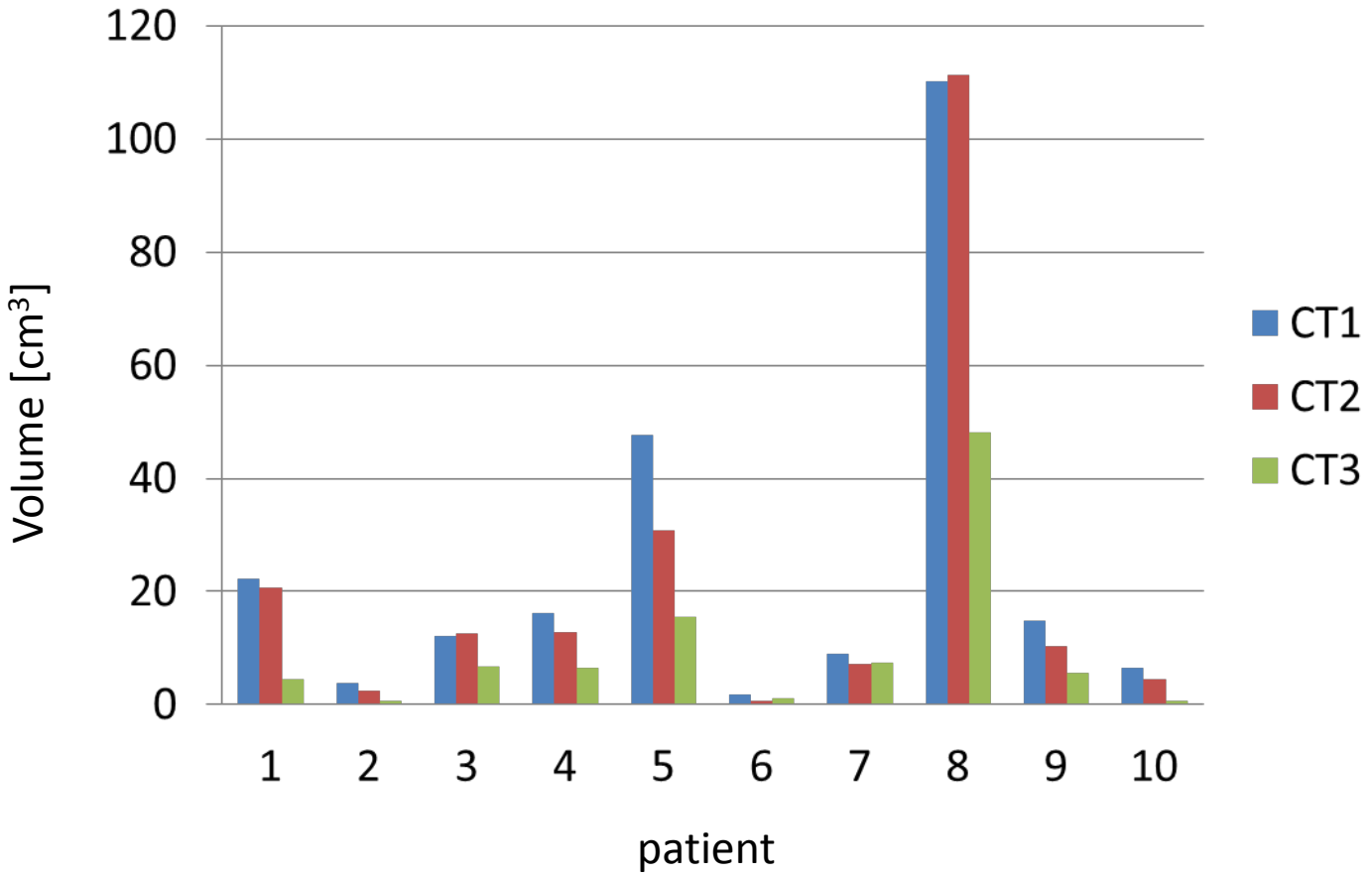

Berwouts et al. *Radiat Oncol* 2013;107:310-6.

Parotid gland volume changes during radiotherapy

Reference	Radiotherapy technique	Per-treatment imaging time	Δ pretreatment volume/ per-treatment volume
Barker 2004	2DRT/3DCRT/IMRT	3/week	-0.6%/day
Nishimura 2006	IMRT	Week 3-4	-25%
Castadot 2010	IMRT	Week 2,3,4,5	Ipsilateral: -0.9%/day Contralateral: -1%/day
Ahn 2010	IMRT	Week 3	-24%

Barker et al. *IJROBP* 2004;59:960-70.
Nishimura et al. *IJROBP* 2006;64:355-62.
Castadot et al. *Radiother Oncol* 2010;95:209-17.
Ahn et al. *IJROBP* 2010;80:677-85.

Parotid gland volume changes during adaptive radiotherapy

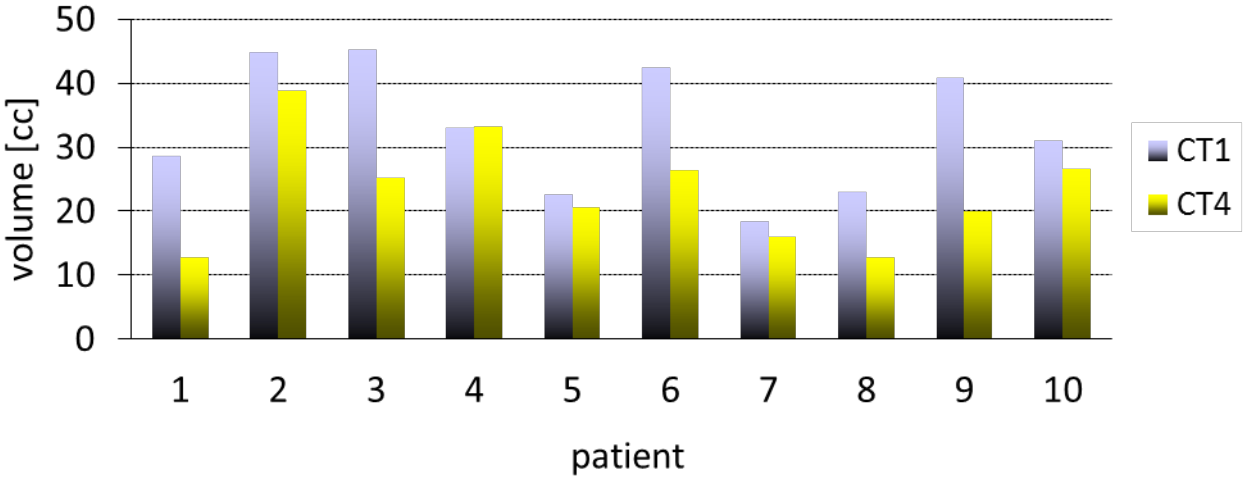

Ipsilateral gland

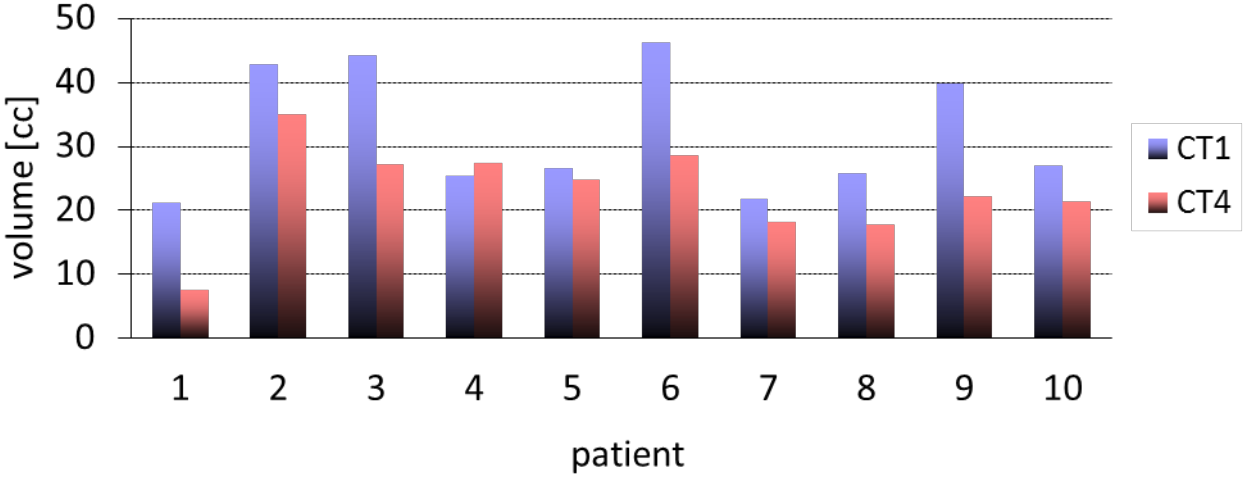

Contralateral gland

Berwouts et al. *Radiat Oncol* 2013;107:310-6.

Adaptive radiation therapy

"Adaptive radiotherapy is a close-loop radiation treatment process where the treatment plan can be modified using a systematic feedback of measurements."

(Yan et al, 1997)

Measurements:

- Tumor & OAR anatomy (position, shape & volume):
  - Intra-fraction
  - Inter-fraction.
- Tumor & OAR biology (multiparameter biologic image-defined).
- Treatment dose.

Yan et al. *Phys Med Biol* 1997;42:123-32.

Adaptive IMRT: trigged (anatomic changes)

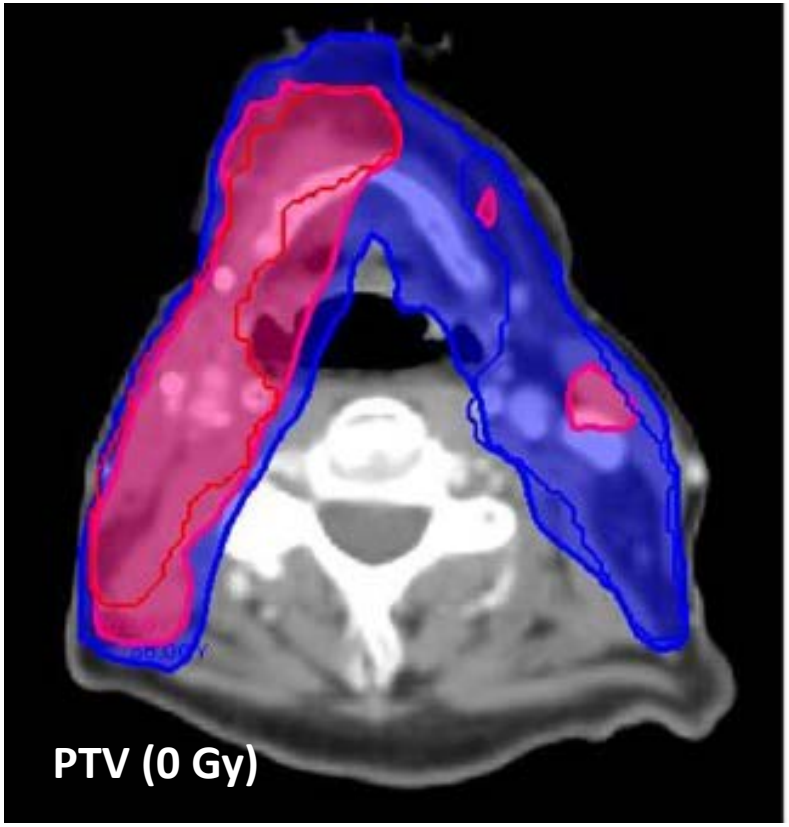

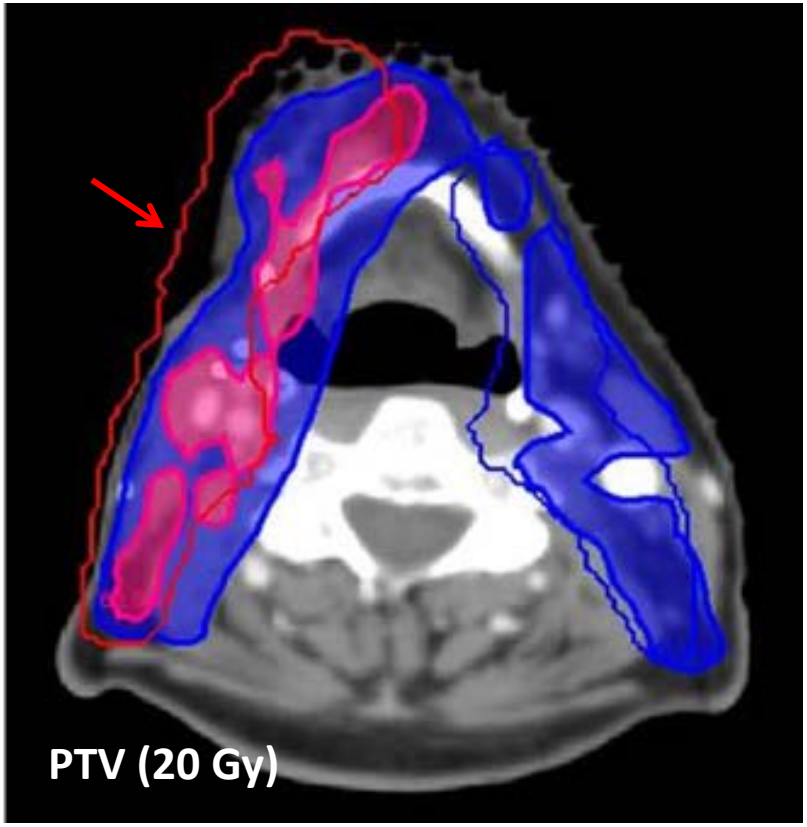

Chen et al. *Head Neck* 2014; 83:986-93.

Adaptive IMRT: trigged (dose)

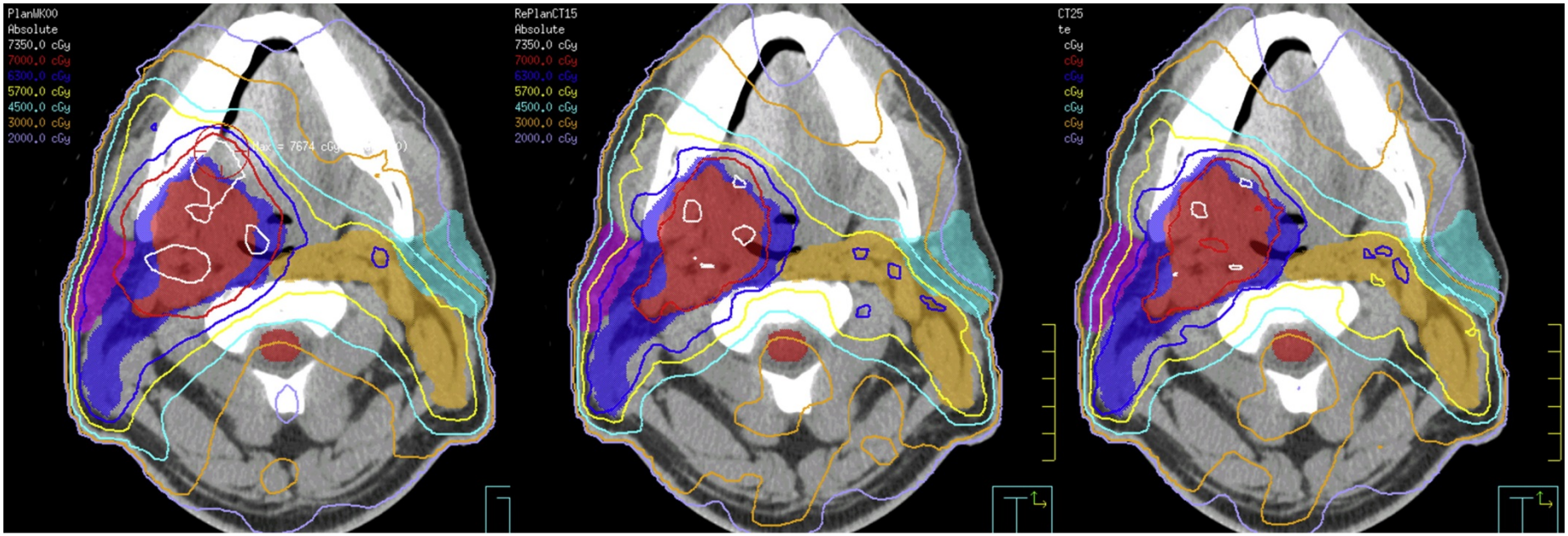

Orig.plan

1st replan

2nd replan

Schwartz et al. *IJROBP* 2012;83:986-93.

Adaptive IMRT: planned (biologic changes)

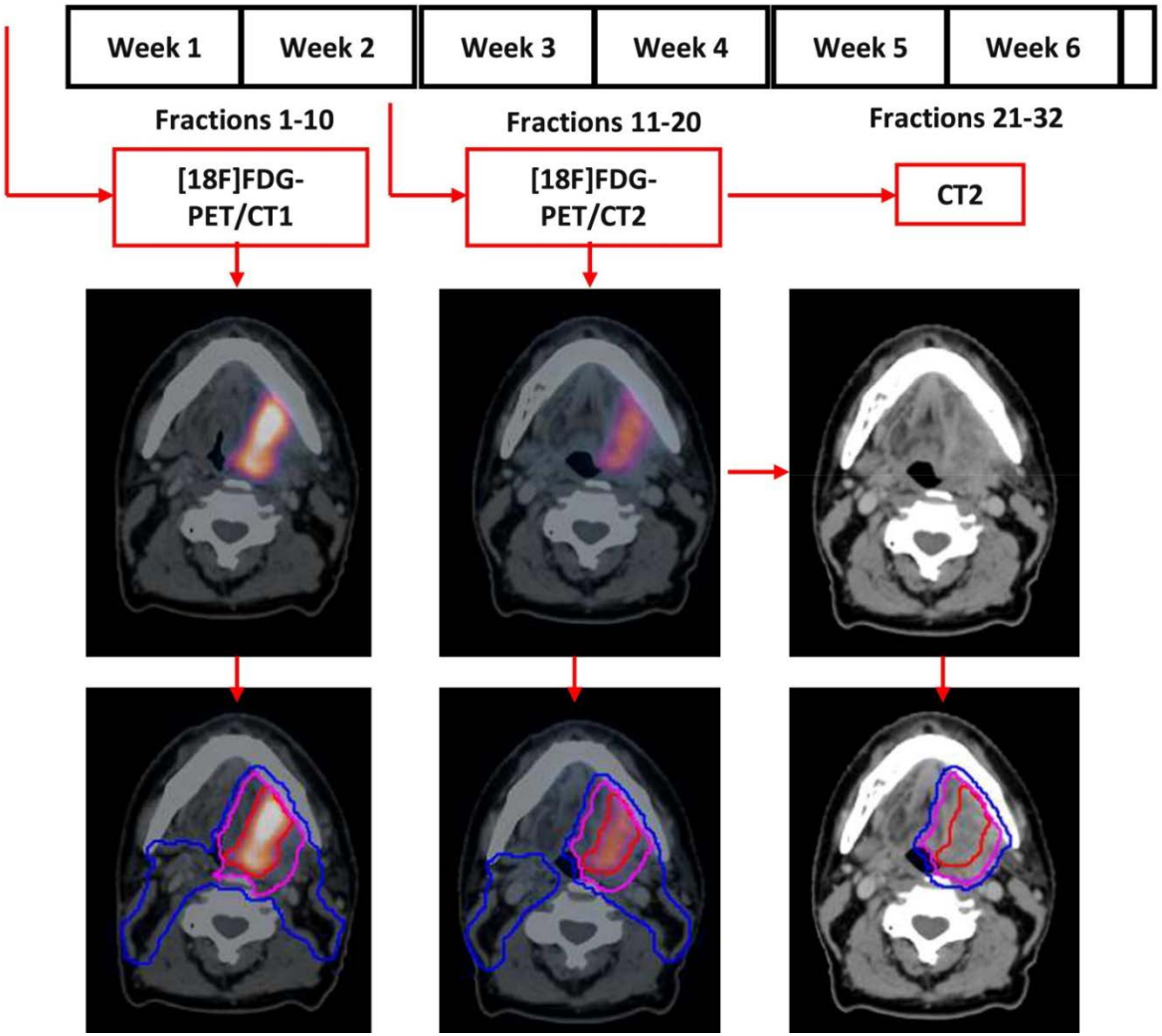

Duprez et al. *IJROBP* 2011;80:1045-55.

Adaptive IMRT

End-point/measurement	Trigged		Planned
	Anatomic	Dose	Biologic
	n = 51	*n*=22	*n* = 21
Tumor site: oropharynx	22 (43%)	22 (100%)	11 (52%)
Other	29 (57%)	-	10 (48%)
Median follow-up (month)	30	31	25
2-year local control	-	100%	95%
2-year regional control	-	95%	93%
2-year locoregional control	78%	-	-
Topography of locoregional recurrence	4 high-dose PTV	Not reported	2 GTV (PET) 1 Elective neck

Chen at al. *Head Neck* 2014;83:986-93.
Schwartz et al. *IJROBP* 2012;83:986-93.
Madani et al. *Radiother Oncol* 2011;80:1045-55.

Adaptive radiation therapy: what to consider

- Choice of mesurements:
  - Anatomic changes
  - Biologic changes
  - Dose
- Defining target volumes:
  - The pretreatment GTV/CTV
  - The pretreatment GTV/CTV adapted to changed OARs
  - The new GTV & the pretreatment CTV
  - The new GTV/CTV
- Delineation method:
  - Manual
  - Autopropagation (autosegmentation)
- Treatment planning, dose accumulation & reporting
- Resources

Take home messages

- FDG-PET is value-added in the GTV-T determination.
- Contrast CT is sufficient to define the GTV-N.
- The CTV-T margins are defined by an institutional or study protocol.
- The CTV-N margins are 10 mm for IMRT & 13-15 mm for 3D-CRT.
- The consensus 2015 guidelines specify OAR delineation.
- Per-treatment target & OAR volume changes are individual.
- Adaptive radiotherapy should become a standard, though a comprehensive treatment protocol should be thought out first.

Post Scriptum

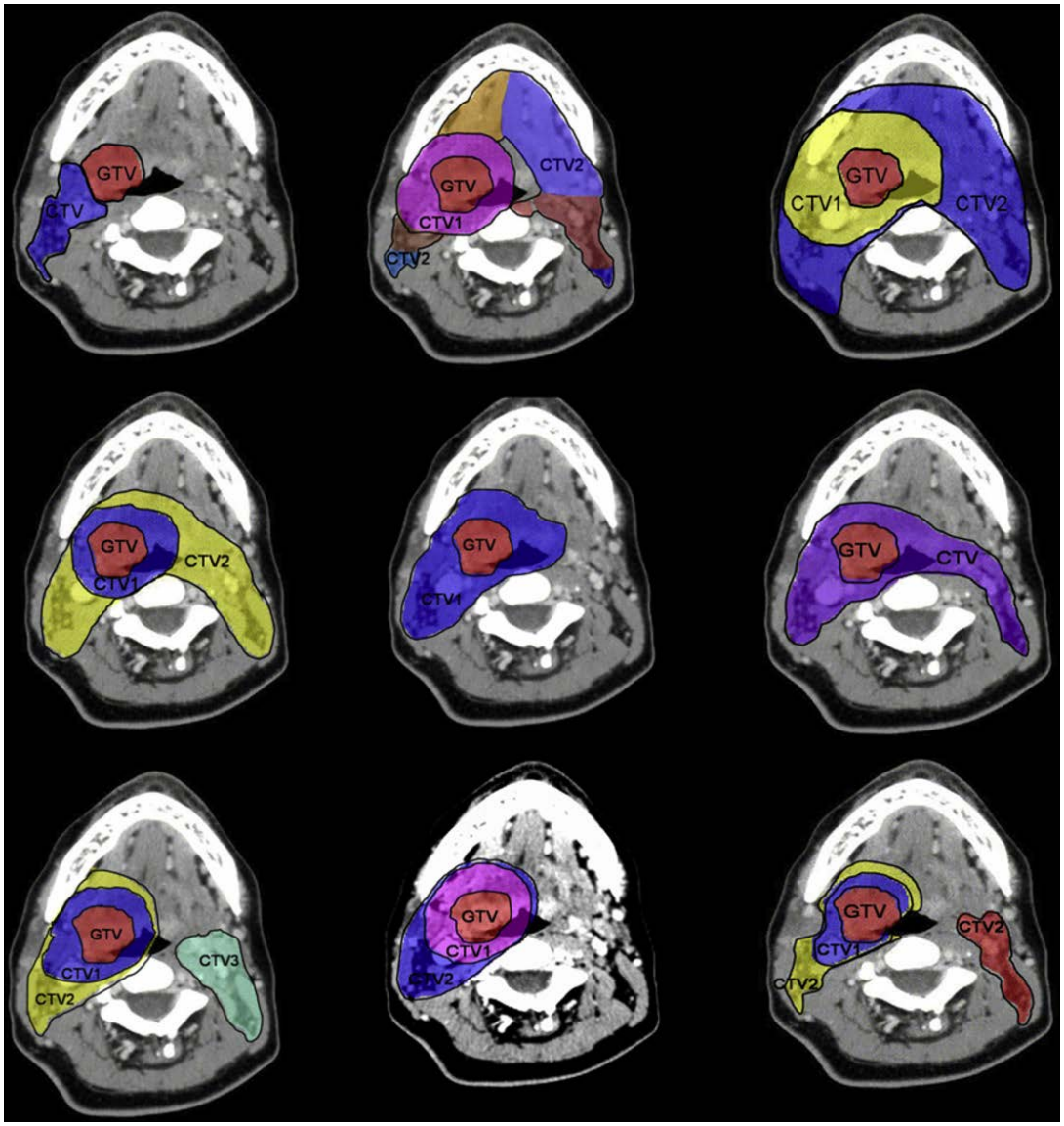

Hong, Tome, Harari. *Radiat Oncol* 2012;103:92-8**.**

ESTRO Course: Target Volume Definition

Imaging for Determining the Gross Tumor Volume (GTV): CNS Tumors

Stefan Delorme

dkfz.

Learning Objectives

- To understand potential and limitations of CT, MRI and PET for detection and characterization of CNS tumors
- CT
- MRI
- PET/CT
- Functional imaging

dkfz.

CT

- Not state-of-the-art for diagnosis, esp. low grade glioma
- For planning purposes and emergencies
- Only if MRI not possible or available
- Exceptions:
  - High grade glioma
  - Meningioma
  - AVMs

dkfz.

Slice orientation

dkfz.

Image contrasts

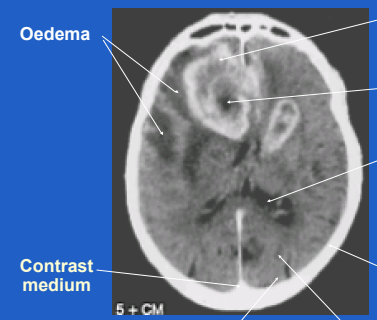

dkfz.

Slice by slice...

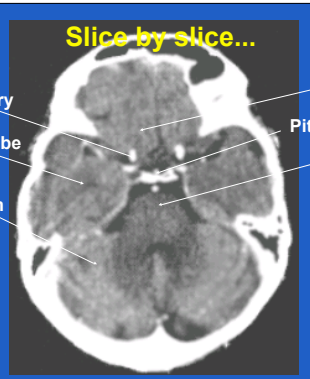

dkfz.

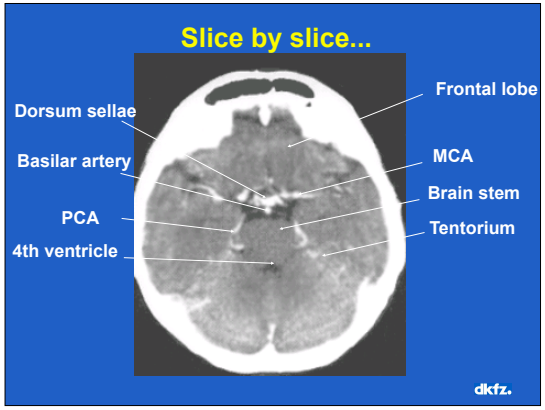
Slice by slice...
Dorsum sellae
Basilar artery
PCA
4th ventricle
Frontal lobe
MCA
Brain stem
Tentorium
dkfz.

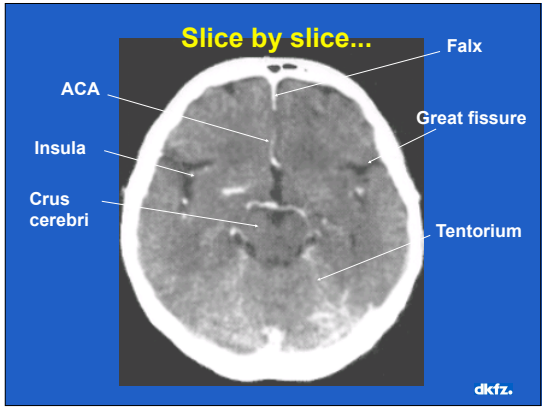
Slice by slice...
ACA
Insula
Crus cerebri
Falx
Great fissure
Tentorium
dkfz.

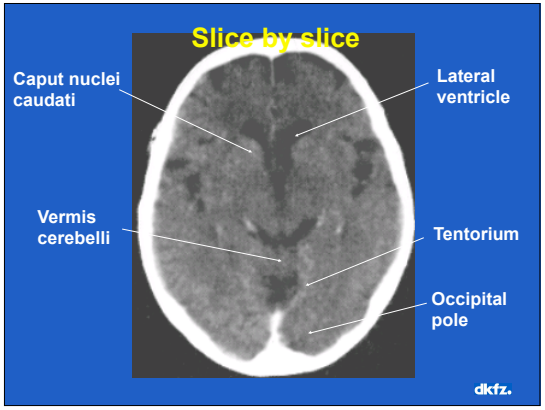
Slice by slice
Caput nuclei caudati
Vermis cerebelli
Lateral ventricle
Tentorium
Occipital pole
dkfz.

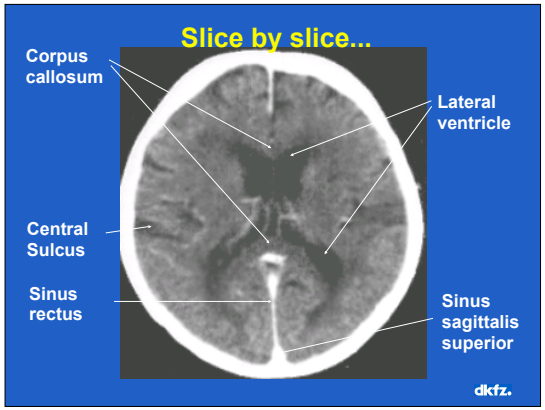
Slice by slice...
Corpus callosum
Central Sulcus
Sinus rectus
Lateral ventricle
Sinus sagittalis superior
dkfz.

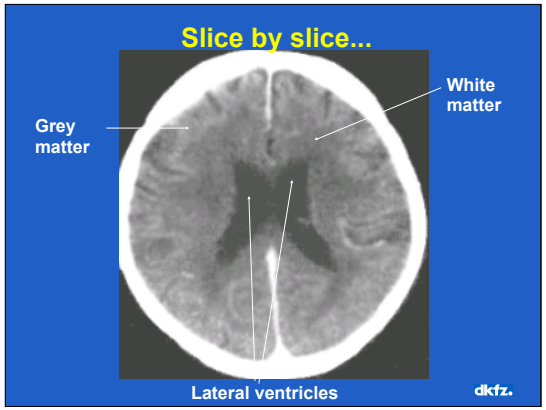
Slice by slice...
Grey matter
White matter
Lateral ventricles
dkfz.

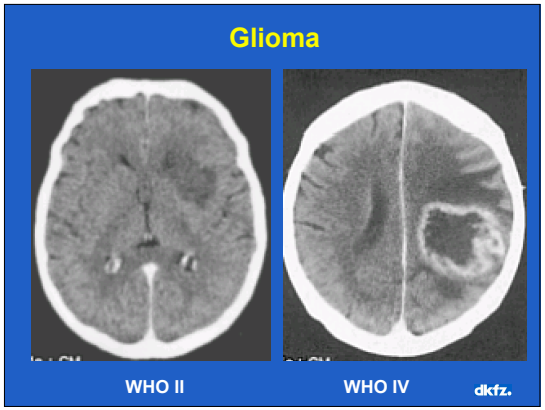
Glioma
WHO II
WHO IV
dkfz.

MRI

- State-of-the art for detection, delineation, and characterization
- Functional imaging, incl.
  - MR angiography
  - Perfusion
  - Flow
  - Neurofunctional MRI (BOLD)
  - Diffusion imaging (DWI+DTI)
  - MR spectroscopy

dkfz.

Image contrasts: T1-weighted

Bright:

Short T1:
- Fat
- Hematoma (depending on age !)
- Contrast medium: Disturbance of blood-brain barrier
- Proteins

Dark:

Long T1:
- Water
- Bone, Calcium

Moving blood

Air

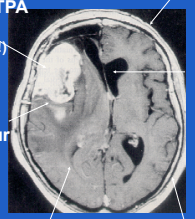

dkfz.

Image contrasts: T2-weighted

Bright:

Long T2:
- Fat
- Hematoma (Methemoglobin)
- Fluid
- Most tumours

Dark:

Short T2:
- Contrast medium
- Bone, Calcium
- Hematoma (Hämosiderine)

Moving blood

Air

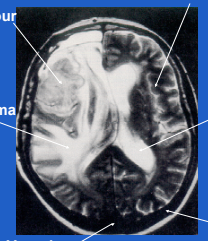

dkfz.

Image Contrasts: FLAIR

FL uid
A ttenuated
I nversion
R ecovery

= T2 with dark fluid

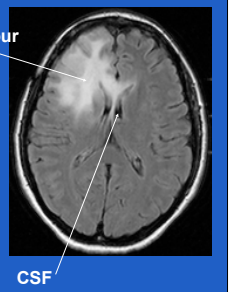

dkfz.

Image contrasts: Proton-weighted

Bright:
- Fat
- Fluid
- Tumours

Dark:
- Blood flow
- Air
- Bone

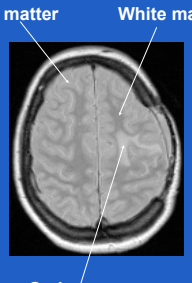

dkfz.

Intracranial tumors

- **Intraaxial**
  - Supratentorial
    - Glioma
    - Lymphoma
    - Metastases
  - Infratentorial
    - Glioma
    - Medulloblastoma
    - Ependymoma
    - Hemangioblastoma
- **Extraaxial**
  - Supratentorial
    - Meningioma
    - Pituitary adenoma
    - Bone tumors
    - Meningial metastases
  - Infratentorial
    - Schwannoma
    - Meningioma
    - Epidermoid
    - Chordoma

dkfz.

CT and MRI

- Grade II glioma, supratentorial, intraaxial

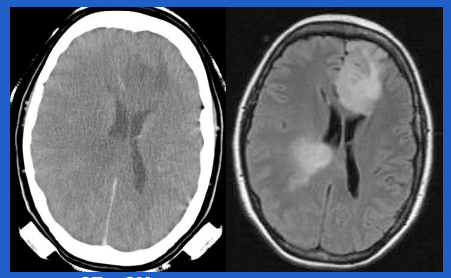

CT + CM FLAIR

dkfz.

CT and MRI

- Oligodendroglioma, supratentorial, intraaxial

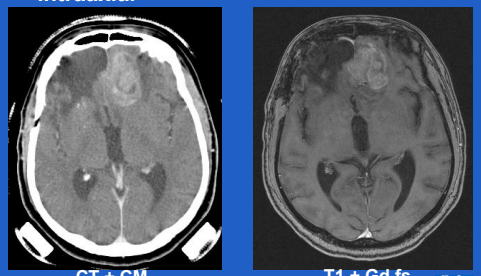

CT + CM T1 + Gd fs

dkfz.

CT and MRI

- Metastasis, supratentorial, intraaxial

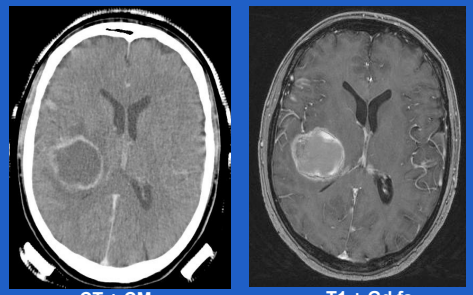

CT + CM T1 + Gd fs

dkfz.

CT and MRI

- Meningioma, supratentorial, extraaxial

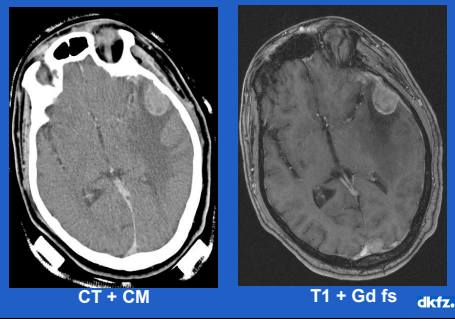

CT + CM T1 + Gd fs

dkfz.

MRI: Value of FLAIR

- Delineation: recurrent glioma

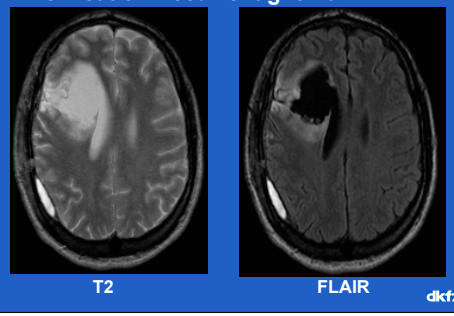

T2 FLAIR

dkfz.

Grading of gliomas

dkfz.

Pilocytic Astrocytoma

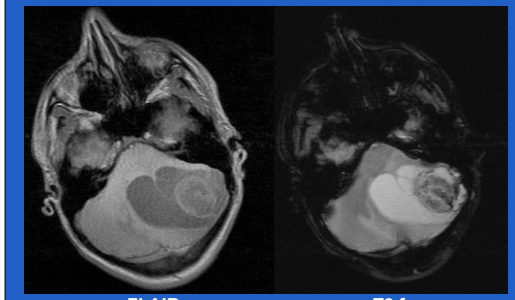

FLAIR T2 fs

dkfz.

Pilocytic astrocytoma

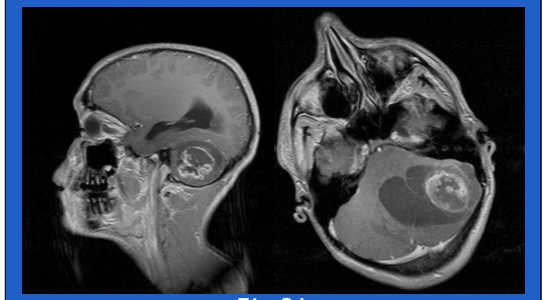

T1 + Gd

dkfz.

Fibrillary Astrocytoma (WHO II)

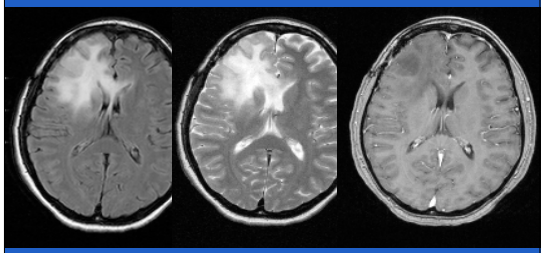

dkfz.

Anaplastic Astrocytoma (WHO III)

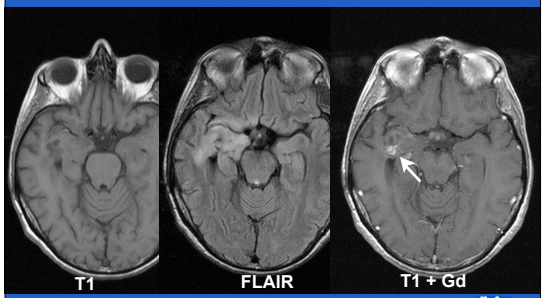

T1 FLAIR T1 + Gd

dkfz.

Oligodendroglioma

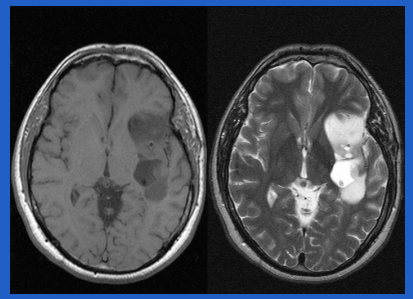

T1 T2

dkfz.

Oligodendroglioma

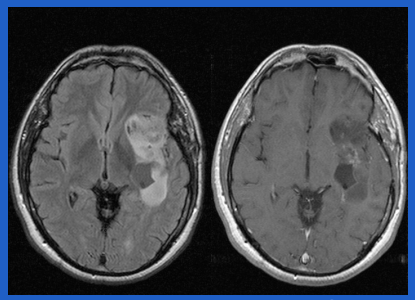

FLAIR T1 + Gd

dkfz.

Glioblastoma = Grade IV glioma

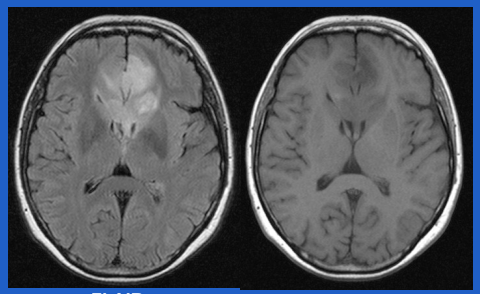

FLAIR T1

dkfz.

Glioblastoma

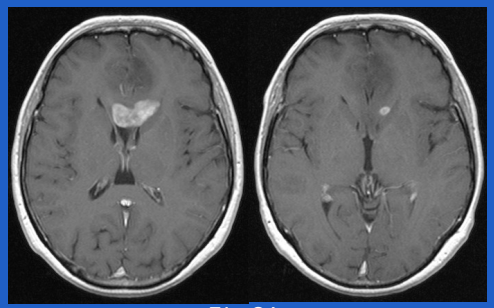

T1 + Gd

dkfz.

Glioblastoma

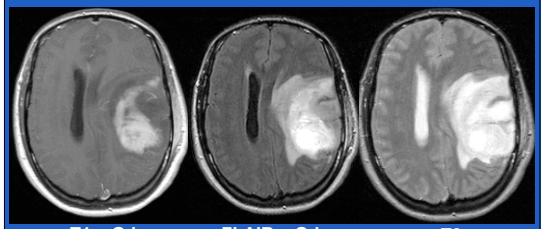

T1 + Gd FLAIR + Gd T2

dkfz.

Major problems

- True extent of tumour
  - Oedema or Tumor?
  - Tumour in seemingly normal brain tissue?
- Heterogeneity of tumours
  - Grade III components without BBB disturbance
  - BBB disturbance or neovascular changes?
- Treatment-induced changes
  - T2 hyperintensities
  - BBB disturbance

dkfz.

True extent of tumour

- Gliomas:
  - Grade II: Everything that is T2 hyperintense is tumour!
  - Grade III and IV:
    - » GTV: Contrast-enhancing area
    - » T2-hyperintensities: Grade II components plus edema -> CTV
    - » Tumour to be expected even in seemingly normal brain
- Metastases:
  - Tumor confined to contrast-enhancing area
  - T2 hyperintensities are oedema!
- Lymphoma:
  - Is a generalised CNS disease

dkfz.

Some little helpers...

- Dynamic contrast-enhanced T1w imaging
  - Malignant and vital foci
- Dynamic contrast-enhanced susceptibiltity imaging
  - Malignant foci in non-enhancing gliomas
- Spectroscopy
  - Malignant and vital foci
  - DD tumor vs. Oedema
- PET with 18-FDG, 18-FET, or 11-C-Methionine
  - Metabolically active tumour

dkfz.

Dynamic contrast-enhanced T1w imaging

dkfz.

DCE MRI of Glioma

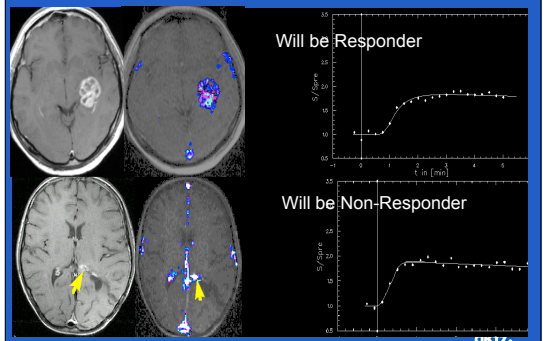

dkfz.

DCE MRI of Glioma

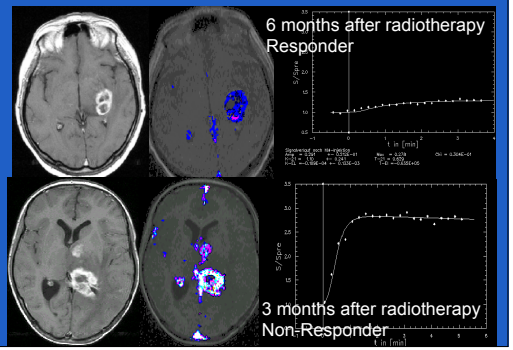

Dynamic contrast-enhanced susceptibility imaging

dkfz.

Perfusion MRI

- Grade II or Grade III?

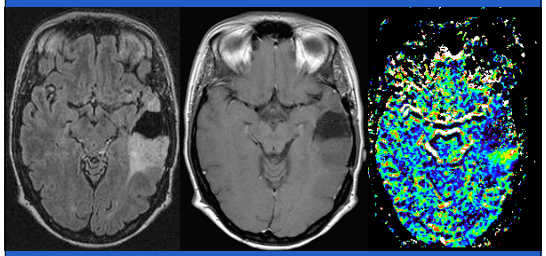

dkfz.

MRI Perfusion of Grade II Glioma

Initial Values

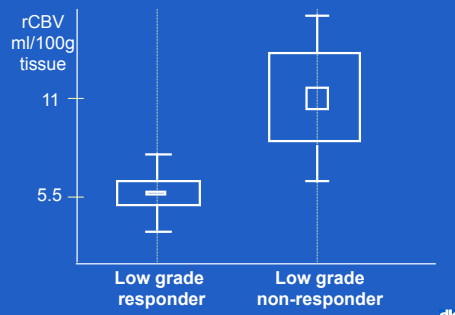

dkfz.

Spectroscopy

dkfz.

Spectroscopic imaging

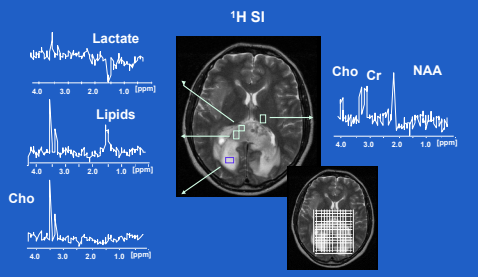

dkfz.

MR Spectroscopy

- **Glioma**

Radionecrosis Progression

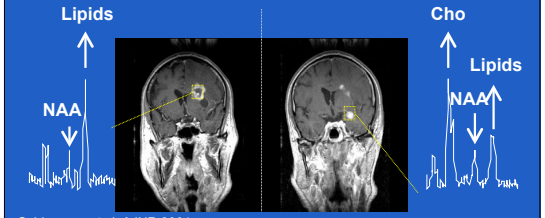

Schlemmer et al. AJNR 2001

dkfz.

Pseudoreponse

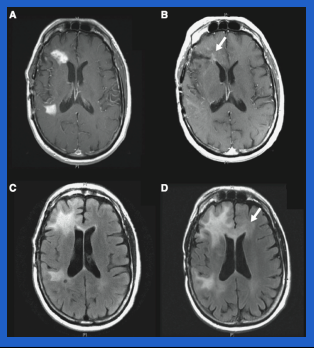

dkfz.

RANO* Response criteria in CNS tumors

Criterion	CR	PR	SD	PD
T1 Gd-enhancing disease	None	≥50% decrease	<50% decrease but <25% increase	≥25% incrase
T2/FLAIR lesion	Stable or decreased	Stable or decreased	Stable or decreased	Increased
New lesion	None	None	None	Present
Corticosteroids needed	None	Stable or less	Stable or less	N/A or more
Clinical status	Stable or improved	Stable or improved	Stable or improved	Deteriorated
Requirement for response	All	All	All	Any

** RANO = Response assessment in neuro-oncology*

Wen PN et al. JCO 28:1963-1972 (2010)

dkfz.

PET and PET/CT

- **Grading: Characterization by different tracers**
  - **11C-methionine (MET),**
  - **18F-fluoroethyl-L-tyrosine (FET)**

Grosu et al. Strahlenther Onkol 2005

dkfz.

11C-Methionine-PET

- Glioma III

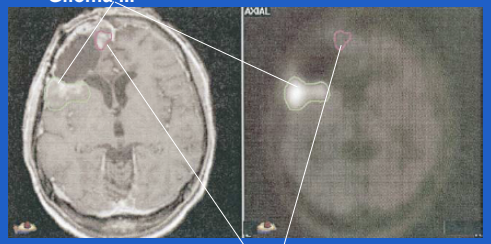

T1w post CM MET-PET

Traumatic BBB disturbance

Grosu et al. IJROBP 2005

dkfz.

Take home

- CT for dose calculation
- MRI for determination of GTV and grading
- Software-based CT/MRI fusion for planning
- PET under investigation for delineation
- Evaluation of additional contributions by functional/metabolic MRI and PET (different tracers) ongoing

CTV for gliomas

Neil Burnet & Sarah Jefferies

University of Cambridge Department of Oncology,

Oncology Centre, Addenbrooke's Hospital, Cambridge, UK

PLEASE ORDER & PAY AT THE COUNTER

CNS Tumours

Introduction

High Grade Glioma (HGG)

CTV and PTV

Low grade Glioma (LGG)

CTV and PTV

Normal tissue tolerance



Learning Objectives

To understand the concept of GTV to CTV

To understand the evidence base for
GTV to CTV in gliomas

To understand the PTV margin

High Grade Glioma (HGG)

HGG:

- Grade III = anaplastic astrocytoma
- Grade IV = glioblastoma

Management principles somewhat different

- molecular pathology now being included in grading and management decisions

CTV margins are typically the same

HGG

HGGs are intrinsic tumours

They infiltrate widely at a microscopic level

There are very few barriers to spread

CNS tumour spread is the cause of all our problems with HGG



Tumour Spread

Tumours can spread along white matter tracts

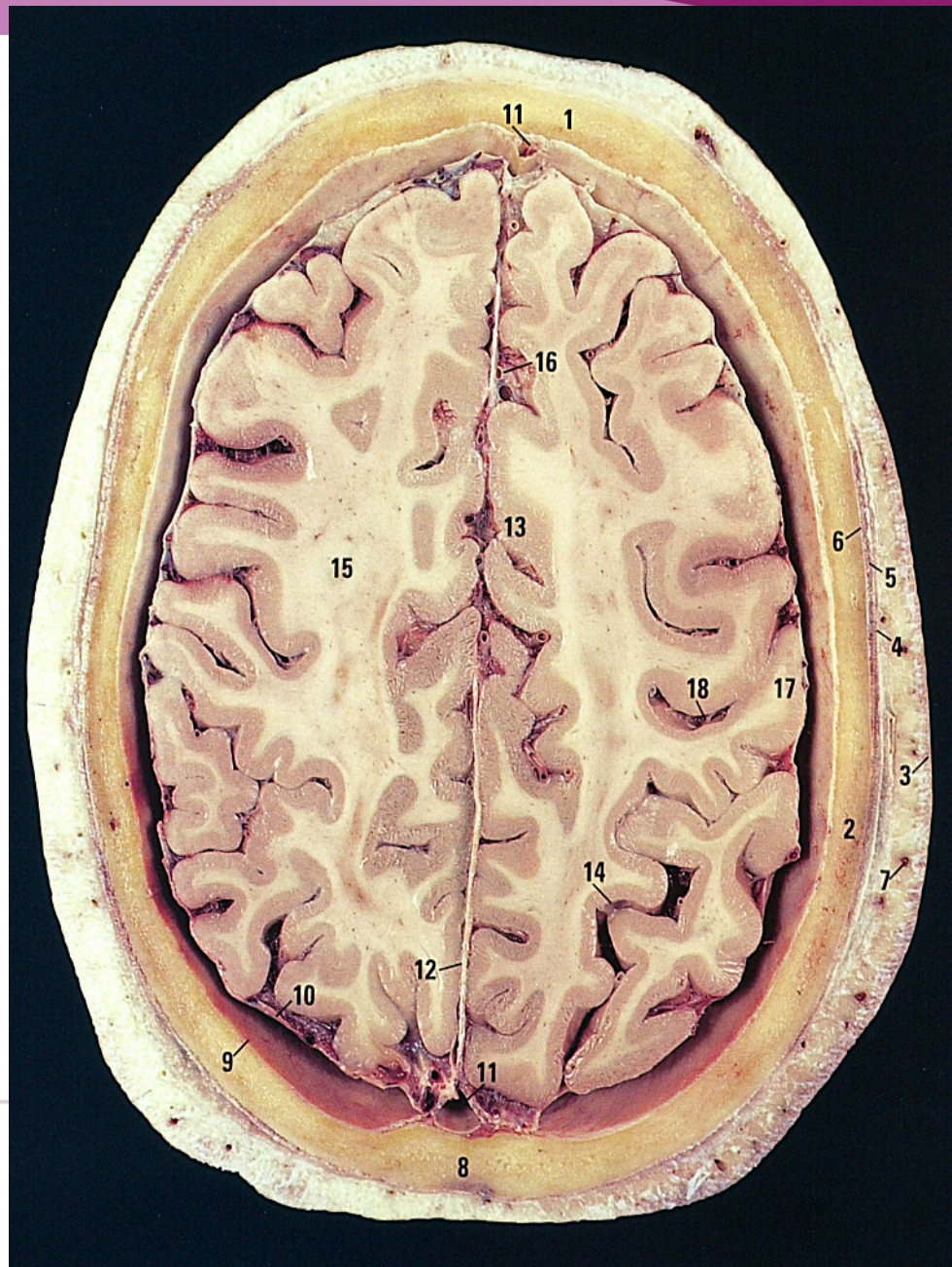

Tumour Spread

Gliomas “surf” along white matter tracts

Tumour Spread

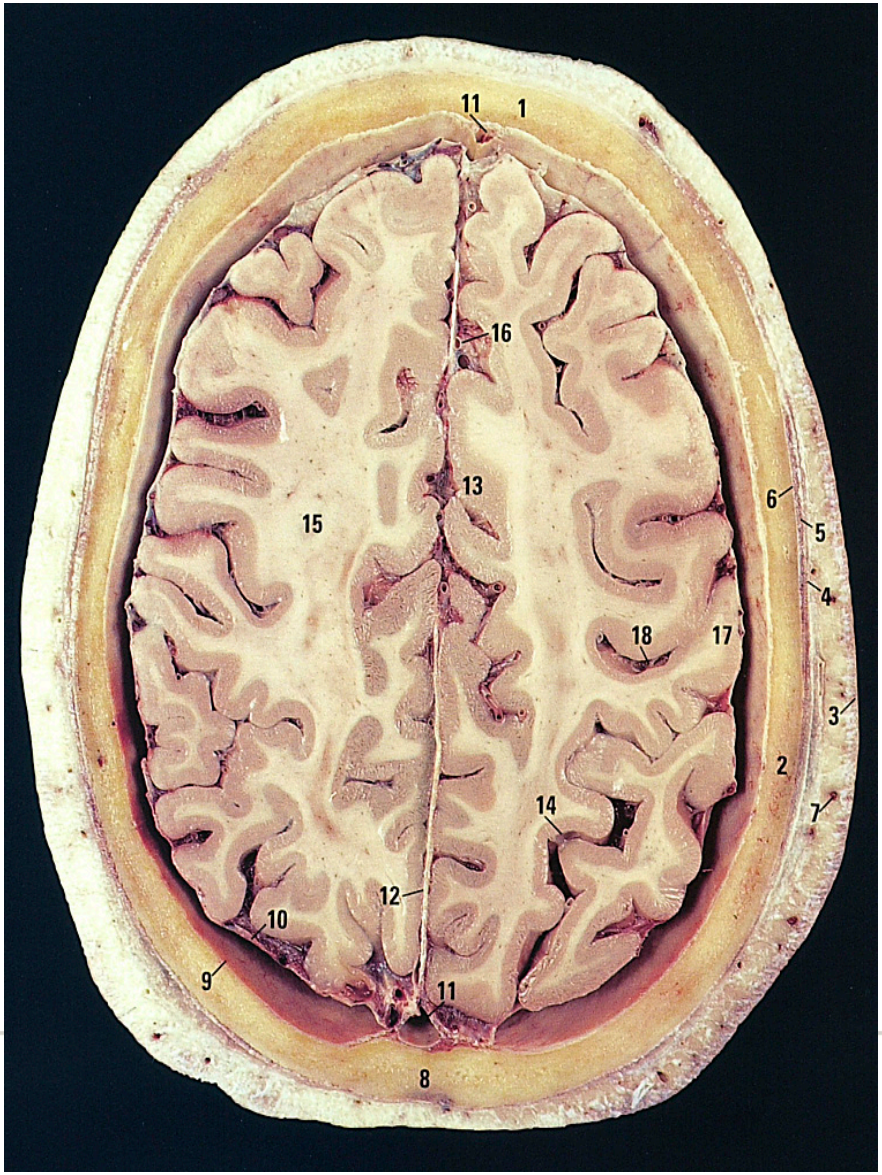

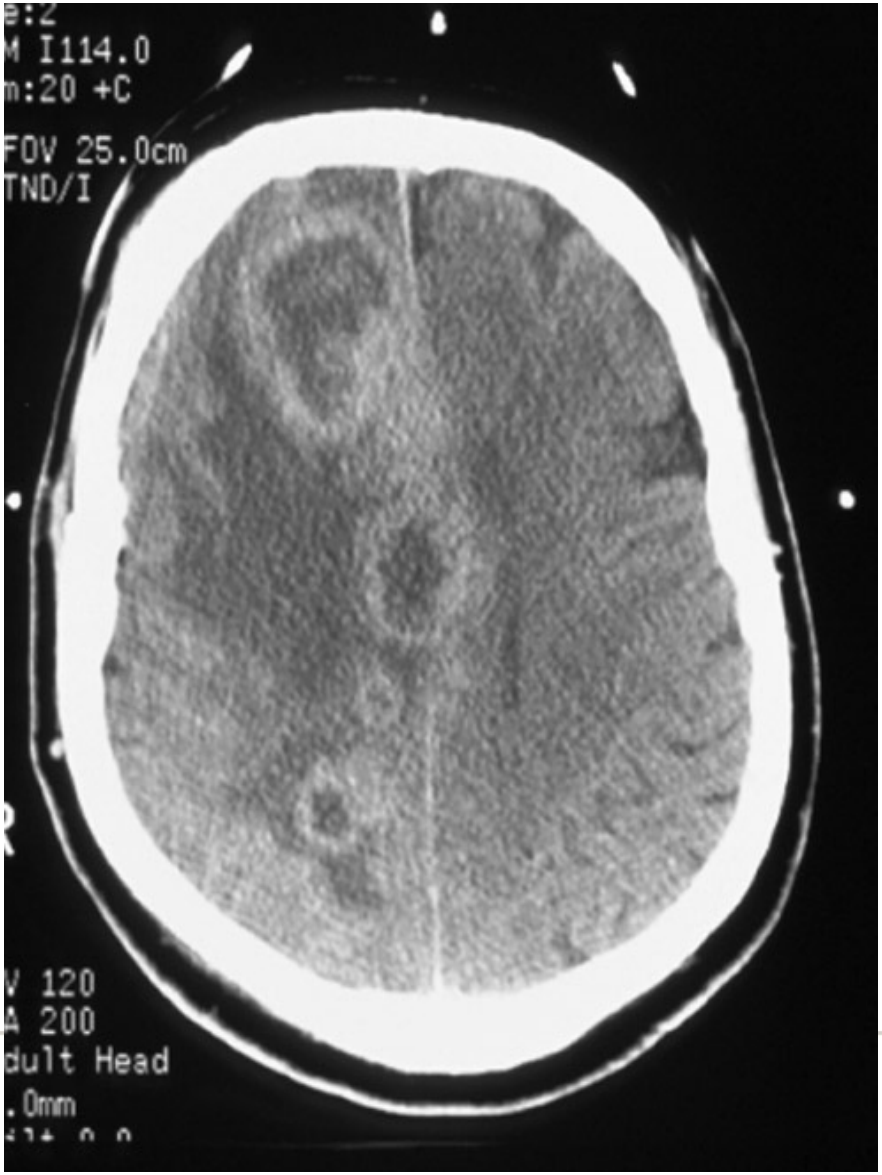

Tumour Spread

The corpus callosum is important for tumour spread

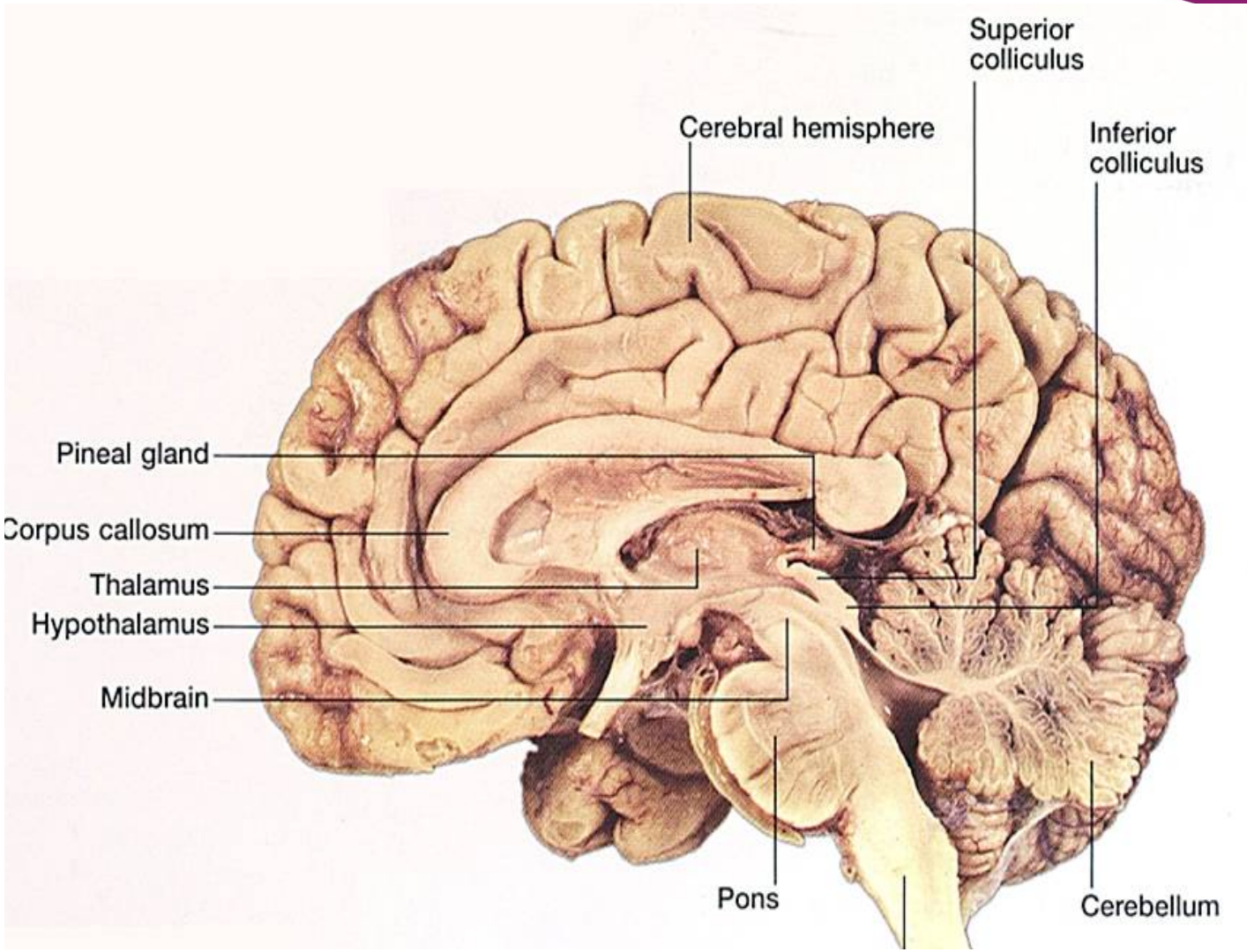

Tumour spread

Tumour spread

- Bi-frontal GBM
- Spread through corpus callosum
- Early dementia
- (*Not* for radical treatment)

Tumour spread

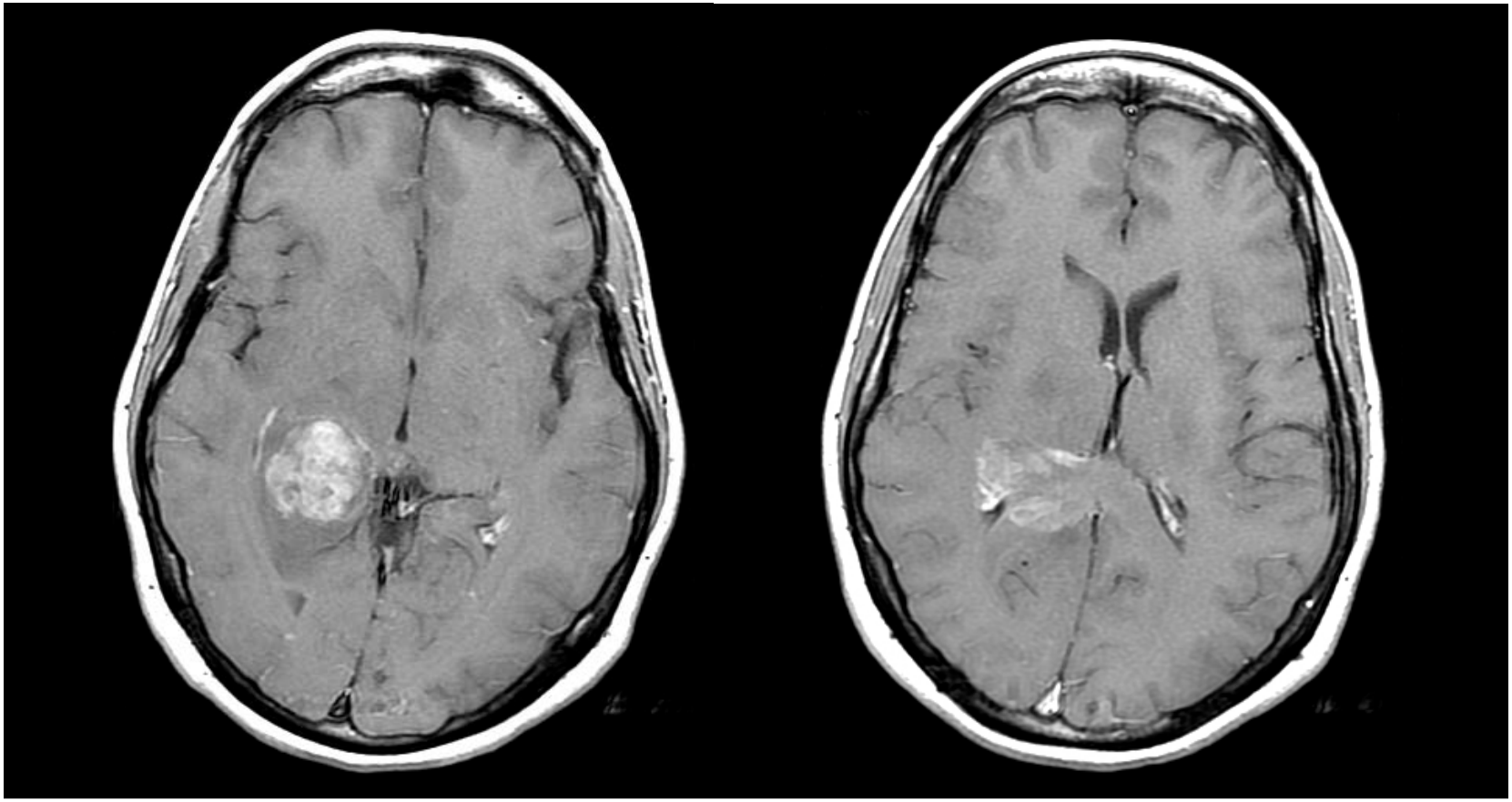

Spread through posterior corpus callosum

No barrier inferiorly, & excellent white matter pathway

Barriers

Gliomas spread through the brain

Tumours can spread up and down – as well as front to back and across

The skull, falx and tent prevent spread

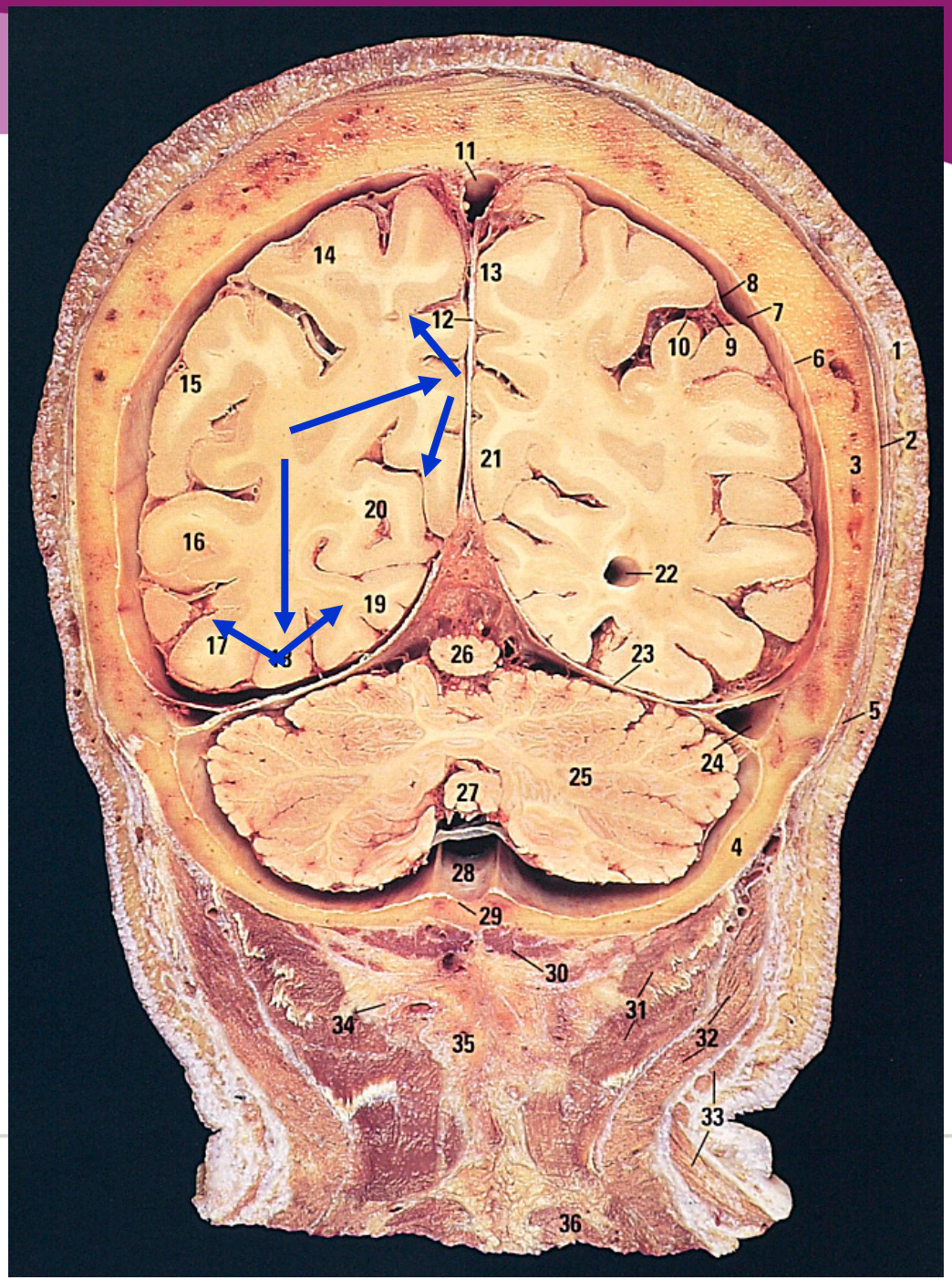

Tumour spread

Spread into corpus callosum and brain stem

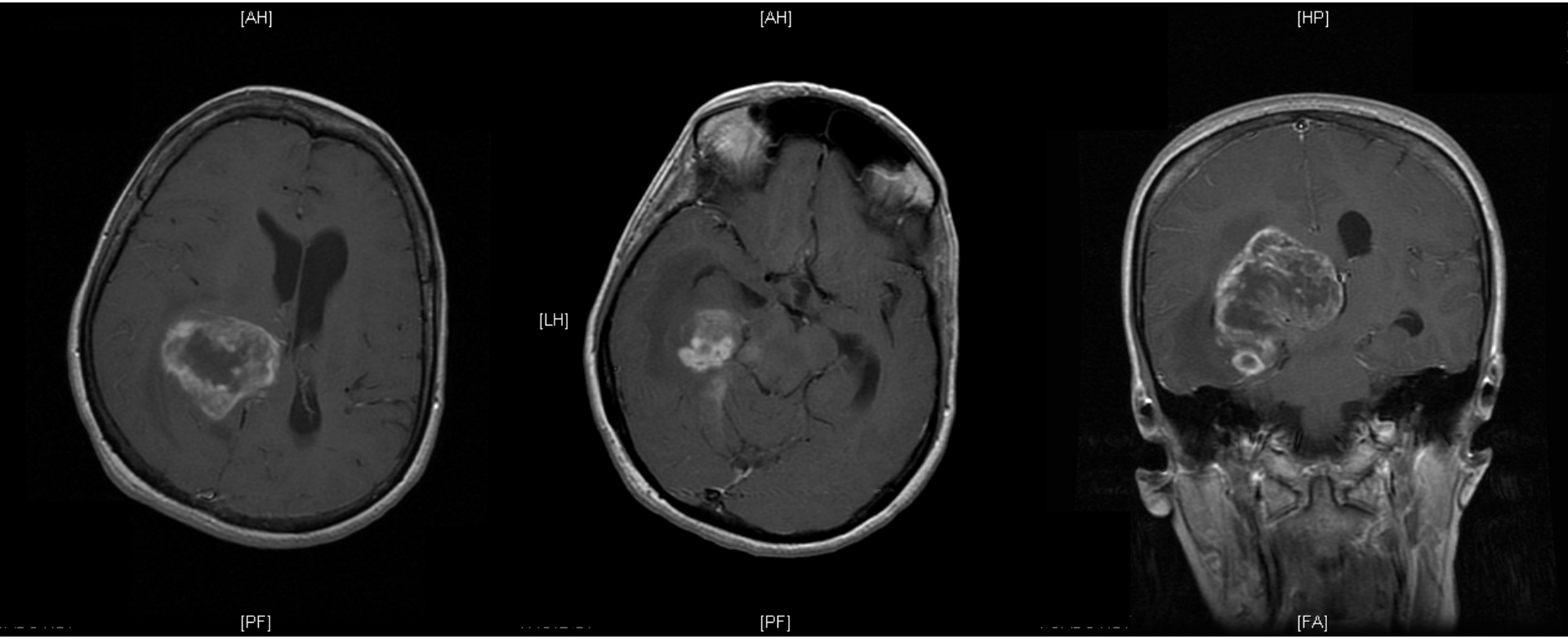

Inter-thalamic adhesion

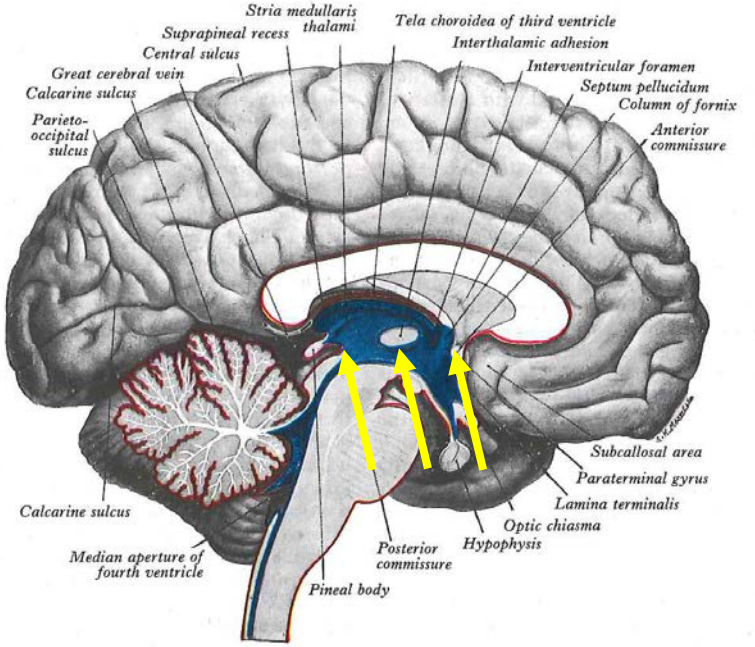

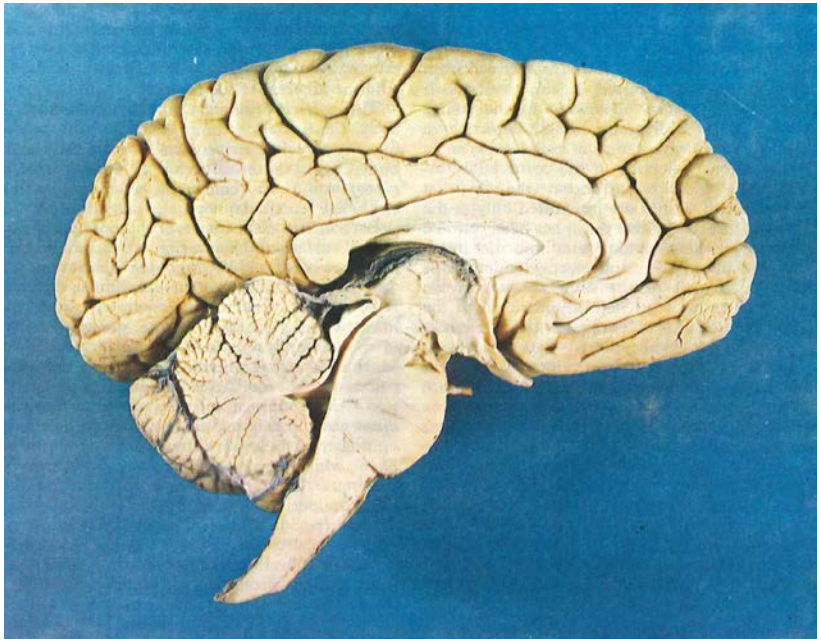

Inter-thalamic adhesion

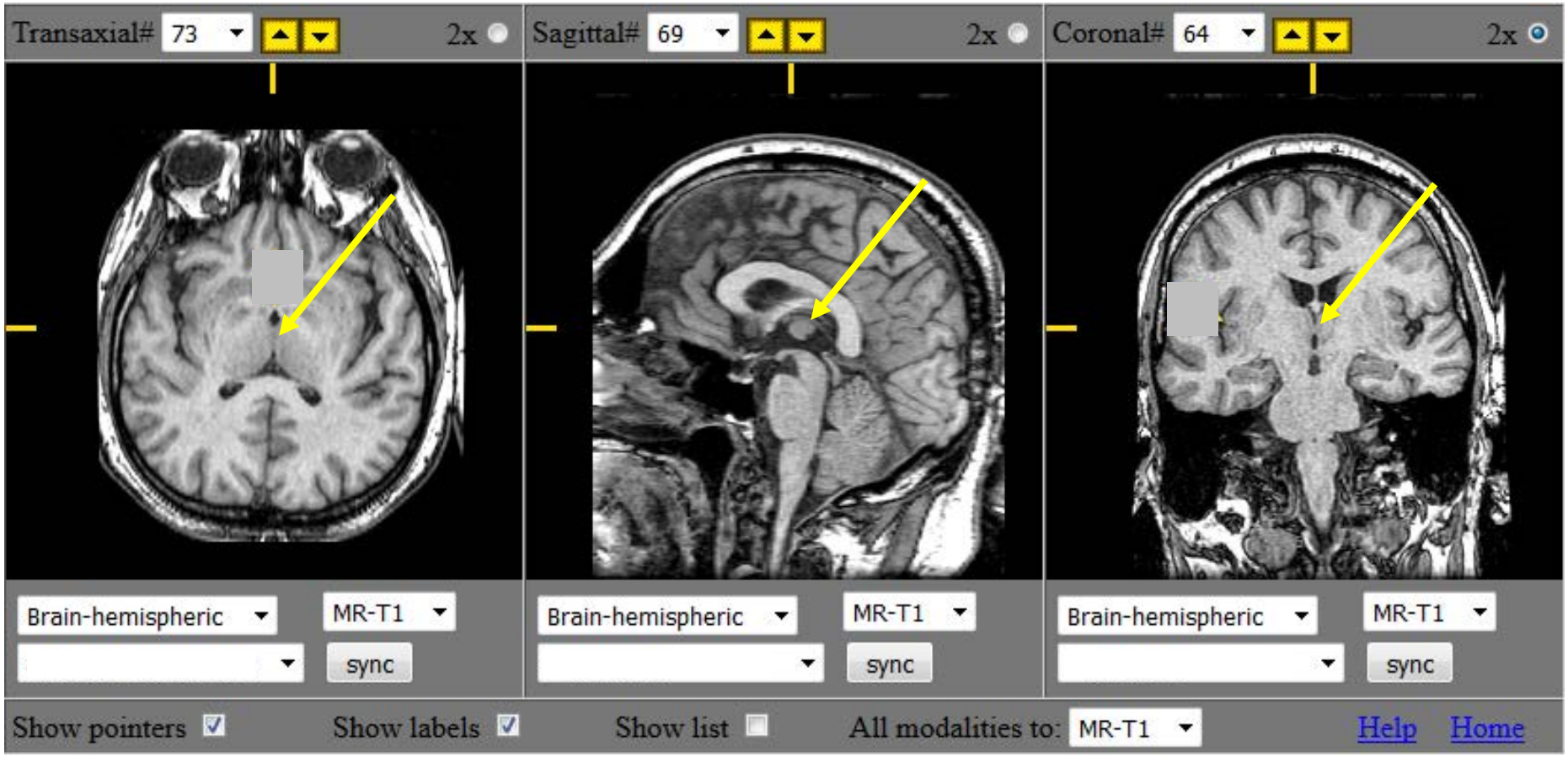

http://www.med.harvard.edu/AANLIB/cases/caseNA/pb9.htm

Tumour Spread

Tumour spread is the reason for large target volumes (ie the CTV margin) for patients with HGG

Editing CTV against anatomical boundaries makes sense

It is not as useful as you might think because of the pathways for potential spread, especially across the midline

HGG - CTV

Imaging shows gross tumour well (GTV)

Microscopic CTV not seen at all

Use optimal imaging

Need careful preparation for target volume delineation

Essentials

CT for dose calculation

MRI for GTV (select optimum sequences)

Software for CT/MRI fusion for planning

Metabolic/functional imaging may contribute in the future

HGG - GTV

Post operative imaging is preferable

- Within 72 hours can assess residual gross tumour

Debulking surgery

- Reduces the volume of the GTV
- Reduces displacement of brain

Steroids also reduce mass effect by reducing oedema

- The effect is progressive

GBM - presentation

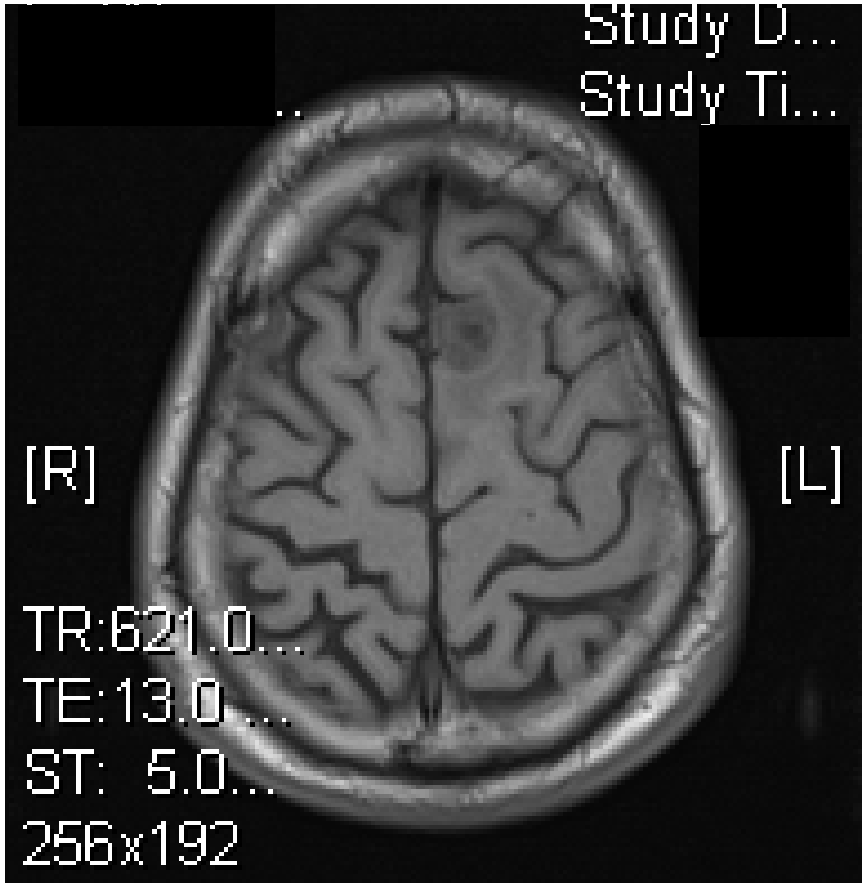

T1 no contrast

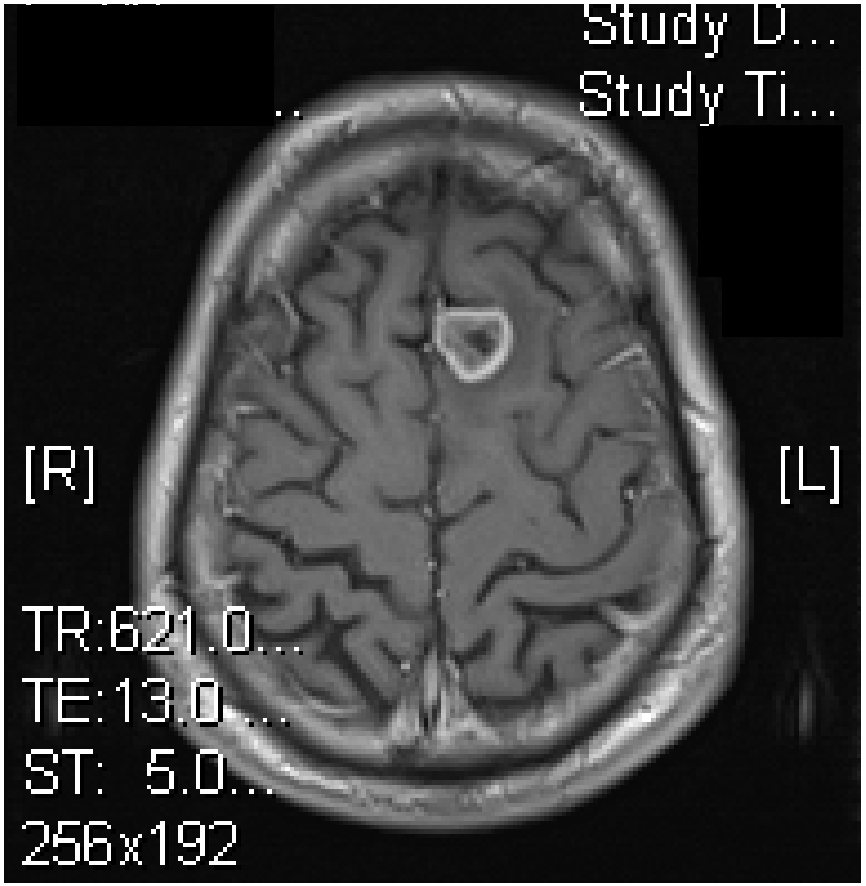

T1 + Gd

ESTRO School

GBM early post-op imaging

Post-op imaging – at 24 – 48 hours

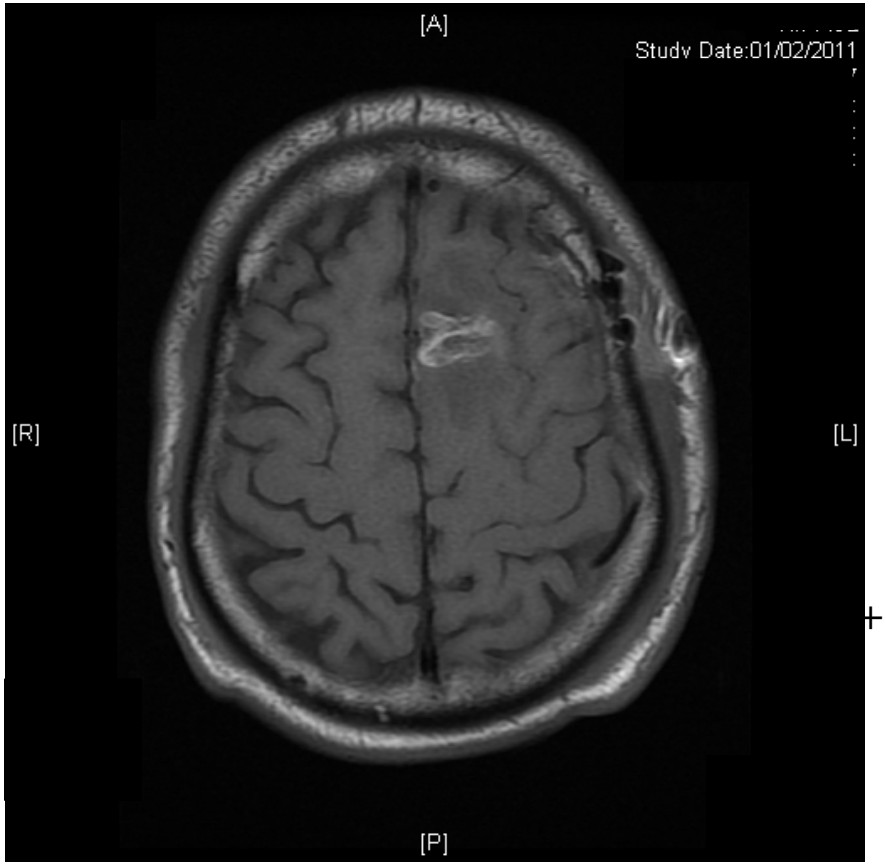

+ G

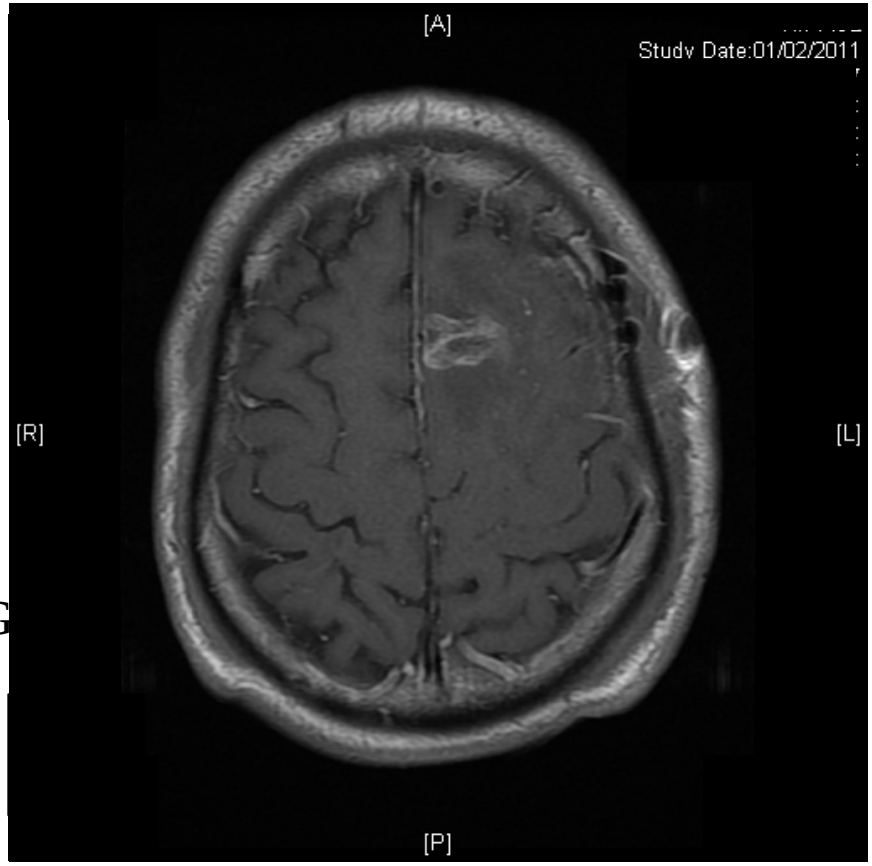

ESTRO School

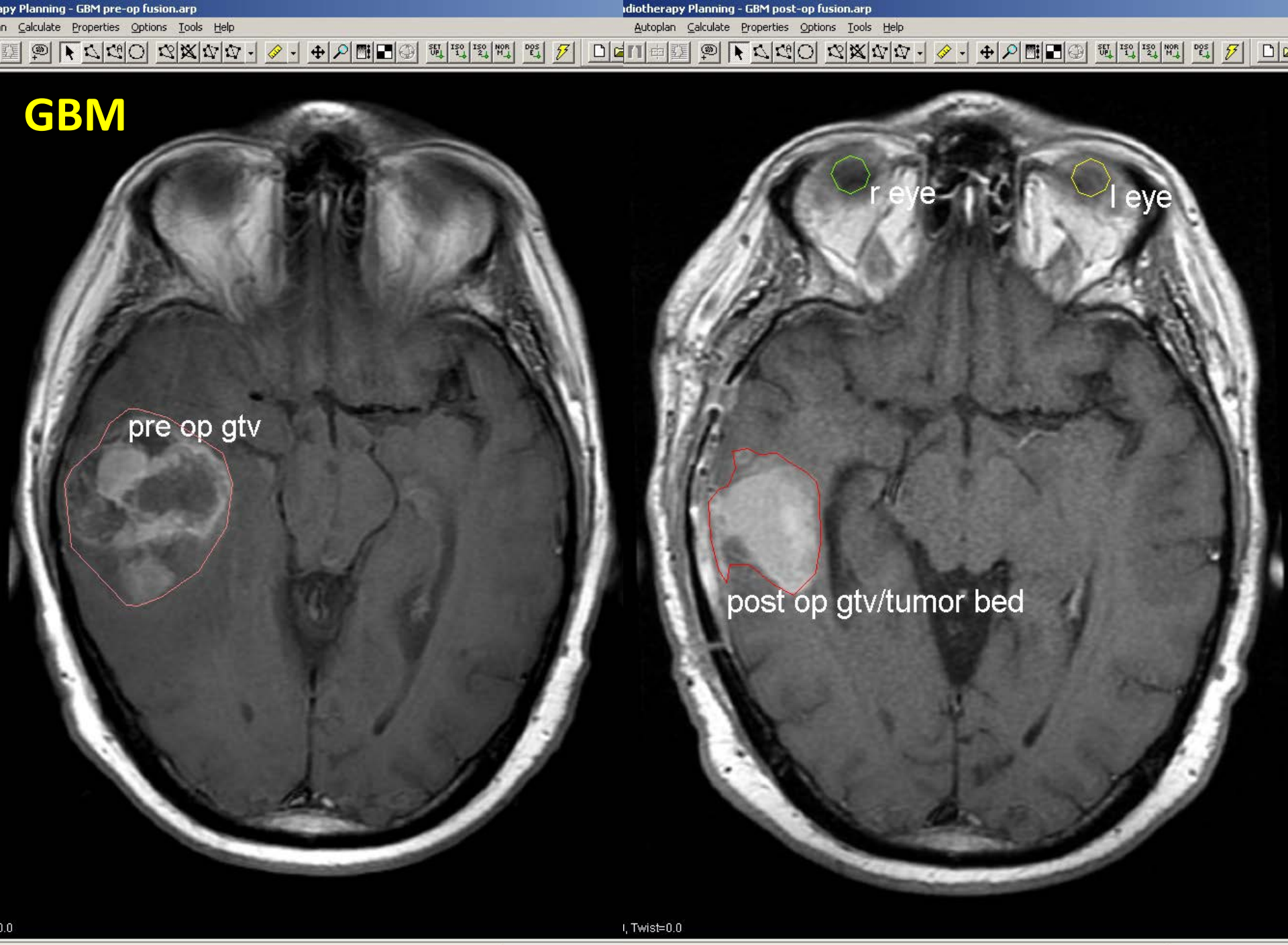
GBM
apy Planning - GBM pre-op fusion.arp
n Calculate Properties Options Tools Help
adiotherapy Planning - GBM post-op fusion.arp
Autoplan Calculate Properties Options Tools Help
pre op gtv
r eye
l eye
post op gtv/tumor bed
0.0
l, Twist=0.0

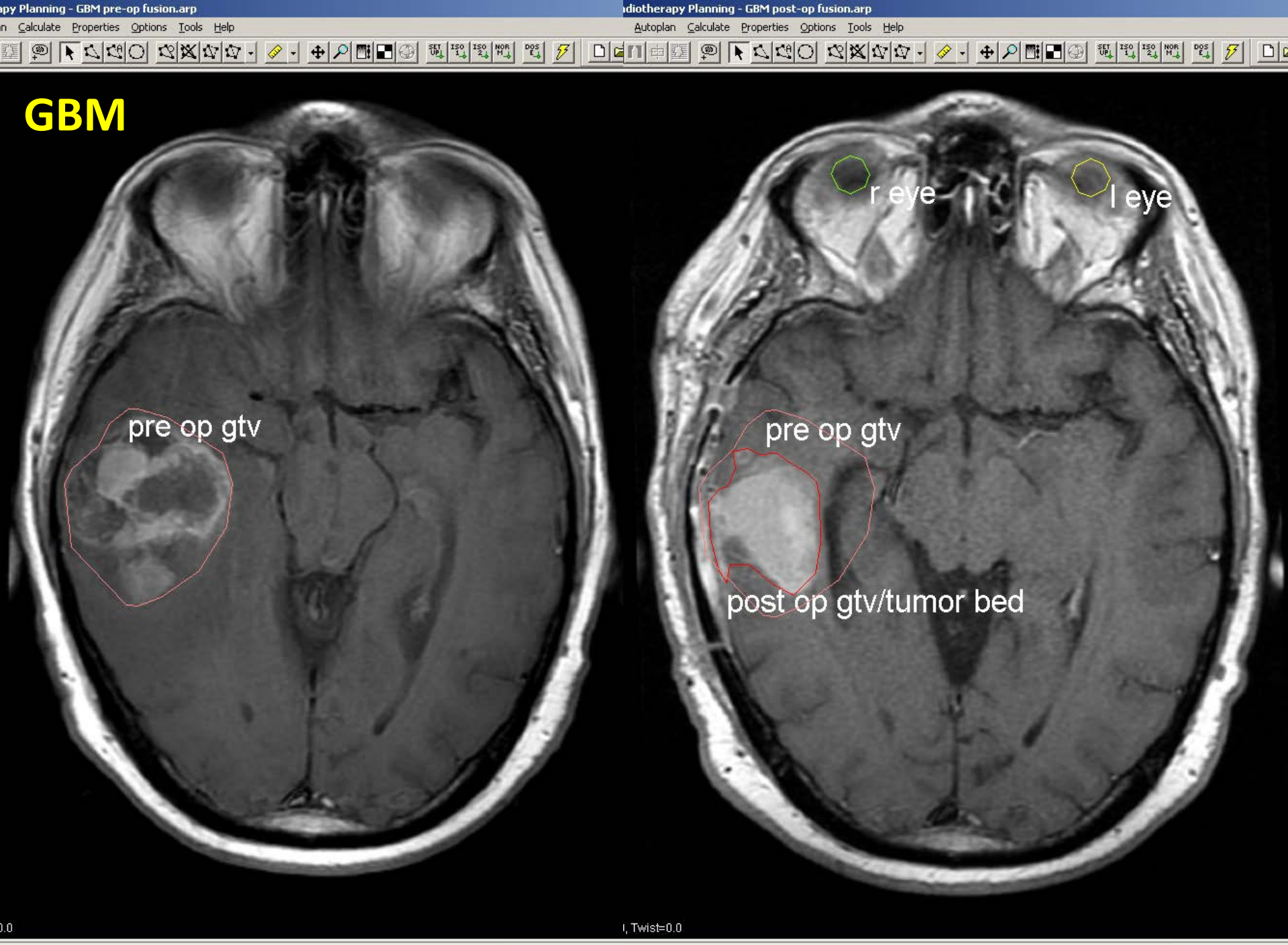
GBM
apy Planning - GBM pre-op fusion.arp
n Calculate Properties Options Tools Help
pre op gtv
0.0
diotherapy Planning - GBM post-op fusion.arp
Autoplan Calculate Properties Options Tools Help
r eye
l eye
pre op gtv
post op gtv/tumor bed
l, Twist=0.0

GBM

- Significant reduction in volume
- Also reduction in brain shift
- Note reduction superiorly

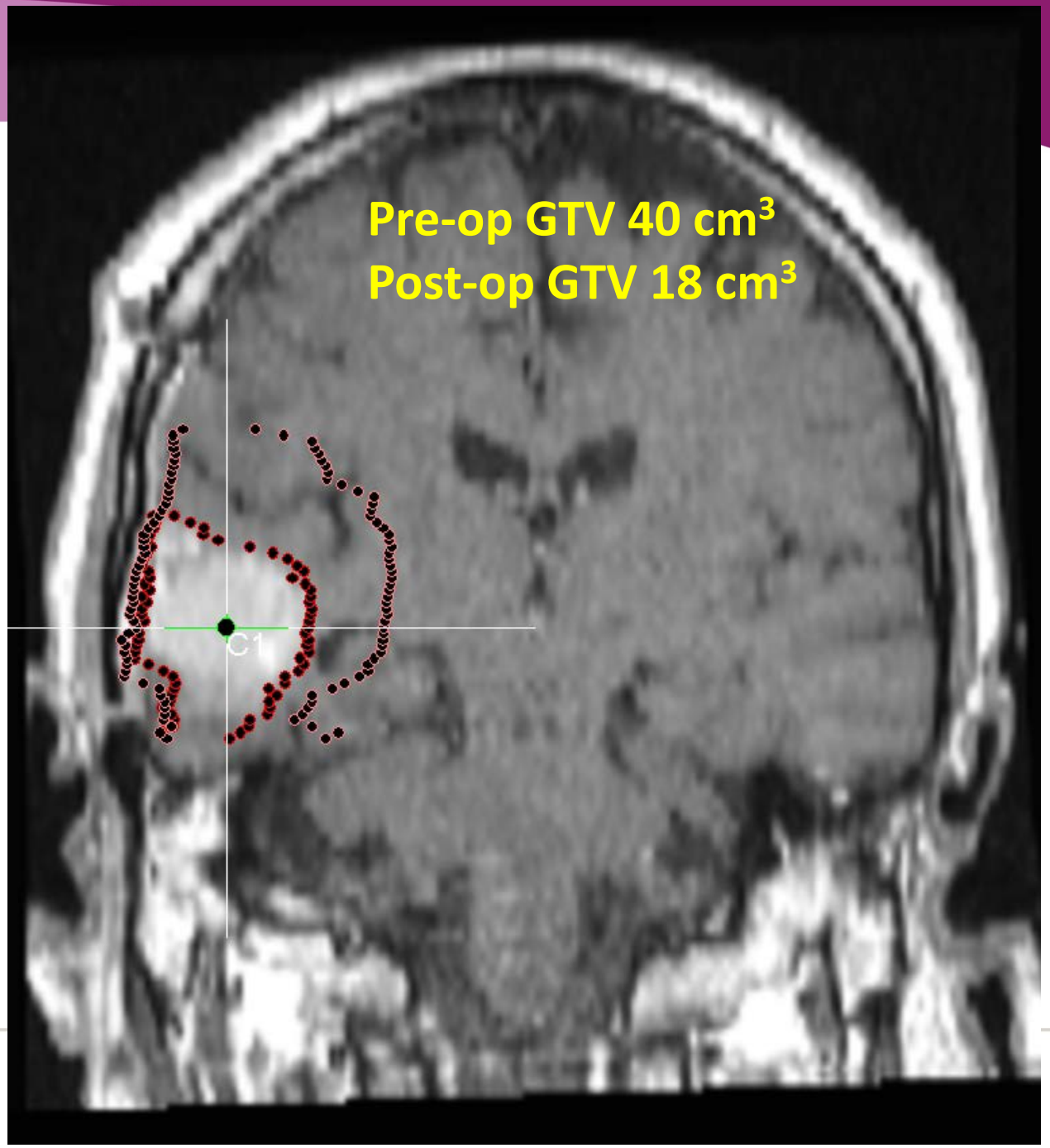

HGG - GTV

For high grade tumour, beware rapid growth

Scan near to the start of RT

Example scans ....

HGG - GTV

Small GBM in man of 50

MRI at time of initial Presentation

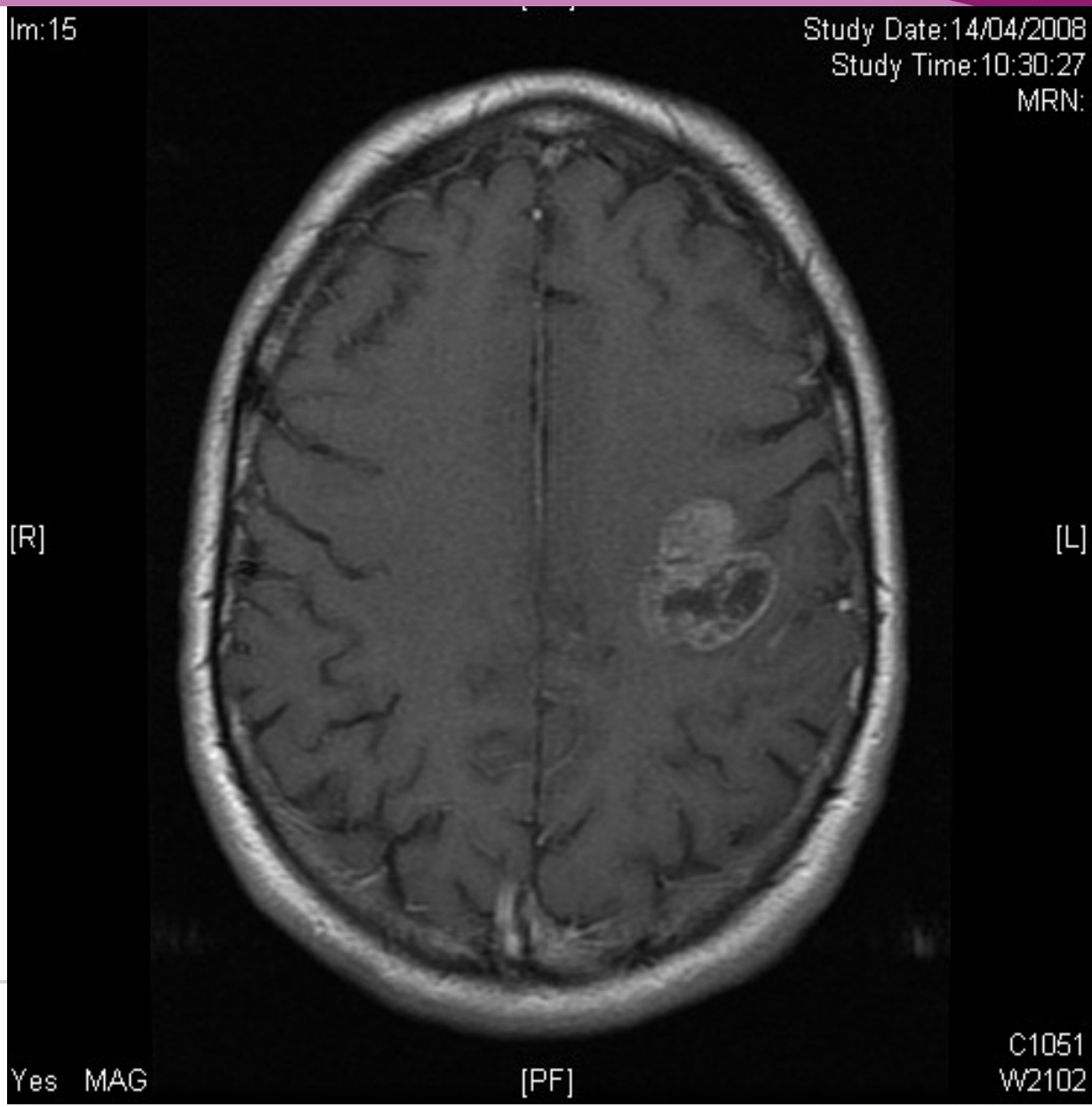

HGG - GTV

RT planning scan 3 weeks later

Target volume now very different

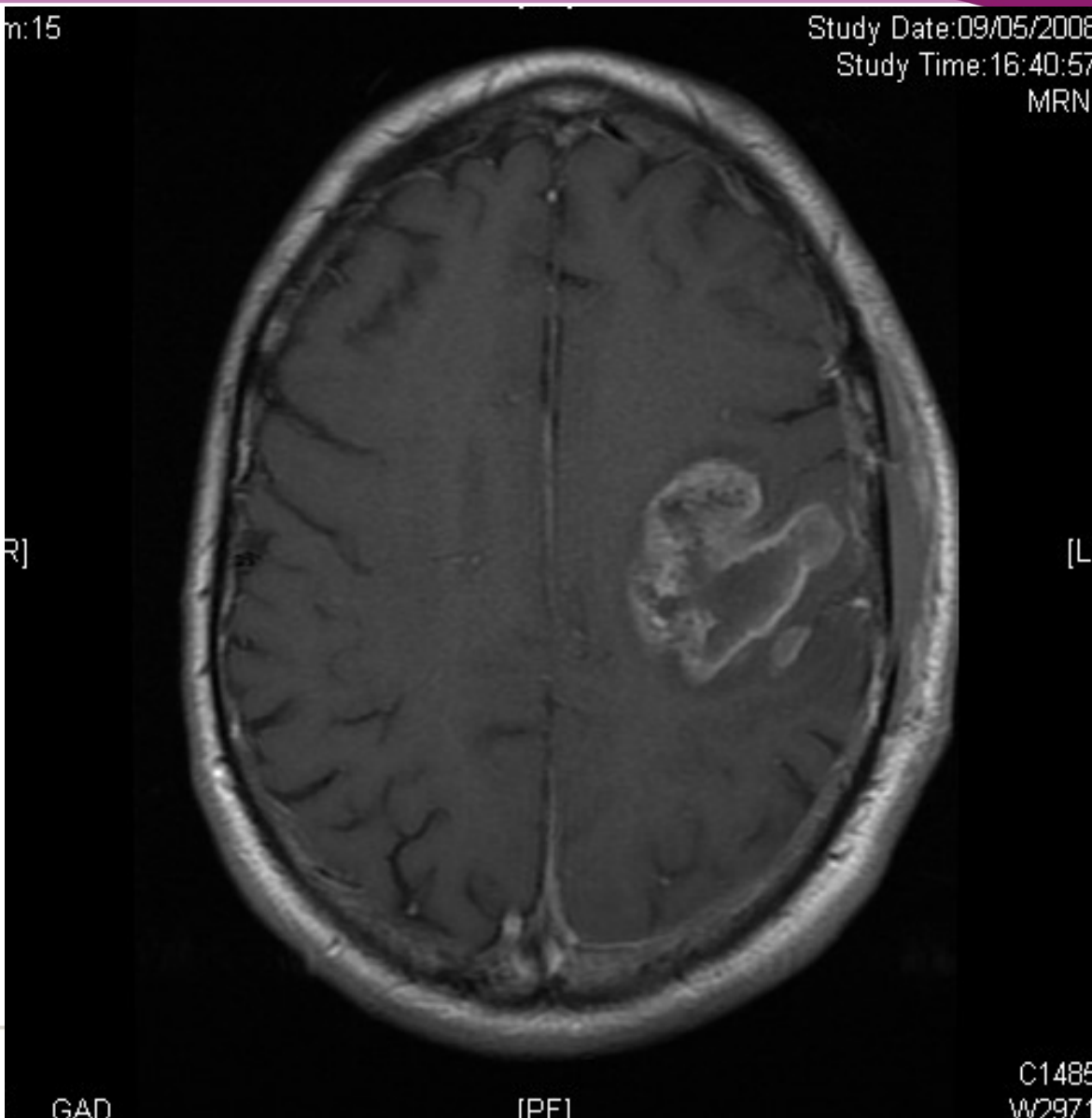

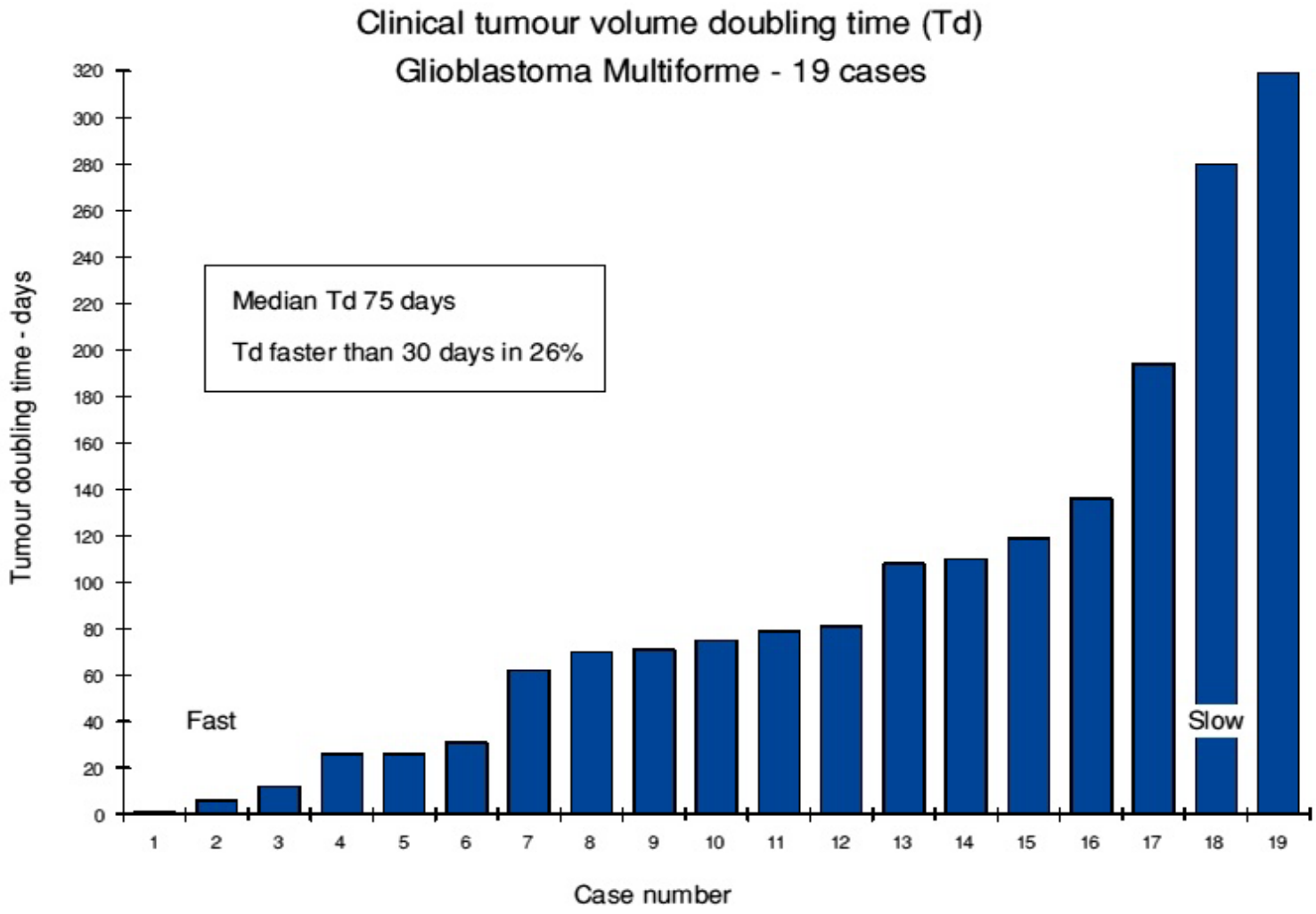
Clinical tumour volume doubling time (Td)
Glioblastoma Multiforme - 19 cases
Median Td 75 days
Td faster than 30 days in 26%
Fast
Slow
Tumour doubling time - days
Case number
0
20
40
60
80
100
120
140
160
180
200
220
240
260
280
300
320
1
2
3
4
5
6
7
8
9
10
11
12
13
14
15
16
17
18
19

HGG Invasion

High grade gliomas probably vary in invasiveness between patients, but this is not measurable at present

Very infiltrative HGGs may be better treated palliatively

Very localised ***might*** be suitable for dose escalation

GTV – True extent of tumour

True extent of tumour

- Gliomas:
  - Grade III and IV:
    - GTV: Contrast-enhancing area
    - T2-hyperintensities: Grade II components plus edema -> CTV
    - Tumour to be expected even in seemingly normal brain

HGG – GTV definitions

High grade gliomas

GTV = Contrast-enhancing edge

or = Contrast-enhancing edge + surgical cavity

Surgical Cavity

- Original resection (temporal lobectomy) 1992
- Routine follow up

HGG – GTV / CTV

Recurrence in ‘empty’ temporal fossa

Initially observed for 4 months

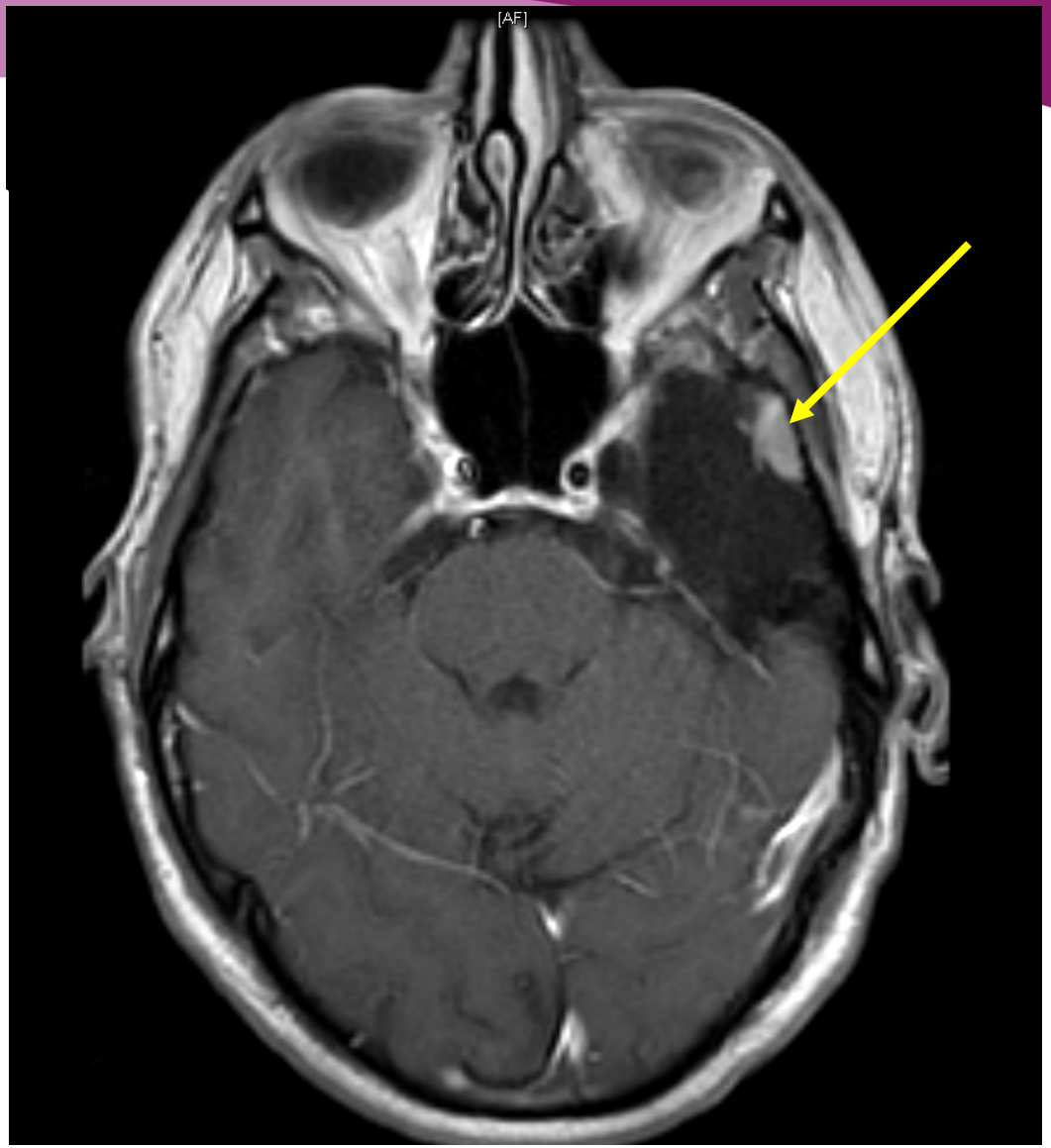

HGG – GTV / CTV

Low grade glioma

Recurrence in temporal fossa

Now HGG

Cavity should be in target – GTV or CTV?

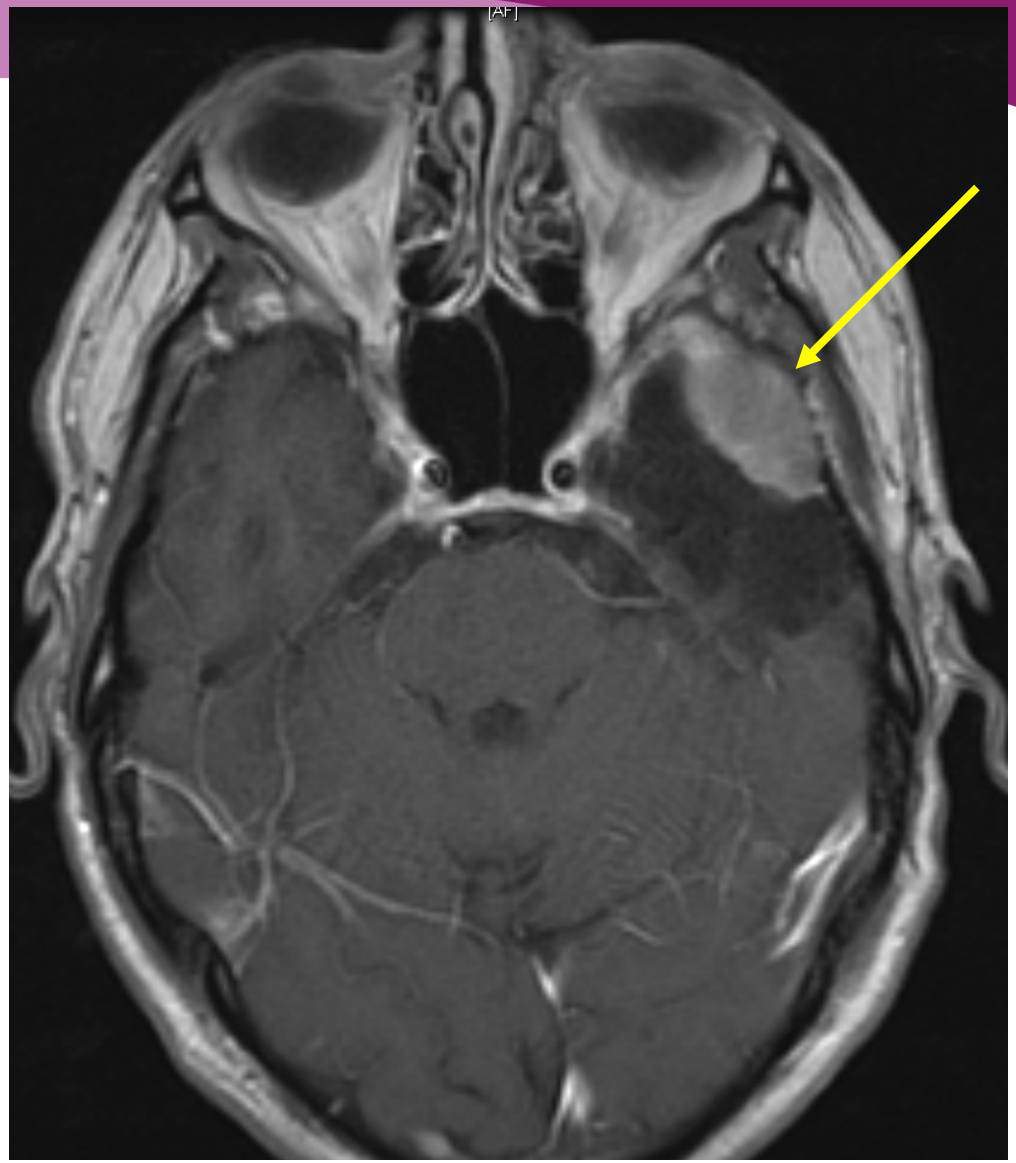

Planning CT

(+ contrast)

MR co-registered

T1 + Gd

CT +MRI

Starting delineation

GTV

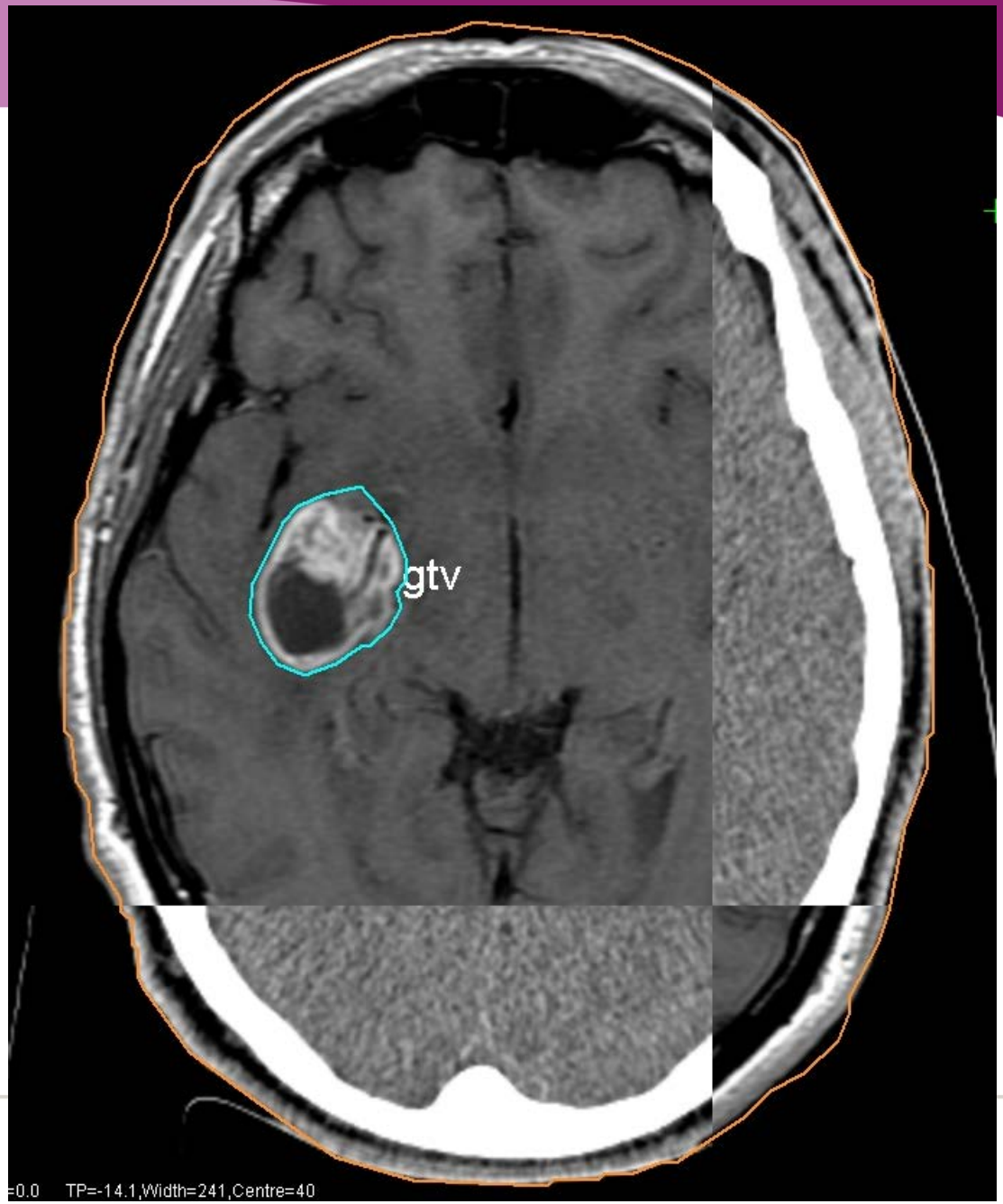

From GTV to CTV

Vincent van Gogh
The Starry Night 1889

ESTRO School

HGG – CTV Suggested margins

- Whole brain or localised RT?
- Outcome studies suggest localised RT is as good for TCP

Marsa et al 256 pts, Cancer 1975; 36: 1681-89

Shapiro et al 571 pts randomised, J Neurosurg 1989; 71: 1-9

Kita et al 43 pts randomised, Gan No Rinsho 1989; 35: 1289-94

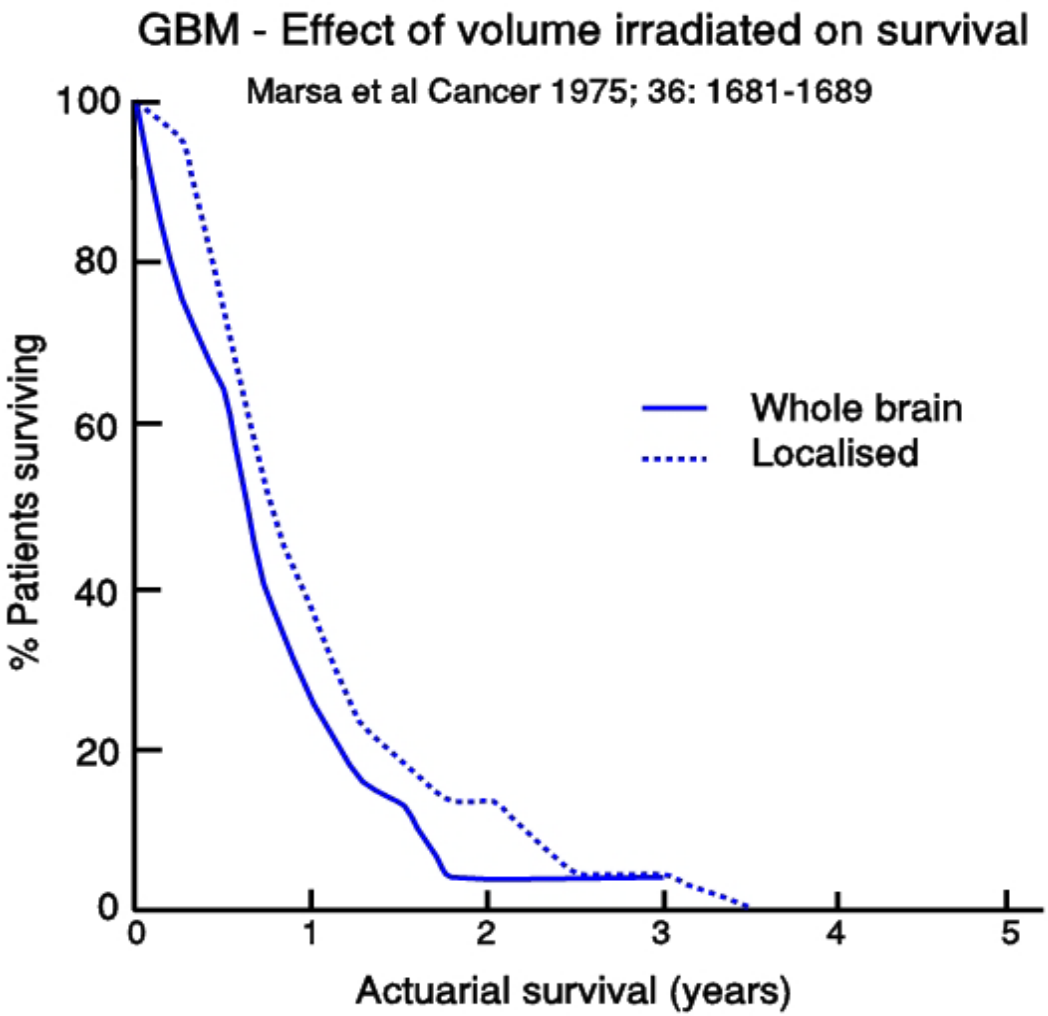
GBM - Effect of volume irradiated on survival
Marsa et al Cancer 1975; 36: 1681-1689
100
80
60
40
20
0
% Patients surviving
Whole brain
Localised
0
1
2
3
4
5
Actuarial survival (years)

HGG - CTV

- Data exist to guide margins from:
  - post mortem studies
  - biopsy studies
  - clinical experience of recurrence patterns

Jansen EP et al. Radiother Oncol 2000; 56: 151-166

HGG - CTV

- In 80 - 90% of cases in studies of post mortem, biopsy, or recurrence, tumour extends up to ≈ 2 cm from edge of gross tumour (ie GTV)
- This suggests a CTV margin : 2 – 3 cm
- ***Not*** necessary to include all oedema

Oedema

- Oedema is an unreliable measure of tumour spread
  - It does contain tumour cells
- Steroids reduce oedema
  - Progressive effect
  - Not an antitumour effect
- Not recommended as basis for CTV

Oedema reduced by steroids

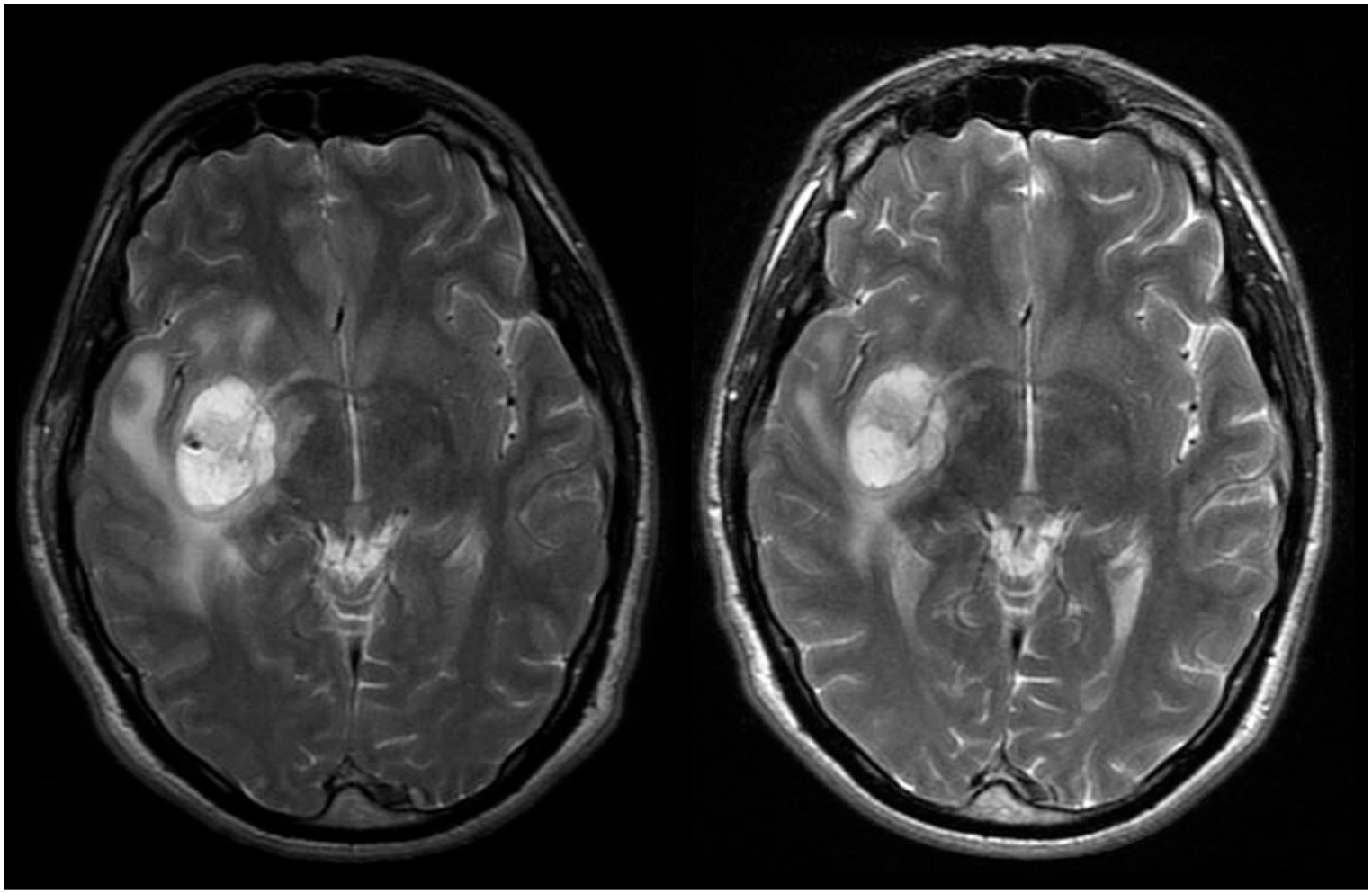

1 week post op (biopsy)

1 week later – RT planning

HGG - CTV

- Some study protocols require inclusion of all oedema

  GTV defined as abnormal signal on FLAIR

  Then CTV adds further 2 cm

- This gives very large volumes:

Glioblastoma

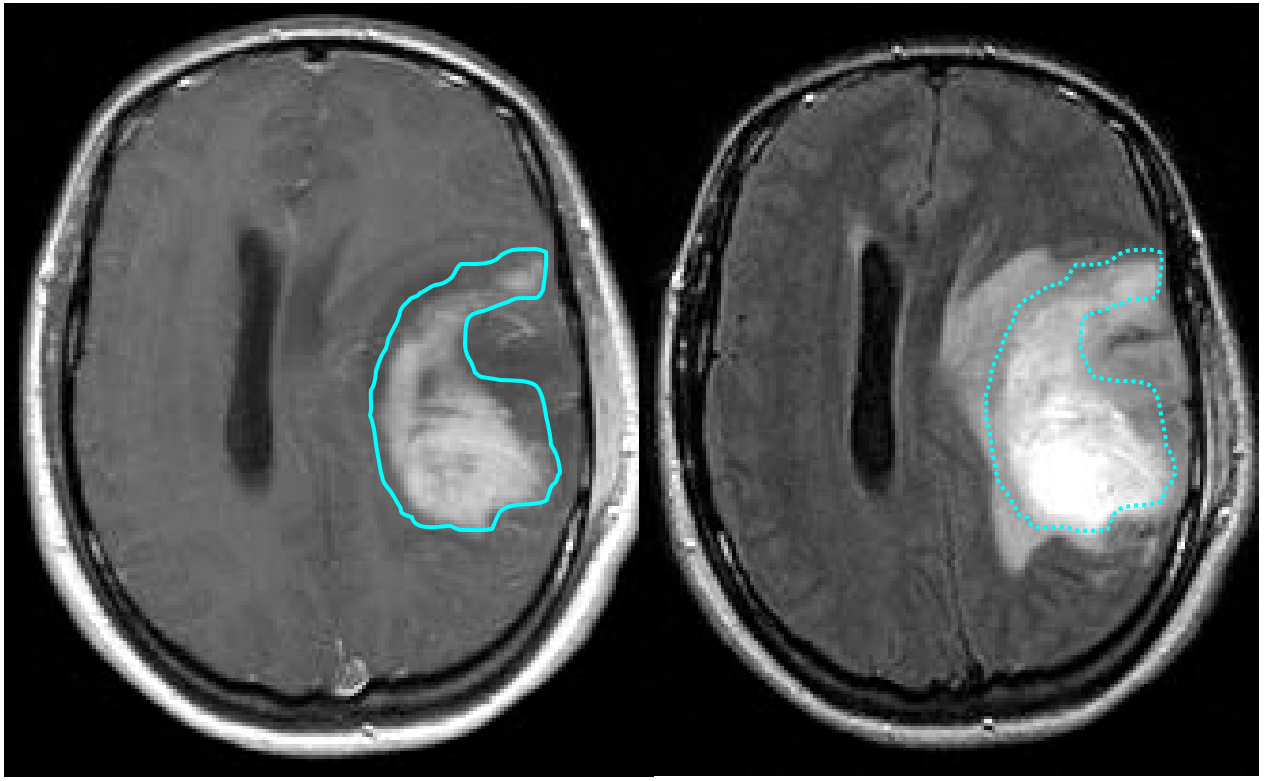

T1 + Gd **FLAIR + Gd**

GTV definition
- T1 + Gd
- FLAIR

Stefan Delorme

ESTRO School

Glioblastoma

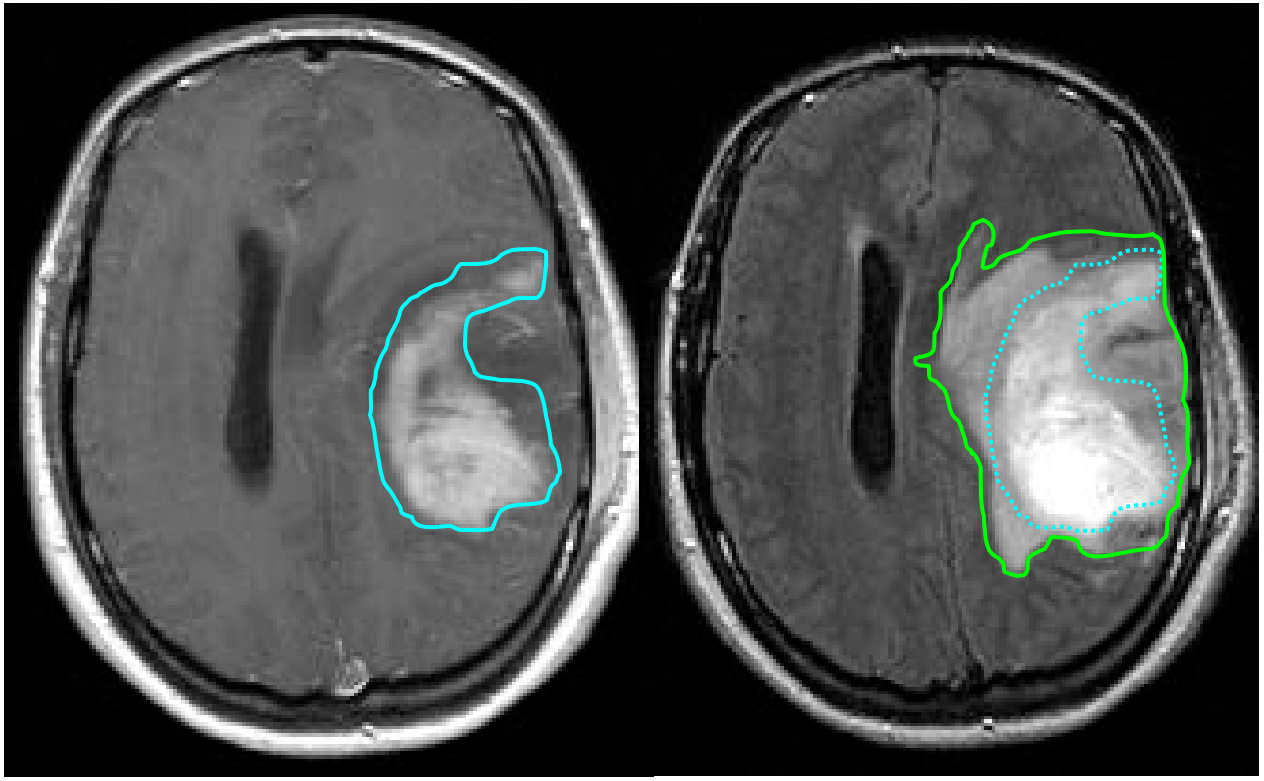

T1 + Gd **FLAIR + Gd**

GTV definition
- T1 + Gd
- FLAIR

Glioblastoma

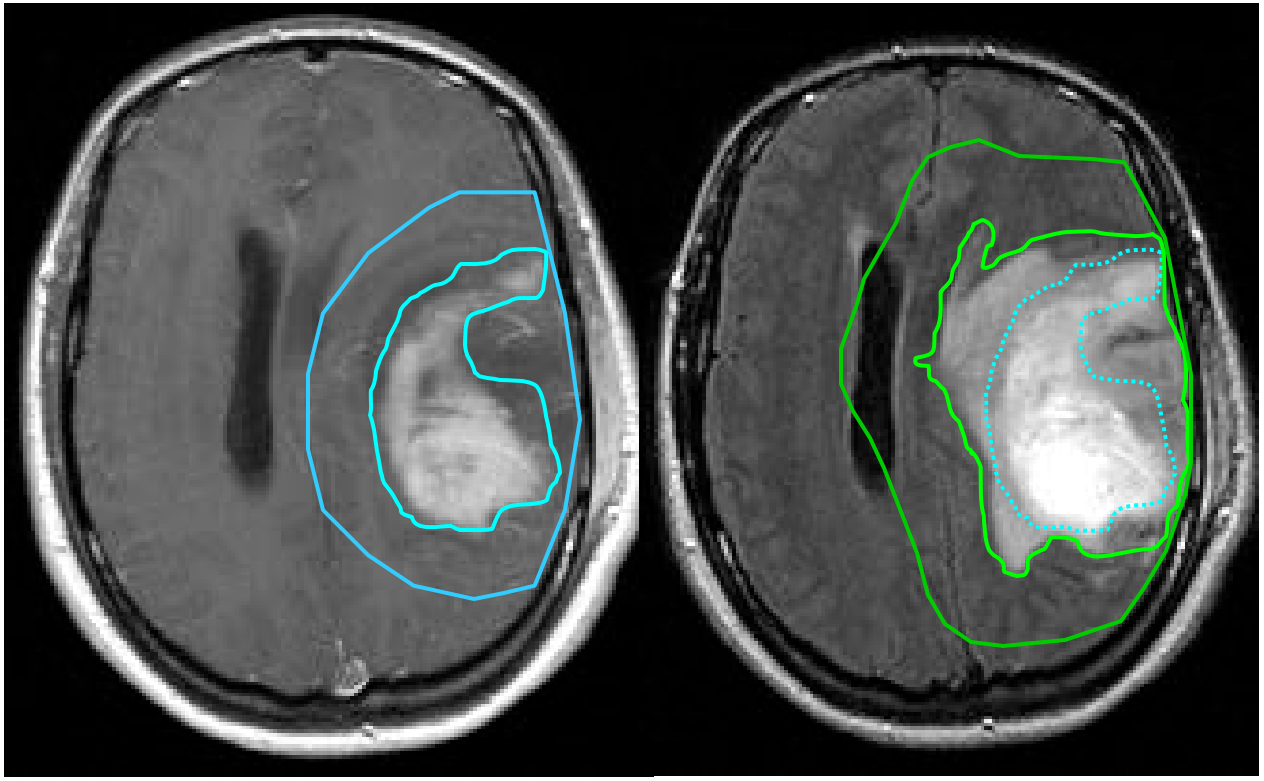

T1 + Gd **FLAIR + Gd**

GTV definition
- T1 + Gd
- FLAIR

Evidence:
- T1 + Gd

Volume:
- T1 + Gd

Oedema – include or not?

48 patients GBM

Treated with RT – 2cm margin for CTV

All recurred

Replanned – including oedema as per RTOG protocol

Chang et al., 2007 Int J Radiat Oncol Biol Phys 2007

Oedema – include or not?

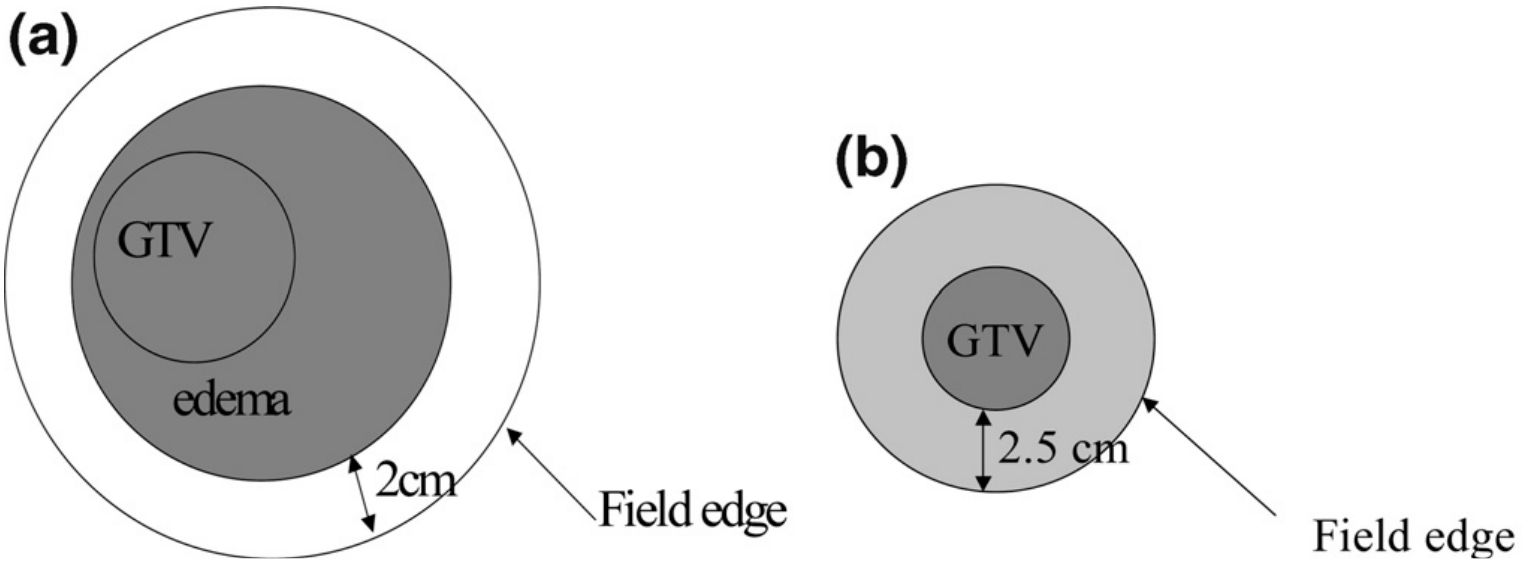

Oedema – include or not?

Pattern of failure was **identical** between the two sets of plans

- 40 central
- 3 in-field
- 3 marginal
- 2 distant recurrence

With 2-cm margin

- smaller median % volume of brain irradiated to 30 Gy, 46 Gy, and 50 Gy

Minniti et al. Radiother Oncol 2010; 97: 377-381

GTV - T1+Gd or oedema

Minniti et al. Radiother Oncol. 2010; 97(3): 377-81

Contents lists available at ScienceDirect

Radiotherapy and Oncology

journal homepage: www.thegreenjournal.com

CNS radiotherapy

Patterns of failure and comparison of different target volume delineations in patients with glioblastoma treated with conformal radiotherapy plus concomitant and adjuvant temozolomide

Giuseppe Minniti [a,b,*], Dante Amelio [c], Maurizio Amichetti [c], Maurizio Salvati [b], Roberta Muni [a], Alessandro Bozzao [d], Gaetano Lanzetta [b], Stefania Scarpino [e], Antonella Arcella [b], Riccardo Maurizi Enrici [a]

NO difference in recurrence patterns whichever approach would have been used

No difference in recurrence patterns with TMZ

HGG - CTV

Select best imaging

GTV = Contrast-enhancing edge

or = Contrast-enhancing edge + surgical cavity *

CTV = GTV plus (1.5) - 2.5 cm

* applies principally to temporal fossa after lobectomy

CT +MR

Starting delineation

GTV

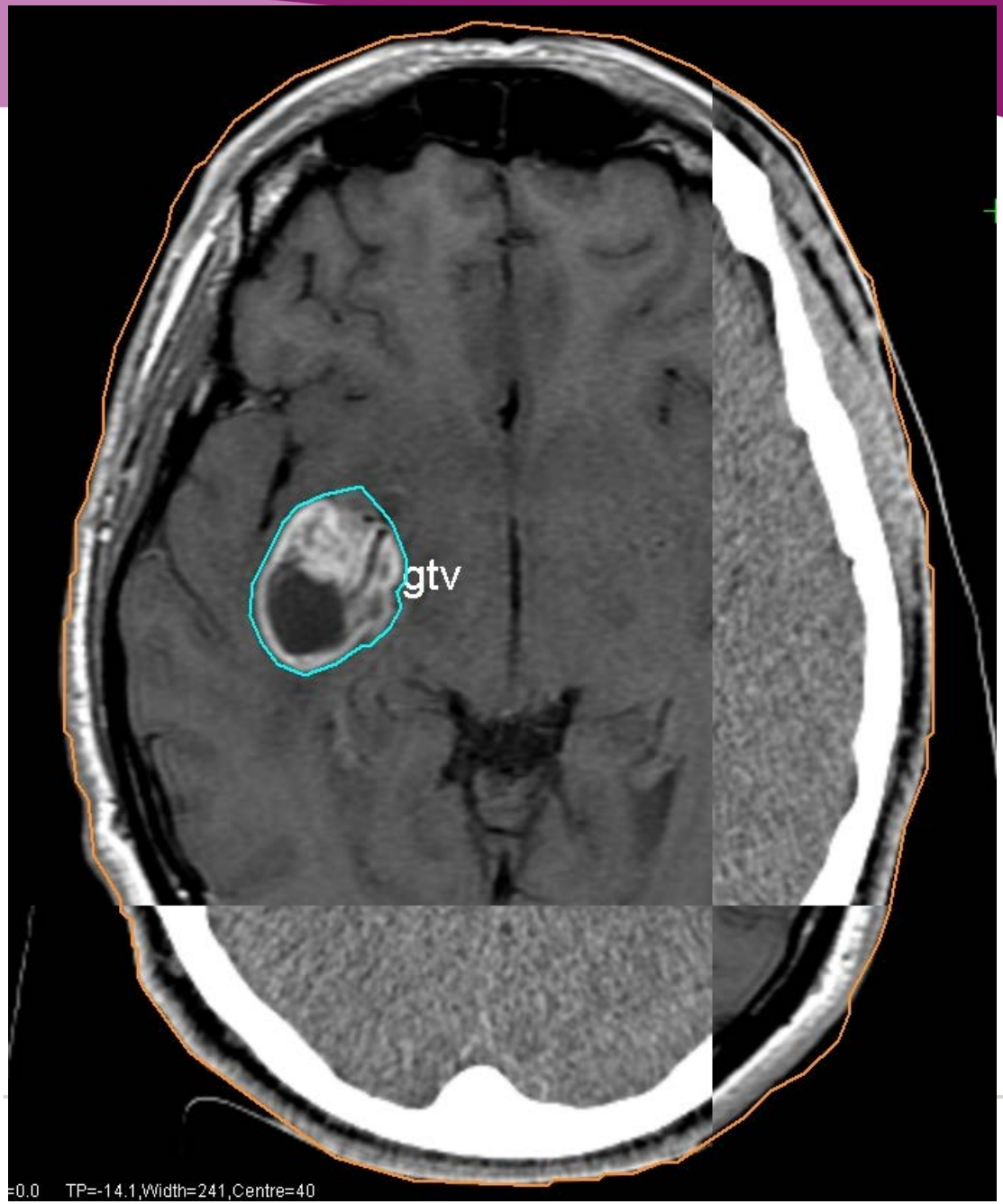

CTV added

Margin = 2.5 cm

Grown
isotropically,
up to skull

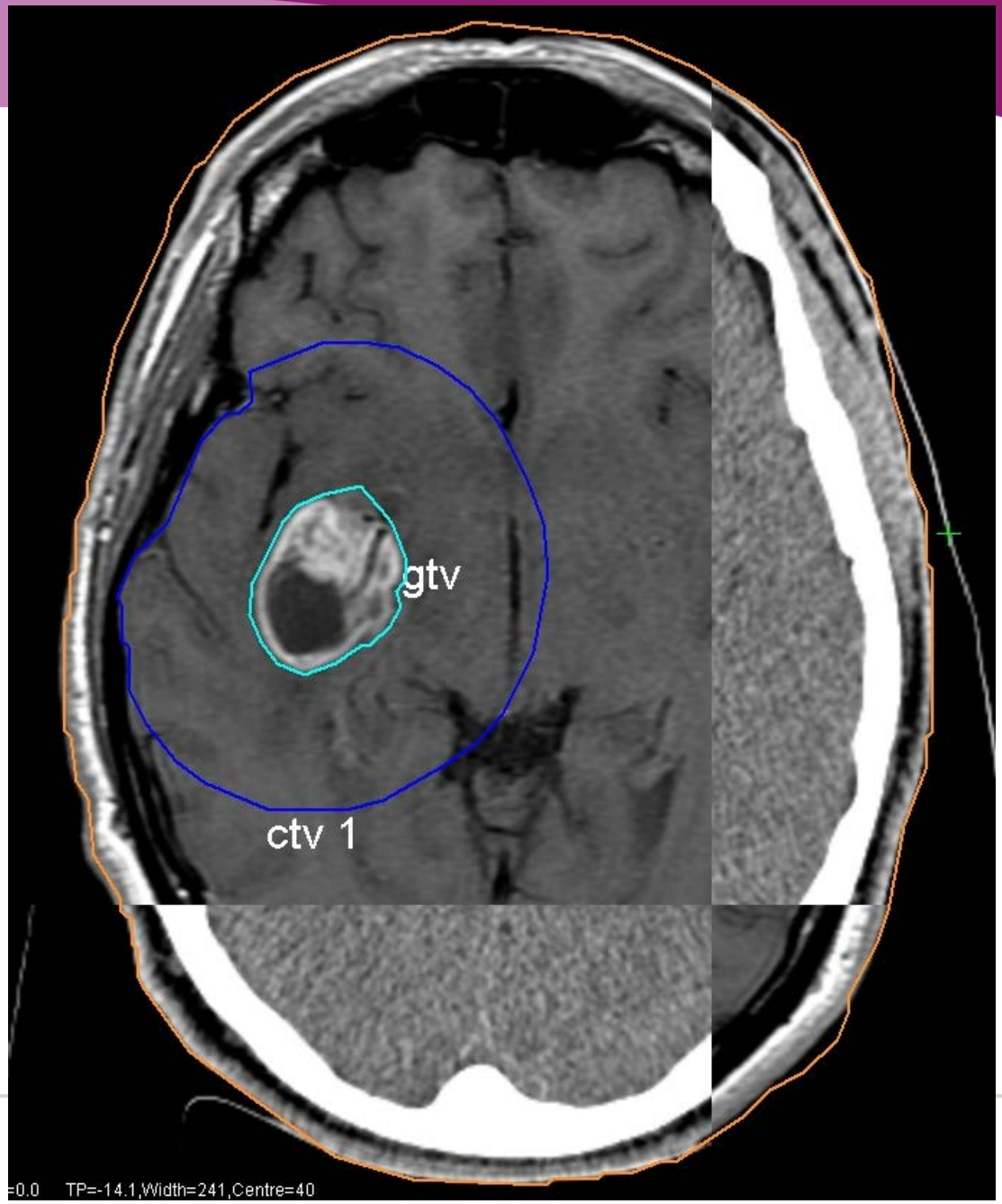

High grade glioma - PTV

Use the ‘Margin Recipe’ - PTV = $2.5\Sigma + 0.7\sigma$

Measure the standard deviations in each department

Our dept – PTV margin = 0.3 cm with IGRT

Systematic errors (mm)			
Gaussian			
Σdoctor	0.0	0.0	0.0
Σmotion	0.0	0.0	0.0
Σtransfer	0.1	0.1	0.1
Σset-up	0.25	0.25	0.25
Σ(combined)	**0.3**	**0.3**	**0.3**
Linear			
b	0.0	0.0	0.0
a	0.0	0.0	0.0
Treatment Execution errors			
Gaussian			
σset-up	0.3	0.3	0.3
σmotion(target shape)	0.0	0.0	0.0
σp	5.5	5.5	5.5
σ(combined)	**5.5**	**5.5**	**5.5**
Planning parameter (β)	1.64	1.64	1.64
Semi-sides			
systematic	0.7	0.7	0.7
execution	9.0	9.0	9.0
breathing	0.0	0.0	0.0
scalar (a-βσp)	-9.0	-9.0	-9.0
Total CTV-PTV margin	**0.7**	**0.7**	**0.7**

Skull shown

Auto-outlined using CT

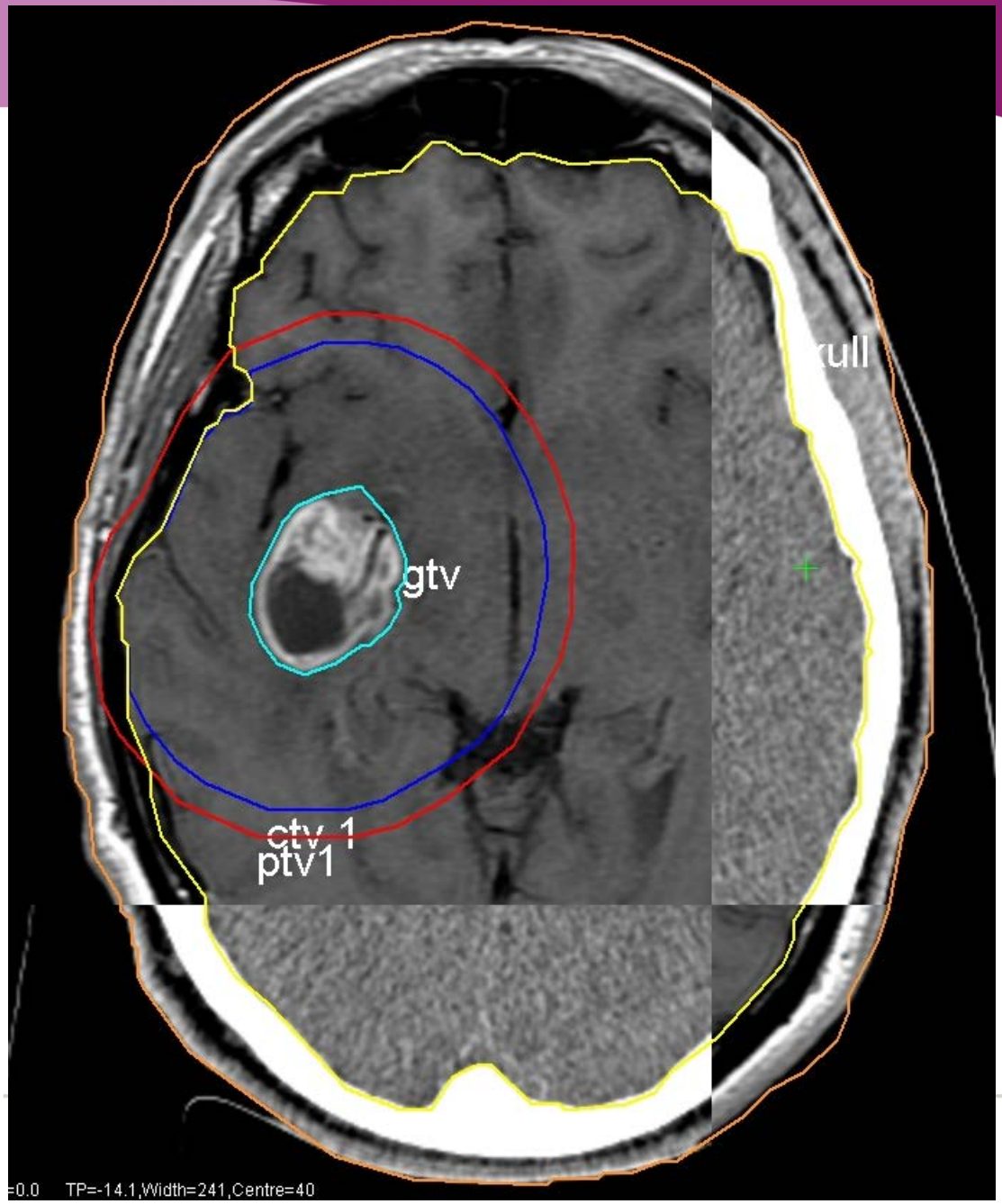

Final volumes on CT

GTV

CTV

PTV

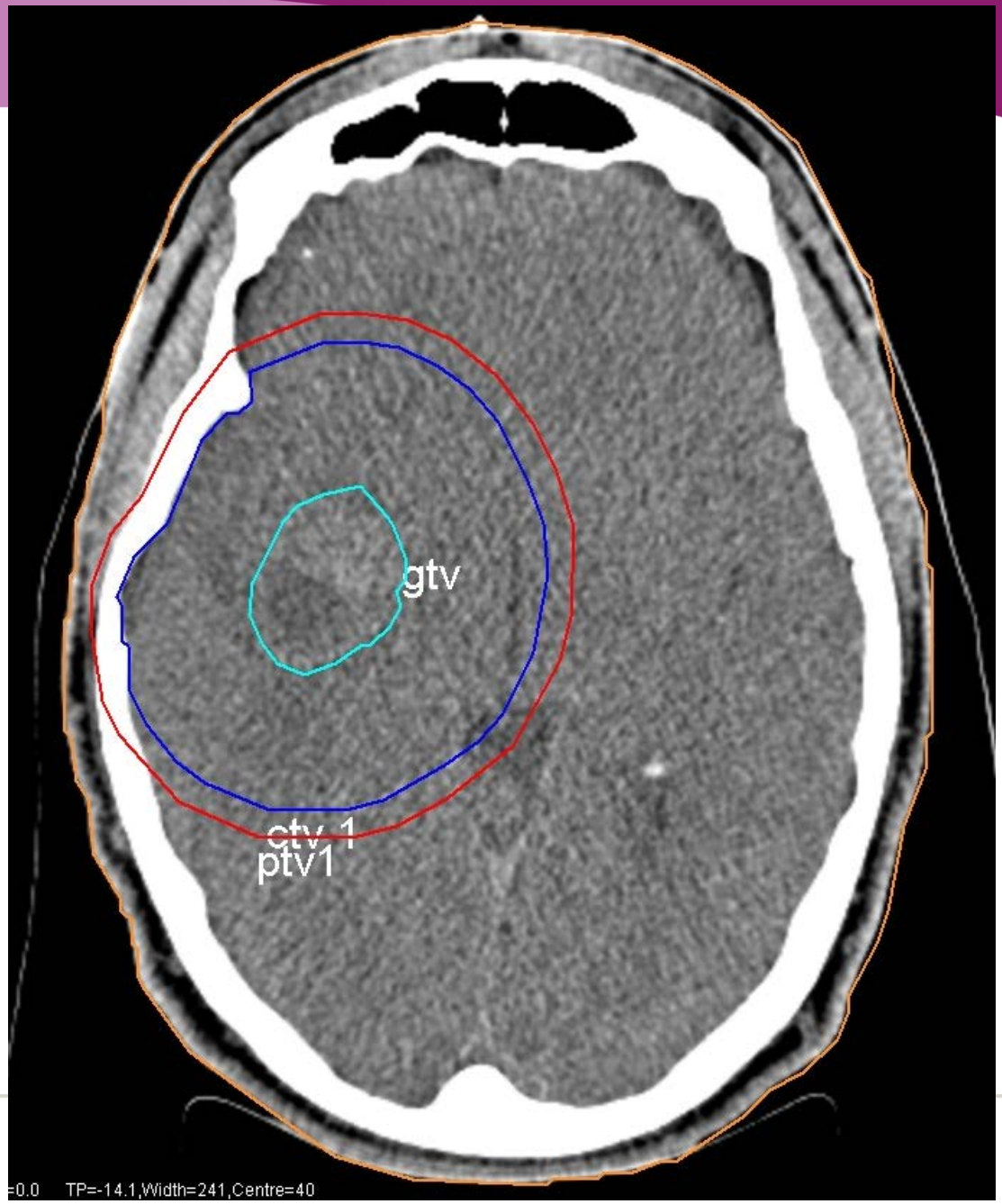

High grade glioma

Suggested doses

Total dose 60 Gy / 30# (GBM)

2 phases (or simultaneous with IMRT)

Phase 1 : 50 Gy / 25#

Phase 2 : 10 / 5 #

+ Temozolomide (TMZ) – concurrent + adjuvant

Summary

High grade gliomas

- GTV Enhancing tumour edge on CT/MRI
- CTV 2.5 cm (+/- Phase 2 with 1.5 cm)
- PTV 0.5 cm

Total 3 cm

NB Stupp trial:

PTV “defined as GTV plus a margin of 2–3 cm”

CNS case

- Example of plan for GBM patient
- IMRT technique
  - Dose to match conformal 2 phase approach
- 1 phase integrated approach
  - Outer PTV - 54 Gy/30# (≈ Phase 1 – 50 Gy/25#)
  - Inner PTV - 60 Gy/30# (≈ Phase 2 – 10 Gy/ 5#)

Glioblastoma
60 Gy/30# + TMZ

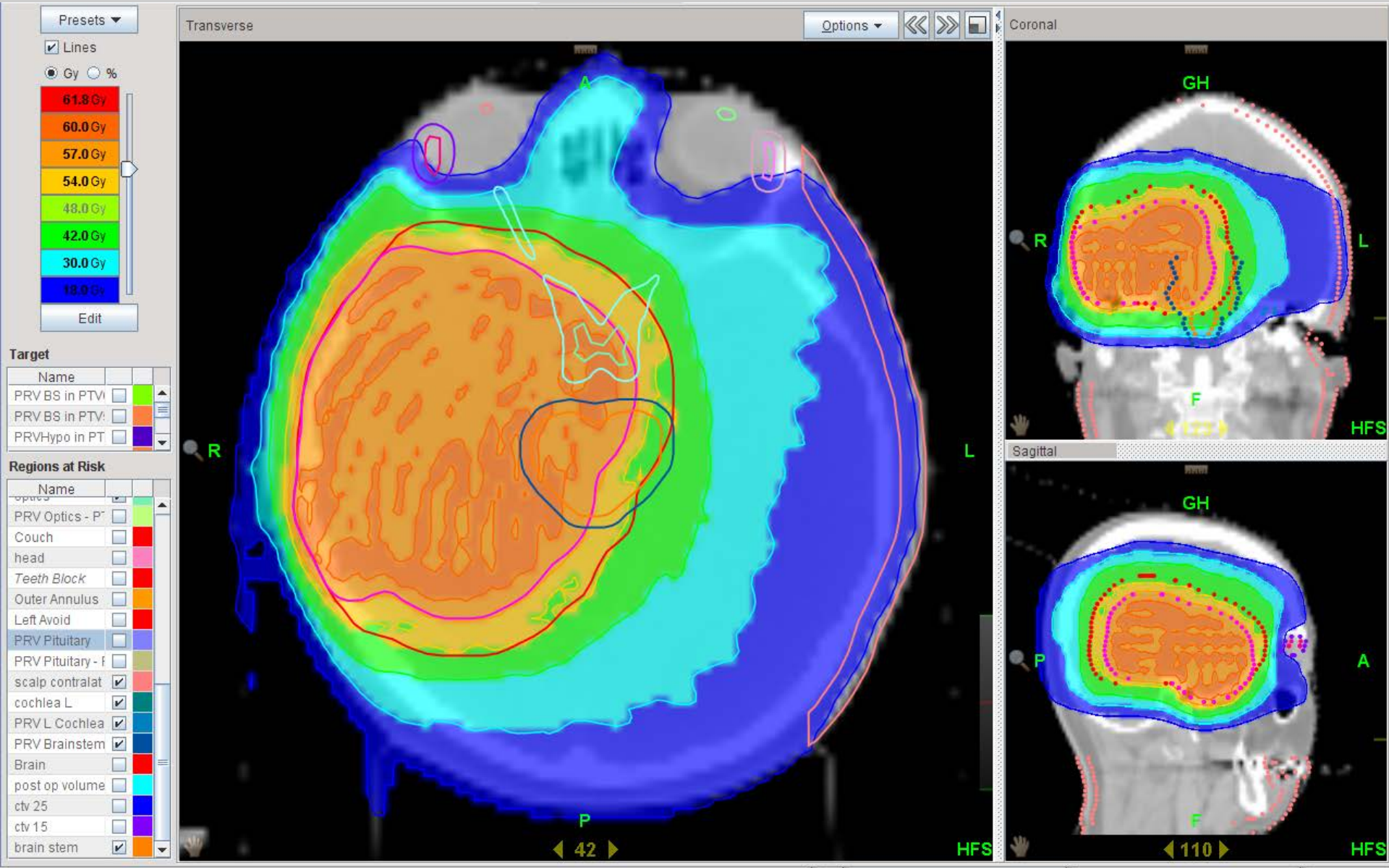

Glioblastoma

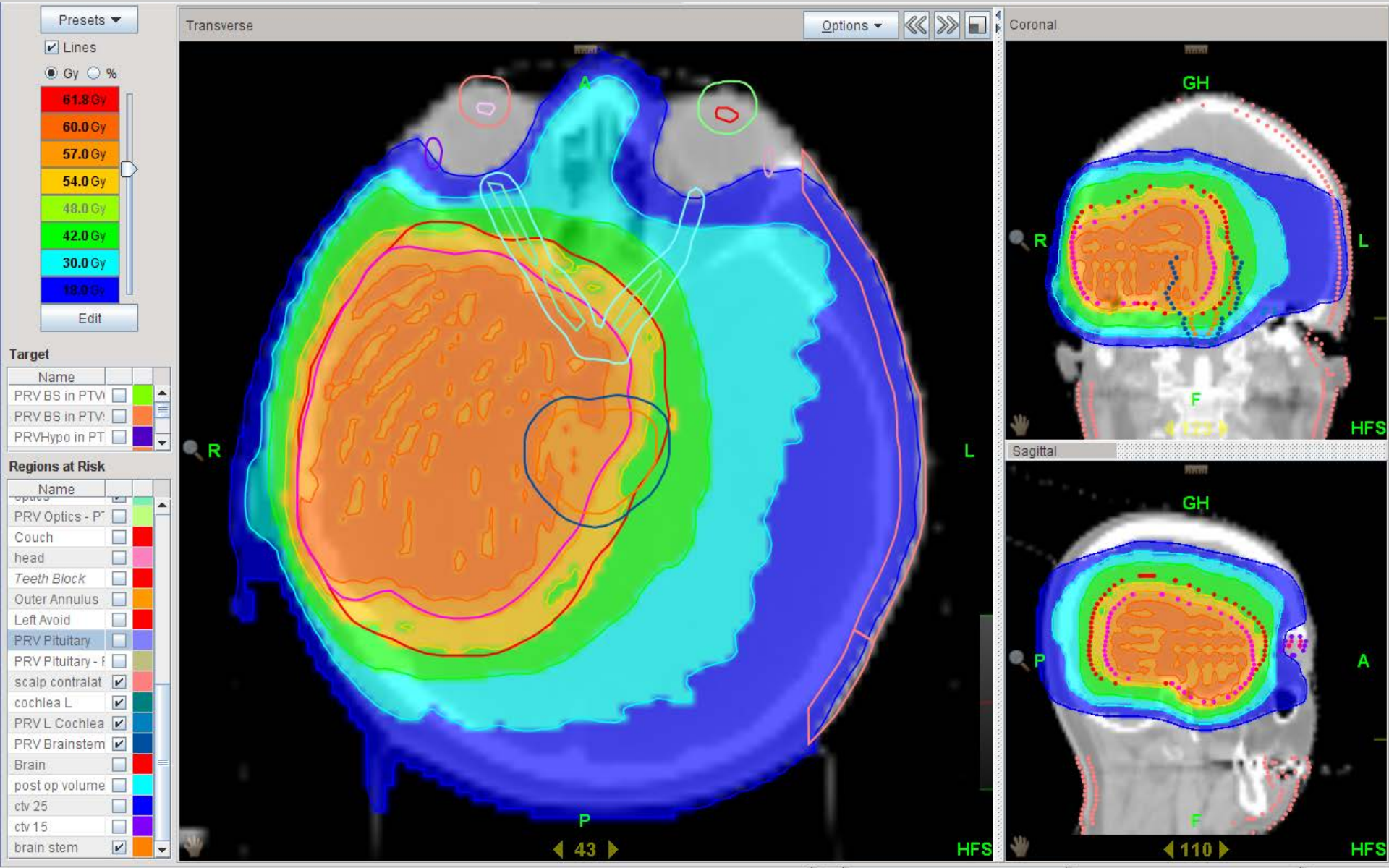

Glioblastoma

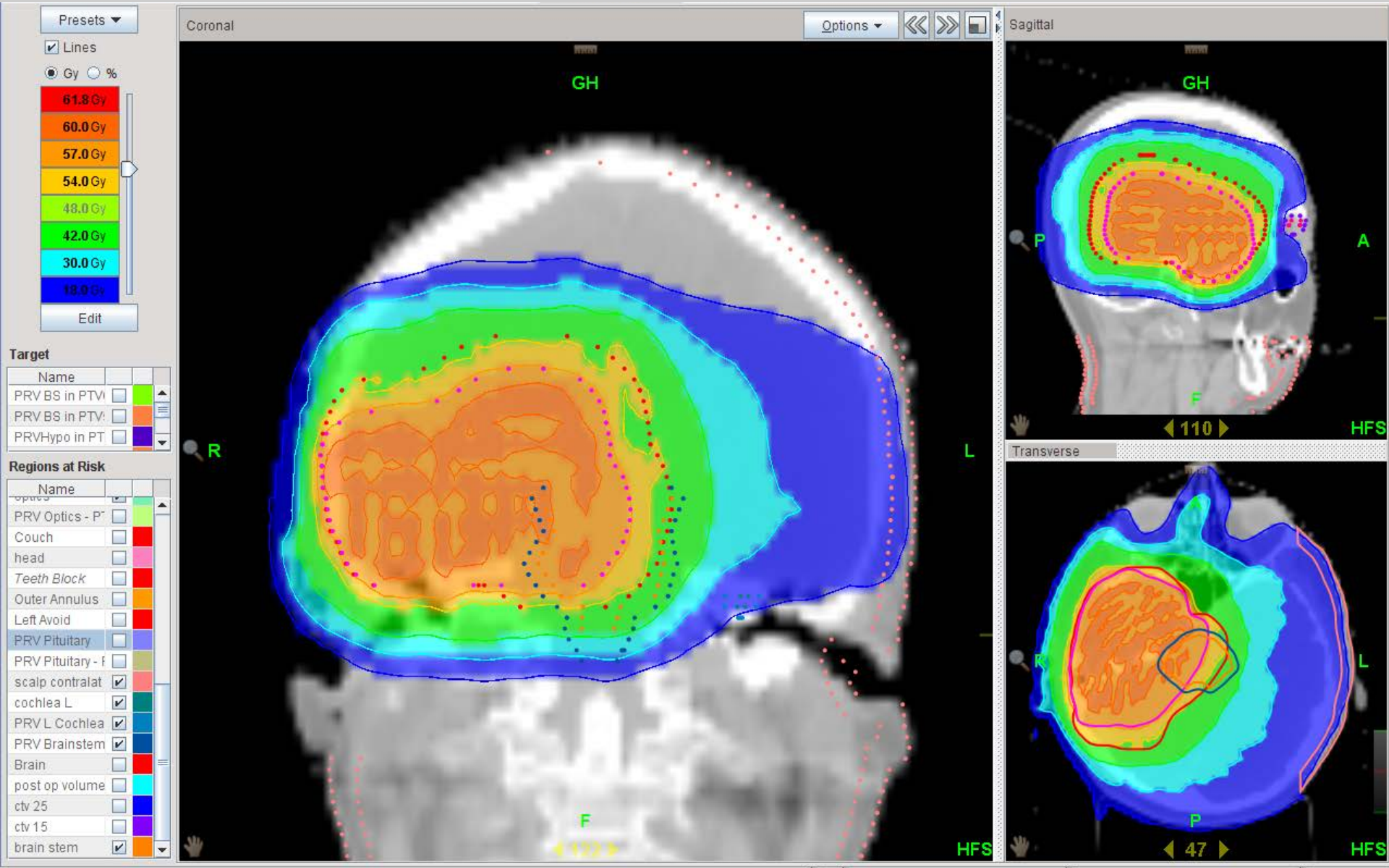

GBM - IMRT plan DVHs

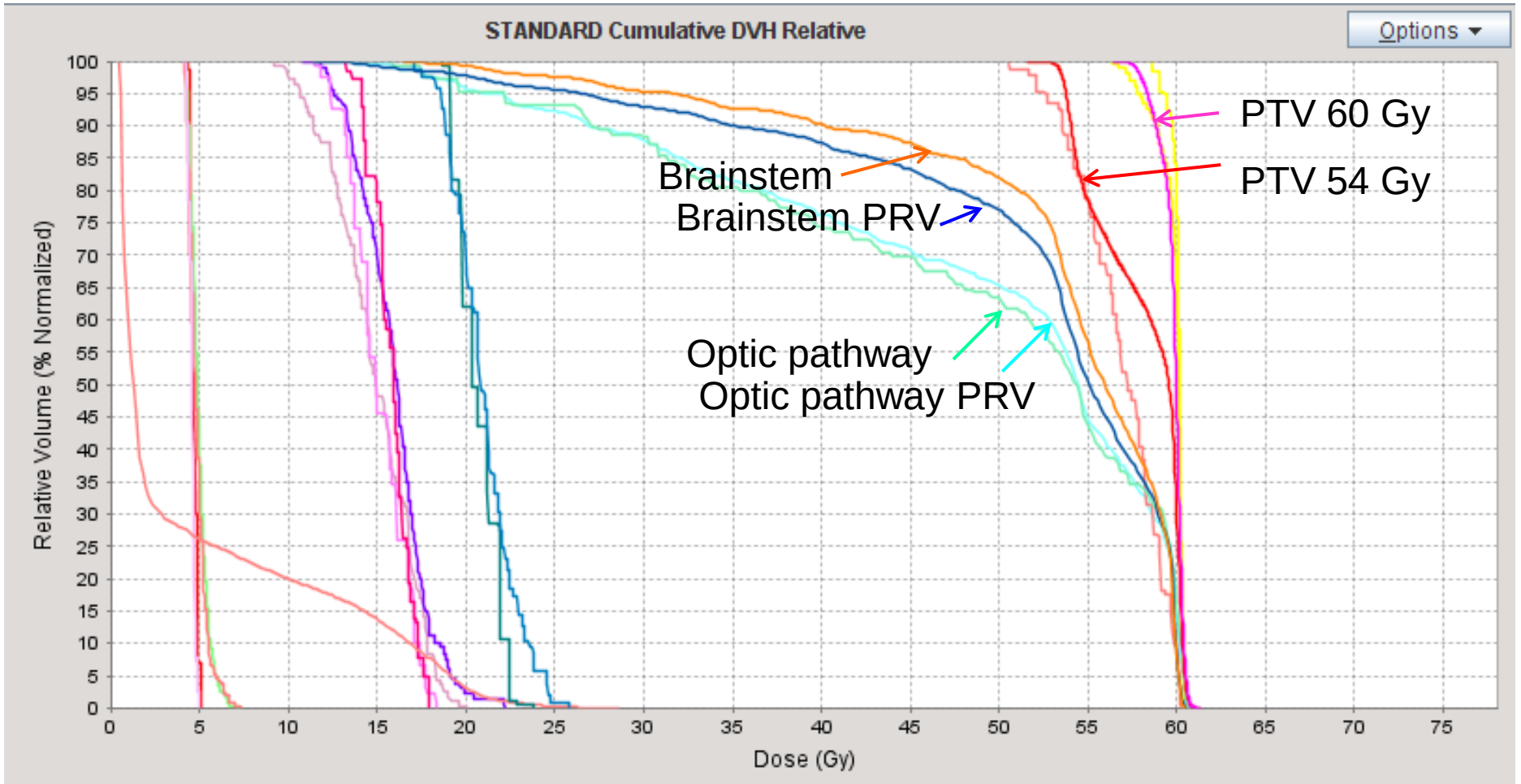

ESTRO School

The Bridge of Sighs Cambridge (not Venice)

Low Grade Glioma (LGG)

Low grade glioma

RT has an important role

Progression is delayed, overall survival unchanged

- Timing of RT may be discussed with patient

In LGG neurological deficits may ***improve*** with RT

Low grade glioma

Late effects of RT on cognition unclear

Role of chemotherapy compared to RT is not (yet) clear

EORTC randomised trial (BR13) – early results do not show an advantage for chemotherapy over RT

LGG - Timing of RT

CLINICAL INVESTIGATION **Brain**

RANDOMIZED TRIAL ON THE EFFICACY OF RADIOTHERAPY FOR CEREBRAL LOW-GRADE GLIOMA IN THE ADULT: EUROPEAN ORGANIZATION FOR RESEARCH AND TREATMENT OF CANCER STUDY 22845 WITH THE MEDICAL RESEARCH COUNCIL STUDY BRO4: AN INTERIM ANALYSIS

Early postoperative conventional RT improves the time to progression (progression-free survival)

Overall survival time ***same***

Karim AB et al. IJROBP 2002; 52(2): 316-24

ESTRO School

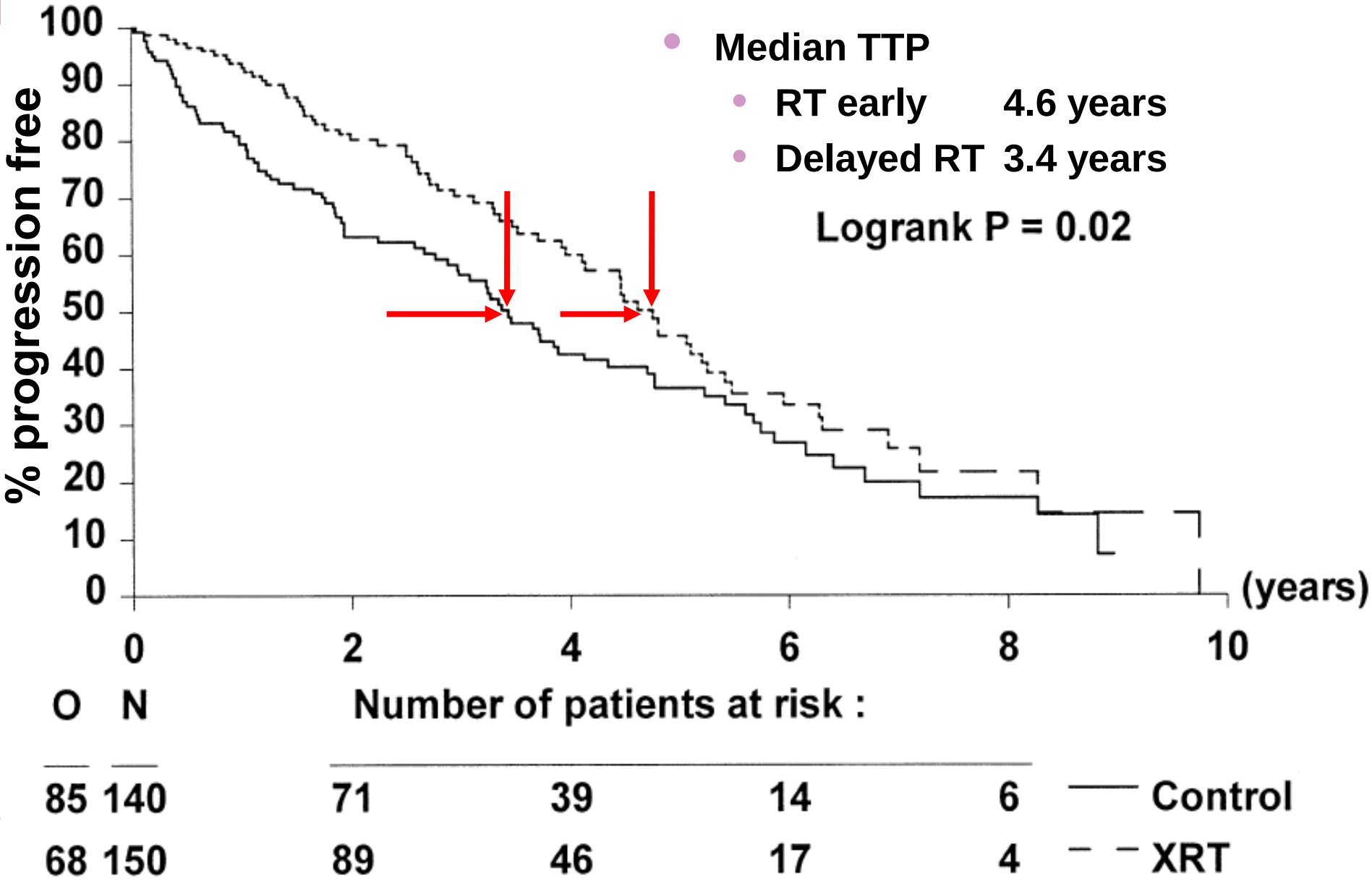
% progression free
100
90
80
70
60
50
40
30
20
10
0
0
2
4
6
8
10
(years)
Median TTP
RT early 4.6 years
Delayed RT 3.4 years
Logrank P = 0.02
O N
Number of patients at risk :
85 140 71 39 14 6 Control
68 150 89 46 17 4 XRT

LGG – RT dose

Dose of RT (EORTC 22844)

Randomised : 45 Gy : 59.4 Gy (@ 1.8 Gy/#)

5 year survival - *no* difference - 58% : 59%

Toxicity worse with 59.4 Gy

(Is this real, or a small study effect?)

Low grade glioma

Suggested doses

Single phase

Total dose : 45 Gy – 50.4 – 54 Gy – 59.6 Gy

25 – 28 – 30 – 33 #

LGG - GTV

Diffuse pattern of infiltration

Best shown on MRI, especially T2W or FLAIR

MRI shows lesion slightly larger than CT

Infiltrates into functioning brain (unlike HGG which is destructive)

GTV – True extent of tumour

True extent of tumour

- **Gliomas:**
  - **Grade II: Everything that is T2 hyperintense is tumour!**

Oligodendroglioma

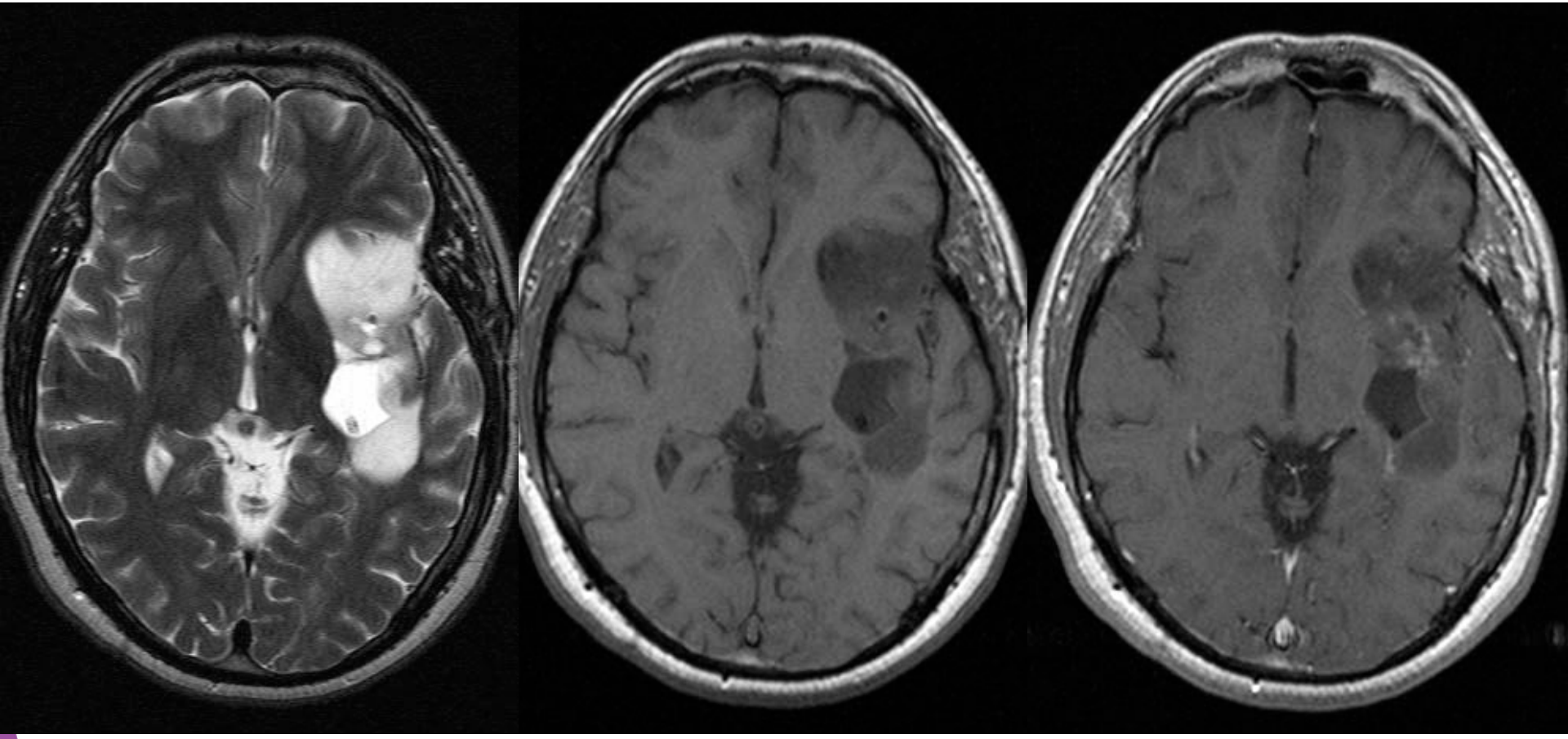

T2 **T1** **T1 + Gd**

Stefan Delorme

ESTRO School

Fibrillary Astrocytoma (WHO II)

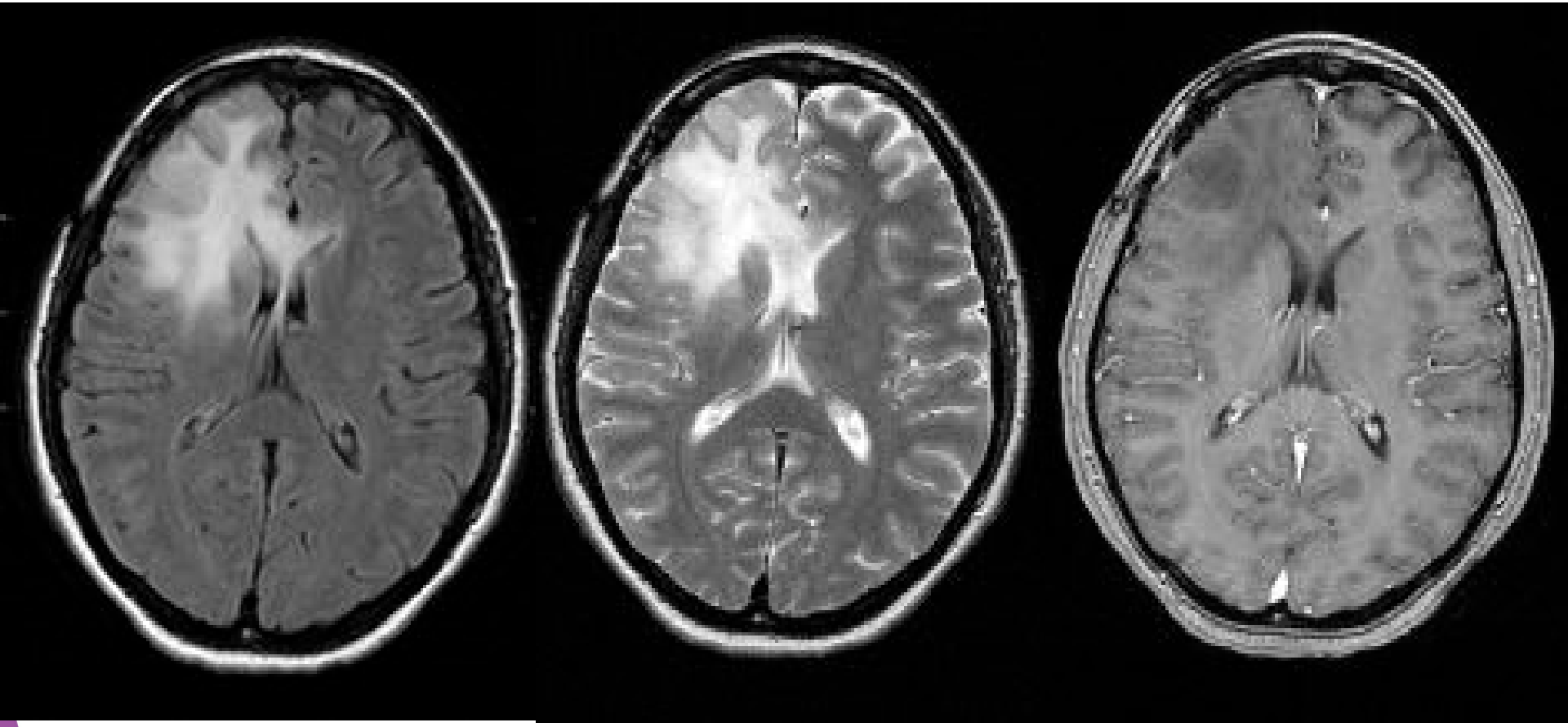

FLAIR **T2** **T1 + Gd**

Stefan Delorme

ESTRO School

Low grade glioma - CTV

Recurrence patterns

Pu et al, IJROBP 1995; 31(3): 461-466

- 11 patients
- Tumour (GTV) defined as T2 signal abnormality
- All recurred

All recurrences within GTV

LGG

Grade II oligodendroglioma

Calcification seen on CT

Little change due to rest of tumour

LGG

Whole tumour visible on MR

T2 (or FLAIR)

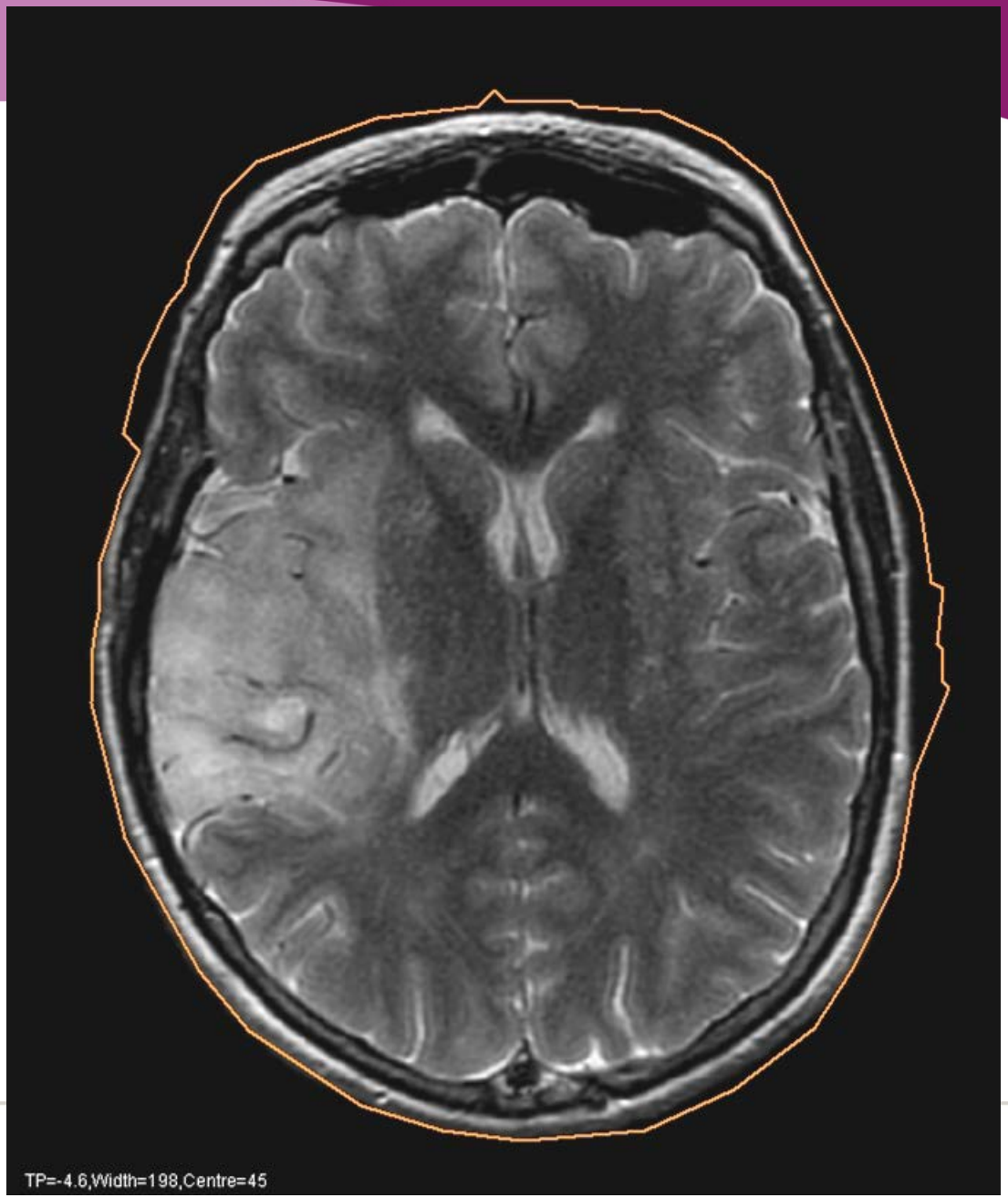

LGG

CT:MR

co-registered for planning

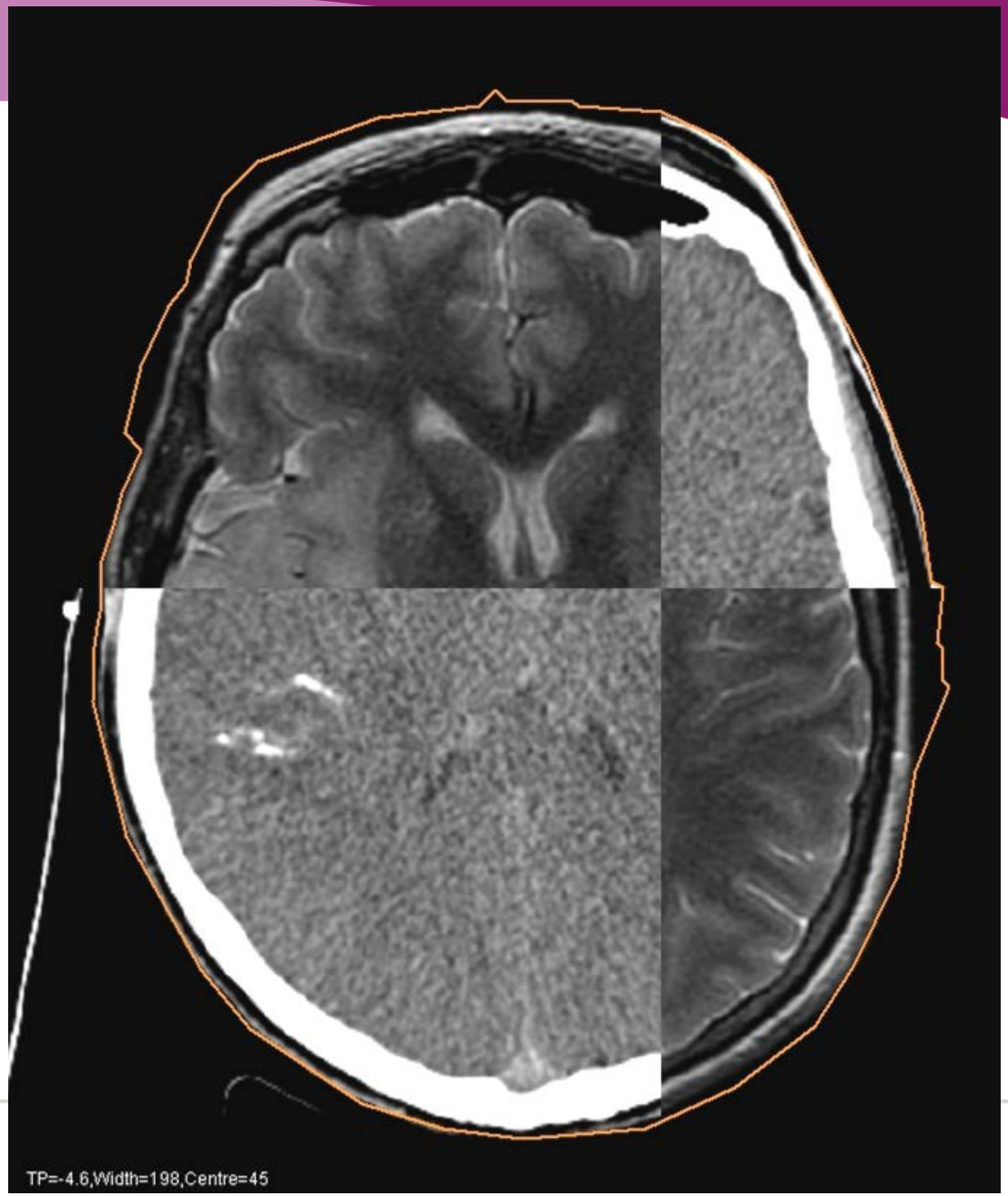

LGG

GTV defined as T2 abnormality

Some areas of edge still difficult to define

(deliberately not drawn exactly onto skull)

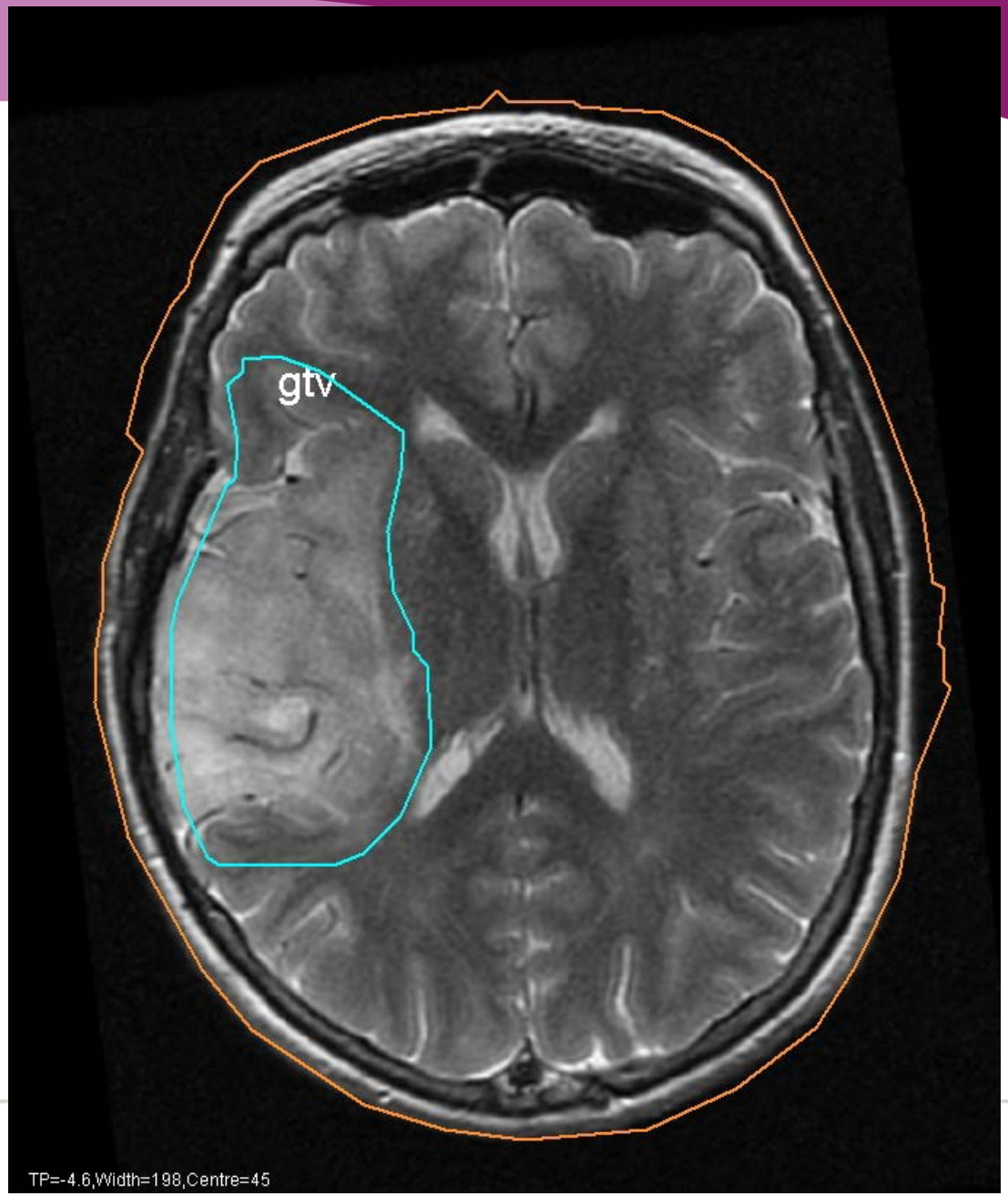

LGG

CTV added

Margin = 1.5 cm

Grown
isotropically,
up to skull

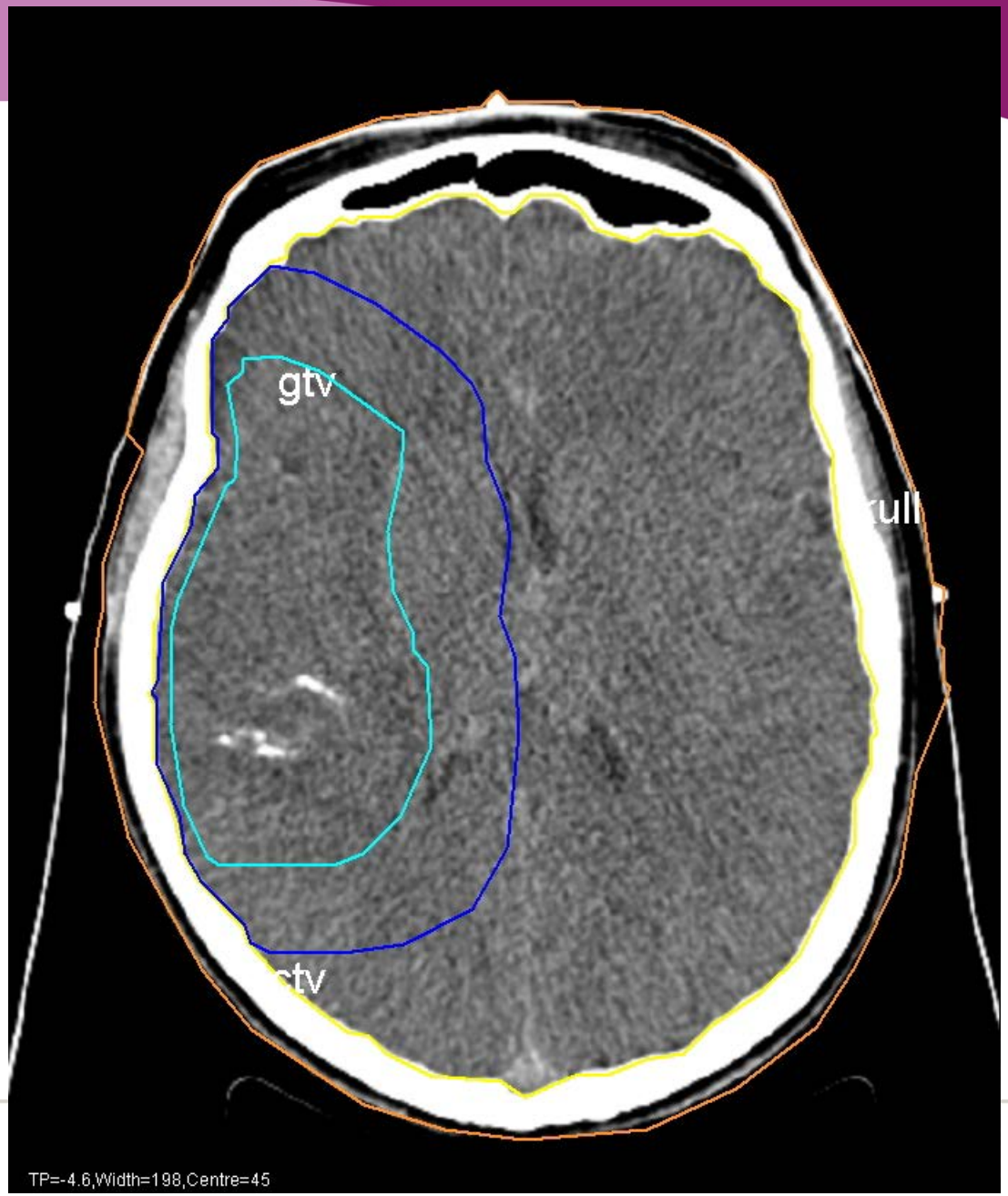

LGG – CTV Suggested margins

GTV = edge of low density on CT and/or high signal on T2W MRI/Flair

CTV = GTV plus 1.5 cm (1 - 2 cm)

Summary

Low grade gliomas

- GTV MR T2W/Flair
- CTV 1.5 cm
- PTV 0.5 cm

Total 2 cm

LGG cases

Deliver single phase

54 Gy/30# standard tumours

55 Gy/33# very large, brain stem

An example plan

- Excellent dose homogeneity
- Multiple OARs considered
- Generally good OAR sparing

Brainstem glioma – radiological grade II

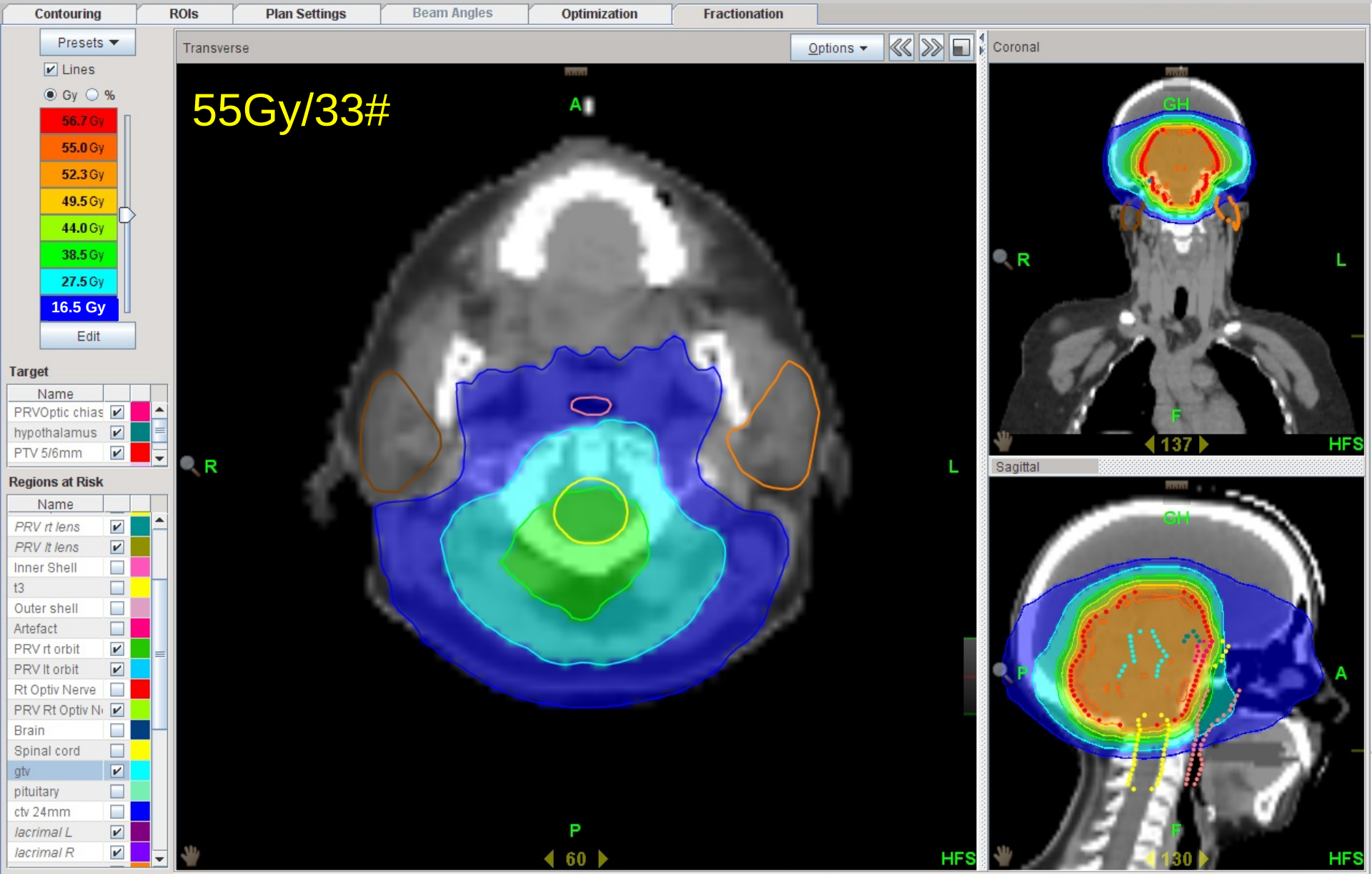

Brainstem glioma – radiological grade II

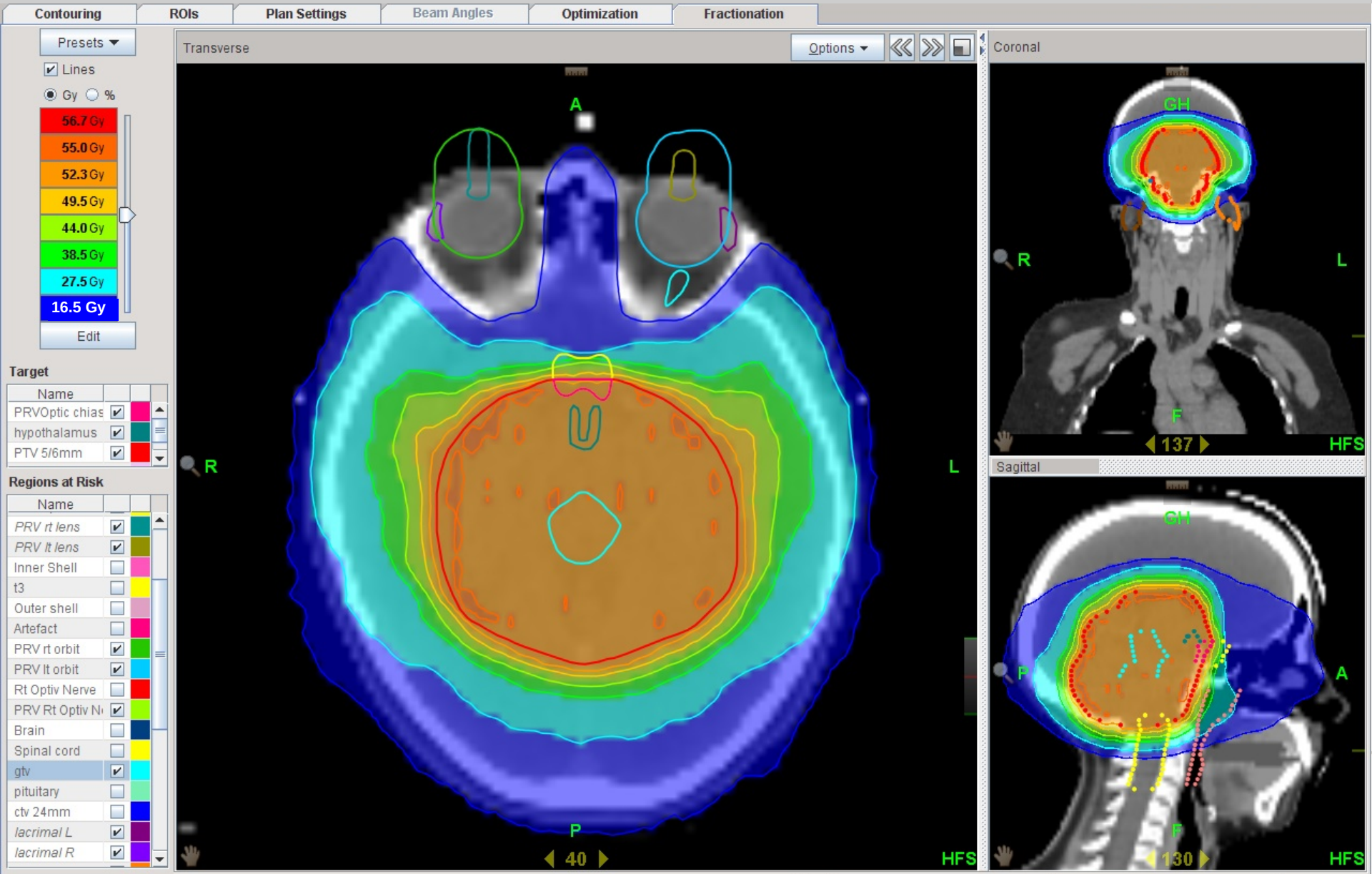

Brainstem glioma – radiological grade II

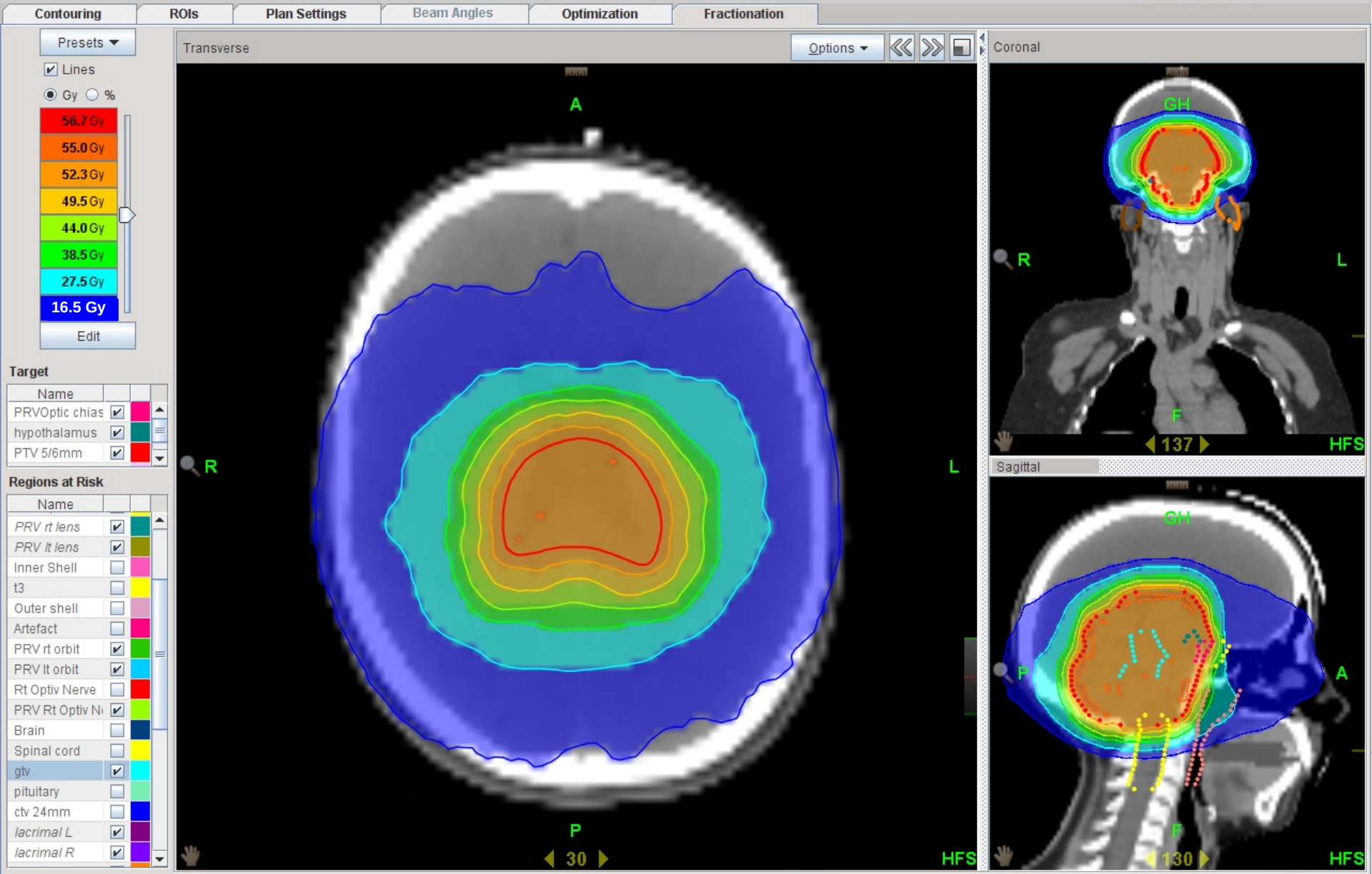

1

Brainstem glioma – radiological grade II

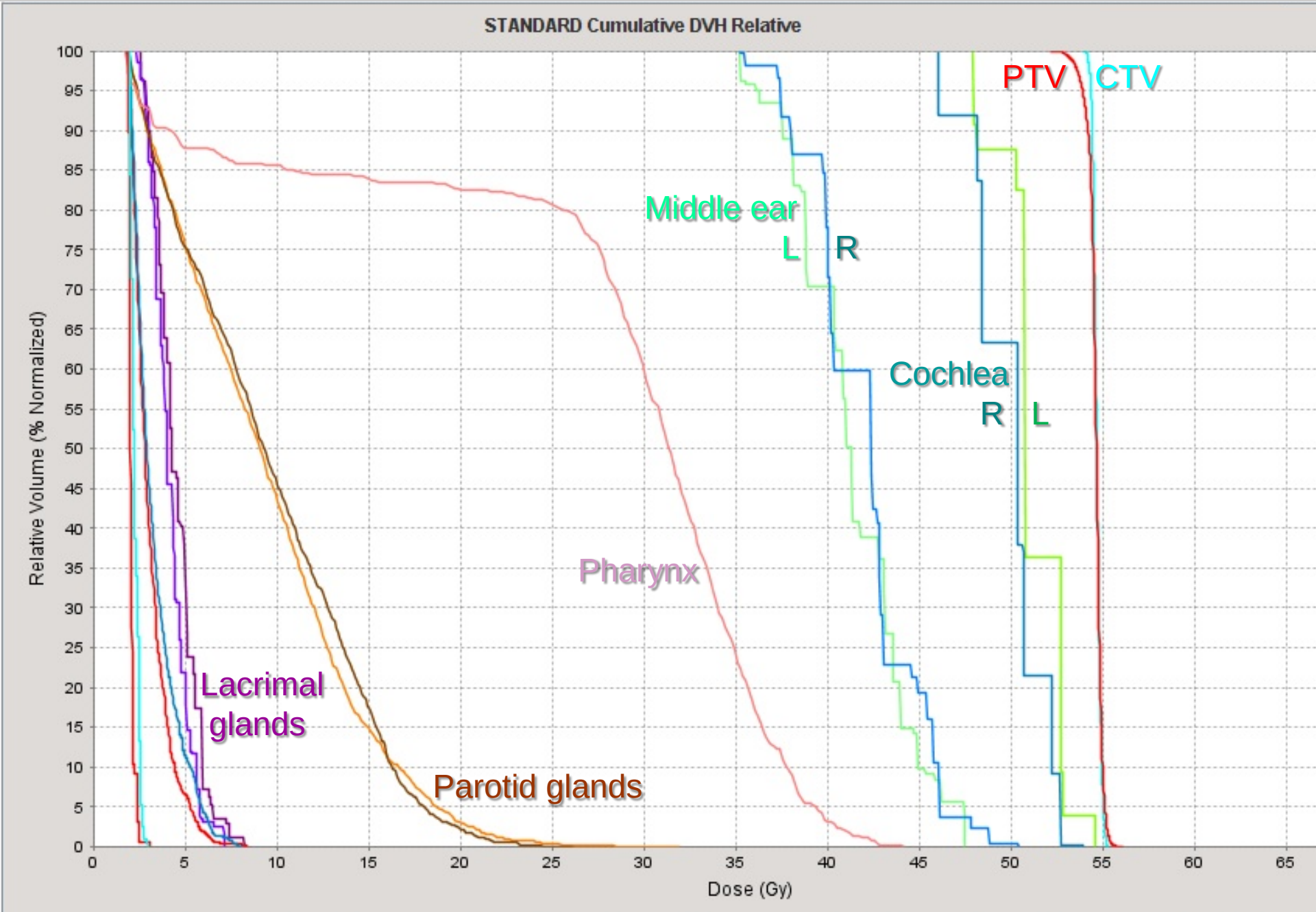

Normal tissue tolerance

New Guidelines for OAR

ARTICLE IN PRESS

Radiotherapy and Oncology xxx (2015) xxx–xxx

Contents lists available at ScienceDirect

Radiotherapy and Oncology

journal homepage: www.thegreenjournal.com



Original article

CT-based delineation of organs at risk in the head and neck region: DAHANCA, EORTC, GORTEC, HKNPCSG, NCIC CTG, NCRI, NRG Oncology and TROG consensus guidelines

Charlotte L. Brouwer [a,*,1], Roel J.H.M. Steenbakkers [a,1], Jean Bourhis [b], Wilfried Budach [c], Cai Grau [d], Vincent Grégoire [e], Marcel van Herk [f], Anne Lee [g], Philippe Maingon [h], Chris Nutting [i], Brian O'Sullivan [j], Sandro V. Porceddu [k], David I. Rosenthal [l], Nanna M. Sijtsema [a], Johannes A. Langendijk [a]

http://dx.doi.org/10.1016/j.radonc.2015.07.041

ESTRO School

Normal tissue tolerance

Normal tissue tolerance limits RT doses

RT ‘tolerance’ depends on context

- What is an acceptable risk depends on the tumour
- Higher risk, from higher dose, is acceptable where risk of disease recurrence is high – like GBM

But

- As survival increases, same risk may be less acceptable

Optic nerve tolerance & risk

What is the tolerance of the optic pathway ?

Might tolerance be altered by concurrent TMZ ?

Optic nerve tolerance & risk

Emami 1991 – (blindness within 5 years)

Probably too conservative

5% risk 50 Gy 50% risk 65 Gy

Mayo 2010 – for 1.8 – 2.0 Gy/#

50 Gy = "near zero" incidence

3 – 7% risk 55 – 60 Gy (? 5% for 57.5 Gy)

(Tolerance ***might*** be lower with co-morbidity)

Emami B et al IJROBP 1991; 21: 109-122

Mayo C et al IJROBP 2010; 76(3 Suppl): S28–S35 (QUANTEC)

Chemo + RT for GBM

Lancet Oncol 2009; 10: 459–66

Stupp et al.

~ 20% 3 year survival ~10% 5 year survival

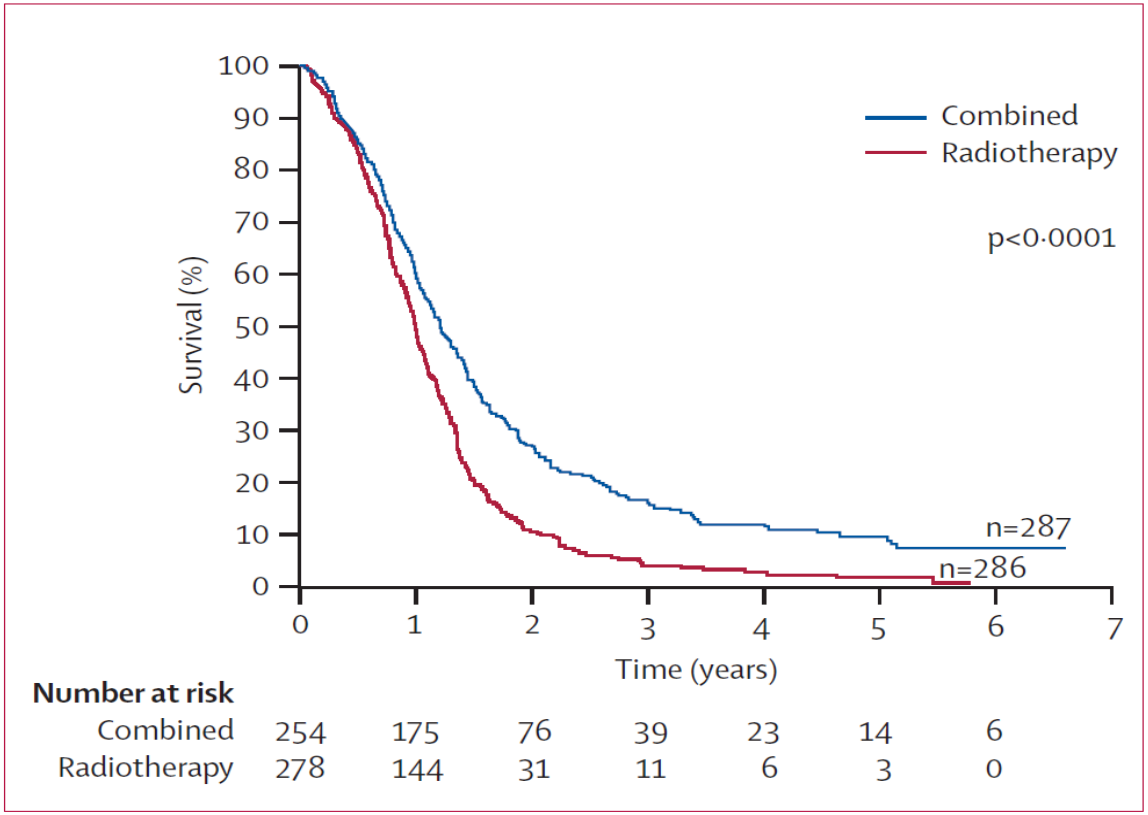

Figure 2: **Kaplan-Meier estimates of overall survival by treatment group**

ESTRO School

Optic nerve tolerance & risk

Stupp trial (Ataman EJC 2004)

The recommended maximum doses were below 55 Gy for the optic chiasm (and brainstem)

In QA on 53 cases; optic chiasm dose known in 48

Max dose > 55 Gy in 10/48 cases (i.e. ~ 20%)

Ataman Eur J Cancer 2004: 40: 1724-1730

ESTRO School

Optic nerve tolerance & risk

Stupp 2009 - risk with 55/60 Gy + TMZ

1 patient affected	~ 20% - dose assumed to be 60 Gy
	~ 200 alive at risk at 9 months
	~ 100 alive at risk at 2 years
	~ 20 pts at risk
Therefore risk*	~ 1 in 20 = 5%

But 17pts alive @ 5 years

ESTRO School

Optic nerve tolerance & risk

Emami et al IJROBP 1991

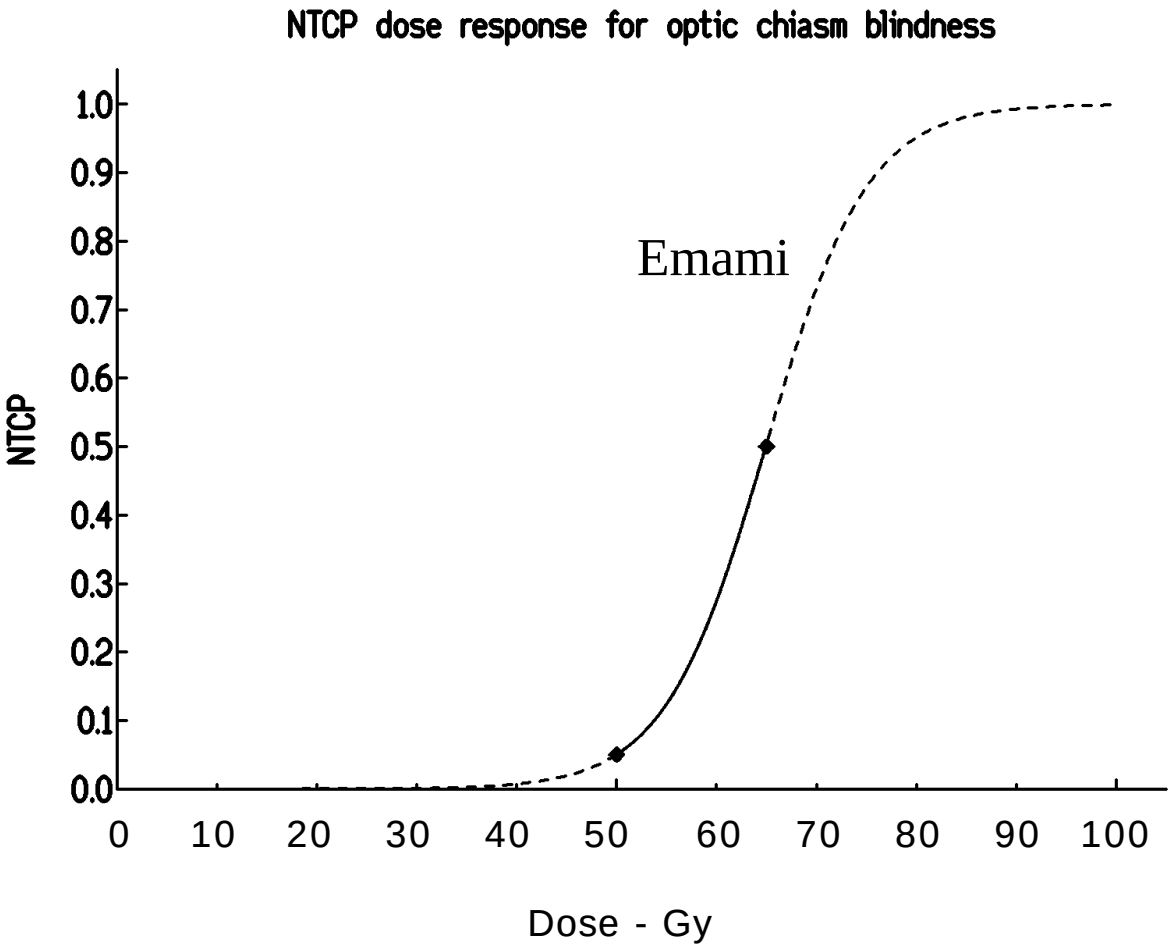

Optic nerve tolerance & risk

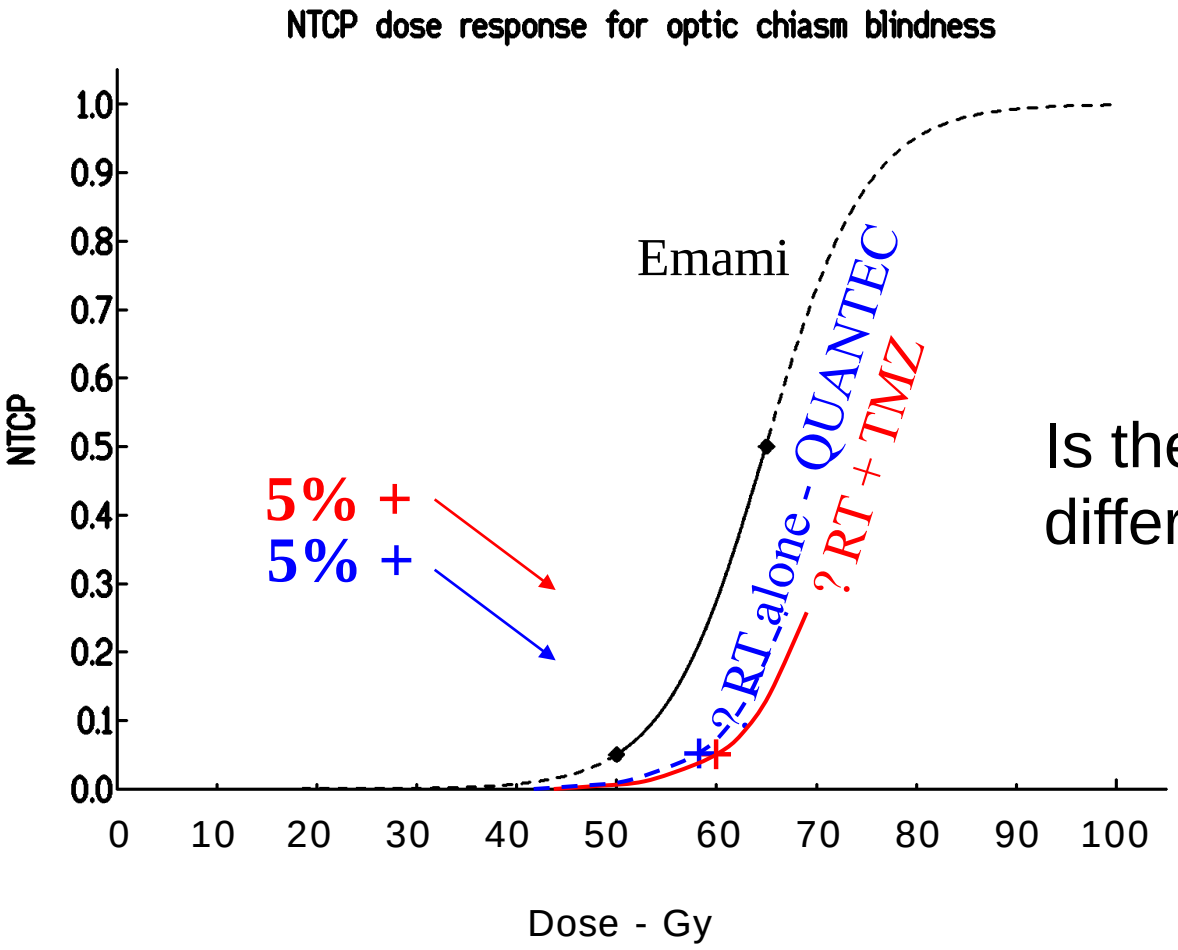

Is there a difference?

Optic nerve tolerance & risk

Comparing review with trial data suggests ***no*** increase in risk from the addition of TMZ to RT

Therefore the risk can be considered – recommended maximum doses

- Optic pathway – 55Gy
- Brainstem - 55Gy

- In some cases higher doses can be considered

Thank you !

ESTRO School

ANATOMY & LYMPH NODE DRAINAGE FOR UPPER GI CANCER

Dr Brendan Carey
St James's University Hospital
Leeds
UK

- Normal Anatomy
- Tumour Anatomy

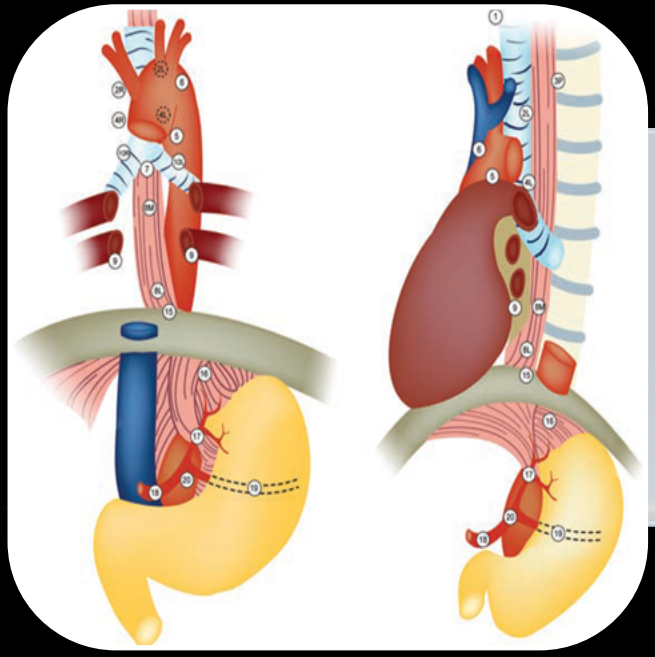

- Nodal Drainage

IMAGING THE ANATOMY

CT → EUS → PET CT

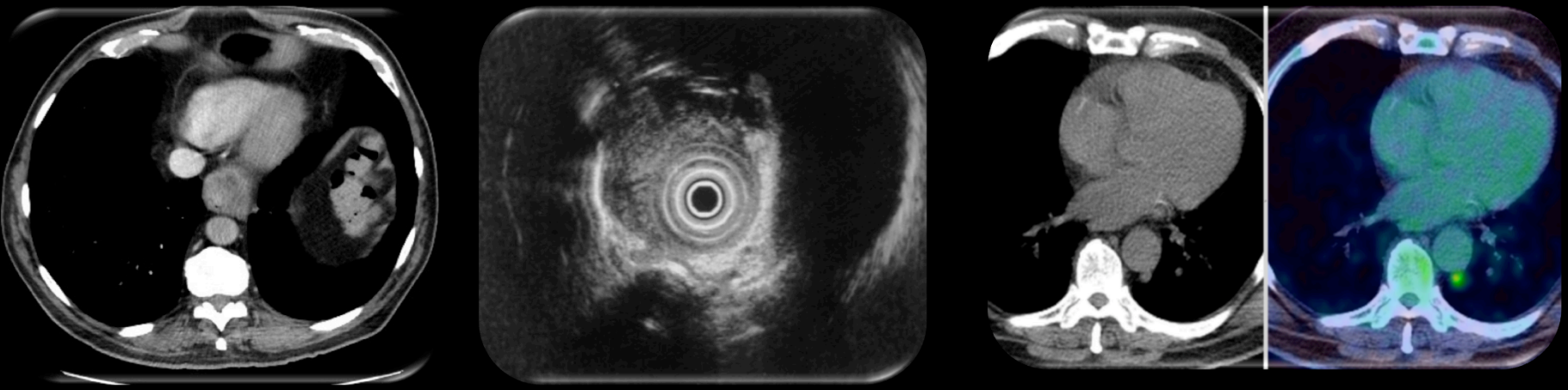

UPPER GI CANCER : ANATOMICAL IMAGING

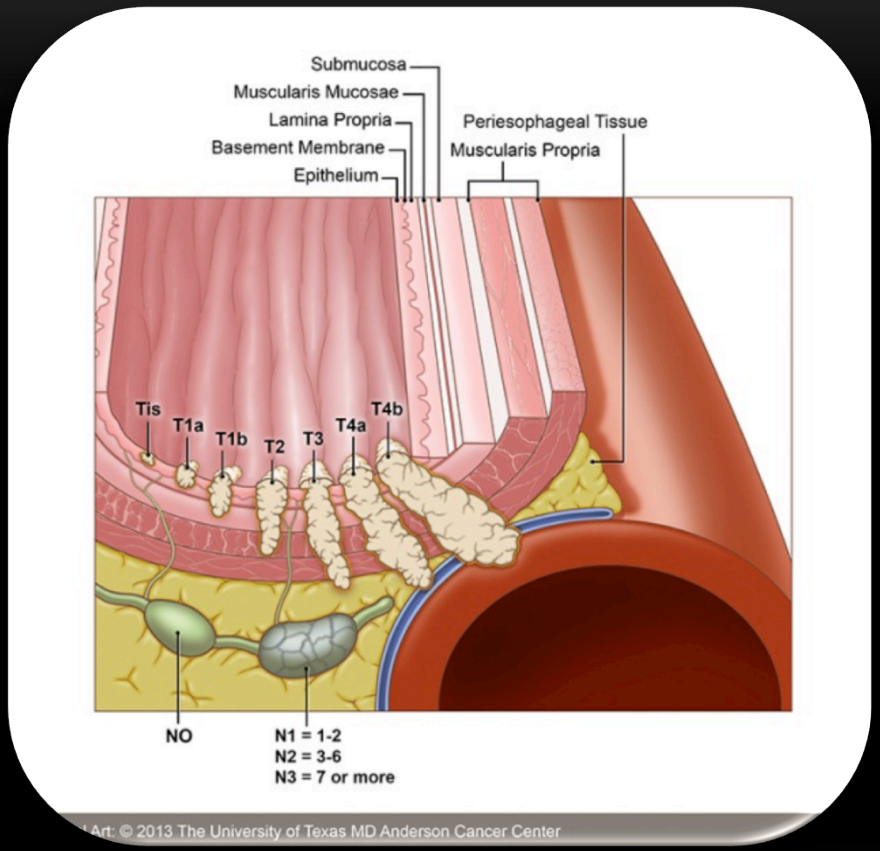

- **CT** is the initial imaging and staging following pathological confirmation of the tumour
- **PET/CT** is the most sensitive test for distant disease
- **EUS** is the best modality for ascertaining depth of tumour invasion and presence of regional lymph nodes

OESOPHAGUS 7TH EDITION
(2009)

N0	No regional lymph node metastasis
N1	1 to 2 regional lymph nodes
N2	3 to 6
N3	>6
M0	No Distant Metastasis
M1	Distant metastasis present

Tis	Carcinoma in situ /High-grade dysplasia
T1	lamina propria / submucosa
	T1a lamina propria / muscularis mucosae
	T1b submucosa
T2	muscularis propria
T3	adventitia
T4	adjacent structures
	T4a pleura, pericardium, diaphragm, or adjacent peritoneum
	T4b other adjacent structures,
	(aorta, vertebral body, trachea)

ANATOMY OESOPHAGUS

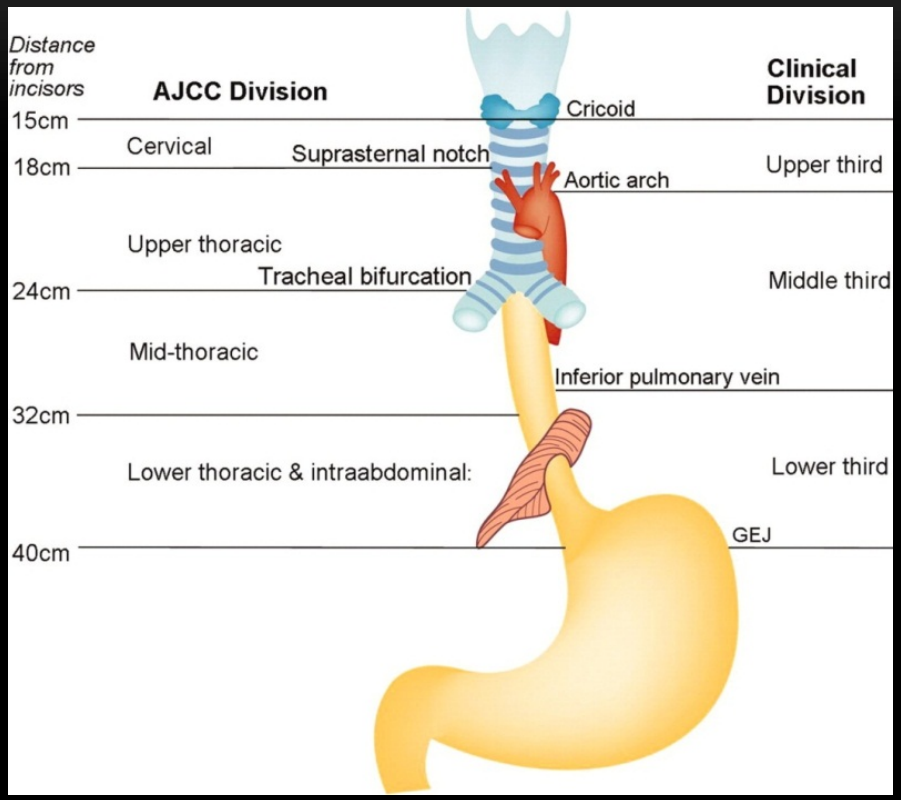

- In clinical practice, most radiologists and surgeons divide the oesophagus into three parts:
- upper third, from the cricopharyngeus to the superior portion of the aortic arch;
- middle third, from the superior portion of the aortic arch to the inferior pulmonary vein;
- Distal third, from the inferior pulmonary vein to the gastroesophageal junction

The behaviour and treatment of oesophageal cancer vary with these anatomic locations.

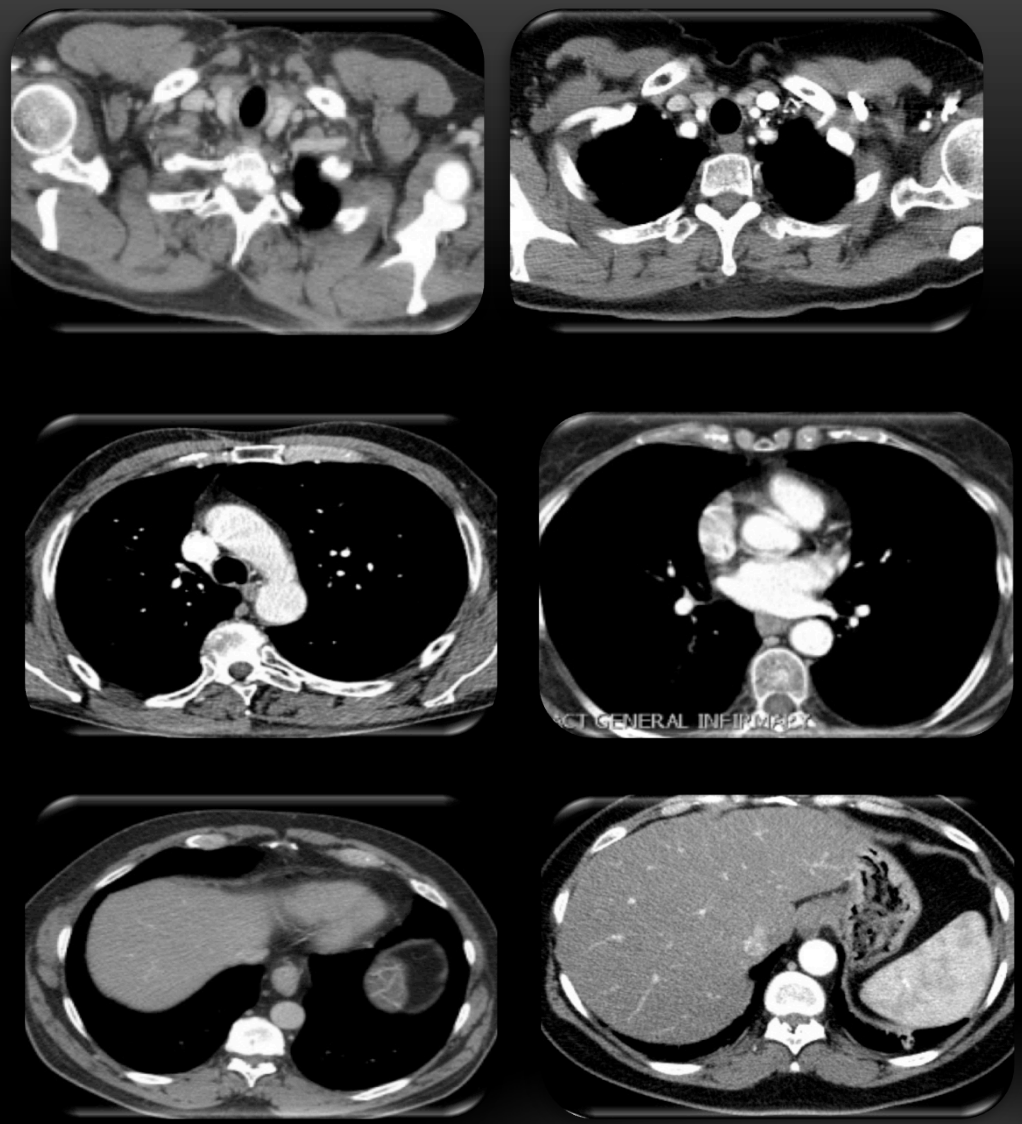

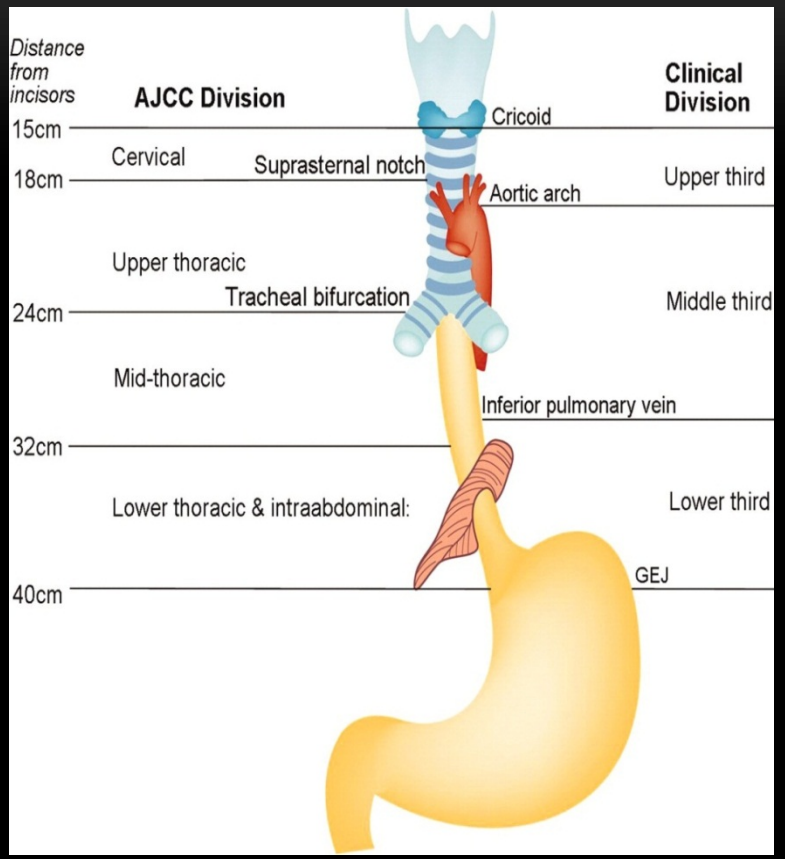
Distance from incisors
AJCC Division
Clinical Division
15cm
Cricoid
Cervical
Suprasternal notch
18cm
Upper third
Aortic arch
Upper thoracic
Tracheal bifurcation
24cm
Middle third
Mid-thoracic
Inferior pulmonary vein
32cm
Lower thoracic & intraabdominal:
Lower third
GEJ
40cm

The normal esophageal wall is usually less than 3 mm thick at CT when the oesophagus is distended

any wall thickness greater than 5 mm is considered abnormal

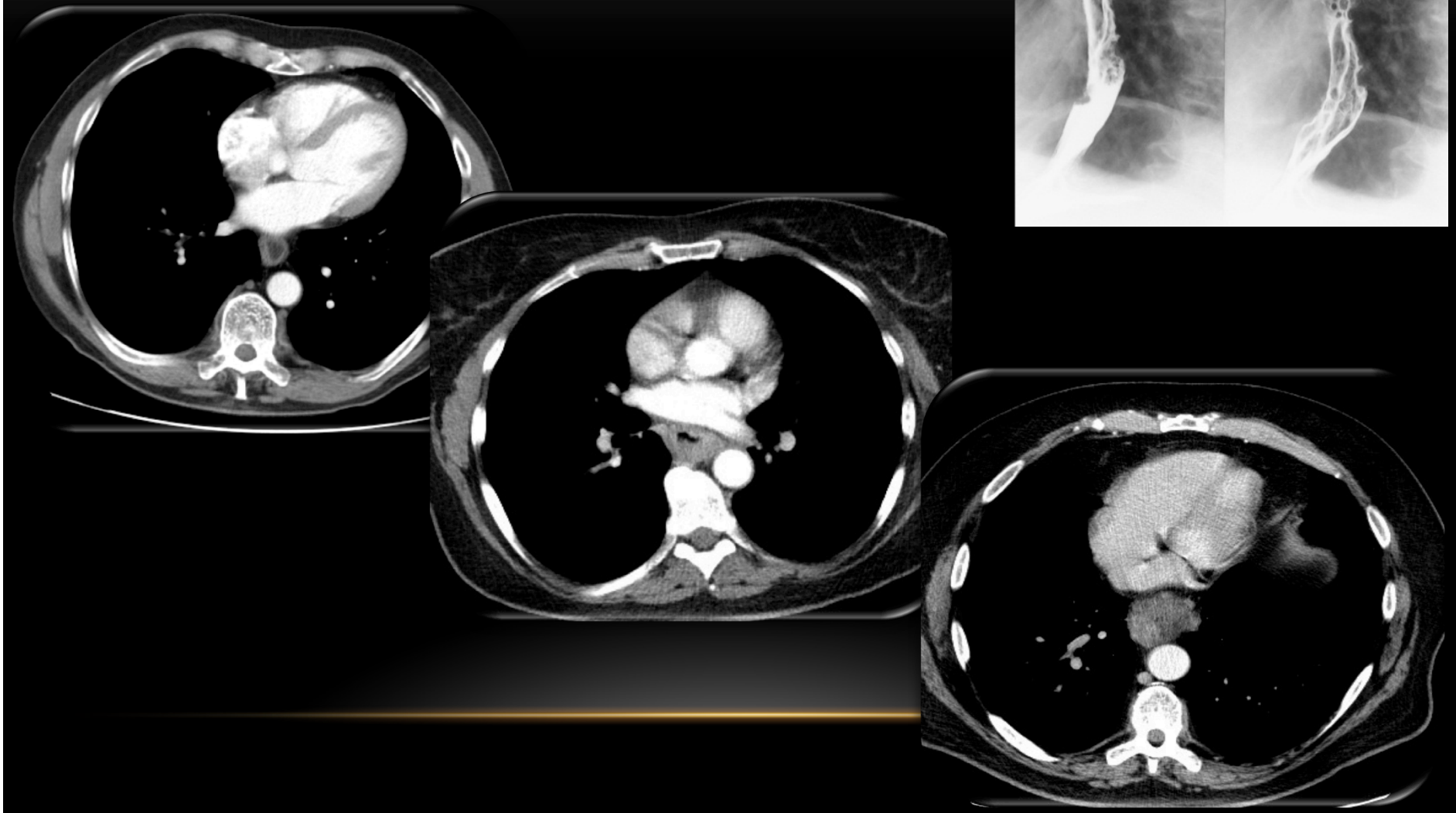

Anteriorly, the oesophagus is related to the trachea, right pulmonary artery, left bronchus, pericardium with left atrium, and diaphragm.

The thoracic duct lies on the left side, and the left recurrent laryngeal nerve lies in the left tracheoesophageal groove. Laterally, on the left side, it is related to the aorta and left subclavian artery; on the right side, it is related to the azygos vein.

In the posterior mediastinum, the oesophagus is related to the descending thoracic aorta, left mediastinal pleura, azygos vein, and cardiac and pulmonary pleura

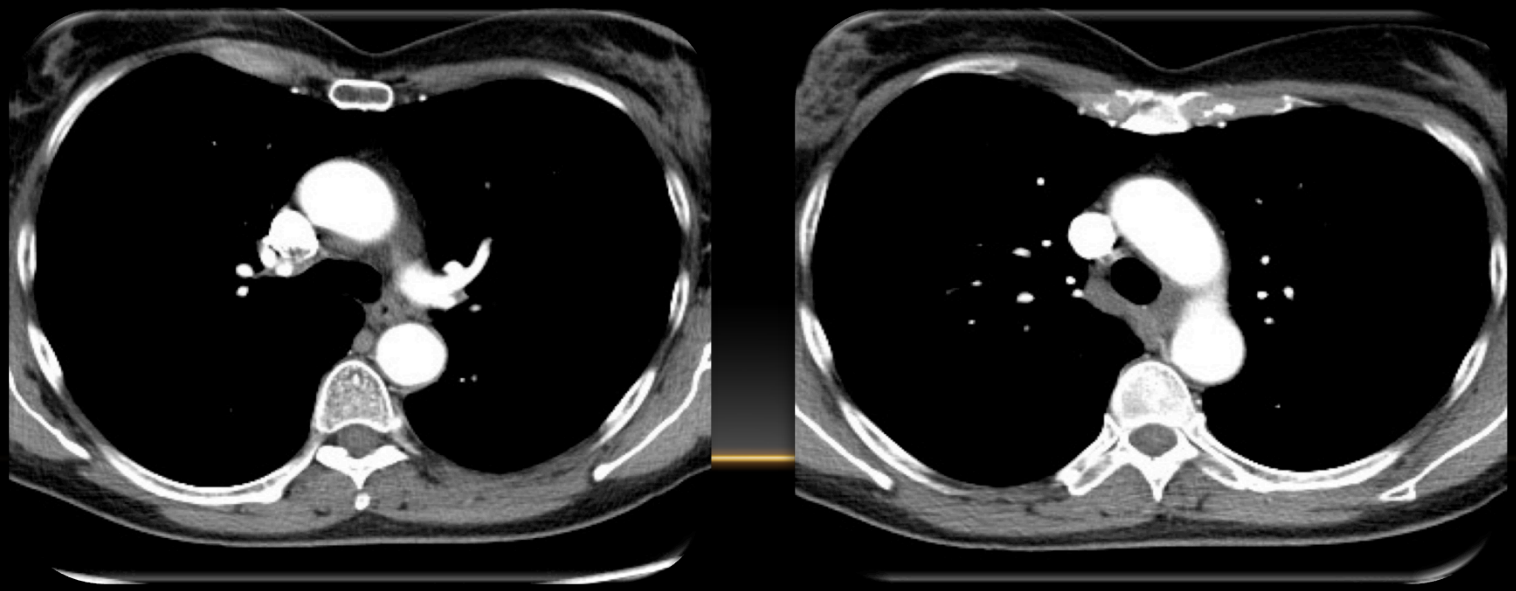

The oesophagus passes through the right crus of the diaphragm

It lies in the oesophageal groove on the posterior surface of the left lobe of the liver and curves sharply to the left to join the stomach at the cardia.

The right border continues evenly into the lesser curvature, whereas the left border is separated from the fundus of the stomach by the cardiac notch.

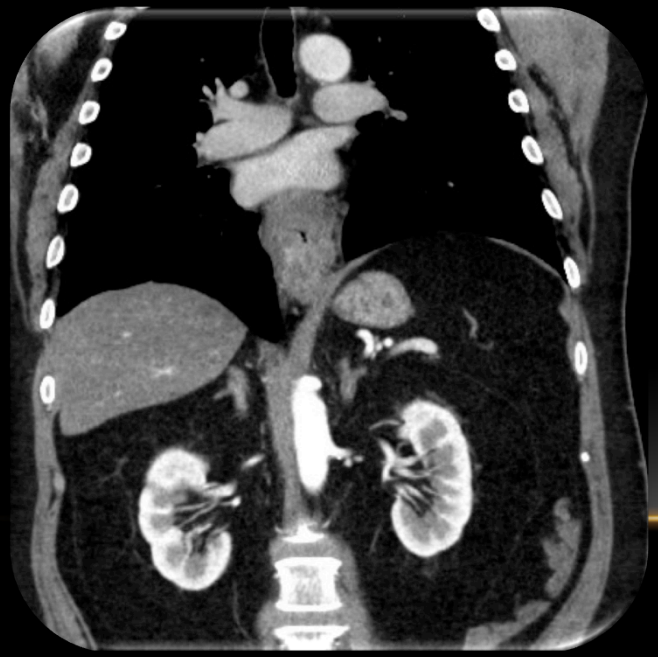

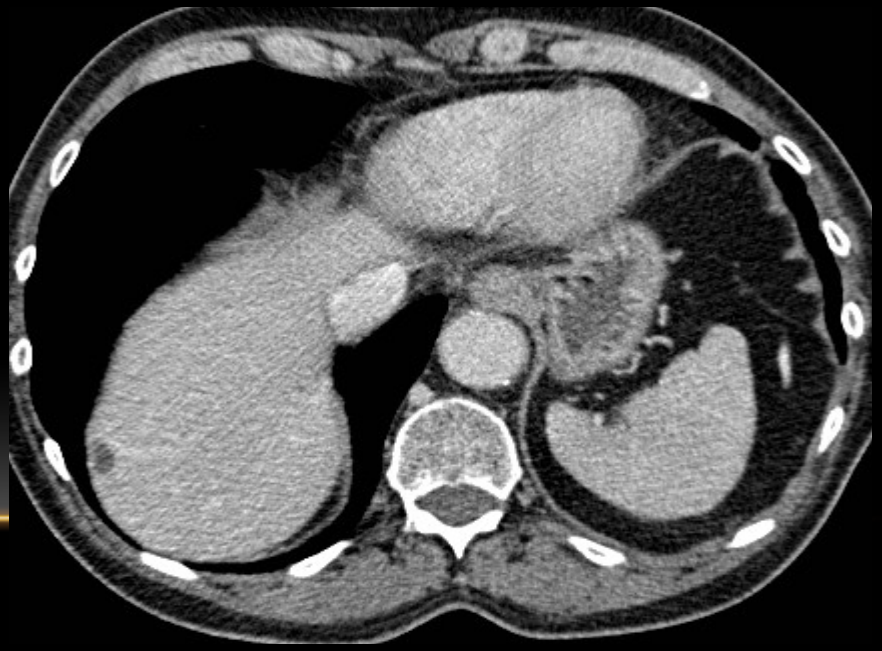

The postcricoid region of the hypopharynx includes the mucosa and submucosa extending from the inferior aspect of the arytenoids to the bottom of the cricoid cartilage.

The lateral margins merge with the medial wall of each pyriform sinus at approximately that level where the cricoid cartilage makes an anterior bend.

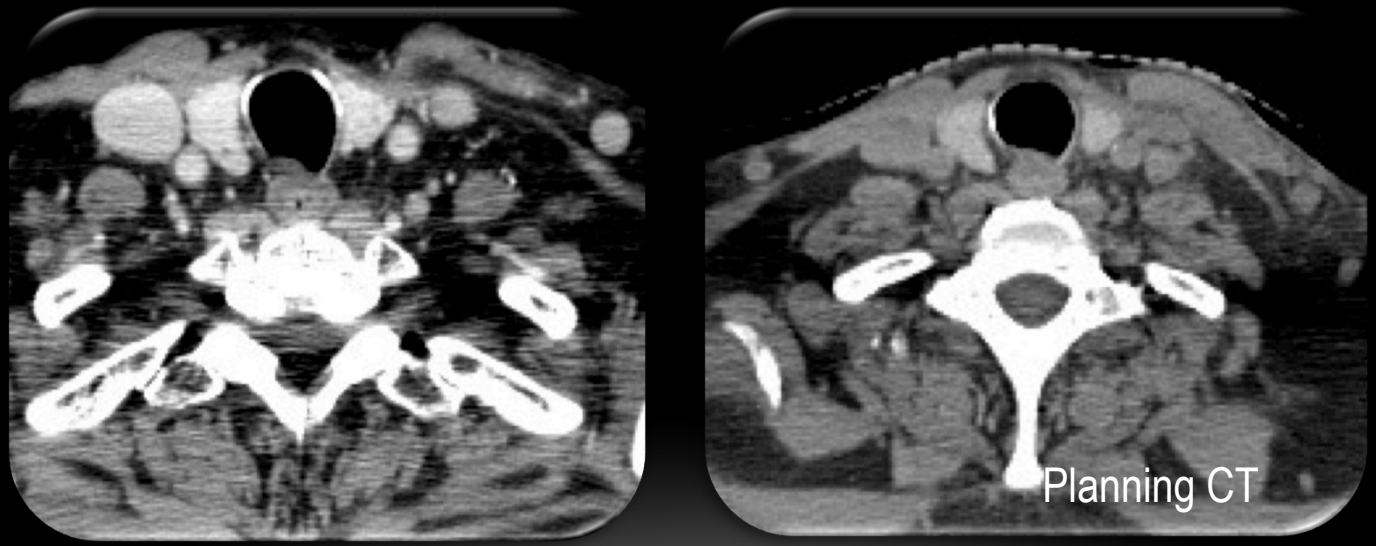

The regional lymph node “map” is important for clinical staging and lymph node sampling

All lymphatic channels intercommunicate- lymphatic fluid from any portion of the oesophagus may move to any other portion and may spread to any region of the thorax or draining nodes.

Tumours in the distal oesophagus are more likely to metastasize to the abdomen,

Lymphatic spread of cancer in the upper or midesophagus can also result in metastasis to celiac or other abdominal lymph nodes.

The flow of lymph in the upper two-thirds of the oesophagus tends to be upward, whereas that in the distal third tends to be downward

EUS is the most accurate T-staging investigation (e.g. accuracy of up to 95% for T3 and T4 disease)

CT makes a very useful contribution to the T-stage, especially in recognising T3 disease and alerting to possible T4 involvement (e.g. accuracy of 85% for mediastinal invasion)

PET does not have any major role in T-staging (e.g. sensitivity of <50% for T1).

Role is in N and M staging

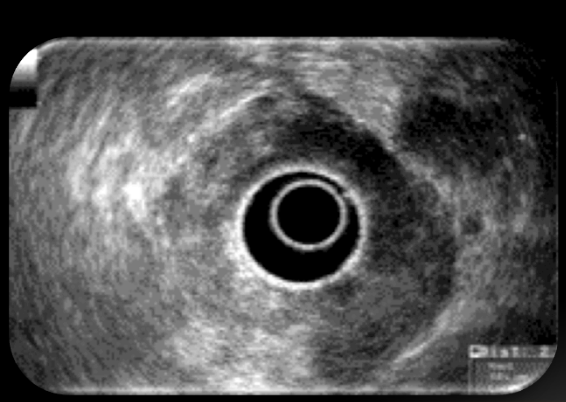

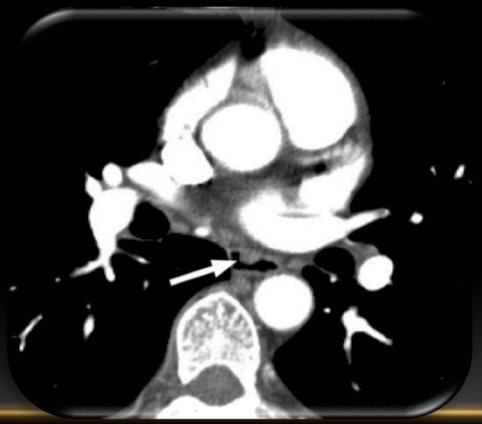

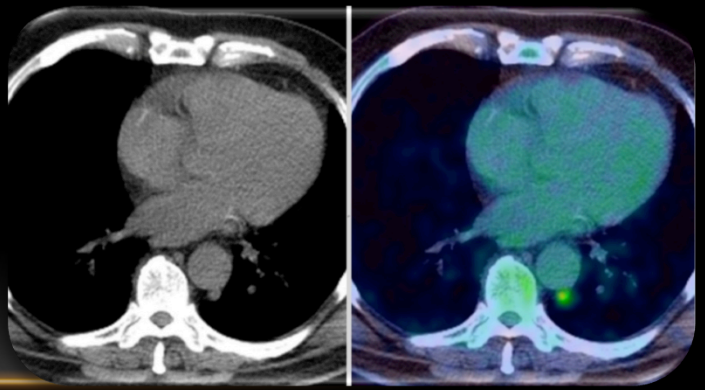

EUS: T-STAGING

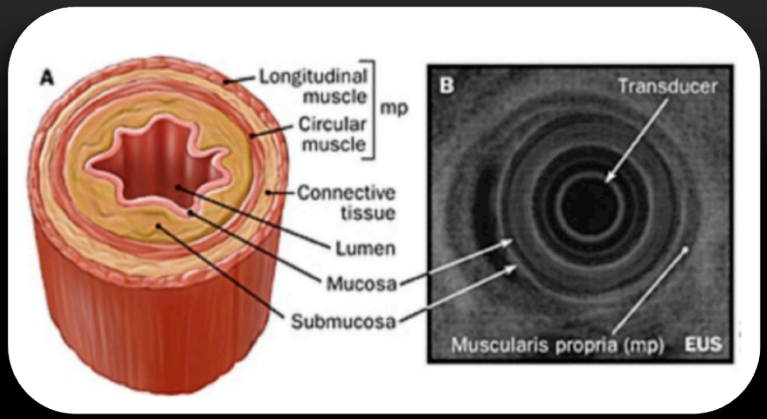

The oesophageal wall is visualized as five alternating layers of differing echogenicity, allowing accurate preoperative determination of the depth of tumour invasion .

Endoscopic US can accurately help differentiate between T1, T2, and T3 disease, which is important for neoadjuvant treatment

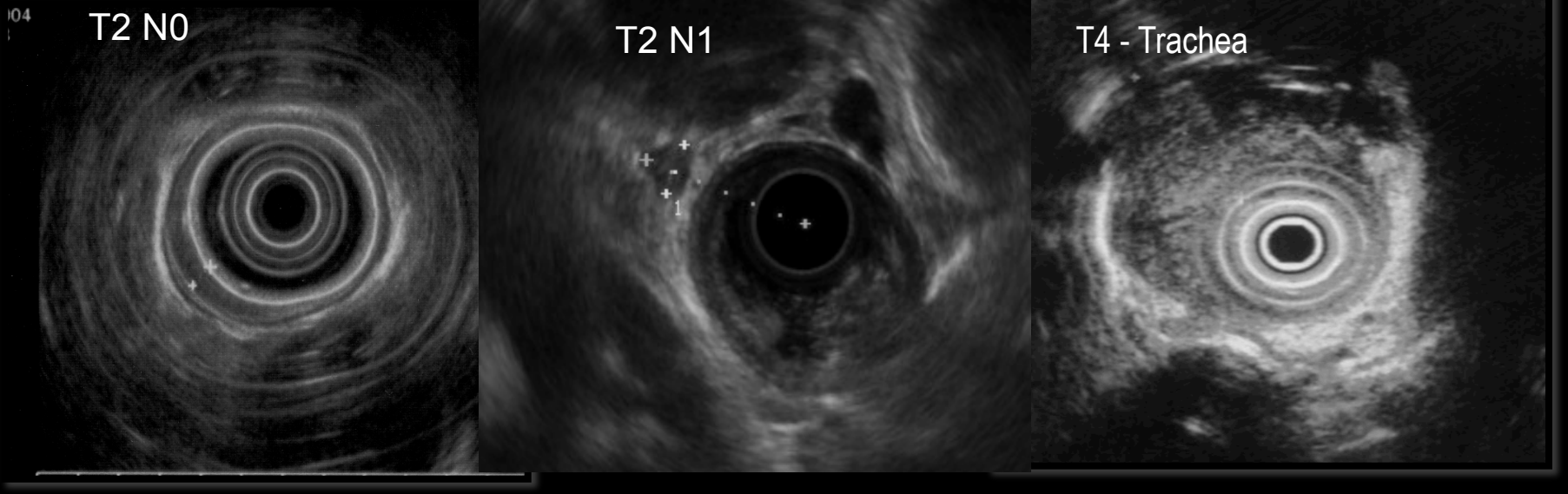

EUS: LIMITATIONS

- Operator dependent
- Inter-observer variability
- Non-traversable tumours
- Risk of perforation (<1%)

The OVERALL primary oesophageal tumour detection rate with PET-CT is approx. 92.7%

The limited spatial resolution of PET particularly limits visualization of early-stage carcinomas with small volumes (Tis, T1 and T2).

Another consequence of the poor spatial resolution of PET and the poor contrast resolution of CT, is the limited role in evaluating the depth of invasion (T-stage) of oesophageal cancers.

EUS is the preferred method for primary tumour staging

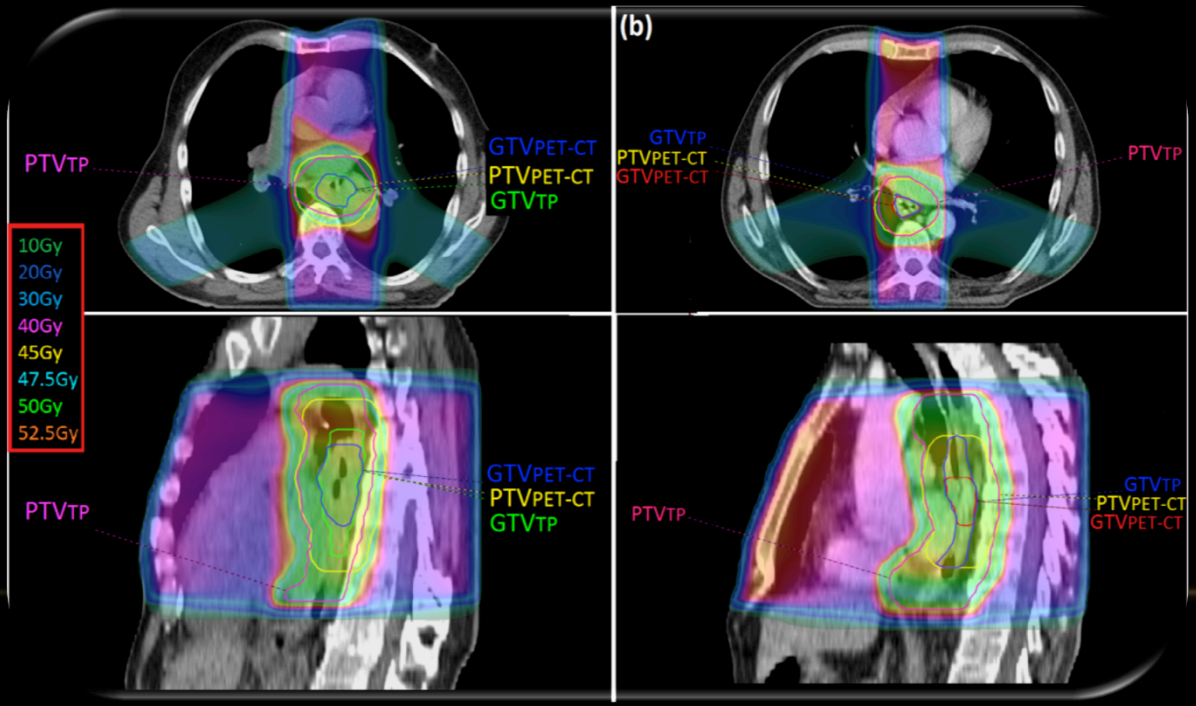

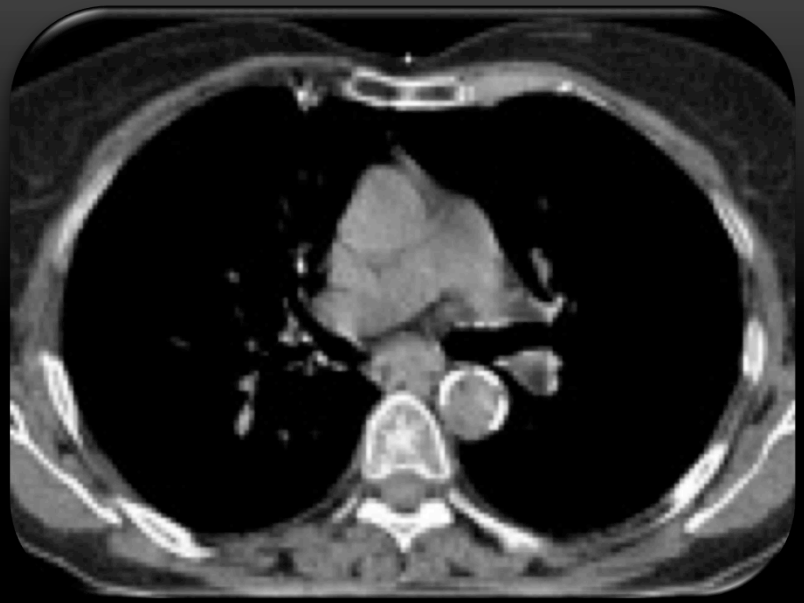

68 year old with mid oesophagus adenocarcinoma

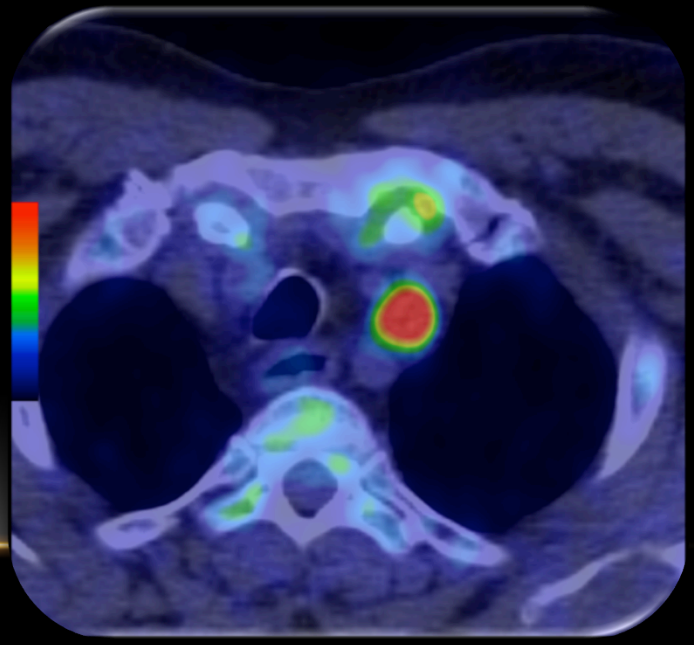

60 year old with distal oesophagus adenocarcinoma

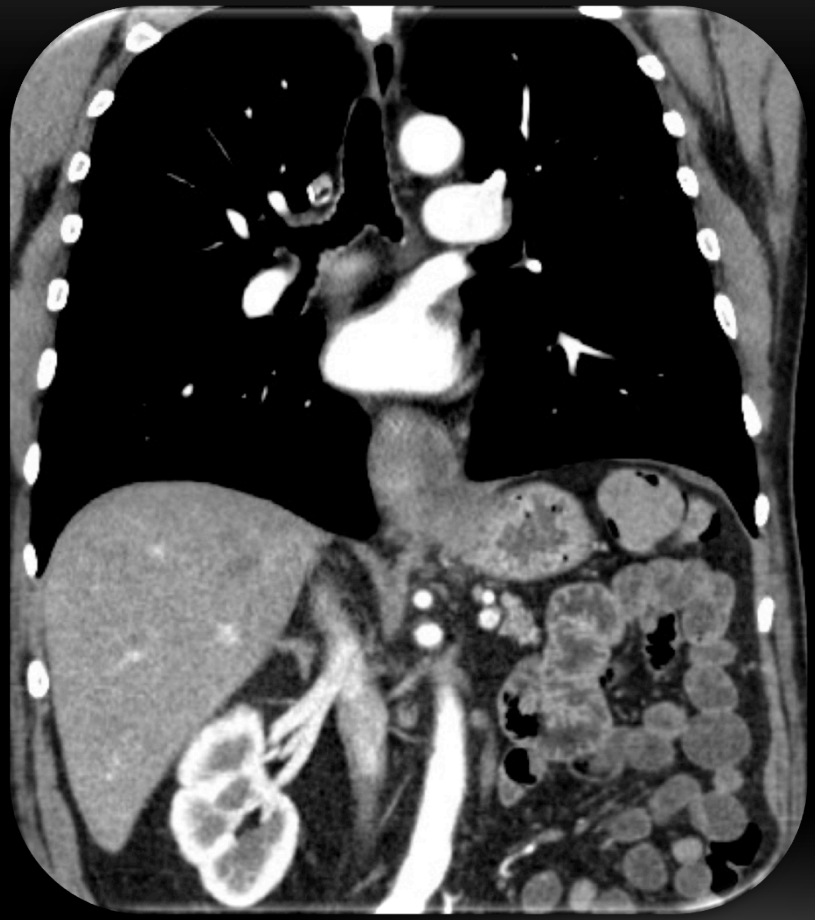

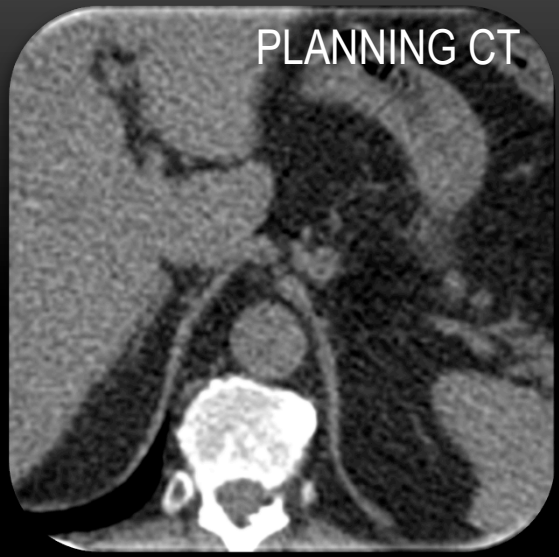

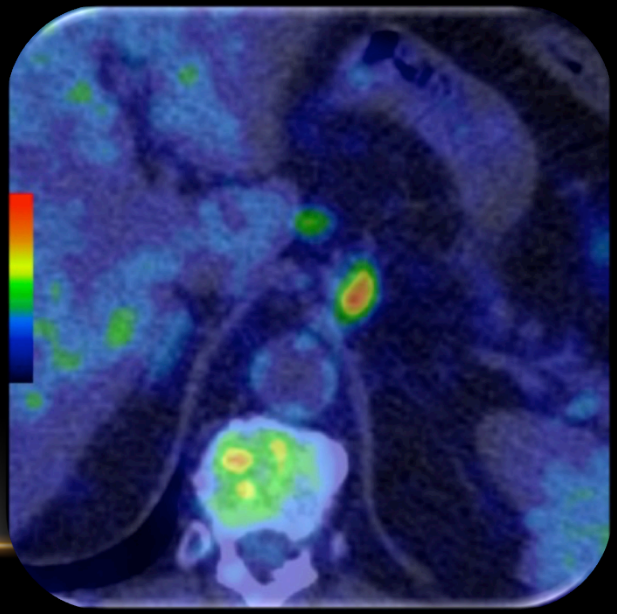

CT (+ EUS) are most commonly used for defining GTV in oesophageal cancer, but CT is not able to precisely demonstrate the proximal and distal margins of oesophageal tumours in many cases.

PET-CT enables delineation of the biologically active tumour volume, and its depiction of oesophageal tumours has been shown to correlate well with patholgy

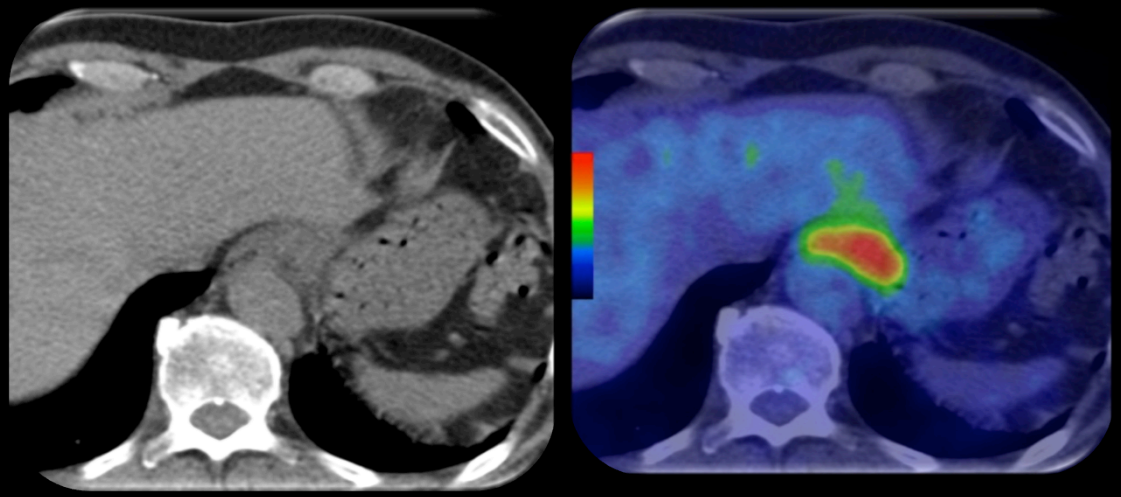

Standard implementation of PET-CT into the tumour delineation process for radiation treatment planning remains subject of research and requires further clinical validation

Malignant tumours of the cervical oesophagus are uncommon and account for only 2–10% of all carcinomas of the oesophagus.

Carcinoma of the cervical oesophagus easily and frequently extends upward to the hypopharynx or downward to the thoracic oesophagus.

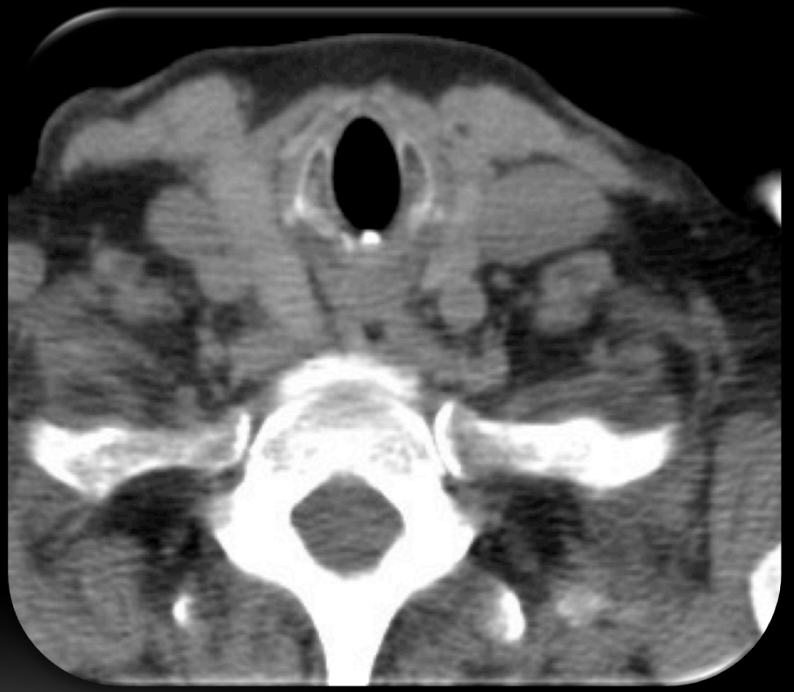

N-STAGING

CT uses size criteria for depiction of nodal disease, with an overall accuracy of only 45-60%.

EUS uses several criteria, i.e. size, shape, echogenicity, and borders, with an overall accuracy of 75-85% for local nodes.

PET has relatively poor sensitivity (50%) but high specificity (85%), and is useful in detecting diseased nodes *distant* to the tumour

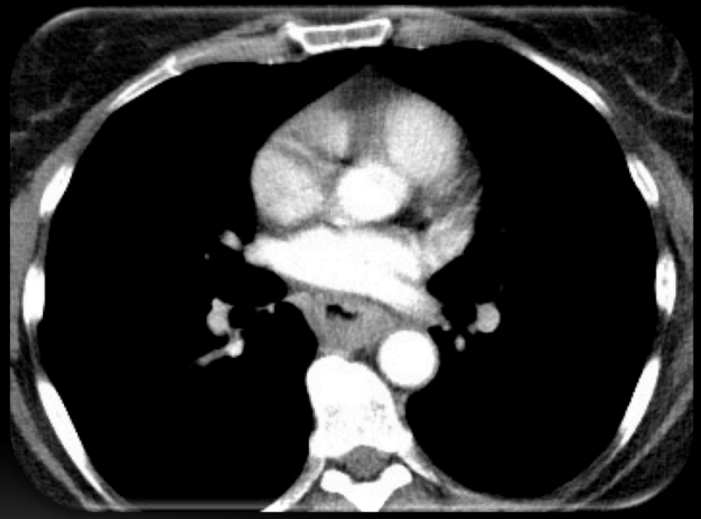

In tumours located in the lower oesophagus, node metastases are more frequent in the upper mediastinum than the mid-mediastinum or lower mediastinum.

Tumours in the mid-oesophagus, node metastases are often more frequent in the supraclavicular area than the mid or lower mediastinum.

Tumours in the distal oesophagus are more likely to metastasize to the abdomen, lymphatic spread of cancer in the upper or mid oesophagus can also spread to celiac nodes

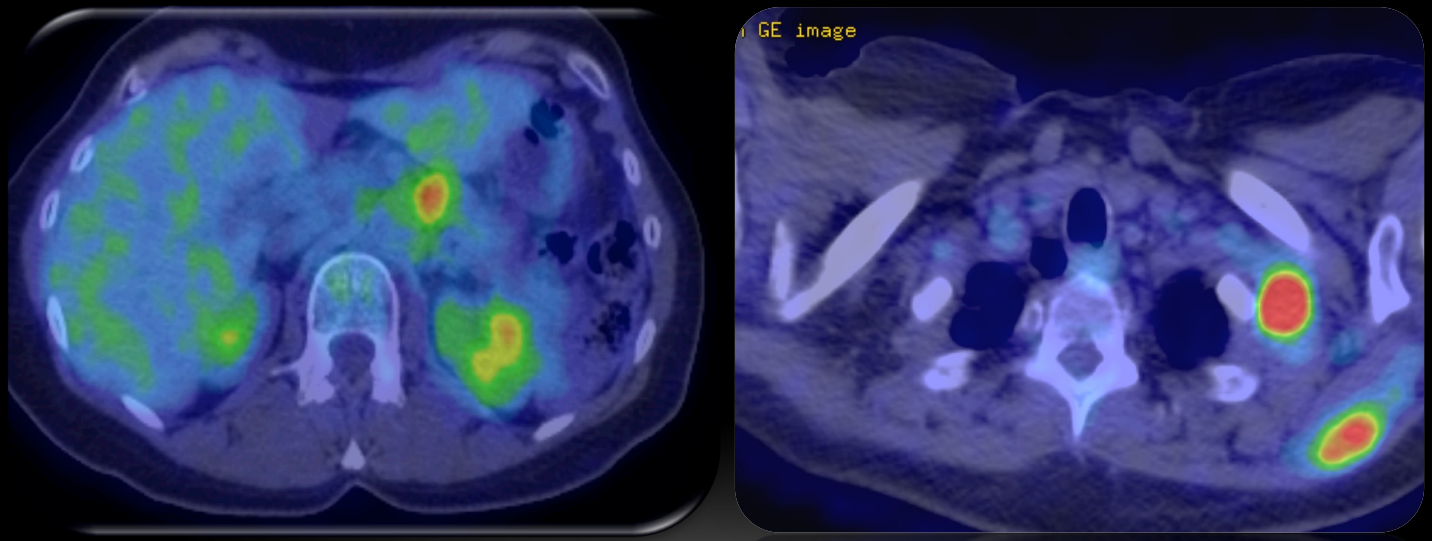

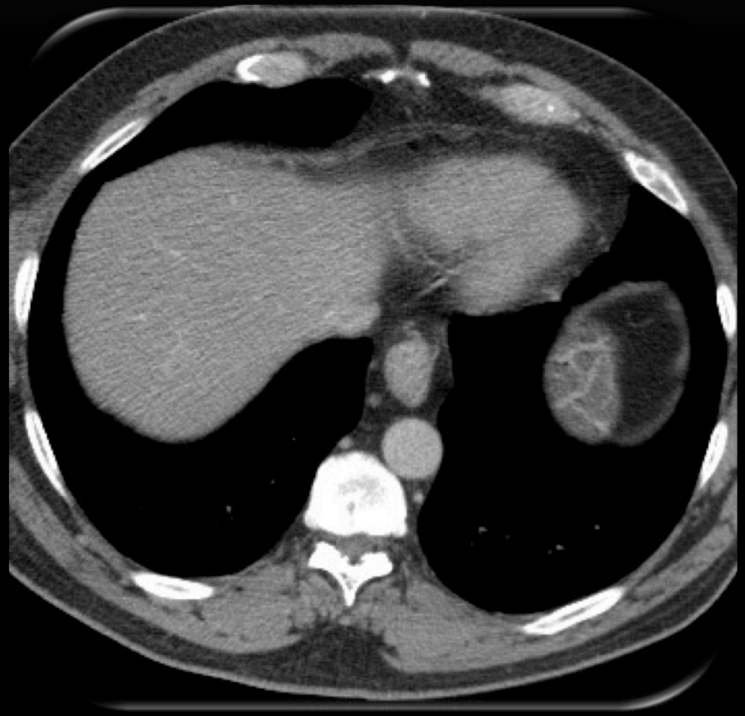

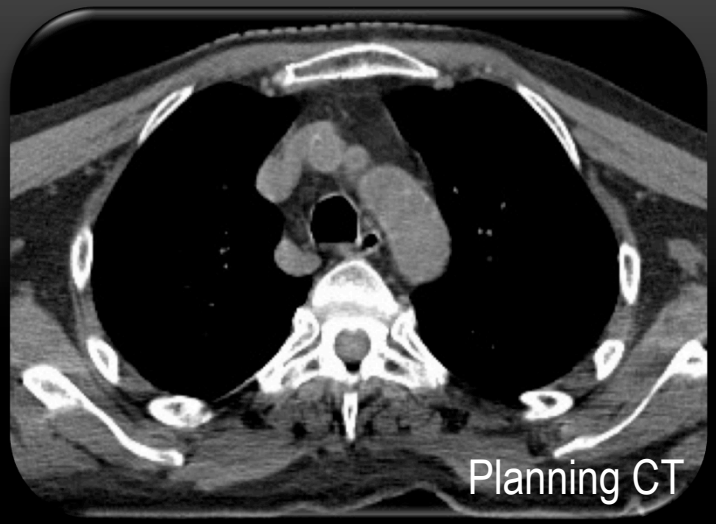

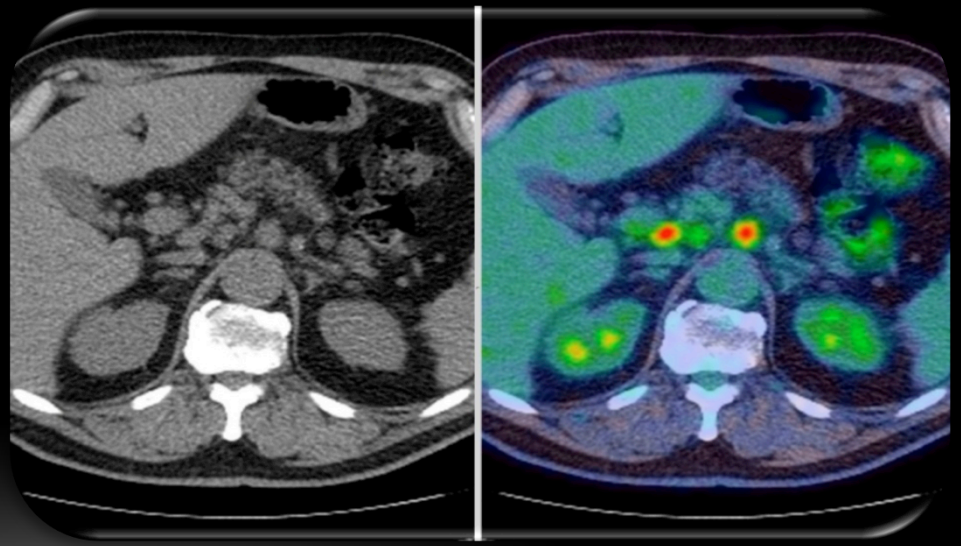

68 year old. Distal adenocarcinoma

REMEMBER ANATOMY MOVES !

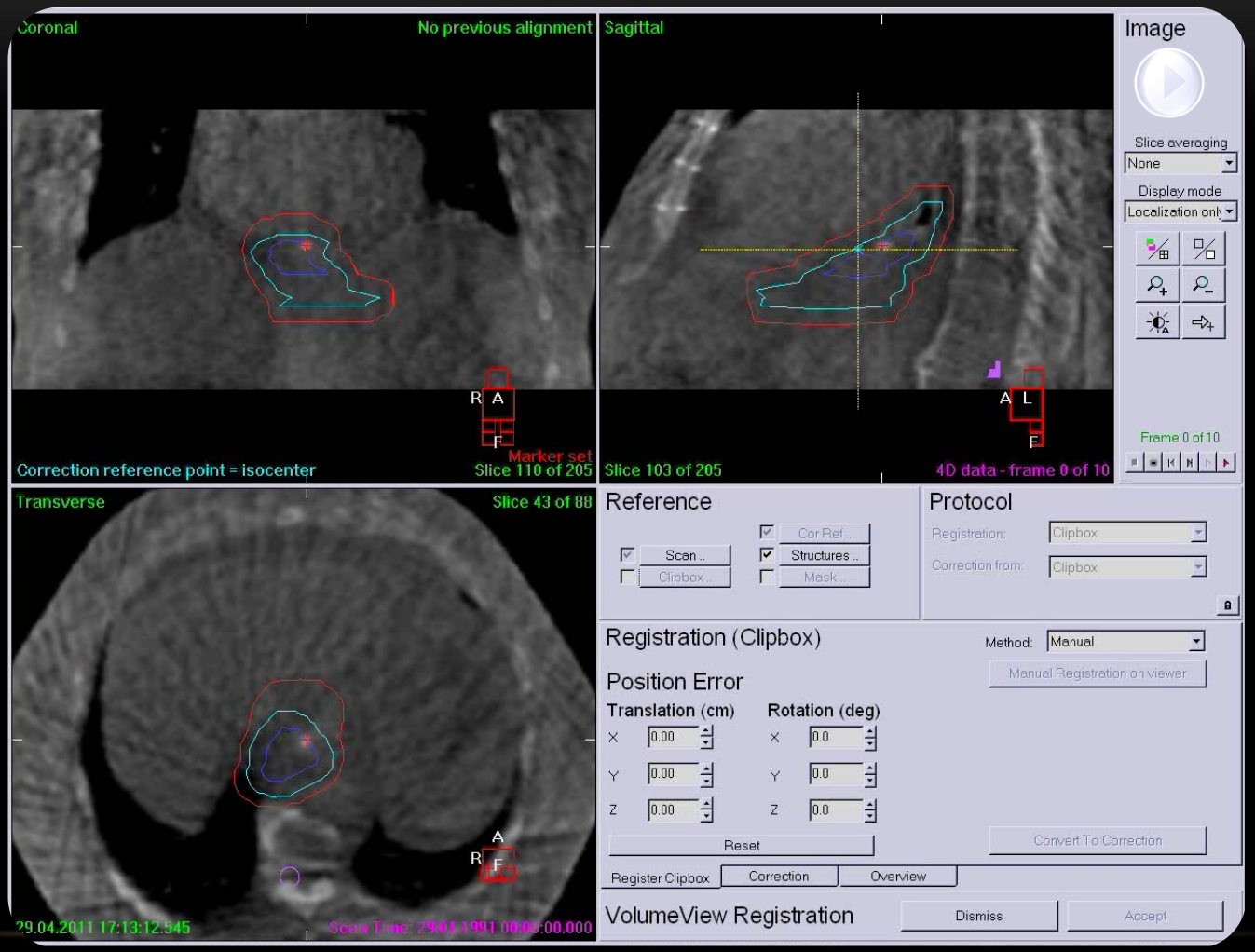

GASTRIC CANCER: RELEVANT ANATOMY

- **Gastric cancer is the fourth most common cancer worldwide**

- Patients with advanced gastric cancer have a 5-year survival rate of 7%–27%, whereas those with early gastric cancer have a 5-year survival rate of 85%–100%

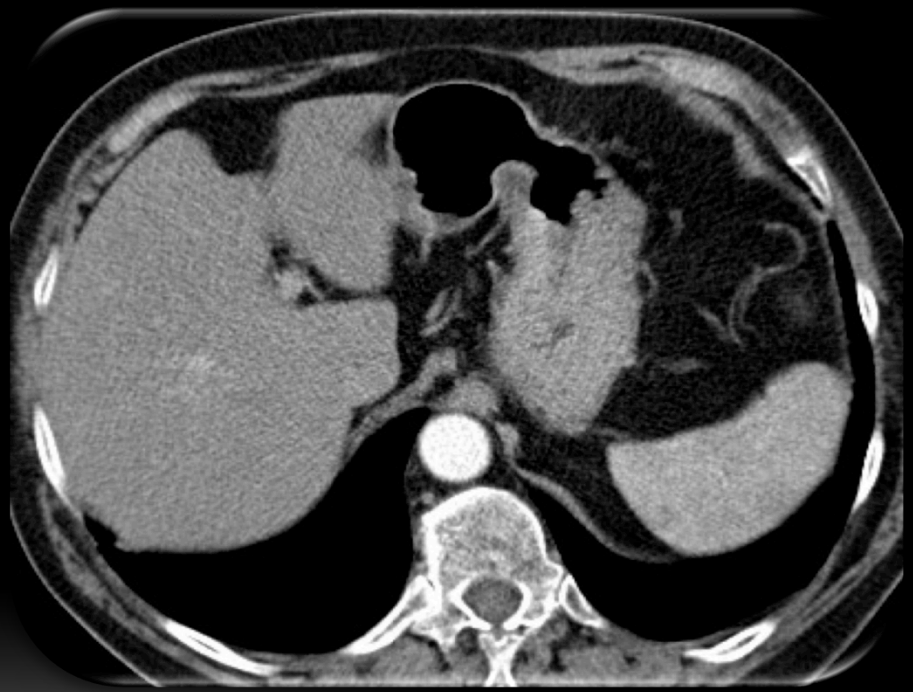

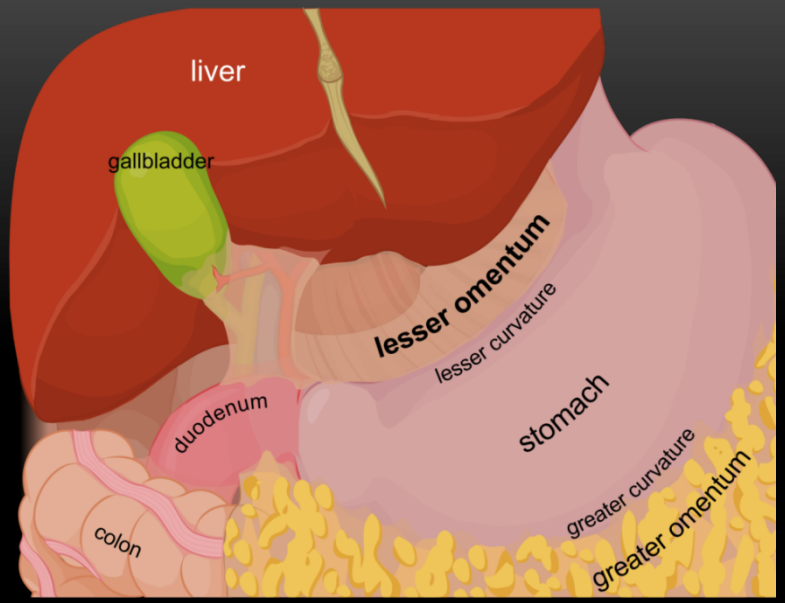

The gastrohepatic ligament is a peritoneal ligament that together with the hepatoduodenal ligament forms the lesser omentum.

The gastrohepatic ligament extends from the fissure of the porta hepatis to the lesser curvature of the stomach.

The gastrohepatic ligament is identified at CT as a fat-containing area between the stomach and liver.

GASTRO-HEPATIC LIGAMENT : IMPORTANT ANATOMY

ANATOMY GASTRIC LYMPH NODES

The regional lymph nodes of the stomach are classified into four compartments according to the Japanese Research Society for Gastric Cancer.

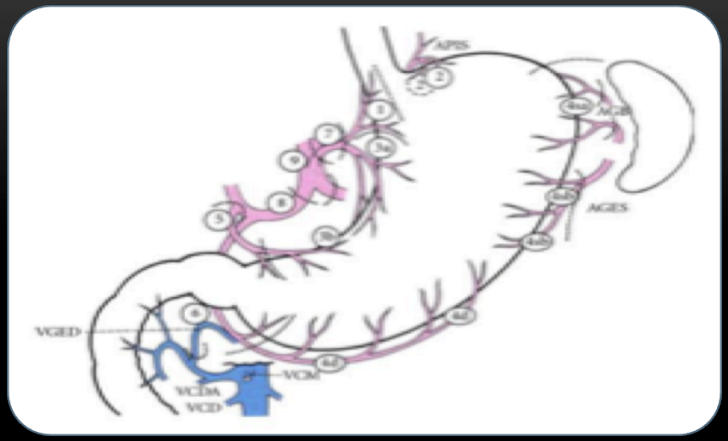

- **Compartment I -** perigastric lymph nodes (stations 1–6).
- **Compartment II** - lymph nodes along the left gastric artery (station 7) and common hepatic artery (station 8), around the celiac axis (station 9), at the splenic hilum (station 10), and along the splenic artery (station 11).
- **Compartment III** - lymph nodes in the hepatoduodenal ligament (station 12), at the posterior aspect of the head of the pancreas (station 13), and at the root of the mesentery (station 14).
- When the cancer is located in the lower third of the stomach, lymph nodes along the splenic artery are classified as compartment III nodes.
- **Compartment IV** - lymph nodes along the middle colic vessels (station 15) and the paraaortic lymph nodes (station 16) .

- Under the new AJCC classification system, N staging is based on the ***number*** of positive nodes (N1 = 1-6 nodes; N2 = 7-15 nodes; N3 > 15)

(This approach differs from the previous classification system, which was based on anatomic location)

- Several studies have confirmed the superiority of number of positive nodes in the estimation of prognosis , but anatomic nodal location remains a valuable criterion because the D classification, a description of the extent of lymphadenectomy, is determined according to the level of lymph node dissection (D1–D4).

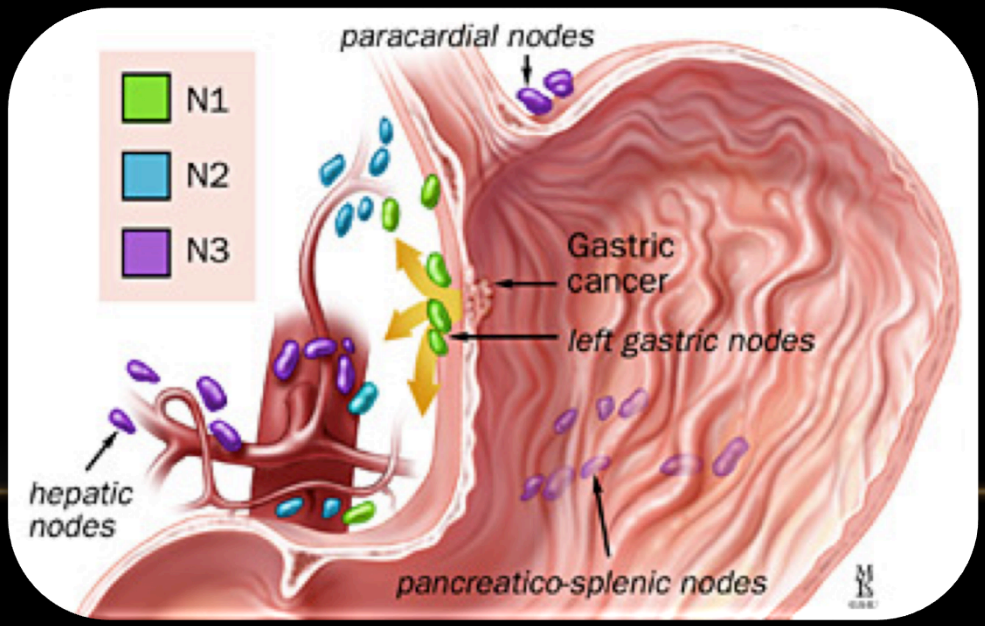

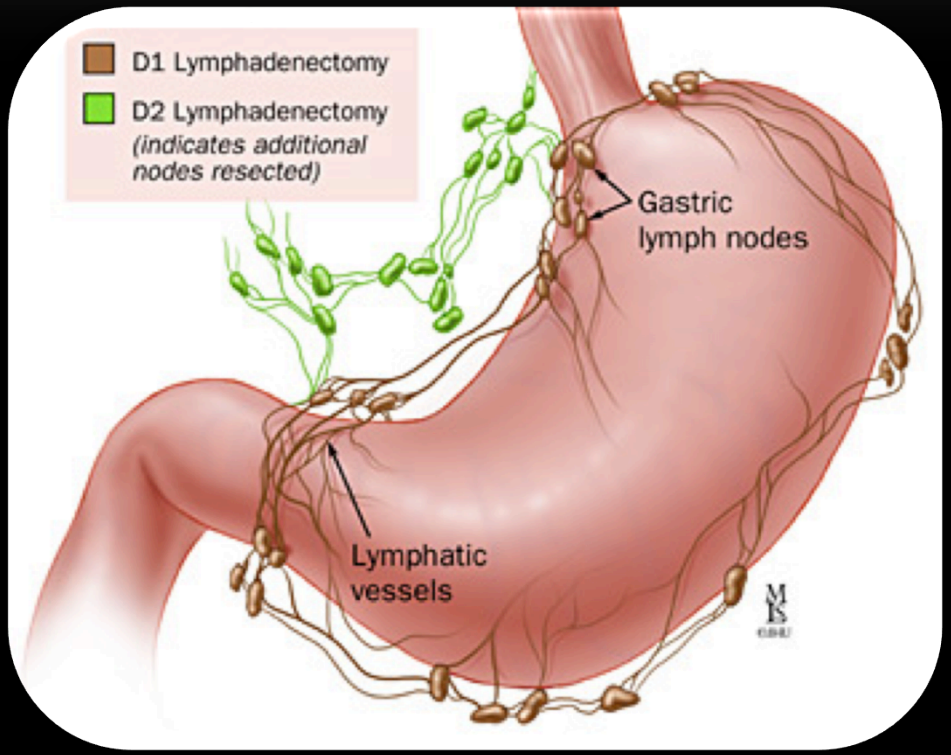
D1 Lymphadenectomy
D2 Lymphadenectomy
(indicates additional nodes resected)
Gastric lymph nodes
Lymphatic vessels

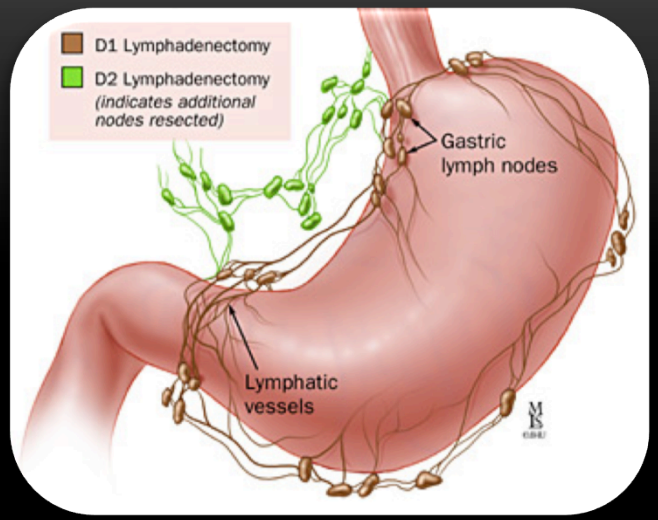
D1 Lymphadenectomy
D2 Lymphadenectomy
(indicates additional nodes resected)
Gastric lymph nodes
Lymphatic vessels

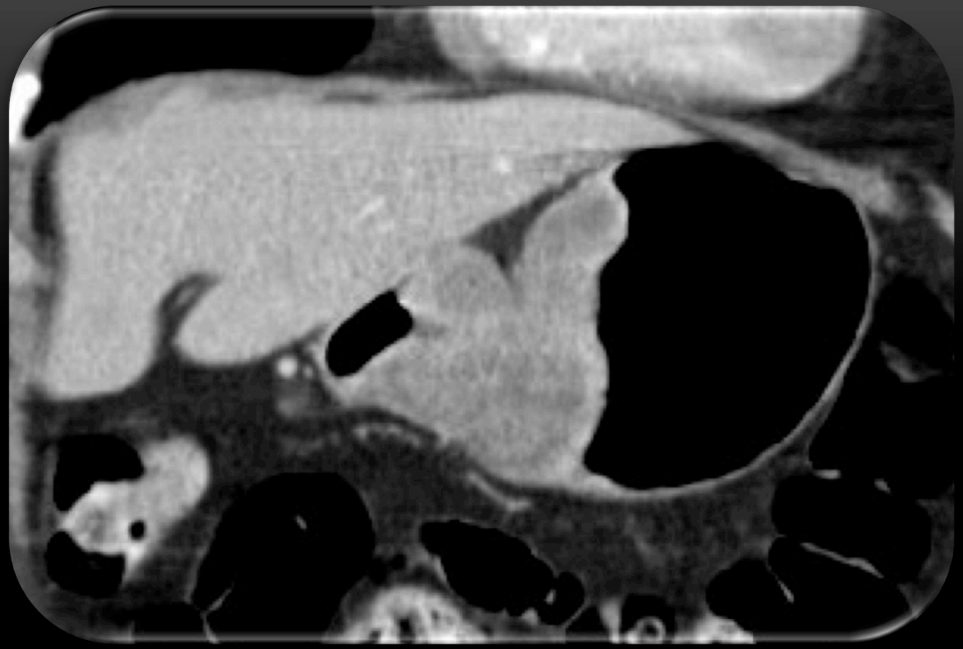

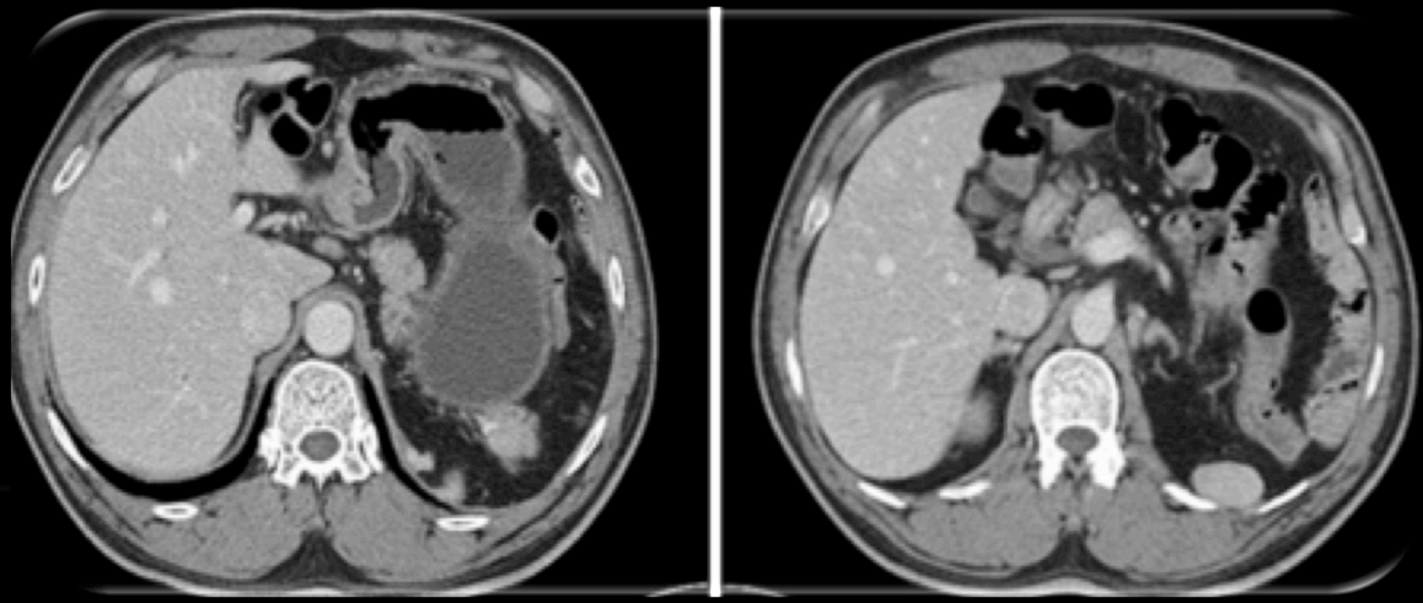

SUMMARY



GTV and CTV delineation for Esophageal cancer- Organ at risk delineation

M.A. Gambacorta

Radiotherapy Dept.
Università Cattolica del Sacro Cuore
Rome

Policlinico Agostino Gemelli
Università Cattolica del Sacro Cuore

Gemelli ART
Advanced Radiation Therapy

Esophageal cancer

- Treatment approaches
- Sites of recurrences
- Target volume delineation

Esophageal cancer

- Treatment approaches
- Sites of recurrences
- Target volume delineation

Treatment approaches

- Treatable disease
- Rarely curable: results of surgery alone

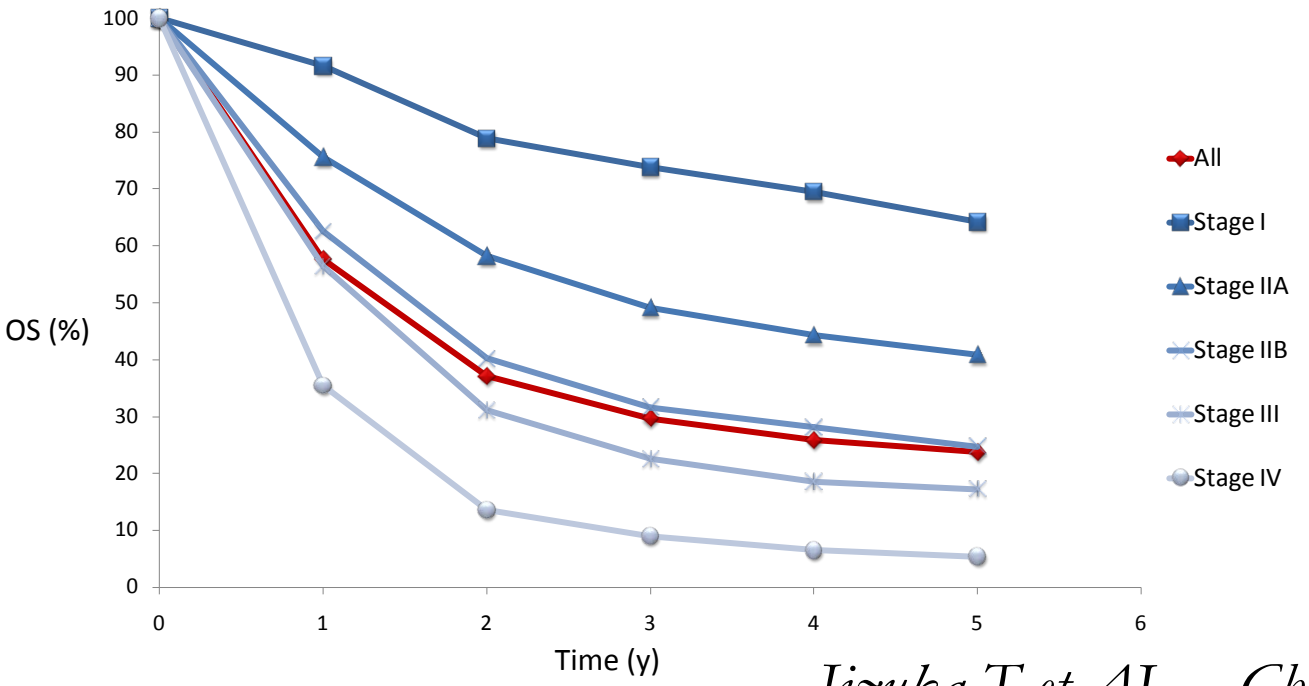

Iizuka T et AL – Chest– 1989

Treatment approaches

Surgery vs **RT alone** vs **Chemoradiation**

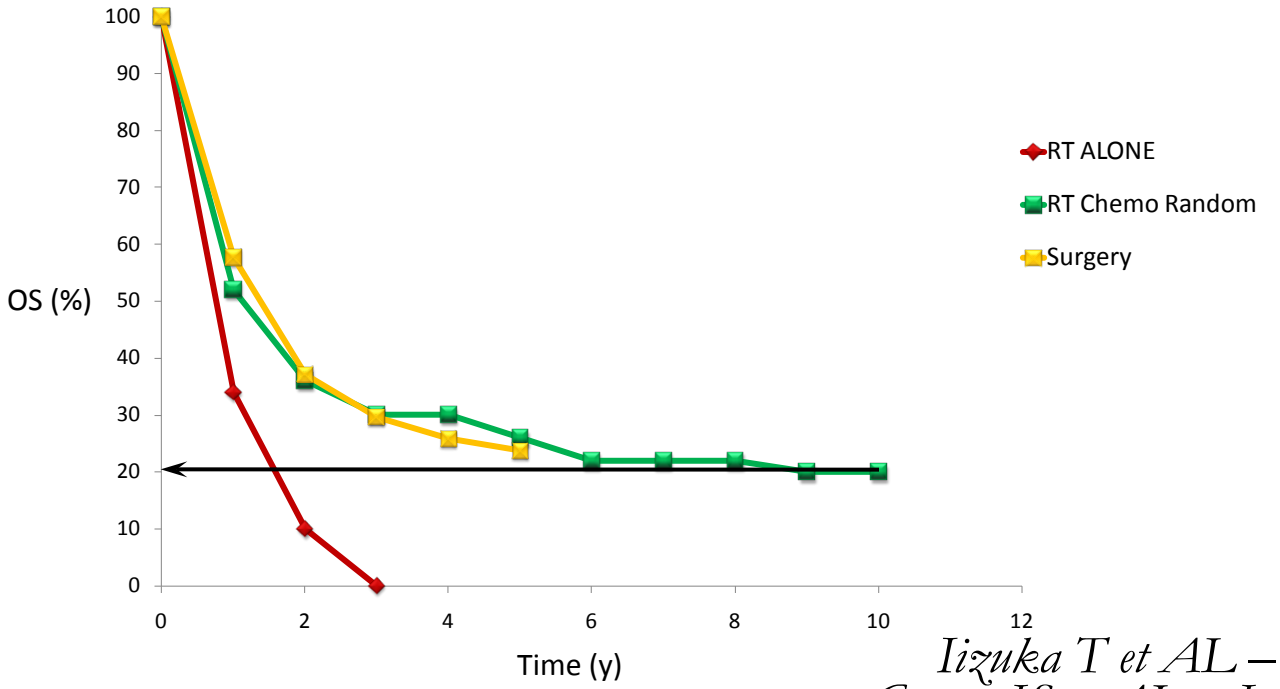

Iizuka T et AL – Chest– 1989
Cooper JS et AL – JAMA – 1999

Treatment approaches

Surgery vs **pre-op Chemoradiation**

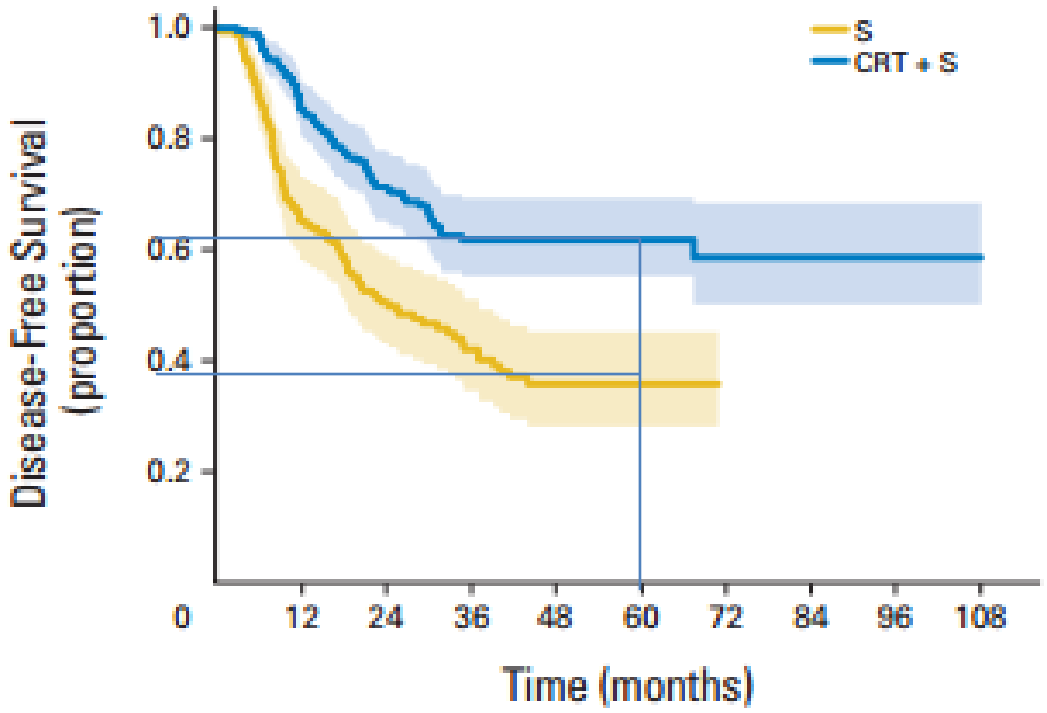

Oppedijk V et al- JCO-2014

Treatment indications

Locally advanced **Esophageal cancer**

- **Resectable cancer, Fit patient** → **CT-RT ⟶ SURG**
- **Unresectable cancer, Fit patient** → **Exclusive CT-RT**
- **Unfit patient** → **Exclusive RT**

NCCN guidelines -2015

Esophageal cancer

- Treatment approaches
- Sites of recurrences
- Target volume delineation

Sites of recurrence

Surgery vs Pre-op chemoradiation

Table 2. Results of Univariable Cox Regression Analysis of RFS Time per Treatment Arm in Patients Undergoing Resection (n = 374)

	S Arm (n = 161)		CRT + S Arm (n = 213)				
Site of Recurrence	No.	%	No.	%	HR	95% CI	*P*
Anastomosis					0.28	0.11 to 0.72	**.008**
Mediastinum					0.29	0.16 to 0.53	**< .001**
Supraclavicular					0.83	0.31 to 2.2	.71
Celiac axis	11	6.9	8	3.8	0.42	0.17 to 1.04	.06
Para-aortic	17	10.6	14	6.6	0.53	0.26 to 1.1	.08
Peritoneal carcinomatosis	22	13.7	9	4.2	0.27	0.12 to 0.58	**.01**
Hematogenous	57	35.4	61	28.6	0.67	0.46 to 0.96	**.03**

NOTE. Bold font indicates significance.
Abbreviations: CRT, chemoradiotherapy; HR, hazard ratio; RFS, recurrence-free survival; S, surgery.

33% of all rec

24% of all rec

Oppedijk V et al- JCO-2014

Sites of recurrence

Radiotherapy vs Chemoradiation

Location of Disease at First Treatment Failure*

First Failure	No. (%) Alive Following Radiation Therapy Only (Randomized)	No. (%) Alive Following Combined Modality Therapy	
		Randomized	Nonrandomized
None	0 (0)	13 (21)	4 (6)
Persistent Local-regional	33 (53)	23 (38)	33 (48)
Distant only	9 (15)	5 (8)	11 (16)
Local, regional, and distant	9 (15)	5 (8)	7 (10)
Death			
Disease sites not specified	3 (5)	3 (5)	3 (4)
Other	5 (8)	10 (16)	10 (15)
Unknown	3 (5)	2 (3)	1 (1)
Total	**62 (100)**	**61 (100)**	**69 (100)**

*Data updated October 1, 1998. Percentages are estimated.

Cooper JS et AL – JAMA – 1999

Esophageal cancer

- Treatment approaches
- Sites of recurrences
- Target volume delineation:
  - **GTV T-N**
  - **CTV T-N**
  - **CTV elective nodes**

Esophageal cancer

- Treatment approaches
- Sites of recurrences
- Target volume delineation:
  - **GTV T-N**
  - **CTV T-N**
  - **CTV elective nodes**

Target volume delineation

- Basic anatomy of esophagus

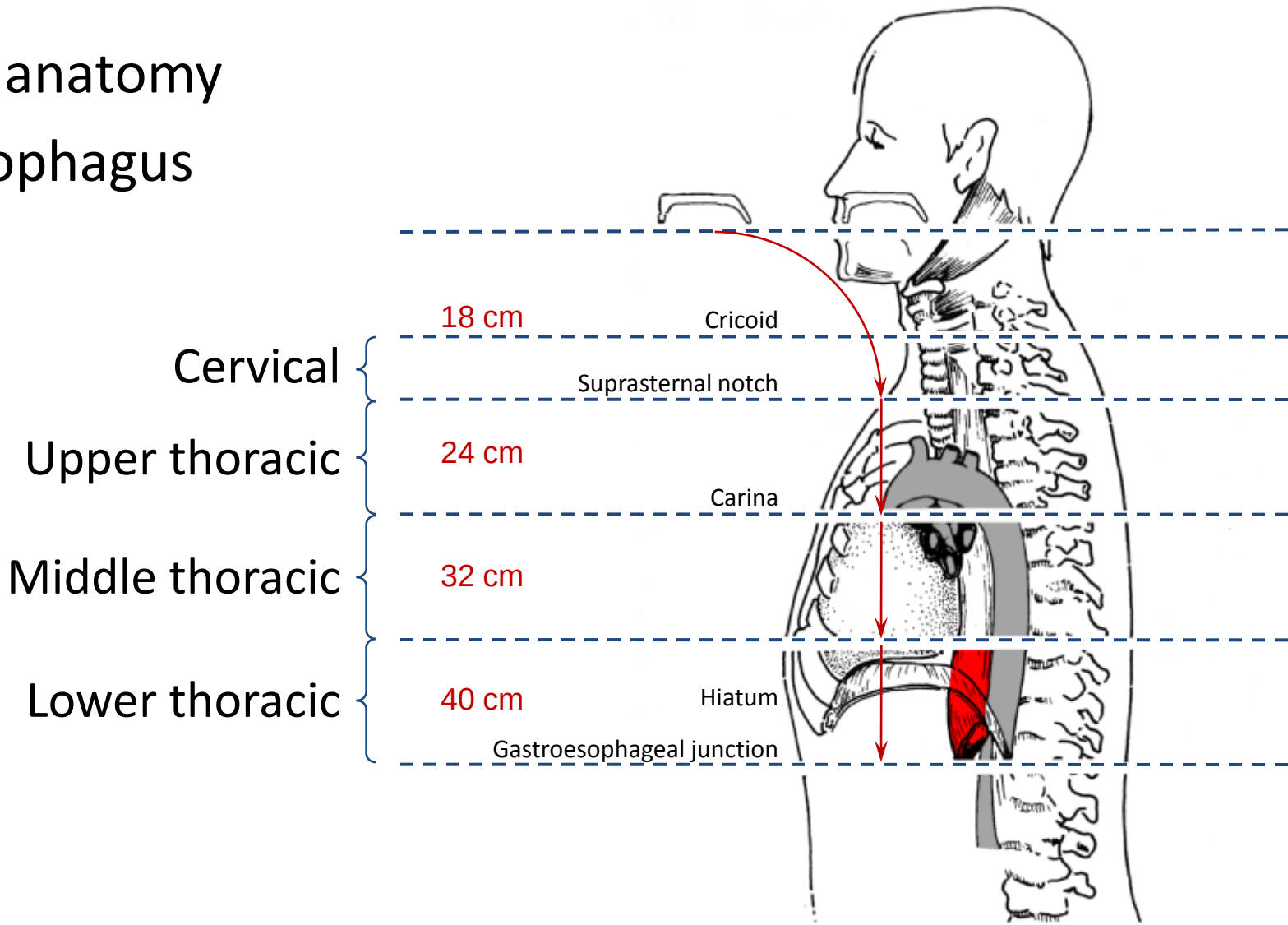

GTV definition

- Esophagogram
- EUS
- CT
- PET

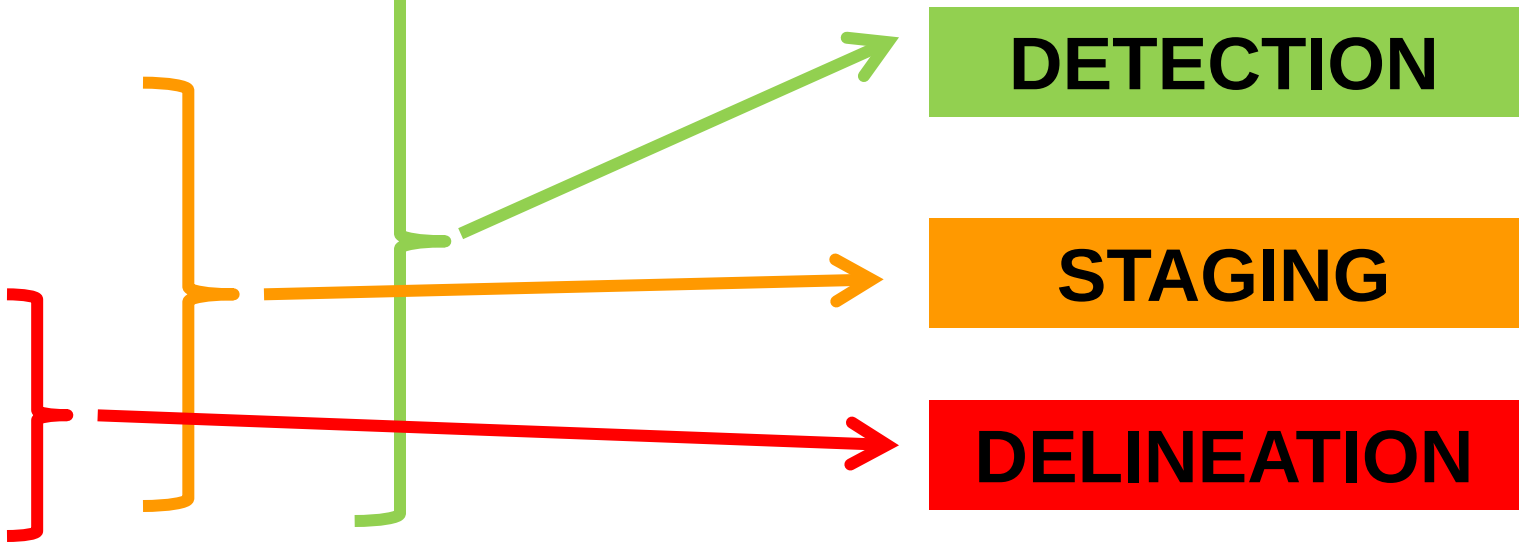

GTV definition

- Esophagography: CC extension, 2D treatment
- EUS & EUS-FNA: T wall infiltration; adjacent N+
- Endoscopy (esophagoscopy, bronchoscopy): T extension, bronchus invasion
- **CT scan**
- **PET & PET CT**

Plukker JThM – Best Pract Res Clin Gastroenterol – 2006
Fiore D – Radiol Med – 2006

GTV-T definition:CT Scan

TUMOR

- Definition of extension based on wall thickness:
  - common with benign disease (esophagitis, hypertrophy due to obstruction, fluid/food, others)
- Definition of mediastinal invasion based on fat invasion:
  - frequently **impossible to distinguish normal fat planes** for mid-esophageal area; underweights patients; GEJ loss of esophageal fat
- Definition of tumor volume in the lower part hampered by motion artifacts (heart), paucity of fat

Plukker JThM – Best Pract Res Clin Gastroenterol – 2006

CT Scan for GTV-T definition: infiltration of adjacent organs

- Angle of contact criterion: no infiltration

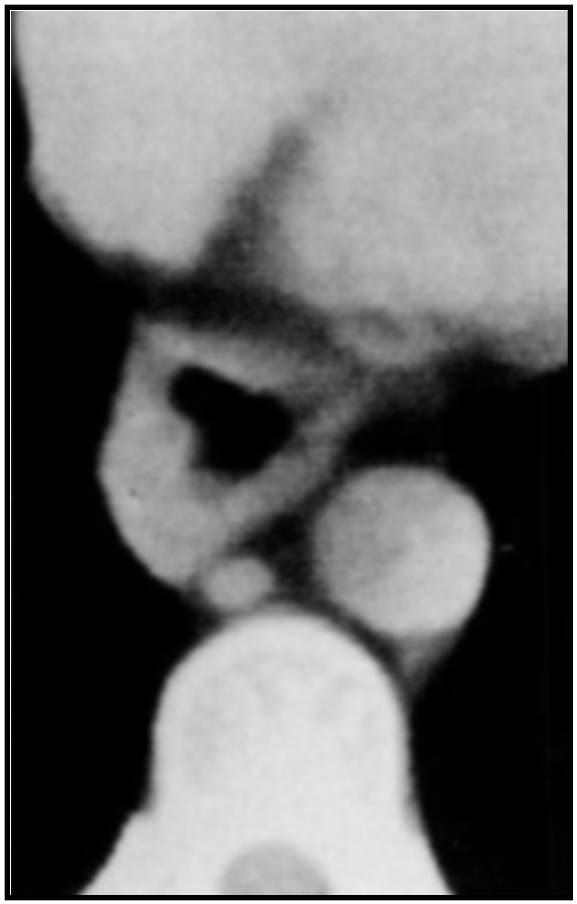

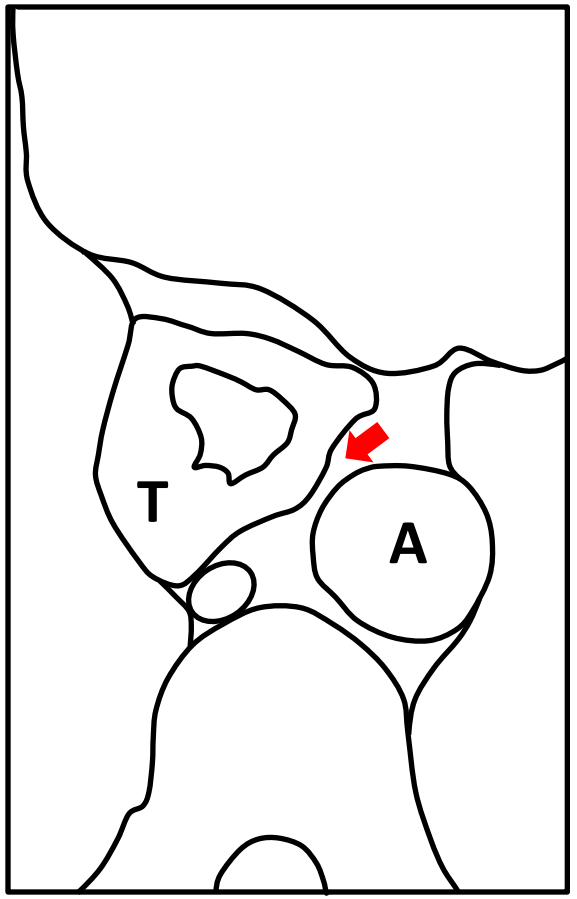

$\alpha \leq 45^{\circ}$ or
no contact

Picus D – Radiology – 1983

CT Scan for GTV-T definition: infiltration of adjacent organs

- Angle of contact criterion: unsure infiltration

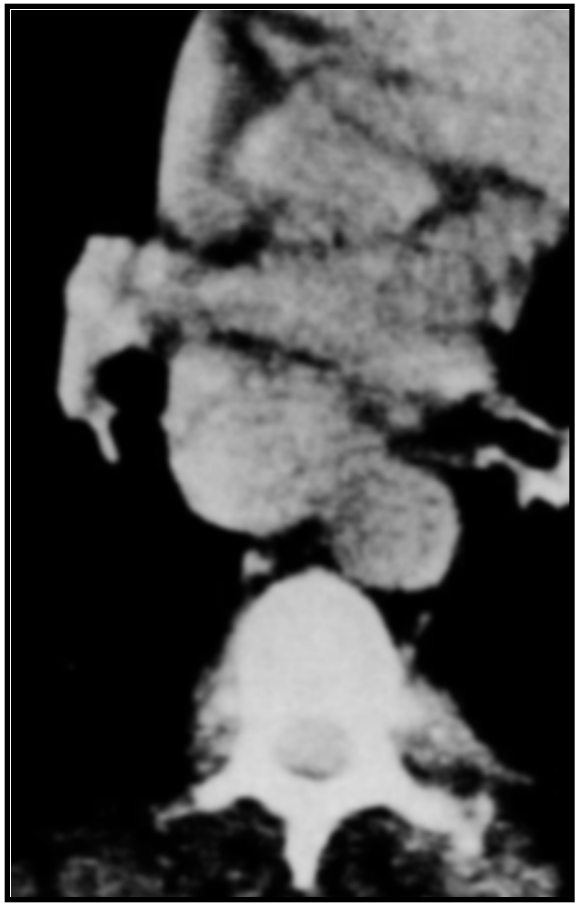

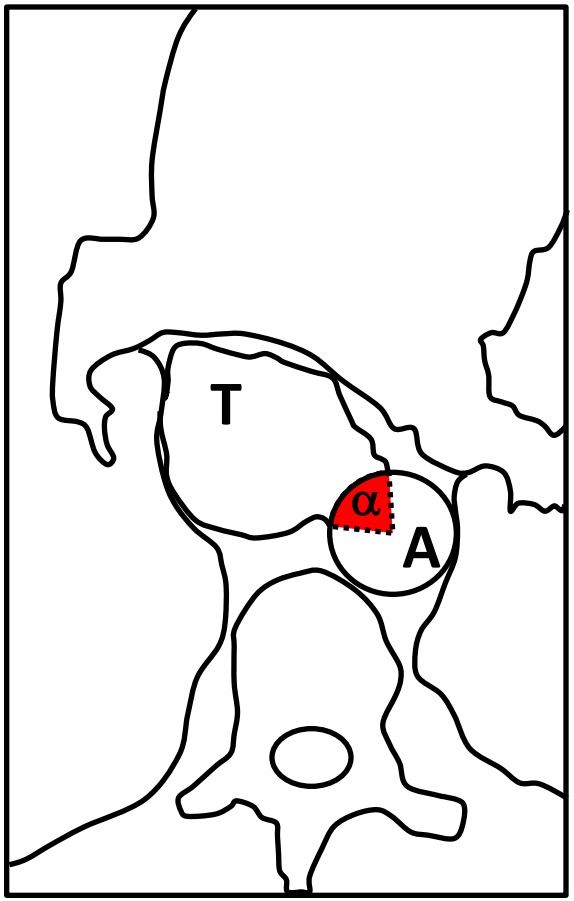

Picus D – Radiology – 1983

CT Scan for GTV-T definition: infiltration of adjacent organs

- Angle of contact criterion: infiltration of aorta

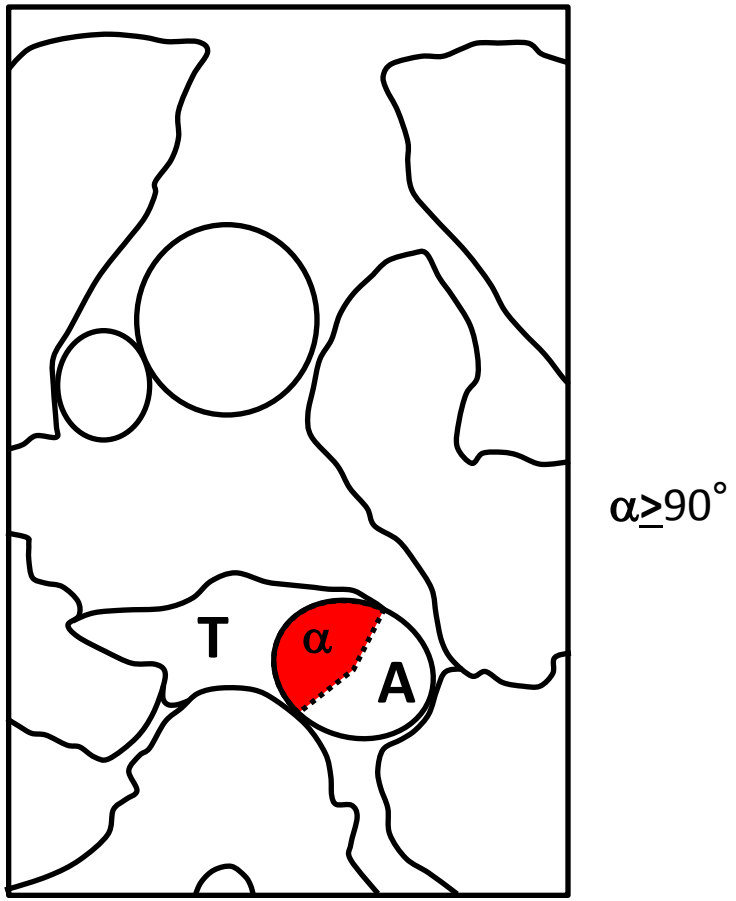

Picus D – Radiology – 1983

GTV-N definition:CT Scan

NODES: **Size, border, density, central fatty hilum**

- **LIMITATIONS:**
  - **Lymphnodal** metastases **adjacent** to the esophageal wall are not visible
  - **Dimensional criterion** can be not sufficient for all cases:
    - Metastases have been found in **lymphnodes lower than 7mm** in larger diameter
    - **Lymphnodes > 1 cm** may be enlarged by **inflammation**
  - Reported overall accuracy < 60% for mediastinal lymph nodes, from 39% to 74% in coeliac and abdominal lymph nodes

Patel AN – Surg Clin North Am – 2005

Plukker JThM – Best Pract Res Clin Gastroenterol – 2006

Picus D – Radiology – 1983

CT Scan for GTV-N definition: lymphnodal metastases

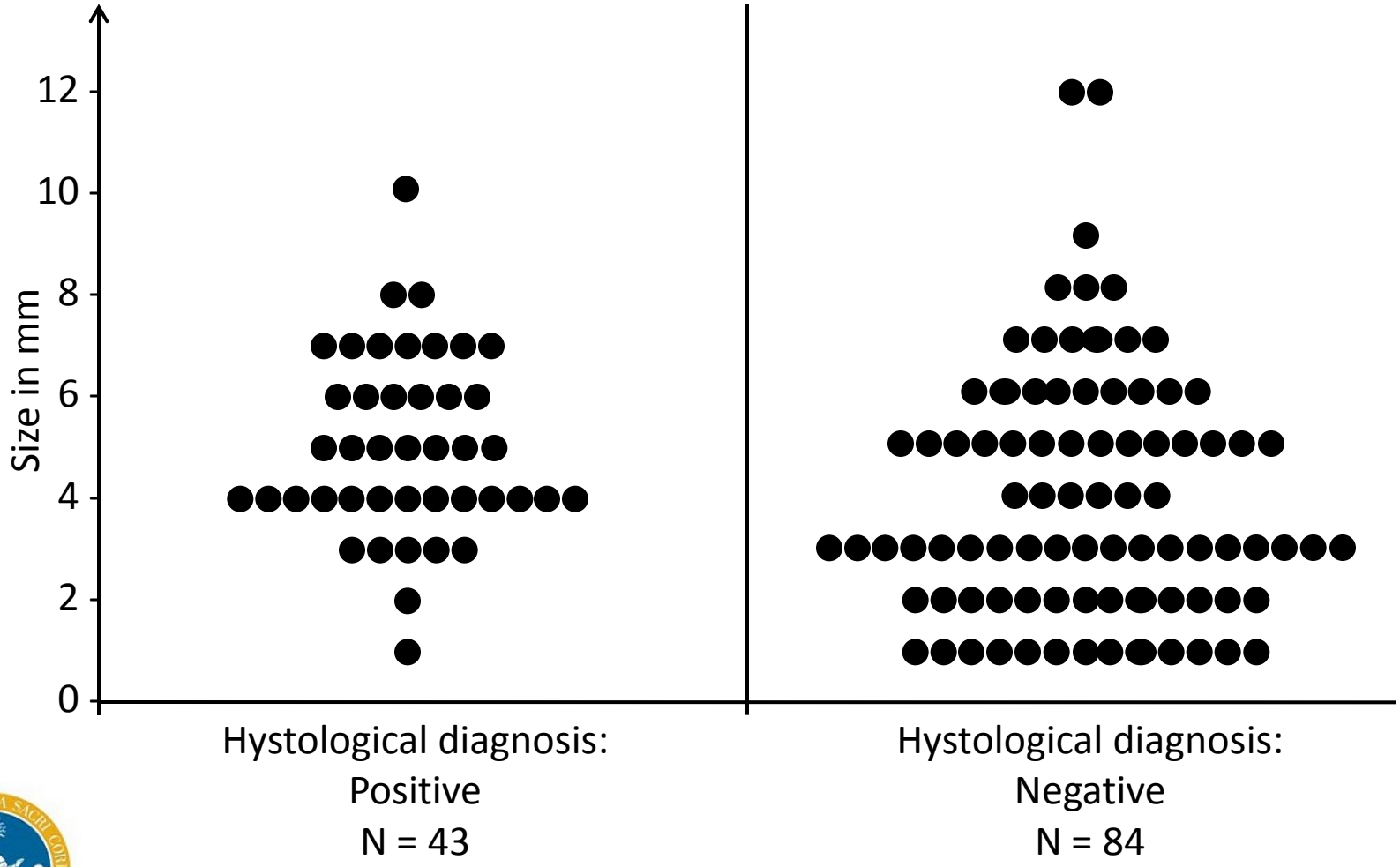

Picus D – Radiology – 1983

How to improve GTV definition

- **Endoscopic ultrasound (EUS-FNA)**
  - **Tumor** wall infiltration
  - **Nodes** near to the tumor
  - Nodes Biopsy

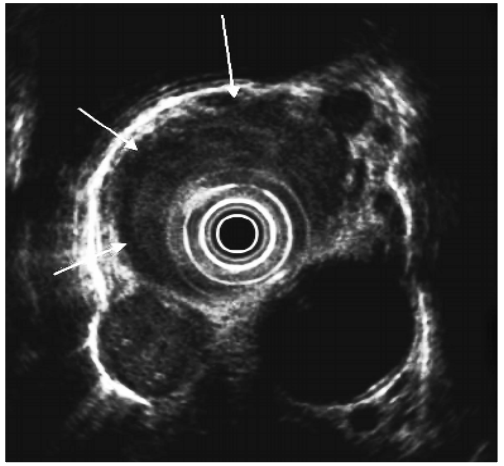

- **PET & CT-PET**
  - Distant occult metastases
  - **Uncertain lymphnodesfar from T**
  - **Detection of primary tumor**

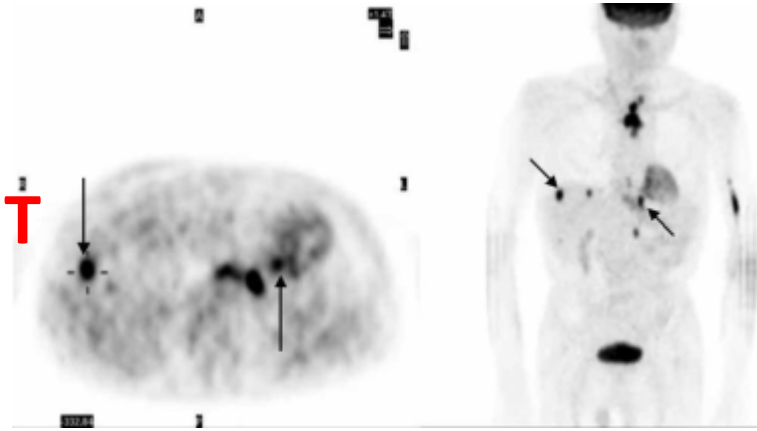

GTV delineation in CT & PET

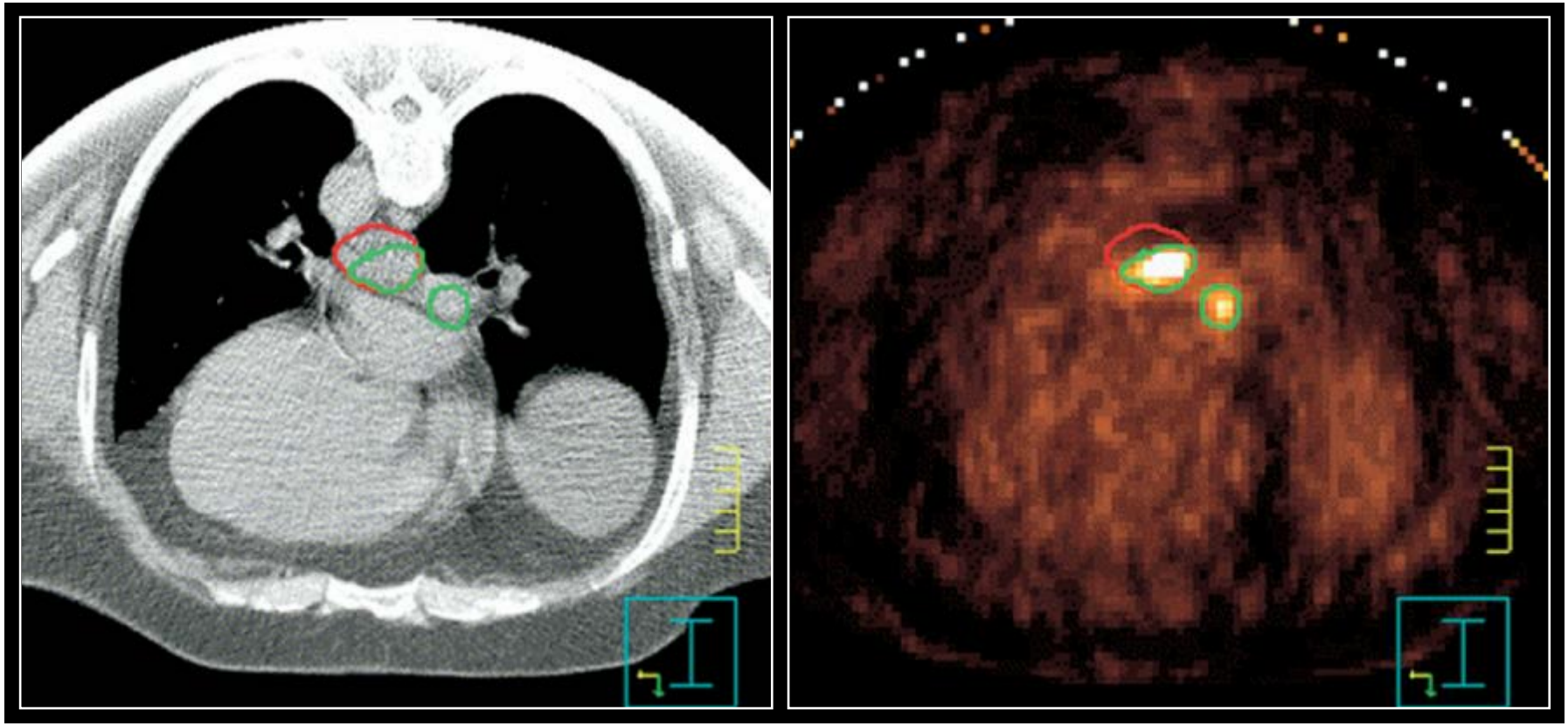

Gondi V – IJROBP– 2007

GTV delineation in CT & PET

Comparison of radiotherapy planning volumes using hybrid fluorodeoxyglucose positron-emission tomography/computed tomography (FDG-PET/CT) imaging versus CT imaging alone in patients with esophageal cancer

Patient	$GTV_{PET/CT}$ (cm^3)	GTV_{CT} (cm^3)	% Relative difference*	Intersection	Union	Conformality index
1	60.4	53.4	13.11%	27.4	86.4	0.317
2	17.9	24.5	−26.94%	16.3	26.1	0.627
3	18.5	18.2	1.65%	15.3	21.4	0.713
4	94.7	128.9	−26.53%	76.3	147.4	0.517
5	63.5	123.2	−48.46%	59.9	126.8	0.472
6	64.7	48.5	33.40%	26.3	85.4	0.308
7	39.3	158.1	−75.14%	35.8	162.6	0.220
8	58.6	21.4	173.83%	19.5	60.5	0.322
9	55.6	61.5	−9.59%	52.0	65.2	0.797
10	140.3	187.7	−25.25%	68.6	187.7	0.366
11	26.1	69.2	−62.28%	23.1	72.2	0.320
12	62.5	69.6	−10.20%	52.5	79.6	0.660
13	34.3	43.6	−21.33%	29.0	48.9	0.592
14	192.7	231.4	−16.72%	177.5	246.6	0.720
15	116.2	89.6	29.69%	23.0	176.7	0.130
16	76.0	64.4	18.01%	35.4	105.1	0.337
Mean						0.464

Smaller GTV: 62.5%

Gondi V – IJROBP– 2007

GTV delineation in CT & PET

Comparison of radiotherapy planning volumes using hybrid fluorodeoxyglucose positron-emission tomography/computed tomography (FDG-PET/CT) imaging versus CT imaging alone in patients with esophageal cancer

Patient	$GTV_{PET/CT}$ (cm^3)	GTV_{CT} (cm^3)	% Relative difference*	Intersection	Union	Conformality index
1	60.4	53.4	13.11%	27.4	86.4	0.317
2	17.9	24.5	−26.94%	16.3	26.1	0.627
3	18.5	18.2	1.65%	15.3	21.4	0.713
4	94.7	128.9	−26.53%	76.3	147.4	0.517
5	63.5	123.2	−48.46%	59.9	126.8	0.472
6	64.7	48.5	33.40%	26.3	85.4	0.308
7	39.3	158.1	−75.14%	35.8	162.6	0.220
8	58.6	21.4	173.83%	19.5	60.5	0.322
9	55.6	61.5	−9.59%	52.0	65.2	0.797
10	140.3	187.7	−25.25%	68.6	187.7	0.366
11	26.1	69.2	−62.28%	23.1	72.2	0.320
12	62.5	69.6	−10.20%	52.5	79.6	0.660
13	34.3	43.6	−21.33%	29.0	48.9	0.592
14	192.7	231.4	−16.72%	177.5	246.6	0.720
15	116.2	89.6	29.69%	23.0	176.7	0.130
16	76.0	64.4	18.01%	35.4	105.1	0.337
Mean						0.464

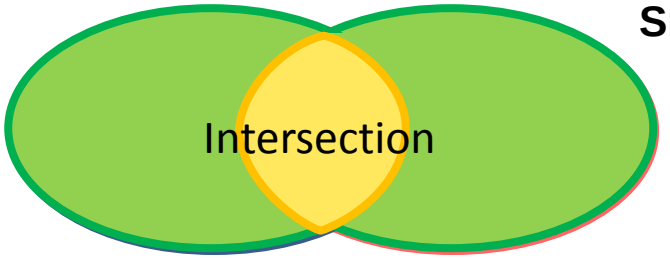

Smaller GTV: 62.5%

Union

$$CI = \frac{\text{Intersection}}{\text{Union}}$$

Overlap: 44%

Gondi V – IJROBP– 2007

GTV delineation: PET & pathology

PET-CT delineation

Pathology

Overlapping measurements

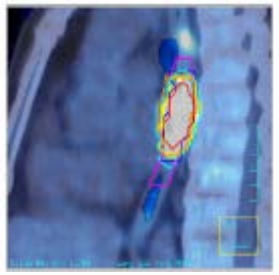

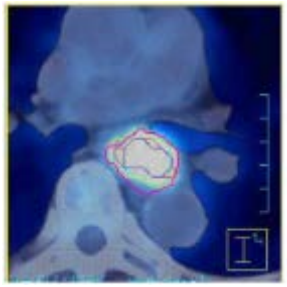

lenght

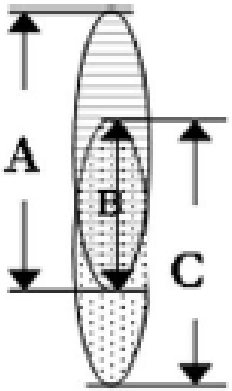

$CI' = B^2 / (A * C)$

$A = L_{ct}$

$B = Intersection$

$C = L_{path}$

Delineation modalities:

1. CT: **manual**
2. SUV bcg + 20% (SUV max – SUV bcg)
3. SUV bcg + 40% (SUV max – SUV bcg)
4. SUV 2.5;
5. 40% SUV max

automatic

GTV

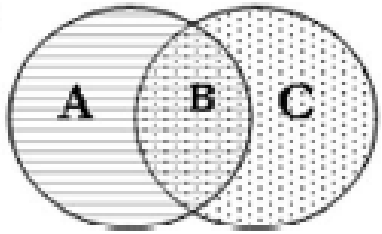

$CI = B^2 / (A * C)$

$A = GTV_{ct}$

$B = Intersection$

$C = GTV_{path}$

Yu V. et al – Radiother Oncol. – 2009

GTV delineation in PET & pathology

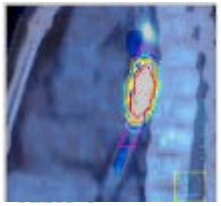

Lenght

Mean lengths of the esophageal tumor measured by different methods and the corresponding CI's.

	L_{CT}	$L_{20\%}$	$L_{40\%}$	$L_{2.5}$	$L_{40\%M}$	L_{path}
Mean ± SD (cm)	6.30 ± 2.69	5.55 ± 2.48	6.80 ± 2.92	6.65 ± 2.66	4.88 ± 1.99	5.90 ± 2.38
P value (L_x vs. L_{path})	0.4140	0.1051	0.0454	0.0757	0.0001	–
$CI'_{x\&path}$	0.68 ± 0.16	0.84 ± 0.17	0.76 ± 0.14	0.78 ± 0.15	0.80 ± 0.11	–
P value ($CI'_{CT\&path}$ vs. $CI'_{x\&path}$)	–	0.0002	NS	NS	0.0291	–
P value ($CI'_{20\%\&path}$ vs. $CI'_{x\&path}$)	–	–	NS	NS	NS	–
P value ($CI'_{40\%\&path}$ vs. $CI'_{x\&path}$)	–	–	–	NS	NS	–
P value ($CI'_{2.5\&path}$ vs. $CI'_{x\&path}$)	–	–	–	–	NS	–

Lenght 20%

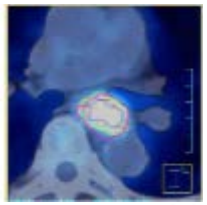

GTV

Mean GTVs of the esophageal tumor measured by different methods and the corresponding CIs.

	GTV_{CT}	$GTV_{20\%}$	$GTV_{40\%}$	$GTV_{2.5}$	$GTV_{40\%M}$	GTV_{path}
Mean ± SD (cm^3)	29.16 ± 18.56	18.75 ± 12.37	12.52 ± 8.08	22.69 ± 14.84	9.18 ± 5.96	28.16 ± 17.02
P value (GTV_x vs. GTV_{path})	0.4339	0.0000	0.0000	0.0008	0.0000	–
$CI_{x\&path}$	0.77 ± 0.17	0.52 ± 0.16	0.27 ± 0.09	0.52 ± 0.20	0.28 ± 0.08	–
P value ($CI_{CT\&path}$ vs. $CI_{x\&path}$)	–	0.0000	0.0000	0.0000	0.0000	–
P value ($CI_{20\%\&path}$ vs. $CI_{x\&path}$)	–	–	0.0000	NS	0.0000	–
P value ($CI_{40\%\&path}$ vs. $CI_{x\&path}$)	–	–	–	0.0000	NS	–
P value ($CI_{2.5\&path}$ vs. $CI_{x\&path}$)	–	–	–	–	0.0000	–

Yu V. et al – Radiother Oncol. – 2009

GTV delineation: PET & variability

- 10 GEJ ca undergoing RT
- 6 Radiation Oncologists
- CT alone vs PET-CT (manual)
- **Median observer overlap analysis** (bars = Observer Agreement Index)
- Plans using PET-CT **reduced both interobserver and intraobserver variability**

Inter-observer variability

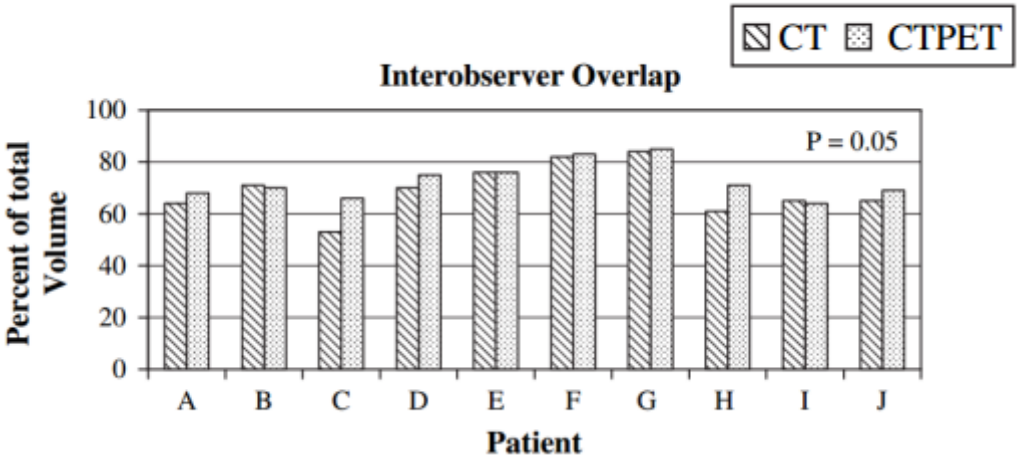

PET-CT vs CT: 72.7% vs 69.1%

Intra-observer variability

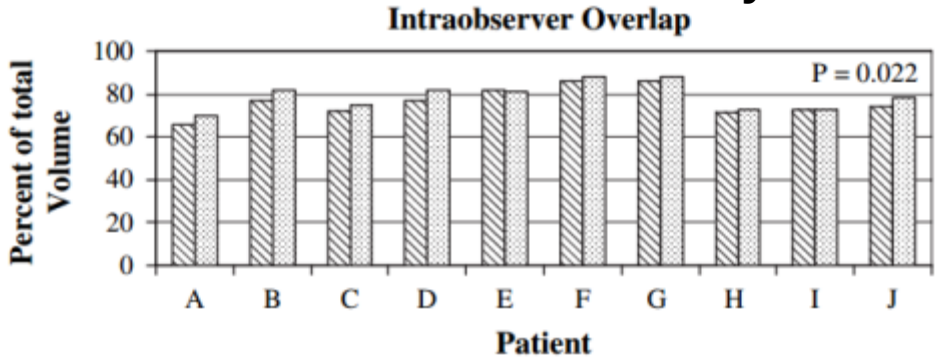

PET-CT vs CT: 78.7% vs 76.1%

Vesprini D. et al – Radiother Oncol. – 2010

GTV delineation: PET & variability

- 10 GEJ ca undergoing RT
- 6 Radiation Oncologists

- CT alone vs PET-CT (manual)

- **Median observer overlap analysis** (bars = Observer Agreement Index)

- Plans using PET-CT **reduced both interobserver and intraobserver variability**

Inter-observer variability

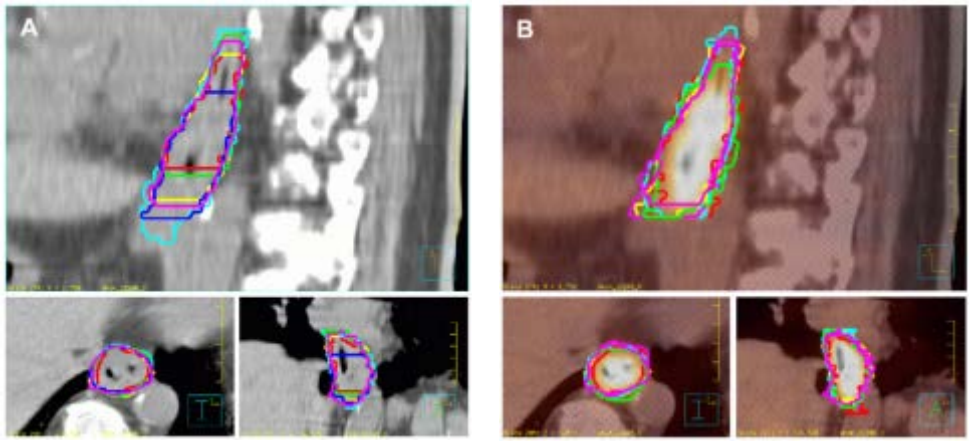

Intra-observer variability

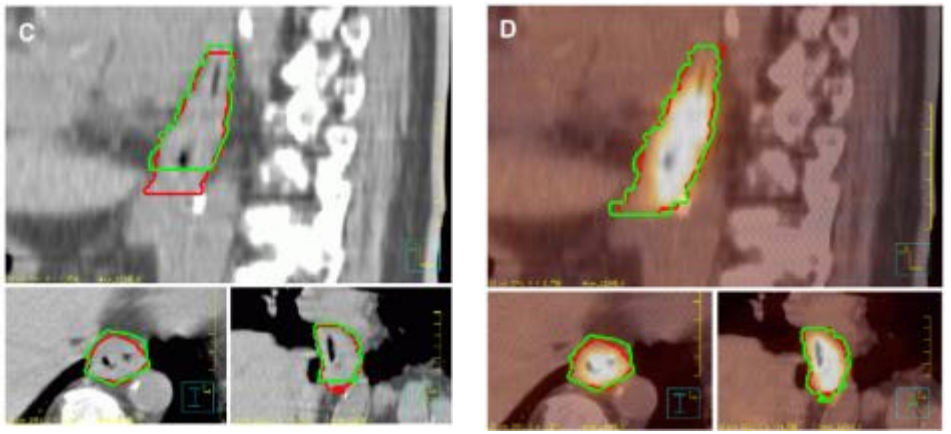

Vesprini D. et al – Radiother Oncol. – 2010

PET for GTV definition: summary

- **GTV-T:**
  - accurate in definition of **length** with threshold (GTV 20%), not good for the entire GTV
  - Decrease **variability** (inter-intra)
- **GTV-N:**
  - high specificity **90%**
  - low sensitivity **57%:**
    - Poor spatial resolution (nodes adjacent to the primary)
    - Partial volume effect (size 5-10mm)

GTV delineation: summary



- **GTV should be delineated on CT**
- **GTV should be increased to incorporate FDG-PET avid disease**
- **GTV should not be decreased because of lack of PET avidity**
- **Take information from other imaging modalities (i.e.EUS)**

Esophageal cancer

- Treatment approaches
- Sites of recurrences
- Target volume delineation:
  - **GTV T-N**
  - **CTV T-N**
  - **CTV elective nodes**

CTV definition in clinical trials

Study	Phase 1 Description
RTOG 8501	Field extended from SCF to GEJ, omit SCF with lower third tumors
INT 0122	Field borders included tumor plus 5cm inferiorly and superiorly with radial margins of 2cm
RTOG 0113/0426	CTV defined as GTV plus 4 cm superiorly and inferiorly with lateral margin of 1cm; plus regional nodes. CTV included SCF nodes with tumors above carina and celiac nodes for distal tumors. PTV expansion was 1-2 cm
Stahl et al 2005 Ph 111	(CTV I = gross tumor with craniocaudal margins of 2 cm and transverse margins of 1 cm.) CTV II contained additional margins (subclinical disease) adjacent the CTV I, with extension of 3 cm in the oral/aboral directions and 1 cm transverse. SCF & ICF and the lower cervical nodes were included in CTV II for upper thoracic esophagus. The PTV contained the CTV + 0.5 cm.
Bedenne et al 2007 Ph 111	Radiotherapy included the macroscopic tumor and lymph nodes, with a 3-cm proximal and distal margin and a 2-cm radial margin.
Others	Field borders = tumor plus 5 cm superior and inferiorly with a lateral distance of 2 cm

CTV-T

Length along esophagus

Analysis of surgical specimens of esophageal **SCC** (n=34) and gastroesophageal junction **adenocarcinoma** (n=32) to define the extension of **microscopic spread**

Gao XS – IJROBP– 2007

CTV-T Length along esophagus

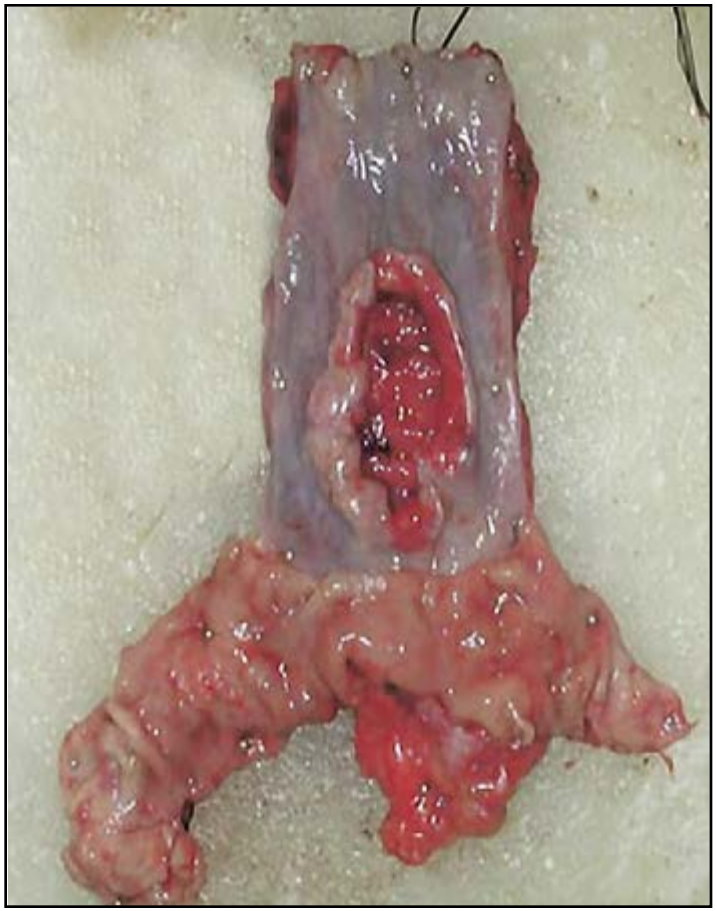

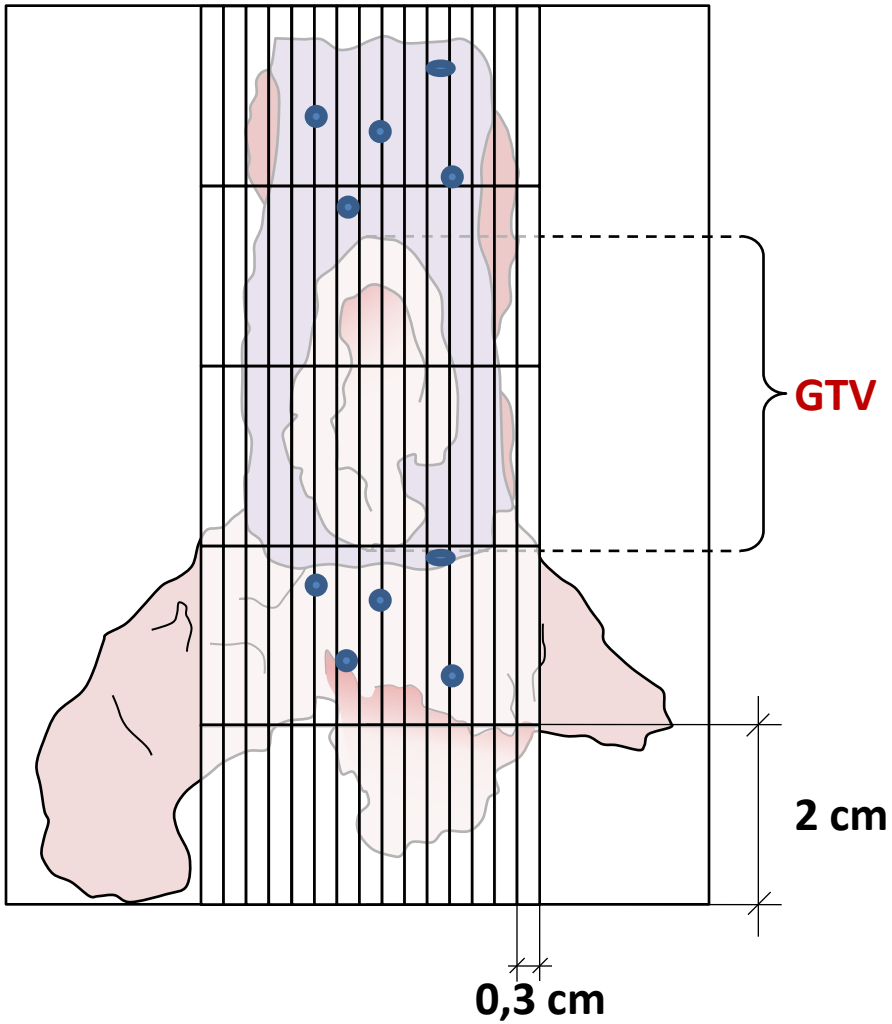

Gao XS – IJROBP– 2007

CTV Length along esophagus

- Microscopic findings to define subclinical spread (SCC, mid thoracic)

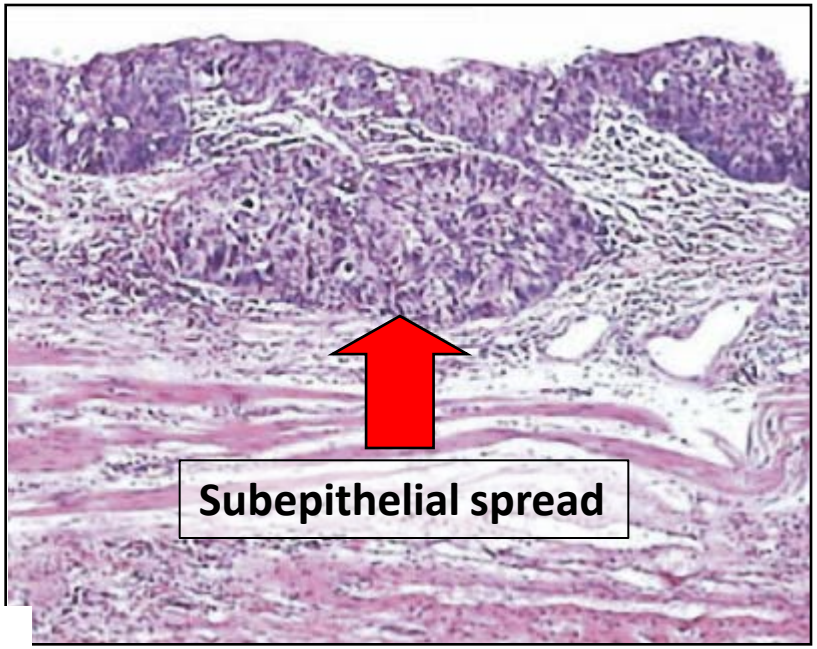

Gao XS – IJROBP– 2007

CTV Length along esophagus

- Microscopic findings to define subclinical spread (adenoca, GEJ)

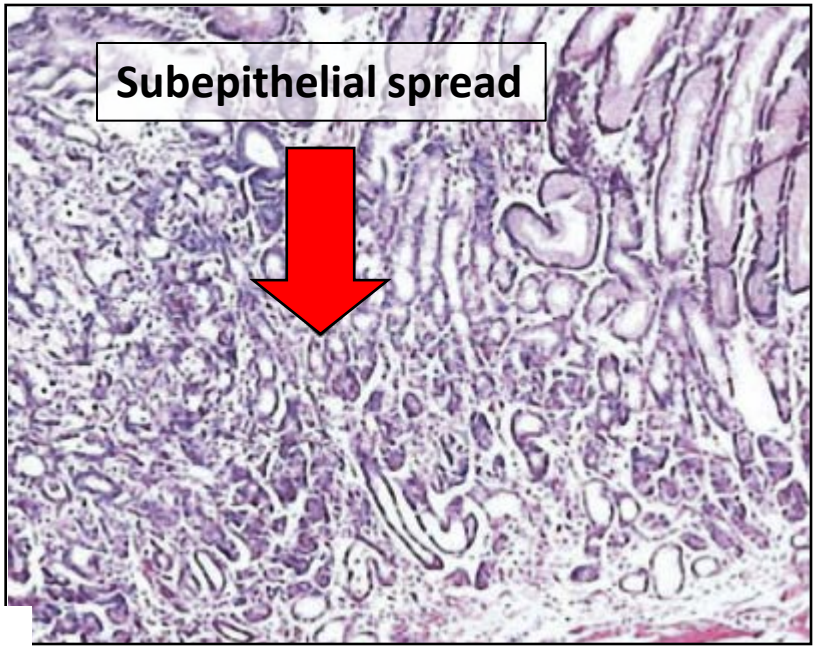

Gao XS – IJROBP– 2007

CTV Length along esophagus

- Microscopic findings to define subclinical spread (endovascular embolization)

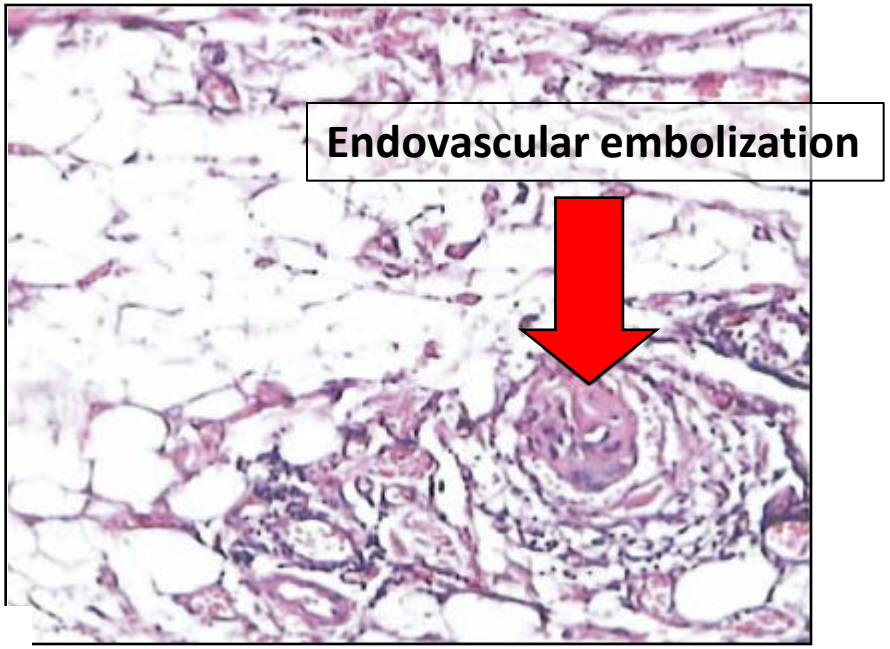

Gao XS – IJROBP– 2007

CTV longitudinal margins

- **SCC (mean micro distance):**

  10.5 ± 13.5 mm proximally → 94% within **30 mm**

  10.6 ± 8.1 mm distally

  N+ 35%

- **Adenoca GEJ (mean micro distance):**

  10.3 ± 7.2 mm proximally → 94% within

  18.3 ± 16.3 mm distally **30 mm proximal**

  N+ 47% **50 mm distal**

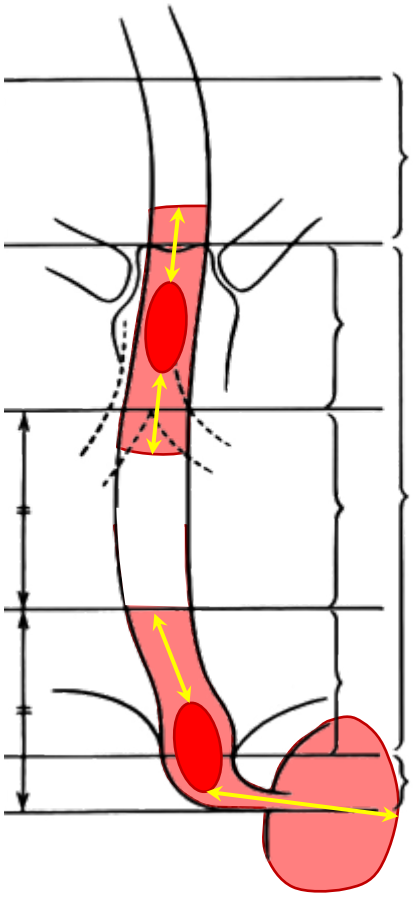

Gao XS – IJROBP– 2007

CTV radial margins

GTV + 1-2 cm margin, anatomical structures

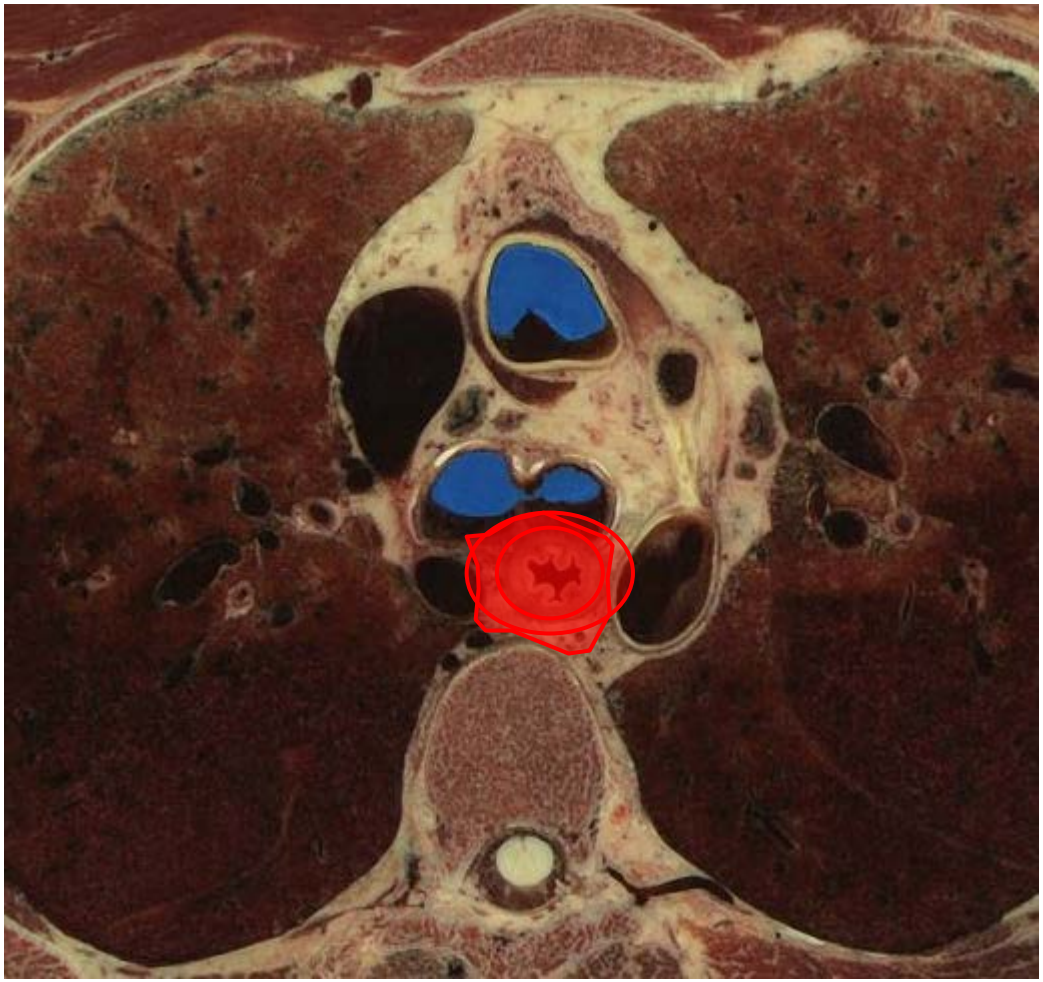

CTVs definition

CTV-T

SCC: GTV-T + 3 cm CC + 1-2 cm radial*

ADC:GTV-T + 3 cm prox and 5 cm dist + 1-2 cm radial*

(*adjust according anatomy)

CTV-N = GTV-N + nodal area

CTV-boost = GTV + 2 cm CC

Esophageal cancer

- Treatment approaches
- Sites of recurrences
- Target volume delineation:
  - **GTV T-N**
  - **CTV T-N**
  - **CTV elective nodes**

The importance of lymphnodal spread

- Results of retrospective analysis on 359 surgical patients
- Analysis of pathological findings, number of N1 patients and correlation with T stage

Rice ET et Al – Ann Thorac Surg – 1998

The importance of lymphnodal spread

Univariable and Multivariable Clinical Factors Predicting N1 Disease

	Univariable Results			Multivariable Results		
Variable	OR	95% CI	*p* Value	OR	95% CI	*p* Value
Sex						
Male/female	1.3	0.7–2.2	0.39	. . .	. . .	NC
Age at operation						
Per 10-year increase	0.9	0.8–1.1	0.48	. . .	. . .	NC
Barrett's mucosa						
No/yes	2.3	1.5–3.6	<0.001	. . .	. . .	NS
Signet ring cells						
Yes/no	2.4	1.2–4.8	0.014	. . .	. . .	NS
T status						
2/1	6.3	2.3–17.5	<0.001	5.9	2.0–17.5	0.001
3/1	28.0	12.0–65.2	<0.001	23.0	9.4–56.2	<0.001
4/1	16.6	3.4–81.5	<0.001	34.8	5.9–205.4	<0.001
Cell type						
AD/SQ	1.9	1.1–3.4	0.032	3.8	1.9–7.8	<0.001
AS/SQ	1.7	0.4–7.2	0.44	1.3	0.3–5.9	0.76
Differentiation						
Not well/Well	11.1	4.5–27.3	<0.001	3.9	1.3–11.8	0.014

AD = adenocarcinoma; AS = adenosquamous carcinoma; CI = confidence interval; OR = odds ratio; NC = not considered in multivariable model; NS = not significant in multivariable model; SQ = squamous cell carcinoma.

Rice ET et Al – Ann Thorac Surg – 1998

The importance of lymphnodal spread

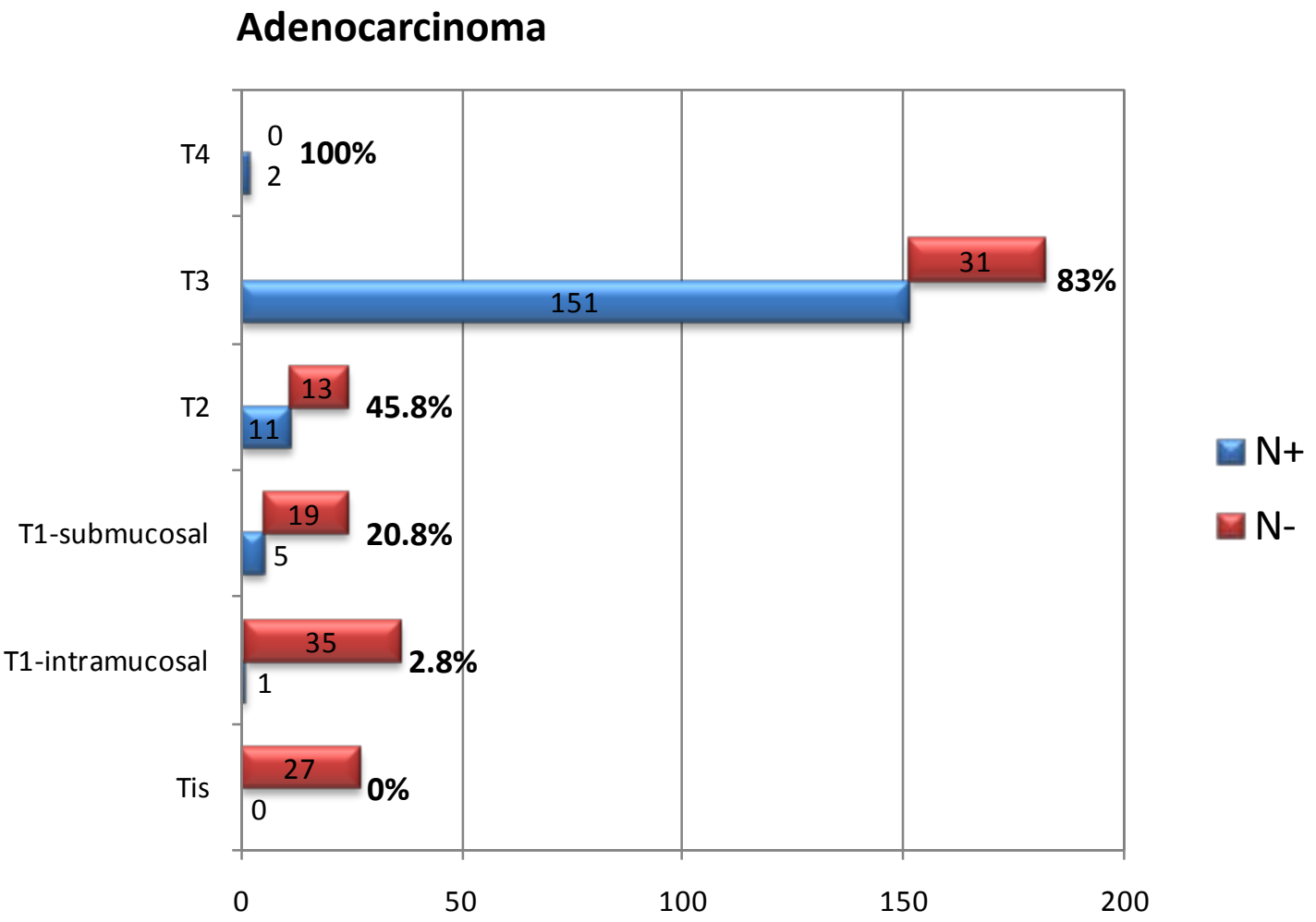

Rice ET et Al – Ann Thorac Surg – 1998

The importance of lymphnodal spread

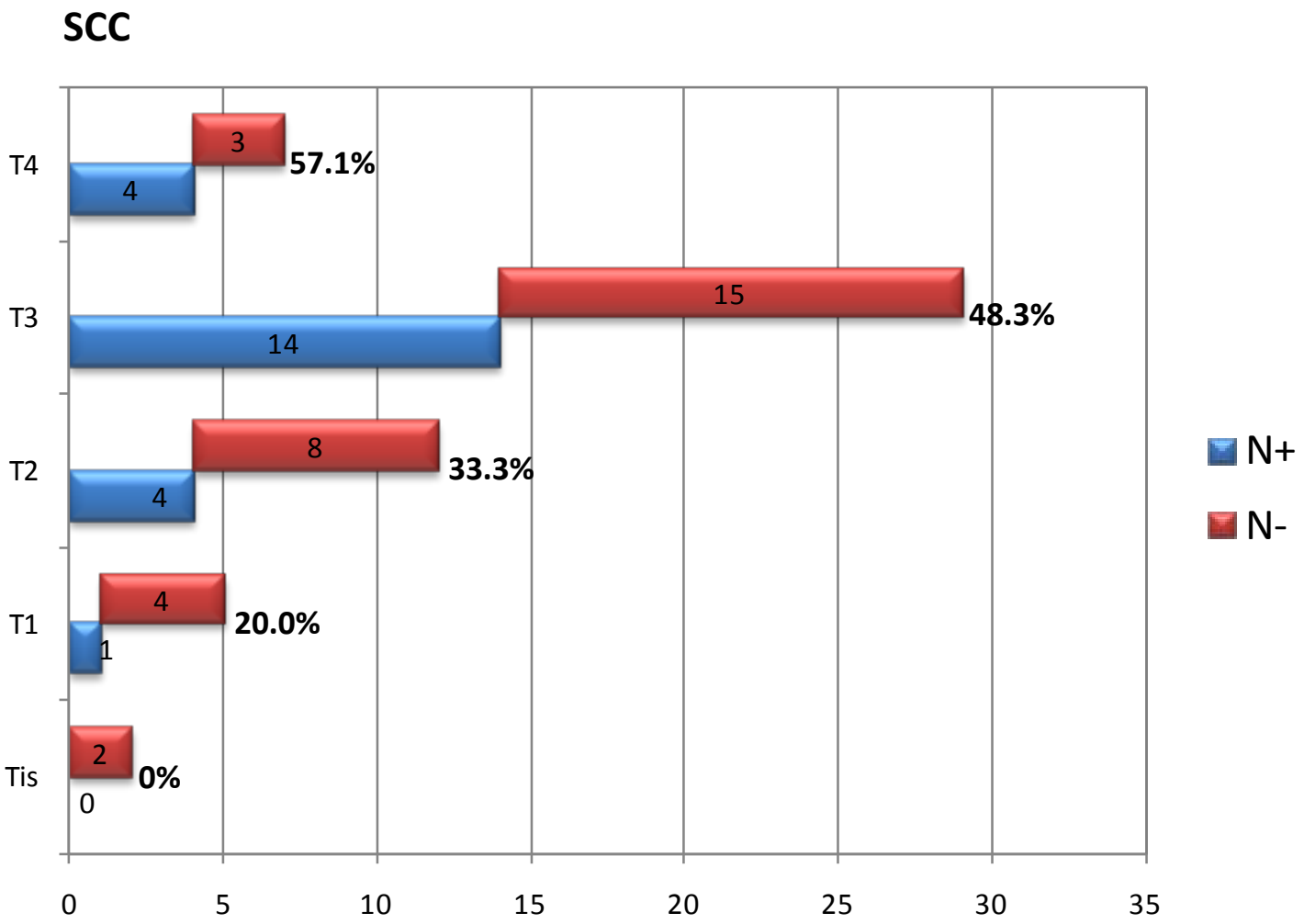

Rice ET et Al – Ann Thorac Surg – 1998

The importance of lymphnodal spread

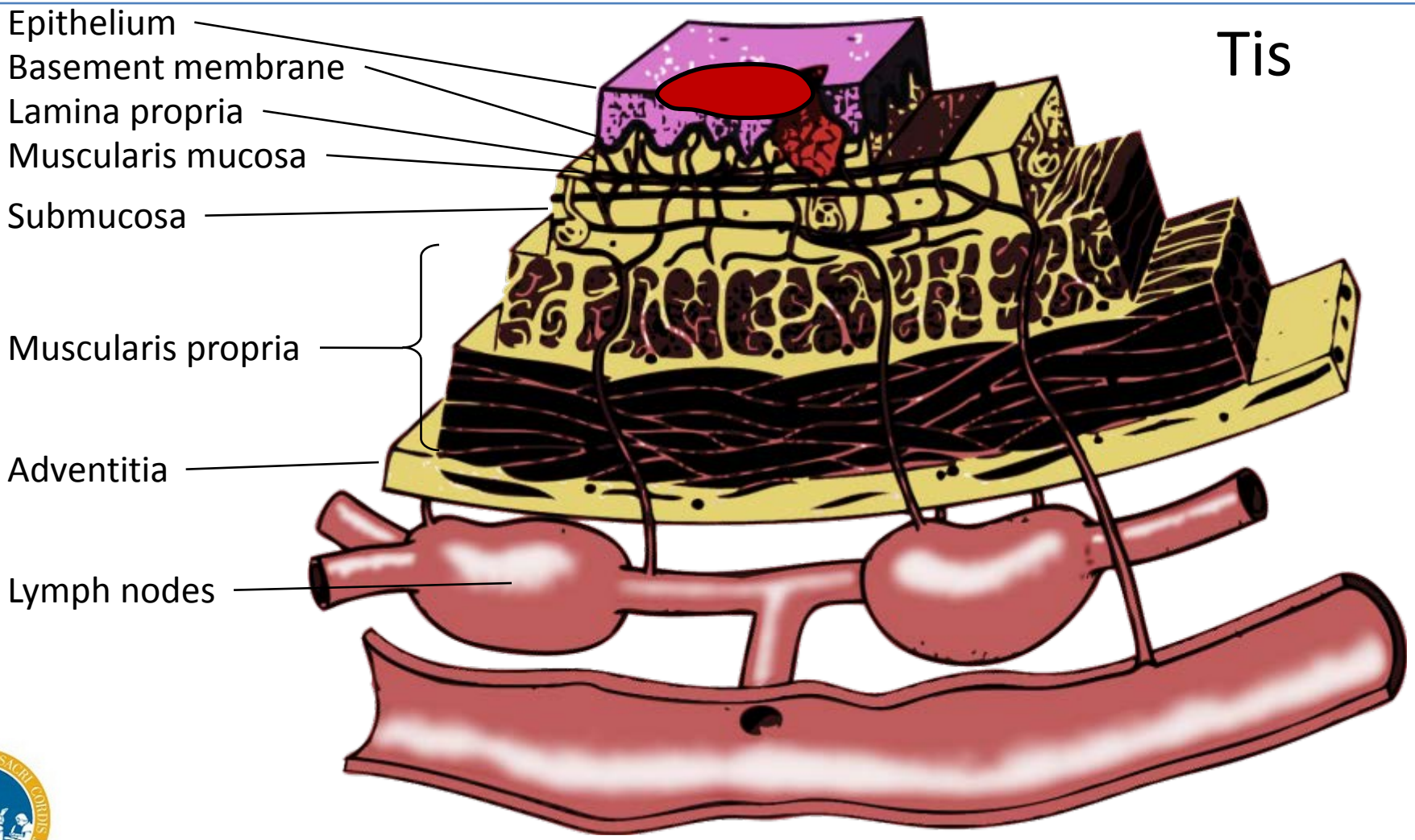

Mod. from Rice ET et Al – Ann Thorac Surg – 1998

The importance of lymphnodal spread

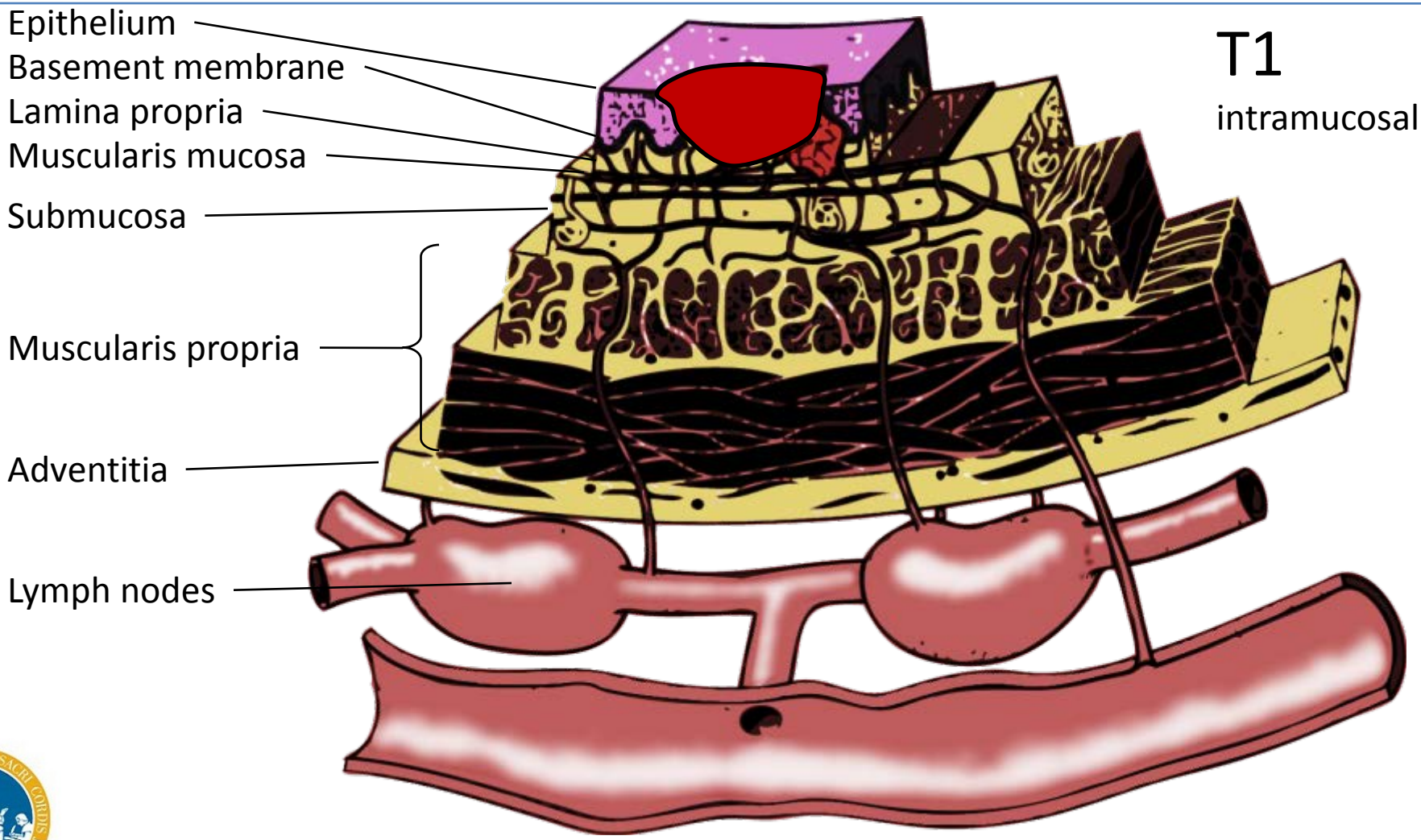

Mod. from Rice ET et Al – Ann Thorac Surg – 1998

The importance of lymphnodal spread

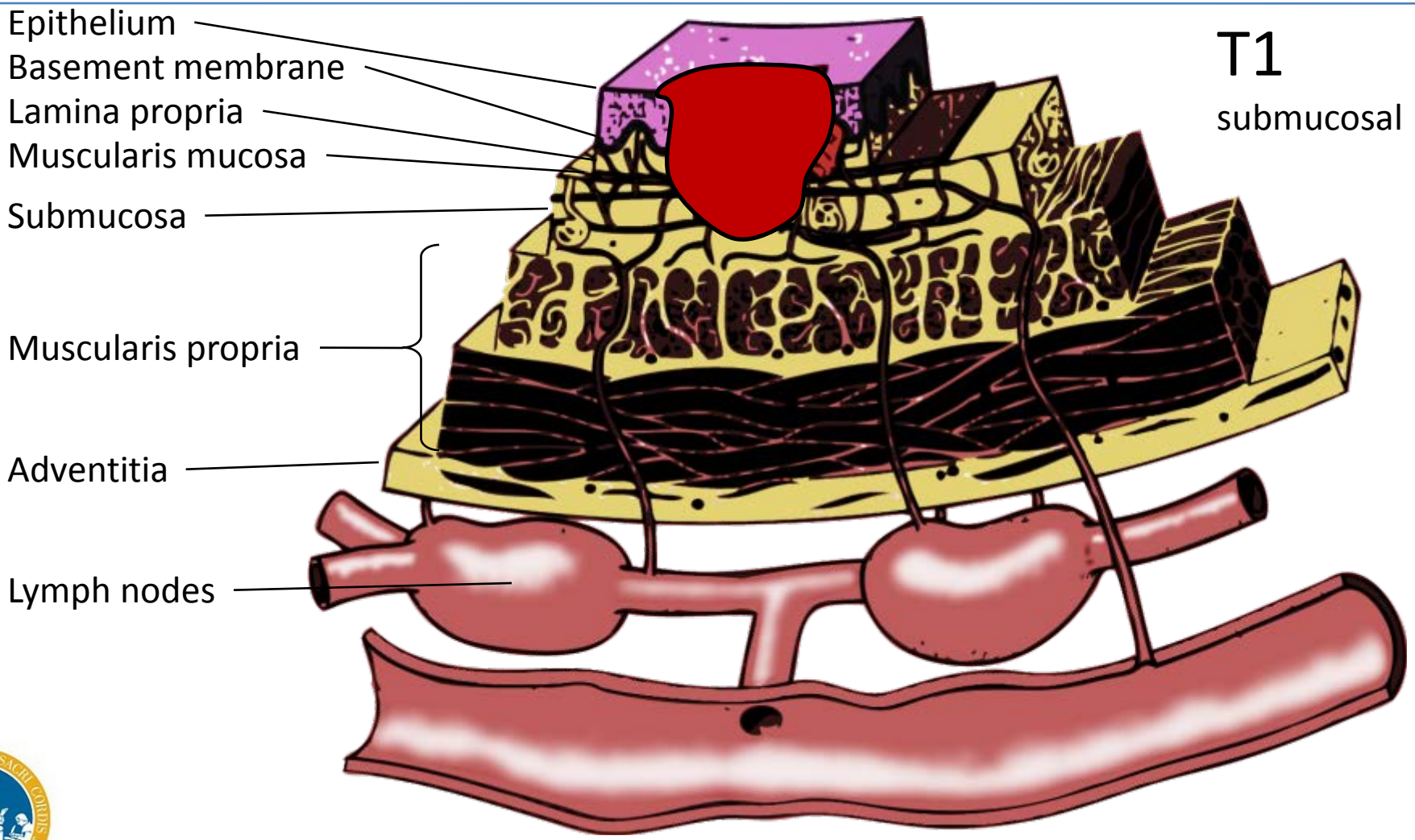

Mod. from Rice ET et Al – Ann Thorac Surg – 1998

The importance of lymphnodal spread

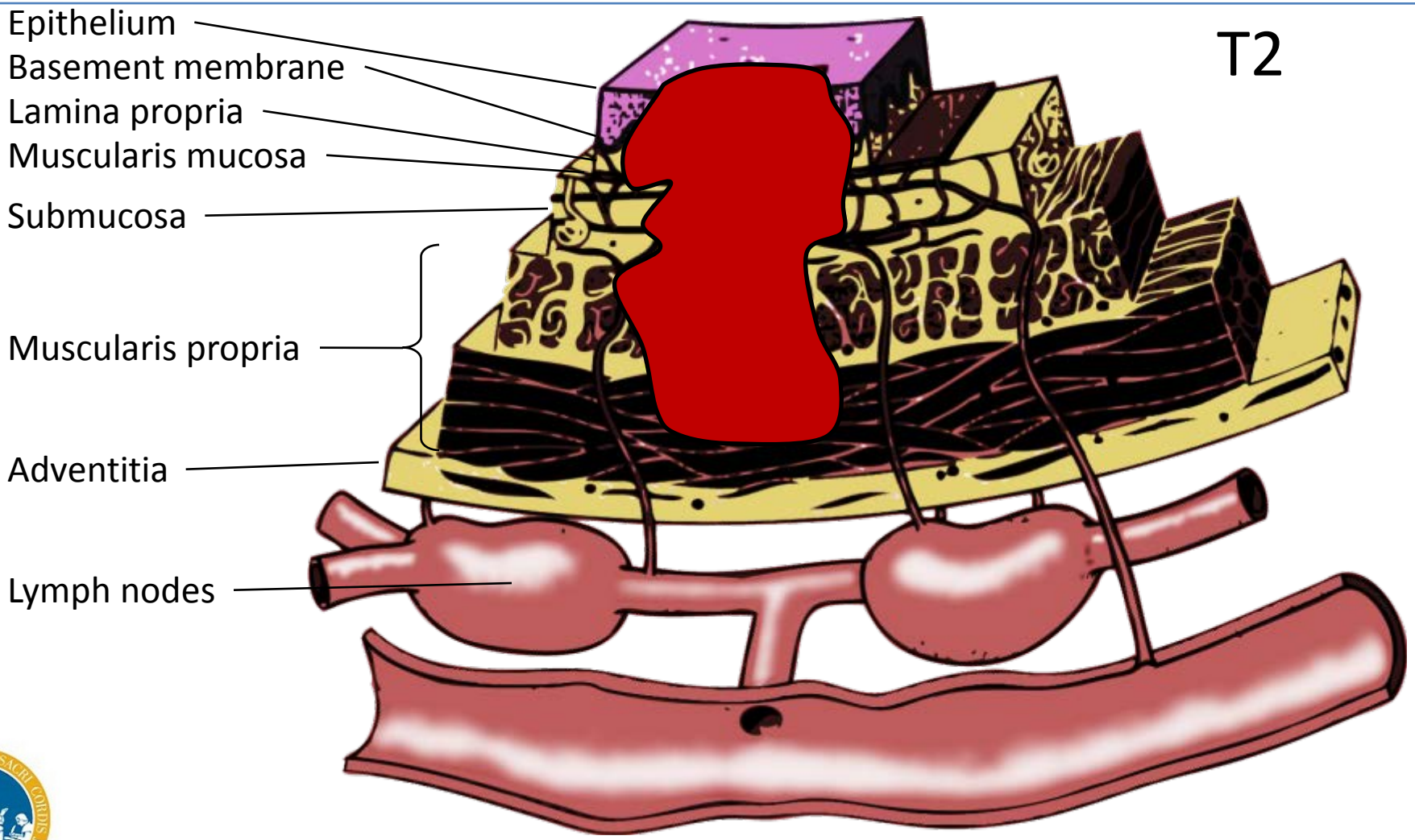

Mod. from Rice ET et Al – Ann Thorac Surg – 1998

The importance of lymphnodal spread

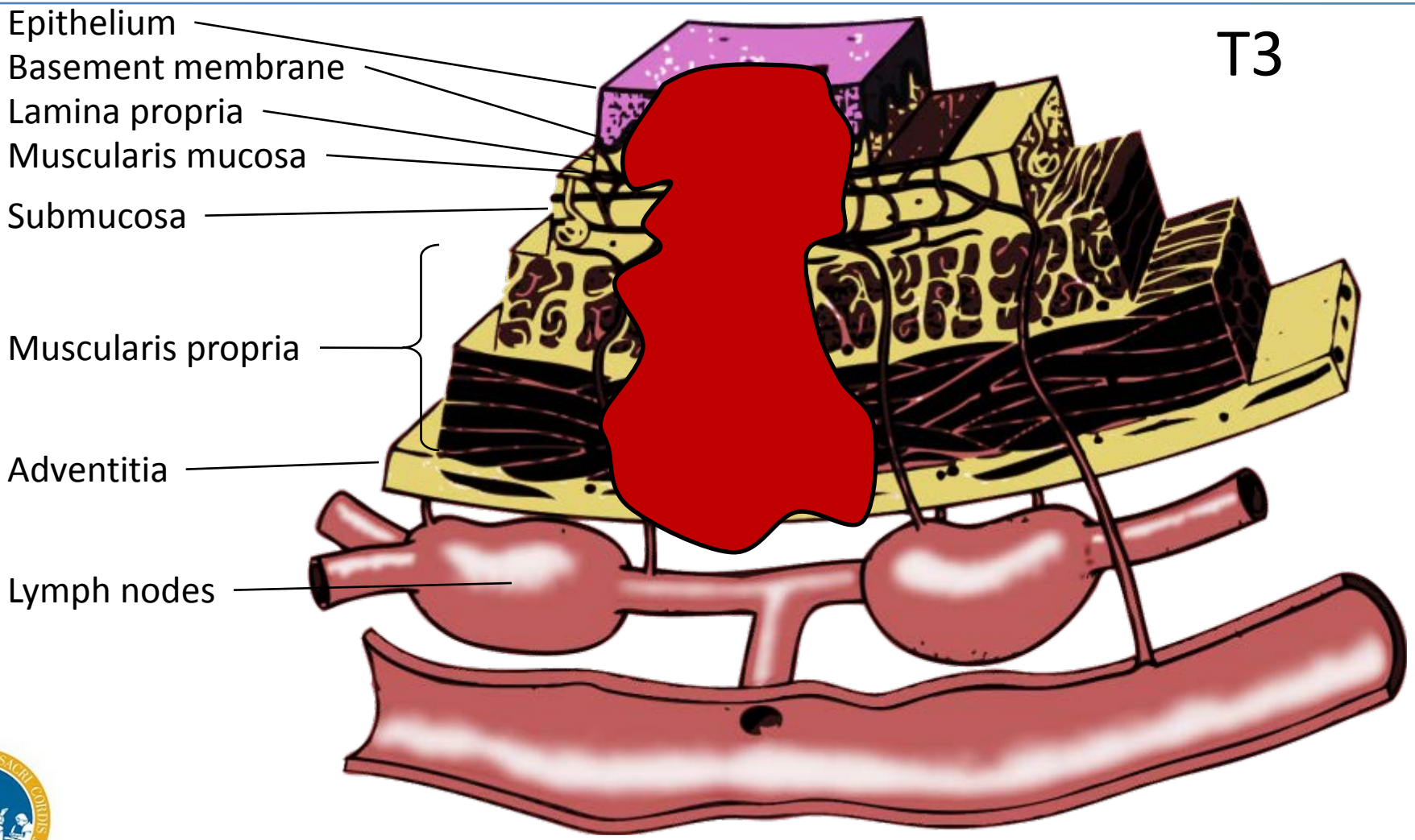

Mod. from Rice ET et Al – Ann Thorac Surg – 1998

The importance of lymphnodal spread

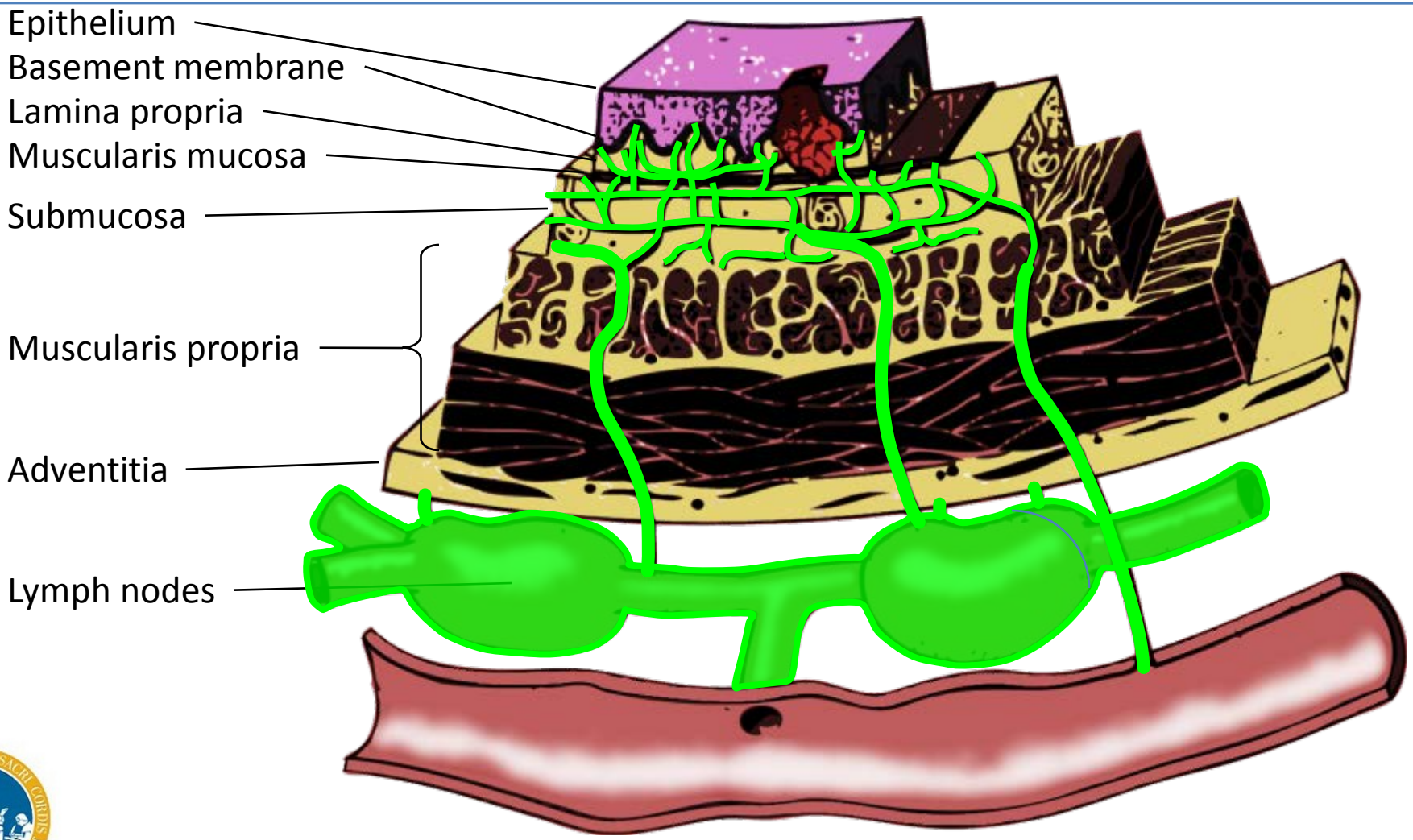

Mod. from Rice ET et Al – Ann Thorac Surg – 1998

Lymphnodal spread according to T location

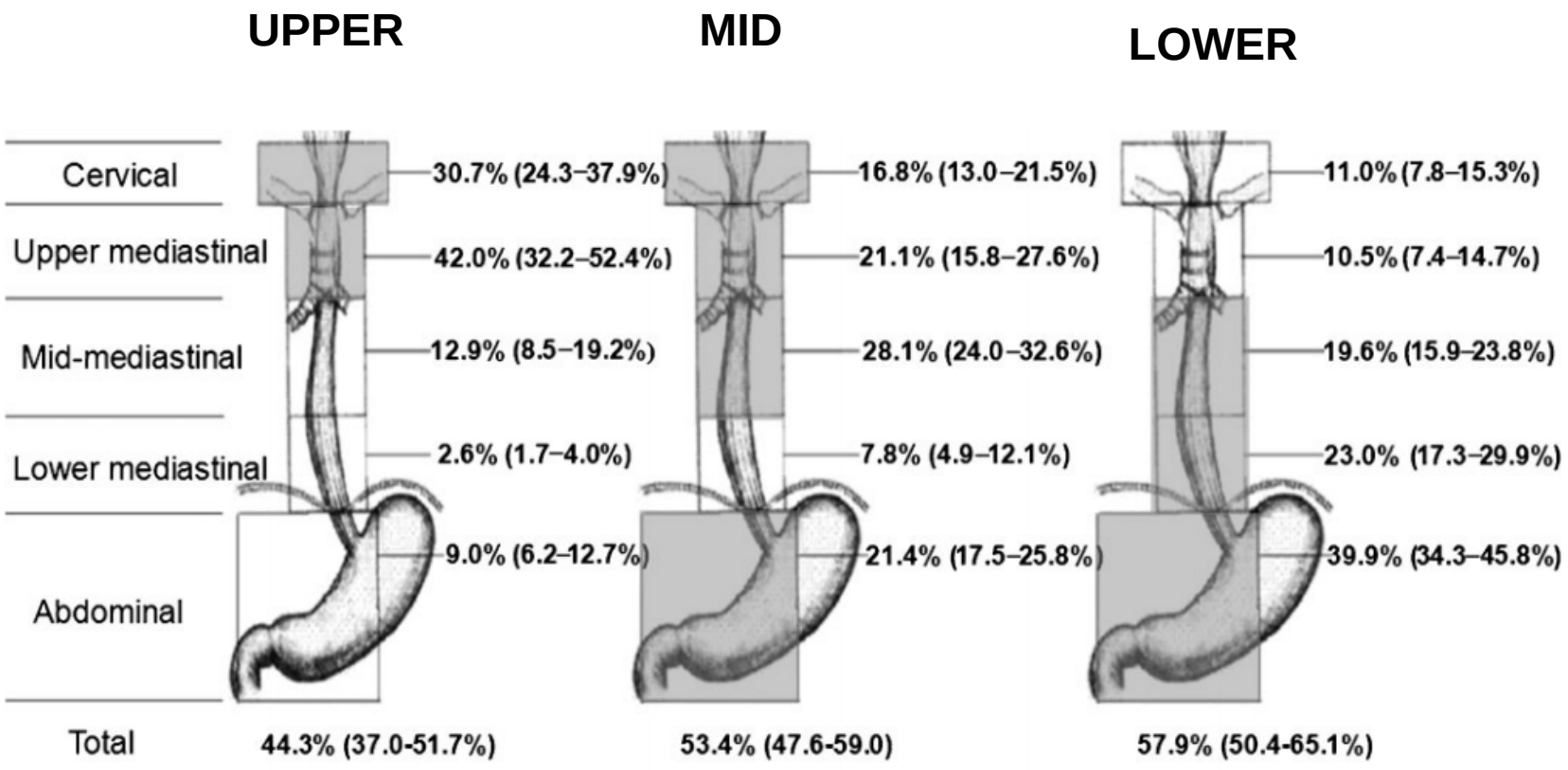

Metanalysis of 45 surgical studies (n 18.415)

Ding XET et Al – Br J Radiol– 2012

Lymphnodes classification

- Divided in 3 levels:
  - Cervical (Gregoire)
  - Thoracic (RTOG-)
  - Abdominal (RTOG-JGCA)

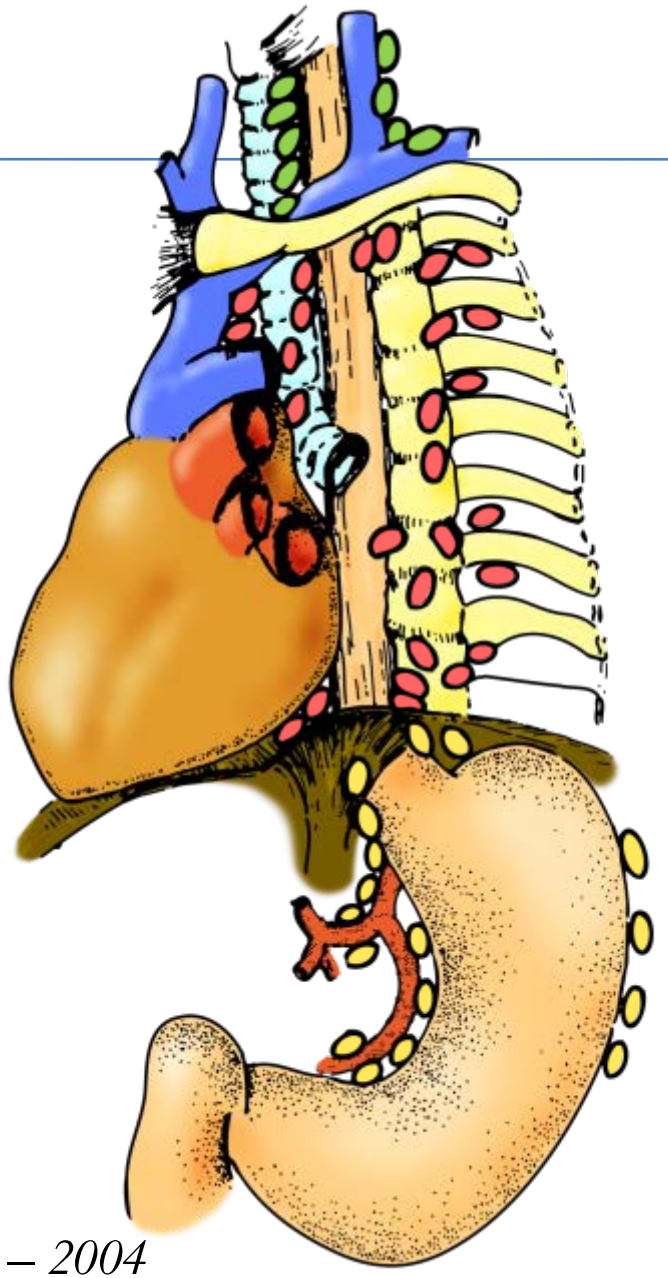

Grègoire et al. –Radiother Oncol – 2014
Korst et al. –J Thorac. Cardiovasc. Surg– 1998
Japanese Society for Esophageal Diseases – Esophagus – 2004

Cervical level

- Deep nodes

Dahanca, EORTC, HKNPCSG, NCIC CTG, NCRI, RTOG
IV a lower jugular lymph-nodes
IV b medial sovraclavicular nodes
VI b pre-laryngeal, pre-tracheal and para-tracheal (recurrent laryngeal nerve) nodes

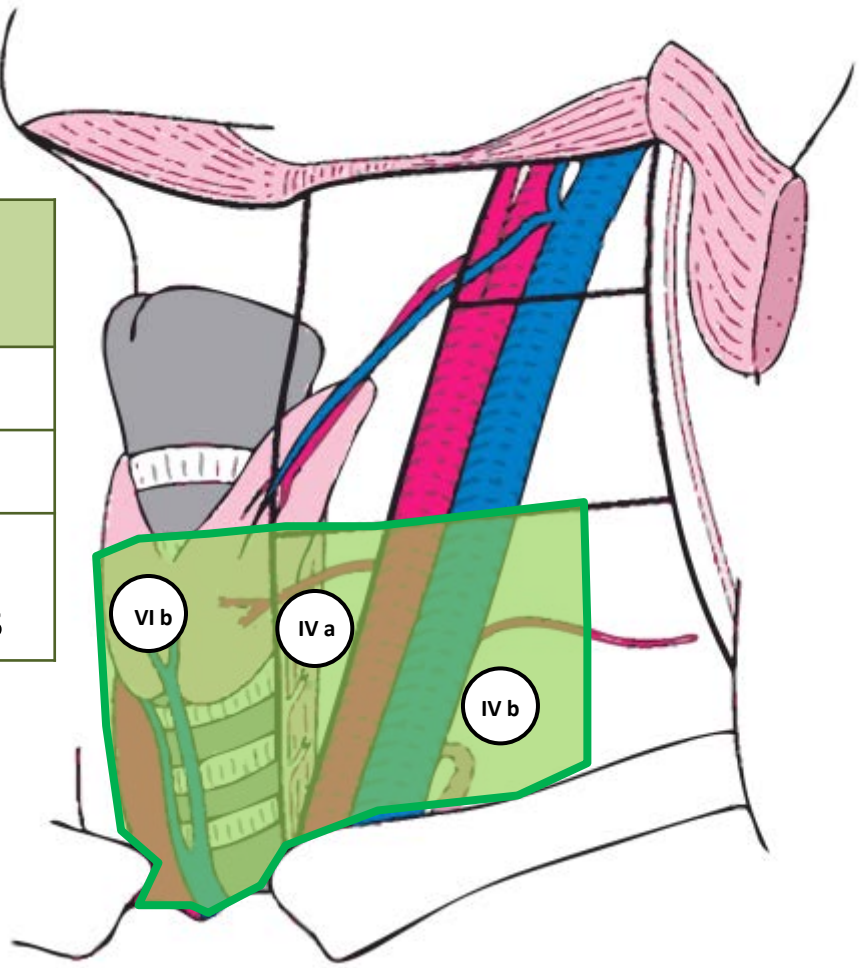

Grègoire et al. –Radiother Oncol – 2014

Cervical lymphnodes: axial anatomy

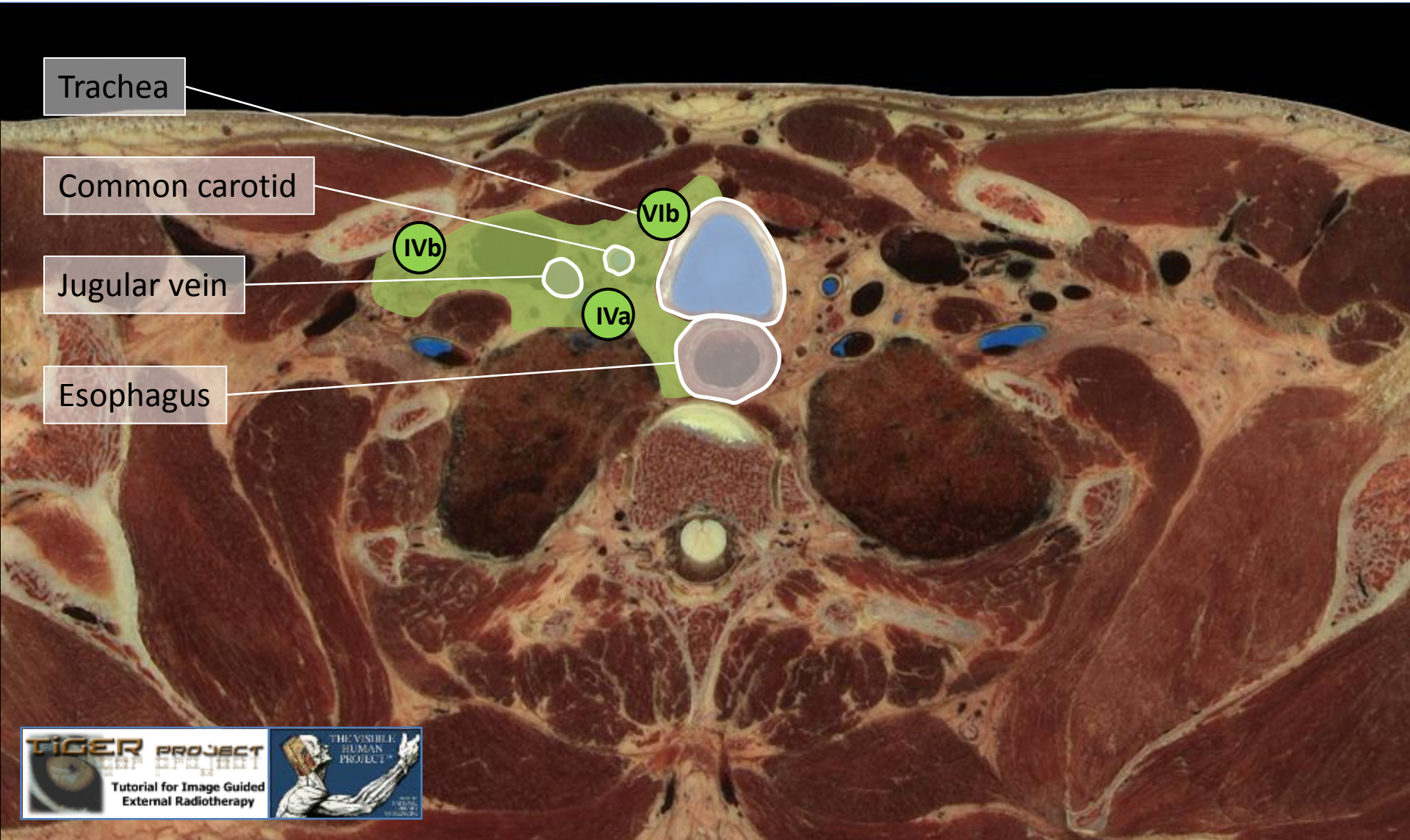

Cervical CT axial anatomy

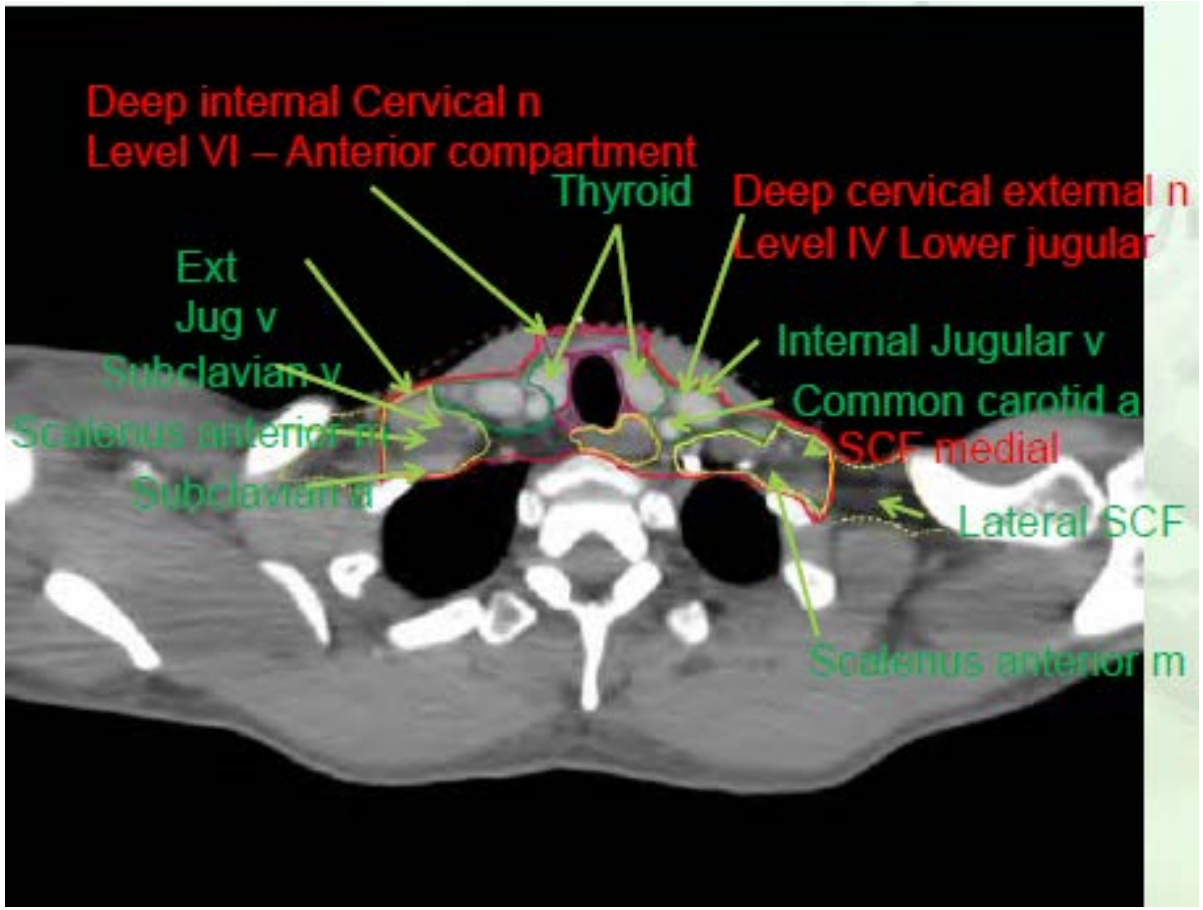

Thoracic level

RTOG Korske
2 (R-L) Superior paratracheal
3 P Posterior mediastinal
4 (R-L) Inferior paratracheal
5 A-P window
6 Anterior mediastinal
7 Subcarinal
8 (M-L) Middle/Lower paraesophageal
9 (L-R) Pulmonary ligament
10 (R-L) Tracheobronchial
15 Diaphragmatic

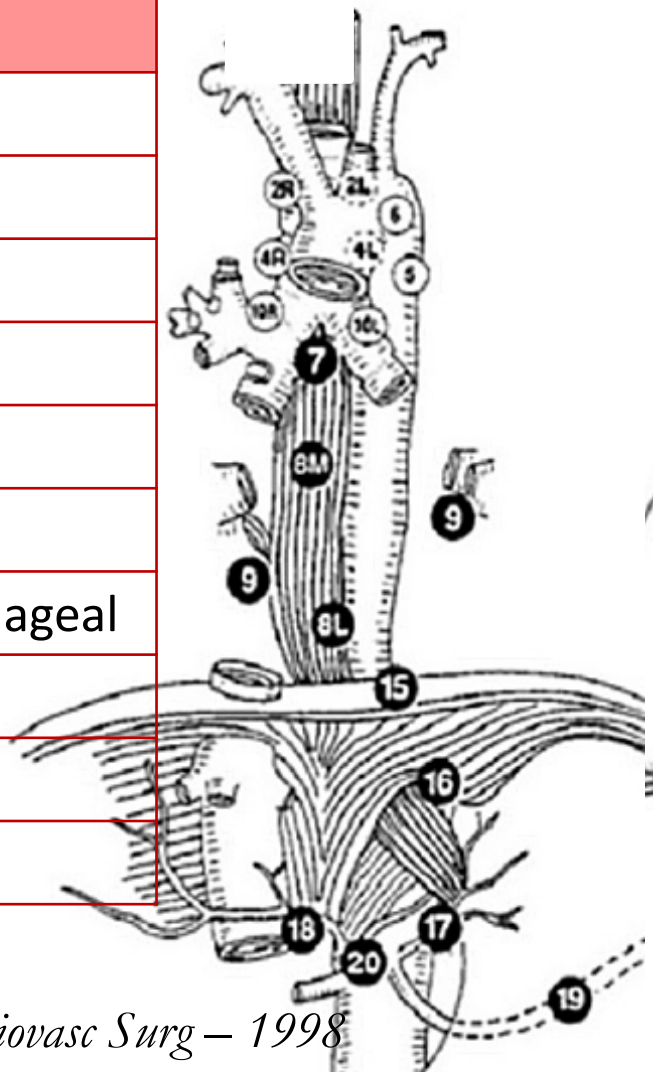

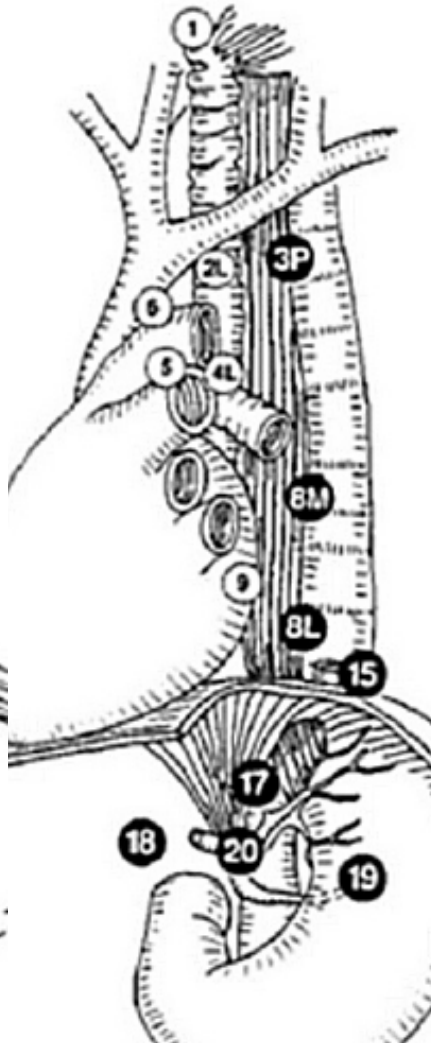

Korst RJ et al– Cardiovasc Surg – 1998

Thoracic level: axial anatomy

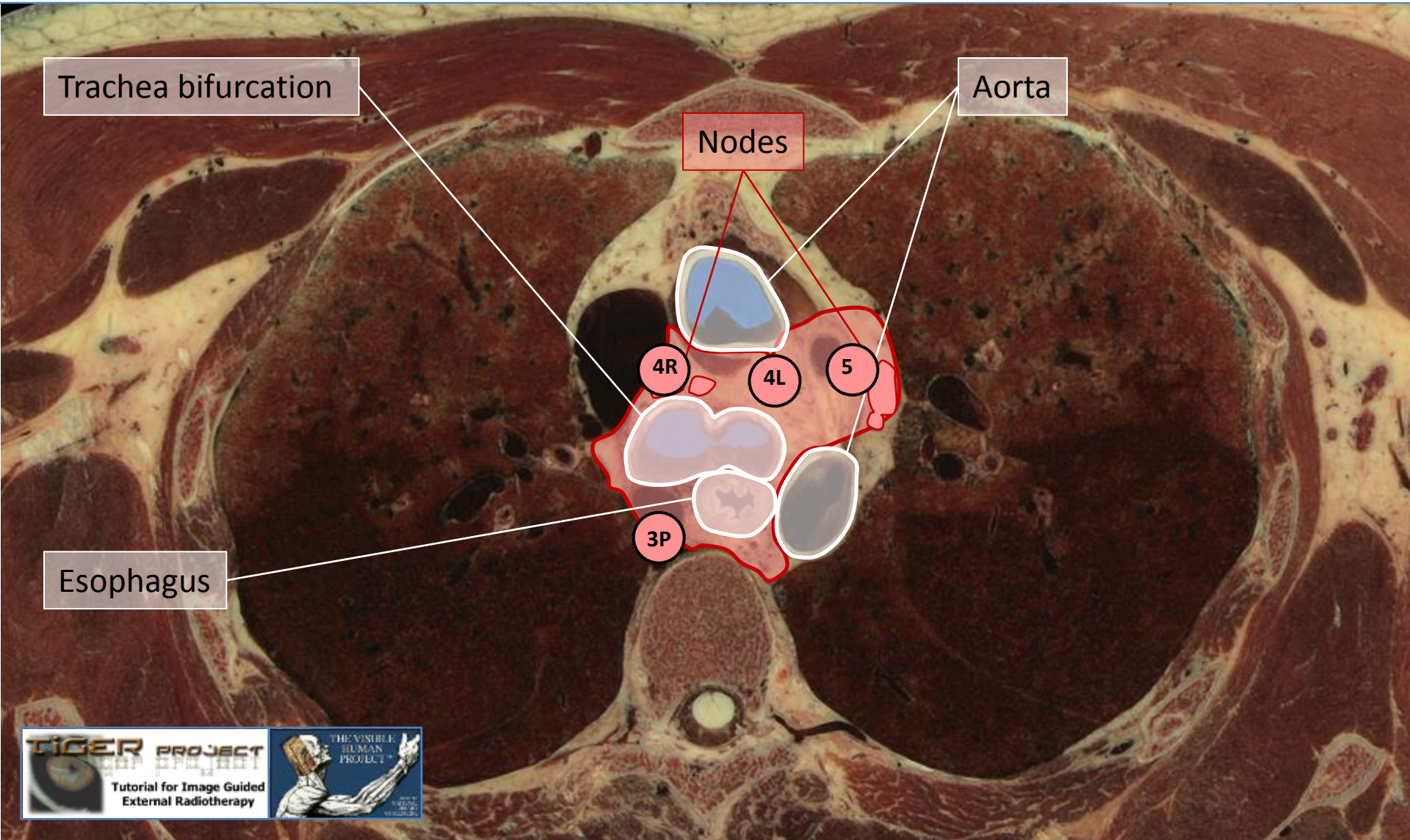

TIGER PROJECT
Tutorial for Image Guided External Radiotherapy
THE VISIBLE HUMAN PROJECT

Thoracic CT anatomy

Thoracic level: axial anatomy

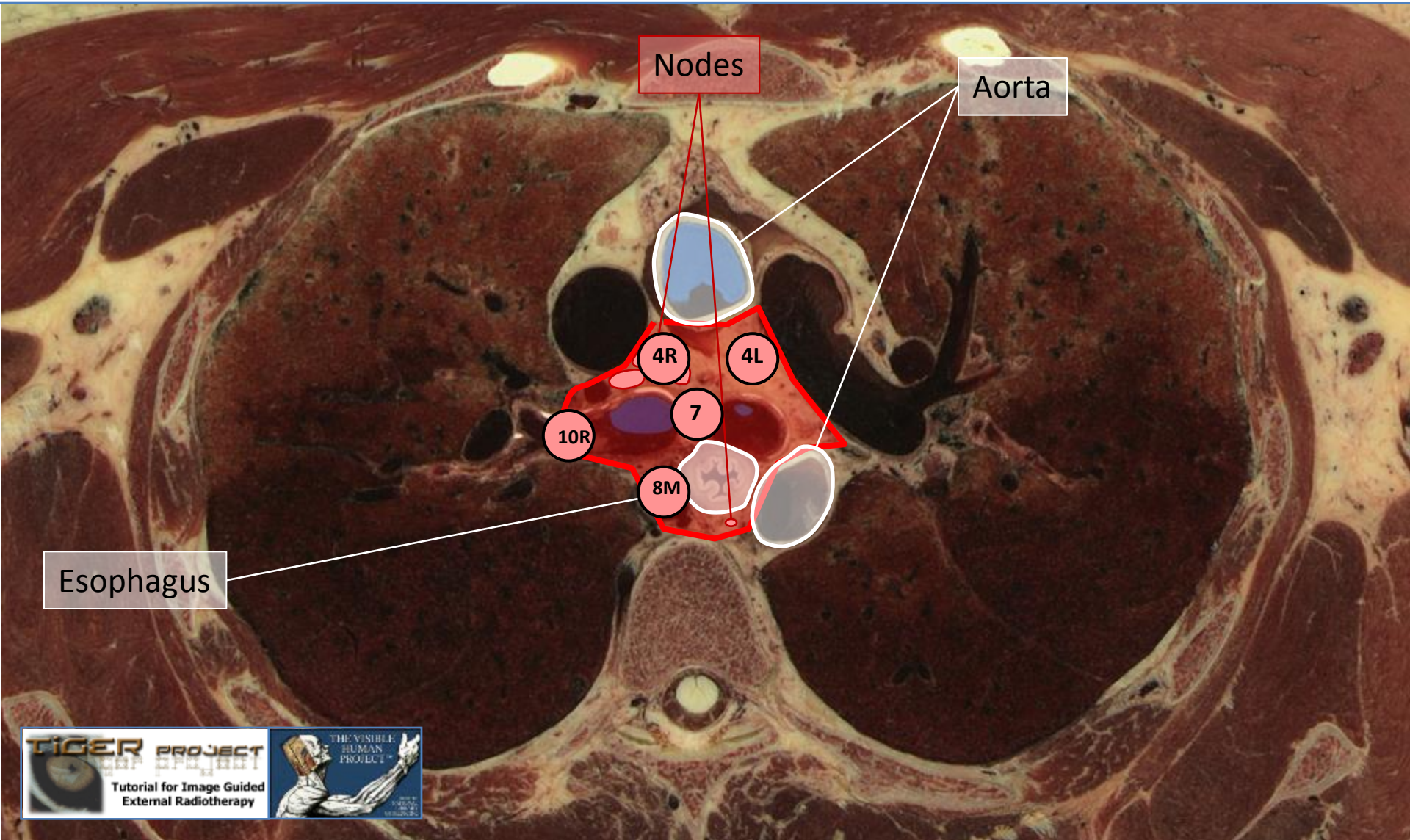

TIGER PROJECT
Tutorial for Image Guided External Radiotherapy
THE VISIBLE HUMAN PROJECT

Thoracic CT anatomy

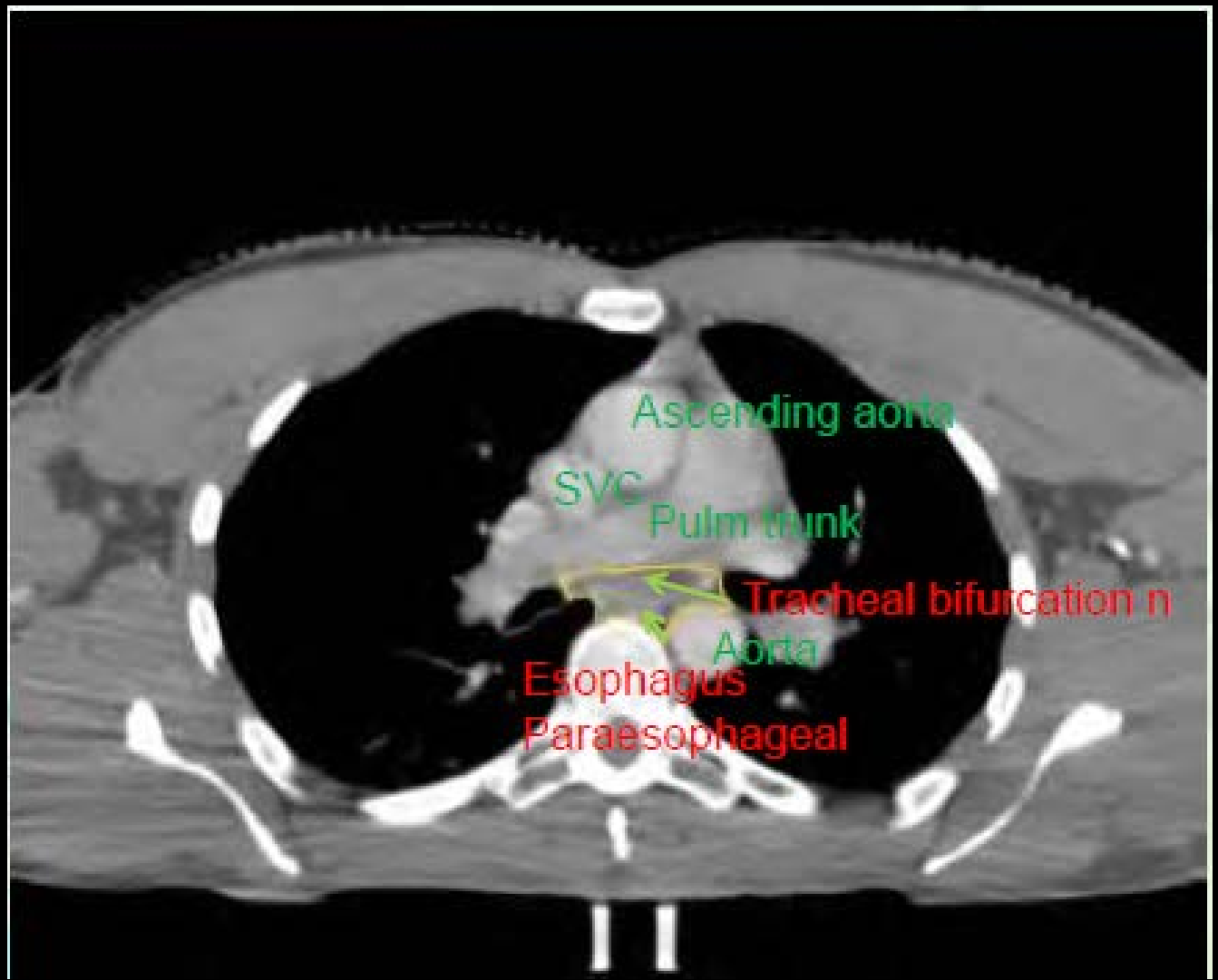

Abdominal level

Korst classification	JSED Classification
16 paracardiac	**1** Right cardiac
	2 Left cardial
17 Left gastric artery	**7** Left gastric artery
18 Common hepatic art	**8** Common hepatic art
19 splenic	**11** splenic artery
20 celiac artery	**9** celiac artery

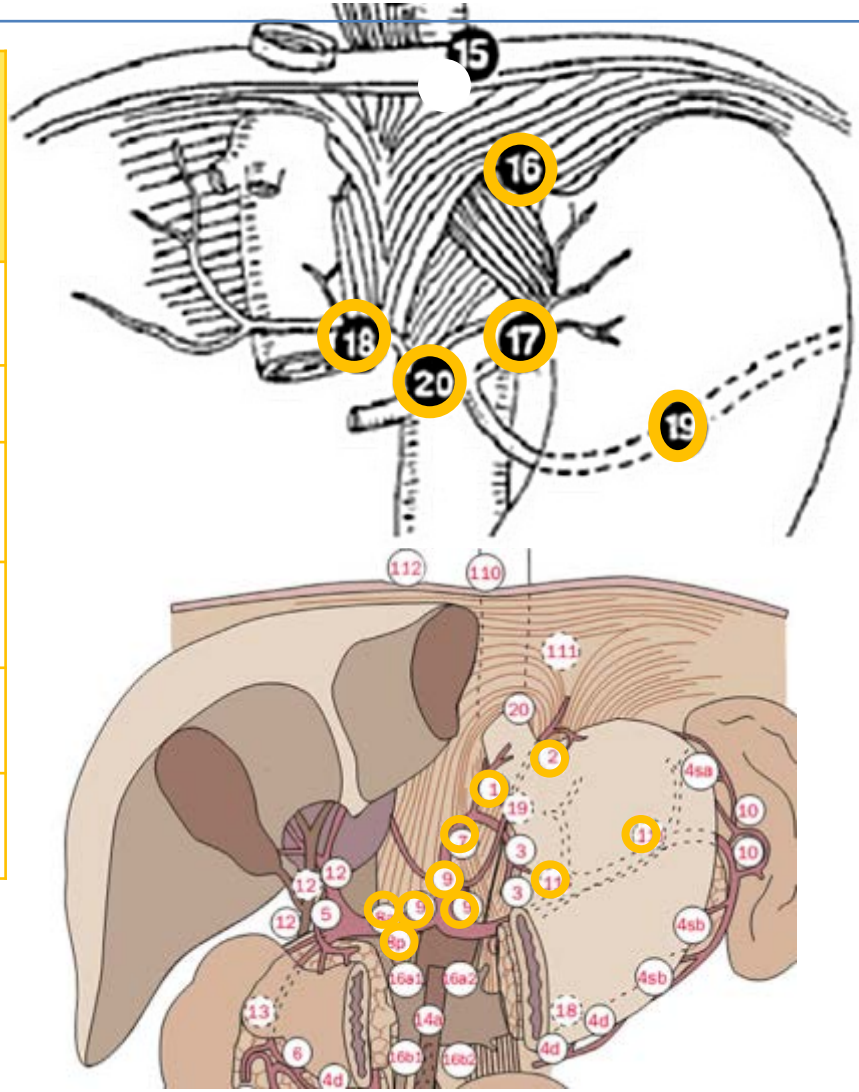

Japanese Society for Esophageal Diseases – Esophagus – 2004

Abdominal level: axial anatomy

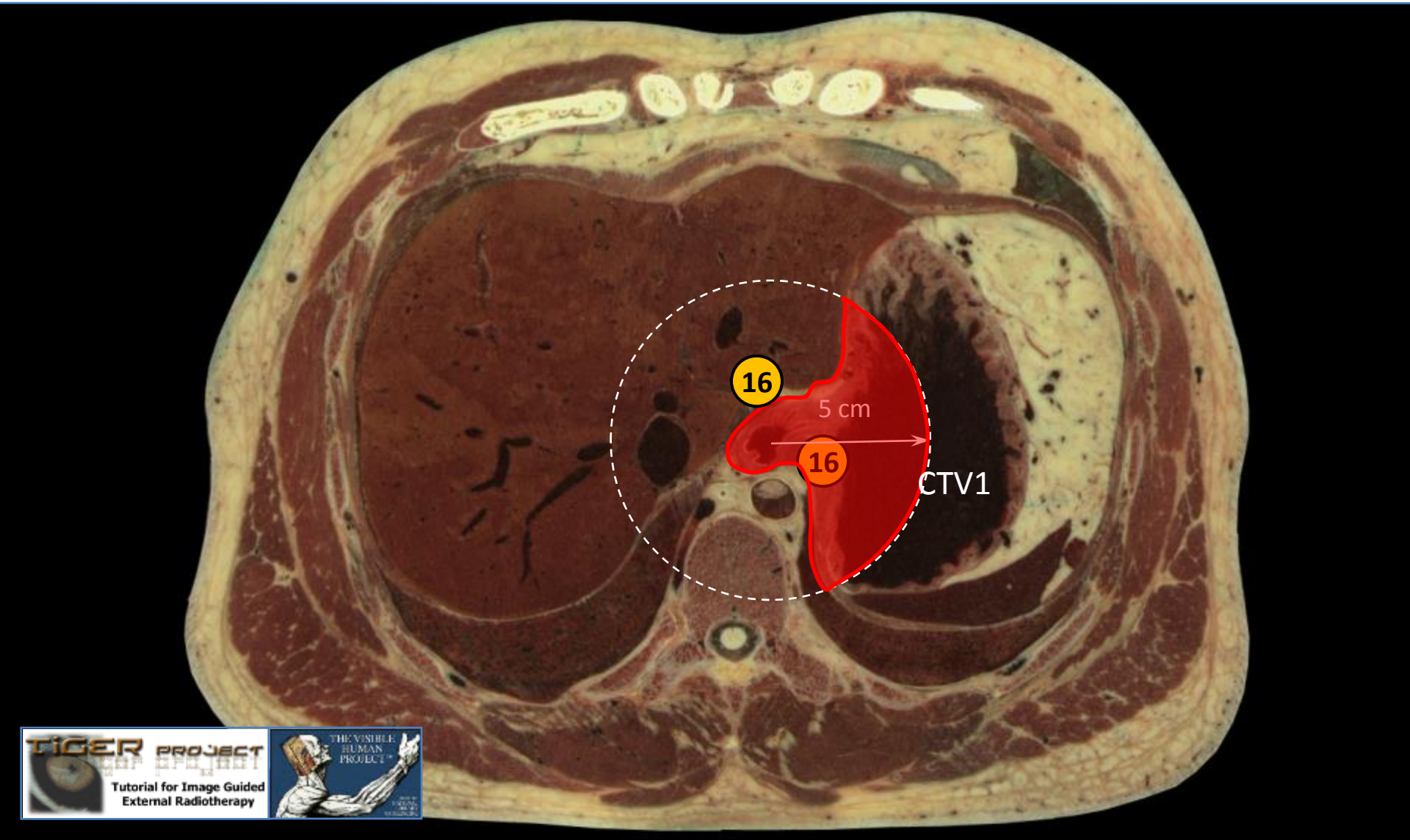

CTV-elective definition

- **Nodes with positive possibility of ≥ 20%**
- **Depends on tumor site**

CTV-elective: cervical

Station number	
III (Grégoire)	Homolateral cervical if positive suvraclavicular nodes
IV ab, VI b (Grégoire)	**Supra-clavicular**
2 LR	**Sup paratracheal**
4 LR	**Inf paratracheal**
3 P	**Post mediastinal**

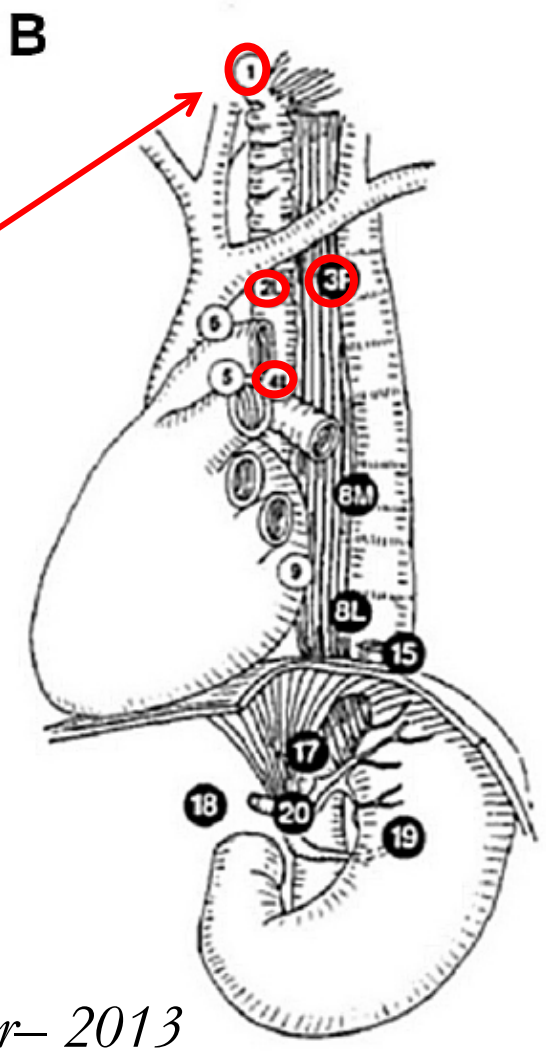

Lazarescu I et al – Cancer Radiother– 2013

CTV-elective: upper thoracic

Station number	
IV ab, VI b (Grégoire)	Supra-clavicular
2 LR	Sup paratracheal
4 LR	Inf paratracheal
3 P	Post mediastinal
5	AP window

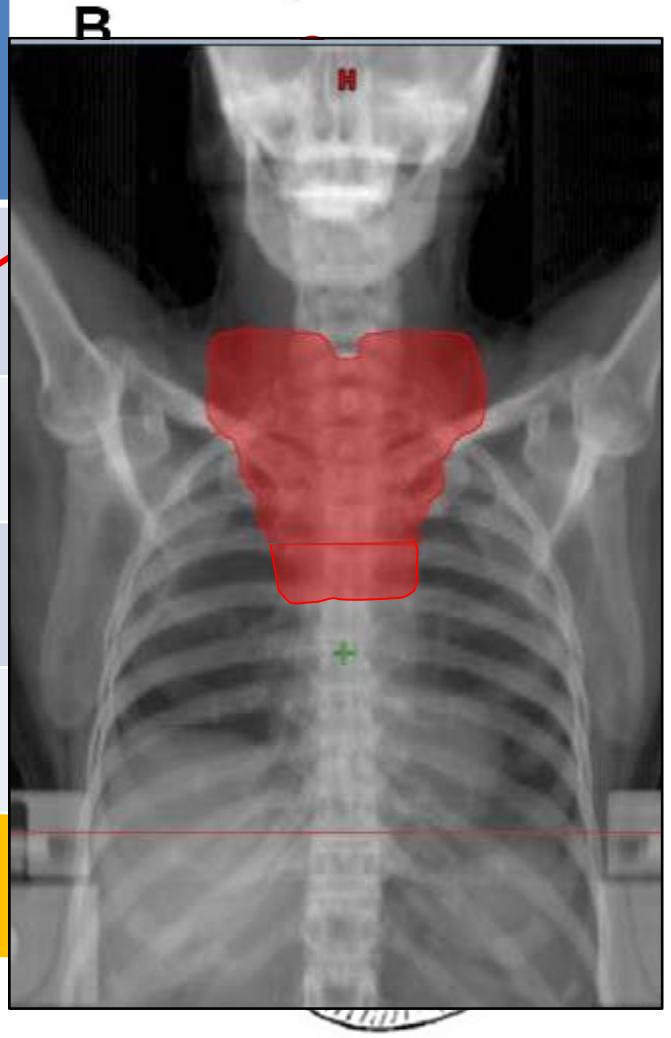

Lazarescu I et al – Cancer Radiother– 2013

CTV-elective: middle thoracic

Station number	
2 LR	Sup paratracheal
5	AP window
7	Sub-carinal
8ml	Para-esoph mid and inf
9	Pulm ligament
10	Tracheo bronchial
7 (JGCA)	L gastric artery

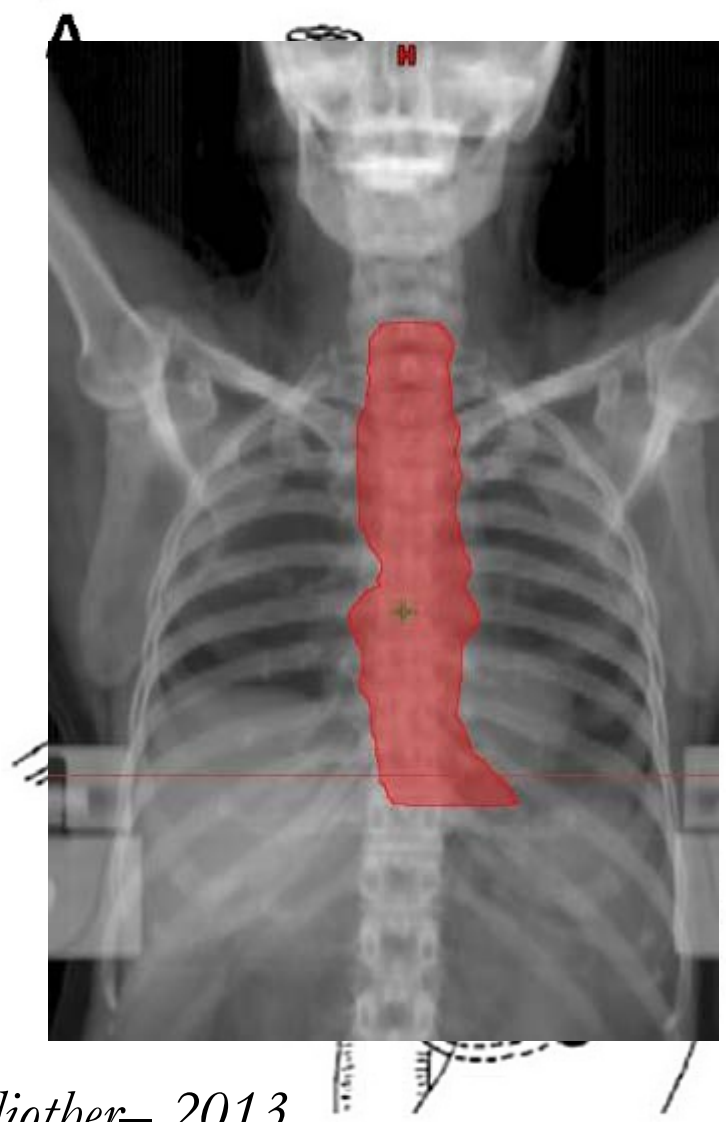

Lazarescu I et al – Cancer Radiother– 2013

CTV-elective: lower thoracic

Station number	
7	Sub-carinal
8l	Para-esoph inf
9	Pulm ligament
15-16	Supra-infra diaphragmatic
1-2 (JGCA)	RL paracardia
7 (JGCA)	L gastric artery

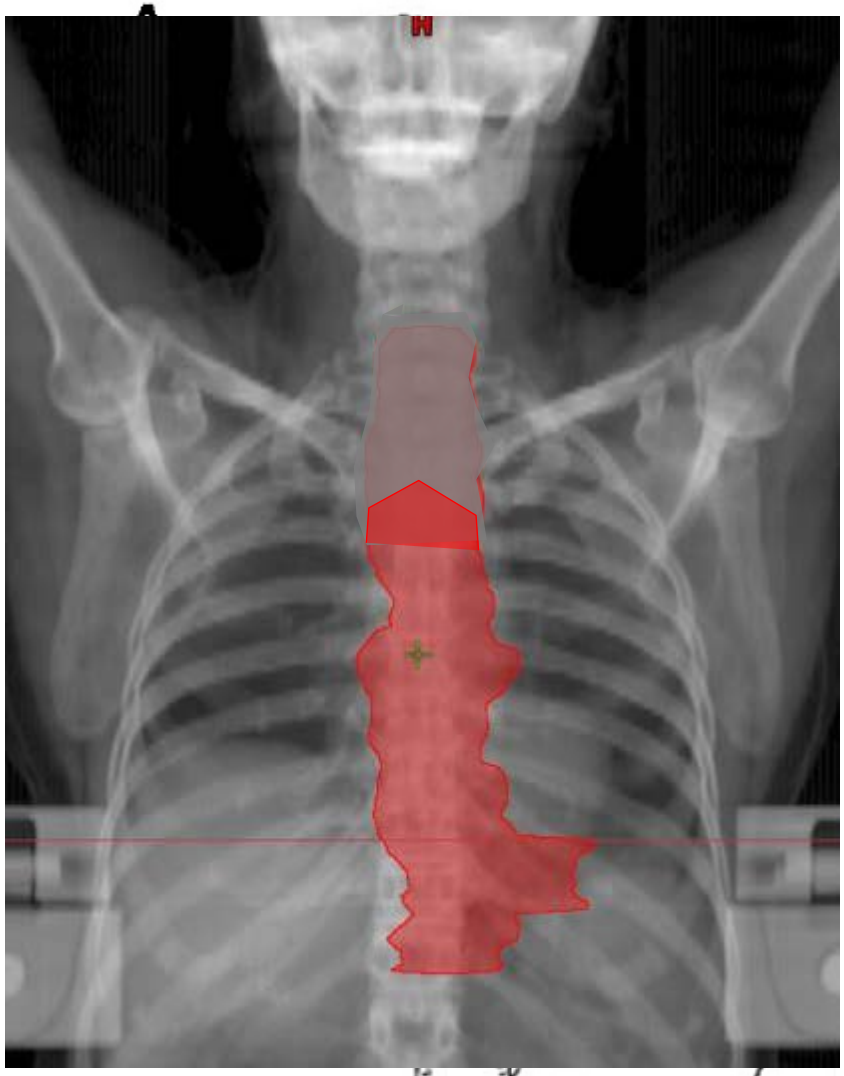

Lazarescu I et al – Cancer Radiother– 2013

Take home

- **RT (with chemo)** has an important role in esophagus cancer treatment
- **GTV definition**: **on CT**, **PET** might help for **localization-length-variability**, **never decrease** CTVs according to PET
- **CTV-T:** longitudinal **3-5 cm** according hystology
- **CTV-N:** include any positive + area delineation
- **CTV-elective:** modulated according **tumor site**
- Beware the lymphnodal **different classifications**

Gastro-esophageal tumor

Classification

- **Type I:**
  - **> 1 cm above the GEJ up to 5 c**
- **Type II: cardia tumors**
  - **1 cm oral 2 cm ab-oral the GEJ**
- **Type III:**
  - **> 2 cm, < 5 cm GEJ in the stomach**

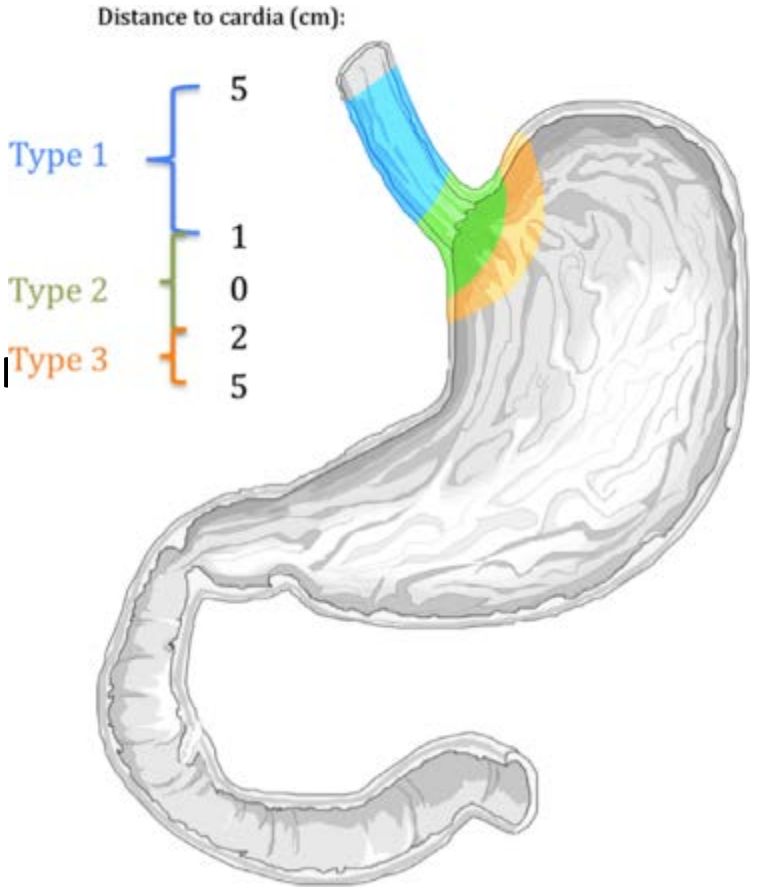

Matzinger O et al – Raadiother Oncol – 2009

GEJ: GTV and CTV (T, N)

- **Tumor:**
  - **GTV**: primary – perigastric tissue
  - **CTV** = GTV + **1.5 cm**
- **Nodal:**
  - **GTV:** positive nodes
  - **CTV**: GTV + **0.5 cm**

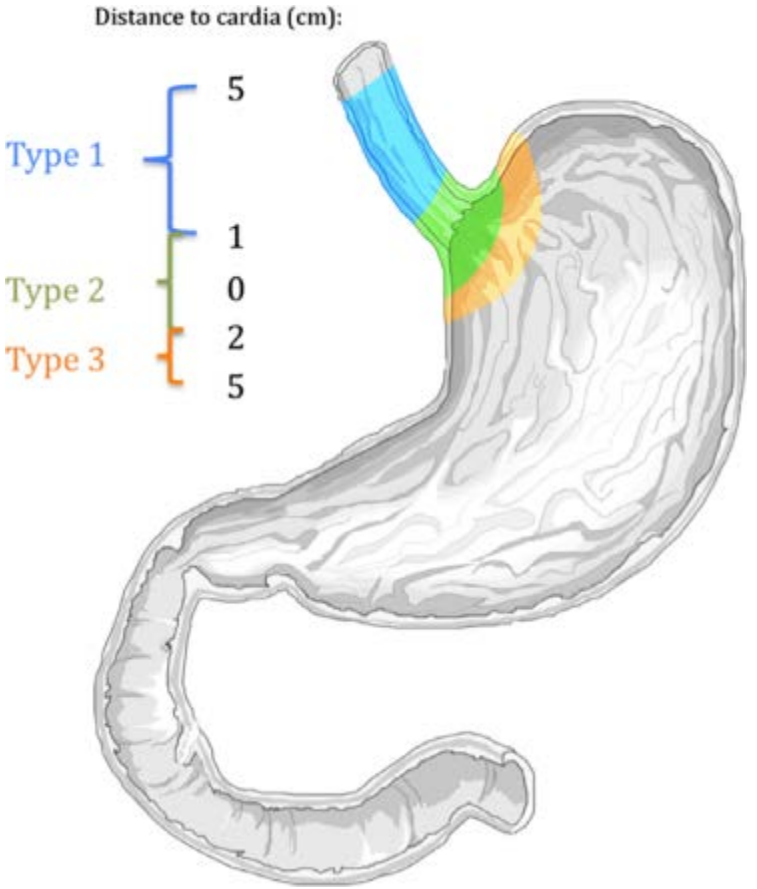

Matzinger O et al – Raadiother Oncol – 2009

CTV elective: nodes classification

Nodal group	Station Number
Para-esophageal, suvra-diaphragmatic, post mediatinum	110-111-112
Infra-diaphragmatic, esophageal iatus	19-20
Paracardia	1 – 2
Lesser/Greater Curvature	3 – 4
Suprapyloric	5
Infrapyloric	6
Left Gastric Artery	7
Common Epatic Artery	8
Celiac Axis	9
Splenic Artery/Hilum	10 – 11
Hepatoduodenal Ligamentum	12

Japanese Gastric Cancer Association Gastric Cancer - 2011

CTV elective: nodes classification

Paraesophageal/paradiaphagmatic

perigastric

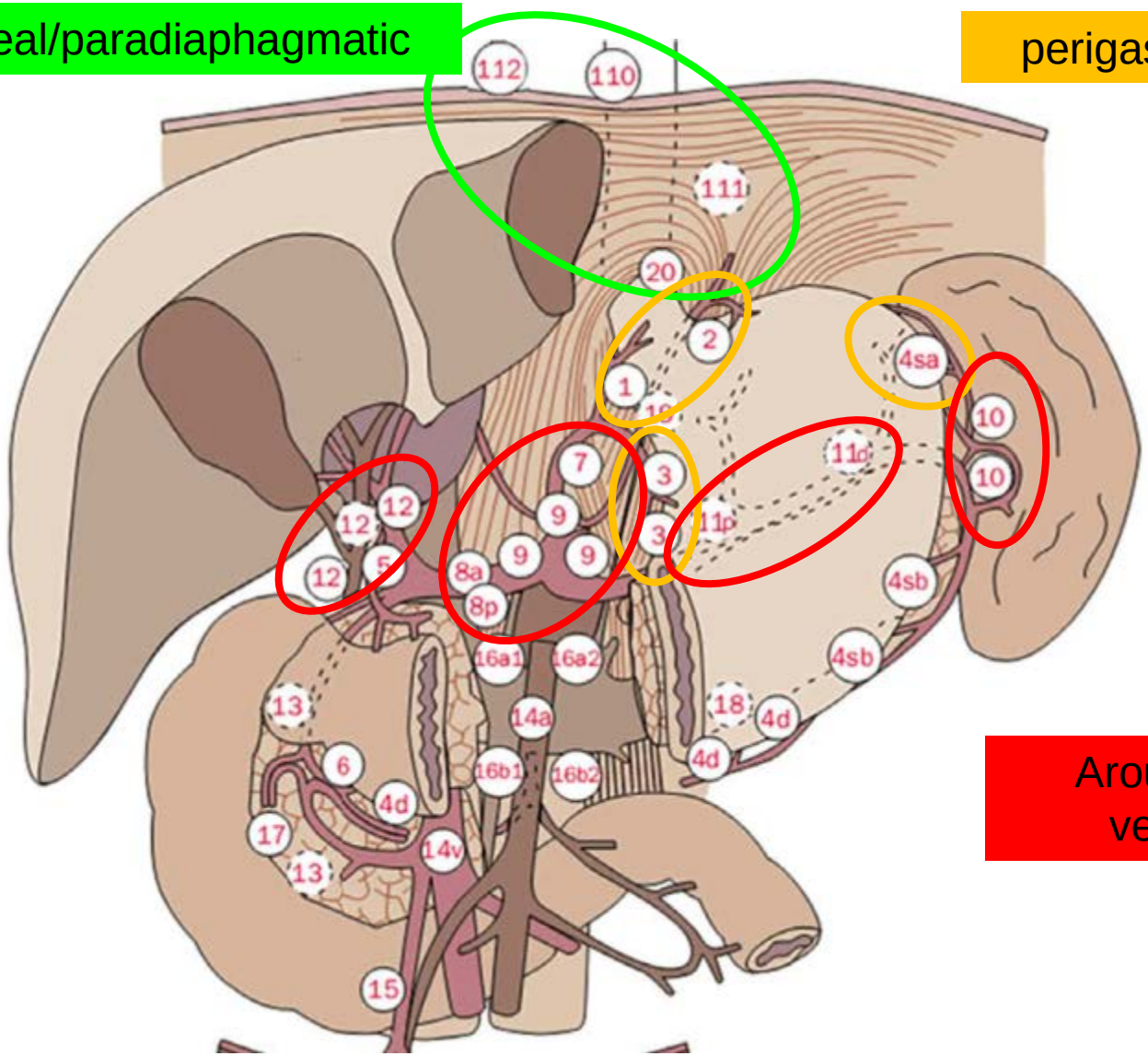

Around the vessels

Japanese Gastric Cancer Association Gastric Cancer - 2011

CTV elective: CT axial anatomy

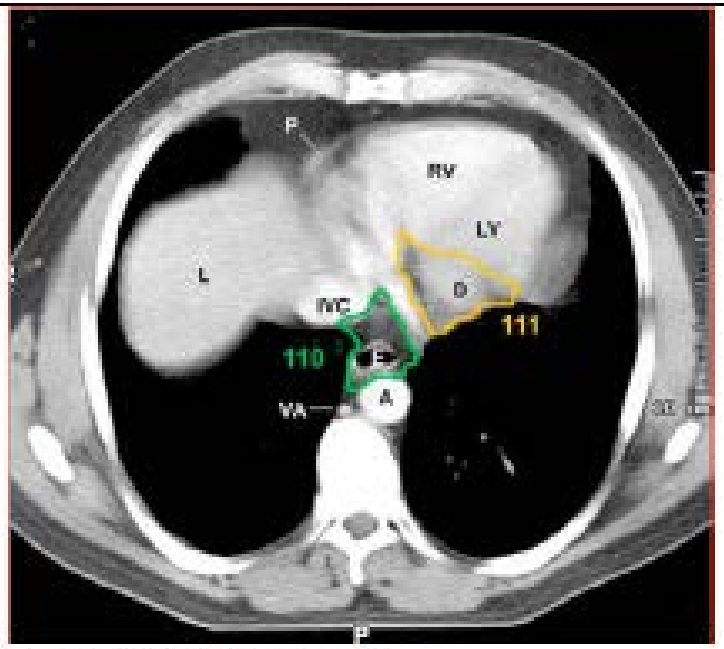

110 - Paraoesophageal LN
111 - Supradiaphragmatic LN

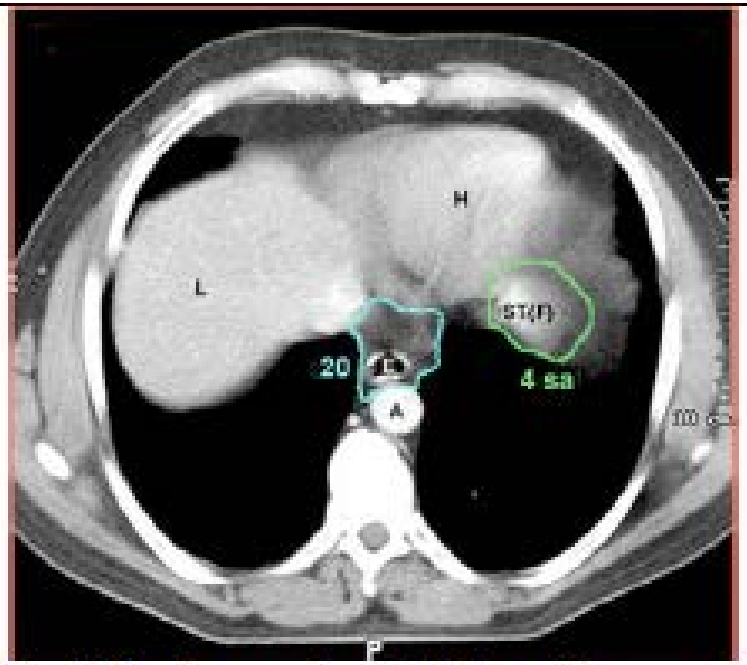

20 - LN in the oesophageal hiatus of the diaphragm
4sa - LN along the short gastric vessels

Matzinger O et al – Raadiother Oncol – 2009

CTV elective: CT axial anatomy

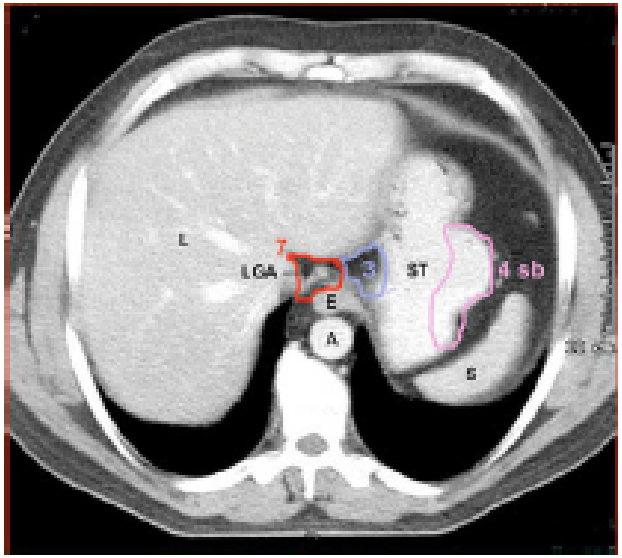

3 - LN along the lesser curvature
4sb - LN along the left gastroepiploic vessels
7 - LN along the left gastric artery

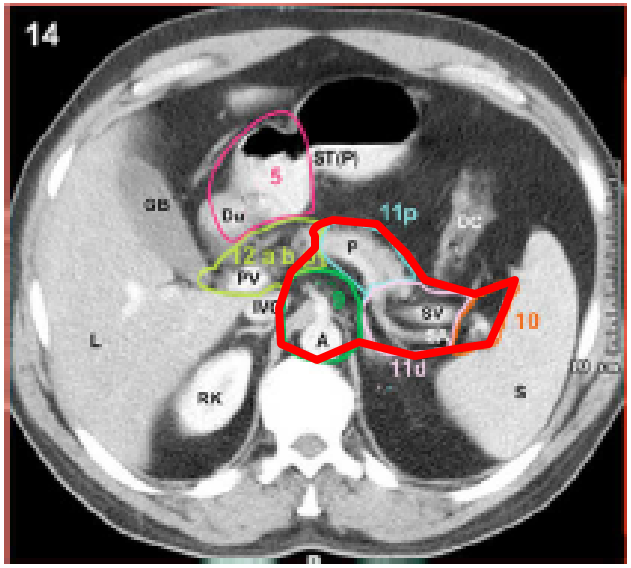

5 - Suprapyloric LN,
9 - LN around the celiac artery
10 - LN at the splenic hilum
11p - LN along the proximal splenic artery
11d - LN along the distal splenic artery
12 a, b, p - LN in the hepatoduodenal ligament

Matzinger O et al – Raadiother Oncol – 2009

GEJ: CTV elective; Type I

JGCA	
110 111 112	Para-esophageal Supra-diaphragmatic Posterior mediastinal
19	Infra-diaphragmatic
20	Esophageal iatus
1-2	R-L para-cardia
7	Left gastric Artery
9	Celiac axis

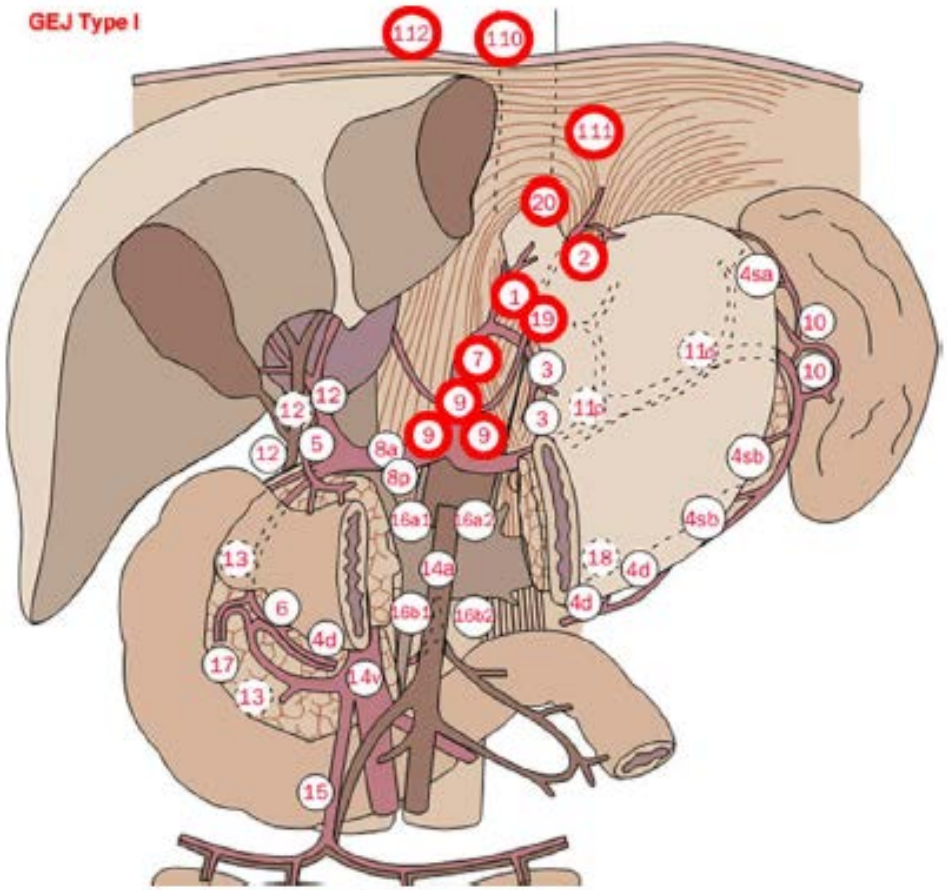

Matzinger O et al – Raadiother Oncol – 2009

GEJ: CTV elective; Type II

JGCA	
110 111	Para-esophageal Supra-diaphragmatic
112	Posterior mediastinal
19	Infra-diaphragmatic
20	Esophageal iatus
1-2	R-L para-cardia
3	Lesser curvature
4sa	Greater curvature (SGV) proximal
7	L gastric Artery
9	Celiac axis
11p	Splenic artery proximal

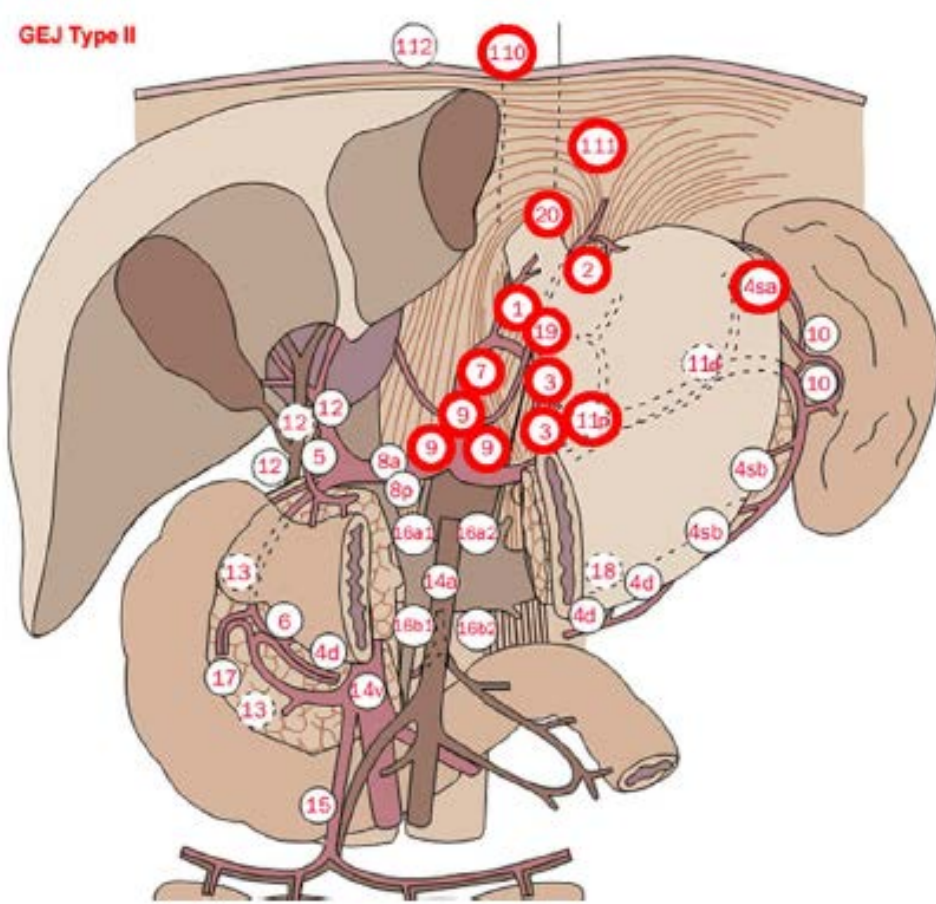

Matzinger O et al – Raadiother Oncol – 2009

GEJ: CTV elective; Type III

JGCA	
110 111	Para-esophageal Supra-diaphragmatic
112	Posterior mediastinal
19	Infra-diaphragmatic
20	Esophageal iatus
1-2	R-L para-cardia
3	Lesser curvature
4sa	Greater curvature (SGV) proximal
7	L gastric Artery
9	Celiac axis
11p	Splenic artery proximal
11 d	Splenic artery proximal
10	Splenic hilum

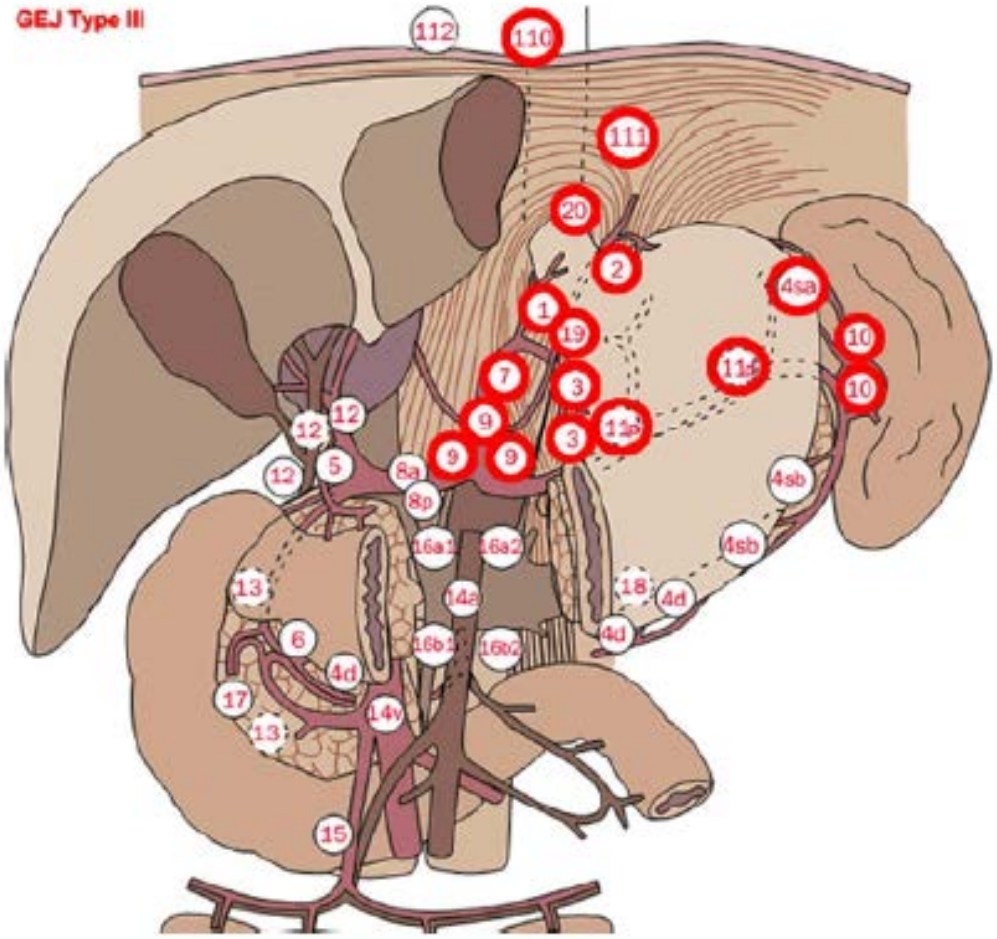

Matzinger O et al – Raadiother Oncol – 2009

OARs organization and delineation

model	organ	dosimetric parameters	delineation
		D max, Dvol	Partial volume
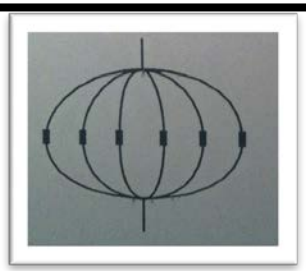	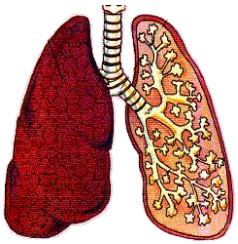	MD, Vd	Entire volume
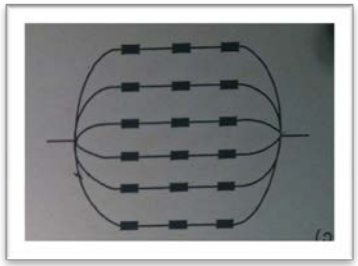		D max, Vd	Entire volume
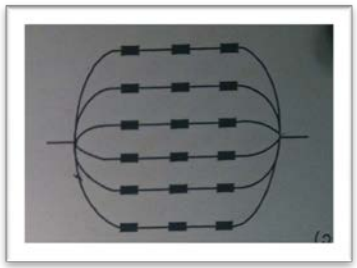	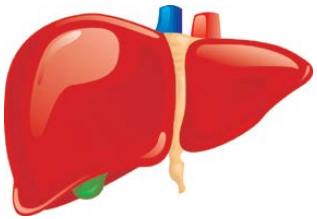	D max, Vd	Entire volume Partial volume

OARs constraints and delineation

organ	Toxicity	dosimetric parameters	delineation
	Myelopathy	Dmax < 45 Gy Dmax < 40Gy (when conc CT)	2 cm above and belove the CTV
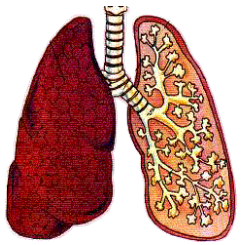	Post-op Pneumonitis ARDS	V10Gy < 40% V15 Gy < 30% V20 Gy < 40% V5 Gy < 2300 cc	Both lungs
	Pericardium Myocardium Coronary reduction EF	V25 Gy< 50% V40 Gy < 30%	Entire heart
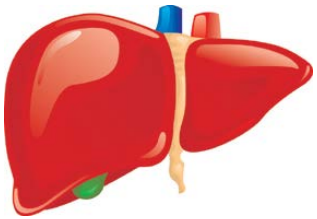	Radiation Induced Liver Disease	V30 Gy < 30%	Entire liver

QUANTEC– IJROBP- 2010

OARs delineation variability

OAR delineation variability

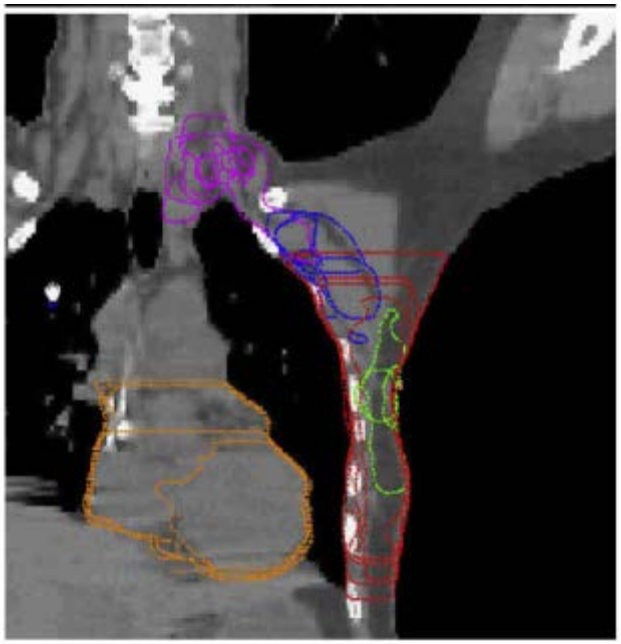

Dose **reported** to OAR

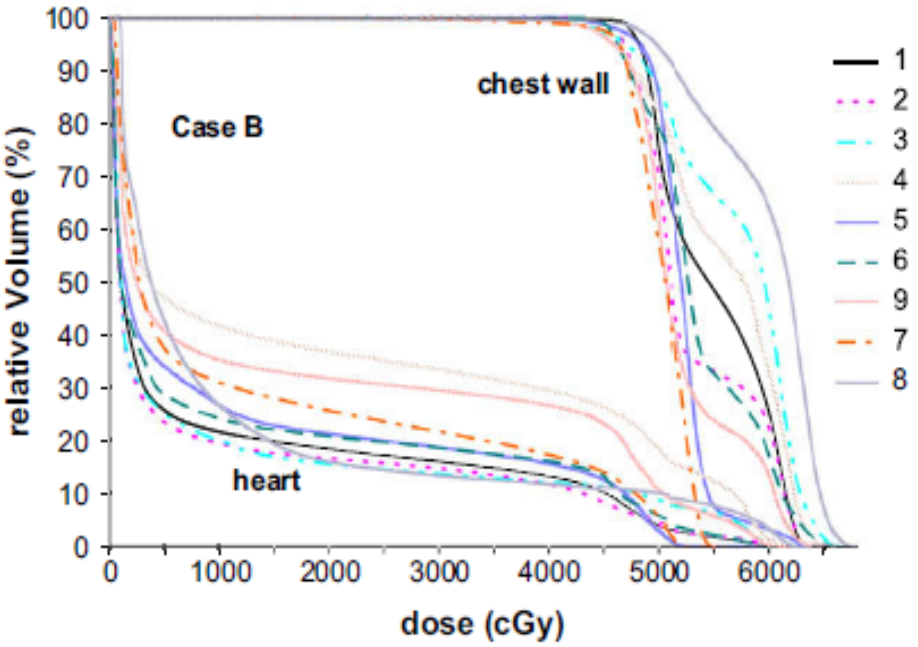

Li XA et al. – IJROBP- 2009

OARs not preventable toxicities

Esophagus:
Is the target!!
stenosis at the level of the previuos tumor

DYSPHAGIA: 16%

Thyroid:
in cervical and upper esophagus
entire prescribed dose

HYPOTHIROIDISM: 36%
Dose > 30Gy

Fujiwara M et al. – J Rad Res- 2015

GTV and CTV for gastric cancer – Delineation of Organ at risk

M.A. Gambacorta

Università Cattolica del Sacro Cuore
Rome

Policlinico Agostino Gemelli
Università Cattolica del Sacro Cuore

GemelliART
Advanced Radiation Therapy

Target Volume Definition

- Evidences
- Areas at risk
- CTV definition

Evidences:
Surgical treatment

Radical surgery "R0": definition

T: Total Gastrectomy or Partial Gastrectomy distance of (clear) surgical margin from the **T**: **4+ cm**

N: **lymphadenectomy** extend to the next **N-** level over the last posive nodes (e.g. **D1 if N0, D2 if N1**)

Japanese Gastric Cancer Association Gastric Cancer - 2011

Evidences: Surgical nodes dissection

Type of dissection	Nodal group		Station Number
D1	N1	Paracardia	1 – 2
		Lesser/Greater Curvature	3 – 4
		Suprapyloric	5
		Infrapyloric	6
D2	N2	Left Gastric Artery	7
		Common Epatic Artery	8
		Celiac Axis	9
		Splenic Artery/Hilum	10 – 11
		Hepatoduodenal Ligamentum	12
D3	N3	Others (distant nodes)	13 – 16

Japanese Gastric Cancer Association Gastric Cancer - 2011

Evidences: Sites of Recurrence

Locoregional

Peritoneal seeding

Distant Metastases

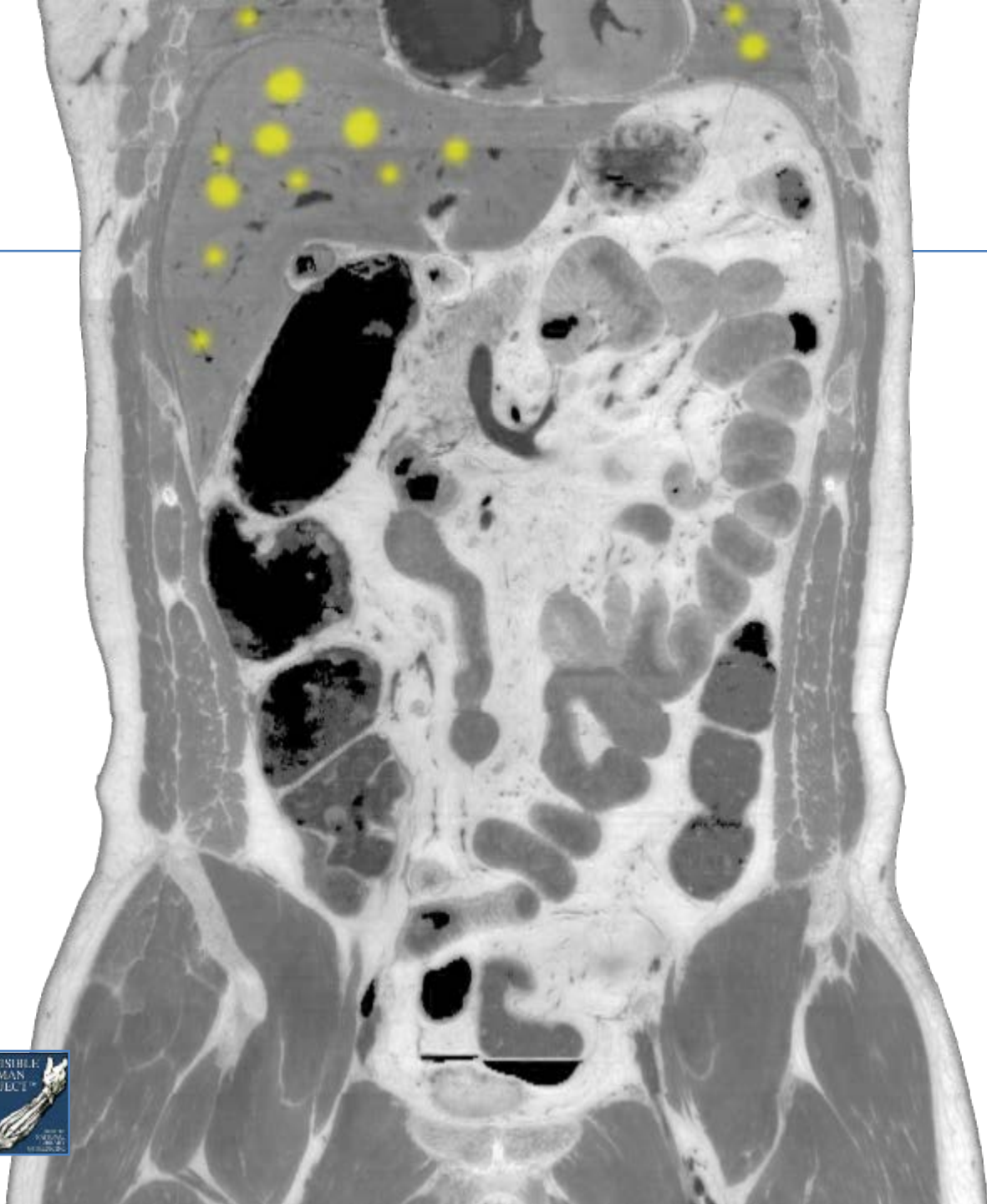

Evidences: Sites of Recurrence

Site of recurrence	Only failure	Any component
Locoregional	23%	69%
Peritoneal seeding	21%	42%
Distant metastases	5%	23%

Gunderson LL Sosin H – IJROBP - 1982

Evidences:
INT-0116 Overall Survival

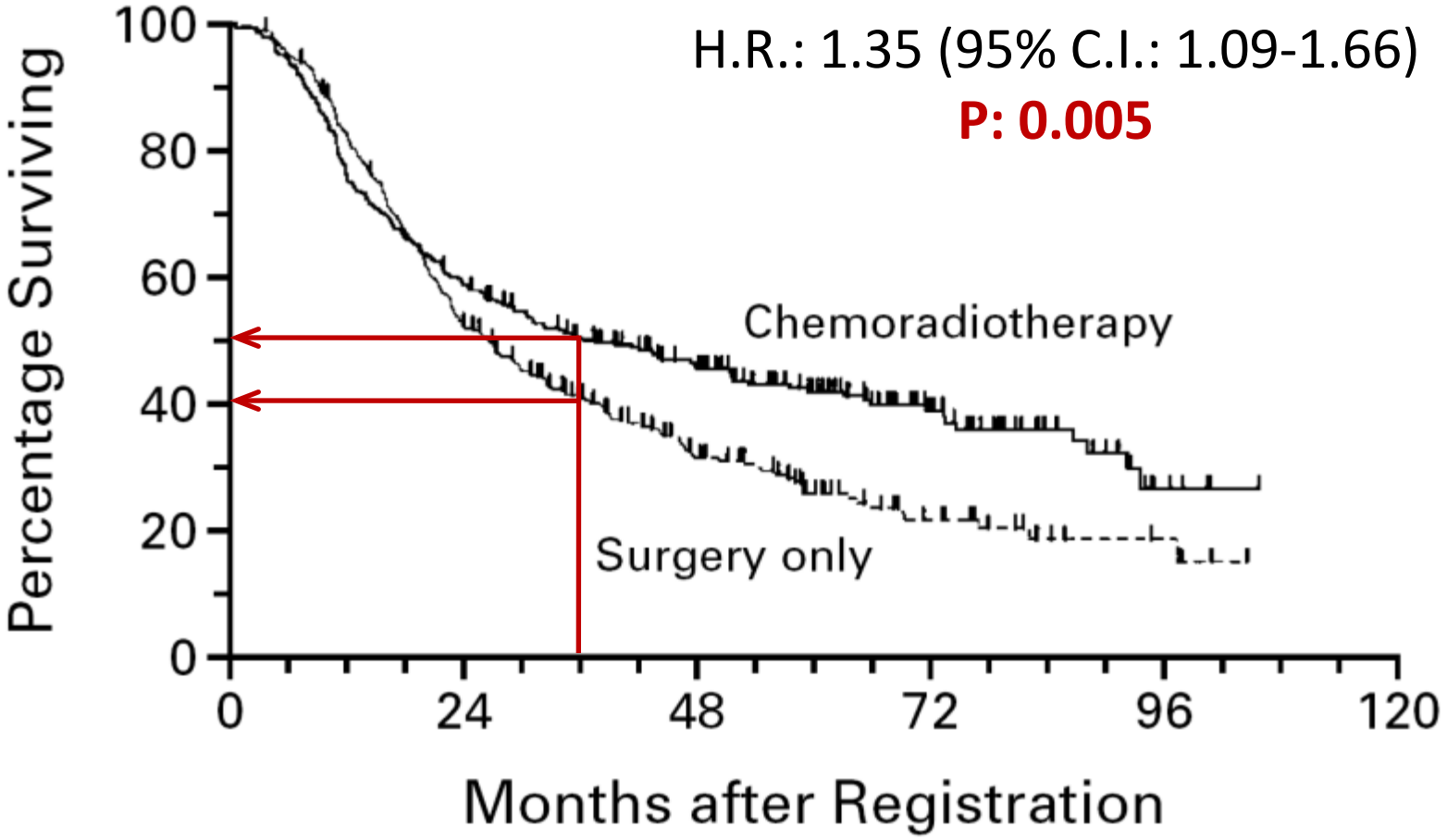

Mcdonald JS et Al – New England Journal of Medicine - 2001

Evidences:
INT-0116 Surgical Quality Review

D2 Lymphnode dissection was recommended

D0: 54%

Incomplete resection of perigastric nodes

D1: 36%

Complete resection of perigastric nodes

D2: 10%

Extended resection of vascular nodes

D0 vs D2

No significant difference in survival by Cox multivariate analysis

RTCHEM

All subgroups had a survival benefit

Mcdonald JS et Al – New England Journal of Medicine – 2001

B. Minsky – personal communication – 2005

Treatment Guidelines

Stage I	Surgery if T2 or N1 postop. Chemoradiation Chemorad before surg in clinical trial
Stage II	Surgery + postop. Chemoradiation (1) + periop. Chemotherapy(2) Chemorad before surg in clinical trial
Stage III	Surgery (if no extensive nodal involvement) + postop. Chemoradiation (1) + periop. Chemotherapy (2) Chemorad before surg in clinical trial
Stage IV M-	Surgery (if no extensive nodal involvement) + postop. Chemoradiation (1) + periop. Chemotherapy (2)
Stage IV M+	Chemotherapy

(1) *Mcdonald JS et Al – New Engl J Med – 2001*

(2) *Cunningham D et Al – New Engl J Med – 2006*

Evidences:
Why preoperative treatments?

…in approximately ***50%***
of newly diagnosed cases,
the tumour is beyond its
local-regional margins…

Ajani JA et AL – JCO – 2005

Evidences:
Why preoperative treatments?

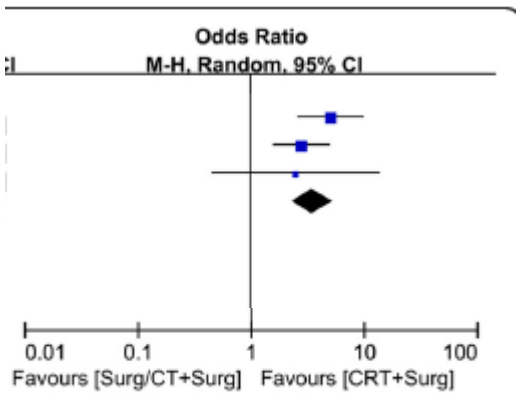

R0 resection

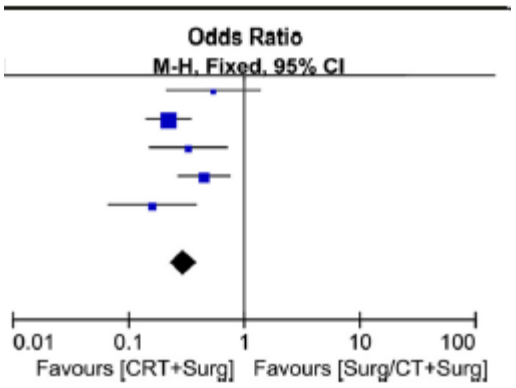

Nodal metastases

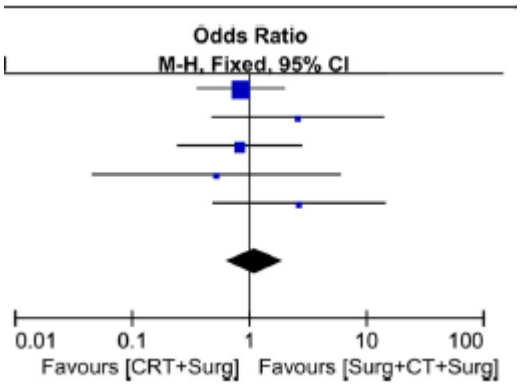

Perioperative mortality

Metanalysis of 7 RCTs: 869 adenoca pts

Fu T et AL – BMC Cancer – 2015

Evidences: compliance

	Macdonald 281 pts	Korean 544 pts	UCSC 43 pts
RT-CT compl	64.0%	75.0%	91.0%
G3 Ac Tox	41.0%	23.5%	18.6%
G4 Ac Tox	32.0%	6.0%	-

Mcdonald JS et Al – New Engl J Med – 2001

Kim S et Al – IJROBP – 2005

Evidences: compliance, RT targeting

INT-0116

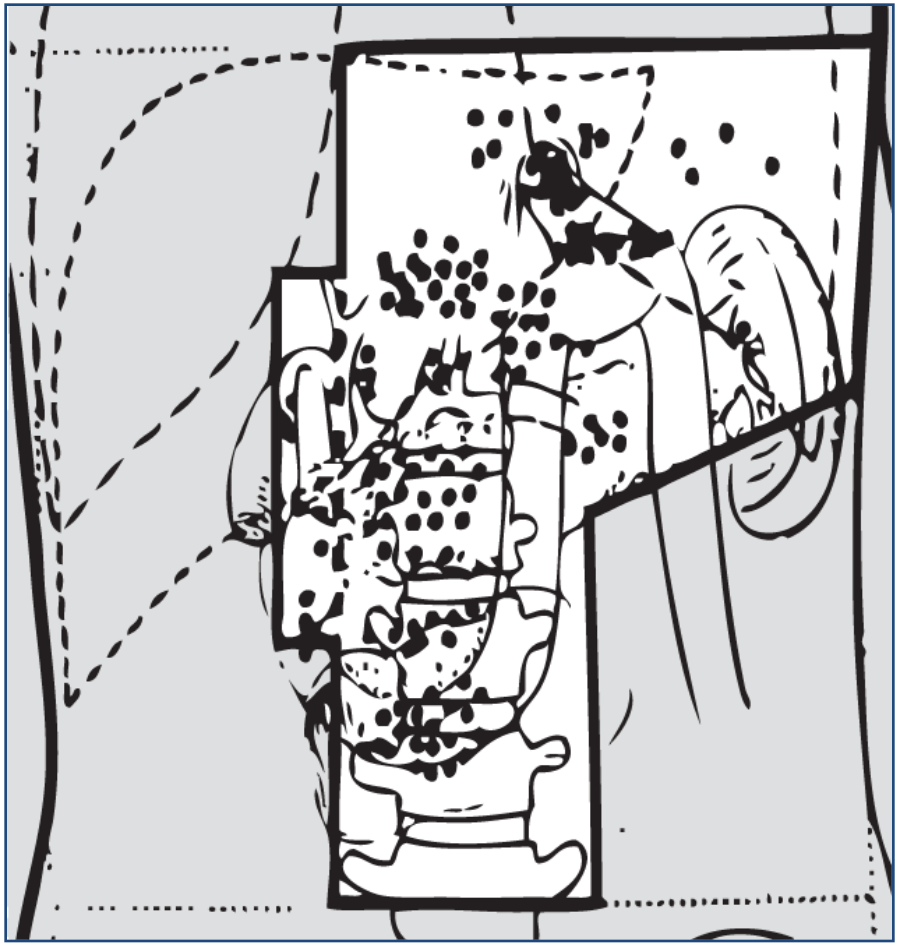

Korean

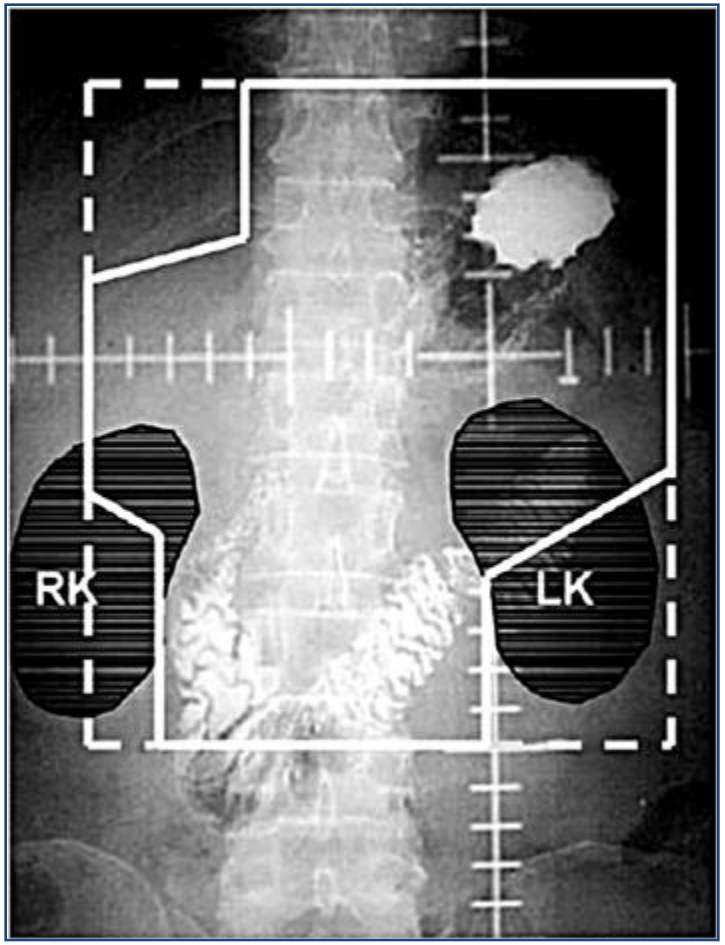

Mcdonald JS et Al – New Engl J Med – 2001

Kim S et Al – IJROBP – 2005

Evidences: compliance, RT targeting

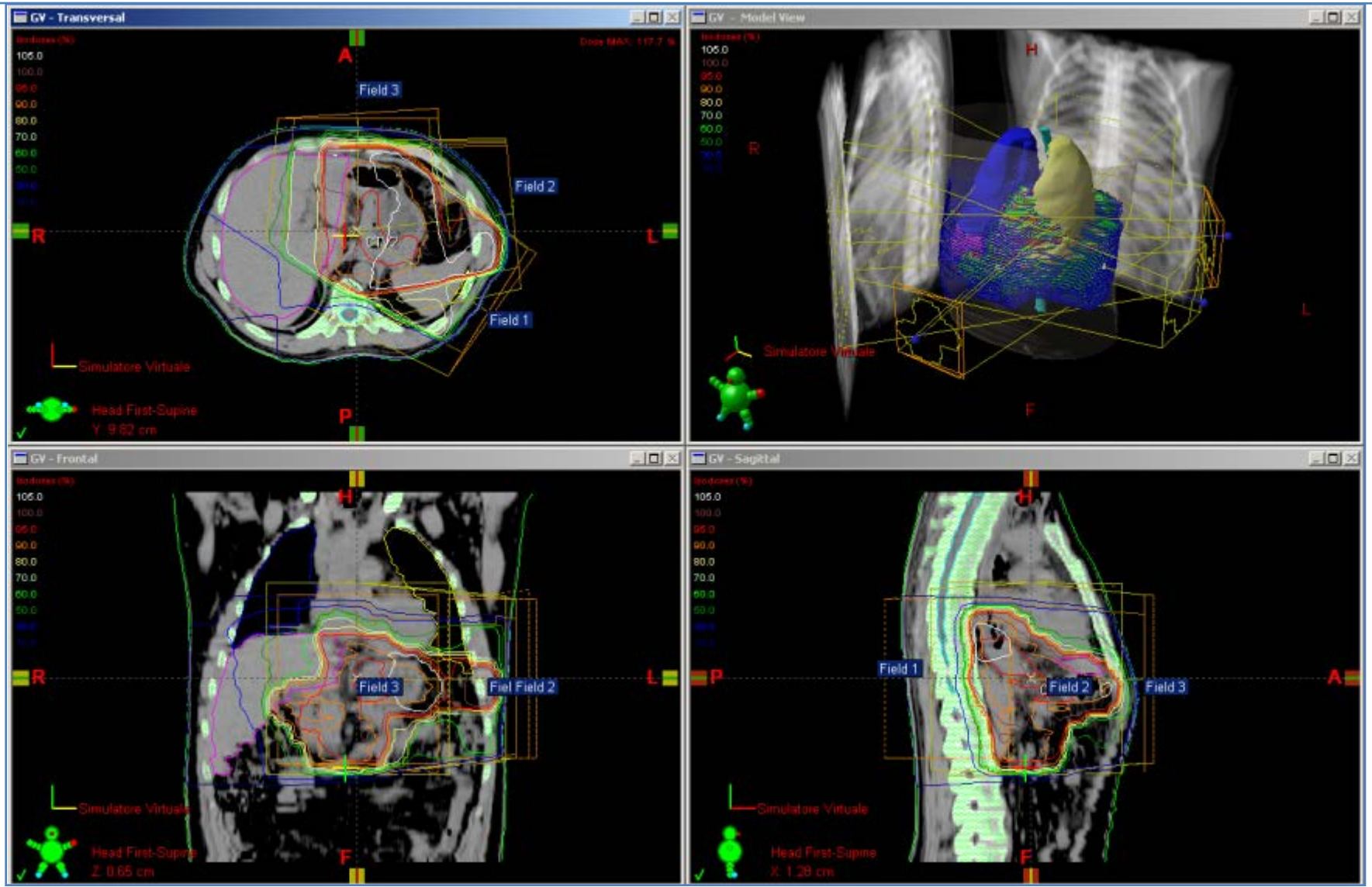

Target Volume Definition

- Backgroung
- Areas at risk
- CTV definition

Areas at risk

- Tumor bed/remnant
- Anastomosis & Stump

POST-OP

- T & N: GTV and CTV
- Gastric CTV

PRE-OP

- Elective nodes

PRE/POST-OP

Areas at risk

- **Tumor bed/remnant**
- Anastomosis & Stump

POST-OP

- T & N: GTV and CTV
- Gastric CTV

PRE-OP

- Elective nodes

PRE/POST-OP

Areas at risk post-op: Tumor bed/remnant

1. **Gastric remnant:** always treat when **Partial Gastrectomy**
2. **T1-2 tumors**: tumor bed **not necessarily**
3. **T3-T4 tumors:** involvement, adherence, clips (usually covered in Nodal CTV)
4. **Anterior abdominal wall:** only in **T3-4 tumors** with **invasion** or a close relationship with the anterior abdominal wall on pre-operative imaging or when described by the surgeon *durante operatione*
5. **Proximal tumors:** *at least* 2/3-3/4 of the **left medial hemidiaphragm**
6. **Hepatogastric ligament:** (i.e. part of lesser omentum between liver and lesser curvature, which contains peri-gastric nodes)

Areas at Risk post-op: Tumor bed

Areas at Risk post-op: Tumor bed

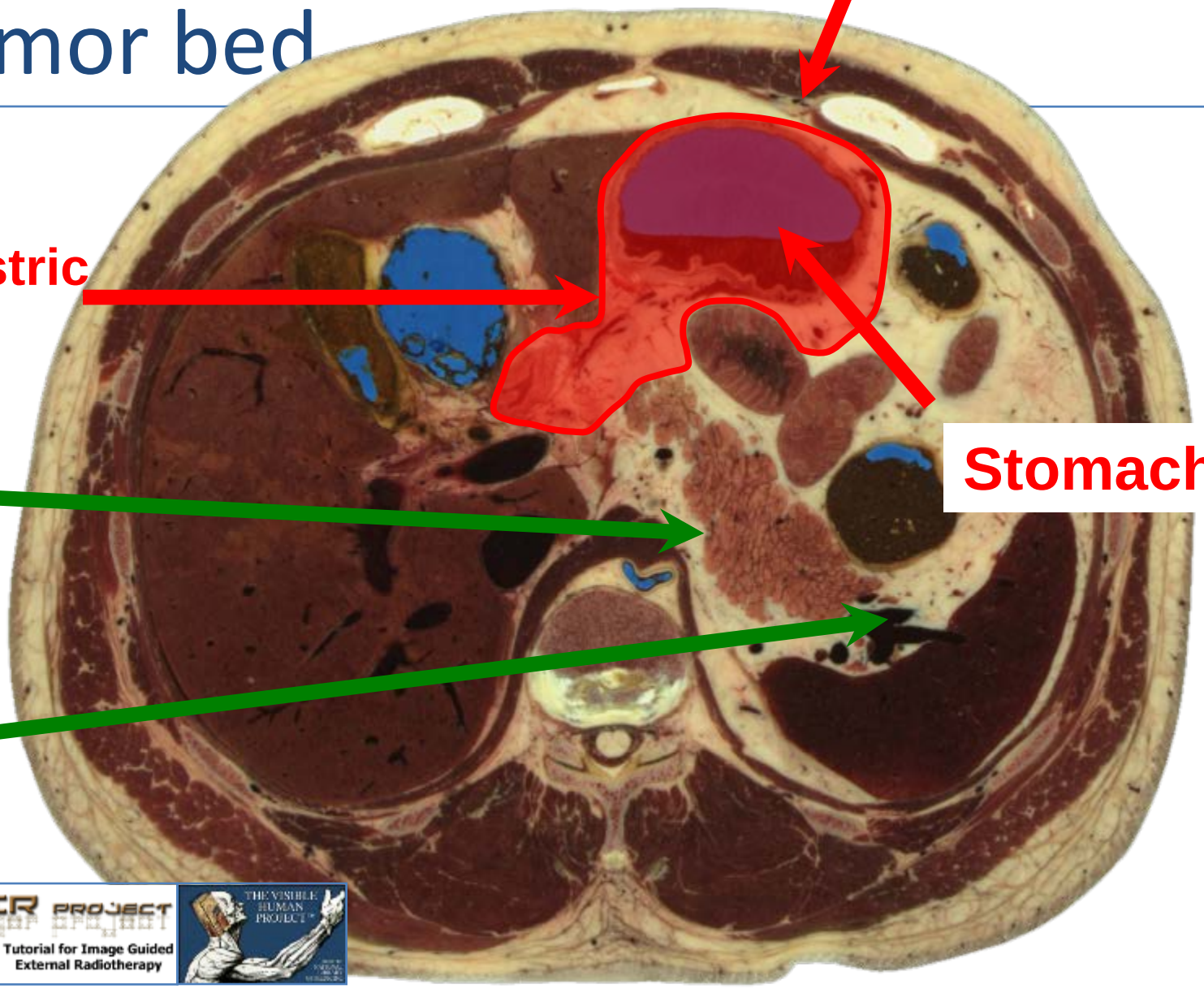

TIGER PROJECT
Tutorial for Image Guided External Radiotherapy
THE VISIBLE HUMAN PROJECT

Areas at risk post-op

- Tumor bed/remnant
- **Anastomosis & Stump**

POST-OP

- T & N: GTV and CTV
- Gastric CTV

PRE-OP

- Elective nodes

PRE/POST-OP

Areas at Risk post-op: Anastomosis & Stump

1. **Anastomosis**

Esophago-jejunal has to be included in **proximal 3rd tumors**

2. **Duodenal stump:**

YES! in distal 3rd tumors

search the staples on CT!!

Esophago-jejunal: proximal tumor, total gastrectomy, Roux en Y

Gastro-jejunal: distal tumor, partial gastrectomy

Gastro-duodenal: middle tumor, partial gastrectomy

Gastro-esophageal: proximal tumor, partial gastrectomy

Area at Risk post-op: Anastomosis

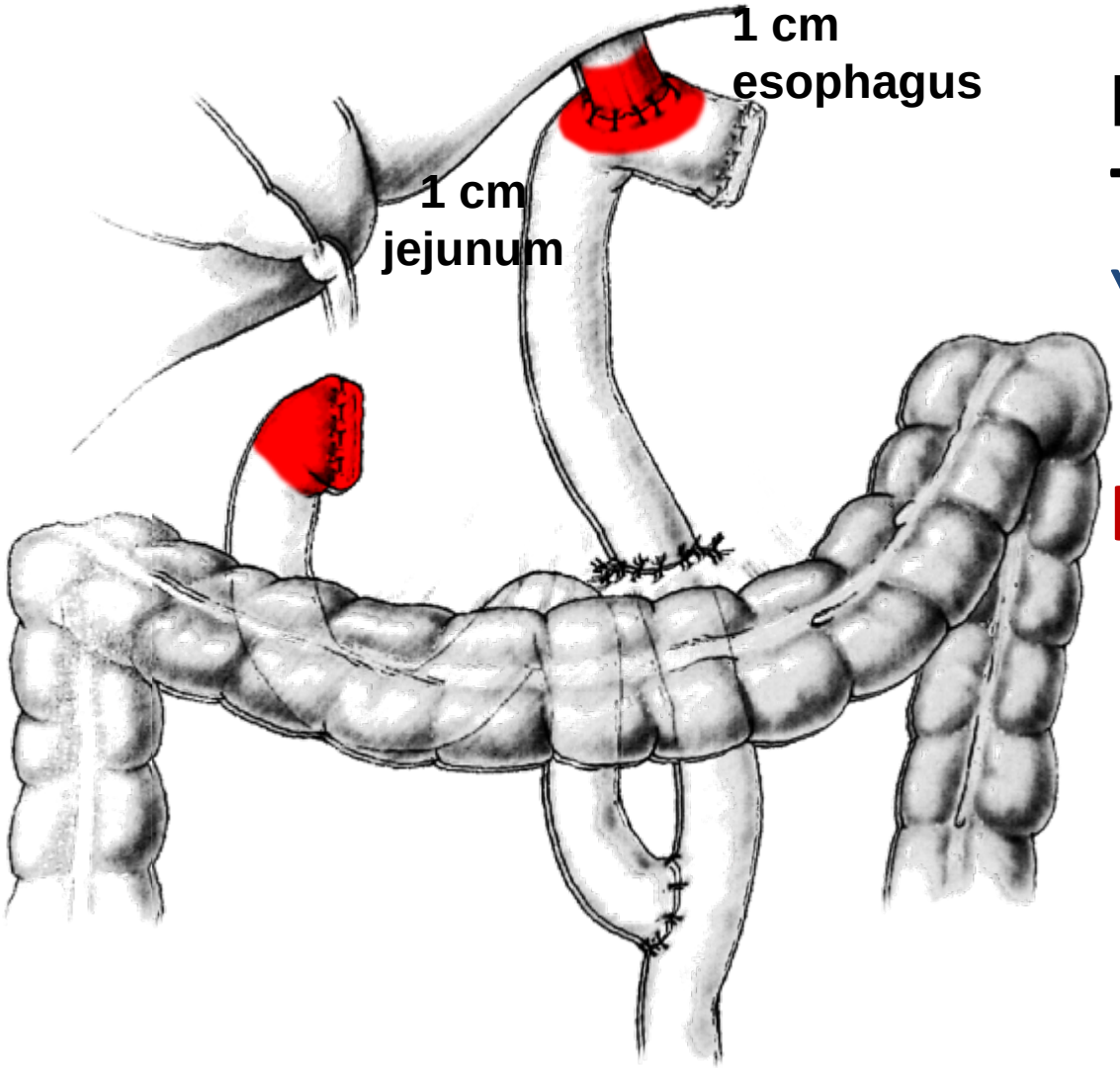

Esophago-jejunal
Total gastrectomy
Y sec Roux

proximal tumor

Area at Risk: Anastomosis & Stump

Y sec Roux

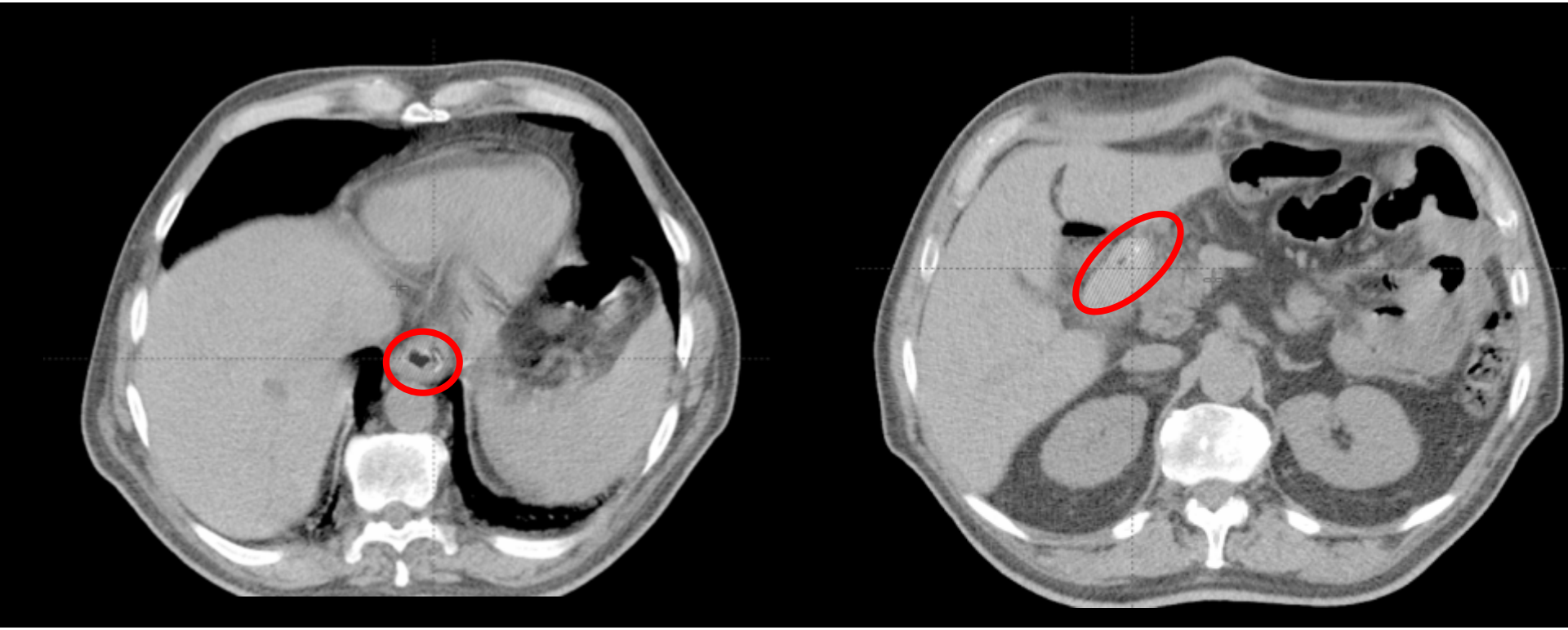

Anastomosis

Stump

Area at Risk post-op: Duodenal Stump

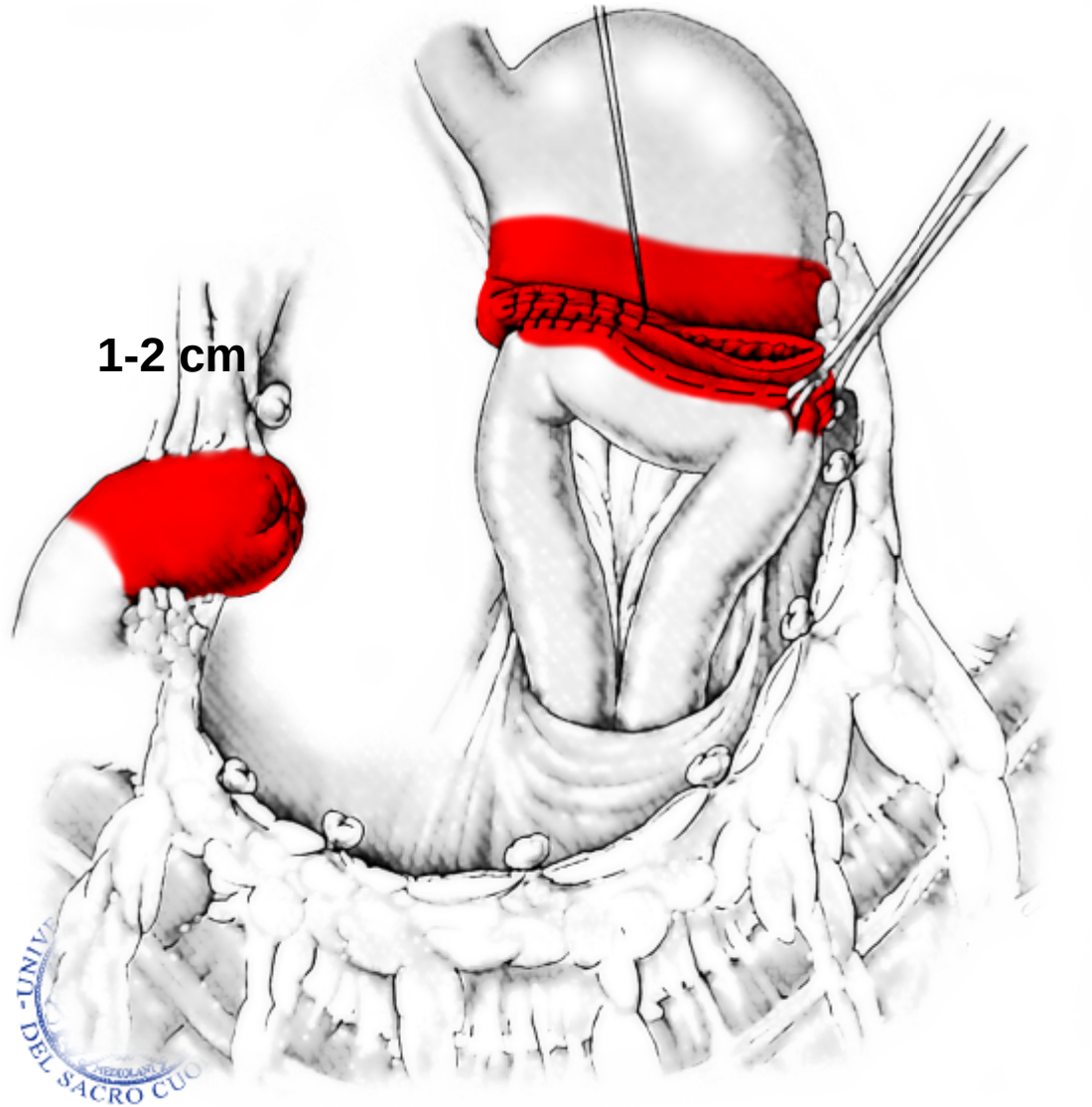

Gastro-jejunal

Partial gastrectomy:

Billroth II

Distal tumor

Area at Risk post-op: Anastomosis & Stump

Billroth II

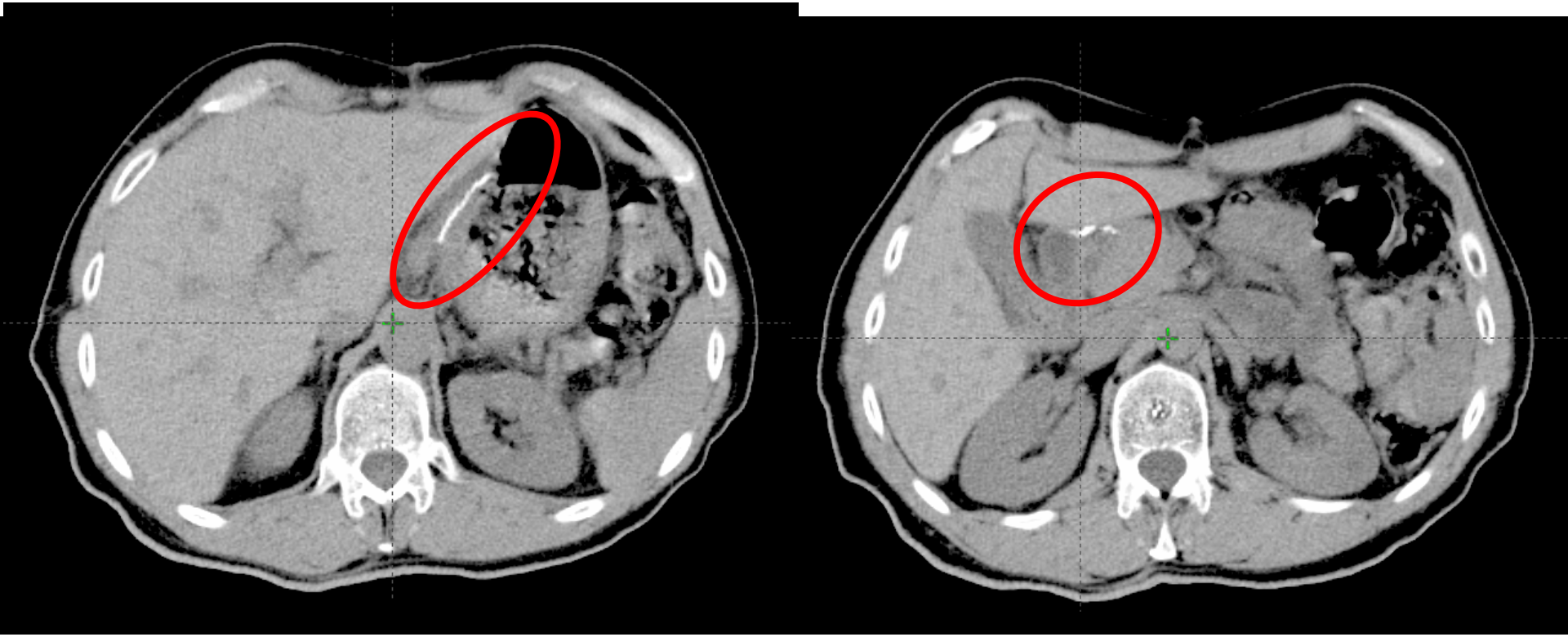

Anastomosis

Stump

Target volume definition: pre-op

- Tumor bed/remnant
- Anastomosis & Stump

POST-OP

- **T & N: GTV and CTV**
- **Gastric CTV**

PRE-OP

- Elective nodes

Matzinger O et al – Raadiother Oncol – 2009

Target volume definition: pre-op

- **ONLY ONE VOLUME**
  should be considered throughout radiotherapy

- **NO CONE-DOWN or BOOST volume**

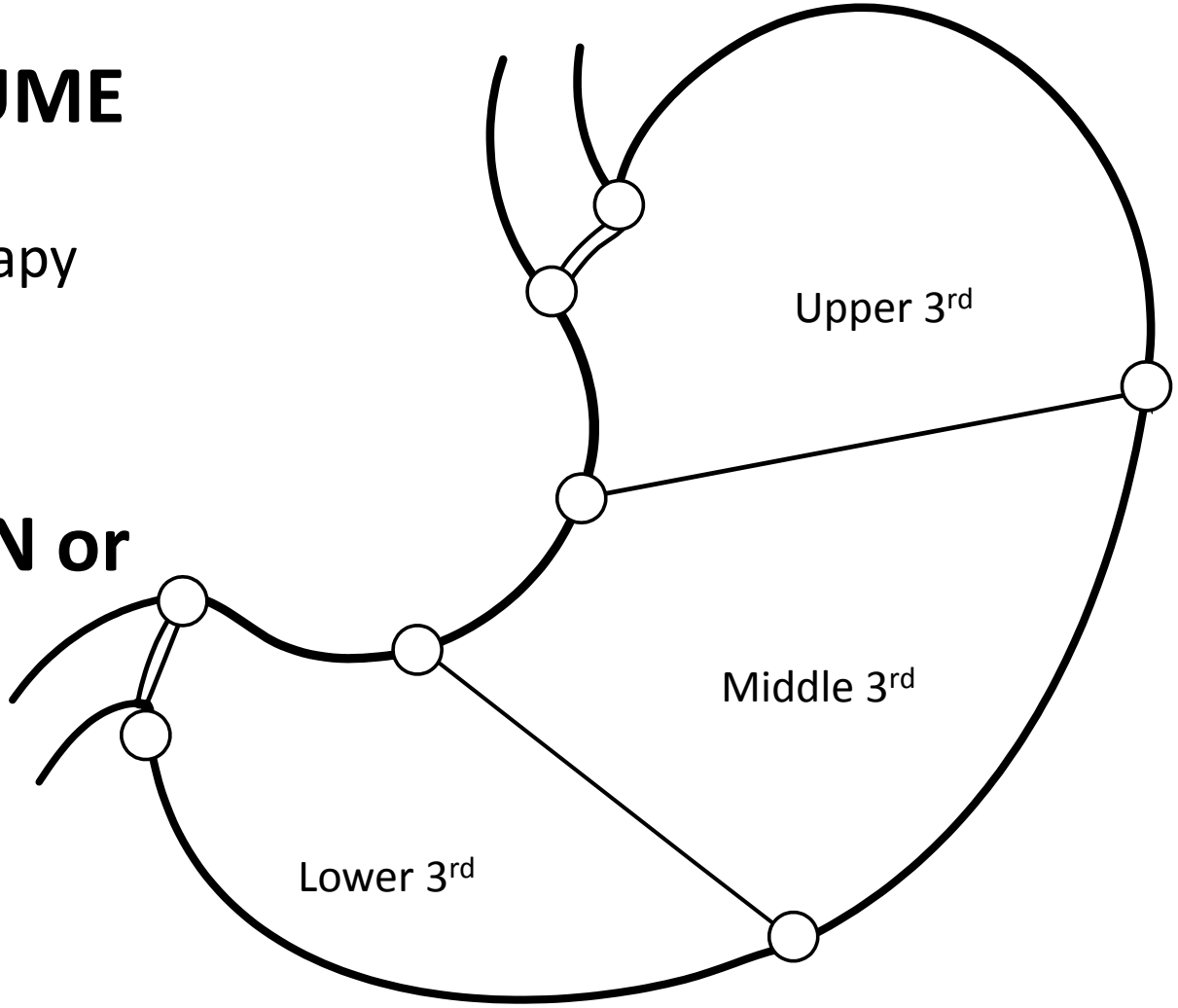

Matzinger O et al – Raadiother Oncol – 2009

Target volume definition: pre-op

- **Tumor:**
  - **GTV**: primary – perigastric tissue
  - **CTV** = GTV + **1.5 cm**
- **Nodal:**
  - **GTV:** positive nodes
  - **CTV**: GTV + **0.5 cm**

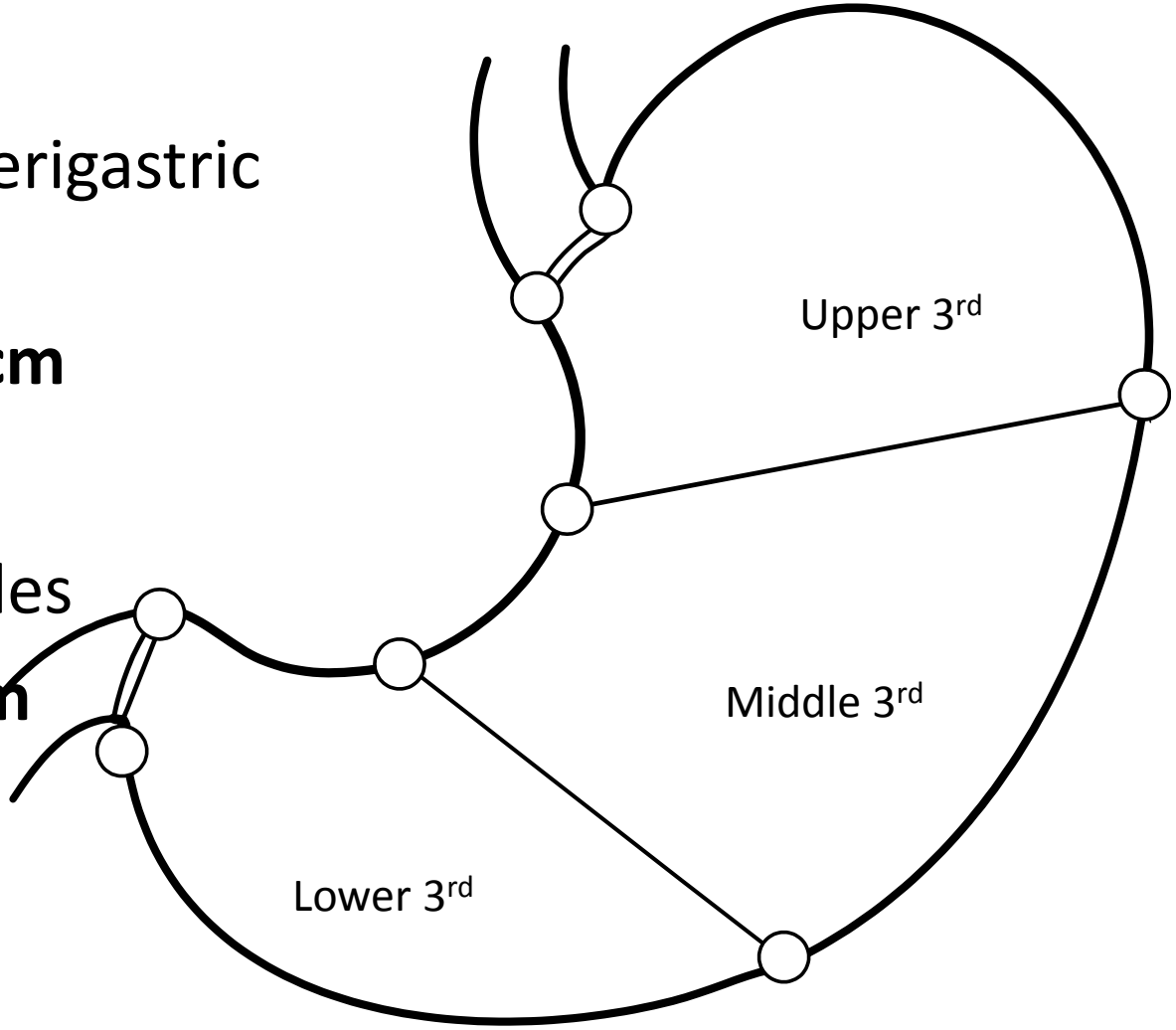

Matzinger O et al – Raadiother Oncol – 2009

Target volume definition: pre-op

CTV gastric:

- **Upper 3rd:** exclusion of antrum and pylorus
- **Middle 3rd**: entire stomach
- **Lower 3rd:** exclusion of cardia and fundus

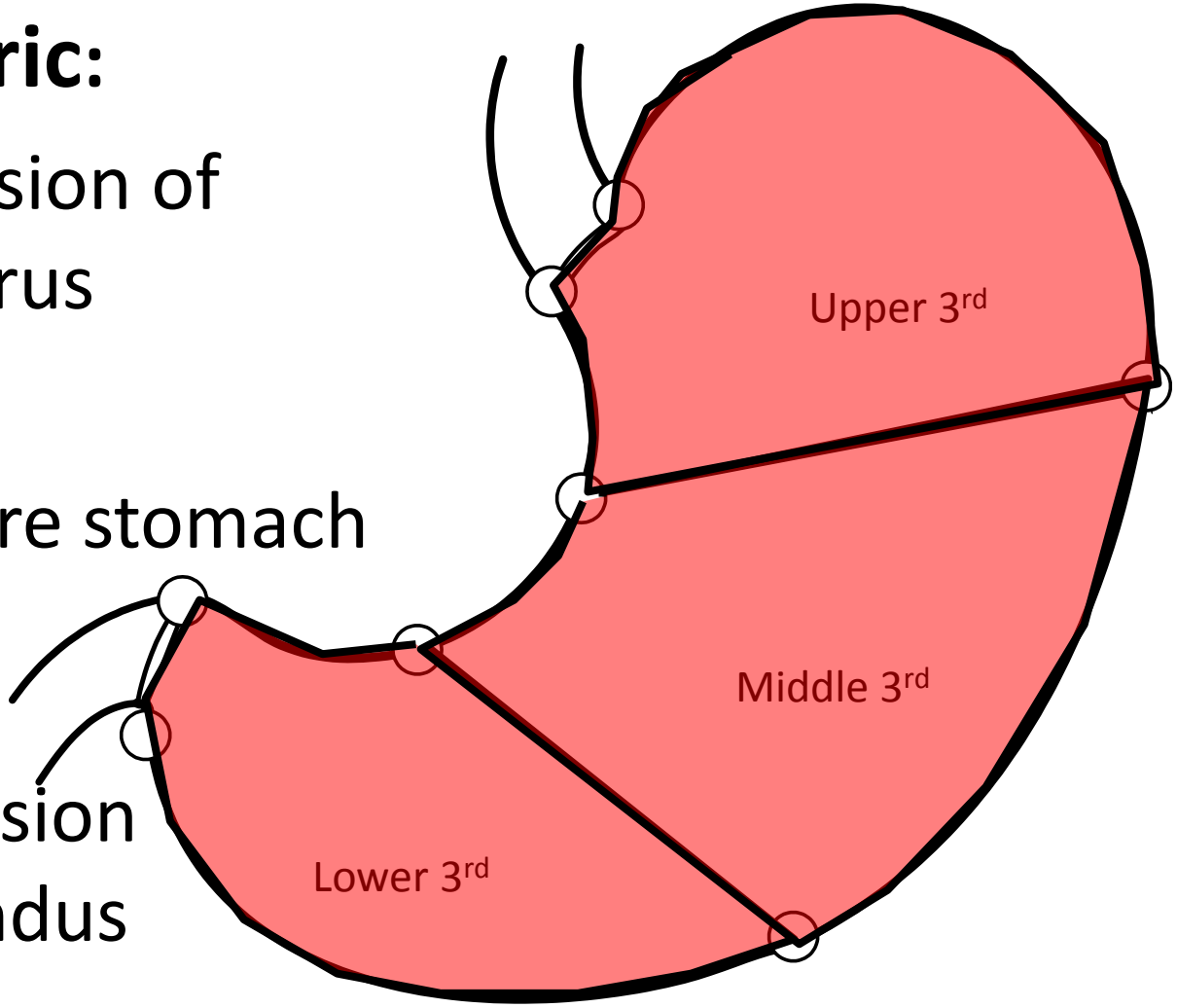

Matzinger O et al – Raadiother Oncol – 2009

Area at Risk pre/post-op: Elective Nodes

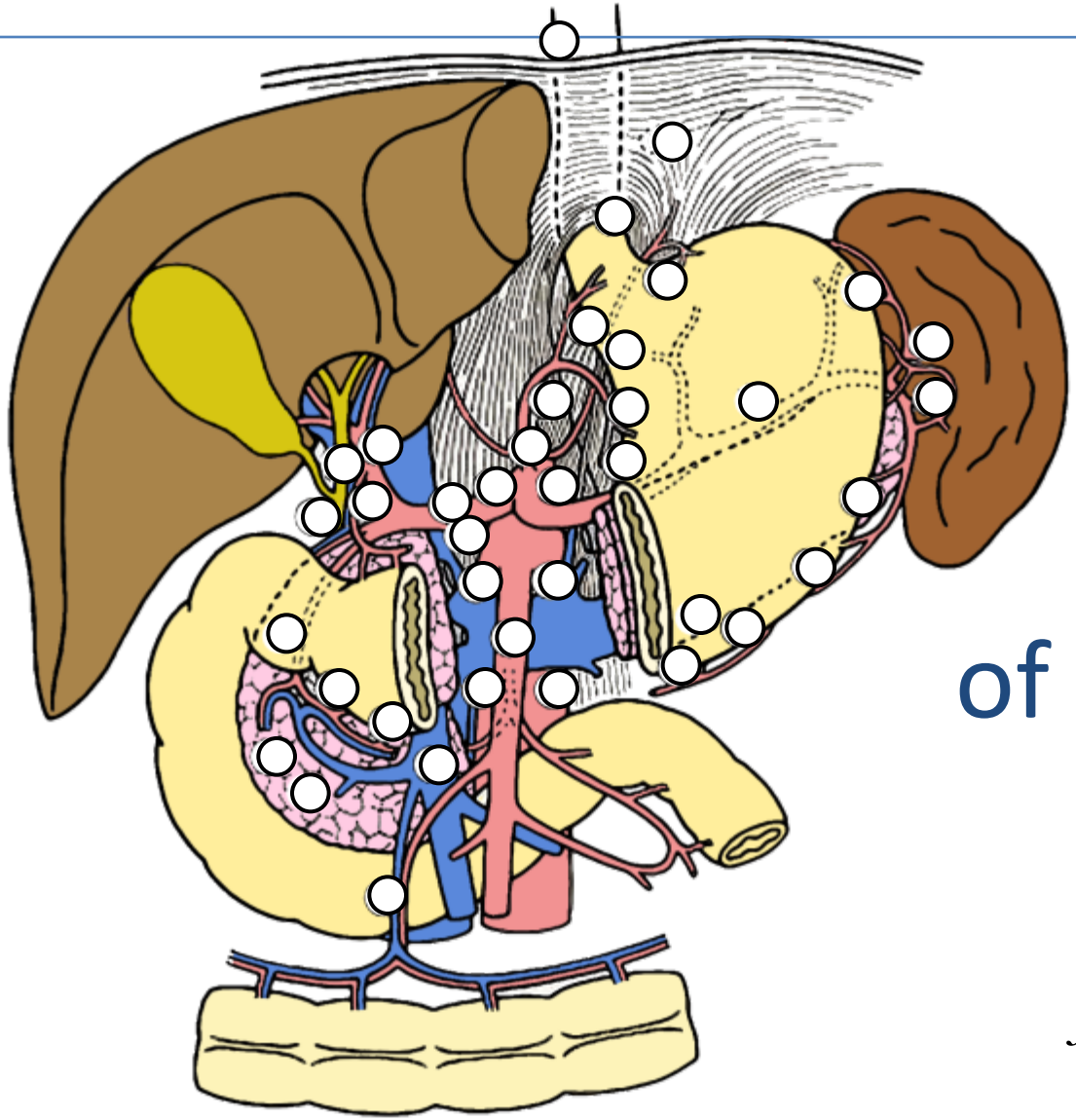

85%!!!

of N+ for all stages

Japanese Gastric Cancer Association
Gastric Cancer - 2011

Area at Risk pre/post-op: Elective Nodes

Martinez-Monge, R. et al. Radiology *1999;211:815-828*

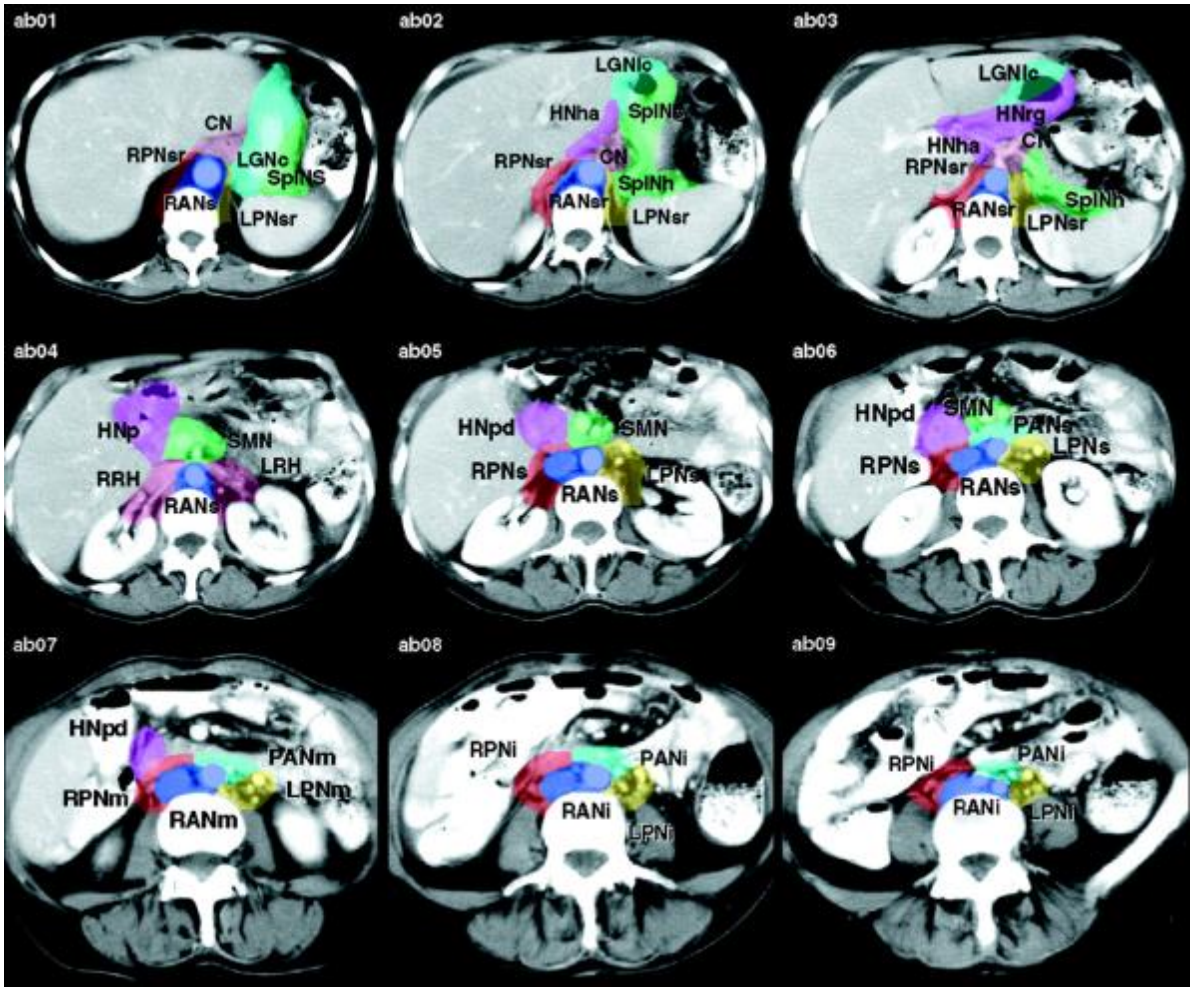

Areas at Risk: Elective Nodes

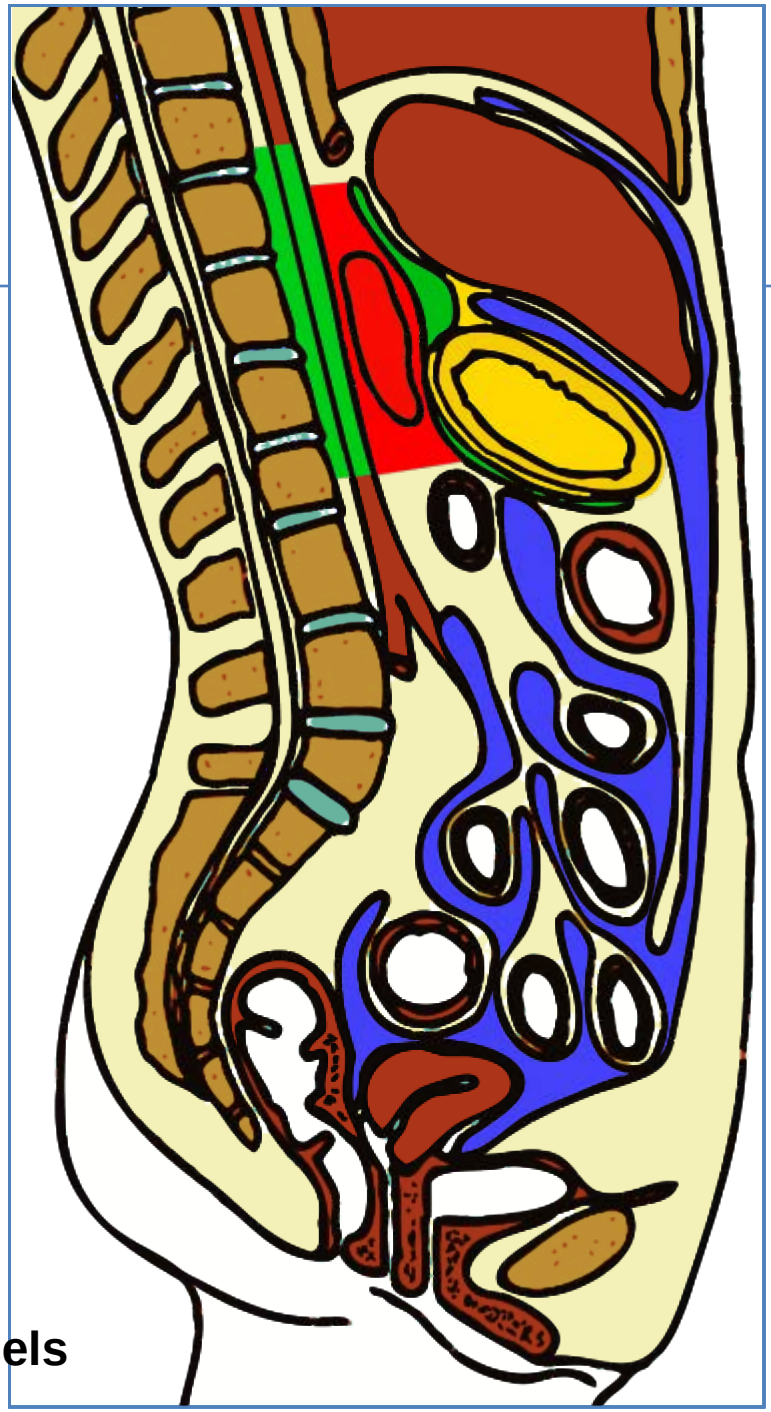

Gastric level

Pancreatic level

Vascular level

0.5 – 1 cm margin around the vessels

Gastric level (1 – 6)

JGCA Classification	Martinez-Monge classification
1. Right paracardia 2. Left paracardia	LGNc juxtacardiac
3. LN along lesser curvature 4. LN along greater curvature	LGNlc lesser curvature SPlNs Splenic Nodes HNrg Right gastroepiploic
5. Suprapyloric 6. Infrapyloric	HNp suprapyloric HNp infrapyloric

0.5 – 1 cm margin around the vessels

Gastric level (1 – 6)

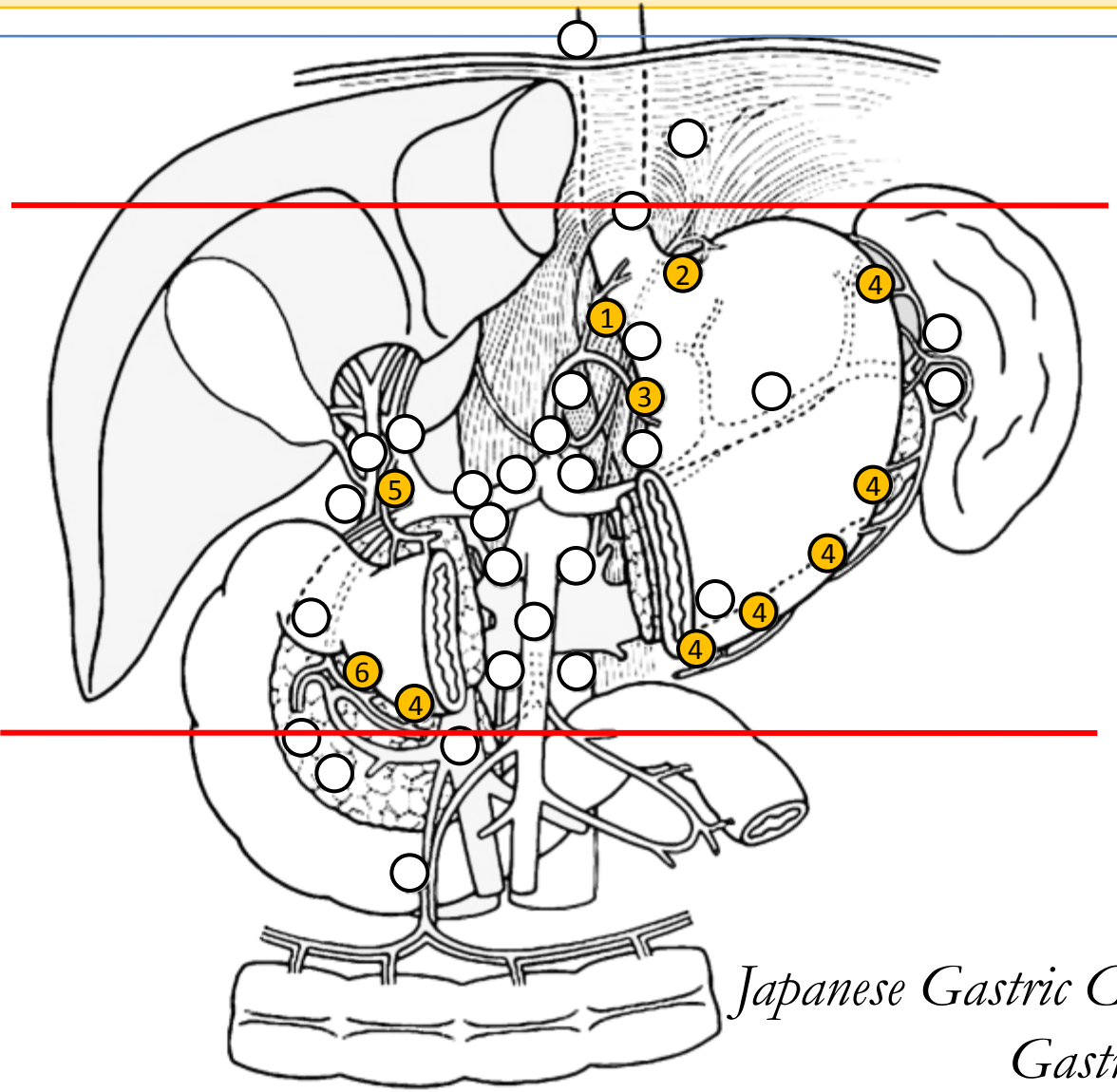

Japanese Gastric Cancer Association
Gastric Cancer - 1998

Gastric level (1 – 6): axial anatomy

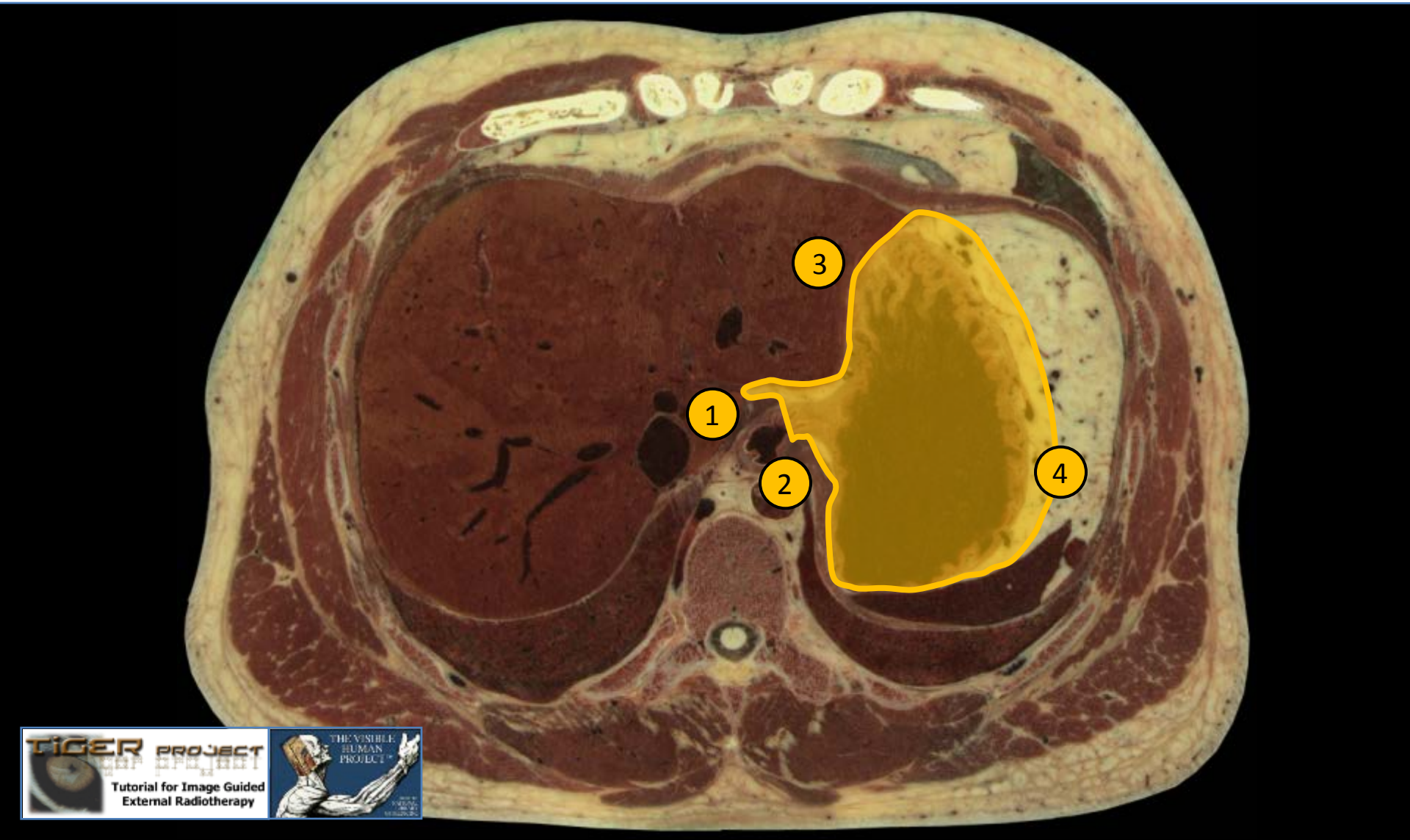

Gastric level (1 – 6): axial anatomy

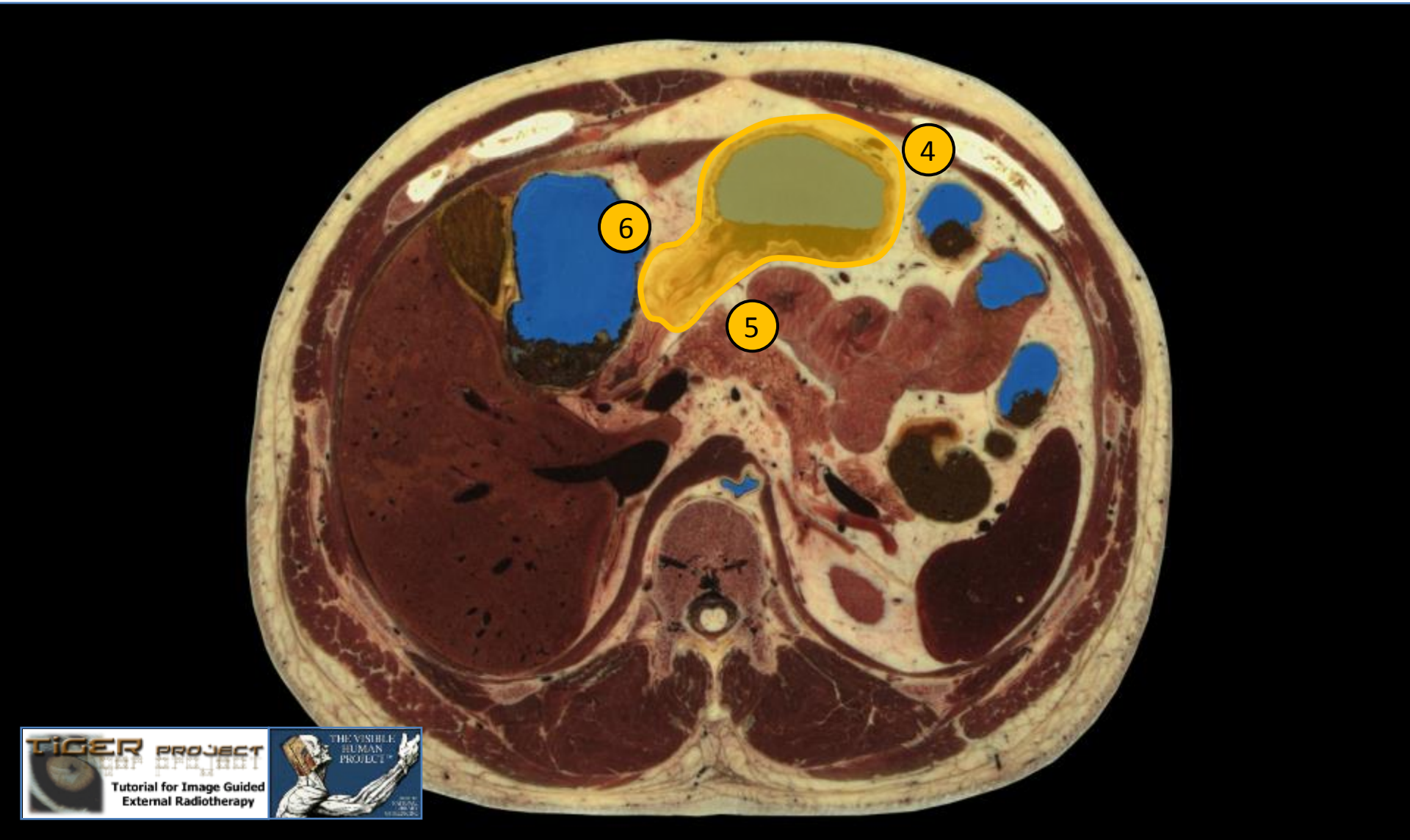

TIGER PROJECT
Tutorial for Image Guided External Radiotherapy
THE VISIBLE HUMAN PROJECT

Gastric level (1 – 6): CT anatomy

CN: Celiac

LGNc: Left Gastric

SplNS: Splenic

LPNsr: Left paraortic

RPNsr: Right paraortic

RANs: Retroaortic

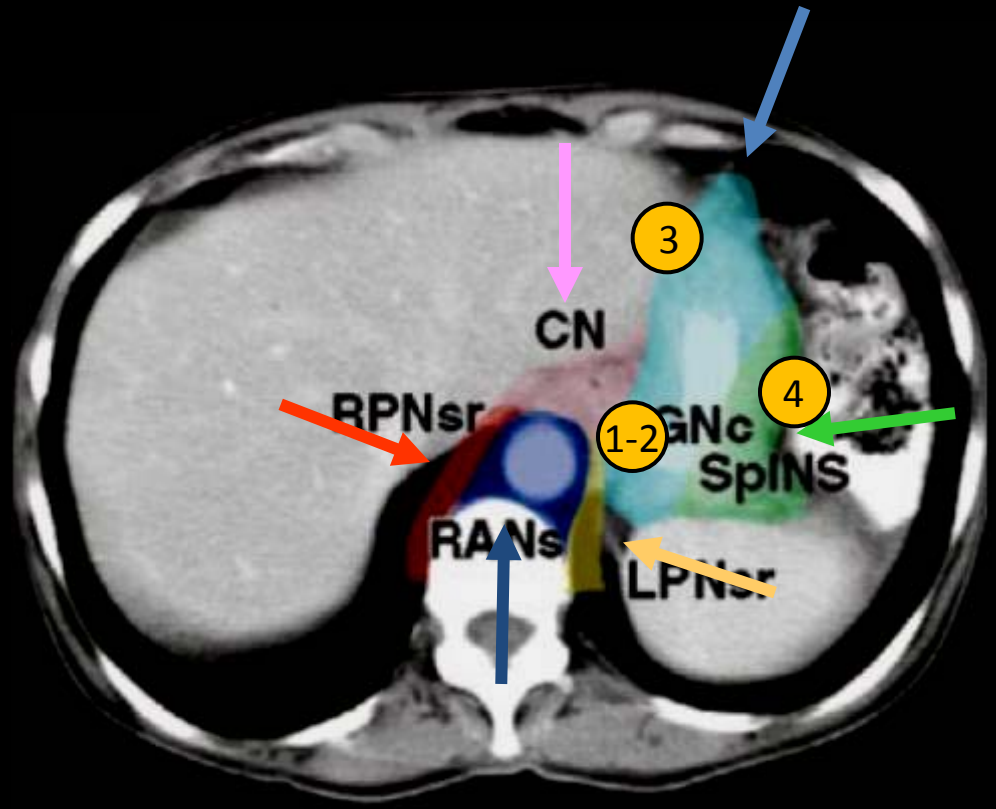

Martinez-Monge, R. et al. - Radiology - 1999

Gastric level (1 – 6): CT anatomy

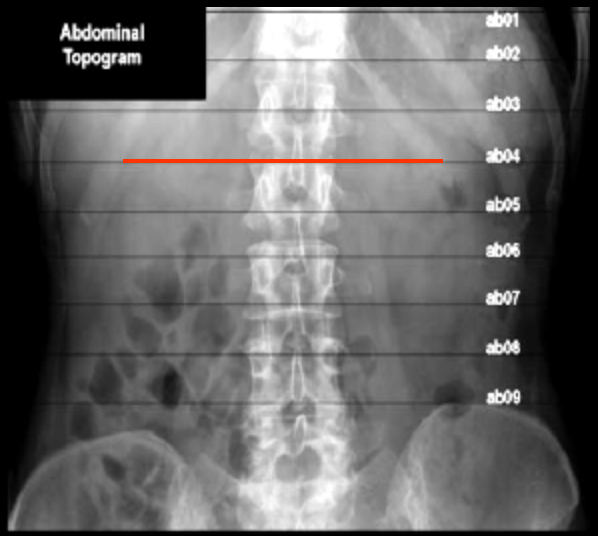

RRH: Right Renal Hilum
RANs: Retroaortic
LRH: Left Renal Hilum
SMN: Superior Mesenteric
HNp: Suprapyloric
Infrapyloric

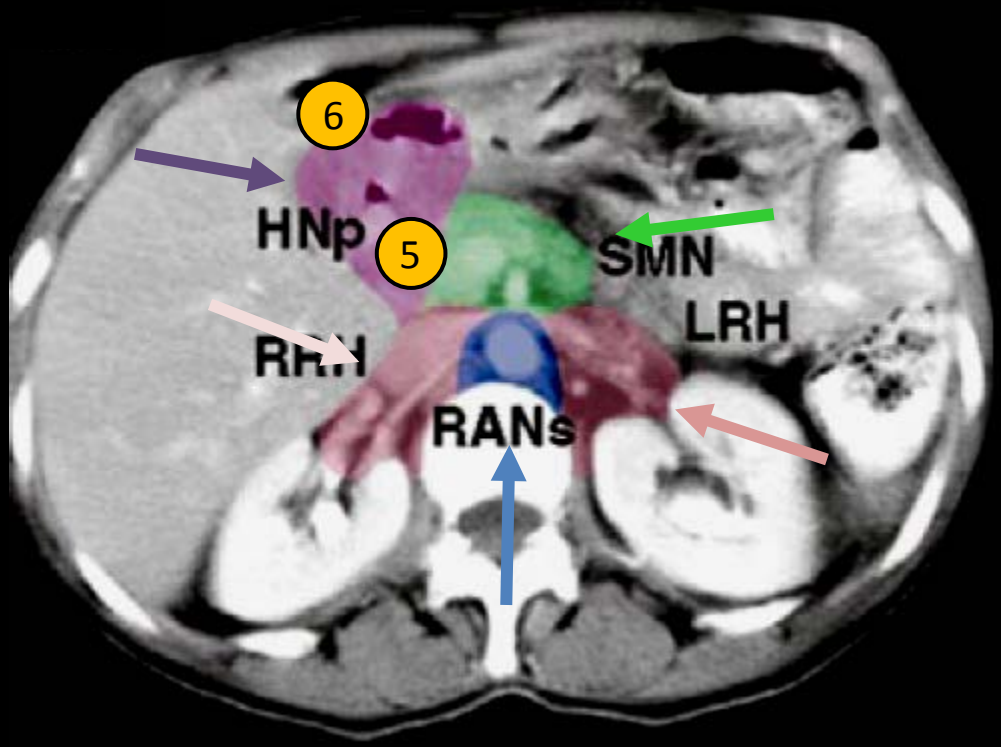

Martinez-Monge, R. et al. - Radiology - 1999

Gastric level (1 – 6): 3D recon

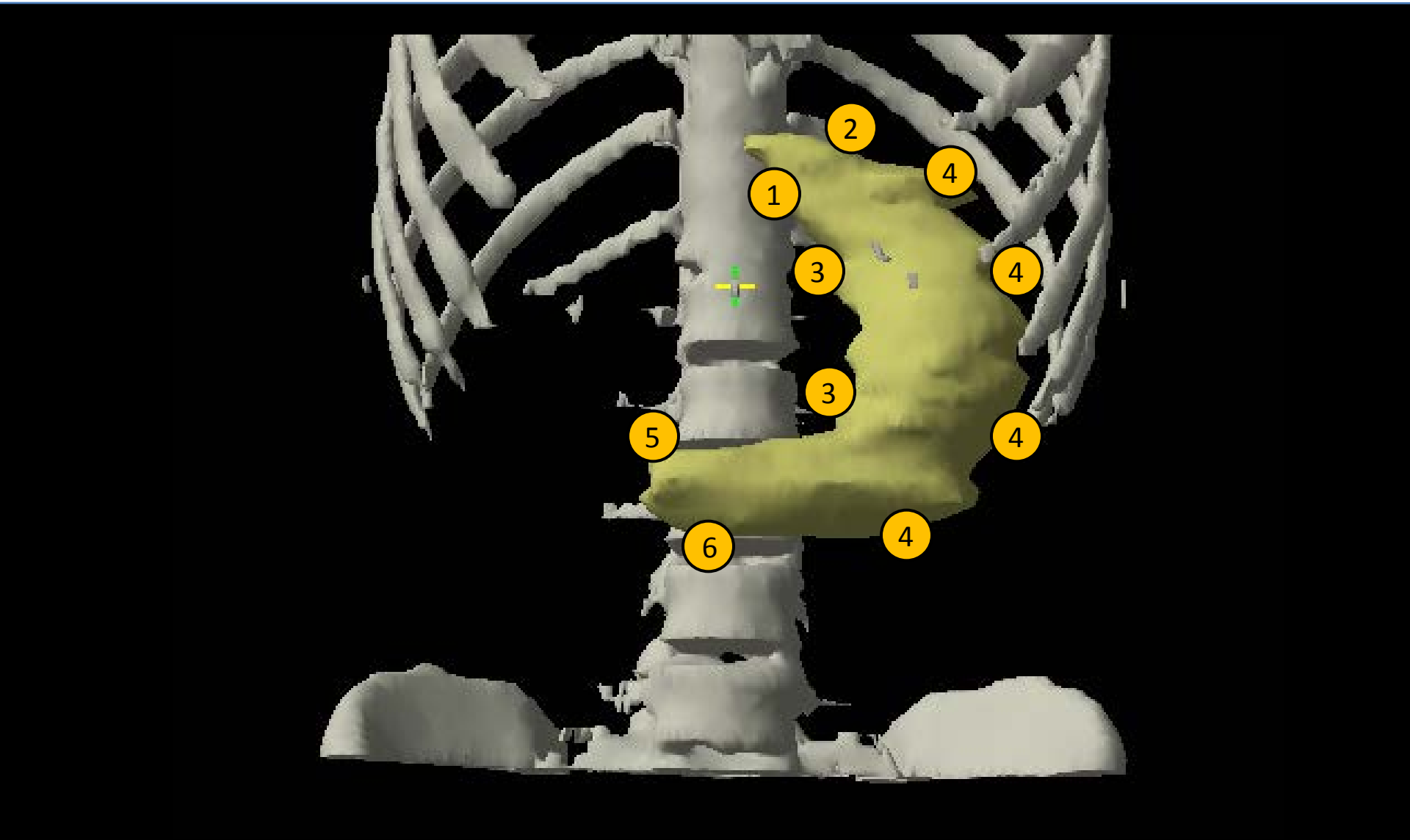

Pancreatic level (7 – 18)

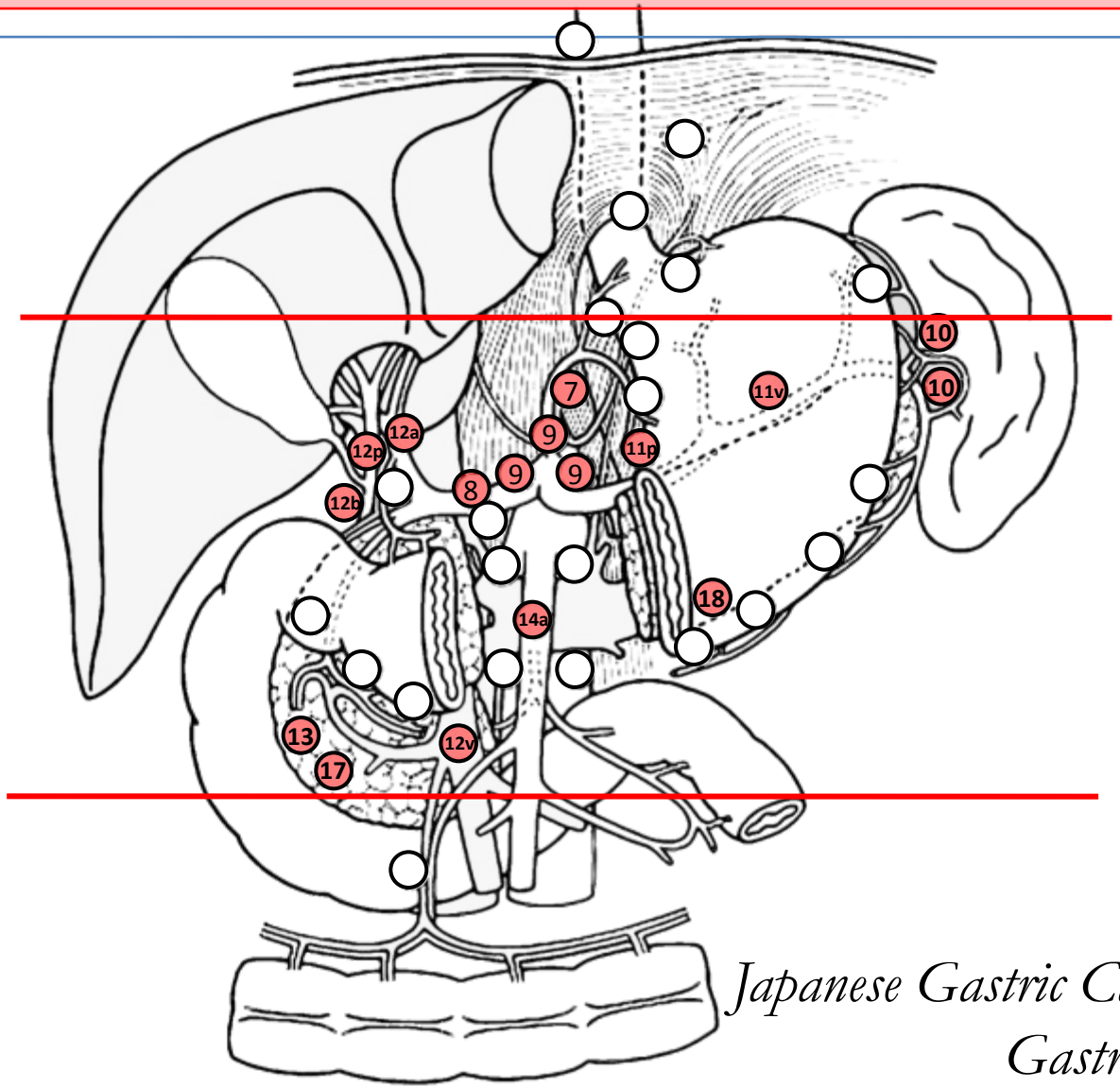

Japanese Gastric Cancer Association

Gastric Cancer - 1998

Pancreatic level (7 – 18)

JGCA Classification	Martinez-Monge classification
7. LN along the left gastric artery	**LGNlc** Left Gastric Nodes Lesser Curvature
8. LN along the hepatic artery	**Hnha** Hepatic Nodes, Hepatic Artery
9. LN around the celiac axis	**CN** Celiac Axis Nodes
10. LN at the splenic hilum 11p. LN along the proximal splenic artery 11v. LN along the distal splenic vein	**SplNh** Splenic Hilum (Splenopancreatic)

0.5 – 1 cm margin around the vessels

Pancreatic level (7 – 18)

JGCA Classification	Martinez-Monge classification
12a. LN in the hepatoduodenal ligament (hepatc artery)	**Hnha** Hepatic Nodes, Hepatic Artery
12b. LN in the hepatoduodenal ligament (bile duct)	**Hnp** Hepatic Nodes
12p. LN in the hepatoduodenal ligament (portal vein)	**Hnp** Hepatic Nodes

0.5 – 1 cm margin around the vessels

Pancreatic level (7 – 18)

JGCA Classification	Martinez-Monge classification
13. LN on the post. surface of the pancreas head	**HNpd** Pancreaticoduodenal
14a.LN along the sup. mesenteric artery **14v.**LN along the sup. mesenteric vein	**SMN** Superior Mesenteric
17. LN on the ant. surface of the pancreas head	**HNpd** Pancreaticoduodenal
18. LN on the post. surface of the pancreas	**PANs-m** Preaortic nodes

0.5 – 1 cm margin around the vessels

Pancreatic level (7 – 18): axial anatomy

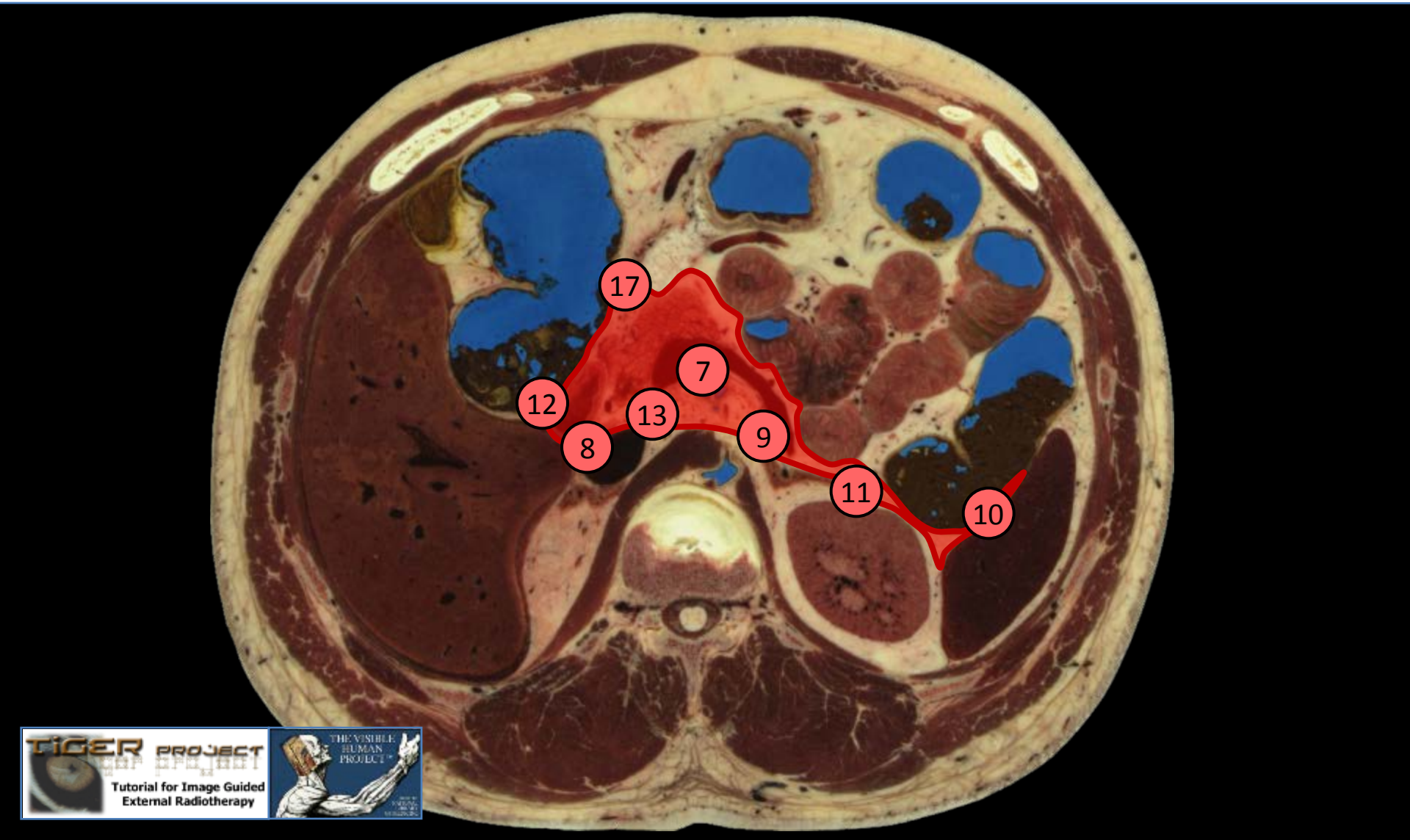

Pancreatic level (7 – 18): axial anatomy

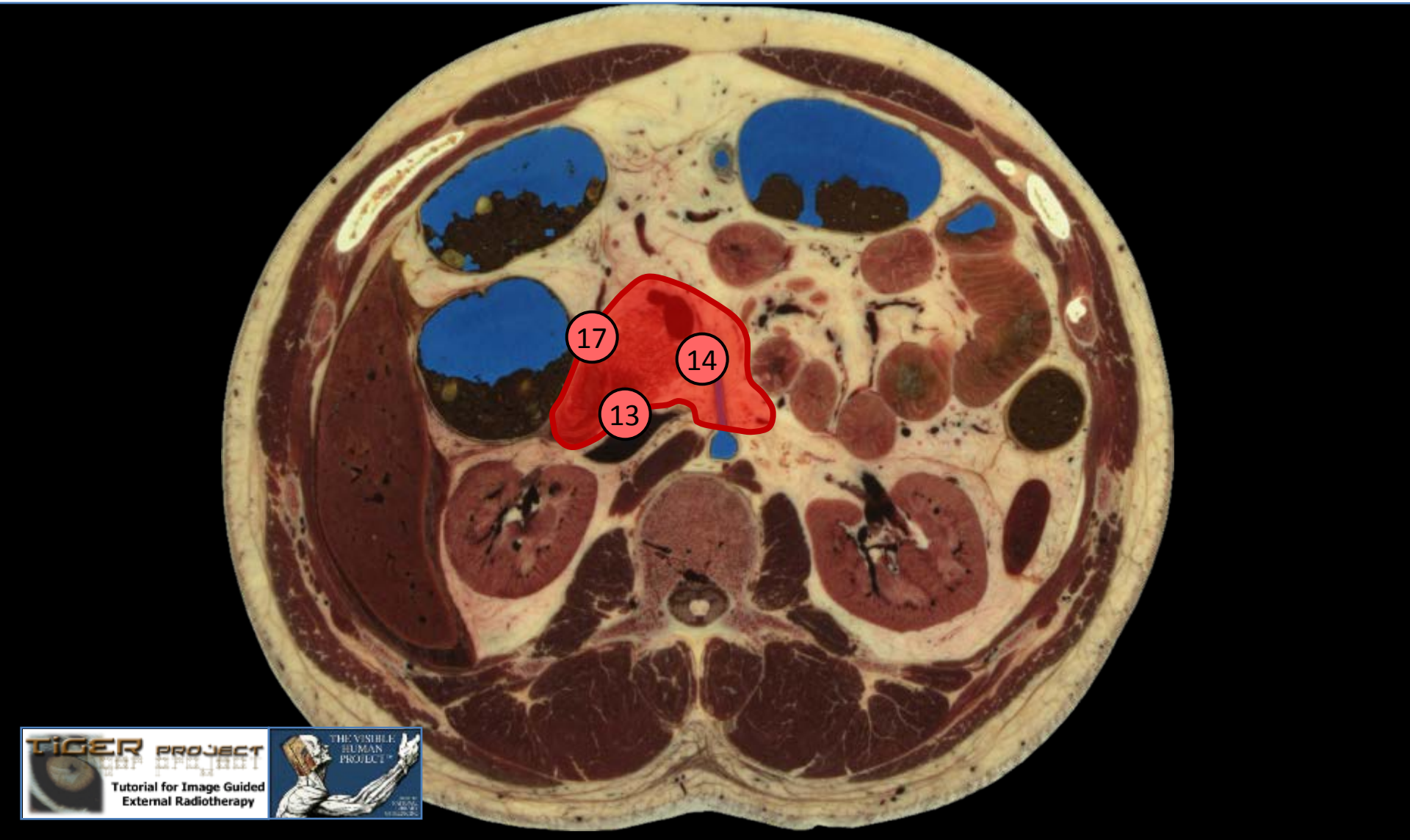

TIGER PROJECT
Tutorial for Image Guided External Radiotherapy
THE VISIBLE HUMAN PROJECT

Pancreatic level (7 – 18): CT anatomy

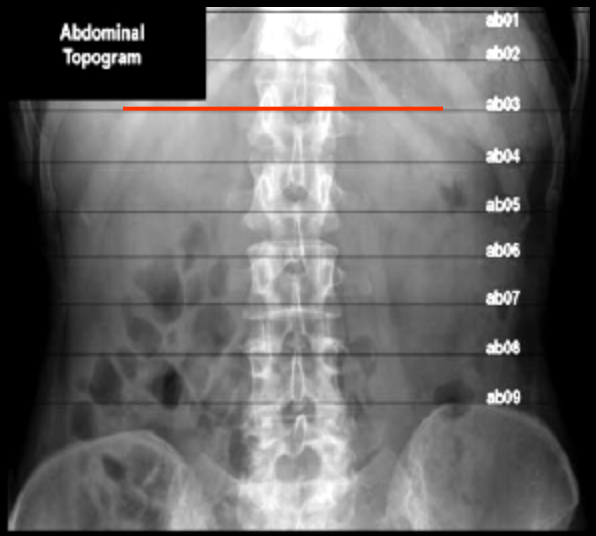

RPNsr: Right paraortic

RANs: Retroaortic

LPNsr: Left paraortic

SplNh: Splenic Hilum

CN: Celiac

HNrg: Hepatic right gastroepiploic

LGNlc: Left Gastric

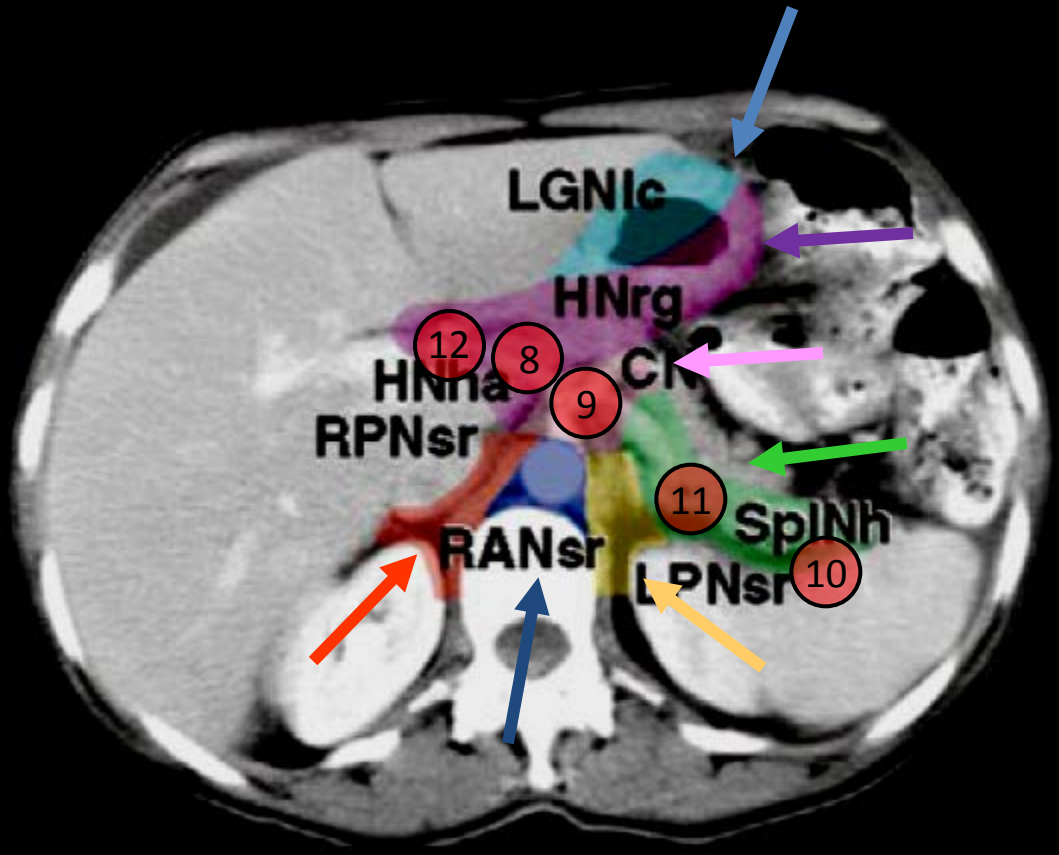

Martinez-Monge, R. et al. - Radiology - 1999

Pancreatic level (7 – 18): CT anatomy

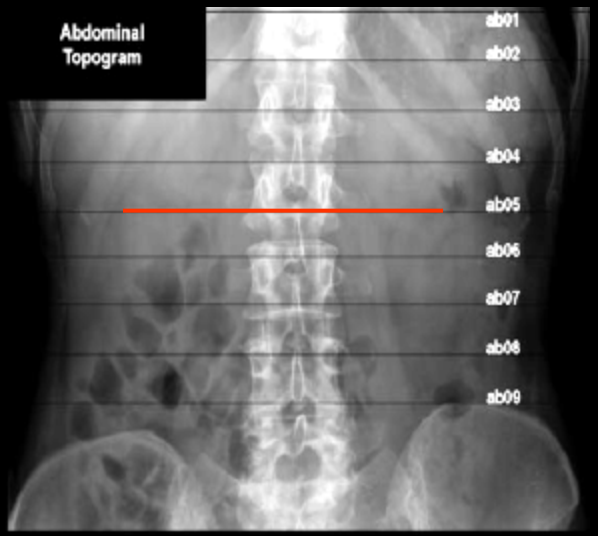

RPNsr: Right paraortic

RANs: Retroaortic

LPNsr: Left paraortic

SMN: Superior Mesenteric

HNpd: Pancreatico duodenal

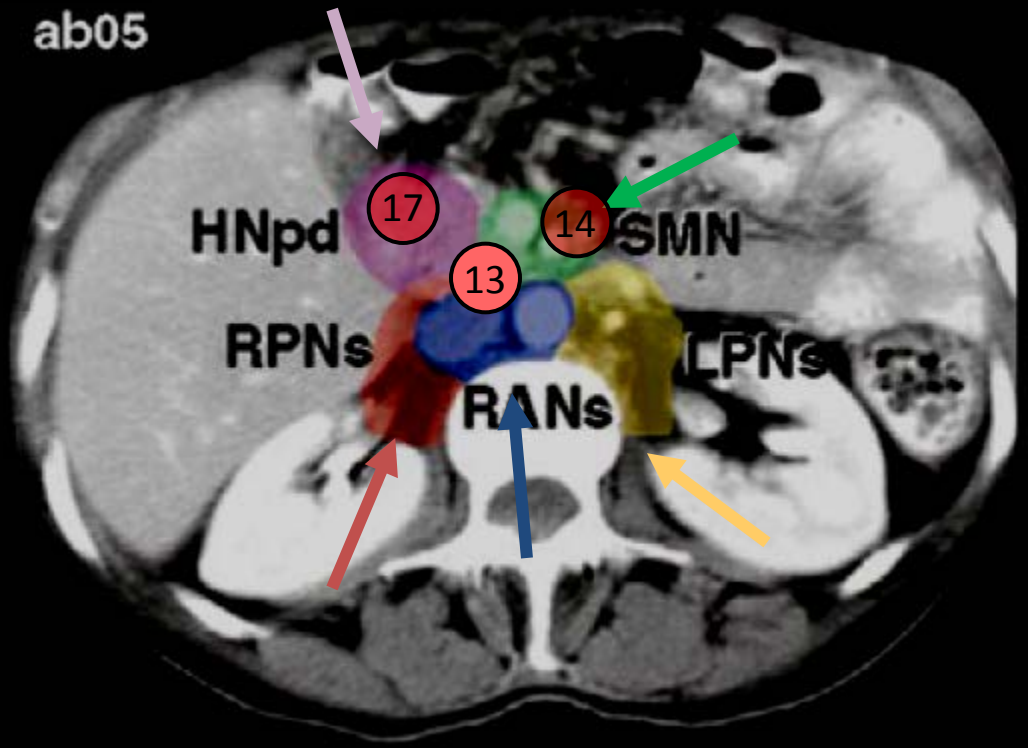

Martinez-Monge, R. et al. - Radiology - 1999

Pancreatic level (7 – 18): 3D Recon

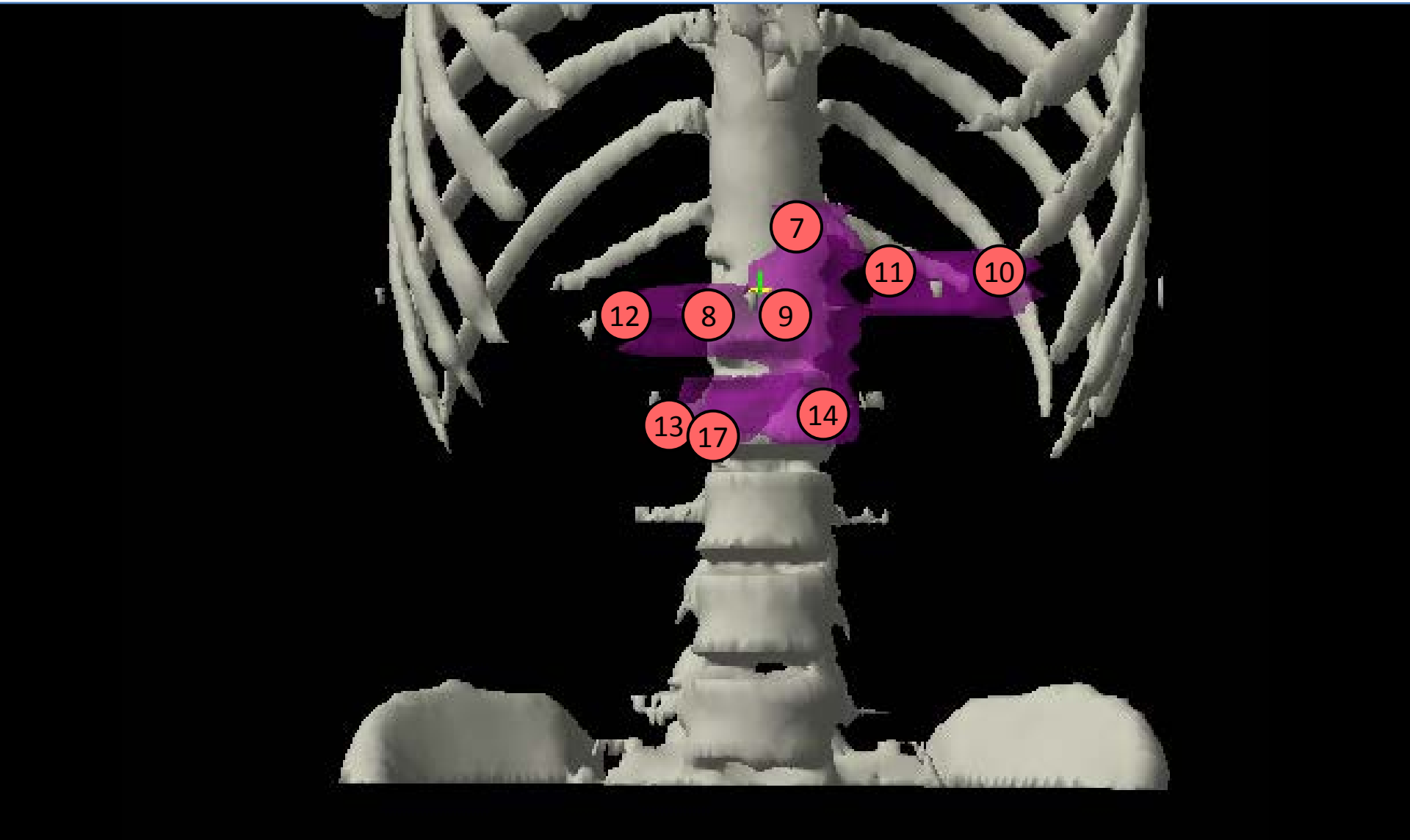

Vascular level (16-19)

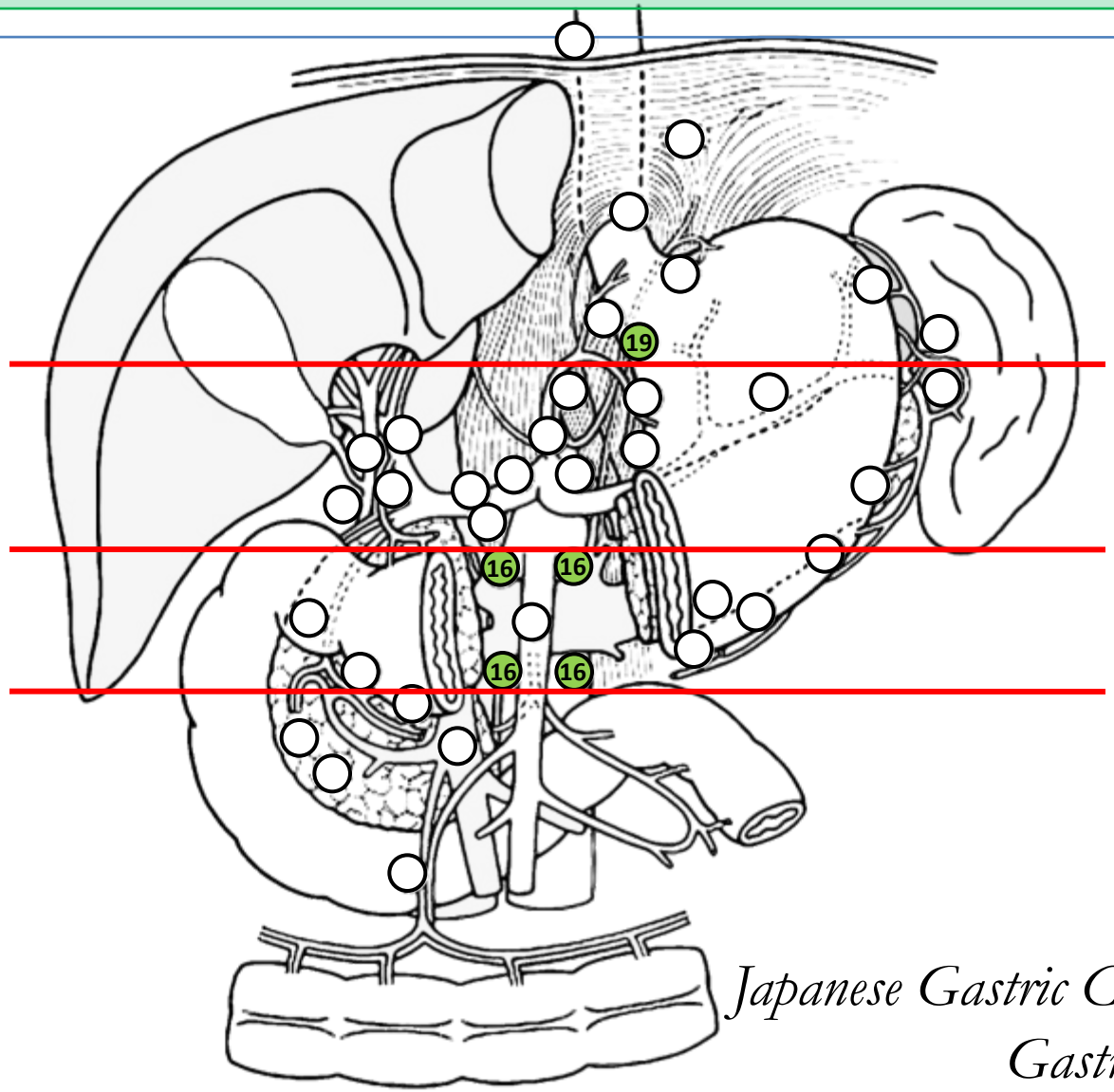

Japanese Gastric Cancer Association
Gastric Cancer - 1998

Vascular level (16-19)

JGCA Classification	Martinez-Monge classification
16a1. LN in the **aortic iatus**→ **sup margin of celiac axis**	**RANs** Retroaortic Nodes **RPNs** Right Paraortic Nodes **LPNs** Left Paraortic Nodes
16a2. LN along the abdominal aorta (**sup. margin celiac axis** → **inf. margin left renal vein**)	**RANs** Retroaortic Nodes **RPNs** Right Paraortic Nodes **LPNs** Left Paraortic Nodes

0.5 – 1 cm margin around the vessels

Vascular level (16-19)

JGCA Classification	Martinez-Monge classification
16b1. LN along the abdominal aorta (**inf. margin left renal vein → sup. margin inf. mesenteric artery**)	**RANm** Retroaortic Nodes **RPNm** Right Paraortic Nodes **LPNm** Left Paraortic Nodes
16b2. LN along the abdominal aorta (**inf. margin inf. mesenteric artery → inf. margin aortic bifurcation**)	**RANi** Retroaortic Nodes **RPNi** Right Paraortic Nodes **LPNi** Left Paraortic Nodes
19. LN infradiafragmatic	**RANs** Retroaortic Nodes **LPNsr** Left Paraortic Nodes

0.5 – 1 cm margin around the vessels

Vascular level (16-19): topography

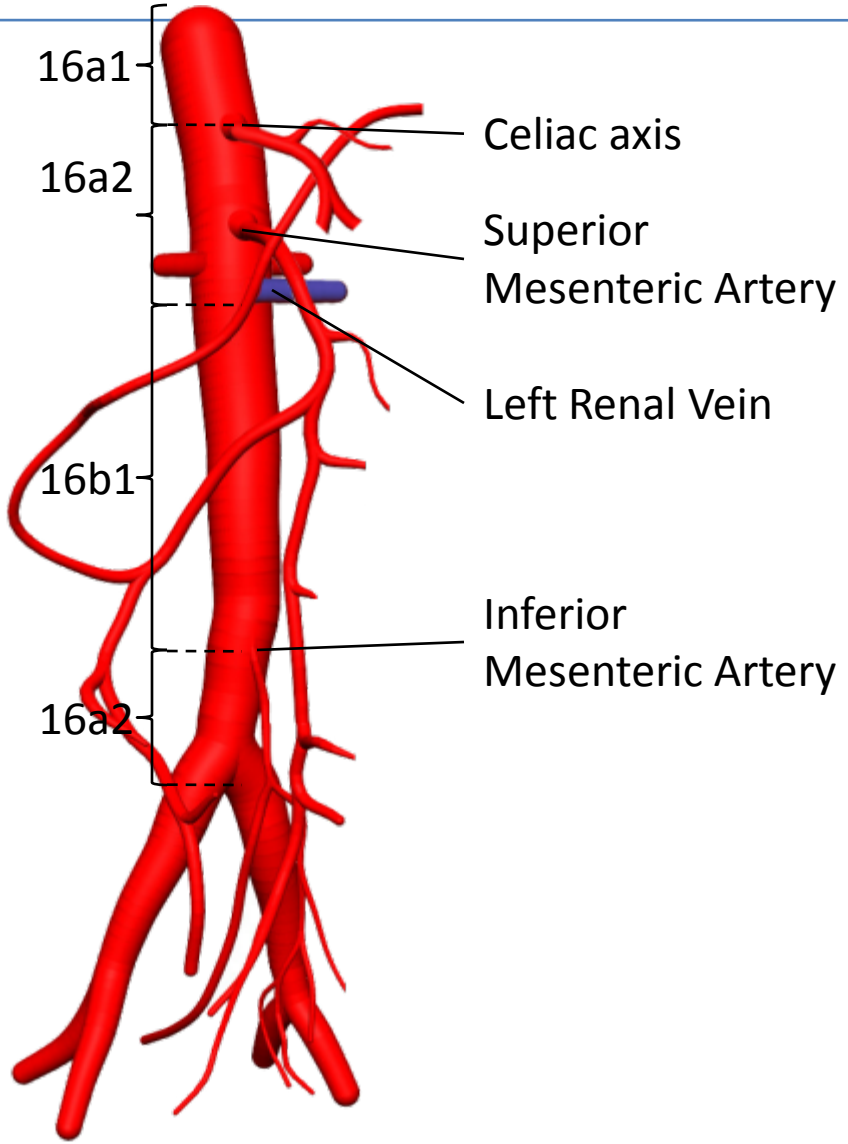

Vascular level (16-19): axial anatomy

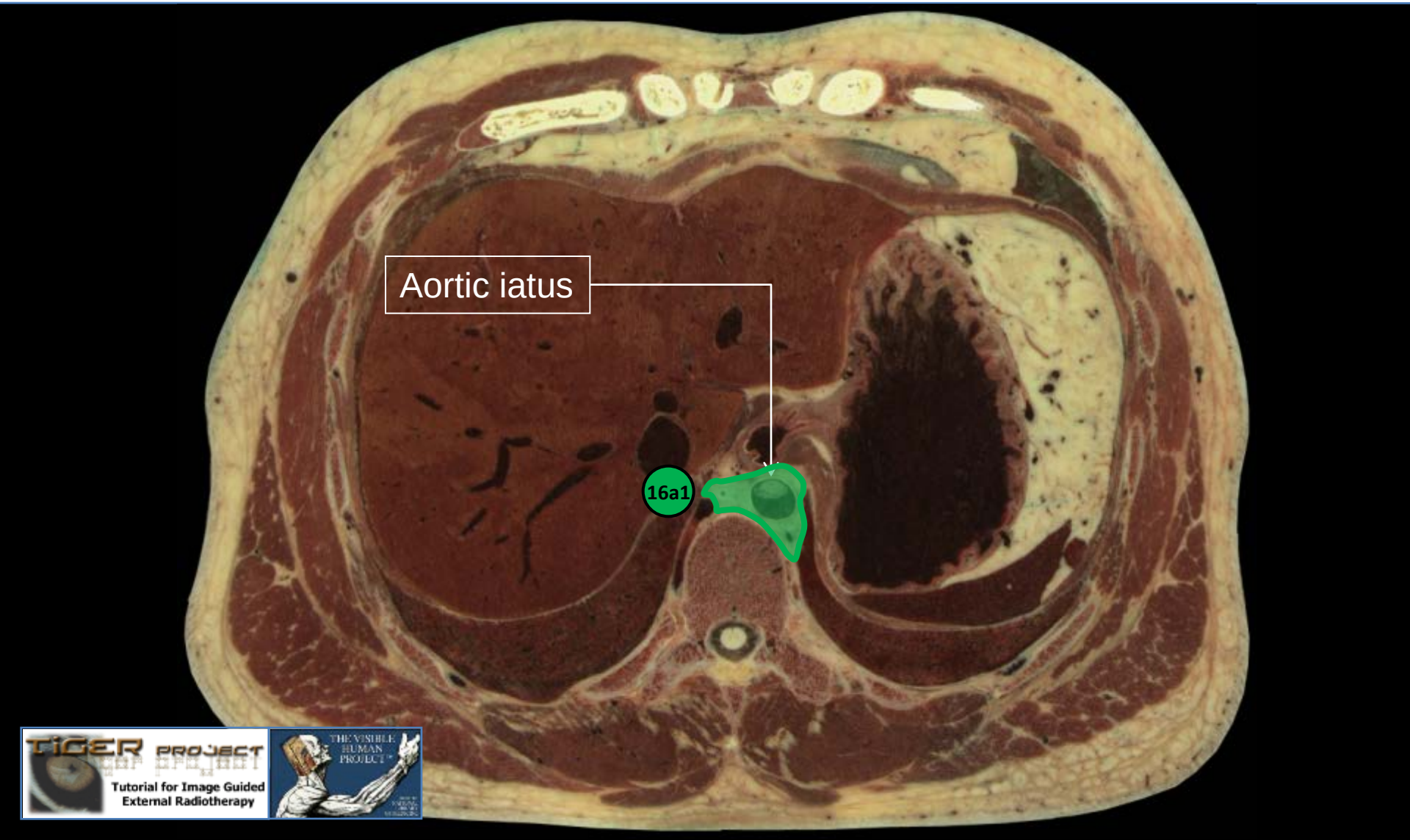

Vascular level (16-19): axial anatomy

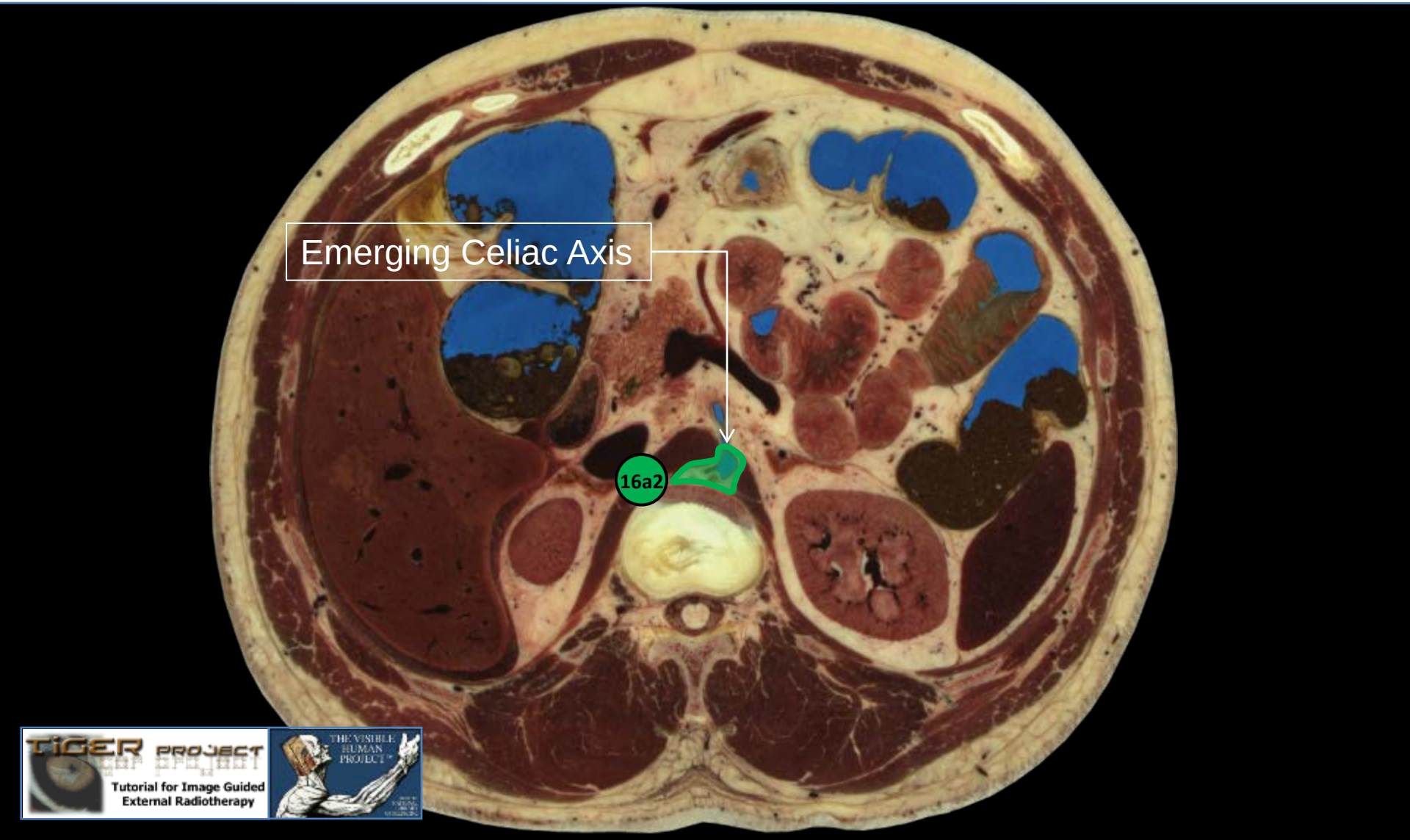

TIGER PROJECT
Tutorial for Image Guided External Radiotherapy
THE VISIBLE HUMAN PROJECT

Vascular level (16-19): axial anatomy

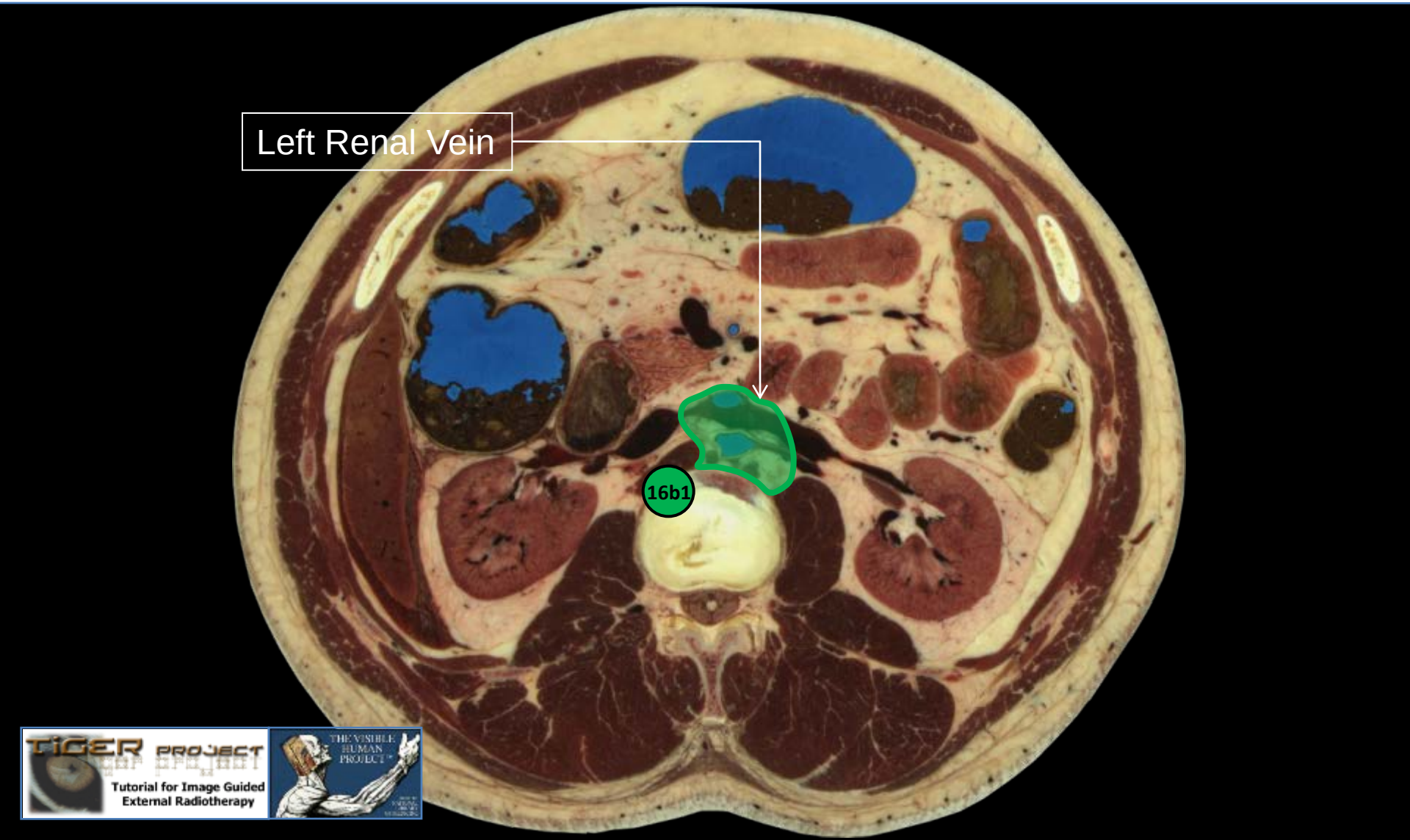

Vascular level (16-19): axial anatomy

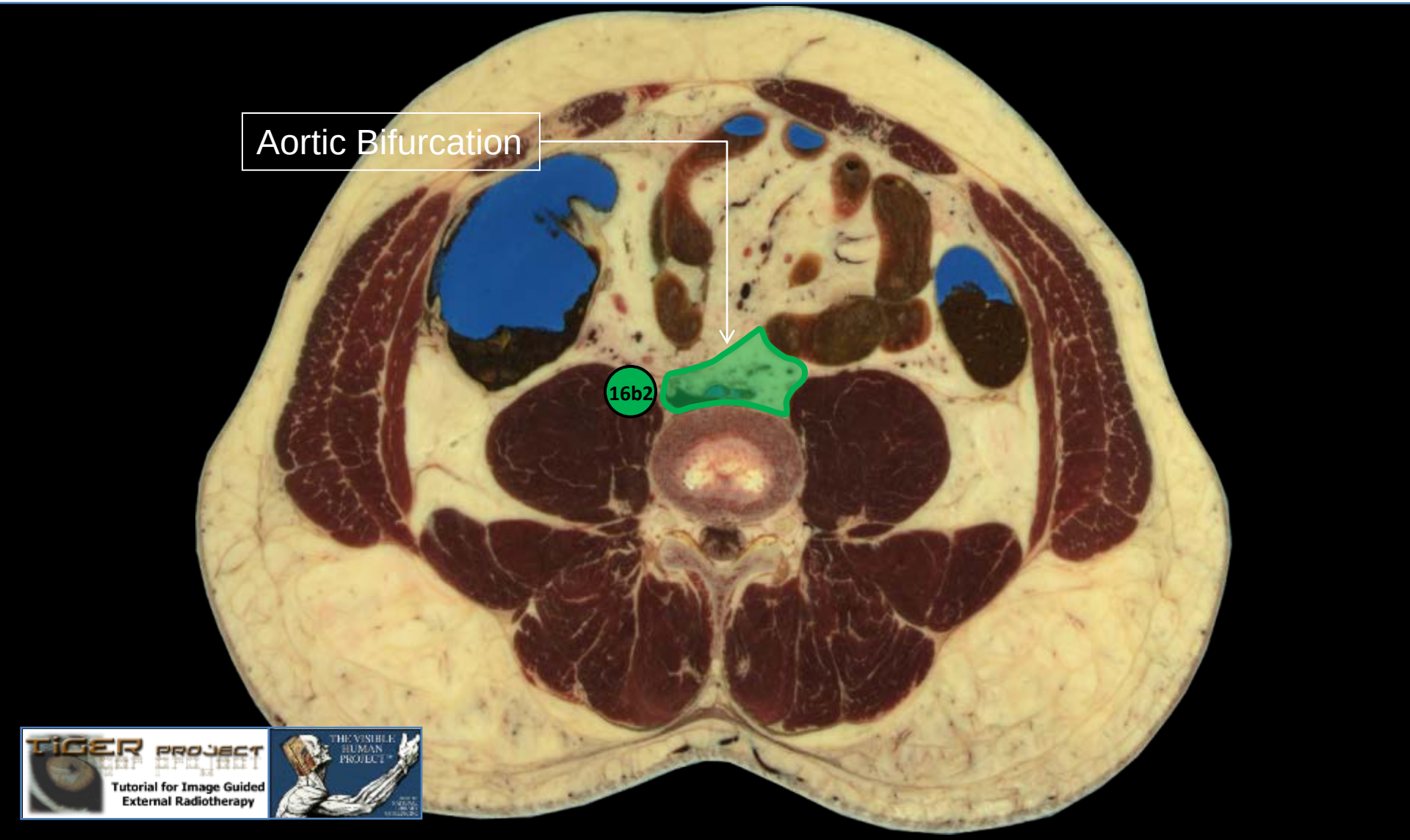

TIGER PROJECT
Tutorial for Image Guided External Radiotherapy
THE VISIBLE HUMAN PROJECT

Vascular level (16-19): CT anatomy

LPNsr: **Left paraortic**

RPNsr: **Right paraortic**

RANs: **Retroaortic**

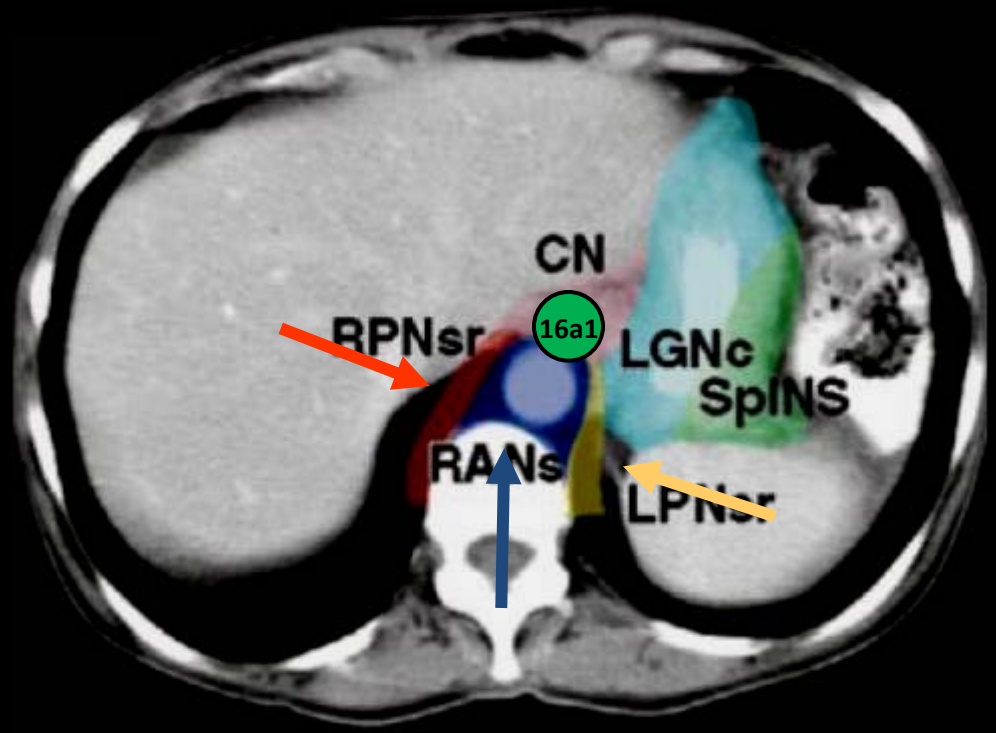

Martinez-Monge, R. et al. - Radiology - 1999

Vascular level (16-19): CT anatomy

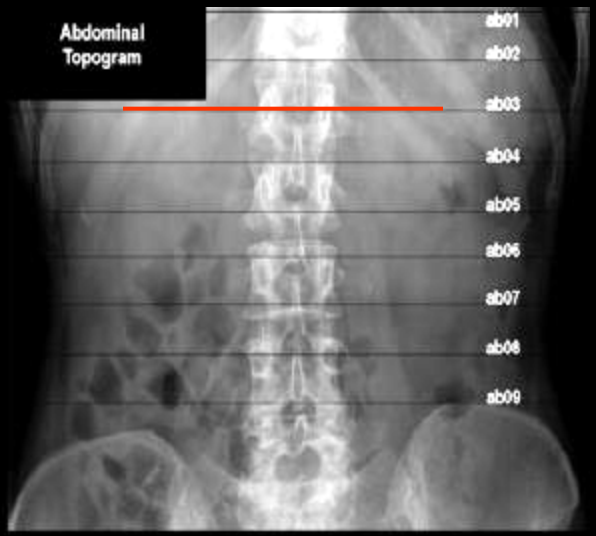

RPNsr: Right paraortic

RANs: Retroaortic

LPNsr: Left paraortic

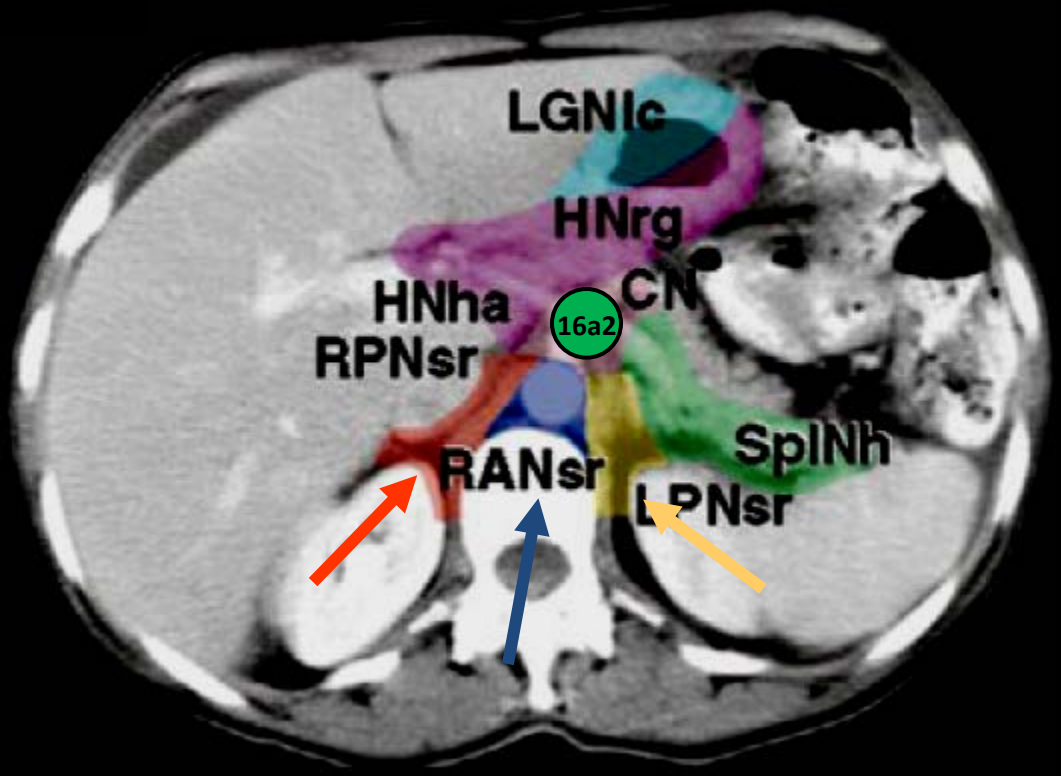

Martinez-Monge, R. et al. - Radiology - 1999

Vascular level (16-19): CT anatomy

RRH: Right Renal Hilum

RANs: Retroaortic

LRH: Left Renal Hilum

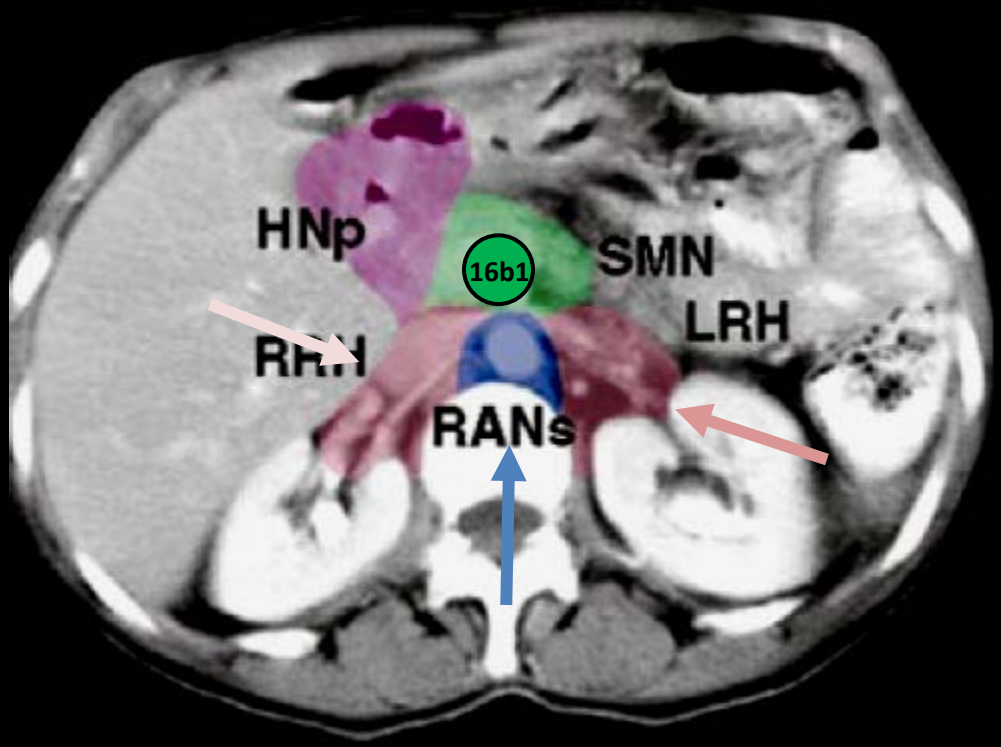

Martinez-Monge, R. et al. - Radiology - 1999

Vascular level (16-19): CT anatomy

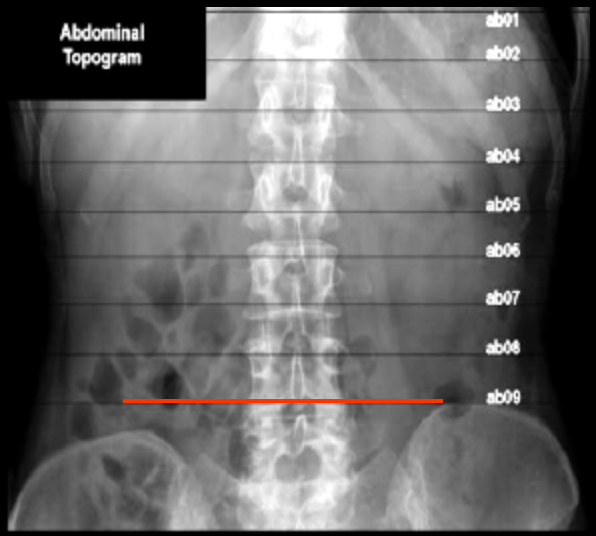

RPNi: Right paraortic

RANi: Retroaortic

LPNi: Left paraortic

PANi: Preaortic

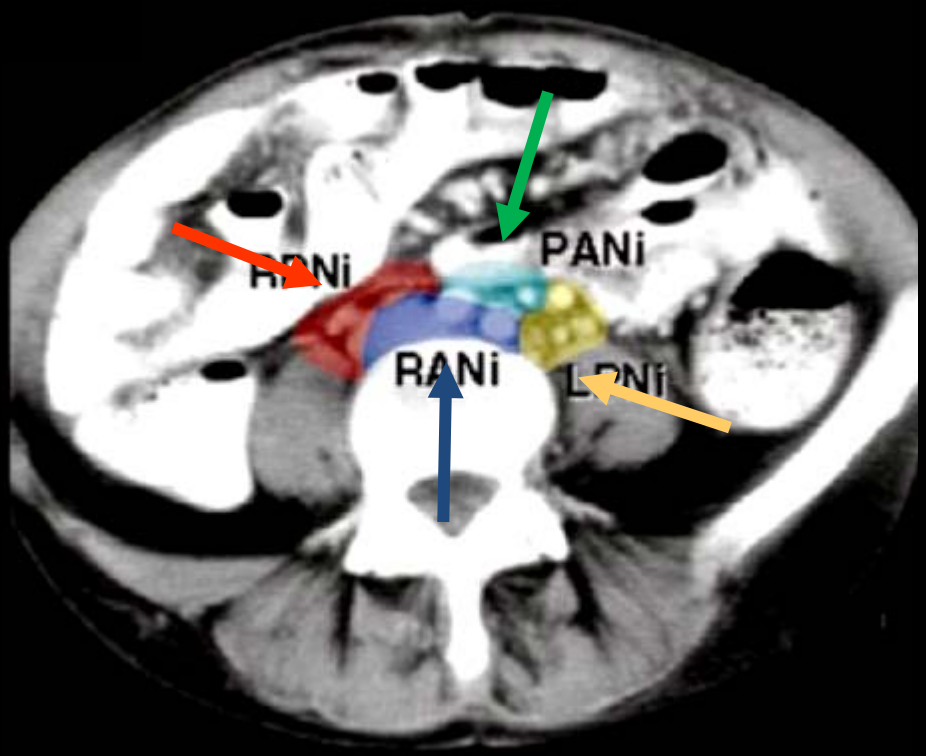

Martinez-Monge, R. et al. - Radiology - 1999

Vascular level (16-19): 3D Recon

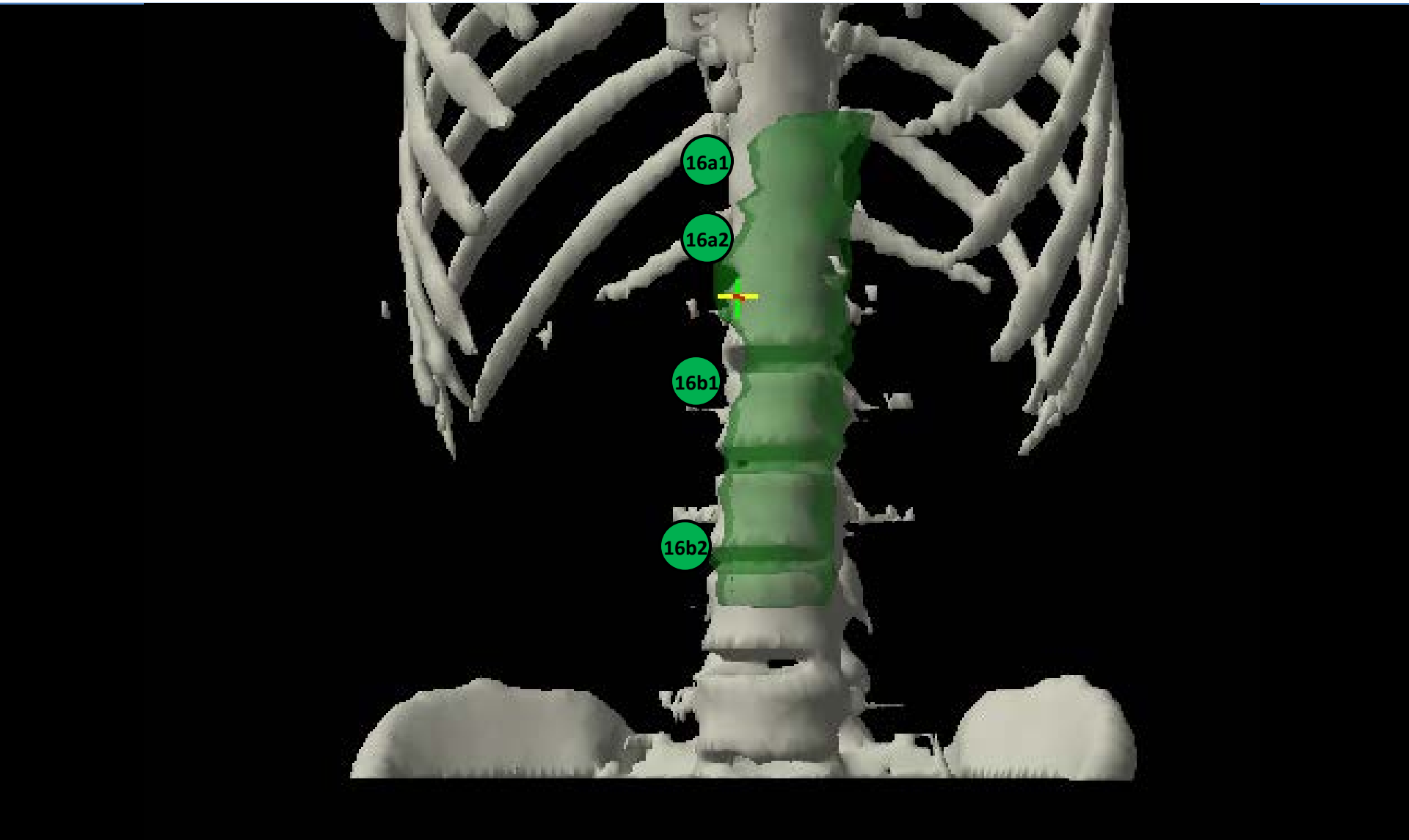

Target Volume Delineation

- Evidences
- Areas at risk
- CTV definition

CTV Delineation

Pre-Op & D0 Surgery

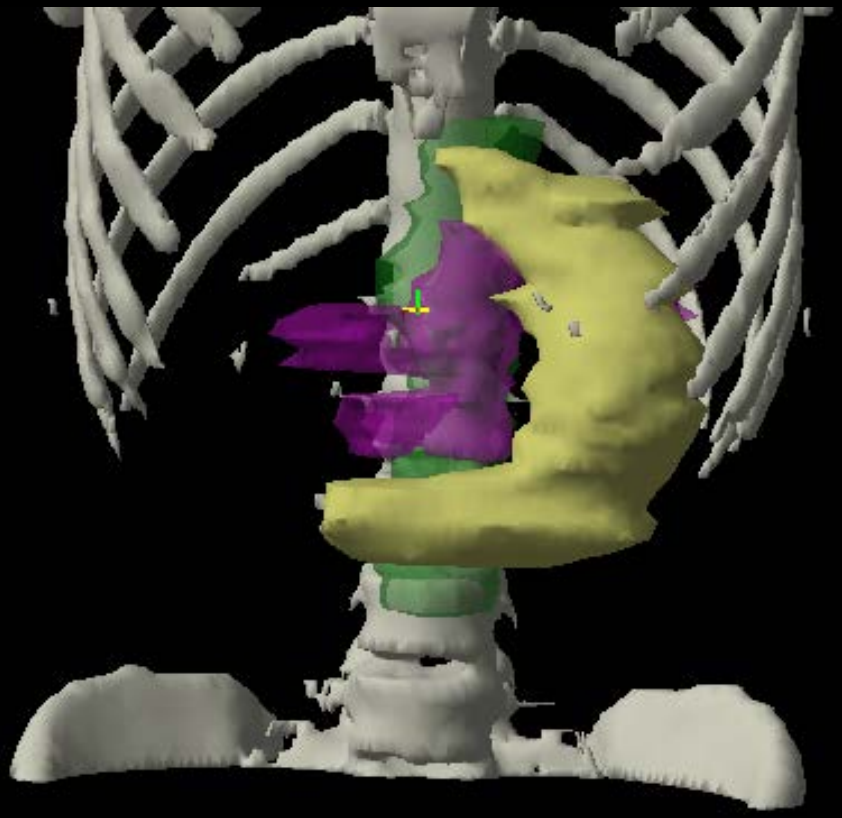

Post-Operative D1+

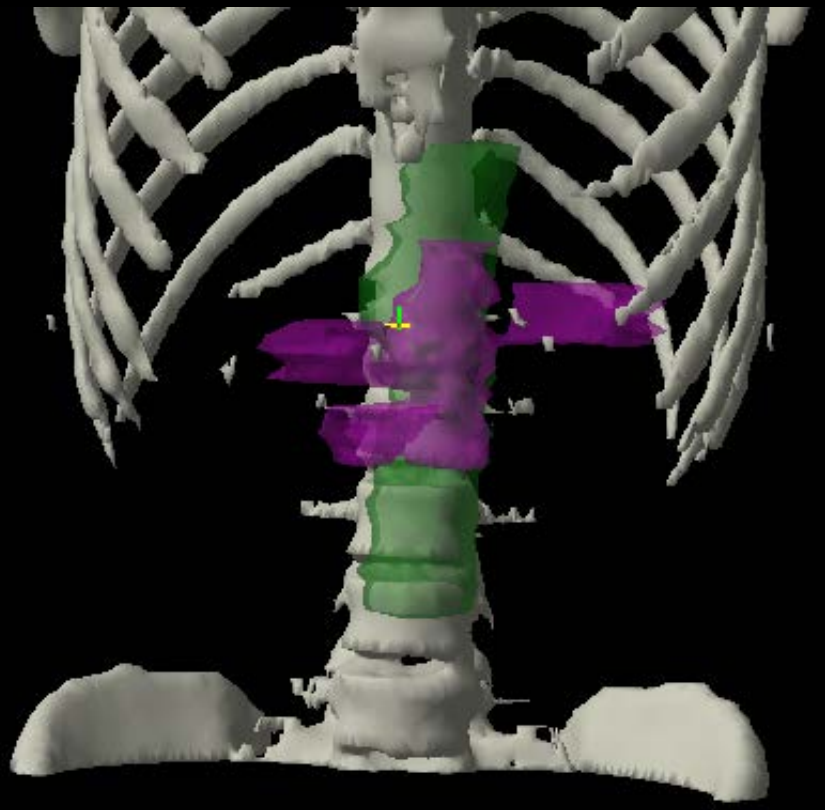

CTV Definition: GTV Site

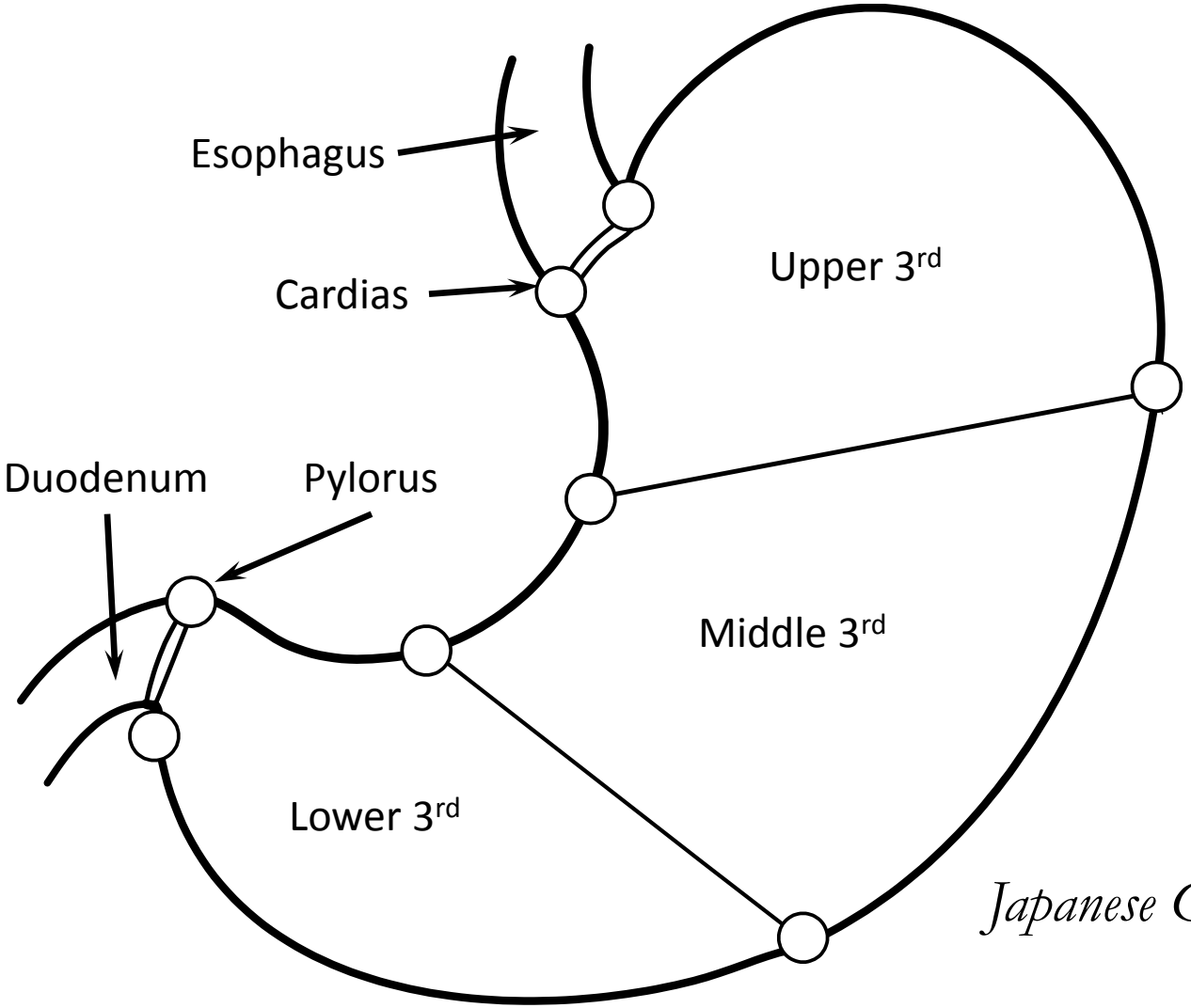

Japanese Gastric Cancer Association
Gastric Cancer - 2011

CTV Definition

Nodal Group	Station Number	Upper 3rd (%)	Middle 3rd (%)	Lower 3rd (%)
		N = 339	N = 318	N = 150
Paracardia	1 – 2	22	9	
Lesser/Greater Curvature	3 – 4	25	36	37
Suprapyloric	5			12
Infrapyloric	6		15	49
Left Gastric Artery	7	19	22	23
Common Epatic Artery	8	7	11	25
Celiac Axis	9	13	8	13
Splenic Artery/Hilum	10 – 11	11		
Hepatoduodenal Ligamentum	12			8
Others (distant nodes)	13 – 16			

Tepper JE, Gunderson L – Radiother Oncol - 2002

Lymph nodes recurrences after D2 dissection, in stage III (N+)

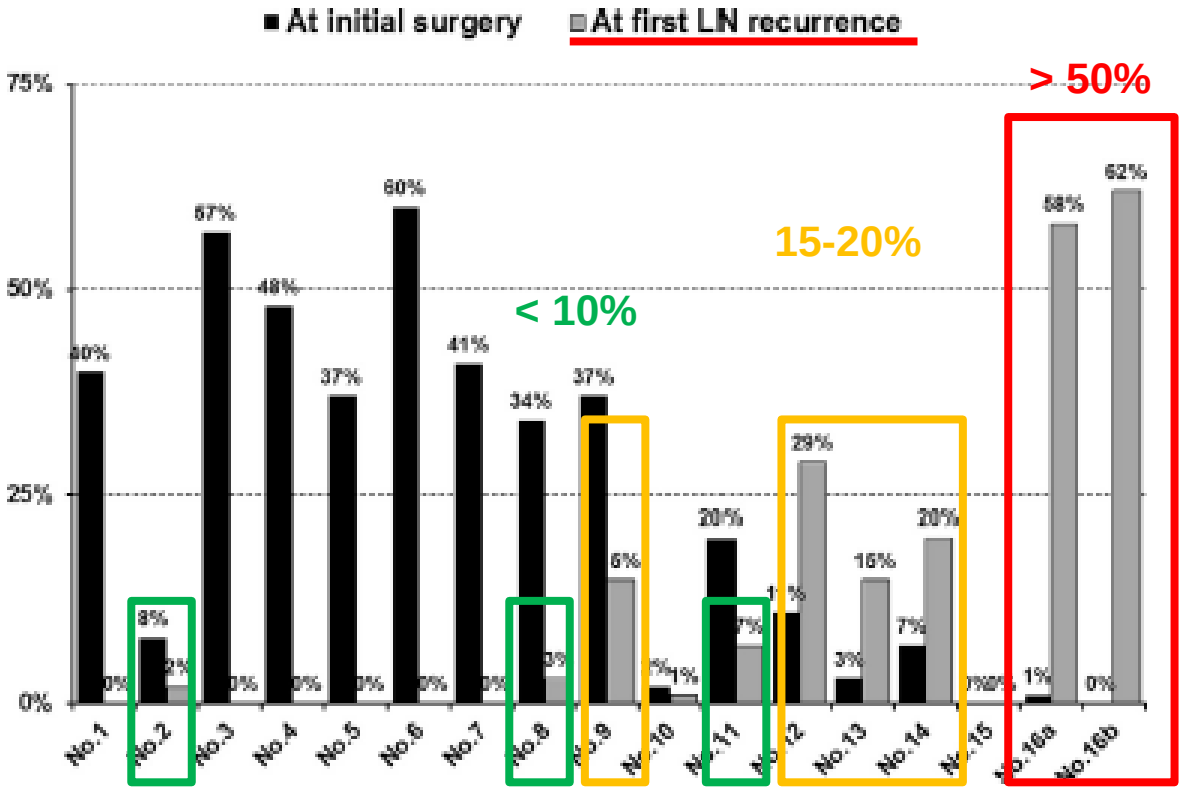

Yoon HI et al – Radiother Oncol - 2013

Lymph nodes recurrences after D2 dissection, in stage III (N+)

Tumor site	Lymph node station & %	
Upper 3rd	**16** (aortic)	> 50%
	9 (celiac)	30%
	10 (splenic hilum)	10%
	13 (pancreatico-duodenal)	10%
Middle 3rd	**16** (aortic)	> 50%
	12 (hepato-duodenal)	26%
	14 (SMA)	10%
Lower 3rd	**16** (aortic)	> 50%
	14 (SMA)	41%
	12 (hepato-duodenal)	24%
	11 (splenic artery)	12%
	9 (celiac)	12%
	2 (left gastric artery)	12%

Yoon HI et al – Radiother Oncol - 2013

Target Volume Delineation Upper 3rd

Nodal Group	Station Number	Upper 3rd (%)	Middle 3rd (%)	Lower 3rd (%)
		N = 339	N = 318	N = 150
Paracardia	1 – 2	22	9	
Lesser/Greater Curvature	3 – 4	25	36	37
Suprapyloric	5			12
Infrapyloric	6		15	49
Left Gastric Artery	7	19	22	23
Common Epatic Artery	8	7	11	25
Celiac Axis	9	13	8	13
Splenic Artery/Hilum	10 – 11	11		
Hepatoduodenal Ligamentum	12			8
Others (distant nodes)	13 – 16			

Tepper JE, Gunderson L – Radiother Oncol - 2002

Target Volume Delineation: Nodal CTV delineation for Upper 3rd

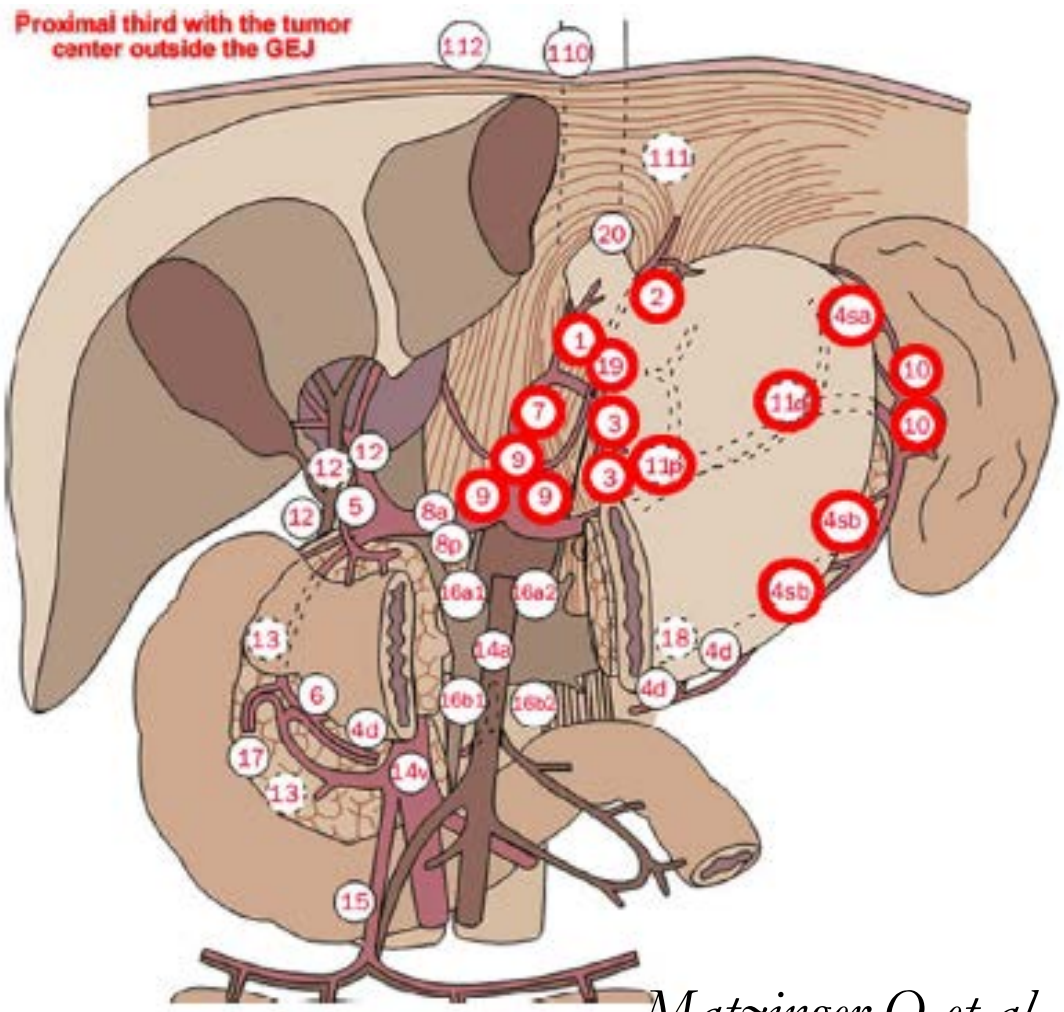

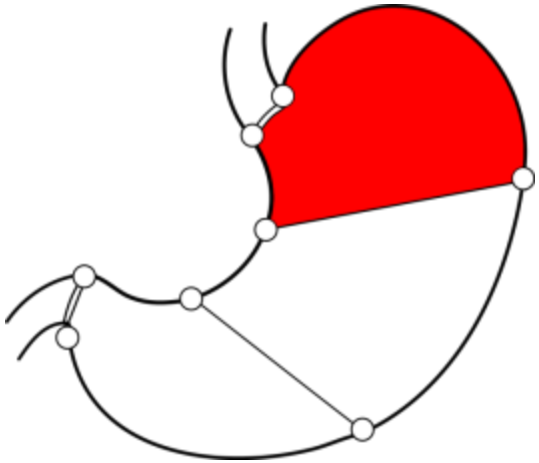

O High Risk

Matzinger O et al – Raadiother Oncol – 2009

Lymph nodes recurrences after D2 dissection, in stage III (N+)

Tumor site	Lymph node stations	Rate (%)
Upper 3rd	**16** (aortic)	> 50%
	9 (celiac)	30%
	10 (splenic hilum)	10%
	13 (pancreatico-duodenal)	10%

Yoon HI et al – Radiother Oncol - 2013

Target Volume Delineation: Nodal CTV delineation for Upper 3rd

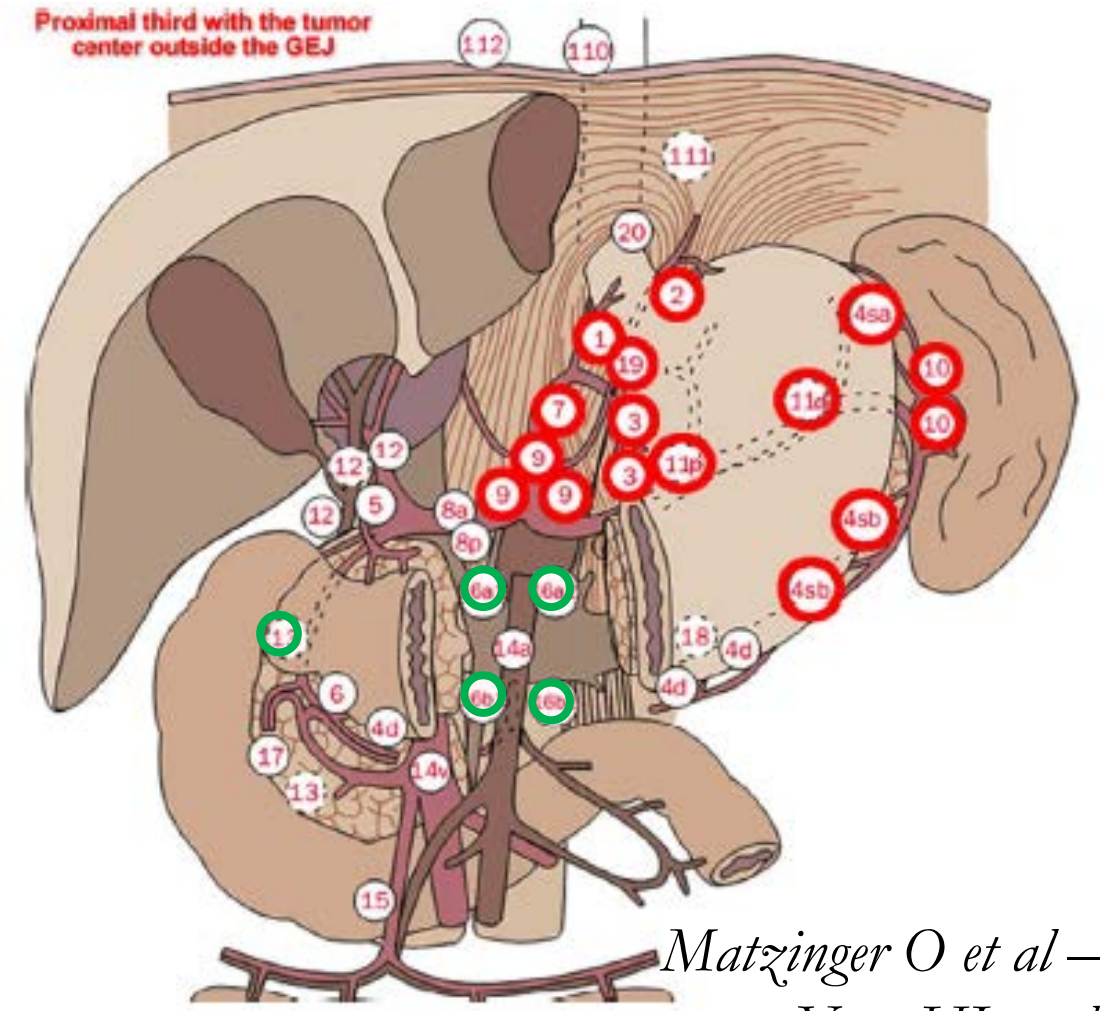

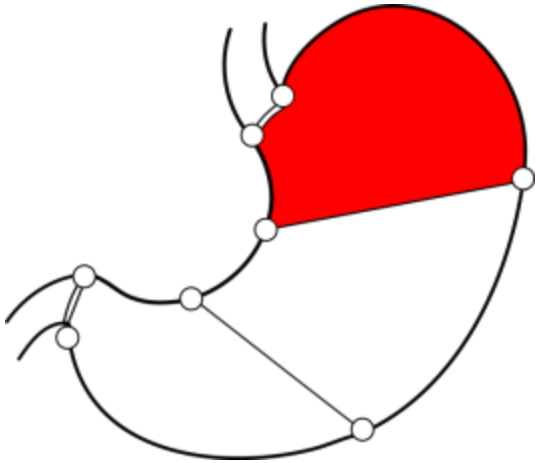

High Risk

If N+

Matzinger O et al – Raadiother Oncol – 2009

Yoon HI et al – Radiother Oncol - 2013

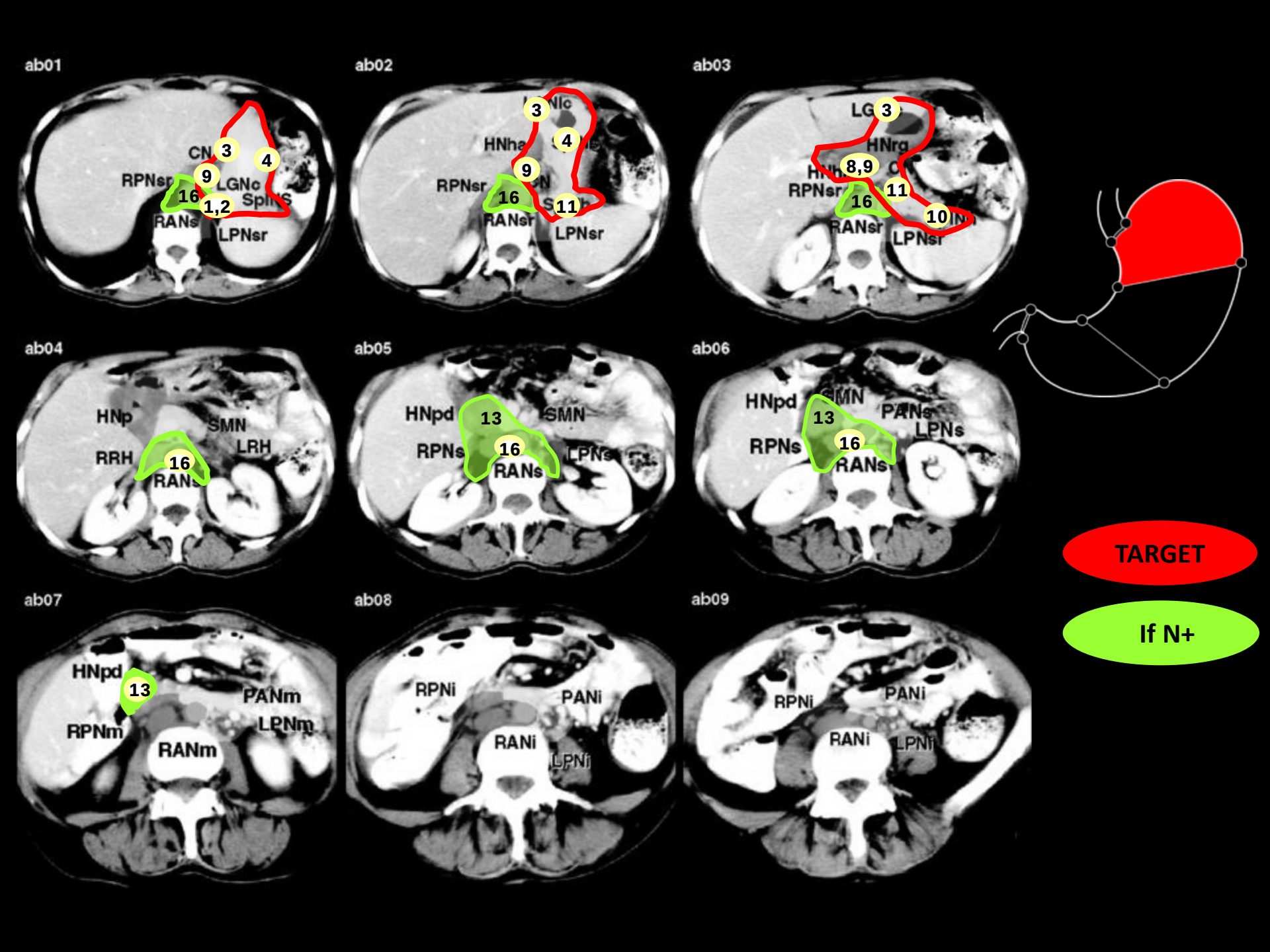
ab01
CN
3
4
9
RPNsr
LGNc
16
1,2
RANs
LPNsr
ab02
3
HNha
4
9
RPNsr
16
11
RANsr
LPNsr
ab03
LG
3
HNrg
8,9
RPNsr
11
16
10
RANsr
LPNsr
ab04
HNp
SMN
LRH
RRH
16
RANs
ab05
HNpd
13
SMN
RPNs
16
LPNs
RANs
ab06
HNpd
13
SMN
PANs
LPNs
RPNs
16
RANs
ab07
HNpd
13
PANm
LPNm
RPNm
RANm
ab08
RPNi
PANi
RANi
LPNi
ab09
RPNi
PANi
RANi
LPNi
TARGET
If N+

Target Volume Delineation: CTV & Field definition for Upper 3rd

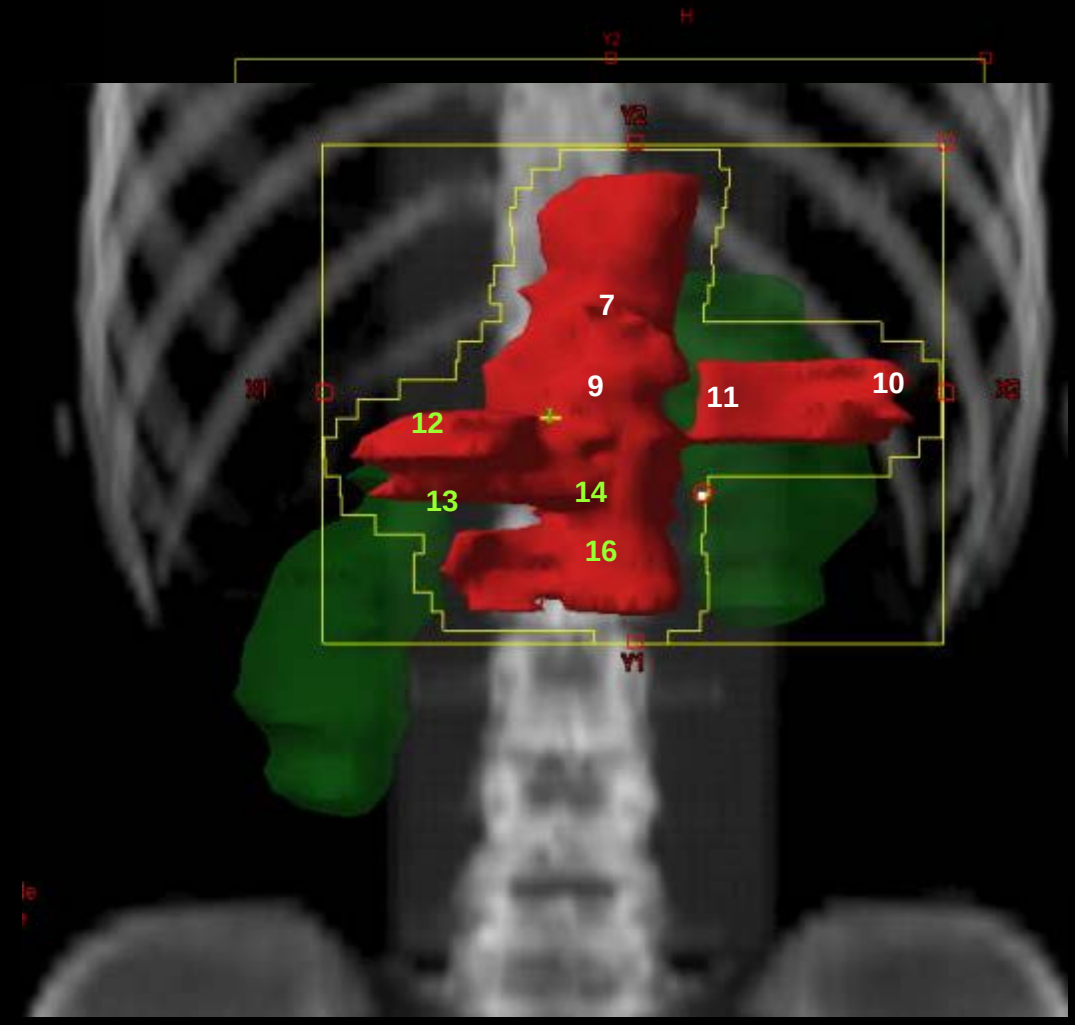

Post-op

3D BEV

CTV Definition Middle 3rd

Nodal Group	Station Number	Upper 3rd (%)	Middle 3rd (%)	Lower 3rd (%)
		N = 339	N = 318	N = 150
Paracardia	1 – 2	22	9	
Lesser/Greater Curvature	3 – 4	25	36	37
Suprapyloric	5			12
Infrapyloric	6		15	49
Left Gastric Artery	7	19	22	23
Common Epatic Artery	8	7	11	25
Celiac Axis	9	13	8	13
Splenic Artery/Hilum	10 – 11	11		
Hepatoduodenal Ligamentum	12			8
Others (distant nodes)	13 – 16			

Tepper JE, Gunderson L – Radiother Oncol - 2002

CTV Definition:
Nodal CTV delineation for Middle 3rd

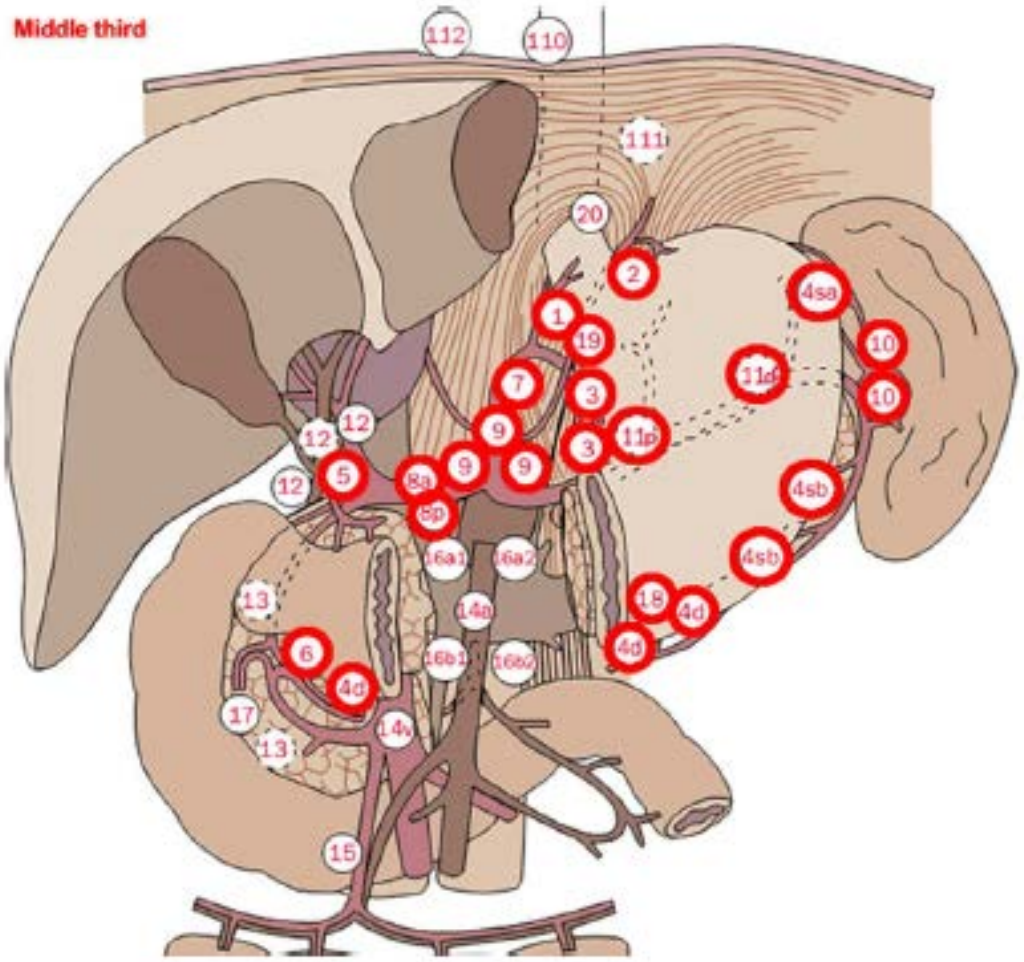

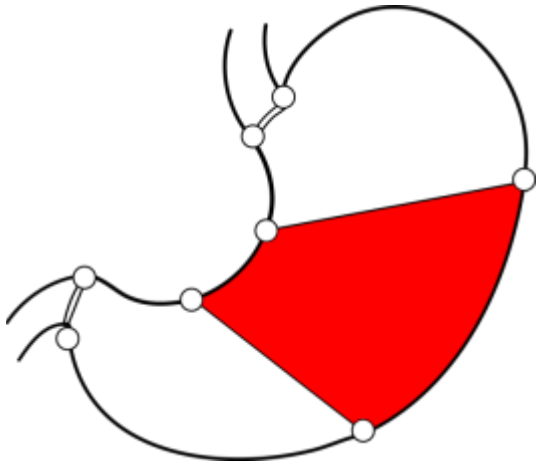

High Risk

Matzinger O et al – Raadiother Oncol – 2009

Lymph nodes recurrences after D2 dissection, in stage III (N+)

Tumor site	Lymph node stations	Rate (%)
Middle 3rd	**16** (aortic) **12** (hepato-gastric) **14** (SMA)	> 50% 26% 10%

Yoon HI et al – Radiother Oncol - 2013

CTV Definition:
Nodal CTV delineation for Upper 3rd

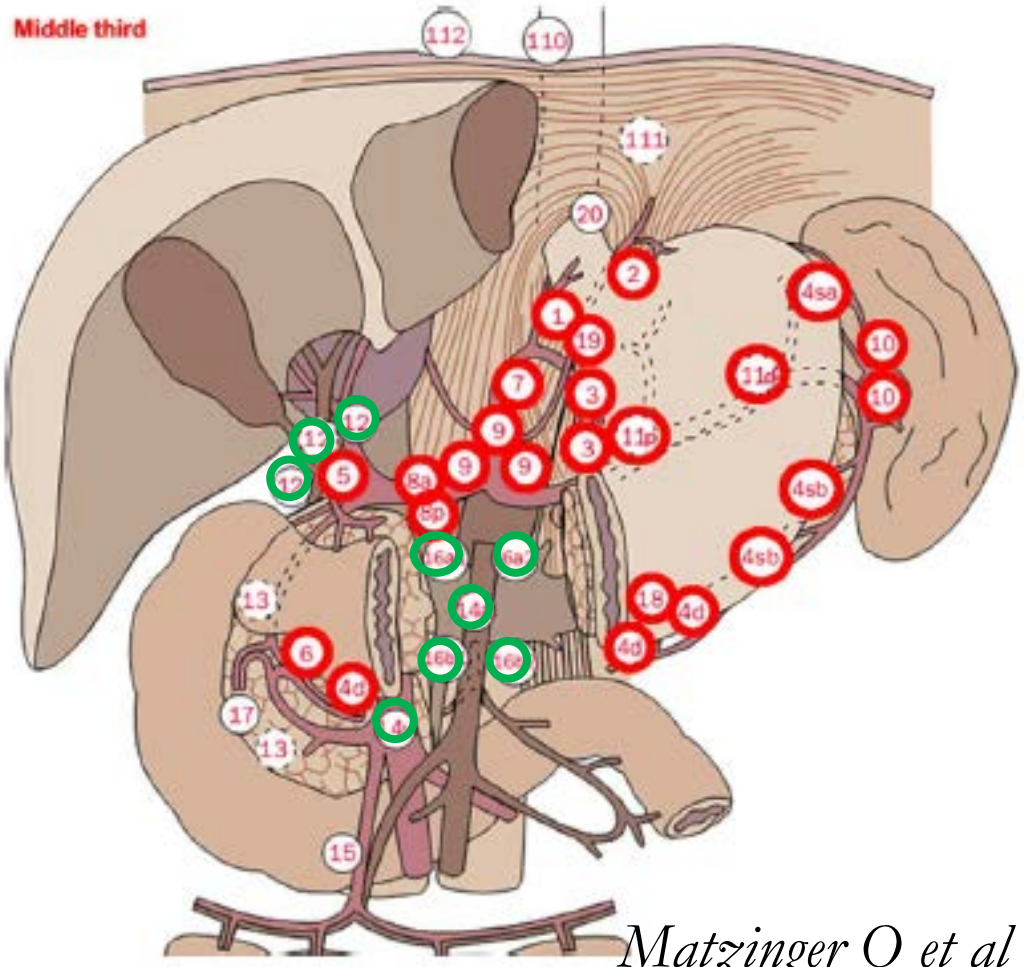

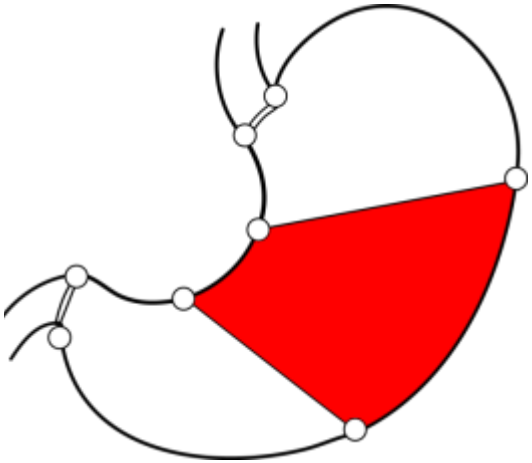

High Risk

If N+

Matzinger O et al – Raadiother Oncol – 2009

Yoon HI et al – Radiother Oncol - 2013

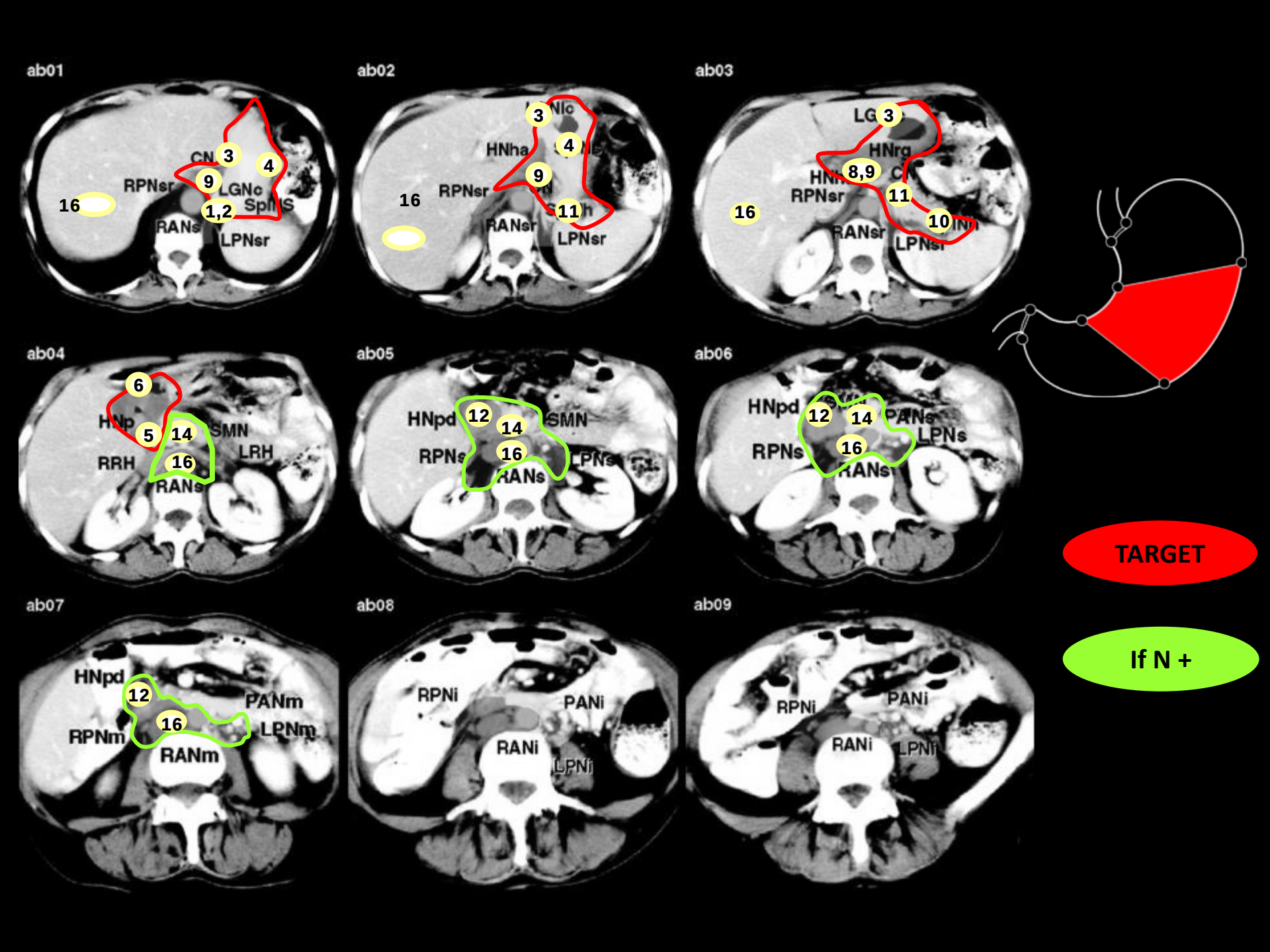
ab01
CN
3
4
9
RPNsr
LGNc
16
1,2
RANs
LPNsr
ab02
3
HNha
4
9
16
RPNsr
11
RANsr
LPNsr
ab03
LG
3
HNrg
8,9
RPNsr
11
16
10
RANsr
LPNsr
ab04
6
HNp
5
14
SMN
RRH
16
LRH
RANs
ab05
HNpd
12
14
SMN
RPNs
16
RANs
ab06
HNpd
12
14
PANs
LPNs
RPNs
16
RANs
ab07
HNpd
12
PANm
16
RPNm
LPNm
RANm
ab08
RPNi
PANi
RANi
LPNi
ab09
RPNi
PANi
RANi
LPNi
TARGET
If N +

CTV Definition:
CTV & Field definition for Middle3rd

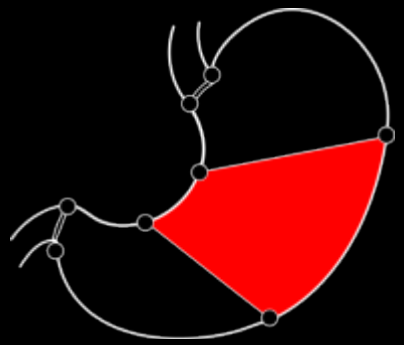

3D BEV

Preop

CTV Definition Lower 3rd

Nodal Group	Station Number	Upper 3rd (%)	Middle 3rd (%)	Lower 3rd (%)
		N = 339	N = 318	N = 150
Paracardia	1 – 2	22	9	
Lesser/Greater Curvature	3 – 4	25	36	37
Suprapyloric	5			12
Infrapyloric	6		15	49
Left Gastric Artery	7	19	22	23
Common Epatic Artery	8	7	11	25
Celiac Axis	9	13	8	13
Splenic Artery/Hilum	10 – 11	11		
Hepatoduodenal Ligamentum	12			8
Others (distant nodes)	13 – 16			

Tepper JE, Gunderson L – Radiother Oncol - 2002

CTV Definition:
Nodal CTV delineation for Lower 3rd

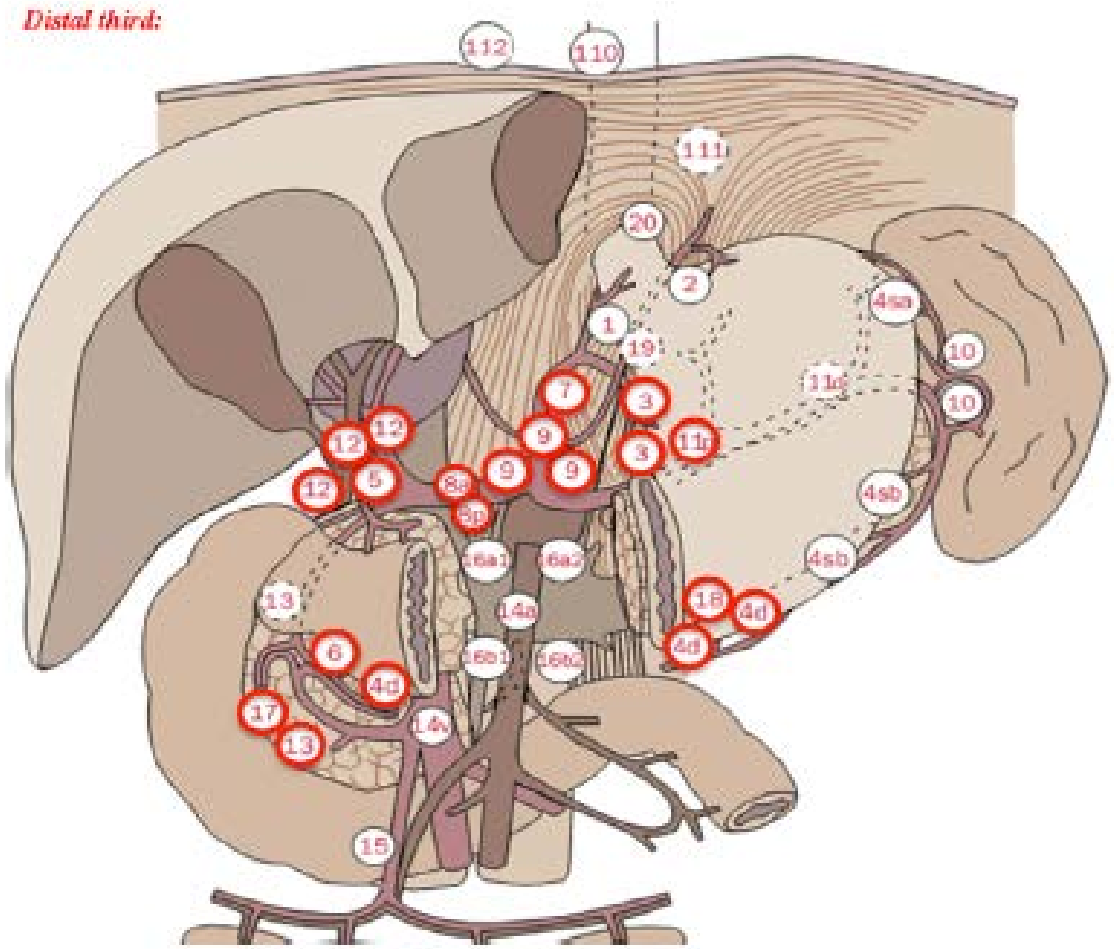

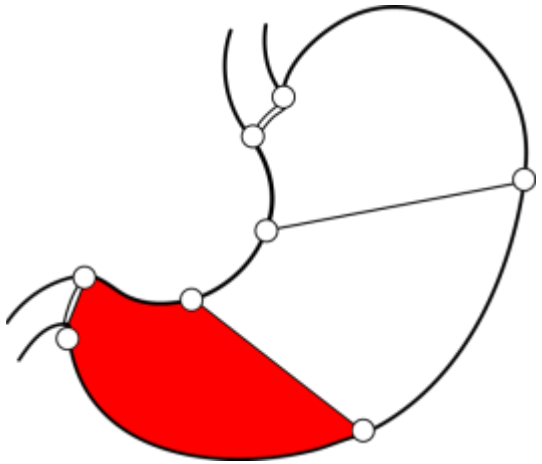

○ High Risk

Lymph nodes recurrences after D2 dissection, in stage III (N+)

Tumor site	Lymph node stations	Rate (%)
Lower 3rd	**16** (aortic)	> 50%
	14 (SMA)	41%
	12 (hepato-duodenal)	24%
	11 (splenic artery)	12%
	9 (celiac)	12%
	2 (left paracardia)	12%

Yoon HI et al – Radiother Oncol - 2013

CTV Definition:
Nodal CTV delineation for Lower 3rd

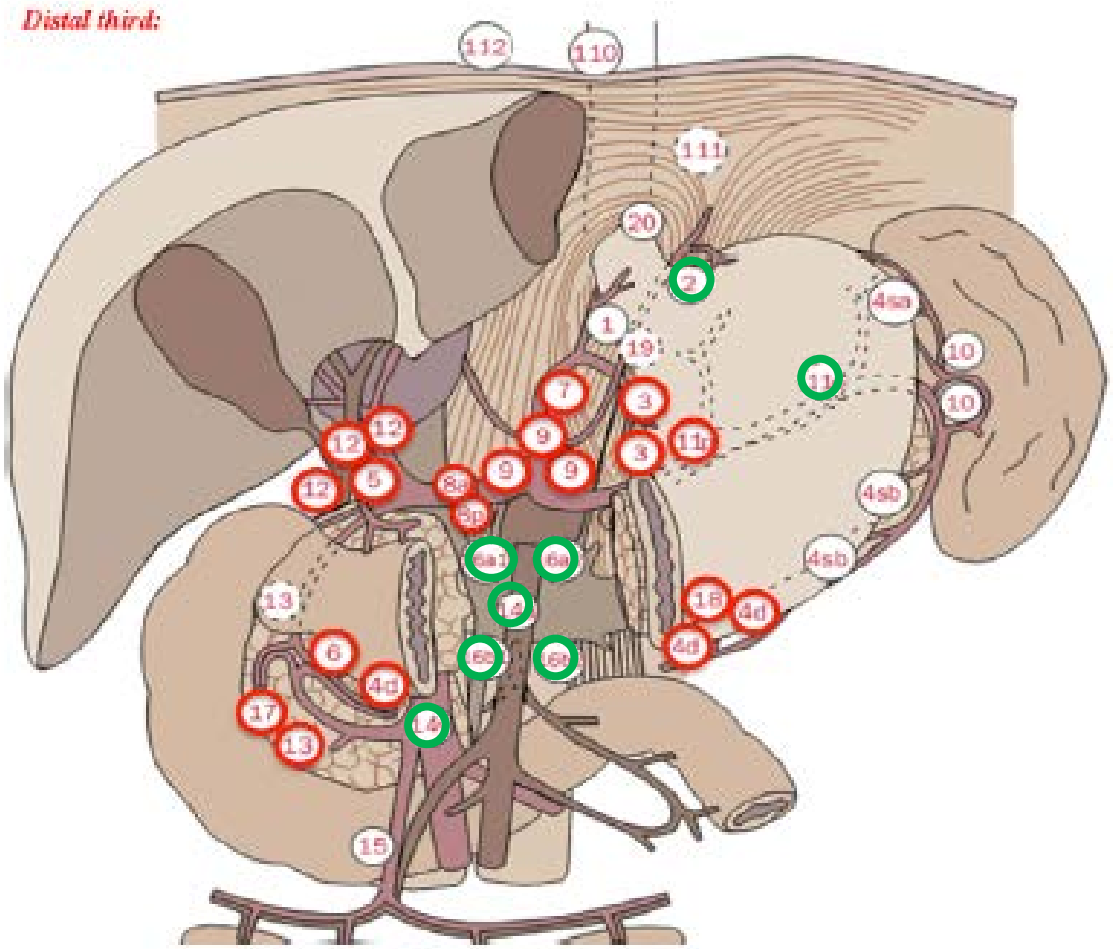

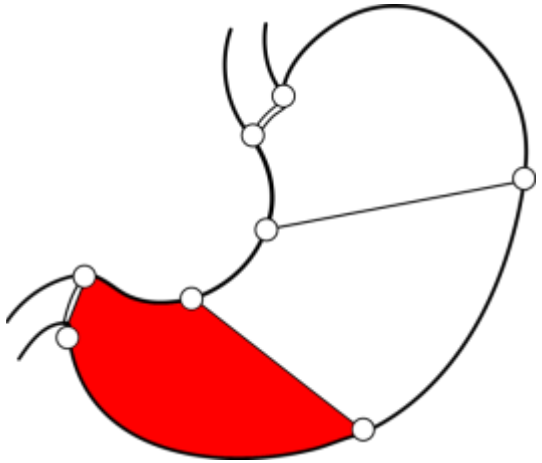

High Risk

If N+

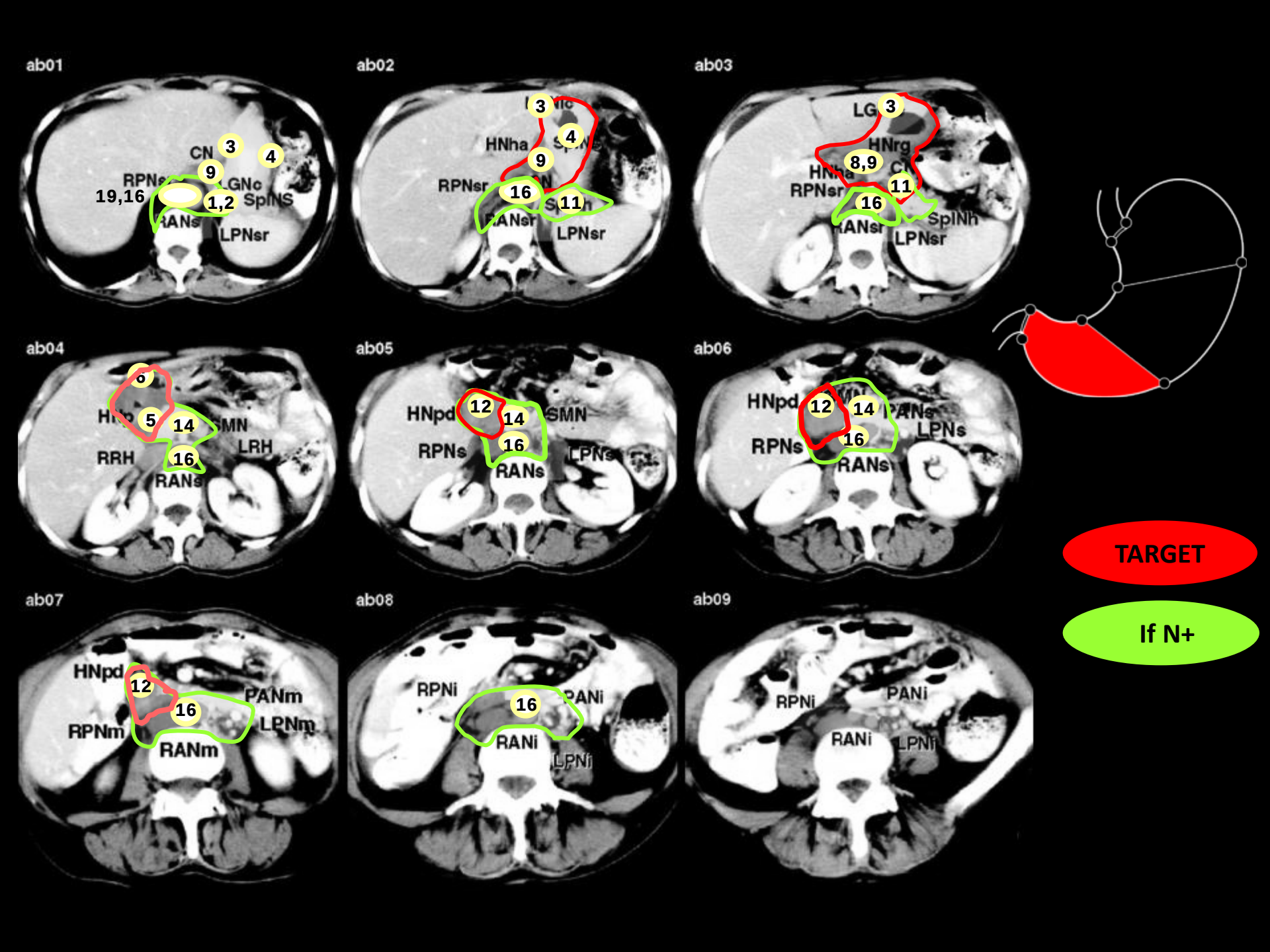
ab01
CN
3
4
9
RPNs
LGNc
19,16
1,2
SplNS
RANs
LPNsr
ab02
3
HNha
4
9
RPNsr
16
11
LPNsr
ab03
LG
3
HNrg
8,9
RPNsr
11
16
SplNh
LPNsr
ab04
5
14
SMN
LRH
RRH
16
RANs
ab05
HNpd
12
14
SMN
RPNs
16
RANs
ab06
HNpd
12
14
RPNs
16
LPNs
ab07
HNpd
12
PANm
16
RPNm
LPNm
RANm
ab08
RPNi
16
PANi
RANi
LPNi
ab09
RPNi
PANi
RANi
LPNi
TARGET
If N+

CTV Definition:
CTV & Field definition for Lower 3rd

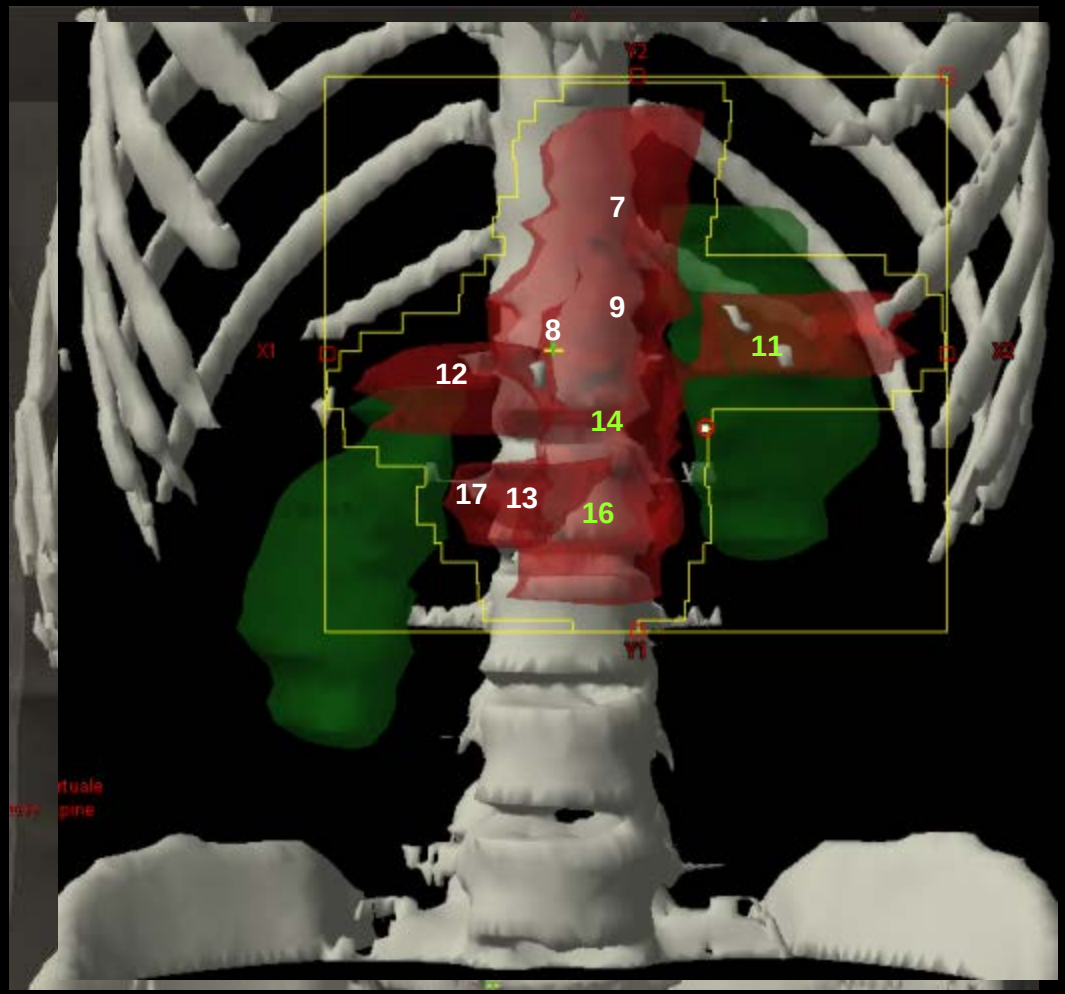

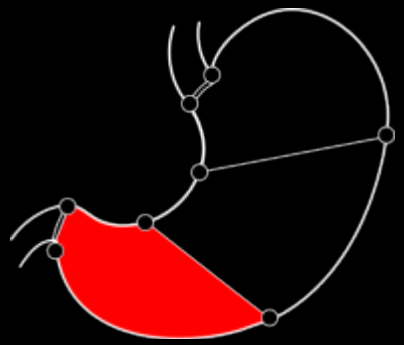

3D BEV

Post-op

Inter-observer variability: Post-op without delineation protol

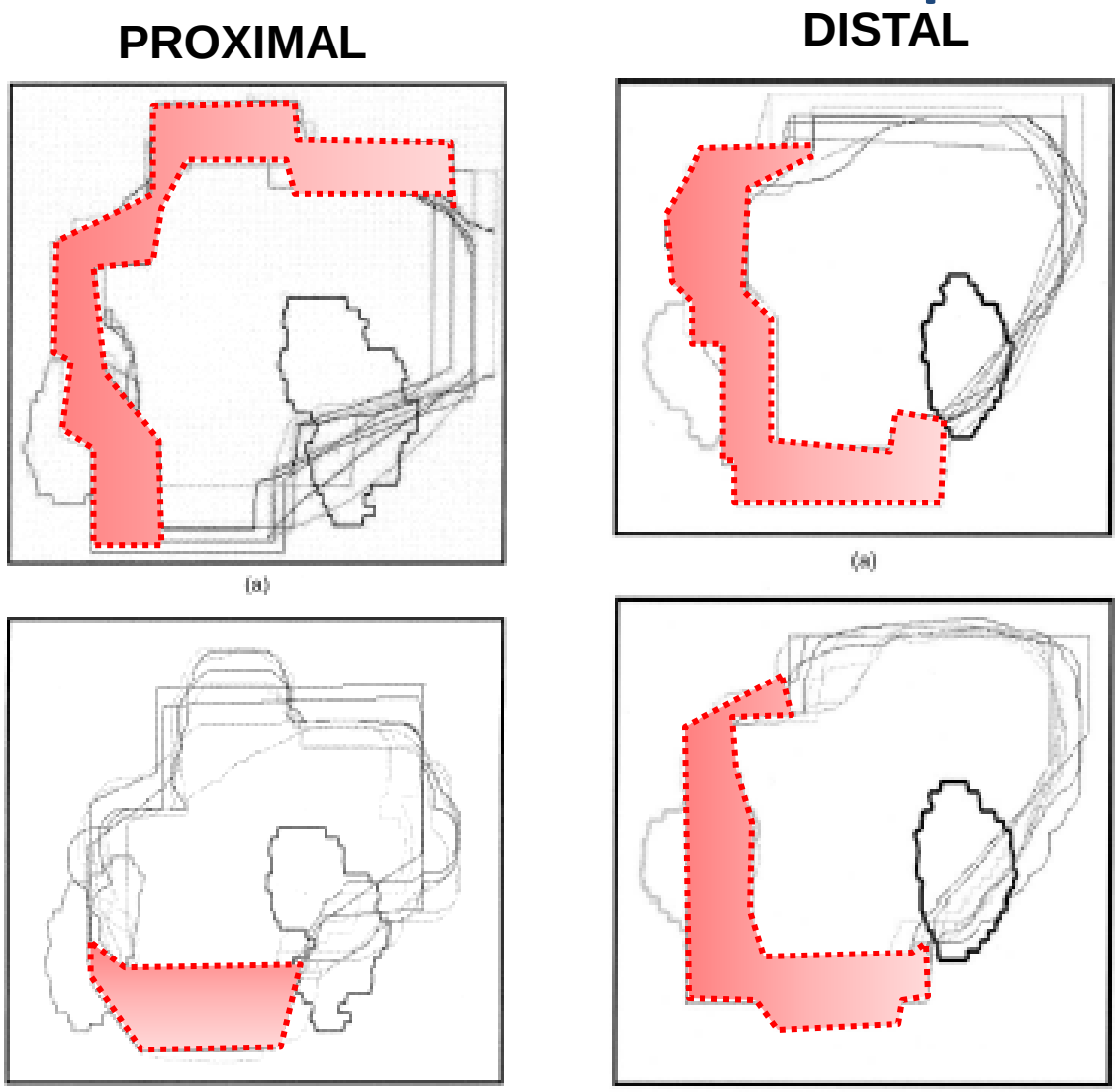

Chung HT et al– IJROBP- 2004

Inter-observer variability: Post-op with delineation protocol

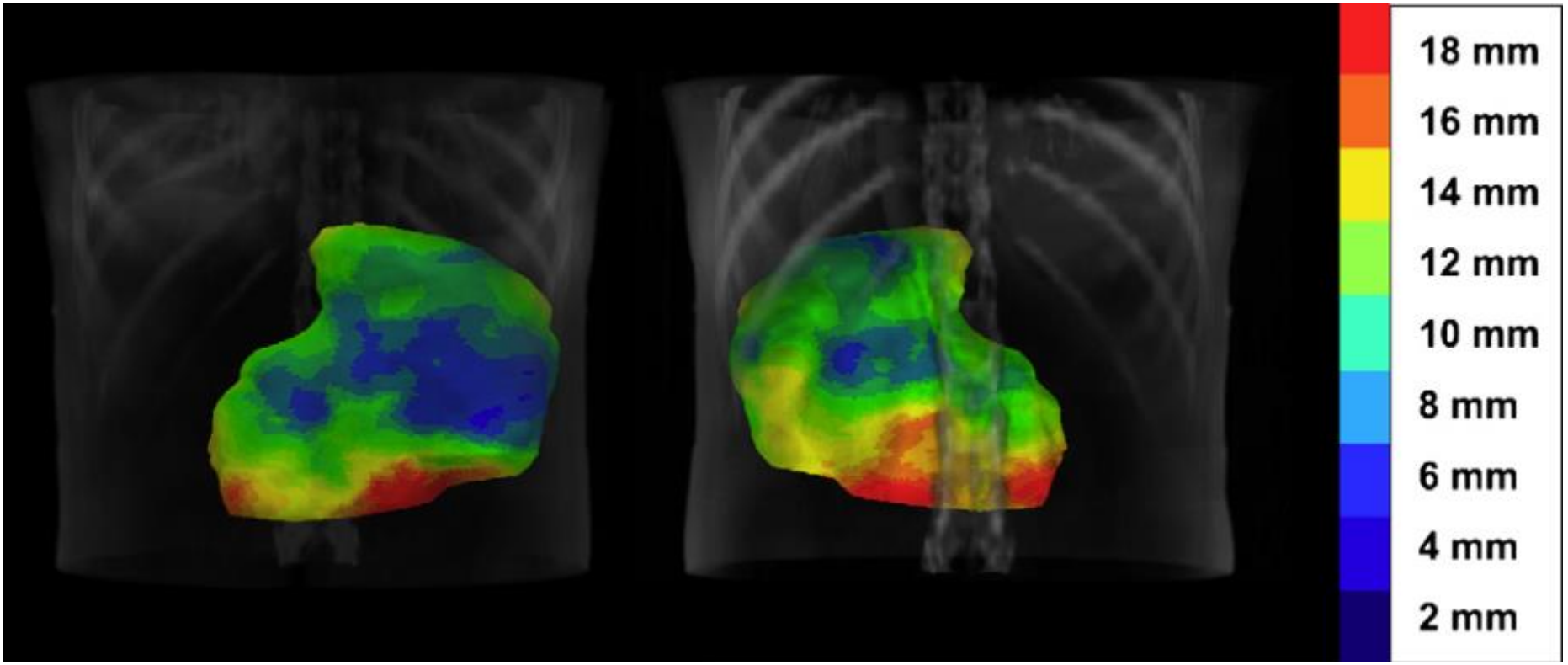

Jansen PM et al– IJROBP- 2010

ITV and PTV

‘Individualized identification of target volume motion has to be performed if possible’

If NOT:

ITV-volume = CTV + 1.5 cm

PTV-volume = ITV + 0.5 cm

Matzinger O et al – Raadiother Oncol – 2009

ITV post-op: remnant

Figure 1. Picture showing gastric remnant contours during course of image-guided intensity-modulated radiotherapy. Megavoltage CT from various fractions is overlaid on Day 1.

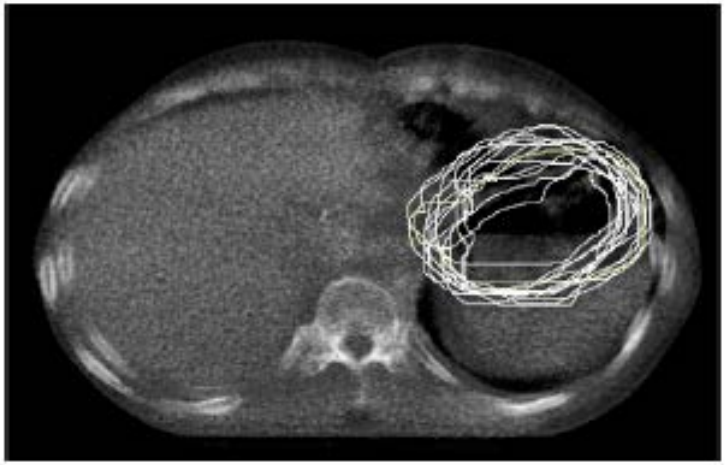

Figure 2. Picture showing the gastric remnant going out of the contoured gastric remnant during daily treatment as seen on megavoltage CT matched with the planning scan.

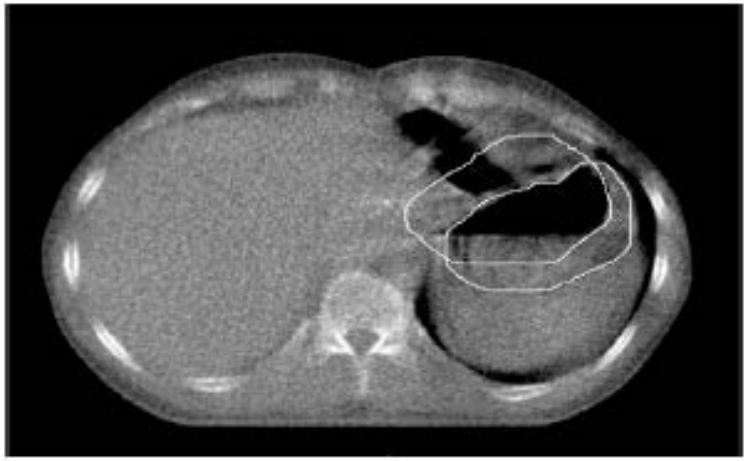

Table 4. The population set-up errors and clinical target volume (CTV) to internal target volume (ITV) margins for three directions

Displacement	Systematic error (mm)	Random error (mm)	CTV to ITV margin (van Herk)	Mean + 2SD
Mediolateral	6	6	19.2	20
Superoinferior	4	5	13.5	15
Anteroposterior	2	4	7.8	9

SD, standard deviation.

Aggarval A et al – BJR - 2013

Organ At Risk

INT-0116: compliance to chemoradiation

REASON FOR CESSATION (281 pts in chemo group)	NO. OF PATIENTS	(%)
Protocol treatment completed	181	(64)
Toxic effects	**49**	**(17)**
Patient declined further treatment	23	(8)
Progression of disease	13	(5)
Death	3	(1)
Other	12	(4)

Mcdonald JS et Al – New England Journal of Medicine - 2001

INT-0116: Side Effects (Grade 3 - 4 WHO)

TYPE OF TOXIC EFFECT	NO. OF PATIENTS	(%)
Hematologic	**148**	**(54)**
Gastrointestinal	**89**	**(33)**
Influenza-like	25	(9)
Infection	16	(6)
Neurologic	12	(4)
Cardiovascular	11	(4)
Pain	9	(3)
Metabolic	5	(2)
Hepatic	4	(1)
Lung-related	3	(1)
Death	3	(1)

Mcdonald JS et Al – New England Journal of Medicine - 2001

OARs constraints and delineation

organ	Toxicity	dosimetric parameters	delineation
	Myelopathy	Dmax < 45 Gy Dmax < 40Gy (when conc CT)	2 cm above and belove the CTV
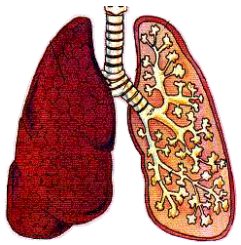	Post-op Pneumonitis ARDS	V10Gy < 40% V15 Gy < 30% V20 Gy < 40% V5 Gy < 2300 cc	Both lungs
	Pericardium Myocardium Coronary reduction EF	V25 Gy< 50% V40 Gy < 30%	Entire heart
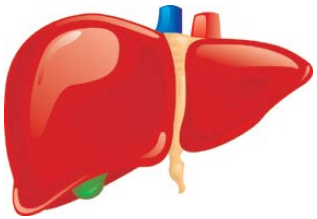	Radiation Induced Liver Disease	V30 Gy < 30%	Entire liver

QUANTEC– IJROBP- 2010

OARs constraints and delineation

organ	Toxicity	dosimetric parameters	delineation
	Critical relevant **renal dysfunction**	**Omolateral V20 < 70%** **Controlateral V20 < 30%** **Combined Functional Renal V20 <50%**	**Both kidneys Separate and combined**
	Grade 3+ acute toxicity	**V15 < 120 cc** **V45 < 195 cc**	**Bowel loops** **Bowel cavity** (entire potential space in the peritoneal cavity)

QUANTEC– IJROBP- 2010

Conclusions: Target Volume Definition

GTV:

- only in preoperative, included in the CTV, **NO boost volume**

CTV:

- **Modulated**: surgery, tumor site, tumor stage
- **Challenging**: CT axial anatomy (post-operative)
- **Variability**: large inter-observer also with GL

ITV:

- Movement is critical in **pre-operative or partial gastrectomy**

ANATOMY & LYMPH NODE DRAINAGE FOR LOWER GI CANCER

Dr Brendan Carey

St James's University Hospital

Leeds

UK



Imaging Techniques to show GTV anatomy

Normal & Tumour anatomy

Lymph Node Drainage

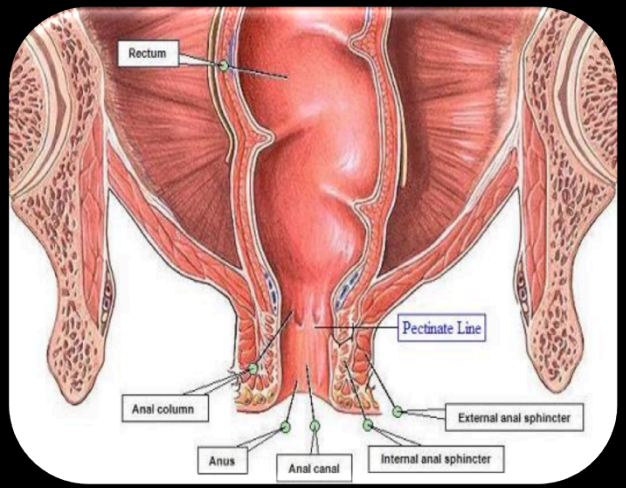

Use *ALL* available information- clinical and imaging to define anatomy for treatment volumes

Low rectal cancer:
0- 5 cm from the anal verge

Mid rectal cancer:
5-10 cm from the anal verge

High rectal cancer:
10-15 cm from the anal verge

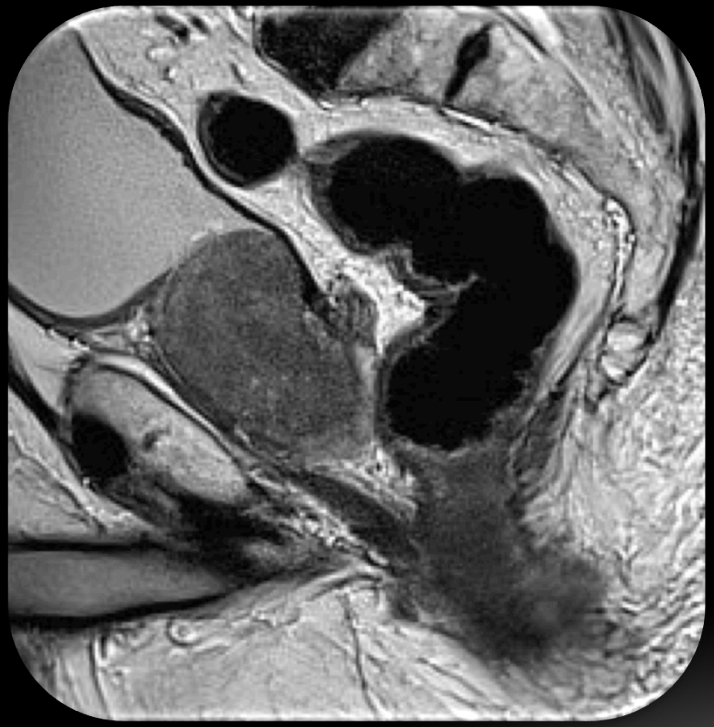

The rectosigmoid junction is arbitrarily defined as 15 cm above the anal verge.
A tumor more than 15 cm above the anal verge is regarded and treated as a sigmoid tumor.

The anal verge cannot be seen clearly on MRI
- measure from the anorectal angle.

MRI – NORMAL RECTUM

Submucosa seen as a higher signal layer deep to low signal muscularis propria

- **Normal rectal ≤ 6mm thick**

MESORECTUM

Contains:

- **Rectum**
- **Fat**
- **Lymph nodes**
- **Vessels**

Variable thickness & surrounds rectum in eccentric fashion

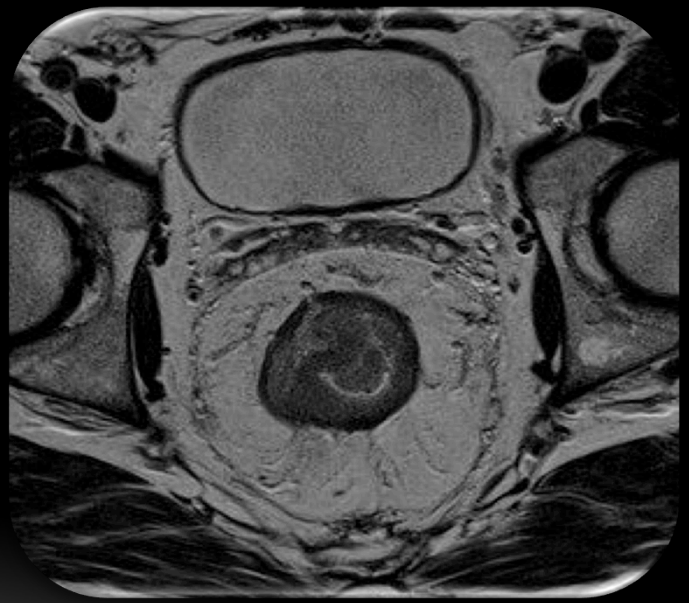

CRM : CIRUMFERENTIAL RESECTION MARGIN

The role of MRI is to determine whether TME-surgery is possible or whether there is an advanced tumour that needs chemoradiation

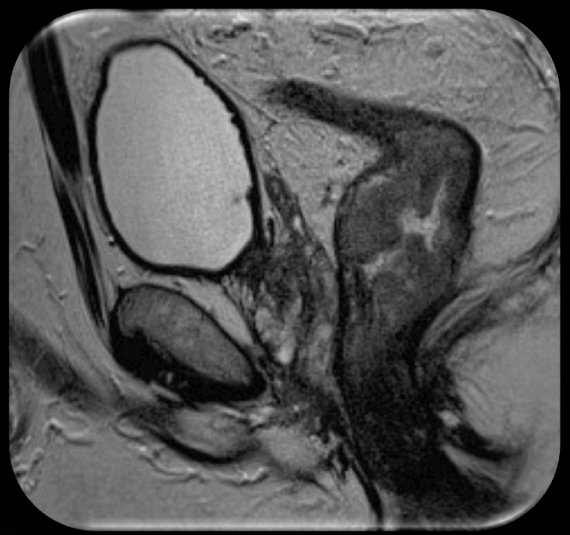

Mesorectal Fascia and CRM

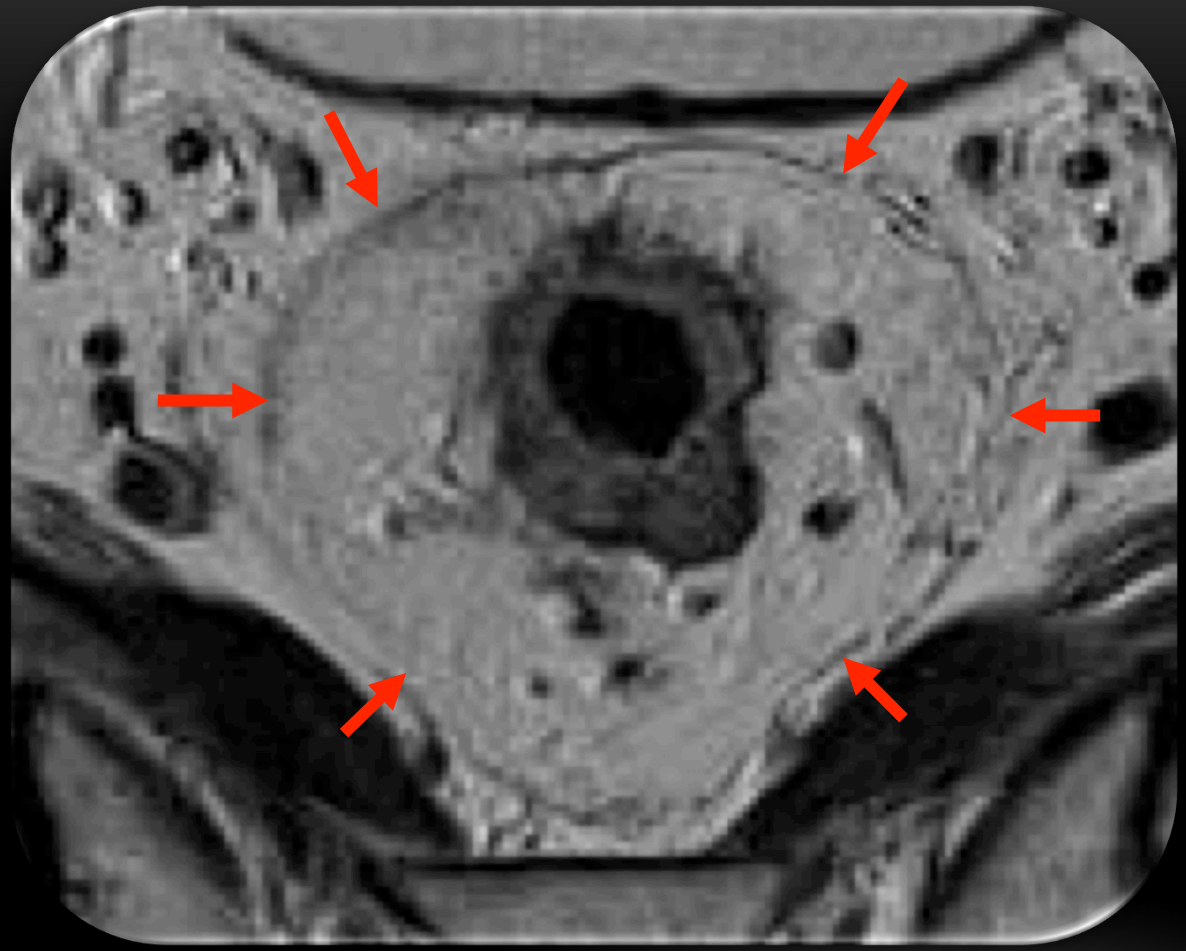

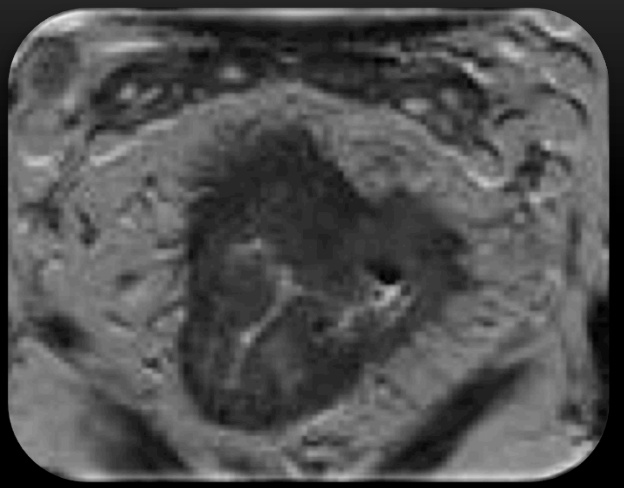

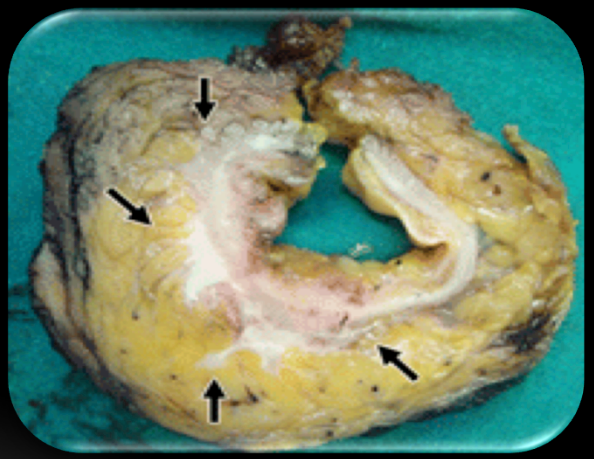

Mesorectal Fascia and CRM

Tumour *involving or within 1mm* of the MRE is a strong predictor for local recurrence

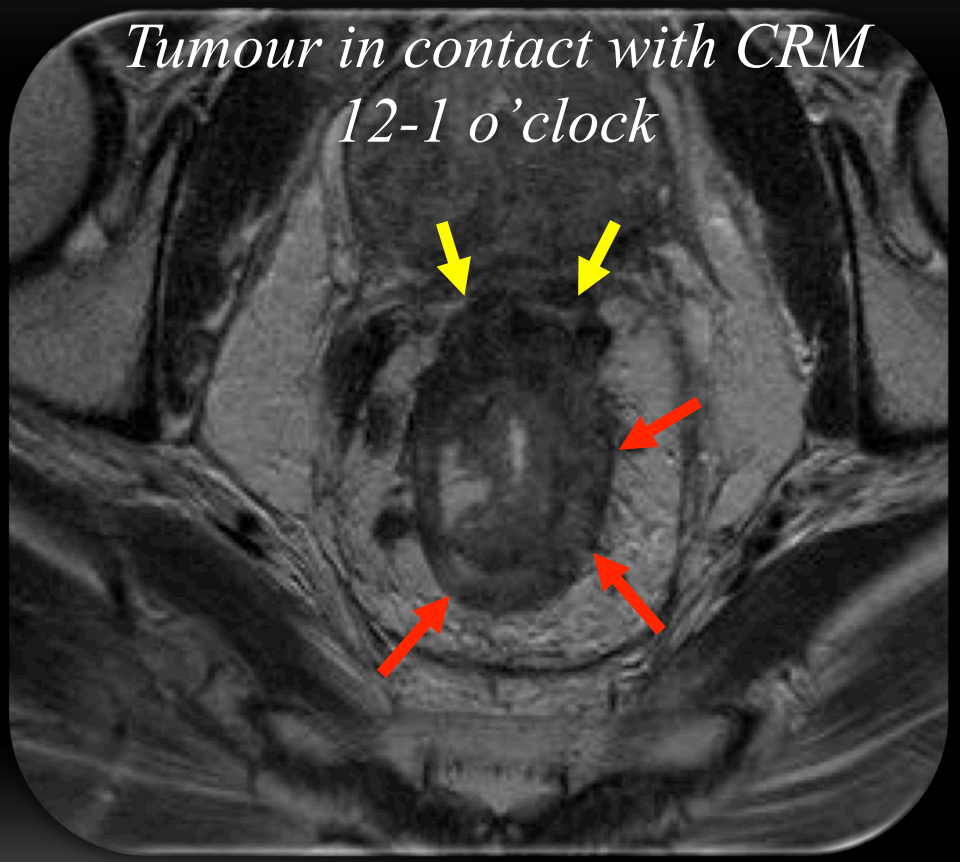

THE CRM ON PLANNING CT

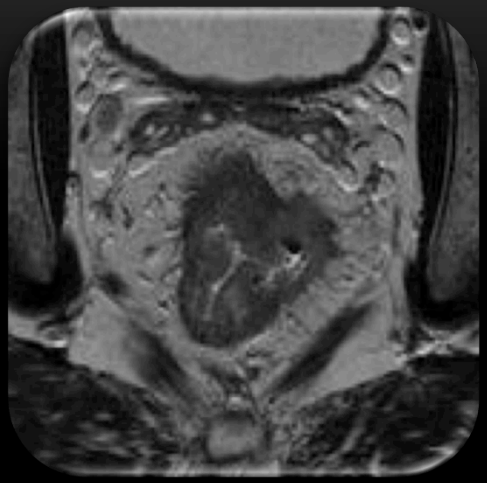

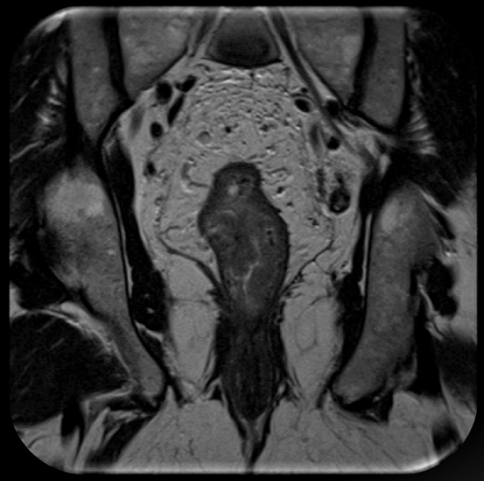

Distance from tumour to CRM more important predictor for local control rate than T stage

T stage does not differentiate between T3 tumours with a wide CRM and narrow CRM

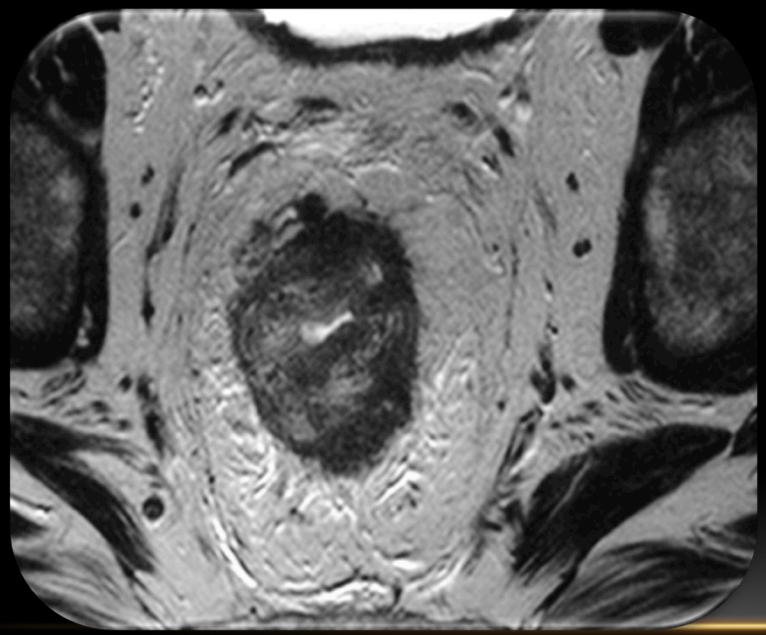

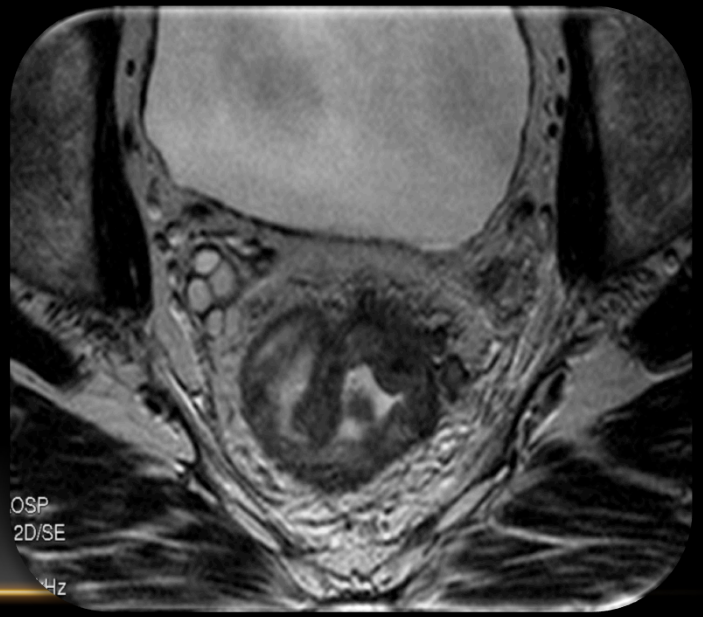

Peritoneal reflection

- **The anterior aspect of the upper and mid rectum has a peritoneal covering**
- **If tumour invades this anterior surface it is Peritoneal invasion (i.e. T4)**

ANATOMY OF RECTAL CANCER ON MRI

Mural thickening, discontinuity of normal anatomic layers, replacement of muscle

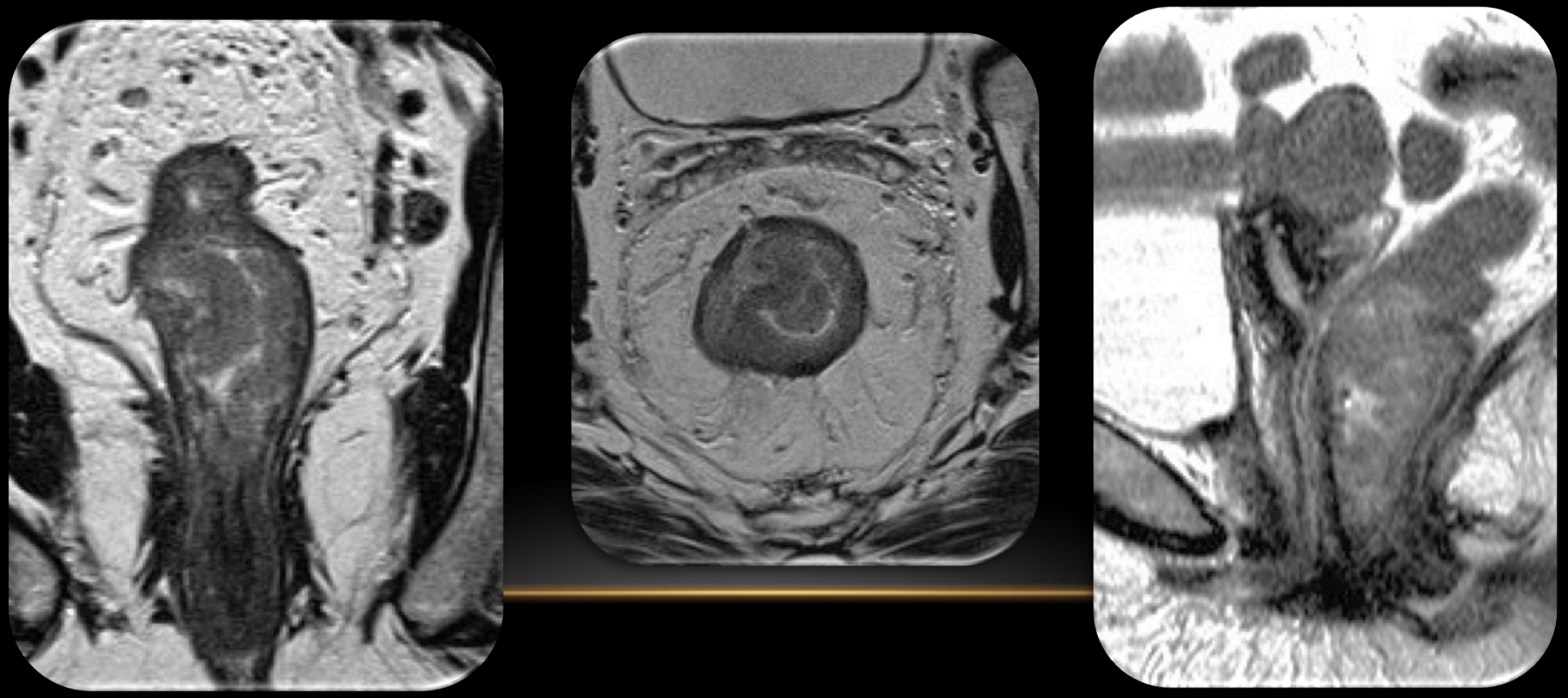

ANATOMY OF RECTAL CANCER

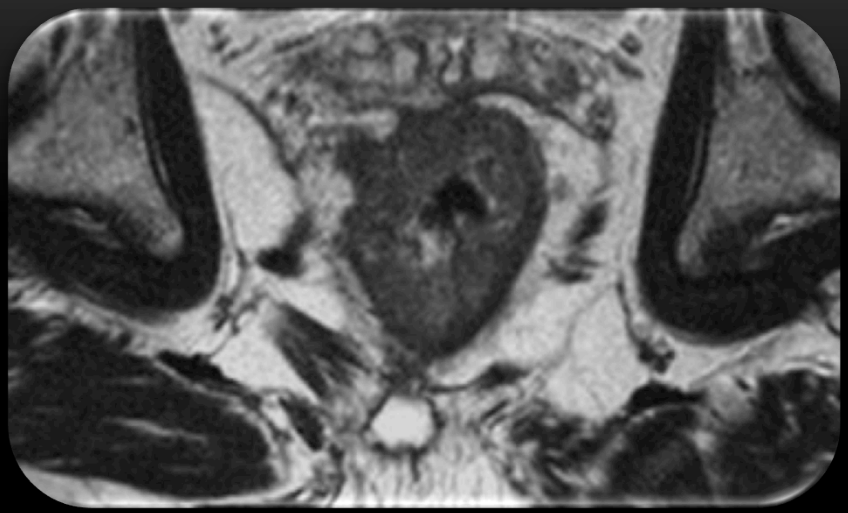

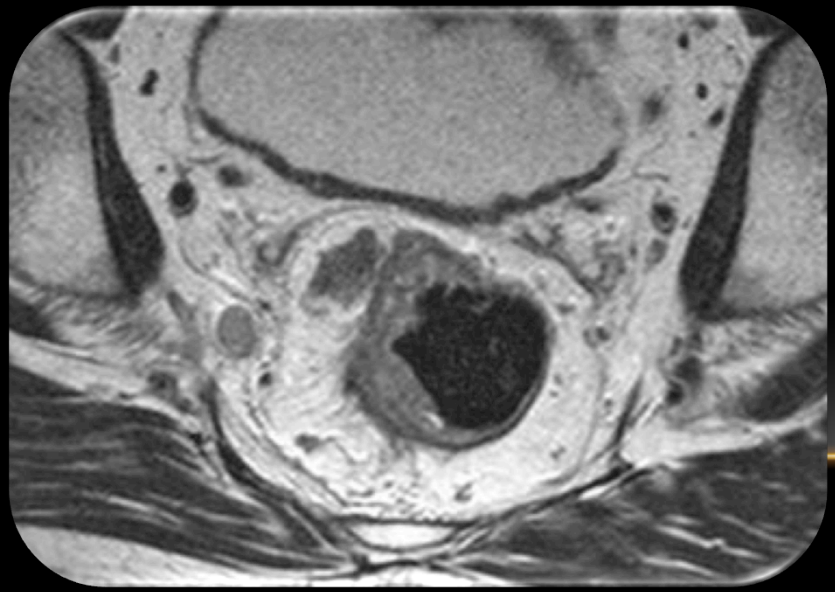

T1 tumour signal in submucosa but no tumour extending into circular layer of muscularis propria

T2 intermediate signal into muscularis propria but no tumour seen in perirectal fat

T3 broad-based mass or nodular projection into perirectal fat

T4 tumour extending into adjacent organs or through peritoneal reflection

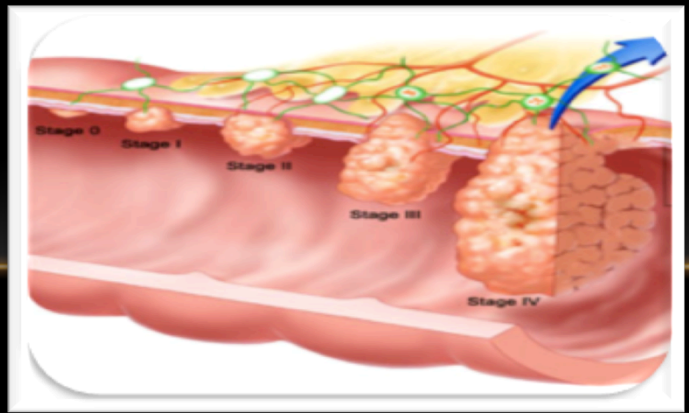

Identify tumour anatomy

Extent of tumour, relationship to mesorectal fascia and sphincters

Nodal assessment

T1 OR T2

Cannot reliably distinguish T1 from T2 tumours on MRI

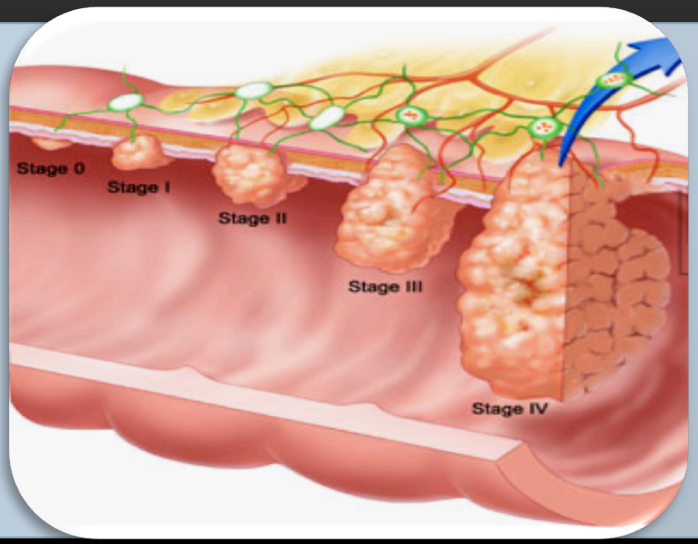

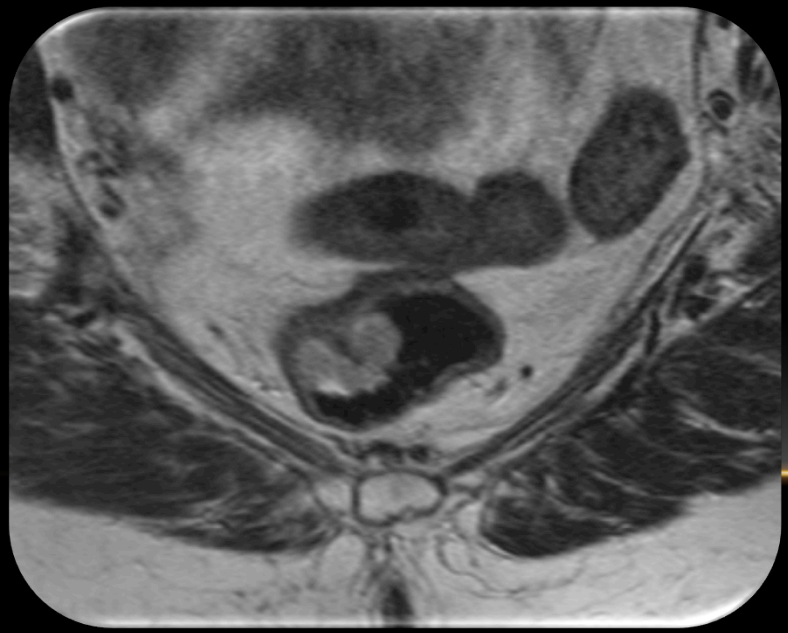

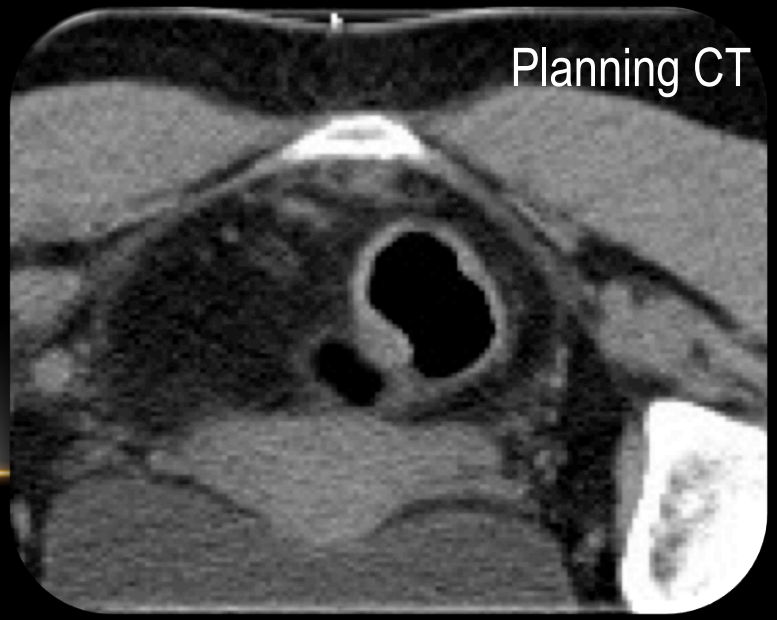

T2 / T3

Some tumours incite a desmoplastic response
-often overstaged by MRI as T3

Mimics T3 disease

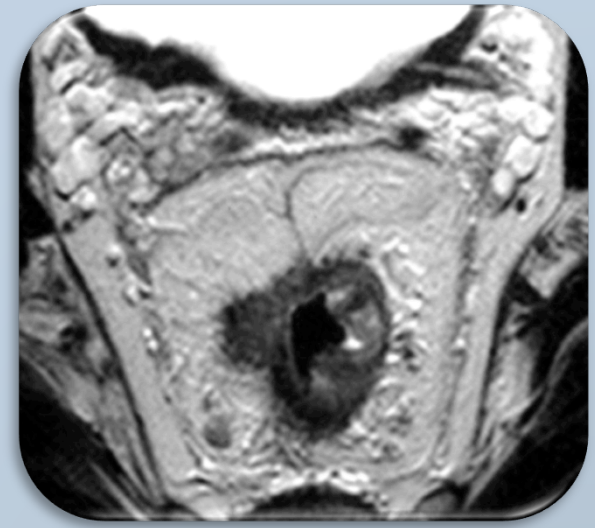

MRI cannot distinguish desmoplasia without tumour cells (pT2) from that with tumour cells (pT3)

T3 RECTAL TUMOURS

- **80% of rectal tumours are T3 at presentation**

Heterogeneous group

- **-full thickness wall involvement /visible tumour in perirectal fat /tumour involving CRMT**
- **T3 broad-based mass or nodular projection into perirectal fat**

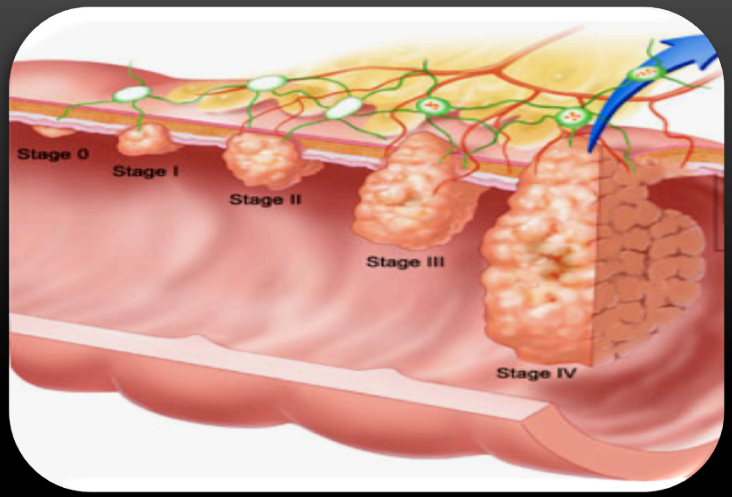

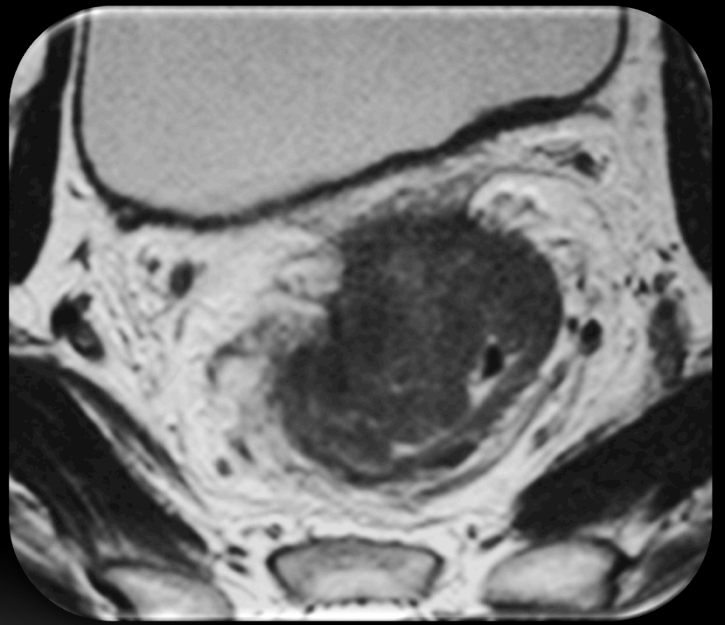

MERCURY study group
Radiology 2007

T3 tumours – "bad"

- Usually offered Chemoradiotherapy *before* surgery

The depth of tumor invasion outside the muscularis propria as measured at MRI was within 0.5 mm of that measured at histopathologic examination

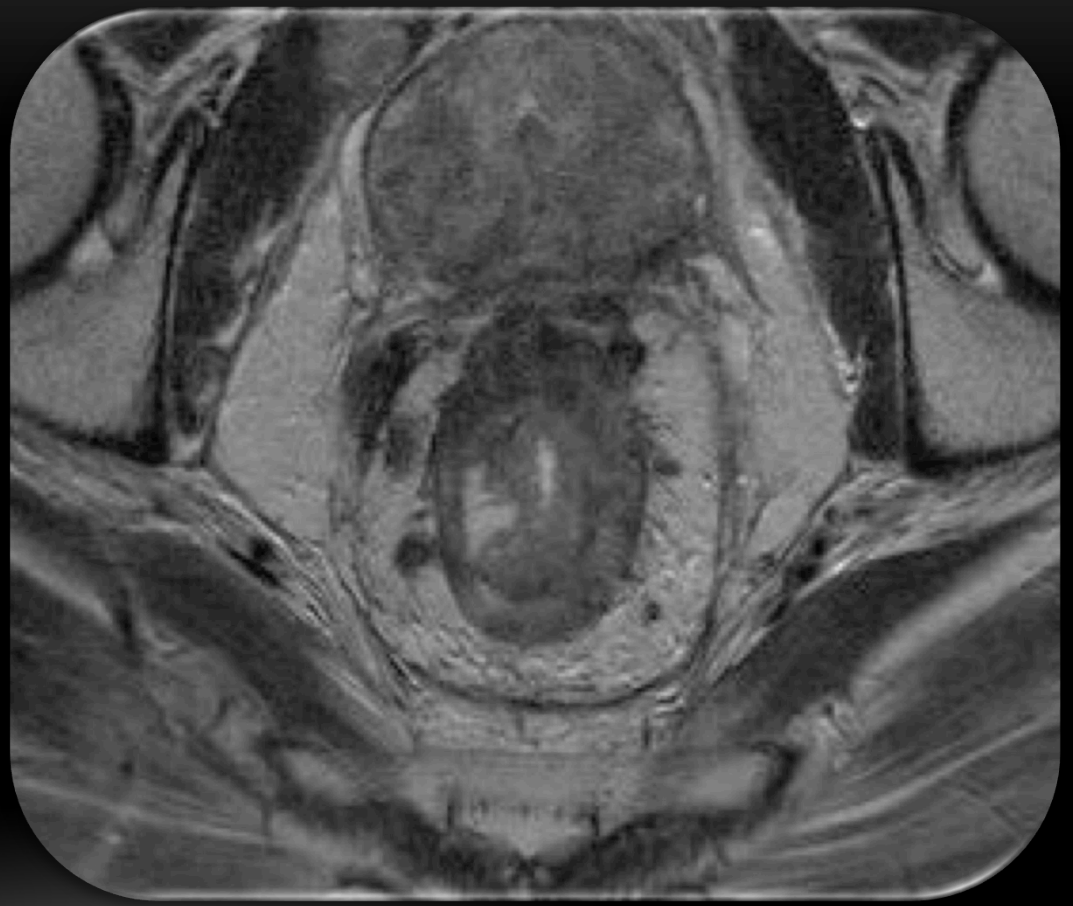

T4 RECTAL TUMOURS

T4 tumour extending into adjacent organs or through peritoneal reflection

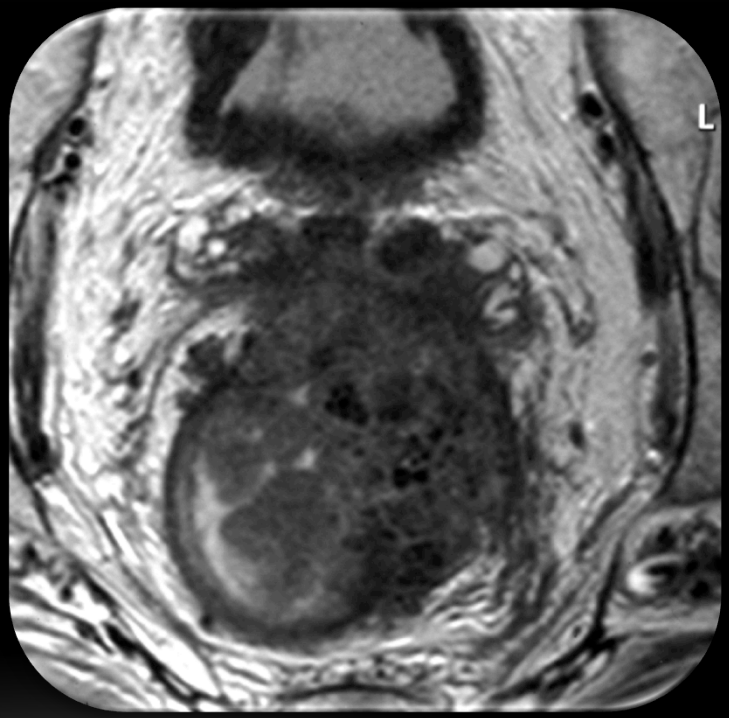

T 4 Rectal Cancer

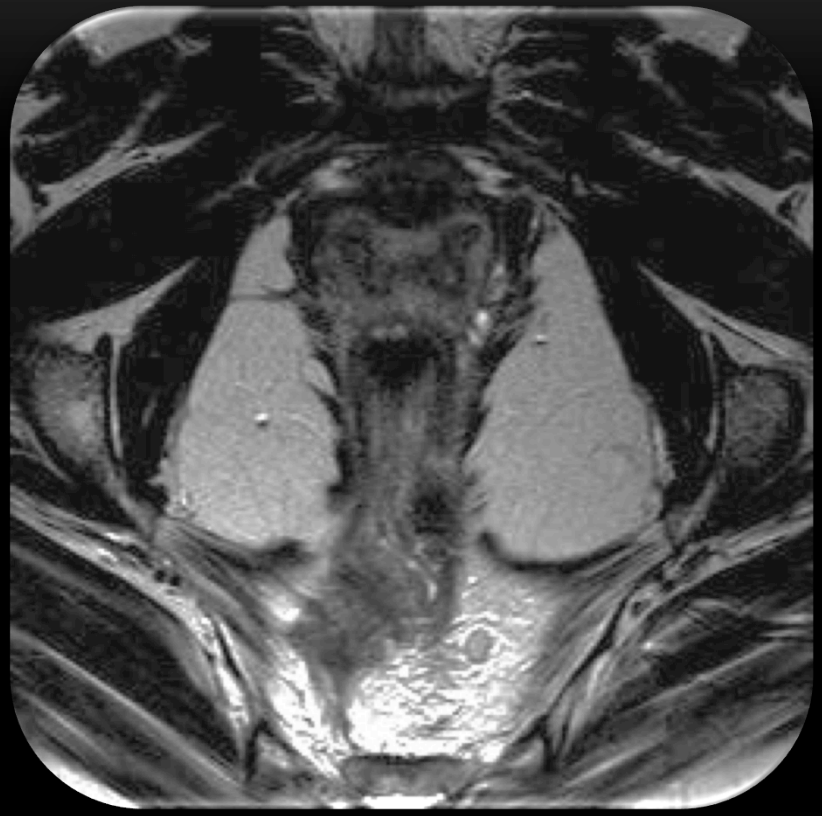

RECTAL CANCER ON MRI

Mucinous adenocarcinomas account for 10-15 % of all colon and rectal adenocarcinomas.

Mucinous tumours are high signal on T2W sequences

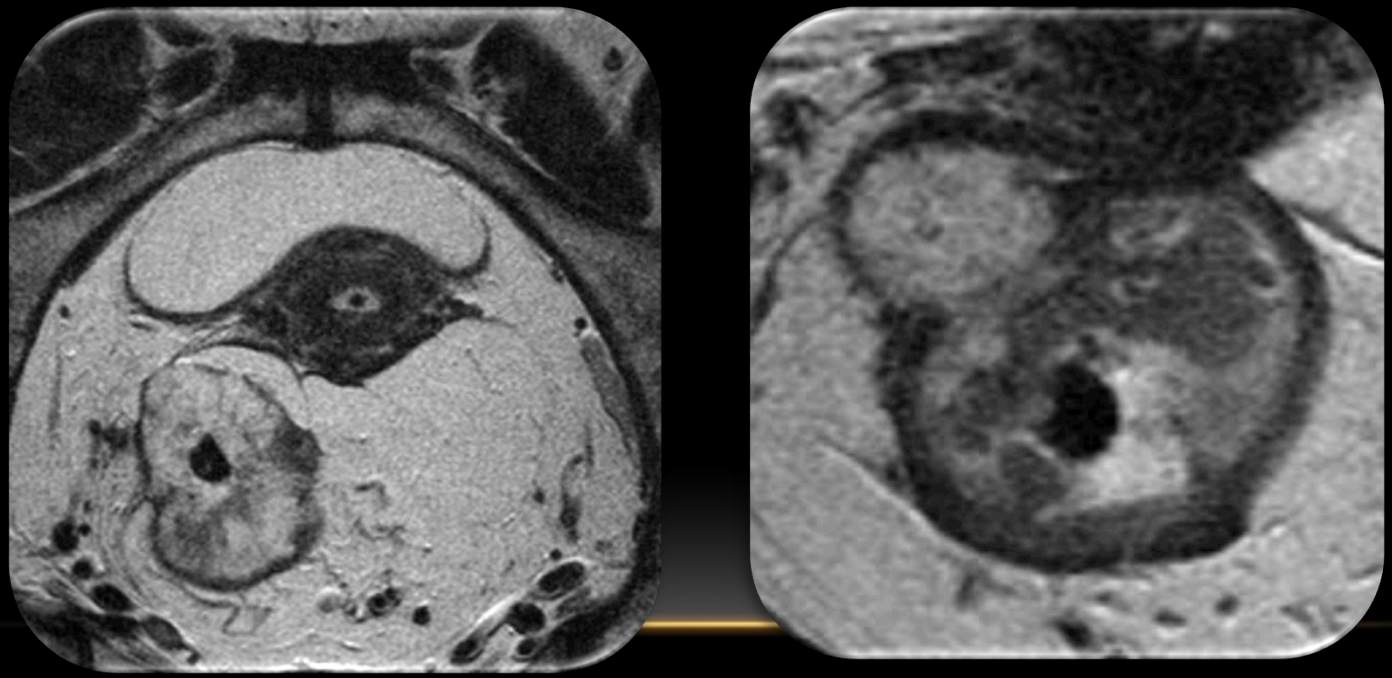

ANATOMY - LOW RECTAL TUMOURS

VERY LOW / ABSENT MESORECTUM → Higher incidence of involved resection margins → Difficult to accurately assess extent of T3

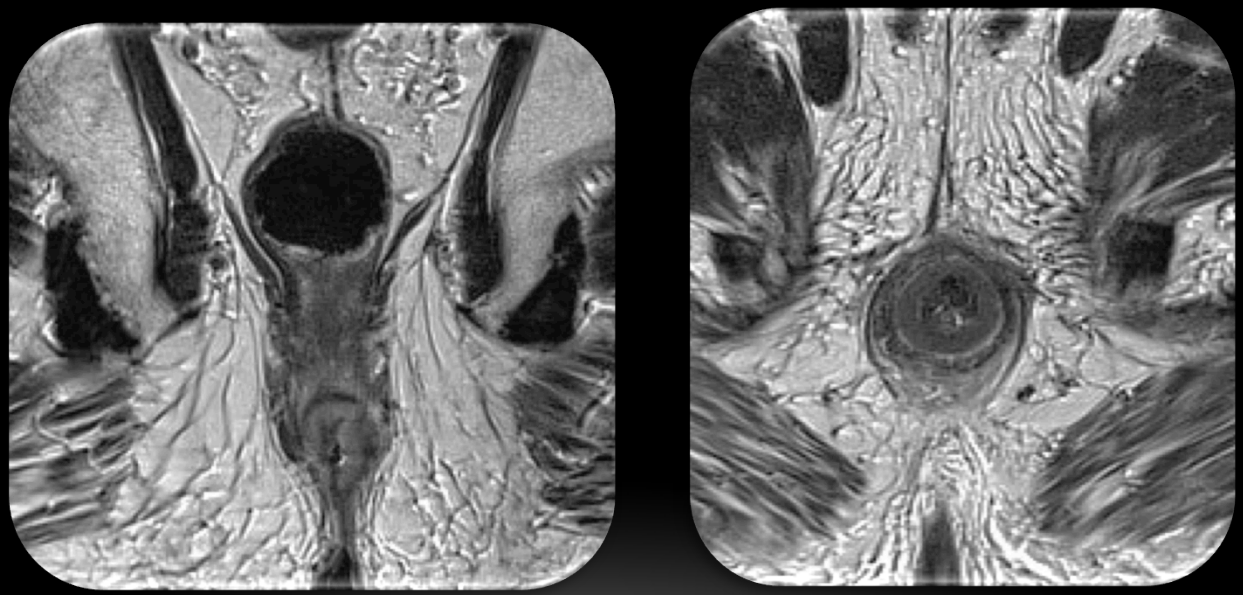

LOW RECTAL TUMOURS: DIAGNOSTIC MRI … PLANNING CT

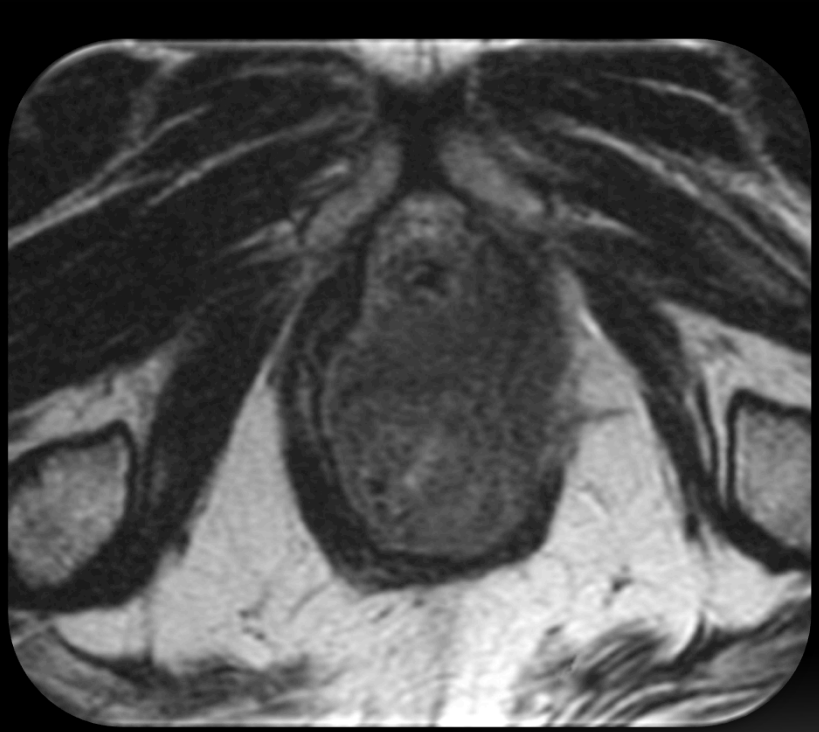

RECTAL CANCER – NODAL STAGING

- **Nx: No description of lymph node involvement is possible because of incomplete information**
- **N0: No lymph node involvement is found**
- **N1: Cancer cells found in 1 to 3 nearby lymph nodes**
- **N2: Cancer cells found in 4 or more nearby lymph nodes**

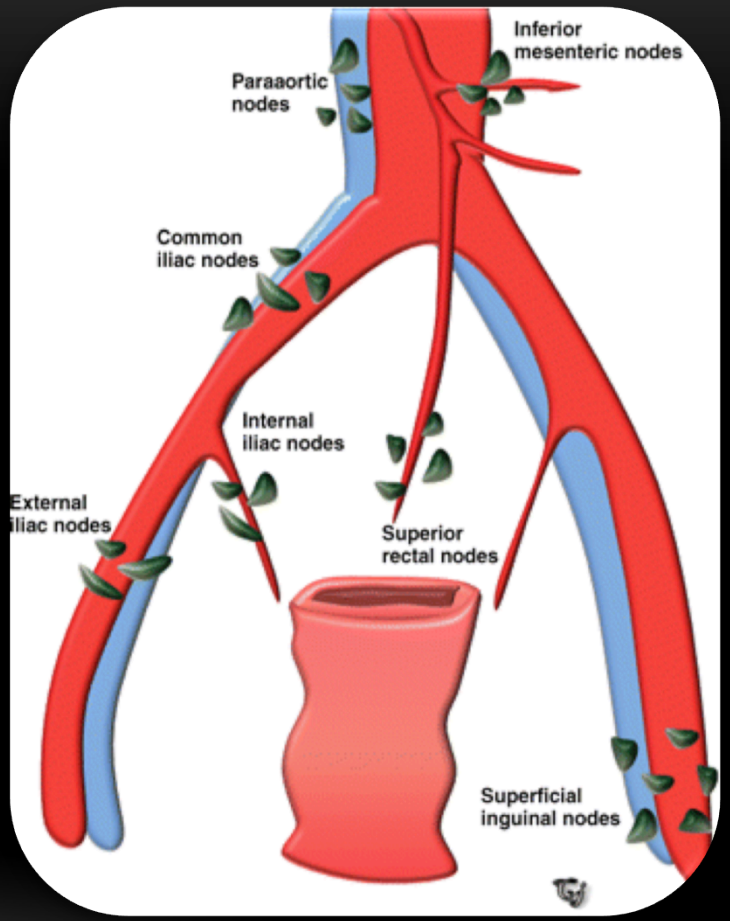

The most common pathway of nodal spread from rectal tumours is to mesorectal nodes, followed by to superior rectal and inferior mesenteric nodes

Midrectal tumours also spread through lymphatic vessels along the midrectal vessels to internal iliac nodes

Low rectal tumours may also involve superficial inguinal nodes.

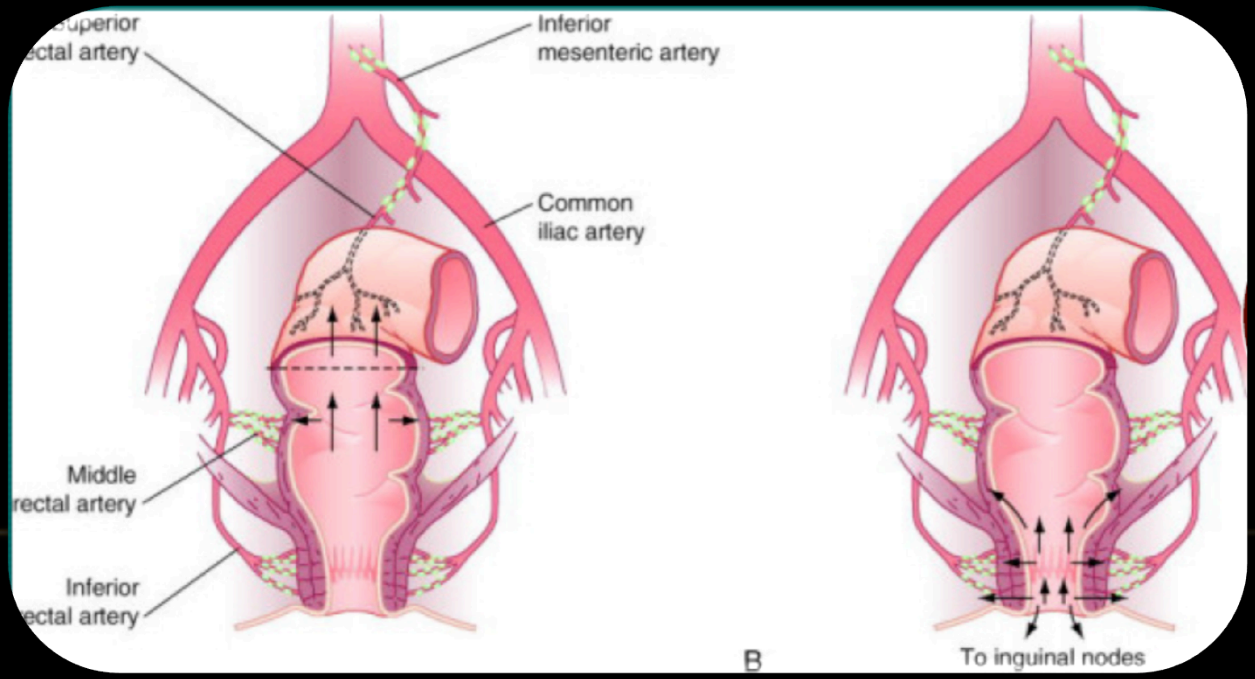

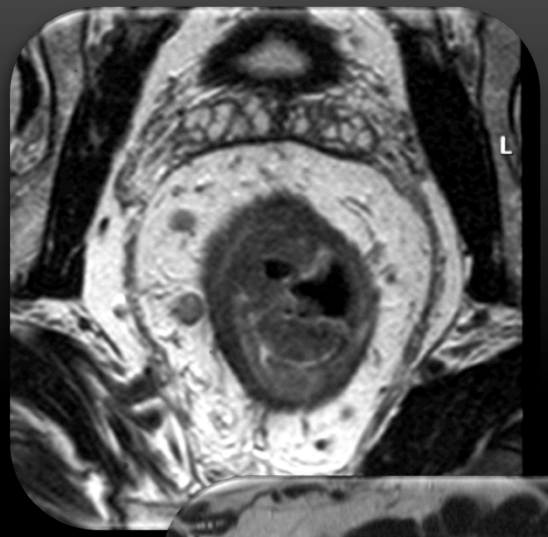

Mesorectal Nodes13%
(pT0) to 64% (pT3)

Inferior Mesenteric Artery nodes
mid/upper tumours

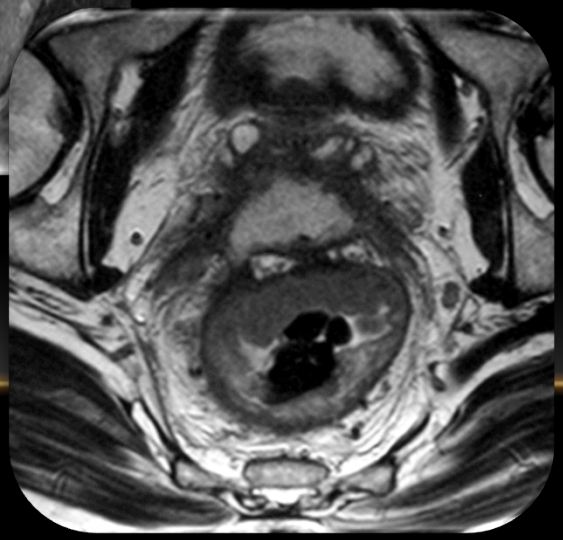

Lateral iliac nodes
mid/lower tumours

Lymph node status is one of the principal indicators of prognosis in patients with rectal cancer.

Nodes lying outside the mesorectal fascia not removed at TME

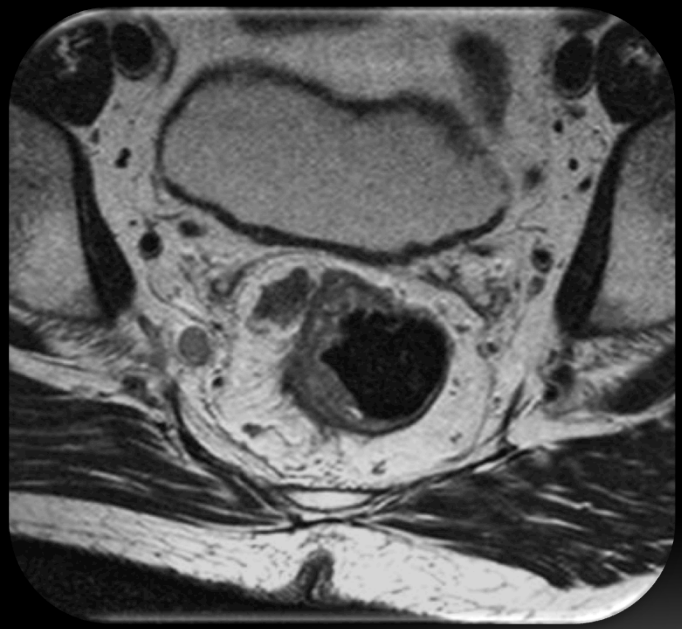

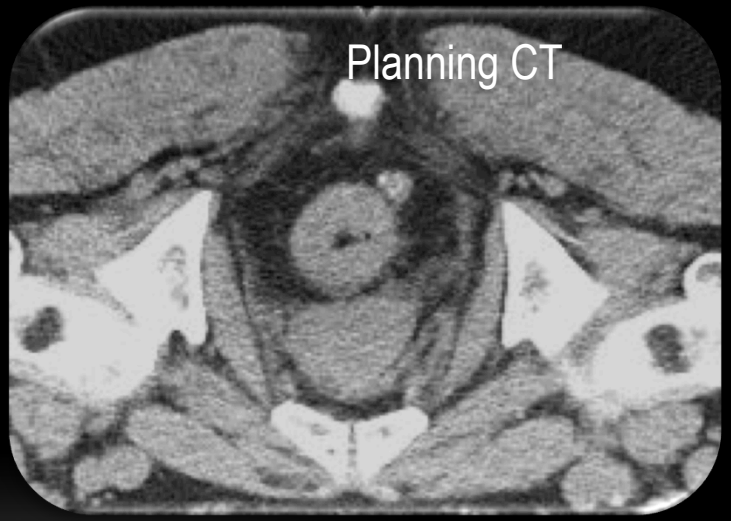

INFERIOR MESENTERIC ARTERY NODES

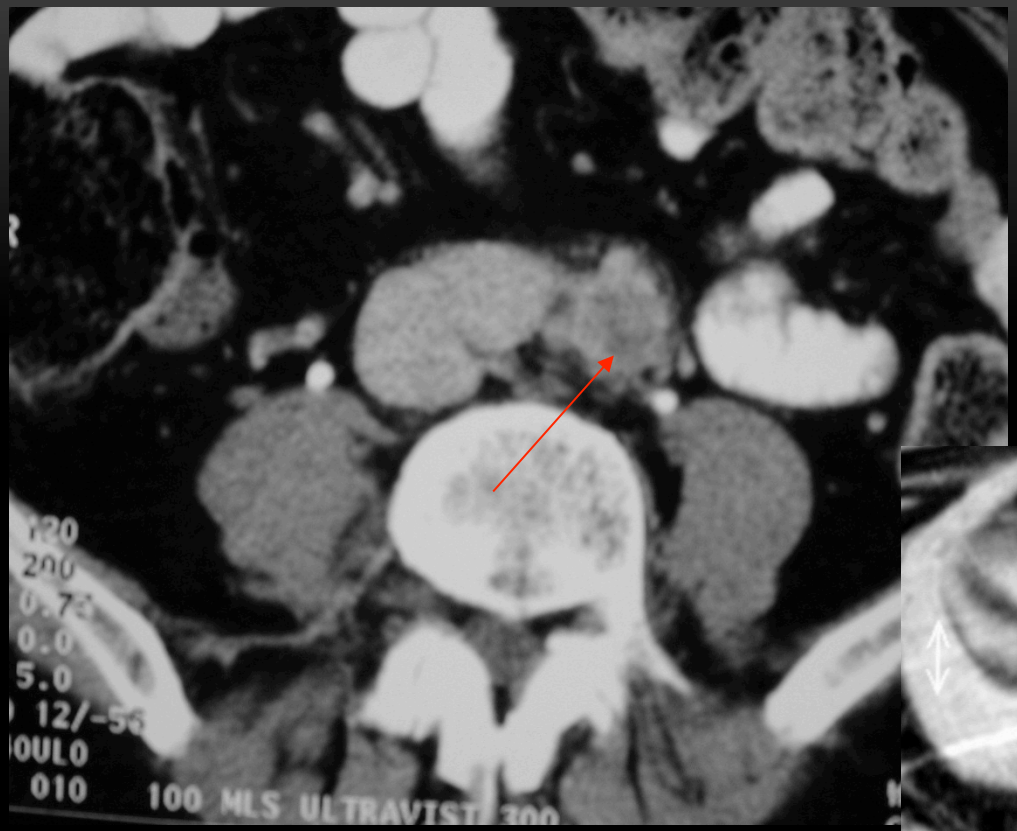

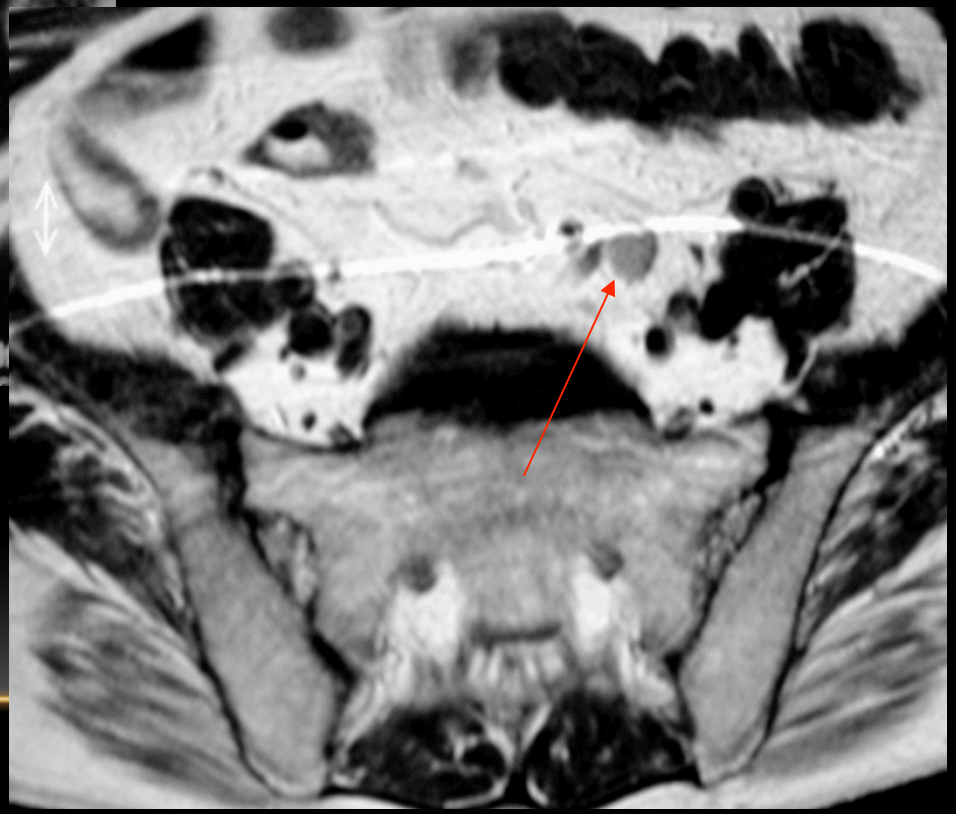

Mesorectal nodes

- **Relationship to CRM *not* so important**
- ***Positive nodes within 1mm of CRM not strong predictor of local recurrence* (vs. direct tumour spread)**
- **Main risk is 4 or more +ve nodes (N2)**
- **N1 (1-3 +ve)**

Shihab et al Br J Surg 2010

Pelvic side wall nodes

- Not in a usual surgical resection
- Difficult to identify when laparoscopic resection (or even open)
- Can be targeted with a ‘boost’ of radiotherapy
- Not an independent prognostic factor

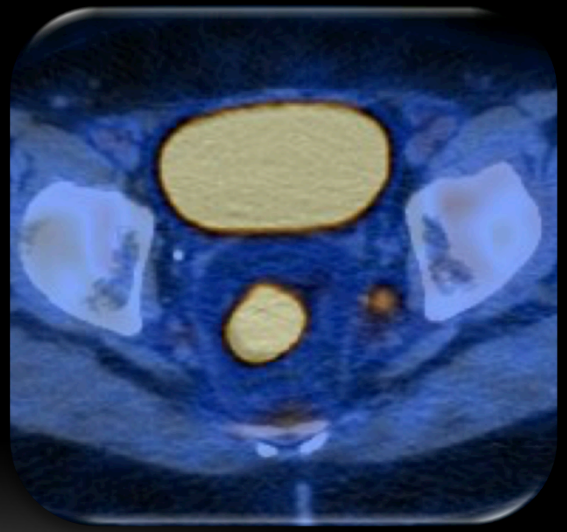

MERCURY Study Group Br J Surg 2011

MRI OF RECTAL CANCER: VASCULAR INVASION

Although vascular invasion does not affect treatment decision making and is assessed at pathologic analysis, it has prognostic significance and, if possible, should be evaluated at imaging

Smith et al AJR 2008

Anatomy : vascular invasion

- Present in up to 50% specimens
- Poor prognostic factor
- Increases risk of distant metastasis and pelvic side wall nodal disease

Linear tumour extension along vessels – often nodular

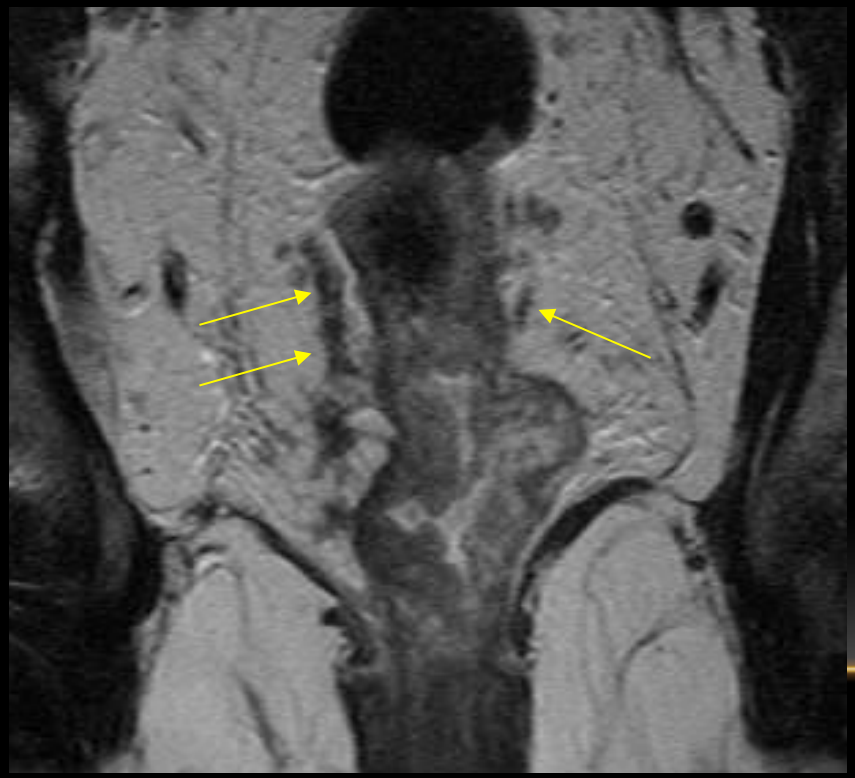

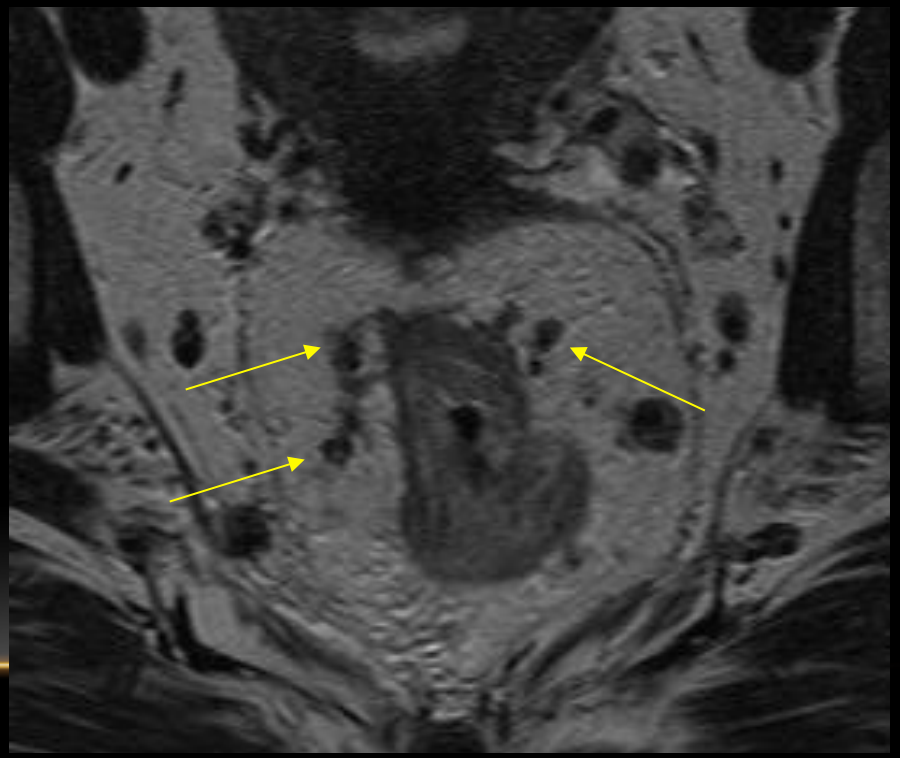

MRI AFTER CRT: MUCINOUS TUMOURS

High T2 signal - inactive mucin lakes

CRT may i*ncrease* mucinous differentiation in some tumours

R0 resection more difficult to predict with mucinous tumours

Allen AJR 2007

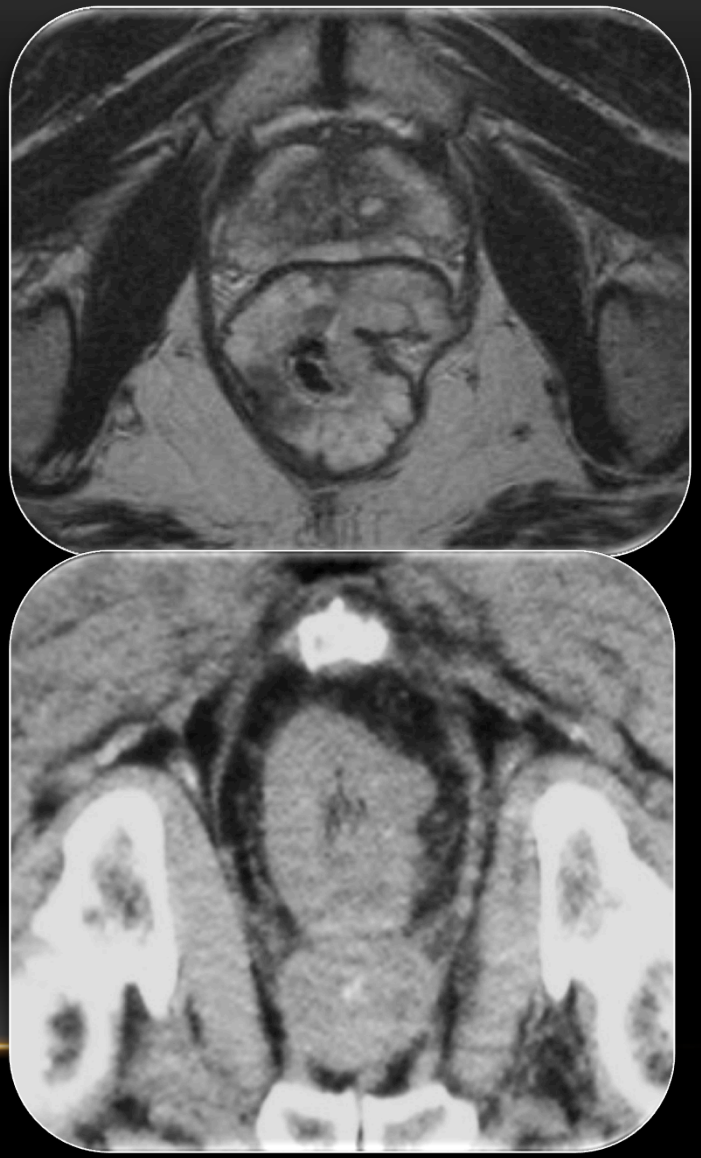

SUMMARY

Target Volume Delineation ESTRO Course

Budapest 4-7 October 2015

GTV and CTV for Rectal Cancer

Maria Antonietta Gambacorta

Radiotherapy Department

Università Cattolica del Sacro Cuore

Rome Italy

after 2000 randomized trials

Trial	Pre ERT	Winner
German trial	Pre RT+ vs Post RT	Pre RT

Trial	Short ERT	Winner
Duch Trial	SC RT+TME vs TME	SC RT
MRC C07	SC RT+TME vs TME	SC RT

Trial	Long ERT	Winner
EORTC 22921	LC RT vs C-RT	C-RT
FFCD 9203	LC RT vs C-RT	C-RT
Scandinavian	LC RT vs C-RT	C-RT

Trial	Short vs Long	Winner
Polish Trial	SC RT vs C-RT	=
TROG Trial	SC RT vs C-RT	C-RT

after 2000 randomized trials

Trial	Short ERT	Winner
Dutch Trial	SC RT+T	
NCIC CTG	RT+T	

SURVIVAL
no improvement

Local control
improvement

Trial	Long ERT	Winner
EORTC 22921	LC RT vs C-RT	C-RT
FFCD 9203	LC RT vs C-RT	C-RT
Polish Trial	SC RT vs C-RT	=
TROG Trial		
Scandinavian	LC RT vs C-RT	C-RT

Acute Toxicity
increased

CTV: what to include

1. GTV

2. MESORECTM and PRESACRAL SPACE

3. LATERAL NODES

4. Sphincter Complex & Inguinal Nodes

CTV in rectal cancer

Surgery targets

Tumor (GTV)

Mesorectum

Not surgery targets

Mesorectal fascia

Presacral region

Lateral lymphnodes

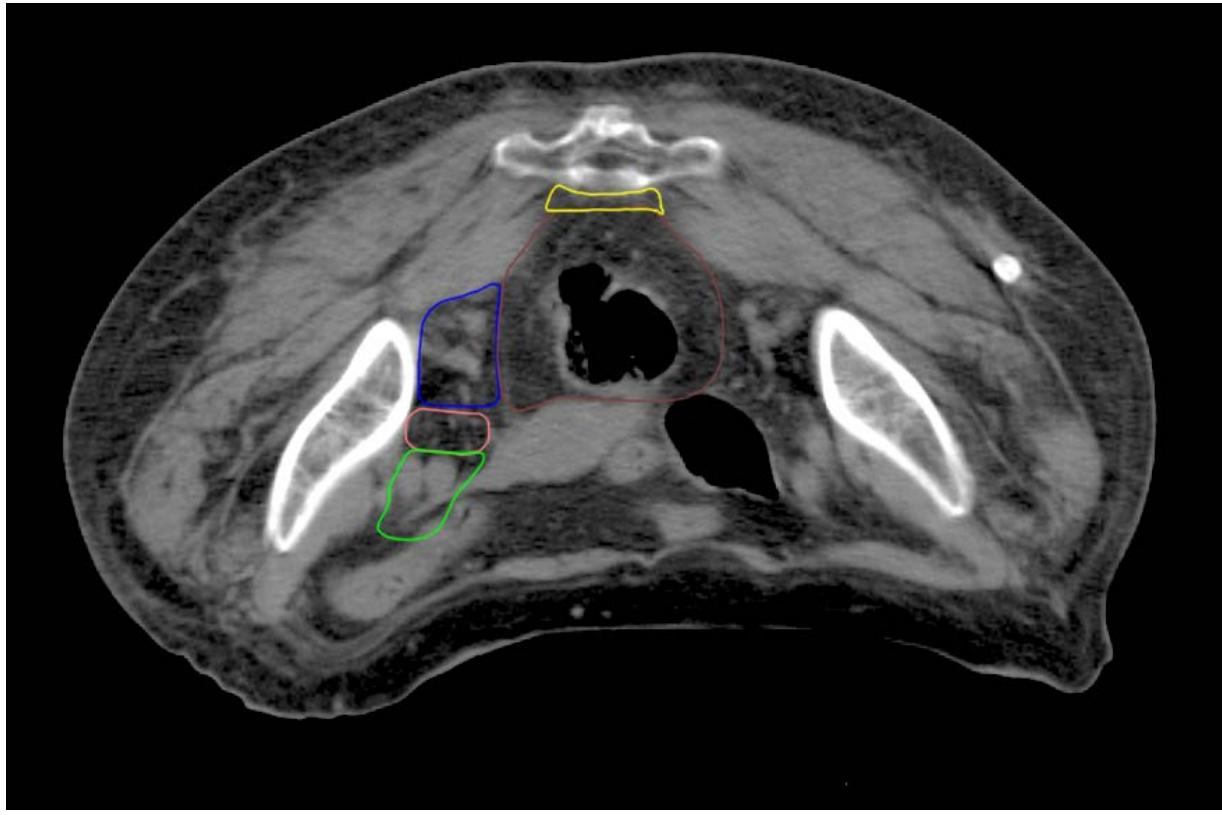

TME clinical target

"…en bloc removal of the rectum together with the mesorectal fat column"

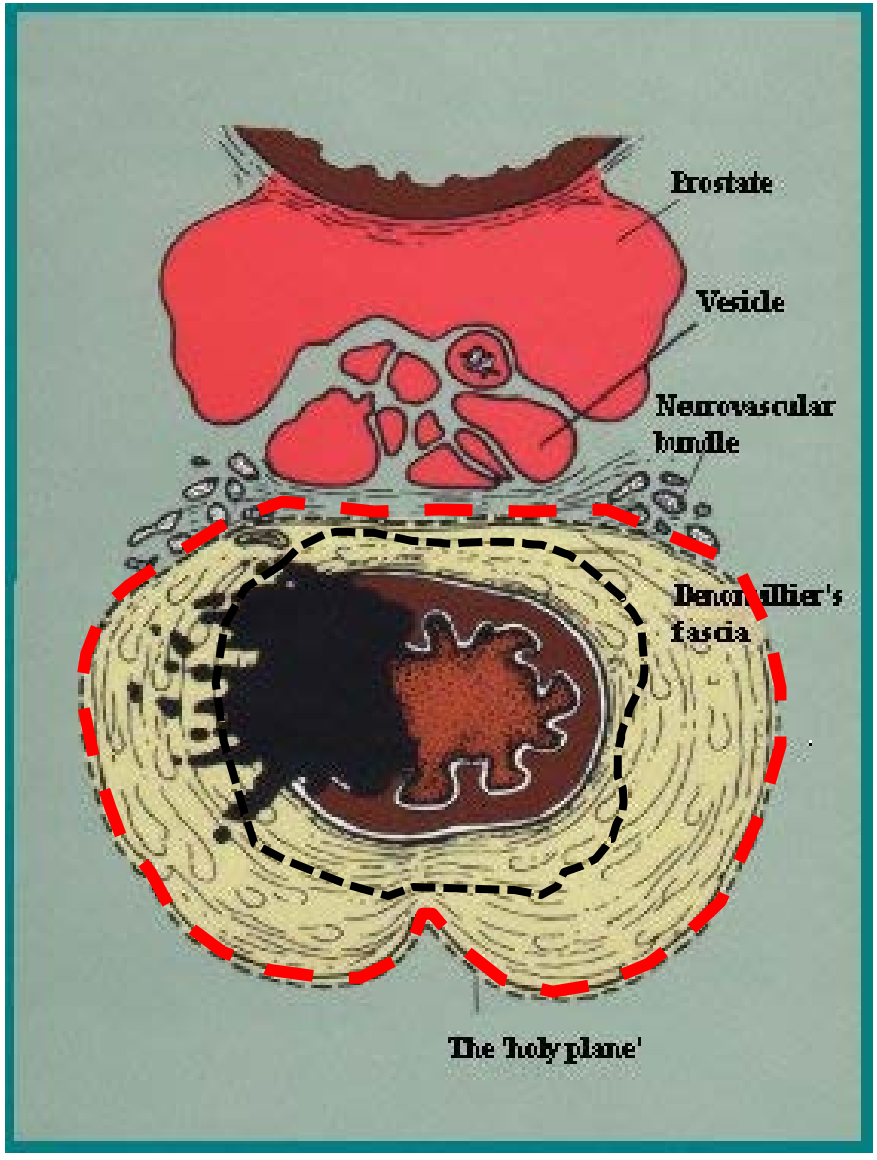

TME clinical target

removed

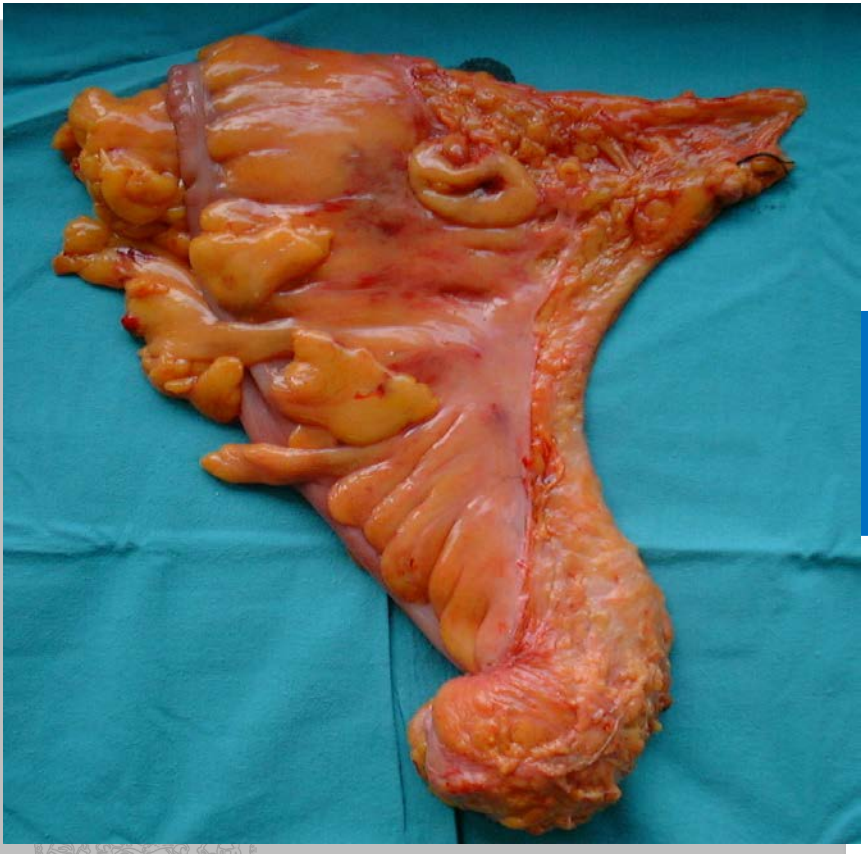

- **TUMOR: GTV**
- **MESORECTUM: Nodes**

TME clinical target

removed

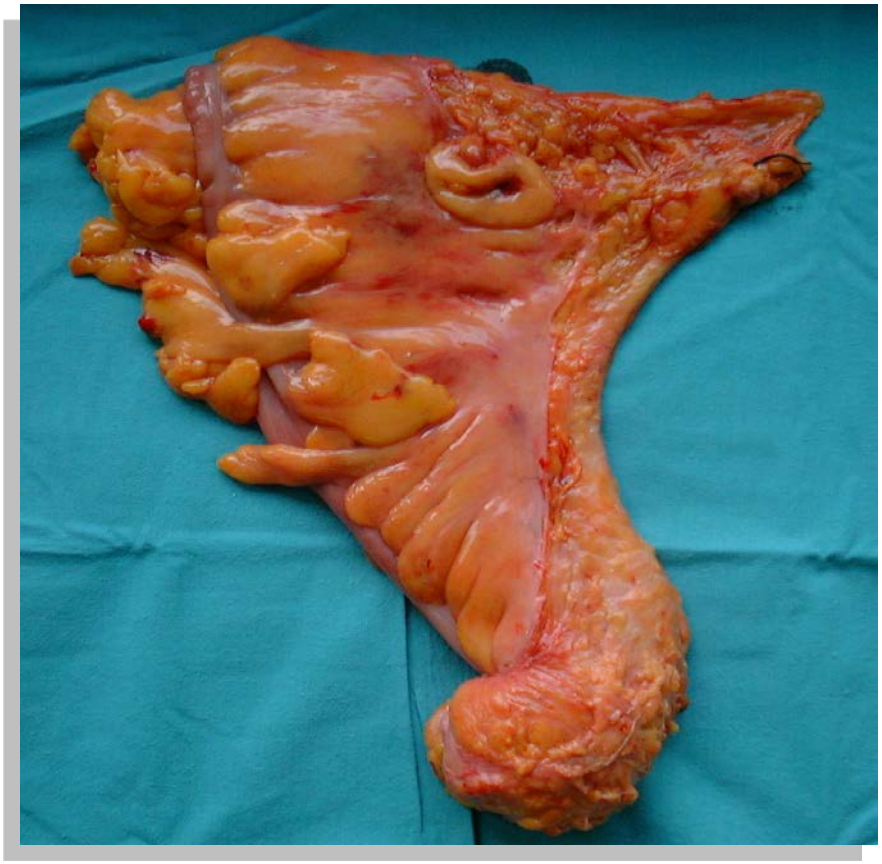

left

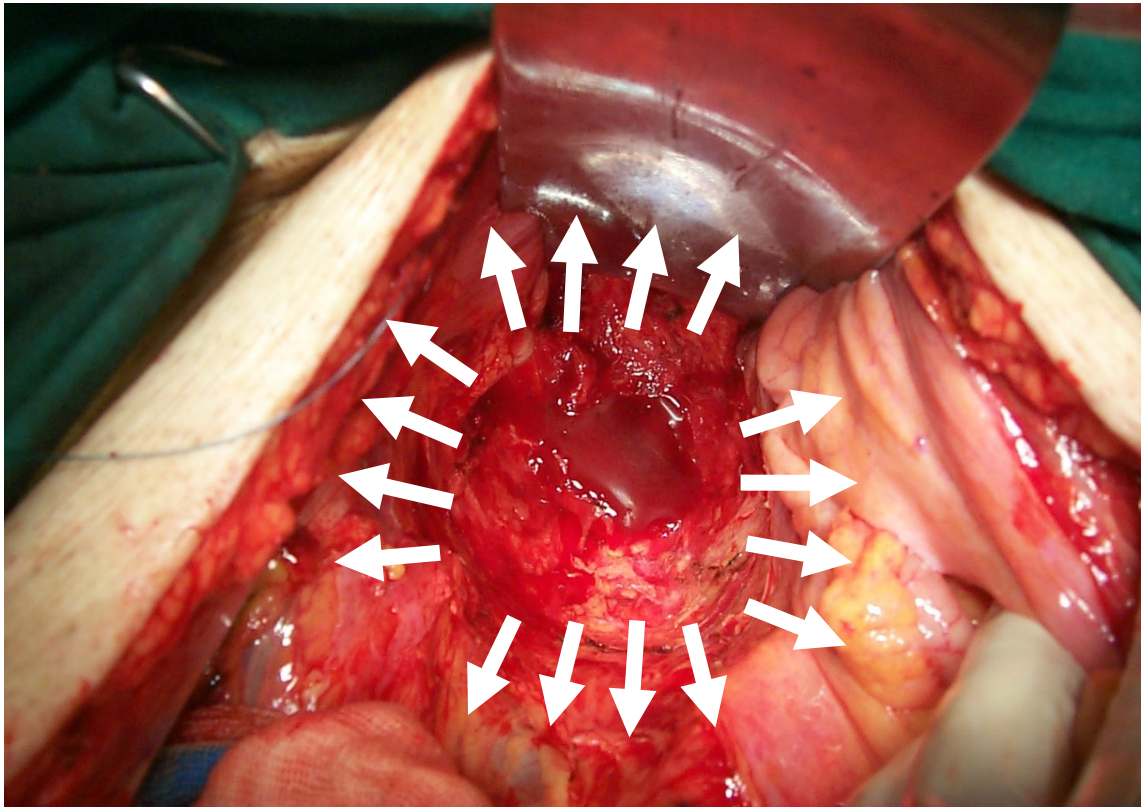

Not surgical targets

Mesorectal fascia

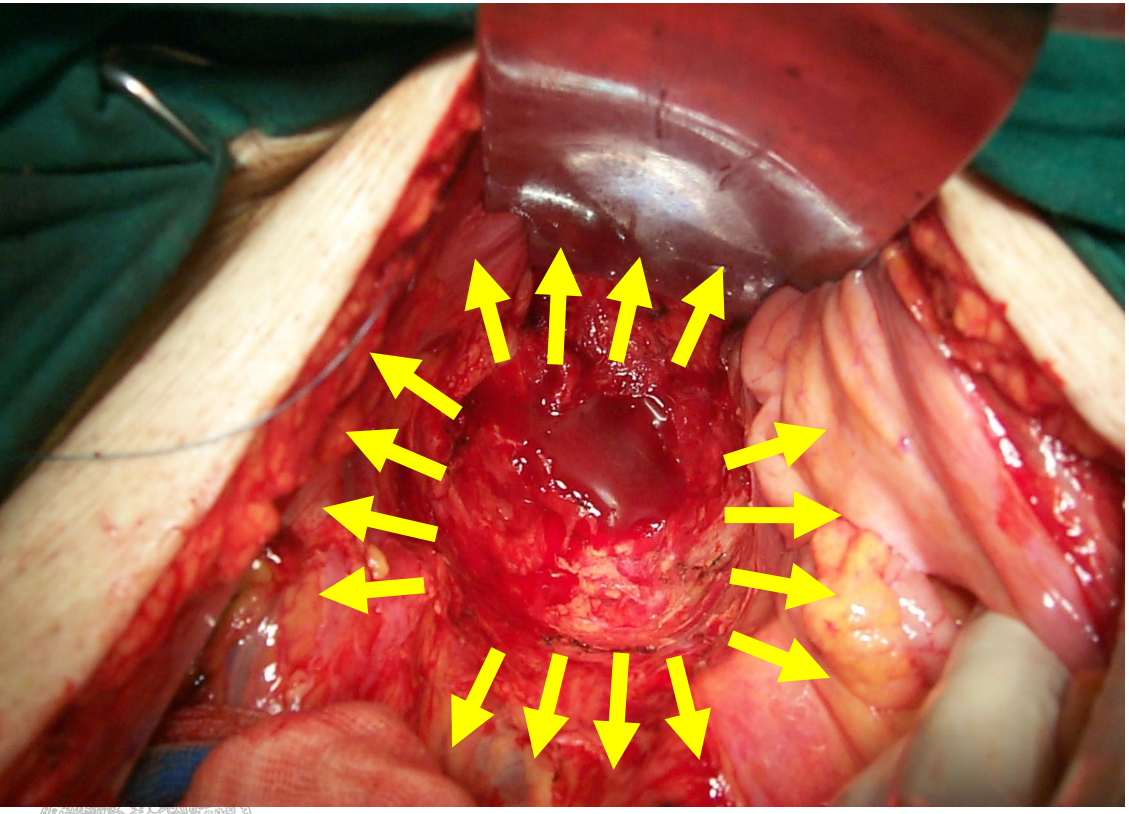

Not surgical targets

Presacral Space

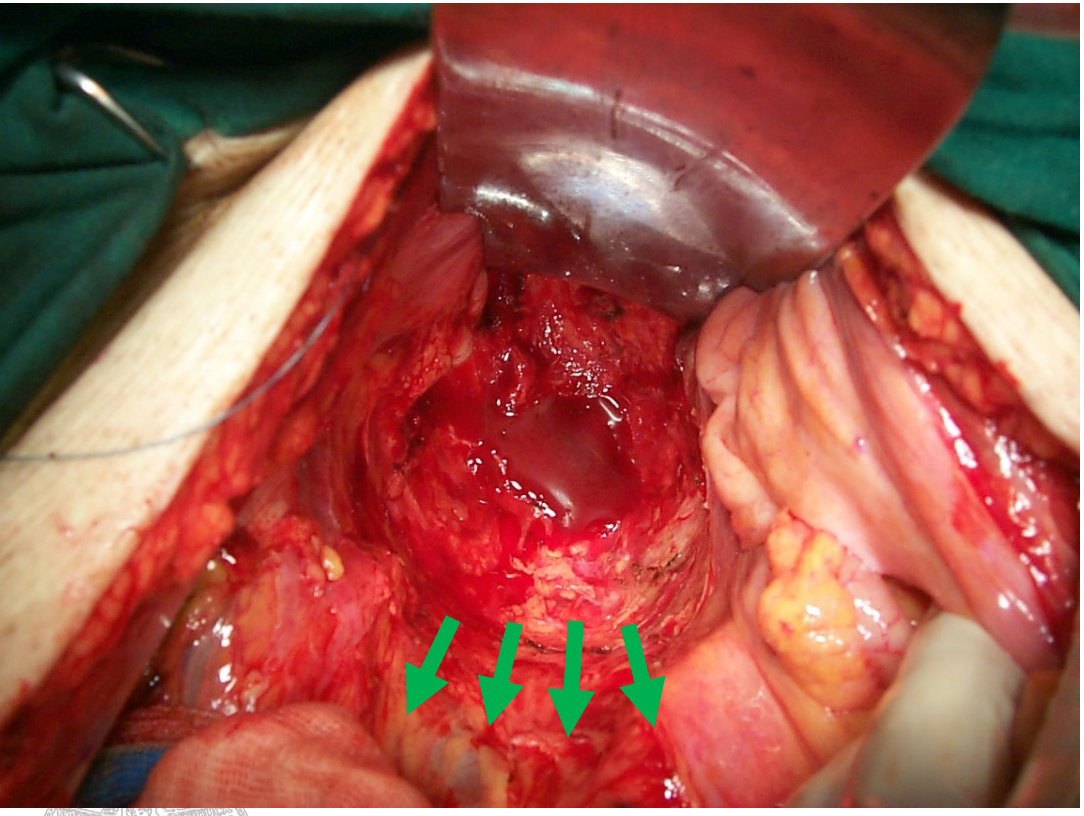

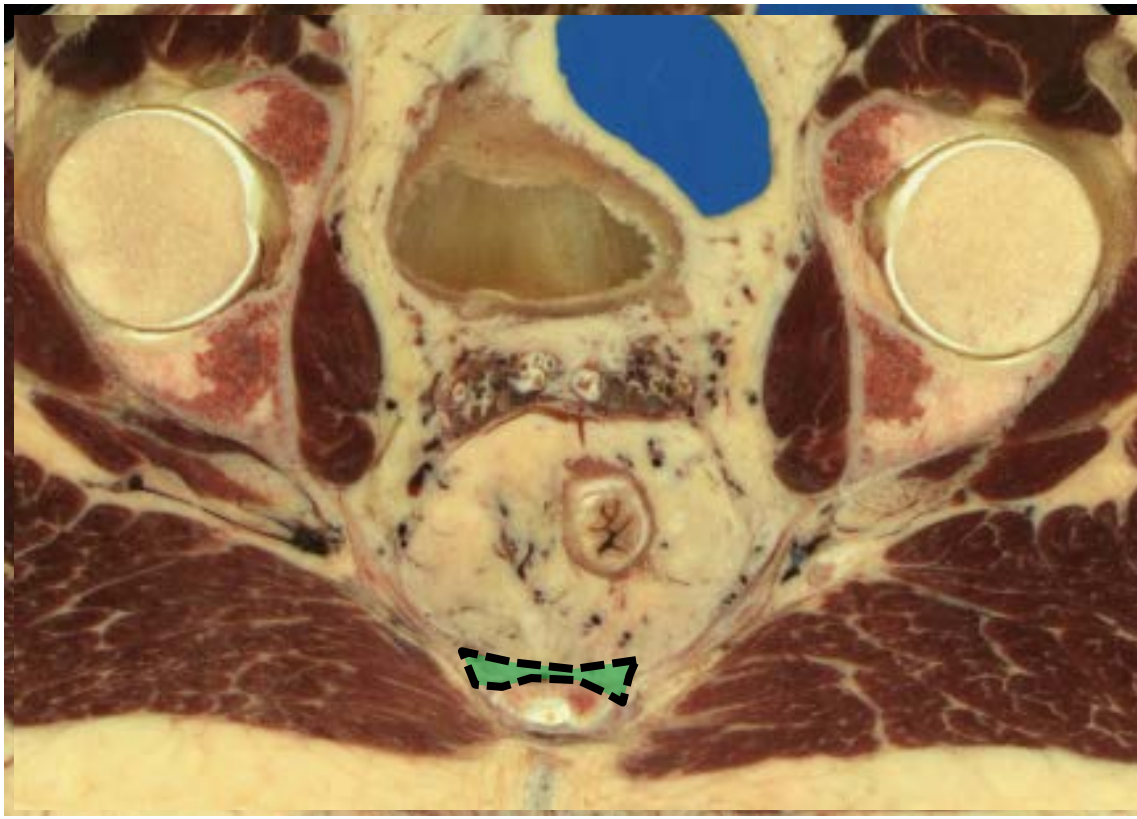

Not surgical targets

Lateral Spaces Nodes

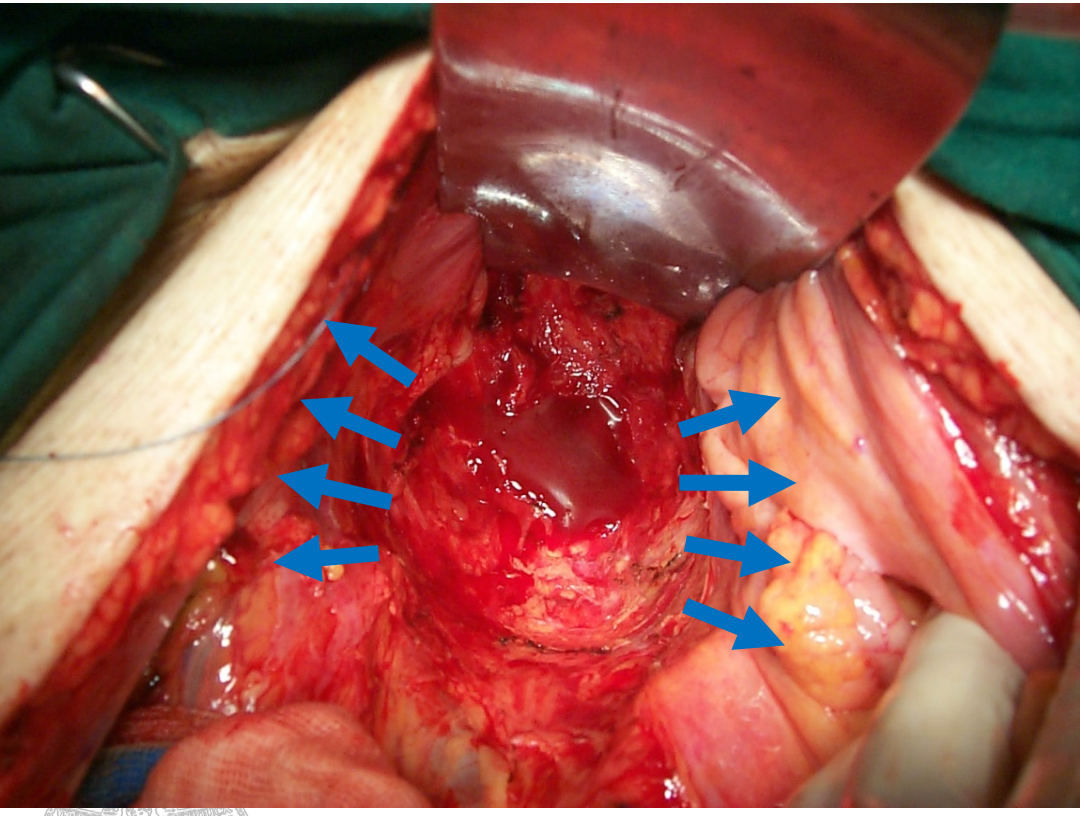

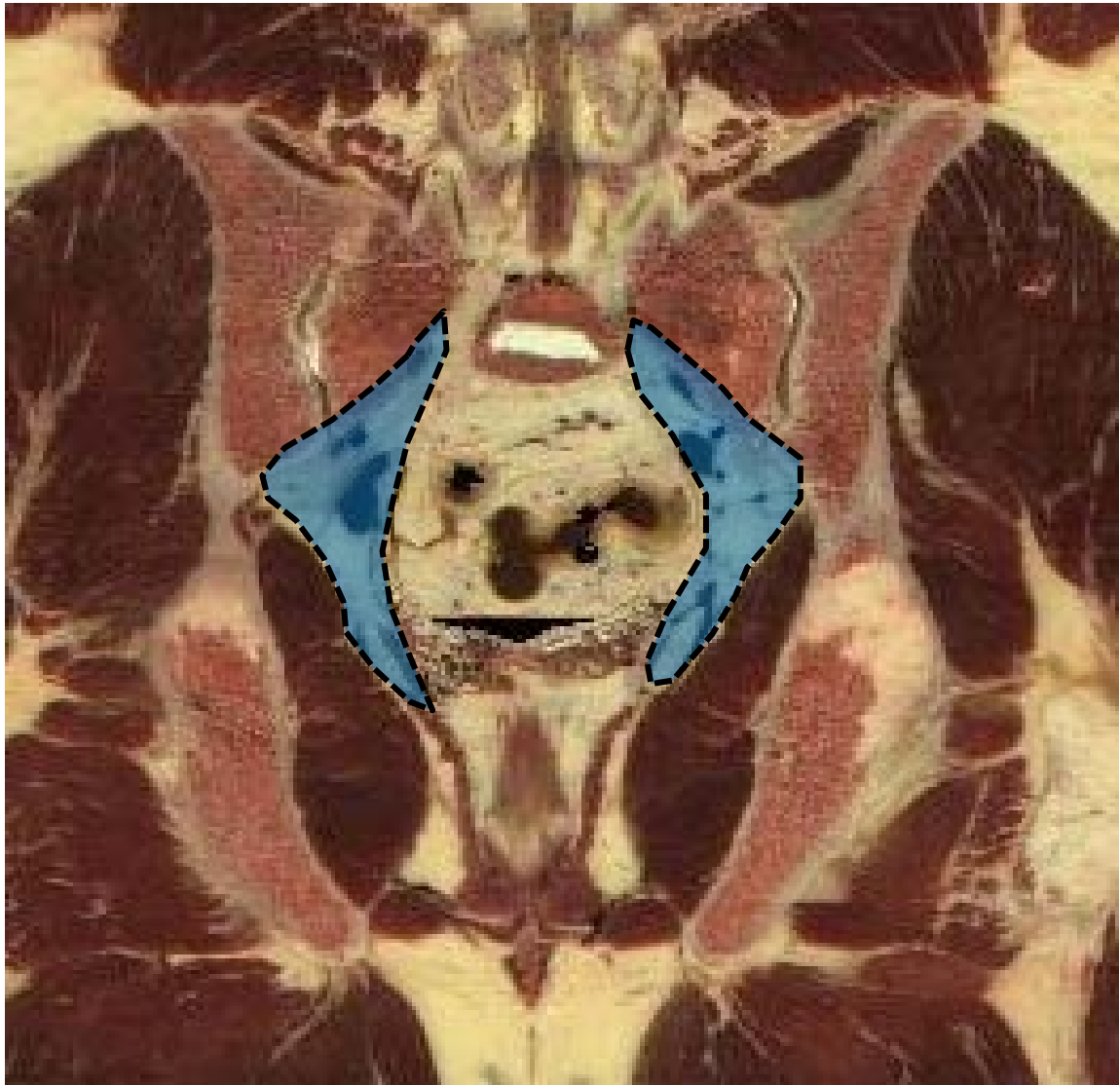

Not surgical targets

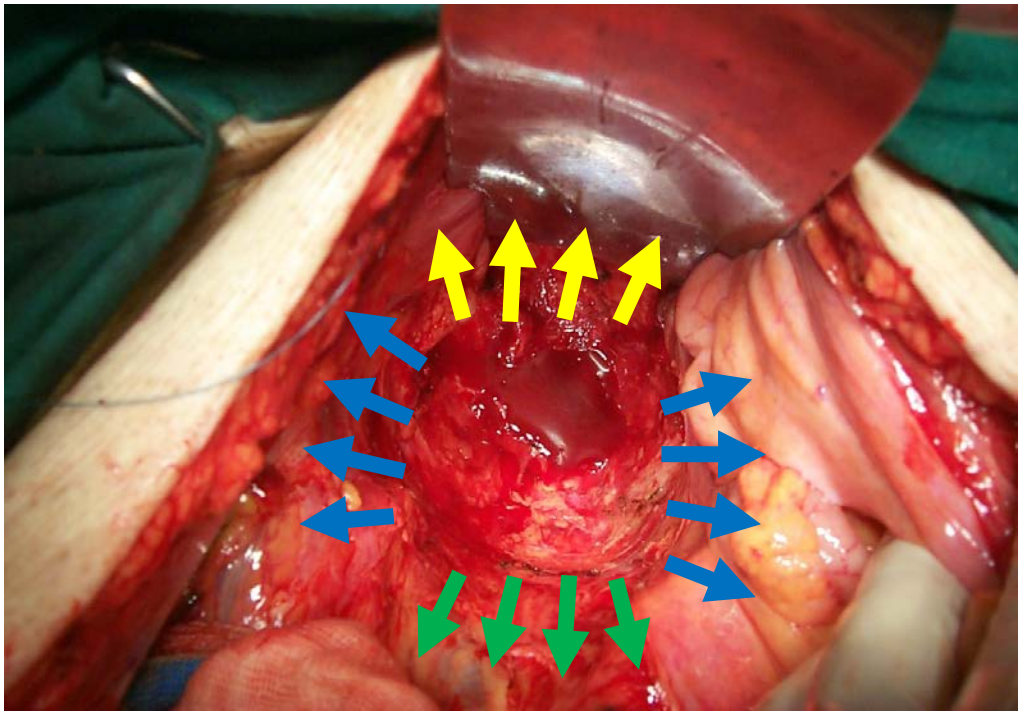

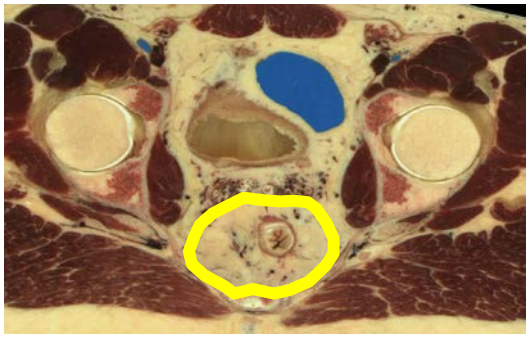

Mesorectal Fascia

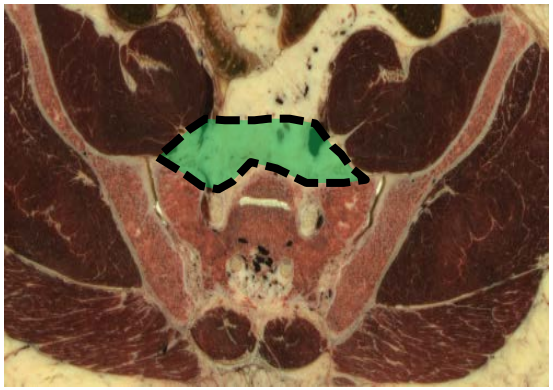

Prescral Space

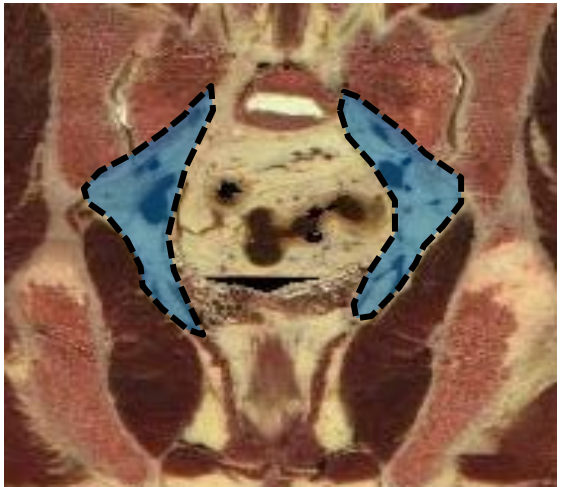

Lateral Nodes

Surgical targets

removed

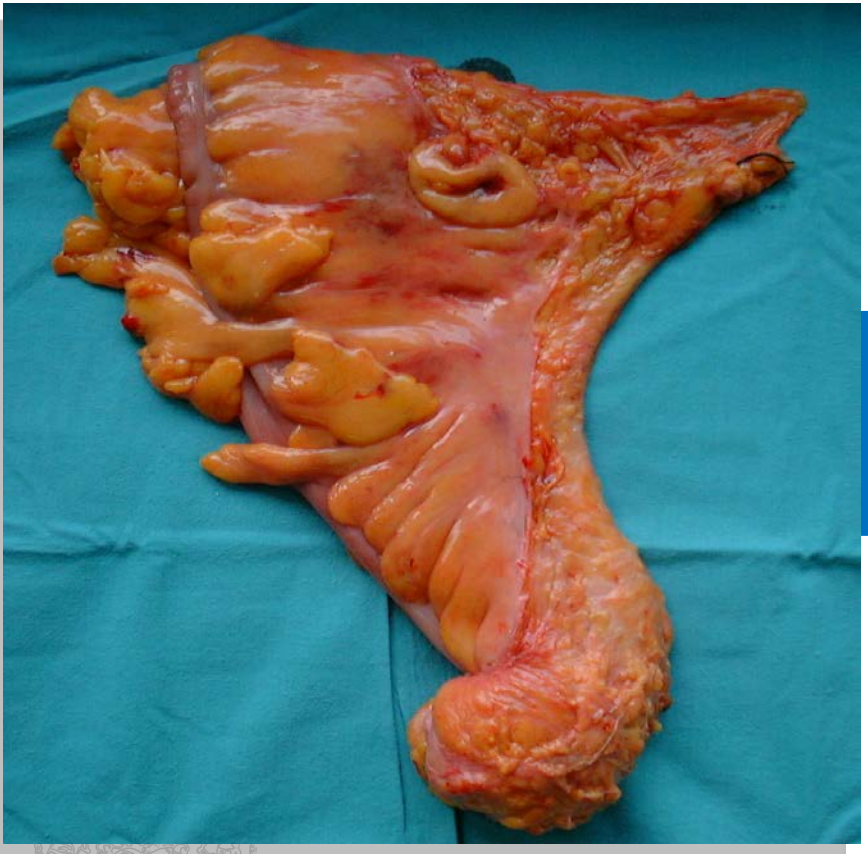

- **TUMOR: GTV**
- **MESORECTUM: Nodes**

GTV: the tumor

GTV: removed by surgery

Long course RT-CT and delayed surgery

Boost: Local control; shrinkage/regression

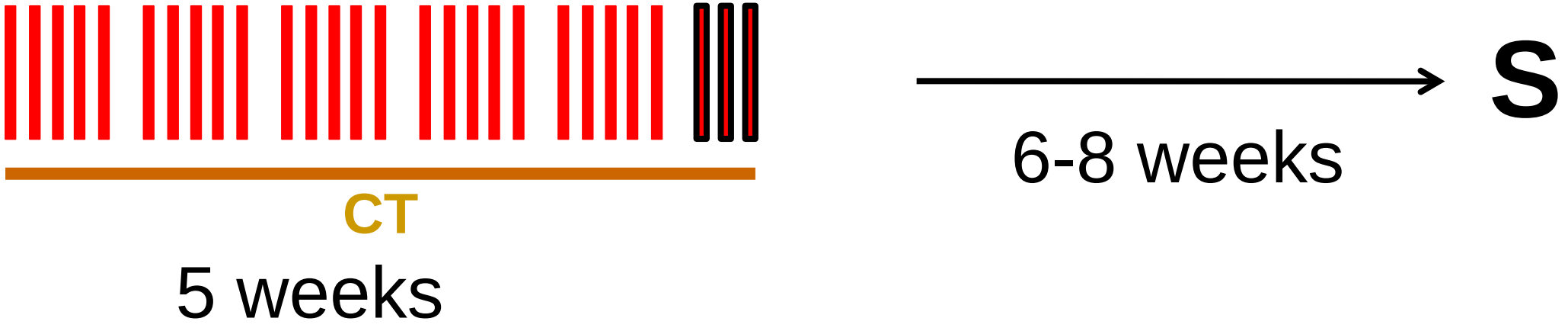

CTV1: the tumor + margin

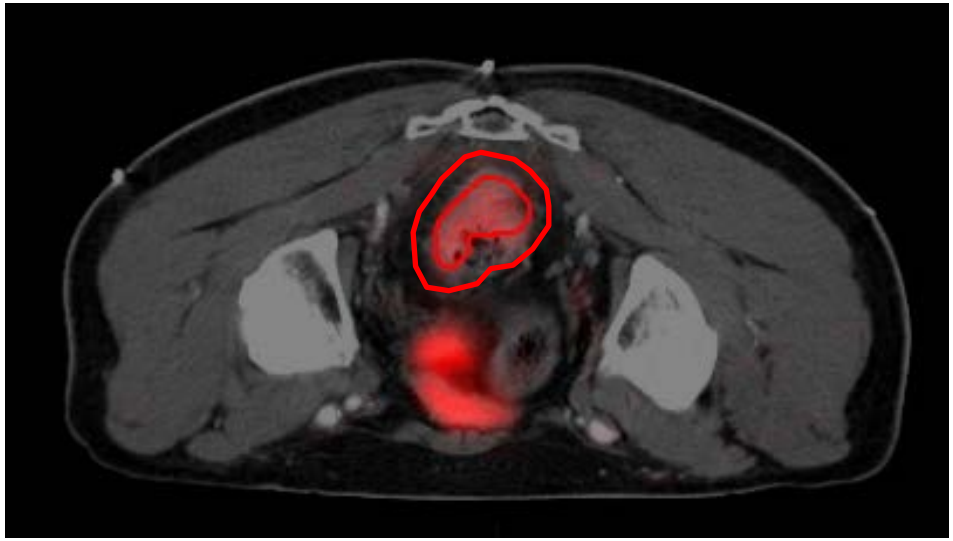

GTV + margin

GTV + corresponding mesorectum

Myerson et al IJROBP 2009

CTV1: the tumor + margin

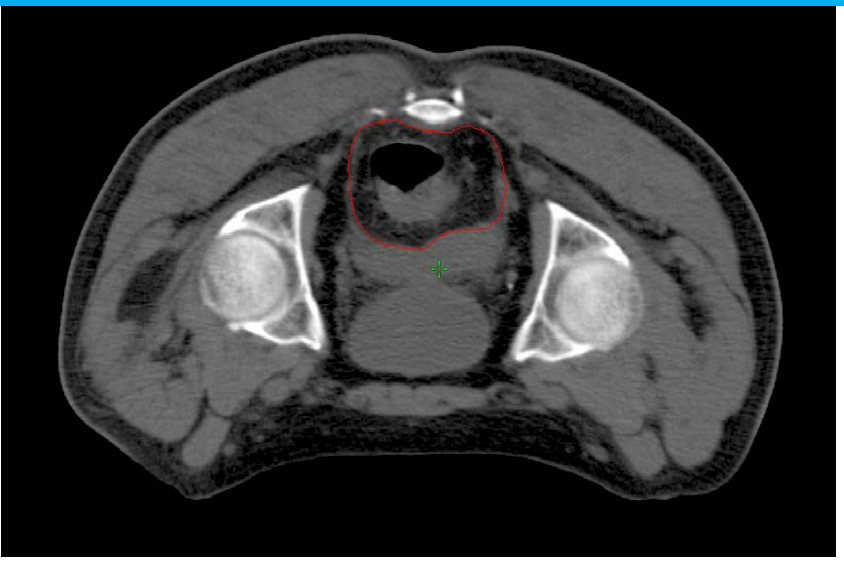

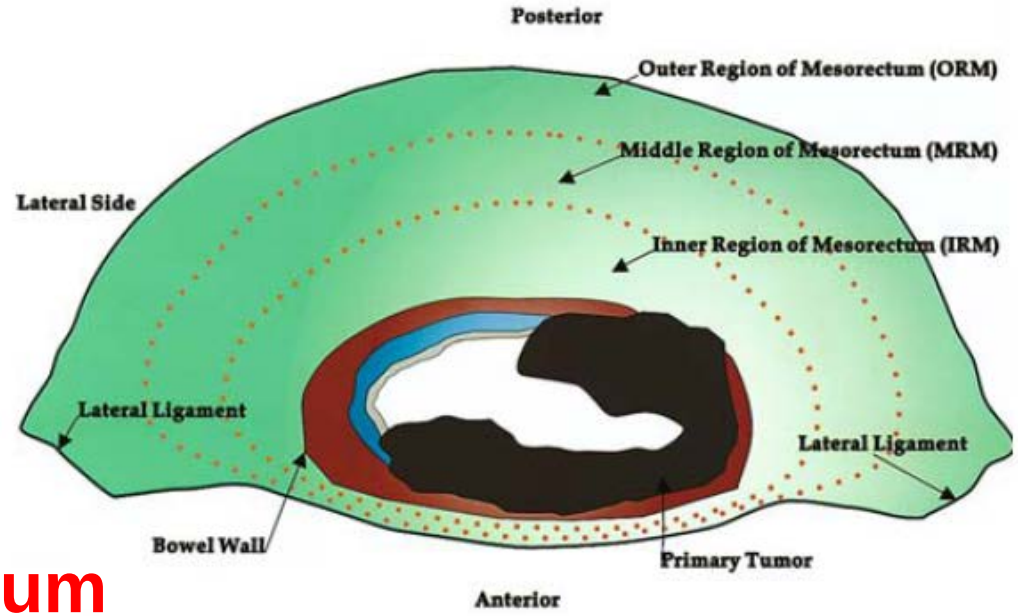

GTV + corresponding mesorectum

Microscopic tumor deposits in the Mesorectum: **38%**

Outer Region of the Mesorectum: **25%**

Distal tumor deposits in the mesorectal fat **3 cm** from the cancer: **6.5%**

Myerson et al IJROBP 2009

Wang et al. Int J Colorectal dis 2005

CTV2: mesorectum

Removed by TME

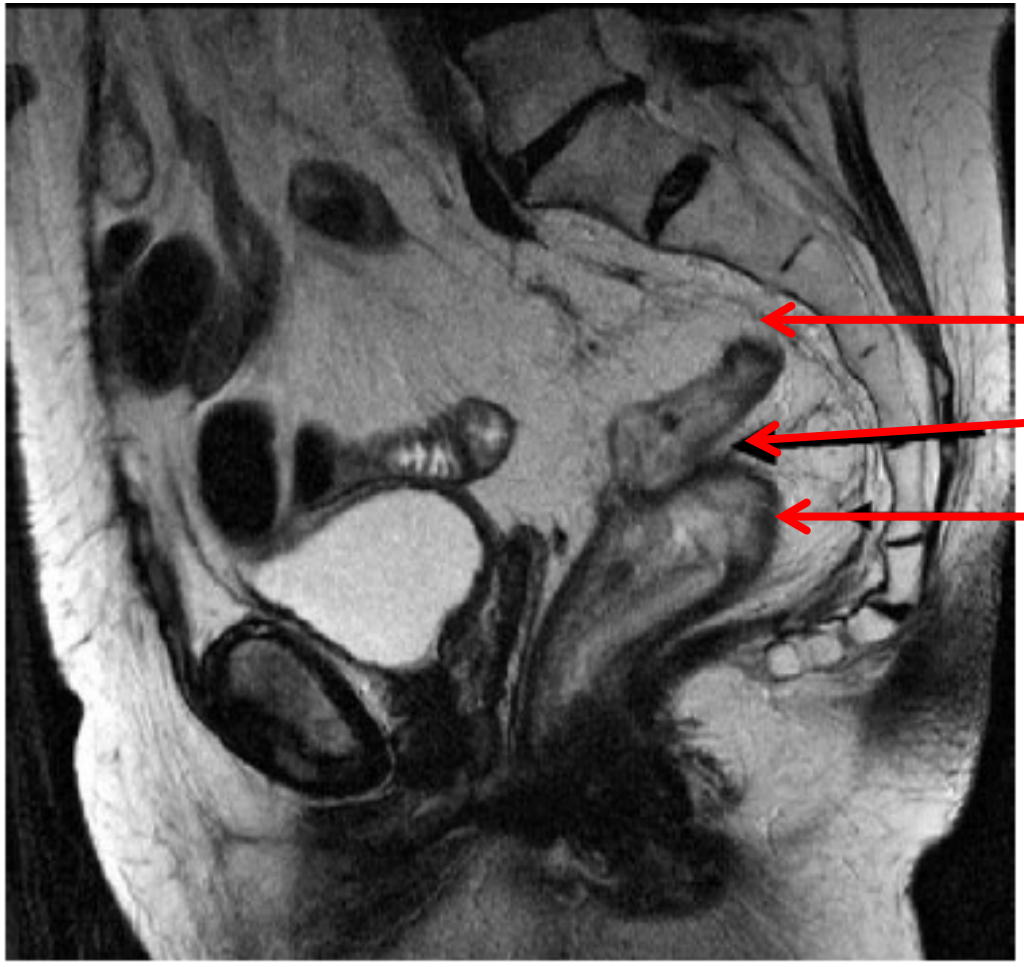

Residual distal mesorectal fat

in **50%** of patients who

underwent **TME**

Kusters et al. EJCO 2010
Syc et al IJROBP 2006

CTV2: mesorectum

RT-TME decrease anastomotic LR

Subsites of local recurrence.

	RT + (n = 713)	RT − (n = 704)
Presacral	15 (2.0)	25 (3.6)
Lateral	9 (1.1)	14 (1.9)
Anterior	6 (0.7)	14 (1.9)
Anastomosis	5 (0.7)	19 (2.7)
Perineum	0 (0)	4 (0.6)
Unknown	1 (0.1)	2 (0.3)
TOTAL	36 (4.6)	78 (11.0)

Values in parenthesis are 5-year LR-rates, by competing risks analysis.

Anastomotic LR had residual mesorectum

Kusters et al. EJCO 2010

CTV2: mesorectum

Positive Nodes – Radiotherapy - Local Recurrence

Local recurrence rate according to distal margin and lymph node status.

	RT−			RT+		
Distal margin	N0	*N+*		N0	*N+*	
0–5 mm	5.6	30.0		11.8	28.6	
6–10 mm	8.8	34.6		0	0	
11–20 mm	4.6	29.7		0	7.2	
>21 mm	5.5	8.6		1.7	5.8	
TOTAL	5.6	19.4	<0.001	1.7	9.3	<0.001

In LAR and Hartmann procedures. Values are 5-year local recurrence percentages.

Kusters et al. EJCO 2010

Not surgical targets

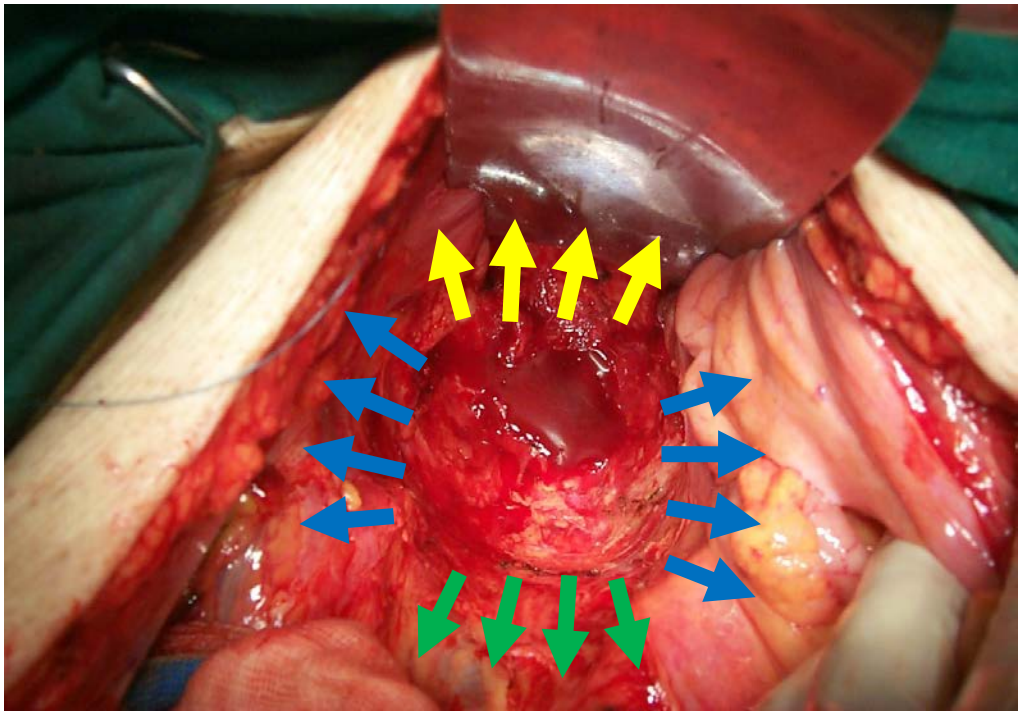

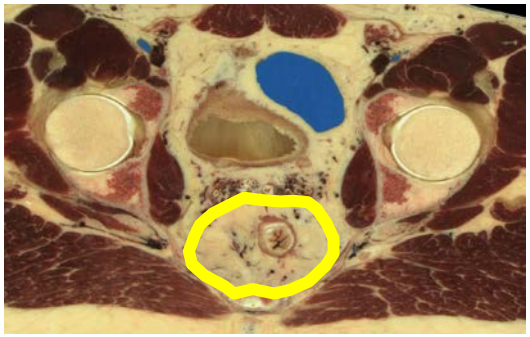

Mesorectal Fascia

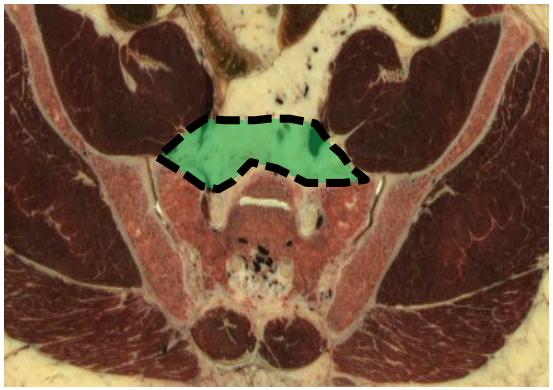

Prescral Space

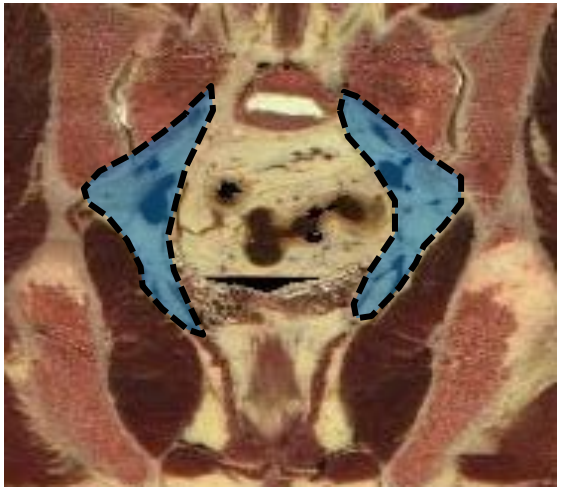

Lateral Nodes

Mesorectal Fascia

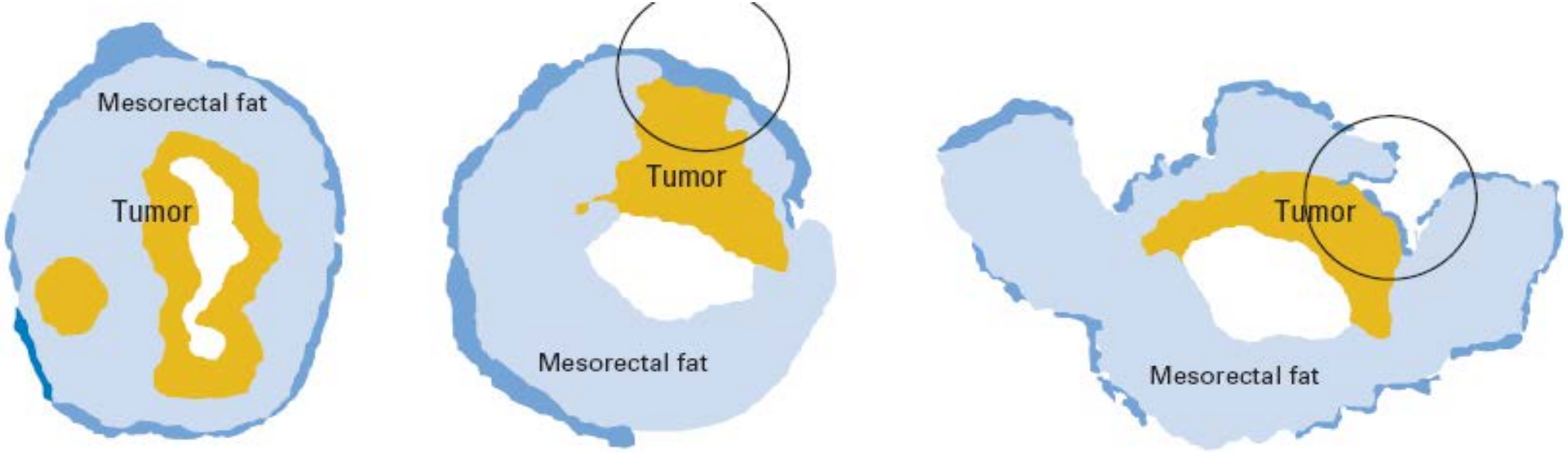

Circurferential Resection Margin

Naagtegaal et al. JCO 2009

CRM and Oucomes

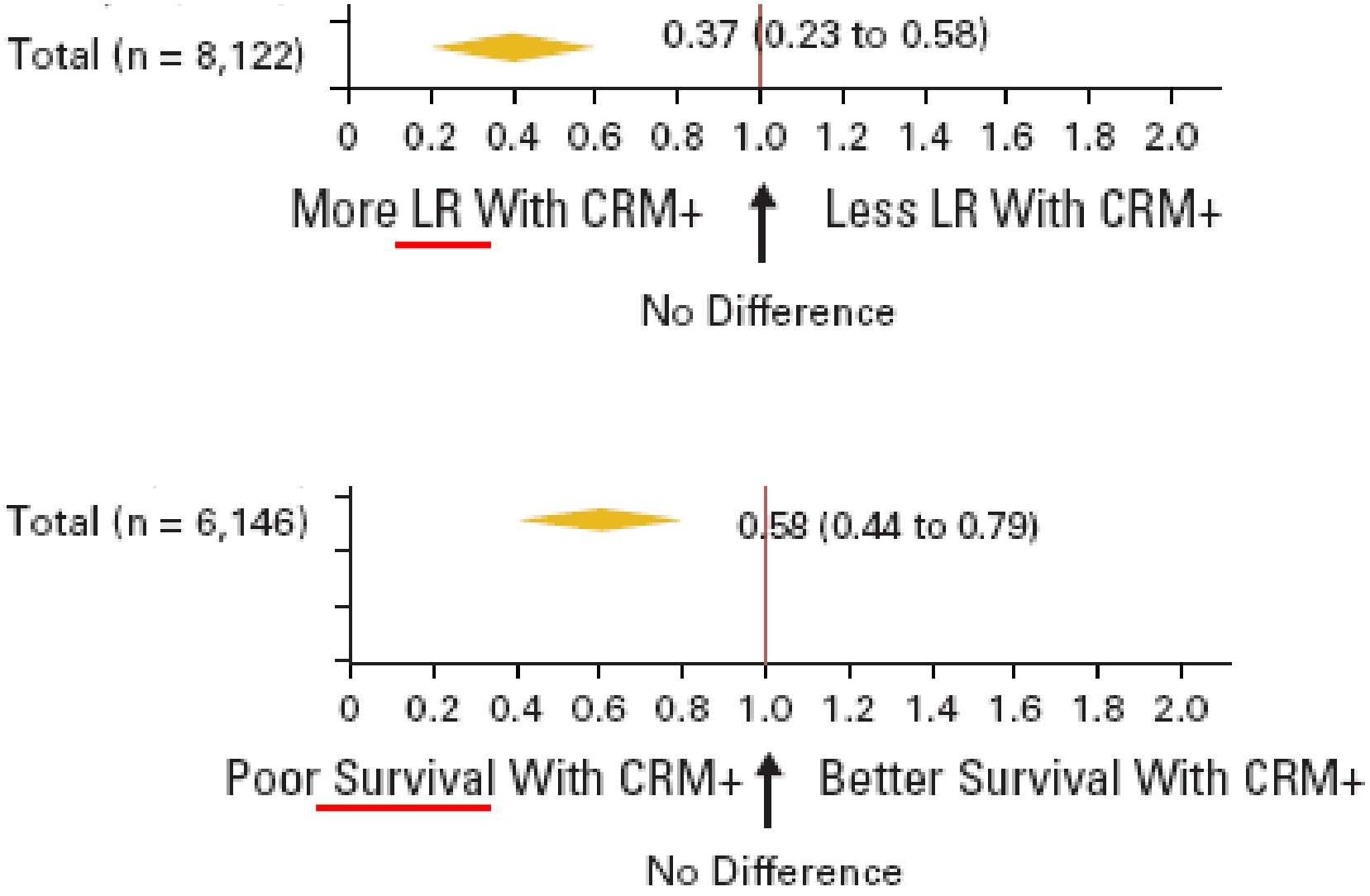

Naagtegaal et al. JCO 2009

Mesorectal Fascia

"[...] margin involvement is not always present in the macroscopically most suspected area, but might be present in other areas [...]. The examination of additional microsopic slides had led to an increase in CRM-positive patients from 6% to 27% of patients and from 6 to 16 patients"

Naagtegaal et al. JCO 2009

Mesorectal Fascia by treatment

preradiation

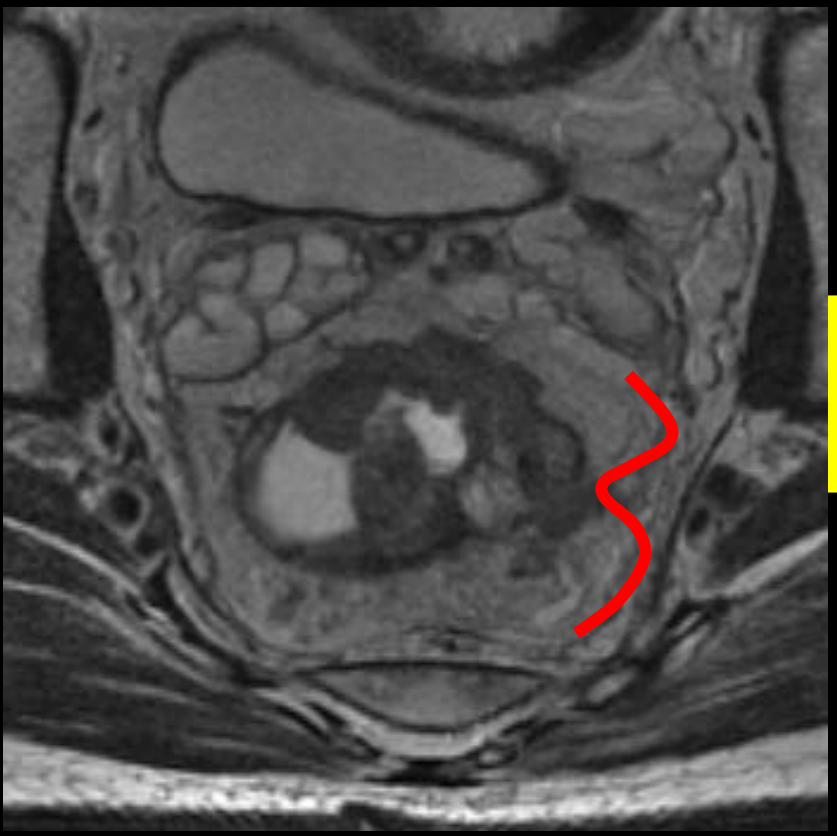

LC-CRT

postradiation

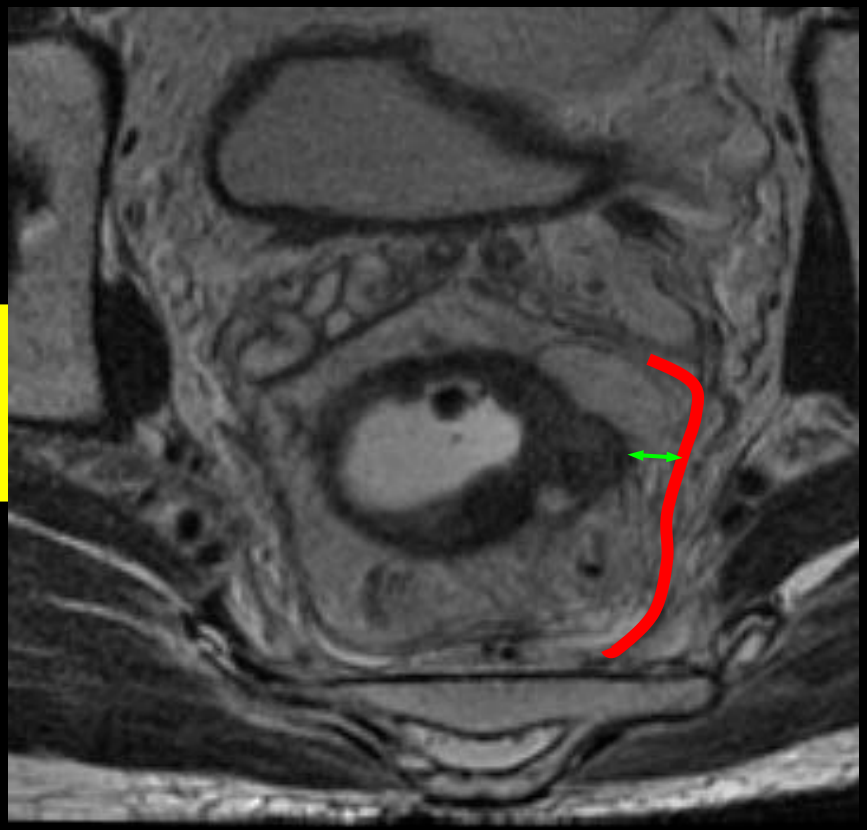

CRM by treatment

	Preop **Short RT**	Preop **Long RTCH**
pCRM+	**13 %**	**4 %**

p = 0.017

Bujko K et al, Radioth Oncol 2006

Outcomes by treatment

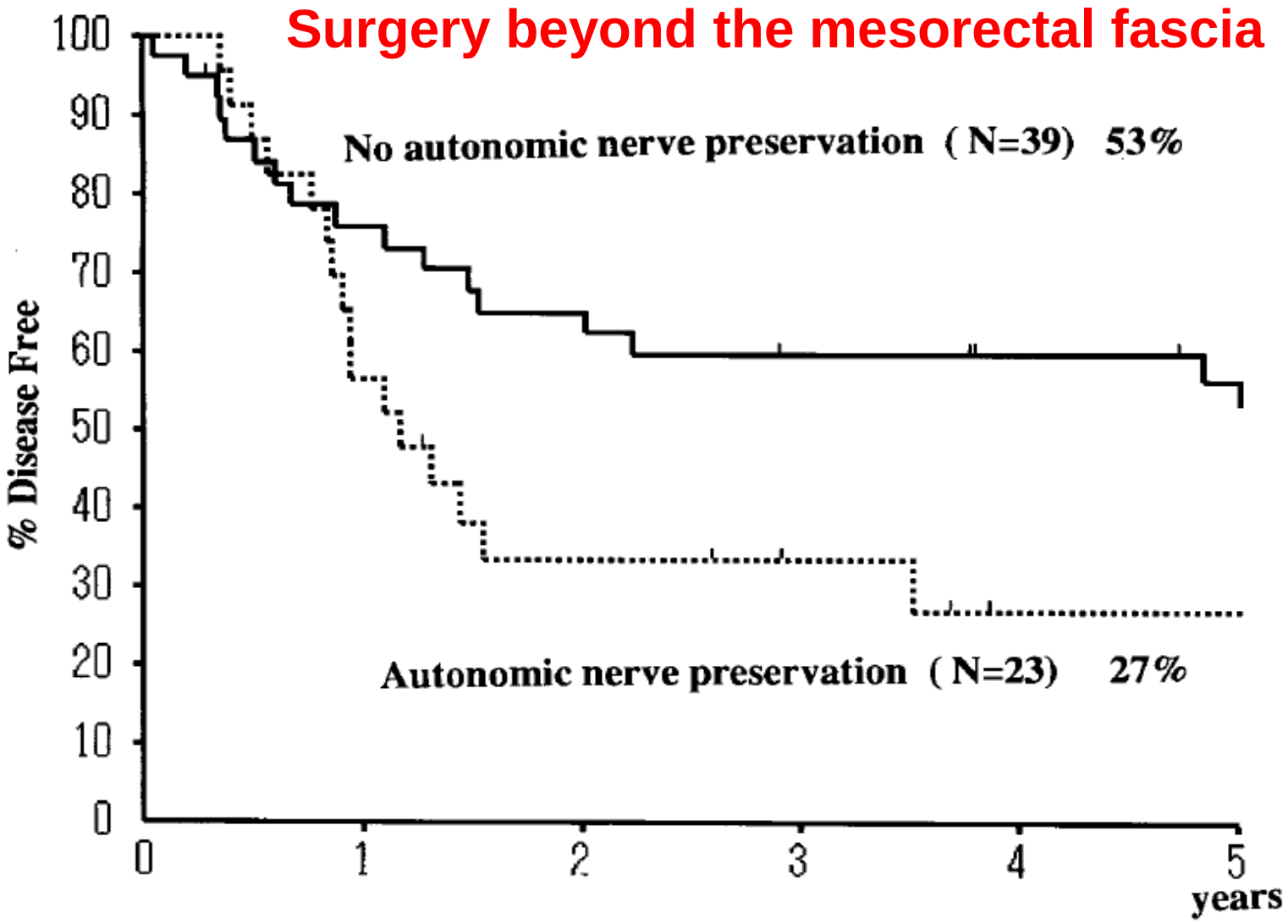

Moriya et al. World J Surg 1997

Mesorectal fascia anatomy

Inferior hypogastric pexus

Mesorectal fascia

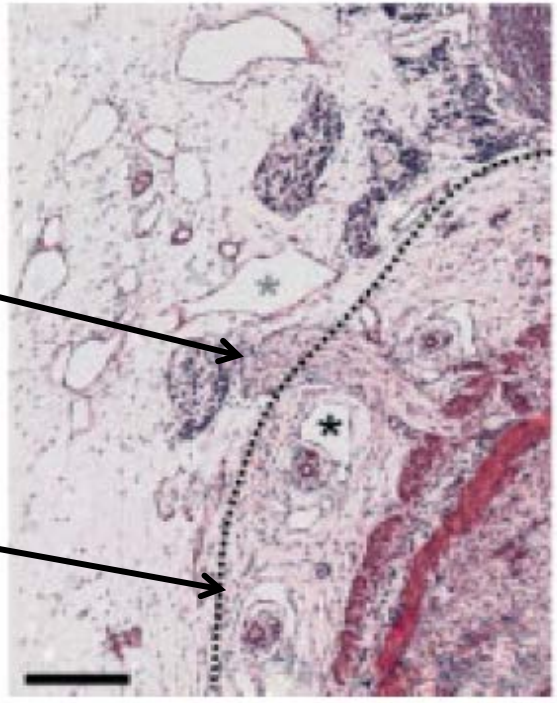

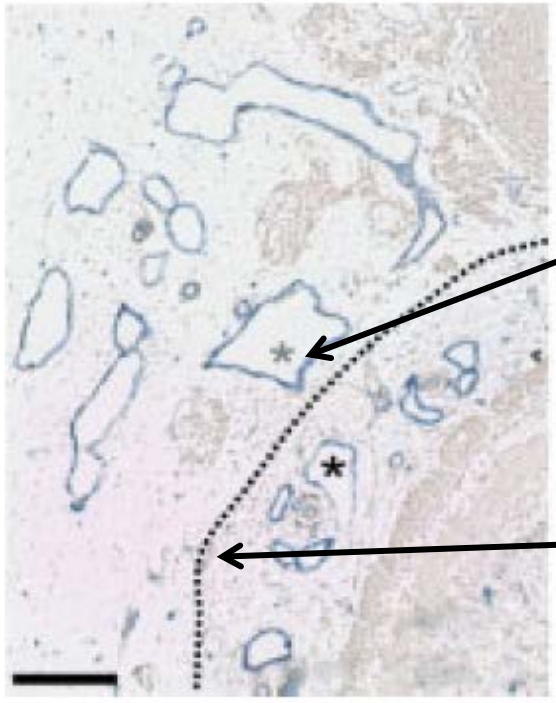

Lymphatic tissue

Mesorect al fascia

h Detail, haematoxylin and azophloxin stain

i Detail, lymph tissue immunostain

In the proximity of the mesorectum, the autonomic nervous system and the lymph vessels had a very close relationship.

Kusters et al BJS 2010

Presacral Space

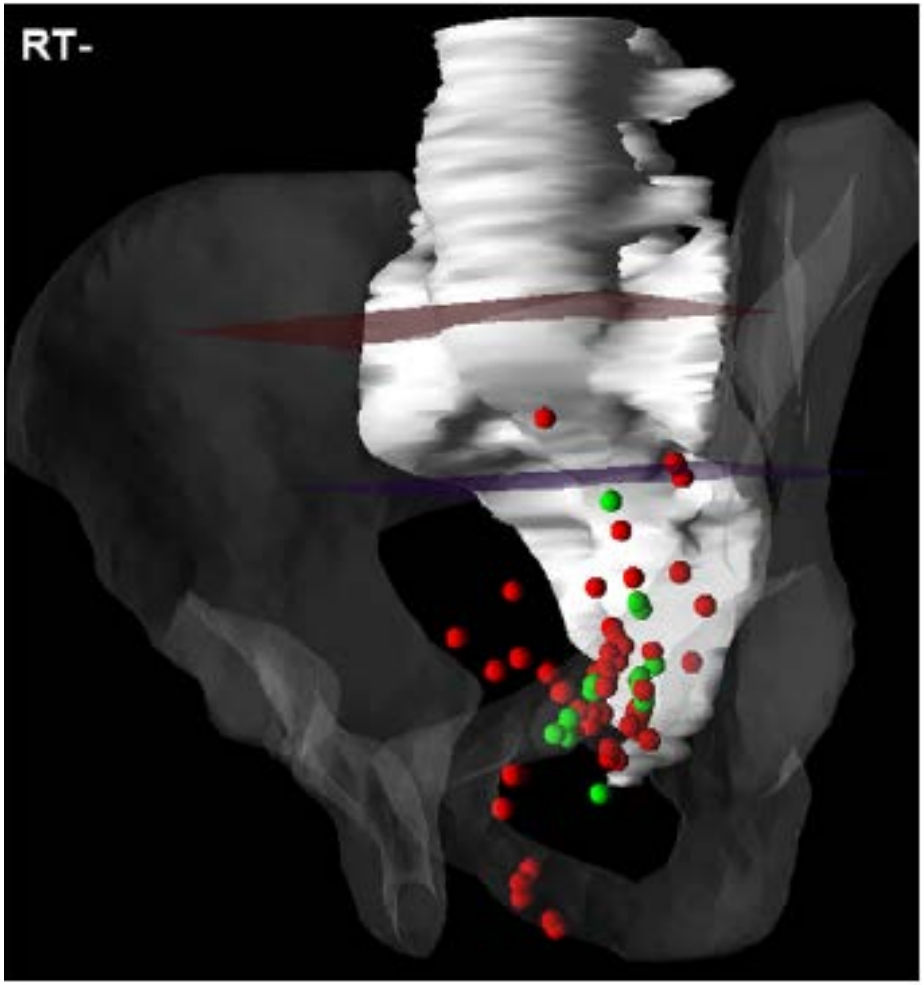

The majority of RL in the posterior lower 2/3 of the pelvis

Nijkamp et al IJROBP 2011
Hruby et al. IJROBP 2003

Presacral Space

Subsites of local recurrence.

	RT + (n = 713)	RT − (n = 704)
Presacral	15 (2.0)	25 (3.6)
Lateral	9 (1.1)	14 (1.9)
Anterior	6 (0.7)	14 (1.9)
Anastomosis	5 (0.7)	19 (2.7)
Perineum	0 (0)	4 (0.6)
Unknown	1 (0.1)	2 (0.3)
TOTAL	36 (4.6)	78 (11.0)

Values in parenthesis are 5-year LR-rates, by competing risks analysis.
RT = preoperative radiotherapy.

Kusters et al EJCO 2010

Why…if presacral space is

- **the easiest plane of dissection during surgery**
- **always in radiotherapy fiels**
- **boosted region (ERT/IORT)**
- **no lymphatic tissue in presacral area**

Kusters et al BJS 2010

Presacral and Lateral space

The authors hypothesized that, when mobilizing the rectum during surgical excision, lymph fluid and tumour cells flow into the lateral lymph node system. As this lateral lymph tissue is left behind in a standard TME and partly damaged during sharp dissection of the lateral ligament, one would expect the basins to start leaking after the procedure. This lymph fluid, collected presacrally in a seroma, might give rise to local tumour recurrence.

Kusters et al BJS 2010

Lateral Spaces

5 yrs OS when N+ extra-mesorectal: **~40%**

Positive LLN in surgical series: ~15 %

- T stage and location
- Grading
- N+mesorectal

Kusters et al Ann Surg 2009

Lateral Spaces

Radioterapy vs Surgery (LLND*)

same results with less side effects (sexual & urinary)

*Lateral Lymph Node Dissection

Kusters et al Ann Surg 2009

Lateral Spaces

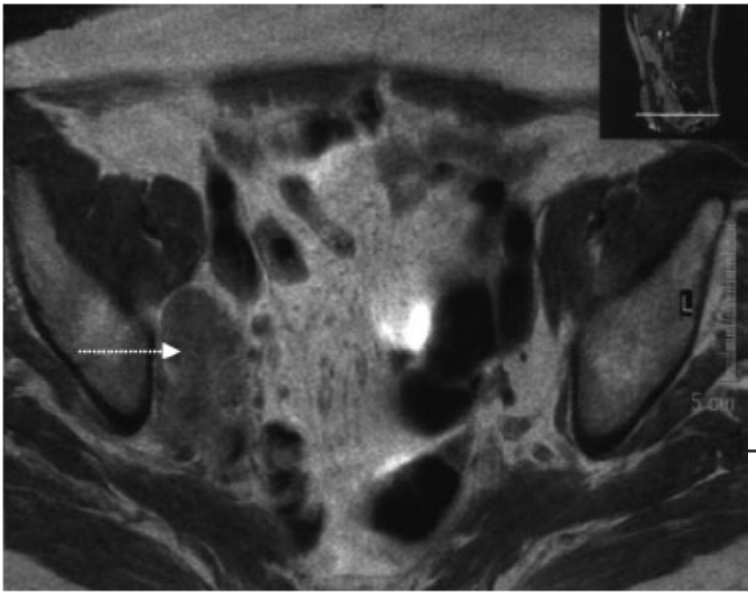

Relapses in the lateral spaces in radiological series: <10%

					Recurrent tumor location					
								Pelvic wall		
Primary tumor level (cm)	RT	Patients (n)	TME	Visible mesorectal fat	Anastomotic	Presacral midline	Presacral asymmetric	Medial	Lateral	Pelvic floor
0–5	All	39	38	8	7	14	12	7	4	19
	No	13	13	3	2	3	7	1	1	7
	Yes	26	25	5	5	11	5	6	3	12
6–10	All	20	18	13	10	9	5	5	2	1
	No	11	10	6	4	4	4	2	2	0
	Yes	9	8	7	6	5	1	3	0	1
11–15	All	24	16	21	16	4	3	5	0	1
	No	15	8	13	11	2	2	2	0	1
	Yes	9	8	8	5	2	1	3	0	0

Syc et al IJROBP 2008

Lateral Spaces

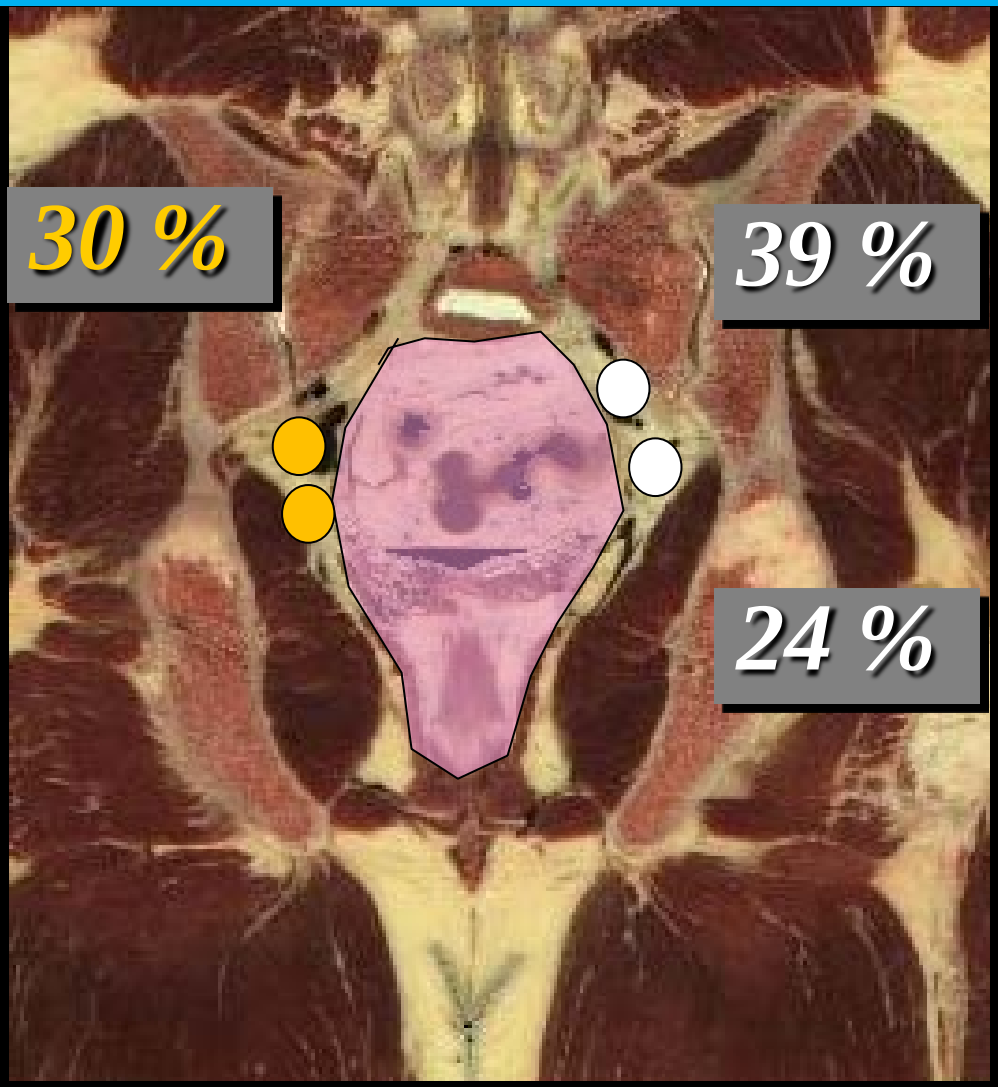

Tumor location

≤ 5 cm to dentate line

< peritoneal reflection

Diameter of rectal tumor

> 3 cm

< peritoneal reflection

Takahashi T et Al – Dis Colon Rectum -2000

Steup WH et Al – Eur J Cancer - 2002

Lateral Space

% pN+

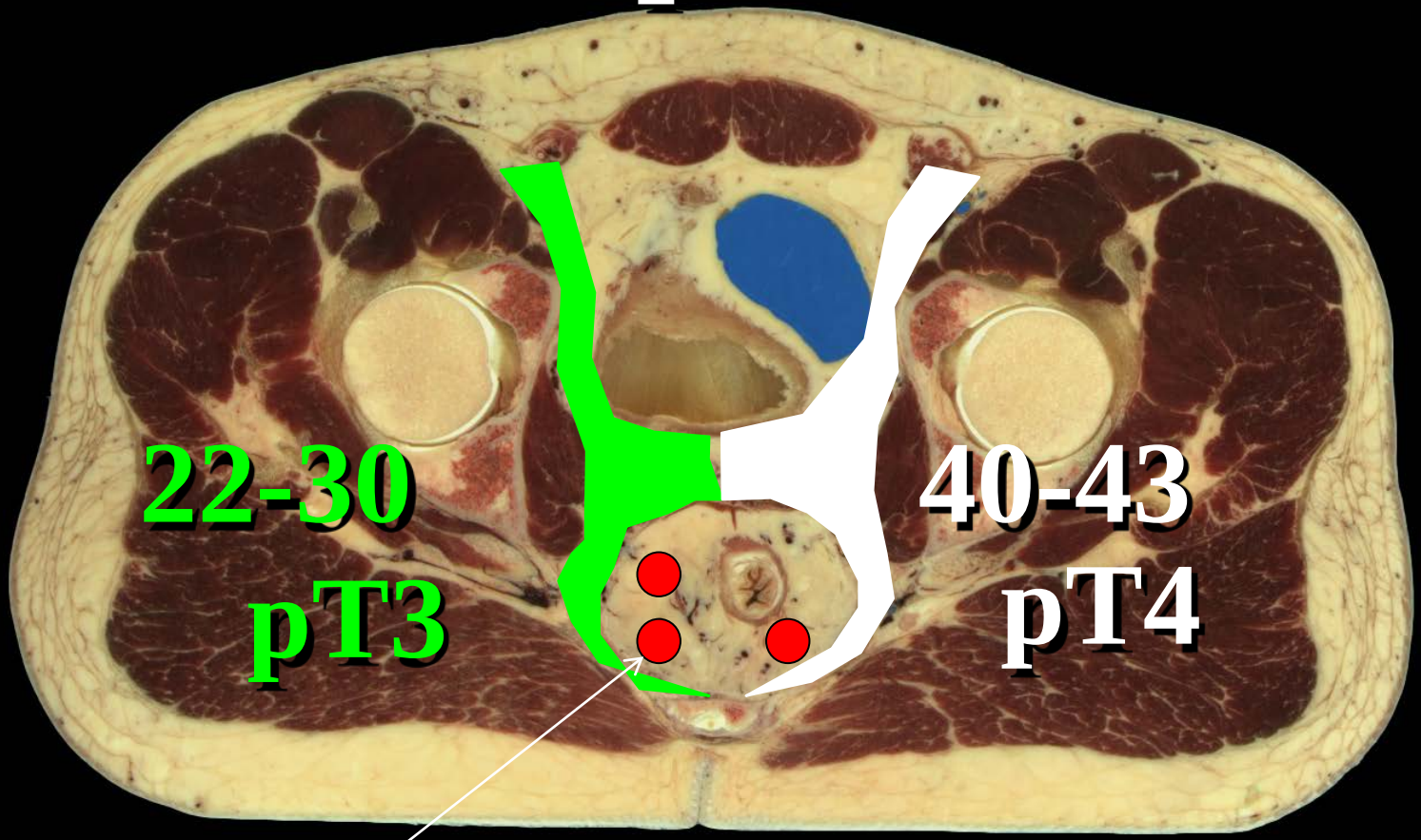

When N+
mesorectal

Moriya Y et Al - World J Surg - 1997

Hida J et Al -J Am Coll Surg - 1997

Lateral Spaces

Mesorectal Fascia

middle rectal artery/vein

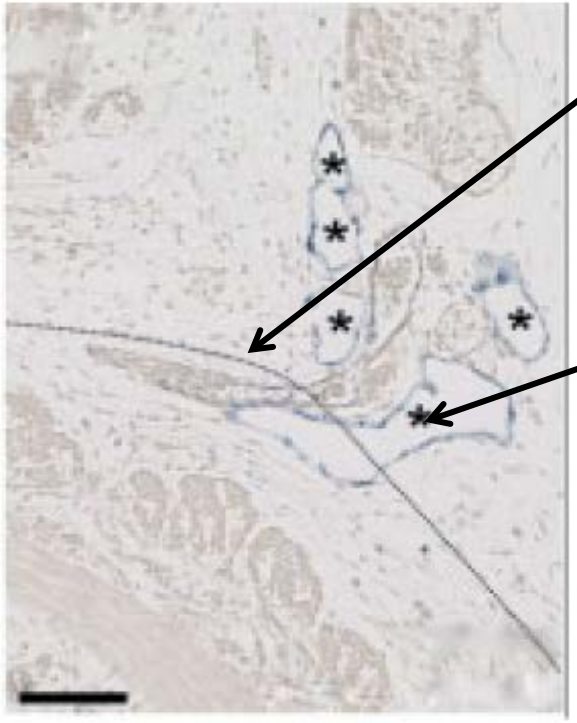

Mesorectal Fascia

Lymphatic tissue

d Detail, smooth muscle immunostain

e Detail, lymph tissue immunostain

"The middle rectal artery/veins entered the mesorectum below the peritoneal reflection[...]. Vessels were accompained by lymph tissue "

Kusters et al BJS 2010

Lateral Spaces

middle rectal artery/vein + lymphatic vessels

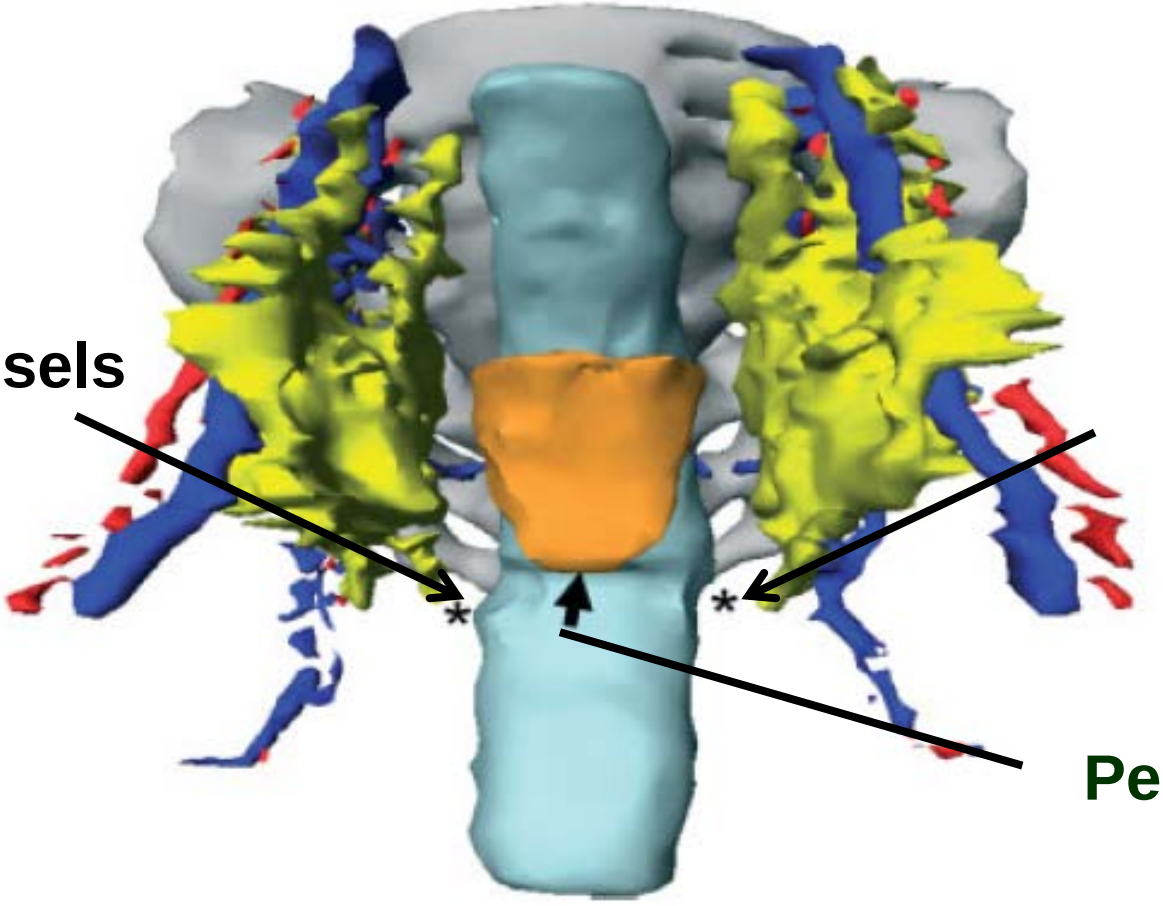

middle rectal artery/vein + lymphatic vessels

Peritoneal Reflection

Kusters et al BJS 2010

Delineation guidelines

Good consensus in subsites to be included in the Rectal Cancer CTV

Low consensus in subsites boundaries

DIFFERENT DELINEATION GUIDELINES!

European

Revision of literature for LR

ANATOMICAL SUBSITES

No consensus for boudaries

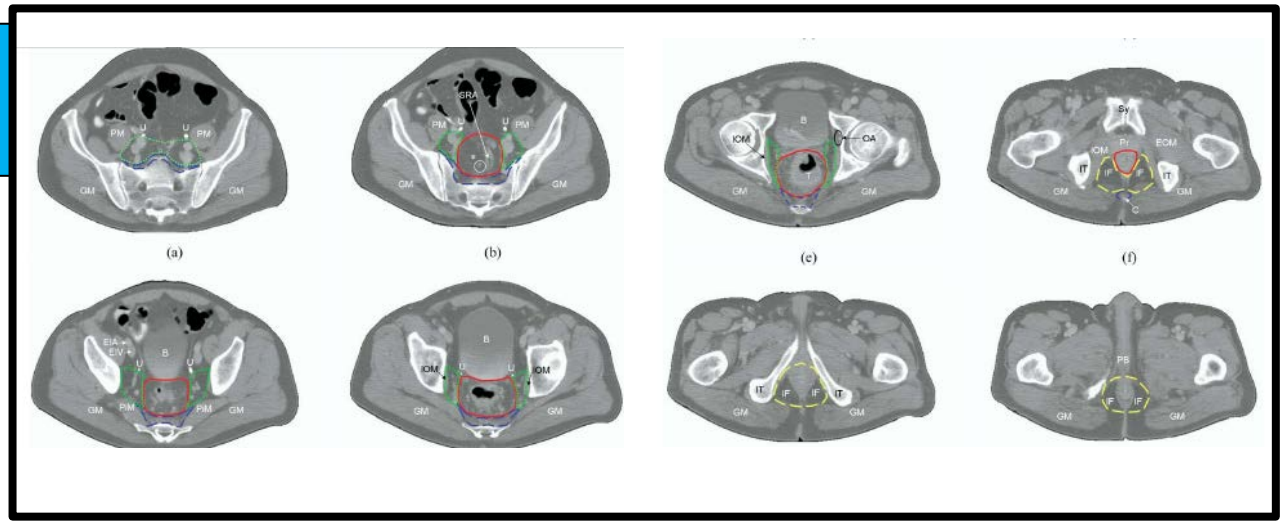

Roels S et al. IJROBP 2006

US

No literature revision

RT CTVs

EXPERT consensus

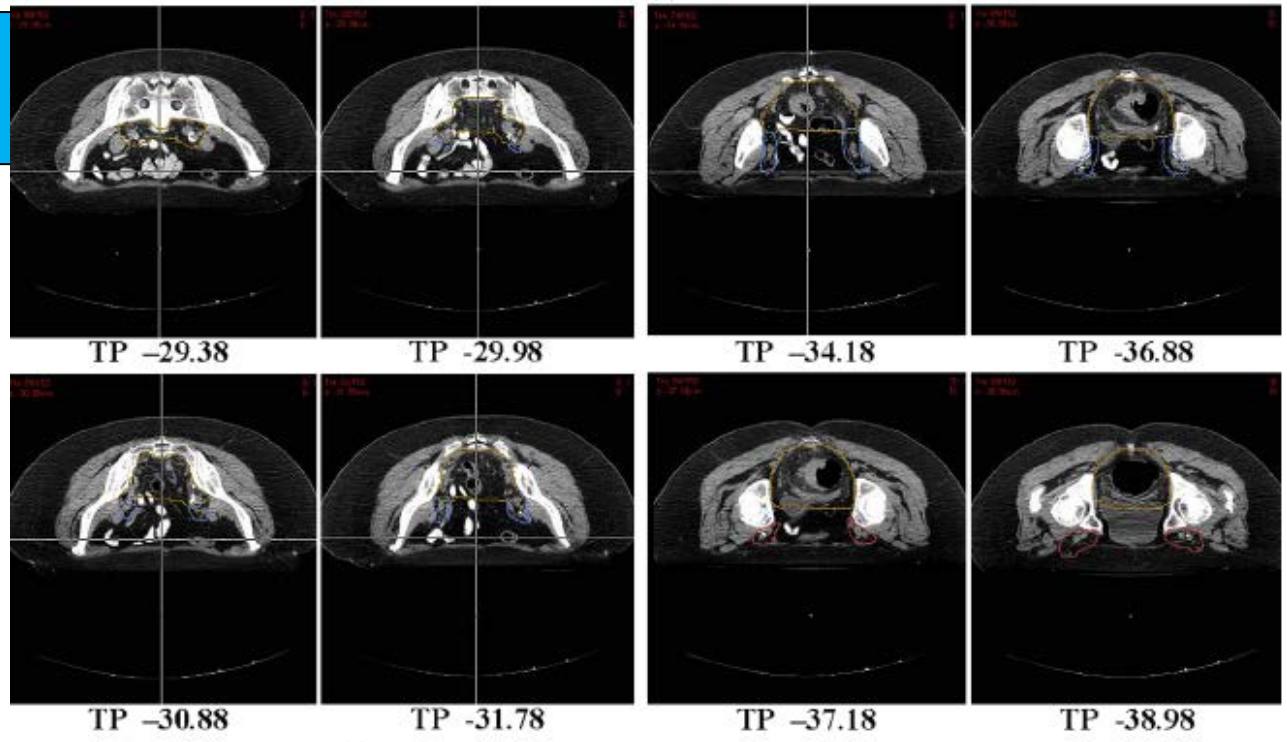

Myerson RJ et al. IJROBP 2008

Delineation guidelines

NO

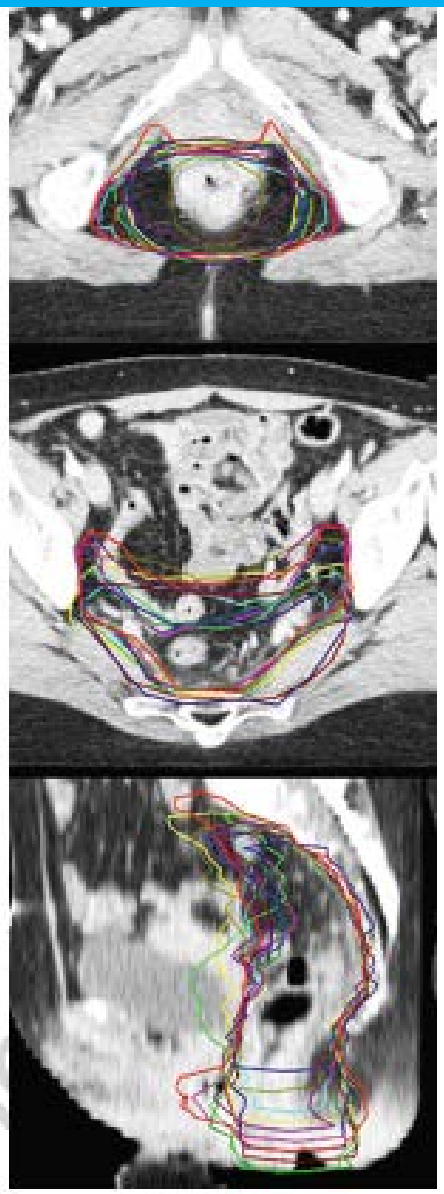

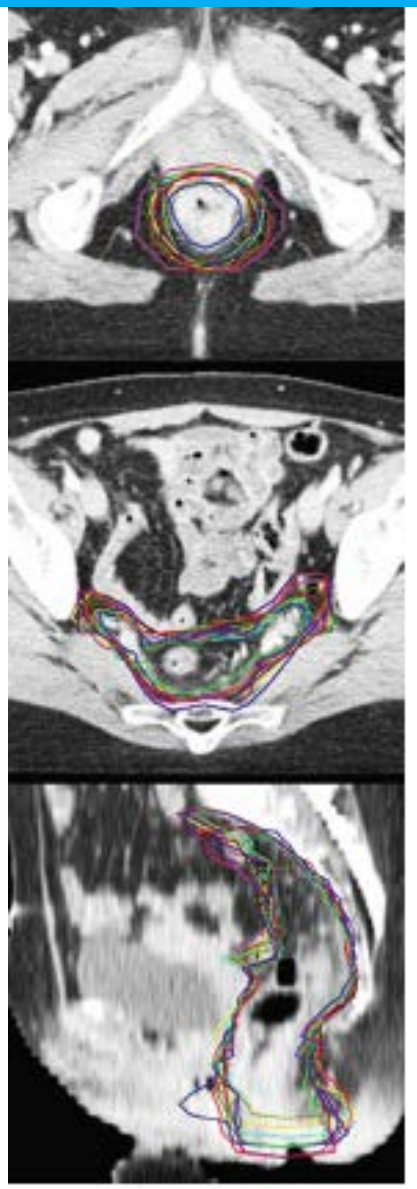

YES

Nijkamp J et al. Multidisciplinary Magement of Rectal Cancer 2012

Mesorectum: delineation guidelines

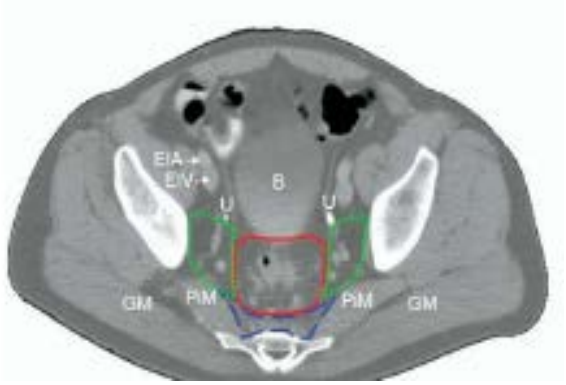

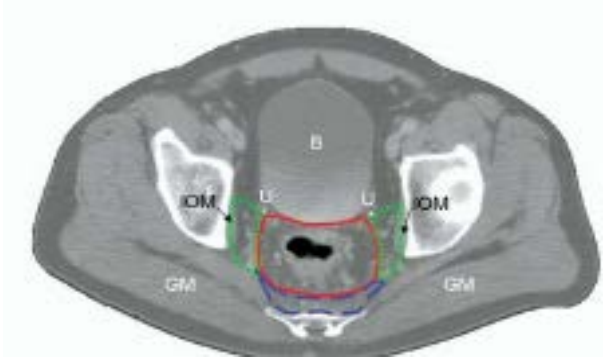

SUPERIOR
bifurcation of the IMA into the sigmoid artery and the upper rectal artery

ANTERIOR
Denonvillier **fascia**,recto-vaginal septum; anterior **pelvic organs**

Roels et al IJROBP 2006

Mesorectum: delineation guidelines

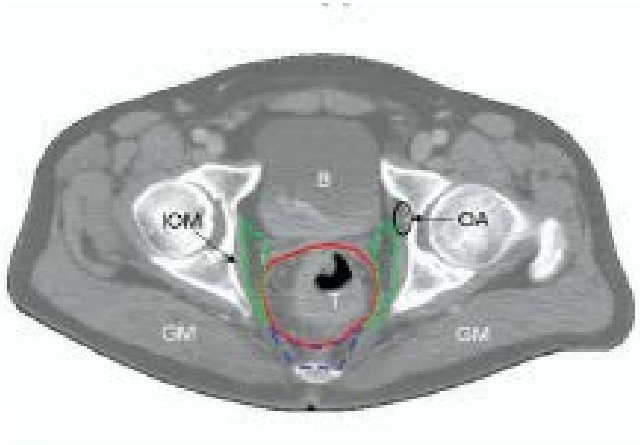

LATERAL
Mesorectal fascia

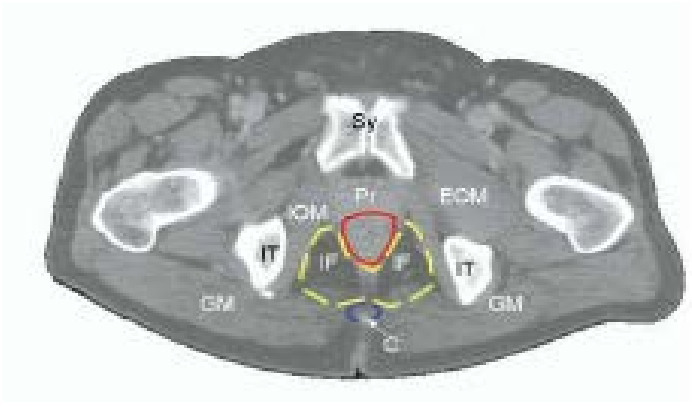

INFERIOR
Inserction of the levator ani muscle into the rectal wall

Roels et al IJROBP 2006

Presacral: delineation guidelines

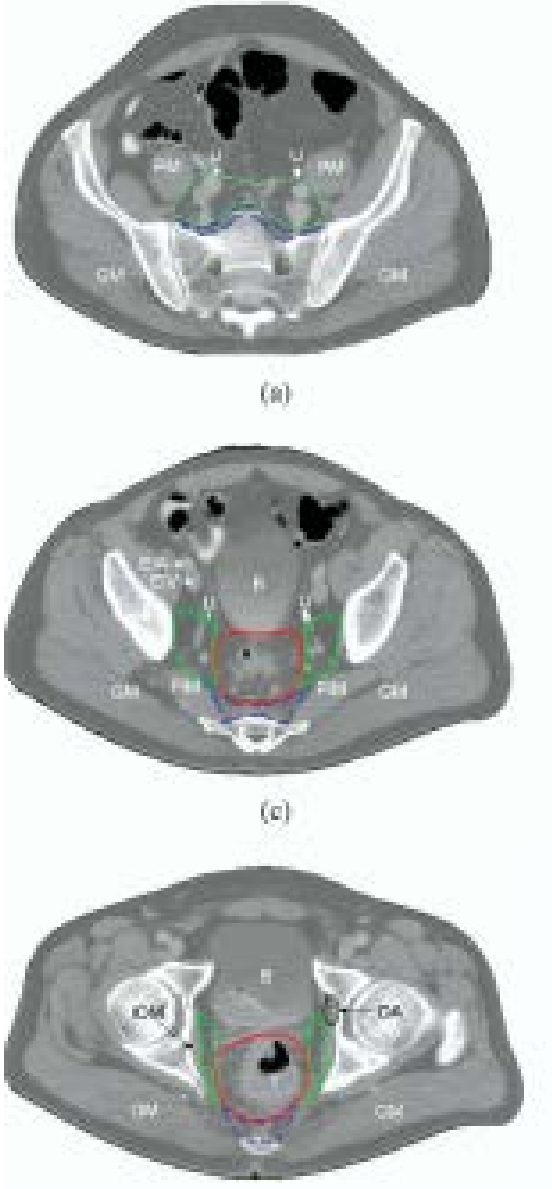

SUPERIOR
Sacral promontory

POSTERIOR
Sacrum

ANTERIOR
Mesorectum or 1 cm ventral to the sacrum

INFERIOR
Coccyx

LATERAL
Lateral borders of the Sacrum

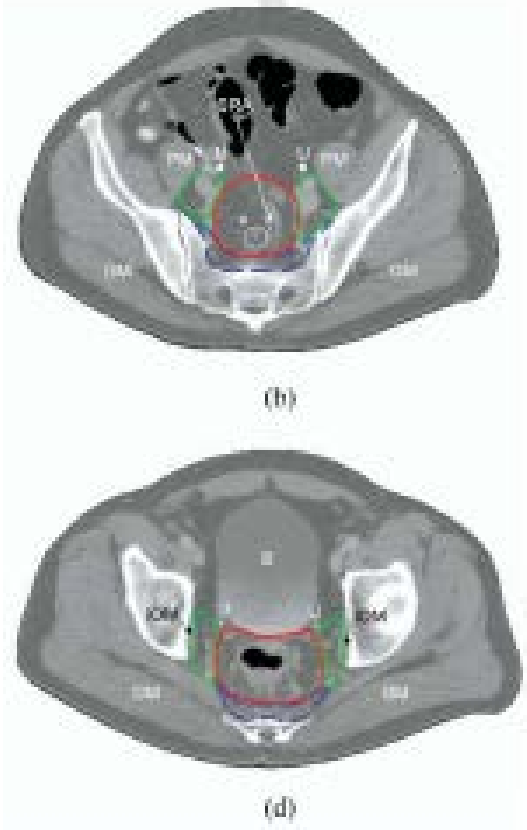

Roels et al IJROBP 2006

Lateral spaces: delineation guidelines

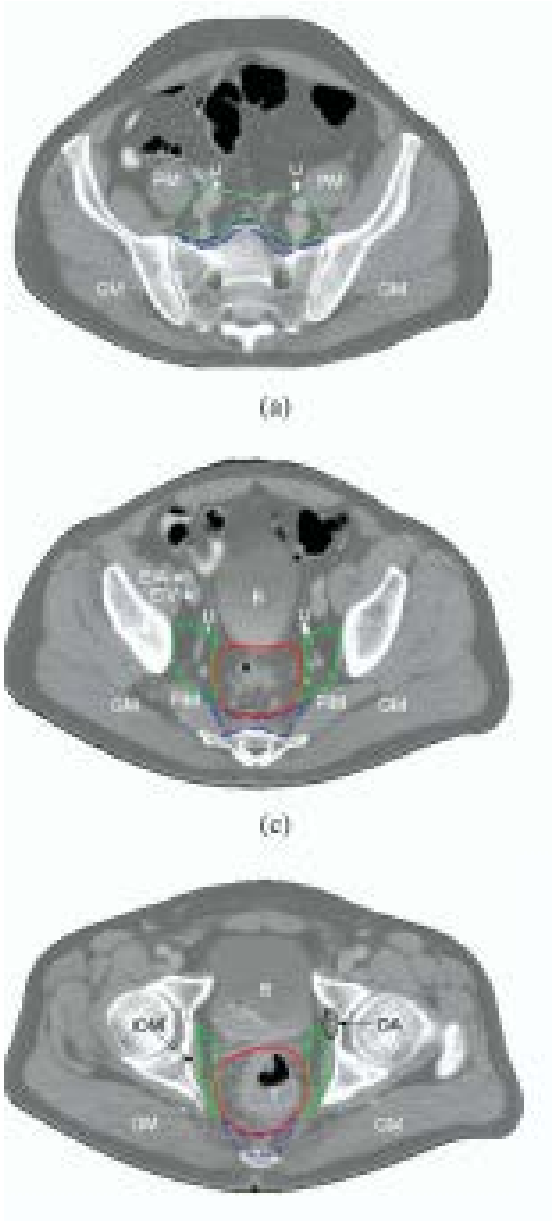

SUPERIOR
Bifurcation of iliac vessels

POSTERIOR
Sacro-iliac joints

ANTERIOR
ureter

INFERIOR
Where the obt artery enters in the obt canal

LATERAL
Psoas; ischium; piriform; intern ob; levator ani muscles

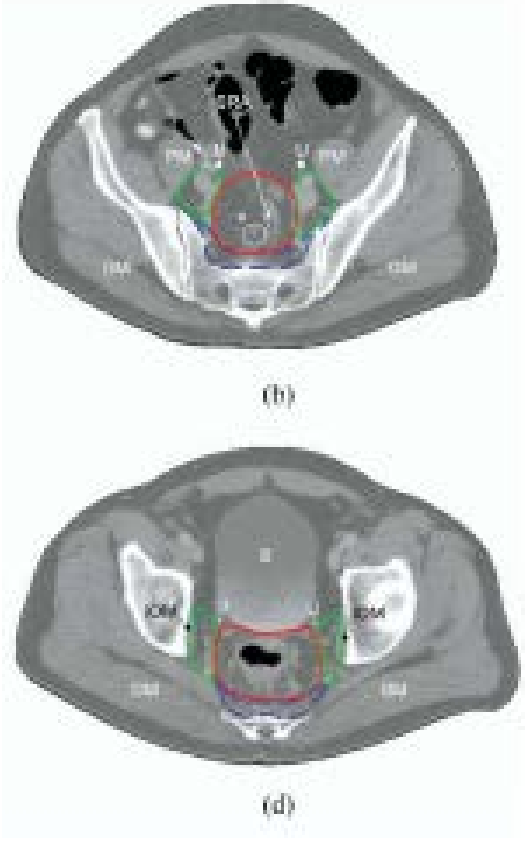

Roels et al IJROBP 2006

Lateral Spaces

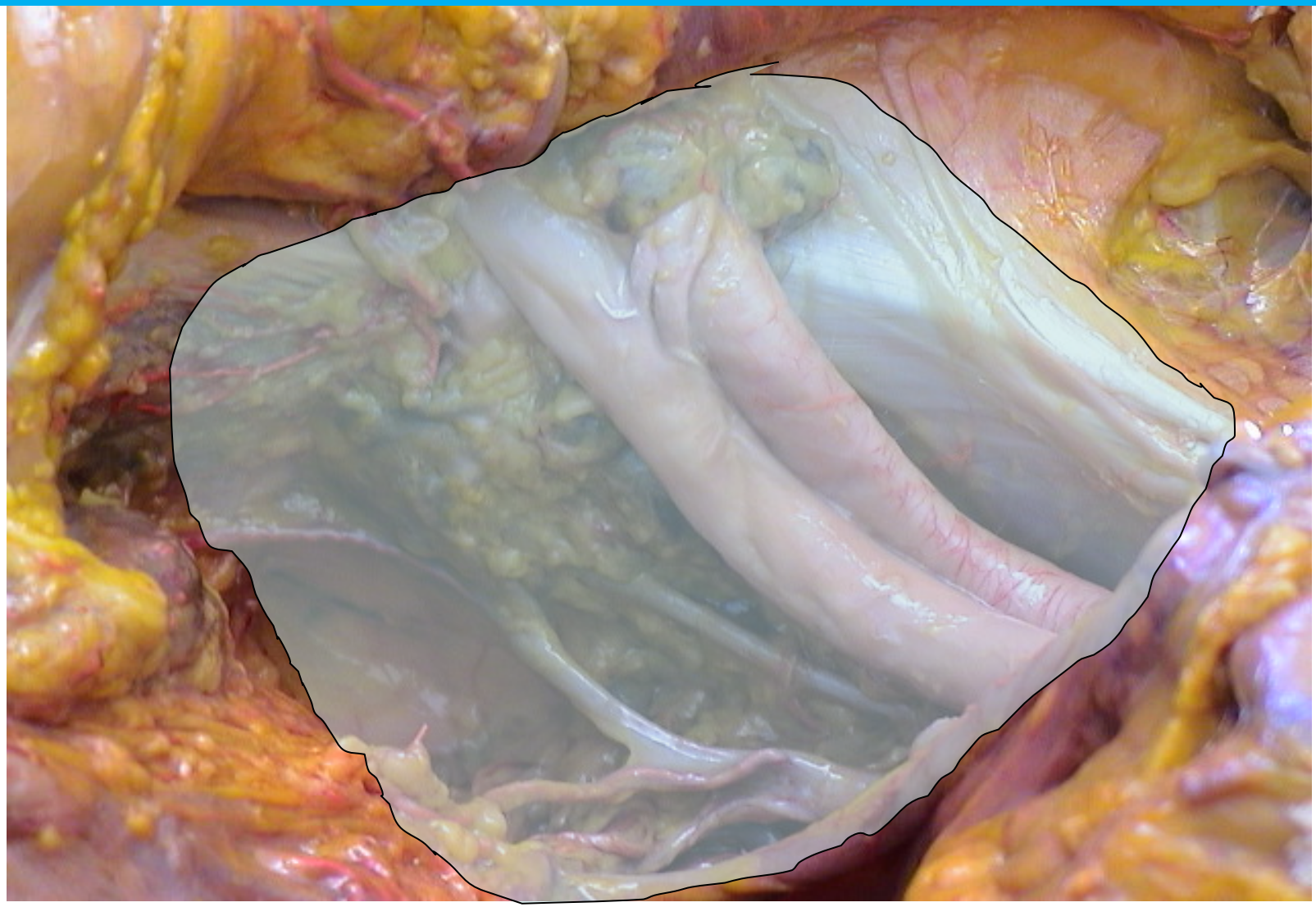

Lateral Spaces

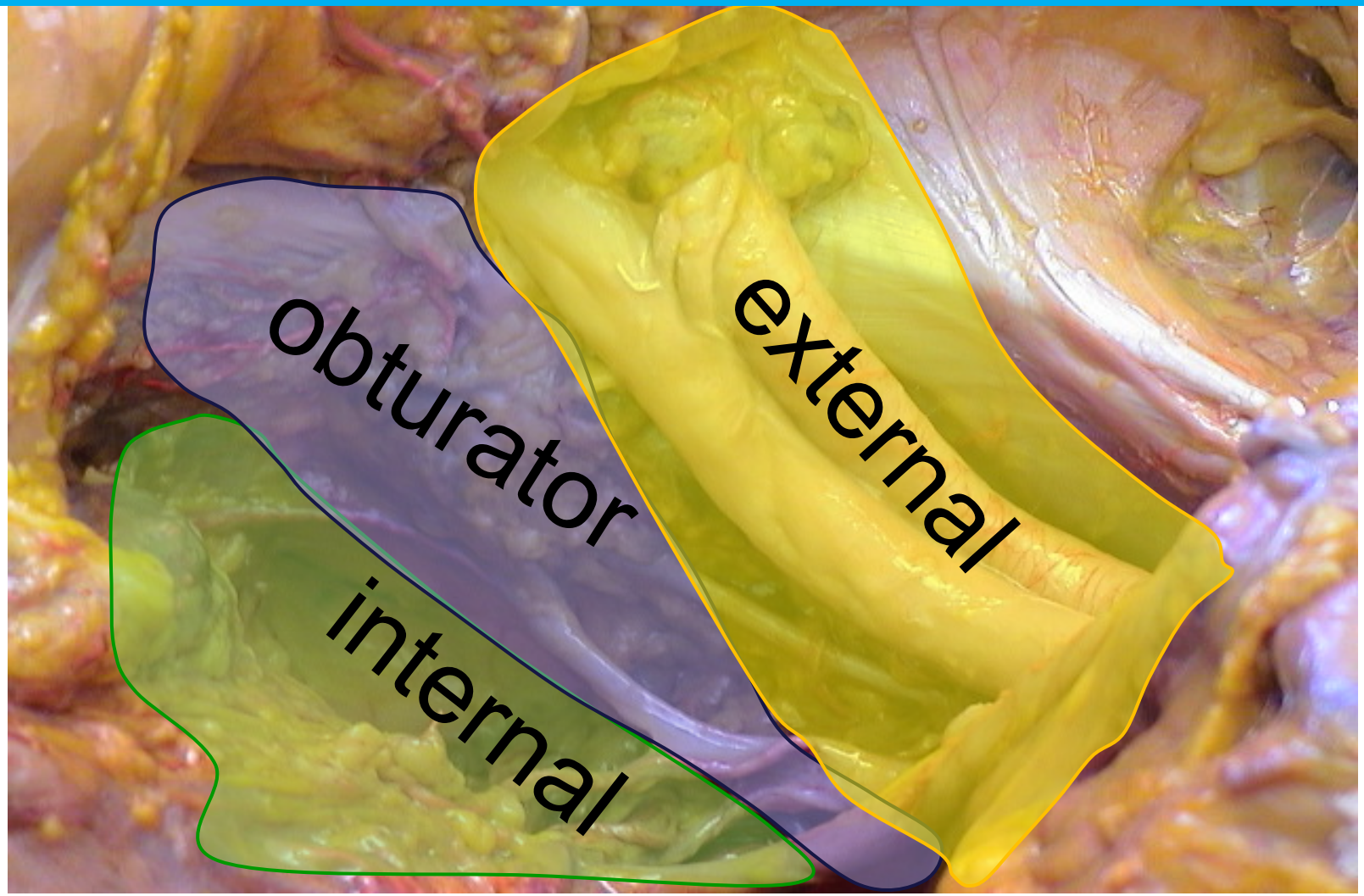

Lateral Space obturator nodes

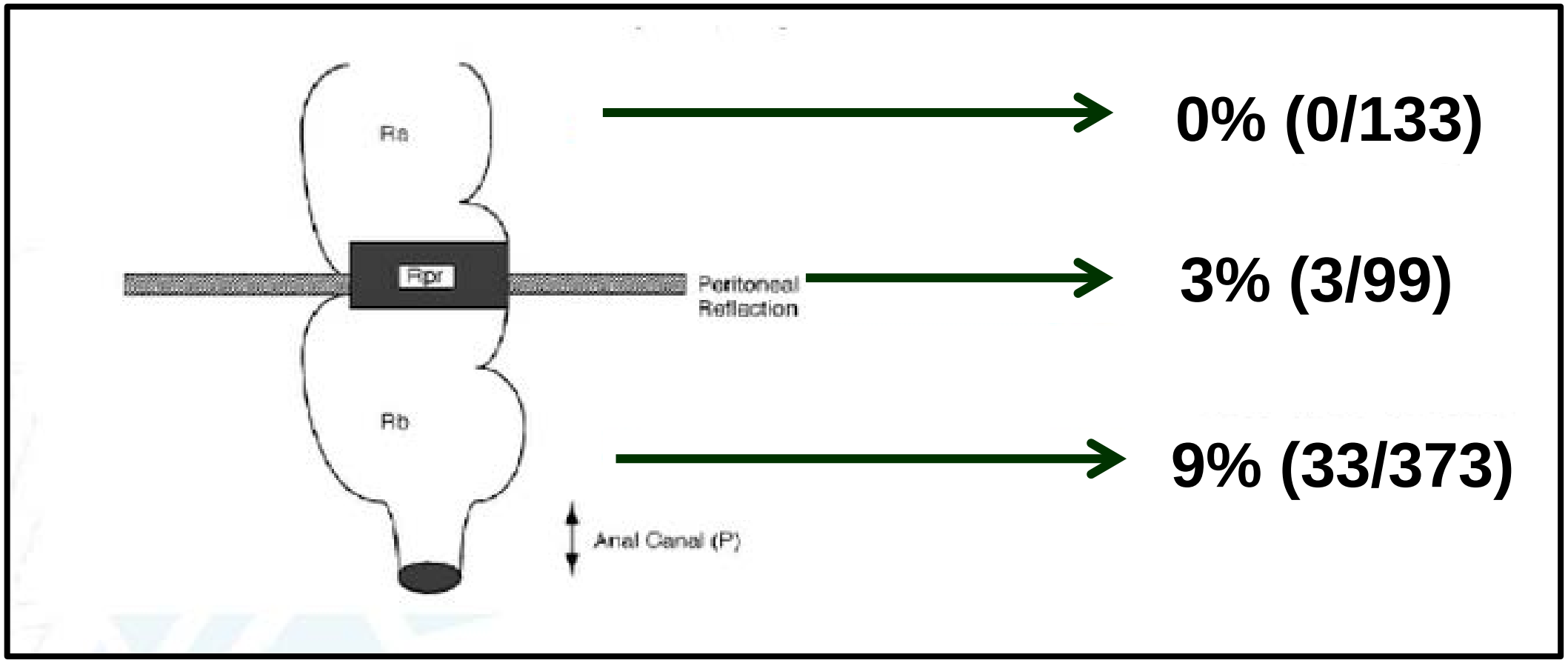

Steup et al EJC 200

External iliac nodes

- RL very rare in EIN: **4%**
- **When positive nodes: 9%**
- Found in **low seated tumors:**
- **APR vs LAR = 5% vs 3%**

Usually NOT included in the CTV, unless invasion of anterior organ

LOW CONSENSUS

Delineation guidelines

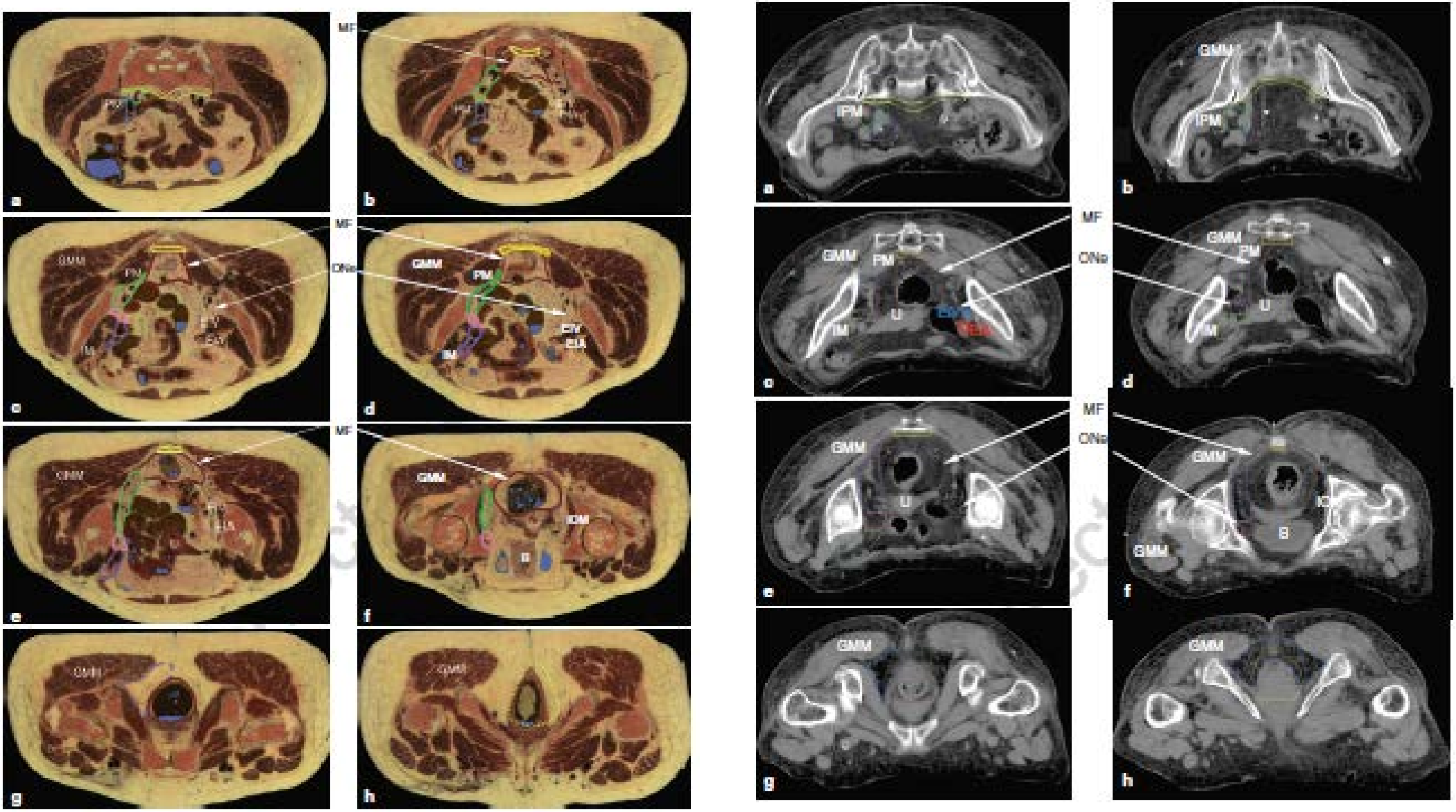

Gambacorta MA et al. Multidisciplinary Magement of Rectal Cancer

Delineation guidelines

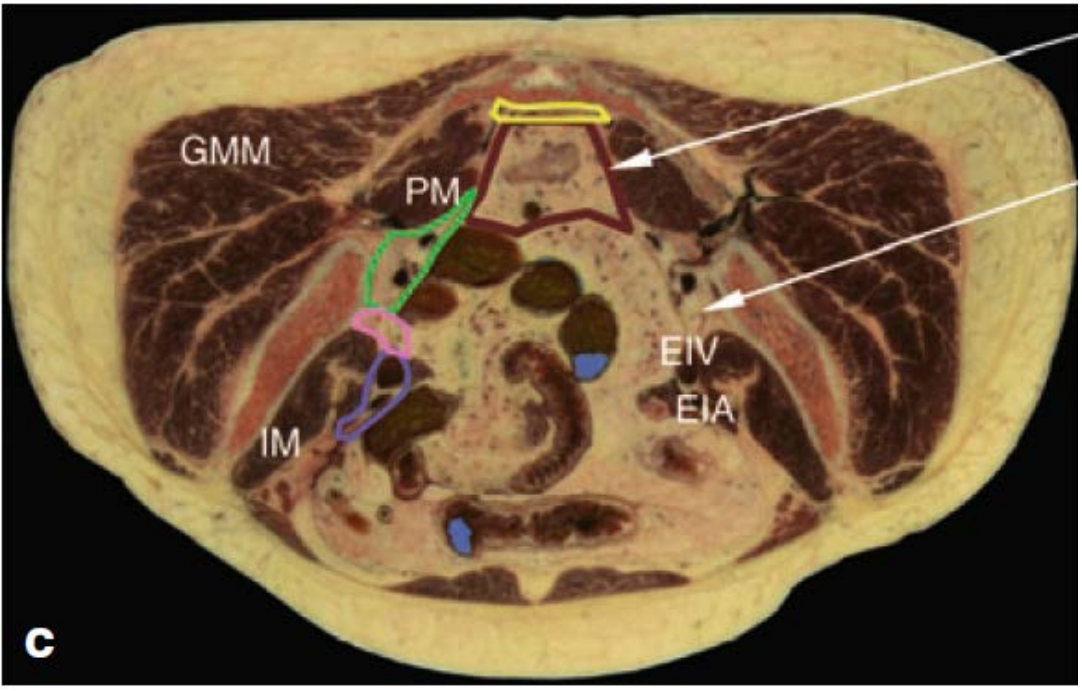

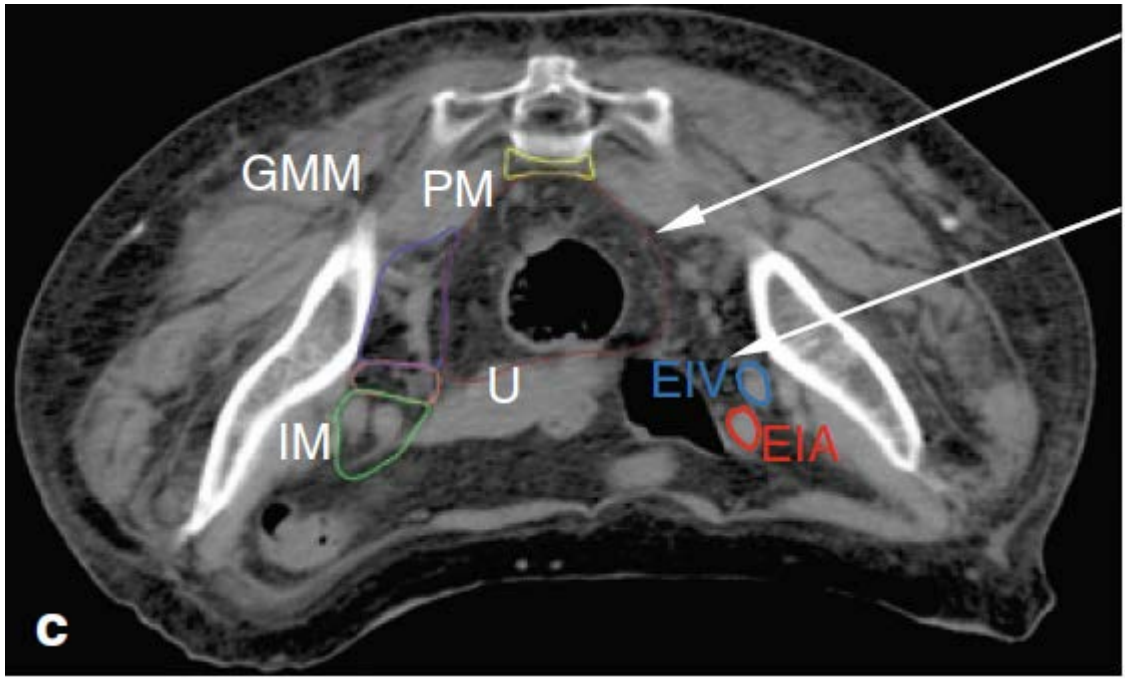

Gambacorta MA et al. Multidisciplinary Magement of Rectal Cancer

CTV modulation

	Presaral space	Mesorectum	Internal iliac nodes	Obturator nodes	Extrenal iliac nodes	sphincter complex	ischiorectal fossae
cT3 high (above the peritoneal reflection)	+	+	+				
cT3 mid-low (below the peritoneal reflection)	+	+	+	+		+ (when sphincter infiltration)	+ (when direct tumor infiltration)
Any cT with massive positive internal iliac nodes	+	+	+	+		+ (when sphincter infiltration)	+ (when direct tumor infiltration)
Any cT with massive positive obturator nodes nodes	+	+	+	+	+	+ (when sphincter infiltration)	+ (when direct tumor infiltration)
cT4 with for anterior pelvic organ	+	+	+	+	+	+ (when sphincter infiltration)	+ (when direct tumor infiltration)

Gambacorta et al. Multidisciplinary Magement of Rectal Cancer 2012

	Presaral space	Mesorectum	Internal iliac nodes	Obturator nodes	Extrenal iliac nodes	sphincter complex	ischiorectal fossae
cT3 high (above the peritoneal reflection)	+	+	+				
cT3 mid-low (below the peritoneal reflection)	+	+	+				
Any cT with massive positive internal iliac nodes	+	+	+				
Any cT with massive positive obturator nodes nodes	+	+	+				
cT4 with for anterior pelvic organ	+	+	+				

Gambacorta et al. Multidisciplinary Magement of Rectal Cancer 2012

	Presaral space	Mesorectum	Internal iliac nodes	Obturator nodes	Extrenal iliac nodes	sphincter complex	ischiorectal fossae
cT3 high (above the peritoneal reflection)	+	+	+				
cT3 mid-low (below the peritoneal reflection)	+	+	+	+			
Any cT with massive positive internal iliac nodes	+	+	+	+			
Any cT with massive positive obturator nodes nodes	+	+	+	+			
cT4 with for anterior pelvic organ	+	+	+	+			

Gambacorta et al. Multidisciplinary Magement of Rectal Cancer 2012

	Presaral space	Mesorectum	Internal iliac nodes	Obturator nodes	Extrenal iliac nodes	sphincter complex	ischiorectal fossae
cT3 high (above the peritoneal reflection)	+	+	+				
cT3 mid-low (below the peritoneal reflection)	+	+	+	+			
Any cT with massive positive internal iliac nodes	+	+	+	+			
Any cT with massive positive obturator nodes nodes	+	+	+	+	+		
cT4 with for anterior pelvic organ	+	+	+	+	+		

Gambacorta MA et al. Multidisciplinary Magement of Rectal Cancer

	Presaral space	Mesorectum	Internal iliac nodes	Obturator nodes	Extrenal iliac nodes	sphincter complex	ischiorectal fossae
cT3 high (above the peritoneal reflection)	+	+	+				
cT3 mid-low (below the peritoneal reflection)	+	+	+	+			
Any cT with massive positive internal iliac nodes	+	+	+	+			
Any cT with massive positive obturator nodes nodes	+	+	+	+	+		
cT4 with for anterior pelvic organ	+	+	+	+	+		

Gambacorta MA et al. Multidisciplinary Magement of Rectal Cancer

CTV modulation

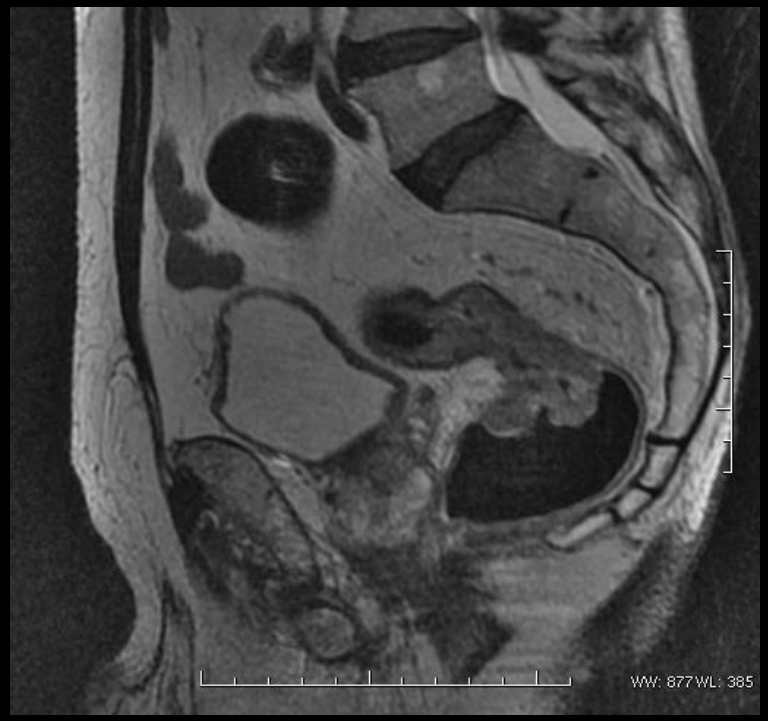

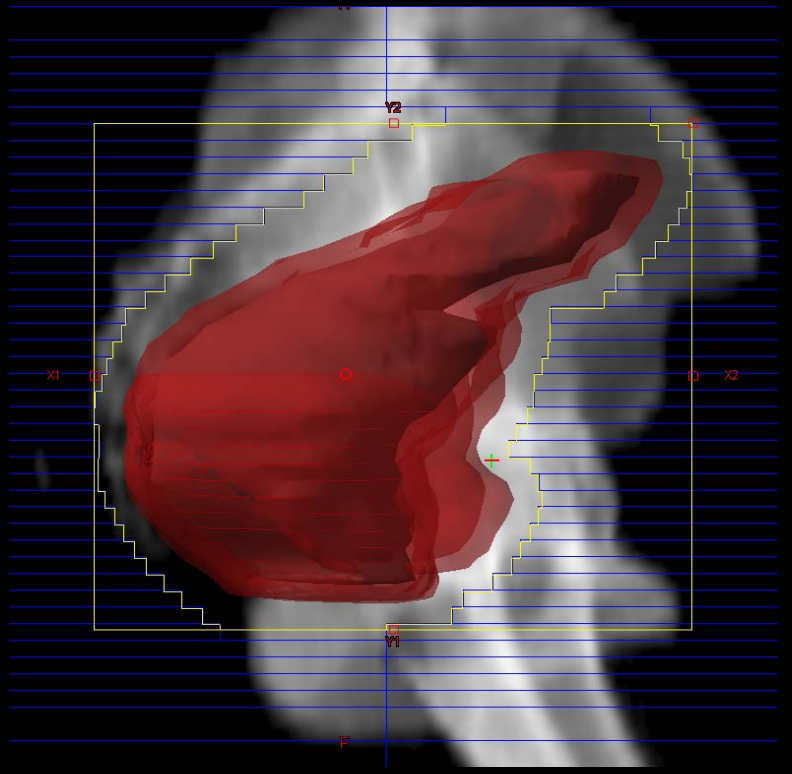

Mid tumor above the PR

CTV modulation

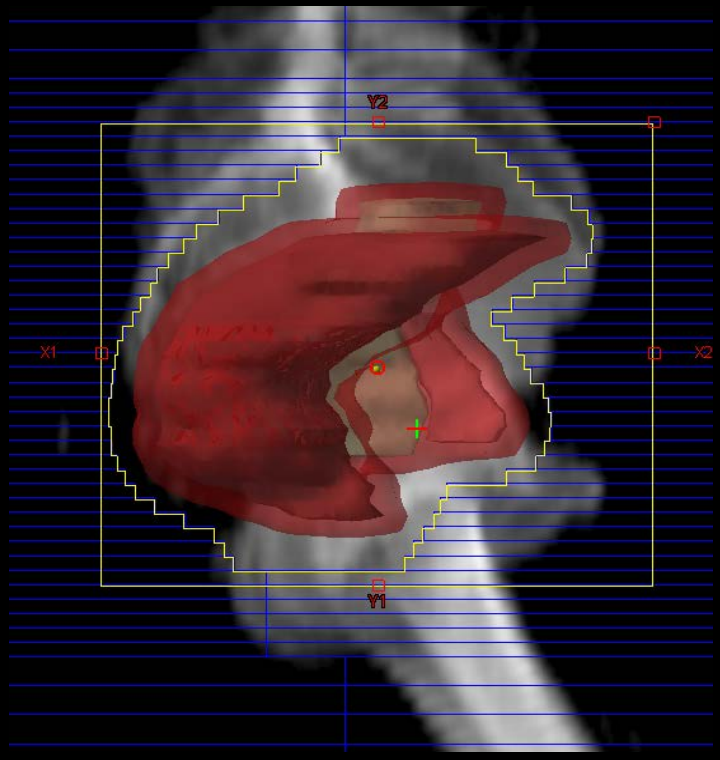

low tumor below the PR

Gambacorta MA et al. Multidisciplinary Magement of Rectal Cancer 2012

CTV modulation

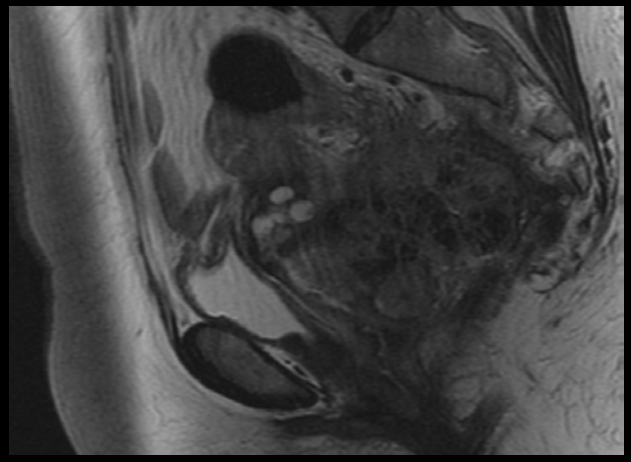

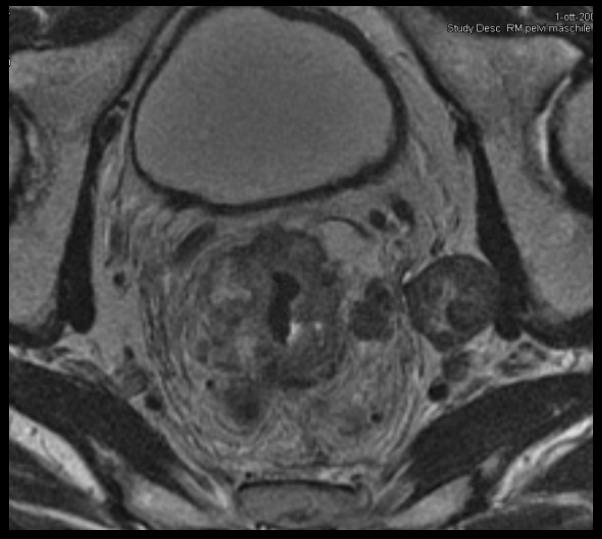

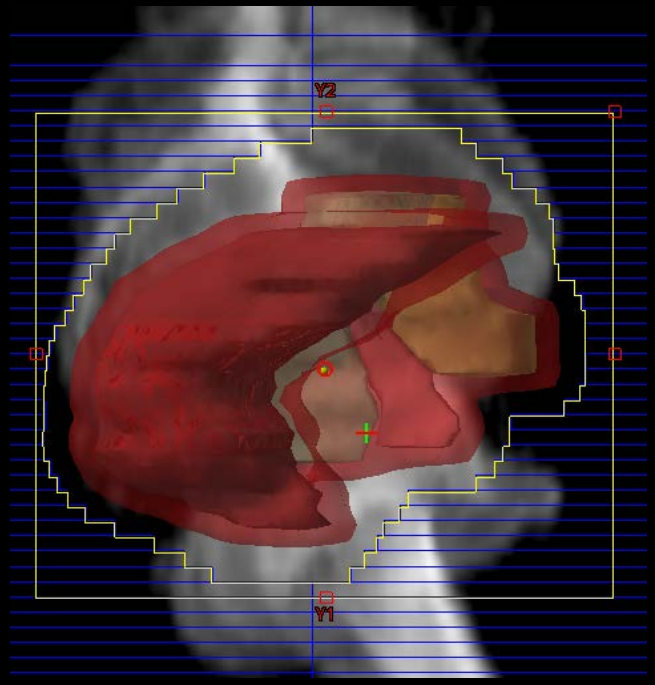

cT4 invading anterior organ or N+ in the lateral space

Gambacorta MA et al. Multidisciplinary Magement of Rectal Cancer 2012

Inferior pelvic subsite
(sphincter complex and ischiorectal fossae)

- **IPS** has a risk of **LR: 4%,**
- low seated tumors **(<6 cm** from the AV): **8%**
- after APR: **11%**

- **Reccomendation for inclusion in CTV**
  - T ≤ 6 cm from AV (central part), when a SSS
  - T invading anal sphincter and APR

Roels et al IJROBP 2006

Inferior pelvic subsite

Levator ani anatomic barrier

No lymphatic in the ischiorectal fossae

sphincter complex + margin:
when direct infiltration

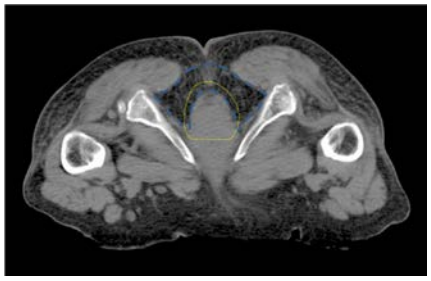

Ischiorectal fossae:
when direct infiltration

Myerson et al IJROBP 2009

Bujiko IJROBP 2007

Inferior pelvic subsite

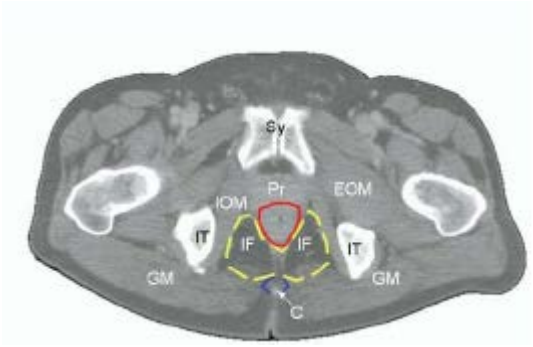

LATERAL
internal obturator muscles,
ischial tuberosities

POSTERIOR
coccix gluteal muscles

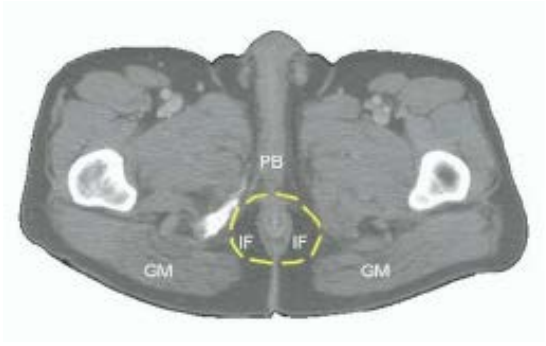

ANTERIOR
penile bulb

Roels et al IJROBP 2006

CTV modulation

	Presaral space	Mesorectum	Internal iliac nodes	Obturator nodes	Extrenal iliac nodes	sphincter complex	ischiorectal fossae
cT3 high (above the peritoneal reflection)	+	+	+				
cT3 mid-low (below the peritoneal reflection)	+	+	+	+		+ (when sphincter infiltration)	+ (when direct tumor infiltration)
Any cT with massive positive internal iliac nodes	+	+	+	+		+ (when sphincter infiltration)	+ (when direct tumor infiltration)
Any cT with massive positive obturator nodes nodes	+	+	+	+	+	+ (when sphincter infiltration)	+ (when direct tumor infiltration)
cT4 with for anterior pelvic organ	+	+	+	+	+	+ (when sphincter infiltration)	+ (when direct tumor infiltration)

Gambacorta et al. Multidisciplinary Magement of Rectal Cancer 2012

Inguinal nodes

RL very rare in IN: **1%**

Found in **low seated tumors**

Usually included in the CTV, in RC invading the **anus, lower third of the vagina**.

LOW CONSENSUS

Roels et al IJROBP 2006

Myerson et al IJROBP 2009

PTV definition

Shape variation

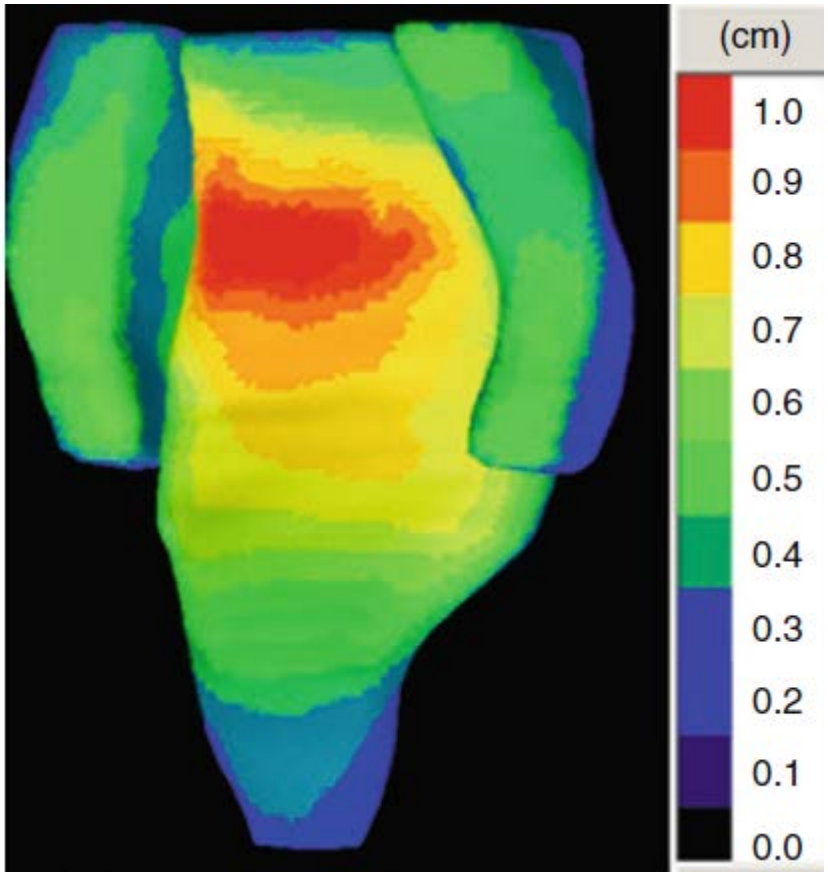

Set-up

Prone up to **0.24 cm**

left-right direction

Supine < 0.1 cm

Nijkamp J et al. Radiother Oncol 2009

To summarize

- Refer to **GUIDELINES** to reduce variability
- **Modulate CTV** according to T stage and T location
- Account for **CTV shape variations**
- **SET-UP:**

  Prone position + belly board + full bladder: (less SB) in **3D**

  Supine position: (MORE STABLE) in **IMRT**

GTV and CTV delineation for Anal Cancer
Delineation of Organ at Risk in Ano-Rectal cancer

M.A. Gambacorta

Radiotherapy Dept.
Università Cattolica del Sacro Cuore
Rome

Policlinico Agostino Gemelli
Università Cattolica del Sacro Cuore

GemelliART
Advanced Radiation Therapy



Radiotherapy and Oncology
June 2014 111(3):330–339,

clinical practice guidelines

Annals of Oncology 00: 1–11, 2014
doi:10.1093/annonc/mdu159

Anal cancer: ESMO-ESSO-ESTRO Clinical Practice Guidelines for diagnosis, treatment and follow-up†

R. Glynne-Jones[1], P. J. Nilsson[2], C. Aschele[3], V. Goh[4], D. Peiffert[5], A. Cervantes[6] & D. Arnold[7*]

[1]*Centre for Cancer Treatment, Mount Vernon Hospital, Northwood, Middlesex, UK;* [2]*Department of Molecular Medicine and Surgery, Karolinska Institutet and Center for Surgical Gastroenterology, Karolinska University Hospital, Stockholm, Sweden;* [3]*Medical Oncology and Hematology, Felettino Hospital, La Spezia, Italy;* [4]*Division of Imaging Sciences and Biomedical Engineering, King's College London, London, UK;* [5]*Department of Radiotherapy, Centre Alexis Vautrin, Vandoeuvre-lès-Nancy, France;* [6]*Department of Hematology and Medical Oncology, INCLIVA, University of Valencia, Valencia, Spain;* [7]*Klinik für Tumorbiologie, Freiburg, Germany*

The anal canal extends from the anorectal junction to the anal margin

The columnar, or cylindric, epithelium of the rectum extends to about 1 cm above the dentate line where the anal transitional zone begins.

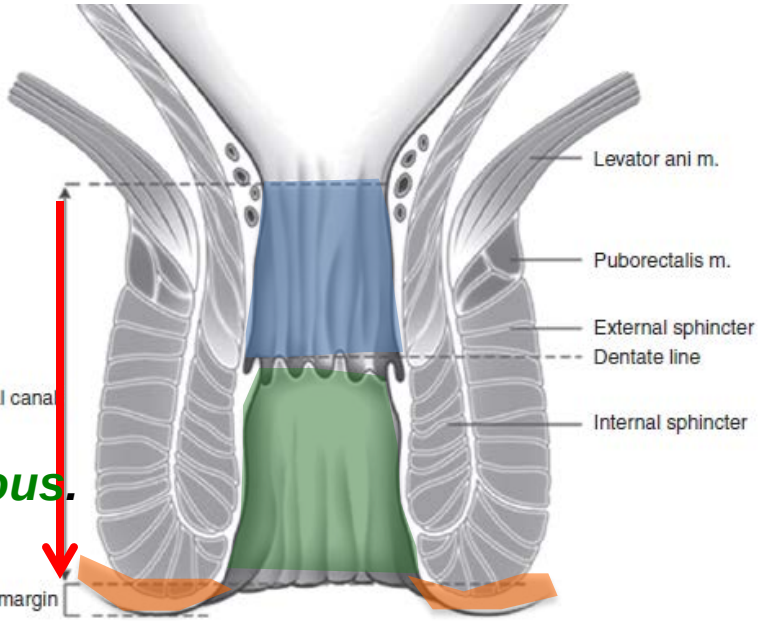

Below the dentate line the epithelium is all squamous.

The anal margin is the pigmented skin immediately surrounding the anal orifice, extending laterally to a radius of approximately 5 cm.

LYMPHATIC PATHWAYS

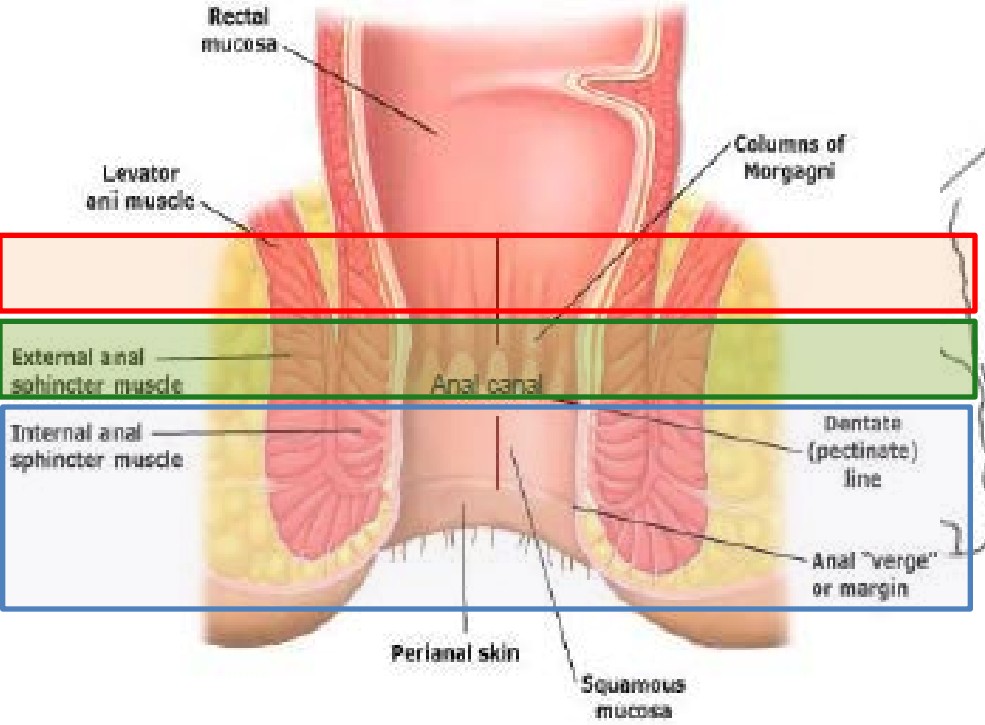

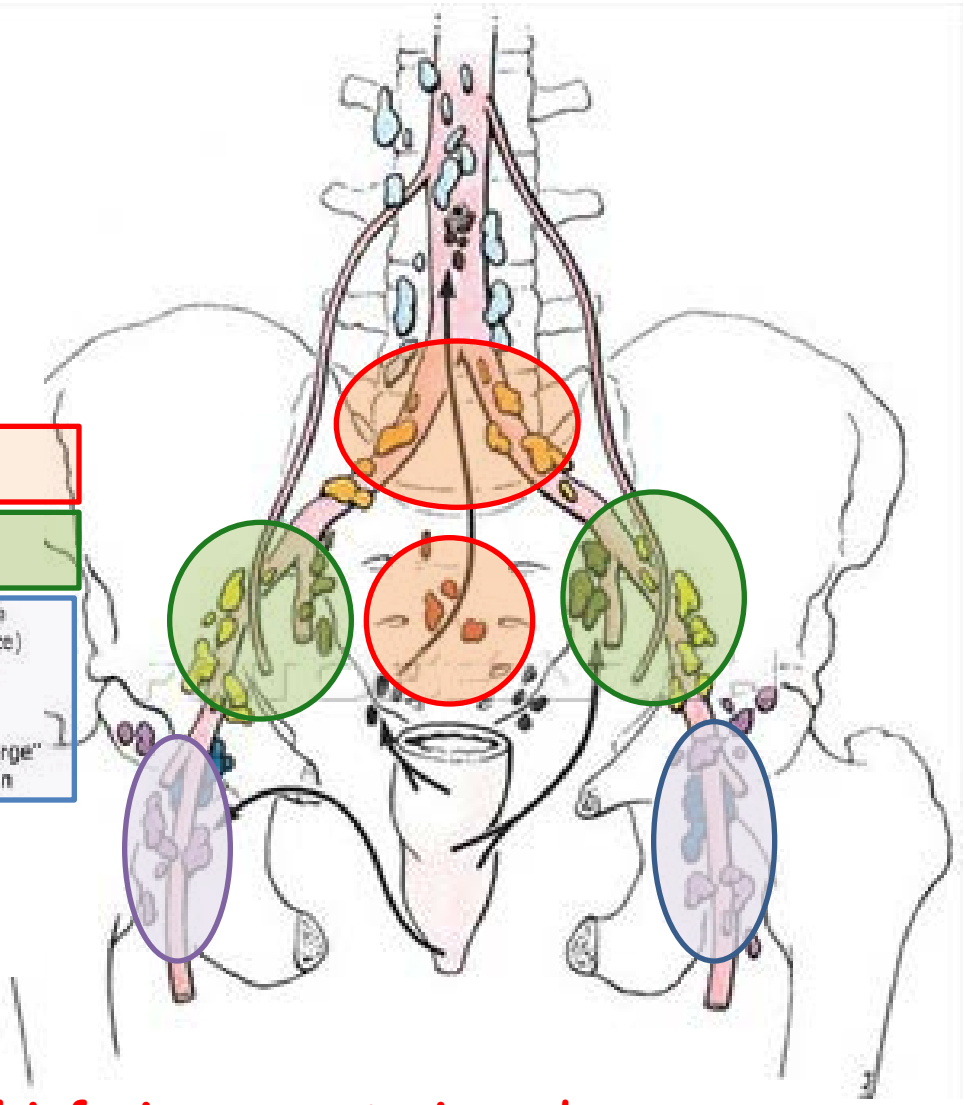

Perirectal, superior hemorroidal and inferior mesenteric nodes

Internal pudendal, hypogastric and obturator nodes

Inguinal, femoral and external iliac nodes

The overall risk of **regional nodal involvement** at diagnosis is about **25%**. **Pelvic lymph node metastases** have been found in as many as **30%** of patients treated by abdominoperineal resection.

Extrapelvic metastases are identified in **fewer than 10%** of patients.

Superior hemorrhoidal nodes metastases are present in about in **25%,**

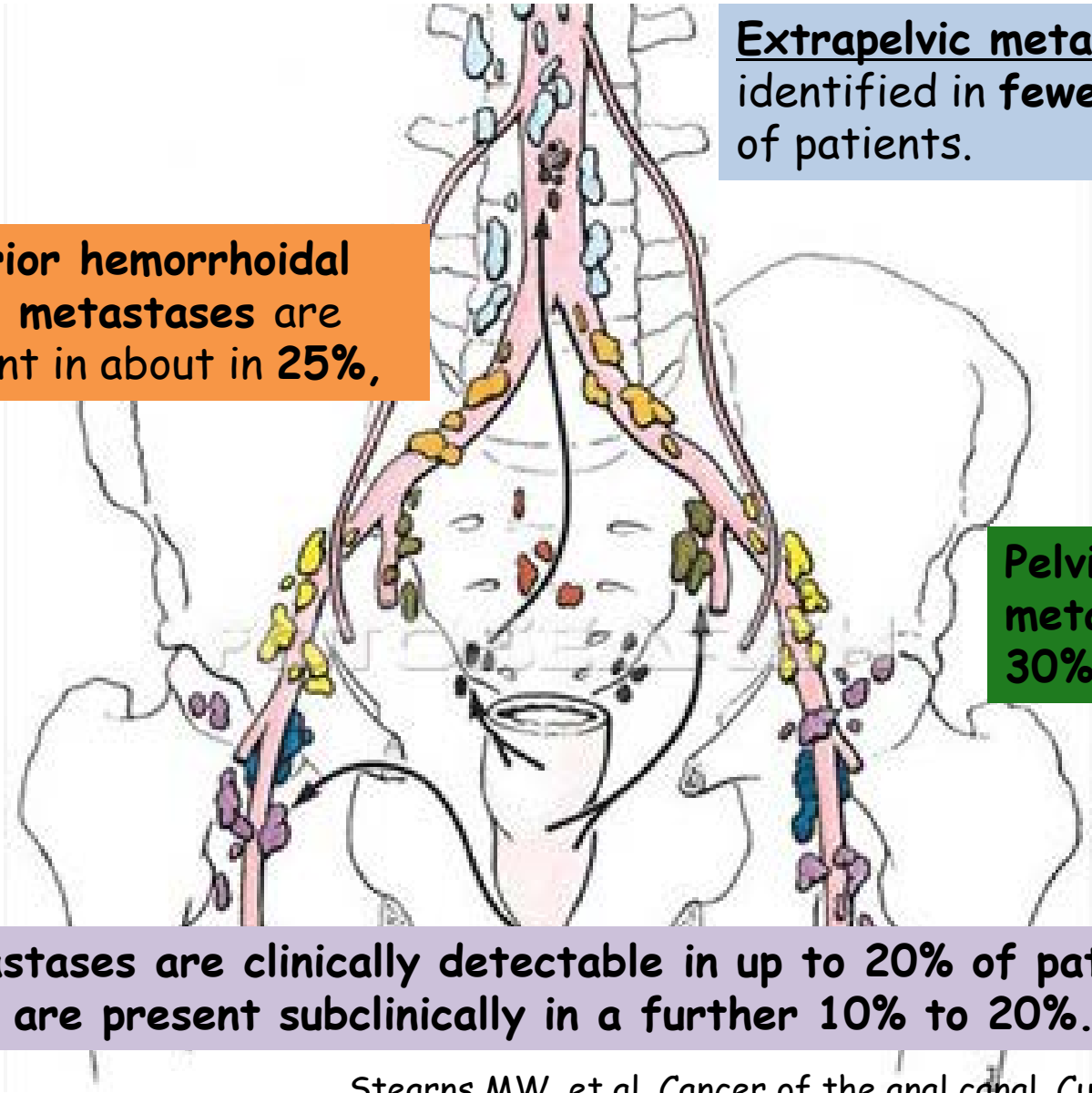

Pelvic nodes metastases in **30%**

Inguinal metastases are clinically detectable in up to 20% of patients at initial diagnosis and are present subclinically in a further 10% to 20%.

Stearns MW, et al. Cancer of the anal canal. Curr Probl Cancer 1980

The finding in surgical series of histopathologically verified metastases in the **pararectal and internal iliac nodes in up to 30%** and in **inguinal nodes in up to 20%** has encouraged most centers to irradiate these node groups electively.

As a result, planning target volumes may be extensive.

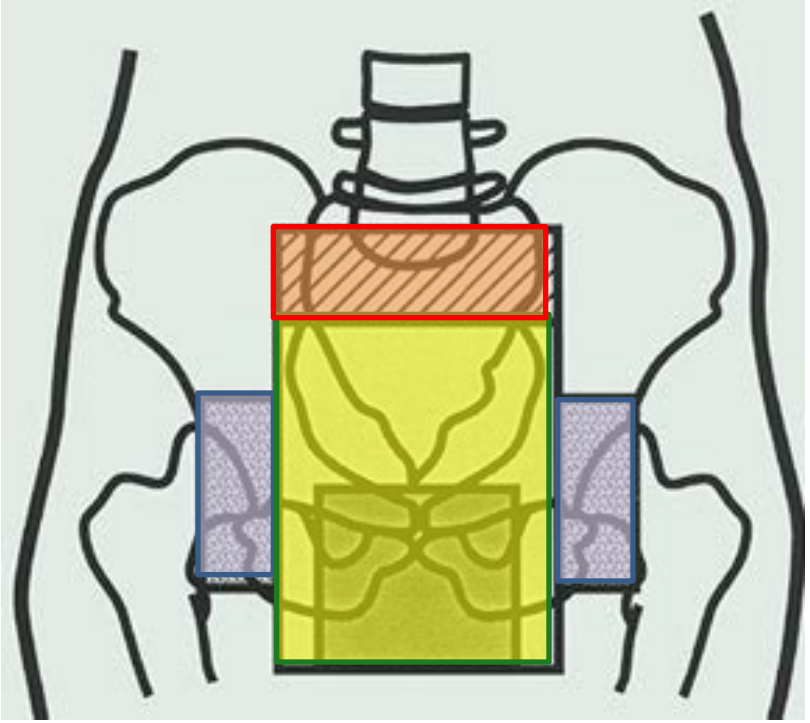

Only well-differentiated squamous cell cancers ≤2 cm in size situated in the distal canal appear to have a risk of nodal metastases <5%.

PATTERNS OF RECURRENCE

180 SCCAC patients, retrospectively reviewed
(173 patients mitomycin-based CHT-RT)
January 1990 - March 2007
Memorial Sloan-Kettering Cancer Center
Median primary tumor dose = **45 Gy**
3-year LRF = 23%.

56% had local-only failure

22% had both local and regional failure

22% had regional-only failure.

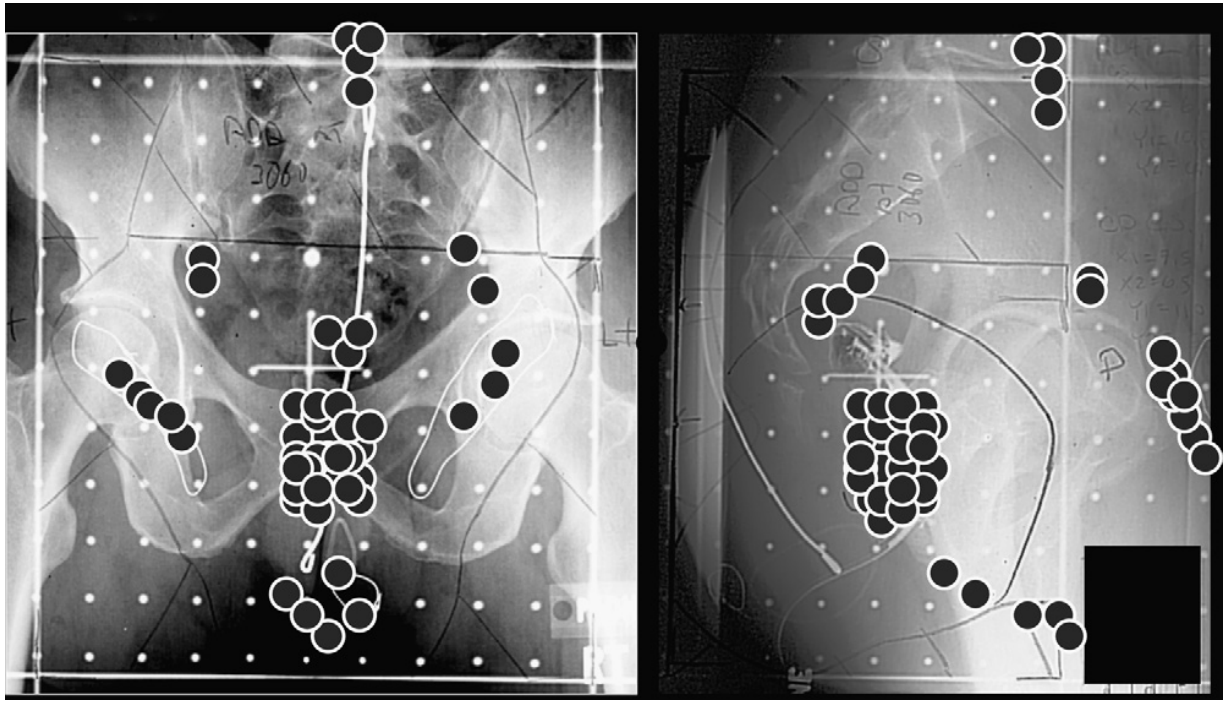

J. L. Wright et al, Int. J. Radiation Oncology Biol. Phys. 2010

PATTERNS OF RECURRENCE

167 SCCAC patients CHT-RT

September 1992 and August 2004
M. D. Anderson Cancer Center

Median primary tumor dose = **55 Gy**
LRF=14%
estimated 3-year LRC = 81%.

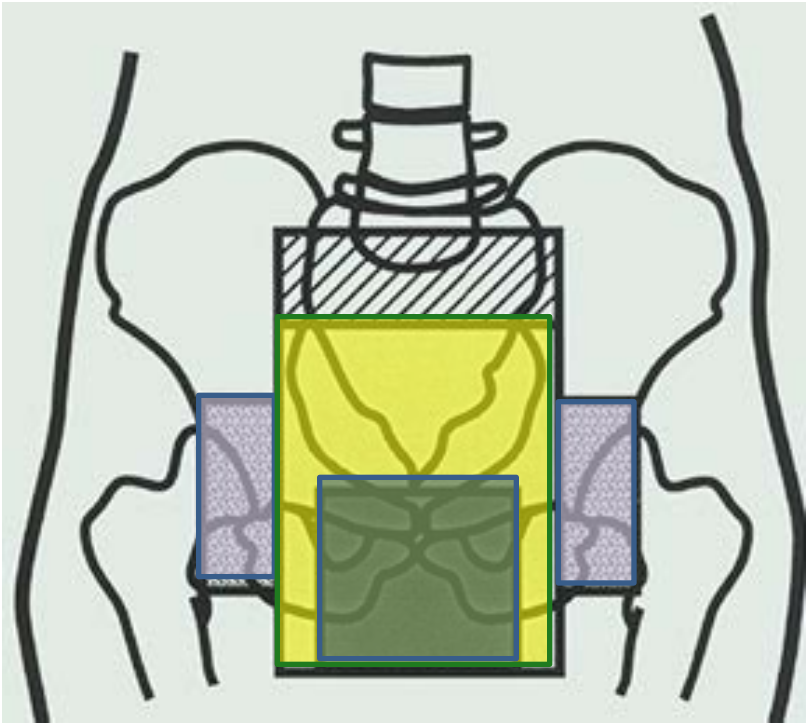

Site	Number of failures (%)
Anus/rectum	18 (75)
Presacral/iliac	5 (21)
Inguinal	1 (4)

P. Das et al, Int. J. Radiation Oncology Biol. Phys. 2007

Critical issues: inguinal nodes

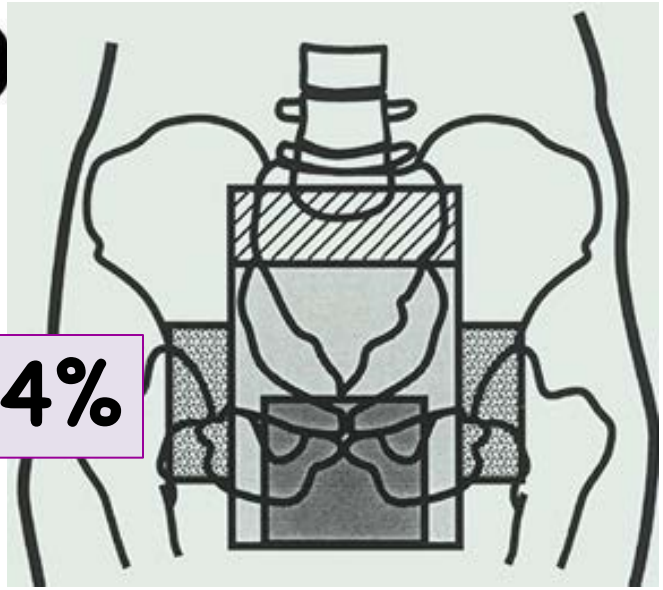

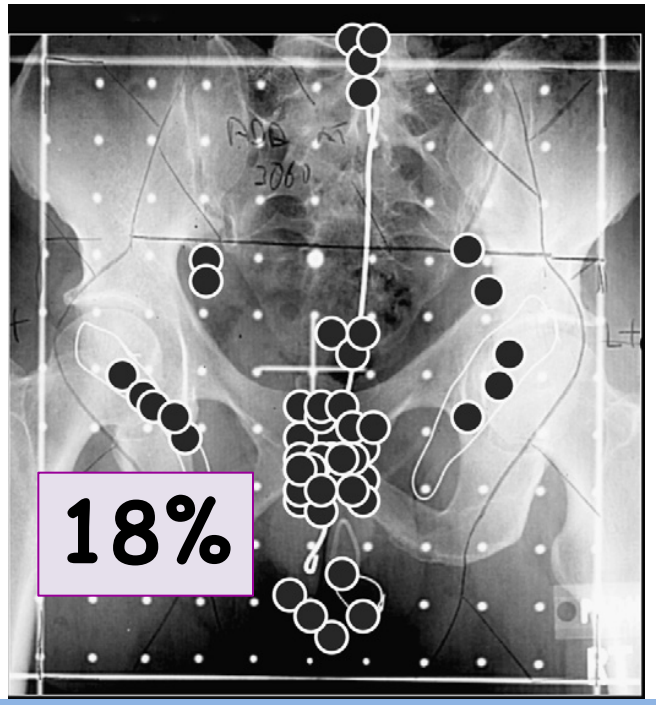

This difference may be related to the higher dose delivered to **involved inguinal nodes** in study of Das P. et al (**55 Gy**) vs the prescribed dose to the inguinal nodes in all inguinal failures in the study of Wright et al. was **45 Gy**.

J. L. Wright et al, Int. J. Radiation Oncology Biol. Phys. 2010

P. Das et al, Int. J. Radiation Oncology Biol. Phys. 2007

PROPHYLACTIC INGUINAL IRRADIATION

retrospective study of 208 SCCAC patients
2000-2004
PII dose = 45 -50 Gy

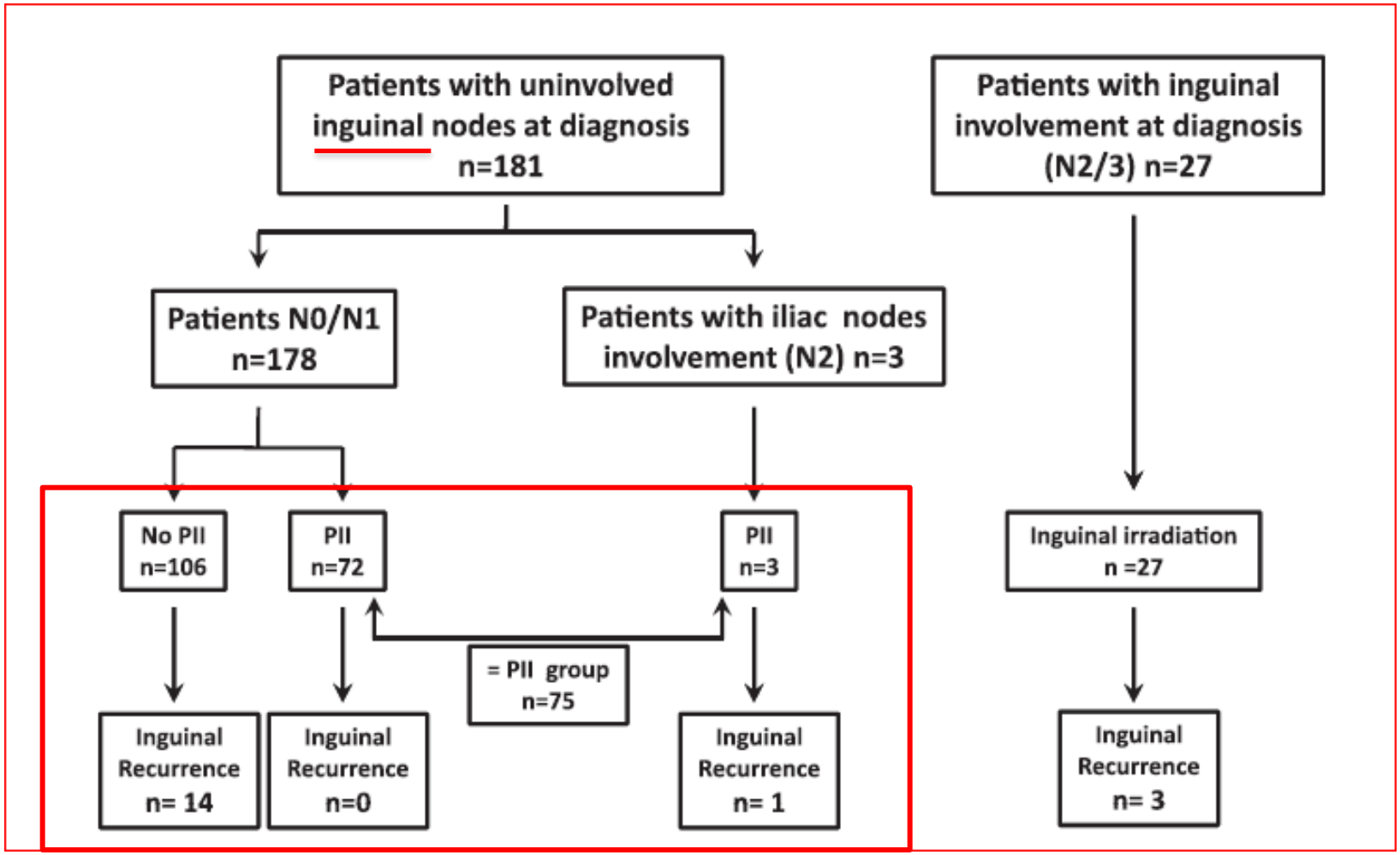

C. ORTHOLAN et al. Int. J. Radiation Oncology Biol. Phys., 2012

PROPHYLACTIC INGUINAL IRRADIATION

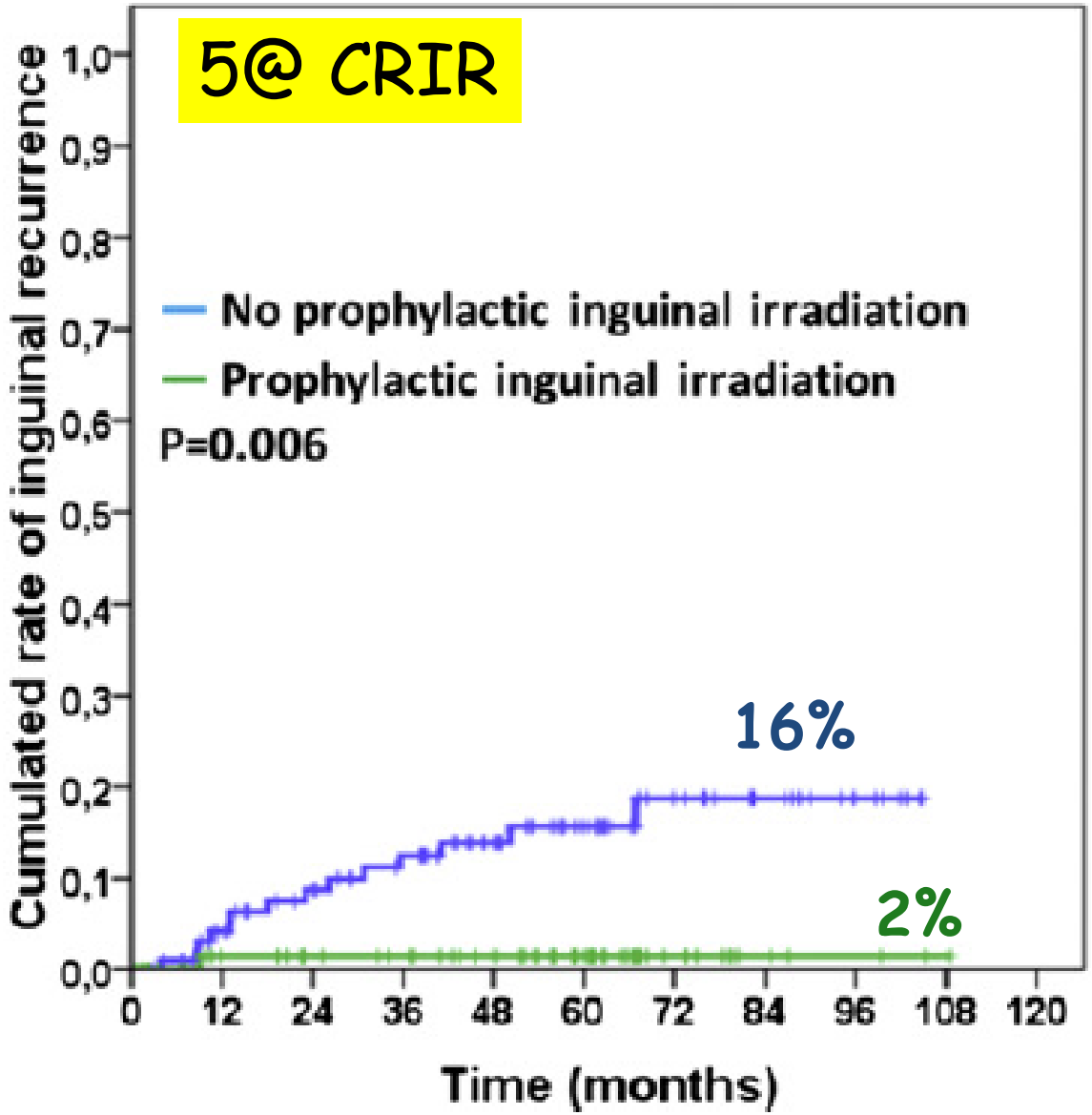

In the PII group 5-year CRIR was significantly lower (p= 0.006)

In the PII group, no Grade >2 toxicity of the lower extremity was observed

In the no PII group, the 5-year CRIR was 12% and 30% for T1-T2 and T3-T4 respectively (p = 0.02).

In the PII group, the 5-year CRIR was not different in T1-2 vs T3-4 (0% vs 3%)

PII didn't affect OS and DFS

C. ORTHOLAN et al. Int. J. Radiation Oncology Biol. Phys., 2012

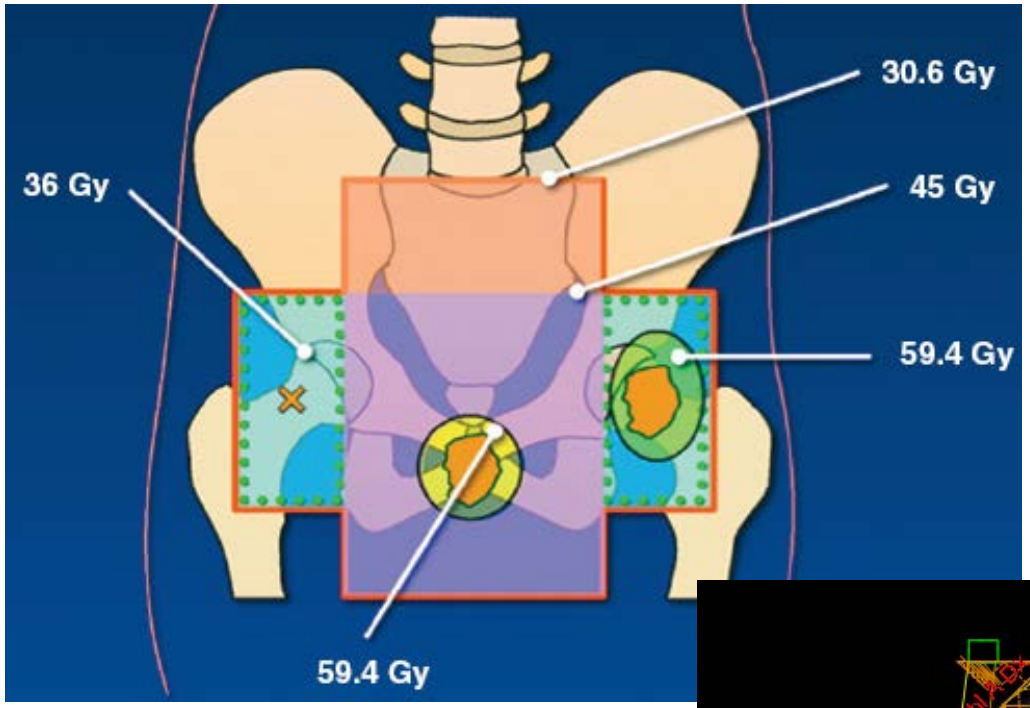

With the advent of CT-planning and conformal radiation techniques including **IMRT**, comes the **prerequisite** for **accurate and consistent contouring of target volumes.**

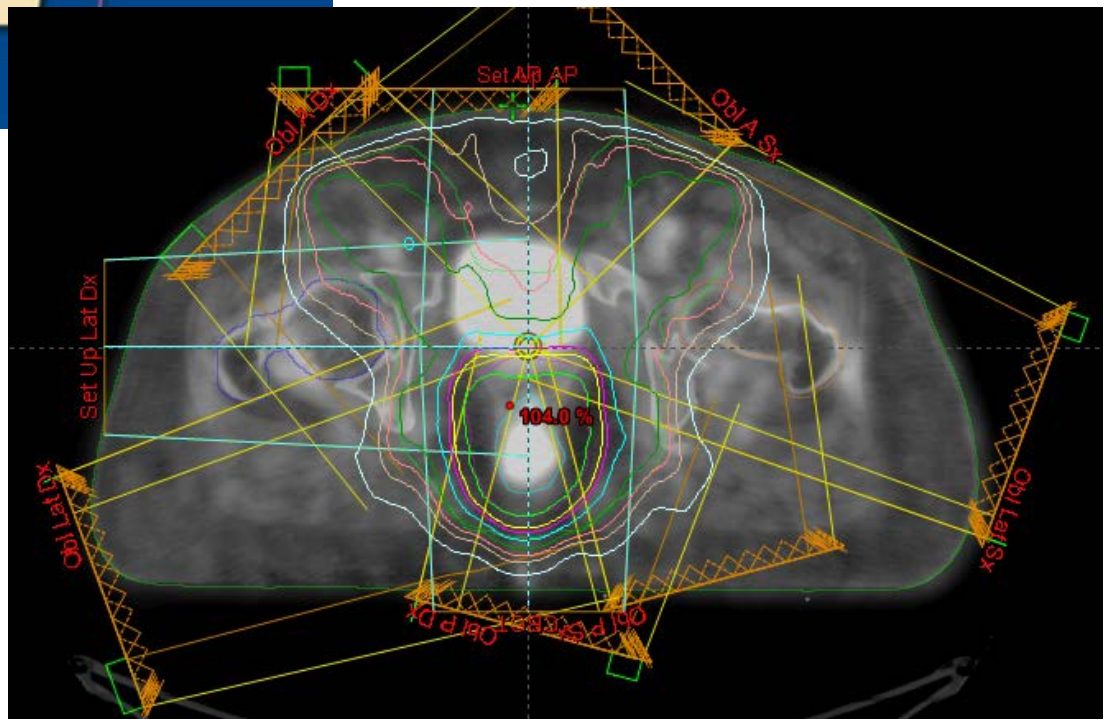

Clinical Investigation: Gastrointestinal Cancer

RTOG 0529: A Phase 2 Evaluation of Dose-Painted Intensity Modulated Radiation Therapy in Combination With 5-Fluorouracil and Mitomycin-C for the Reduction of Acute Morbidity in Carcinoma of the Anal Canal

Kachnic LA, Winter K, Myerson RJ, et al. Int J Radiat Oncol Biol Phys. 2013

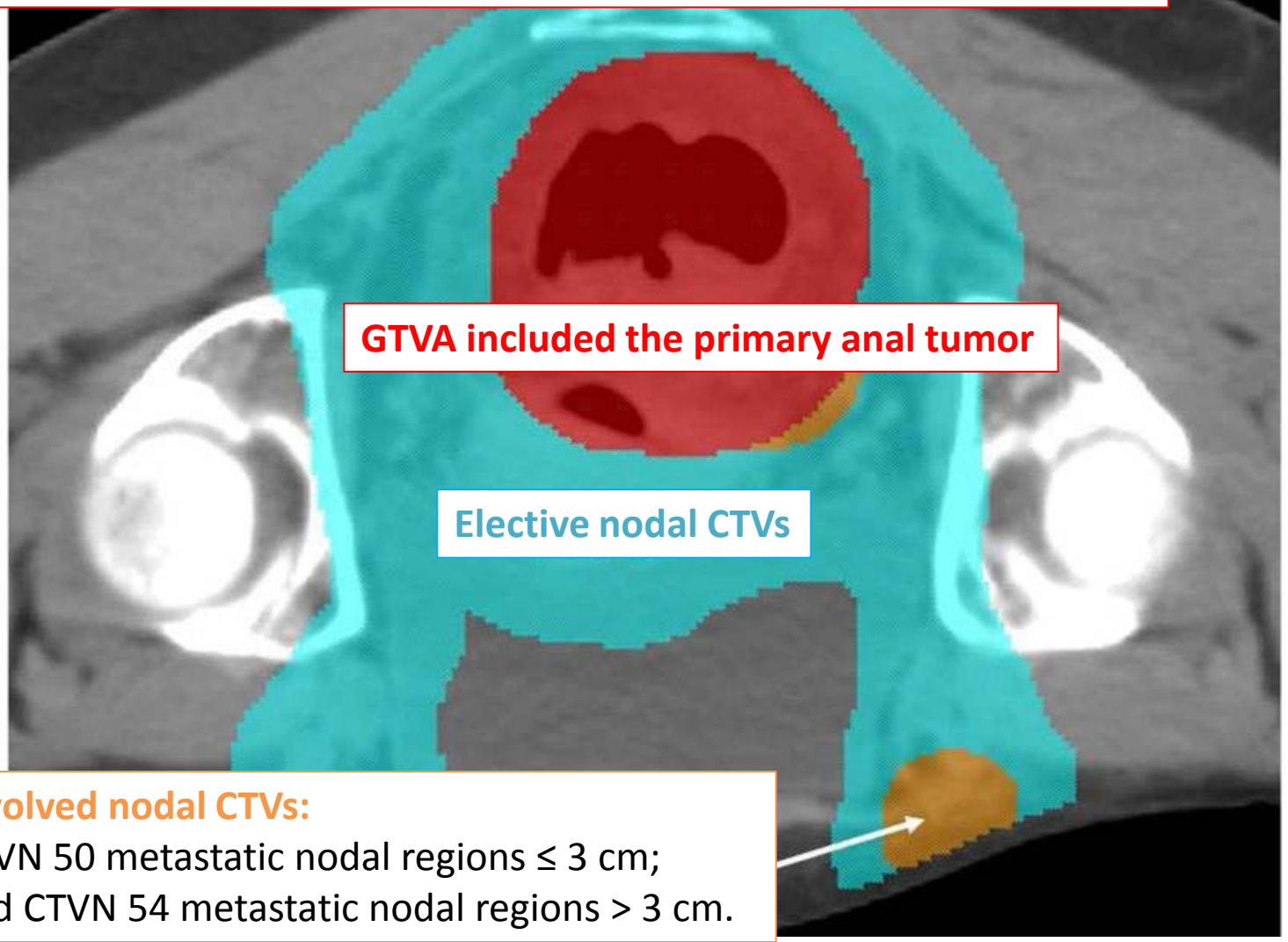

Involved nodal CTVs:

CTVN 50 metastatic nodal regions ≤ 3 cm;
and CTVN 54 metastatic nodal regions > 3 cm.

Clinical Investigation: Gastrointestinal Cancer

RTOG 0529: A Phase 2 Evaluation of Dose-Painted Intensity Modulated Radiation Therapy in Combination With 5-Fluorouracil and Mitomycin-C for the Reduction of Acute Morbidity in Carcinoma of the Anal Canal

Kachnic LA, Winter K, Myerson RJ, et al. Int J Radiat Oncol Biol Phys. 2013

Radiation Planning Quality Assurance

Of the 52 DP-
submission, 4
investigator c
of elective no
nodal groups
bowel 45%). E
normal tissue
dosing, and 39
coverage. On
dosing, and on
who did not at
reproducible i

n initial
assed. Incorrect
), miscontouring
33%, iliac
el 60%, large
ption and
ent for tumor
femoral head
cerning target
nvestigators
s considered

Incorrect contouring (81%)

GTV: 21%

CTV elective N:

Mesorectum	55%
Presacrum	43%
Inguinal fossa	33%
Iliac nodes	31%

CLINICAL INVESTIGATION Rectum

ELECTIVE CLINICAL TARGET VOLUMES FOR CONFORMAL THERAPY IN ANORECTAL CANCER: A RADIATION THERAPY ONCOLOGY GROUP CONSENSUS PANEL CONTOURING ATLAS

Elective nodal CTVs

CTVA: internal iliac, pre-sacral, peri-rectal.
CTVB: external iliac nodal region
CTVC: inguinal nodal region

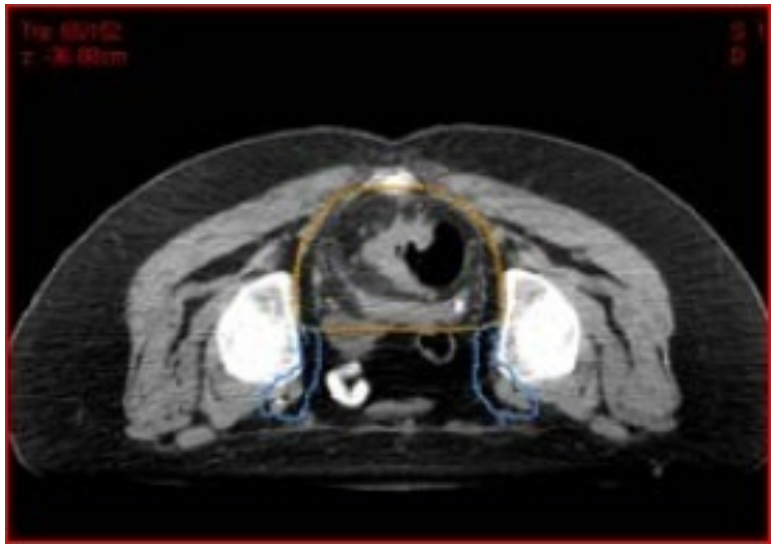

LIMITATIONS:
•no clear definition of the different anatomical boundaries

Myerson RJ, Garofalo MC, El Naqa I, et al. Int J Radiat Oncol Biol Phys. 2009

CLINICAL INVESTIGATION Rectum

ELECTIVE CLINICAL TARGET VOLUMES FOR CONFORMAL THERAPY IN ANORECTAL CANCER: A RADIATION THERAPY ONCOLOGY GROUP CONSENSUS PANEL CONTOURING ATLAS

CTVA: internal iliac, pre-sacral, peri-rectal

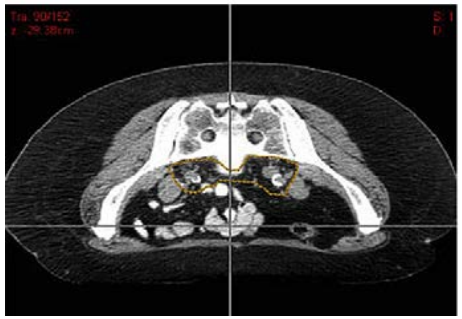

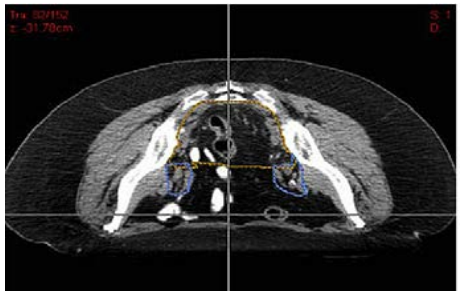

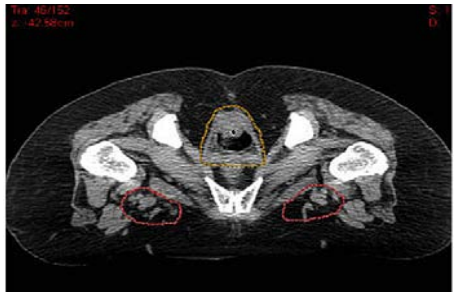

Cranial:

- Bifurcation of the common iliac vessels into external/internal iliacs (bony landmark: sacral promontory)
- Recto-sigmoid junction

Anterior:

- 1 cm anterior to the sacrum
- Perirectal fascia
- 1 cm into the bladder
- Pelvic organs

sup

inf

Lateral and posterior:

- Pelvic side-wall muscles or bones

Caudal:

Anal canal + 2 cm around, the anal verge
Anal skin involved + 2 cm beyond

Myerson RJ, Garofalo MC, El Naqa I, et al. Int J Radiat Oncol Biol Phys. 2009

CLINICAL INVESTIGATION Rectum

ELECTIVE CLINICAL TARGET VOLUMES FOR CONFORMAL THERAPY IN ANORECTAL CANCER: A RADIATION THERAPY ONCOLOGY GROUP CONSENSUS PANEL CONTOURING ATLAS

CTVB: external iliac nodal region

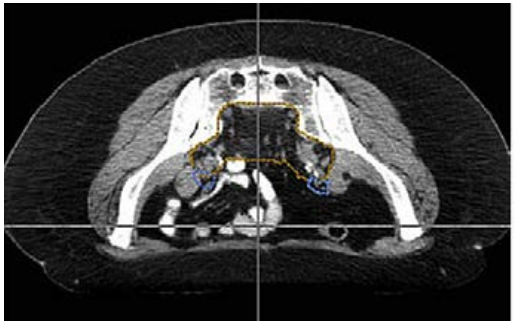

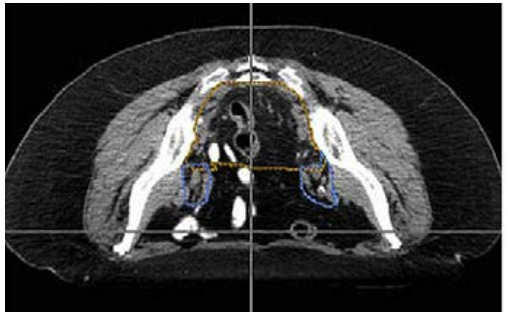

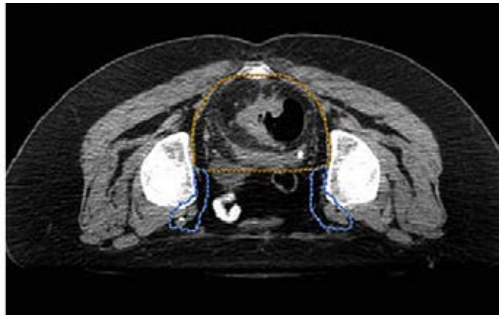

Cranial:

- Bifurcation of the common iliac vessels into external/internal

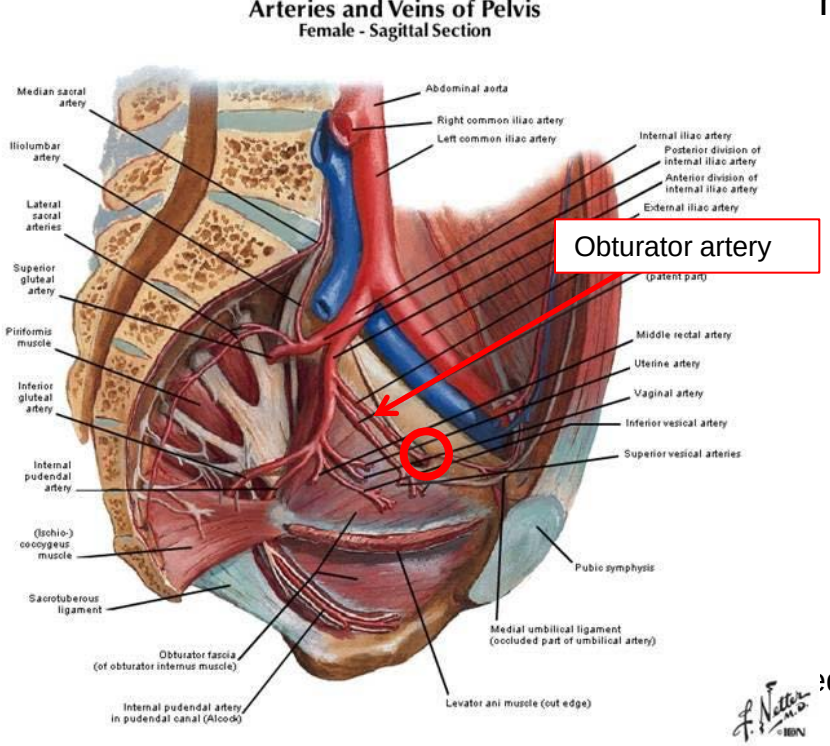

edge of

Myerson RJ, Garofalo MC, El Naqa I, et al. Int J Radiat Oncol Biol Phys. 2009

CLINICAL INVESTIGATION Rectum

ELECTIVE CLINICAL TARGET VOLUMES FOR CONFORMAL THERAPY IN ANORECTAL CANCER: A RADIATION THERAPY ONCOLOGY GROUP CONSENSUS PANEL CONTOURING ATLAS

CTVC: inguinal nodal region

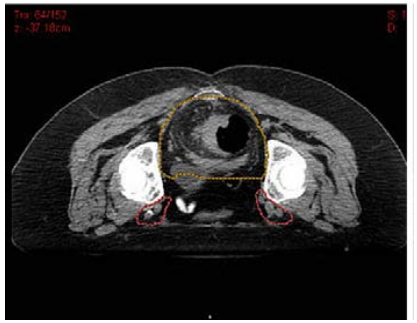

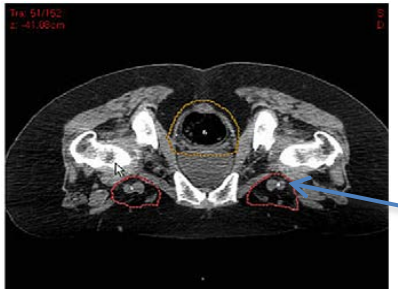

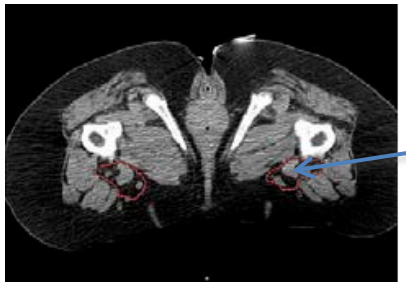

Cranial:

caudad edge of internal obturator vessels (bony landmark: upper edge of the superior rami pubic)

Caudal:

2 cm below the saphenous-femural junction

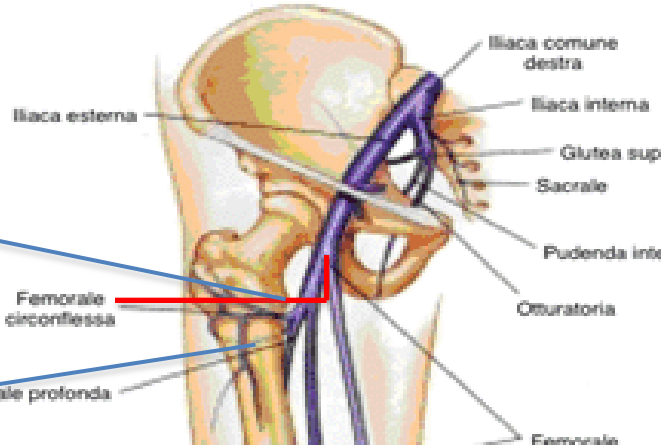

Myerson RJ, Garofalo MC, El Naqa I, et al. Int J Radiat Oncol Biol Phys. 2009

Clinical Investigation: Gastrointestinal Cancer

Australasian Gastrointestinal Trials Group (AGITG) Contouring Atlas and Planning Guidelines for Intensity-Modulated Radiotherapy in Anal Cancer

M. Ng, et al. (AGITG) Int J Radiation Oncol Biol Phys, 2012

ELECTIVE NODAL VOLUMES

mesorectum

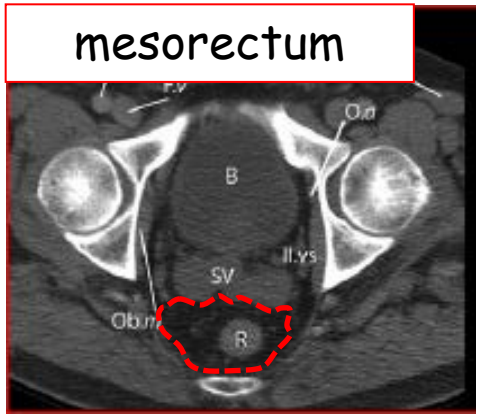

presacral space

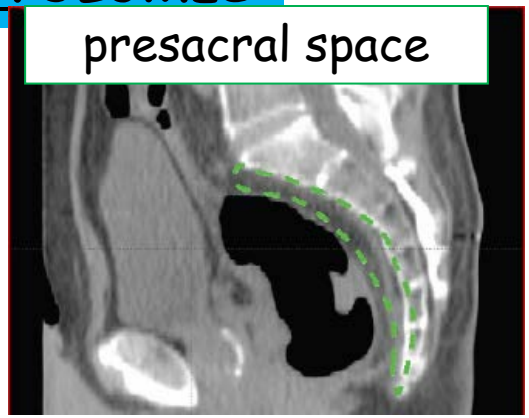

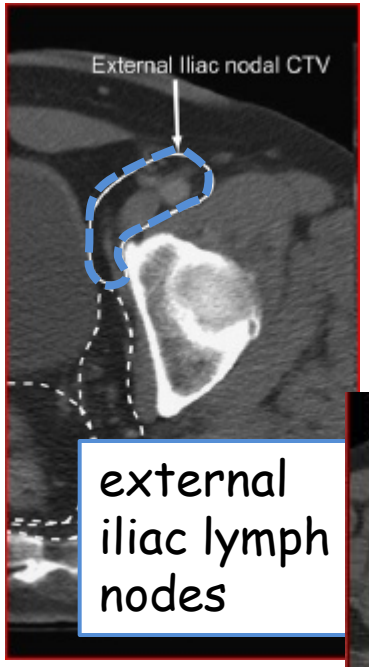

external iliac lymph nodes

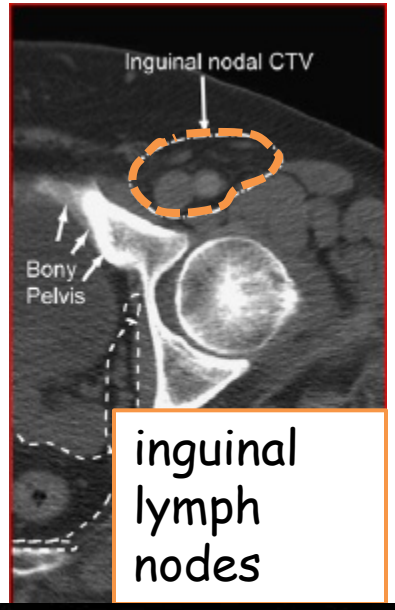

inguinal lymph nodes

ischiorectal fossa

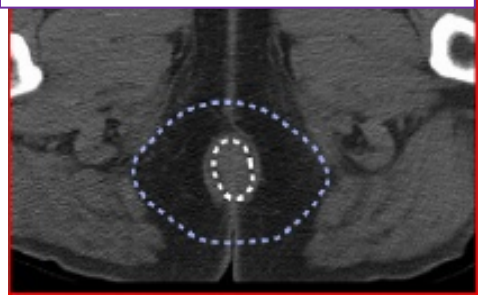

internal iliac lymph nodes

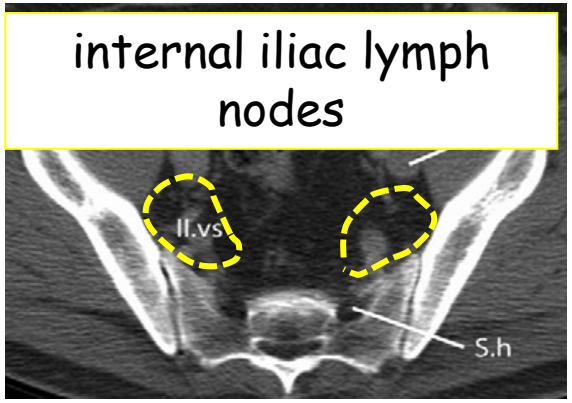

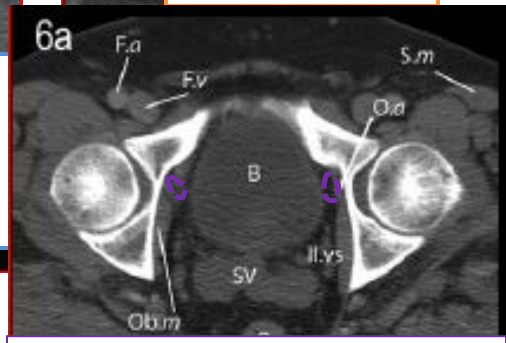

obturator lymph nodes

CTV borders for individual nodal groups

MESORECTUM

Cranial =the recto-sigmoid junction

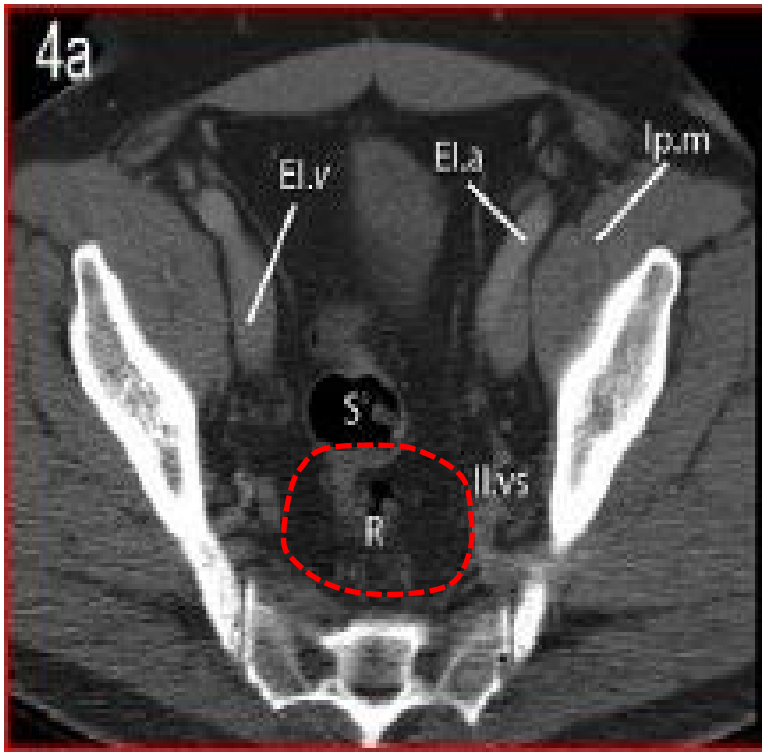

Cranial = superior rectal artery bending anteriorly

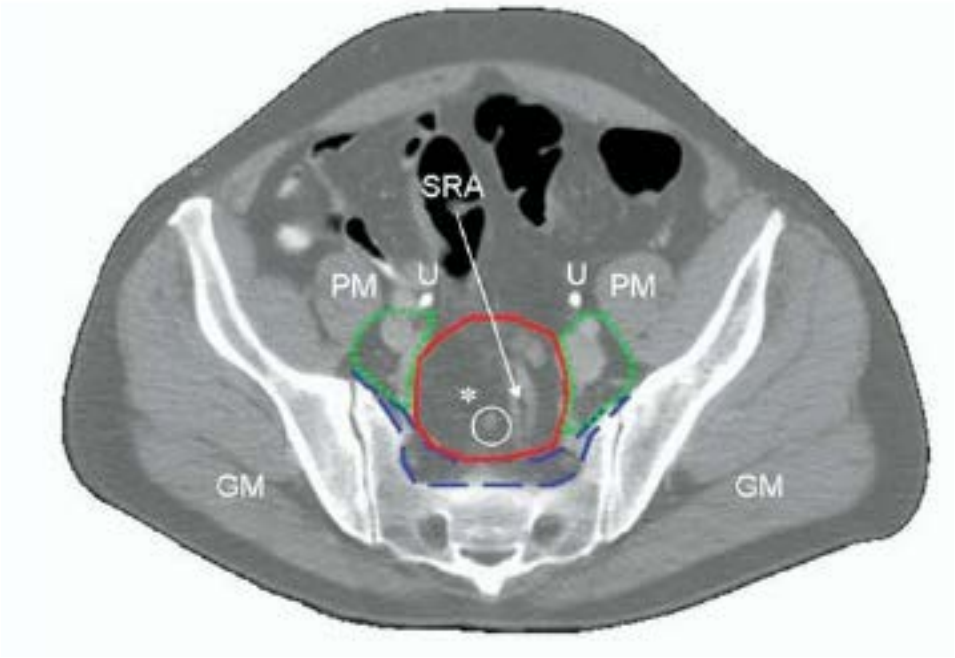

M. Ng, et al. (AGITG) Int J Radiation Oncol Biol Phys, 2012

S. Roels Int. J. Radiation Oncology Biol. Phys., 2006

MESORECTUM

Caudal =the ano-rectal junction

levator ani muscles

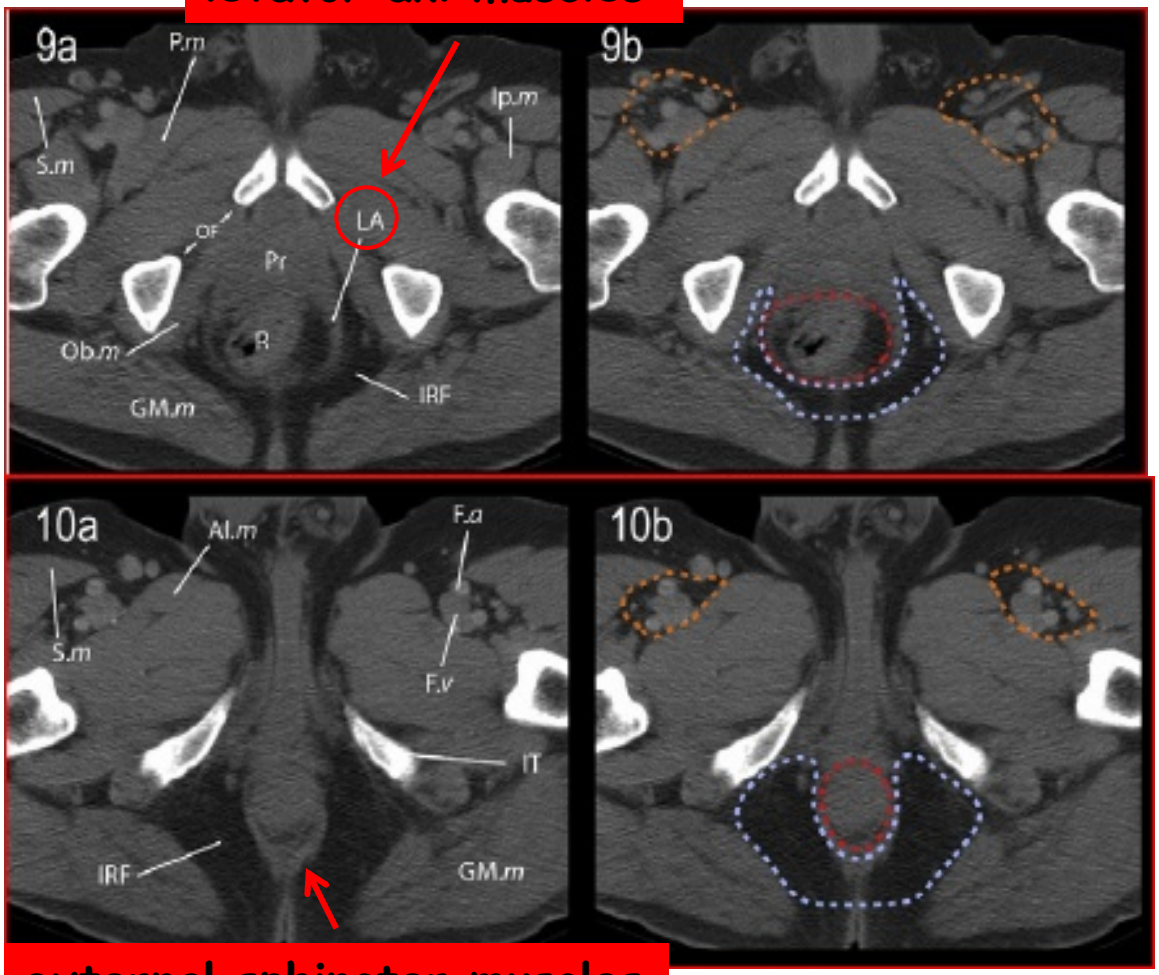

external sphincter muscles

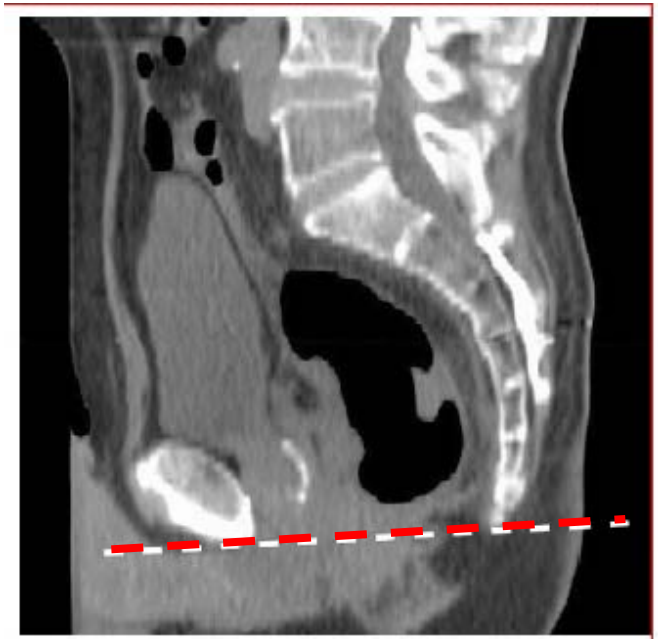

M. Ng, et al. (AGITG) Int J Radiation Oncol Biol Phys, 2012

MESORECTUM

Lateral, in the upper pelvis = internal iliac lymph node group

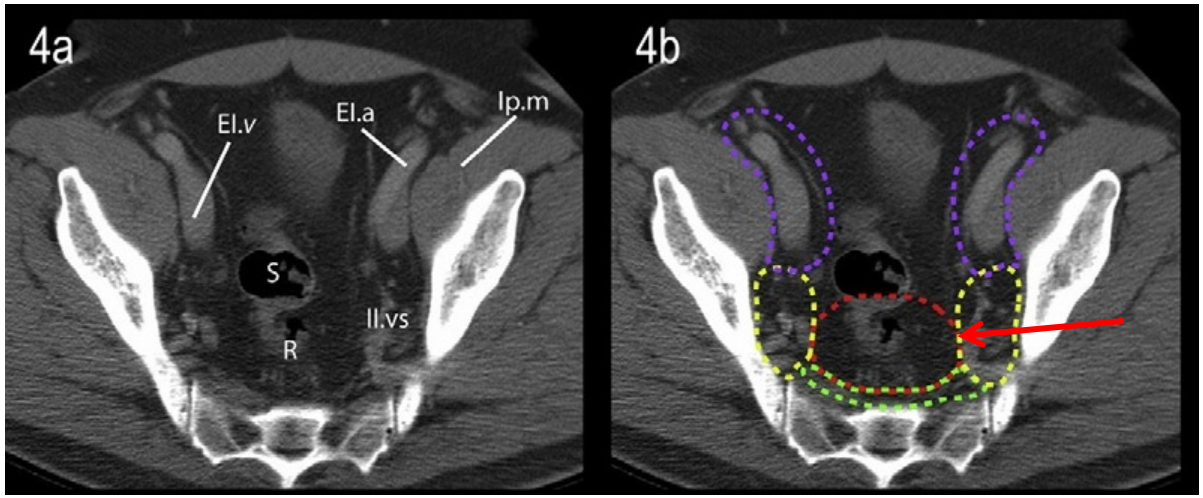

Lateral, in the lower pelvis = the border is the medial edge of the levator ani.

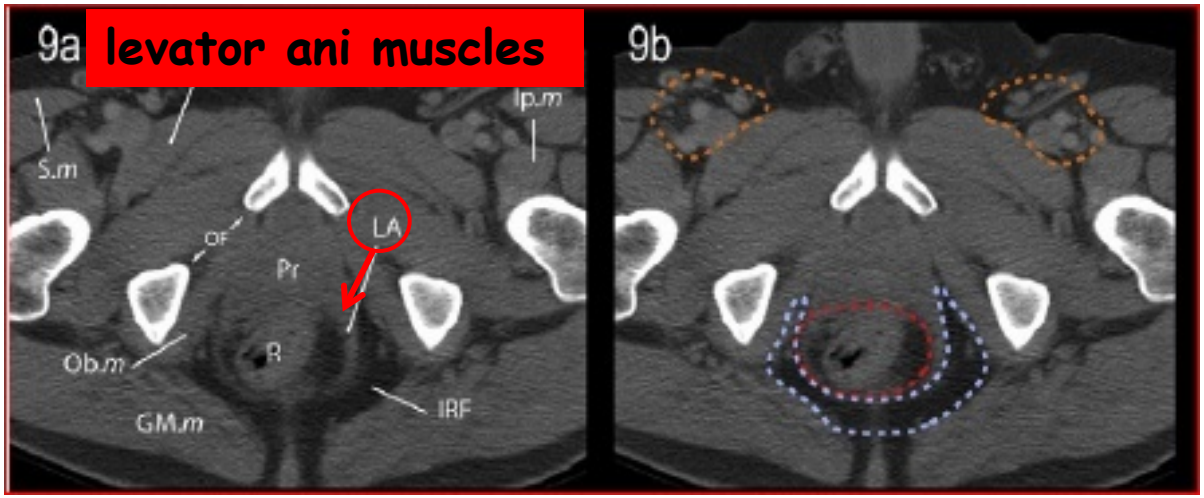

M. Ng, et al. (AGITG) Int J Radiation Oncol Biol Phys, 2012

MESORECTUM

Anterior =For males, the penile bulb and prostate in the lower pelvis, and by the posterior edge of the seminal vesicles (SV) and bladder in the mid pelvis. In females, the boundary is formed by the bladder, vagina, cervix, and uterus.

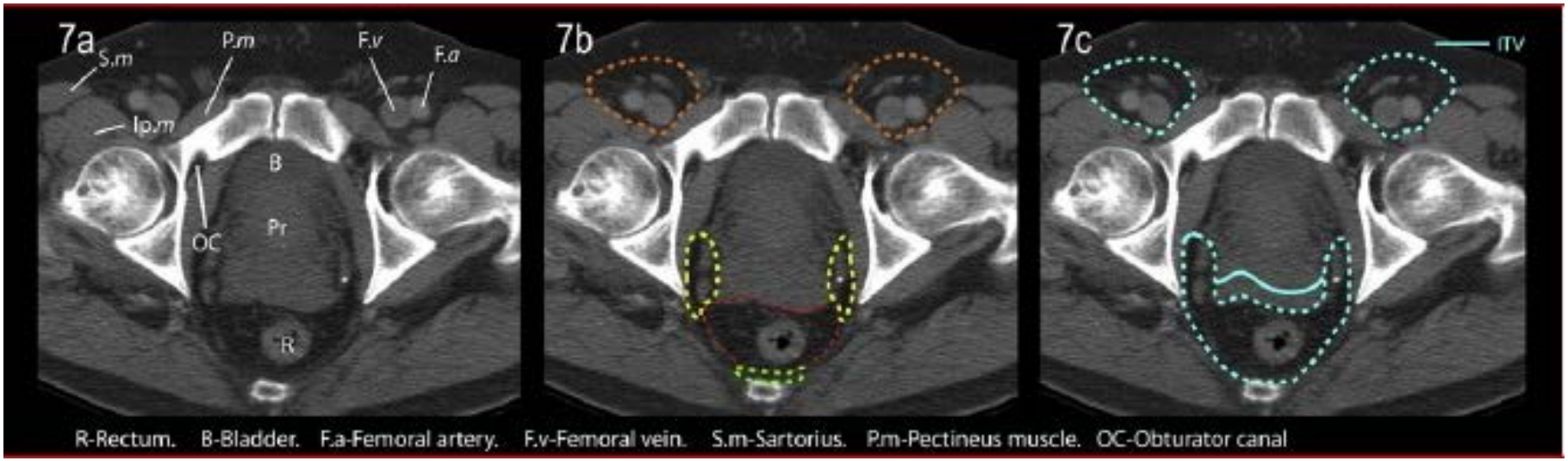

Posterior =The presacral space

M. Ng, et al. (AGITG) Int J Radiation Oncol Biol Phys, 2012

PRESACRAL SPACE

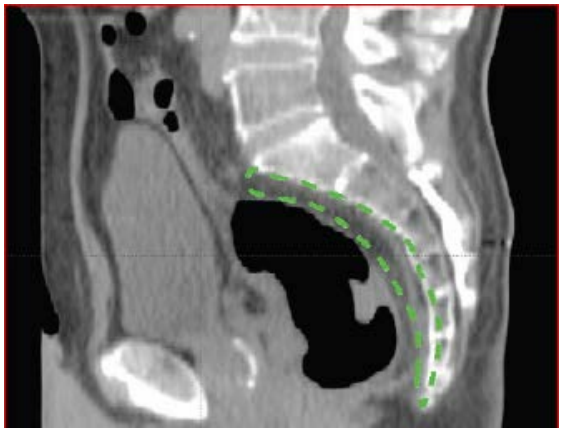

Cranial: The sacral promontory.

Caudal: The inferior edge of the coccyx

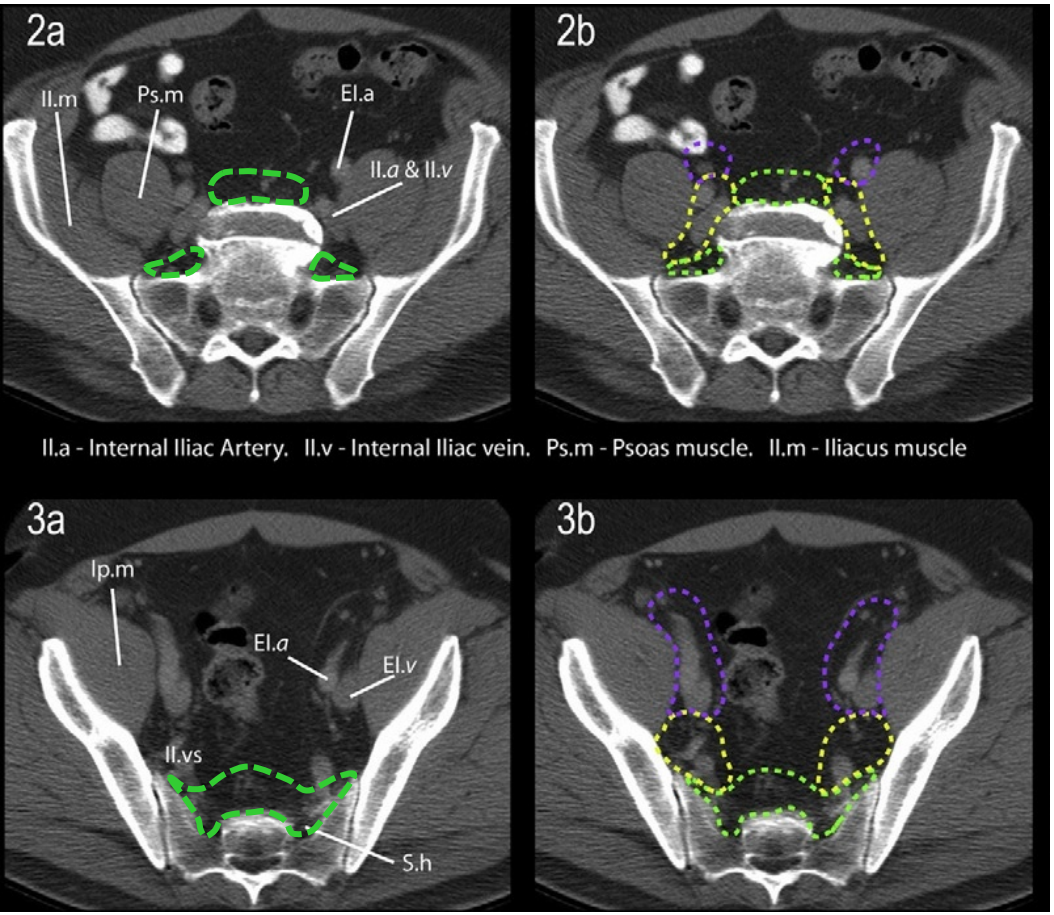

Lateral: The sacro-iliac joints.

Anterior: 10 mm anterior to the anterior sacral border.

Posterior: The anterior border of the sacral bone.

Taylor A et al. Clin Oncol (R Coll Radiol). 2007

M. Ng, et al. (AGITG) Int J Radiation Oncol Biol Phys, 2012

ISCHIORECTAL FOSSA

Cranial = levator ani, gluteus maximus, and obturator internus

Anterior = at the level where the obturator internus muscle, levator ani, and anal sphincter muscles fuse.
Inferiorly, at least 10- to 20-mm anterior to the sphincter muscles.

Posterior = a transverse plane joining the anterior edge of the medial walls of the gluteus maximus muscle.

Lateral =ischial tuberosity, obturator internus, and gluteus maximus muscles

Caudal =at the level of the anal verge

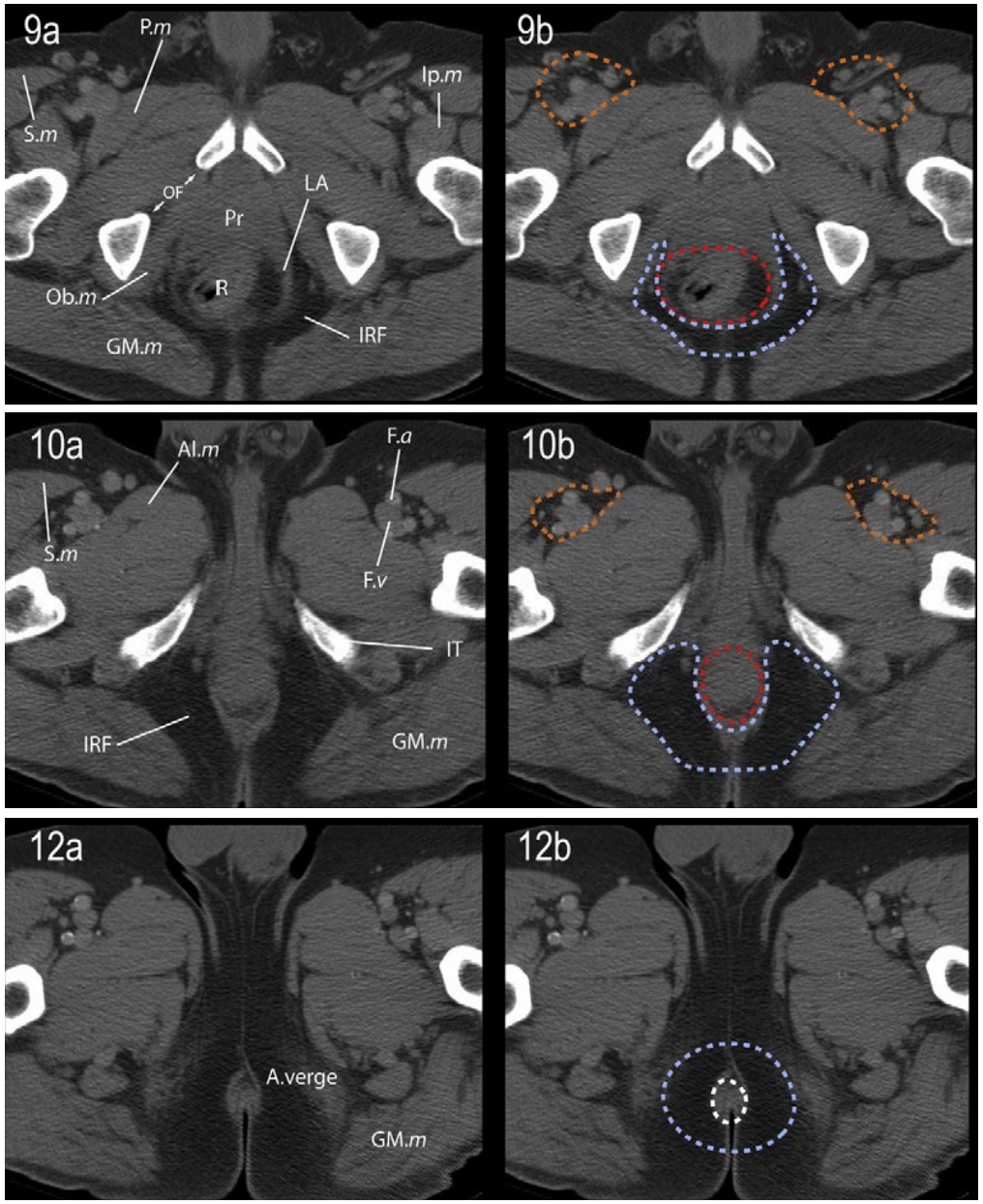

M. Ng, et al. (AGITG) Int J Radiation Oncol Biol Phys, 2012

Original Article

An Atlas of the Pelvic Lymph Node Regions to Aid Radiotherapy Target Volume Definition

A. Taylor*, A. G. Rockall†, M. E. B. Powell*

*Department of Radiotherapy, St Bartholomew's Hospital, London, UK; †Department of Radiology, St Bartholomew's Hospital, London, UK

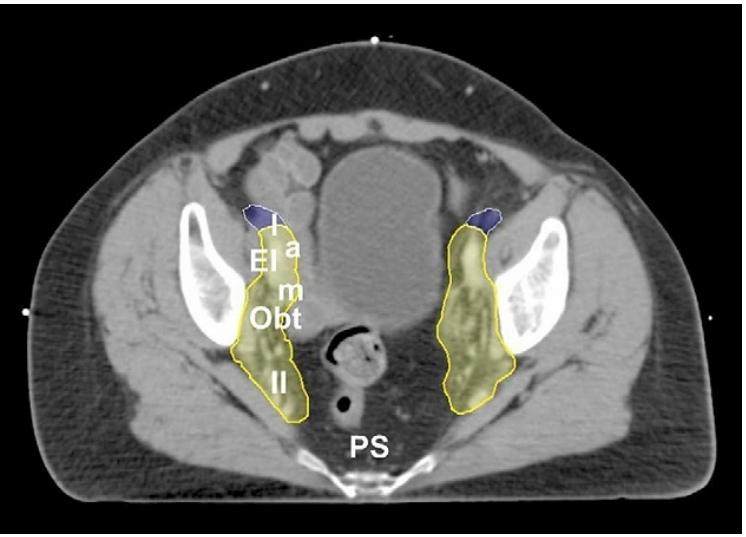

Table 1 — Summary of the guidelines for delineating nodal regions

Lymph node group	Recommended margins*
Common iliac	7 mm margin around vessels. Extend posterior and lateral borders to psoas and vertebral body
External iliac	7 mm margin around vessels. Extend anterior border by a further 10 mm anterolaterally along the iliopsoas muscle to include the lateral external iliac nodes
Internal iliac	7 mm margin around vessels. Extend lateral borders to pelvic side wall
Obturator	Join external and internal iliac regions with a 17 mm wide strip along the pelvic side wall
Pre-sacral	Subaortic: 10 mm strip over anterior sacrum Mesorectal: cover entire mesorectal space

*Also include any visible nodes.

Taylor A et al. Clin Oncol (R Coll Radiol). 2007

INTERNAL ILIAC LYMPH NODES

Cranial = Bifurcation of the common iliac artery into the external and internal iliac arteries (usually corresponds to the L5-S1 interspace level).

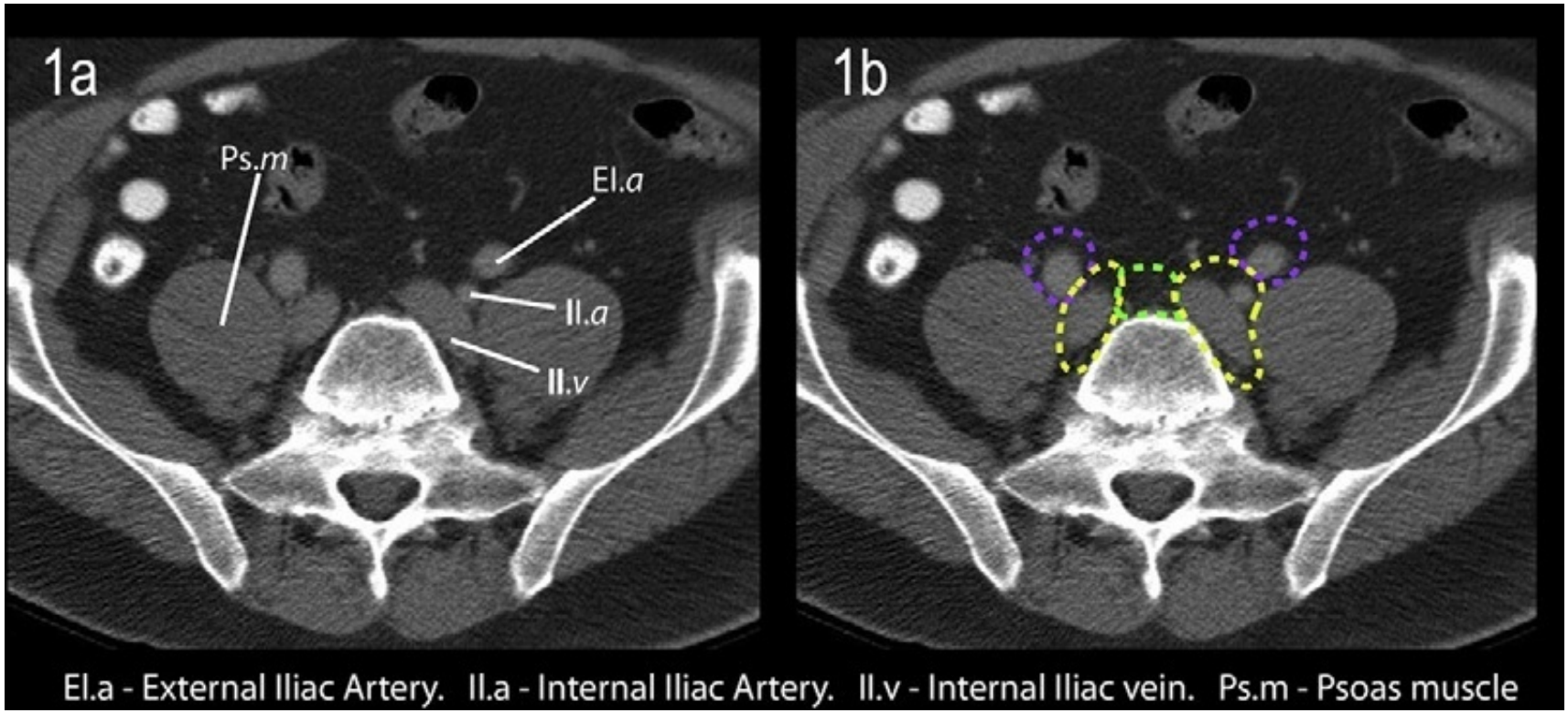

M. Ng, et al. (AGITG) Int J Radiation Oncol Biol Phys, 2012

INTERNAL ILIAC LYMPH NODES

Caudal = where the fibers of the levator ani insert into the obturator fascia and obturator internus muscle, at the level of the obturator canal, or at the level where there is no space between the obturator internus muscle and the midline organs (bladder, SV)

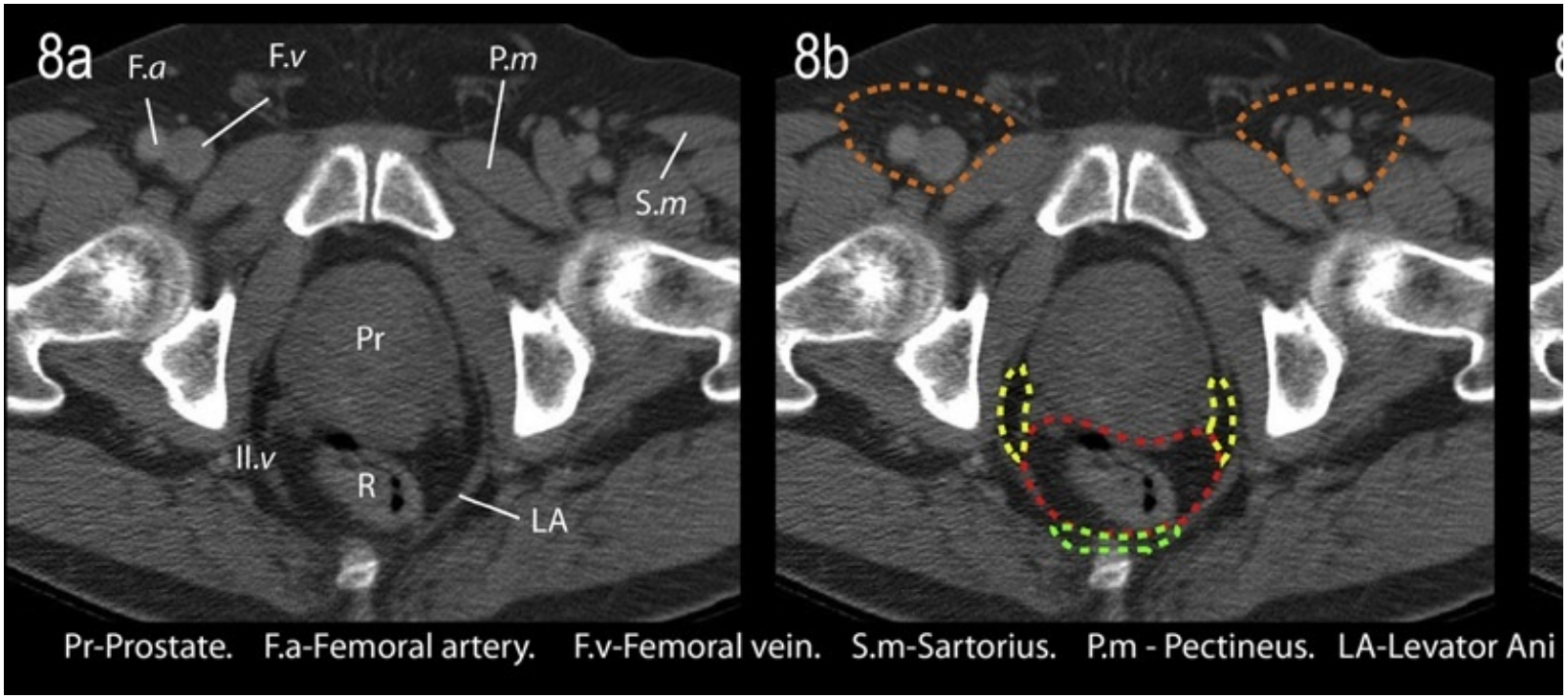

M. Ng, et al. (AGITG) Int J Radiation Oncol Biol Phys, 2012

INTERNAL ILIAC LYMPH NODES

Lateral in the lower pelvis = The medial edge of the obturator internus muscle (or bone where the obturator internus is not present)

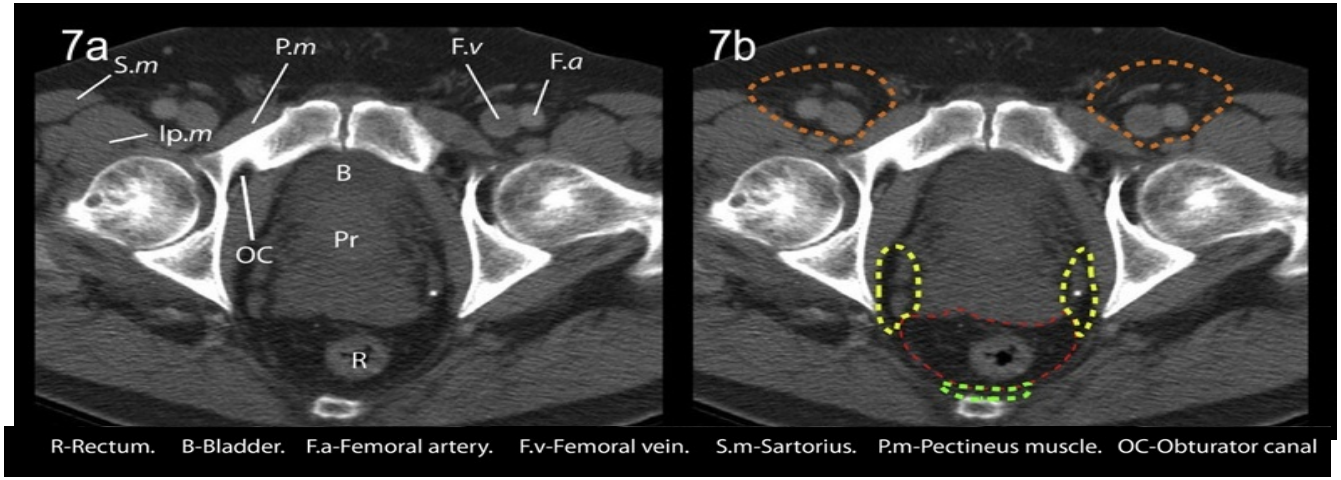

Lateral in the upper pelvis = the iliopsoas muscle in.

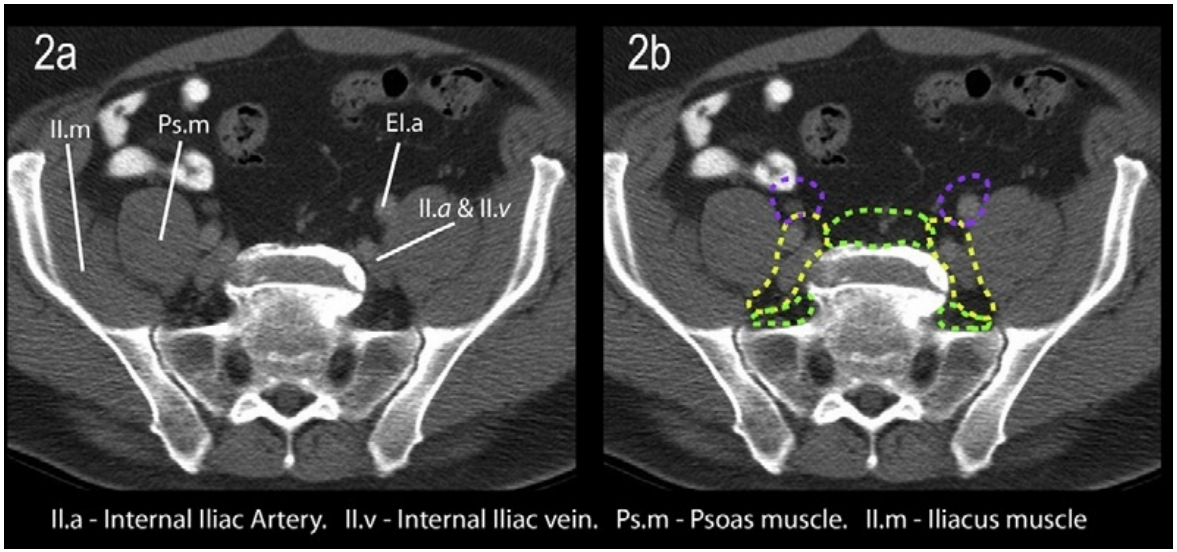

M. Ng, et al. (AGITG) Int J Radiation Oncol Biol Phys, 2012

INTERNAL ILIAC LYMPH NODES

Medial in the lower pelvis = the mesorectum and the presacral space.

Medial in the upper pelvis = the internal iliac vessels + 7 mm medial margin

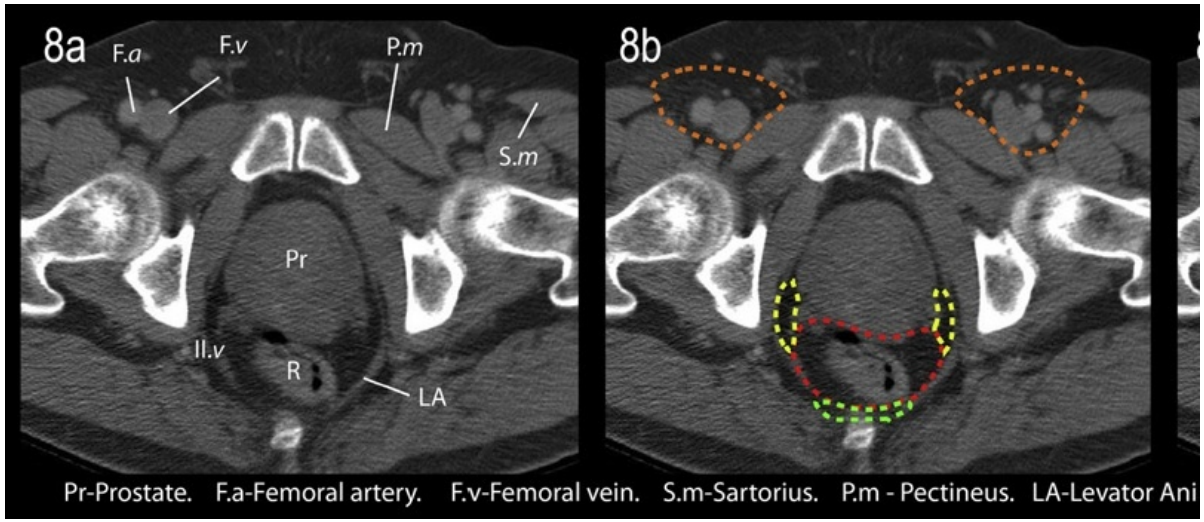

Anterior in the lower pelvis = the obturator internus muscle or bone.
Anterior in the upper pelvis = the internal iliac vessels + 7 mm medial margin

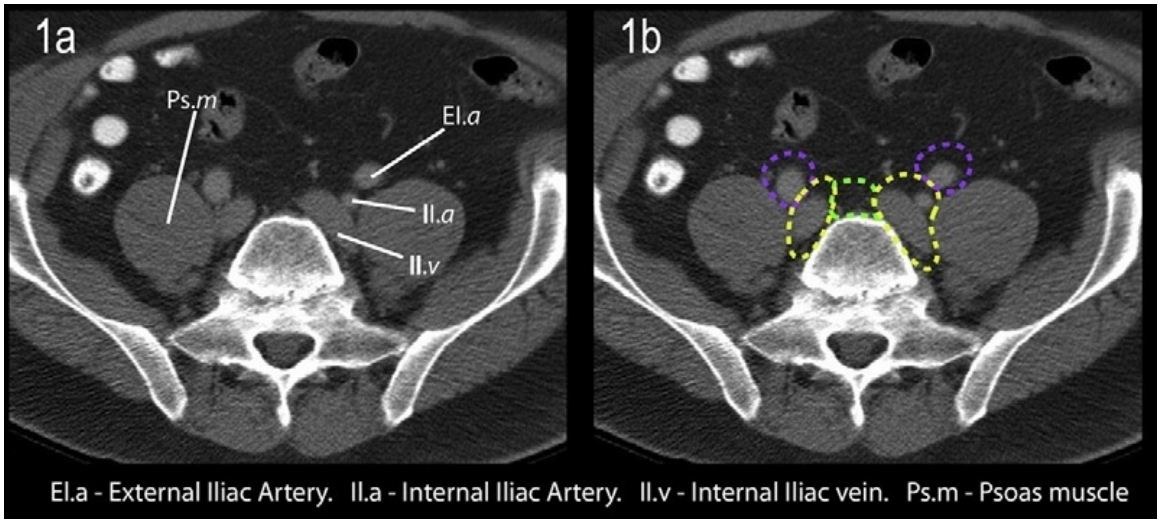

Taylor A et al. Clin Oncol (R Coll Radiol). 2007
M. Ng, et al. (AGITG) Int J Radiation Oncol Biol Phys, 2012

OBTURATOR LYMPH NODES

Along the obturator artery, a branch of the internal iliac artery that usually starts at the level of the acetabulum, and exits via the obturator canal.

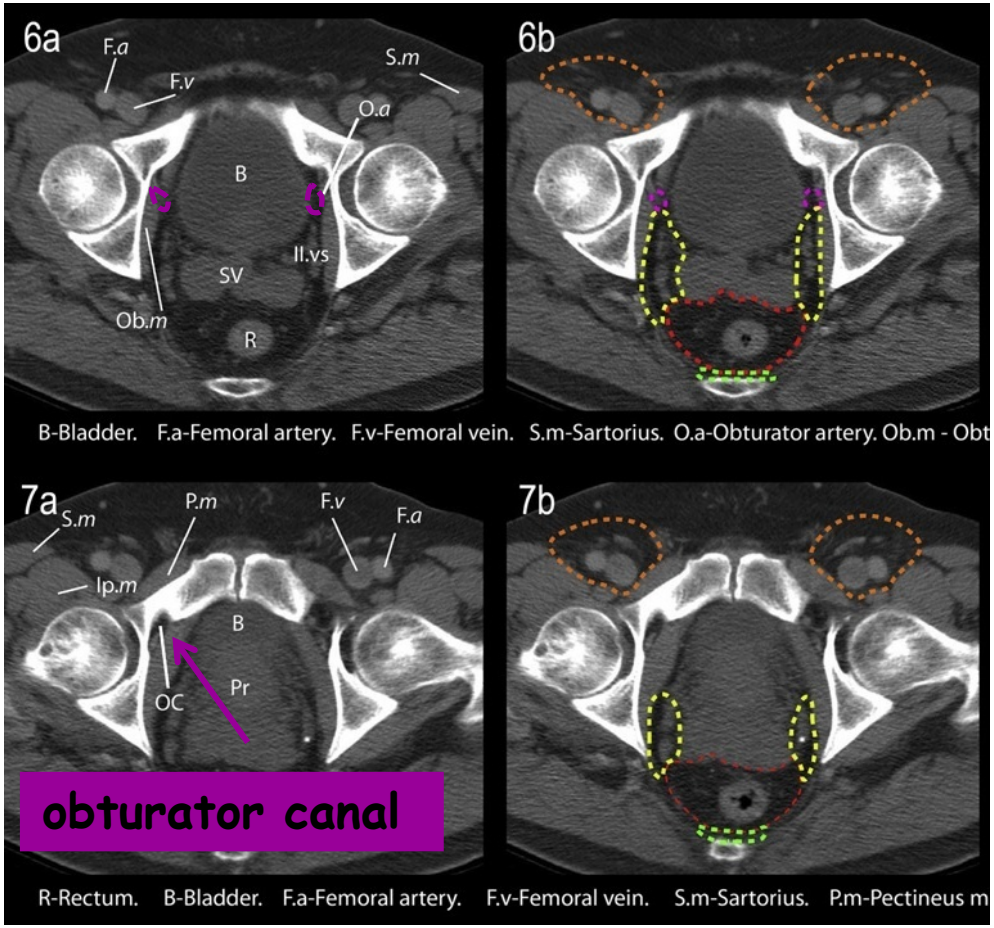

Cranial = 3 to 5 mm cranial to the obturator canal where the obturator artery is sometimes visible.

Caudal =The obturator canal,where the obturator artery has exited the pelvis.

Anterior = The anterior extent of the obturator internus muscle.

Posterior = The internal iliac lymph node grou

Lateral = The obturator internus muscle.

Medial = The bladder.

M. Ng, et al. (AGITG) Int J Radiation Oncol Biol Phys, 2012

EXTERNAL ILIAC LYMPH NODES

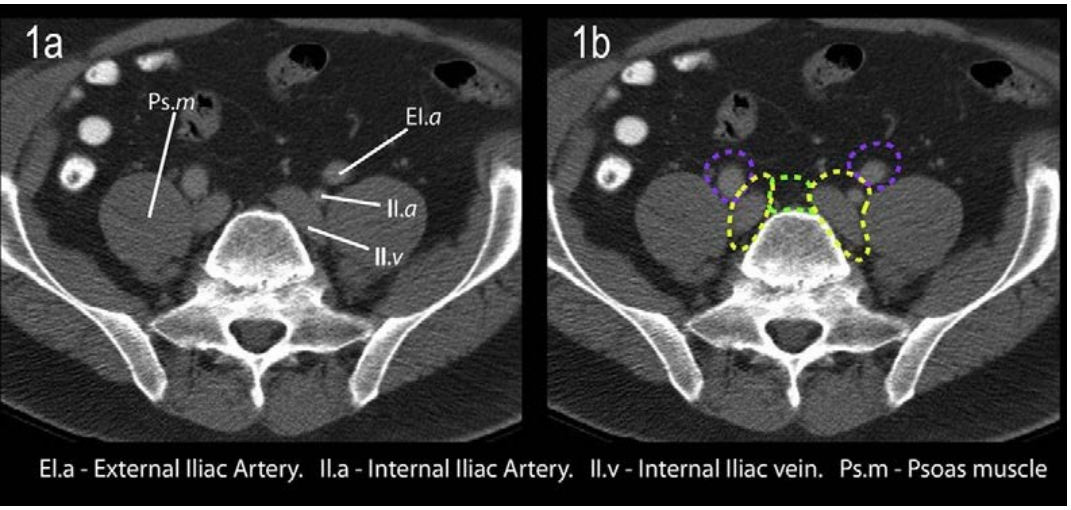

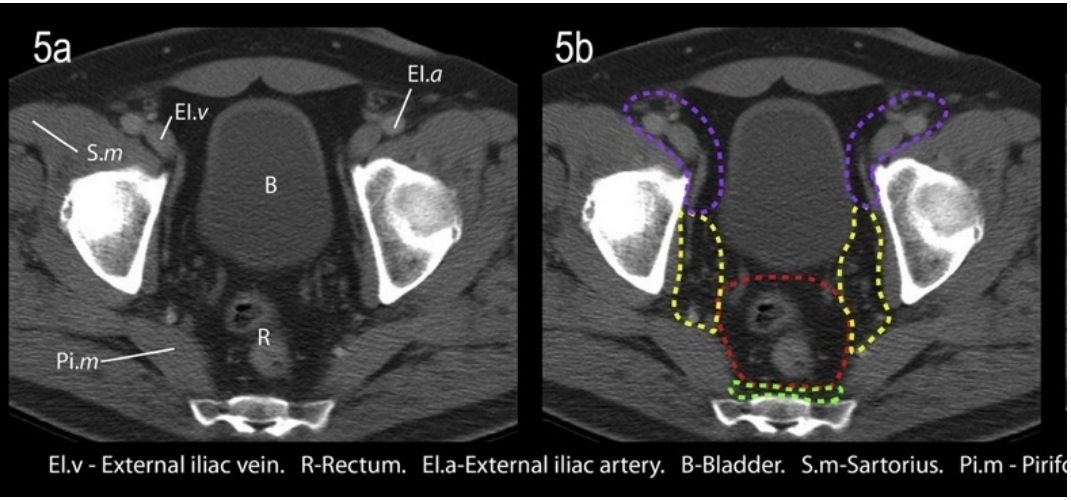

Cranial = Bifurcation of the common iliac artery into the external and internal iliac arteries.

Lateral =The iliopsoas muscle

Medially = the bladder or a 7-mm margin around the vessels

Anterior = A 7-mm margin anterior to the external iliac vessels

Posterior = The internal iliac lymph node group

Caudal =The level where the external iliac vessels are still located within the bony pelvis before continuing as the femoral. This transition usually occurs between the acetabulum's roof and the superior pubic rami

Taylor A et al. Clin Oncol (R Coll Radiol). 2007
M. Ng, et al. (AGITG) Int J Radiation Oncol Biol Phys, 2012

INGUINAL LYMPH NODES

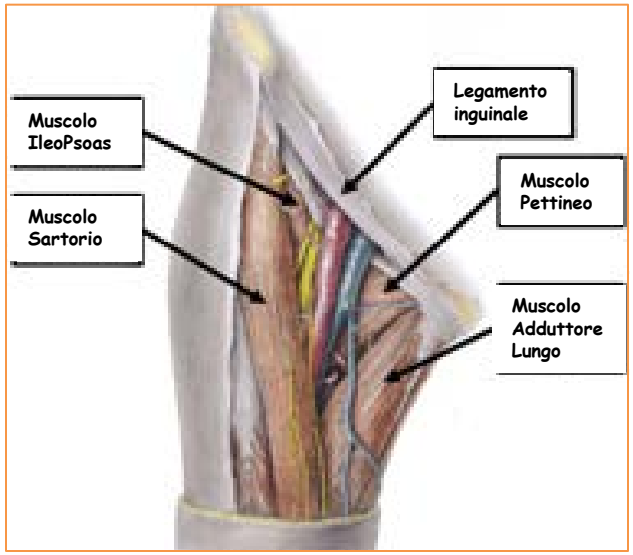

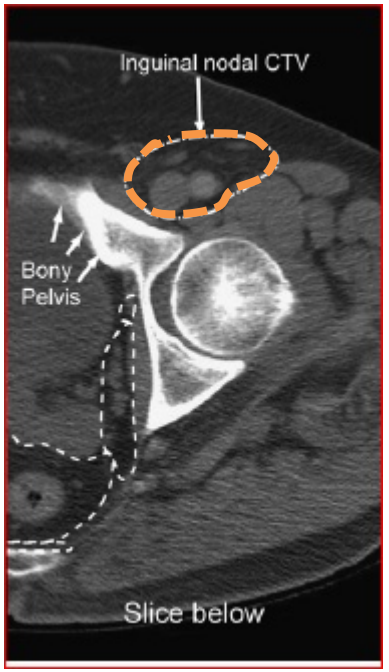

Caudal = lower edge of the ischial tuberosities

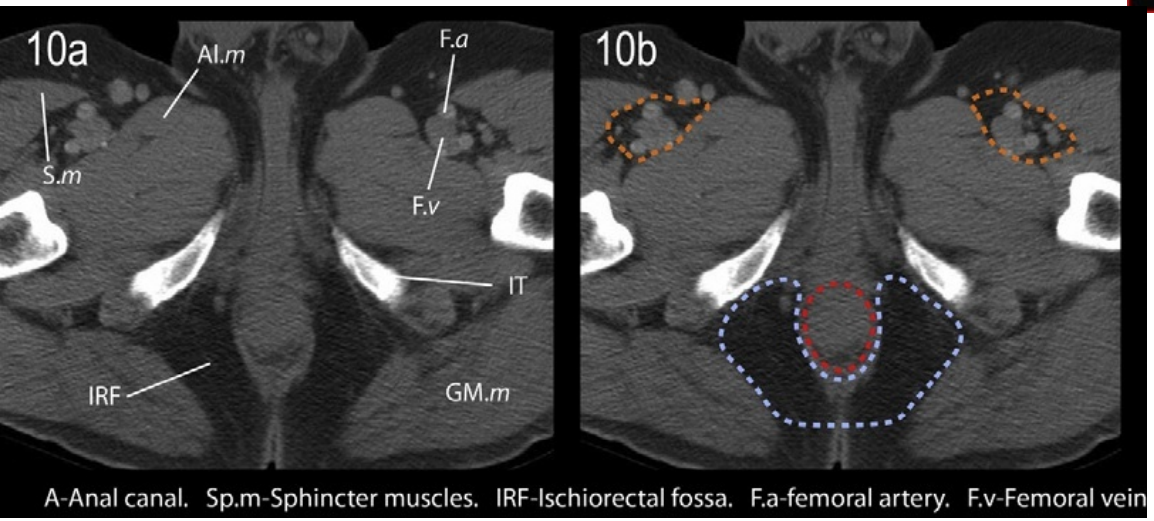

Cranial =The level where the external iliac artery leaves the bony pelvis to become the femoral artery.

Taylor A et al. Clin Oncol (R Coll Radiol). 2007
M. Ng, et al. (AGITG) Int J Radiation Oncol Biol Phys, 2012

INGUINAL LYMPH NODES

Posterior =The bed of the femoral triangle is formed by the iliopsoas, pectineus, and adductor longus muscles.

Anterior = on the inguinal vessels + 20 mm, inclusive of any visible lymph nodes or lymphocoeles

Lateral = The medial edge of sartorius or iliopsoas

Medial = A 10- to 20-mm margin around the femoral vessels. The medial third to half of the pectineus or adductor longus muscle serves as an approximate border.

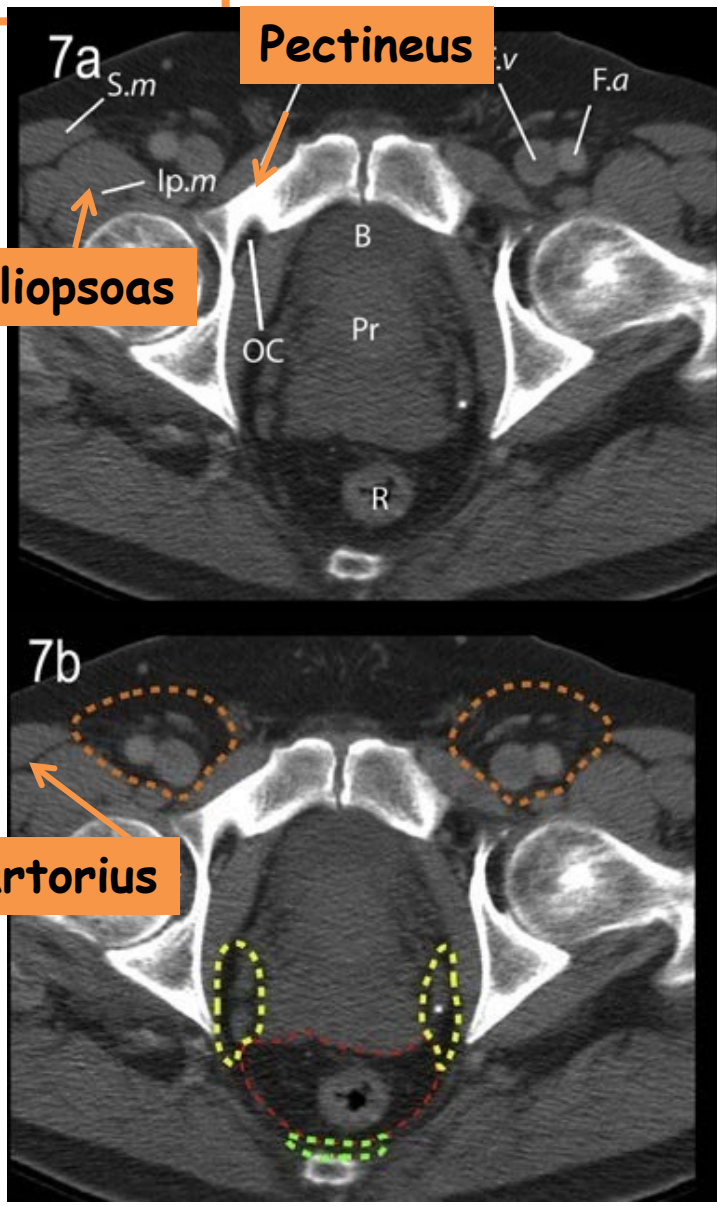

Taylor A et al. Clin Oncol (R Coll Radiol). 2007
M. Ng, et al. (AGITG) Int J Radiation Oncol Biol Phys, 2012

CTV COMBINED

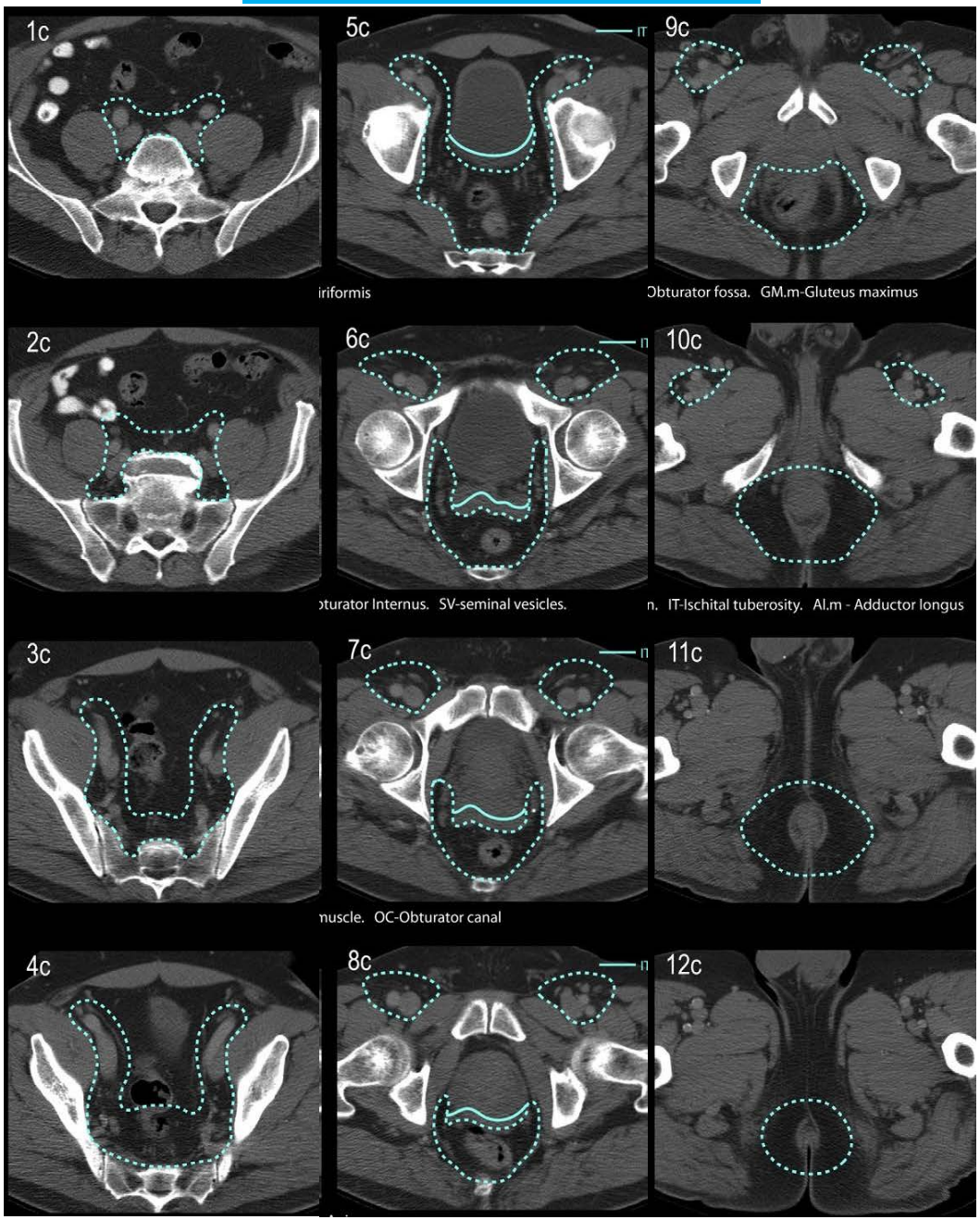

Clinical Investigation: Gastrointestinal Cancer

Australasian Gastrointestinal Trials Group (AGITG) Contouring Atlas and Planning Guidelines for Intensity-Modulated Radiotherapy in Anal Cancer

M. Ng, et al. (AGITG) Int J Radiation Oncol Biol Phys, 2012

CLINICAL TARGET VOLUME FOR GROSS DISEASE

PRIMARY TUMOR

CTV = **GTV** + entire anal canal + internal and external sphinter + 20 mm ispotropic margin

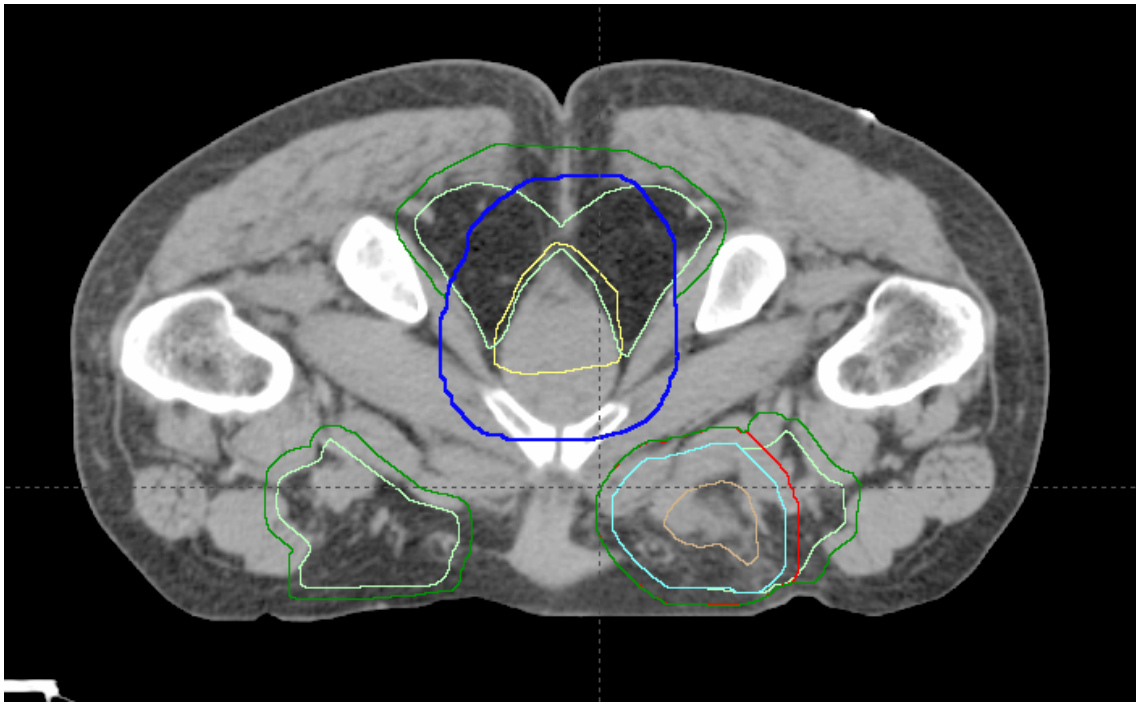

M. Ng, et al. (AGITG) Int J Radiation Oncol Biol Phys, 2012

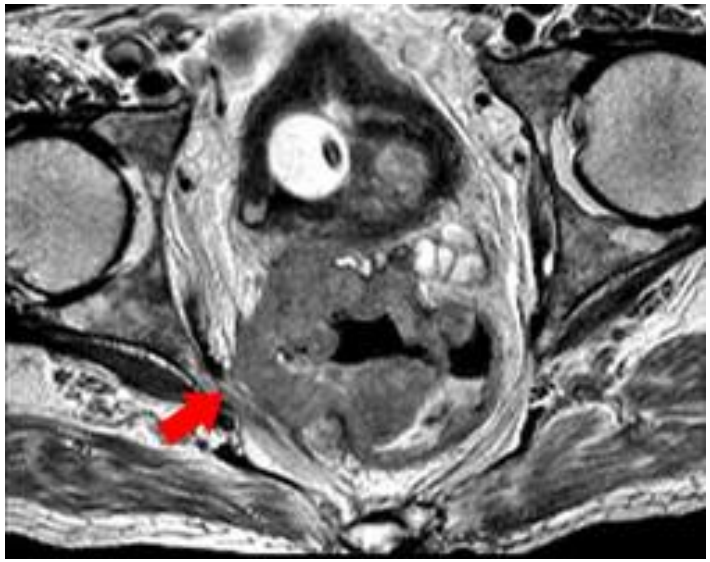

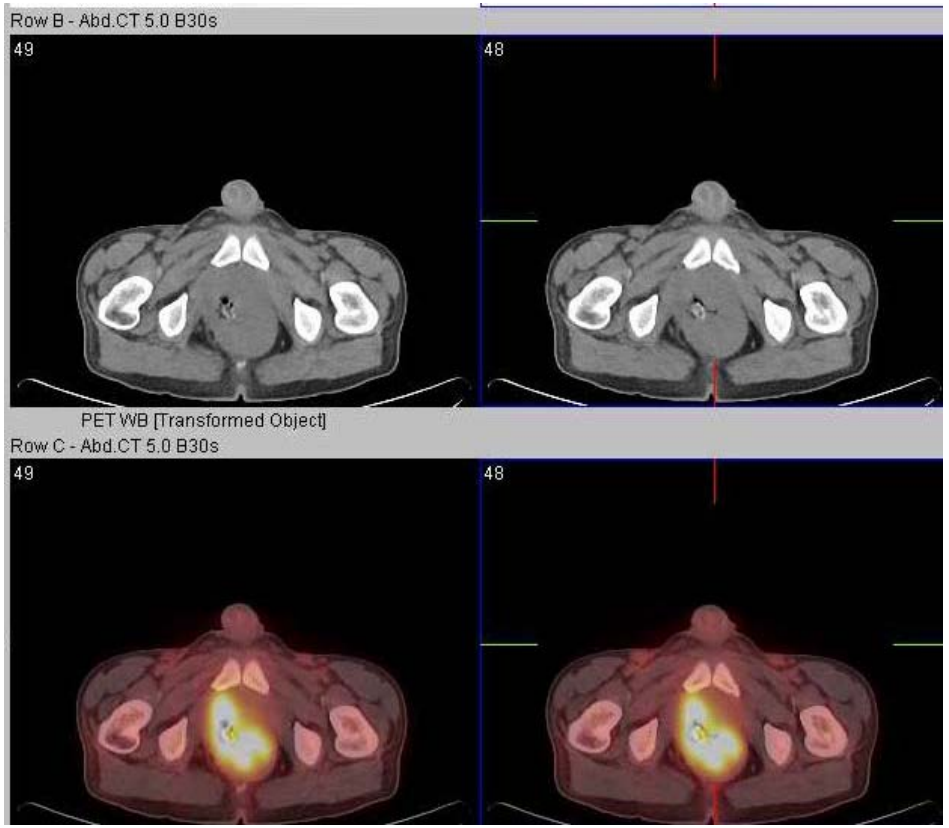

For very **advanced anal** or rectal cancers, extending through the mesorectum or the levators, the group's recommendation is to add ~2 cm margin up to bone wherever the cancer extends beyond the usual compartments.

An MRI and/or PET/CT scan is strongly recommended in such cases.

Myerson RJ, Garofalo MC, El Naqa I, et al. Int J Radiat Oncol Biol Phys. 2009

Krengli *et al. Radiation Oncology* 2010, **5**:10
http://www.ro-journal.com/content/5/1/10

RADIATION ONCOLOGY

RESEARCH Open Access

FDG-PET/CT imaging for staging and target volume delineation in conformal radiotherapy of anal carcinoma

Marco Krengli[1,2*], Maria E Milia[1], Lucia Turri[1], Eleonora Mones[3], Maria C Bassi[1], Barbara Cannillo[3], Letizia Deantonio[1], Gianmauro Sacchetti[4], Marco Brambilla[3], Eugenio Inglese[4]

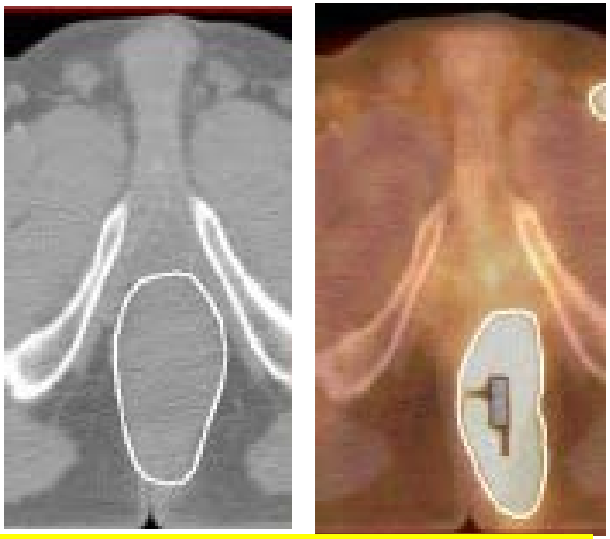

For the T3-T4 cases CT images may be unable to clearly detect the tumor extension in relation with the close proximity of muscle structures especially at the level of the perineum. As a matter of fact, CT images may overestimate tumor volume in low rectal cancer compared to FDG-PET/CT orMR

The British Journal of Radiology, 82 (2009), 509–513

BIR The British Institute of Radiology

SHORT COMMUNICATION

MR *vs* CT imaging: low rectal cancer tumour delineation for three-dimensional conformal radiotherapy

[1]B D P O'NEILL, MB, MRCPI, FFRRCSI, [2]G SALERNO, MRCS, [3]K THOMAS, BSC, [1]D M TAIT, MD and [4]G BROWN, FRCR

[1]*Department of Clinical Oncology, Royal Marsden Hospital, Sutton, Surrey SM2 5PT,* [2]*Pelican Cancer Foundation, North Hampshire Hospital, Basingstoke, and Departments of* [3]*Medical Statistics and* [4]*Radiology, Royal Marsden Hospital, Sutton, Surrey SM2 5PT, UK*

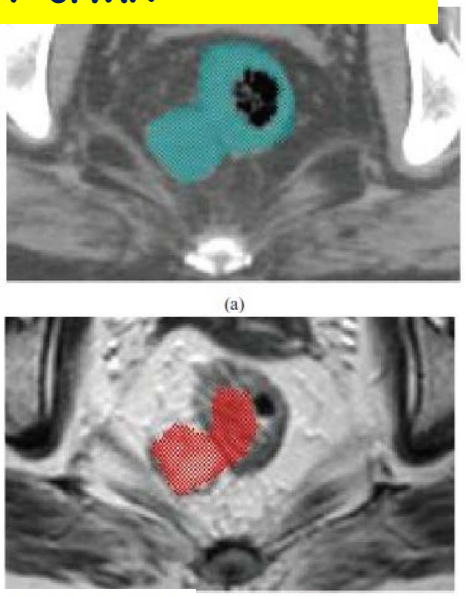

Figure 2. (a) Axial CT and (b) axial T_2 fast spin-echo (TR 3900, TE 120) MR images from the same patient, showing a T3 rectal adenocarcinoma. The shaded areas represent gross tumour volume delineation by the same radiologist. This overestimation of tumour volume on CT was consistent for all patients.

Clinical Investigation: Gastrointestinal Cancer

Australasian Gastrointestinal Trials Group (AGITG) Contouring Atlas and Planning Guidelines for Intensity-Modulated Radiotherapy in Anal Cancer

M. Ng, et al. (AGITG) Int J Radiation Oncol Biol Phys, 2012

CLINICAL TARGET VOLUME FOR GROSS DISEASE

INVOLVED NODE(S)

CTV = **Involved nodes** + 10-20 mm ispotropic margin, respecting anatomical boundaries.

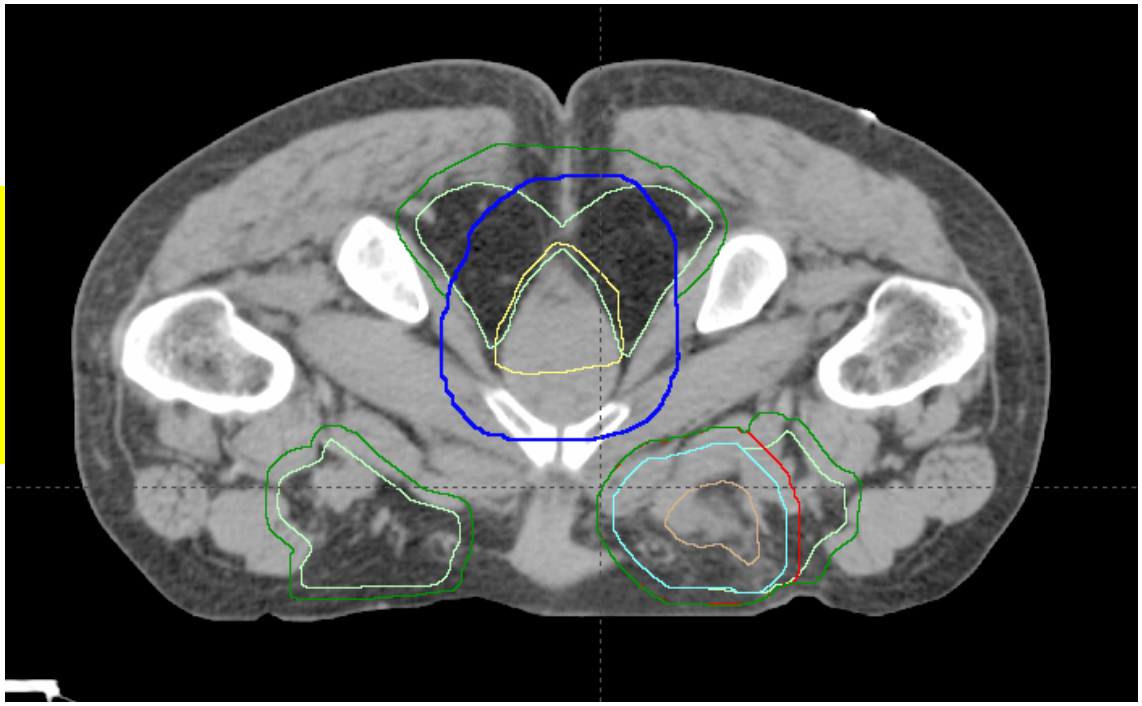

M. Ng, et al. (AGITG) Int J Radiation Oncol Biol Phys, 2012

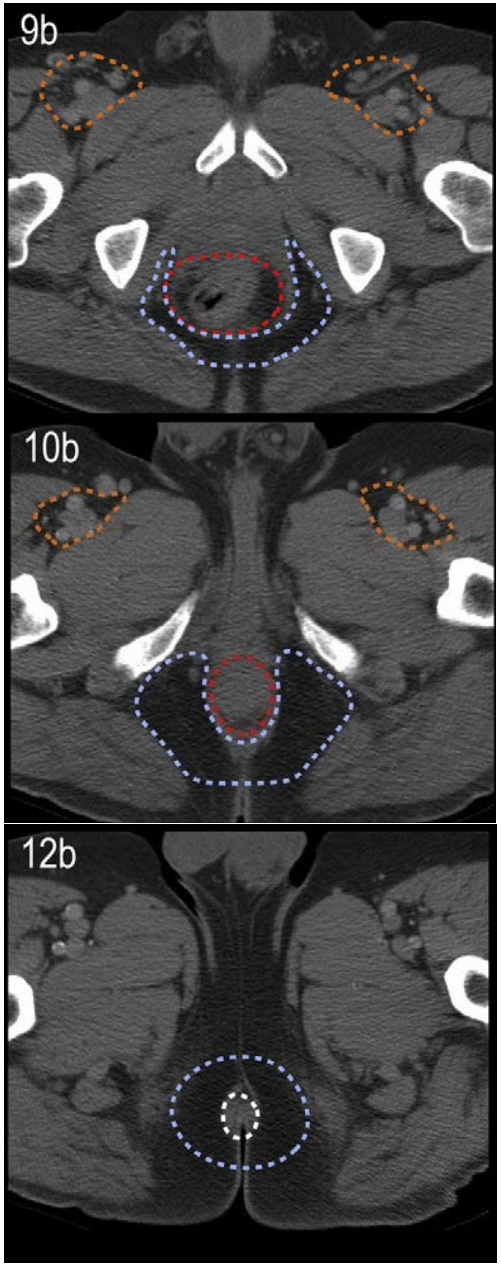

Critical issues

ISCHIORECTAL FOSSA

The RTOG guidelines do not consider the IRF to be an area at risk.

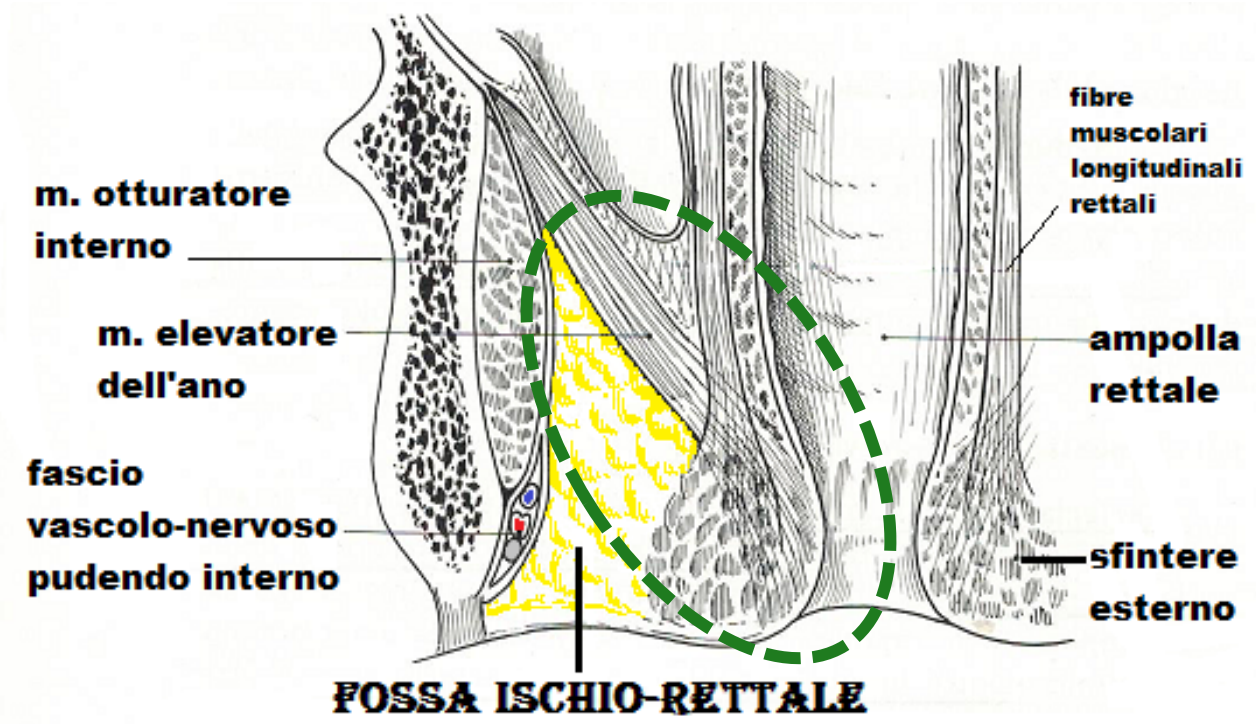

M. Ng, et al. (AGITG) Int J Radiation Oncol Biol Phys, 2012

OARs in ano-rectal

Anal cancer delineation

- **Definitive chemoradiation**
- High doses
- **IMRT** strongly recommended
- **Atlas available** different concept:

CTV (RTOG) VS **subsites** (TROG)

Clinical Investigation: Gastrointestinal Cancer

Australasian Gastrointestinal Trials Group (AGITG) Contouring Atlas and Planning Guidelines for Intensity-Modulated Radiotherapy in Anal Cancer

M. Ng, et al. (AGITG) Int J Radiation Oncol Biol Phys, 2012

Organs at risk (OAR)

Clinical Investigation: Genitourinary Cancer

Pelvic Normal Tissue Contouring Guidelines for Radiation Therapy: A Radiation Therapy Oncology Group Consensus Panel Atlas

Gay HA et al. Int J Radiat Oncol Biol Phys. 2012

Organs at risk (OAR)

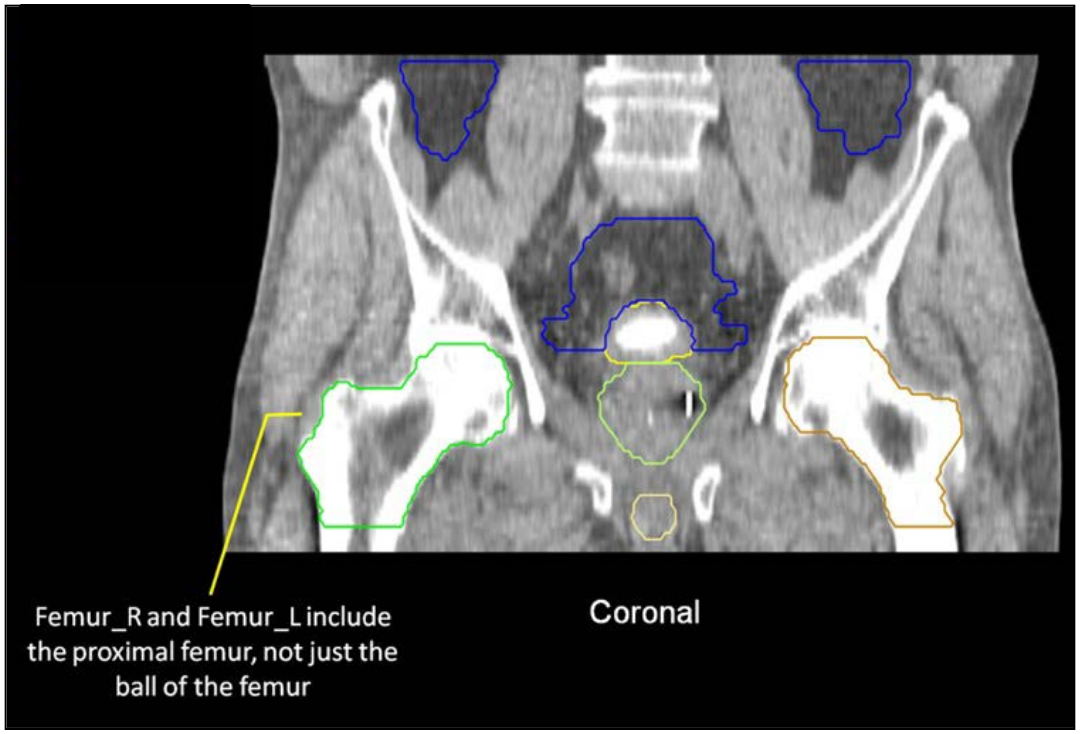

Femoral head and neck: The entire femoral head and neck should be contoured. The inferior extent is the cranial edge of the lesser trochanter.

Urinary bladder: The entire external outline of the bladder wall should be contoured.

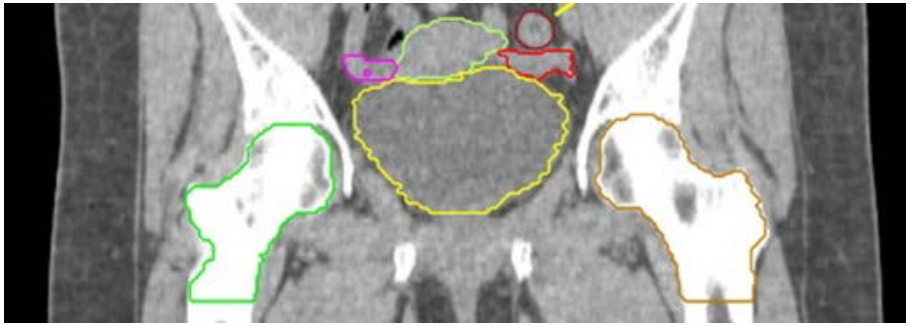

Gay HA et al. Int J Radiat Oncol Biol Phys. 2012
M. Ng, et al. (AGITG) Int J Radiation Oncol Biol Phys, 2012

Clinical Investigation: Gastrointestinal Cancer

Australasian Gastrointestinal Trials Group (AGITG) Contouring Atlas and Planning Guidelines for Intensity-Modulated Radiotherapy in Anal Cancer

M. Ng, et al. (AGITG) Int J Radiation Oncol Biol Phys, 2012

Organs at risk (OAR)

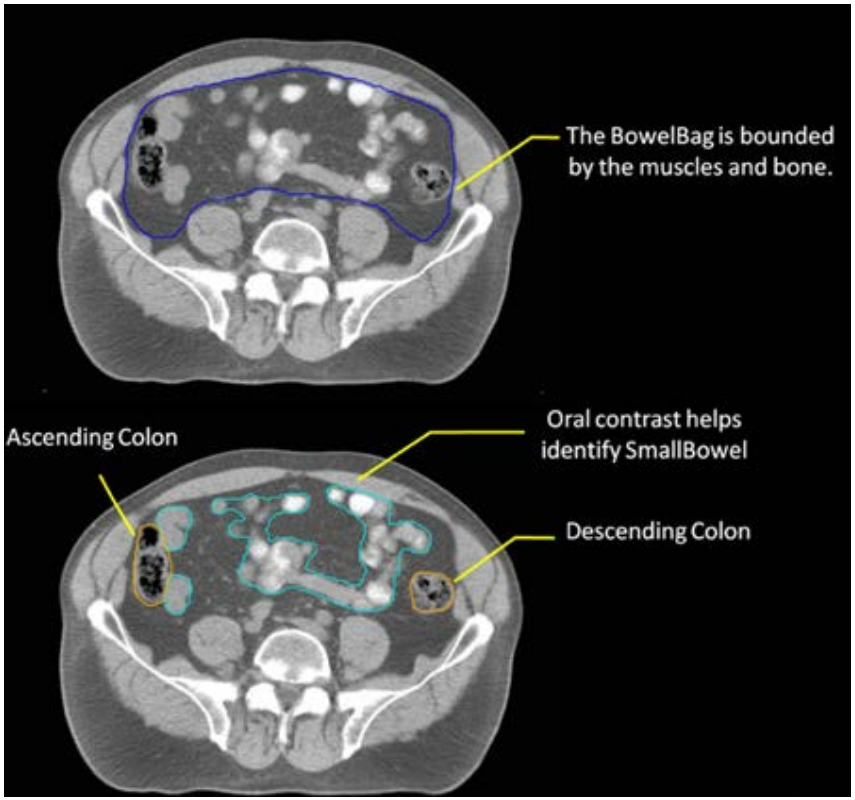

Bowel: Small bowel and large bowel, opacified or nonopacified, should be delineated from 15-mm superior to the cranial aspect of the PTV, extending inferiorly to the recto-sigmoid junction.

Devisetty K, et al. Radiother Oncol 2009

Bowel NOS: Peritoneal space occupied or potentially occupied by bowel,large or small.
Small boweld: To distinguish from large bowel, the use of o.c., administered 30 minutes before scanning, is encouraged. The small bowel can be outlined as loops containing contrast.
Large boweld: All intestine seen above the rectum; usually delineated as the bowel starting with noncircular or oval structures or above 15 cm.

Gay HA et al. Int J Radiat Oncol Biol Phys. 2012

M. Ng, et al. (AGITG) Int J Radiation Oncol Biol Phys, 2012

SB-Positioning: prone vs supine

: analysis of dose

	PTV ∩ V_{SB} (cm^3)		V_{SB} (cm^3)	Median dose to SB	
				%	Gy
	PP	SP	SP	PP	SP
Minimum	2.0	13.0	13.0	21.1	27.5
Maximum	264.0	397.0	397.0	78.3	97.4
Mean	74.0	108.6	108.6	33.0	47.8
Median	44.5	97.0	97.0	30.8	47.3
	$p < 0.005$		.005	$p < 0.001$	

SB = sm
SP = supin
) V_{SB} = volume

Koelbl O et al. IJROBP 1999

Small Bowel displacement

small bowel “dispacement devices”:

full bladder

belly board/false table-top

Small Bowel displacement

belly board vs full bladder:

Belly-Board+Full-Bladder >Full-Bladder > Belly-Board

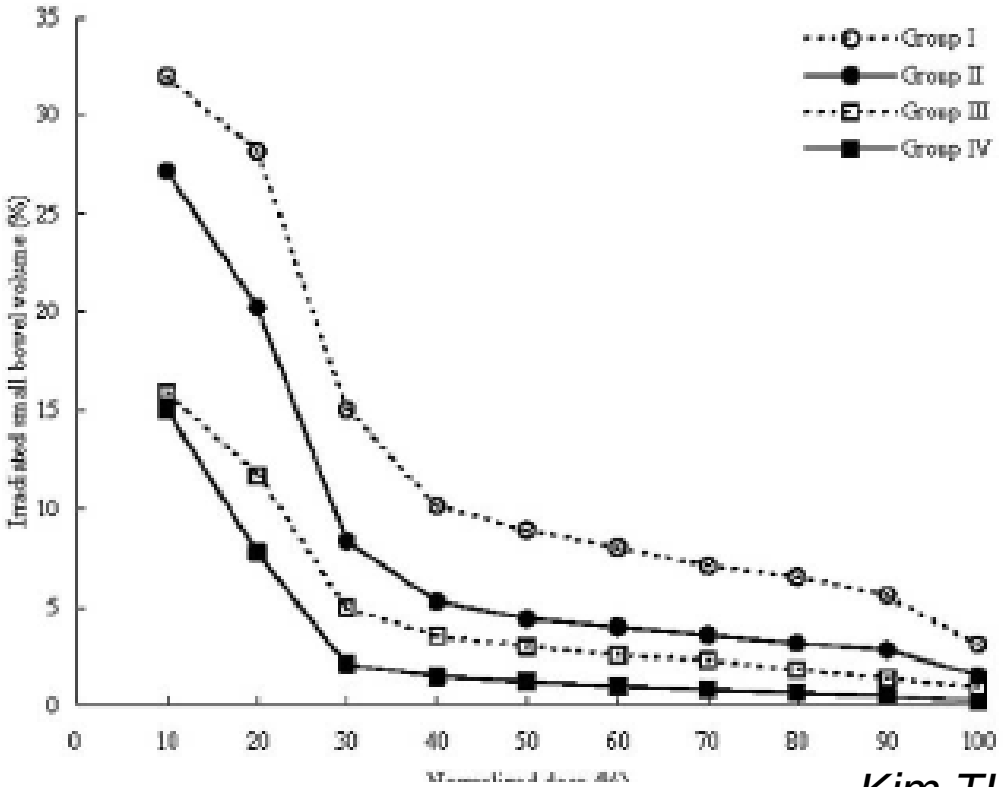

Kim TH et al. IJROBP 2005

Small Bowel displacement

Full bladder limitations:

restriction of urination of about 2h

variation in bladder distension:

age, other illnesses, surgery, toxicity…

Kim TH et al. IJROBP 2005

Un-intentional release of stool

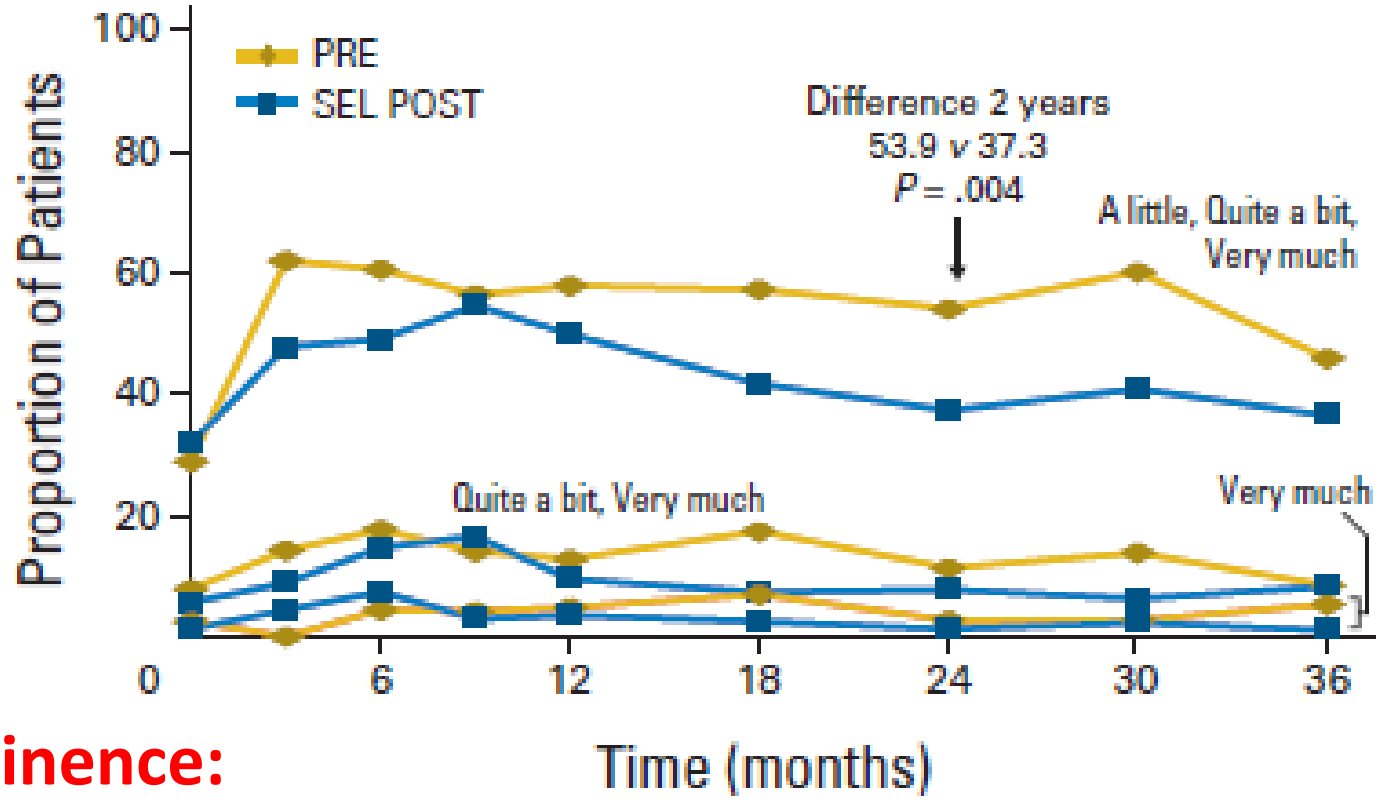

- **Incontinence:**
- **anal sphincter inclusion:**
- **y 93% vs no 65%** **(p = 0.059)**

Stephens et al JCO 2010
Lange MM et al Br J Surg

Clinical Investigation: Gastrointestinal Cancer

Australasian Gastrointestinal Trials Group (AGITG) Contouring Atlas and Planning Guidelines for Intensity-Modulated Radiotherapy in Anal Cancer

M. Ng, et al. (AGITG) Int J Radiation Oncol Biol Phys, 2012

Organs at risk (OAR)

External genitalia and perineum.
In **MALES**: the bulb penis, scrotum, and area including skin and fat anterior to the pubic symphysis. In **FEMALES**: the clitoris, labia majora and minora, and area including skin and fat anterior to pubic symphysis. The cranial extent of this volume is the caudal edge of the pubic symphysis.

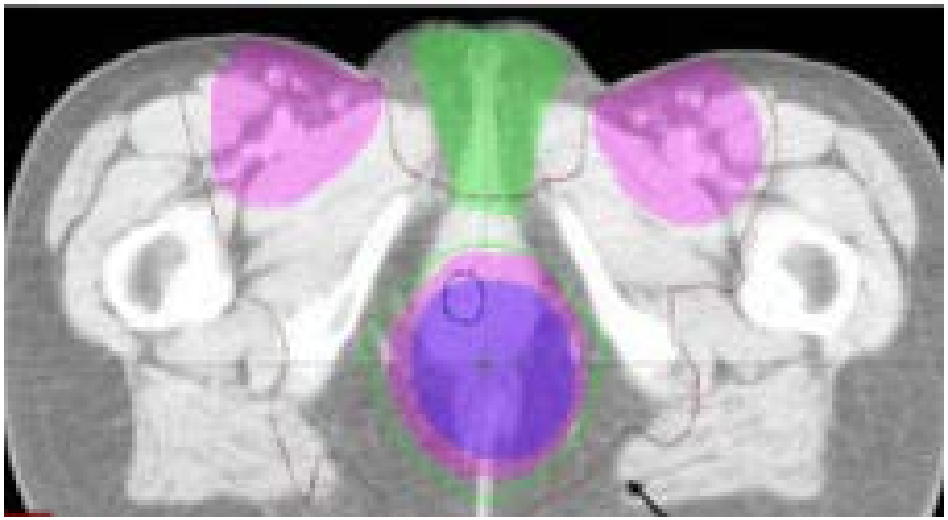

Bone marrow: Both iliac crests will be used to define "bone marrow." Delineation will extend cranially from the top of the iliac crests to the superior part of the acetabulum caudally. The left and right iliac crests are combined into one volume

Gay HA et al. Int J Radiat Oncol Biol Phys. 2012
M. Ng, et al. (AGITG) Int J Radiation Oncol Biol Phys, 2012

Penile Bulb

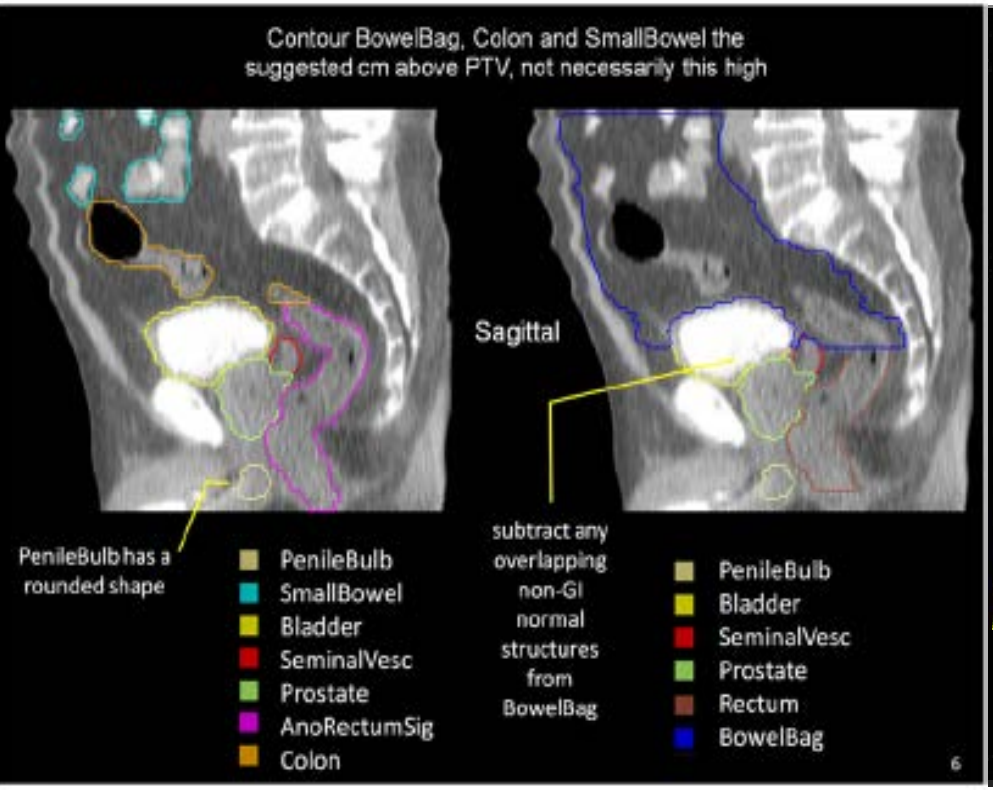
Contour BowelBag, Colon and SmallBowel the suggested cm above PTV, not necessarily this high
Sagittal
PenileBulb has a rounded shape
PenileBulb
SmallBowel
Bladder
SeminalVesc
Prostate
AnoRectumSig
Colon
subtract any overlapping non-GI normal structures from BowelBag
PenileBulb
Bladder
SeminalVesc
Prostate
Rectum
BowelBag
6

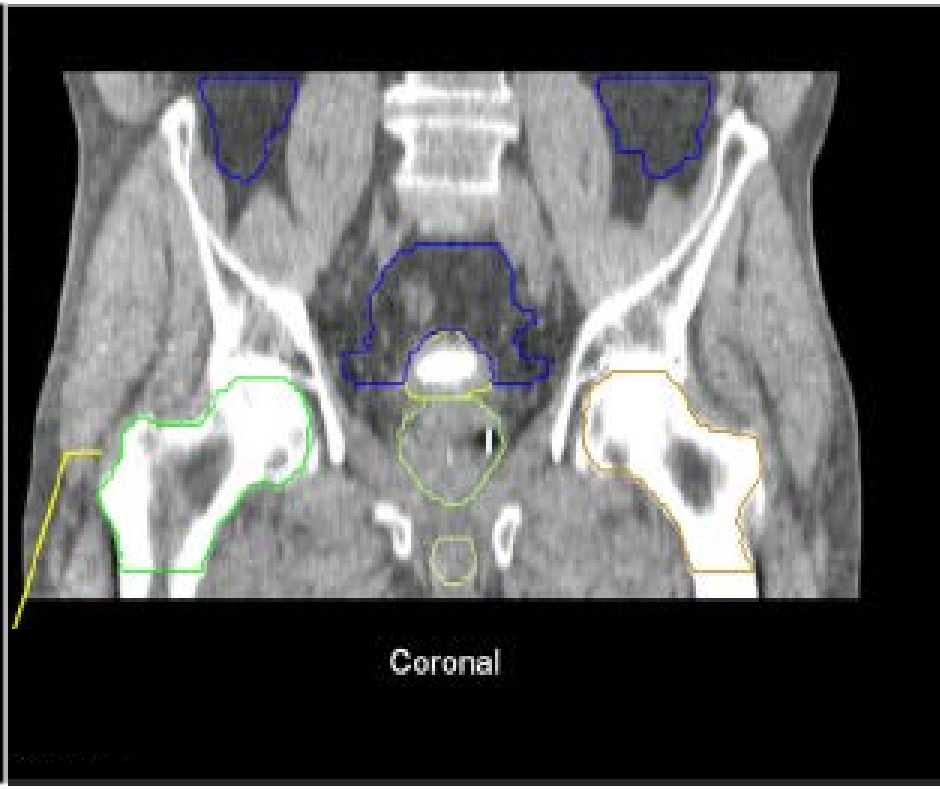
Coronal

Sexual Function

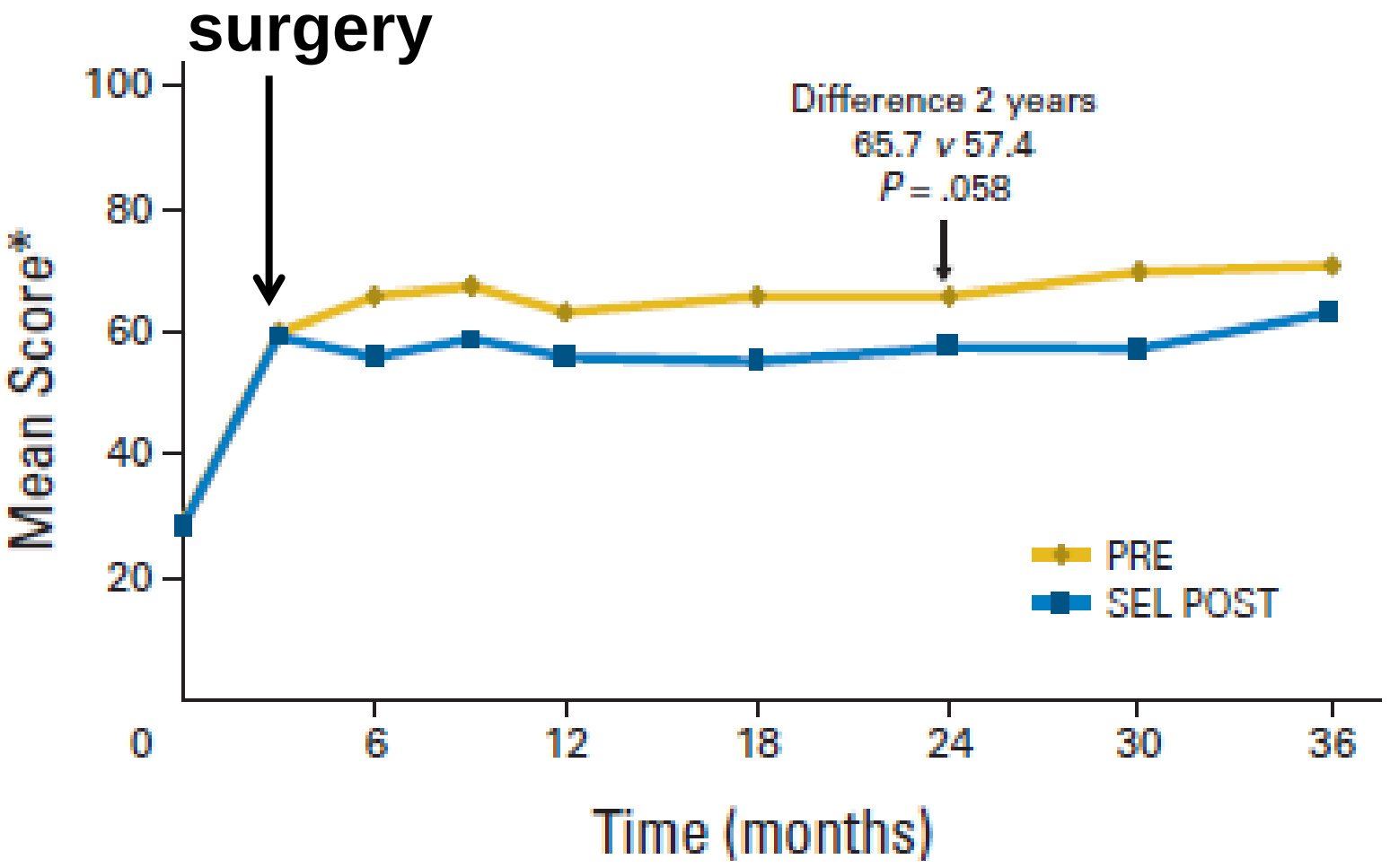

*Only 11% of women completed the questionnaire at 2 yrs

Stephens et al JCO 2010

Sexual Function

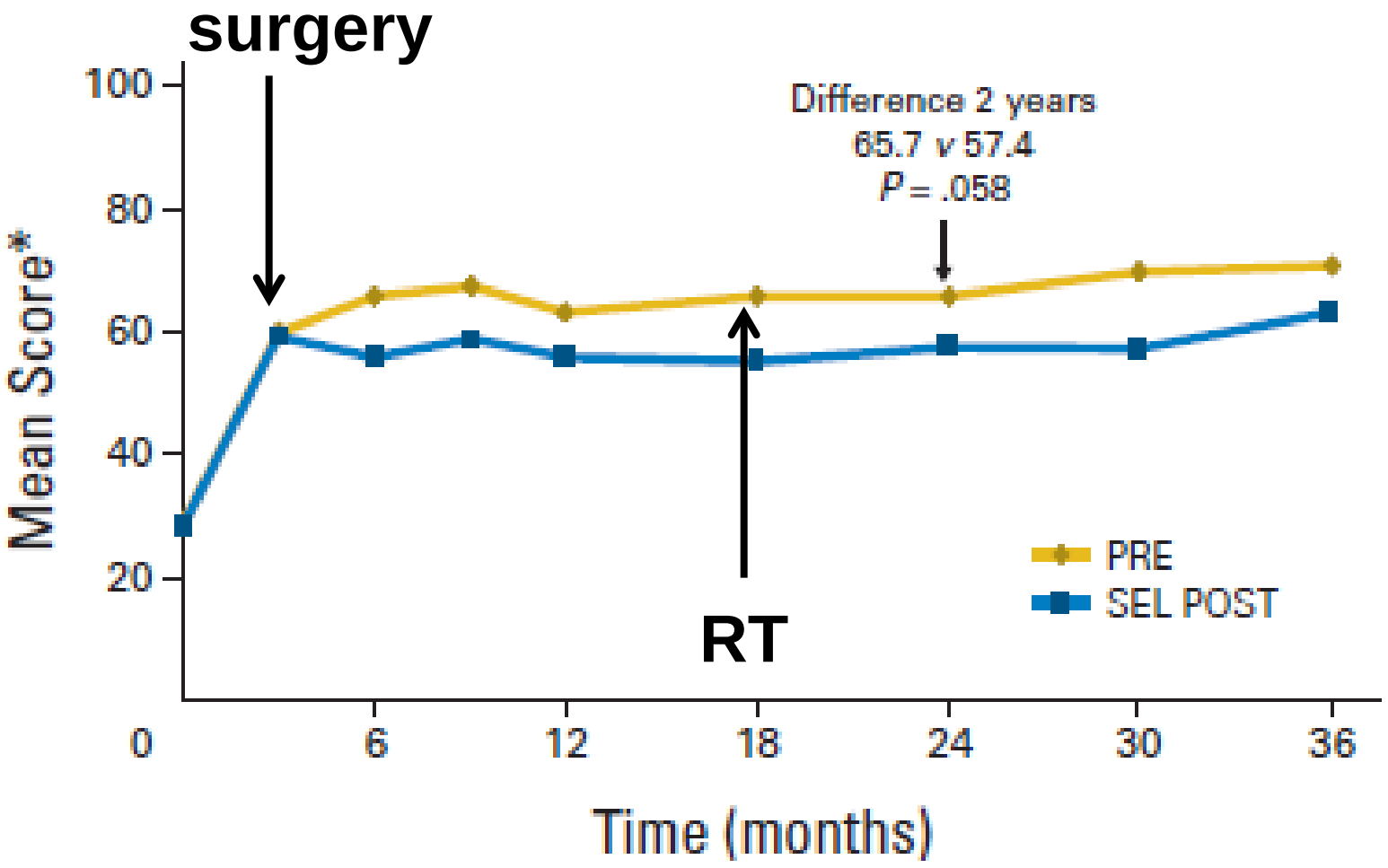

*Only 11% of women completed the questionnaire at 2 yrs

Stephens et al JCO 2010

Penile Bulb

Sexual Dysfunction	D70%
0%	0-40 Gy
80%	40-70 Gy
100%	> 70 Gy

Fish et al Urology 2001

Sexual Dysfunction

NOT in the GUIDELINES!!!

TESTICLES

Increasing the distance from the field:

decreases scattered dose to the testicles.

Mean 3.56 Gy (0,7-8,4Gy): permanent infertility; hypogonadism

VAGINA

Avoiding of the **inferior 3rd** : decreases dryness and pain during intercourse

Hermann et al Radiother Oncol 2005

Bujiko K. in Multid Manag Rectal Cancer. Springer 2012

Ano-Rectum OAR

- Anus: IMRT, proper definition of OARs
- Rectum: multimodality toxicity
- Atlas available
- OARs not included in GUIDELINES

ANATOMY & LYMPH NODE DRAINAGE FOR GYNAECOLOGICAL CANCER

Dr Brendan Carey

St James's University Hospital

Leeds

UK



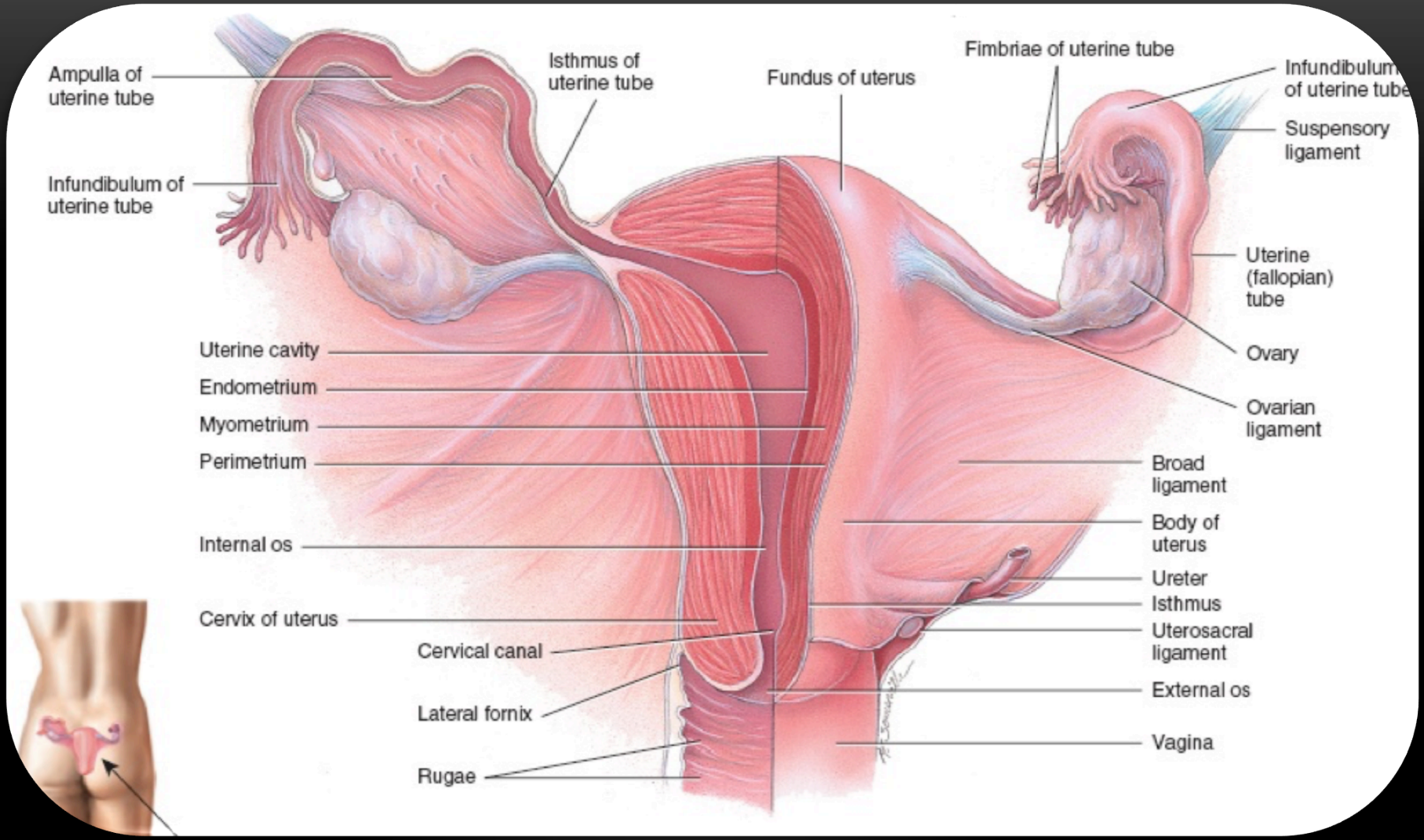
Ampulla of uterine tube
Infundibulum of uterine tube
Isthmus of uterine tube
Fundus of uterus
Fimbriae of uterine tube
Infundibulum of uterine tube
Suspensory ligament
Uterine (fallopian) tube
Ovary
Ovarian ligament
Uterine cavity
Endometrium
Myometrium
Perimetrium
Broad ligament
Body of uterus
Internal os
Ureter
Isthmus
Cervix of uterus
Uterosacral ligament
Cervical canal
External os
Lateral fornix
Vagina
Rugae

GYN CANCER : IMAGING THE ANATOMY

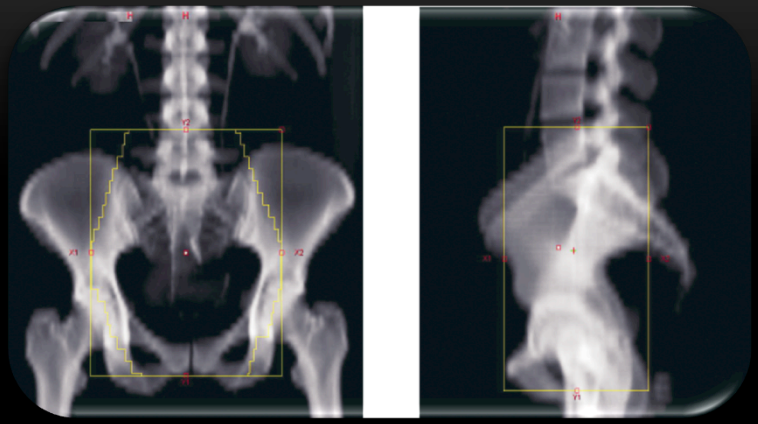

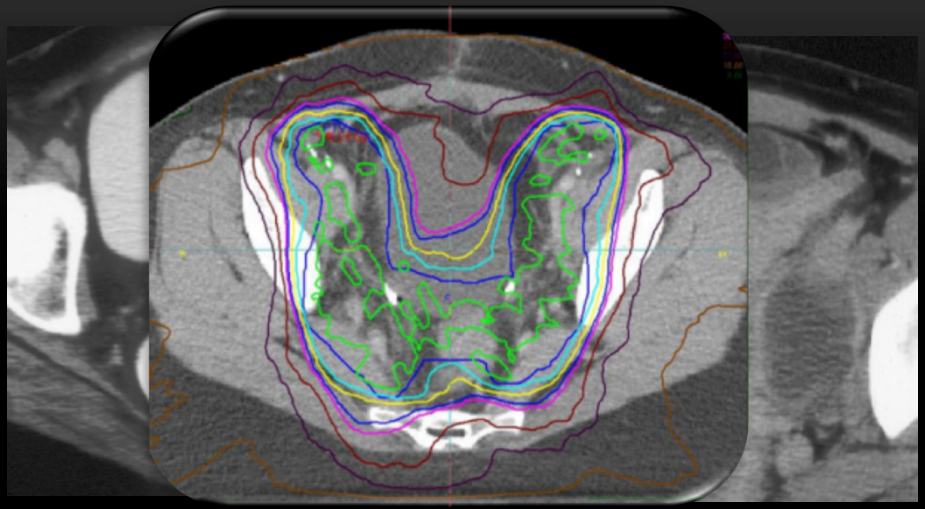

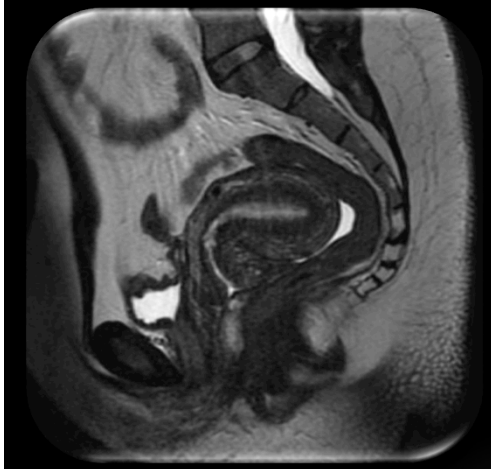

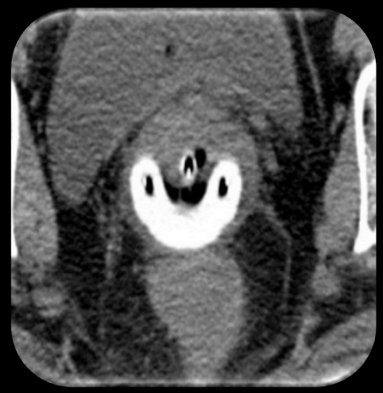

CERVIX CANCER

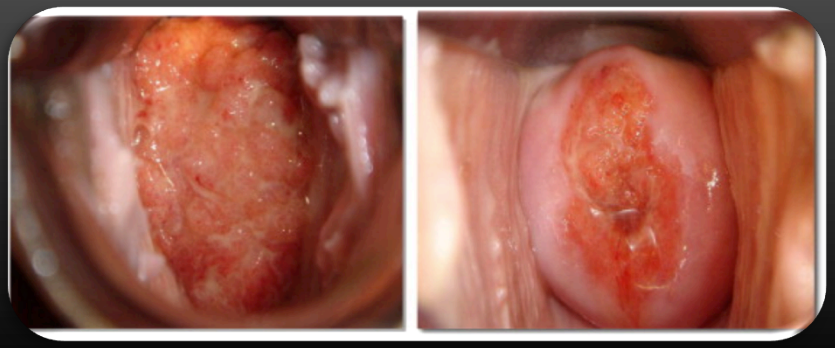

- The original staging for cervical carcinoma was introduced in 1928. This was a staging system based on clinical exam and it largely remains so today. There have been 8 revisions since 1950 and the most recent changes occurred in 2009.

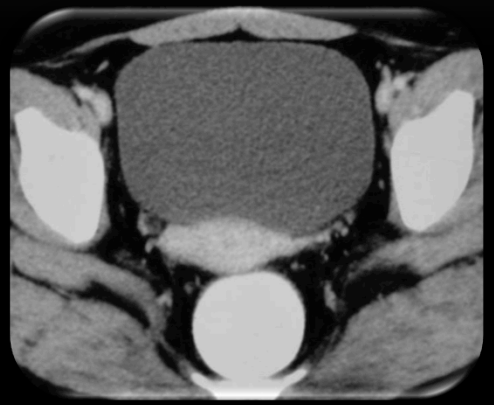

- Clinical staging errors occur in up to 25% of Stage I and Stage II disease; in 50-65% of Stage IIA to IIIB disease; and in 67% of Stage IVA disease.

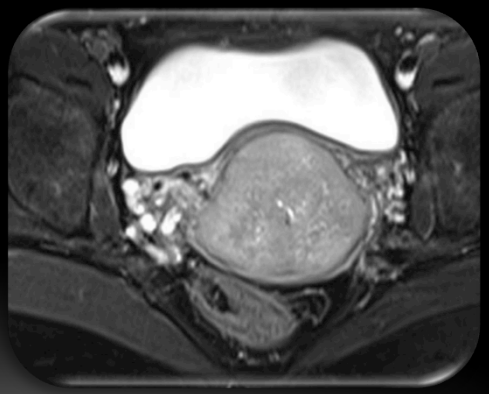

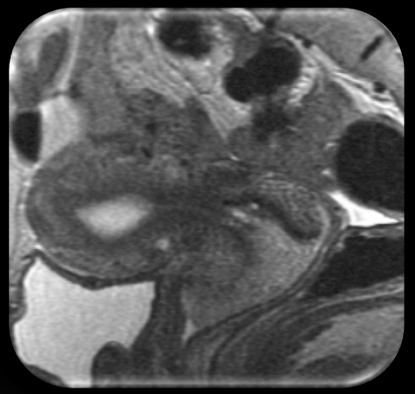

- Overall, compared with surgery, clinical staging underestimates the stage in 25-67% of cases and overestimates in 2%

- Squamous cervical tumours occur at the squamo-columnar junction.

- In premenopausal women this is at the level of the ectocervix and consequently tumours are often exophytic

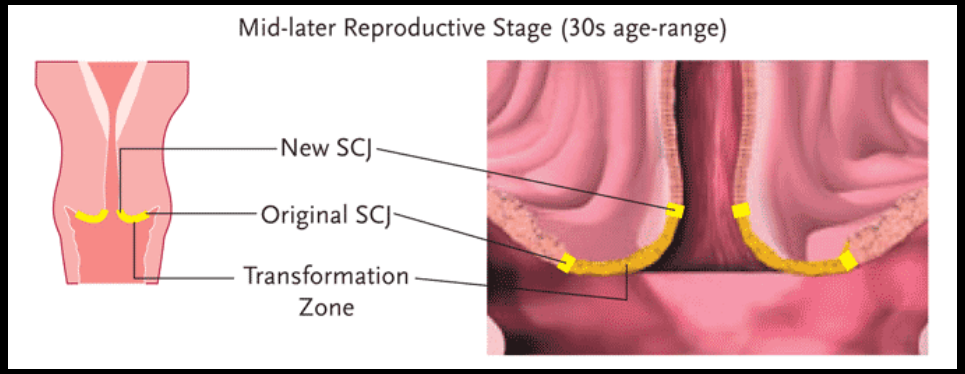

- In post menopausal women the junction migrates up the endocervical canal.
- Tumours in this group often grow superiorly into the uterine body
- Obstruction of the endometrial cavity may occur

UTERINE ZONAL ANATOMY ON T2W

- Inner high signal intensity stripe
- Low signal intensity junctional zone
- Intermediate signal intensity myometrium

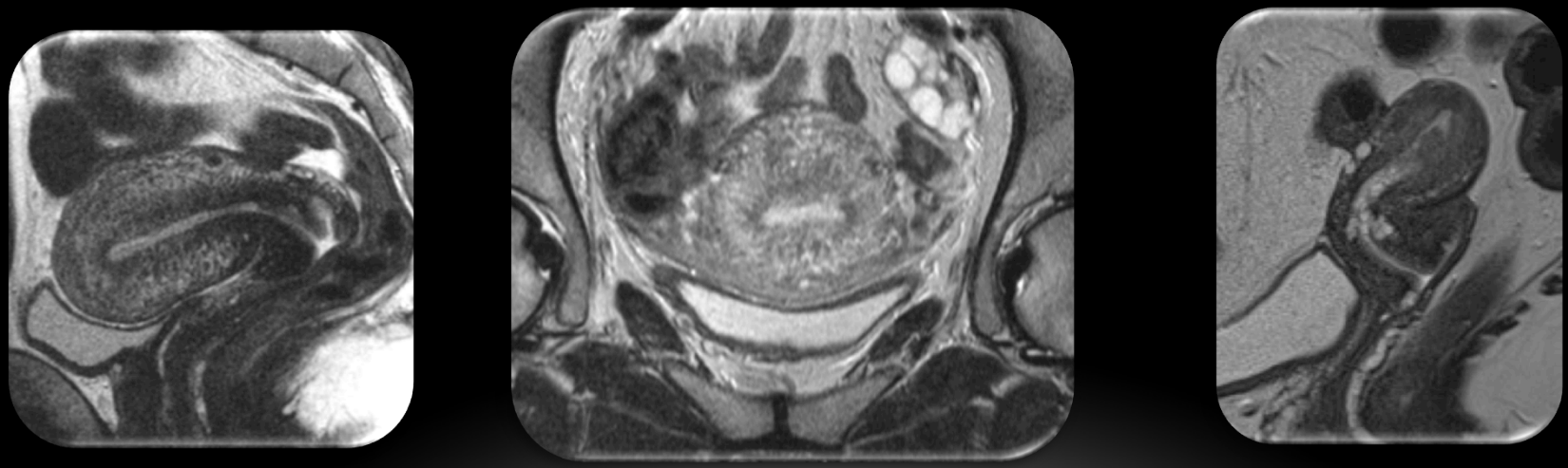

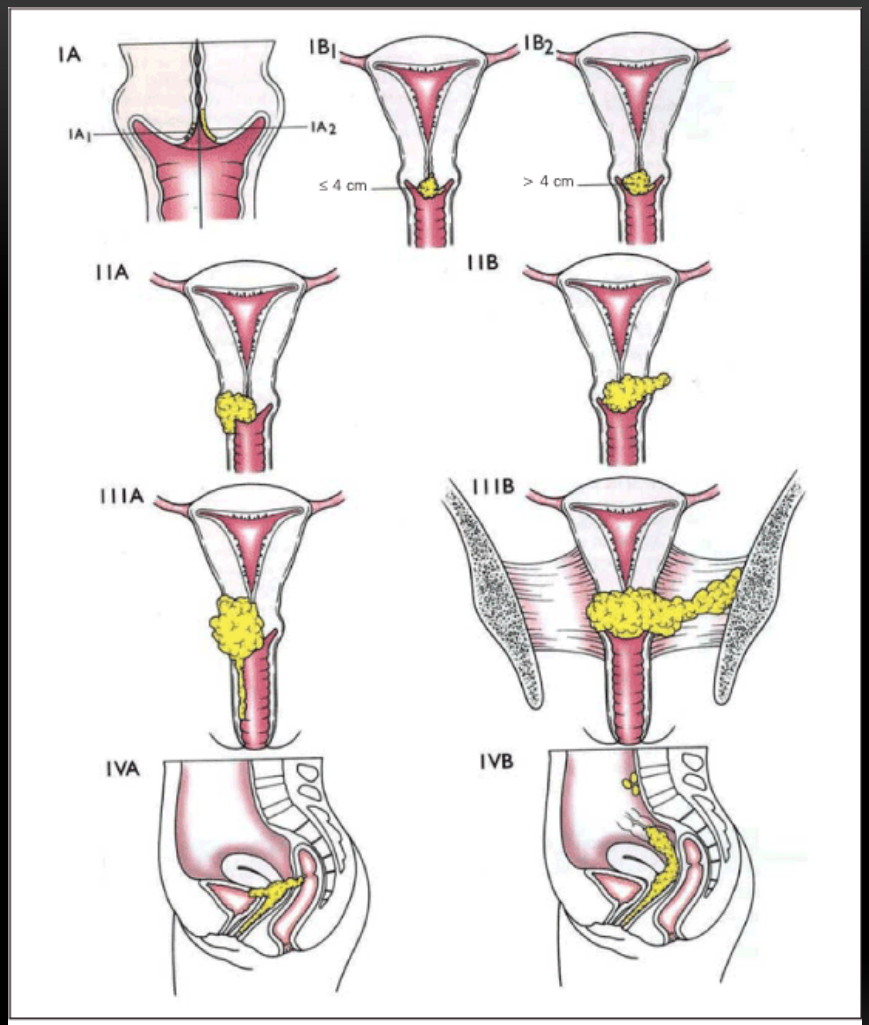

Figure 1. Staging of uterine cervix carcinoma according to FIGO[3].

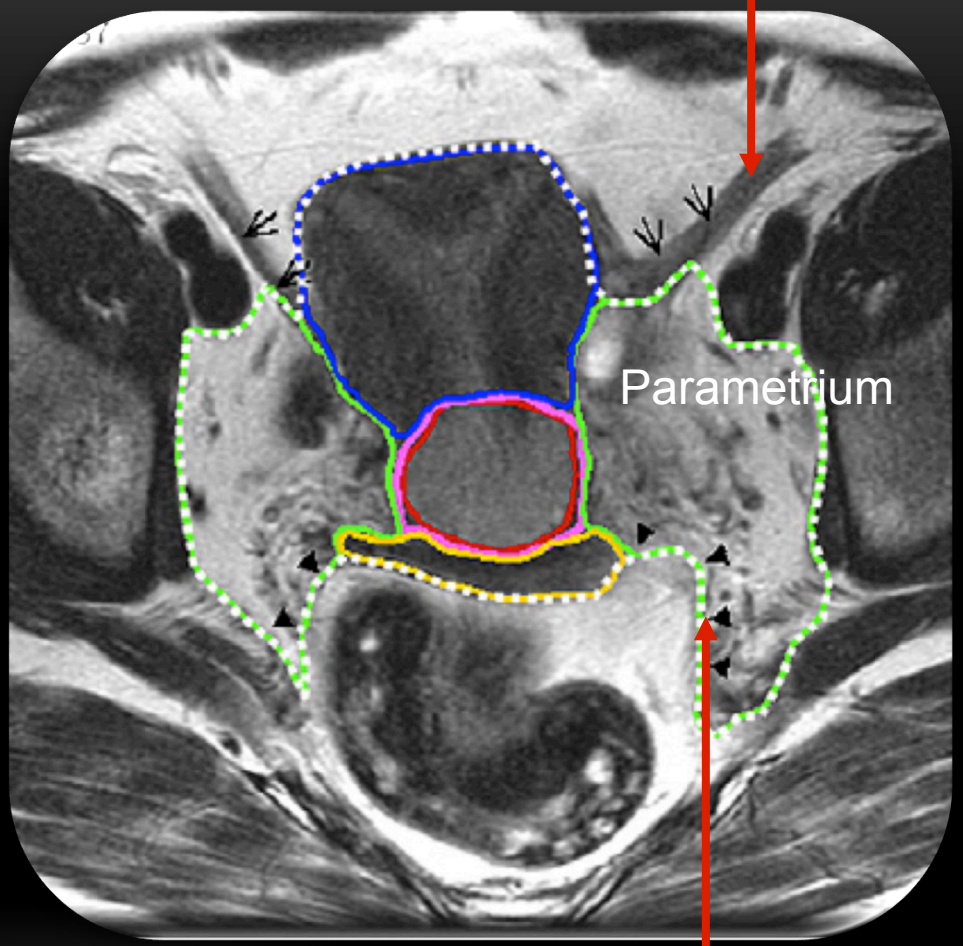

ANATOMY OF CERVIX CANCER ON MRI

- Increased fibrous tissue in the cervical stroma causes it to be ***lower*** signal than myometrium

- Tumour appears as ***increased*** signal intensity material replacing the low signal cervical stroma

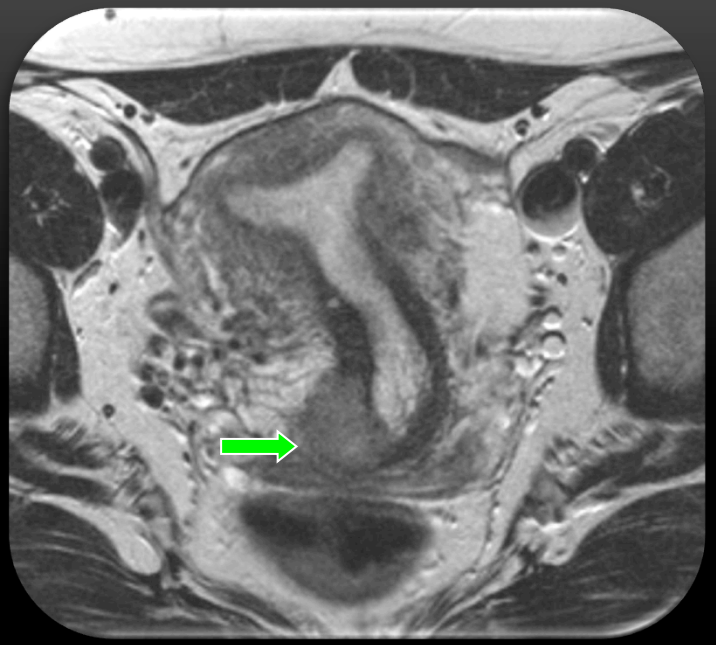

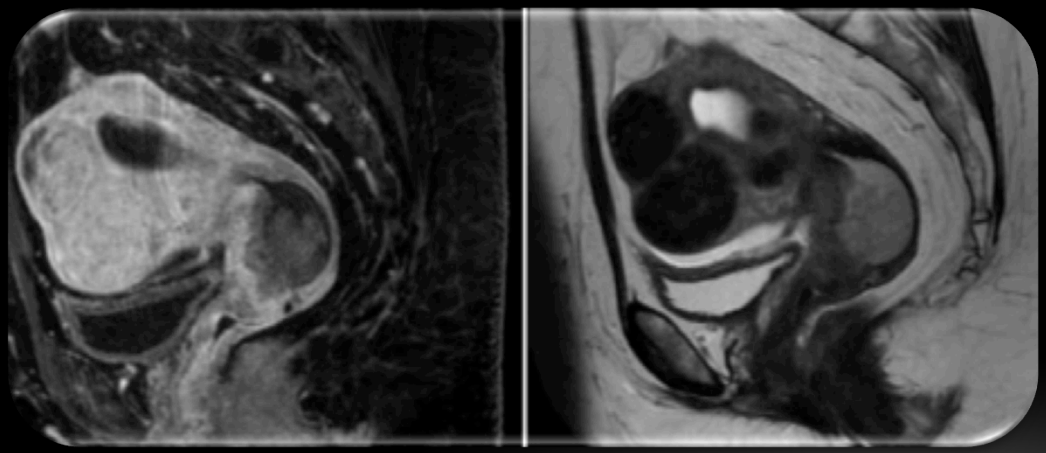

- MRI is the only imaging technique that can give an accurate anatomically-based measurement of tumour length and volume
- Tumour volume is an independent poor prognostic factor

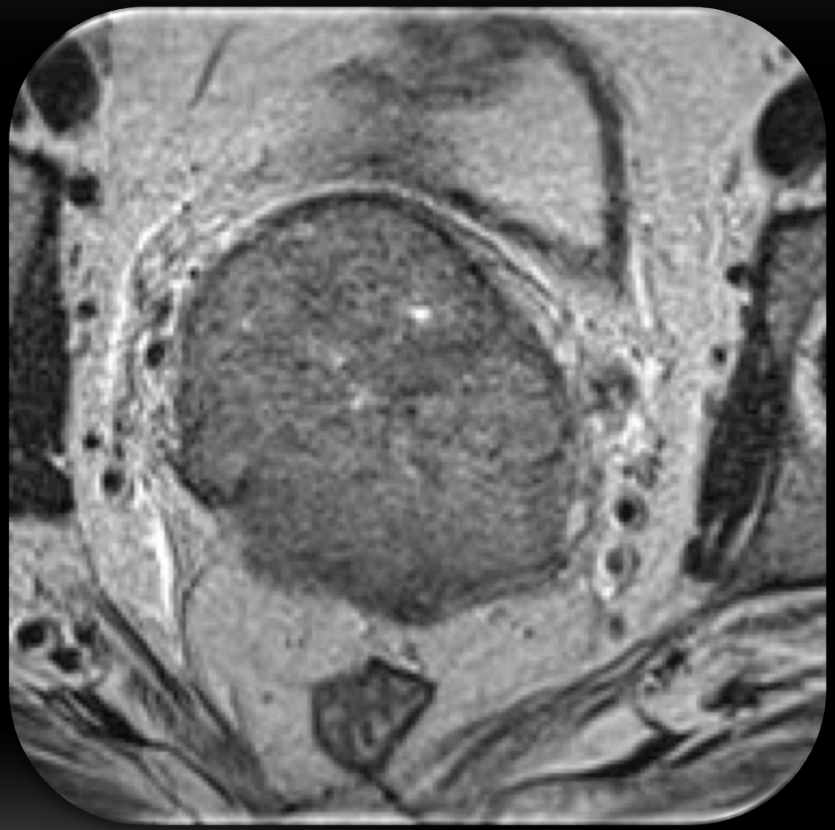

STAGE 1B CERVIX CANCER

- **Confined to cervix**
- **Intermediate signal tumour against low signal stroma**
- **Intact low signal intensity stromal**

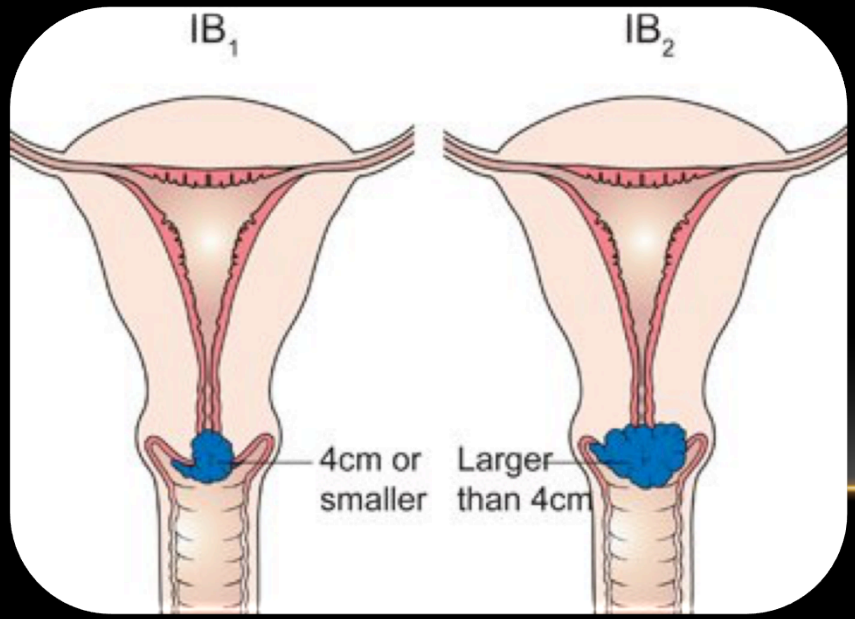

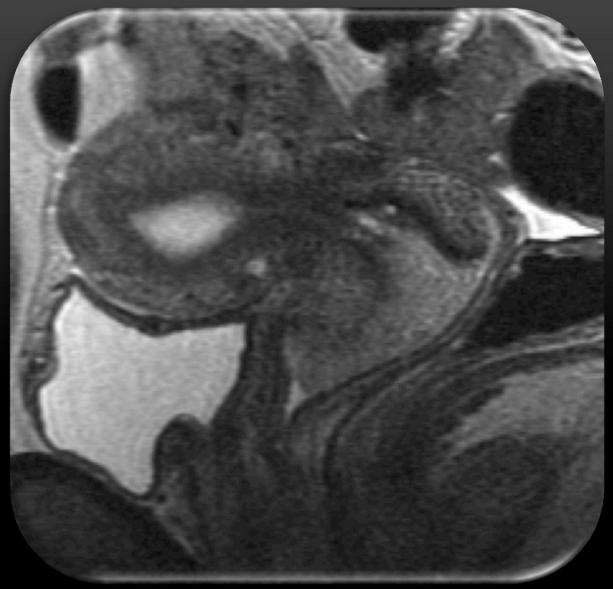

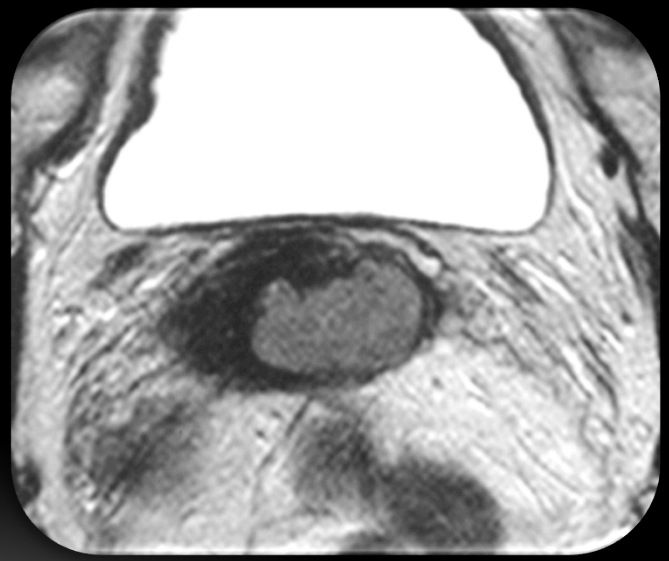

BULKY STAGE IB DISEASE

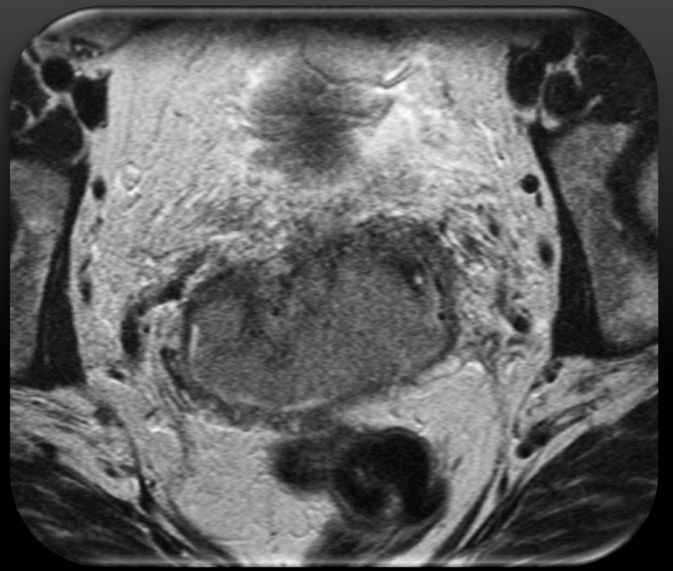

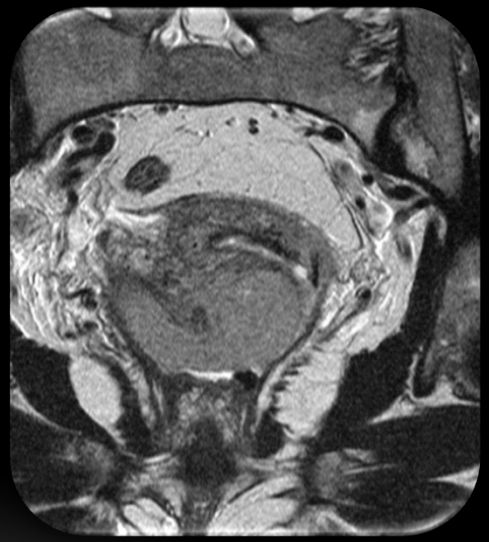

STAGE IIA – INVOLVING UPPER 2/3RDS OF VAGINA

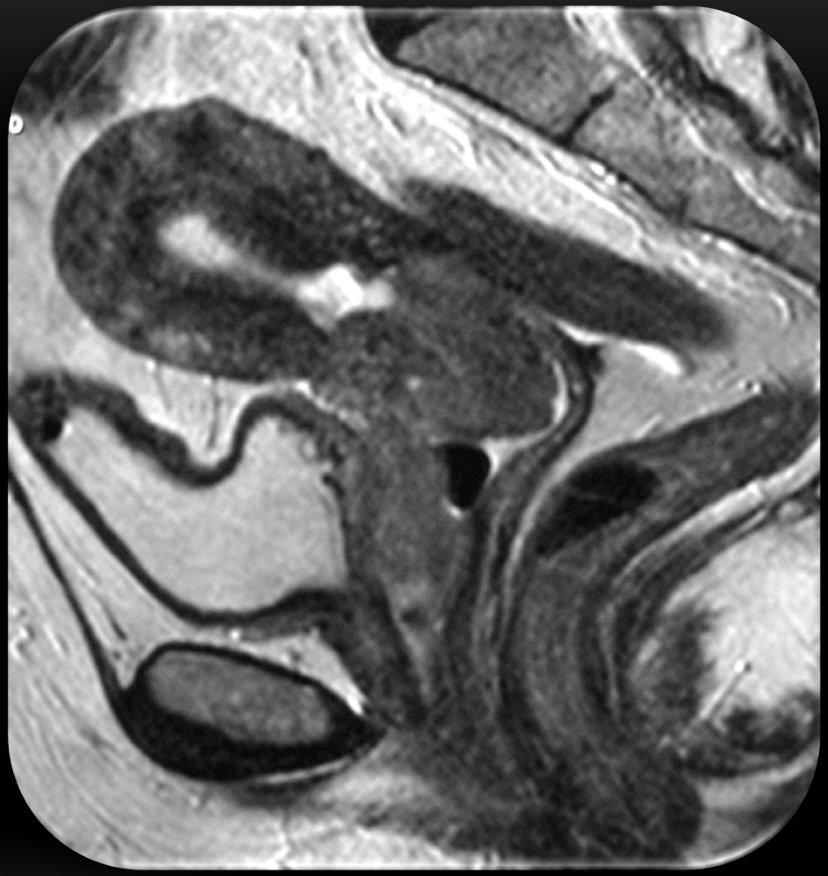

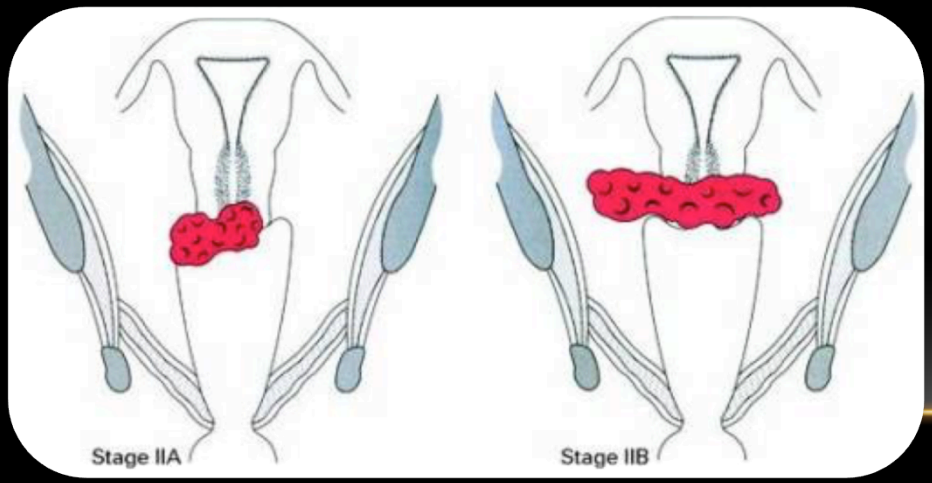

KNOW ANATOMY VAGINA

- **What is the inferior extent of the tumour?**
- **What is GTV**

  - affects the CTV-T
- **Influence on Nodal coverage**

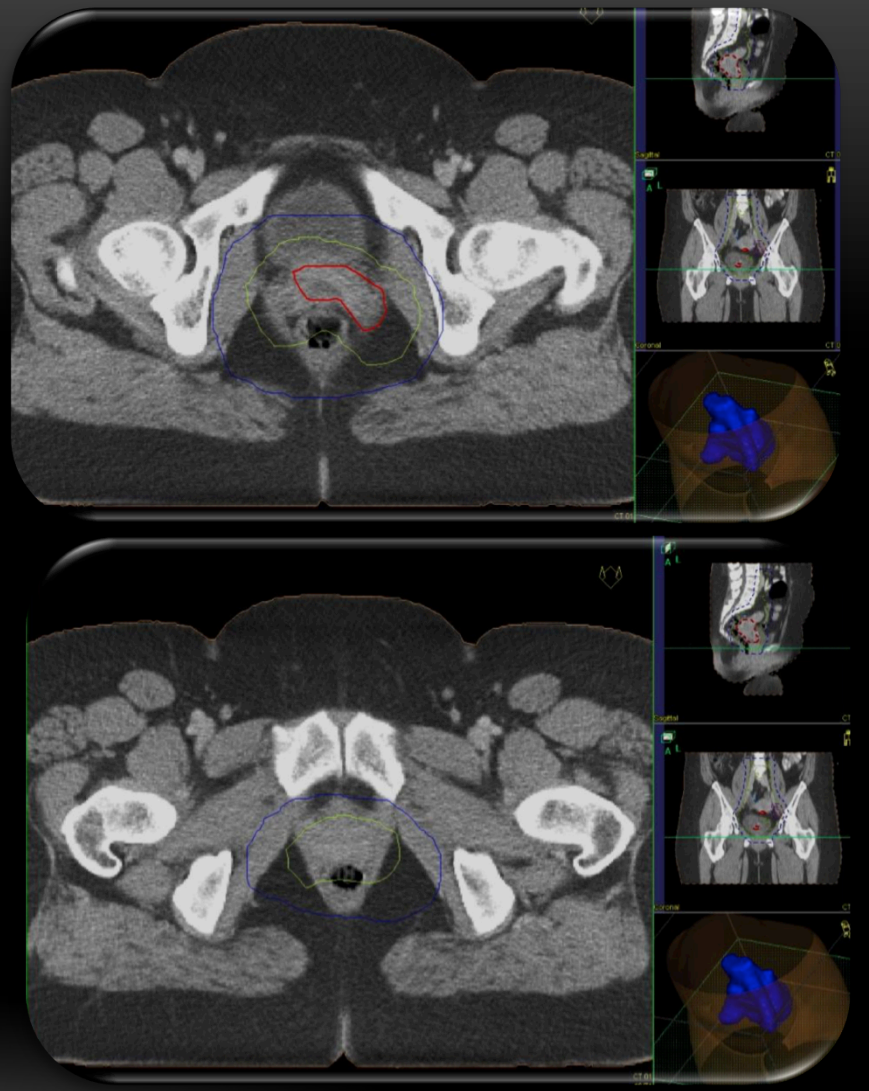

Vaginal involvement assessed

- **Not as good as clinical examination**
- **Difficult to see on Planning CT**

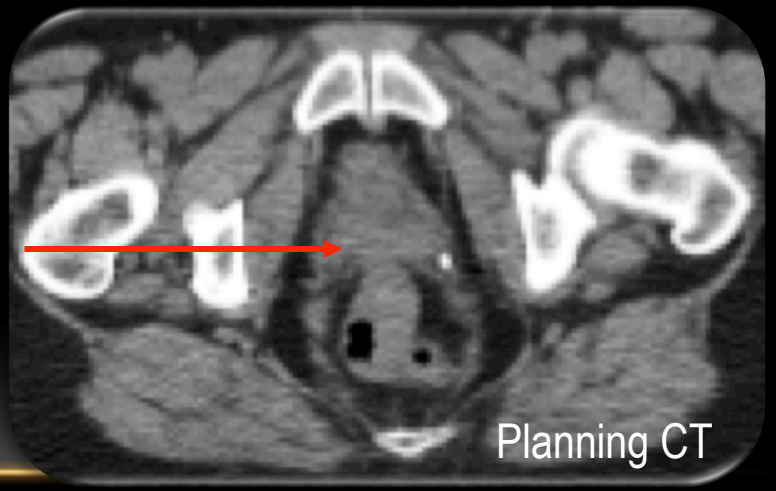

LIMITATIONS OF MRI FOR DEFINING GTV

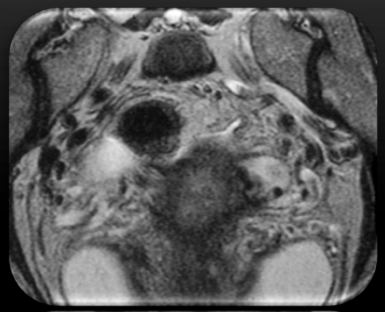

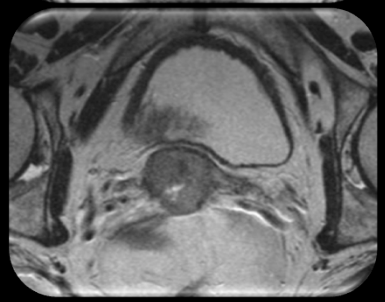

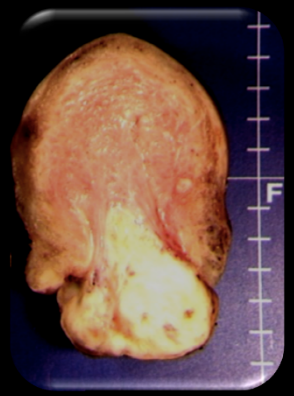

False positive for parametrial invasion
oedema
inflammation

Post large loop excision of the transition zone (LLETZ) or cone biopsy

Haemorrhage, granulation tissue

In premenopausal women this is at the level of the ectocervix and consequently tumours are often exophytic

LIMITATIONS OF MRI FOR ANATOMY - EXOPHYTIC TUMOURS

- Young women
- Bulky tumours
- Prolapse down into vagina

One of the most common causes of confusion is the presence of a large exophytic tumour where the vaginal wall is misinterpreted as the circumferential cervical stroma

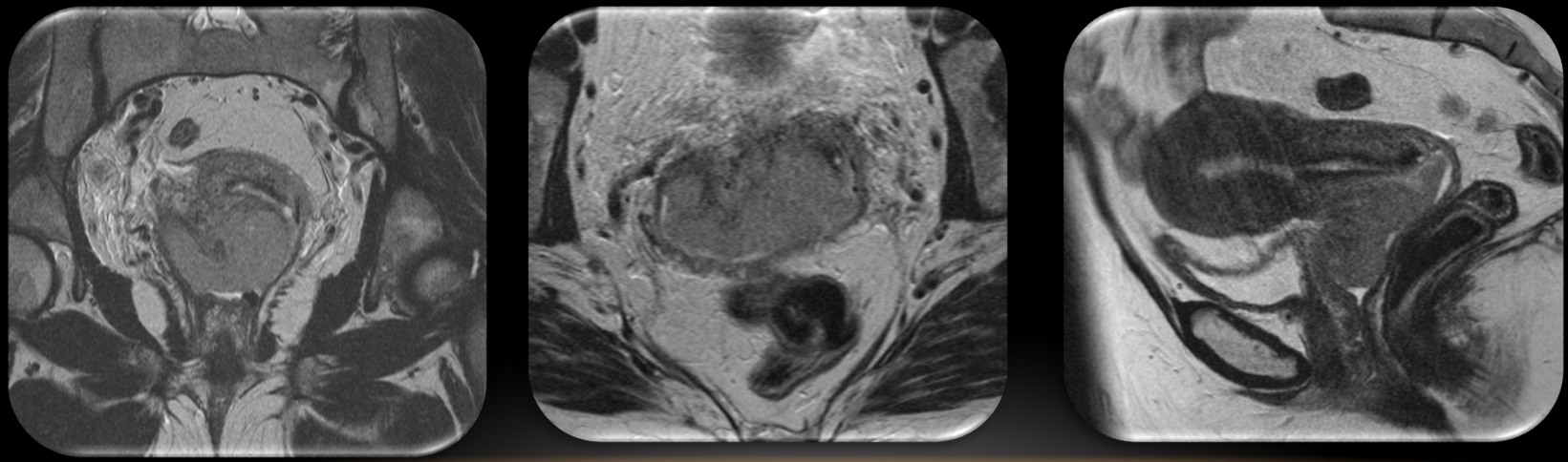

STAGE IIB DISEASE

- **Deficient stromal ring**
- **Tumour extending into parametrium**

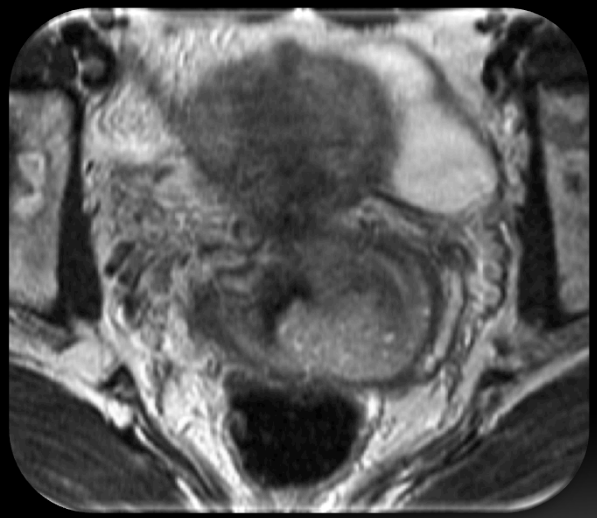

STAGE IIIA – LOWER VAGINA

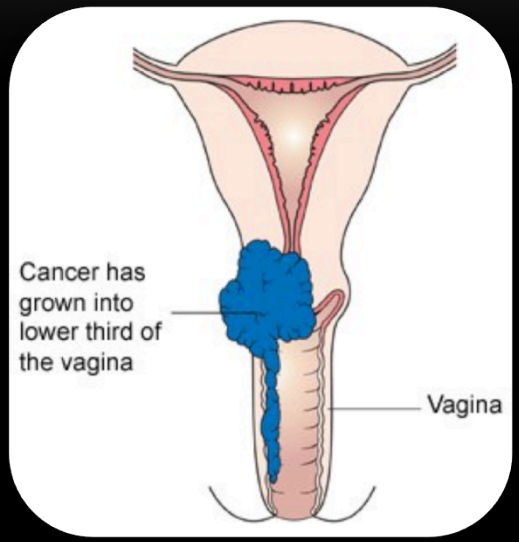

HYDRONEPHROSIS – STAGE IIIB

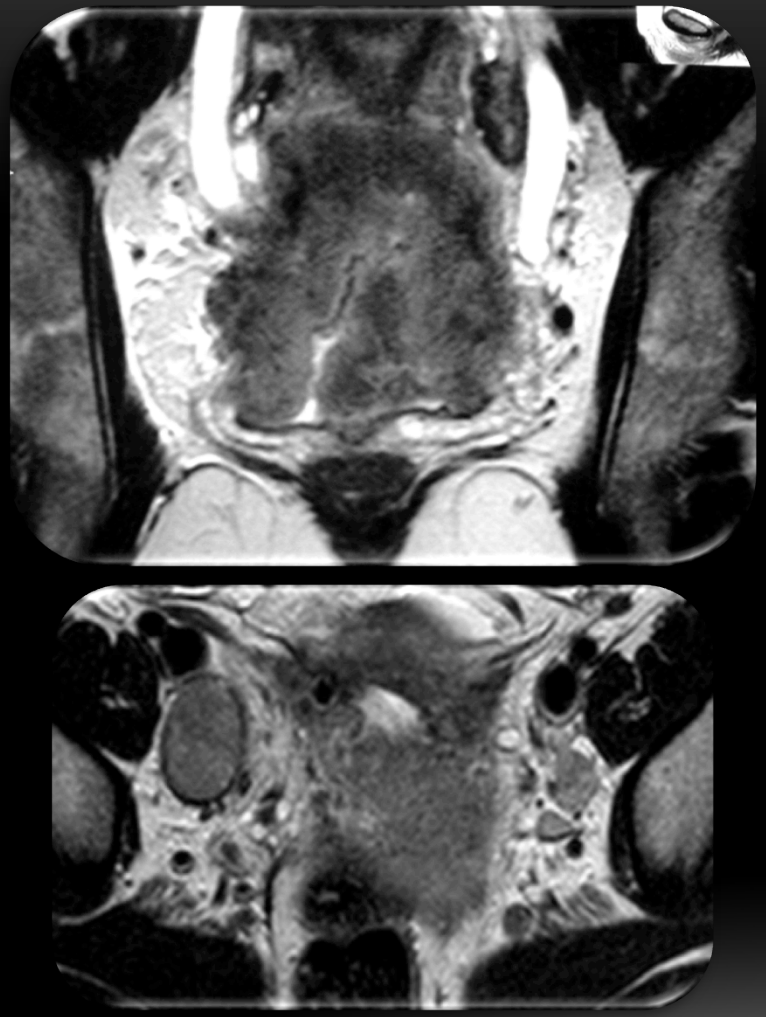

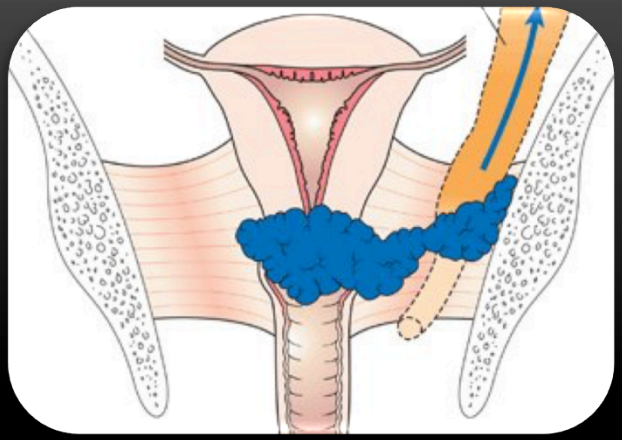

STAGE IV DISEASE

Tumour extending through the bladder wall and mucosa into the lumen

BRACHYTHERAPY – KNOWLEDGE OF ANATOMY ESSENTIAL

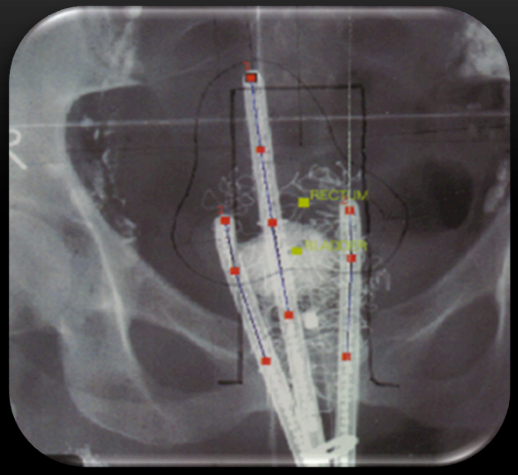

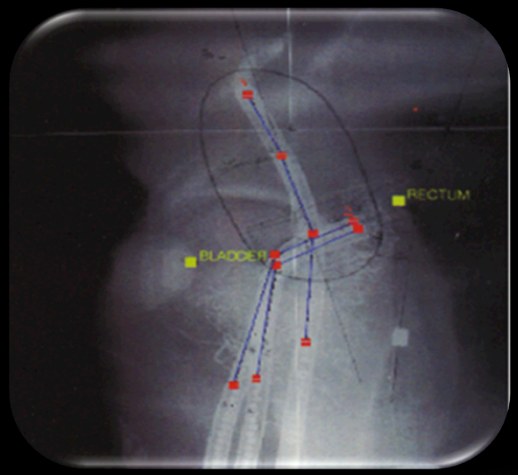

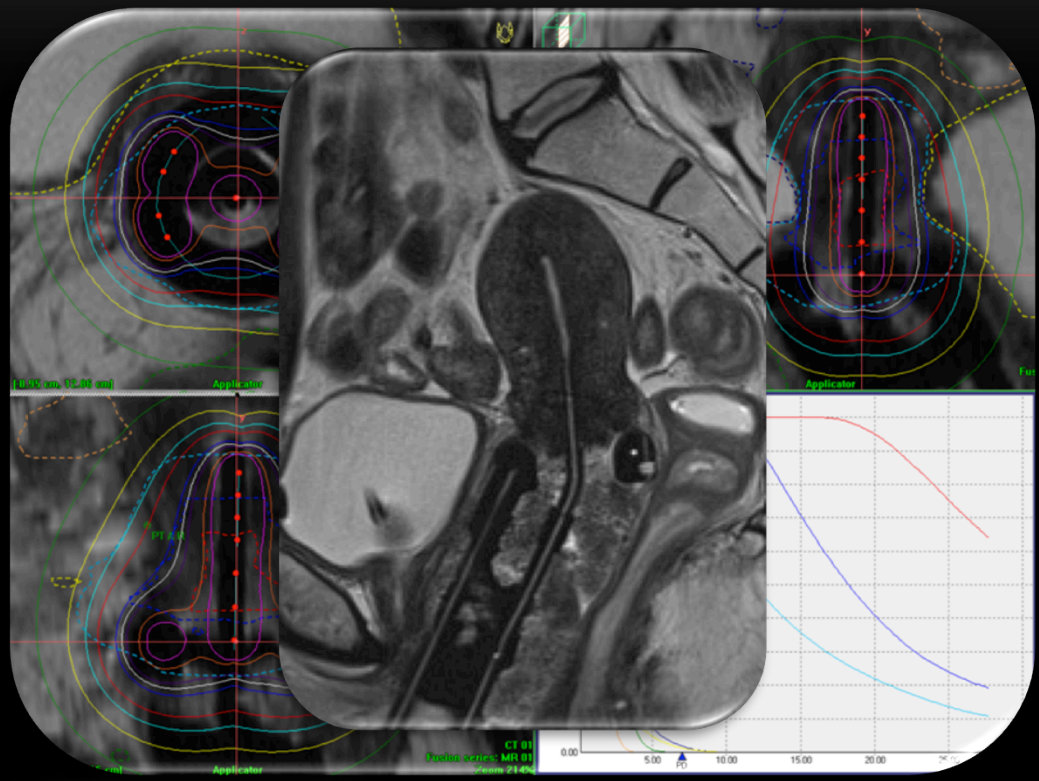

BRACHYTHERAPY : MRI ANATOMY ESSENTIAL

- EMBRACE study
- MRI compatible brachytherapy applicators
- Use MR Imaging for delineation of visible GTV
- ‘High risk’ CTV

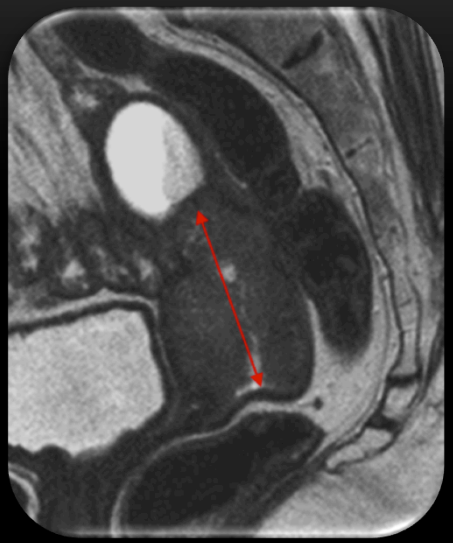

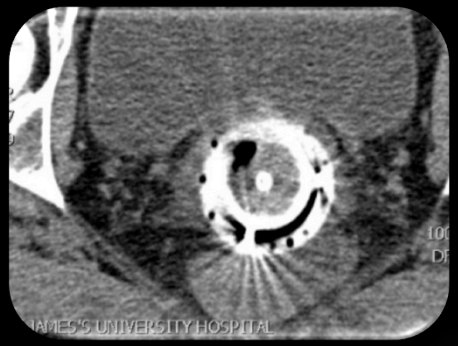

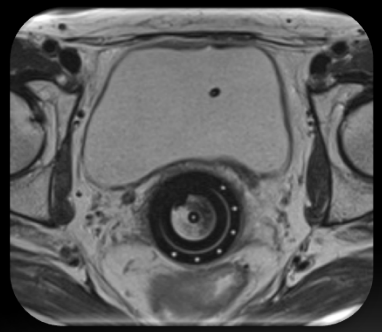

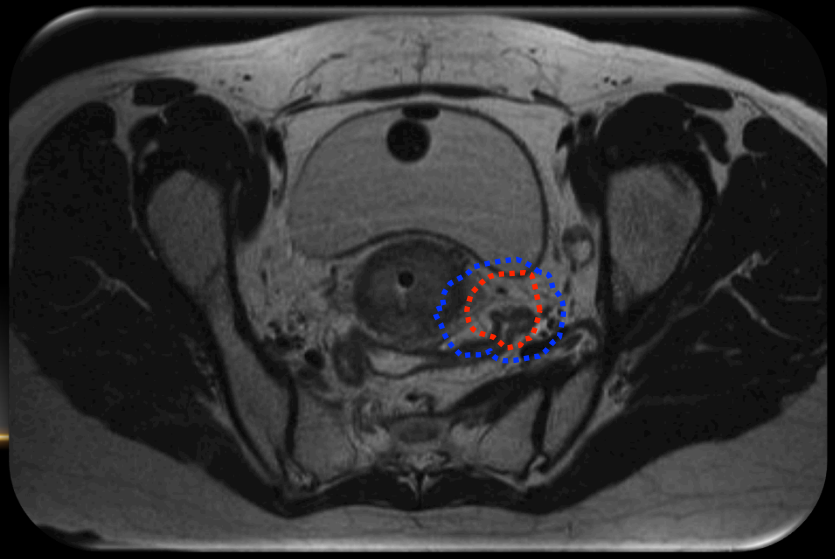

INTERSTITIAL NEEDLES ; CORRELATE CT AND MRI ANATOMY

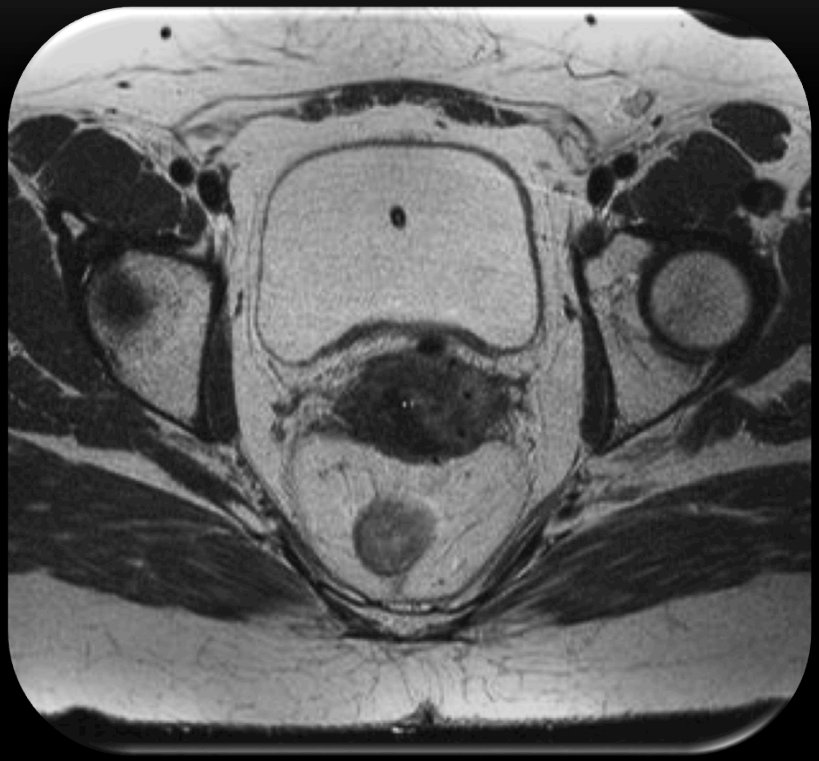

ANATOMY OF TUMOUR SPREAD : ENDOMETRIAL CANCER

- Endometrial Cancer spreads by direct infiltration or via lymphatic, transtubal peritoneal seeding or hematogenous routes.
- The location of lymph nodes metastases reflects the portion of the uterus involved by the cancer.
- The parametrial, paracervical, and the obturator lymph nodes are involved when the cancer affects the middle and lower third of the uterus. The common iliac and obturator lymph nodes are involved when the tumour is located in the upper corpus or fundus of the uterus.

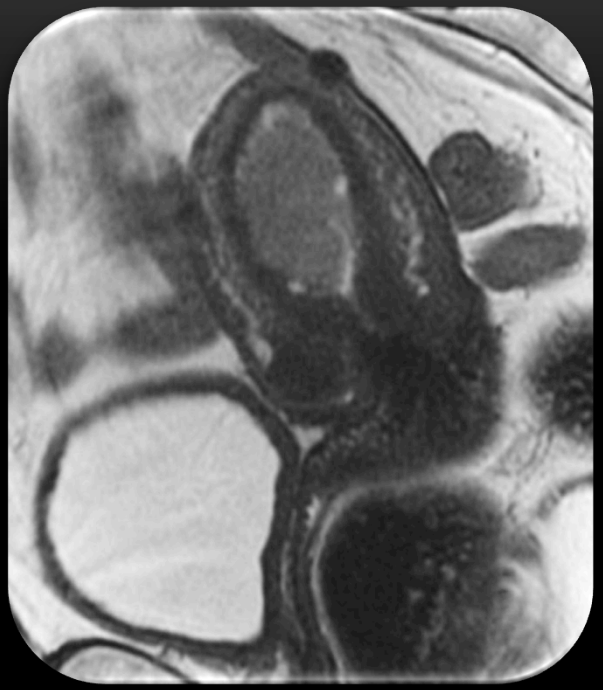

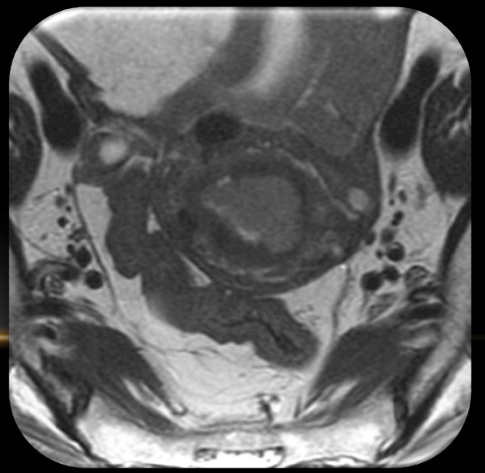

ENDOMETRIAL CANCER LOOK ON MRI

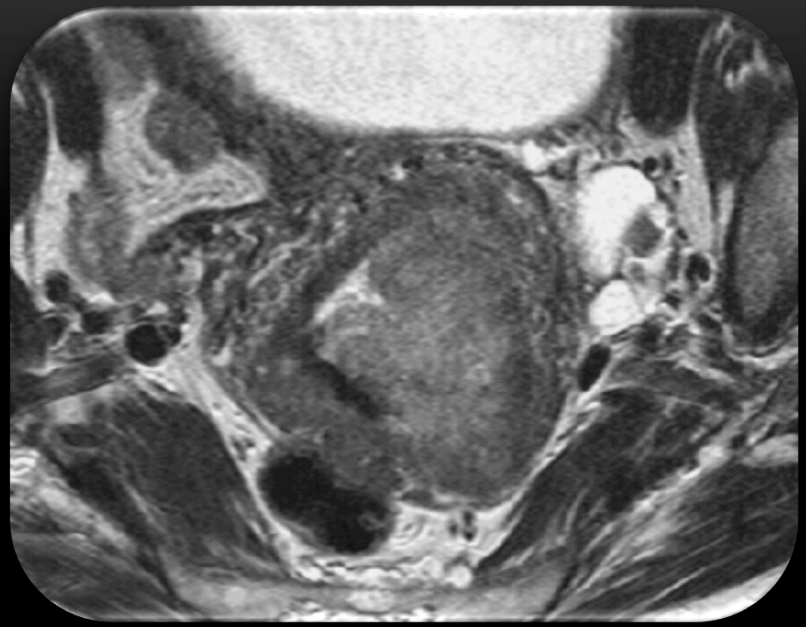

- Bland intermediate signal intensity material within the endometrial cavity
- Disruption of the low SI junctional zone used to diagnose invasive disease

INVOLVEMENT OF THE CERVIX

- ? More radical surgical approach
- Adjuvant RT

- Reported accuracy of MRI in detecting cervical invasion – up to 92%
- Sensitivities of 75 – 80%
- 94 – 96%

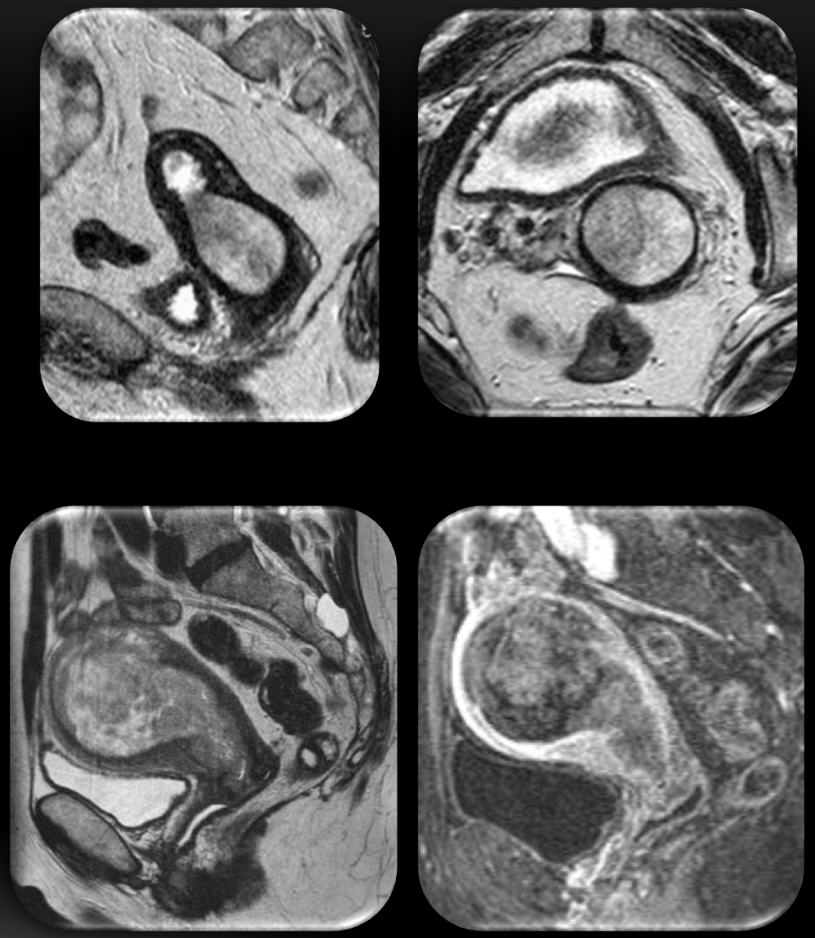

Ovaries….

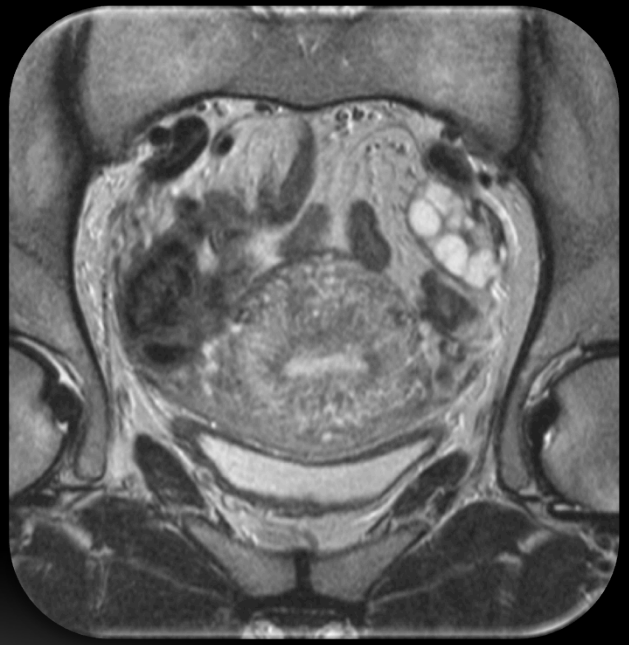

Do not confuse with Lymph Nodes

PELVIC NODES FOLLOW VESSELS

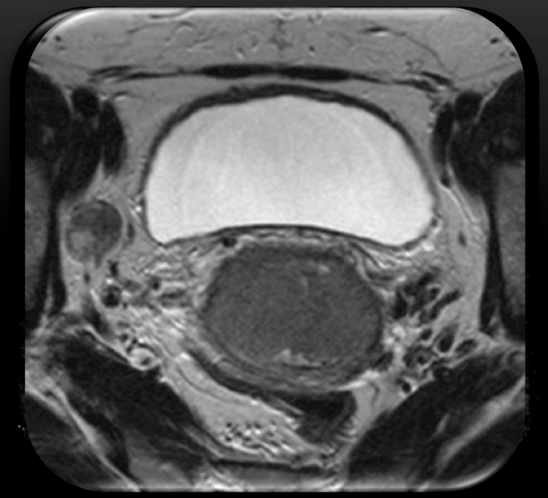

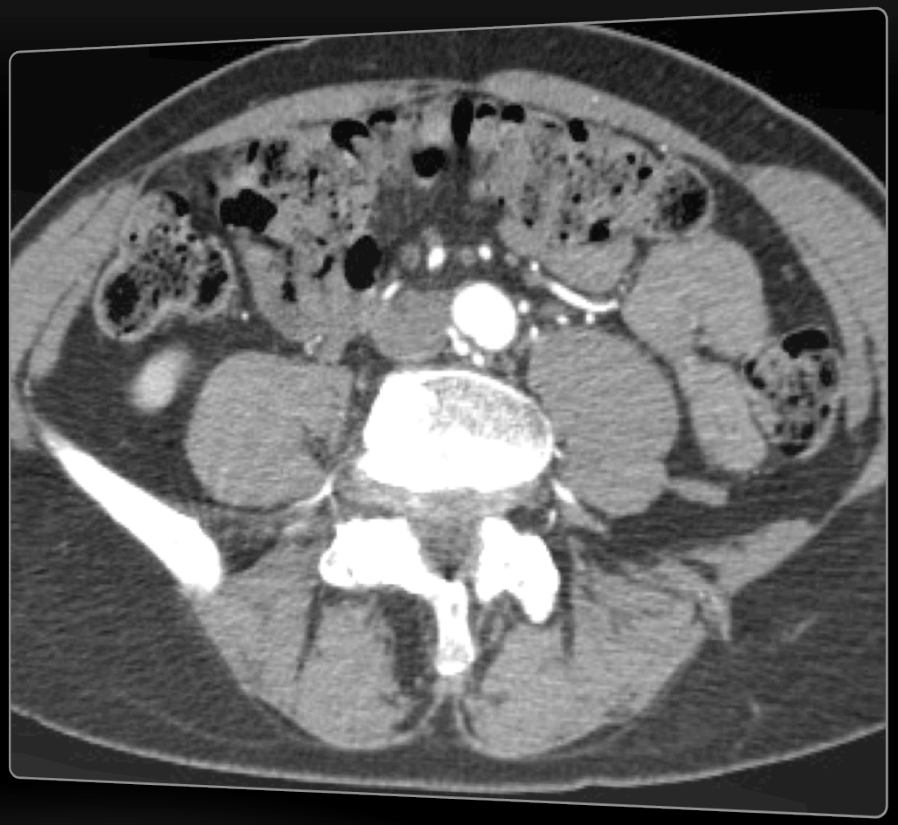

NODAL DISEASE : ANATOMY

Within the pelvis, cervical cancer spreads first to parametrial nodes, then to obturator, internal and external iliac nodes. In more advanced disease, common iliac and para-aortic nodes may be involved.

Although not incorporated in the FIGO staging system, presence of lymph node metastases has significant prognostic and treatment consequences. The 5-year survival for node positive patients is 39-54% compared with 67-92% in patients without nodal involvement .

In early stage tumour, involvement of any node is important as it excludes curative surgery changing the treatment to either chemoradiotherapy alone, or debulking surgery and neo-adjuvant chemoradiotherapy.

In advanced tumours, detection of para-aortic nodes is important for planning the extent of the radiation field.

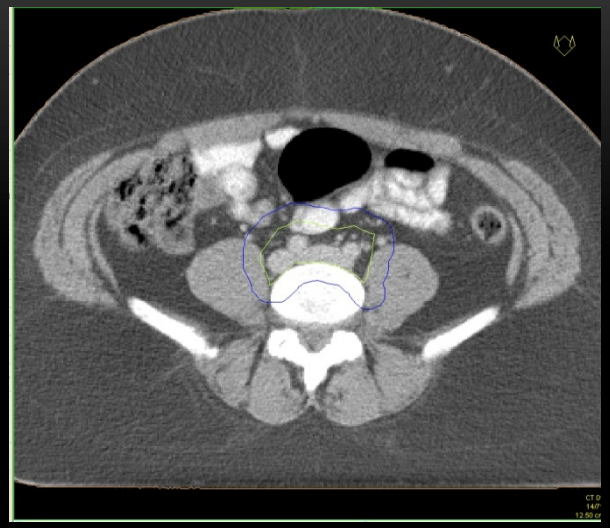

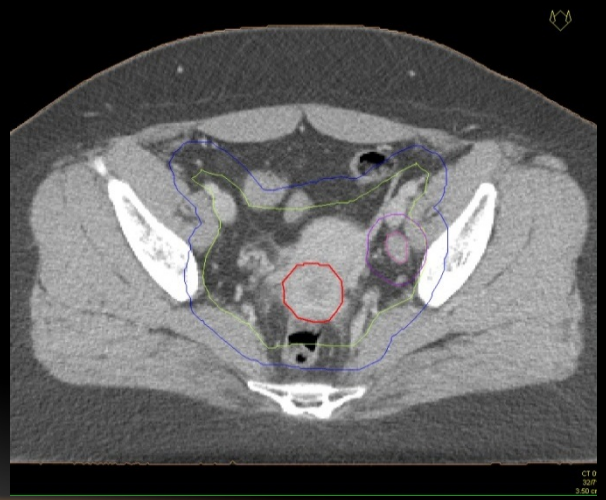

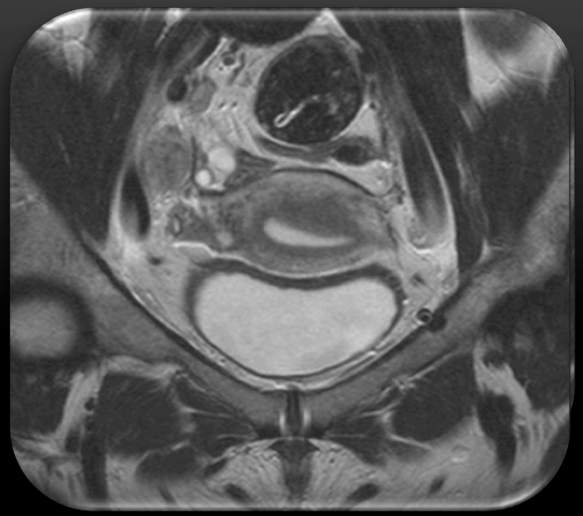

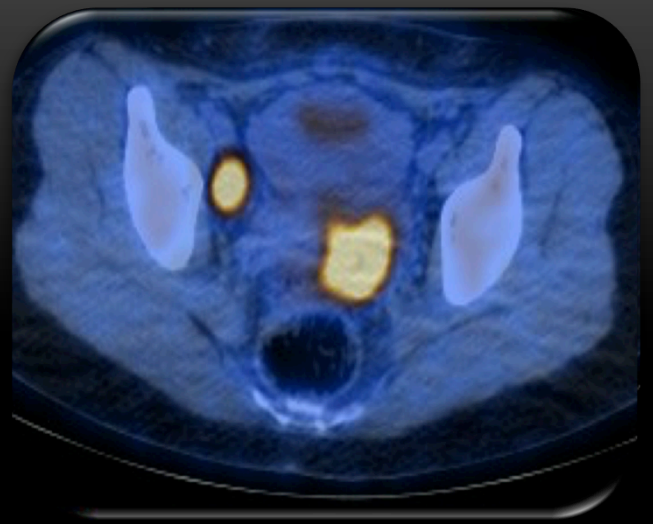

- Limitations to nodal assessment with all imaging techniques
- Size criteria (>9mm probably metastatic)
- Consistency and outline
- Inability to identify metastatic disease in normal sized nodes

ABNORMAL NODES?

- **Size – they get bigger**
- **Shape – they become rounded**
- **They form confluent masses**
- **Then they obstruct structures**

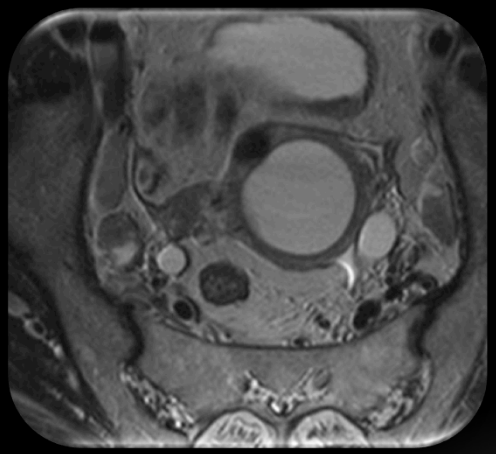

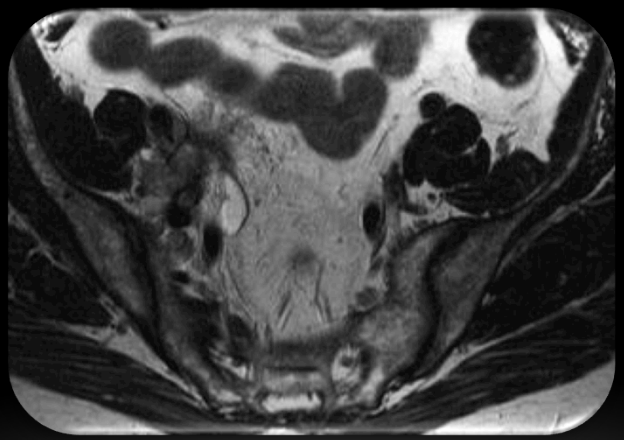

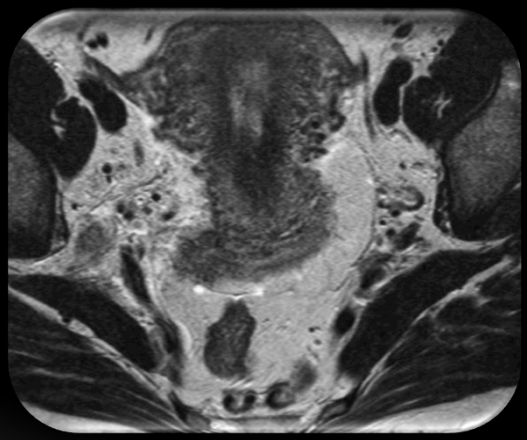

EXTERNAL ILIAC NODES – 3 CHAINS

- **Lateral chain – lateral aspect of the artery**
- **Middle chain – anterior and medial to the vein**
- **Medial chain – posterior to the vein against the pelvic side wall**

OBTURATOR NODES

- Considered part of the medial external iliac nodal group
- They lie in the obturator fossa along the pelvic side wall

COMMON ILIAC NODES

- Common iliac nodes are located lateral and posterior to the vessels
- They may lie some distance away from the vascular pedicle

COMMON ILIAC NODES

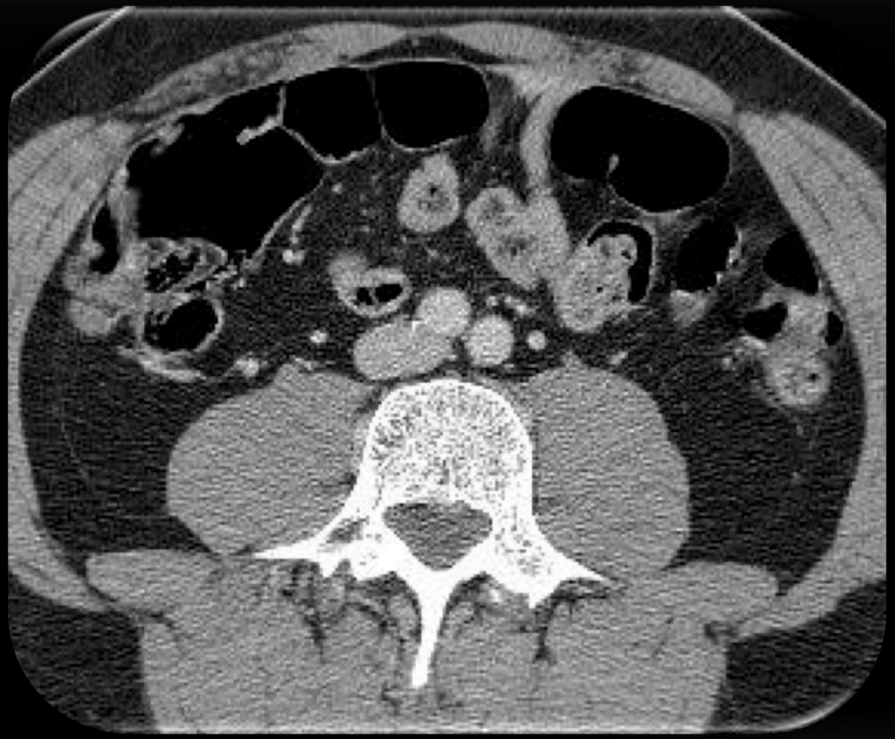

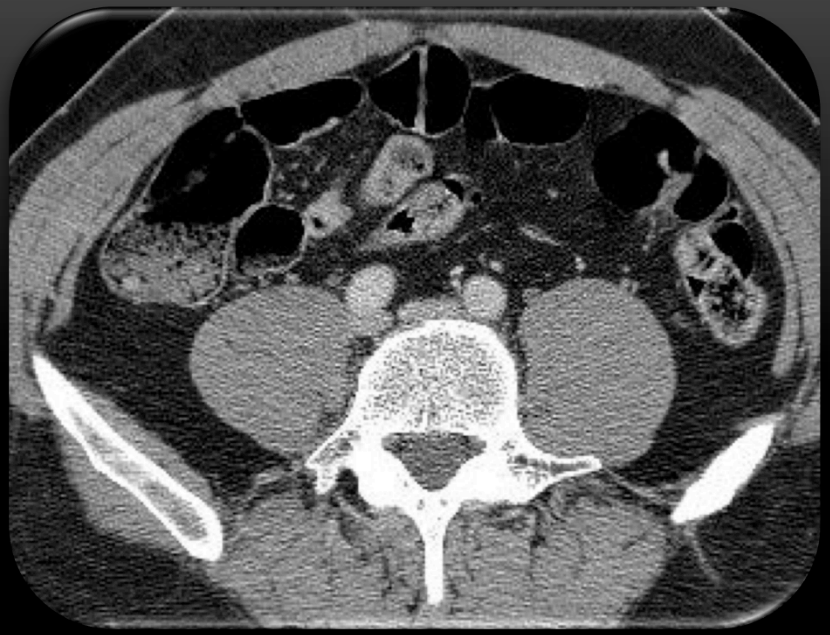

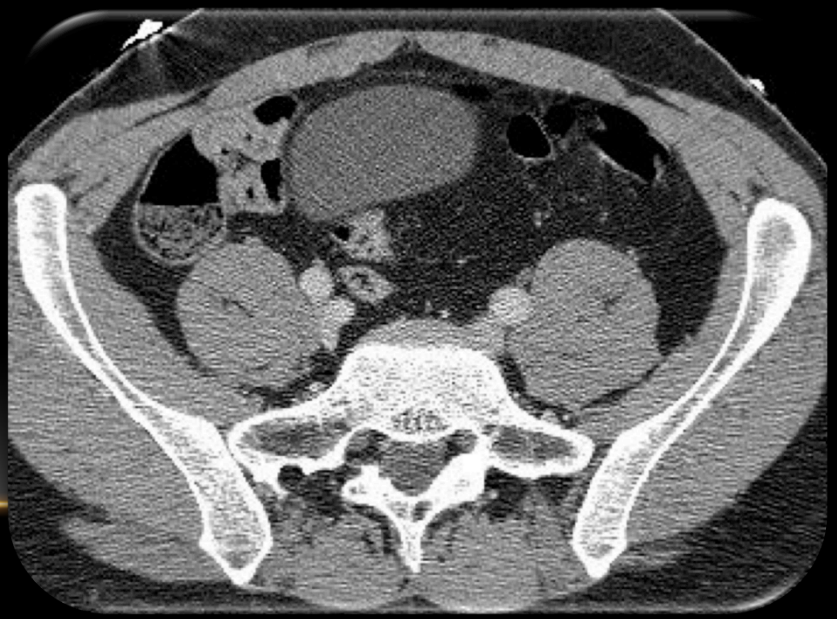



Summary…..

Have a Rest !!

TVD for cervical cancer: primary setting

Target volume : defined by “risk of relapse”

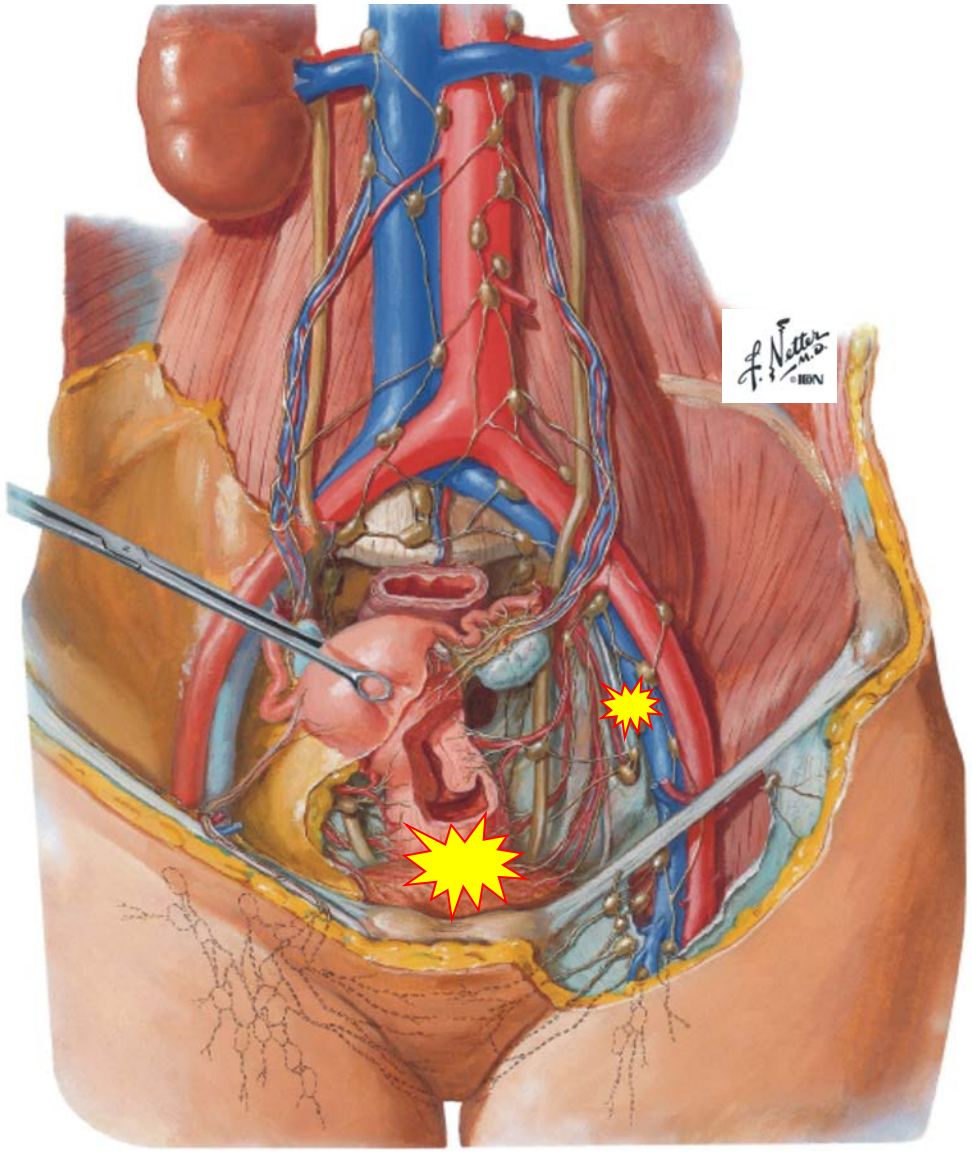

Interactive atlas of human anatomy

Target volume : defined by “risk of relapse”

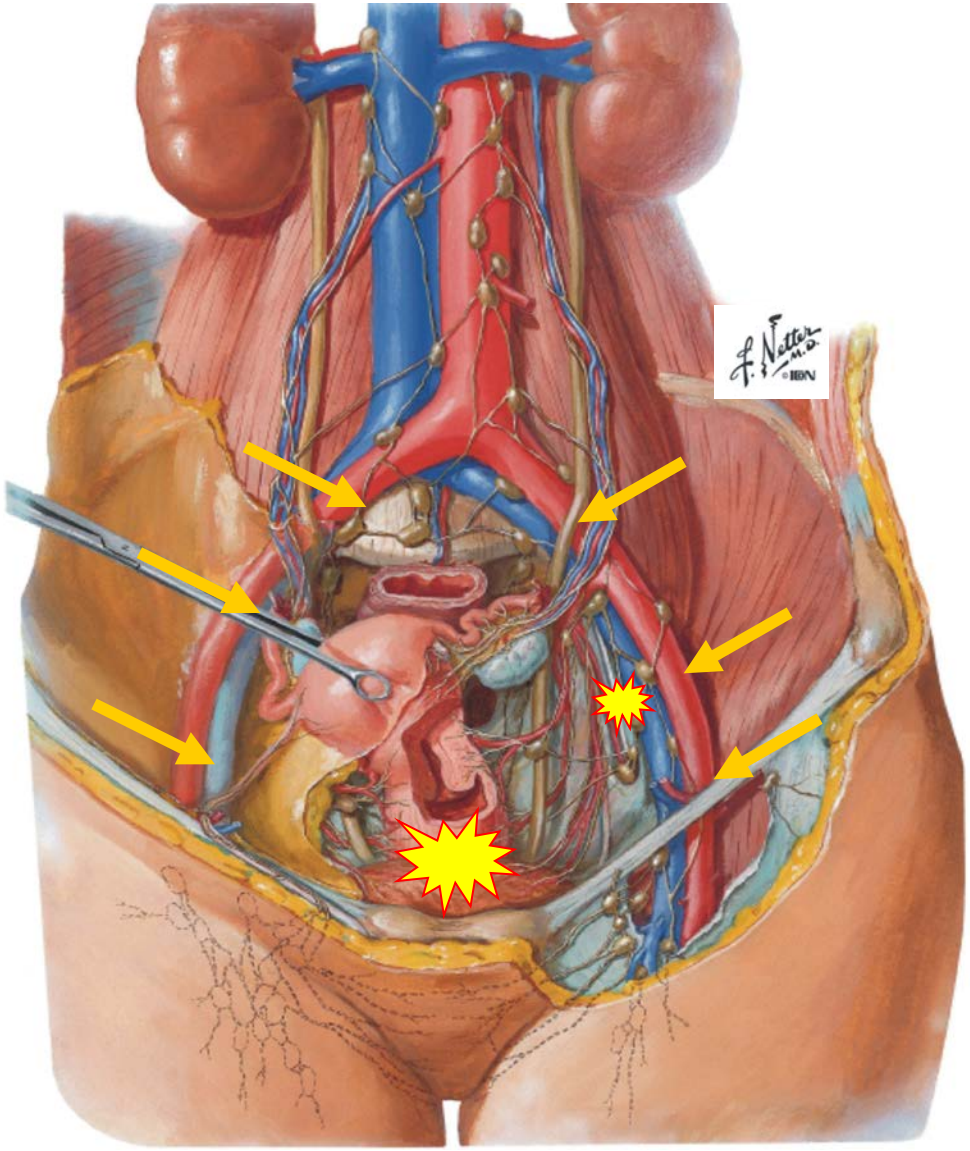

Interactive atlas of human anatomy

Gross tumor volume

Correct TVD starts with **optimal** imaging

combine morphological and biological imaging

Correct TVD starts with **optimal** imaging

combine morphological and biological imaging

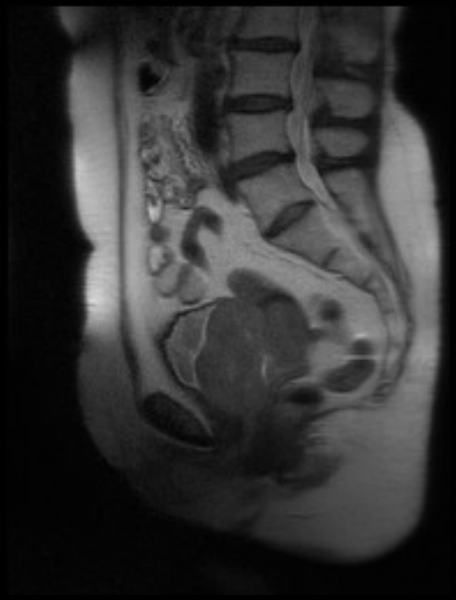

T2w MRI
- T-staging

Correct TVD starts with **optimal** imaging

combine morphological and biological imaging

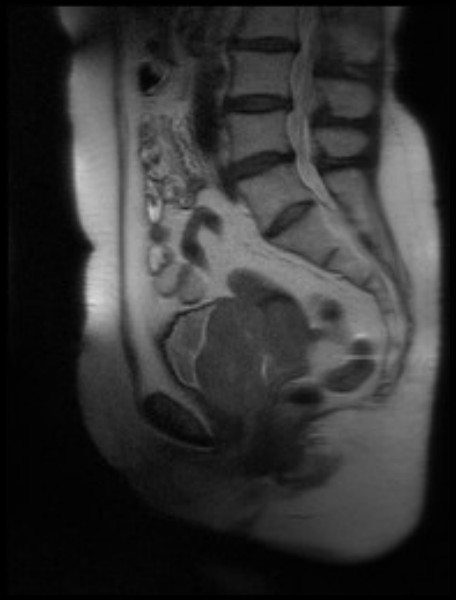

T2w MRI
- T-staging

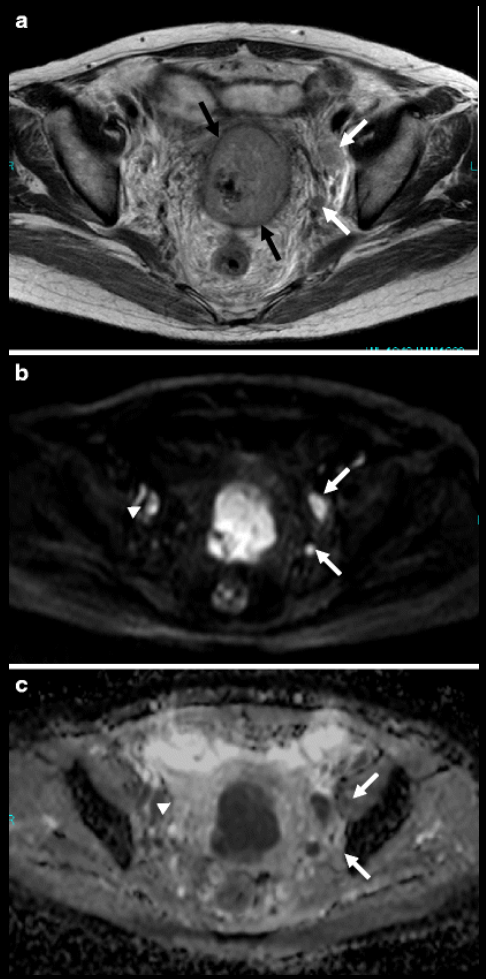

DWI MRI
- T & N-staging

Correct TVD starts with **optimal** imaging

combine morphological and biological imaging

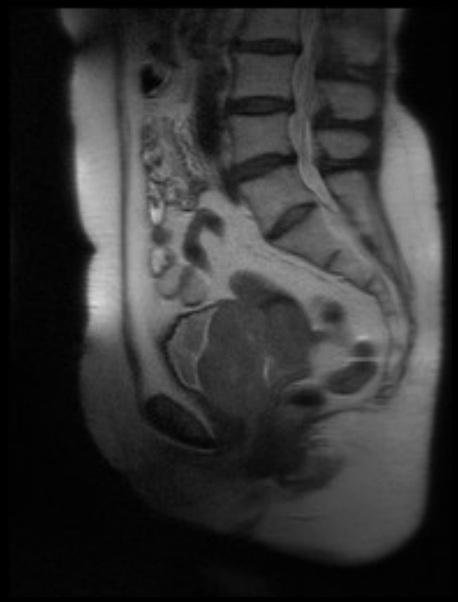

T2w MRI
- T-staging

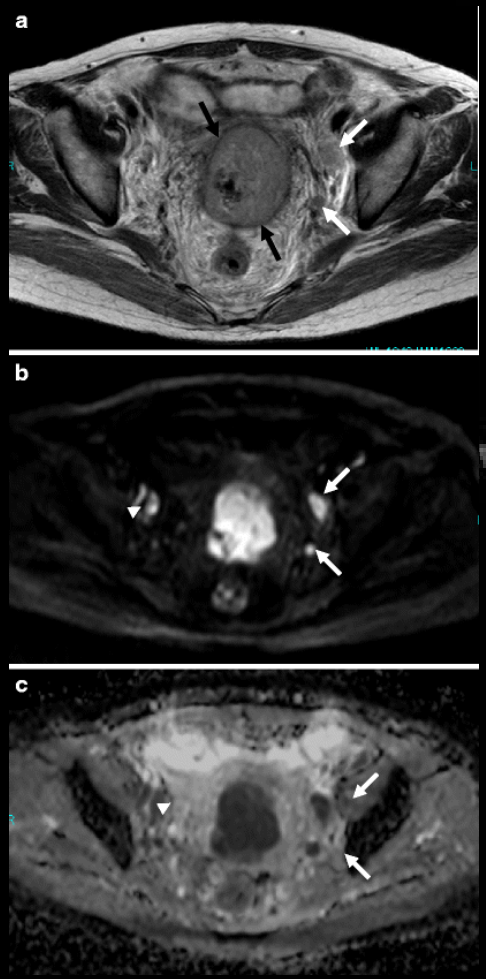

DWI MRI
- T & N-staging

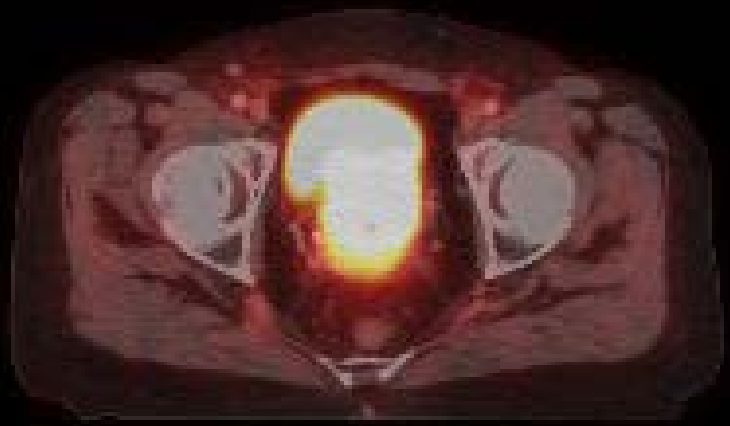

18 FDG PET-CT:
- Primary tumor
- Lymph nodes
  - high sensitivity
  - high specificity

Magnetic resonance: recommendations from GEC-ESTRO

Spasmolytic agent (IV / IM)

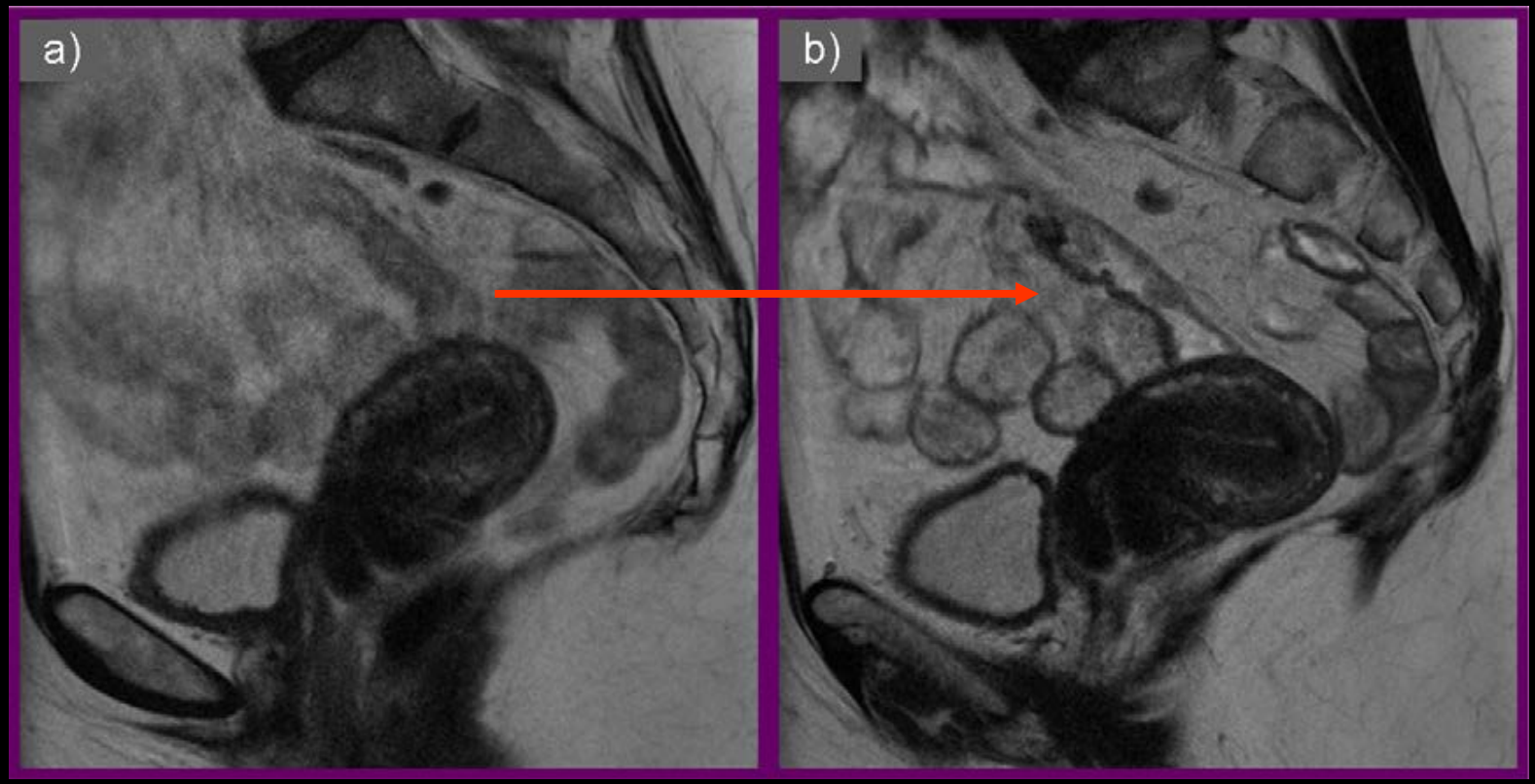

Importance of field strength

1.5 Tesla

0.2 Tesla

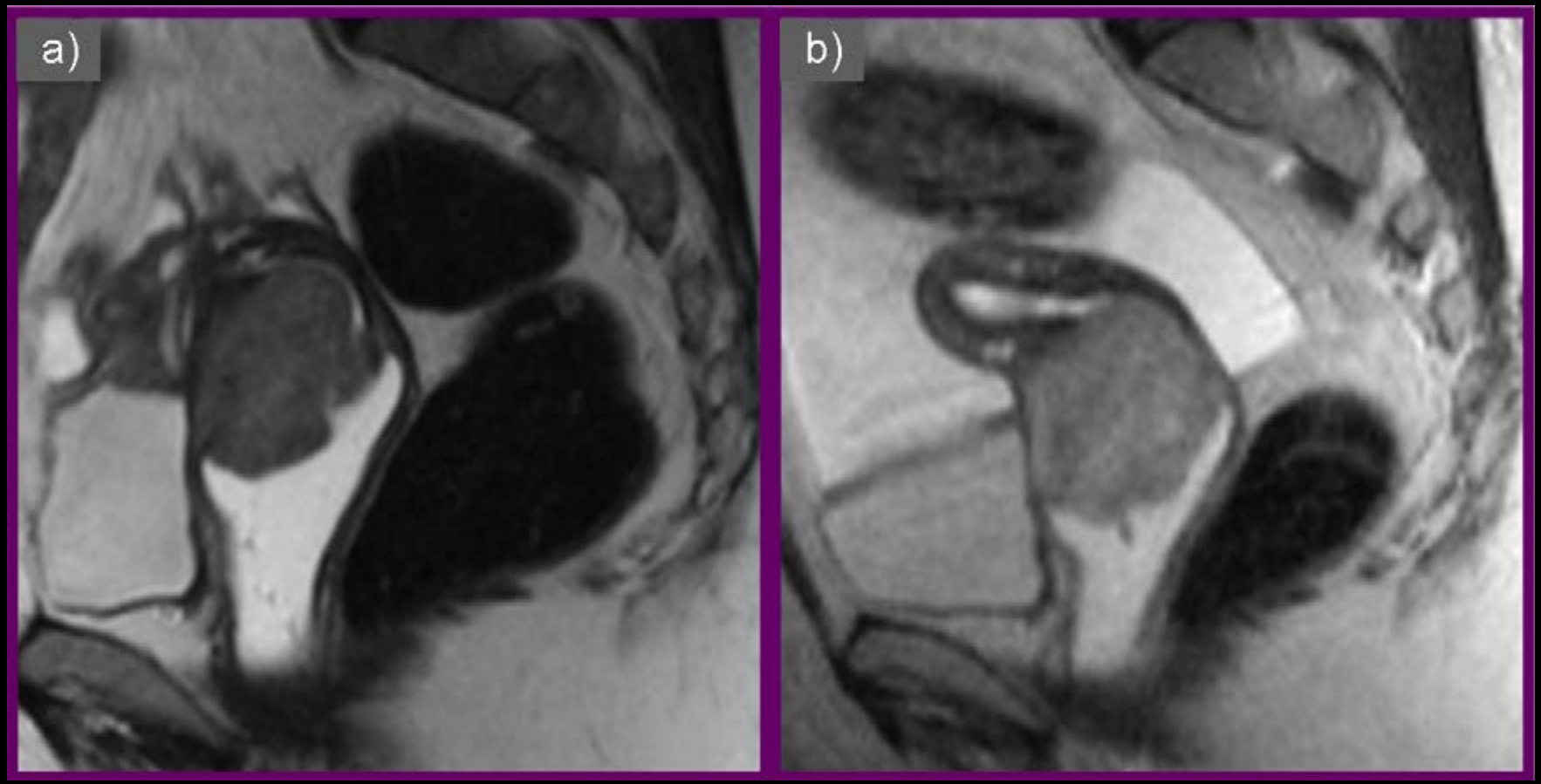

Correct TVD starts with **optimal** imaging

combine morphological and biological imaging

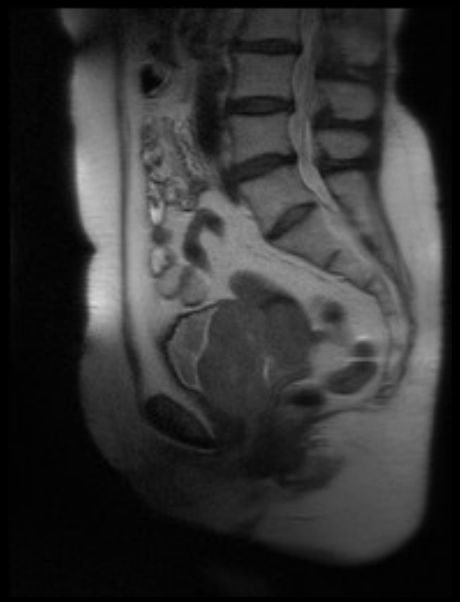

T2w MRI
- T-staging

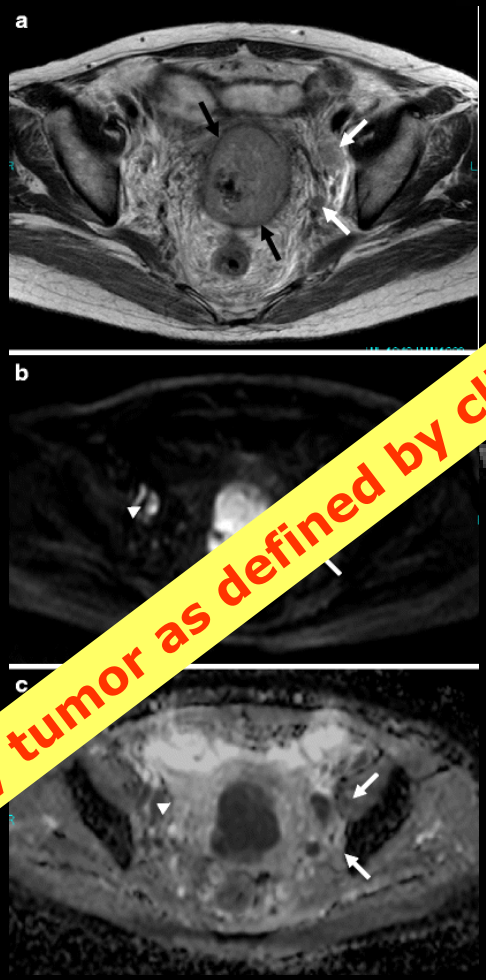

DWI MRI
- T & N-staging

18 FDG PET-CT:
- Primary tumor
- Lymph nodes
  - high sensitivity
  - high specificity

GTV: primary tumor as defined by clinical examination and imaging

Clinical target volume

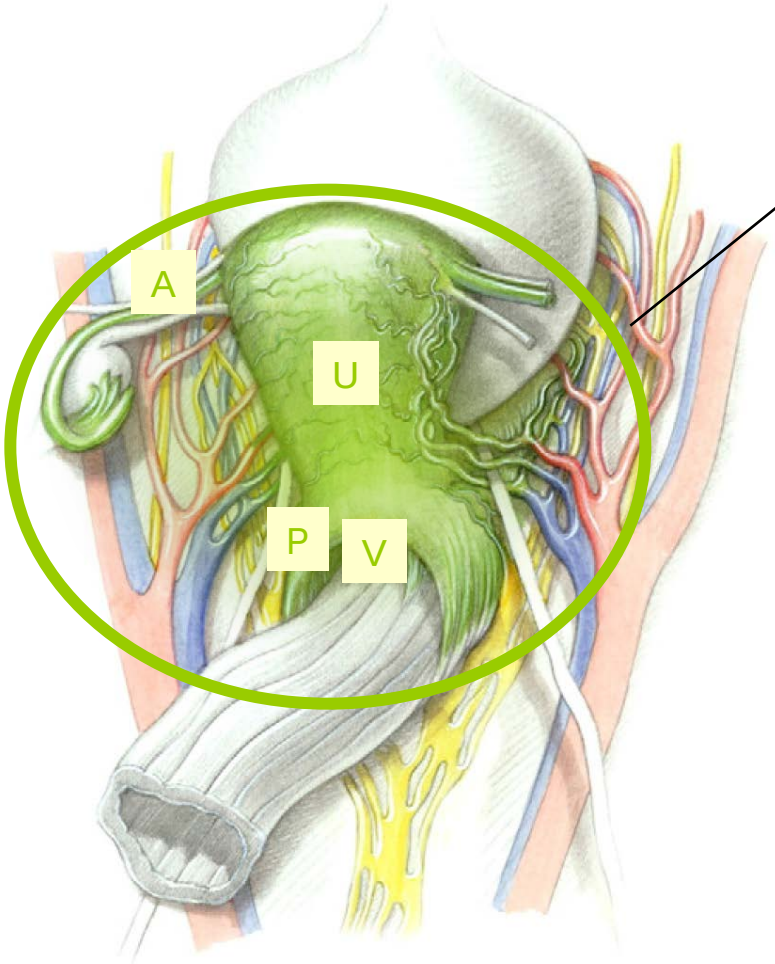

Uterovaginal compartiment

Product of differentiation of the Müllerian canal

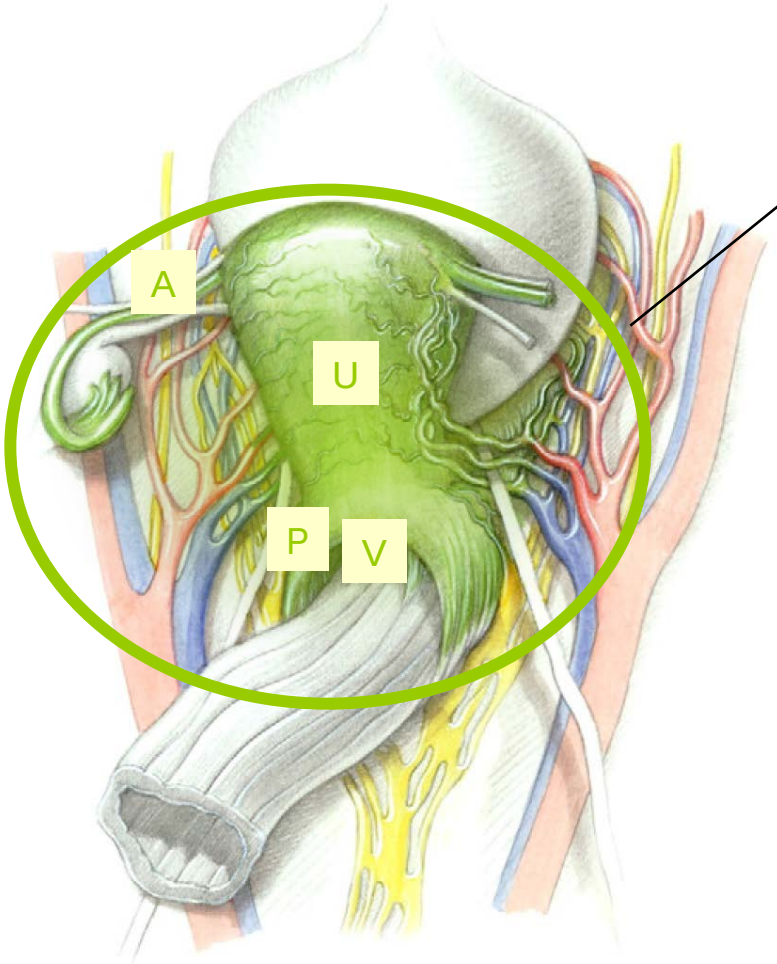

Uterovaginal compartiment

Product of differentiation of the Müllerian canal

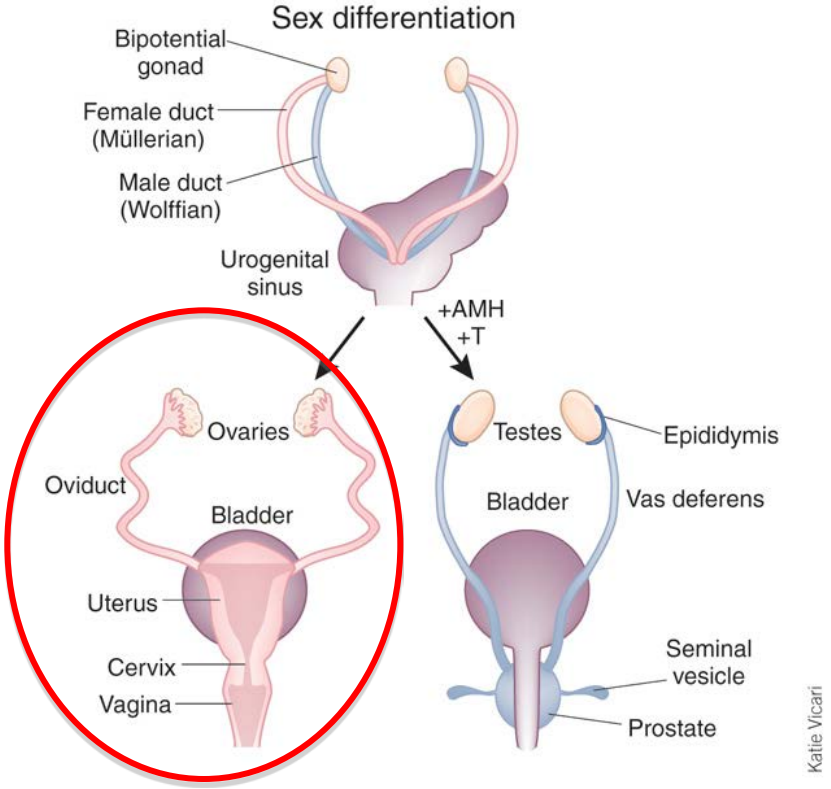

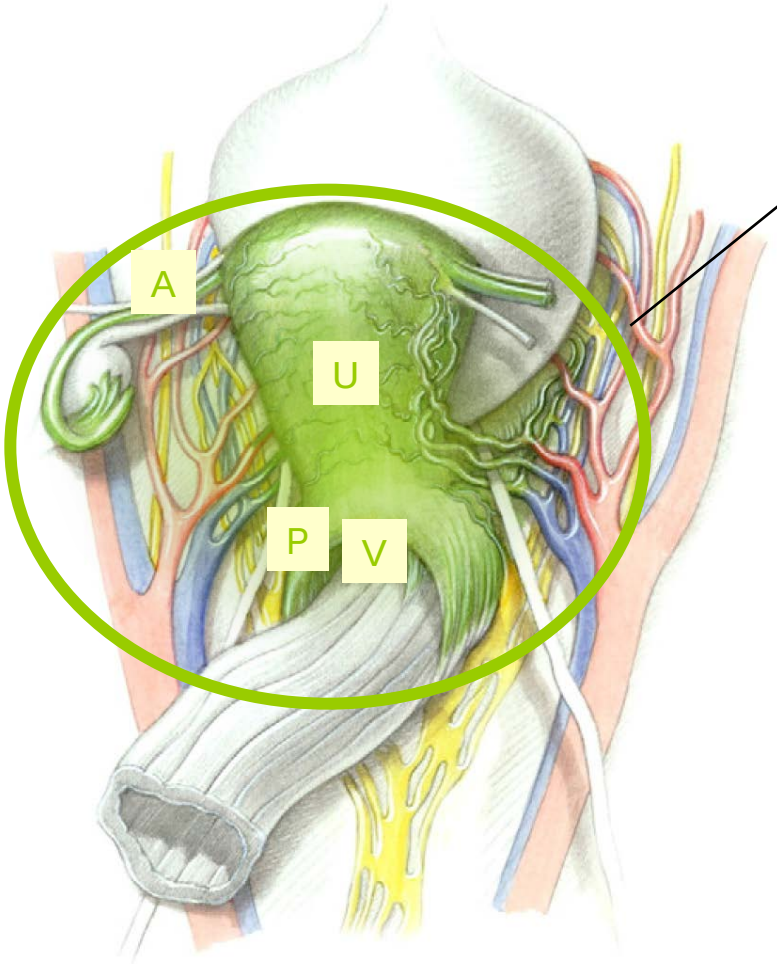

Uterovaginal compartiment

Product of differentiation of the Müllerian canal

+ GTV

CTV

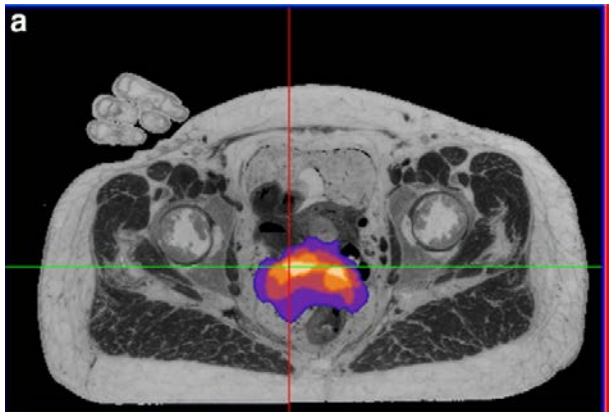

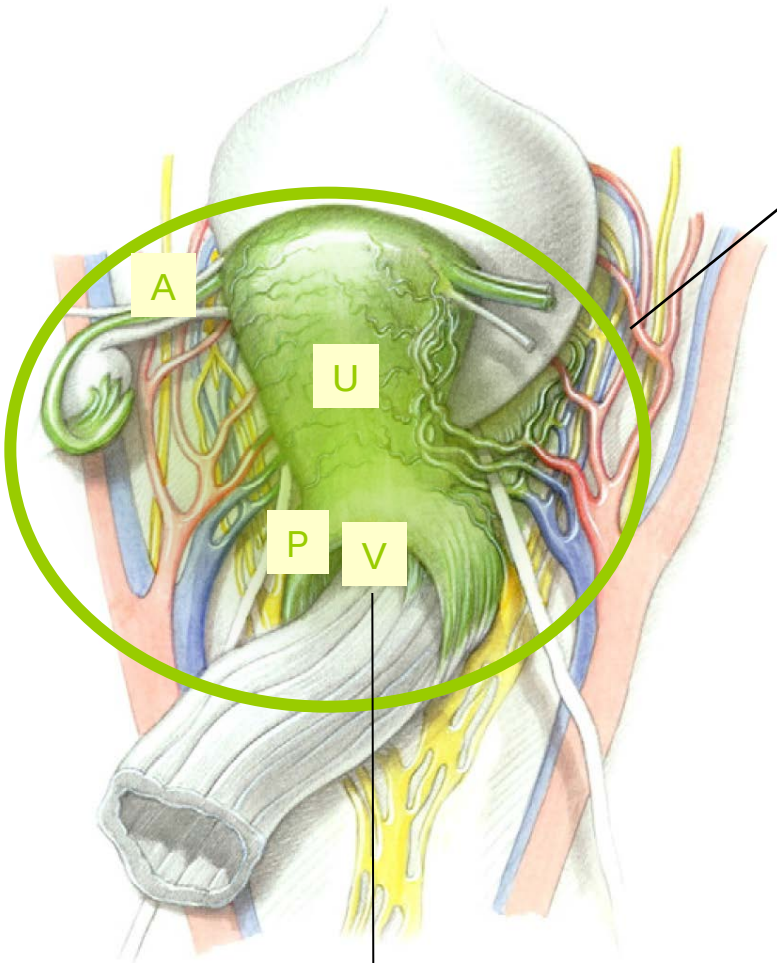

Upper 1/3 when no macro invasion

if macro invasion: + 2 cm

Uterovaginal compartiment

Product of differentiation of the Müllerian canal

+ GTV

CTV

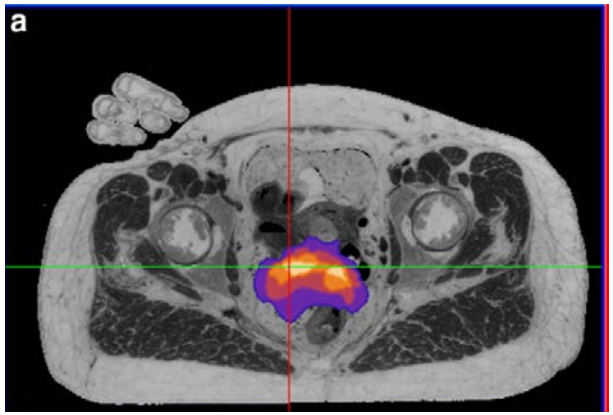

Pelvic lymph nodes delineation

CTV definition-lymph nodes

MAPPING PELVIC LYMPH NODES: GUIDELINES FOR DELINEATION IN INTENSITY-MODULATED RADIOTHERAPY

External-internal iliac nodes | common iliac nodes | Para-aortic nodes

Small W IJROBP 2008

CTV LN delineation
= Vessels + 7 mm

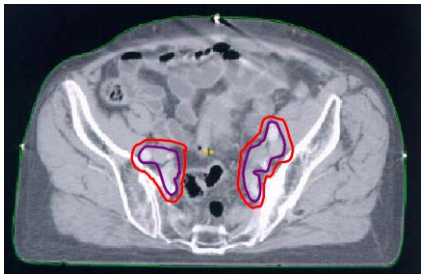

I. Barillot

Target volume delineation

(stage IIIA)

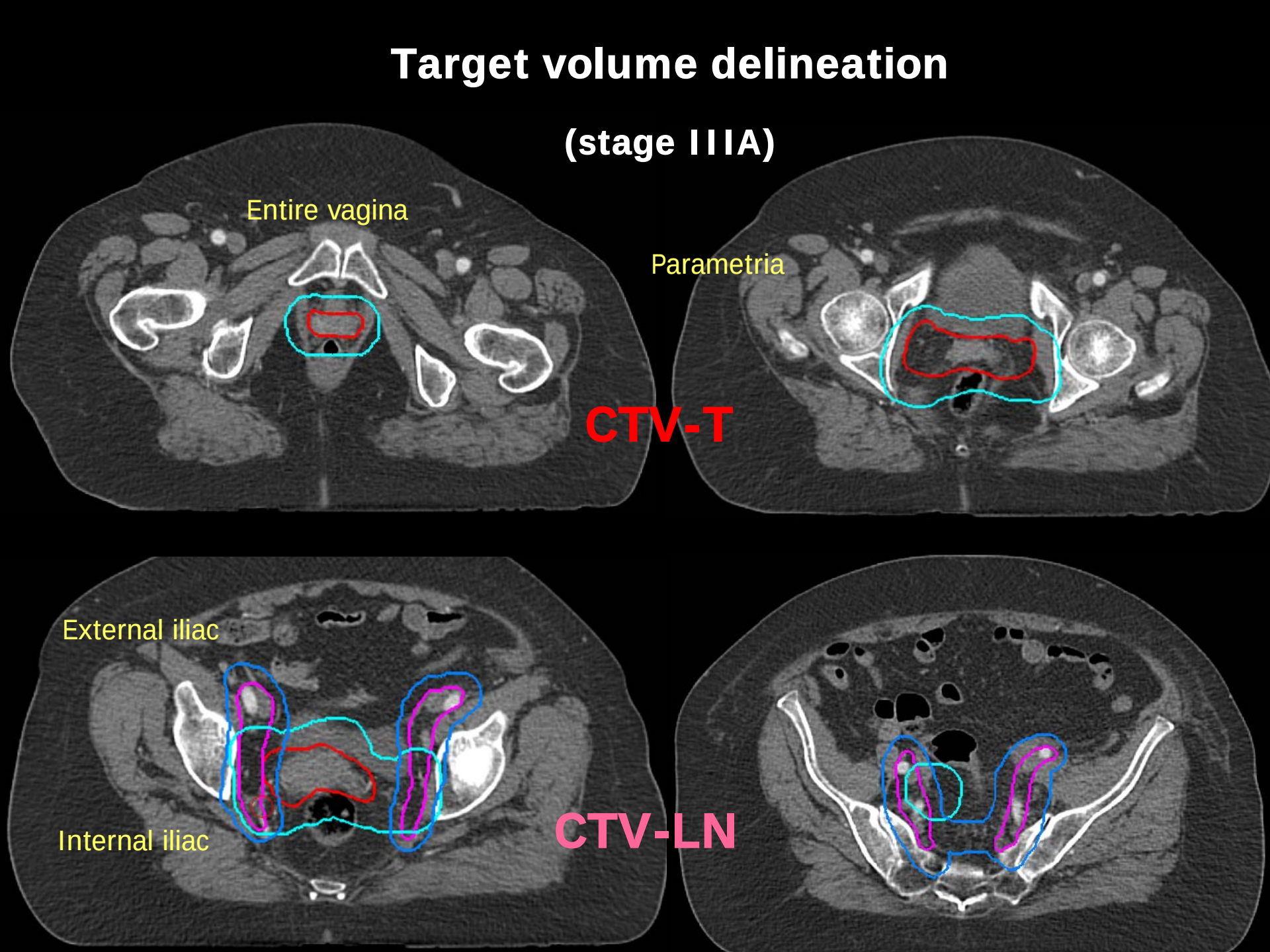

Major issue: healthy tissue

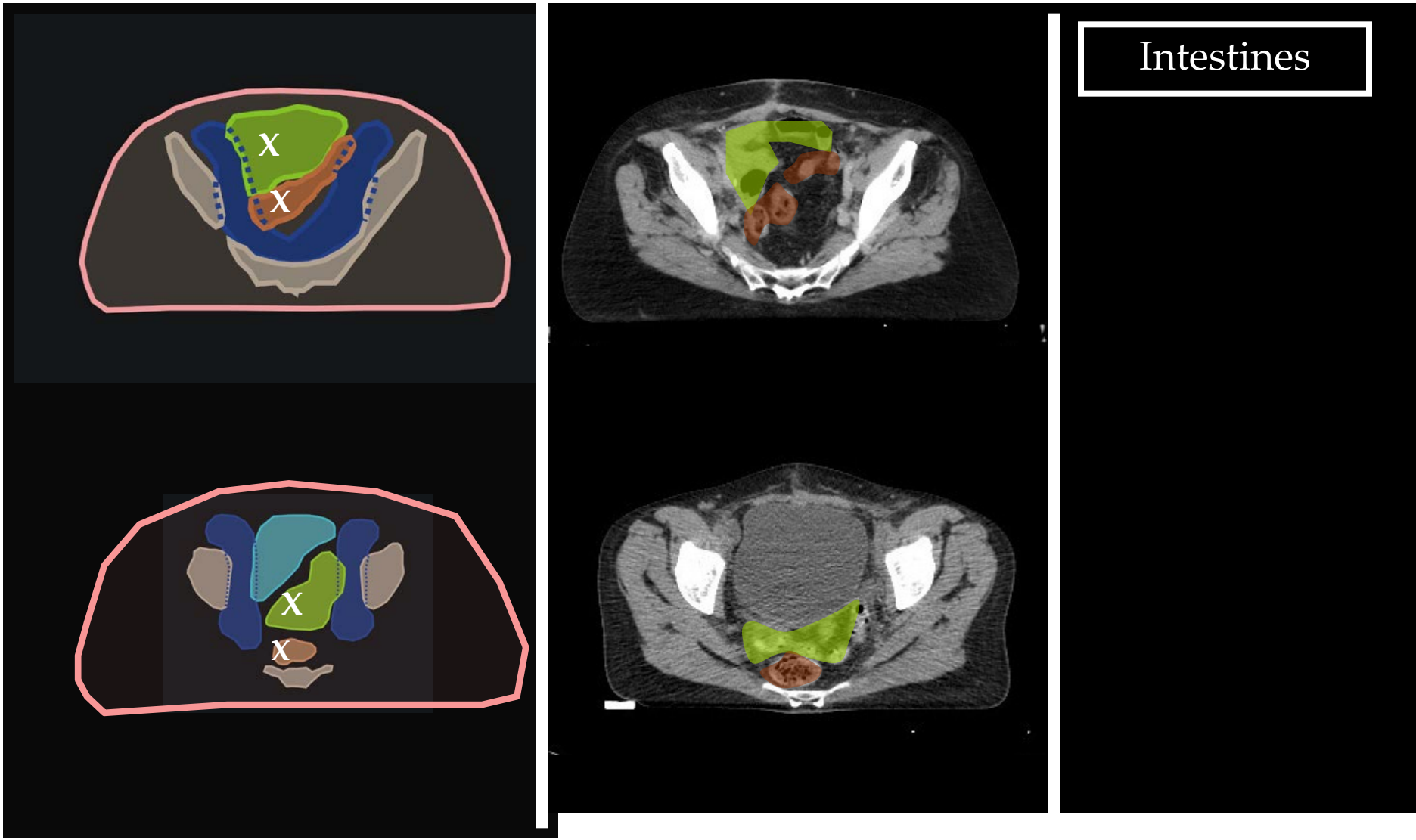

Major issue: healthy tissue

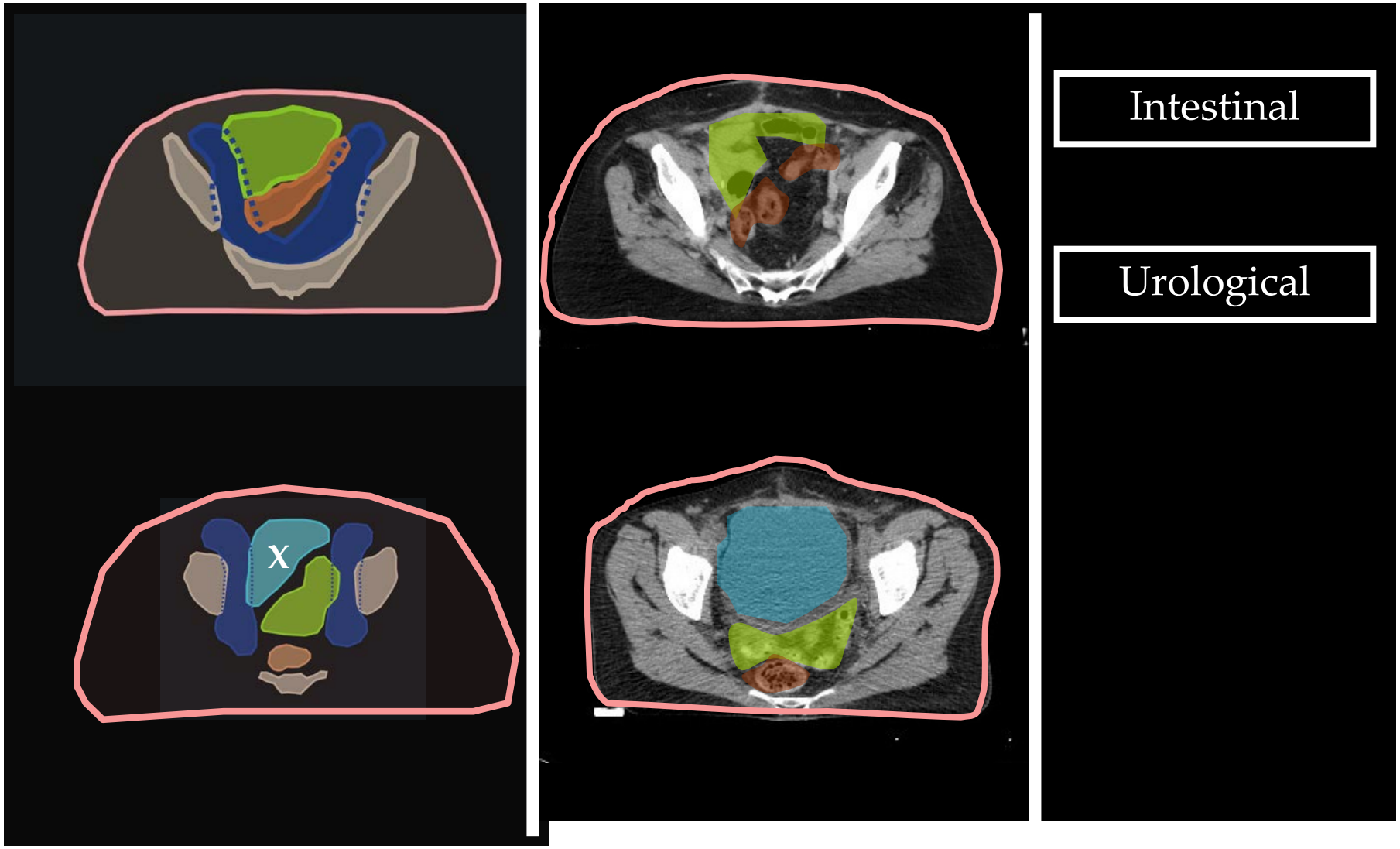

Major issue: healthy tissue

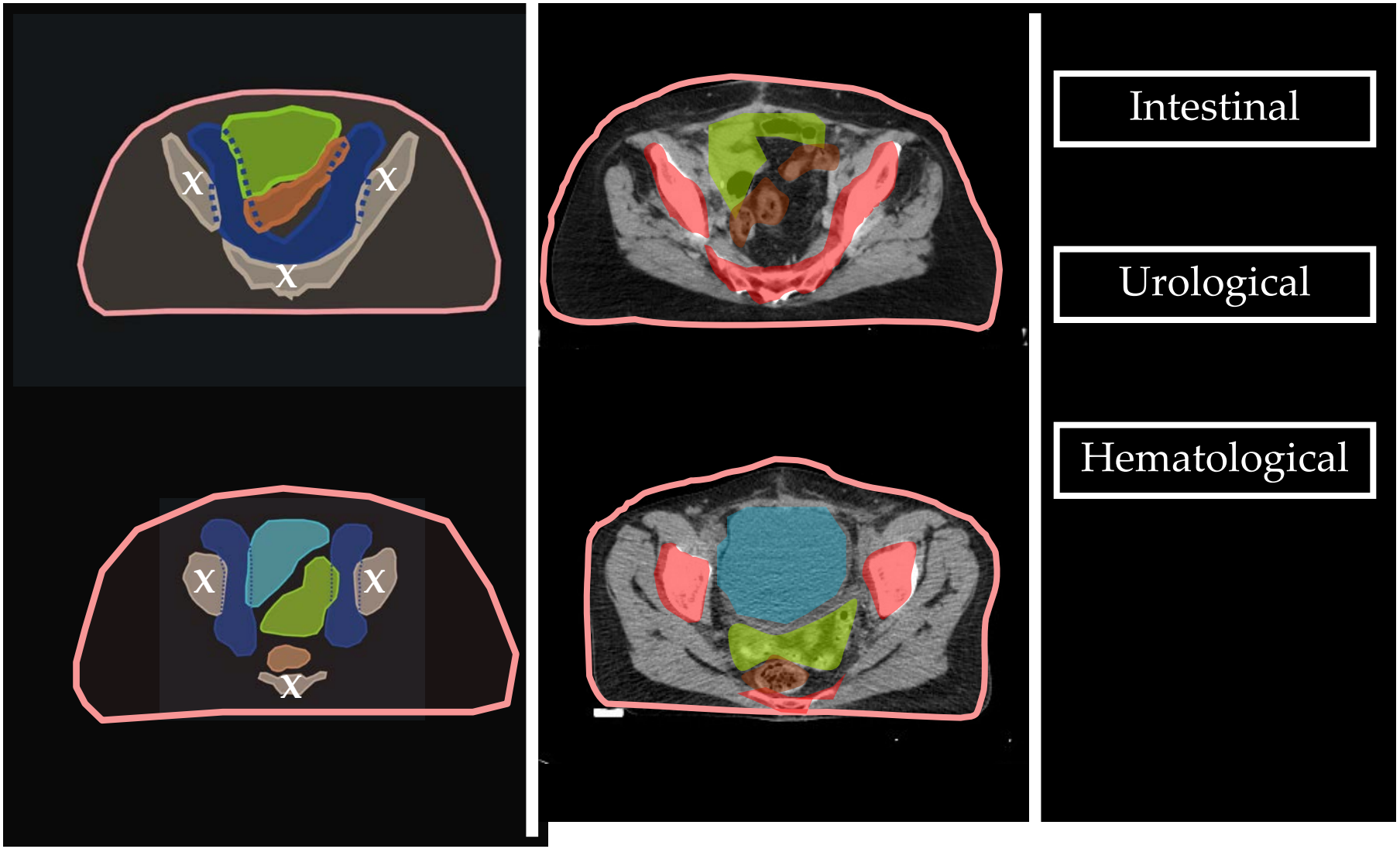

Major issue: healthy tissue

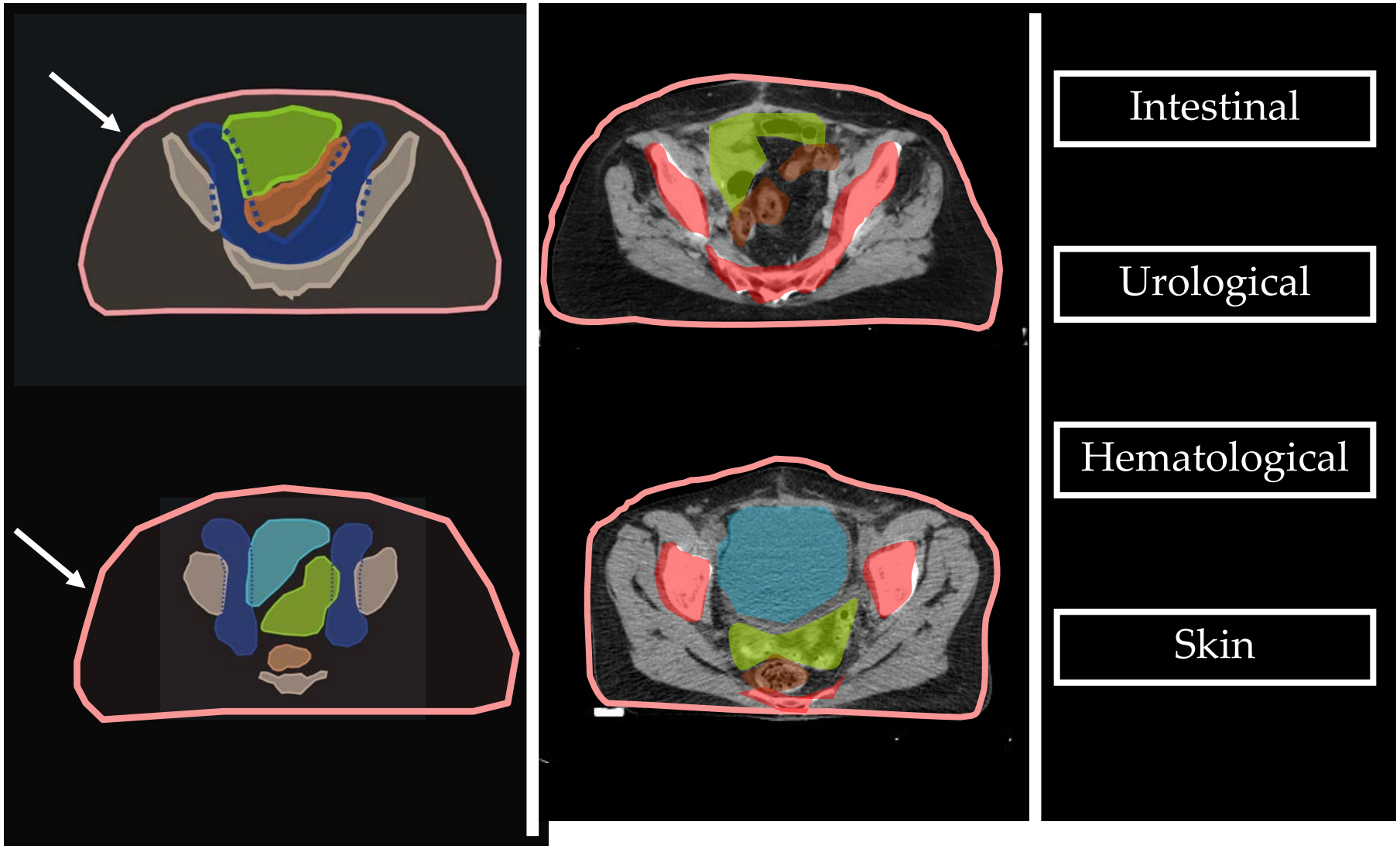

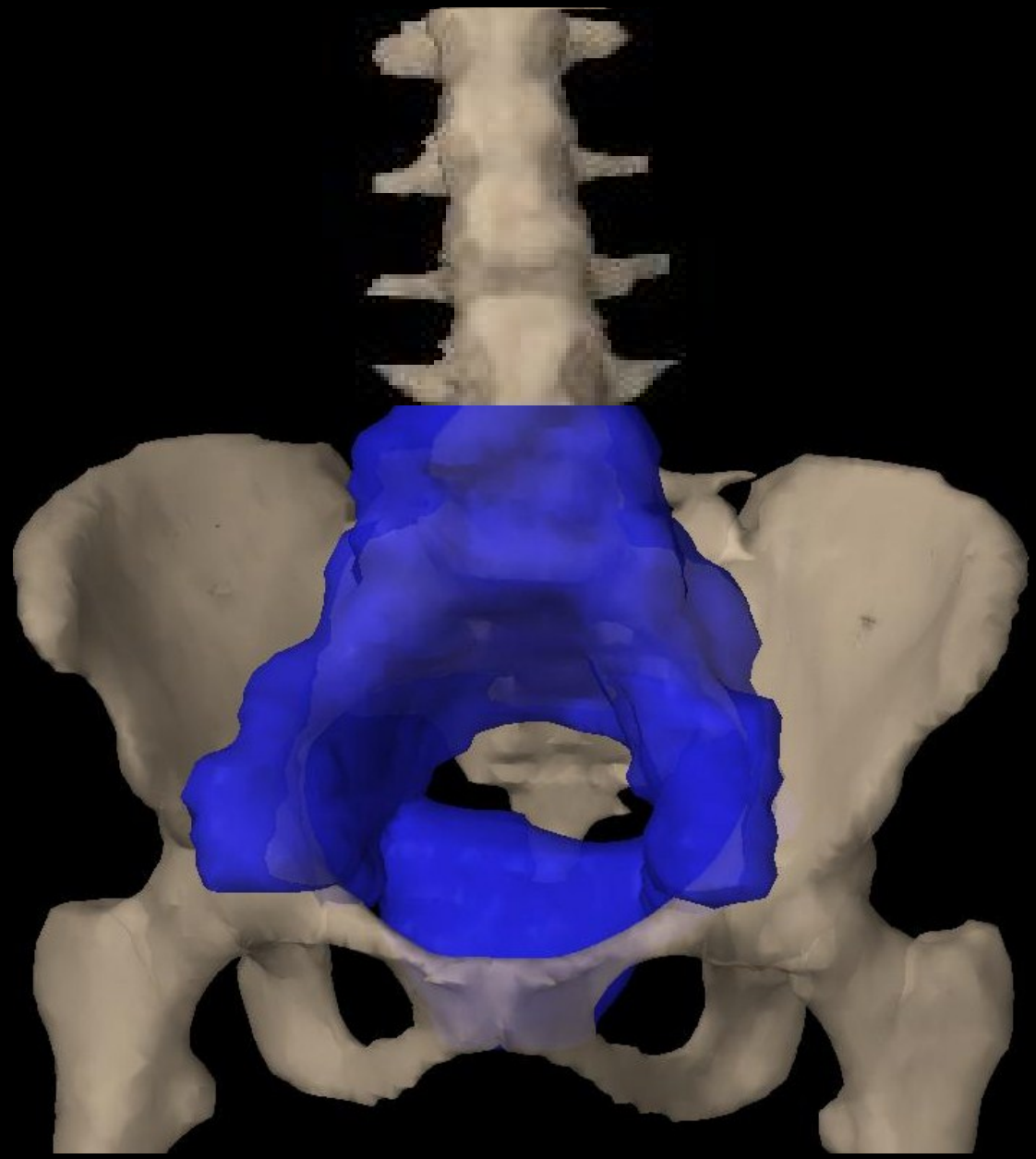

PTV margins??

Int. J. Radiation Oncology Biol. Phys., Vol. 80, No. 1, pp. 273–280, 2011
Copyright © 2011 Elsevier Inc.
Printed in the USA. All rights reserved
0360-3016/$–see front matter

doi:10.1016/j.ijrobp.2010.06.003

PHYSICS CONTRIBUTION

DAILY ONLINE CONE BEAM COMPUTED TOMOGRAPHY TO ASSESS INTERFRACTIONAL MOTION IN PATIENTS WITH INTACT CERVICAL CANCER

Neelam Tyagi, Ph.D., John H. Lewis, M.S., Catheryn M. Yashar, M.D.,
Daniel Vo, Steve B. Jiang, Ph.D., Arno J. Mundt, M.D., and Loren K. Mell, M.D.

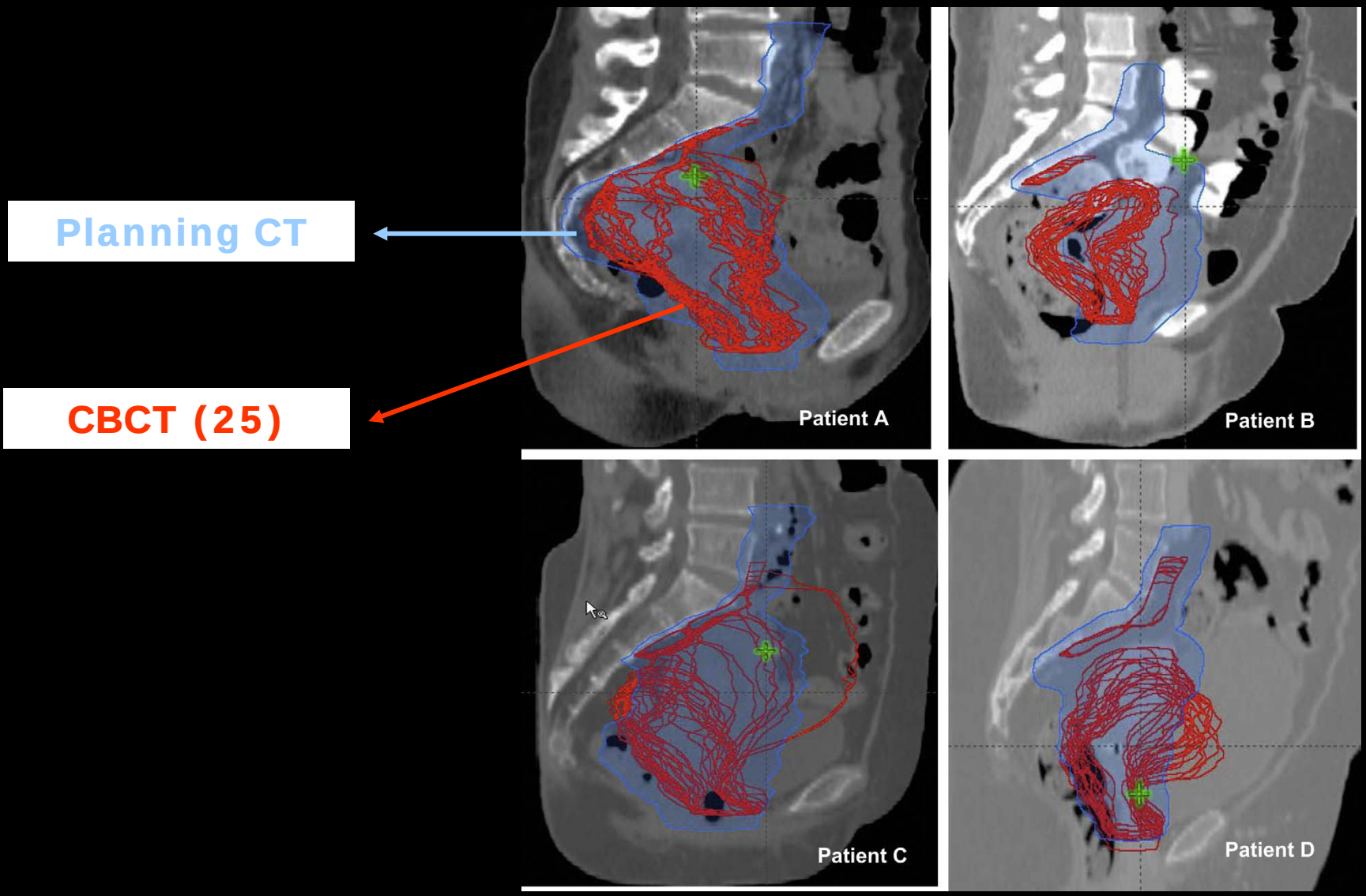
Planning CT
CBCT (25)
Patient A
Patient B
Patient C
Patient D

Int. J. Radiation Oncology Biol. Phys., Vol. 80, No. 1, pp. 273–280, 2011
Copyright © 2011 Elsevier Inc.
Printed in the USA. All rights reserved
0360-3016/$–see front matter

ELSEVIER

doi:10.1016/j.ijrobp.2010.06.003

PHYSICS CONTRIBUTION

DAILY ONLINE CONE BEAM COMPUTED TOMOGRAPHY TO ASSESS INTERFRACTIONAL MOTION IN PATIENTS WITH INTACT CERVICAL CANCER

Neelam Tyagi, Ph.D., John H. Lewis, M.S., Catheryn M. Yashar, M.D.,
Daniel Vo, Steve B. Jiang, Ph.D., Arno J. Mundt, M.D., and Loren K. Mell, M.D.

Margin (mm)	Mean % of fractions missing (range)	Mean volume missed (cc) (range)	% of mean volume missed (range)	Mean % of fractions missing (range)	
				Cervical region	Fundus region
0	100 (100–100)	45 (15–112)	10 (3–28)	95 (75–100)	100 (100–100)
3	99 (92–100)	25 (10–84)	6 (2–21)	80 (54–100)	89 (33–100)
5	95 (73–100)	20 (5–72)	4 (1–18)	65 (25–100)	84 (5–100)
7	87 (54–100)	14 (0–62)	3 (0–16)	50 (0–100)	70 (0–100)
10	59 (0–100)	9 (0–46)	2 (0–12)	36 (0–100)	54 (0–96)
15	32 (0–100)	4 (0–21)	1 (0–5)	19 (0–100)	22 (0–73)
20	19 (0–100)	2 (0–8)	0 (0–2)	11 (0–88)	11 (0–58)
25	14 (0–83)	1 (0–4)	0 (0–1)	7 (0–59)	7 (0–33)
30	7 (0–33)	0 (0–2)	0 (0–0)	1 (0–6)	4 (0–17)
35	2 (0–13)	0 (0–1)	0 (0–0)	0 (0–0)	2 (0–13)
40	0 (0–0)	0 (0–0)	0 (0–0)	0 (0–0)	0 (0–0)

Target volume delineation

(stage IIIA)

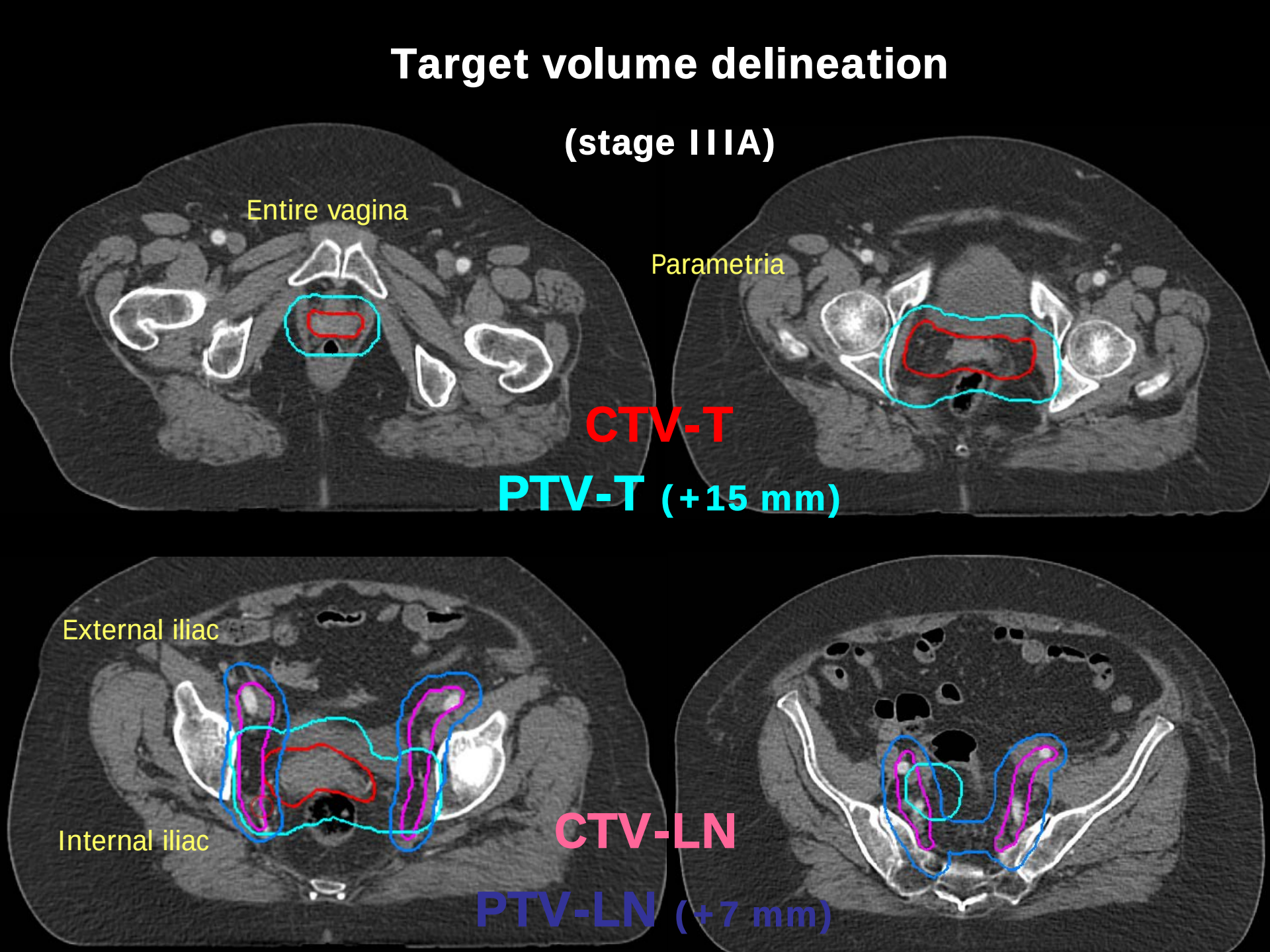

Target volume delineation

(stage IIB +left external iliac LN)

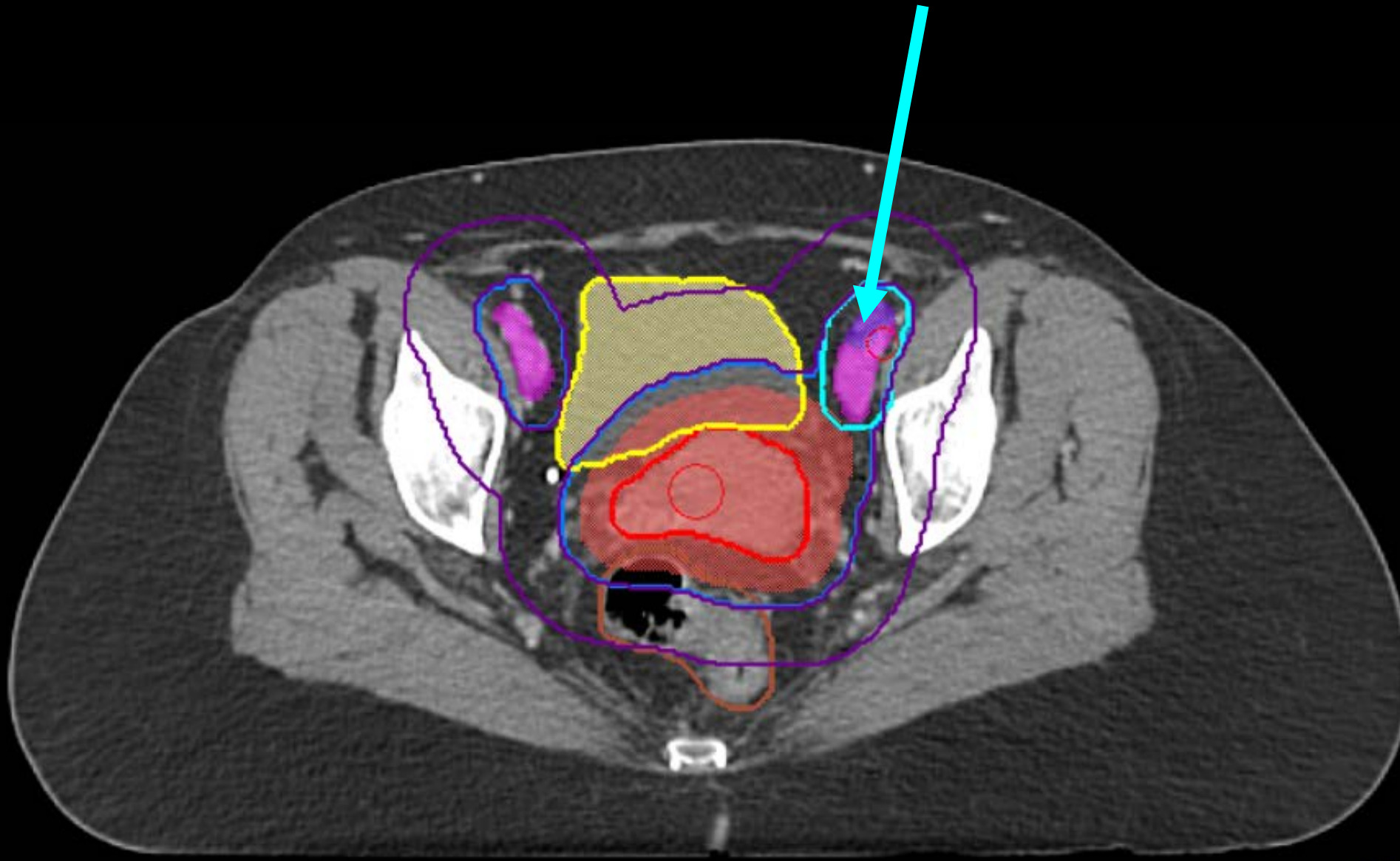

Obliquet 36 Volume 2/Volume 1
Ex: 6313
Se: 516350
P: 51.4
S 1737
DFOV 102.4 cm
187/35
7201.3
0.0
50 % PET
4.0/
4.0mm /4.0sp
04:07:36 PM
m=0.0 M=7201.3 CNTS
S 713
L
GTV_PET

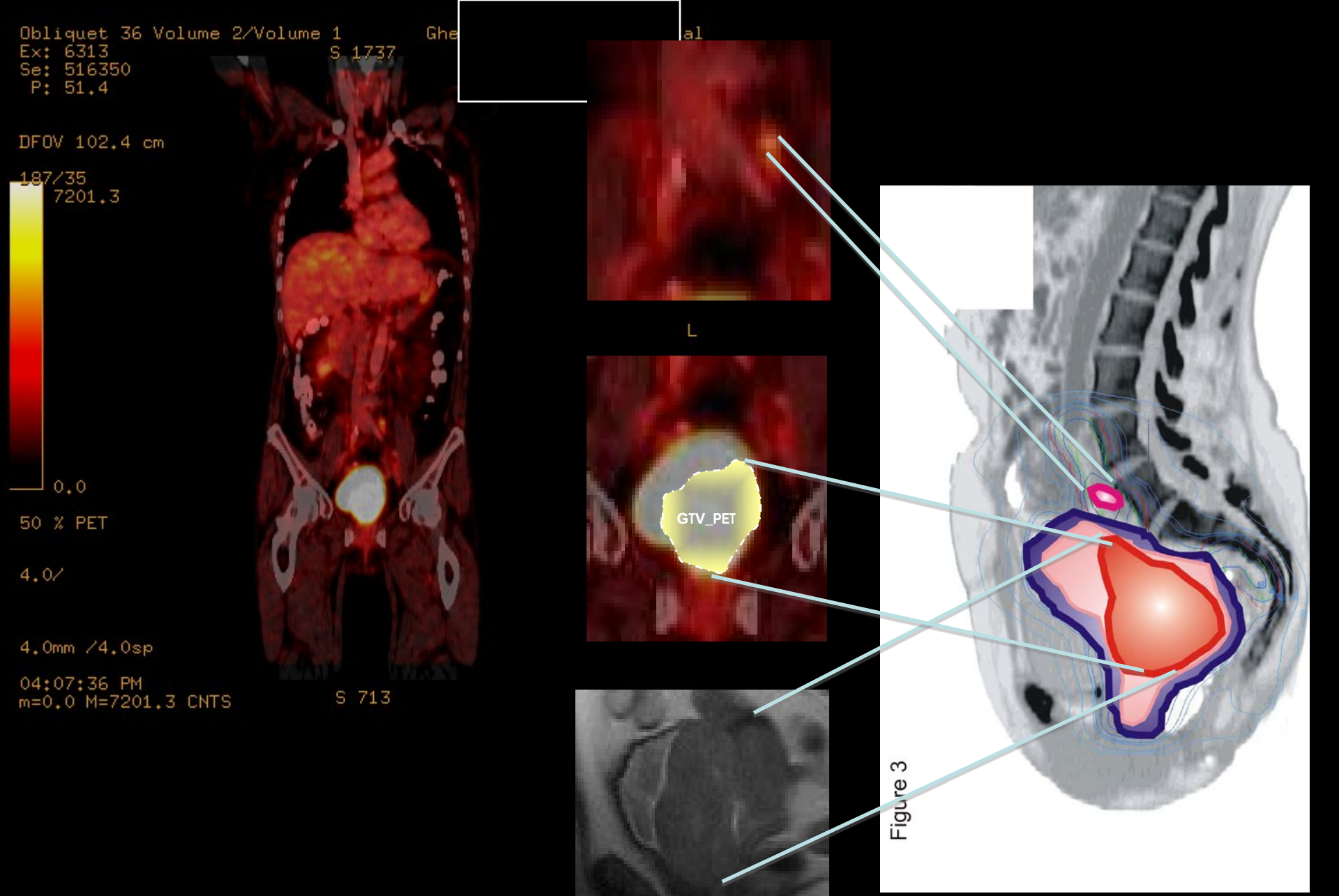
Obliquet 36 Volume 2/Volume 1
Ex: 6313
Se: 516350
P: 51.4
S 1737
DFOV 102.4 cm
187/35
7201.3
0.0
50 % PET
4.0/
4.0mm /4.0sp
04:07:36 PM
m=0.0 M=7201.3 CNTS
S 713
L
GTV_PET

Figure 3

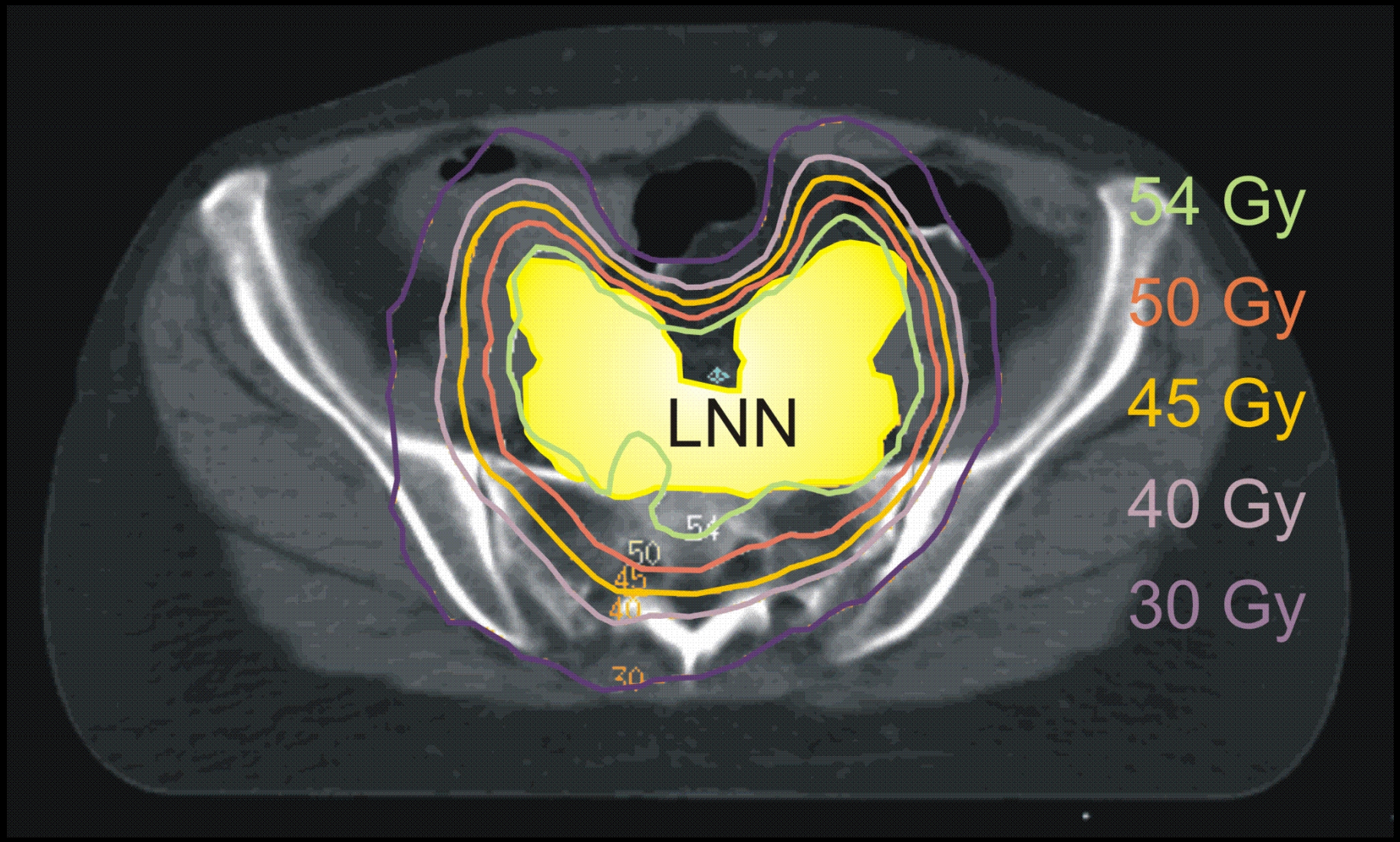
LNN
54 Gy
50 Gy
45 Gy
40 Gy
30 Gy
54
50
45
40
30

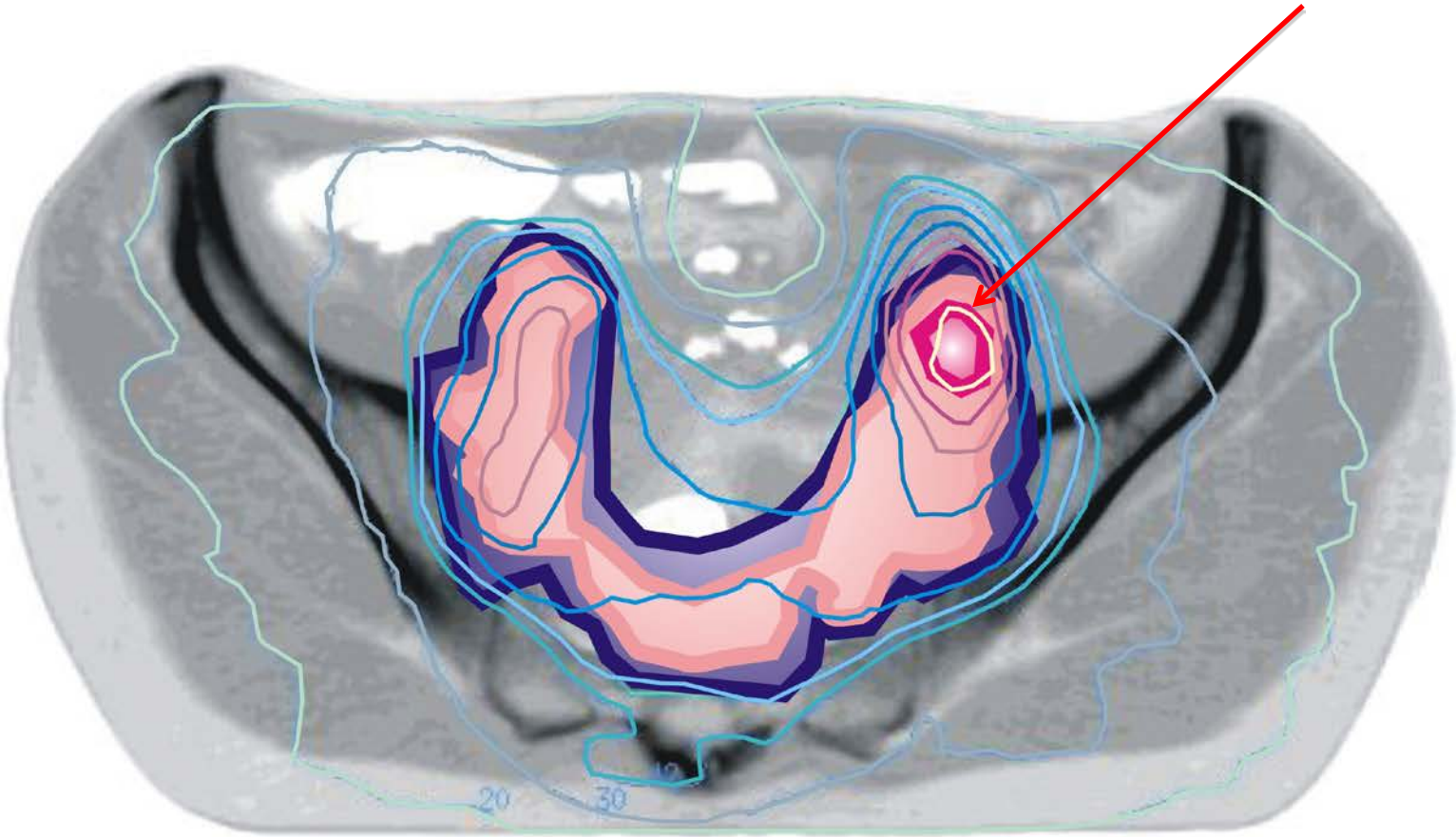
20
30

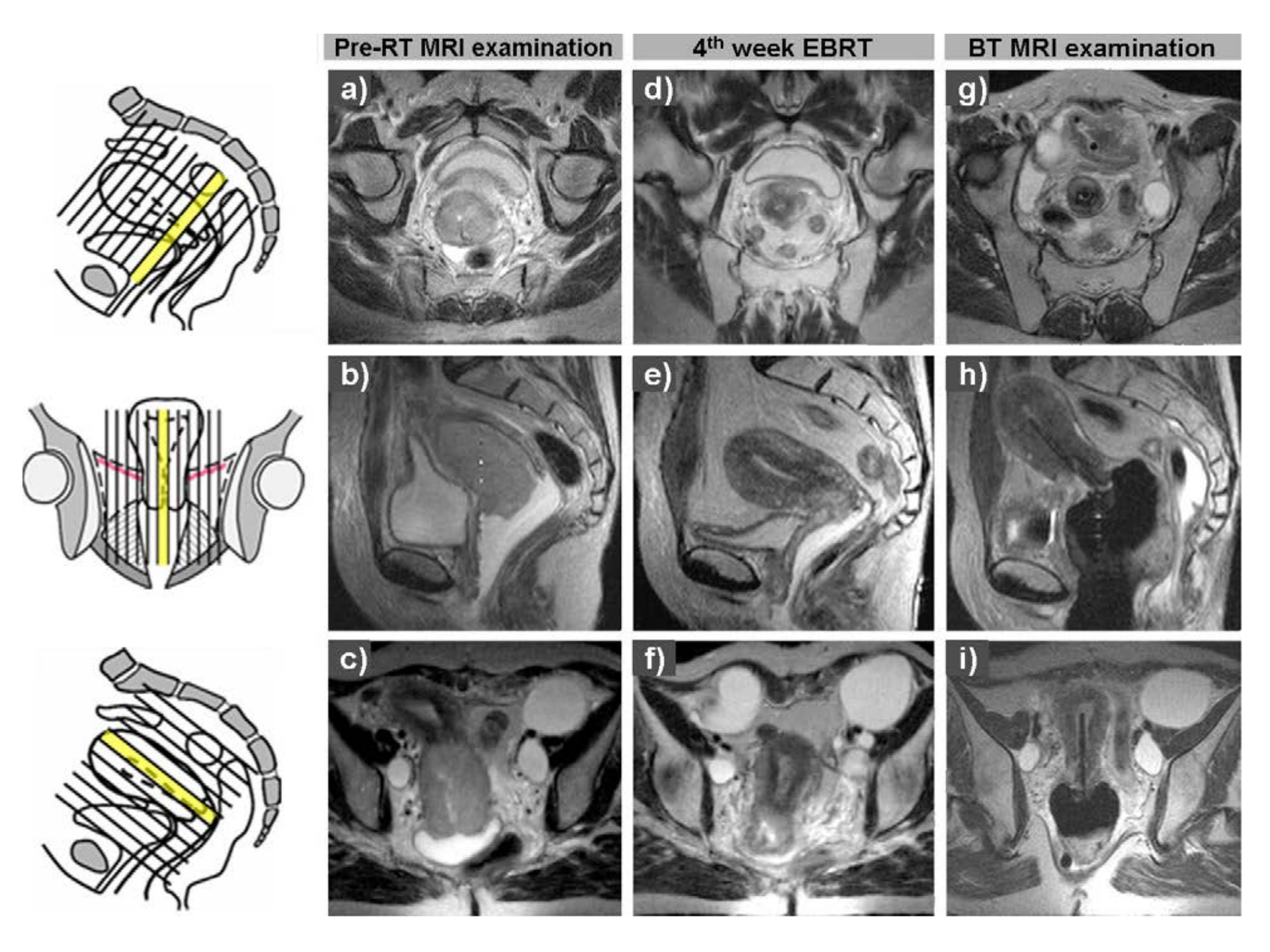
Pre-RT MRI examination
4th week EBRT
BT MRI examination
a)
b)
c)
d)
e)
f)
g)
h)
i)

Primary setting

Weekly MR-based re-planning

AUTOMATED WEEKLY REPLANNING FOR INTENSITY-MODULATED RADIOTHERAPY OF CERVIX CANCER

JAMES STEWART, M.A.SC.,* KAREN LIM, M.B.B.S.,*† VALERIE KELLY, M.SC.,*† JASON XIE, M.SC.,* KRISTY K. BROCK, PH.D.,*†‡ JOANNE MOSELEY, B.MATH.,* YOUNG-BIN CHO, PH.D.,*† ANTHONY FYLES, M.D.,*† ANNA LUNDIN, M.SC.,§ HENRIK REHBINDER, PH.D.,§ JOHAN LÖF, PH.D.,§ DAVID JAFFRAY, PH.D.,*‡ AND MICHAEL MILOSEVIC, M.D., FRCPC.*†

IJROBP 2010: 78: 350-8

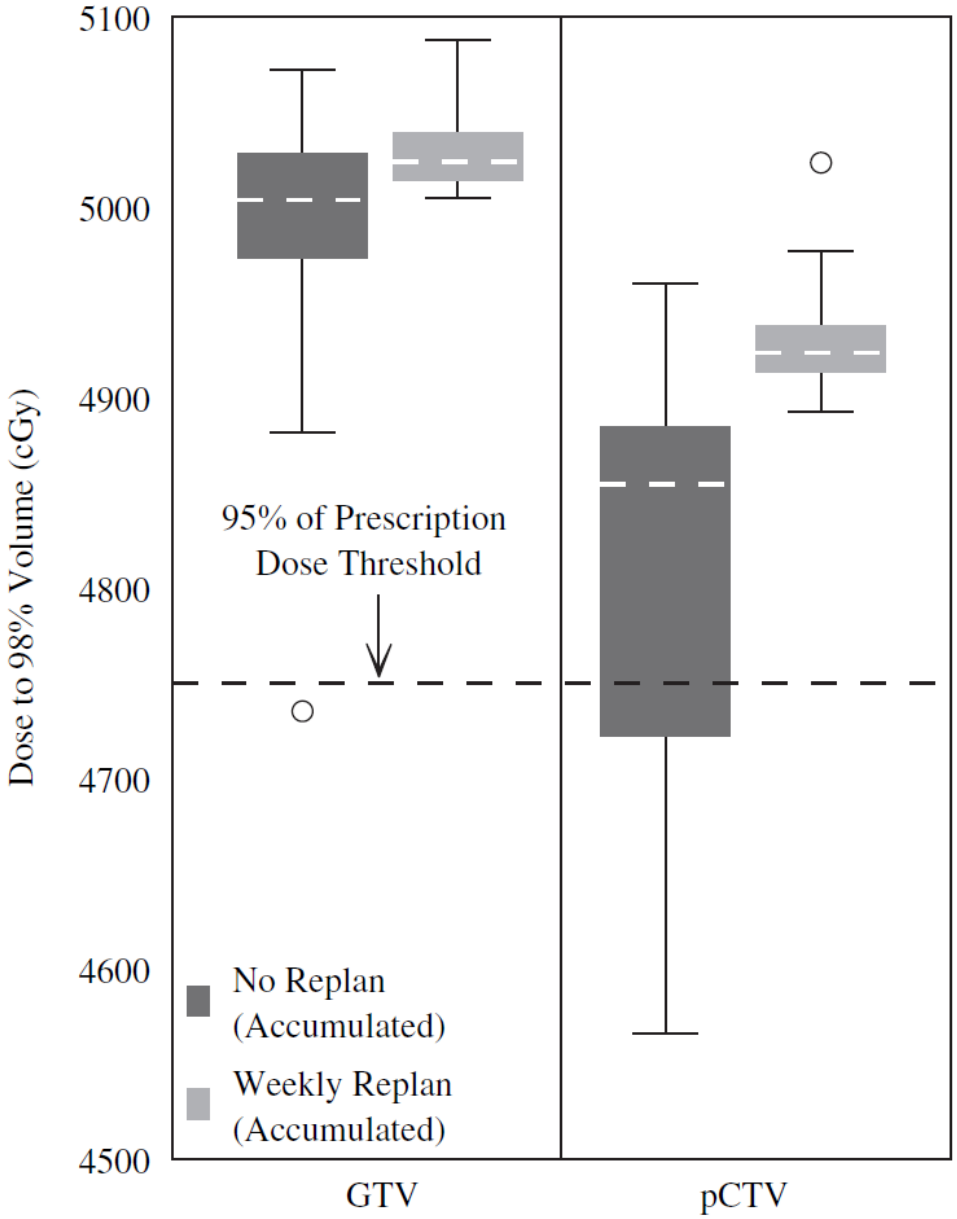
5100
5000
4900
4800
4700
4600
4500
Dose to 98% Volume (cGy)
95% of Prescription
Dose Threshold
No Replan
(Accumulated)
Weekly Replan
(Accumulated)
GTV
pCTV

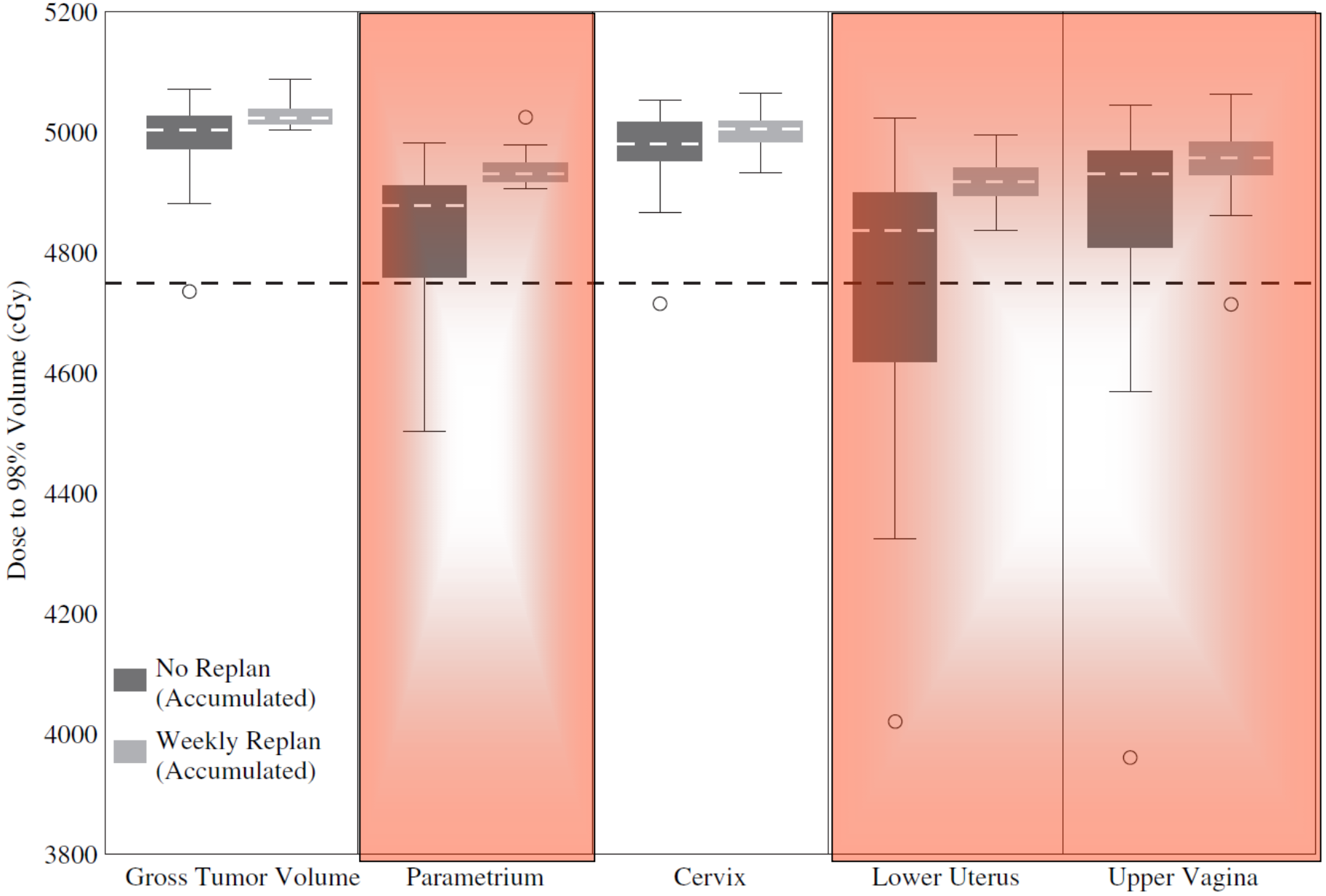
5200
5000
4800
4600
4400
4200
4000
3800
Dose to 98% Volume (cGy)
No Replan (Accumulated)
Weekly Replan (Accumulated)
Gross Tumor Volume
Parametrium
Cervix
Lower Uterus
Upper Vagina

Take home messages:

- Use modern (incl. biological) imaging

- Delineate positive LN separately

- Adaptive planning might be near future

Caféplan Gent

CONSENSUS GUIDELINES FOR DELINEATION OF CLINICAL TARGET VOLUME FOR INTENSITY-MODULATED PELVIC RADIOTHERAPY IN POSTOPERATIVE TREATMENT OF ENDOMETRIAL AND CERVICAL CANCER

William Small, Jr., M.D.,* Loren K. Mell, M.D.,† Penny Anderson, M.D.,‡
Carien Creutzberg, M.D.,§ Jennifer De Los Santos, M.D.,¶ David Gaffney, M.D., Ph.D.,‖
Anuja Jhingran, M.D.,# Lorraine Portelance, M.D.,** Tracey Schefter, M.D.,††
Revathy Iyer, M.D.,‡‡ Mahesh Varia, M.D.,§§ Kathryn Winter, M.S.,¶¶ and Arno J. Mundt, M.D.‖‖

Target site	Definition
Common iliac lymph nodes	From 7 mm below L4–L5 interspace to level of bifurcation of common iliac arteries into external and internal iliac arteries
External iliac lymph nodes	From level of bifurcation of common iliac artery into external artery to level of superior aspect of femoral head where it becomes femoral artery
Internal iliac lymph nodes	From level of bifurcation of common iliac artery into internal artery, along its branches (obturator, hypogastric) terminating in paravaginal tissues at level of vaginal cuff
Upper vagina	Vaginal cuff and 3 cm of vagina inferior to cuff
Parametrial/paravaginal tissue	From vaginal cuff to medial edge of internal obturator muscle/ischial ramus on each side
Presacral lymph nodes*	Lymph node region anterior to S1and S2 region

Target site	Definition
Common iliac lymph nodes	From 7 mm below L4–L5 interspace to level of bifurcation of common iliac arteries into external and internal iliac arteries
External iliac lymph nodes	From level of bifurcation of common iliac artery into external artery to level of superior aspect of femoral head where it becomes femoral artery
Internal iliac lymph nodes	From level of bifurcation of common iliac artery into internal artery, along its branches (obturator, hypogastric) terminating in paravaginal tissues at level of vaginal cuff
Upper vagina	Vaginal cuff and 3 cm of vagina inferior to cuff
Parametrial/paravaginal tissue	From vaginal cuff to medial edge of internal obturator muscle/ischial ramus on each side
Presacral lymph nodes*	Lymph node region anterior to S1and S2 region

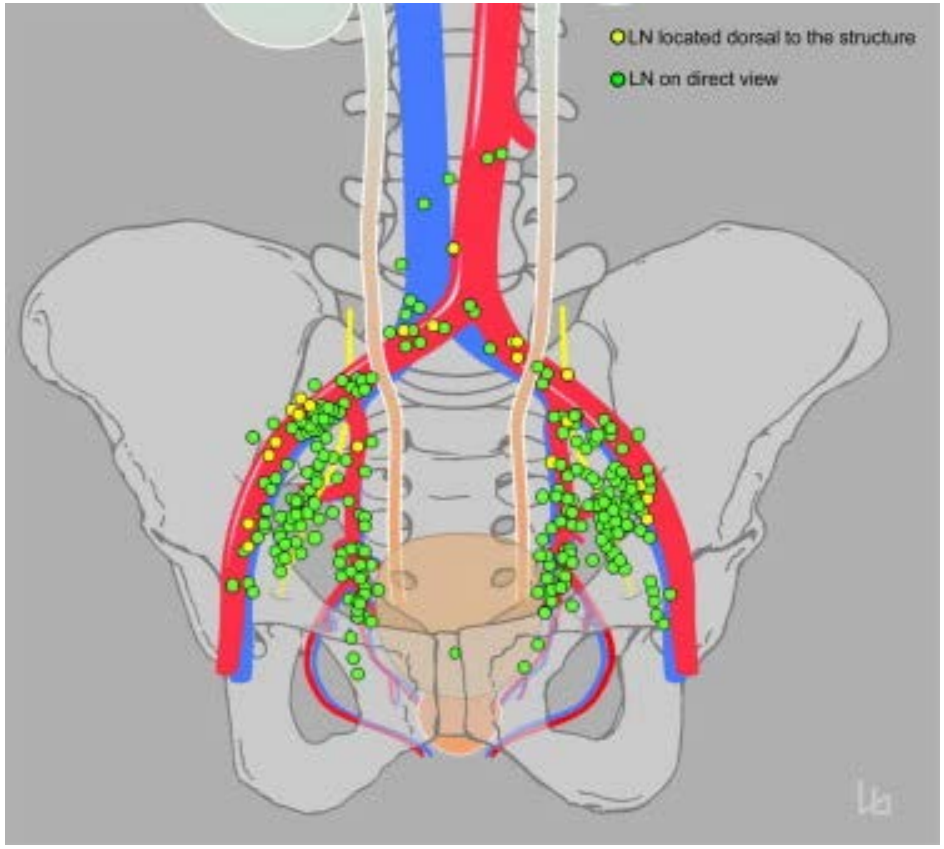

Upper CTV: aortic bifurcation

Upper CTV: aortic bifurcation

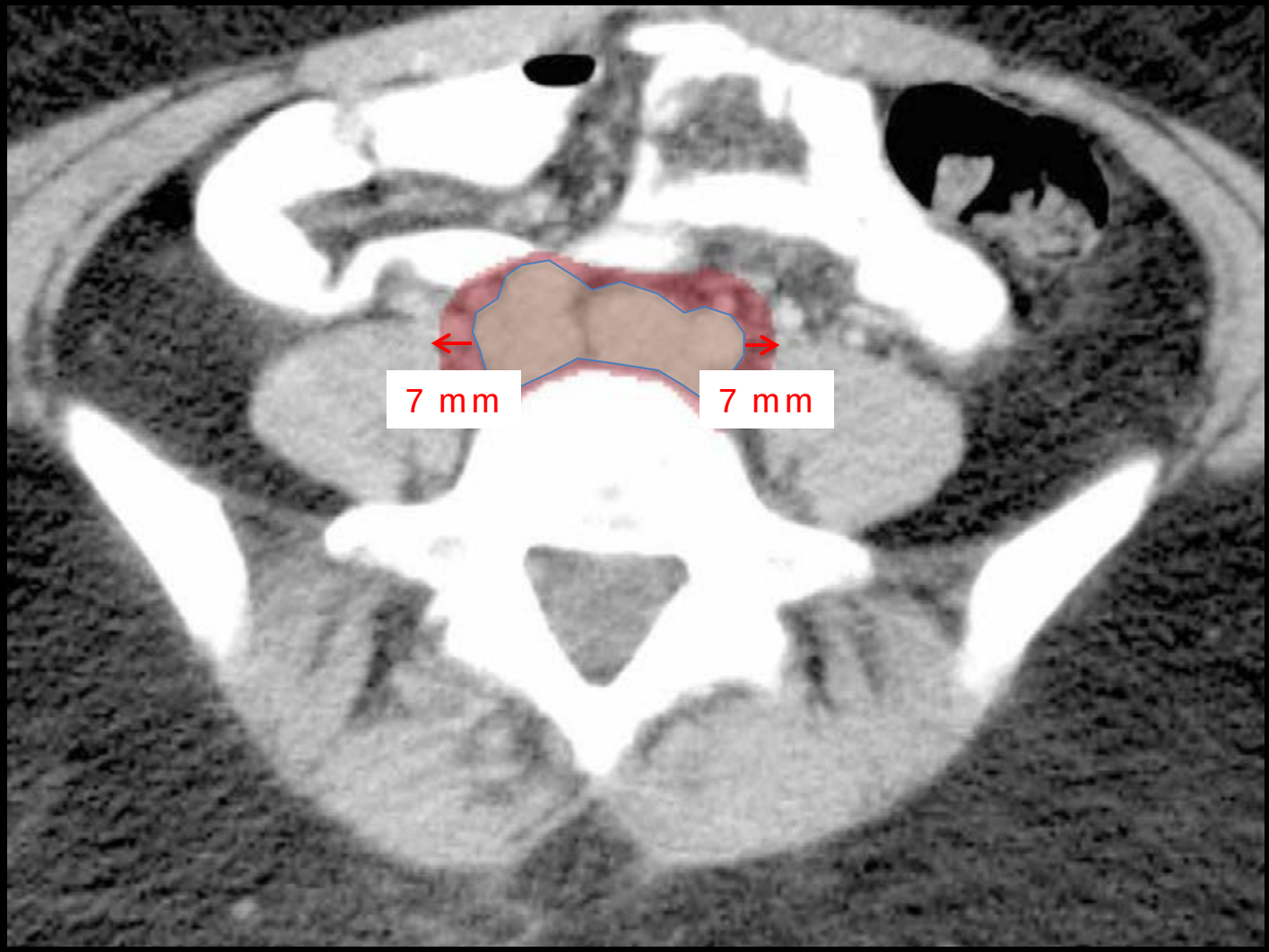

Upper CTV: aortic bifurcation

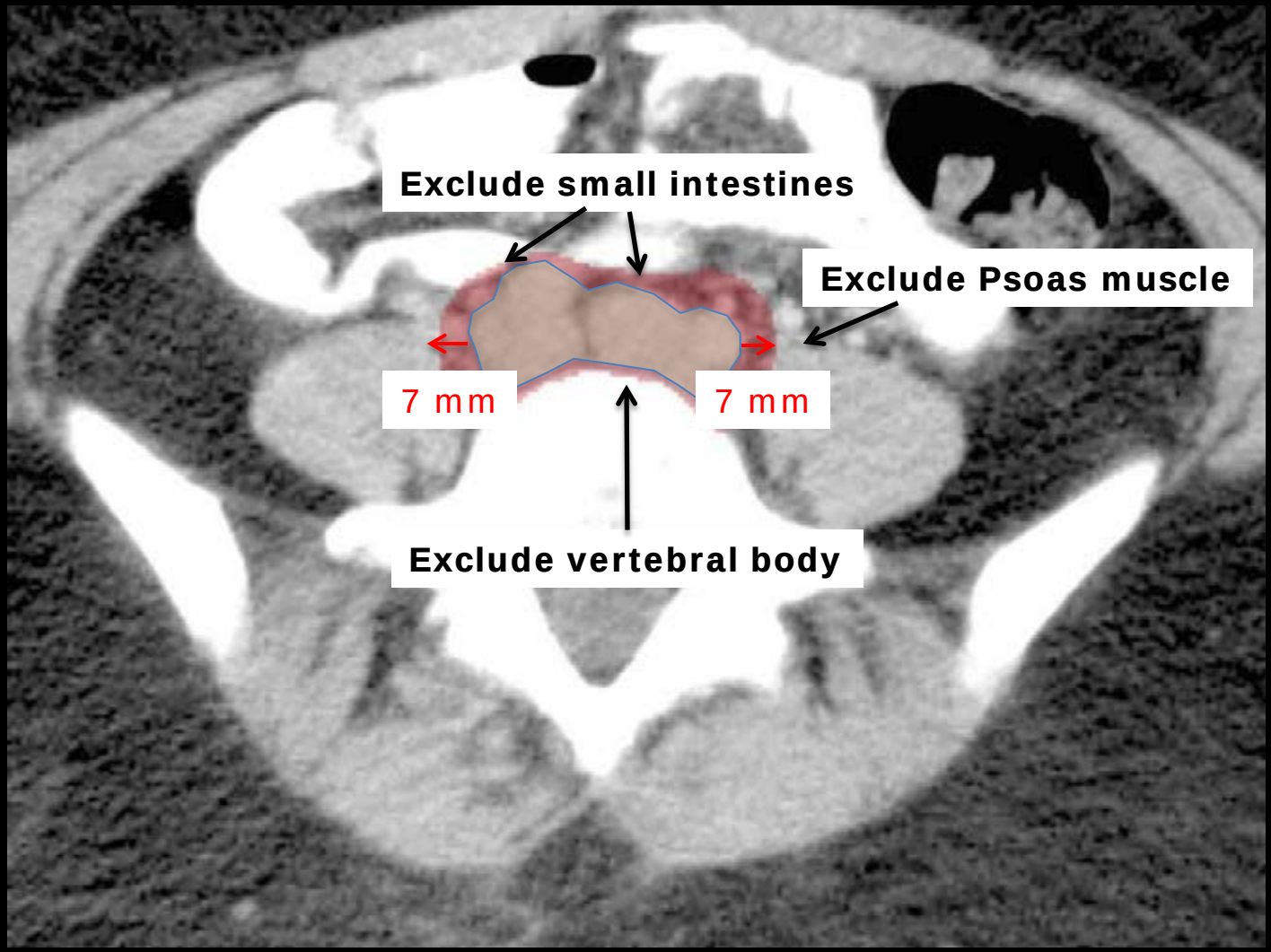

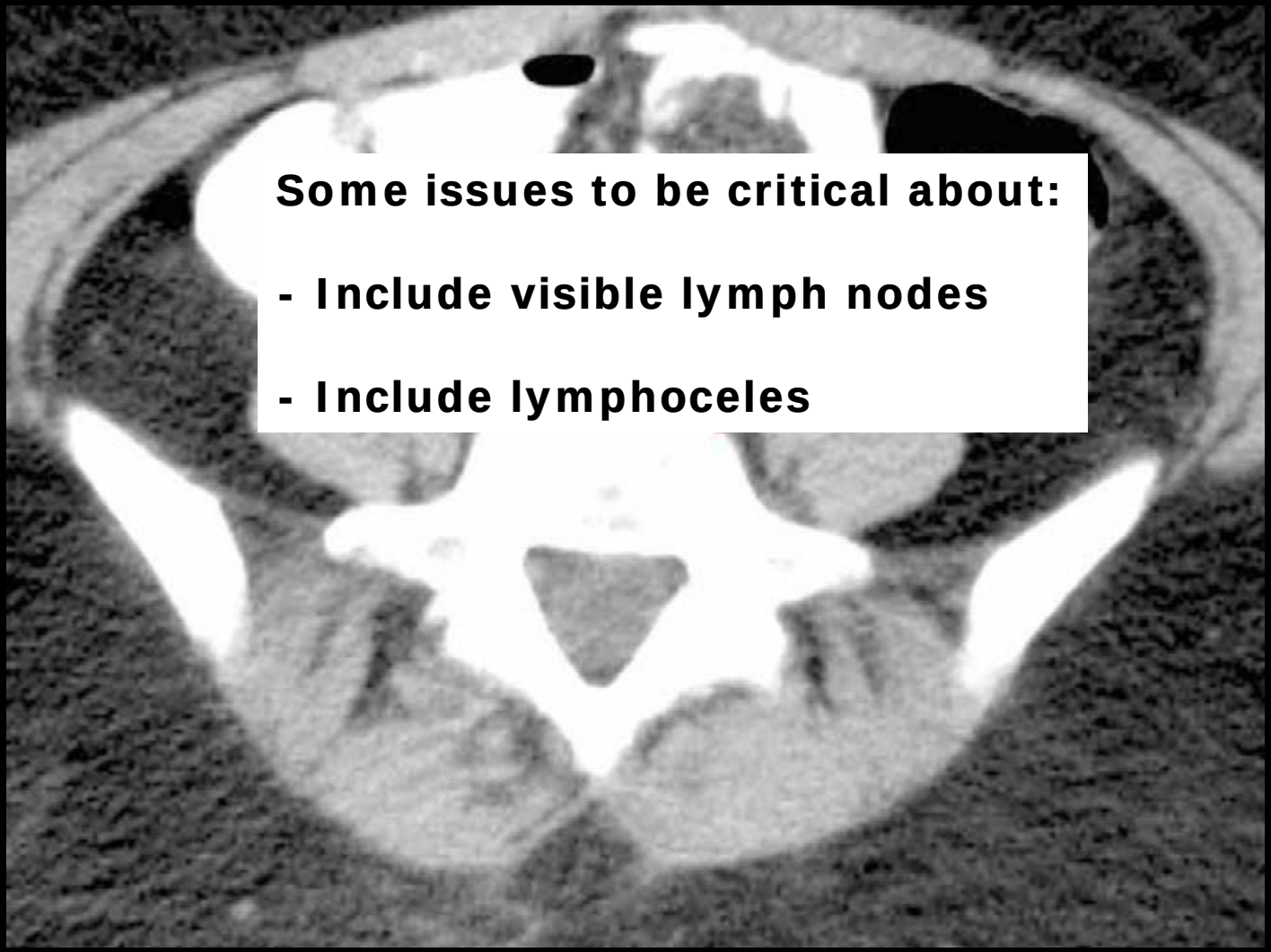
Some issues to be critical about:
- Include visible lymph nodes
- Include lymphoceles

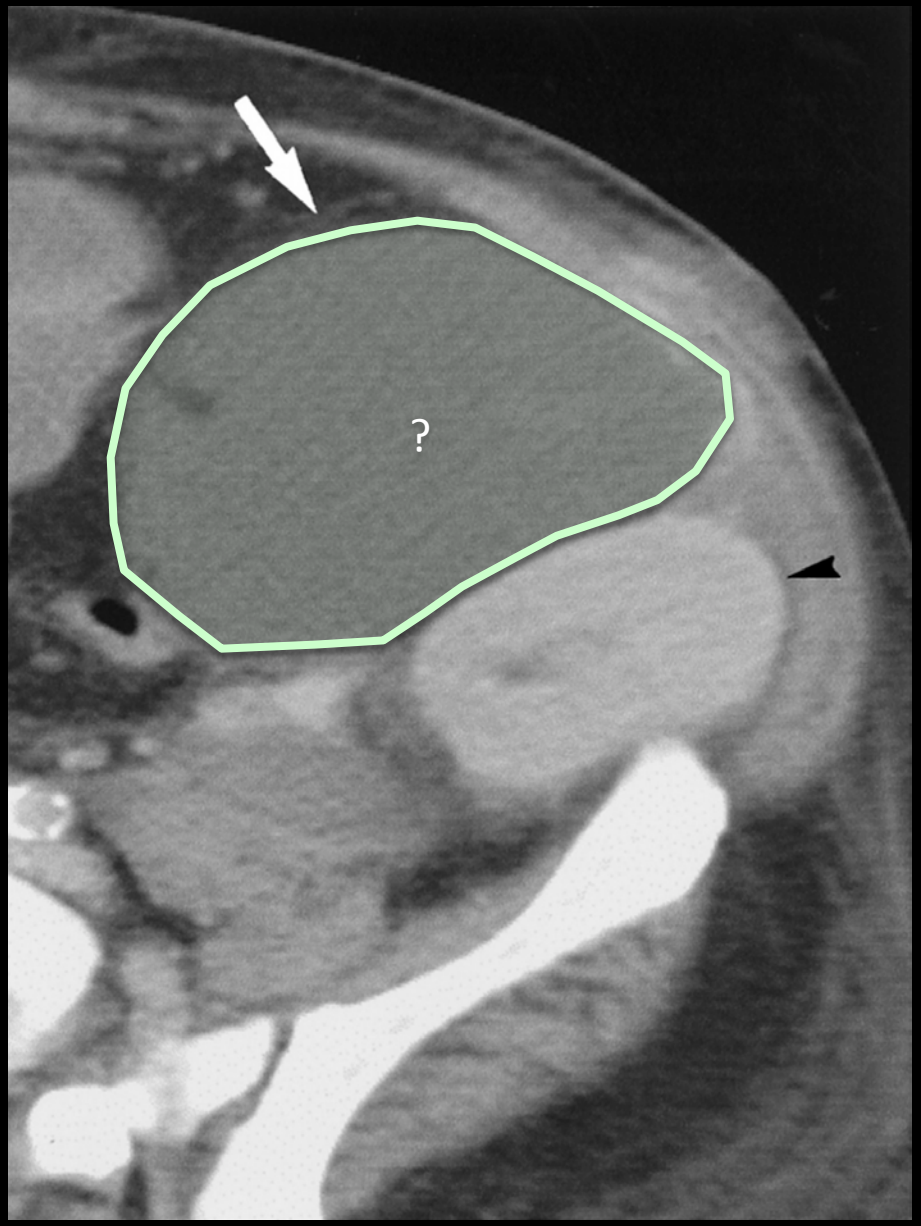

Upper CTV: common iliac vessels – presacral region

Upper CTV: common iliac vessels – presacral region

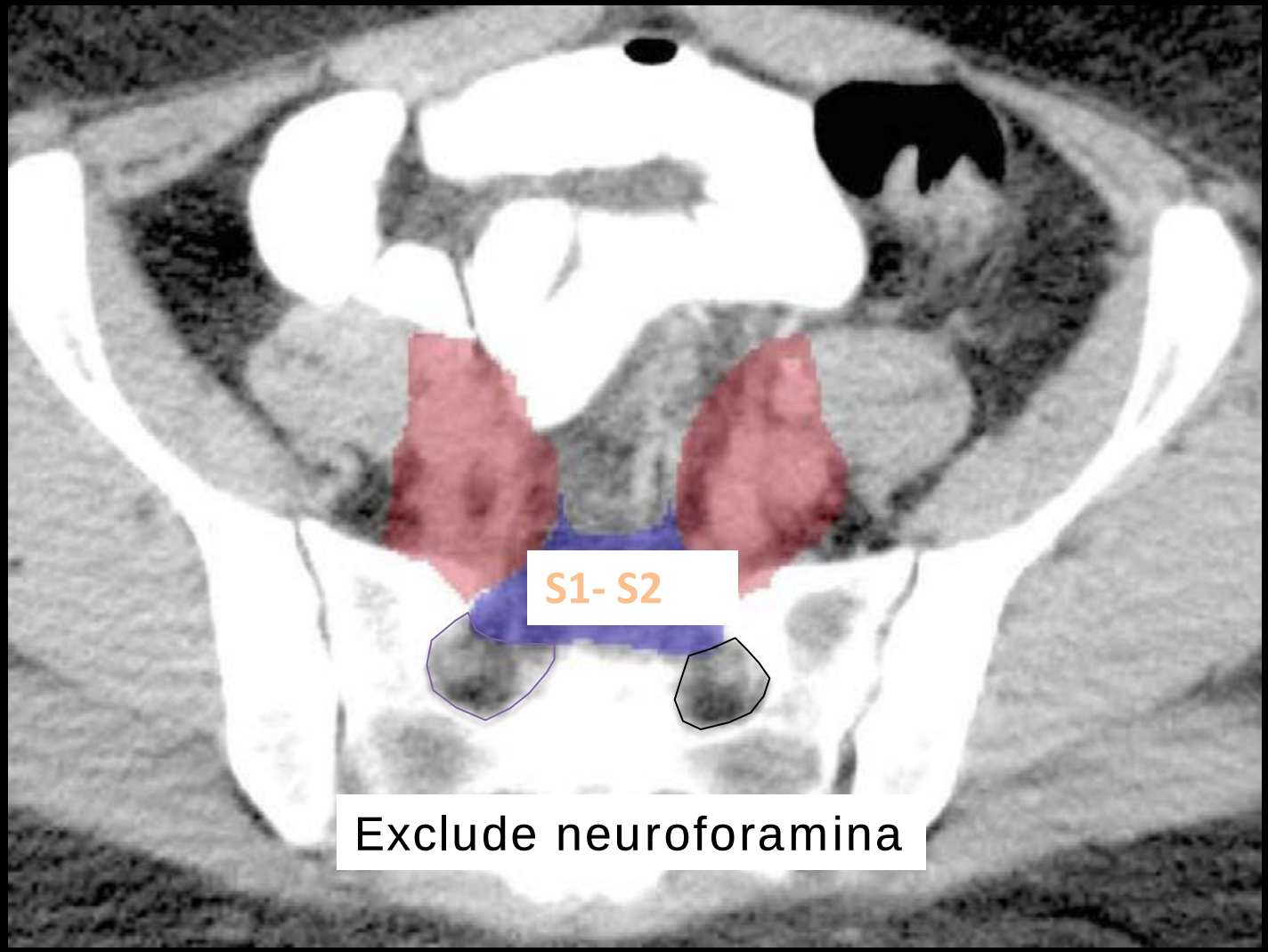

Middle CTV: internal/external iliac vessels– presacral region

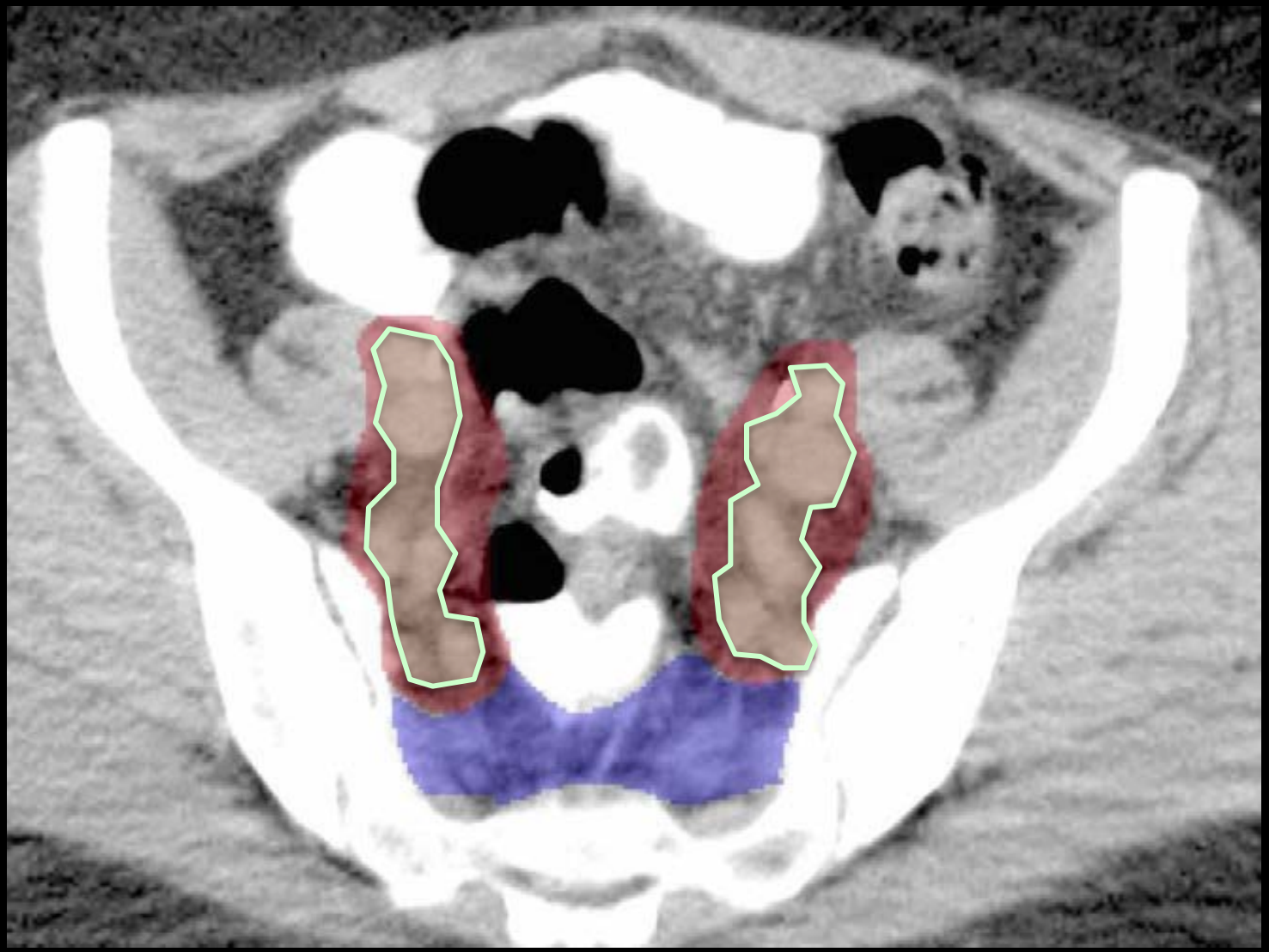

Middle CTV: internal/external iliac vessels– presacral region

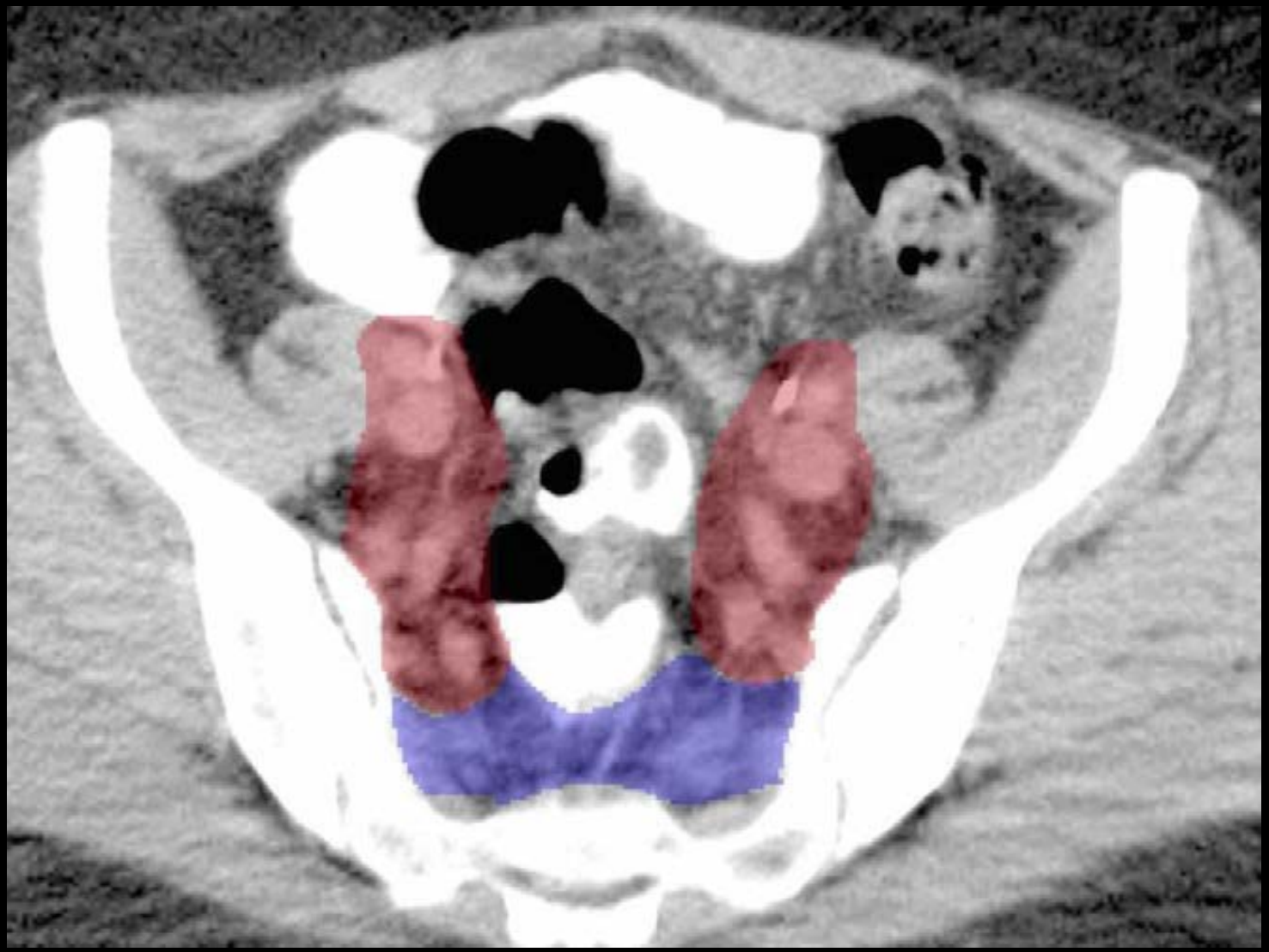

Parametrial / Vaginal CTV

Vaginal CTV

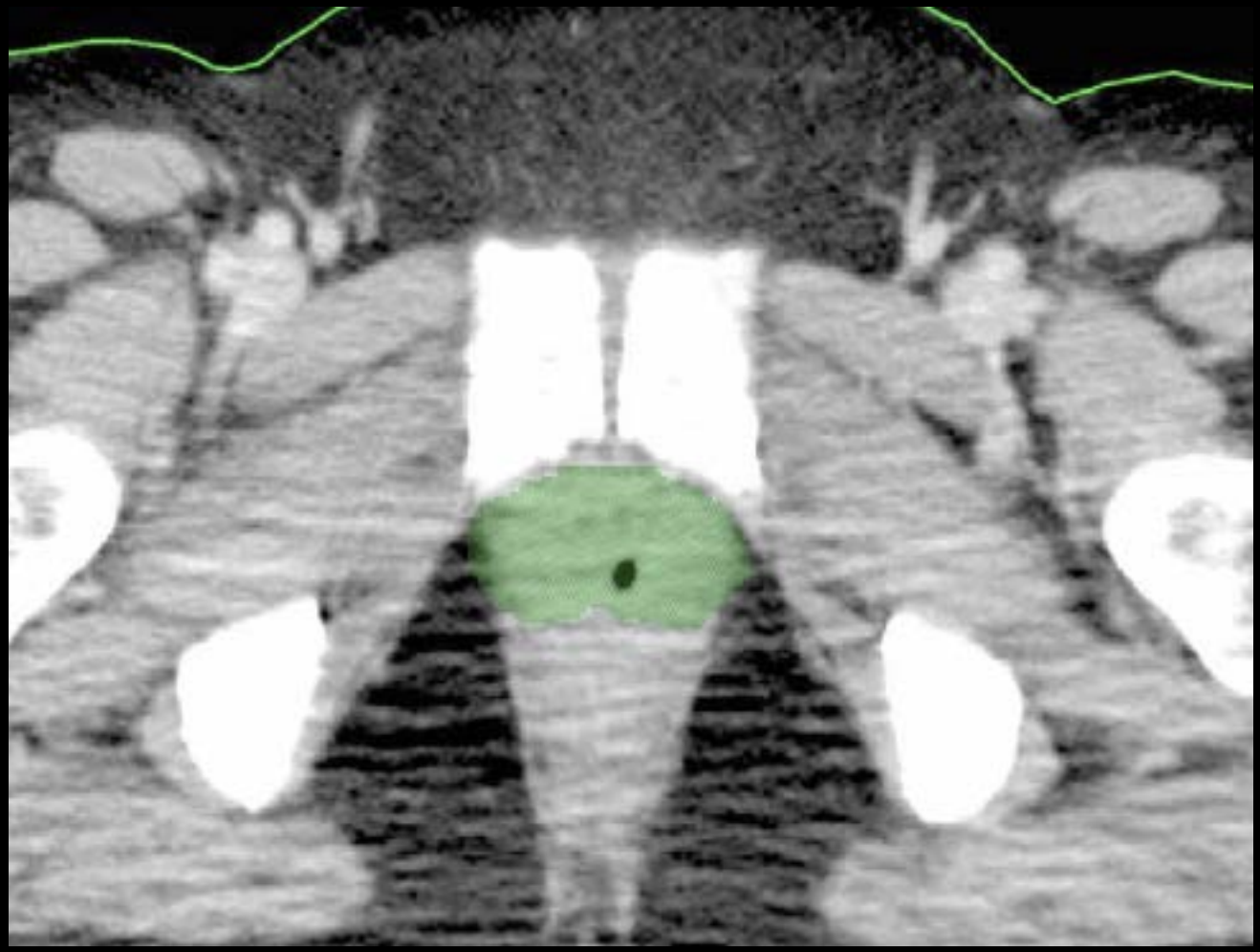

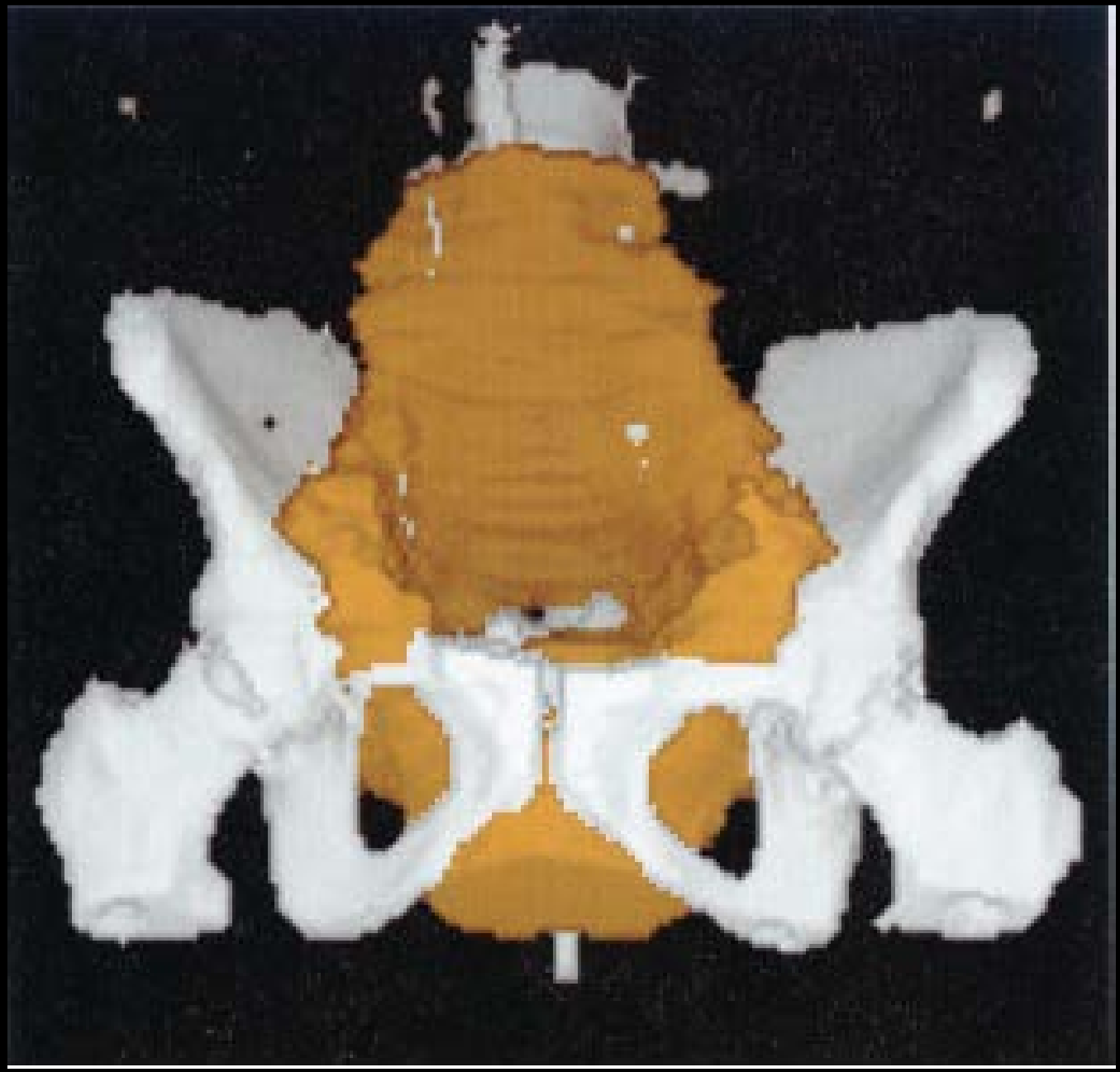

Postoperative setting: heterogeneous situation

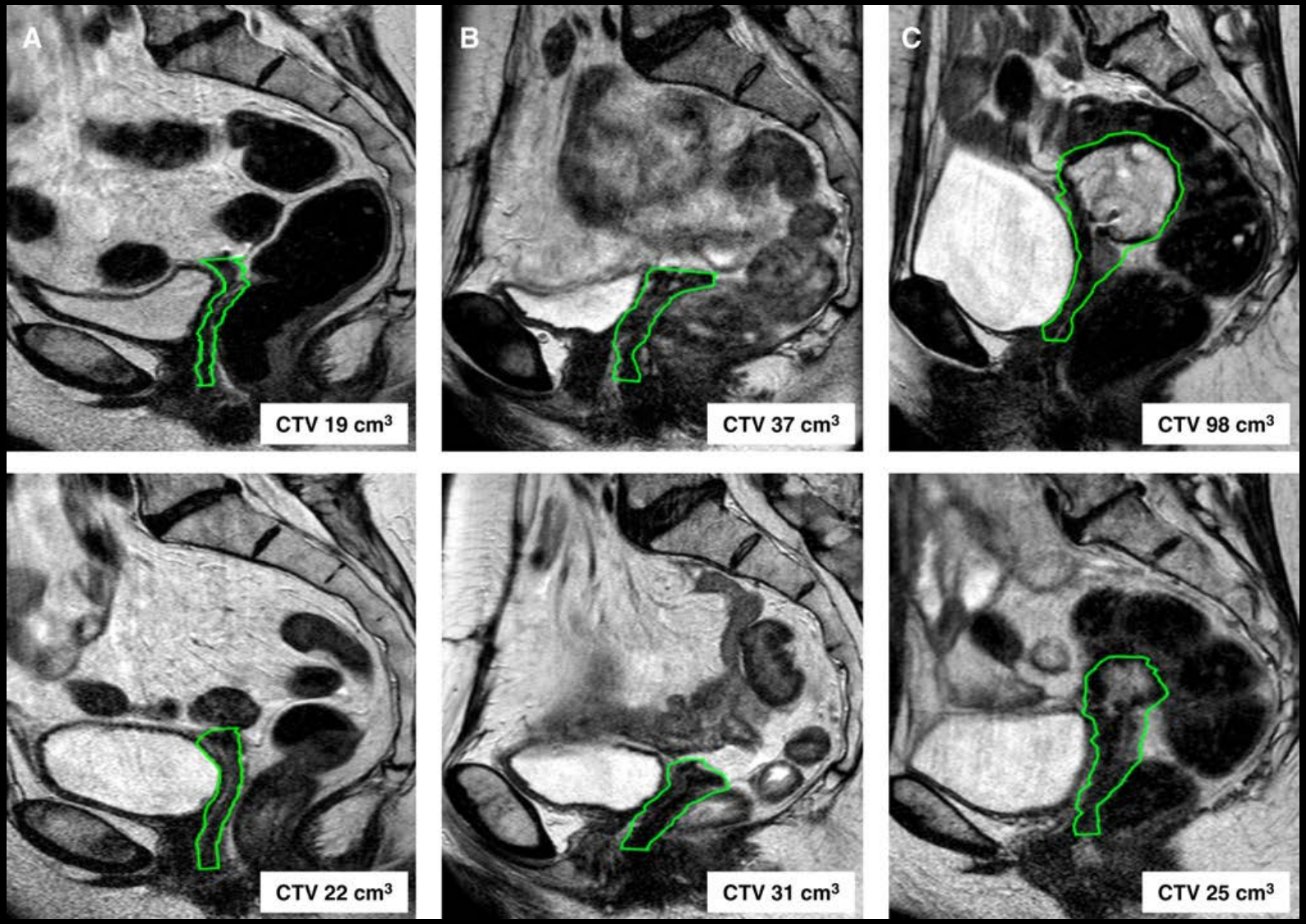

Vaginal cuff marker

MAGNITUDE OF INTERFRACTIONAL VAGINAL CUFF MOVEMENT: IMPLICATIONS FOR EXTERNAL IRRADIATION

DANIEL J. MA, M.D.,* MARTHA MICHALETZ-LORENZ, M.S.,† S. MURTY GODDU, PH.D., AND PERRY W. GRIGSBY, M.D.*‡§

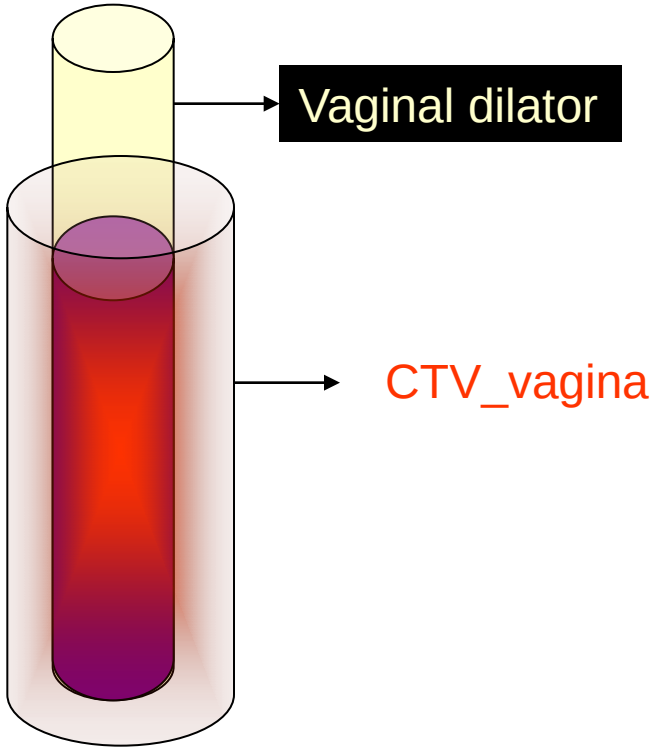

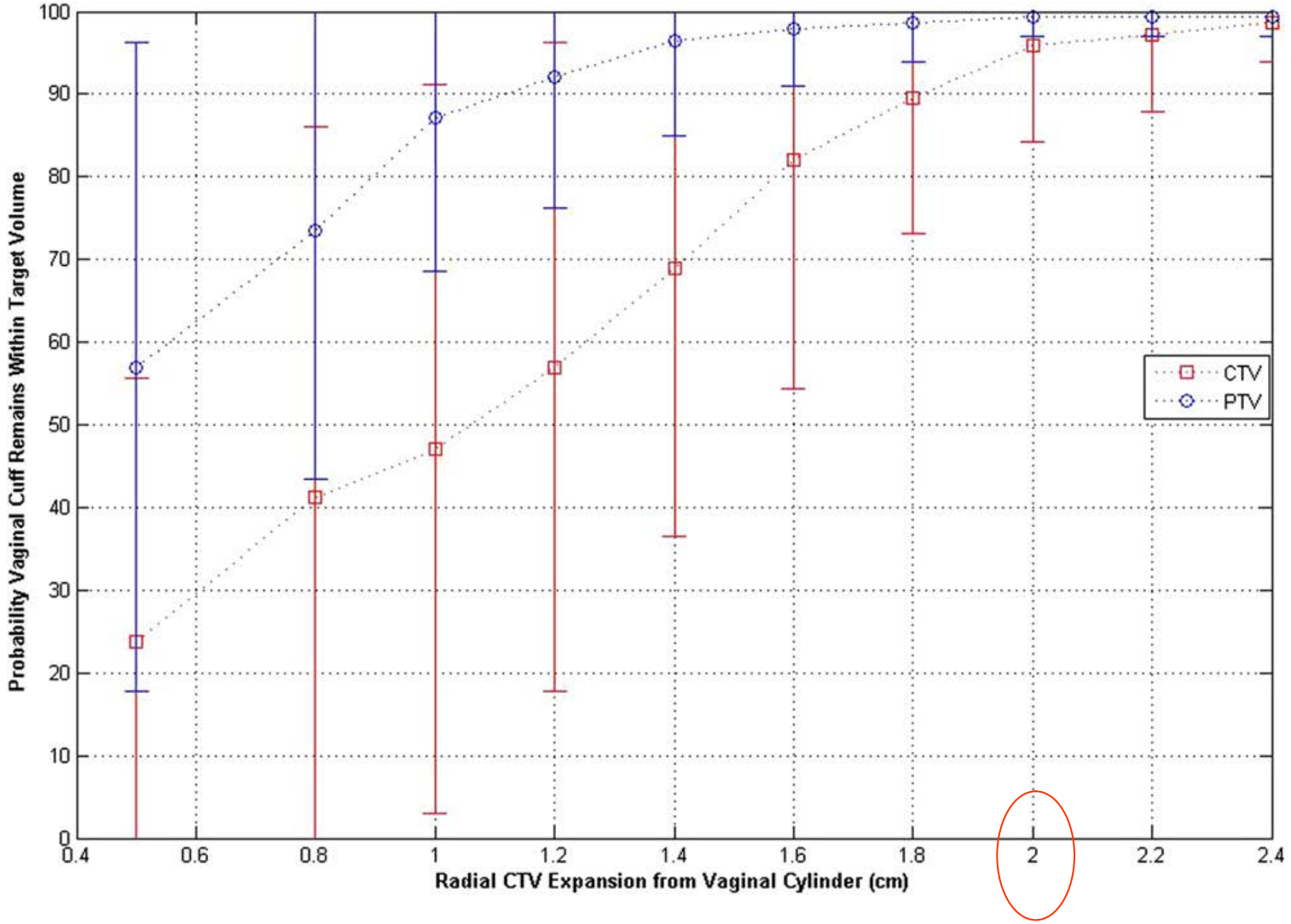
Probability Vaginal Cuff Remains Within Target Volume
Radial CTV Expansion from Vaginal Cylinder (cm)
CTV
PTV
0
10
20
30
40
50
60
70
80
90
100
0.4
0.6
0.8
1
1.2
1.4
1.6
1.8
2
2.2
2.4

ASSESSMENT OF ORGAN MOTION IN POSTOPERATIVE ENDOMETRIAL AND CERVICAL CANCER PATIENTS TREATED WITH INTENSITY-MODULATED RADIATION THERAPY

ELEANOR E. R. HARRIS, M.D., KUJTIM LATIFI, M.S., CHAD RUSTHOVEN, B.S., KEN JAVEDAN, PH.D., AND KENNETH FORSTER, PH.D.

- Daily CBCT
- Vaginal wall organ motion
- n=22
- upper vaginal ½, expanded with 10mm
- 3 fiducial markers, COM

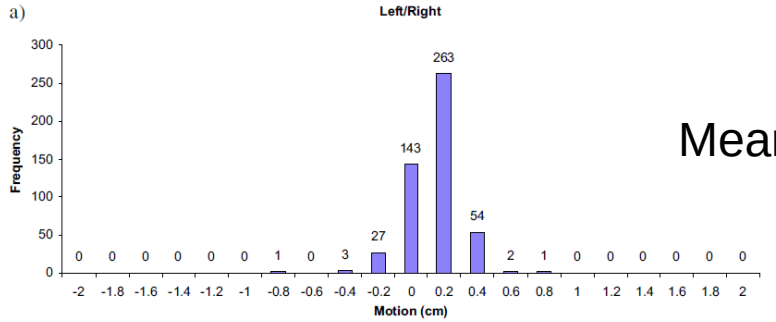

Mean LR motion 1.2 mm

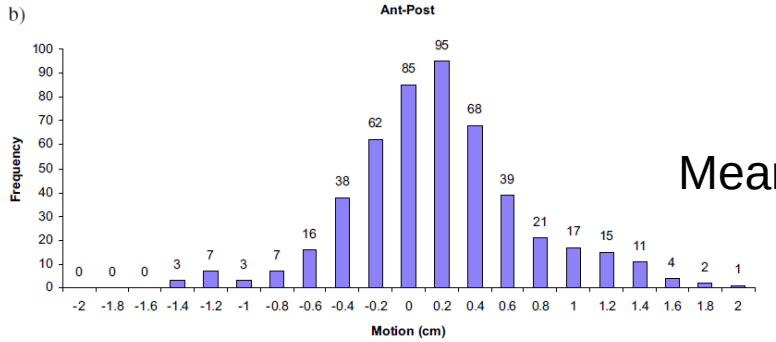

Mean AP motion 4.0 mm

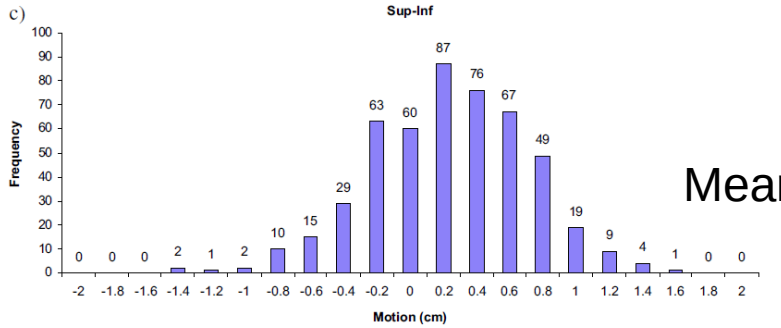

Mean SI motion 4.0 mm

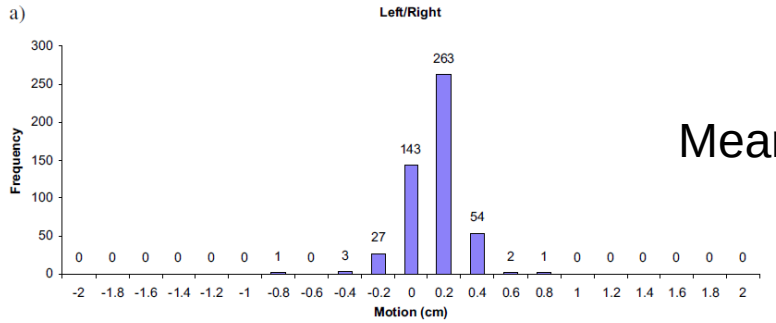

Mean LR motion 1.2 mm

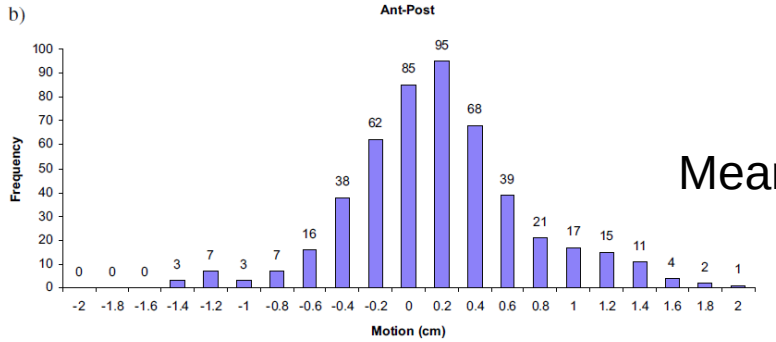

Mean AP motion 4.0 mm

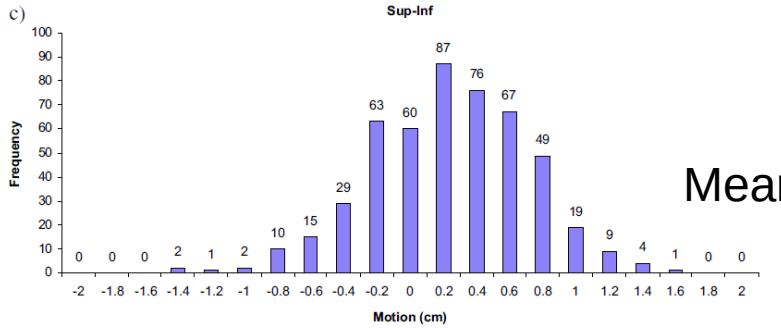

Mean SI motion 4.0 mm

<u>To ensure 95% coverage</u>:

- LR: 3.1 mm needed
- AP: 12.1 mm needed
- SI: 9.5 mm needed

<u>Total motion (COM): 15.7 mm</u>

Homogeneous margins?

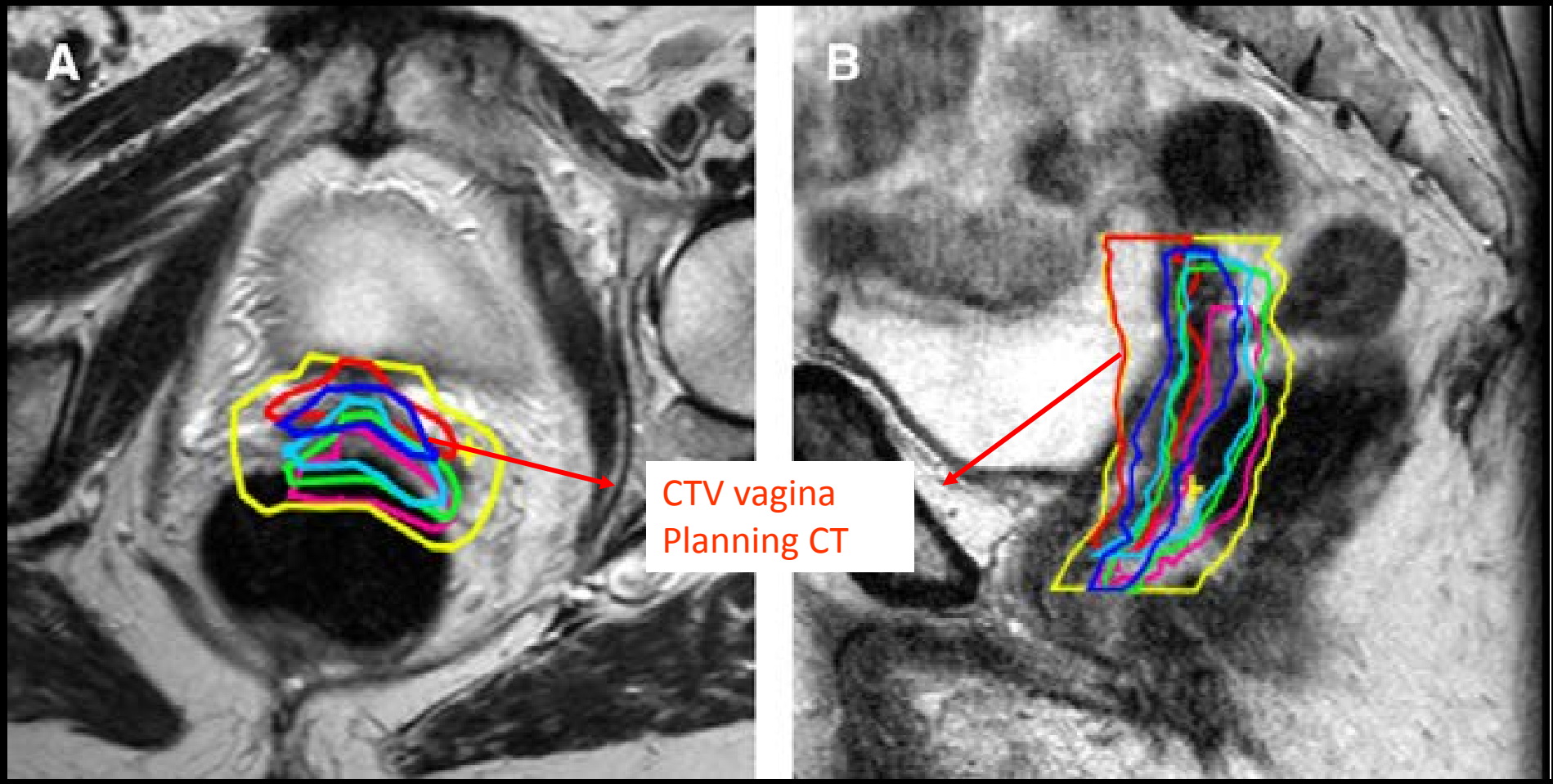

Jürgenliemk-Schulz et al. R&O; 2011;98:

Homogeneous margins?

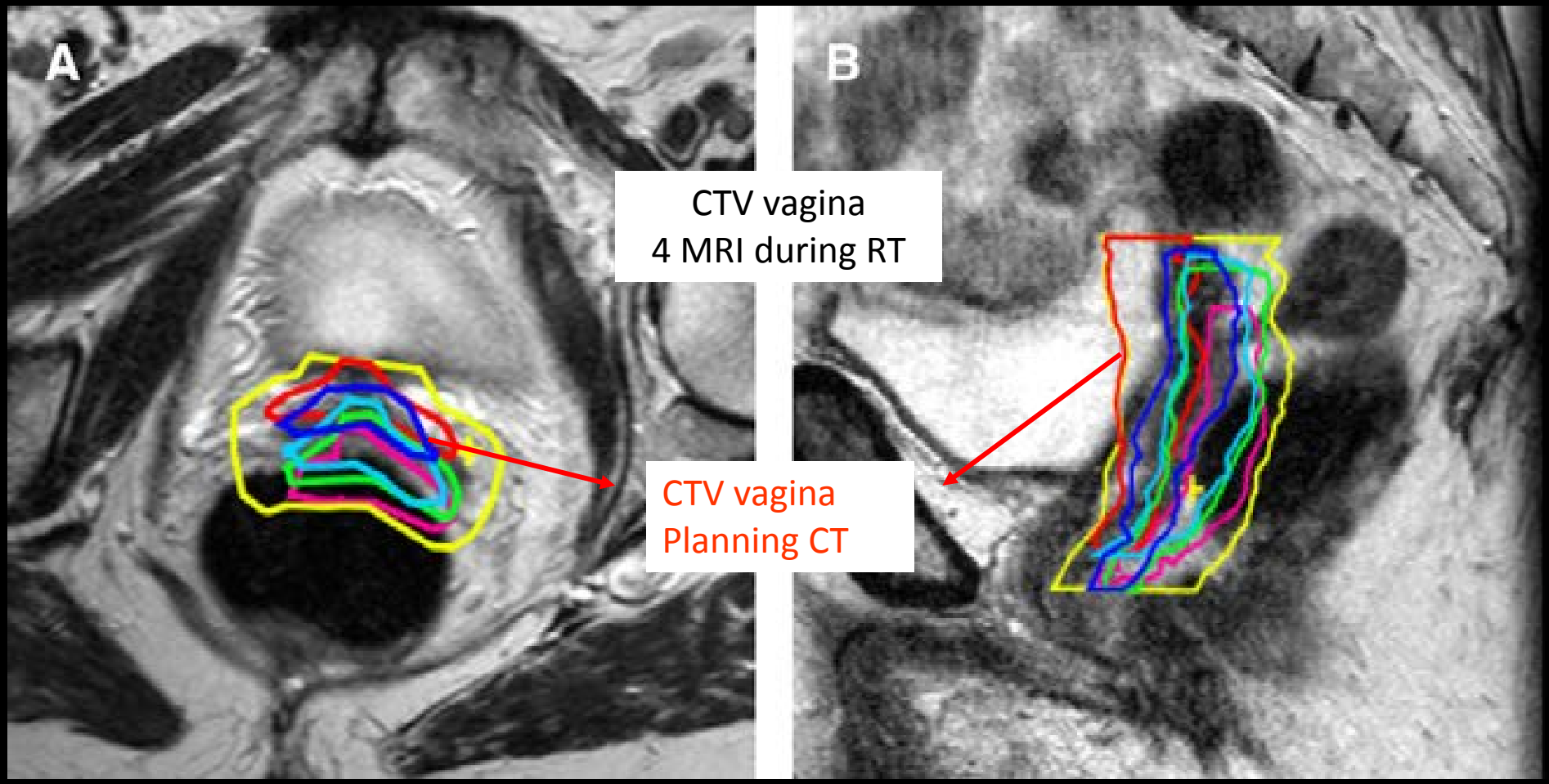

Jürgenliemk-Schulz et al. R&O; 2011;98:

Homogeneous margins?

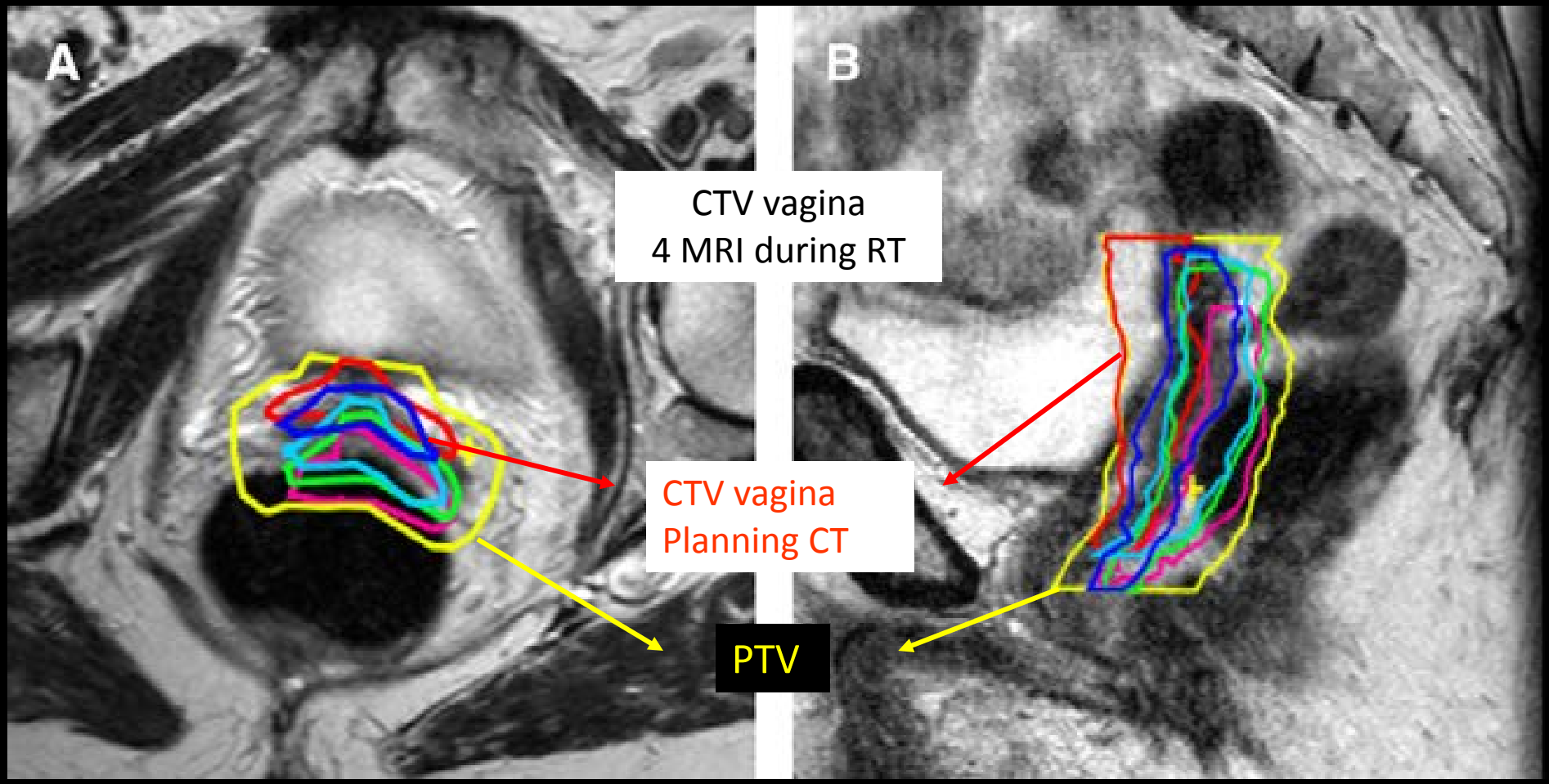

Jürgenliemk-Schulz et al. R&O; 2011;98:

Suggested margins:

To encompass 90% of the vaginal volumes:
- AP; 19 mm
- LR: 11 mm
- S(I): 15 mm

To encompass 95% of the vaginal volumes:
- AP: 23 mm
- LR: 18 mm
- S(I): 15 mm

Jürgenliemk-Schulz et al. R&O; 2011;98: 244-8.

What NOT to do!

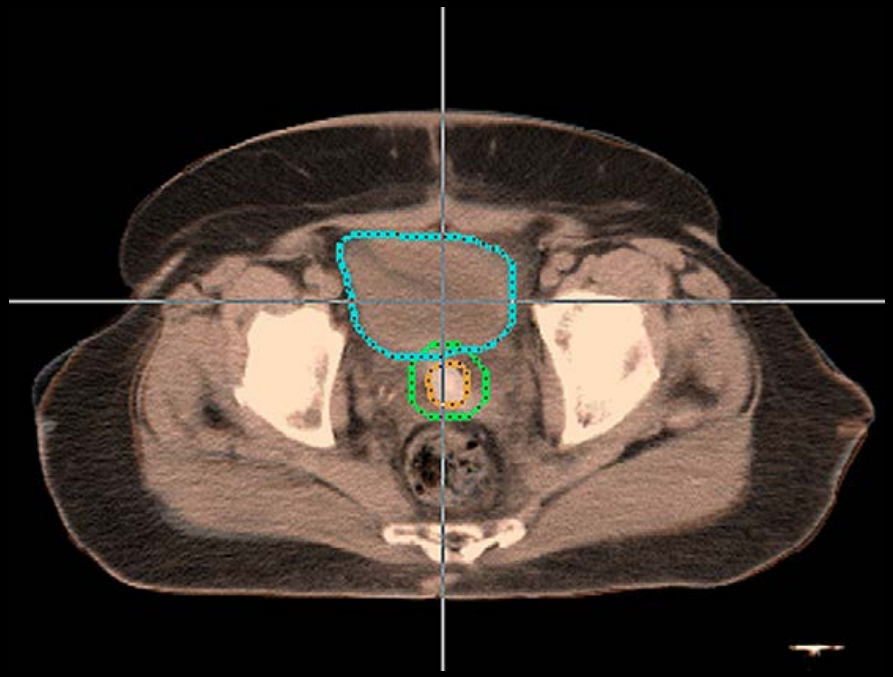

(a)

(b)

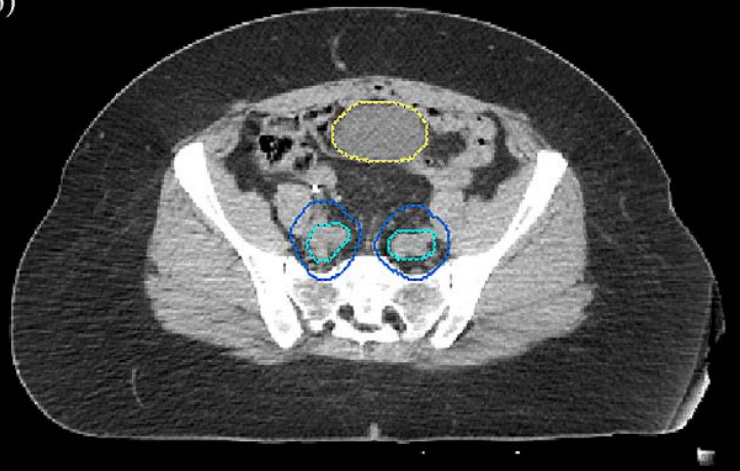

Take home messages:

Lymph nodes are similar to prostate LN areas

! Inguinal nodes are not part of the CTV, except in particular cases ...

Margins of >15 mm to ensure sufficient coverage of vaginal volumes

Point of discussion (future?)

PALN??

TICKETS

ESTRO Course: Target Volume Definition

Imaging for Determining the Gross Tumor Volume (GTV): Prostate Cancer

Stefan Delorme

dkfz. DEUTSCHES KREBSFORSCHUNGSZENTRUM IN DER HELMHOLTZ-GEMEINSCHAFT

Learning Objectives

- To understand prostate anatomy
- To comprehend the staging system for prostate cancer
- To appreciate potentials and shortcomings of imaging method for GTV delineation
  - CT
  - MRI
- To be aware of functional imaging modalities
  - Dynamic CE MRI
  - MRS
  - DWI
  - PET

dkfz.

Anatomy

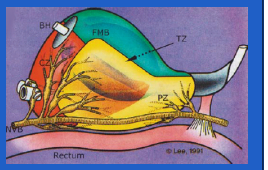

- Yellow: Peripheral gland
- Blue: Transitional zone
- Red: Central gland
- Green: Anterior fibromuscular zone

dkfz

CT above the bladder

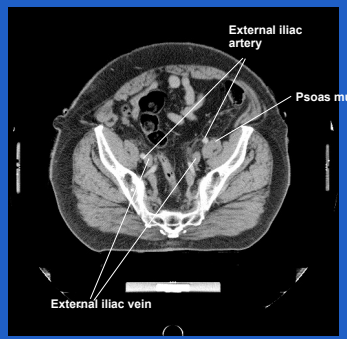

dkfz.

Roof of the bladder

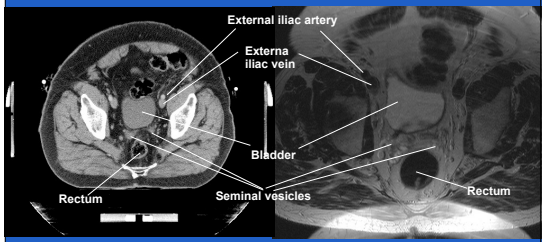

dkfz.

Floor of bladder I

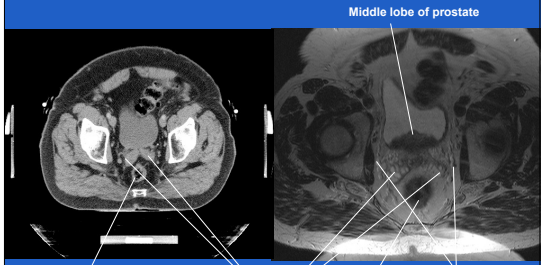

dkfz.

Floor of the bladder II

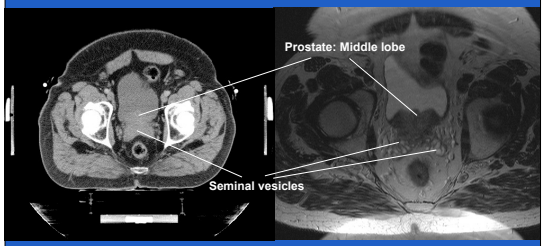

dkfz.

Prostate: Middle portion I

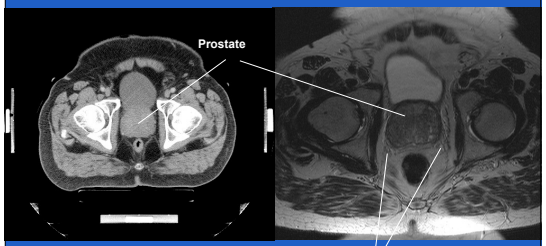

dkfz.

Prostate: Mittdle portion II

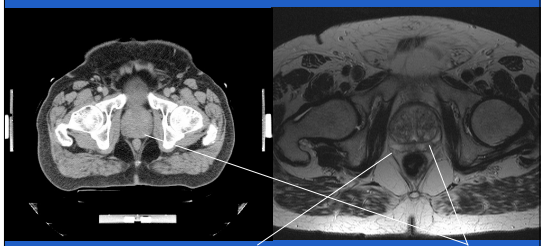

dkfz.

Prostate: Apex

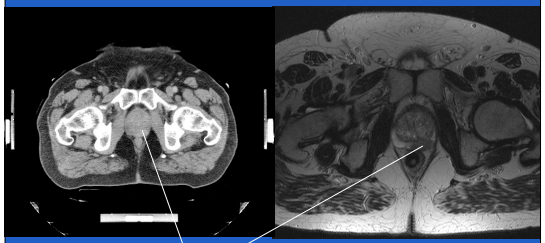

dkfz.

Anatomy of the Prostate: MRI

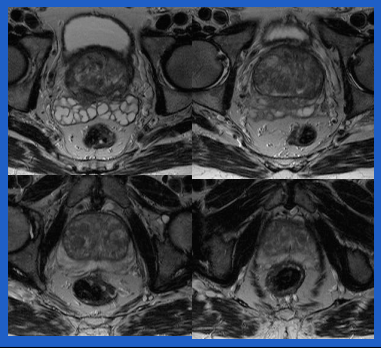

dkfz.

TNM Stages

- T1 Not palpable
  - T1a <5% of resected tissue involved
  - T1b > 5% of resected tissue involved
  - T1c Diagnosed by punch biopsy
- T2 Limited to prostate
  - T2a less than half lobe involved
  - T2b More than half lobe involved
  - T2c Bilateral tumour
- T3 Extracapsular extension
  - T3a Not involving seminal vesicles
  - T3b Involving seminal vesicles
- T4 Tumour fixed or invading other organs

dkfz.

CT

- T-Staging: Detection
  - T 1 – not palpable — not detectable
  - T 2 – confined to prostate — not detectable
  - T 3/4 – extracapsular extension: infiltration of seminal vesicles, neurovascular bundle, rectum, bladder — difficult
- Grading: not possible

➡ CT not the method of choice

dkfz.

MRI

dkfz.

Benign Hyperplasia

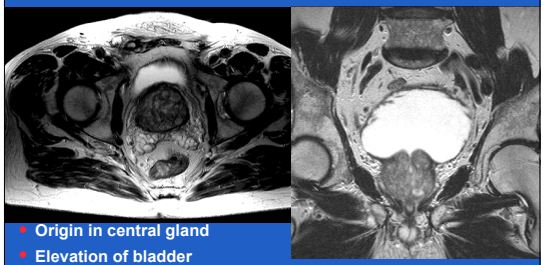

- Origin in central gland
- Elevation of bladder
- Protrusion of middle lobe
- Confined within capsule

dkfz.

Prostate Carcinoma

T2a	T2b	T2c
(<50% 1 lobe)	(>50% 1 lobe)	(both lobes)

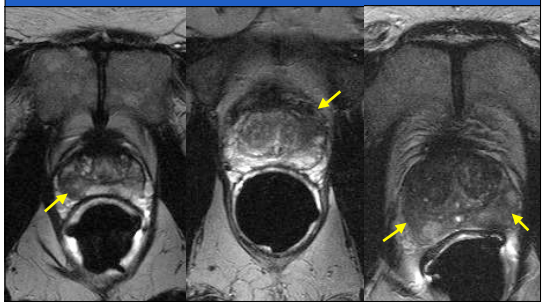

Prostate Carcinoma

T3b

extracapsular extension + infiltration of seminal vesicles

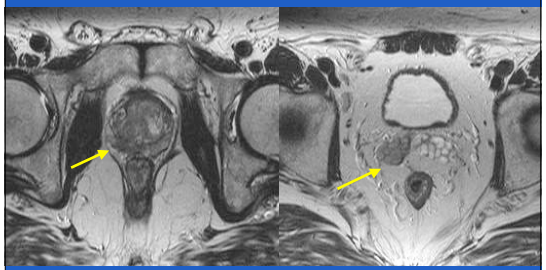

dkfz.

Extracapsular Extension

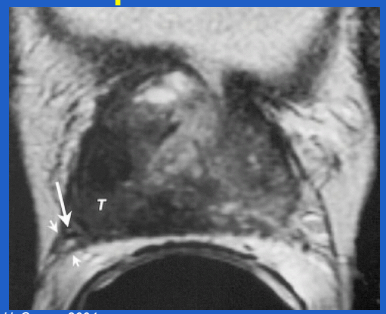

Hricak H, Cancer 2004

dkfz.

MRI

- T-Staging: Detection
  - T1 – not palpable — difficult
  - T 2 – confined to prostate — easily detectable
  - T 3/4 – extracapsular extension: infiltration of neurovascular bundle, seminal vesicles, rectum, bladder — superior to CT
- Grading: Characterization — not possible (yet?)

dkfz.

Reality

dkfz.

Where is the tumour?

T2w MRI | Histology

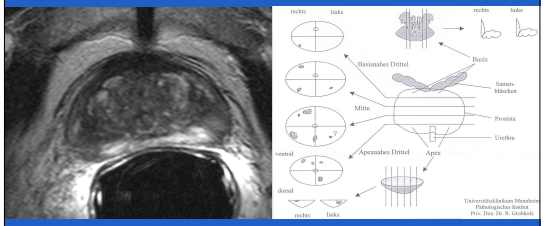

dkfz.

Differential Diagnosis

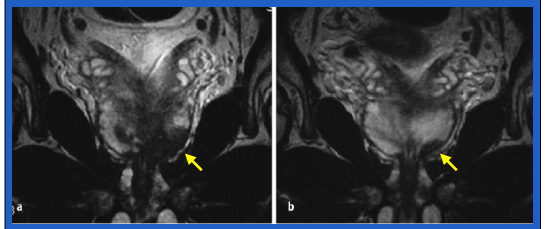

Chronic Prostatitis:
Low intensity areas decreased after 3 months of antibiotics

dkfz.

Extracapsular Extension

Presurgical Variable	Sensitivity	Specificity
Serum PSA level*	27.7 (23/83)	87.4 (228/261)
Gleason score†	30.1 (25/83)	90.4 (236/261)
Clinical stage of tumor‡	56.6 (47/83)	60.9 (159/261)
Greatest percentage of cancer in all core biopsy specimens§	36.1 (30/83)	89.6 (232/259)
Percentage of cancer-positive core specimens in all core biopsy specimens§	35.0 (28/80)	81.0 (196/242)
PNI presence at needle biopsy‖	25.3 (21/83)	89.7 (234/261)
Endorectal MR imaging findings#	42.2 (35/83)	95.4 (249/261)

Wang L, Radiology 2004

dkfz.

Lymph node drainage

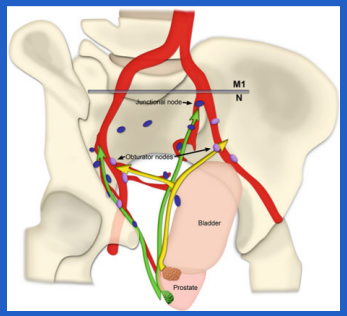

Yellow: Lateral route
-> External iliac LN

Green: Hypogastric route
-> Internal iliac LN

dkfz.

Obturator lymph nodes

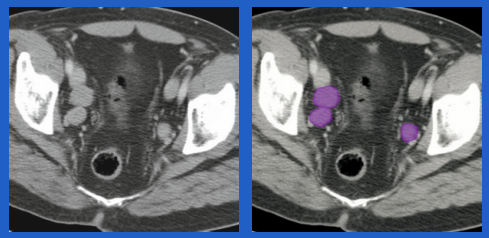

dkfz.

Obturator lymph node

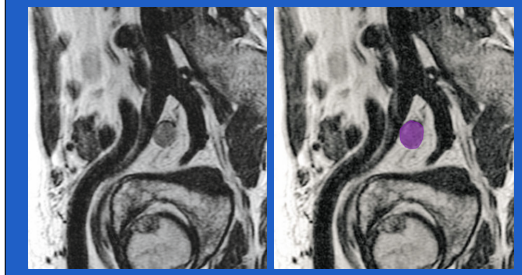

dkfz.

External iliac lymph node

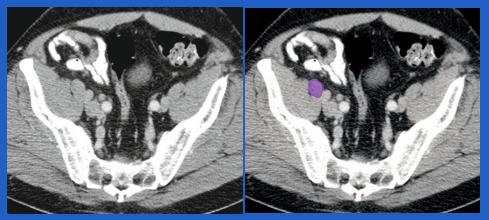

dkfz.

Internal iliac lymph node

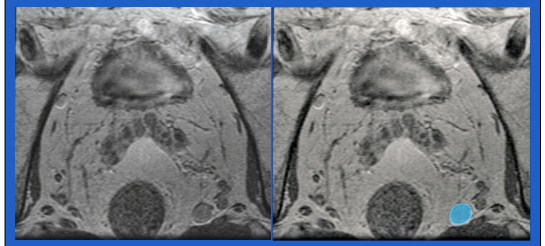

dkfz.

Presacral lymph node

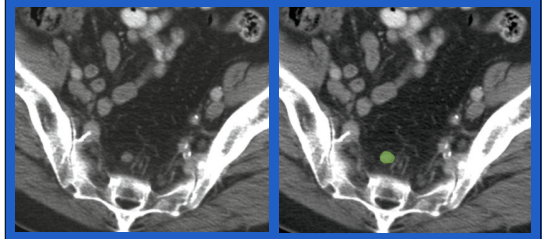

dkfz.

Common iliac lymph node: M1

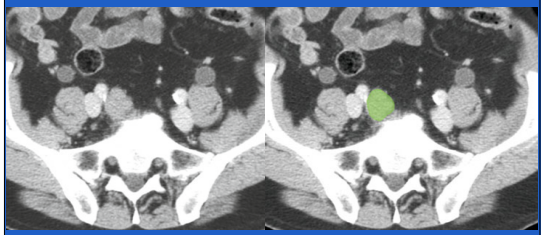

dkfz.

Accuracy for lymph node metastases

50 : 50

dkfz.

Possible remedies

dkfz.

Dynamic, contrast-enhanced MRI

- Description of signal time curve
- Pharmacokinetic 2-compartmental model

Prostate carcinoma

Benign hyperplasia

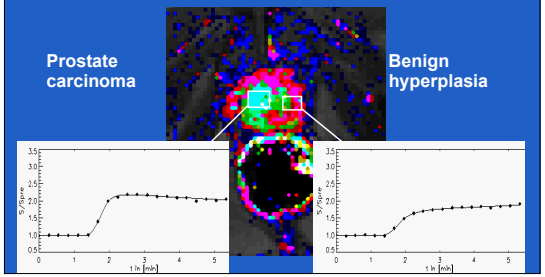

High-resolution Contrast MRI

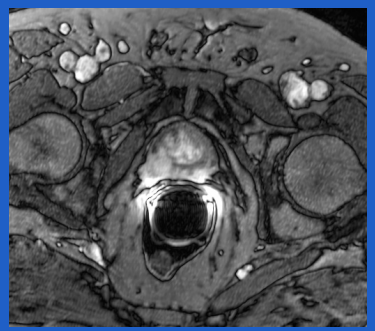

dkfz.

Spectroscopy

- Metabolites:
  - Choline (Cho) = Proliferation marker
  - Citrate (Ci), produced by prostatic cell = specific marker for vital glandular tissue
  - BPH: Citrate moderately decreased
  - Carcinoma: Citrate decreased, choline increased

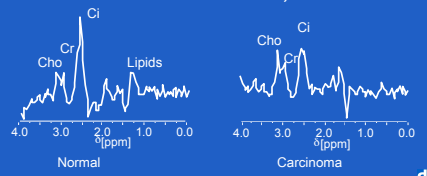

dkfz.

MRS in prostate cancer

- Grading/Characterization: MR Spectroscopy

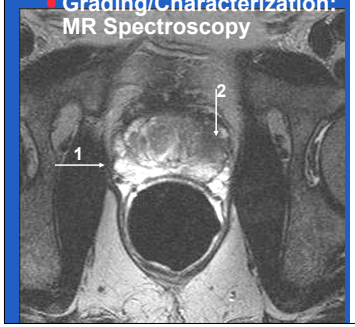

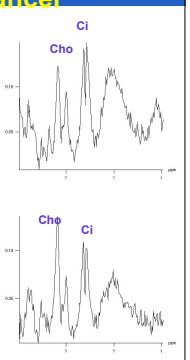

Results

Author	n	Sens [%]	Spec [%]	Method
Scheidler J 1999	52	77 - 81	41 - 61	T2
		63	75	MRS
Ito H 2003	111	87	74	dyn. MRI, peripheral
		68	87	dyn. MRI, central
Müller-Lisse U 2003	Review	80	80	T2 + MRS
Yuen JS 2004	24	57	88	T2
		57	82	MRS
		100	70	T2+ or MRS+

dkfz.

Prostate carcinoma: T2

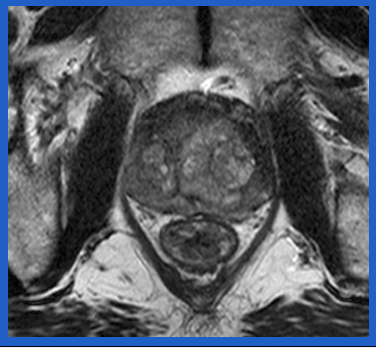

dkfz.

Prostate carcinoma: DCE-MRI

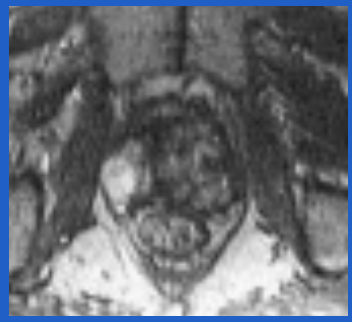

dkfz.

Prostate carcinoma: DWI

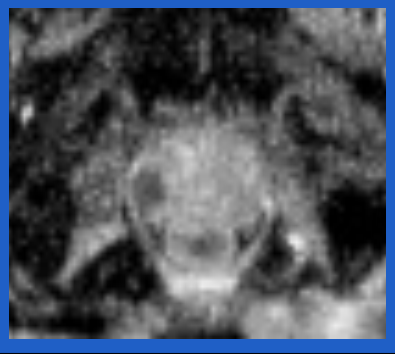

dkfz.

FDG-PET

- T-Staging: Detection
- Sensitivity localized disease 67%
  advanced disease 92%
- Limitations
  - Low glucose uptake
  - Large overlap between tumor and benign hyperplasia
  - Renal excretion of FDG into the bladder

Grosu A, Strahlenther Onkol 2005

dkfz.

Choline PET

- Better than FDG-PET
- Still overlap between tumor and benign hyperplasia
- N-Staging
  - Sensitivity 80%,
  - Specificity 96%
  - CT+MRI: Sensitivity 47%, specificity 98%

dkfz.

PSMA PET

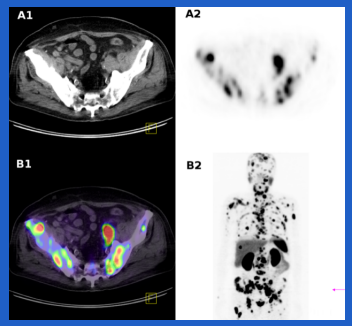

Eder M et al. Bioconjugate Chem 2012; 23: 688-697.
Afshar-Oromieh A et al. Eur J Nucl Med Mol Imaging 2013; 40: 486-495.

dkfz.

New methods - new love

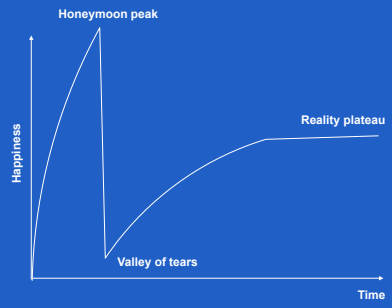

dkfz.

Difficult cases

dkfz.

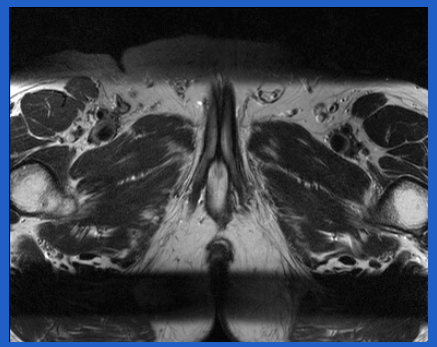

dkfz.

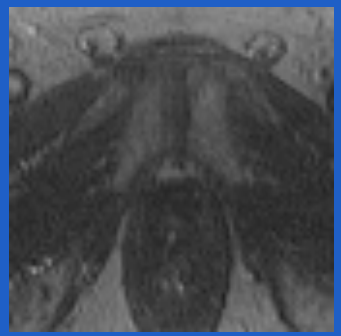

dkfz.

Carcinoma T3b

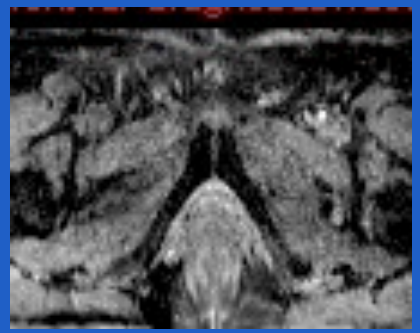

dkfz.

Missing the forest
because of all the trees

dkfz.

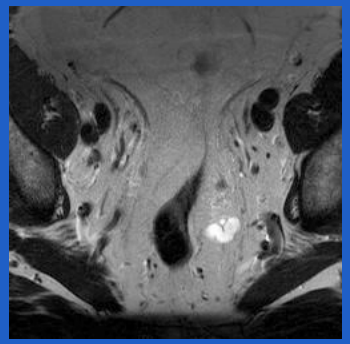

dkfz.

Ventral prostate carcinoma

dkfz.

Needle in a haystack

dkfz.

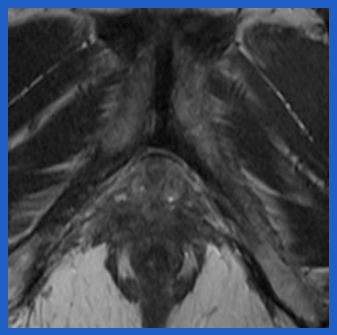

dkfz.

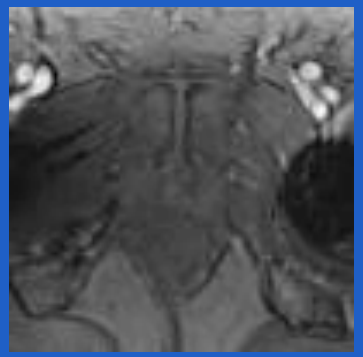

dkfz.

Very small carcinoma

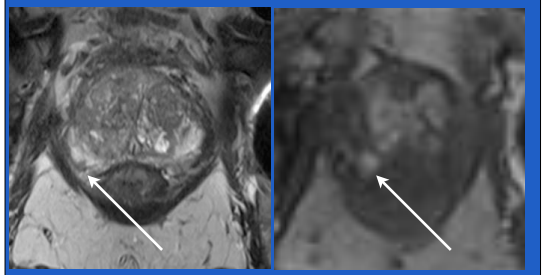

dkfz.

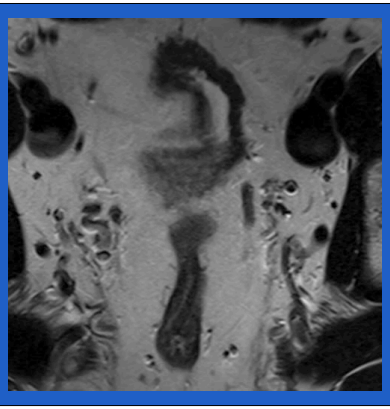

dkfz.

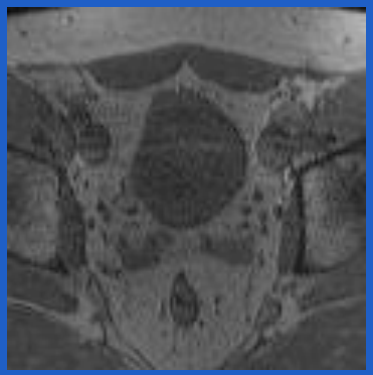

dkfz.

Central prostate carcinoma

dkfz.

Mimickry

dkfz.

Response assessment: What we would expect

- T2: Reduced conspicuity
  - Loss of tumor mass
  - Reduced water content of peripheral zone
- DCE MRI: Reduction of CM uptake
  - Decreased angiogenesis
  - ... But counteracted by inflammation
- DWI: Reduced conspicuity, increase in ADC
  - Loss of cellular density
  - ... But contaminated by T2 effects

dkfz.

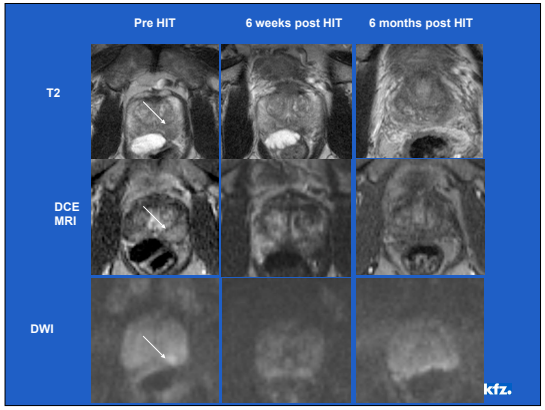

T2 pre and post radiation

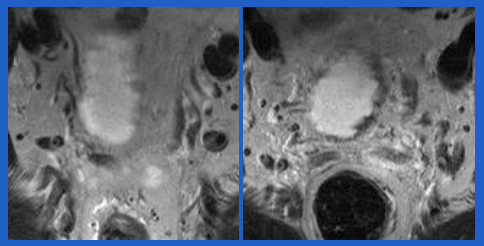

dkfz.

DWI pre and post radiation

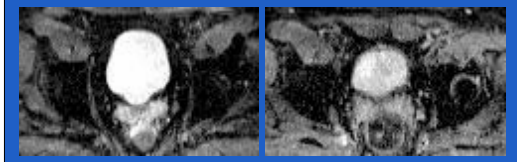

dkfz.

Radiation-induced changes

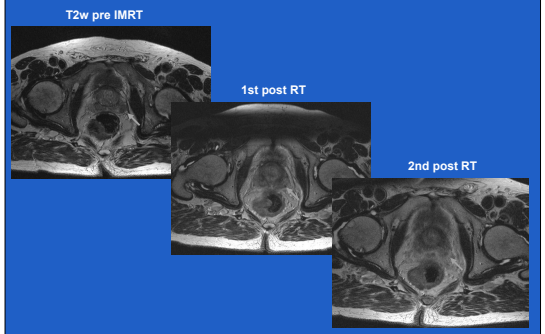

Oncological Guidelines: Imaging

- CT of the abdomen
- MRI of the pelvis
- Chest x-ray if PSA > 20 ng/ml, or high risk patients
- Bone scintigraphy if PSA > 10 ng/ml

dkfz.

Take home

- CT is limited for
  - T-stage
  - Extracapsular extension
  - N-stage
- MRI method of choice for
  - T-stage
  - Extracapsular extension
  - Localization of leading tumor mass, if present
- PET requires dedicated tracers for improved T- and N-staging
  - C-11 Choline
  - Ga 68 PSMA

s.delorme@dkfz.de, Radiologie – E010, Innovative Krebsdiagnostik und -therapie

dkfz.

Volume of interest: GTV=CTV

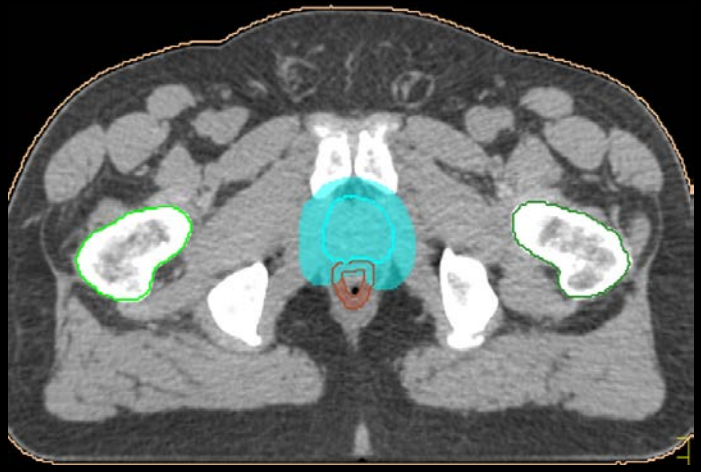

Prostate (CTV)

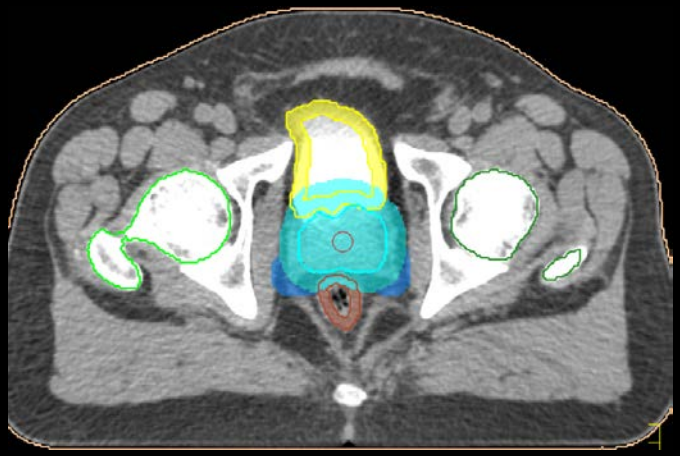

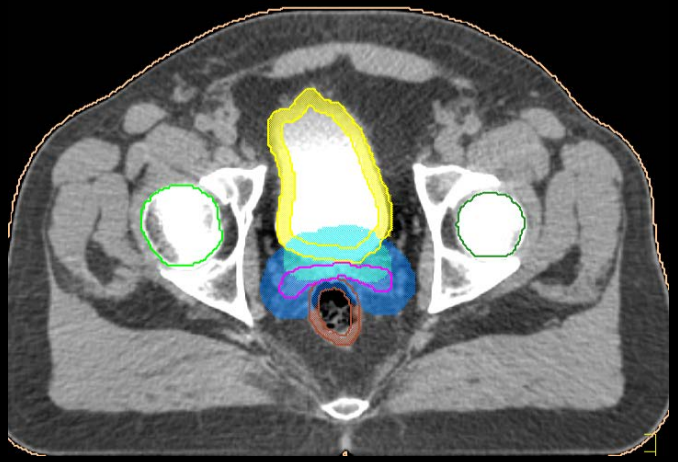

SV (CTV)

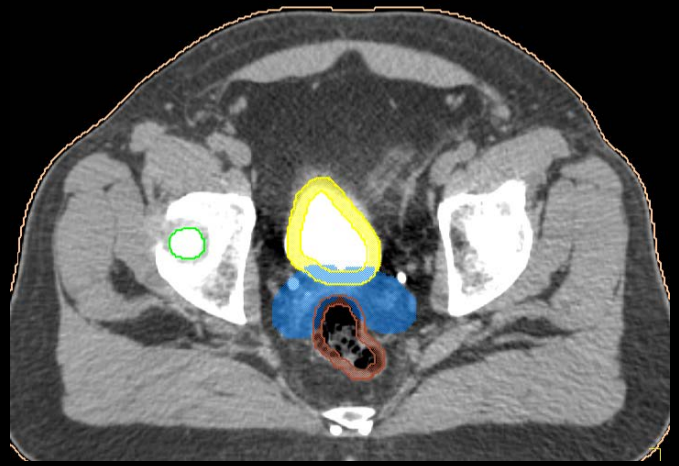

MRI for prostate delineation

CT scan over-estimates the apex

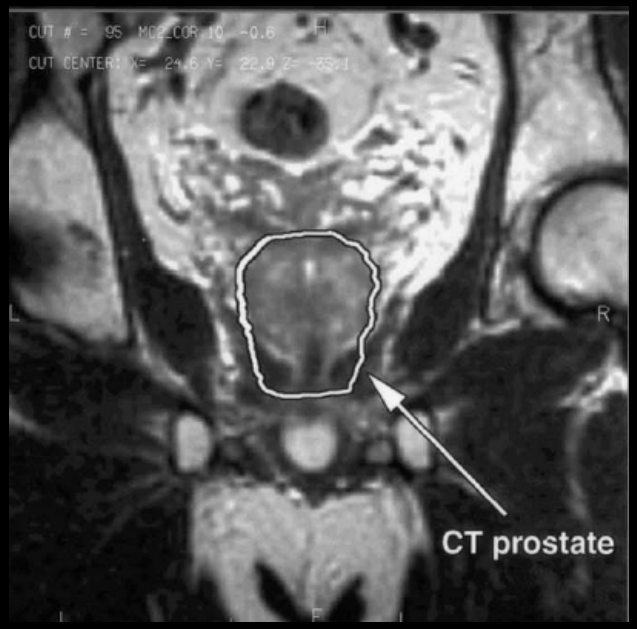

MRI for prostate delineation

CT scan over-estimates the apex

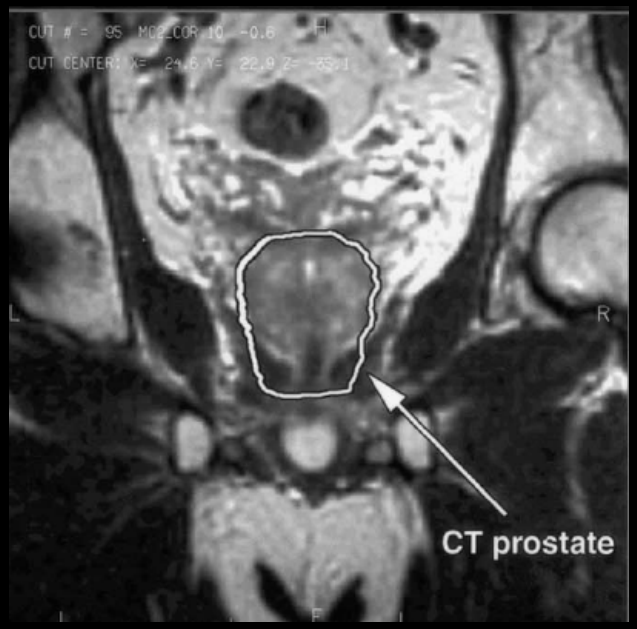

Prostate reference imaging = MRI

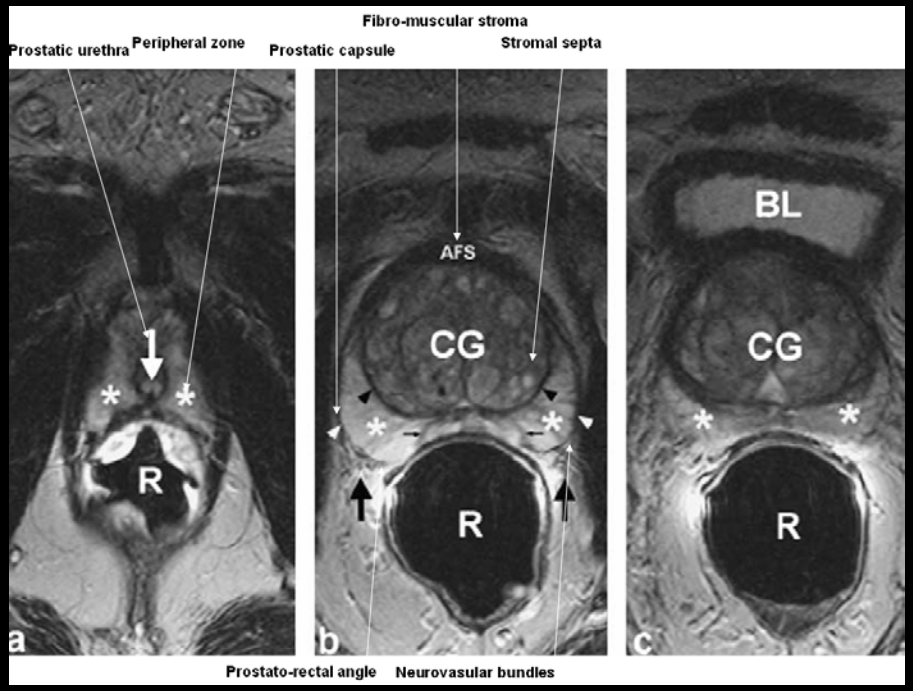

➔ **MRI used for delineation however need for MRI to CT registration tool**

MR in radiotherapy: Debois IJROBP 1999; 45: 857-865.

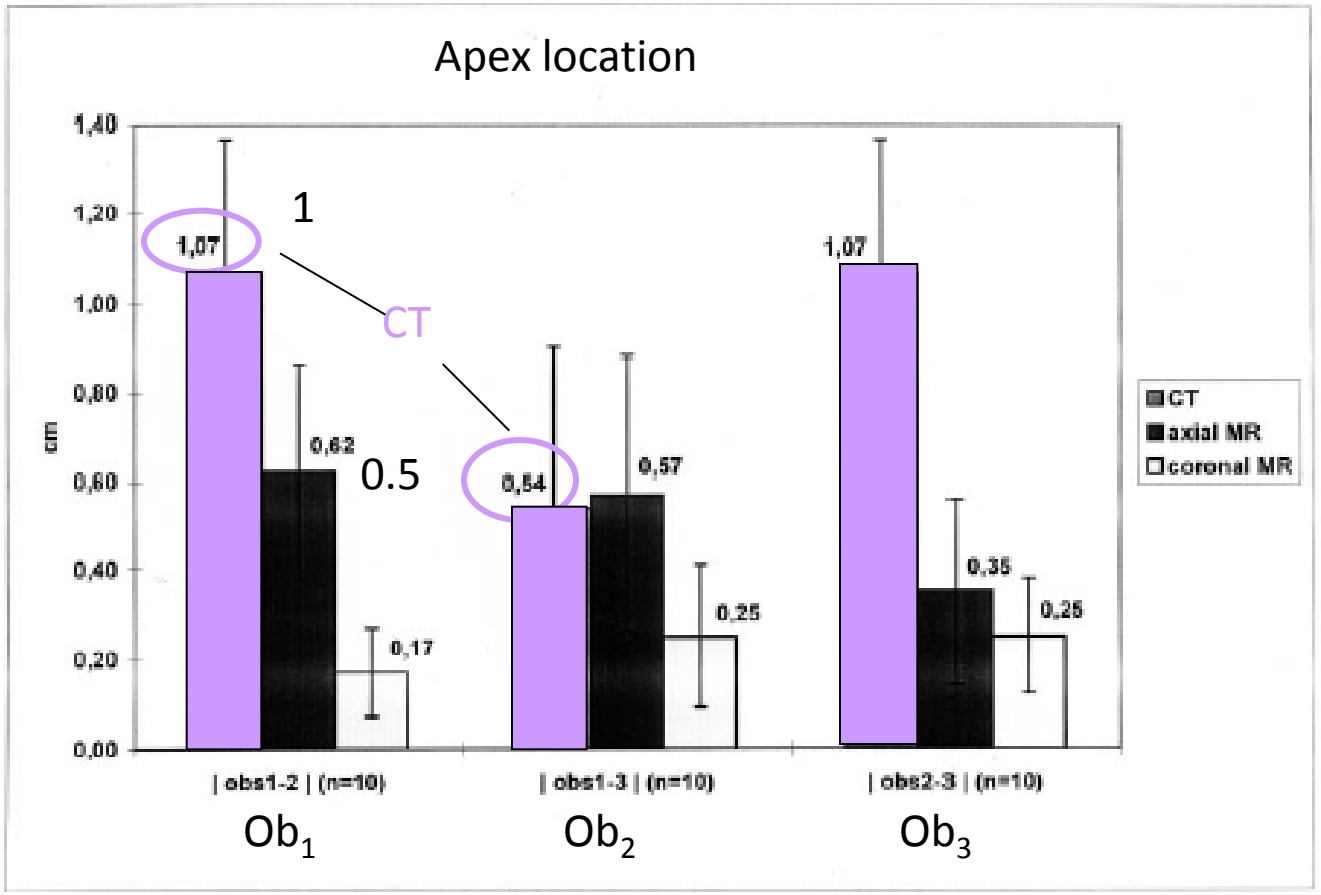

Fig. 3. Mean over the 10 patients of the absolute pairwise difference of the apex location for the different image modalities: CT (left column), axial (middle column), and coronal MR (right column).

MR in radiotherapy: Debois IJROBP 1999; 45: 857-865.

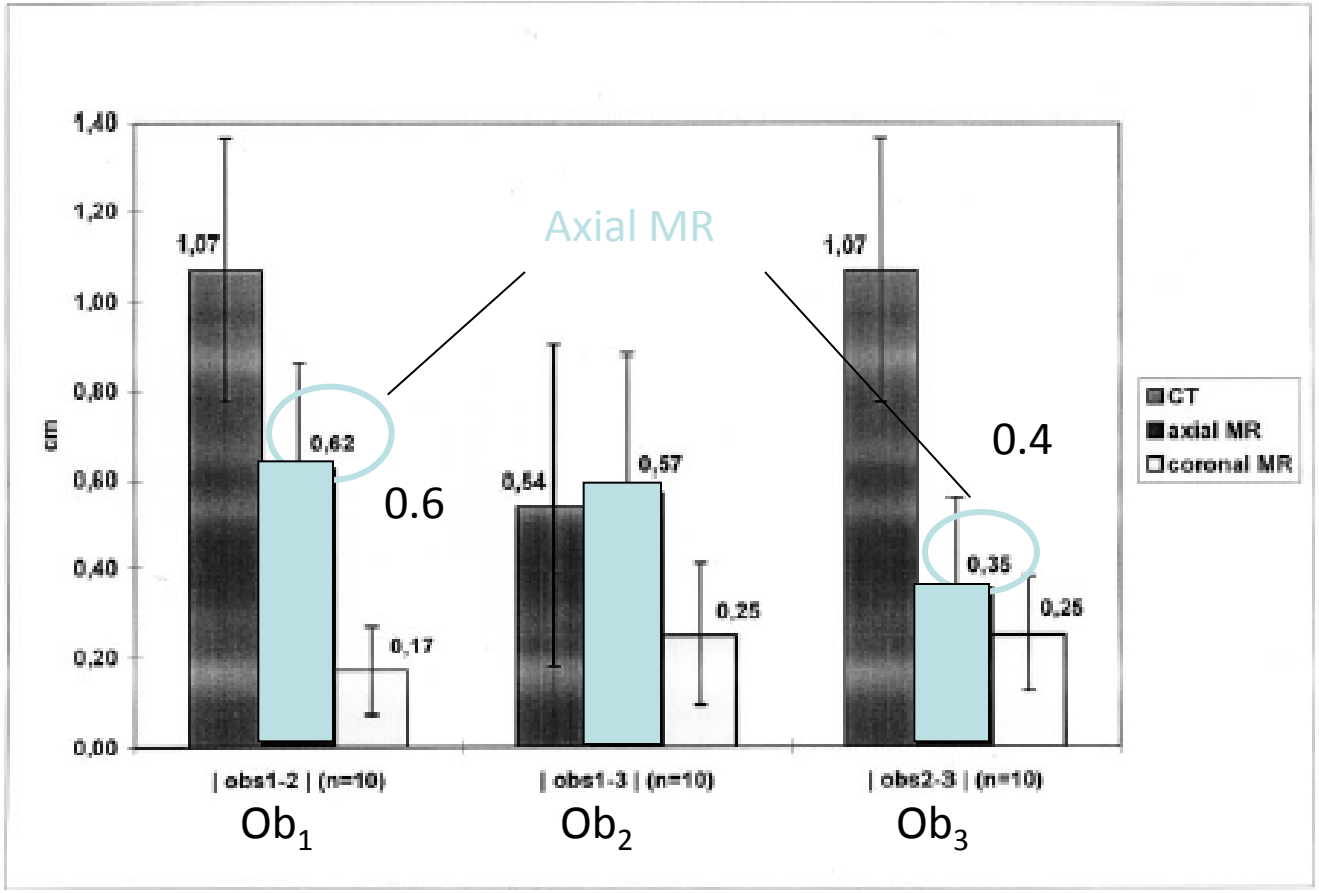

Fig. 3. Mean over the 10 patients of the absolute pairwise difference of the apex location for the different image modalities: CT (left column), axial (middle column), and coronal MR (right column).

MR in radiotherapy: Debois IJROBP 1999; 45: 857-865.

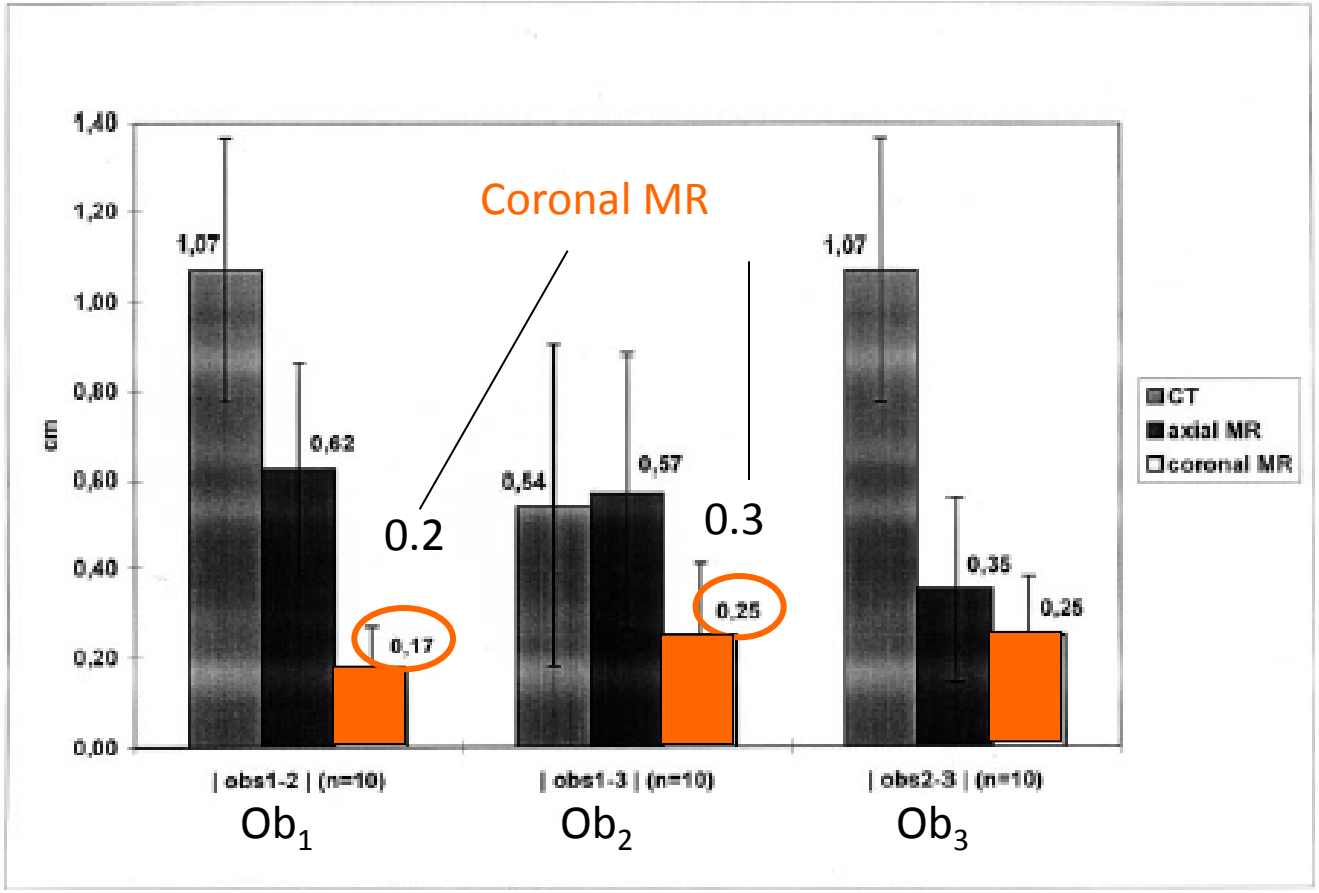

Fig. 3. Mean over the 10 patients of the absolute pairwise difference of the apex location for the different image modalities: CT (left column), axial (middle column), and coronal MR (right column).

MR in radiotherapy: Debois IJROBP 1999; 45: 857-865.

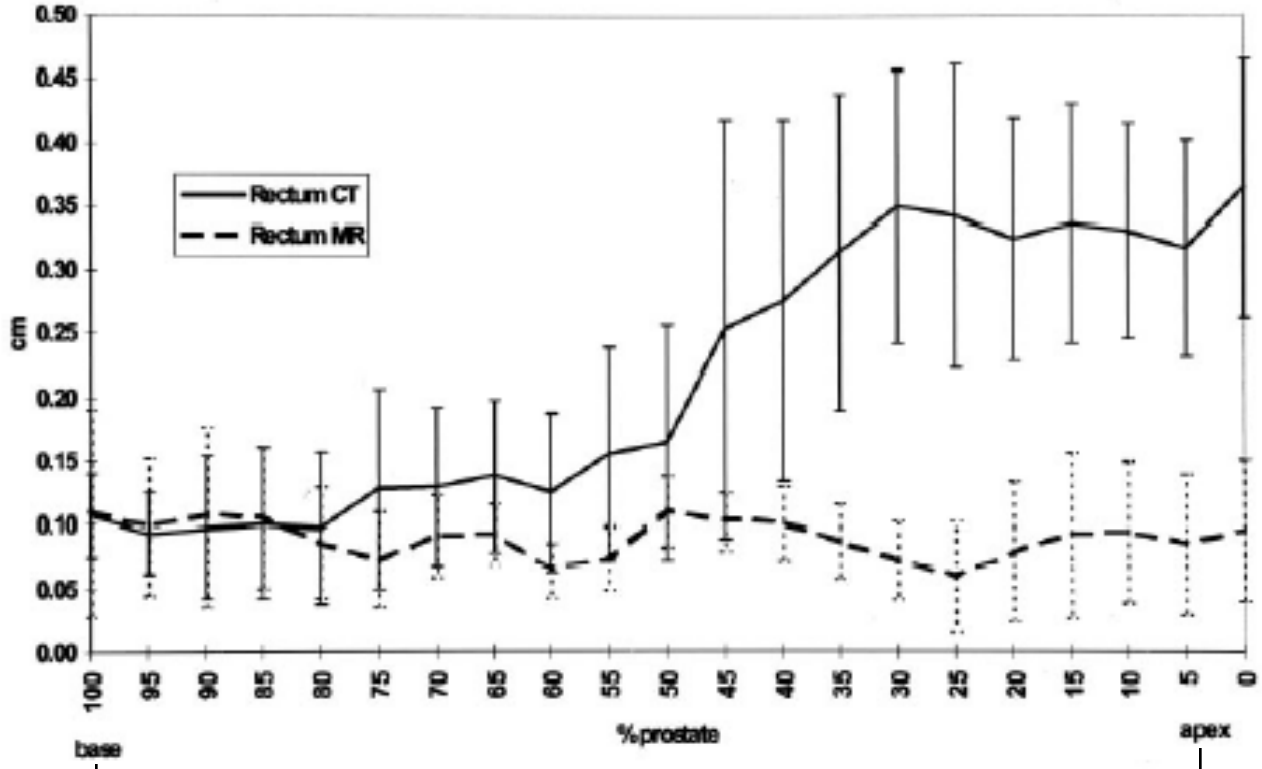

Fig. 5. Interobserver variation of the delineation of the anterior aspect of the rectal wall in CT and axial MR. 100% is the base and 0% the apex of the prostate.

base

apex

CT



MRI



CT

MRI

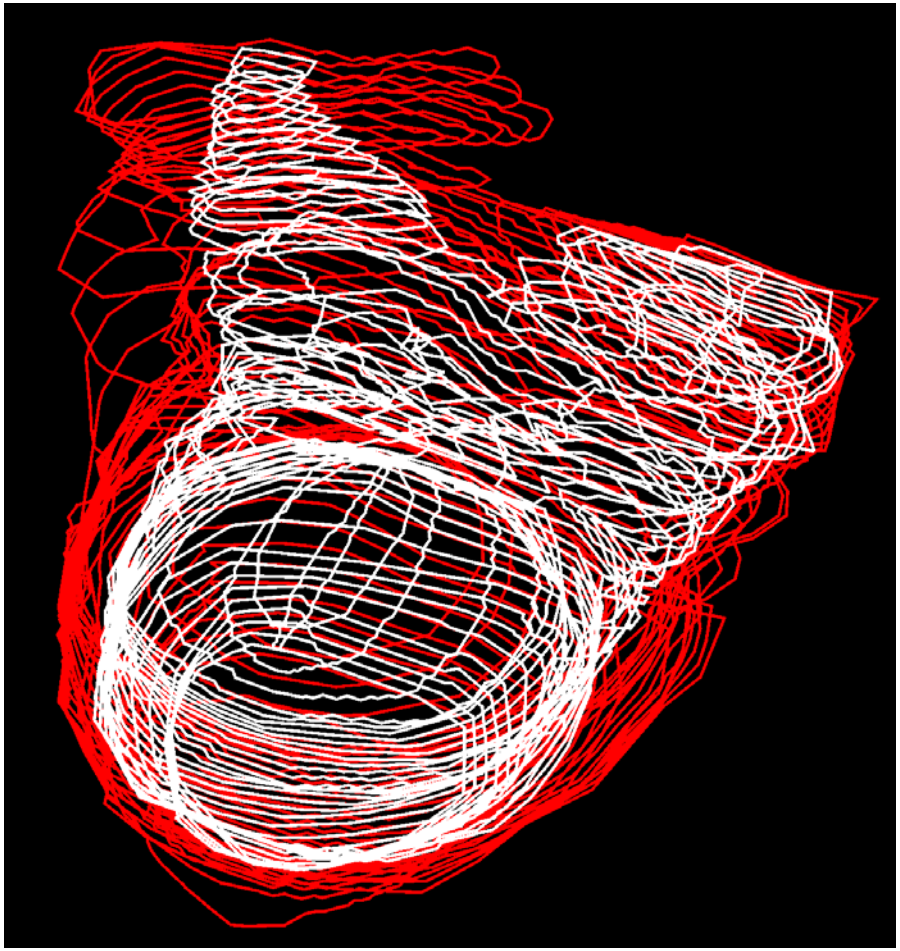



Don’t forget the basics

ANATOMIC VARIATIONS: clinical impact

MDACC study

127 pts

Total dose = 78 Gy

➔ population divided in 2 parts according to median rectal volume values

ANATOMIC VARIATIONS: clinical impact

MDACC study

127 pts

Total dose = 78 Gy

➔ population divided in 2 parts according to median rectal volume values

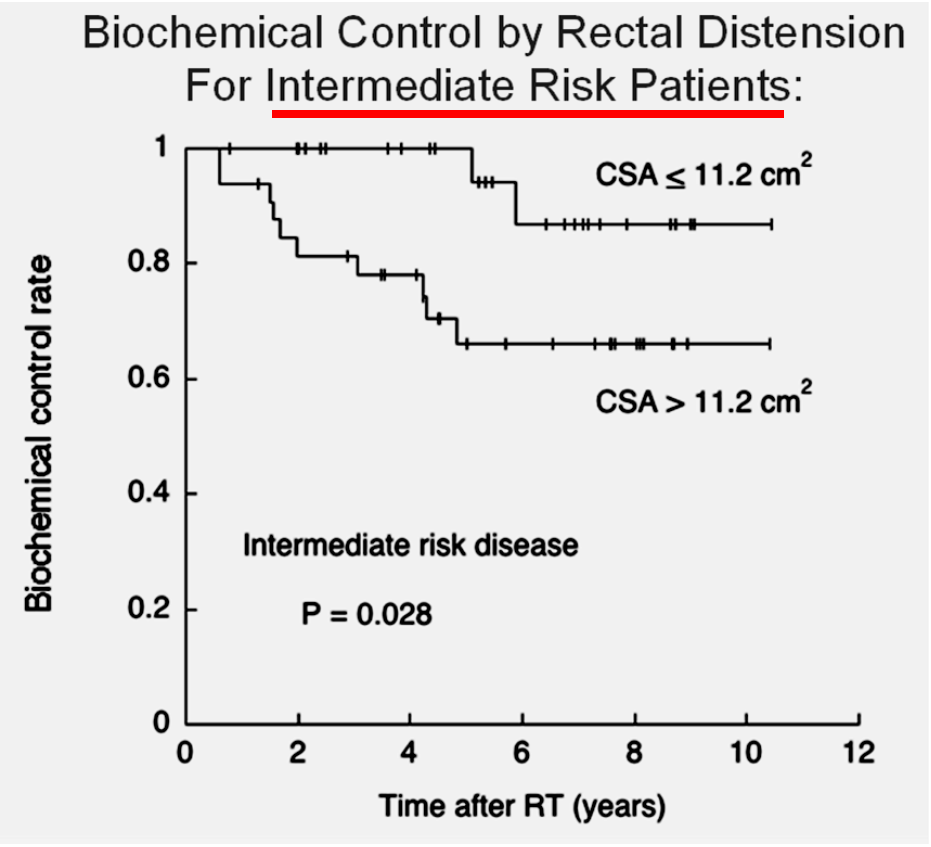

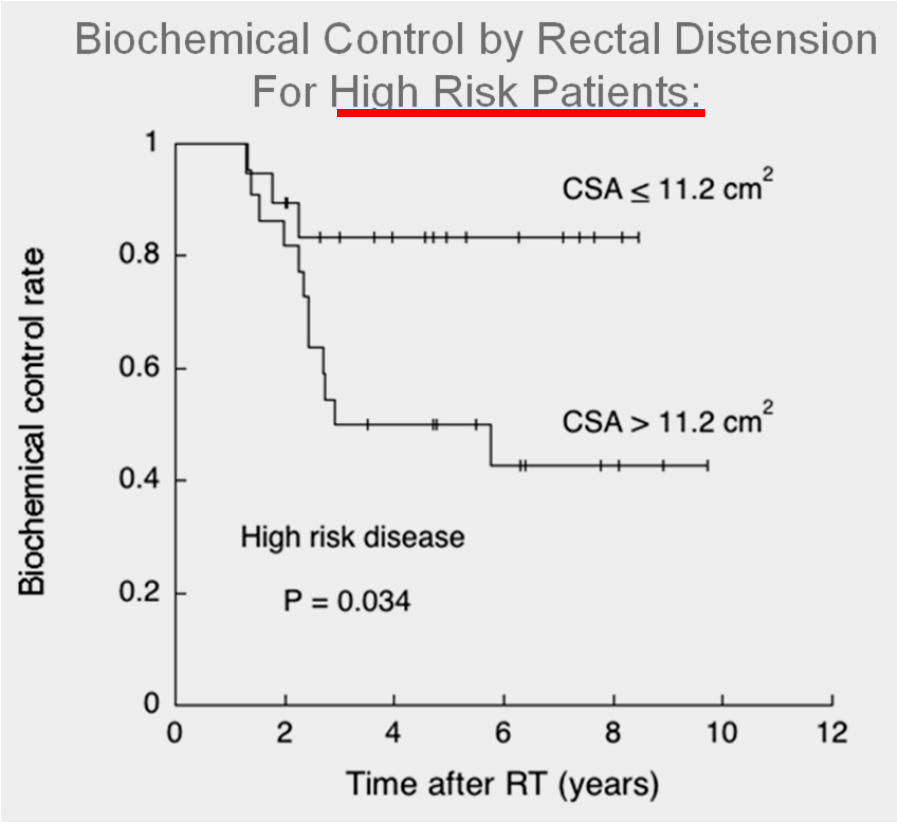

ANATOMIC VARIATIONS: clinical impact

MDACC study

Biochemical failure

(Multivariate Analysis)

Risk Factor	Hazard Ratio	P
High risk Disease (T,Gleason, PSA)	2.45	0.016
Rectal distension on the planning CT (> median value)	3.89	0.003

ANATOMIC VARIATIONS: clinical impact

MDACC study

Biochemical fai

(Multivariate A

Risk Factor	d Ratio	P
High risk Disease (T,Gleason, PSA)	2.45	0.016
Rectal distension pla (> me alue)	3.89	0.003

Confirmed by Engels et al. IJROBP 2009
Confirmed by Engels et al. RO 2014

ANATOMIC VARIATIONS: clinical impact

MDACC study

Predicted probability of tumor without any treatment effect in 2-yr biopsy as a function of CSA:

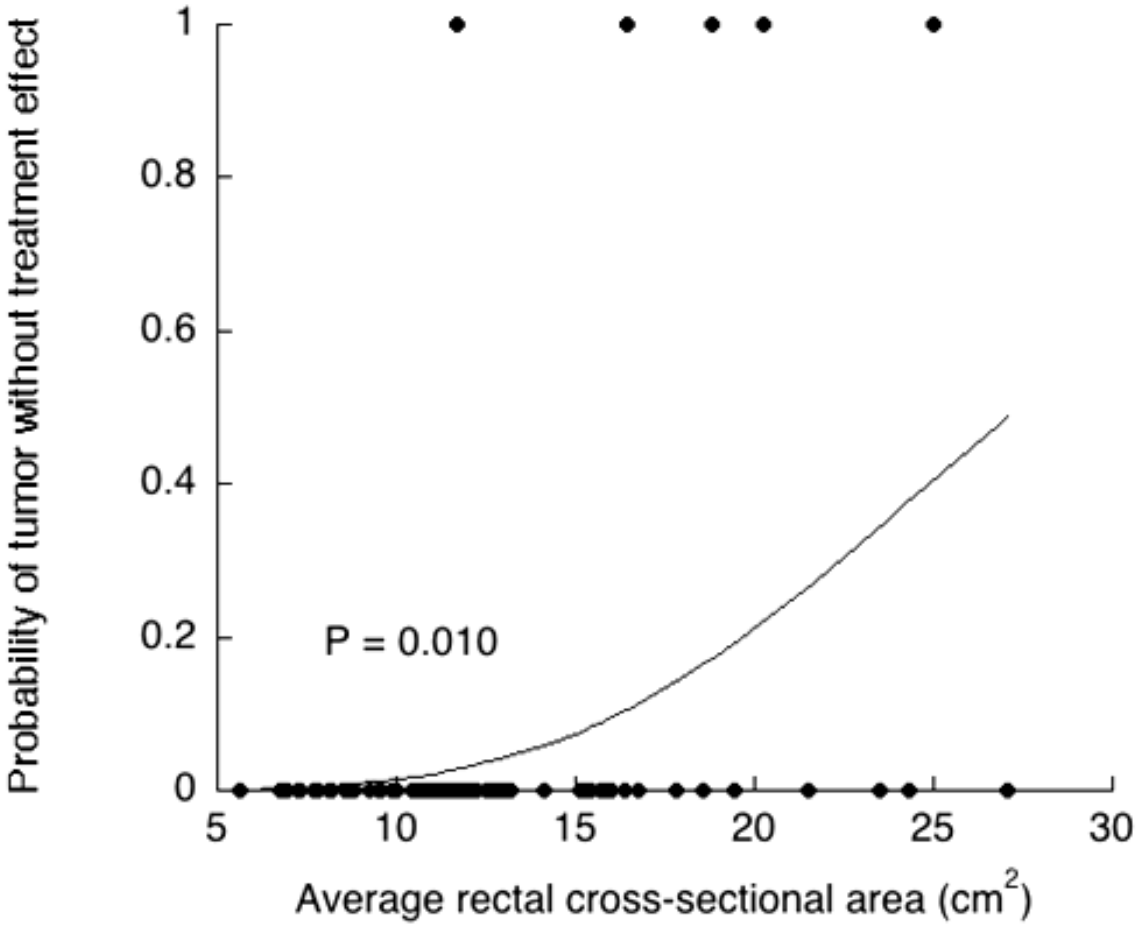

Positive biopsy

Rectal distension

What if no MRI?

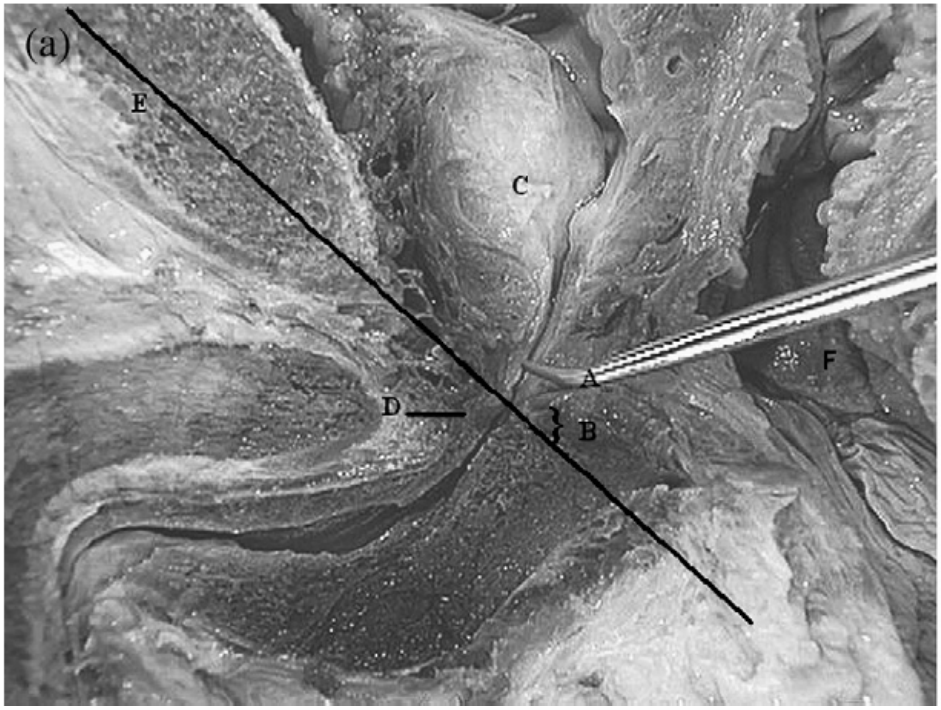

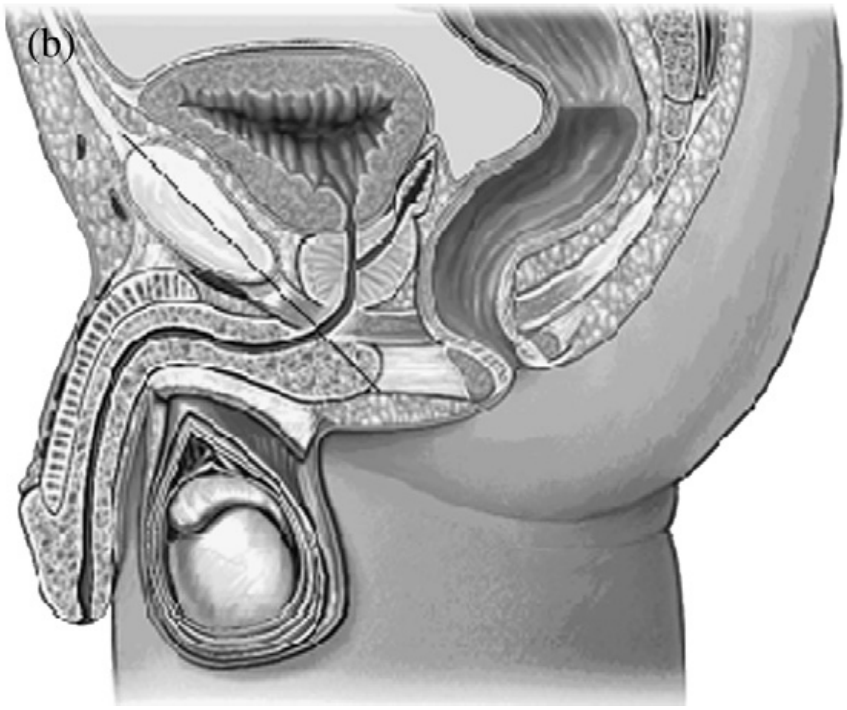

Organs at risk

-Rectum: straightforward

- Bladder: not straigthforward (Dmax<80 Gy)

- Femoral heads (Dmax<70 Gy)

- Sigmoid colon (=R)

- Small intestine (Dmax <70 Gy)

Late radiotherapy-induced lower intestinal toxicity (RILIT) of intensity-modulated radiotherapy for prostate cancer: The need for adapting toxicity scales and the appearance of the sigmoid colon as co-responsible organ for lower intestinal toxicity☆

Valérie Fonteyne[a,*], Wilfried De Neve[a], Geert Villeirs[b], Carlos De Wagter[a], Gert De Meerleer[a]

Organs at risk

-Rectum: straightforward

- Bladder: not straigthforward (Dmax<80 Gy)

- Femoral heads (Dmax<70 Gy)

- Sigmoid colon (=R)

- Small intestine (Dmax <70 Gy)

The Incidence of Inclusion of the Sigmoid Colon and Small Bowel in the Planning Target Volume in Radiotherapy for Prostate Cancer

Gert O. De Meerleer , Geert M. Villeirs, Luc Vakaet, Louke J. Delrue, Wilfried J. De Neve

Strahlenther Oncol 2006

60% !!!

20% !!!

« Ghost » volumes

to avoid hot spot in non-delineated healthy tissue at the inverse planning

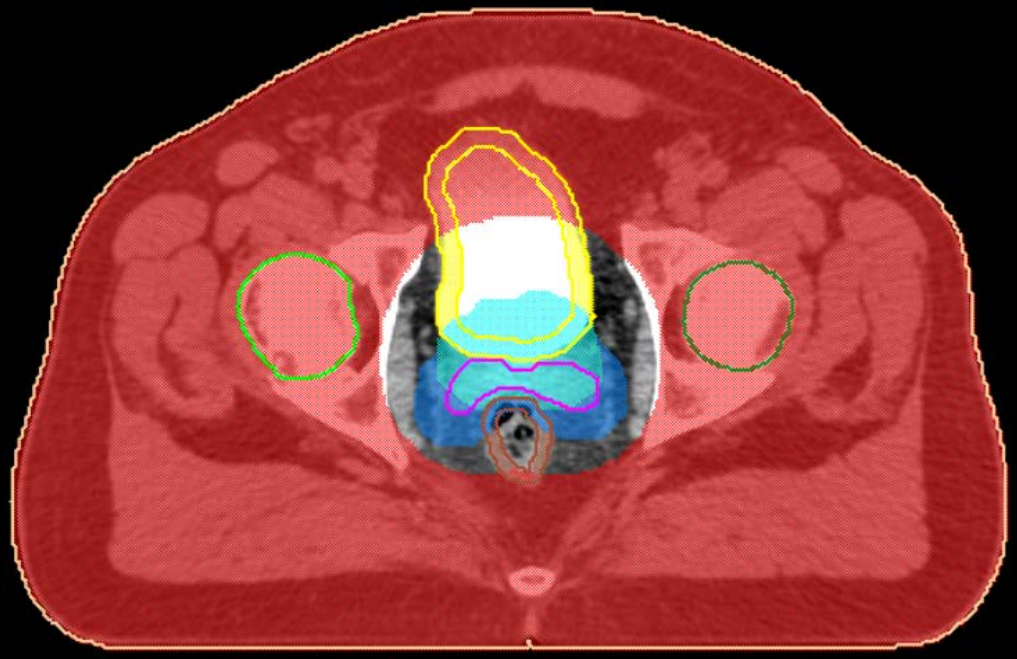

Healthy tissue

= external cont –(PTV+2cm)

CTV-PTV margin (from measurements)

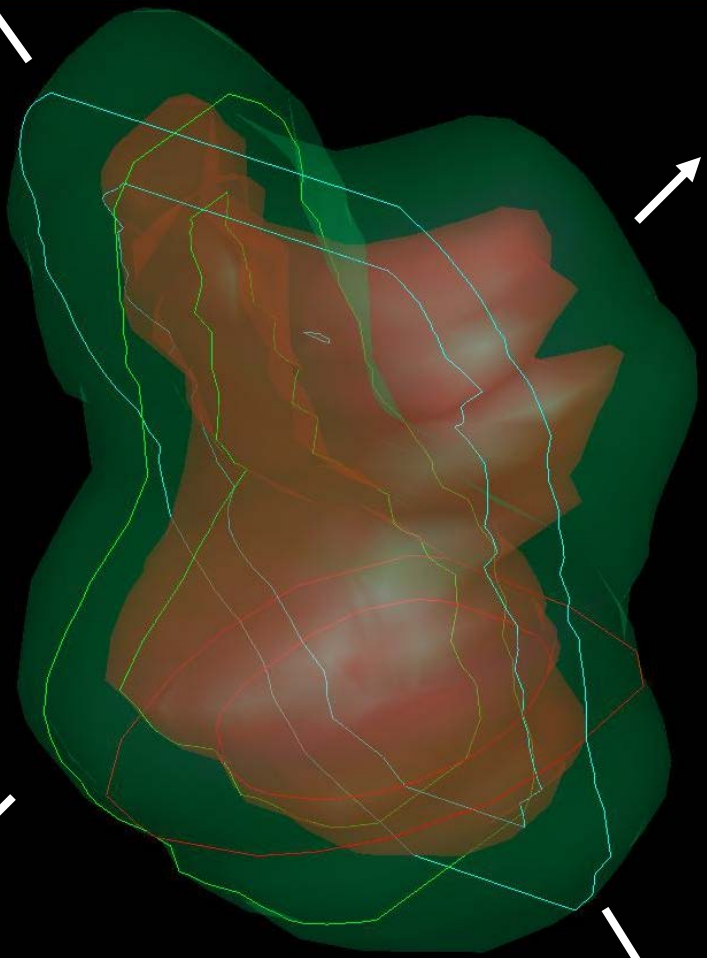

Sup = 7-10 mm

Post = 8-10 mm

WITHOUT IGRT (bone)

Lat = 5-8 mm

Ant = 8-10 mm

Inf = 7-10 mm

Is IGRT suggorate for margin reduction?

	Group 1 (n=25)	Group 2 (n=25)	
LR margin	3 mm	6 mm	
AP margin	5 mm	6 mm	
SI margin	4 mm	6 mm	
FFBF @ 5 years	74%	96%	P=0.04

Engels, Radiother Oncol, 2014

Is IGRT suggorate for margin reduction?

	Group 1 (n=25)	Group 2 (n=25)	
LR margin	3 mm	mm	
AP margin	5 mm		
SI margin		6 mm	
FFBF @ 5 years		96%	P=0.04

NO !!

Engels, Radiother Oncol, 2014

CTV-PTV margin

More margins for the SV ion)

Sup = 7-10 mm

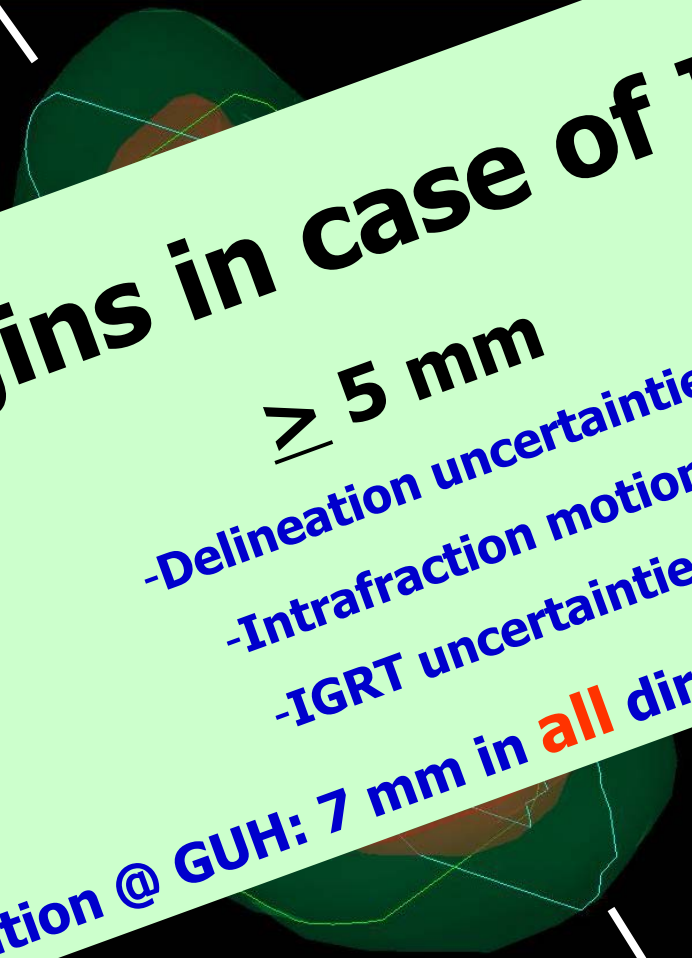

Ant = 8-1

Inf = 7-10 mm

➔ margins in case of IGRT

≥ 5 mm

-Delineation uncertainties

-Intrafraction motion

-IGRT uncertainties

-Situation @ GUH: 7 mm in all directions, daily CBCT

The future of EBRT ?

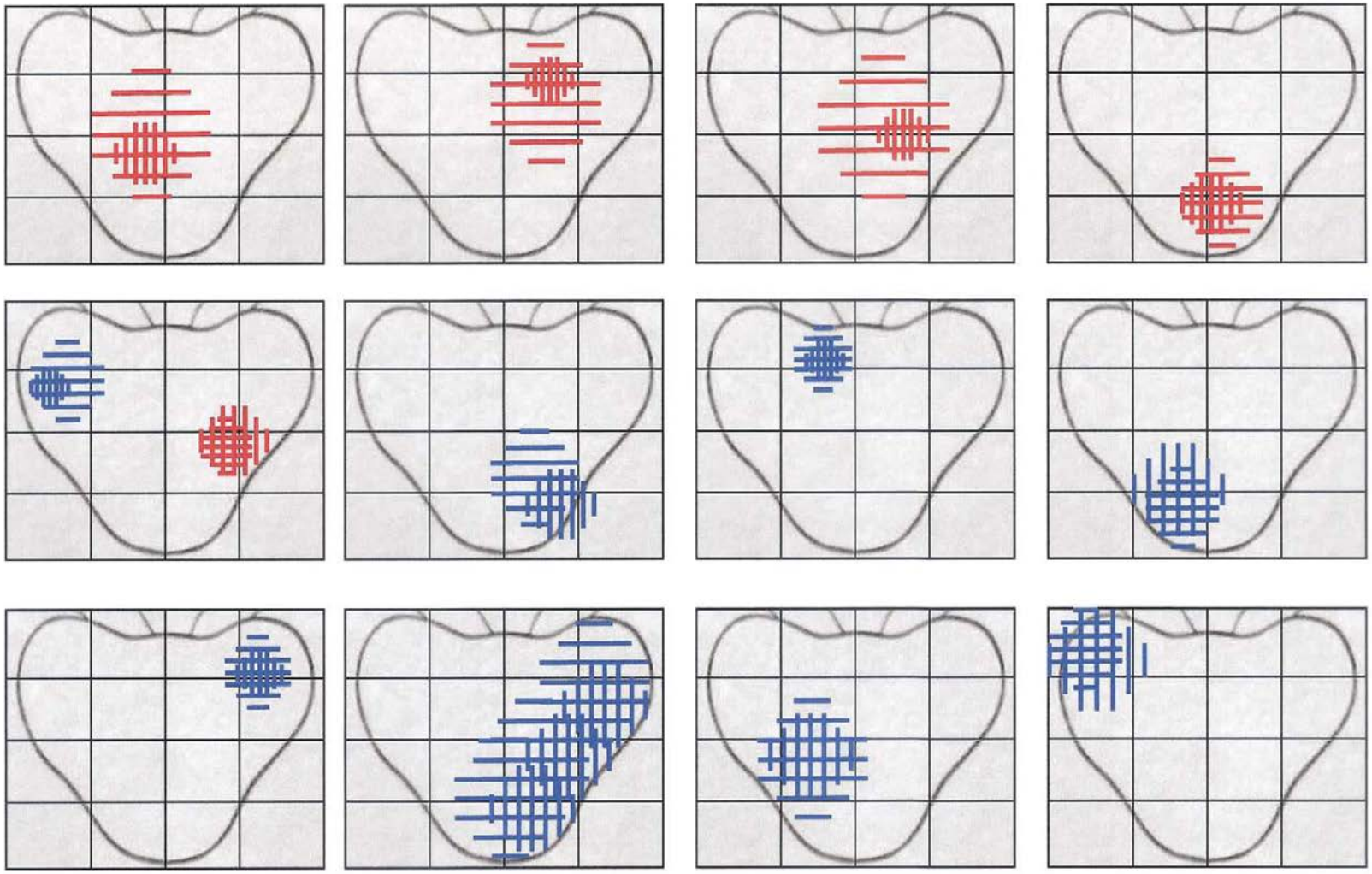

Fig. 3. Initial tumor extent (indicated with horizontal lines) and extent of disease progression at its identification (indicated with vertical lines) in 12 patients with local failure. Red lines indicate tumors with a complete response; blue lines indicate tumors with no or a partial response.

Cellini et al, IJROBP 2002; 53:595-599: 12/12 local failures in the prostate.

N= 9

MRI

C

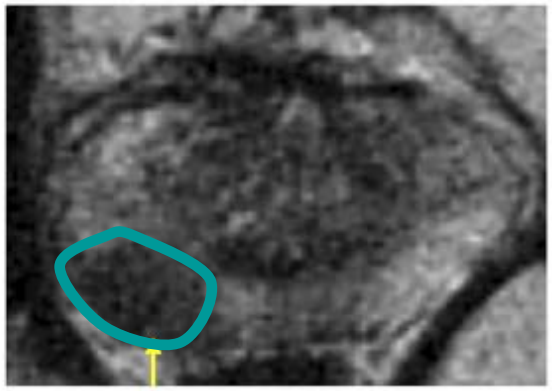

Pre-RT MRI

Pucar et al. Int J Radiat Oncol Biol Phys 2007

N= 9

MRI

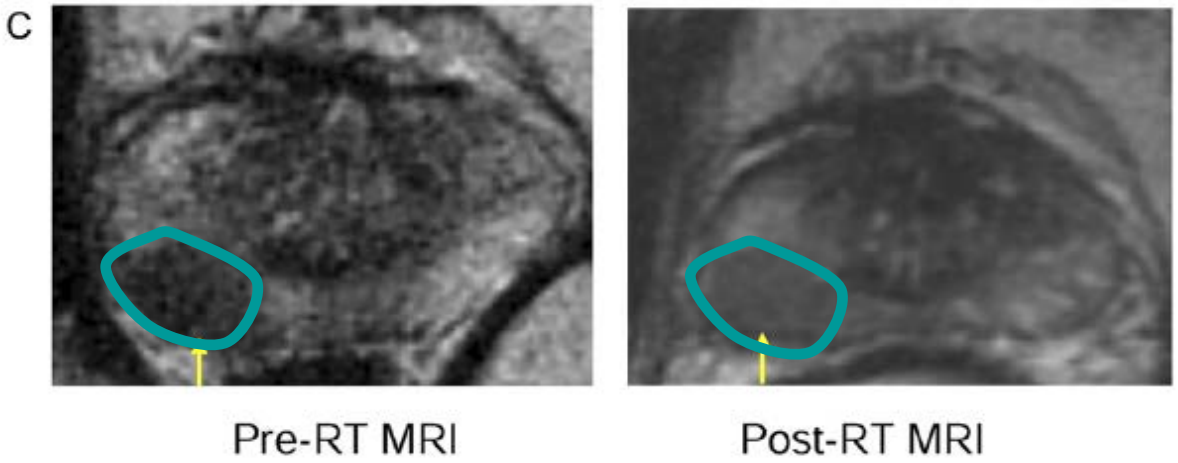

Pucar et al. Int J Radiat Oncol Biol Phys 2007

N= 9

MRI

Salvage Radical Prostatectomy

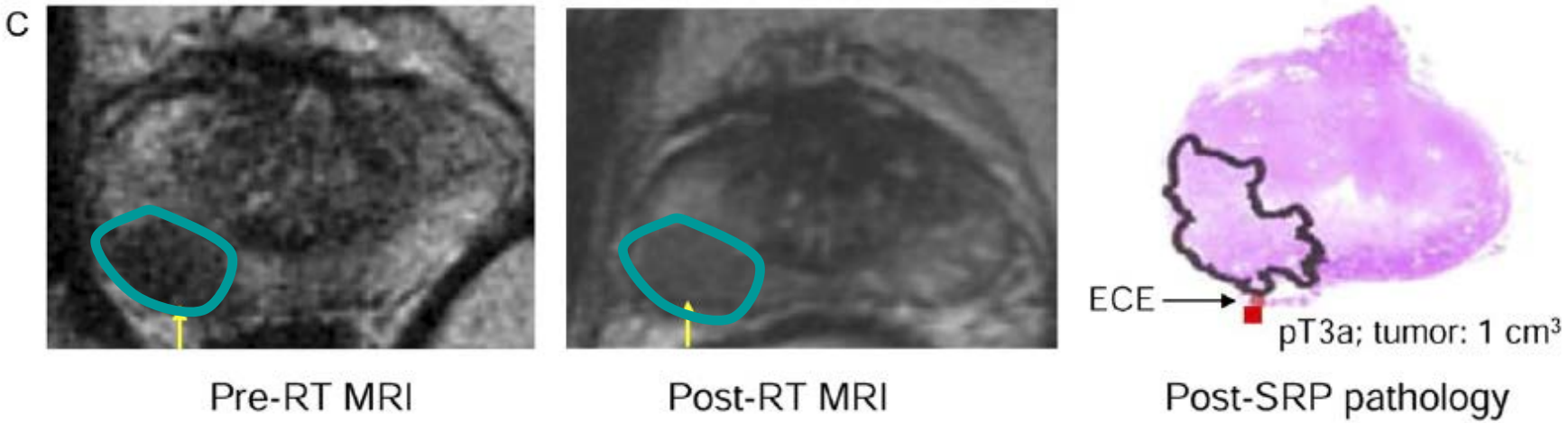

Pucar et al. Int J Radiat Oncol Biol Phys 2007

Challenge

To safely focus the highest dose to the intraprostatic lesion, because most recurrences originate at the initial tumour site.

- **Condition 1: no compromise in CTV dose as prostate cancer mostly is multifocal**
- **Condition 2: no increase in rectal complication probability**

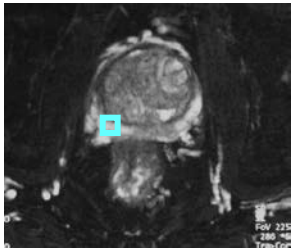

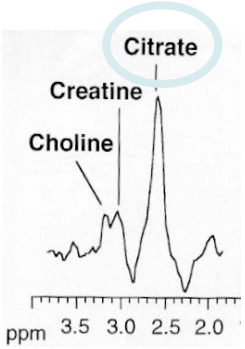
Citrate
Creatine
Choline
ppm 3.5 3.0 2.5 2.0

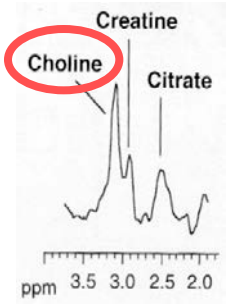
Creatine
Choline
Citrate
ppm 3.5 3.0 2.5 2.0

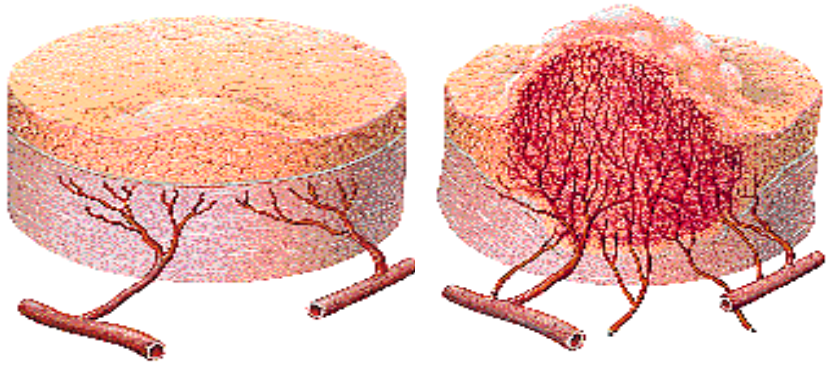

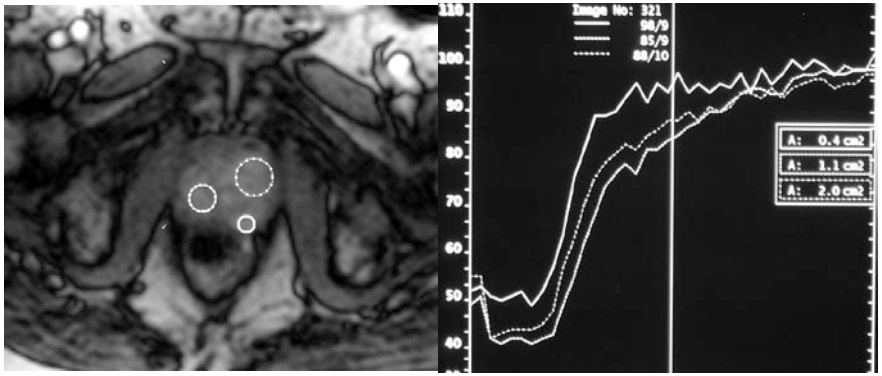
A: 0.4 cm2
A: 1.1 cm2
A: 2.0 cm2

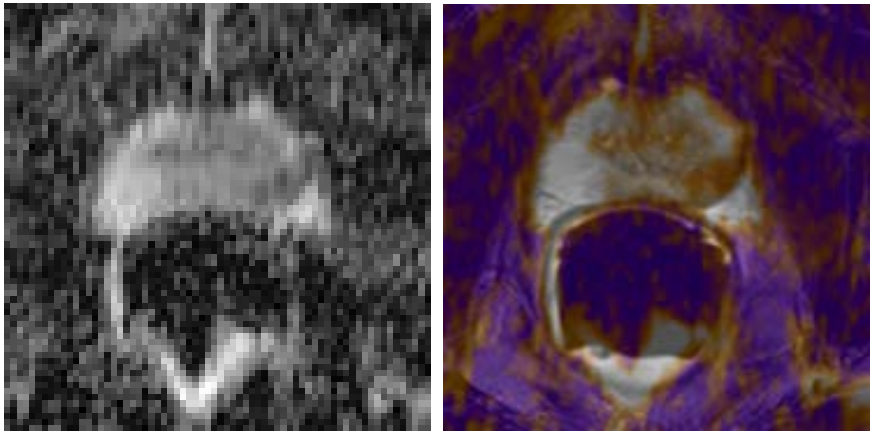

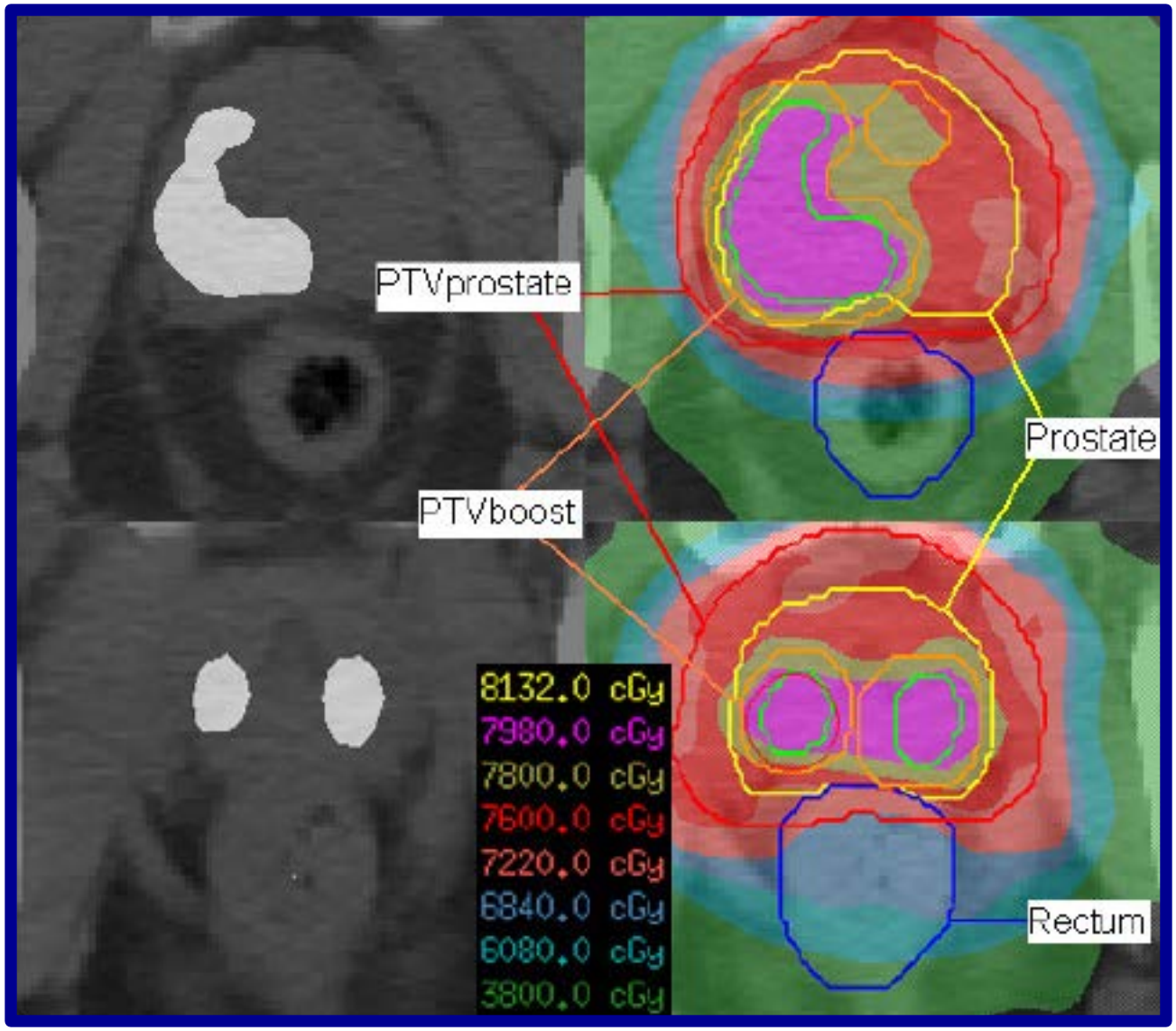

N=67:

76 Gy: 21
SIB 80 Gy: 46

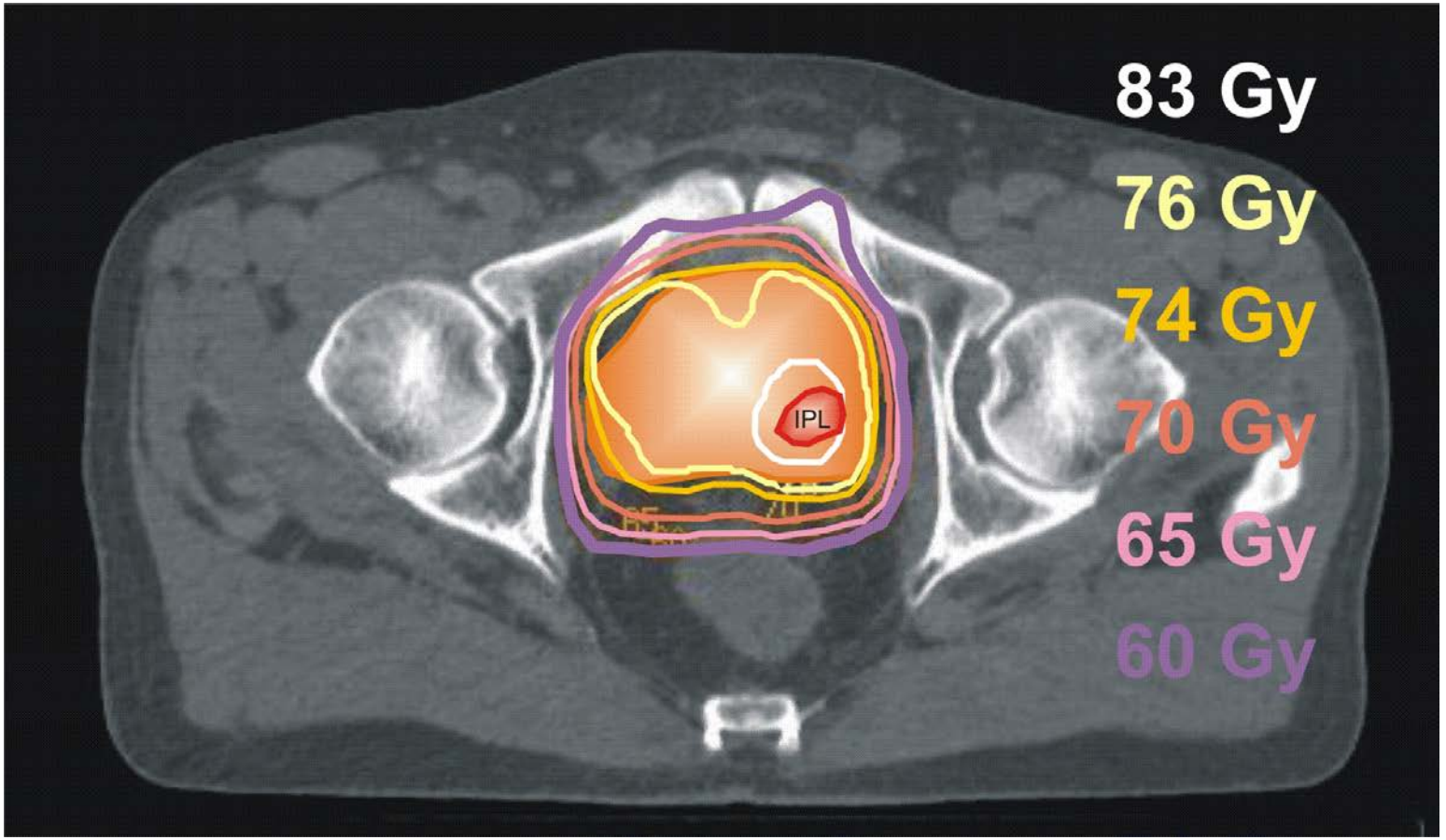
83 Gy
76 Gy
74 Gy
70 Gy
65 Gy
60 Gy
IPL

Biochemical control ≈ IPL for high risk

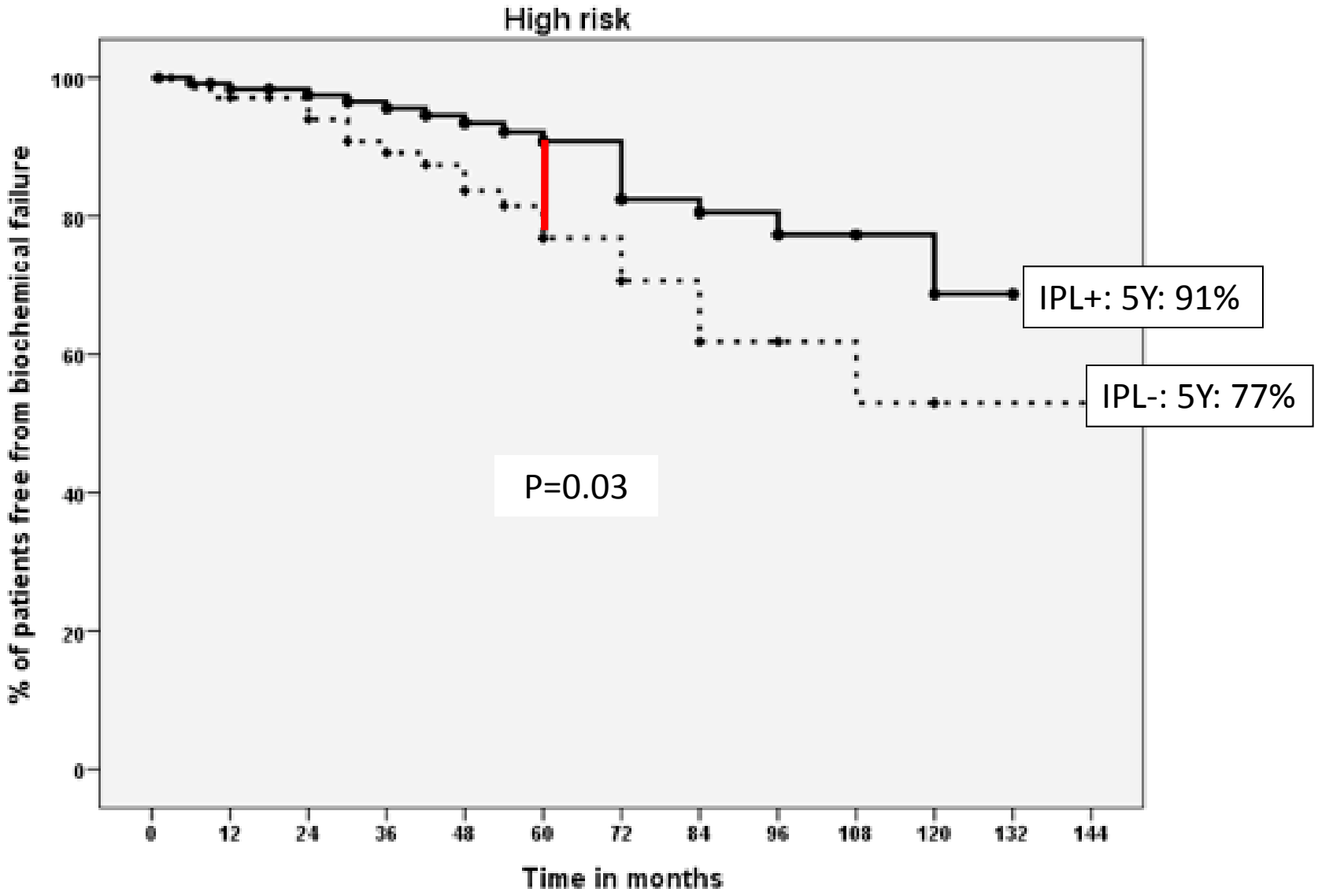

Elective nodal irradiation?

Roach III at al. RTOG 94-13: JCO 2003; 21: 1904-1911.

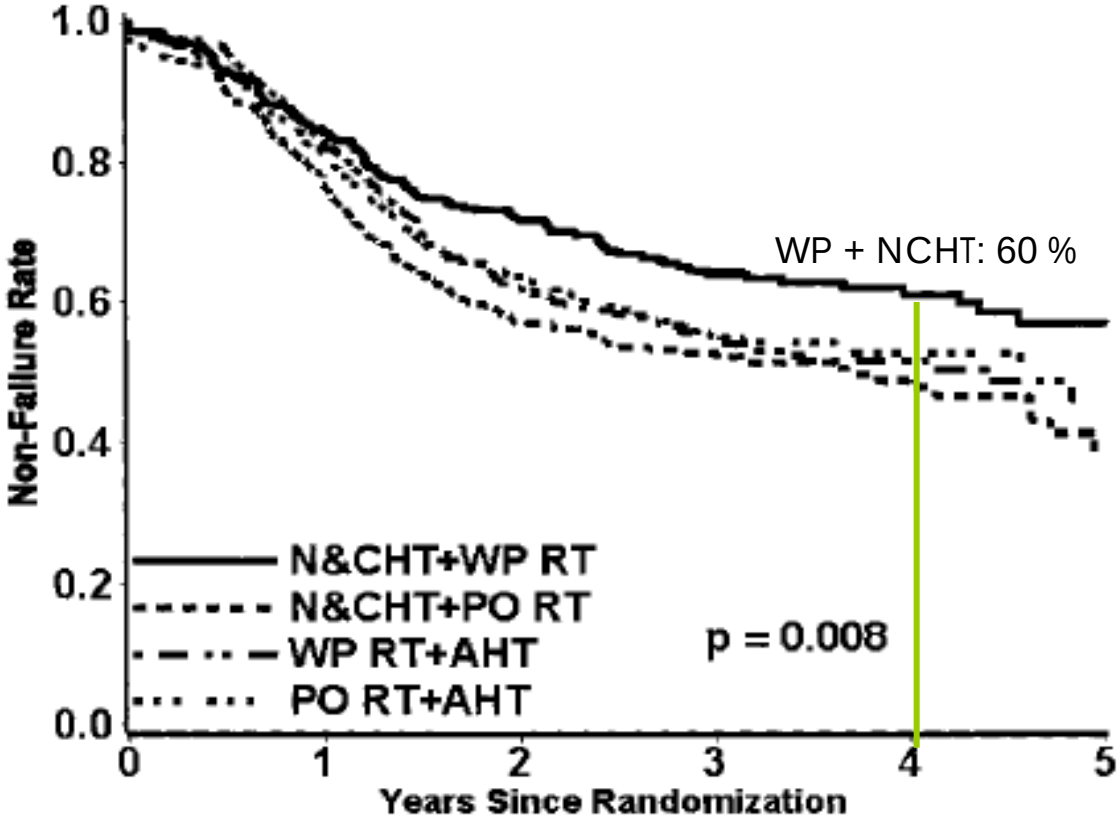

Fig 3. Four-year progression-free advantage for whole pelvic (WP) radiotherapy (RT) and neoadjuvant and concurrent hormonal therapy (NCHT)compared with prostate only (PO) RT and NCHT, and WP RT or PO RT and adjuvant hormonal therapy (AHT; 60 *v* 44, 49% and 50% respectively, $P = .008$).

PFS@ 4 years

PO + NCHT: 44 %
WP + AHT: 49%
PO + AHT: 50%

NO OVERALL SURVIVAL BENEFIT !!

Significantly more acute and late GI toxicities

Table 4. Late radiation Grade 3+ toxicities

Group	*n*	Toxicities	% with toxicity at 5 years	95% CI	*p*-value*
Grade 3+ GU					
Whole-pelvis	309	11	3.0	(1.1, 4.9)	0.24
Mini-pelvis†	169	4	2.4	(0.0, 4.8)	
Prostate-only	131	1	0	—	
Grade 3+ GI					
Whole-pelvis	309	15	4.3	(2.0, 6.6)	0.006
Mini-pelvis†	169	2	1.2	(0, 2.9)	
Prostate-only	131	0	0	—	

Roach III et al. IJROBP 2006; 66: 647 - 653

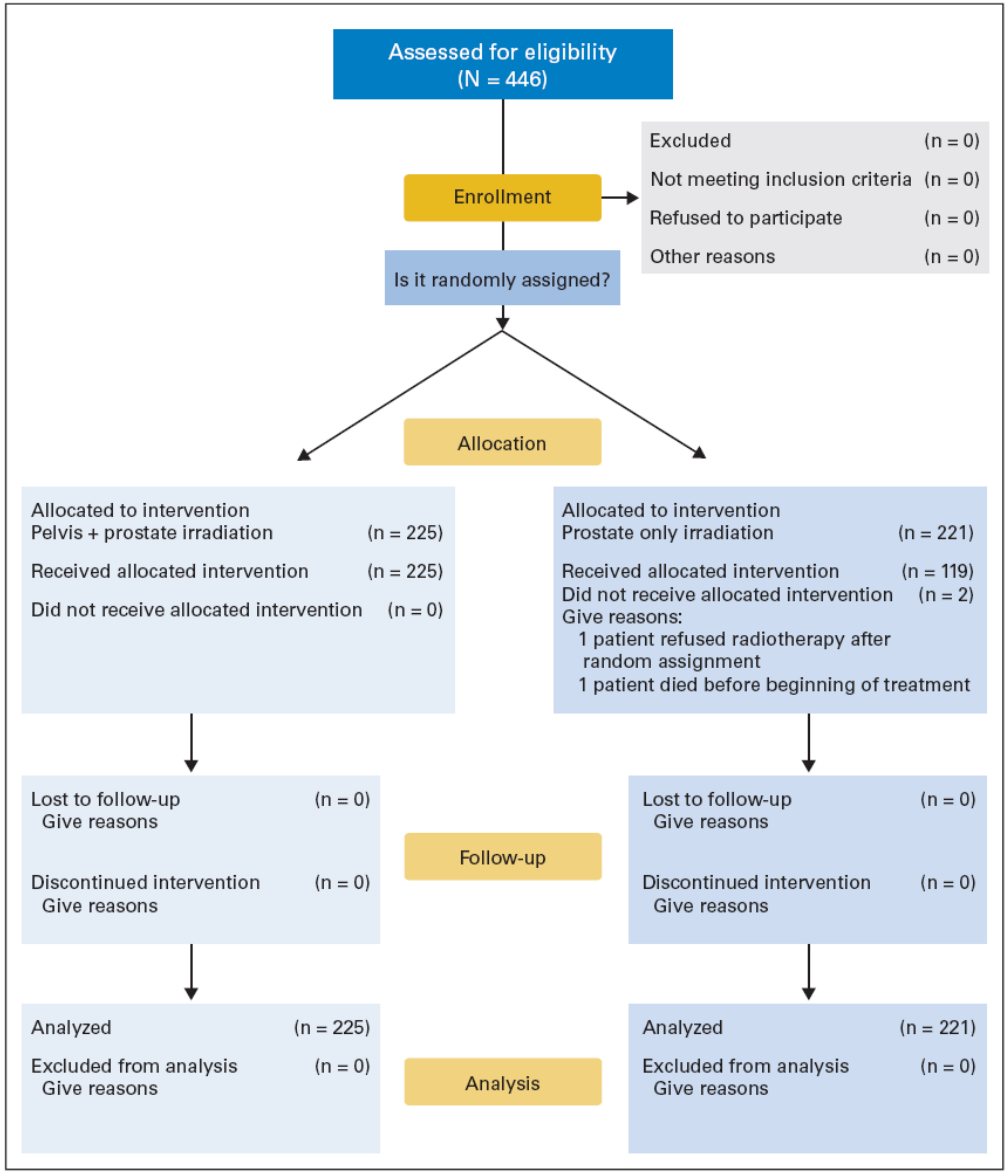

Pommier JCO 2007; 25: 5366 – 5373.

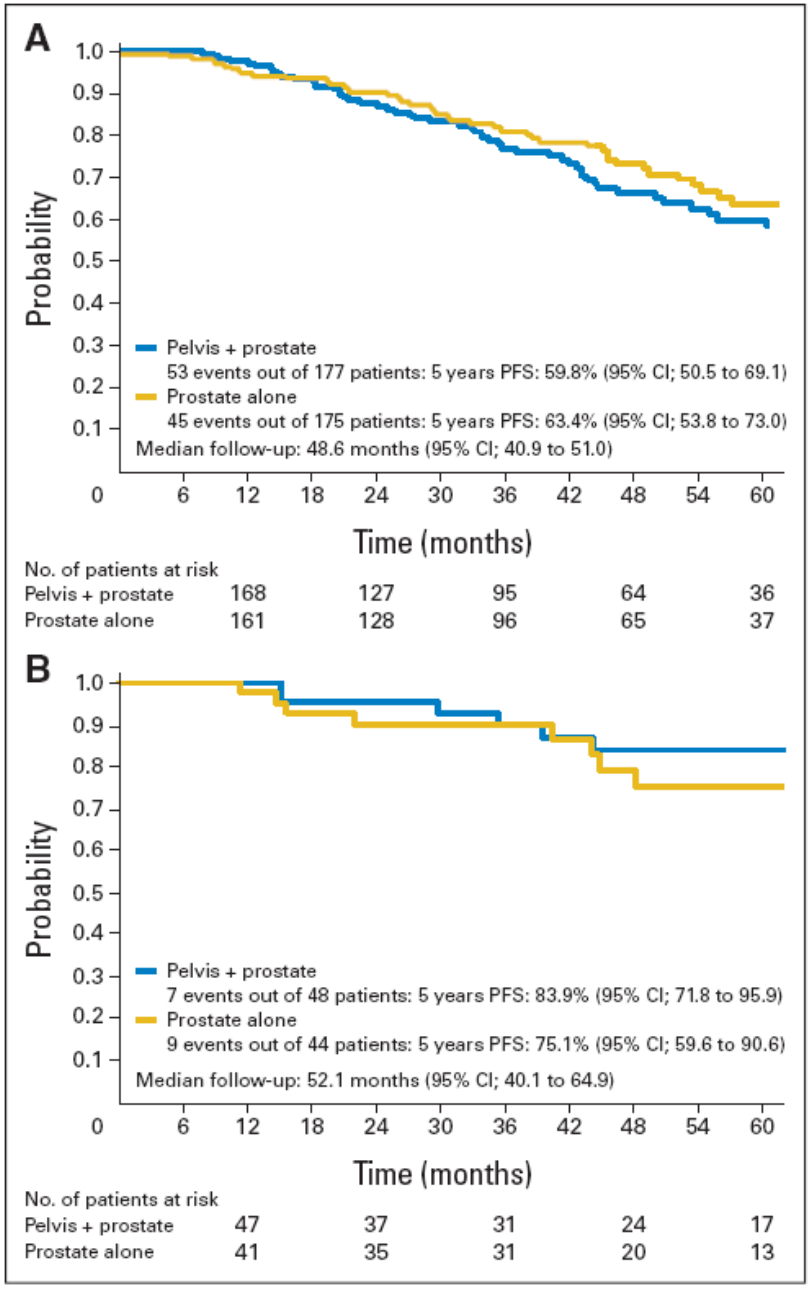

Fig 2. Progression-free survival (PFS) according to the stratified groups. (A) High-risk group. (B) Low-risk group.

Overall PFS @5 years
Pelvis group: 66 %
Prostate group: 65%
P=NS

Pommier JCO 2007; 25: 5366 – 5373.

Nodal areas removed by surgeon

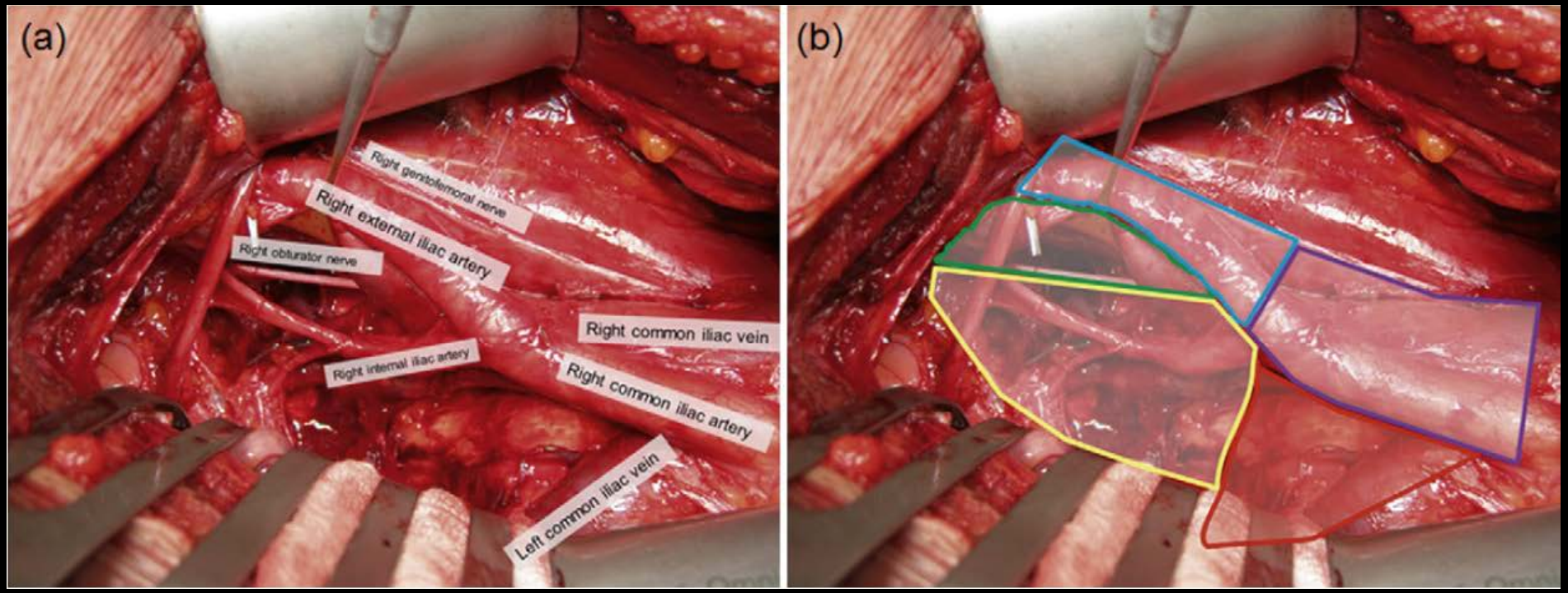

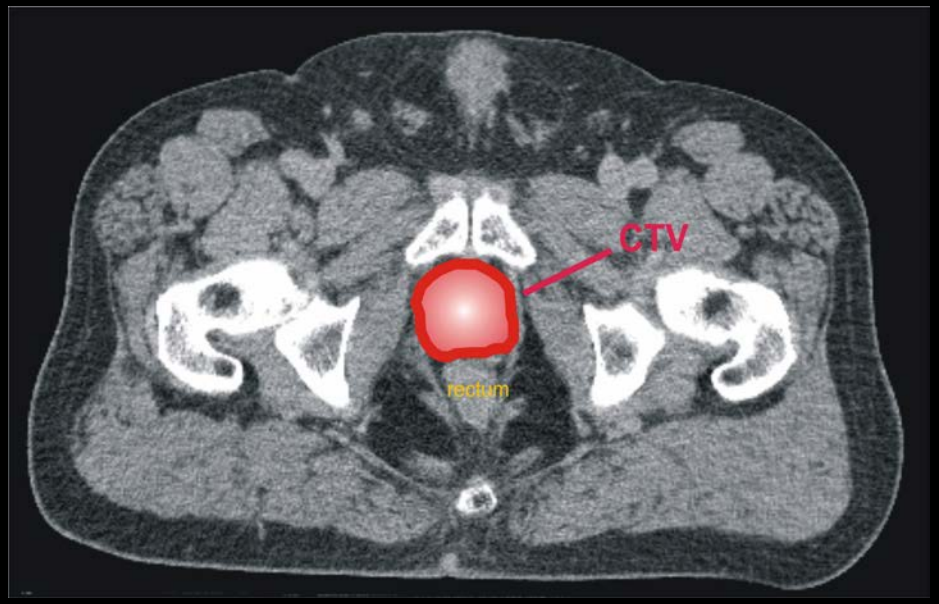
CTV
rectum

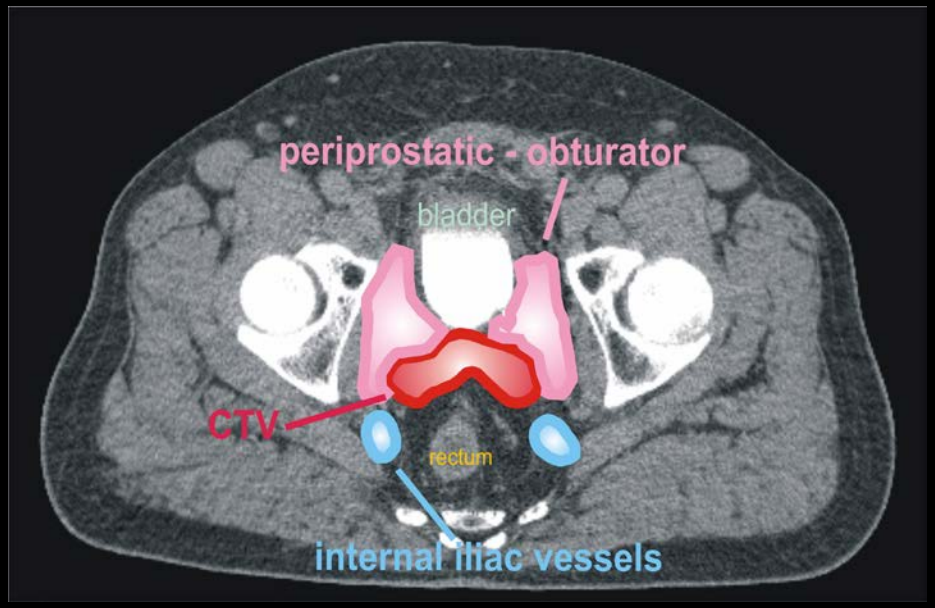
periprostatic - obturator
bladder
CTV
rectum
internal iliac vessels

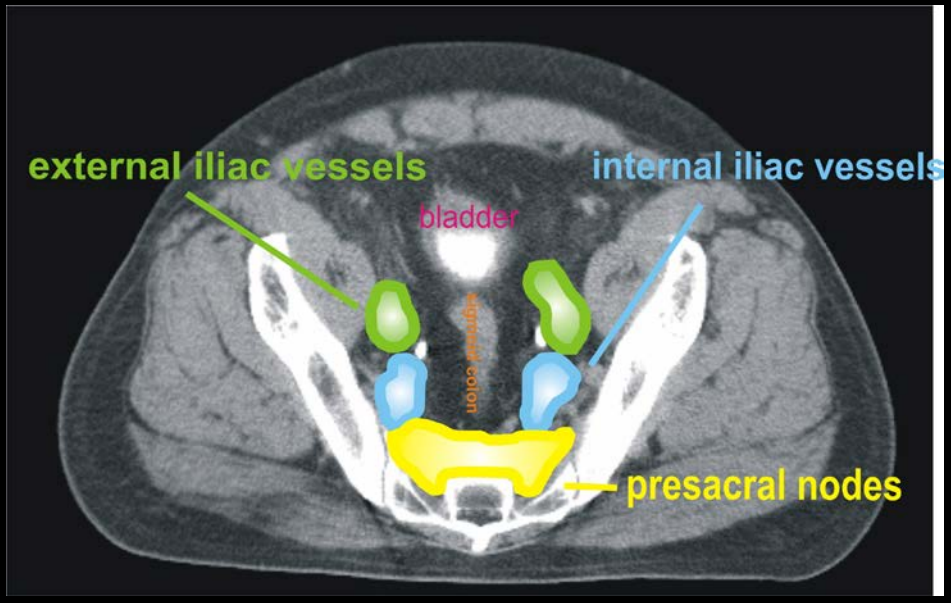
external iliac vessels
internal iliac vessels
bladder
sigmoid colon
presacral nodes

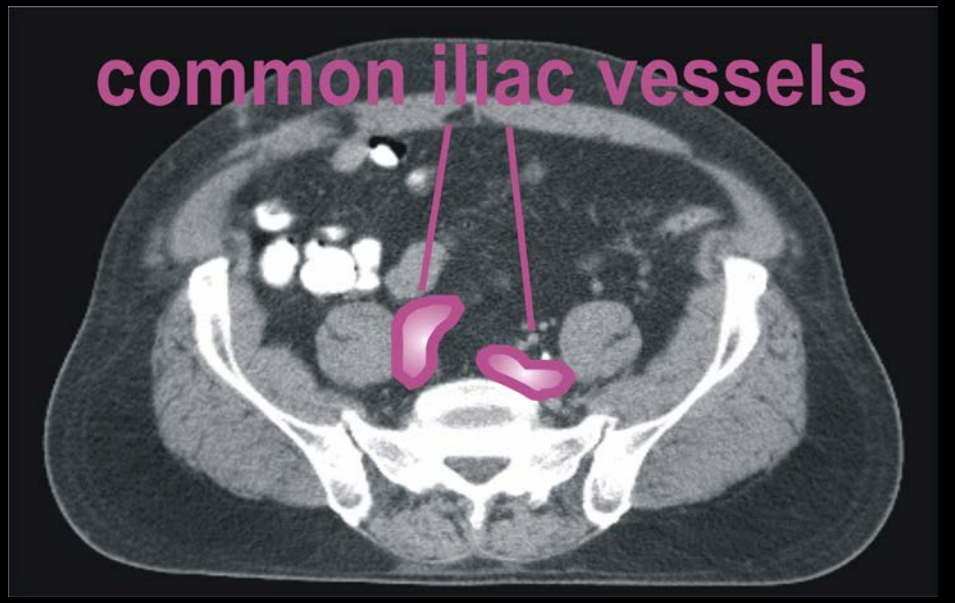
common iliac vessels

Even a 4-fields box definition is not so simple…

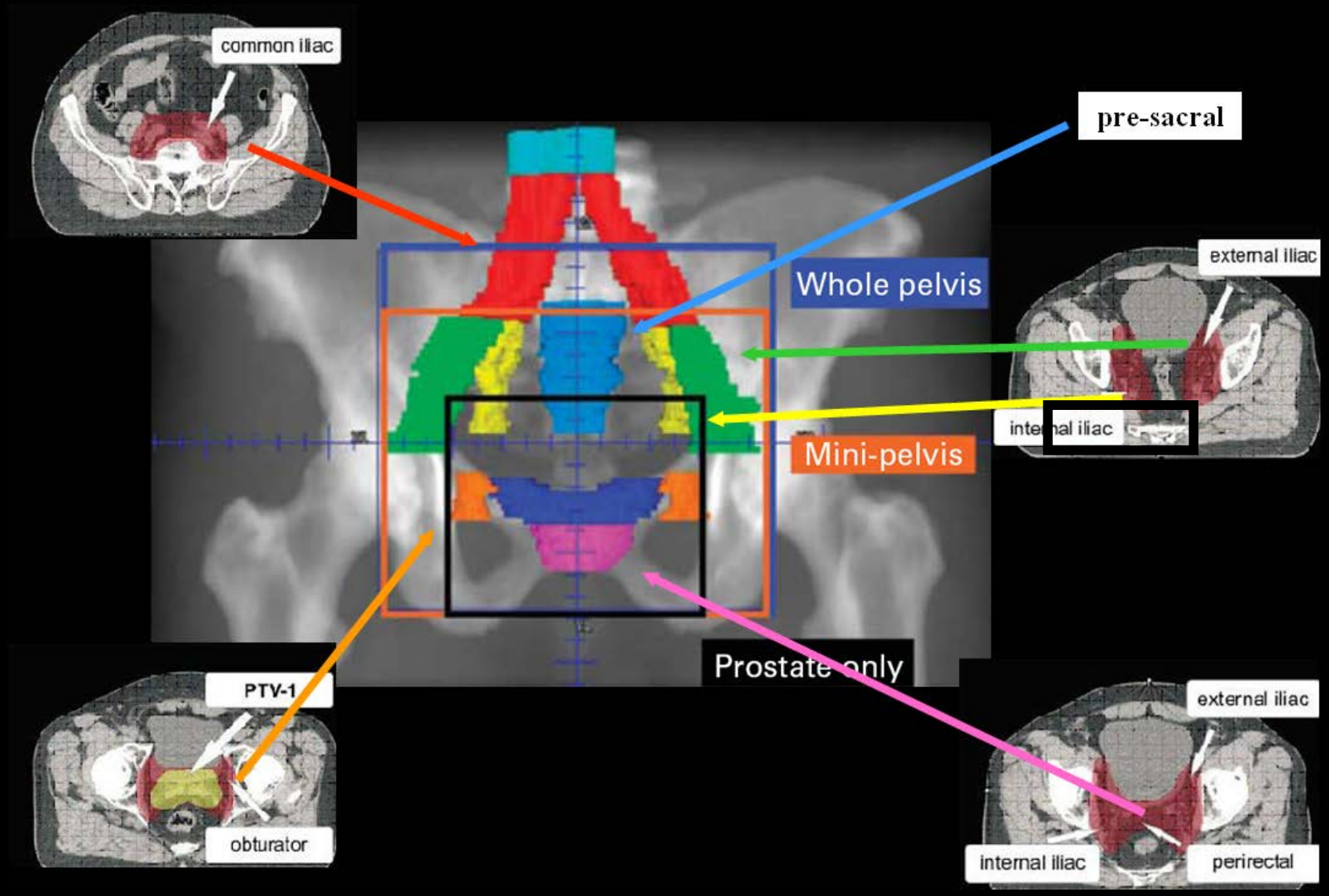

How do we do it? Lets' discuss

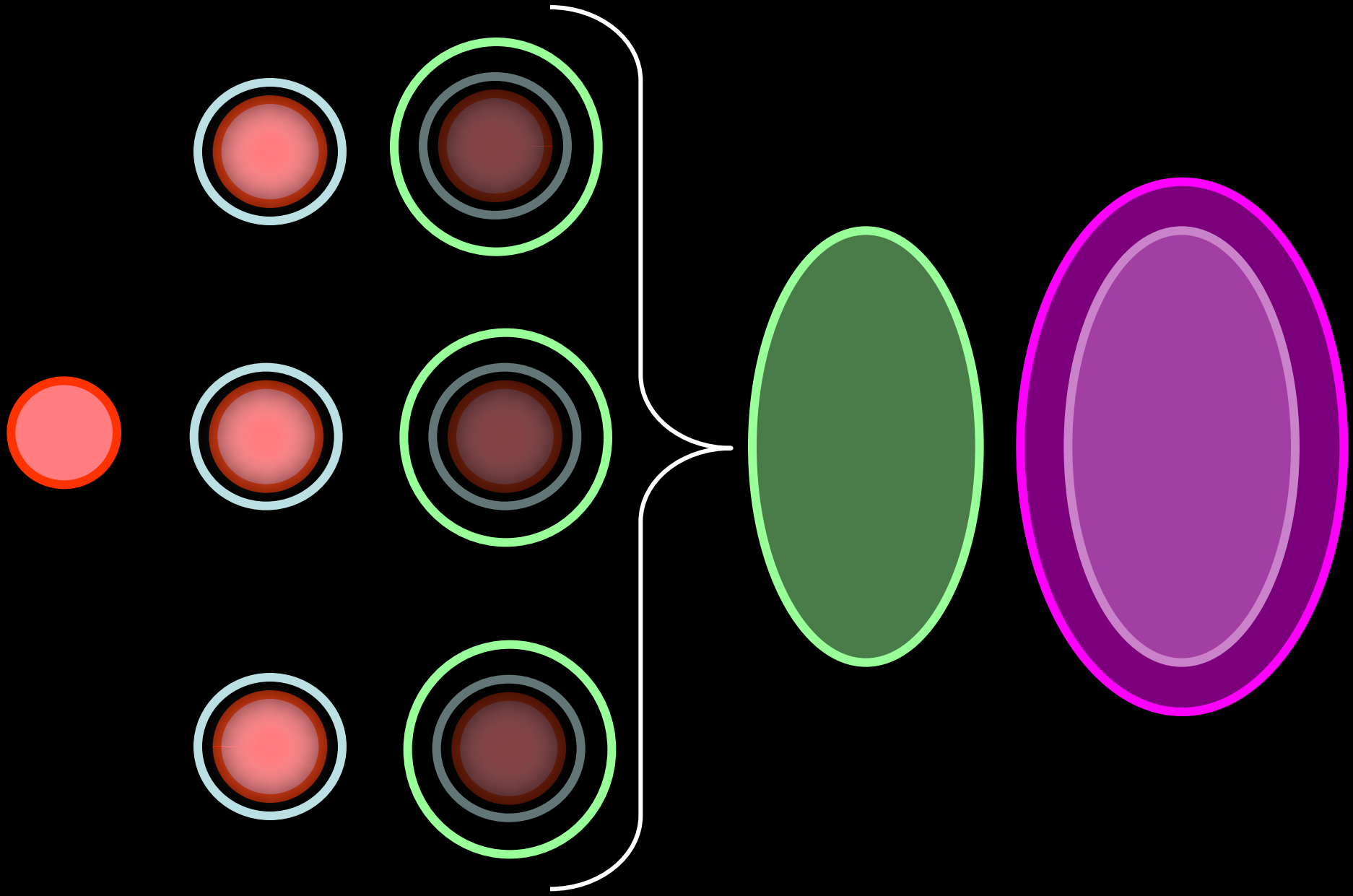

« Ghost » volumes for optimization

Ring:

5-35 mm/PTV

What if pN+ disease?

JOURNAL OF CLINICAL ONCOLOGY ORIGINAL REPORT

Impact of Adjuvant Radiotherapy on Survival of Patients With Node-Positive Prostate Cancer

Firas Abdollah, R. Jeffrey Karnes, Nazareno Suardi, Cesare Cozzarini, Giorgio Gandaglia, Nicola Fossati, Damiano Vizziello, Maxine Sun, Pierre I. Karakiewicz, Mani Menon, Francesco Montorsi, and Alberto Briganti

JOURNAL OF CLINICAL ONCOLOGY ORIGINAL REPORT

Impact of Adjuvant Radiotherapy on Survival of Patients With Node-Positive Prostate Cancer

Firas Abdollah, R. Jeffrey Karnes, Nazareno Suardi, Cesare Cozzarini, Giorgio Gandaglia, Nicola Fossati, Damiano Vizziello, Maxine Sun, Pierre I. Karakiewicz, Mani Menon, Francesco Montorsi, and Alberto Briganti

Variable	All Cohort No.	All Cohort %	aHT No.	aHT %	aHT and aRT No.	aHT and aRT %	*P*
Pathologic Gleason score							< .001
≤ 6	155	14	123	17.1	32	8.3	
7	518	46.8	358	49.7	160	41.5	
≥ 8	434	39.2	240	33.3	194	50.3	
Pathologic tumor stage							< .001
pT2/pT3a	351	31.7	267	37	84	21.8	
pT3b	681	61.5	427	59.2	254	65.8	
pT4	75	6.8	27	3.7	48	12.4	
Surgical margin status							< .001
Negative	450	40.7	337	46.7	113	29.3	
Positive	657	59.3	384	53.3	273	70.7	
No. of positive nodes							.04
Mean	2.5		2.4		2.8		
Median	1.0		1.0		2.0		
IQR	1.0-3.0		1.0-2.0		1.0-3.0		
No. of removed lymph nodes							< .001
Mean	15.8		14.1		18.9		
Median	14.0		13.0		17.0		
IQR	10.0-20.0		9.0-18.0		12.0-23.0		

Eight-Year CSM-Free Survival (95% CI)

	Entire Cohort	aHT Alone	aRT + aHT	*P*
Gleason score 2–6 (n = 133; 12%)	98.6 (95.8 to 100)	98.4 (95.4 to 100)	100 (100 to 100)	.7
pT2/pT3a and negative SM (n = 131; 11.8%)	96.6 (93.4 to 99.9)	96.8 (93.2 to 100)	96.3 (89.4 to 100)	.4
pT3b/pT4 or positive SM (n = 552; 49.9%)	86.7 (83.0 to 90.6)	84.2 (79.7 to 89.0)	93.1 (87.5 to 99.1)	.03
Positive nodes = 3–4 (n = 160; 14.5%)	85.3 (78.9 to 92.1)	78.8 (69.7 to 89.0)	96.5 (91.8 to 100)	.02
Positive nodes > 4 (n = 131; 11.8%)	72.2 (62.7 to 83.1)	72.0 (60.9 to 85.2)	74.7 (59.2 to 94.3)	.9

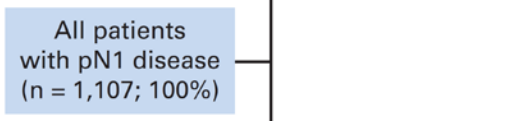

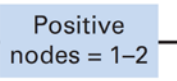

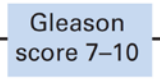

Eight-Year CSM-Free Survival (95% CI)

	Entire Cohort	aHT Alone	aRT + aHT	*P*
Gleason score 2–6 (n = 133; 12%)	98.6 (95.8 to 100)	98.4 (95.4 to 100)	100 (100 to 100)	.7
pT2/pT3a and negative SM (n = 131; 11.8%)	96.6 (93.4 to 99.9)	96.8 (93.2 to 100)	96.3 (89.4 to 100)	.4
pT3b/pT4 or positive SM (n = 552; 49.9%)	86.7 (83.0 to 90.6)	84.2 (79.7 to 89.0)	93.1 (87.5 to 99.1)	.03
Positive nodes = 3–4 (n = 160; 14.5%)	85.3 (78.9 to 92.1)	78.8 (69.7 to 89.0)	96.5 (91.8 to 100)	.02
Positive nodes > 4 (n = 131; 11.8%)	72.2 (62.7 to 83.1)	72.0 (60.9 to 85.2)	74.7 (59.2 to 94.3)	.9

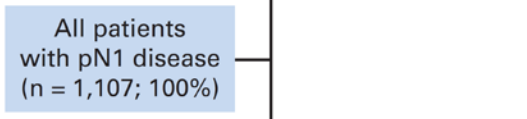

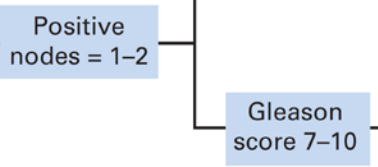

Eight-Year CSM-Free Survival (95% CI)

	Entire Cohort	aHT Alone	aRT + aHT	*P*
Gleason score 2–6 (n = 133; 12%)	98.6 (95.8 to 100)	98.4 (95.4 to 100)	100 (100 to 100)	.7
pT2/pT3a and negative SM (n = 131; 11.8%)	96.6 (93.4 to 99.9)	96.8 (93.2 to 100)	96.3 (89.4 to 100)	.4
pT3b/pT4 or positive SM (n = 552; 49.9%)	86.7 (83.0 to 90.6)	84.2 (79.7 to 89.0)	93.1 (87.5 to 99.1)	.03
Positive nodes = 3–4 (n = 160; 14.5%)	85.3 (78.9 to 92.1)	78.8 (69.7 to 89.0)	96.5 (91.8 to 100)	.02
Positive nodes > 4 (n = 131; 11.8%)	72.2 (62.7 to 83.1)	72.0 (60.9 to 85.2)	74.7 (59.2 to 94.3)	.9

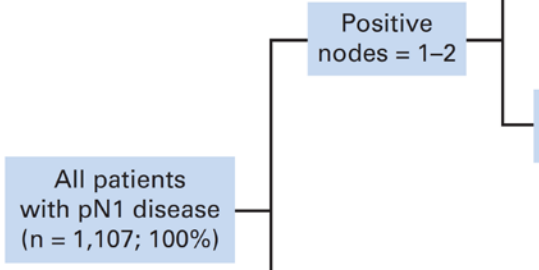

Eight-Year CSM-Free Survival (95% CI)

	Entire Cohort	aHT Alone	aRT + aHT	*P*
Gleason score 2–6 (n = 133; 12%)	98.6 (95.8 to 100)	98.4 (95.4 to 100)	100 (100 to 100)	.7
pT2/pT3a and negative SM (n = 131; 11.8%)	96.6 (93.4 to 99.9)	96.8 (93.2 to 100)	96.3 (89.4 to 100)	.4
pT3b/pT4 or positive SM (n = 552; 49.9%)	86.7 (83.0 to 90.6)	84.2 (79.7 to 89.0)	93.1 (87.5 to 99.1)	.03
Positive nodes = 3–4 (n = 160; 14.5%)	85.3 (78.9 to 92.1)	78.8 (69.7 to 89.0)	96.5 (91.8 to 100)	.02
Positive nodes > 4 (n = 131; 11.8%)	72.2 (62.7 to 83.1)	72.0 (60.9 to 85.2)	74.7 (59.2 to 94.3)	.9

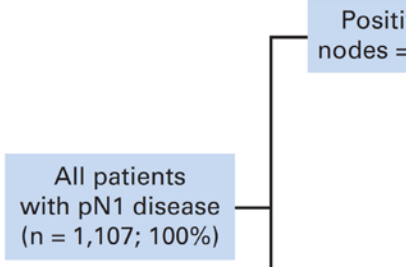

Eight-Year CSM-Free Survival (95% CI)

	Entire Cohort	aHT Alone	aRT + aHT	*P*
Gleason score 2–6 (n = 133; 12%)	98.6 (95.8 to 100)	98.4 (95.4 to 100)	100 (100 to 100)	.7
pT2/pT3a and negative SM (n = 131; 11.8%)	96.6 (93.4 to 99.9)	96.8 (93.2 to 100)	96.3 (89.4 to 100)	.4
pT3b/pT4 or positive SM (n = 552; 49.9%)	86.7 (83.0 to 90.6)	84.2 (79.7 to 89.0)	93.1 (87.5 to 99.1)	.03
Positive nodes = 3–4 (n = 160; 14.5%)	85.3 (78.9 to 92.1)	78.8 (69.7 to 89.0)	96.5 (91.8 to 100)	.02
Positive nodes > 4 (n = 131; 11.8%)	72.2 (62.7 to 83.1)	72.0 (60.9 to 85.2)	74.7 (59.2 to 94.3)	.9

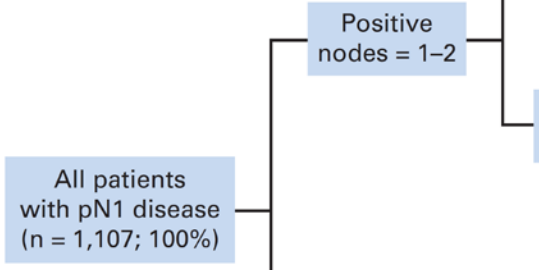

Eight-Year CSM-Free Survival (95% CI)

	Entire Cohort	aHT Alone	aRT + aHT	*P*
Gleason score 2–6 (n = 133; 12%)	98.6 (95.8 to 100)	98.4 (95.4 to 100)	100 (100 to 100)	.7
pT2/pT3a and negative SM (n = 131; 11.8%)	96.6 (93.4 to 99.9)	96.8 (93.2 to 100)	96.3 (89.4 to 100)	.4
pT3b/pT4 or positive SM (n = 552; 49.9%)	86.7 (83.0 to 90.6)	84.2 (79.7 to 89.0)	93.1 (87.5 to 99.1)	.03
Positive nodes = 3–4 (n = 160; 14.5%)	85.3 (78.9 to 92.1)	78.8 (69.7 to 89.0)	96.5 (91.8 to 100)	.02
Positive nodes > 4 (n = 131; 11.8%)	72.2 (62.7 to 83.1)	72.0 (60.9 to 85.2)	74.7 (59.2 to 94.3)	.9



Eight-Year CSM-Free Survival (95% CI)

	Entire Cohort	aHT Alone	aRT + aHT	*P*
Gleason score 2–6 (n = 133; 12%)	98.6 (95.8 to 100)	98.4 (95.4 to 100)	100 (100 to 100)	.7
pT2/pT3a and negative SM (n = 131; 11.8%)	96.6 (93.4 to 99.9)	96.8 (93.2 to 100)	96.3 (89.4 to 100)	.4
pT3b/pT4 or positive SM (n = 552; 49.9%)	86.7 (83.0 to 90.6)	84.2 (79.7 to 89.0)	93.1 (87.5 to 99.1)	.03
Positive nodes = 3–4 (n = 160; 14.5%)	85.3 (78.9 to 92.1)	78.8 (69.7 to 89.0)	96.5 (91.8 to 100)	.02
Positive nodes > 4 (n = 131; 11.8%)	72.2 (62.7 to 83.1)	72.0 (60.9 to 85.2)	74.7 (59.2 to 94.3)	.9

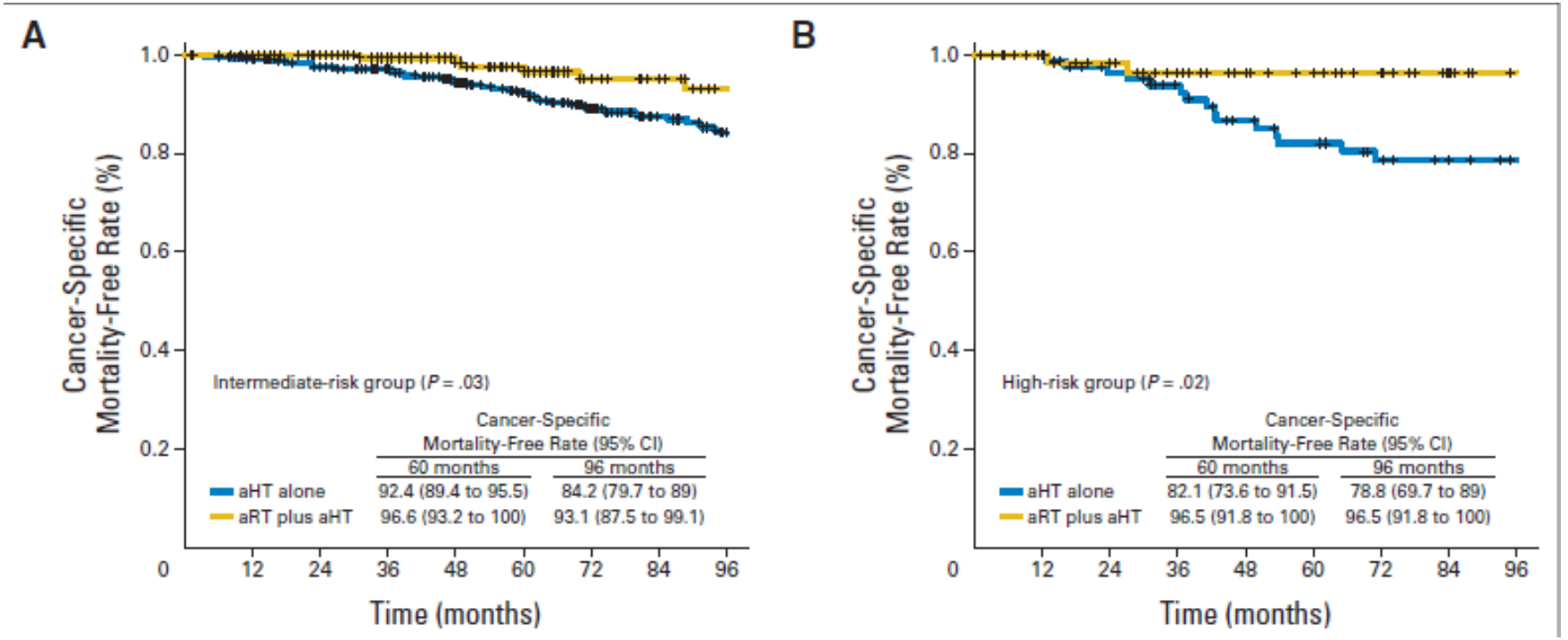
A
1.0
0.8
0.6
0.4
0.2
0
Cancer-Specific Mortality-Free Rate (%)
Intermediate-risk group (P = .03)
Cancer-Specific Mortality-Free Rate (95% CI)
60 months
96 months
aHT alone
92.4 (89.4 to 95.5)
84.2 (79.7 to 89)
aRT plus aHT
96.6 (93.2 to 100)
93.1 (87.5 to 99.1)
12
24
36
48
60
72
84
96
Time (months)
B
1.0
0.8
0.6
0.4
0.2
0
Cancer-Specific Mortality-Free Rate (%)
High-risk group (P = .02)
Cancer-Specific Mortality-Free Rate (95% CI)
60 months
96 months
aHT alone
82.1 (73.6 to 91.5)
78.8 (69.7 to 89)
aRT plus aHT
96.5 (91.8 to 100)
96.5 (91.8 to 100)
12
24
36
48
60
72
84
96
Time (months)

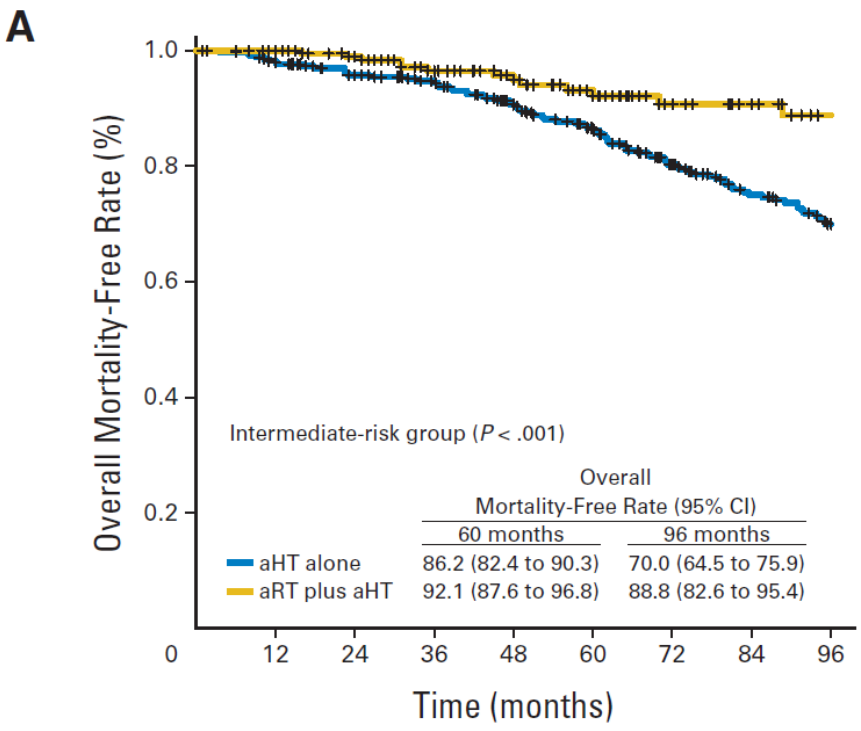
A
Overall Mortality-Free Rate (%)
1.0
0.8
0.6
0.4
0.2
0
12
24
36
48
60
72
84
96
Time (months)
Intermediate-risk group (P < .001)
Overall Mortality-Free Rate (95% CI)
60 months
96 months
aHT alone
86.2 (82.4 to 90.3)
70.0 (64.5 to 75.9)
aRT plus aHT
92.1 (87.6 to 96.8)
88.8 (82.6 to 95.4)

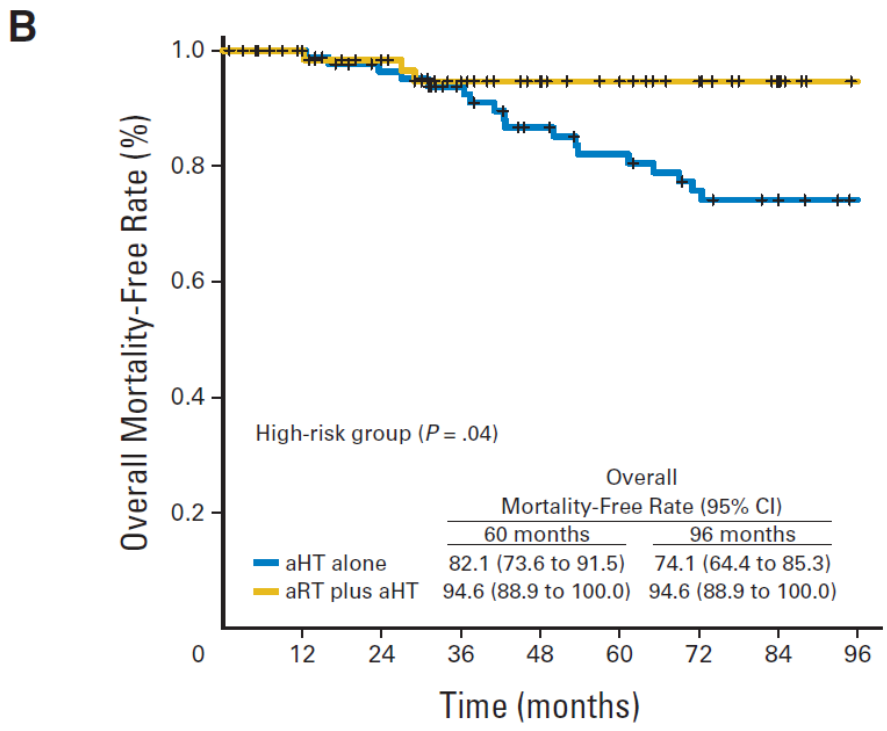
B
Overall Mortality-Free Rate (%)
1.0
0.8
0.6
0.4
0.2
0
12
24
36
48
60
72
84
96
Time (months)
High-risk group (P = .04)
Overall Mortality-Free Rate (95% CI)
60 months
96 months
aHT alone
82.1 (73.6 to 91.5)
74.1 (64.4 to 85.3)
aRT plus aHT
94.6 (88.9 to 100.0)
94.6 (88.9 to 100.0)

Postoperative setting?

TERMINATOR 3
RISE OF THE MACHINES
THE WAR BEGINS JULY 2
TM AND © 2003 C2 AND ITS RELATED ENTITIES. ALL RIGHTS RESERVED. PRIVATE USE ONLY. SALE, DUPLICATION OR OTHER TRANSFER OF THIS MATERIAL IS STRICTLY PROHIBITED.

Where do local relpases after RP occur?

Location of the local relapses in the prostatic bed after radical prostatectomy

	Patients	Diagnosis	Anastomosis		Other sites
Silverman [38]	31	Clinically detected or PSA rising, biopsy confirmed	31	Posterior: 16 Anterior: 9 Combination: 6	–
Connolly [10]	61	PSA rising biopsy confirmed	42	Posterior: 26 Anterior: 5 Lateral: 11	Retrovesical: 8 Bladder neck: 10 Combination: 1
Leventis [24]	31	Clinically detected or PSA rising, biopsy confirmed	17		Retrovesical: 2 Bladder neck: 7 Combination: 5
Sella [36]	39	MRI detected (15/39 biopsy confirmed)	12		Retrovesical: 17 Residual SV: 9 Combination: 1
Total	162		102 (63%)		Retrovesical: 27 (17%) Bladder neck: 17 (10%) Other: 16 (10%)

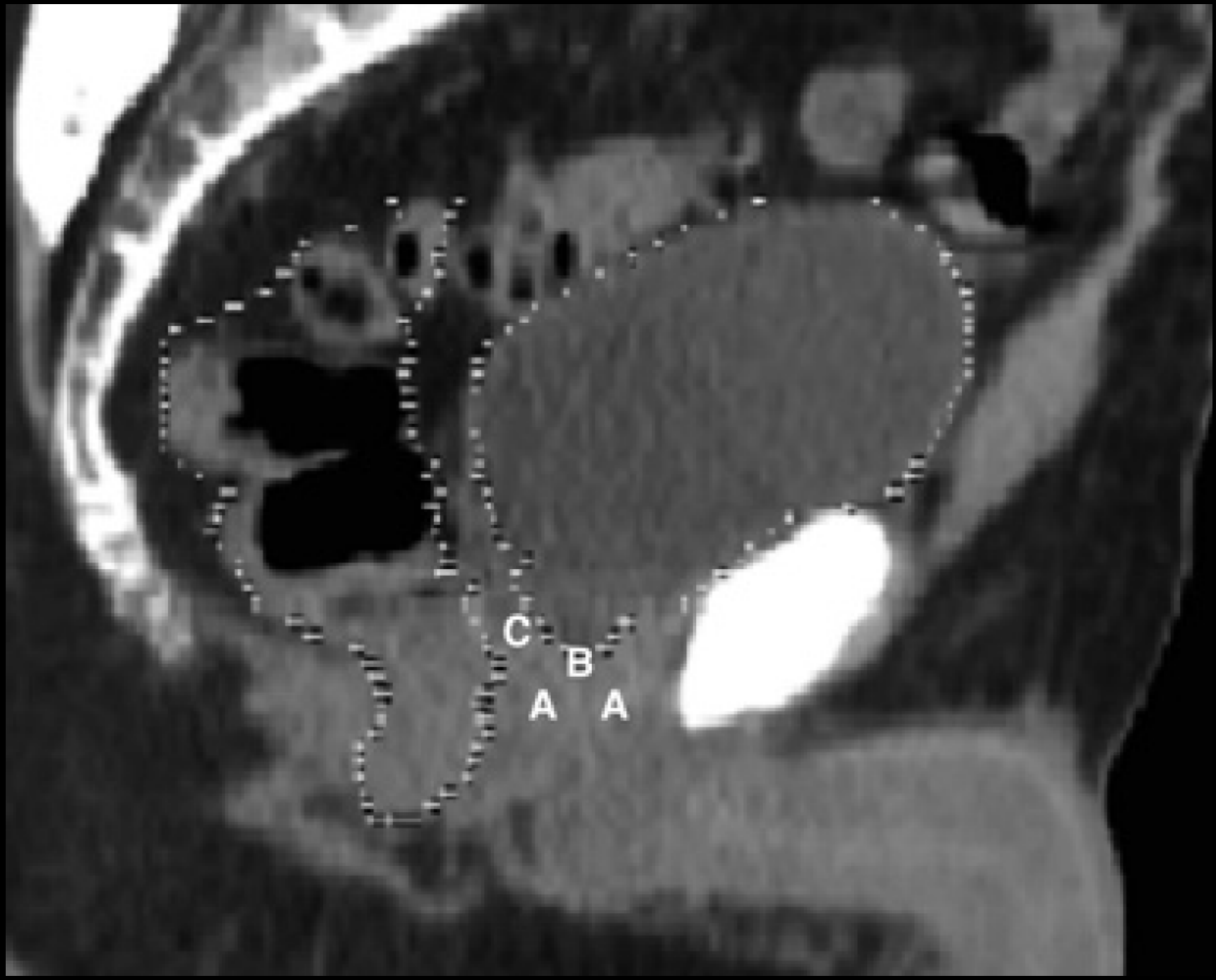
C
B
A
A

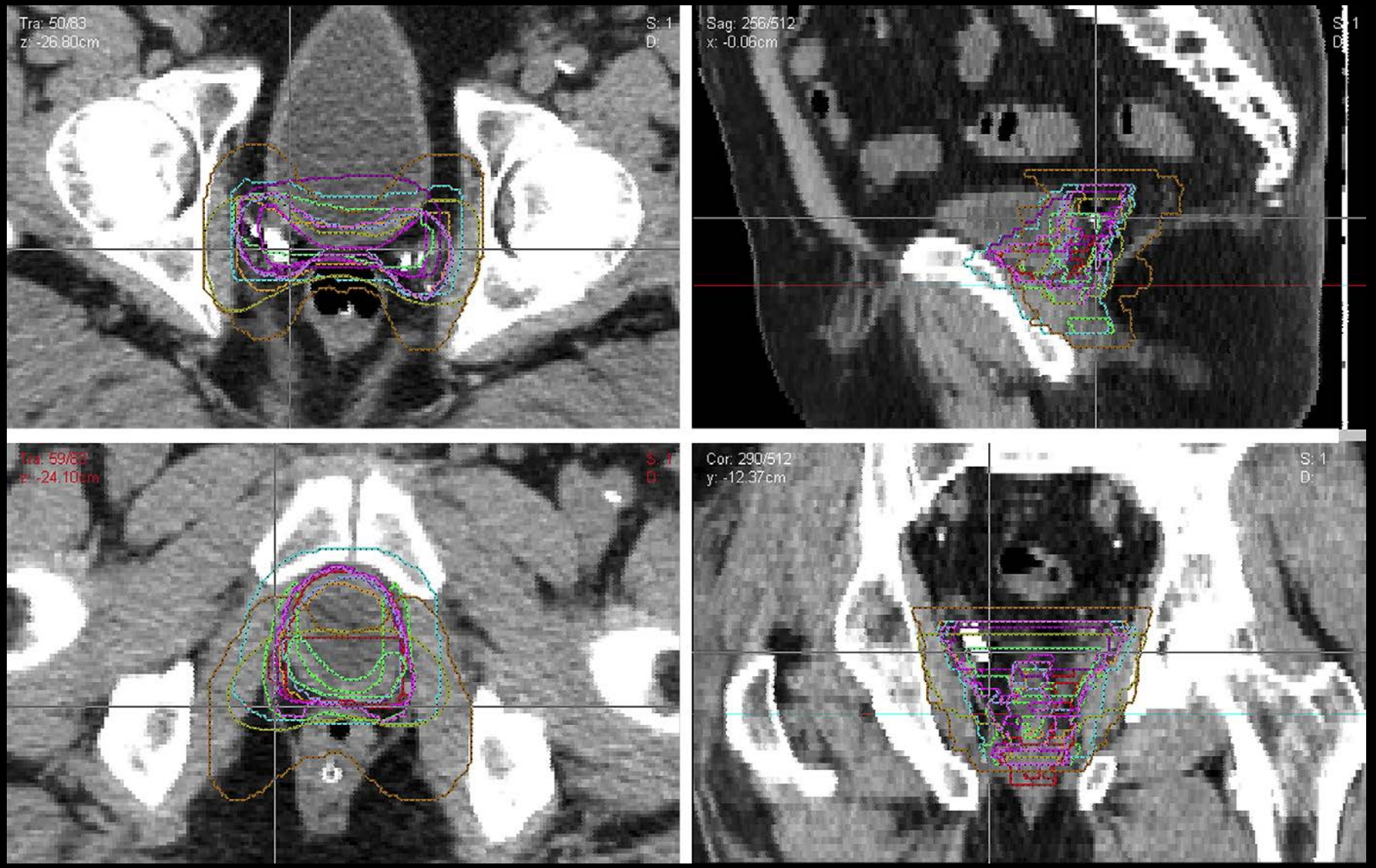
Tra: 50/83
z: -26.80cm
S: 1
D:
Sag: 256/512
x: -0.06cm
Tra: 59/83
z: -24.10cm
Cor: 290/512
y: -12.37cm

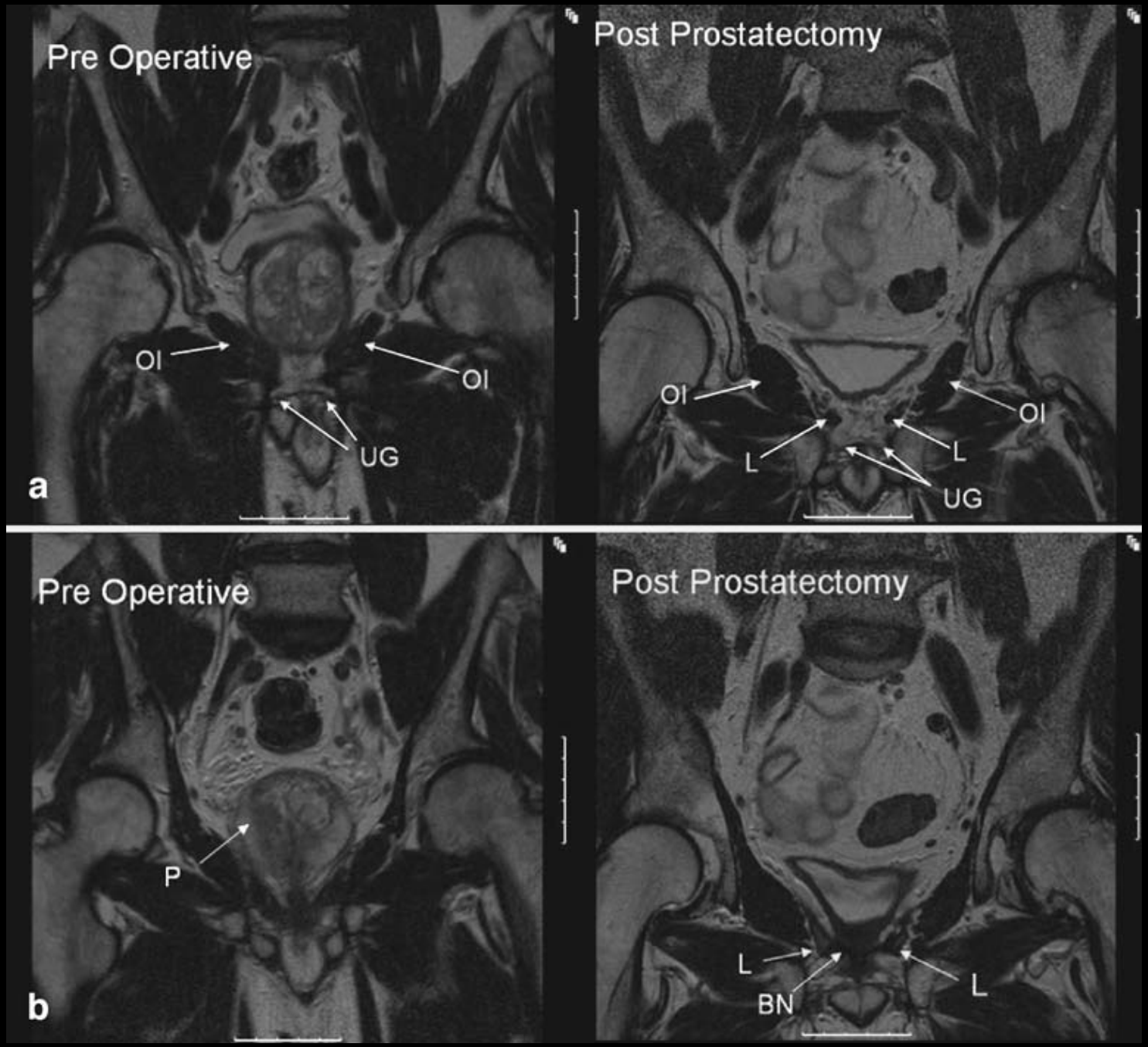
Pre Operative
Post Prostatectomy
OI
OI
UG
a
OI
OI
L
L
UG
Pre Operative
Post Prostatectomy
P
b
L
L
BN

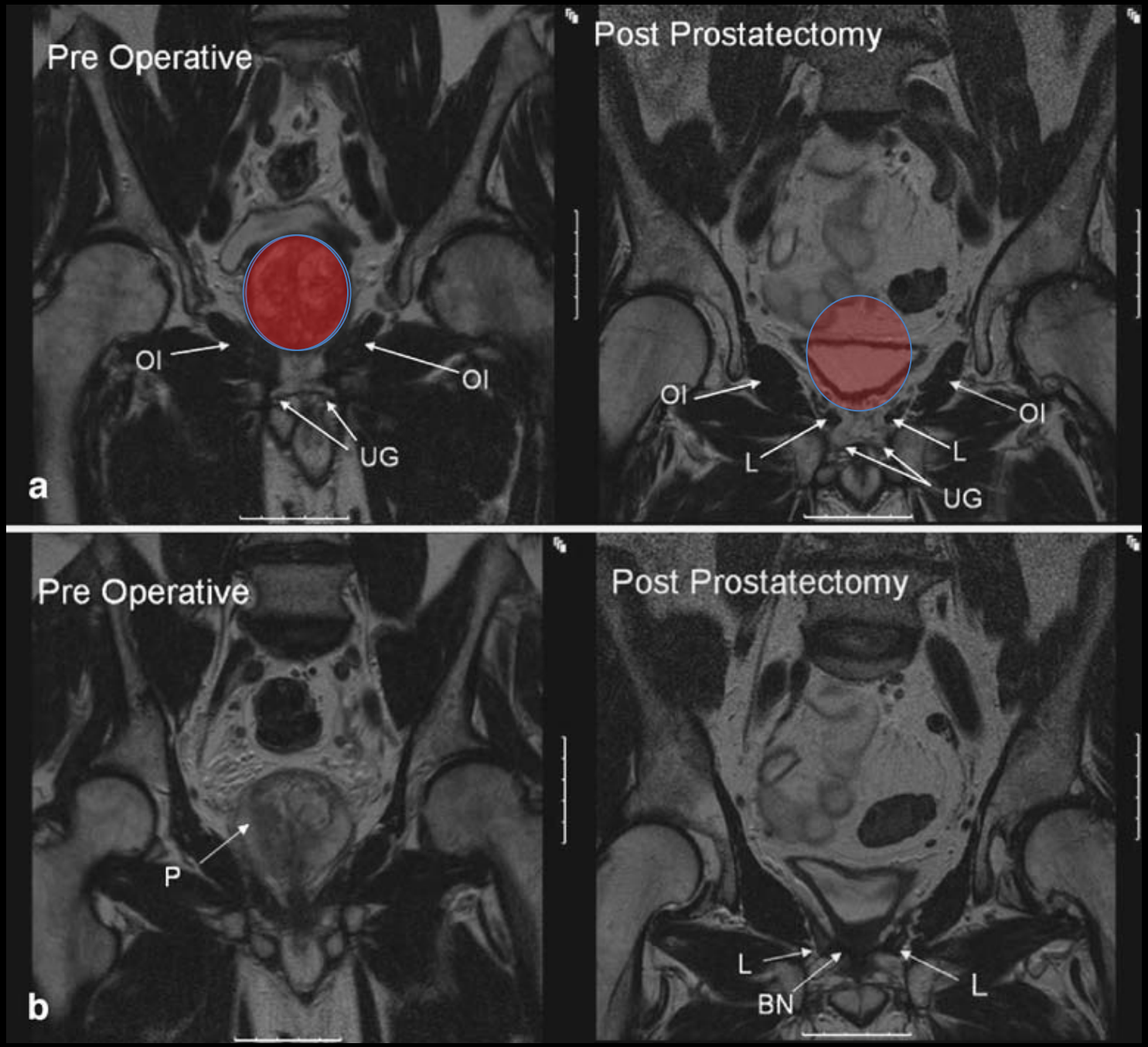
Pre Operative
OI
OI
UG
a
Post Prostatectomy
OI
OI
L
L
UG
Pre Operative
P
b
Post Prostatectomy
L
L
BN

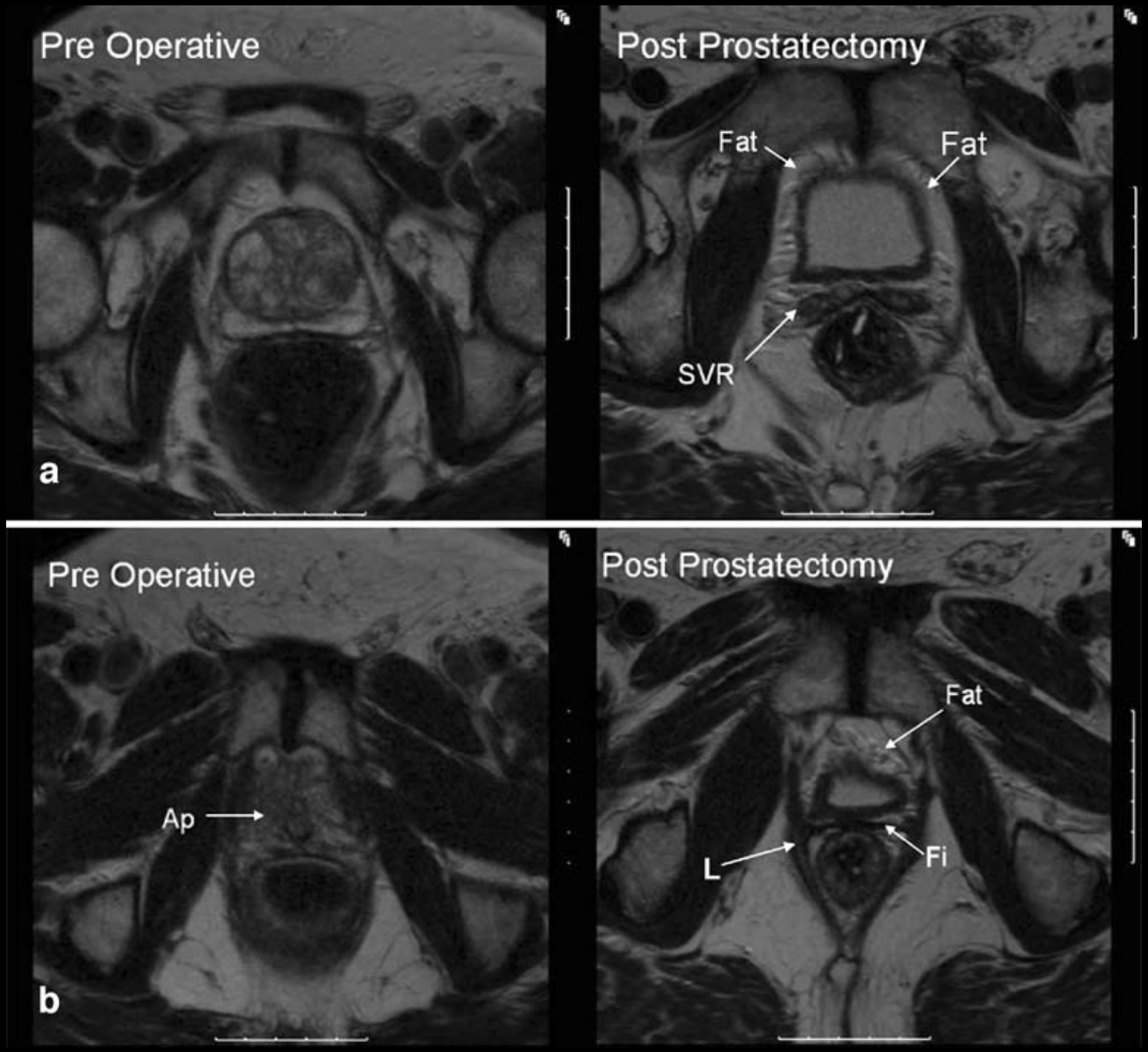
Pre Operative
Post Prostatectomy
Fat
Fat
SVR
a
Pre Operative
Post Prostatectomy
Ap
Fat
L
Fi
b

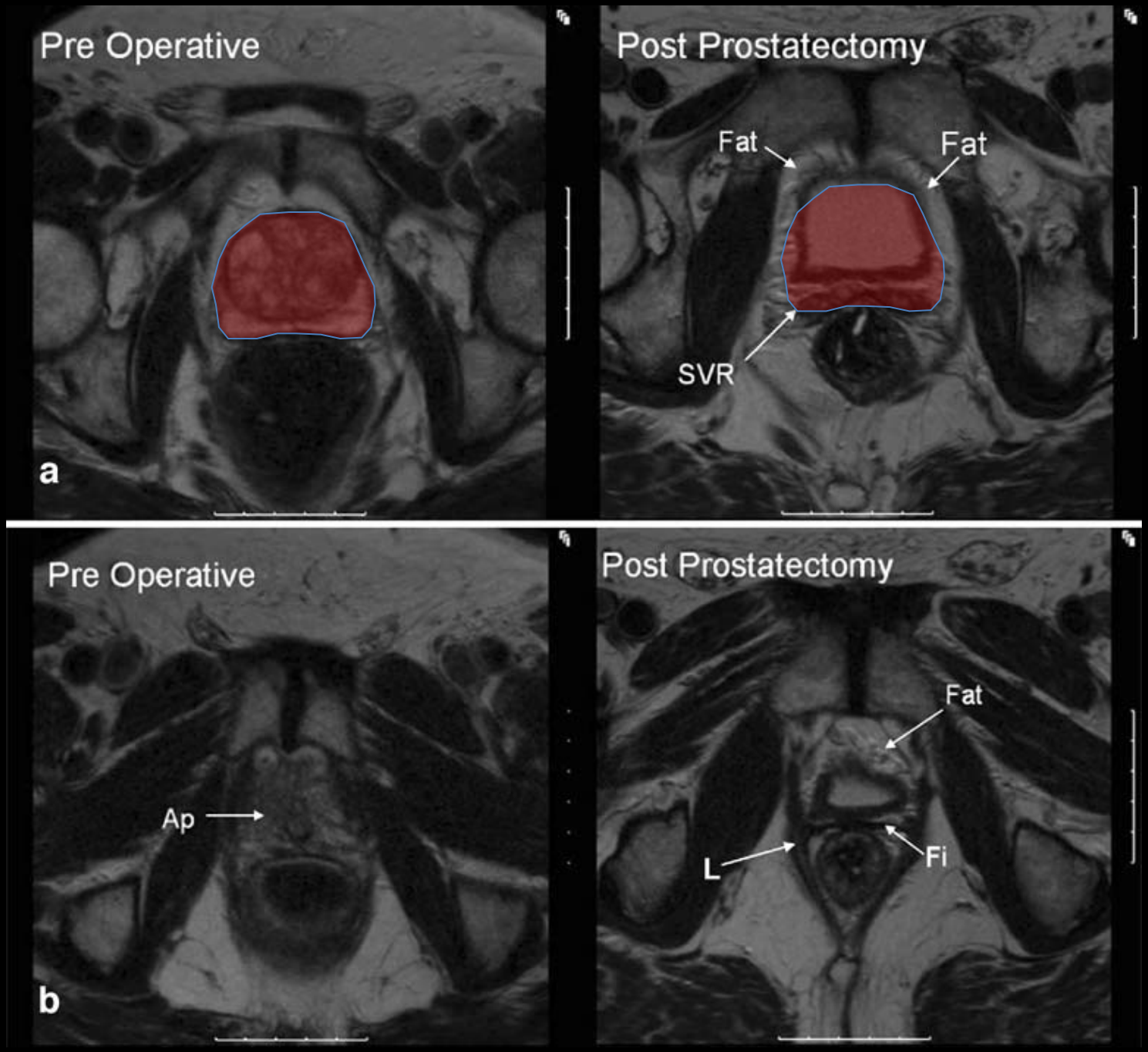
Pre Operative
Post Prostatectomy
Fat
Fat
SVR
a
Pre Operative
Post Prostatectomy
Ap
Fat
L
Fi
b

DEVELOPMENT OF RTOG CONSENSUS GUIDELINES FOR THE DEFINITION OF THE CLINICAL TARGET VOLUME FOR POSTOPERATIVE CONFORMAL RADIATION THERAPY FOR PROSTATE CANCER

JEFF M. MICHALSKI, M.D.,* COLLEEN LAWTON, M.D.,† ISSAM EL NAQA, PH.D.,* MARK RITTER, M.D.,‡ ELIZABETH O'MEARA, C.M.D.,§ MICHAEL J. SEIDER, M.D.,‖ W. ROBERT LEE, M.D.,¶ SETH A. ROSENTHAL, M.D.,** THOMAS PISANSKY, M.D.,†† CHARLES CATTON, M.D.,‡‡ RICHARD K. VALICENTI, M.D.,§§ ANTHONY L. ZIETMAN, M.D.,‖‖ WALTER R. BOSCH, PH.D.,* HOWARD SANDLER, M.D.,¶¶ MARK K. BUYYOUNOUSKI, M.D.,*** AND CYNTHIA MÉNARD, M.D.‡‡

Below the superior edge of the symphysis pubis		Comments
Anterior	Posterior edge of pubic bone	
Posterior	Anterior rectal wall	May need to be concave around lateral aspects
Inferior	8–12 mm below vesicourethral anastomosis	May include more if concern for apical margin. Can extend to slice above penile bulb if vesicourethral anastomosis not well visualized
Lateral	Levator ani muscles, obturator internus	
Above the superior edge of the symphysis pubis		
Anterior	Posterior 1–2 cm of bladder wall	
Posterior	Mesorectal fascia	
Superior	Level of cut end of vas deferens or 3–4 cm above top of symphysis	Vas may retract postoperatively; include seminal vesicle remnants if pathologically involved
Lateral	Sacrorectogenitopubic fascia	If concern about extraprostatic disease at base may extend to obturator internus

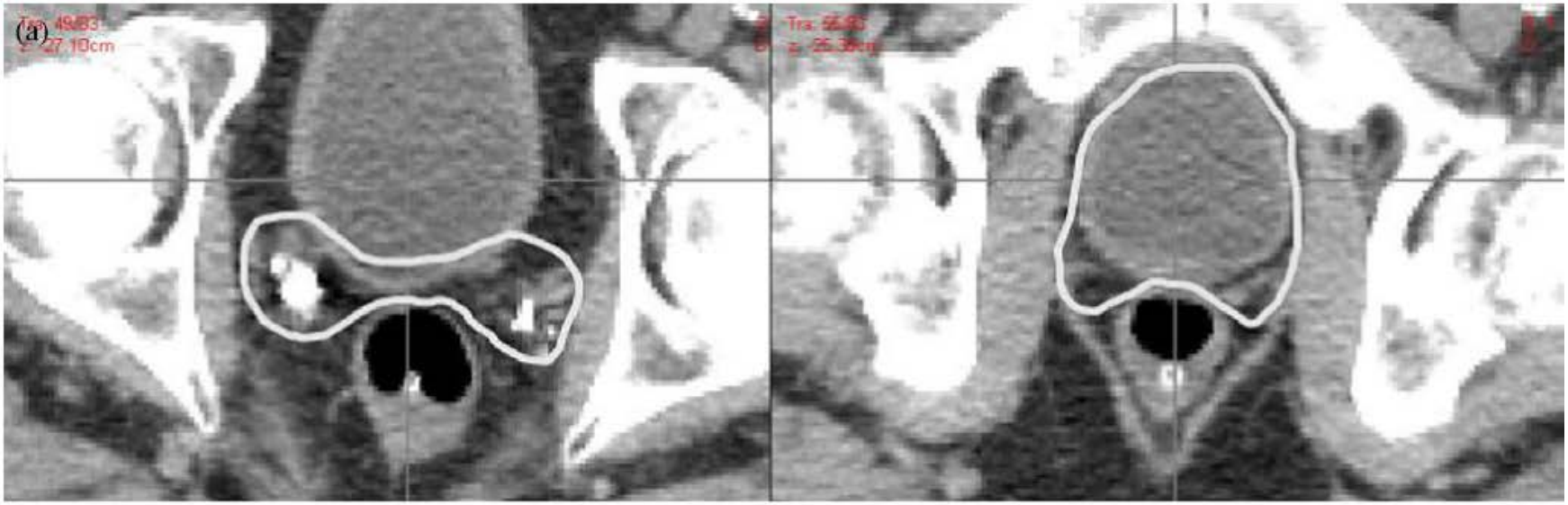

Anatomical borders

NO CTV at this anatomical level!

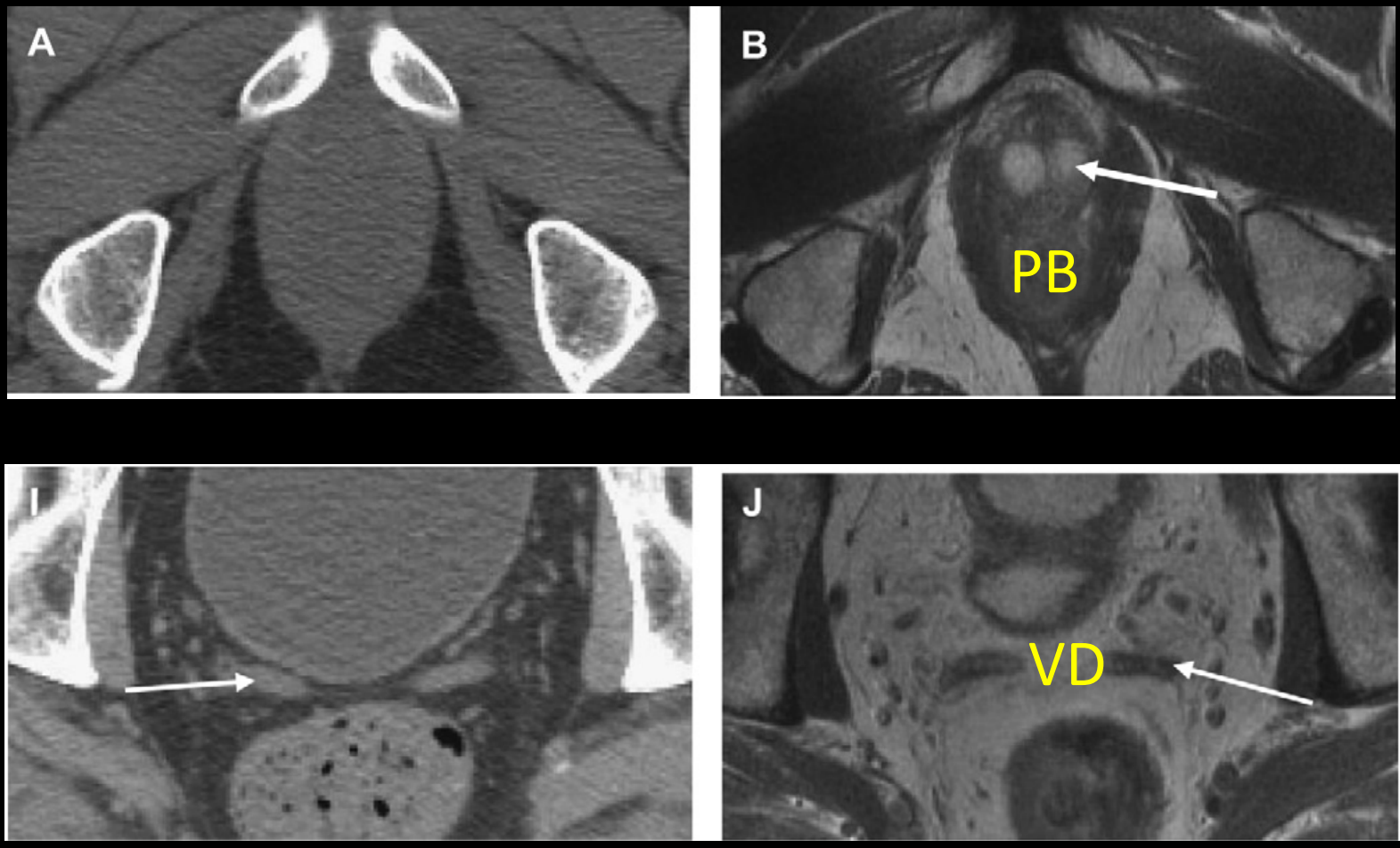

Inferior: 8 mm below VUA

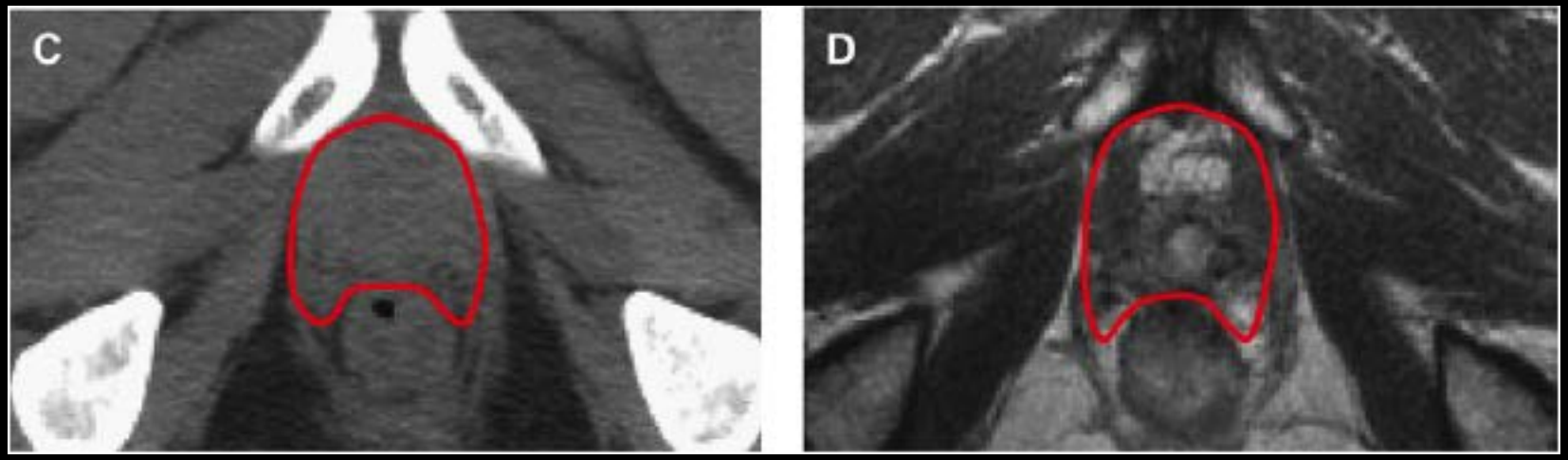

Anterior: pubic symphysis
Lateral: LAM / IOM

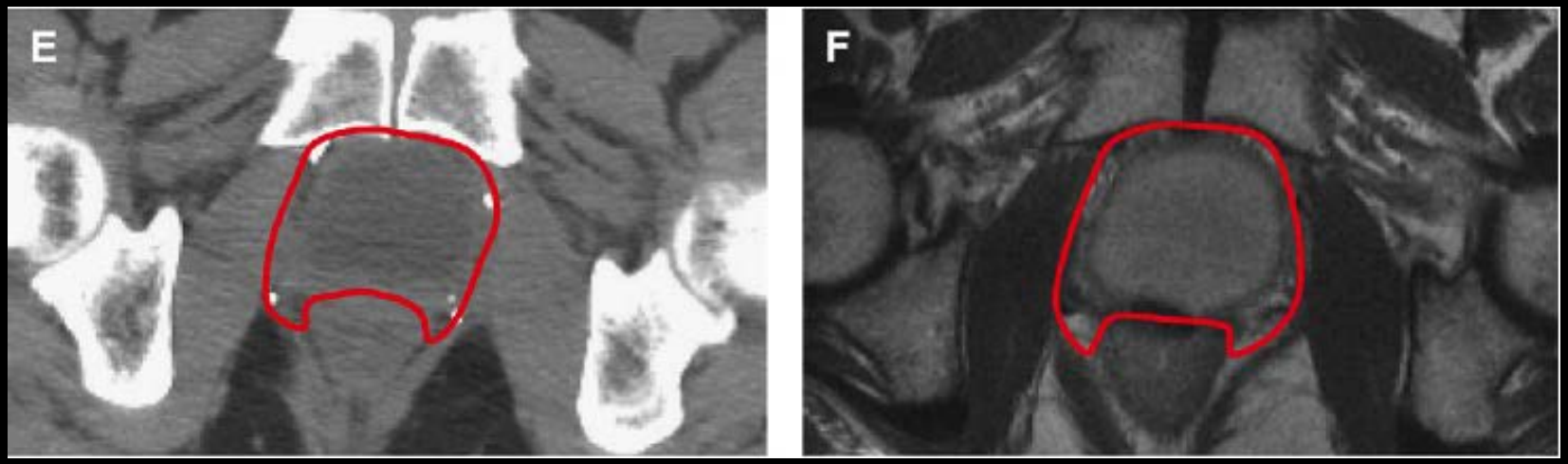

Superior: surgical clips

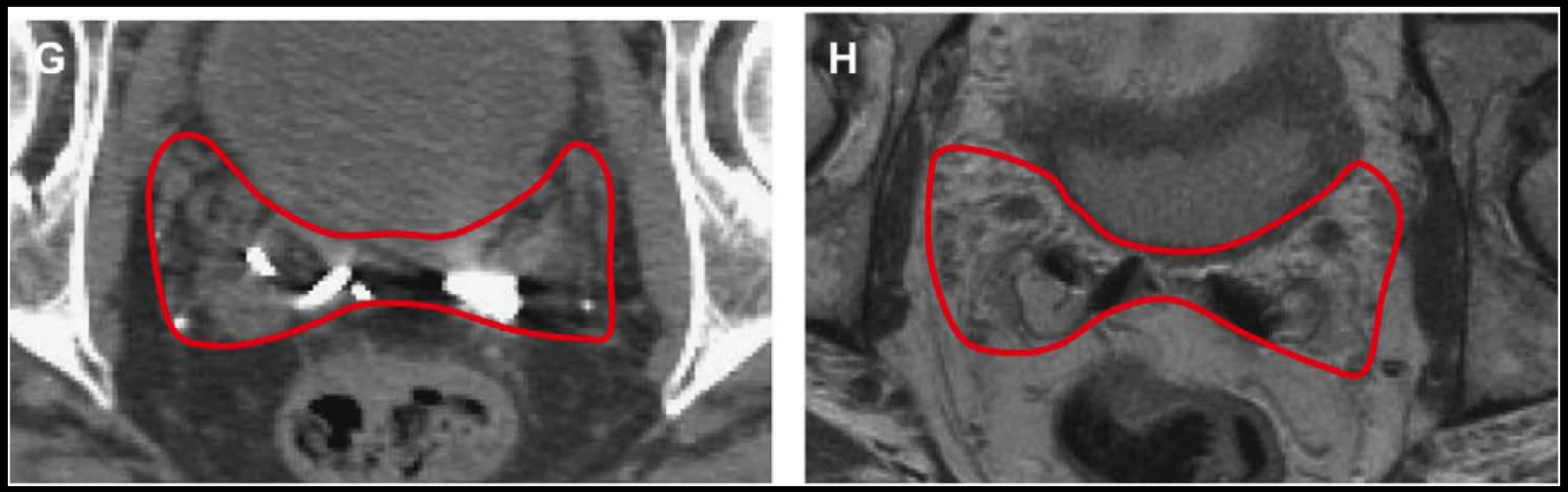

M

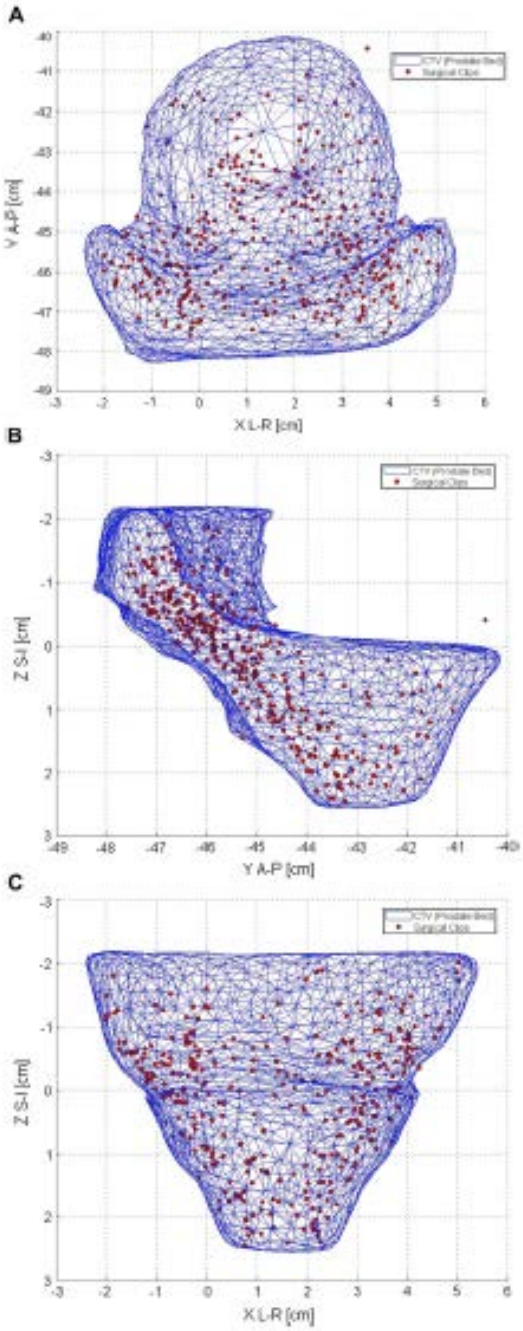
A
CTV (Prostate Bed)
Surgical Clips
Y A-P [cm]
X L-R [cm]
B
CTV (Prostate Bed)
Surgical Clips
Z S-I [cm]
Y A-P [cm]
C
CTV (Prostate Bed)
Surgical Clips
Z S-I [cm]
X L-R [cm]

Radiotherapy and Oncology 84 (2007) 121–127
www.thegreenjournal.com

Prostate radiotherapy - EORTC

Guidelines for target volume definition in post-operative radiotherapy for prostate cancer, on behalf of the EORTC Radiation Oncology Group

Philip Poortmans[a,*], Alberto Bossi[b], Katia Vandeputte[c], Mathieu Bosset[d], Raymond Miralbell[e], Philippe Maingon[f], Dirk Boehmer[g], Tom Budiharto[h], Zvi Symon[i], Alfons C.M. van den Bergh[j], Christopher Scrase[k], Hendrik Van Poppel[l], Michel Bolla[m]

+: Use pathology data

Position	Anatomical border
Centrally	Urethra-vesical anastomosis
Cranially	Bladder neck, up to the base of the seminal vesicles
Posteriorly	Up to but not including the outer rectal wall, cranially including the most posterior part of the bladder
Caudally	Including the apex (15 mm cranially from the penile bulb)
Laterally	Up to the neurovascular bundles (if removed up to the ilio-obturatic muscles)
Anteriorly	Including the anastomosis and the urethral axis

DELINEATION OF THE POSTPROSTATECTOMY PROSTATE BED USING COMPUTED TOMOGRAPHY: INTEROBSERVER VARIABILITY FOLLOWING THE EORTC DELINEATION GUIDELINES

Piet Ost, M.D.,* Gert De Meerleer, M.D., Ph.D.,* Tom Vercauteren, MSc.,* Werner De Gersem, Ir., Ph.D.,* Liv Veldeman, M.D.,* Katrien Vandecasteele, M.D.,* Valérie Fonteyne, M.D., Ph.D.,* and Geert Villeirs, M.D., Ph.D.†

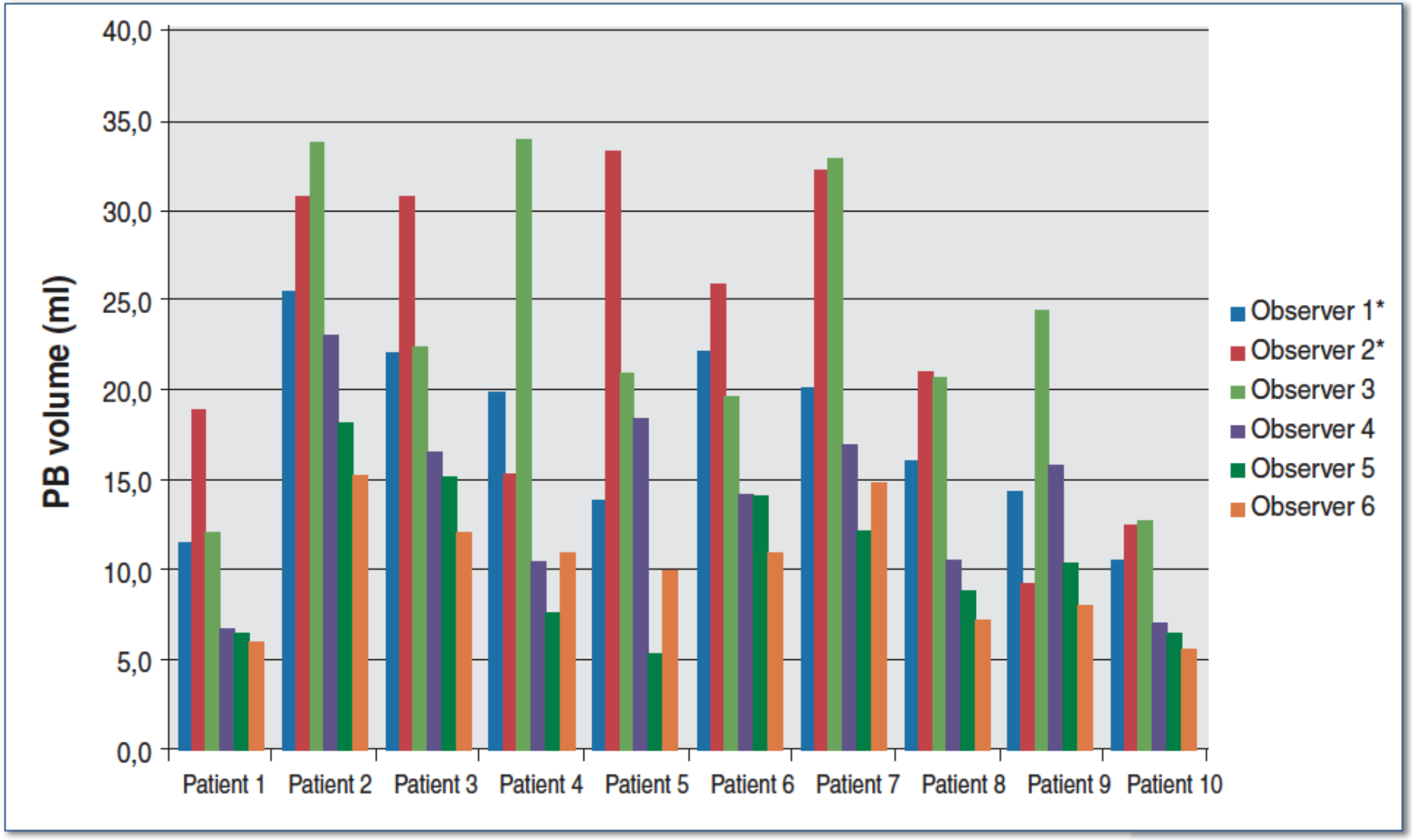

Figure 1A: The volume of the prostate bed (PB) for all patients and observers.

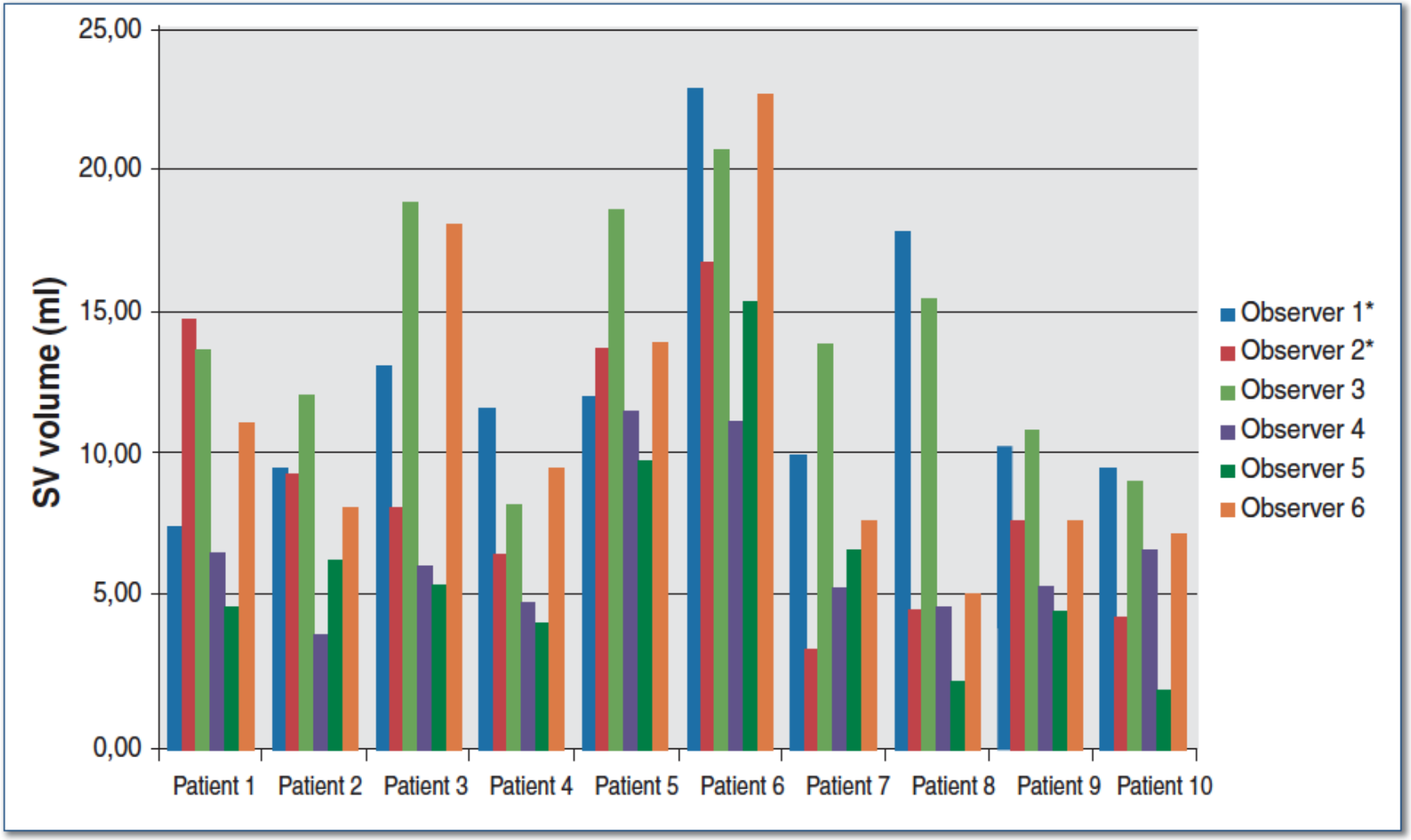

Figure 1B: The volume of the seminal vesicles (SV) for all patients and observers.
*Observer 1 and 2 were less experienced compared to the other observers.

50% confidence level

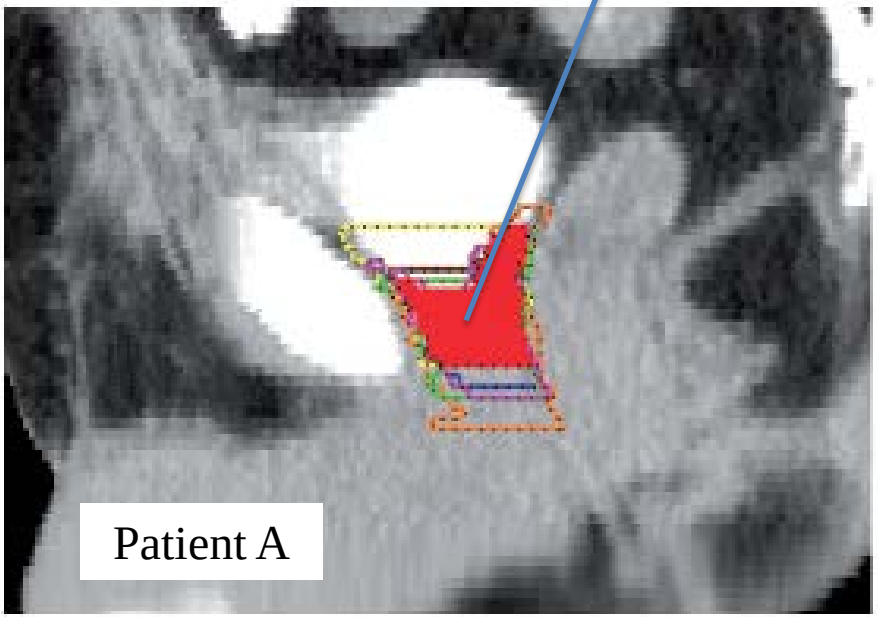

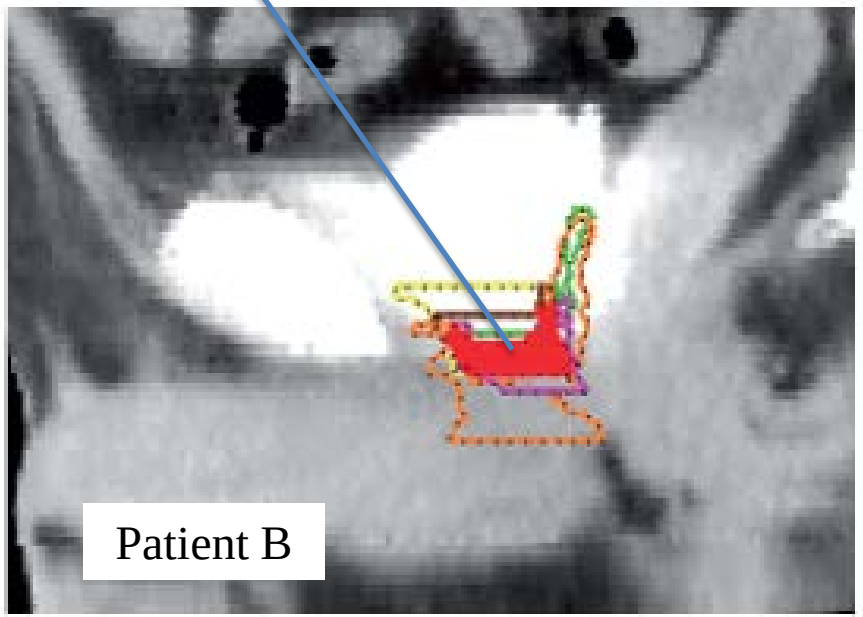

Moderate agreement

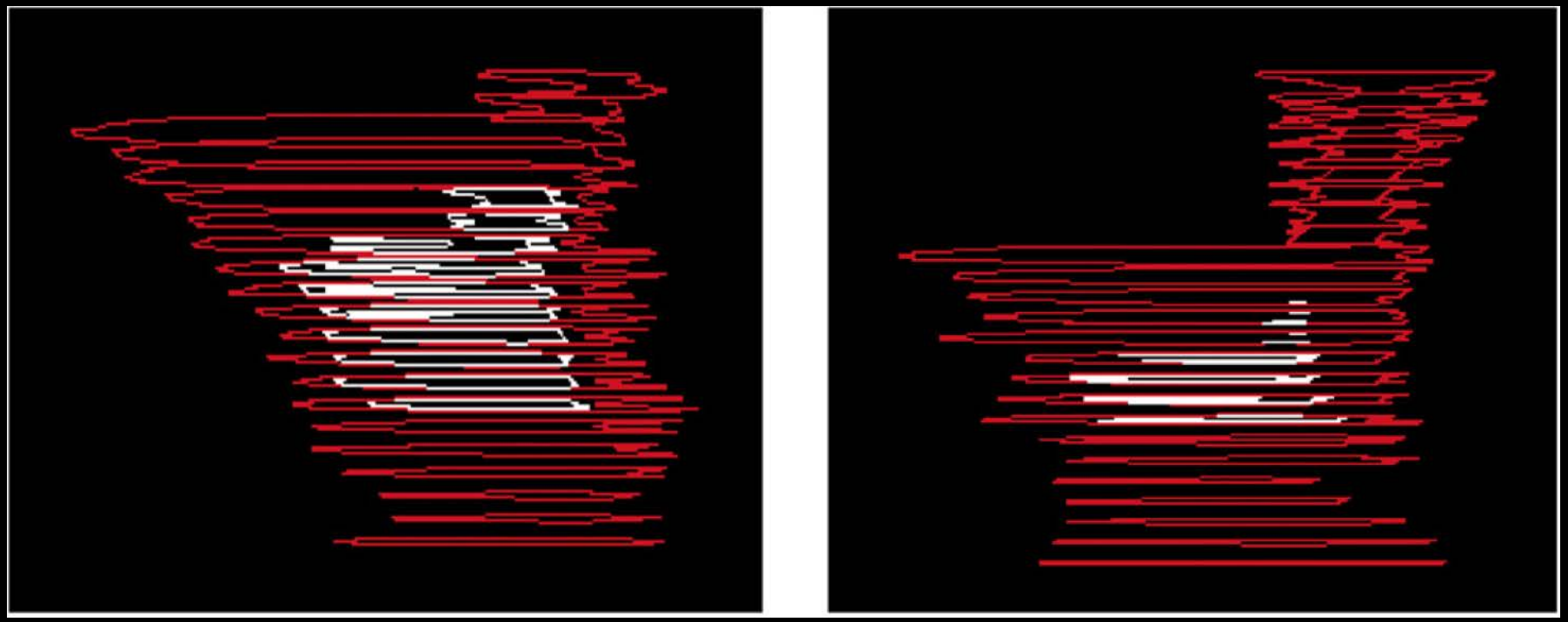

Critical questions	remarks	suggestions ...
1. Inferior: 15 mm?	Too large	use postop MRI
2. Superior: BN?	Too vague	use IV contrast / MRI
3. Anterior: VUA / urethral axis	Too vague	use postop MRI
4. Posterior: ARW	CT?	use postop MRI
5. Lateral: NVB / IOM	CT?	use postop MRO

Table 3. Percentage of treatment errors exceeding various PTV margins

	Interfraction displacements greater than margin (%)						
	PTV margin (mm)						
	3	4	5	6	7	8	10
ART protocol							
Posterior	8	5	3	0.9	0	0	0
Anterior	10	5	3	1	0.8	0.6	0.2
Right	6	3	0.4	0.2	0	0	0
Left	14	7	2	1	0.4	0.2	0
Superior	2	0.6	0.4	0.2	0	0	0
Inferior	3	3	2	1	0.6	0.2	0
Conventional RT							
Posterior	8	5	2	0.4	0.2	0	0
Anterior	33	22	13	9	5	3	1
Right	8	7	6	4	2	2	0.2
Left	27	17	10	5	3	2	0.2
Superior	4	2	1.5	0.4	0	0	0
Inferior	16	7	3	0.6	0.2	0	0

Take home messages

1. Use IV contrast and postoperative MRI if possible

2. Treat always remnants of the SV

3. Include surgical clips

4. Use pathology report

5. Use margins for PTV >5 mm. @ GUH: 7mm

Eur Radiol (2008) 18: 1281–1291
DOI 10.1007/s00330-008-0867-3

UROGENITAL

Steven D. Allen
Alan Thompson
S. Aslam Sohaib

The normal post-surgical anatomy of the male pelvis following radical prostatectomy as assessed by magnetic resonance imaging

Your course venue ...